Third Edition

OPERATIVE OTOLARYNGOLOGY

HEAD AND NECK SURGERY

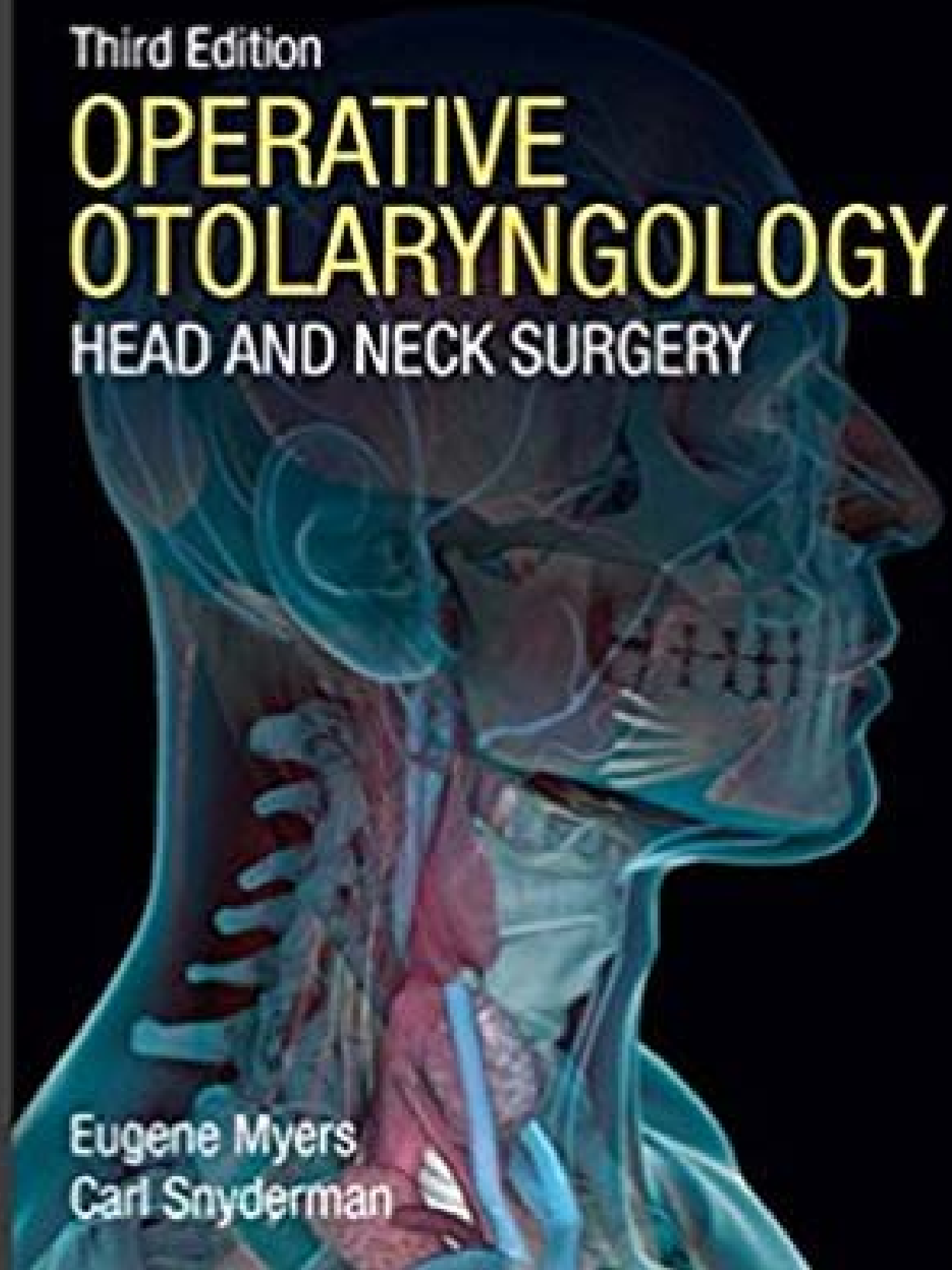

Eugene Myers
Carl Snyderman

ELSEVIER

Volume 1

Operative Otolaryngology-Head and Neck Surgery

THIRD EDITION

EDITORS

EUGENE N. MYERS, MD, FACS, FRCS EDIN (HON)
Distinguished Professor and Emeritus Chair
Department of Otolaryngology
University of Pittsburgh School of Medicine
Professor
Department of Oral and Maxillofacial Surgery
University of Pittsburgh School of Dental Medicine
Pittsburgh, Pennsylvania

CARL H. SNYDERMAN, MD, MBA, FACS
Professor
Department of Otolaryngology and Neurological Surgery
University of Pittsburgh School of Medicine
Co-Director
Center for Cranial Base Surgery
University of Pittsburgh Medical Center
Pittsburgh, Pennsylvania

SECTION EDITORS
Elizabeth A. Blair, MD
Jeffrey Bumpous, MD
Ricardo L. Carrau, MD
Sukgi Choi, MD
Frederic W.B. Deleyannis, MD
Johan Fagan, MD
Berrylin Ferguson, MD
Sheng-Po Hao, MD
Barry E. Hirsch, MD
Jonas T. Johnson, MD
Stella Lee, MD
Bert O'Malley, Jr., MD
Anna M. Pou, MD
Christopher H. Rassekh, MD
Clark A. Rosen, MD
Barry M. Schaitkin, MD
Alfred A. Simental, Jr., MD
Carl H. Snyderman, MD
Ryan Soose, MD
Tonya Stefko, MD
Rohan R. Walvekar, MD
Eric W. Wang, MD

ELSEVIER

Volume 2

Operative Otolaryngology-Head and Neck Surgery

THIRD EDITION

EDITORS

EUGENE N. MYERS, MD, FACS, FRCS EDIN (HON)
Distinguished Professor and Emeritus Chair
Department of Otolaryngology
University of Pittsburgh School of Medicine
Professor
Department of Oral and Maxillofacial Surgery
University of Pittsburgh School of Dental Medicine
Pittsburgh, Pennsylvania

CARL H. SNYDERMAN, MD, MBA, FACS
Professor
Department of Otolaryngology and Neurological Surgery
University of Pittsburgh School of Medicine
Co-Director
Center for Cranial Base Surgery
University of Pittsburgh Medical Center
Pittsburgh, Pennsylvania

SECTION EDITORS
Elizabeth A. Blair, MD
Jeffrey Bumpous, MD
Ricardo L. Carrau, MD
Sukgi Choi, MD
Frederic W.B. Deleyannis, MD
Johan Fagan, MD
Berrylin Ferguson, MD
Sheng-Po Hao, MD
Barry E. Hirsch, MD
Jonas T. Johnson, MD
Stella Lee, MD
Bert O'Malley, Jr., MD
Anna M. Pou, MD
Christopher H. Rassekh, MD
Clark A. Rosen, MD
Barry M. Schaitkin, MD
Alfred A. Simental, Jr., MD
Carl H. Snyderman, MD
Ryan Soose, MD
Tonya Stefko, MD
Rohan R. Walvekar, MD
Eric W. Wang, MD

ELSEVIER

Contributors

Julie P. Adelman, MD
Department of Otolaryngology
University of Pittsburgh
Pennsylvania
Chapter 143

William G. Albergotti, MD
Resident
Otolaryngology
University of Pittsburgh
Medical Center
Pittsburgh, Pennsylvania
Chapters 23, 112

Brendan Alleyne, MD
Resident
Department of Plastic Surgery
Cleveland Clinic Foundation
Cleveland, Ohio
Chapter 174

Cuneyt M. Alper, MD
Professor
Otolaryngology
University of Pittsburgh School of
Medicine
Pittsburgh, Pennsylvania;
Professor
Clinical and Translational Research
Institute
Pittsburgh, Pennsylvania
Chapter 203

Samantha Anne, MD, MS
Assistant Professor of Surgery
Medical Director
Pediatric Ear & Hearing Disorders
Pediatric Otolaryngology
Head & Neck Institute
Cleveland Clinic
Cleveland, Ohio
Chapter 200

Stephanie Moody Antonio, MD, FACS
Associate Professor
Department of Otolaryngology
Eastern Virginia Medical School
Norfolk, Virginia
Chapter 141

Moises A. Arriaga, MD, MBA
Clinical Professor and Director of
Otology and Neurotology
Otolaryngology and Neurosurgery
Louisiana State University Health
Sciences Center
New Orleans, Louisiana;
Medical Director
LSU-Our Lady of the Lake Hearing and
Balance Center
Our Lady of the Lake Regional Medical
Center
Baton Rouge, Louisiana
Chapter 140

Canset Aydin, MD
Otolaryngology Head and Neck
Surgery Specialist
Otolaryngology
Head and Neck Surgery
Liv Hospital
Ankara, Turkey
Chapters 33, 101

Roya Azadarmaki, MD
Division of Otology-Neurotology
Metropolitan NeuroEar Group
Rockville, Maryland
Chapter 129

Christopher Azbell, MD
Resident
Department of Otolaryngology
University of Louisville
Louisville, Kentucky
Chapter 86

Christie Barnes, MS, MD
Assistant Professor
Otolaryngology
Head and Neck Surgery
University of Nebraska Medical Center
Omaha, Nebraska
Chapter 97

Rachel Barry, MD
Resident
Department of Otolaryngology
Louisiana State University Health
Sciences Center
New Orleans, Louisiana
Chapter 89

Richard Bauer, III, DMD, MD
Assistant Professor
Oral and Maxillofacial Surgery
University of Pittsburgh School of
Dental Medicine
Pittsburgh, Pennsylvania;
Staff Surgeon
Oral and Maxillofacial Surgery
University of Pittsburgh Medical Center
Pittsburgh, Pennsylvania
Chapters 58, 59

Nadim Bikhazi, MD
Otolaryngology
Ogden Clinic
Ogden, Utah
Chapter 102

Elizabeth A. Blair, MD
Professor
Surgery
Section Otolaryngology
Head and Neck Surgery
University of Chicago
Chicago, Illinois
Chapter 31

Charles D. Bluestone, MD
Distinguished Emeritus Professor of
Otolaryngology
University of Pittsburgh School of
Medicine
Pittsburgh, Pennsylvania;
Former Director
Pediatric Otolaryngology
Children's Hospital of Pittsburgh of
UPMC
Pittsburgh, Pennsylvania

Arturo Bonilla, MD
Founder and Director
Microtia Congenital Ear Deformity
Institute
San Antonio, Texas
Chapter 207

Brian J. Boyce, MD
Assistant Professor
Otolaryngology
Head and Neck Surgery
University of Florida
Gainesville, Florida
Chapters 63, 74

Margherita Bruni, MD
Otolaryngology Attending
Department of Otolaryngology
Northshore University Hospital
Manhasset, New York
Chapters 167, 168

Craig A. Buchman, MD
Lindburg Professor and Chair
Otolaryngology
Head and Neck Surgery
Washington University in St. Louis
St. Louis, Missouri
Chapter 137

Jeffrey Bumpous, MD
J. Samuel Bumgardner Professor and Chairman
Otolaryngology
Head and Neck Surgery, and Communicative Disorders
University of Louisville
Louisville, Kentucky
Chapters 27, 83, 86

Anna M. Butrymowicz, MD
Attending Physician
Division of Otolaryngology
Jacobi Medical Center
Bronx, New York
Chapter 65

J. Kenneth Byrd, MD
Assistant Professor
Otolaryngology
Medical College of Georgia
Augusta, Georgia
Chapters 15, 117

Thomas L. Carroll, MD
Instructor
Otolaryngology
Harvard University School of Medicine
Director
Brigham and Women's Voice Program
Surgery
Division of Otolaryngology
Brigham and Women's Hospital
Boston, Massachusetts;
Boston, Massachusetts
Chapter 3

Ricardo L. Carrau, MD
Professor
Department of Otolaryngology
Head and Neck Surgery
The Ohio State University
Columbus, Ohio;
Professor
Department of Neurological Surgery
The Ohio State University
Columbus, Ohio
Chapters 6, 10, 46, 116, 119

Nathan Cass, MD
Resident Physician
Department of Otolaryngology
University of Colorado
Aurora, Colorado
Chapter 165

Stephen P. Cass, MD
Professor
Department of Otolaryngology
University of Colorado
Aurora, Colorado
Chapter 148

Raymond Chai, MD
Assistant Professor
Department of Otolaryngology
Icahn School of Medicine at Mount Sinai
New York
Chapters 36, 45

Michael D. Chambers, DMD, MD
Resident
Oral and Maxillofacial Surgery
University of Pittsburgh Medical Center
Pittsburgh, Pennsylvania
Chapters 13, 105

C.Y. Joseph Chang, MD
Director
Texas Ear Center
Texas Ear, Nose, and Throat Specialists
Houston, Texas;
Clinical Professor
Department of Otolaryngology–Head and Neck Surgery
University of Texas–Houston Medical School
Houston, Texas
Chapters 142, 145, 148

Douglas A. Chen, MD
Pittsburgh Ear Associates
Pittsburgh, Pennsylvania;
Director
Division of Neurotology
Department of Neurosurgery
Allegheny General Hospital
Pittsburgh, Pennsylvania
Chapter 131

David H. Chi, MD
Associate Professor
Otolaryngology
University of Pittsburgh School of Medicine
Children's Hospital of Pittsburgh
Pittsburgh, Pennsylvania
Chapters 204, 205

Rebecca Chiffer, MD
Fellow
Pittsburgh Ear Associates
Pittsburgh, Pennsylvania
Chapter 131

Christopher J. Chin, MD, FRCSC
Clinical Fellow
Otolaryngology
Head and Neck Surgery
University of Toronto
Toronto, Ontario, Canada
Chapter 116

Robert J. Chiu, MD
Facial Plastic Surgeon
Private Practice
Pittsburgh, Pennsylvania
Chapter 193

Garret Choby, MD
Resident
Department of Otolaryngology
University of Pittsburgh Medical Center
Pittsburgh, Pennsylvania
Chapters 39, 108

Sukgi Choi, MD
Professor
Otolaryngology
University of Pittsburgh School of Medicine
Pittsburgh, Pennsylvania;
Chief and Eberly Chair
Pediatric Otolaryngology
Children's Hospital of Pittsburgh of UPMC
Pittsburgh, Pennsylvania
Chapters 193, 194, 195, 198

Courtney T. Chou, MD
Resident Physician
Otolaryngology
University of Pittsburgh Medical Center
Pittsburgh, Pennsylvania
Chapter 180

Neil A. Christie, MD
Assistant Professor
Thoracic Surgery
University of Pittsburgh School of Medicine
Pittsburgh, Pennsylvania
Chapters 18, 22

Apostolos Christopoulos, MD, MSc, FRCSC
Dr Azar-Angélil Chair in Head and Neck Oncology
Associate Professor Division of Otorhinolaryngology - Head and Neck
Chapter 50

William Chung, DDS, MD
Professor
Department of Oral and Maxillofacial Surgery
University of Pittsburgh School of Dental Medicine
Pittsburgh, Pennsylvania
Chapters 13, 105, 121, 185

David M. Cognetti, MD, FACS
Associate Professor
Department of Otolaryngology
Head and Neck Surgery
Sidney Kimmel Cancer Center at Thomas Jefferson University
Philadelphia, Pennsylvania
Chapters 37, 63, 74, 75

Michael S. Cohen, MD
Instructor
Department of Otolaryngology
Harvard Medical School
Boston, Massachusetts;
Division of Pediatric Otolaryngology
Massachusetts Eye and Ear Infirmary
Boston, Massachusetts
Chapter 205

Patrick Colley, MD
Assistant Professor
Department of Otolaryngology
New York Eye and Ear Infirmary of Mount Sinai
The Mount Sinai Hospital
Mount Sinai Beth Israel, New York
Chapter 124

Peter D. Costantino, MD
Professor & Chair
Department Of Otolaryngology-Head & Neck Surgery, and Oral & Maxillofacial Surgery;
Professor of Neurosurgery
Hofstra-Northwell School of Medicine
Lenox Hill Hospital & Manhattan Eye Ear, & Throat Hospital;
Professor of Patient Oriented Research
The Feinstein Research Institute;
Senior Vice-President & Executive Director
The New York Head & Neck Institute
Otolaryngology-Head & Neck Surgery Service Line
Northwell Health, New York
Chapters 167, 168

Bernard J. Costello, DMD, MD, FACS
Professor and Fellowship Program Director
Department of Oral and Maxillofacial Surgery
Associate Dean for Faculty Affairs
University of Pittsburgh
School of Dental Medicine
Pittsburgh, Pennsylvania;
Chief
Pediatric Oral and Maxillofacial Surgery
Children's Hospital of Pittsburgh
Professor and Fellowship Program Director Department of Oral and Maxillofacial Surgery
University of Pittsburgh Medical Center Eye and Ear Institute
Pittsburgh, Pennsylvania
Chapters 186, 206

Michael Cunningham, MD
Professor
Department of Otology and Laryngology
Harvard Medical School
Otolaryngologist-in-Chief
Department of Otolaryngology and Communication Enhancement
Boston Children's Hospital
Chapter 201

John R. DeAlmeida, MD, MSc
Head and Neck Surgeon
Otolaryngology
Head and Neck Surgery
Princess Margaret Cancer Centre
Toronto, Ontario, Canada
Chapter 114

Kavita Dedhia, MD
Assistant Professor
Otolaryngology
Head and Neck Surgery
Emory University
Atlanta, Georgia
Chapter 130

Raj C. Dedhia, MD, MS
Assistant Professor
Otolaryngology and Sleep Medicine
Emory University
Atlanta, Georgia
Chapters 52, 54, 59

Amir R. Dehdashti, MD FACS
Director Cerebrovascular Neurosurgery Research
Neurosurgery
Northshore University Hospital
Manhasset, New York
Chapters 167, 168

Timothy DeKlotz, MD
Assistant Professor
Otolaryngology
Head and Neck Surgery
Medstar Georgetown University Hospital
Washington, DC
Chapter 150

Frederic W.B. Deleyiannis, MD, MPhil, MPH
Professor
Division of Plastic Surgery
Departments of Surgery and Otolaryngology
University of Colorado
Aurora, Colorado
Chapters 162, 163, 165

Craig Derkay, MD
Professor and Vice-Chairman
Otolaryngology
Head and Neck Surgery
Eastern Virginia Medical School
Norfolk, Virginia;
Director
Pediatric Otolaryngology
Children's Hospital of the King's Daughters
Norfolk, Virginia
Chapter 196

Matilda Dhima, DMD, MS
Maxillofacial Prosthodontist
Department of Prosthodontics
University of Pittsburgh
School of Dental Medicine;
Pittsburgh, Pennsylvania
Chapter 188

Joseph E. Dohar, MD, MS
Professor
Otolaryngology
University of Pittsburgh School of Medicine
Pittsburgh, Pennsylvania;
Professor
Communication Science and Disorders
University of Pittsburgh School of Health and Rehabilitation Sciences
Pittsburgh, Pennsylvania
Chapter 192

Stephanie E. Dreifuss, MD
Plastic Surgery Resident
Department of Plastic Surgery
University of Pittsburgh Medical Center
Pittsburgh, Pennsylvania
Chapter 164

Umamaheswar Duvvuri, MD, PhD
Assistant Professor
Department of Otolaryngology
University of Pittsburgh School of Medicine
Eye and Ear Institute
Pittsburgh, Pennsylvania
Chapters 15, 55, 61, 80

David E. Eibling, MD, FACS
Professor
Department of Otolaryngology
University of Pittsburgh School of Medicine
Pittsburgh, Pennsylvania;
Assistant Chief of Surgery
Surgical Service
VA Pittsburgh Healthcare System
Pittsburgh, Pennsylvania
Chapters 13, 19, 21

Donovan Eu, MBBS, MRCS, MMed
Dr, Otolaryngology
Head and Neck Surgery
National University Hospital Singapore
Singapore, Singapore
Chapter 31

Johan Fagan, MBChB, MMed, FCS (ORL)
Professor and Chairman
Department of Otorhinolaryngology
University of Cape Town
Cape Town, South Africa
Chapters 11, 29, 72

Berrylin J. Ferguson†, MD, FACS
Professor
Department of Otolaryngology
University of Pittsburgh School of Medicine
Pittsburgh, Pennsylvania
Chapters 94, 100

†Deceased

Robert L. Ferris, MD, PhD
UPMC Endowed Professor and Vice-Chair
Director
Hillman Cancer Center
Chief
Division of Head and Neck Surgery
Associate Director for Translational Research Co-Leader
Cancer Immunology Program Co-Director
Tumor Microenvironment Center
University of Pittsburgh Cancer Institute
Pittsburgh, Pennsylvania
Chapters 62, 79

Pedro Andrade Filho, MD
Assistant Professor
Otolaryngology
Loma Linda University
Loma Linda, California
Chapter 85

Rebecca E. Fraioli
Assistant Professor
Department of Otolaryngology - Head and Neck Surgery
Albert Einstein College of Medicine
Bronx, New York;
Attending Physician
Montefiore Medical Center
Bronx, New York
Chapters 48, 91, 159

Roxana Fu, MD
Oculoplastics Fellow
Ophthalmology
University of Louisville
Louisville, Kentucky
Chapter 153

Lisa Galati, MD
Associate Professor
Otolaryngology
Albany Medical Center
Albany, New York
Chapters 76, 92, 183

Paul A. Gardner, MD
Associate Professor of Neurological Surgery
University of Pittsburgh School of Medicine
Co-Director
Center for Cranial Base Surgery
University of Pittsburgh Medical Center
Pittsburgh, Pennsylvania
Chapters 122, 123, 177

Catharine B. Garland, MD
Fellow in Craniofacial Surgery
Plastic Surgery
Children's Hospital of Pittsburgh of UPMC
Pittsburgh, Pennsylvania
Chapters 175, 176

Brian Gastman, MD
Director of the CCF Melanoma Program
Associate Professor of Surgery
Cleveland Clinic Lerner College of Medicine
Staff
CCF
Dermatology and Plastic Surgery Institute
Department of Plastic Surgery
Dual appointments in: Taussig Cancer Center
Lerner Research Institute
Department of Immunology
Head and Neck Institute
Cleveland Clinic Foundation
Cleveland, Ohio
Chapter 174

Mathew Geltzeiler, MD
Otolaryngology
Fellow in Head and Neck Surgery
University of Pittsburgh Medical Center
Pittsburgh, Pennsylvania
Chapter 62

Grant S. Gillman, MD, FRCS(C)
Associate Professor
Otolaryngology
University of Pittsburgh School of Medicine
Pittsburgh
Pennsylvania
Chapters 95, 156

Morgan R. Godin, MD
Resident
Ophthalmology
Duke University
Durham, North Carolina
Chapter 179

Andrew N. Goldberg, MD, MSCE, FACS
Professor;
Director
Division of Rhinology and Sinus Surgery
Department of Otolaryngology
Head and Neck Surgery
University of California
San Francisco, San Francisco, California
Chapter 102

Richard A. Goldman, MD
Assistant Professor
Department of Otolaryngology, Head and Neck Surgery
Sidney Kimmel Cancer Center at Thomas Jefferson University
Philadelphia, Pennsylvania
Chapter 75

Jesse Goldstein, MD
Assistant Professor
Department of Plastic Surgery
University of Pittsburgh School of Medicine
Children's Hospital of Pittsburgh
Pittsburgh, Pennsylvania
Chapters 175, 176, 202

Amit Goyal, MD
Resident Physician
Department of Neurosurgery
University of Minnesota
Minneapolis, Minnesota
Chapter 115

Emiro Caicedo Granados, MD, MS, FACS
Assistant Professor
Otolaryngology Head and Neck Surgery
University of Minnesota
Minneapolis, Minnesota
Chapter 115

Trevor Hackman, MD, FACS
Associate Professor
Otolaryngology
Head and Neck Surgery
University of North Carolina
Chapel Hill, North Carolina
Chapters 47, 87, 171, 172

Steven Hamilton, MD
Assistant Professor
Otolaryngology
University of Colorado School of Medicine
Colorado Springs, Colorado;
Assistant Professor
Pediatric Otolaryngology
Children's Hospital Colorado
Colorado Springs, Colorado
Chapter 201

Ehab Hanna, MD
Professor and Director of Skull Base Surgery
Vice Chairman
Department of Head and Neck Surgery
University of Texas MD Anderson Cancer Center
Houston, Texas
Chapter 106

Sheng-Po Hao, MD
Professor and Chairman
Department of Otolaryngology
Head and Neck Surgery
Shin Kong Wu Ho-Su Memorial Hospital
Taipei, Taiwan;
Director
Comprehensive Oral Cancer Center
Shin Kong Wu Ho-Su Memorial Hospital
Taipei, Taiwan
Chapters 41, 43

Michele Hargreaves, MD, MBA
ENT Specialists of North Florida
Jacksonville, Florida
Chapter 127

Bridget C. Hathaway, MD
Assistant Professor
Otolaryngology
University of Pittsburgh School of Medicine
Pittsburgh, Pennsylvania
Chapter 46

Kyle Hatten, MD
Otorhinolaryngology
Head and Neck Surgery
Hospital of the University of Pennsylvania
Philadelphia, Pennsylvania
Chapter 70

Laura Hetzler, MD, FACS
Assistant Professor and Program Director
Otolaryngology
Head and Neck Surgery
Louisiana State University Health Sciences Center
New Orleans, Louisiana
Chapter 178

Douglas M. Hildrew, MD
Assistant Professor
Surgery-Otolaryngology
Yale School of Medicine
New Haven, Connecticut
Chapters 126, 132, 135

Barry E. Hirsch, MD
Professor of Otolaryngology
University of Pittsburgh School of Medicine
Pittsburgh, Pennsylvania
Chapters 126, 132

Benjamin L. Hodnett, MD, PhD
Fellow
Otorhinolaryngology
Head and Neck Surgery
University of Pennsylvania
Philadelphia, Pennsylvania
Chapter 17

Sefik A. Hosal, MD
Professor
Otolaryngology
Head and Neck Surgery
Liv Hospital
Ankara, Turkey
Chapters 33, 101

Jeffrey Hotaling, MD
Clinical Instructor
Otolaryngology
Head and Neck Surgery
Thomas Jefferson University
Philadelphia, Pennsylvania
Chapter 37

Brittany Howard, MD
Department of Otolaryngology
Head and Neck Surgery
Mayo Clinic Arizona
Phoenix, Arizona;
Head and Neck Oncology and Microvascular Fellowship
Department of Otolaryngology
Head and Neck Surgery
University of North Carolina
Chapel Hill, North Carolina
Chapters 171, 172

Phillip Huyett, MD
Resident Physician
Department of Otolaryngology
University of Pittsburgh Medical Center
Pittsburgh, Pennsylvania
Chapters 26, 90, 111, 192

Andrew F. Inglis, Jr., MD
Associate Professor
Otolaryngology
Head and Neck Surgery
University of Washington
Seattle, Washington
Chapter 200

Noel Jabbour, MD
Assistant Professor
Otolaryngology
University of Pittsburgh School of Medicine
Pittsburgh, Pennsylvania;
Associate Director
Fellowship Program
Pediatric Otolaryngology
Children's Hospital of Pittsburgh of UPMC
Pittsburgh, Pennsylvania
Chapters 202, 206, 207, 209

Neal M. Jackson, MD
Department of Otolaryngology- Head and Neck Surgery
Louisiana State University
Health Sciences Center
New Orleans,
Lousiana
Chapter 121

David Jang, MD
Assistant Professor
Head and Neck Surgery and Communication Sciences
Duke University
Durham, North Carolina
Chapter 120

David M. Johnson, MD
Department of Otolaryngology
University of Pittsburgh Medical Center
Pittsburgh, Pennsylvania
Chapter 19

Jonas T. Johnson, MD
Chairman
Department of Otolaryngology
Eye and Ear Institute
Pittsburgh, Pennsylvania
Chapters 12, 69

Sameep Kadakia, MD
Resident Physician
Otolaryngology
Head and Neck Surgery
Mount Sinai–New York Eye and Ear
New York
Chapter 45

Jason I. Kass, MD, PhD
Assistant Professor
Department of Otolaryngology
Boston University
Boston, Massachusetts
Chapters 49, 60, 73, 169

Don Keamy, Jr., MD, MPH
Instructor Otology and Laryngology
Otology and Laryngology
Mass Eye and Ear/Harvard Medical School
Boston, Massachusetts
Chapter 55

Alexandra Kejner, MD
Assistant Professor
Surgery-Otolaryngology
Yale School of Medicine
New Haven, Connecticut;
Attending Physician
Surgery-Otolaryngology
West Haven VA
West Haven, Connecticut
Chapter 35

David Kent, MD
Fellow in Sleep Medicine and Sleep Surgery
Division of Pulmonary
Critical Care and Sleep Medicine
University of Southern California
Los Angeles, California
Chapters 52, 53, 56

Cherine H. Kim, MD, PhD
Department of Otolaryngology
Head and Neck Surgery
Loma Linda University Medical Center
Loma Linda, California
Chapter 67

Seungwon Kim, MD
Associate Professor
Department of Otolaryngology
University of Pittsburgh School of Medicine
Eye and Ear Institute
Pittsburgh, Pennsylvania
Chapters 40, 93

Dennis J. Kitsko, DO
Assistant Professor
Otolaryngology
University of Pittsburgh School of Medicine;
Co-Director
The Hearing Center
Pediatric Otolaryngology
Children's Hospital of Pittsburgh of UPMC
Pittsburgh, Pennsylvania
Chapter 130

Karen M. Kost, MDCM, FRCSC
Professor
Otolaryngology
Head and Neck Surgery
McGill University Health Centre;
Director
Voice and Dysphagia Laboratory
McGill University
Montreal, Quebec, Canada
Chapter 20

Priya Krishna, MD, MS
Assistant Professor
Otolaryngology
Head and Neck Surgery
Loma Linda University School of Medicine;
Co-Director
Voice and Swallowing Center
Loma Linda University Medical Center
Loma Linda, California
Chapter 1

Summit Kundaria, MD
Director
Nuance Facial Plastics
Charlotte, North Carolina
Chapter 155

Daniel Kwon, MD
Department of Otolaryngology
Head and Neck Surgery
Loma Linda University Medical Center
Loma Linda, California
Chapter 82

Tack-Kyun Kwon, MD, PhD
Associate Professor
Otolaryngology
Head and Neck Surgery
Seoul National University
Seoul, South Korea
Chapter 7

Miriam N. Lango, MD
Associate Professor
Surgical Oncology
Fox Chase Cancer Center/Temple University Health System;
Associate Professor
Otolaryngology
Head and Neck Institute/Temple University Hospital
Philadelphia, Pennsylvania
Chapters 14, 28, 81

Brian Lee, DO
Attending Physician
Concord Otolaryngology
Head and Neck Surgery P.A.
Concord, New Hampshire
Chapters 7, 96

Stella E. Lee, MD
Assistant Professor
Department of Otolaryngology
University of Pittsburgh School of Medicine
Pittsburgh, Pennsylvania
Chapters 5, 7, 16, 95, 96, 108

Steve Lee, MD, PhD
Assistant Professor
Otolaryngology
Loma Linda University
Loma Linda, California
Chapter 82

Paul Leong, MD
Director
Sistine Facial Plastic and Laser Surgery
Pittsburgh, Pennsylvania
Chapters 155, 157

Andrea Lewis, MD, Fellow of AAOA, Sleep Board Certification
Assistant Professor
Associate Program Director
Department of Otolaryngology and Communicative Sciences
University of Mississippi Medical Center
Jackson, Mississippi
Chapters 51, 57

Benjamin W. Light, MD
Light Facial Plastic Surgery
Decatur, Alabama
Chapters 155, 157

Chwee M. Lim, MBBS, MRCS(Edin), MMed(ORL)
Assistant Professor
Otolaryngology
National University of Singapore
Consultant
Otolaryngology
Head and Neck Surgery
National University Health System;
Singapore, Singapore
Chapters 31, 80

R. Jun Lin, MD, FRCSC, MSc
Assistant Professor
Otolaryngology-Head and Neck Surgery
University of Toronto
Toronto, Ontario, Canada
Chapter 5

Jason A. Liss, MD
Assistant Professor
Ophthalmology
Duke University
Durham, North Carolina
Chapter 179

Yuan F. Liu, MD
Resident Physician
Otolaryngology
Head and Neck Surgery
Loma Linda University Medical Center
Loma Linda, California
Chapter 78

Joseph Losee, MD
Ross H. Musgrave Professor of Pediatric Plastic Surgery
Department of Plastic Surgery
University of Pittsburgh School of Medicine;
Chief
Division of Pediatric Plastic Surgery
Children's Hospital of Pittsburgh
Pittsburgh, Pennsylvania
Chapters 175, 176

Charles B. MacDonald, MD
Associate Professor
Otolaryngology
University of Tennessee Health Science Center
Memphis, Tennessee
Chapter 134

Zoe M. MacIsaac, MD
Department of Plastic Surgery
University of Pittsburgh Medical Center
Pittsburgh, Pennsylvania
Chapter 170

Li-Xing Man, MSc, MD, MPA
Assistant Professor
Otolaryngology
Head and Neck Surgery
University of Rochester
Rochester, New York
Chapters 100, 112

David Mandell, MD
Center for Pediatric Otolaryngology
Head and Neck Surgery
Boynton Beach;
Affiliate Associate Professor
Clinical Biomedical Science
Charles E. Schmidt College of Medicine
Florida Atlantic University
Boca Raton, Florida
Chapter 197

Mark Mandell-Brown, MD
Director
The Plastic Surgery Experts
Mandell-Brown Plastic Surgery Center;
Volunteer Instructor
Department of Otolaryngology
University of Cincinnati College of Medicine
Cincinnati, Ohio
Chapter 158

Ernest K. Manders, MD
Professor
Department of Plastic Surgery
University of Pittsburgh School of Medicine
Pittsburgh, Pennsylvania
Chapters 164, 170

Anastasios Maniakas, MD
Centre Hospitalier de l'Université de Montréal–CHUM
Otolaryngology
Head and Neck Surgery
Université de Montréal
Montreal, Quebec, Canada
Chapter 50

Scott Manning, MD
Professor
Otolaryngology
University of Washington
Seattle, Washington
Chapter 189

Jessica H. Maxwell, MD, MPH
Assistant Professor
Otolaryngology
MedStar Georgetown University Hospital;
Staff Physician
Otolaryngology
Washington DC VA Medical Center
Washington, DC
Chapters 40, 69

J. Seth McAfee, MD
Coastal Ear
Nose, and Throat
Neptune, New Jersey
Chapter 138

Andrew A. McCall, MD
Assistant Professor
Otolaryngology
University of Pittsburgh School of Medicine
Pittsburgh, Pennsylvania
Chapter 147

Jonathan L. McJunkin, MD
Assistant Professor
Department of Otolaryngology
Washington University in St. Louis
St. Louis, Missouri
Chapter 137

Vikas Mehta, MD, MPH, FACS
Assistant Professor - Otolaryngology/ Head and Neck Surgery
Montefiore Medical Center
Dept of Otorhinolaryngology
Bronx, NY
Chapters 25, 61, 68

Matthew Mifsud, MD
Fellow in Head and Neck Oncology
Otolaryngology
Head and Neck Surgery
University of Toronto
Toronto, Ontario, Canada
Chapter 114

Mark Mims, MD
Resident
Department of Otolaryngology
University of Pittsburgh Medical Center
Pittsburgh, Pennsylvania
Chapter 24

Howard S. Moskowitz, MD, PhD
Assistant Professor
Otorhinolaryngology
Head and Neck Surgery
Montefiore Medical Center
Albert Einstein College of Medicine
Bronx, New York
Chapter 139

Eugene N. Myers, MD, FACS, FRCS Edin (Hon)
Distinguished Professor and Emeritus Chair
Department of Otolaryngology
University of Pittsburgh School of Medicine;
Professor
Department of Oral and Maxillofacial Surgery
University of Pittsburgh School of Dental Medicine
Pittsburgh, Pennsylvania
Chapters 23, 24, 26, 32, 39, 73, 90, 109, 169

Jeffrey N. Myers, MD, PhD, FACS
Alando J. Ballantyne Distinguished Chair of Head and Neck Surgery
Professor and Director of Research
Deputy Chair for Academic Programs
Department of Head & Neck Surgery
The University of Texas MD Anderson Cancer Center
Houston, Texas
Chapter 71

Melonie Nance, MD
Assistant Professor
Department of Otolaryngology
University of Pittsburgh
Chapter 181

Jayakar Nayak, MD, PhD
Assistant Professor
Otolaryngology
Head and Neck Surgery
Stanford University
Stanford, California
Chapters 99, 110

Jason G. Newman, MD, FACS
Associate Professor
Otorhinolaryngology
Head and Neck Surgery
University of Pennsylvania
Philadelphia, Pennsylvania
Chapters 35, 36

Daniel W. Nuss, MD, FACS
Professor and Chairman
Department of Otolaryngology
Head and Neck Surgery
Louisiana State University
New Orleans, Louisiana
Chapters 44, 66, 121

Bert O'Malley, Jr., MD
Professor and Chair
Otorhinolaryngology
Head and Neck Surgery
University of PA Health System
Philadelphia, Pennsylvania
Chapter 36

Allison Ordemann, MD
Resident Physician
Otolaryngology
Head and Neck Surgery
University of Mississippi Medical Center
Jackson, Mississippi
Chapter 57

Bradley A. Otto, MD
Assistant Professor
Department of Otolaryngology
Head and Neck Surgery
The Ohio State University Wexner Medical Center
Columbus, Ohio
Chapter 97

Harshita Pant, BMBS, FRACS, PhD
Otolaryngology Head and Neck Surgery
University of Adelaide
Adelaide, Australia
Chapter 122

Joshua S. Park, MD
Otolaryngology
Loma Linda University School of Medicine
Loma Linda, California
Chapter 84

Renee E. Park, MD, MPH
Assistant Professor
Pediatric Otolaryngology
Loma Linda University Children's Hospital
Loma Linda, California
Chapter 194

Steven Parnes, MD
Professor Surgery/Otolaryngology
Albany Medical College
Albany, New York
Chapters 65, 182

David W. Parker, II, DDS, MD
Oral and Maxillofacial Surgeon
Private Practice
Advanced Oral and Facial Surgery of the Triad
Kernersville;
Attending Physician
Oral and Maxillofacial Surgery
Forsyth Medical Center
Winston-Salem, North Carolina
Chapter 58

Anju K. Patel, BA, MD
Physician
Department of Otolaryngology
Tufts Medical Center
Boston, Massachusetts
Chapter 3

Chirag R. Patel, MD
Clinical Instructor
Otolaryngology
University of Pittsburgh Medical Center
Pittsburgh, Pennsylvania
Chapter 113

Guy Petruzzelli, MD, PhD, FACS
Physician in Chief
Curtis and Elizabeth Anderson Cancer Institute at Memorial University Medical Center
Memorial University Medical Center
Savannah, Georgia;
Vice-President for Oncology Programs
Memorial University Medical Center
Savannah, Georgia
Chapter 34

Kristina Piastro, MD
Resident
Division of Otolaryngology
Albany Medical Center
Albany, New York
Chapter 182

Carlos D. Pinheiro-Neto, MD, PhD
Assistant Professor and Co-Director Cranial Base Surgery Program
Division of Otolaryngology
Albany Medical Center
Albany, New York
Chapter 183

Karen Pitman, MD
Division of Surgical Oncology
Banner MDACC
Gilbert, Arizona
Chapters 17, 64

Aron Z. Pollack, MD
Assistant Professor
Department of Otolaryngology-Head & Neck Surgery
Lenox Hill-Manhattan Eye, Ear, & Throat Hospital
The Hofstra-North Shore-LIJ School of Medicine
New York
Chapter 98

Anna M. Pou, MD
Professor and Vice Chair
Otolaryngology
Head and Neck Surgery
LSU Health Sciences Center
New Orleans, Louisiana
Chapters 16, 178

Sanjay Prasad, MD FACS
Center for Advanced ENT
Rockville, Maryland
Chapter 129

Daniel M. Prevedello, MD
Associate Professor
Department of Neurological Surgery
Wexner Medical Center
Ohio State University
Columbus, Ohio
Chapter 119

Christopher H. Rassekh, MD
Associate Professor
Otorhinolaryngology
Head and Neck Surgery
University of Pennsylvania
Philadelphia, Pennsylvania
Chapter 70

Yael Raz, MD
Assistant Professor
Department of Otolaryngology
University of Pittsburgh
Pittsburgh, Pennsylvania
Chapter 135

Travis Reeves, BS, MD
Assistant Professor
Otolaryngology
Eastern Virginia Medical School and Children's Hospital of the King's Daughters
Norfolk, Virginia
Chapter 196

Camilo Reyes, MD
Associate Professor
Otolaryngology, skull base surgery and neurosurgery
Emory University
Atlanta, Georgia
Chapter 120

Nikisha Q. Richards, MD
Ophthalmic plastic
Reconstructive and Aesthetic Fellow
Ophthalmology
University of Pittsburgh Medical Center
Pittsburgh, Pennsylvania;
Assistant Professor
Ophthalmology–Oculoplastics
Virginia Commonwealth University Health System
Richmond, Virginia
Chapter 152

Franklin L. Rimell, M.D. MSc.
Department of Otolaryngology
University of Minnesota
Pediatric ENT and Facial Plastic Surgery
Children's Hospital and Clinics of Minnesota
Minneapolis, Minnesota
Chapter 195

Alexander Rivero, MD
Resident Physician
Department of Otolaryngology—Head and Neck Surgery
Kaiser Permanente
Oakland, California
Chapter 133

Kenneth D. Rodriguez, MD
Assistant Professor
Department of Otolaryngology
Head and Neck Surgery
University Hospitals Case Medical Center
Chief of Rhinology
Allergy, and Anterior Skull Base Surgery
Department of Otolaryngology
Head and Neck Surgery
University Hospitals Case Medical Center;
Cleveland, Ohio
Chapter 184

Pamela Roehm, MD, PhD
Director
Division of Otology and Neurotology
Department of Otolaryngology
Head and Neck Surgery
Temple University School of Medicine
Philadelphia, Pennsylvania
Chapter 143

Clark A. Rosen, MD
Professor
Department of Otolaryngology
University of Pittsburgh School of Medicine
Pittsburgh, Pennsylvania;
Director
University of Pittsburgh Voice Center
University of Pittsburgh Medical Center
Pittsburgh, Pennsylvania
Chapters 1, 2, 5, 8, 9

Nicholas R. Rowan, MD
Resident Physician
Department of Otolaryngology
University of Pittsburgh Medical Center
Pittsburgh, Pennsylvania
Chapter 103

Nivedita Sahu, MD
Resident Physician
Otolaryngology
University of Pittsburgh Medical Center
Pittsburgh, Pennsylvania
Chapter 103

Joshua M. Sappington, MD
Fellow
Neurotology
Otology and Lateral Skull Base Surgery
Otolaryngology
Head and Neck Surgery
Louisiana State University Health Science Center and Our Lady of the Lake Regional Medical Center
New Orleans, Louisiana
Chapter 140

Barry M. Schaitkin, MD
Professor
Otolaryngology
University of Pittsburgh School of Medicine
Pittsburgh, Pennsylvania
Chapters 88, 103, 111, 112, 180

Amy Schell, MD
Resident Physician
Department of Otolaryngology
University of Pittsburgh School of Medicine
Pittsburgh, Pennsylvania
Chapters 51, 53

Alex Senchenkov, MD
Associate Professor
Department of Plastic Surgery
The University of Tennessee Health Sciences Center
Memphis, Tennessee
Chapters 164, 170

Gaurav A. Shah, DMD, MD, MPH
Resident
Department of Oral and Maxillofacial Surgery
University of Pittsburgh
Pittsburgh, Pennsylvania
Chapter 185

Jack A. Shohet, MD
Shohet Ear Associates Medical Group
Newport Beach and Seal Beach
Clinical Professor (Volunteer)
Department of Otolaryngology-Head and Neck Surgery
University of California-Irvine
Orange County, California
Chapter 136

Julie P. Shtraks, MD
Resident Physician
Department of Otolaryngology-Head and Neck Surgery
Temple University School of Medicine
Temple University Hospital
Philadelphia, Pennsylvania
Chapter 143

Bianca Siegel, MD
Assistant Professor
Department of Otolaryngology
Wayne State University School of Medicine
Detroit, Michigan;
Children's Hospital of Michigan
Detroit, Michigan
Chapter 195

Natalie L. Silver, MD, MS
Assistant Professor
Department of Otolaryngology
University of Florida
Gainesville, Florida
Chapter 71

Alfred A. Simental, Jr., MD
Chairman
Otolaryngology
Head and Neck Surgery
Loma Linda University School of Medicine
Loma Linda, California
Chapters 67, 78, 84

Jeffrey P. Simons, MD
Associate Professor of Otolaryngology
University of Pittsburgh School of Medicine
Children's Hospital of Pittsburgh of UPMC;
Pittsburgh, Pennsylvania
Chapters 197, 198

Libby J. Smith, DO
Associate Professor Otolaryngology
University of Pittsburgh School of Medicine
Director
Swallowing Disorders Center
University of Pittsburgh Medical Center
Pittsburgh, Pennsylvania
Chapters 2, 9, 10

Carl H. Snyderman, MD, MBA, FACS
Professor
Departments of Otolaryngology and Neurosurgery Neurological Surgery
University of Pittsburgh School of Medicine
Co-Director
Center for Cranial Base Surgery
University of Pittsburgh Medical Center
Pittsburgh, Pennsylvania
Chapters 38, 77, 98, 109, 116, 122, 123, 151

Arturo Solares, MD
Associate Professor
Otolaryngology, Skull Base Surgery and Neurosurgery
Emory University
Atlanta, Georgia
Chapter 120

Mario G. Solari, MD
Assistant Professor
Department of Plastic Surgery
University of Pittsburgh School of Medicine
Pittsburgh, Pennsylvania
Chapters 164, 170

John Song, MD
Associate Professor
Director of Head and Neck Surgery
Department of Otolaryngology
University of Colorado
Aurora, Colorado
Chapter 173

Ryan Soose, MD
Assistant Professor
Department of Otolaryngology
Director
Division of Sleep Surgery
University of Pittsburgh Medical Center
Pittsburgh, Pennsylvania
Chapters 54, 56

Satyan B. Sreenath, MD
Department of Otolaryngology- Head and Neck Surgery
University of North Carolina
School of Medicine at Chapel Hill
Chapel Hill, North Carolina
Chapter 166

Amanda L. Stapleton, MD
Assistant Professor of Otolaryngology
Otolaryngology
University of Pittsburgh School of Medicine
Children's Hospital of Pittsburgh
Pittsburgh, Pennsylvania
Chapter 189

Tonya Stefko, MD
Assistant Professor
Ophthalmology
Otolaryngology, and Neurological Surgery
University of Pittsburgh Medical Center
Pittsburgh, Pennsylvania
Chapters 149, 151, 154, 187

Jeffrey Steitz, MD
Resident Physician
Otolaryngology
Head and Neck Surgery
University of Louisville
Louisville, Kentucky
Chapters 27, 83

Andrew Tassler, MD
Assistant Professor
Otolaryngology
Head and Neck Surgery
Weill Cornell Medical College;
Attending Otolaryngologist
Otolaryngology
Head and Neck Surgery
New York Presbyterian Hospital
New York
Chapters 48, 93

Paul A. Tennant, BS, MD
Assistant Professor
Otolaryngology
Head and Neck Surgery
University of Louisville School of Medicine
Louisville, Kentucky
Chapter 27

Adam Terella, MD
Assistant Professor
Otolaryngology
Head and Neck Surgery
University of Colorado School of Medicine
Aurora, Colorado
Chapter 173

Andrew Thamboo, MD, MHSc
Clinical Instructor
Department of Otolaryngology
Head and Neck Surgery
Stanford University
Stanford, California
Chapter 99

Apurva Thekdi, MD
Director
Texas Voice Center
Houston, Texas
Chapter 8

Brian D. Thorp, MD
Assistant Professor
Department of Otolaryngology-Head and Neck Surgery
University of North Carolina
School of Medicine at Chapel Hill
Chapel Hill, North Carolina, USA
Chapter 166

Prasad John Thottam DO., FAAP
Director Beaumont Children's Hospital Pediatric Aerodigestive Center
Clinical Assistant Professor Michigan State University
Michigan Pediatric Ear, Nose and Throat Associates (MPENTA)
Pediatric Otolaryngology/ Head & Neck Surgery
Detroit, Michigan
Chapter 193

Elizabeth Toh, MD, MBA
Director
Balance and Hearing Implant Center
Department of Otolaryngology
Head and Neck Surgery
Lahey Hospital and Medical Center
Burlington, Massachusetts
Chapters 139, 146

Raymond K. Tsang, MS, MBChB, FRCSEd(ORL), FHKAM(ORL)
Clinical Assistant Professor
Department of Surgery
University of Hong Kong
Hong Kong
Chapter 42

Amanda J. Tschetter, MD
Micrographic Surgery and Dermatologic Oncology (Mohs) Fellow
Skin Cancer Center
Mohs Surgery and Surgical Dermatology
Zitelli & Brodland, P.C.
Pittsburgh, Pennsylvania
Chapter 161

Ramachandra P. Tummala, MD
Associate Professor
Neurosurgery
University of Minnesota
Minneapolis, Minnesota
Chapter 115

Meghan T. Turner, MD
Fellow in Advanced Head and Neck Surgical Oncology
Department of Otolaryngology
University of Pittsburgh School of Medicine
Chapters 12, 79

Kitirat Ungkanont, MD
Associate Professor
Otolaryngology
Faculty of Medicine Siriraj Hospital
Mahidol University
Bangkok, Thailand
Chapter 191

Andrew C. Urquhart, MD, FACS
Attending Physician
Otolaryngology
Head and Neck Surgery
Marshfield Clinic
Marshfield, Wisconsin
Chapter 104

Allan D. Vescan, MD, MSc, FRCSC
Assistant Professor
Otolaryngology
Head and Neck Surgery
University of Toronto
Toronto, Ontario, Canada
Chapter 116

Esther X. Vivas, MD
Assistant Professor
Neurotology and skullbase surgery
Department of Otolaryngology - Head and neck surgery
Emory University
Atlanta, Georgia
Chapter 144

Peter S. Vosler, MD, PhD
Resident Physician
Otolaryngology
University of Pittsburgh Medical Center
Pittsburgh, Pennsylvania
Chapter 32

Evan S. Walgama, MD
Clinical Instructor
Otolaryngology
Head and Neck Surgery
Stanford School of Medicine
Stanford, California
Chapters 99, 110

David D. Walker, MD
Resident
Surgery Section of Otolaryngology
Head and Neck Surgery
University of Chicago
Chicago, Illinois
Chapter 30

Jonathan Walsh, MD
Assistant Professor
Otolaryngology
Johns Hopkins
Baltimore, Maryland
Chapter 199

Rohan R. Walvekar, MD
Associate Professor
Otolaryngology
Head and Neck Surgery
LSU Health Sciences Center
New Orleans, Louisiana
Chapters 66, 88, 89

Eric W. Wang, MD
Associate Professor
Department of Otolaryngology
University of Pittsburgh School of Medicine
Pittsburgh, Pennsylvania
Chapters 24, 113, 117, 150, 156, 184

Peter Weber, MD, MBA
Director
Ear Institute
Mt Sinai and New York Eye and Ear
New York
Chapter 146

William I. Wei, MBBS, FRCS, FACS(Hon.)
Emeritus Professor
Head
Department of Surgery
Director
Li Shu Pui ENT Head and Neck Surgery Centre
Hong Kong Sanatorium & Hospital
Hong Kong SAR, China
Chapter 42

Mark Whitaker, MD
Assistant Professor
Division of Otolaryngology
Department of Surgery
University of Vermont Medical Center
Burlington, Vermont
Chapter 125

Meghan N. Wilson, MD
Fellow Physician at The Children's Hospital of Philadelphia
The Children's Hospital of Philadelphia
Philadelphia,
Pennsylvania
Chapter 121

Todd M. Wine, MD
Assistant Professor
Otolaryngology
University of Colorado Anschutz Medical Campus;
Pediatric Otolaryngologist
Division of Pediatric Otolaryngology
Children's Hospital of Colorado
Aurora, Colorado
Chapter 190

Joshua W. Wood, MD
Resident Physician
Otolaryngology
Head and Neck Surgery
University of Tennessee Health Science Center
Memphis, Tennessee
Chapter 134

Robert Yellon, MD
Professor
Department of Otolaryngology
University of Pittsburgh School of Medicine
Pittsburgh, Pennsylvania
Chapter 208

Yu-Lan (Mary) Ying, MD
Assistant Professor
Otology and Neurotology
Otolaryngology
Rutgers
The State University of New Jersey
Newark, New Jersey
Chapter 128

Noriko Yoshikawa, MD
Head and Neck Surgery
Kaiser Permanente
Oakland, California
Chapter 133

Vyvy Young, MD
Assistant Professor
Otolaryngology
University of Pittsburgh School of Medicine
Pittsburgh, Pennsylvania
Chapter 4

Adam M. Zanation, MD
Associate Professor
Otolaryngology
Head and Neck Surgery
University of North Carolina–Chapel Hill
Chapel Hill, North Carolina
Chapters 107, 124, 166

Carlton J. Zdanski, MD, FAAP, FACS
Associate Professor
Chief
Division of Pediatric Otolaryngology
Department of Otolaryngology/HNS
University of North Carolina School of Medicine
Surgical Director
The North Carolina Children's Airway Center
University of North Carolina School of Medicine
Chapel Hill, North Carolina
Chapter 199

Lee A. Zimmer, MD, PhD
Associate Professor
Otolaryngology
Head and Neck Surgery
University of Cincinnati Medical Center
Cincinnati, Ohio
Chapter 118

John Zitelli, MD
Adjunct Associate Professor
Otolaryngology
University of Pittsburgh School of Medicine
Pittsburgh, Pennsylvania
Chapter 161

ELSEVIER

© 2018 Elsevier Ltd. All rights reserved.
First edition 1997
Second edition 2008

OPERATIVE OTOLARYNGOLOGY: HEAD AND NECK SURGERY ISBN: 978-0-323-40150-0

The right of Eugene N. Myers and Carl H. Snyderman to be identified as editors of the current edition has been asserted by them in accordance with the Copyright, Designs, and Patents Act 1988.

The right of Eugene N. Myers to be identified as editor of the second edition has been asserted by him in accordance with the Copyright, Designs, and Patents Act 1988.

No part of this publication may be reproduced or transmitted in any form or by any means, electronic or mechanical, including photocopying, recording, or any information storage and retrieval system, without permission in writing from the publisher. Details on how to seek permission, further information about the Publisher's permissions policies, and our arrangements with organizations such as the Copyright Clearance Center and the Copyright Licensing Agency, can be found at our website: www.elsevier.com/permissions.

This book and the individual contributions contained in it are protected under copyright by the Publisher (other than as may be noted herein).

Notices

Knowledge and best practice in this field are constantly changing. As new research and experience broaden our understanding, changes in research methods, professional practices, or medical treatment may become necessary.

Practitioners and researchers must always rely on their own experience and knowledge in evaluating and using any information, methods, compounds, or experiments described herein. In using such information or methods they should be mindful of their own safety and the safety of others, including parties for whom they have a professional responsibility.

With respect to any drug or pharmaceutical products identified, readers are advised to check the most current information provided (i) on procedures featured, or (ii) by the manufacturer of each product to be administered, to verify the recommended dose or formula, the method and duration of administration, and contraindications. It is the responsibility of practitioners, relying on their own experience and knowledge of their patients, to make diagnoses, to determine dosages and the best treatment for each individual patient, and to take all appropriate safety precautions.

To the fullest extent of the law, neither the Publisher nor the authors, contributors, or editors, assume any liability for any injury and/or damage to persons or property as a matter of products' liability, negligence, or otherwise, or from any use or operation of any methods, products, instructions, or ideas contained in the material herein.

Content Strategist: Belinda Kuhn
Content Development Specialists: Sam Crowe and Joshua Mearns
Project Manager: Dr. Atiyaah Muskaan/Srividhya Vidhyashankar
Design: Miles Hitchen
Illustration Managers: Amy Faith Heyden and Karen Giacomucci
Grading Scale Artwork: Terry R. Tarrant
Marketing Manager: Melissa Fogarty

Printed in China.

Last digit is the print number: 9 8 7 6 5 4 3 2 1



The Third Edition of Operative Otolaryngology: Head and Neck Surgery is dedicated to the faculty of the Department of Otolaryngology at the University of Pittsburgh School of Medicine, the second generation (our residents and fellows), the third generation (their residents and fellows), and future generations of the Pittsburgh family.

PERSONAL DEDICATION: Eugene N. Myers

To my wife, Barbara, our daughter, Marjorie Fulbright and her husband Cary, our son, Jeffrey N. Myers MD, PhD and his wife Lisa, our grandsons, Alex and Chip Fulbright, Keith, Brett, and Blake Myers, with love and many thanks for your patience with me during the creation of this book.

PERSONAL DEDICATION: Carl H. Snyderman

To my wife, Michelina Fato, MD, for her continuous support and encouragement, to my family (Kelly, Molly, Andrew, and Lucia) for providing perspective regarding life's goals, and to the memory of my father, Sanford Snyderman, MD, who continues to be an inspiration and role model for my life in medicine.

Preface

We are extremely proud to present the Third Edition of *Operative Otolaryngology: Head and Neck Surgery*. Since the publication of the Second Edition in 2008, we have witnessed tremendous progress in our specialty driven by technological advances and scientific inquiry with the refinement of surgical techniques, the development of new surgical approaches, and the genesis of new surgical disciplines. The Third Edition recognizes these changes with new and expanded content to present the latest advances across all disciplines. While we have changed the format for easier access and reliability, we have not changed our commitment to provide an accurate and up to date description of the *hows* and *whys* of reliable surgical techniques for an international audience.

The third edition has 78 more chapters, than the second edition, with new sections on the nasopharynx, pediatrics, sialendoscopy, and sleep disorders. Sections are organized based on anatomical region and subspecialty. Within each section, chapters are arranged from the less-to-more complex. New features of each chapter include: Evidence-Based Medicine Question, Editorial Comment, and Review Questions. One of the biggest advances in head and neck surgery has been the development of robotic surgery. The third edition includes applications of robotic surgery for neoplasia of the oropharynx, nasopharynx, hypopharynx, and larynx; volumetric tongue base reduction for obstructive sleep apnea; tumors of the prestyloid parapharyngeal space; and management of the unknown primary. There are greatly expanded sections on cranial base surgery, otology, reconstruction, and thyroid/parathyroid surgery. Interesting new techniques include: balloon sinuplasty, drug-induced sedated evaluation of obstructive sleep apnea, hyoid suspension, repair of superior canal dehiscence, and implantable middle ear devices. Although surgical techniques eventually fall out of favor and risk becoming obsolete, we recognize the importance of maintaining proficiency with classical procedures, especially in regions of the world where resources are limited or circumstances require a different philosophy of surgical management. We have retained these time-tested techniques alongside minimally invasive alternatives.

Operative Otolaryngology: Head and Neck Surgery has always been about the legacy of the Department of Otolaryngology at the School of Medicine and the University of Pittsburgh Medical Center (UPMC) under the leadership of Eugene N. Myers and Jonas T. Johnson. Collectively, the faculty has had a tremendous impact on generations of residents, fellows, and international scholars. Many of their trainees (both domestic and international) have gone on to establish their own legacy through the promulgation, around the world, of the Pittsburgh way of managing patients. The extended "Pittsburgh family" has grown since the last edition, with a pool of 196 authors and 21 section editors. We are deeply indebted to them for their contributions. All of the authors of this textbook are members of the faculty of the University of Pittsburgh School of Medicine or Dental Medicine, have received training at the University of Pittsburgh Medical Center, or have trained under a graduate of these institutions.

Acknowledgments

We gratefully acknowledge the enormous contributions of our Editorial Coordinator, Beverly Poremba, and her staff: Allison Reiber and Nancy Yim.

We also acknowledge the efficient, good-natured help, guidance, and advice from Belinda Kuhn, Senior Consultant Strategist at Elsevier, along with Sam Crowe, Content Development Specialist, Joshua Mearns, Content Development Specialist, Dr. Atiyaah Muskaan, Project Manager, and Miles Hitchen, Senior Designer, from Elsevier for making this Third Edition possible.

We are eternally indebted to Mary Jo Tutchko for her efforts over the years, on all projects big and small. Nothing would ever get done without her help.

In Memoriam



This edition is dedicated to the memory of Berrylin J. Ferguson, MD, who served as an Associate Editor for the second edition. Dr. Ferguson was Professor of Otolaryngology in the University of Pittsburgh School of Medicine and Director of the Division of Sinonasal Disorders and Allergy at the University of Pittsburgh Medical Center. She established herself as an International leader in rhinology. Her presence is greatly missed.

1 Office-Based Laryngeal Procedures

Priya Krishna, Clark A. Rosen

INTRODUCTION

Office-based laryngeal procedures are quickly gaining popularity. These procedures are cost effective and provide an important alternative for patients who are not good candidates for operative direct laryngoscopy. Included are those patients with contraindications to general anesthesia or who have anatomic variations that result in poor exposure when direct laryngoscopy is attempted. Advantages of procedures performed on an awake patient in the office include the performance of intraoperative assessment of vocal quality without interference from sedation or an endotracheal tube.[1] Described in this chapter are several procedures that can be successfully and relatively easily undertaken in the office setting under local anesthesia.

KEY OPERATIVE LEARNING POINTS

1. The superior arcuate line is the key landmark lateral to the vocal fold for injection augmentation of the vocal fold.
2. Proper positioning of the patient, strong endoscopy skills, adequate anesthesia, and appropriate patient selection are critical to success of an in-office laryngeal procedure.
3. It is important to know exactly where the tip of the needle is prior to injection for *any* type of injection procedure. The angle of the needle in an injection procedure is also an important consideration in ensuring success of the procedure.
4. Avoiding multiple injection sites during injection augmentation improves retention of the injected material.

PREOPERATIVE PERIOD

History

1. History of present illness—Patients may present a variety of complaints:
   a. Hoarseness
   b. Chronic cough
   c. Shortness of breath
   d. Throat pain
   e. Difficulty swallowing
2. Past medical history
   a. Recent surgery where the recurrent laryngeal nerve was at risk
   b. Neurologic disorders (Parkinson's disease, multiple system atrophy, essential tremor)
   c. History of recent intubation
   d. Recent laryngoscopy or laryngeal surgery
   e. History of laryngopharyngeal reflux
   f. Occupational voice use, recreational voice use, or vocal misuse
   g. History of smoking

Physical Examination

1. Perceptual assessment of voice: Breathy voice in glottic insufficiency or breathy breaks with abductor spasmodic dysphonia, strained–strangled voice in case of adductor spasmodic dysphonia, strained voice in case of vocal fold granuloma
2. Raspy voice quality and/or diplophonia with paralysis, paresis, presence of vocal fold lesions of any kind
3. Oral cavity/oropharyngeal anatomy: Interincisal distance, presence, and strength of gag reflex
4. Neck anatomy: Ease of palpating thyroid and cricoid cartilage landmarks, presence of masses
5. Flexible laryngovideostroboscopy demonstrating:
   a. Vocal fold atrophy
   b. Vocal fold hypomobility or immobility
   c. Vocal fold scar demonstrating a decreased mucosal wave
   d. Benign vocal fold lesions: Polyps, cysts, Reinke edema, vocal fold granulomata, and papillomas
   e. Lesions of unknown malignant potential (leukoplakia/hyperkeratosis)
   f. Laryngeal dystonia or tremor

Imaging

No imaging is required preprocedure, although imaging may be recommended in diagnosis of some disease processes being treated by office procedures (outside the scope of this chapter)

Indications

1. Vocal fold injection[2]
   a. Augmentation: Glottic insufficiency of any kind (due to vocal fold paralysis, paresis, atrophy, scar)
   b. Modulation of vocal fold scars (steroids) or subglottic/tracheal scar
   c. Treatment of spasmodic dysphonia
2. Biopsy
   a. Establishment of a diagnosis for a laryngeal lesion
3. Laser[3]
   a. Treatment of vascular lesions of the vocal fold (i.e., ectasias, varices)
   b. Treatment of epithelial and selected subepithelial lesions of the vocal fold (i.e., polyps, cysts, papilloma, Reinke edema, granulomata, glottic webs, leukoplakia, dysplasia)

Contraindications

1. Unstable cardiopulmonary status
2. Allergy to local anesthetics or injectable materials
3. Poor exposure of the endolarynx due to prolapsing arytenoid or severe supraglottic constriction

4. Poorly defined cervical anatomic landmarks (in case of percutaneous injection)
5. Significant tremor in the laryngopharynx

Contraindications to botulinum toxin use:

1. Pregnancy
2. Breast-feeding
3. Impaired abduction of vocal fold (in setting of posterior cricoarytenoid muscle (PCA) injection)
4. Any neuromuscular condition (i.e., myasthenia gravis)
5. Concurrent aminoglycoside treatment

Preoperative Preparation

1. Discontinue antiplatelet/anticoagulants (though no studies to show increased incidence of complications with in office injection).
2. Recommend prescribing a small dose of an anxiolytic (i.e., Xanax 0.5 mg 1 hour prior to procedure and may be repeated once 5 minutes prior to procedure if needed) for patients who know they might experience anxiety.

OPERATIVE PERIOD

Perioperative Antibiotic Prophylaxis

1. Not required—rate of infection is very low, despite this being a clean-contaminated surgical environment

Monitoring

No active monitoring is necessary during an in-office procedure; it is advisable to take preprocedure and postprocedure vital signs.

Anesthesia

1. Nebulizer: 5 cc 4% lidocaine delivered over 10 minutes—useful for per-oral procedures to eliminate the gag reflex
2. Flexible drip catheter: Silastic catheter guided through the channel of the flexible laryngoscope, direct application to larynx of 4% lidocaine, elicit laryngeal "gargle"
3. Percutaneous transtracheal/transcricothyroid injection of 4% lidocaine, which induces vigorous coughing
4. Anesthetize the skin with 1% lidocaine with epinephrine for percutaneous techniques (optional).
5. Be mindful of toxic limit of 7 to 8 mL (5 mg/kg; approximately 350 mg in 70-kg patient)[4].

Positioning

1. Upright position in examination chair for the majority of procedures
2. Option is supine position during electromyographic (EMG)-guided injection of the botulinum toxin

Patient Factors[5]

"the ideal patient has:"

1. Normal or minimal gag reflex
2. Ability to remain calm for 10- to 30-minute duration of procedure
3. Adequate interincisal distance of 20 mm at least (i.e., no trismus)[3]
4. Adequate intranasal airway (to pass laryngoscope, which is 3 to 4 mm in diameter, or TNE scope, which is 5 mm in diameter)
5. Absence of neurologic conditions affecting stability of the head (no torticollis or tremor)
6. Motivated to have the procedure done in the "office" and not the operating room with general anesthesia

Instruments and Equipment to Have Available

- Flexible laryngoscope with distal chip with a channel for passage of a flexible catheter for anesthetic and/or flexible needle passage and/or fiber-based laser (or rigid 70-degree telescope for a one-person approach)
- C-mount camera (attaches to the flexible or rigid laryngoscope)
- Video monitor for visualization (Fig. 1.1)
- Curved Abraham cannula for delivery of topical lidocaine and vocal fold palpation, as needed; alternative: flexible drip catheter placed inside flexible scope channel or an angiocatheter type device to fit in the working channel
- Injection device for transoral injection approach–orotracheal injector or proprietary malleable needles (Merz North America)
- 23-, 25-, or 27-gauge 1.5-inch needles for percutaneous injection (when required) or 20-gauge spinal needle for certain techniques
- Flexible fine-gauge injection needle for use with working channel in flexible laryngoscope
- Endoscopic biopsy forceps to place through working channel or per-oral type biopsy forcep
- Injectable material: Calcium hydroxylapatite, carboxymethylcellulose, hyaluronic acid, micronized dermis (for augmentation), dexamethasone, or triamcinolone
- Alcohol prep pad or topical prep solution (povidone-iodine) for percutaneous injections
- Topical cetacaine spray (benzocaine/tetracaine)
- Topical oxymetazoline and/or 2% Pontocaine or 2% lidocaine mixture for nasal decongestion and anesthesia
- Cotton pledgets
- 4% lidocaine (topical) for drip and nebulization
- 2% lidocaine viscous
- Nebulizer
- Potassium titanyl phosphate (KTP), neodynium:yitrium aluminium garnet (Nd: YAG), or fiber-guided CO_2 lasers

Specific to Botox injection:

- EMG device—either handheld or traditional EMG apparatus
- Botulinum toxin

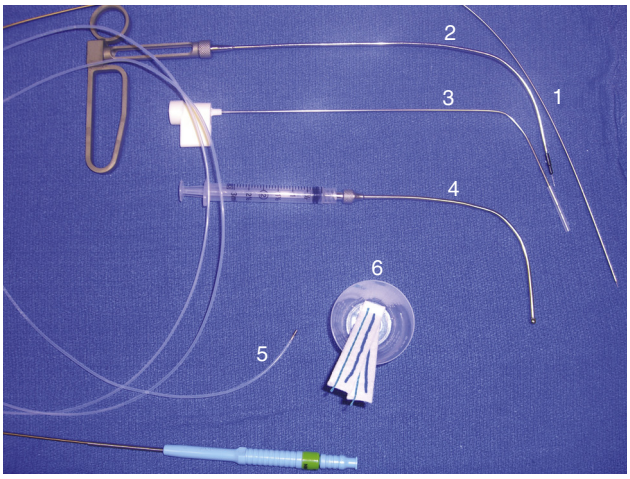

Fig. 1.1. Common equipment used for office laryngeal procedures. *1*, flexible wire sheath with 27-gauge needle; *2*, Xomed orotracheal injector device; *3*, Merz -Bioform malleable 25-gauge orotracheal needle; *4*, 3-mL syringe attached to Ab raham cannula; *5*, end of flexible endoscopic catheter for administration of topical anesthetic; *6*, nasal pledgets.

- Insulated 25- or 26-gauge needle electrode, which is also used to simultaneously administer Botox
- Local anesthetic for skin (1% lidocaine with 1:100,000 epinephrine)—optional

Key Anatomic Landmarks

1. Superior arcuate line—line starting at lateral border of vocalis and where the ventricle starts
2. Thyroid notch—for thyrohyoid technique
3. Thyroid cartilage
4. Cricothyroid membrane—for percutaneous augmentation or botulinum toxin injection

Prerequisite Skills

1. Strong skills with endoscopic procedures
2. Thorough knowledge of external and internal laryngeal anatomic landmarks
3. Laser safety training (for any laser procedure)

Operative Risks

1. Infection
2. Bleeding/hemorrhage
3. Worsening hoarseness due to misplaced injectable (if in a too superficial plane; i.e., Reinke space)
4. Airway obstruction
5. Aspiration due to residual local anesthetic
6. Anesthetic toxicity from overdose

Surgical Techniques

Percutaneous Methods

Percutaneous injection technique (two-person): Transcricothyroid (Fig. 1.2)

- Anesthetize skin with either 1% lidocaine with epinephrine or transtracheal 4% lidocaine injection.
- Bend 25-g 1.5″ needle at 45-degree angle.
- Place needle through cricothyroid space just off midline of the side to be injected.
- Assistant can use flexible laryngoscope to confirm position of the needle.
- Can visualize needle in subglottic airway, aim toward infraglottic surface of vocal fold
- Botox injection using laryngeal EMG guidance does not need visual confirmation (one-person technique).

Percutaneous injection technique (two-person): Thyrohyoid (Fig. 1.3)

- Anesthesia techniques are the same as for the transcricothyroid method.
- Use either 25-g 1.5″ needle or spinal needle.
- Enter thyrohyoid space at thyroid notch at an acute angle, nearly 90 degrees.

Percutaneous injection technique (two-person): Transthyroid cartilage

- Topical anesthesia administered similar to other percutaneous techniques
- Need an endoscopist to help confirm needle position
- Guide 20-gauge spinal needle through thyroid cartilage in perpendicular fashion, and then rotate it anteriorly and horizontal to the ground; position needle 6 to 8 mm lateral to midpoint of thyroid cartilage; spinning the needle through the cartilage like a screw eases insertion.
- Tilt needle laterally toward ipsilateral arytenoid cartilage to run needle parallel to vocal fold; avoid puncturing the epithelium.
- Remove stylet and then attach syringe with injectate; slowly inject under direct visualization from above with laryngoscope.

Per-Oral Injection Technique (Fig. 1.4)

- Use either proprietary needle, which comes with injectable material (Merz Aesthetics), or Xomed orotracheal injector needle.
- For the orotracheal injector, load a slip tip tuberculin syringe with injectable material of choice and attach a disposable needle to the end of shaft.
- Can use nebulized 4% lidocaine (5 cc) to help with depressing gag reflex
- Place ½″ × 3″ pledgets, with a mixture of oxymetazoline and 4% lidocaine into both nasal cavities for at least 5 minutes.

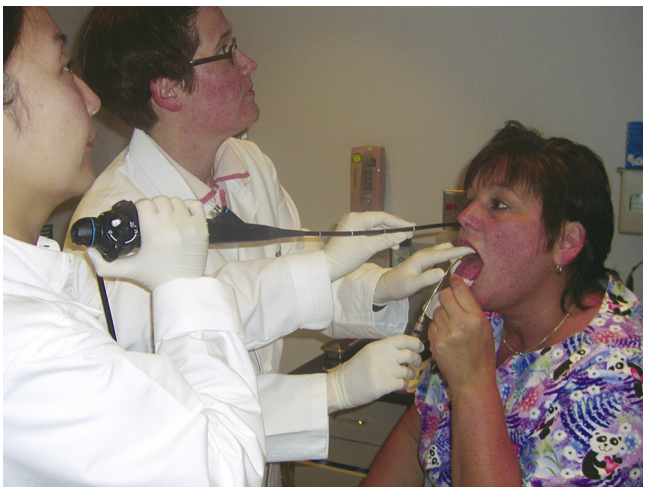

Fig. 1.2. Transoral vocal fold augmentation with endoscopic guidance placement of Abraham cannula. Note positioning of patient.

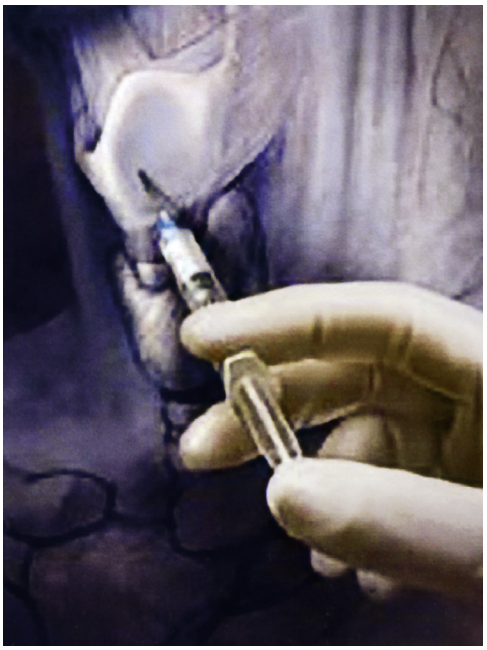

Fig. 1.3. Percutaneous trans-thyroid cartilage approach for vocal fold injection. *(Courtesy of LifeCell Corporation.)*

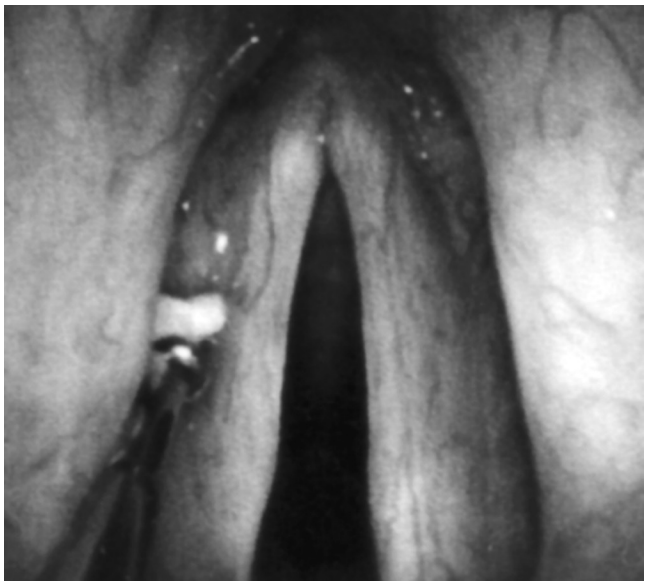

Fig. 1.4. Proper placement of the needle lateral to the vocal fold for augmentation using flexible endoscopy. *(Reprinted with permission from Andrade FP, Carrau R, Buckmire R: Safety and cost-effectiveness of intra-office flexible video-laryngoscopy with transoral vocal fold injection in dysphagic patients. Am J Otolaryngol 27:319-322, 2006.)*



Fig. 1.5. Thyrohyoid approach in cadaver larynx. *(Reprinted with permission from Getz AE, Schar J, Amin M: Thyrohyoid approach to cidofovir injection: a case study. J Voice 19:501-503, 2005.)*

- Remove pledgets. Then guide flexible channel laryngoscope, to the level of the base of the tongue; then use drip catheter with 4% lidocaine to drip sequentially over the base of the tongue, epiglottis, AE folds, and laryngeal vestibule and vocal folds; you can also use Abraham cannula perorally to deliver topical anesthesia.
- Gently palpate vocal folds with the tip of the catheter to confirm adequate anesthesia.
- Apply either a small amount of additional 4% lidocaine or 20% benzocaine (HurriCane) spray to the oropharynx for additional suppression of the gag reflex.
- Have the patient hold his/her own tongue with gauze downward, and ask the patient to bring the jaw forward; alternatively, the surgeon can hold the tongue with the gauze.
- Guide the needle through the oral cavity over the base of the tongue into the endolarynx while visualizing on the monitor.
- Aim for a point just anterior and lateral to the vocal process in the superior arcuate line lateral to the bulk of the thyroarytenoid muscle, feel a "pop" or loss of resistance, and inject the desired amount based on contouring of the vocal fold. Avoid injecting too far medially, which may place a superficial deposit with a poor phonatory result (Fig. 1.5).
- Can confirm adequate closure (if done for augmentation/medialization) via stroboscopy postinjection

Transnasal Biopsy, Laser, or Injection Technique

- Anesthesia is delivered in an identical fashion as described previously, with nebulization and directed delivery of topical anesthesia.
- All instruments—biopsy forceps, laser fiber ensheathed in a metal guide, or endoscopic needle—are placed through the working channel.
- When performing a biopsy, it is important to grasp the tissue in question in the vocal fold and pull with a quick movement to avoid excessive tearing of the mucosa, which can lead to vocal fold scarring; biopsy anywhere else in the larynx requires the same quick movement.
- When using a laser, all personnel must wear protective eyewear specific for the laser type and for papilloma treatment. Use of laser mask is advisable but not required; standard KTP laser settings are 30 to 35 watts, 15 ms pulse width, and 2 pulse per second rate of fire.
- For steroid injection, the needle can be guided to a superficial location within the vocal fold in the treatment of benign lesions, if applicable.

Commons Errors in Technique

1. Multiple injection sites or superficial injection
2. Plugging of the needle in transcartilaginous methods
3. Inadequate visualization
4. Inadequate level of anesthesia
5. Misplaced Botox or diffusion of Botox into surrounding musculature
6. Excessive removal of mucosa leading to vocal fold scarring

POSTOPERATIVE PERIOD

Postoperative/Postprocedure Management

1. No eating or drinking is allowed for 1 hour after the procedure in order to avoid aspiration.
2. For injection augmentation, the patient should observe voice rest for 24 hours.
3. The patient receiving Botox injection for laryngeal dystonia should be told to not expect any effect for at least 2 to 3 days.
4. Voice rest is recommended for between 3 and 6 days for laser treatment of benign vocal fold lesions, except in the case of papilloma (which depends on the amount of mucosal free edge of vocal fold being treated).

Complications

1. Vasovagal reaction
2. Respiratory compromise
3. Misplacement of injectable into the wrong plane, resulting in adverse phonatory outcomes
4. Inadvertent surrounding tissue burns from laser use or excessive laser use, which may cause vocal fold scarring
5. Aspiration pneumonia from too large an injection of botulinum toxin into the laryngeal adductor muscles

Alternate Management Plan

For augmentation/medialization:

1. Voice therapy alone but usually both pre- and postprocedure
2. Laryngeal framework surgery

For chemodenervation (use of Botox/Xeomin)

1. Selective laryngeal adductor denervation

For benign and premalignant vocal fold lesions

1. Microsuspension direct laryngoscopy ± microflap excision ± laser treatment
2. Voice therapy

DISCUSSION

Evidence-Based Medicine Question

Are intralesional steroid injections in the office well tolerated and beneficial in treatment of benign vocal fold lesions?

A meta-analysis of six studies performed in 2013 indicated that these procedures are well tolerated under local anesthesia and demonstrated significant improvements in both objective and subjective measures of vocal quality.

Editorial Comment

Office-based laryngeal procedures have now become the preferred modality of treatment for many otolaryngologists. Not only are they time saving but they avoid the dangers of sedation or general anesthesia. This is not to say that office-based procedures are not without complications. However, serious complications that leave a patient with long-term morbidity or mortality are exceedingly rare. Knowing where one's needle tip is at all times before an awake office-based vocal fold injection augmentation is paramount. The per-oral technique offers the ideal visualization and angle of insertion into the layered vocal fold but also has the steepest learning curve of any of the techniques. Once mastered, though, it provides an effective and predictable intervention. The percutaneous techniques can be more facile to learn and can also offer visualization of the needle tip before injection; however, the depth of insertion can be more unpredictable due to the angle of needle insertion. Indications for office KTP laser continue to grow and now include some benign subepithelial vocal fold lesions and vocal fold scarring (with the intention of remodeling/softening the scar). Patients with chronic epithelial disease such as papilloma and dysplasia are now returning to the OR much less frequently due to office-based KTP laser "maintenance" of these lesions. Almost all of these procedures require more than one person to complete. A reliable and easily reproduceable one-man technique/device for vocal fold injection augmentation that can be performed in the office by any otolaryngologist is hopefully on the horizon.

Thomas L. Carroll

Access the review questions and additional sources list online at http://www.expertconsult.com

REFERENCES

1. Rosen CA, Amin MR, Sulica L, et al. Advances in office-based diagnosis and treatment in laryngology. Laryngoscope 2009;119:S185–214.
   Synopsis: This is an excellent overview of the history of flexible endoscopy and advancements, anesthesia techniques, and indications for various in-office procedures.
2. Sulica L, Rosen CA, Postma GN, et al. Current practice in injection augmentation of the vocal folds: indications, treatment, principles, techniques, and complications. Laryngoscope 2010;120:319–325.
   Synopsis: This is a specific review and comparison of office versus operative vocal fold injections as well as a description of the various techniques currently used in-office for vocal fold injection.
3. Sheu M, Sridharan S, Kuhn M, et al. Multi-institutional experience with the in-office potassium titanyl phosphate laser for laryngeal lesions. J Voice 2012;26(6):806–310.
   Synopsis: This is one of a few multi-institutional studies of KTP laser treatment of multiple types of vocal fold lesions showing lesion regression in 90% overall.
4. Wang S, Simpson CB. Anesthesia for office procedures. Otolaryngol Clin N Am 2013;46:13–19.
   Synopsis: This is a specific overview of the different types of anesthesia available for in-office laryngeal procedures.
5. Young V, Smith LJ, Sulica L, et al. Patient tolerance of awake, inoffice laryngeal procedures: a multi-institutional perspective. Laryngoscope 2012;122:315–321.
   Synopsis: This is a study demonstrating overall very good tolerance by patients of in-office vocal fold procedures.

REVIEW QUESTIONS

1. All of these are relative contraindications for a per-oral approach, except
   a. Head tremor
   b. Trismus
   c. Anxiety
   d. Previous head and neck cancer surgery

2. All of these are approaches to vocal fold augmentation, except
   a. Per-oral
   b. Transcricothryoid
   c. Thyrohyoid
   d. All of the above

3. Vocal fold augmentation is typically done for which of the following indications?
   a. Vocal fold paralysis
   b. Vocal fold polyps
   c. Respiratory papillomatosis
   d. Reinke edema

ADDITIONAL SOURCES

Halum SL, Moberly AC. Patient tolerance of the flexible CO_2 laser for office-based laryngeal surgery. J Voice 2010;24(6):750–754.

Koufman JA, Rees CJ, Frazier WD, et al. Office-based laryngeal laser surgery: a review of 443 cases using three wavelengths. Otolaryngol Head Neck Surg 2007;137:146–151.

Lippert D, Hoffman MR, Dang P, et al. In-office biopsy of upper airway lesions: safety, tolerance and effect on time to treatment. Laryngoscope 2015;125:919–923.

Shah MD, Johns MM. Office-based laryngeal procedures. Otolaryngol Clin N Am 2013;46:75–84.

Wang CT, Liao LJ, Huang TW, et al. Comparison of treatment outcomes of transnasal vocal fold polypectomy versus microlaryngoscopic surgery. Laryngoscope 2015;125:1155–1160.

Zalvan CH, Brown DJ, Oiseth SJ, et al. Comparison of trans-nasal laryngoscopic office based biopsy of laryngopharyngeal lesions with traditional operative biopsy. Eur Arch Otorhinolaryngol 2013;270:2509–2513.

2 Phonomicrosurgery for Benign Vocal Fold Lesions

Clark A. Rosen, Libby J. Smith

INTRODUCTION

Patients complaining of hoarseness, vocal fatigue, diminished vocal range, strain, or other vocal issues require a complete laryngeal examination. Based on the findings of this examination, several treatments may be indicated, including surgery. Phonomicrosurgery (PMS) encompasses a variety of elective operations whose primary goal is to improve the quality of the voice. These procedures focus on precision microsurgical techniques to remove benign vocal fold lesions, while not disrupting surrounding normal tissue. Hirano's body cover theory of vocal fold vibration is paramount in the design of current microsurgical principles and surgical procedures.[1] The delicate interface between the mucosa (cover) and the deeper lamina propria layers and muscle (body) allows for the creation of a mucosal wave (Fig. 2.1). Alterations in the muscosal wave result in dysphonia. Stroboscopy, which provides vital information about the mucosal wave, is absolutely essential in the evaluation of dysphonic patients. Wound healing is optimized by preserving the mucosa whenever possible and limiting surgery to the vocal fold layers involved with pathology (staying as superficial in the vocal fold as possible). The higher content of fibroblasts in the vocal ligament may result in increased scar deposition if surgery extends to this region.[2] Fortunately, the majority of bilateral vocal fold lesions are located within the superficial lamina propria, resulting in expected better postoperative mucosal wave vibration, and thereby likely improving vocal outcomes. Our improved knowledge of vocal fold microanatomy and the use of stroboscopy have led to improved patient care and surgical advancement in PMS.

Sound is the product of subglottic airflow forcing closed vocal folds to open, thereby leading to the generation of a mucosal wave along the medial edge of the vocal fold. Closure of the vocal folds during this vibratory cycle is achieved by the inherent elastic recoil of the vocal fold and the Bernoulli effect. This is called the myoelastic aerodynamic theory of phonation. This cycle usually occurs 100 to 1200 times per second. A mass on the vocal fold can disrupt this normal process and lead to hoarseness and other vocal complaints. Therefore the use of stroboscopy, which allows visualization of the mucosal wave, is indispensable in the care of these patients. Depending on the patient's history and laryngeal examination, either flexible transnasal laryngoscopy with stroboscopy (vocal fold motion abnormalities), or rigid, per-oral, endoscopy with stroboscopy (lesions), or both may need to be performed to fully evaluate the larynx. Such laryngeal examinations will provide the surgeon with an idea of the depth and type of the lesion. Although all vocal fold lesions are sent to pathology for evaluation, it is difficult for pathologists to distinguish between various vocal fold lesions based on their histologic characteristics. Precise classification of benign vocal fold lesions is therefore based on the surgeon's evaluation in the operating room, including magnification with the operating microscope, palpation of the vocal fold, identification of the physical features of the lesion or lesions, such as a cystic or fibrous mass, and location of the pathology.[3]

KEY OPERATIVE LEARNING POINTS

- The key surgical anatomy related to PMS for benign vocal fold lesions involves the layered structure of the membranous true vocal fold.
  - Major components to the layered structure of the vocal fold
    - Epithelium
    - Lamina propria
    - Muscle (thyroarytenoid-lateral cricoarytenoid)
  - The most medial aspect of the muscle that runs from the vocal process of the arytenoid to the thyroid cartilage is named the vocalis muscle.
- Excluding epithelial diseases of the vocal folds, all benign vocal fold lesions arise within the lamina propria, which can be defined as the anatomic space between the epithelium and the muscle of the vocal fold. There are anatomically (or histologically) three distinct layers of the lamina propria.
  - Superficial layer
  - Intermediate layer
  - Deep layer
    - The intermediate and deep layers, also called the vocal ligament, are not surgically distinct.
- From a surgical perspective, there are two key operative locations within the lamina propria
  - Subepithelial space
  - Ligamentous region
- The mucosa of the vocal fold is defined as being composed of the epithelium and the superficial layer of the lamina propria.
- The majority of benign vocal fold lesions occur within the subepithelial space. The most common pathology that occurs in this region includes[4]:
  - Vocal fold nodules
  - Vocal fold polyp(s)
  - Subepithelial cyst(s)
  - Subepithelial fibrous mass(es)
  - Reinke edema
- Lesions that occur in the area of the vocal fold ligament include:
  - Ligamentous vocal fold cyst(s)
  - Ligamentous fibrous mass(es)
  - Rheumatologic lesion(s)[3]
- The majority of benign vocal fold lesions occur in the midportion of the membranous vocal fold, which is positioned halfway between the anterior commissure and the vocal process of the true vocal fold.

TYPES OF BENIGN VOCAL FOLD LESIONS[3]

- Vocal Nodules

Vocal nodules are benign bilateral lesions, not always symmetrical, located within the lamina propria, with normal overlying epithelium. The mucosal wave is normal or near-normal. They are typically located at the midpoint of the musculomembranous vocal fold. Breathy and raspy dysphonia is the result of incomplete vocal fold closure. Vocal nodules tend to occur in patients who use their voices aggressively (i.e., children,

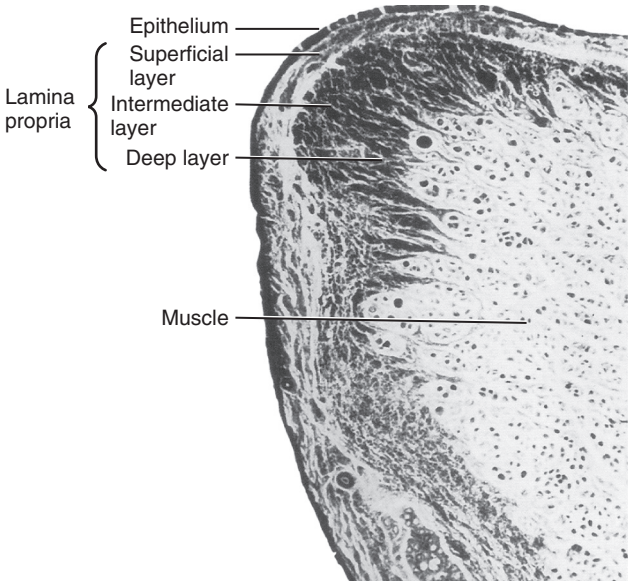

Fig. 2.1. Cross-sectional view of a vocal fold demonstrating layers of the vocal fold lamina propria. *(Reprinted with permission from Hirano M: Clinical Examination of Voice. New York: Springer-Verlag; 1981, p 5.)*

cheerleaders). After the inciting phonotraumatic behavior is eliminated and voice therapy is implemented, these lesions always resolve. Accordingly, surgery is not indicated for vocal nodules.

- Nonspecific Vocal Fold Lesion(s)

These vocal fold lesions are similar to vocal fold nodules. However, these lesions persist after voice therapy, despite resolution or significant improvement of the patient's dysphonia. Because the patients' dysphonia resolves and the lesions are benign, no surgery is indicated.

- Vocal Fold Polyp

A vocal fold polyp is located in the subepithelial space, usually at the midpoint of the musculomembranous vocal fold. It is generally unilateral, sometimes with a contralateral reactive lesion. A vocal fold polyp can be sessile (broadly attached to a vocal fold) or pedunculated (hanging from a stalk). This lesion is believed to be the product of intense phonotrauma or vocal fold hemorrhage. Inflammatory agents, dehydration, hormone treatment, and anti-inflammatory medications may be predisposing factors. Truncation or microflap excision is performed for a vocal fold polyp if the voice is functionally impaired after conservative therapy.

- Vocal Fold Cyst

A vocal fold cyst, both subepithelial and ligamentous, is often unilateral and located at the edge of the midmusculomembranous portion of the vocal fold. The encapsulated structure is thought to be due to glandular duct blockage or phonotrauma or may be congenital. The mucosal wave is more reduced with a ligamentous vocal fold cyst. Proper voice use and voice therapy are often the initial treatments. If this is not adequate to meet the vocal demands of the patient, microflap excision is performed.

- Fibrous Mass

A fibrous mass is composed of irregular fibrous material without clearly defined borders. This lesion can occur in either the subepithelial space or near the ligament of the vocal fold, both with normal overlying epithelium. This mass is often located in the midmembranous vocal fold, either unilateral or bilateral, and therefore incomplete vocal fold closure is common. Unilateral lesions are frequently associated with a contralateral reactive lesion. Development of a fibrous mass is often associated with chronic phonotrauma or hemorrhage. Voice therapy is often the initial treatment. If this fails, surgical excision with a microflap technique is indicated.

Subepithelial fibrous mass(es) have a reduced mucosal wave but not usually as severely reduced as ligamentous fibrous mass(es). When deep dissection is needed to excise these lesions, there is a greater risk of reduced postoperative voice improvement than with more subepithelial fibrous masses.[4]

- Reactive Lesion

Reactive lesions are believed to result from altered contact forces from a primary contralateral lesion, such as a polyp, cyst, or fibrous mass. Videostroboscopy will demonstrate a convex lesion (primary lesion) that fits into a concave reactive lesion (secondary lesion). This lesion can be surgically removed at the same time the primary lesion is removed or left to resolve during the postoperative period. This decision is based on the surgeon's preference and experience.

- Reinke Edema (Polypoid Degeneration, Diffuse Polyposis, Chronic Polypoid Corditis)

Reinke edema involves the deposition of gelatinous material within the subepithelial space. It is usually bilateral but may be asymmetrical or unilateral. These patients' voices are lower in pitch and dysphonic. Clinically, women are affected more often by Reinke edema; however, this may be due to selection bias because women are more bothered by lower vocal pitch and roughness and thus are more prone to seek treatment. The largest risk factor is smoking, followed by reflux and phonotrauma. When the pathologic accumulation is severe, airway obstruction can occur. Primary treatment is to remove the offending agents that led to the development of Reinke edema. Smoking cessation is vital. Voice therapy can occasionally be helpful if the probable cause is phonotrauma. Only after several months of compliance with smoking cessation and other conservative treatments (acid suppression and voice therapy) should surgery be considered, except in the case of airway obstruction. Conservative removal of a portion of the gelatinous material is achieved through a lateral cordotomy on the superior aspect of the vocal fold, followed by suctioning and/or near complete removal of material from the subepithelial space and excision of redundant tissue. Care must be taken because overly aggressive removal of redundant superficial lamina propria will lead to scarring and permanent hoarseness. Laser treatment with the potassium titanyl phosphate (KTP) laser may be a reasonable alternative treatment option.[5]

PREOPERATIVE PERIOD

History

- Dysphonia
  - Speaking voice
  - Singing voice
- Vocal fatigue
  - Speaking voice
  - Singing voice
- Diminished singing range
  - Upper
  - Lower
  - Passaggio (transition from chest to head voice)

- Vocal strain
- Increased effort
  - Speaking voice
  - Singing voice
- Voice use history and demands
  - Speaking voice
  - Singing voice

Physical Examination

- Examination of the head and neck
- Specialized examination of the larynx
  - Flexible laryngoscopy ± rigid laryngoscopy
  - Stroboscopy
    - Evaluation of the vibratory margin so that the vibratory effects of the lesion(s) can be determined. Alteration or diminution of the mucosal wave (vibration along the medial/vibratory margin) leads to dysphonia.
    - This view also allows the clinician to look for associated vocal fold scar(s), which may be an important comorbidity and negatively impact surgical outcome.

Imaging

- Radiologic imaging is very rarely indicated.

Indications

- PMS is an elective procedure. The risks and benefits of surgery should be clearly explained to the patient.
- The patient's vocal limitations (speaking and singing) should be thoroughly reviewed, especially in relation to the vocal requirements of occupational, avocational, and social demands.
- This review process is often conducted over a period of several weeks and involves the patient, the family, a speech therapist, and possibly a singing voice specialist.
- After all nonsurgical therapies (when appropriate) have been exhausted and still more is required of the patient's voice, only then is it appropriate to proceed with PMS.

Contraindications

- Poor patient compliance with voice therapy and/or future healthy voice use
- Inadequate time postoperatively for voice rest and reduced voice use
- Severe comorbidities

Preoperative Preparation

- Preoperative voice therapy is very important in preparing the patient for surgery. One to two sessions are often scheduled if the patient did not receive voice therapy before the decision to undergo surgery.
- Anticoagulant medications should be avoided preoperatively if medically possible.
- Smoking cessation is critical for improved postoperative healing.
- The patient should avoid vocal abuse and misuse preoperatively. These guidelines will prepare the patient and vocal folds for surgery.
- The need for an absolute voice rest (approximately 7 days) and reduced voice use (additional 7 to 10 days) after surgery should be discussed with the patient preoperatively. The amount of voice rest and restricted voice use is determined by the extent of surgery along the vibratory margin of the vocal fold (the medial portion of the vocal fold that makes contact with the other vocal fold during vibration).
- The patient should make the appropriate schedule changes to comply with the prescribed postoperative voice restrictions.
- If the patient has any laryngopharyngeal reflux symptoms (globus, throat clearing, excessive mucus, cough, heartburn[4]), proper acid suppression medications should be started several weeks before surgery. This may decrease the risk for postoperative wound-healing complications.
- Discussion of consent for PMS should include the risks associated with general anesthesia, infection, bleeding, dental injury, injury to the temporomandibular joint, and injury to the lingual nerve.[6]
  - A serious discussion between the patient and surgeon involving the small but real risk of no voice improvement or worsening of vocal function must take place before surgery.
  - Keeping in mind the elective nature of these surgeries, the patient must accept these risks.[7]

OPERATIVE PERIOD

Anesthesia

- Close communication between the surgeon and the anesthesia team is important for successful PMS.
- These procedures require general anesthesia, with complete relaxation of the patient throughout the procedure.
- Preoperative medications
  - Steroids (intravenous [IV])
  - Glycopyrrolate (Robinul) (unless contraindicated) will improve the surgical environment by minimizing swelling and secretions.
  - Acetominophen (IV)
  - Antiemetic agent if indicated
  - A small endotracheal tube (size 5.0 to 5.5) should be placed without the aid of a stylet.
    - Not only does the smaller tube improve visualization for the surgeon, but it also diminishes the chance of injury to the vocal folds during intubation.
    - If a vocal fold(s) is injured during intubation, the planned surgery may need to be postponed.
    - Stressing the importance of careful intubation is often facilitated by discussing the planned surgery with the anesthesia team before the procedure and by the surgeon being present during intubation.
    - If an endotracheal tube will obscure adequate visualization, jet ventilation can be used. Tracheal jet ventilation is preferred over supraglottic jet ventilation because there is no vibration of the operative site nor desiccation of the vocal fold tissues.

Positioning

- Patient positioning is critical to obtain the best visualization of the larynx.
- The optimal position is supine with the neck flexed and the head extended (Fig. 2.2).
  - Obese patients may require "ramping" to place their head and neck in an optimal position of large-bore laryngoscope placement.
  - This can be done with the use of a troop pillow (works best with taller patients).
  - Shorter patients who need "ramping" require multiple rolls of blankets under the shoulders and head to achieve body positioning so that the tragus is on an equal level with the sternal notch.

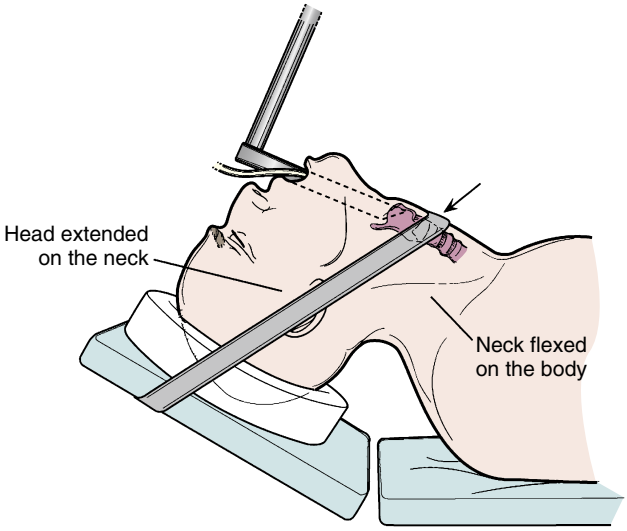

Fig. 2.2. Patient positioning for microsuspension laryngoscopy: neck flexion and head extension. "Arrows shows anterior neck pressure applied to enhance anterior commissure exposure".

Perioperative Antibiotic Prophylaxis

- Required only for mucosal surgery associated with a heart or orthopedic implant

Monitoring

- It is wise to assess for excess tongue pressure from the suspended laryngoscope and consider intermittent release from suspension.
- Persistent complete or near-complete muscle relaxation throughout the procedure is helpful, and thus intermittent monitoring of this is wise.

Instruments and Equipment to Have Available

- A chair for the surgeon that has support for the arms is essential. This chair should be able to be adjusted for height of the base, arm support, and back support. Frequently these types of surgical chairs can be found being used by ophthalmologists.
- Dental guard, standard athletic mouthpiece or custom made by patient's dentist
- Variety of different sizes and shapes of laryngoscopes
  - Large-bore laryngoscopes are vital for precise, detailed, and controlled microsurgery of the vocal folds.
  - Specialized laryngoscopes aid with visualization for patients with "difficult" laryngeal anatomy or when specific areas of the larynx are to be viewed for surgery (posterior commissure, subglottis).
- Laryngoscope suspension device: gallows or rotation/fulcrum. We feel that the former is superior because the vector of force is more advantageous than a rotation/fulcrum device (Lewy or chest holder), which allows a larger laryngoscope to be used with less risk of laryngoscope-related dental injury.
- 0-, 30-, and 70-degree (Fig. 2.3) rigid telescopes (5-mm diameter, approximately 22-cm length)
- A high-quality operating microscope with adjustable eye pieces
- Specialized PMS instruments that include very small scissors, forceps, knife, retratctors (triangular), suctions, and elevators. The working end of these instruments is usually between 1 and 2 mm in diameter.
- A video tower/camera connected to the telescopes and microscope not only aids in student teaching but also allows the operating room staff to know what the surgeon is doing.
- Lasers are of limited use in PMS. There is no distinct advantage to using a laser over a "cold steel" technique, especially in view of the risk of thermal injury and the cost of using a laser.

Key Anatomic Landmarks

- This subepithelial plane is where most benign vocal fold pathology is found, and working in this plane can minimize postoperative scar formation that occurs from dissection in the deeper aspect of the vocal fold layered structure.
- Subligament area is near or within the vocal ligament. Fibrous masses or cysts can occur here and represent a greater chance of postoperative scar tissue from extensive dissection in this area.

Prerequisite Skills

- Able to perform binocular, high-power microscopy
- Bimanual surgery

Operative Risks

1. Intubation injury: Close collaboration with the anesthesia team is needed. Intubation with a small endotracheal tube (i.e., 5.0 or 5.5, designed specifically for microlaryngoscopy) should be carefully placed under direct visualization to avoid inadvertent injury to the vocal folds. Not only can this type of injury be deleterious to the treatment of the lesion but more importantly with severe injuries can be catastrophic to long-term voice outcome.
2. Dental injury: Although rare, major dental injury (i.e., broken tooth) is ameliorated by proper dental protection. It must be noted if the patient has poor dentition, multiple missing teeth, or caps, because these situations increase the risk of sustaining dental injury.
3. Laser airway fire: In situations when a laser is used in treatment of a benign vocal fold lesion (papilloma, Reinke, leukoplakia), all laser safety precautions must be followed at all times: FiO_2 <40%, bulb syringe of saline within reach of the surgeon, wet towels over the patient's head, use of a laser-resistant endotracheal tube, moist pledget over the endotracheal tube cuff, and proper staff eye protection. All operating room staff must be trained in what to do in case of airway fire: turn off oxygen while removing the endotracheal tube, placement of saline into the airway, bronchoscopy to evaluate for injury, and then re-intubate.

Surgical Technique

- The teeth and alveolar ridge are protected with dental protection.
- The largest laryngoscope that can be accommodated should be placed because this allows the surgeon the best exposure while operating on the vocal folds.
- Suspension of the laryngoscope allows the surgeon to operate with both hands, which improves the level of precision achieved. Several suspension devices are currently available: gallows or rotation.
- Velcro or tape can be applied to the anterior aspect of the neck at the level of the cricoid or trachea to improve exposure.[8] Placement of anterior pressure on the thyroid cartilage should be avoided because it will reduce tension on the vocal folds, thereby making PMS more difficult.

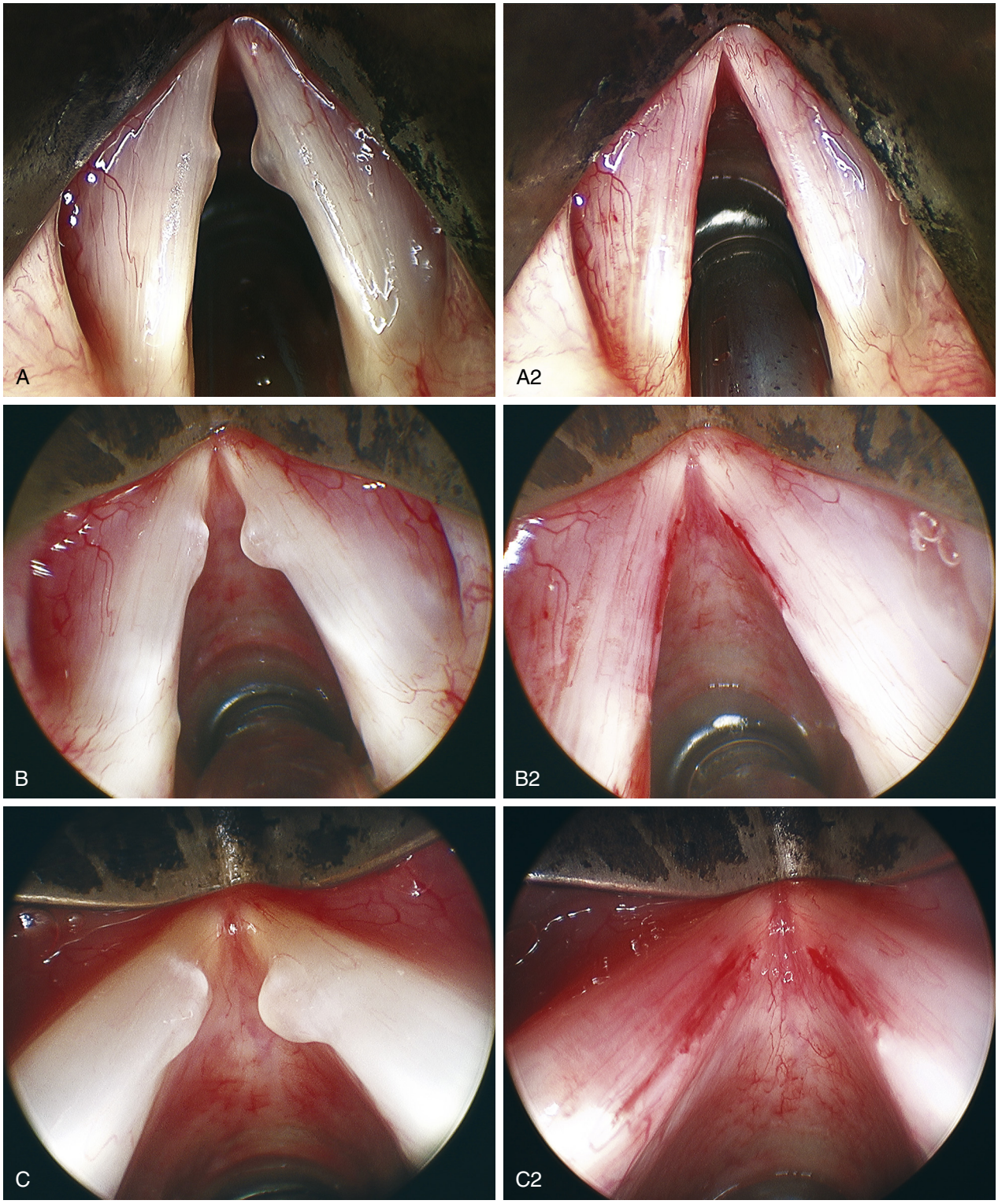

Fig. 2.3. Comparisons of preoperative views of the lesion and postoperative views after microflap surgery with 0-, 30-, and 70-degree telescopes. **A,** Preoperative view with a 0-degree scope. **A2,** Postoperative view with a 0-degree scope. **B,** Preoperative view with a 30-degree scope. **B2,** Postoperative view with a 30-degree scope. **C,** Preoperative view with a 70-degree scope. **C2,** Postoperative view with a 70-degree scope.

Surgeon Ergonomics

- After the patient and laryngoscope are in the operative position, attention should be made to address surgeon ergonomics during surgery.
- Taking a moment to achieve this, which usually requires the operating table to be placed into Trendelenburg position and the alteration of the height of the surgeon's chair, results in fewer musculoskeletal complaints from the surgeon and may improve surgical precision.
- Studies have shown that a favorable ergonomic position includes:
  - Laryngoscope angle of approximately 40 degrees from the horizon
  - Neutral surgeon neck position
  - Forearm stabilization and foot placement on the floor or stationary step[9]

Microflap

- The microflap technique historically involved an incision along the lateral aspect of the superior surface of the vocal fold, with subsequent medial dissection to the lesion. The lesion was then carefully dissected and removed, and the large, medially based microflap was put back into position. Scarring, denoted by decreased mucosal wave seen on stroboscopy, was found in the area of dissection. This observation led to modification of the procedure, with less scarring beyond the confines of the lesion. This new procedure was termed the mini microflap or medial microflap.[2,10]
- This modern microflap involves starting the dissection immediately lateral to the lesion and avoiding unnecessary dissection in healthy tissue. The term *microflap technique* will be used from here on to denote this newer, and more focused, procedure.
- The three guiding principles of microflap excision of subepithelial pathology are as follows:
  - Make the epithelial incision as close to the submucosal pathology (lateral) as possible.
  - Do not disrupt normal tissue surrounding the vocal fold pathology.
  - Stay in as superficial a plane as possible.
- Epinephrine (1:10,000 concentration) is often injected at the base of the lesion before making the incision to ensure hemostasis and to achieve hydrodissection for better identification of the proper surgical plane (submucosal plane).
- The incision, using a sickle or straight knife, is made through the mucosa over, or immediately lateral to, the lesion (Fig. 2.4). This diminishes damage to surrounding normal tissue.
- A small curved elevator is then used to develop the plane between the mucosal microflap and the pathology. It is often easier to develop this plane anterior or posterior to the lesion and then extend it over the lesion itself (Fig. 2.5).
  - This is the most difficult maneuver of microflap surgery and must be done with great patience and caution.
  - In situations with significant epithelial attenuation, such as with polyps, not all the epithelium can be preserved. In these cases, preservation of as much healthy epithelium as possible is attempted.
  - Development of a plane between the submucosal pathology and vocal ligament is often easier, except with vocal fold cyst(s) and fibrous mass(es) involving the vocal ligament.
- Small curved microscissors may be necessary to release fibrous bands between the microflap and submucosal pathology or between the submucosal pathology and the underlying vocal ligament. Once the submucosal pathology has been dissected, it is carefully removed and sent for pathologic examination (Fig. 2.6).
- After removal of the primary lesion, the microflap should be retracted medially, and visual inspection of the operative site should be performed to make sure no other abnormal tissue is present.
- The microflap is then redraped (Fig. 2.7). Upon completion of the microflap excision, the free edge of the vocal fold (leading edge, medial edge) should be palpated and visually completely straight, without concavities or mucosal tags (see Fig. 2.3).
- Hemostasis is achieved by injecting epinephrine (1:10,000) at the surgical site before incision and placing epinephrine-soaked pledgets during and after surgical removal of the lesion.

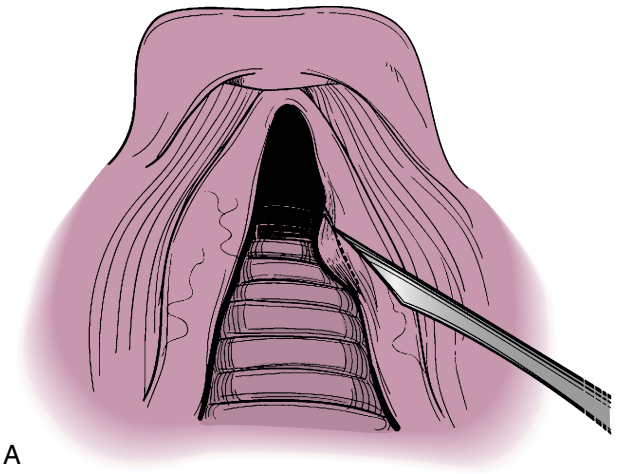

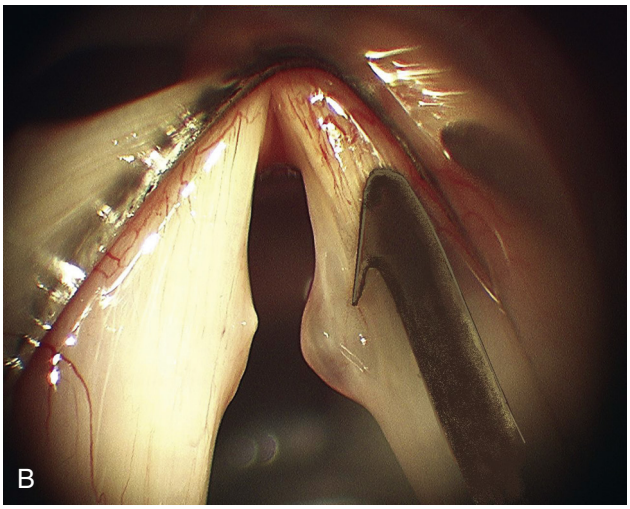

Fig. 2.4. A, Mucosal incision at the junction of vocal fold pathology and the superior surface of the vocal fold. **B,** Cordotomy at the lateral aspect of the lesion with a sickle knife.

Surgical Technique—Truncation

- Truncation (excision) of a vocal fold polyp is occasionally applicable. The lesion must be pedunculated. Indication for truncation versus microflap is severely abnormal epithelium surrounding the vocal fold lesion that would not be of any value to preserve with a microflap technique.
- Submucosal injection for hydrodissection is not recommended before truncation because it will obscure the desired excision location.

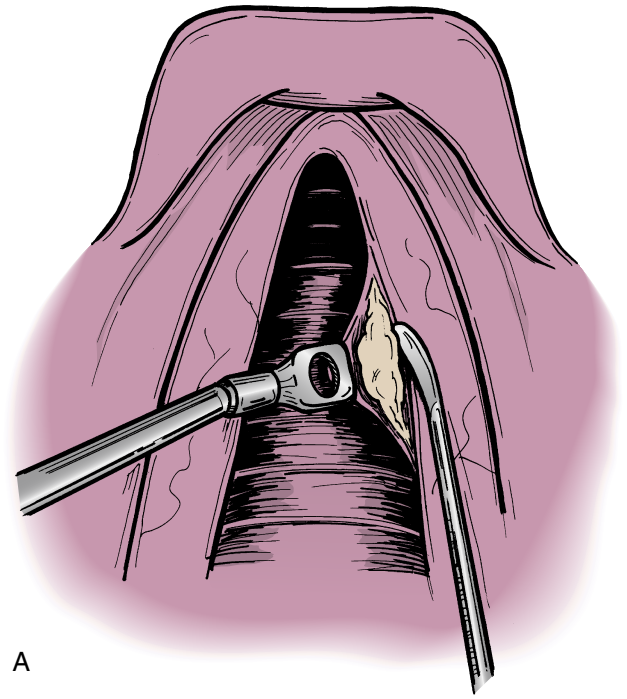

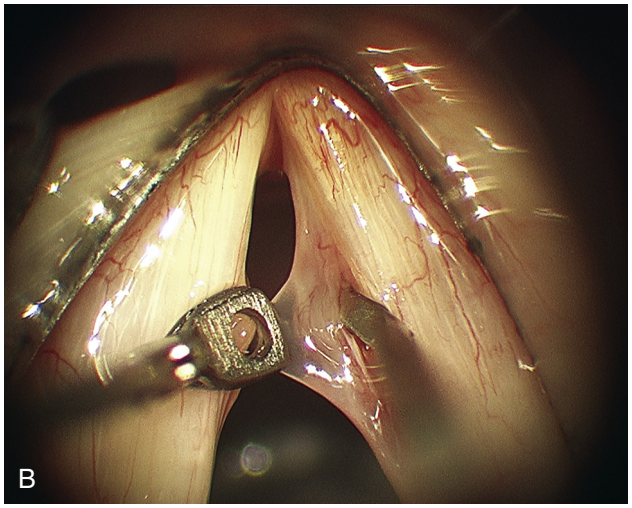

Fig. 2.5. **A** and **B,** Developing a plane with a blunt dissector between the lesion and deeper tissues.

- The pathology is grasped and gently retracted medially, and the stalk is cut at the level of the vocal fold mucosa (Fig. 2.8). A small epithelial defect will be produced.
- Great care should be taken to make sure that the truncation incision is precisely at the junction of the vocal fold pathology and the normal vocal fold free edge. Great care should be taken to not cut into the deeper aspect of the vocal fold during the truncation procedure.
- Hemostasis is achieved with pledgets soaked in epinephrine.

Common Errors in Technique

- Placing a small-bore laryngoscope resulting in suboptimal glottal exposure, which will negatively impact the precision of PMS
- Excessive resection of epithelium
- Placing the microflap incision too far lateral

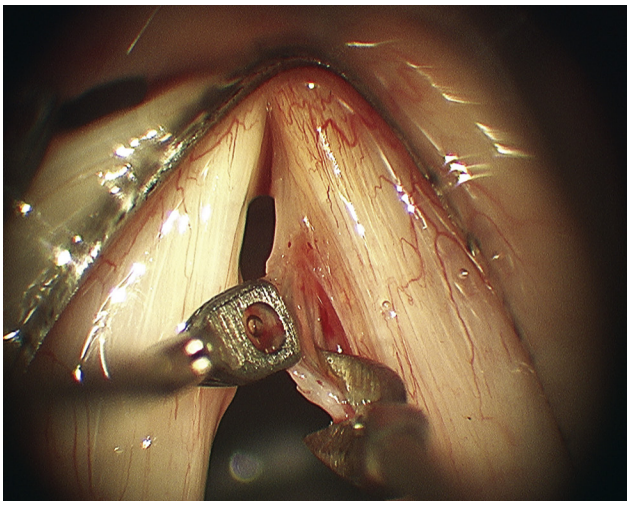

Fig. 2.6. Removal of the lesion and redundant mucosa.

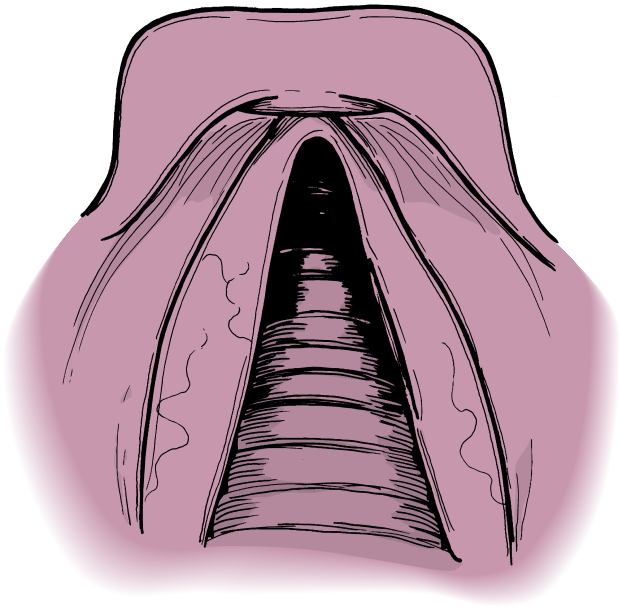

Fig. 2.7. Microflap redraped over the operative site.

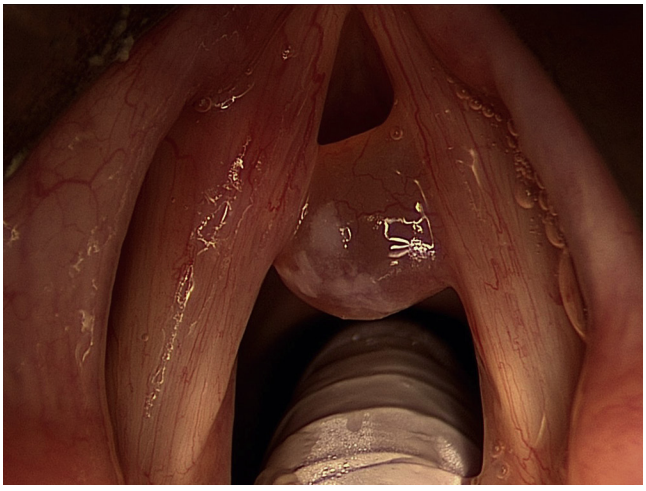

Fig. 2.8. Truncation of a vocal fold polyp *(dashed line).*

- Dissection deep to the lesion before performing the subepithelial dissection. This reduces the countertension that the surgeon relies on to perform the subepithelial dissection.
- Making the microflap incision too short, limiting exposure

POSTOPERATIVE PERIOD

Postoperative Management

- Voice rest is a component of almost every phonomicrosurgical procedure. Absolute (strict) voice rest can range from as short as 2 days to as long as 14 days. The length of absolute voice rest depends on the extent of surgery, patient compliance, and the surgeon's philosophy and past experience.
- Absolute voice rest consists of restrictions on the following activities: talking, whispering, whistling, straining, Valsalva maneuvers, coughing, and sneezing.
- Upon completion of strict voice rest, stroboscopy should be performed to evaluate the level of healing of the vocal fold surgical site. If there is adequate epithelial coverage, the patient is transitioned to light voice use (relative voice rest), usually defined as 5 to 10 minutes of breathy, "airy" voicing per hour. The quantity of voice use is then increased over the subsequent weeks, often with the help of a speech-language pathologist.
- Patients should continue taking acid suspension medications after surgery to aid in the healing process.
- Proper hydration is strongly recommended.
- Continued smoking cessation after surgery is important for maximal healing.
- Postoperative voice therapy is indicated in the majority of PMS patients, to not only optimize final voice quality outcome but to also reduce the chances of return to phonotraumatic behaviors that likely resulted in formation of the initial benign vocal fold lesion.

Complications

- Outcomes of PMS for benign vocal fold lesions are generally extremely good.[2] Akbulut et al. demonstrated that the majority of midmembranous benign vocal fold lesions have an excellent prognosis for patient-perceived improvement in voice. Following PMS, the majority of patients report perceived voice handicaps within the normal range except for ligamentous fibrous mass lesions of the vocal fold.[4] The incidence of restoring the individual to a normal Voice Handicap Index-10 (VHI-10) after surgical excision of the majority of benign midmembranous lesions, except for ligamentous fibrous masses, ranges from 50% to 67%. In addition, the mean postoperative VHI-10 for all of the midmembranous vocal fold lesions (except for ligamentous fibrous masses) surgically treated is less than 11, which suggests a normal perception of voice handicap as patients without voice complaints. Overall, voice outcomes are typically very favorable after PMS; however, it is important that individual responses may vary from the overall core responses referenced previously.
- The factors that determine the level of success following surgical treatment for benign vocal fold lesions typically include:
  - Proper preoperative care,
  - Patient compliance,
  - Surgical precision,
  - Postoperative patient wound healing factors, and
  - Postoperative voice therapy.
- Complications of PMS range from the actions taken to achieve adequate exposure, to technical surgical points, to untoward vocal outcomes.
- The potential for injury to the teeth increases when the patient has poor dentition or multiple missing teeth and when difficulty is encountered in obtaining proper exposure of the larynx. Frequently, these patients can be detected before surgery. Use of reinforced plastic dental guards or firm, moldable splint (i.e., Aquaplast) may mitigate the risk of dental injury.
- Injury to the lingual nerve (numbness of the tongue, change in taste sensation) occurs in approximately 10% to 20% of patients. This is due to pressure from the laryngoscope, which usually resolves within 4 weeks.[6]
- There is a 1% to 2% risk of no voice improvement after PMS, in addition to a 1% to 2% risk of the voice becoming worse after surgery.
  - This is often due to poor wound healing with scar formation and/or comorbid vocal fold scar associated with the vocal fold lesion.
  - If surgery requires deeper dissection into the vocal ligament, scar formation is likely.
  - There is currently no cure for vocal fold scarring, so inadvertent disruption of tissues deep to the superficial lamina propria is discouraged unless mandated by the pathology.
  - If the microflap is not appropriately draped over the surgical wound and therefore does not adhere to the vocal fold, epithelial ingrowth deep to the microflap may occur. Surgical excision of the microflap is then required.
  - Microflap necrosis and flap death can occur with excessive edema and trauma. Accordingly, the flap must always be treated with great care.
  - If necrosis of the microflap occurs, vocal fold healing on its own will take longer.
- Significant postoperative stiffness (scarring) can be treated with several monthly submucosal steroid injections, performed typically under local anesthesia, in an attempt to modify the wound-healing process.

Alternative Management Plan

1. Continued observation is an alternative choice of treatment for benign vocal fold lesions. This is a viable option for patients who are not bothered by their voice quality or it does not adversely affect their quality of life. Often serial, recorded examinations can be used to ensure that there is no progression of disease over time if no surgery is to be performed.
2. Prolonged voice rest is NOT a viable alternative management plan. Rather, it is critical to optimize the laryngeal mechanics of voicing to reduce adverse forces/tension during phonation. This is achieved through voice therapy and compliance on part of the patient. Voice therapy should be done by a dedicated speech-language pathologist who specializes in voice disorders.

DISCUSSION

Evidence-Based Medicine Question

Is there a voice-related treatment outcome difference between ligamentous fibrous mass lesions compared with other subepithelial benign midmembranous vocal fold lesion(s) (subepithelial fibrous mass, vocal fold polyp, vocal nodules, etc.)?

Yes.

Akbulut et al. found that the treatment outcomes for patients with a ligamentous fibrous mass were worse compared with other benign subepithelial midmembranous vocal fold lesions.[4] The difference in treatment outcome most likely

occurs from the more extensive surgical dissection in and near the vocal ligament and the nature of the pathology of the lesion.

Editorial Comment

Laryngeal examination with videostroboscopy provides essential information about the possible type and depth of benign vocal fold lesion(s) and is a core aspect to the evaluation and treatment of patients with benign vocal fold lesions. Preoperative voice care in the form of voice therapy and counseling for surgery is required for most patients and establishes a platform for success after surgery. Worsening of the voice after surgery or no voice improvement (1% to 2% of patients for each) is a real risk and must be discussed with the patient preoperatively. Rushing a patient to surgery before thorough evaluations by a physician and speech therapist is a disservice to the ultimate care of the patient and may downgrade the outcome of the procedure.

A clear understanding of vocal fold anatomy is needed to perform precise microflap surgical dissection. Close collaboration with the anesthesia team, proper patient and surgeon positioning, adequate laryngeal exposure, and proper instrumentation are vital for success.

Imprecise dissection into the deeper layers of the vocal fold (vocal ligament and muscle) will lead to scar formation and thus worse vocal outcomes. Dental injuries do occur, often as a result of poor dentition or improper placement of the laryngoscope. The gallows suspension is superior to a rotation/fulcrum suspension device in both exposure and minimizing dental injury.

Vyvy Young


Access the review questions and additional sources list online at http://www.expertconsult.com

REFERENCES

1. Hirano M. Structure and vibratory behavior of the vocal fold. In: Sawashima M, Cooper F, editors. Dynamic Aspects of Speech Production. Tokyo: University of Tokyo; 1977. p. 13–30.
2. Courey MS, Garrett CG, Ossoff RH. Medial microflap for excision of benign vocal fold lesions. Laryngoscope 1997;107:340–344.
3. Verdolini K, Rosen CA, Branski R. Classification Manual of Voice Disorders. Mahwah, NJ: Lawrence Erlbaum Associates; 2005. p. 36–56.
4. Akbulut S, Gartner-Schmidt J, Gillespie AI, et al. Voice outcomes following treatment of benign midmembranous vocal fold lesions using a nomenclature paradigm. Laryngoscope 2016;126(2):415–420. http://dx.doi.org/10.1002/lary.25488.
5. Young VN, Mallur PS, Wong AW, et al. Analysis of potassium titanyl phosphate laser settings and voice outcomes in the treatment of Reinke's edema. Ann Otol Rhinol Laryngol 2015;124(3):216–220. http://dx.doi.org/10.1177/0003489414549155.
6. Rosen CA, Andrade Filho PA, Scheffel L, et al. Oropharyngeal complications of suspension laryngoscopy: a prospective study. Laryngoscope 2005;115:1681–1684.
7. Zeitels SM, Hillman RE, Desloge R, et al. Phonomicrosurgery in singers and performing artists: treatment outcomes, management theories, and future directions. Ann Otol Rhinol Laryngol Suppl 2002;190:21–40.
8. Zeitels SM, Vaughan CW. "External counterpressure" and "internal distention" for optimal laryngoscopic exposure of the anterior glottic commissure. Ann Otol Rhinol Laryngol 1994;103:669–675.
9. Smith LJ, Trout JM, Sridharan SS, et al. Comparison of microsuspension laryngoscopy positions: a randomized, prospective study. Laryngoscope 2015;125(3):649–654. http://dx.doi.org/10.1002/lary.24932.
10. Sataloff RT, Spiegel JR, Heuer RJ, et al. Laryngeal mini-microflap: a new technique and reassessment of the microflap saga. J Voice 1995;9:198–204.

REVIEW QUESTIONS

1. Select which are not principles of good ergonomics for phonomicrosurgery:
   a. Neck and spine are aligned perpendicular to the floor
   b. Establish a solid base by having the feet supported.
   c. Keeping the arms near shoulder height
   d. Using adjustable eye pieces of the microscope, which are designed to minimize neck flexion or extension
   e. Placing the proximal aspect of the laryngoscope near the height of the surgeon's umbilicus

2. Select which is not an indication for phonomicrosurgery:
   a. Significant speaking voice limitations after maximum amount of nonsurgical therapy
   b. The patient's desire to have "straight edges" of the vocal folds
   c. Significant singing voice limitations after maximum amount of nonsurgical therapy
   d. Decreased pitch and roughness to the voice in a patient with Reinke edema
   e. Frequent voice loss due to a vocal fold lesion despite voice therapy

3. Select statements that apply to microflap surgery of the vocal fold:
   a. Care should be taken to conserve adjacent normal tissue.
   b. The most common plane of dissection is in the subepithelial space.
   c. Dissection deep to the vocal ligament is usually required.
   d. Answers a & b
   e. Answers a, b, & c

4. Appropriate surgical approach for vocal fold cysts and fibrous lesions includes which of the following?
   a. Vocal fold stripping
   b. Partial cordotomy
   c. Microflap
   d. Open lateral approach

5. With surgical excision of a vocal fold cyst, which of the following statements is correct?
   a. Deep dissection to remove the cyst and surrounding cuff of muscle is most appropriate to prevent recurrence.
   b. Stripping of the entire epithelial lining should be done first to better expose the cyst.
   c. Purposeful puncture and drainage of the cyst are helpful for dissection.
   d. Dissection of the superficial epithelium from the cyst prior to deeper dissection is easier and helps to prevent inadvertent tearing of the epithelium.

6. Which of the following patient-positioning techniques is NOT helpful for direct laryngoscopy?
   a. Head extension relative to the neck
   b. Neck flexion
   c. Neck extension with shoulder roll
   d. Patient with head positioned at the end of the bed with the articulated head board of the operating table

7. Which of the following is NOT a key component of phonomicrosurgery?
   a. Wide local excision for prevention of recurrence
   b. Conservative removal of submucosal pathology with preservation of overlying epithelium
   c. Use of high-powered visualization with a microscope
   d. Specialized microinstruments designed for the precision required to preserve the architecture of the vocal folds

8. A 36-year-old male has a left vocal fold exophytic lesion with normal overlying epithelium on examination with no other symptoms and no concerns with his voice or dyspnea. How would you manage this patient?
   a. Surgical removal with microflap
   b. Observation
   c. Surgical removal with wide local excision
   d. In-office biopsy

ADDITIONAL SOURCES

Arffa RE, Krishna P, Gartner-Schmidt J, et al. Normative values for the Voice Handicap Index-10. J Voice 2012;26(4):462–465. http://dx.doi.org/10.1016/j.jvoice.2011.04.006.

Rosen CA, Villagomez VJ. A unique complication of microflap surgery of the vocal fold. Ear Nose Throat J 2001;80:623–624.

Wong A, Baker N, Smith L, et al. Prevalence and risk factors for musculoskeletal problems associated with microlaryngeal surgery: a national survey. Laryngoscope 2014;124(8):1854–1861. http://dx.doi.org/10.1002/lary.24367.

3 Recurrent Respiratory Papillomatosis

Thomas L. Carroll, Anju Patel

INTRODUCTION

Recurrent respiratory papillomatosis (RRP) is a rare viral-induced disease of the upper aerodigestive tract characterized by epithelial lesions. Caused by human papillomavirus (HPV), this disease presents in both children and adults.[1] RRP is considered a benign neoplastic process; however, the disease can lead to significant morbidity and fatal complications, and there is a risk for RRP to transform into an epithelial malignancy (Fig. 3.1).[2]

The prevalence of RRP is approximately 4 in 100,000, with nearly 2000 pediatric cases diagnosed yearly.[1] Juvenile-onset RRP is typically diagnosed prior to age 5 and is considered more "aggressive" than adult-onset RRP, due to the significant impact the RRP lesions can have on the small pediatric airway.[2] In the United States, affected children may undergo more than four procedures yearly and on average nearly 20 in their lifetime.[1] Adult-onset RRP presents most commonly between 20 and 40 years of age (although it can present at any age), with a higher propensity in men. It also typically has a more indolent course with high remission rates.[3]

There are more than 100 HPV subtypes, though HPV 6 and 11 are most commonly associated with RRP. HPV 11 is typically more aggressive in disease progression. Less frequently, HPV 16 and 18 have been linked to RRP, though there is a higher rate of malignant transformation noted with these subtypes.[2] Vertical transmission is seen in juvenile-onset RRP. The route of transmission is not clearly known. Arguments have been made for hematogenous, intrauterine, and direct contact in the birth canal, as patients with juvenile-onset RRP are typically first born and vaginally delivered. Adult onset is associated with reactivation of pediatric disease or secondary to a sexually transmitted disease.[1]

It is theorized that microtears in the epithelium or co-infection with other microbes allows entry of HPV into the body. For example, increased cervical HPV rates are associated with concurrent *Trichomonas vaginalis* infections. These infections are believed to weaken the tight junctions of epithelial cells.[3] Phonotrauma has been speculated as the etiology for entry into the vocal folds. After this occurs, an immune response is formed, and most individuals are able to clear the infection over the span of 2 years.[3] Five percent of the population has HPV DNA identified in the larynx, though significantly fewer actually display findings consistent with RRP. The mechanism behind this remains unclear.[3] Various factors including epidermal growth factor receptor, cyclooxygenase-2, and prostaglandins are overexpressed in papillomas, and this is currently an area of research for further treatment.[3]

Spread beyond the larynx is associated with increased morbidity and mortality and found in 30% of children and 16% of adults with RRP.[1] The most common sites of extralaryngeal spread include the oral cavity, trachea, and bronchi. Development of pulmonary RRP is linked to high mortality, despite aggressive medical and surgical management.[3]

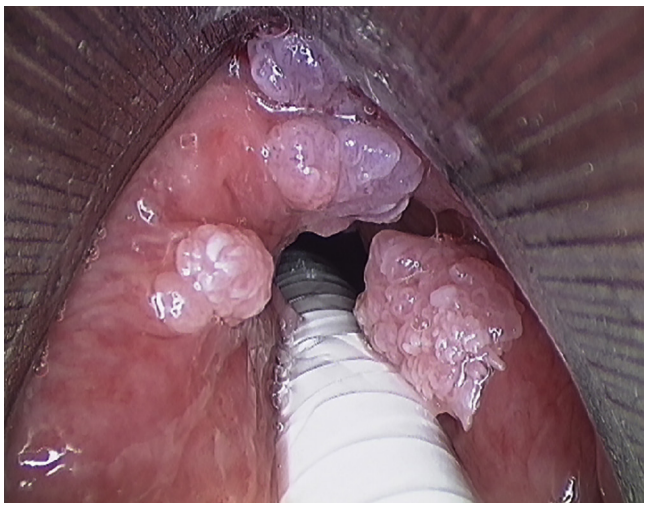

Fig. 3.1. Recurrent respiratory papillomatosis (RRP) of supraglottis and true vocal folds. Notice the frondlike appearance of a typical RRP lesion in this operative view.

KEY OPERATIVE LEARNING POINTS

1. Potassium titanyl-phosphate (KTP) laser offers lesion excision, which is especially advantageous for awake, in-office treatment approaches but is also highly effective when used in the operating room (OR).
2. CO_2 laser and cold knife excision can be employed.
3. Office-based KTP laser is an effective method of removing the lesions and restoration of the voice.
4. Microdébriders can be used for bulky disease in the operative setting but should be used less preferentially in the supraglottis and/or subglottis.

PREOPERATIVE PERIOD

History

1. Hoarseness without periods of clarity
2. Progressive stridor, cough, dyspnea
3. Recurrent pneumonia may be an indicator of pulmonary involvement.
4. Maternal or paternal history of genital warts
5. Immunization history

Physical Examination

1. Voice evaluation
   a. Voice evaluation by a speech language pathologist (SLP) can establish a baseline from which to improve. The patient may require voice therapy after or between surgical procedures, and input from an SLP on the initial visit is helpful. However, voice therapy during active treatment is not usually helpful.
2. Vocal tract endoscopy
   a. Endoscopy, either through a flexible laryngoscope or 70-degree Hopkins rod, can delineate the extent of disease. Flexible endoscopy affords a view of the nasopharynx, which can often demonstrate concurrent RRP lesions on the pharyngeal surface of the soft palate.

Laryngovideostroboscopy can be used as an adjunct to identify more sessile lesions or early recurrences. Chip tip flexible endoscopy can offer better visualization of vascularity and surface contours that often accompany RRP. This technology uses charge-coupled device chips to create digitally based images for endoscopy. Light filters can be employed diagnostically or as an adjunct to office-based KTP laser ablation of RRP.

3. Tracheoscopy
   a. In-office evaluation for extralaryngeal disease can be helpful for preoperative planning. Intubation may not be the best choice if subglottic lesions exist, and jet ventilation would need to be pursued.
4. Auscultation of the lungs

Imaging

Chest radiograph: Not typically indicated but could be used to identify pulmonary disease secondary to obstructive RRP lesions in the lower airways

Computed tomography: Not usually performed unless there is a concern for pulmonary involvement

Additional Testing

1. Pulmonary function tests (PFTs) if there is a concern for pulmonary involvement. Flow loops may be helpful, if there is stridor or dyspnea but no visualized laryngeal disease. It would be used as an adjunct to laryngoscopy and tracheobronchoscopy in cases of more extensive disease.

Indications

1. Dyspnea
2. Dysphonia
3. Globus sensation

Contraindications

None necessary

Preoperative Preparation

1. Discontinue anticoagulant and antiplatelet drugs for 1 week, if possible.
2. Consent for complications: Worsened voice, persistent dyspnea, need for further surgery, infection, injuries associated with suspension laryngoscopy (dental injury, mucosal injury, taste change; see Chapter 2)

OPERATIVE PERIOD

Anesthesia

OR: General, 5.0 microlaryngoscopy endotracheal tube (start with a laser-safe tube if planning on using a laser). This affords good airway control while providing unobstructed visualization of the glottis (see Chapter 2).

Office: Topical 4% lidocaine (techniques includes oxymetazoline-lidocaine spray to bilateral nares, insertion of cotton pledgets soaked with 4% lidocaine, nebulizer treatment with 4% lidocaine, topical drip of 4% lidocaine through a channel scope or with an Abraham cannula (see Chapter 1).

Positioning

OR: Supine, small round headrest, no shoulder roll, neck flexion may be useful if the larynx is very anterior

Office: Sniffing position, which has the patient rest his or her elbows on thighs, chin out, and nose out as if sniffing a flower

Perioperative Antibiotic Prophylaxis

None necessary

Monitoring

OR: Per anesthesia protocol

Office: Preprocedure vital signs. Brief monitoring for 15 to 20 minutes postprocedure in the waiting room is acceptable; no formal postprocedural monitoring or intraprocedure monitoring is used.

Instruments and Equipment to Have Available

1. KTP laser (or CO_2 laser with pattern generator)
2. Laser precaution equipment
3. Microdébrider (OR)
4. Microlaryngeal instruments
5. Suspension microlaryngoscopy setup
6. Microscope with 400 mm lens
7. Operating chair
8. Laryngotracheal anesthesia
9. Channel flexible laryngoscope (office procedure)

Key Anatomic Landmarks

Anterior commissure: Should be visualized at the time of surgery to evaluate for RRP and also monitor and minimize trauma

Prerequisite Skills

1. Flexible laryngoscopy
2. Direct laryngoscopy

Operative Risks

1. Injury to normal laryngeal structures
2. Intraoperative airway fire
3. Suspension laryngoscopy: Dental injury, mucosal injury, metallic taste. Numbness of the tongue may occur and typically resolves spontaneously over 2 to 6 weeks.[4]

Surgical Technique

- OR: Turn the bed 90 degrees. Keep the bed level with a headrest under the head. Apply a tooth guard to protect the maxillary dentition. All exposed facial and upper body skin are covered with wet towels if a laser is to be used. Airway evaluation should now be performed with examination of the oral cavity, oropharynx, hypopharynx, endolarynx, subglottis, and trachea to accurately stage the sites and extent of disease. Use the largest laryngoscope possible. Advance the laryngoscope until optimal exposure of the endolarynx is achieved. Suspend the laryngoscope. Use angled telescopes in 0, 30, and 70 degrees to (1) map out all RRP disease locations and nature, and (2) take photographic documentation. This helps in visualizing the locations of the lesions. The ventricle, undersurface of the vocal folds and anterior and posterior commissures are best visualized with 30- and 70-degree telescopes. The operating microscope is then brought in to further visualize the affected regions. A ½-by 3-inch pledget soaked in saline is placed in the subglottis above the endotracheal tube cuff if the CO_2 laser is to be

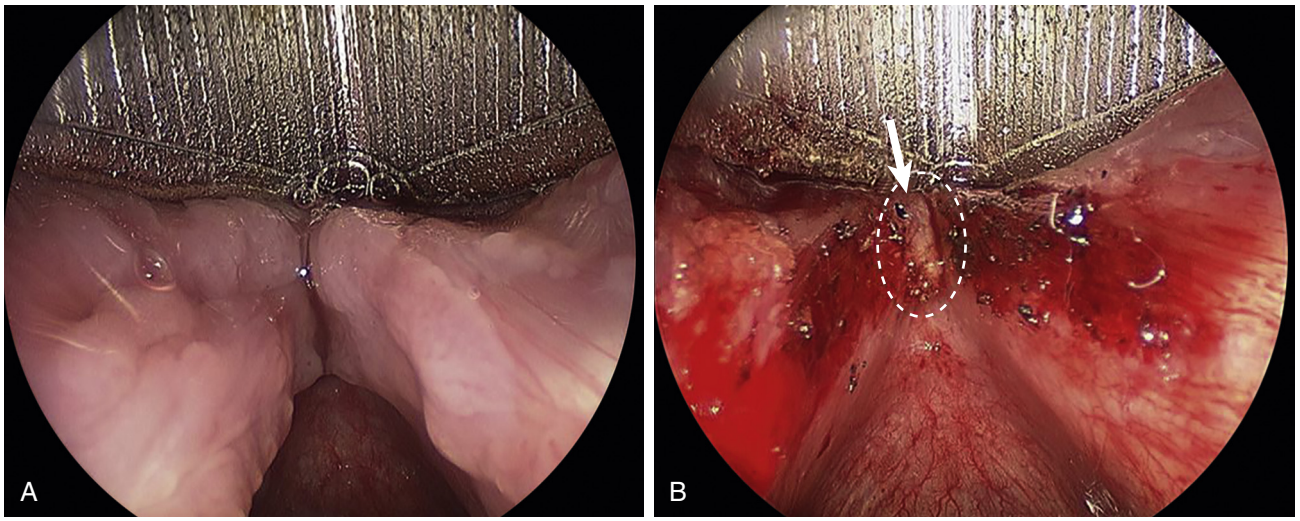

Fig. 3.2. Staging of recurrent respiratory papilloma (RRP) removal from the anterior commissure. **A,** Intraoperative photograph before RRP removal. Notice bilateral anterior commissure lesions. **B,** After right-sided RRP removal. Lesions are intentionally not removed from the left anterior commissure to prevent formation of an anterior glottic web (*arrow* and *circled area*).

used. A small amount of papilloma is excised with cold instruments and sent for biopsy. The remaining papillomas are now removed using the surgeon's method of choice:

- KTP laser removal of RRP can be done in several methods.[5]
  1) KTP removal of RRP (outside-in)
     To minimize the risk of thermal injury to the vocal fold while using the KTP laser for removal of RRP, the KTP laser is fired directly at the RRP, with the laser energy and working distance adjusted to result in a "blanching" effect on the RRP with the KTP laser energy. If the surgeon feels that this treatment effect, KTP-1, will be adequate, then the KTP treatment is done. Additional KTP laser energy can be applied to the operative site, which will cause small epithelial "craters" (i.e., disruption of the epithelium of the RRP tissue). Often this KTP-2 treatment effect will be sufficient for successful RRP treatment. If the RRP is bulky, additional KTP laser energy can be applied (often with laser fiber direct contact), resulting in a KTP-3 treatment effect. If the surgeon's goal is complete removal of the RRP at the time of surgery, after the entire area of RRP has been "blanched" from a conservative and minimal KTP laser energy delivery approach, a suction (5 or 7 French) is used to remove the treated RRP surface. If there is additional RRP present after the treated disease has been removed by suction or cup forceps, the same use of the KTP laser can be employed until there is no gross RRP present at the operative site (KTP-4).
  2) KTP removal of RRP (inside-out)
     Working within the plane between the papilloma and the normal underlying true vocal fold tissue, the lesions can be removed in their entirety while staying as superficial as possible. The KTP laser is often used for areas of minimal disease and can be time consuming if used in an angiolytic fashion. Alternatively, it can be used to remove bulky lesions via a dissection technique that seeks to achieve KTP-4 laser effects.[5] This focuses on ablation of the interface between the normal vocal fold and RRP: Use settings of approximately 30 to 35 watts, 15 millisecond pulse width, and 2 to 3 pulses per second. Beginning at an area of transition between RRP and normal epithelium, the laser can be used to blanch this area until it can be sloughed off with another tool such as suction. Once this plane is established, dissection of the tissue can be performed along the entirety of the undersurface of the lesion (see Video 3.1).
     - "Cold steel" may be used to dissect just below the epithelium and remove the RRP lesion, trying to preserve as much lamina propria as possible.
     - CO_2 laser with pattern generator may also be considered when available and used to ablate the lesions.
     - The microdébrider can be employed to remove bulky lesions and especially above and below the true vocal folds; however, it is not recommended to be used aggressively on the true vocal fold. Often the microdébrider is employed to debulk, and the KTP laser or cold steel can resect the lesions on the true vocal fold tissue.
     - Oxymetazoline or 1:10,000 epinephrine-soaked pledgets are used for hemostasis. At the end of the procedure, laryngotracheal anesthesia is sprayed into the endolarynx for topical anesthesia.
     - Care must be taken at the anterior commissure of the vocal folds. Leaving some residual RRP on one side and staging the surgery into two parts is often employed to avoid a laryngeal web. Alternatively, when using KTP or CO_2 laser, a small amount of RRP can be blanched but left in place (not suctioned off) on one side of the anterior commissure to slough on its own (Fig. 3.2).
- Office: Fig. 3.3 and Video 3.2. Apply anesthetic as instructed previously. (It is optional to place a 14-French nasogastric tube through one nostril and attach it to suction to remove plume during surgery if the patient can tolerate it.) Laser safety precautions should be taken. Thread KTP laser fiber through channel scope. Using a setting of 30 to 35 watts, 2 pulses per second, and a 15 millisecond pulse width, ablate papillomas as tolerated from a patient standpoint. Ideally this technique is used for recurrent lesions or as a staged procedure after the initial biopsy or total surgical removal or for very limited initial lesions.
  - KTP laser treatment effects are described using a five-point classification system[5]:
    - KTP V, noncontact angiolysis
    - KTP 1, epithelial blanching
    - KTP 2, epithelial disruption
    - KTP 3, contact epithelial ablation
    - KTP 4, contact epithelial ablation with tissue removal



Fig. 3.3. In-office potassium titanyl-phosphate (KTP) laser use. The availability of office-based treatments of recurrent respiratory papilloma with KTP laser has revolutionized the management of this disease. The patient can be seated comfortably and be given topical anesthesia, and the surgeon can accomplish in 5 minutes what typically would take an hour or more in the operating room.

Common Errors in Technique

1. Suboptimal exposure due to incorrect placement of the laryngoscope: Ensure that the head and neck are in good placement (neck flexion, head extension), adjust the laryngoscope to the optimal depth such that the anterior commissure can be visualized, and use adhesive tape to apply anterior cricoid pressure if needed.
2. Deep dissection: Deep, cold knife dissection or aggressive CO_2 laser used in a cutting rather than ablative fashion can lead to poor voice outcomes, especially after multiple surgeries due to scar formation in the lamina propria. With the advent of new technologies and techniques, RRP surgery can preserve the voice. Injury from laser heat (i.e., depth of penetration of laser energy) must be considered; the voice may suffer with delayed recovery of lamina propria vibration and possibly permanent scar tissue formation.
3. Patient tolerance of awake, unsedated KTP laser procedure: Nasal anesthesia is most important. Allow the cotton pledgets soaked in lidocaine to remain in the nose for at least 5 minutes. Confirming laryngeal anesthesia by touching areas to be treated with a drip catheter or scope before starting to use the laser helps reassure the clinician of appropriate topical anesthesia. The patient will feel the laser if the surgeon works for too long in one area. The surgeon should change locations to another area of RRP if the patient is uncomfortable during the laser procedure.

POSTOPERATIVE PERIOD

Postoperative Management

1. Initial 4- to 6-week postoperative follow-up
2. Office-based KTP laser procedures for recurrences to avoid another OR procedure
3. Adjust frequency of visits based on recurrence rate or if the location of the disease is impacting voice or breathing.

Complications

1. Worsened voice or breathing due to glottic or subglottic stenosis: May require further surgery to address the area of scarring, though this is a very difficult problem to treat, especially in the setting of active RRP. Anterior glottic webs are the most common scars to form as a result of aggressive, anterior, and bilateral resection with any of the previously listed methods, including KTP laser. This can be prevented by leaving a small area on one side of the anterior commissure with untreated RRP (with a plan to remove on "staged" second look in OR or in office) or ablated/blanched RRP but not removing it or sloughing it off with the suction.

Alternative Management Plan

1. Cidofovir: Antiviral medication that is an adjunct treatment to surgery. It is injected intralesionally and used in an off-label manner. It selectively inhibits viral DNA polymerase and stops viral replication. This medication gained popularity in the 1990s because it increases time intervals between treatments. Patients should be informed that studies in rats with very high-dose exposure have demonstrated an increased rate of malignant transformation. The RRP Task Force indications for cidofovir use include the need for six or more surgeries yearly, increasing frequency of surgeries, and extralaryngeal spread.[6] The recommended dose is approximately 2 mL in children and 4 mL in adults of a 5 mg/mL solution every 2 to 4 weeks, for a trial of 3 to 5 injections.[2] Minimal medication is noted in the serum during and after the procedure.
2. Interferon: Nonspecific regulatory proteins that have antiviral, antiproliferative, and immunomodulating activities. This is a systemic therapy given via subcutaneous injection. Side effects include neuropsychiatric changes and bone marrow suppression. Altered hormone levels may lead to infertility. Effective therapy has been documented; however, a rebound effect occurs once therapy is stopped.[7]
3. Bevacizumab (Avastin): An adjunct treatment to surgery. It is a chemotherapeutic agent that consists of recombinant humanized monoclonal immunoglobulin G1 antibodies that inhibits endothelial growth factor, also injected intralesionally.[8]
4. Indole 3-carbinol (I3C): Compound derived from cruciferous vegetables such as broccoli, brussel sprouts, cabbage, and cauliflower. I3C can also be found as an over-the-counter supplement. It affects cytochrome P450-regulated estrogen metabolism and, as a consequence, inhibits estrogen-dependent growth of papilloma tissue.[7]
5. HPV quadrivalent vaccine: This vaccine uses virus-like particles to produce an antibody response against subtypes 6, 11, 16, and 18. These subtypes are associated with RRP;

therefore, it is critical to discuss this topic with patients and their families. This is not a therapeutic vaccine and thus has no role for patients with active disease. However, widespread pre-HPV-exposure vaccination will lead to the eradication of RRP. The eventual elimination of this disease could be achieved with widespread vaccinations and herd immunity.[7]

DISCUSSION

1. The use of the KTP laser has become more commonplace, often replacing a pulse dyed laser with similar or possibly better tissue interaction.
2. The key to successful voice outcomes is preservation of the lamina propria and conservative surgery.
3. Follow up in office for surveillance and for KTP laser procedures for recurrences.
4. Adjunctive treatments can be helpful in the setting of severe disease, frequent recurrence, or recurrences that are in suboptimal position for voicing.
5. From a preventative standpoint the HPV vaccine offers the strongest potential for eliminating RRP in the future.

Evidence-Based Medicine Question

How is adult-onset RRP transmitted?

Two methods of disease acquisition are postulated in the literature. The first occurs by vertical transmission from mother to child. Patients may be infected with the HPV but do not become symptomatic until later in life. Literature has described increased risk in first-born individuals, delivered vaginally in teenage mothers. However, this is controversial, as Ruiz et al. did not show differences in RRP patients compared with control patients suggesting another mode of transmission is more likely.

The second method is through sexual contact. Having multiple sexual partners has been associated with HPV-related oropharyngeal squamous cell carcinoma and has been considered in other disease processes. Ruiz et al. observed a possible association between RRP and increased number of lifetime vaginal/anal sex partners. There was no association between RRP and the number of oral sex partners noted. They suspect that RRP is not correlated with orogenital contact but rather mouth-to-mouth contact. Therefore, any intimate oral contact could be associated with spread of the disease. Further studies will be needed to evaluate the RRP population more closely and on a greater scale.

Editorial Comment

The diagnosis of true vocal fold RRP is no longer a vocal "death sentence." The implementation of photangiolytic lasers such as pulsed dye and KTP affords the user the ability to remove RRP lesions above the level of the lamina propria in their entirety, preserving vibration and voice. Office-based KTP laser ablation of RRP has afforded patients the ability to avoid multiple missed days from work for both the procedure and the recovery. Adjunctive therapies such as cidofovir continue to have a role in the treatment of RRP, and newer adjuncts such as bevacizumab show promise.

Thomas L. Carroll

Access the review questions and additional sources list online at http://www.expertconsult.com

REFERENCES

1. Wilcox LJ, Hull BP, Baldassari CM, et al. Diagnosis and management of recurrent respiratory papillomatosis. Pediatr Infect Dis J 2014;33(12):1283–1284.
2. Silverman DA, Pitman MJ. Current diagnostic and management trends for recurrent respiratory papillomatosis. Curr Opin Otolaryngol Head Neck Surg 2004;12:532–537.
3. Taliercio S, Cespedes M, Born H, et al. Adult-onset recurrent respiratory papillomatosis: a review of disease pathogenesis and implications for patient counseling. JAMA Otolaryngol Head Neck Surg 2015;141(1):78–83.
4. Rosen CA, Andrade Filho PA, Scheffel L, et al. Oropharyngeal complications of suspension laryngoscopy: a prospective study. Laryngoscope 2005;115(9):1681–1684.
5. Mallur PS, Johns 3rd MM, Amin MR, et al. Proposed classification system for reporting 532-nm pulsed potassium titanyl phosphate laser treatment effects on vocal fold lesions. Laryngoscope 2014;124:1170–1175.
6. Derkay CS, Volsky PG, Rosen CA, et al. Current use of intralesional cidofovir for recurrent respiratory papillomatosis. Laryngoscope 2013;123(3):705–712.
7. Gallagher TQ, Derkay CS. Pharmacotherapy of recurrent respiratory papillomatosis: an expert opinion. Expert Opin Pharmacother 2009;10(4):645–655.
8. Zeitels SM, Barbu AM, Landau-Zemer T, et al. Local injection of bevacizumab (Avastin) and angiolytic KTP laser treatment of recurrent respiratory papillomatosis of the vocal folds: a prospective study. Ann Otol Rhinol Laryngol 2011;120(10):627–634.

REVIEW QUESTIONS

1. Which of the following is an indication for cidofovir use according to the RRP Task Force?
   a. Age less than 10 at diagnosis
   b. Age greater than 50 at diagnosis
   c. Need for 6 or more surgeries yearly
   d. High-risk HPV subtype
   e. RRP that reoccurs on an annual basis

2. Which HPV subtype is most commonly associated with RRP?
   a. HPV 6 and 18
   b. HPV 6 and 11
   c. HPV 11 and 16
   d. HPV 16 and 18
   e. HPV 22 and 27

3. Who is the HPV vaccine currently offered to?
   a. All individuals
   b. Only women over the age of 11 and under age 27
   c. All individuals over the age of 11 and under age 27
   d. All individuals under age 27
   e. Individuals with the recent diagnosis of RRP

ADDITIONAL SOURCES

Rosen CA, Bryson P. Indole-3-carbinol for recurrent respiratory papillomatosis: long-term results. J Voice 2004;18:248–253.

Ruiz R, Achlatis S, Verma A, et al. Risk factors for adult-onset recurrent respiratory papillomatosis. Laryngoscope 2014;124(10):2338–2344.

4 Vocal Fold Injection via Microlaryngoscopy

Vyvy Young

INTRODUCTION

The term *vocal fold injection* (VFI) typically refers to global vocal fold augmentation for purposes of addressing glottic insufficiency,[1] although superficial injection into the lamina propria is performed occasionally (e.g., steroids, as for the treatment of vocal fold scar). In situations where the impact of global augmentation on symptoms is unpredictable, a trial VFI with a temporary material may also be beneficial.[2] Many options for augmentation material are currently available, with variable advantages, disadvantages, and durations of benefit. Advances in technology and techniques now allow Otolaryngologists to perform VFI under either local or general anesthesia.[1] This chapter focuses on VFI via microlaryngoscopy under general anesthesia.

Selection of injection material, type of anesthesia, and location of procedure (e.g., office, operating room, or endoscopy/procedure suite) should be determined on a case-by-case basis. Factors to consider include the patient's medical comorbidities and candidacy for the procedure, patient and/or surgeon preference, expected duration of symptoms/vocal fold motion abnormality (i.e., immediate postoperative period following surgery with high hopes for spontaneous recovery of motion vs. underlying malignancy), need or preference for hemodynamic monitoring, goal of the procedure (e.g., symptom treatment vs. trial), and insurance-related considerations.

VFI via microlaryngoscopy remains an important tool in the care of patients with symptomatic glottic insufficiency. Key advantages of this technique include immobility of the vocal folds and improved precision of injection material placement, complete airway control, and more detailed investigation of the vocal folds (including direct palpation to assess for vocal fold scar or cricoarytenoid joint fixation). Results of VFI are typically excellent in patients with glottic insufficiency related to vocal fold immobility/paralysis; outcomes of VFI for other laryngeal conditions such as vocal fold atrophy or scar tend to be more variable.

KEY OPERATIVE LEARNING POINTS

1. Adequate laryngeal exposure is critical.
2. Familiarity with different types of laryngoscopes
3. Familiarity with different injection material options
4. Typically the goal is global augmentation. (It is important to know when to use superficial injection.)
5. Superficial injection is to be avoided when global augmentation is the goal.

PREOPERATIVE PERIOD

History

1. History of present illness
   a. Voice
      1) Characteristics: breathy, raspy, decreased volume/projection, increased effort, vocal fatigue, vocal strain, tightness, pain with speaking
      2) Aggravating or alleviating factors
         a) For example, voice rest versus prolonged speaking, change in weather/temperature/humidity, stress, medications
   b. Swallowing
      1) Characteristics: dysphagia to liquids versus solids versus pills, coughing or choking episodes, need for Heimlich maneuver, weight loss, change in diet
      2) Aggravating or alleviating factors
         a) Impact of compensatory strategies: head turn, chin tuck, double swallow, liquid wash
      3) Asking about history of recent pneumonia is of critical importance.
   c. Breathing
      1) Characteristics: dyspnea with speaking versus exertion versus rest
      2) Aggravating or alleviating factors
   d. Precipitating factors
      1) Surgery
         a) Thyroid
         b) Cervical spine
         c) Lung
         d) Esophagus
      2) Intubation
         a) Size of endotracheal tube
         b) Duration of intubation
      3) Upper respiratory infection
      4) Accident/trauma
      5) None identifiable
   e. Other associated symptoms
      1) Cough
      2) Globus sensation
      3) Throat clearing
      4) Mucus
      5) Other symptoms including reflux-related (e.g., heartburn, burning sensation in nose/mouth/throat, or bitter/sour taste)
2. Past medical history
   a. Prior treatment and its efficacy
      1) Surgery
      2) Speech therapy
      3) Over-the-counter (OTC) medications (mucolytics, antihistamines, throat sprays, lozenges)
      4) Voice rest
      5) Steroids
      6) Antibiotics
      7) Gargling
      8) Increased fluids (e.g., water, tea)
   b. Medical history
      1) General assessment regarding candidacy for surgical procedure
   c. Surgery
      1) Especially important to include cervical spine, other neck, and/or chest surgery
   d. Family history: usually not helpful
   e. Medications
      1) Antiplatelet drugs
         a) Not a specific contraindication. Important to make sure that patient is counseled appropriately about risk of hemorrhage and even airway compromise.

f. Social history
   1) Tobacco use
      a) Active tobacco use can increase the risk of postoperative coughing (at extubation and in the early postoperative period), which may increase the risk of premature implant extrusion.
   2) Occupation and associated vocal demands (e.g., teacher, cashier, call center worker, attorney, social worker, waiter/bartender)

Physical Examination

1. Examination of the head and neck with focused areas as listed here
2. Examination of the neck
   a. Evidence of prior surgery (e.g., scars) or trauma
   b. Degree of cervical range of motion and any restrictions (flexion or extension); this may affect ease of intubation and/or exposure with the laryngoscope
3. Oral cavity
   a. Evaluate for trismus.
   b. Assess status of patient's dentition. Pay particular attention to the presence of any of the following: caps, crowns, partial dentures, bridges, missing/loose/broken teeth.
   c. Look for torus mandibularis (may require a smaller laryngoscope).
4. Flexible laryngoscopy
   a. Flexible laryngoscopy is critical in the evaluation of patients with voice, swallowing, or breathing symptoms.
   b. Flexible laryngoscopy is superior to rigid oral laryngoscopy in the assessment of vocal fold motion. The use of a rigid Hopkins rod telescope or high-definition chip-tip flexible laryngoscope may allow improved magnification and visualization of specific vocal fold abnormalities (e.g., vocal fold scar, lesions, sulcus vocalis).
   c. Specific task: repeated alternating sniff-/i/ maneuvers are especially useful for assessing vocal fold ABDuction (opening) and ADDuction (closing).

Imaging

1. Typically imaging is indicated only in cases of vocal fold immobility of uncertain etiology.
2. Computed tomography (CT) of the neck can serve to evaluate the course of the recurrent laryngeal nerve.
   a. CT may not be indicated if the history is strongly suggestive of an etiology of vocal fold immobility/paralysis (e.g., anterior cervical diskectomy and fusion (ACDF), thyroidectomy, esophagectomy, lung surgery).
3. Modified barium swallow if indicated to evaluate dysphagia
   a. MBS may be useful in situations where the surgeon is trying to decide whether to proceed with VFI versus continuing with observation alone; the presence of aspiration is a strong indication to proceed. If there is no aspiration, observation may be a reasonable alternative.

Indications

1. Symptomatic glottic insufficiency (which may be due to vocal fold immobility, paresis, atrophy)[1]
   a. Voice
   b. Swallowing
   c. Breathing
   d. Some combination of these symptoms
2. *Trial* VFI[2]
   a. In some cases it is not obvious whether vocal fold augmentation alone will improve voice symptoms. In these patients, the use of a temporary augmentation material as a "trial" VFI may be helpful in clarifying the degree of benefit that may be achieved after vocal fold augmentation.
   b. Examples of situations in which trial VFI may be helpful: vocal fold scar, atrophy, paresis, or concurrent neurologic disease (e.g., causing dysarthria)

Contraindications

1. Patients with medical comorbidities that carry an increased risk for general anesthesia need to carefully weigh the potential risks versus benefits of VFI. The presence of such a risk is not an absolute contraindication, but in such patients VFI under local anesthesia may be a good alternative option. The reader is referred to Chapter 94 and also item 3 under Additional Resources at the end of this chapter.
2. Although not an absolute contraindication, it is strongly suggested that VFI be considered with great caution in cases of a unilateral vocal fold immobility, which is associated with a contralateral vocal fold hypomobility, as these patients will have a baseline decrease in glottic airway size. Further vocal fold augmentation (either unilateral or bilateral) may additionally narrow this already restricted airway and should be undertaken with extreme care.
   a. It is uncommon that the benefits would outweigh the risks in patients with these vocal fold motion abnormalities. (An example might be a patient with documented aspiration who refuses a tracheostomy.) This issue should be considered in depth prior to proceeding.
   b. Extensive counseling of all parties including the patient, his or her family, and other associated services (e.g., Thoracic Surgery) is critical. It is particularly important to discuss the risk of airway compromise and the possibility of requiring urgent intubation and/or tracheostomy.
   c. If VFI is pursued, this should be performed very conservatively, as anteriorly as possible, and under as carefully controlled circumstances as possible.

Preoperative Preparation

1. Flexible laryngoscopy is imperative; additionally, *stroboscopy* is strongly recommended.
   a. Know which side to augment (critical in cases of planned unilateral injection).
   b. Know the size of the glottic gap (helps to guide the degree of augmentation to be performed).
   c. Evaluate the presence of vocal fold height mismatch. This may guide the location of injection material in an attempt to improve "matching" up of vocal fold levels.
   d. Flexible stroboscopy is superior to laryngoscopy alone for the assessment of vocal fold closure, size of the glottic gap, and the presence of vocal fold height mismatch.
2. Counseling to establish expectations (for both patient and family)
   a. The goal is to recover the patient's normal voice, but it is possible that the patient's symptoms may be improved or even resolved without a complete return to "normal." Use of patient self-report questionnaires (i.e., Voice Handicap Index [VHI], VHI-10, Voice Related Quality of Life [VRQOL]) may be helpful in monitoring the patient's degree of symptomatology and response to treatment. I assess pre- and postinjection VHI-10 scores in all patients.
   b. The patient is advised about the potential need for additional procedures. This may be especially appropriate

in cases of temporary VFI (such as following acute-onset vocal fold immobility), but it may even be needed following long-term augmentation, as with adipose tissue.
   c. In cases of trial VFI, the patient is counseled that voice symptoms may improve, decline, or remain unchanged.
3. Discontinue antiplatelet drugs if possible.

OPERATIVE PERIOD

Anesthesia

1. VFI is traditionally performed under general endotracheal anesthesia (GETA). More recent techniques to perform VFI under local anesthesia have been described; the reader is referred to Chapter 1 for further details. This chapter focuses on VFI under GETA.
2. Use as small an endotracheal tube as possible to permit maximal visualization of the vocal folds during laryngoscopy. I prefer a 5.0 microlaryngoscopy tube (MLT) for all laryngeal surgery. This should be taped to the oral commissure, preferably along the upper lip. Taping to the lower lip can sometimes affect oral opening and thus laryngoscopic exposure. Moving the "tube tree" or endotracheal tube holder further down the body (not immediately next to the head and neck) is helpful for keeping the anesthesia circuit out of the way.
3. Perioperative medications: one-time dosing at the start of the case
   a. Dexamethasone (Decadron)—decreases laryngeal edema
   b. Ondansetron (Zofran)—decreases nausea and associated risk for postoperative emesis
   c. Glycopyrrolate—decreases secretions and facilitates visualization during laryngoscopy
4. Laryngotracheal anesthesia (plain lidocaine, either 4% or 2%, based on availability and/or surgeon preference. I prefer 4% spray).
   a. Administered once at intubation (can be done by anesthesia)
   b. Administered a second time at the end of the procedure prior to extubation—decreases risk of laryngospasm and coughing upon extubation
5. A short-duration muscle relaxant is helpful during the procedure.

Positioning

1. Supine
2. No shoulder roll—it would place the patient in a suboptimal position for laryngoscopy
3. It is helpful to have an adjustable headboard to allow neck flexion if needed. Having the operative bed backward can allow this.

Perioperative Antibiotic Prophylaxis

Not indicated

Monitoring

1. Routine anesthesia monitoring
2. Short-duration muscle relaxant

Instruments and Equipment to Have Available

1. Multiple sizes and types of laryngoscopes
   a. Small-caliber laryngoscopes
   b. Longer laryngoscopes
   c. Laryngoscope with anterior "lip"
2. Small-caliber suction (5, 6, or 7 Fr)
3. Head light box depending on the type of light source
4. Reinforced dental guard to prevent injury to the teeth
5. Rigid telescope(s) versus microscope
   a. With camera equipment and monitor—especially helpful in teaching situations

Key Anatomic Landmarks:

1. Superior arcuate line Fig. 4.1
2. Vocal process

Prerequisite Skills

1. Laryngoscopy

Operative Risks

1. Airway compromise
   a. May result from bleeding, overaugmentation, or laryngospasm
2. Vocal fold hemorrhage
3. Poor injection (i.e., too superficial, too anterior, inadequate quantity) resulting in worsening or no change in symptoms
4. Injury to teeth/gums/lips
5. Tongue—numbness or change in taste
   a. Avoid by timely completion of surgery and/or releasing suspension during prolonged cases

Surgical Technique

- Ensure adequate anesthesia/relaxation.
- Eye protection. Drape head for laryngoscopy—this also protects the eyes.
- Reinforce a plastic dental guard with several layers of tape; this provides an easy, convenient, and inexpensive additional layer of protection. Place this reinforced guard over the maxillary dentition. For edentulous patients, a foam pad or moistened gauze may be used to protect the alveolar ridge.
- Pass the laryngoscope by mouth and advance to the larynx under direct visualization.
  - Keep the laryngoscope in the midline—this decreases pressure on the tongue.
  - Attempt to keep the epiglottis in the normal anatomic position as the laryngoscope slides underneath.(Exception: The Lindholm laryngoscope is designed to be placed into the vallecula and so does not pass under the epiglottis.) Folding over of the epiglottis can increase the difficulty of achieving an adequate laryngoscopic view of the vocal folds.
  - Flex the head if necessary.
  - Do not use a shoulder roll.
  - Maintain good direction of pull on the laryngoscope, primarily up and away. Avoid rocking back on the teeth.
- Special note on the choice of laryngoscope:
  - I prefer to use the laryngoscope with the largest possible distal aperture to allow full visualization of both true vocal folds simultaneously. My preference is to start with the largest-caliber universal modular glottiscope or the Dedo, depending on availability. If adequate visualization cannot be achieved in this way, a smaller laryngoscope may be substituted.
  - I prefer the use of the slotted anterior commissure scope when VFI is performed using telescopic guidance (as opposed to microscopic guidance).The slot facilitates manipulation of both a telescope and the needle within the confines of a small-diameter scope.

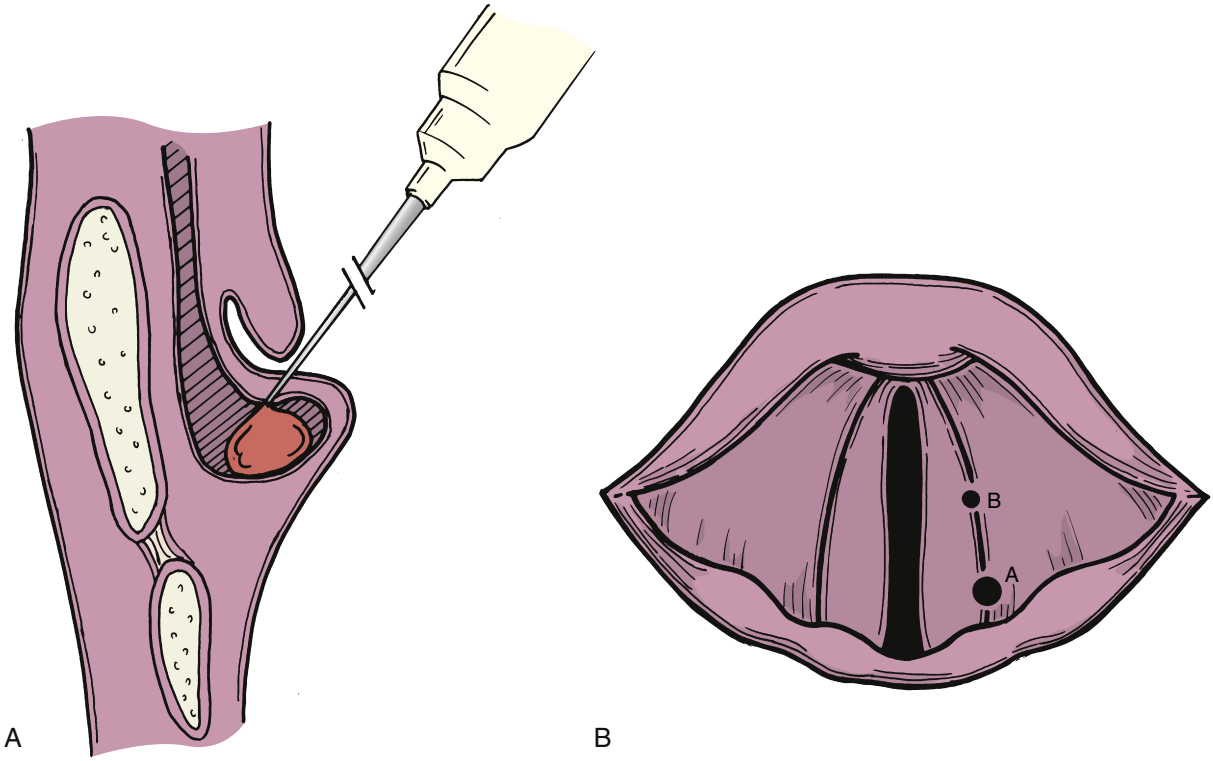

Fig. 4.1. Diagram of the ideal location for deep vocal fold injection, including coronal **(A)** and axial **(B)** views. In 4.1B, Point A represents the intersection between the longitudinal superior arcuate line and the vocal process and is the preferred initial injection site. If needed, additional augmentation can be performed at a secondary site (point B) at the mid-portion of the vocal fold along the superior arcuate line.

  - Be prepared to use different laryngoscopes if adequate visualization cannot be achieved. Check the reinforced dental guard frequently and change it often if there is any evidence of wear or damage to the dental guard. I routinely change to a new reinforced dental guard after two manipulations or changes of laryngoscopes.
- Place the laryngoscope into suspension.
  - I strongly advocate the use of a suspension system that attaches directly to the operating table. This provides maximal stability and minimizes risk to the patient (including dislodgement of the suspension system).
  - Use of alternative suspension systems (such as a Lewy arm) resting on a Mayo stand is acceptable, but strong caution is advocated in these respects:
    - Place patient in optimal position for microscopic visualization prior to placing in suspension. This usually involves ensuring that the operating table is low enough. Trendelenburg positioning of the patient may also be helpful.
    - Remind all OR personnel that once in suspension, the Mayo stand cannot be touched. Have all cameras, light cords, and suction cords appropriately placed before suspension. This avoids inadvertent jostling of the stand with manipulation of any of these cords/lines.
  - Use of alternative suspension systems which rest on the patient's chest are strongly discouraged due to inherent instability of that type of suspension.
- Ensure adequate visualization of the true vocal folds.
  - The goal is simultaneous visualization from the anterior commissure to the vocal processes bilaterally.
  - This may require anterior cricoid pressure, which can be applied with Velcro straps, adhesive tape, or manual pressure (this last option is not recommended but is feasible if no other option exists).
- Magnified examination of the true vocal folds
  - I like to use 5-mm rigid telescopes at various angles (0, 30, and 70 degrees) to fully evaluate the true vocal folds. This allows thorough inspection of the anterior commissure, ventricle, and infraglottic aspect of the vocal folds as well as the mid-membranous portion of the true vocal folds.
  - VFI can be performed using telescopic guidance if needed/preferred (I recommend a 0- or 30-degree telescope for this purpose). I suggest the use of the operating microscope when possible to maximize visualization and precise placement of the VFI.
- Palpation of the true vocal folds
  - Assess the status of cricoarytenoid joint motion by placing an instrument against the vocal process and displacing it laterally. This can be done with a curved blunt laryngeal elevator or a laryngeal suction (not attached to suction tubing).
  - Palpate the true vocal folds themselves to assess for lesions or stiffness suggestive of scar tissue.
- Identify proper location for the VFI.
  - Superficial injection—purposeful placement of injection material (e.g., dexamethasone) into the superficial lamina propria. The reader is referred to item 3 under Additional Resources, at the end of this chapter, for further details.
  - Deep injection
    - Proper placement is at the intersection of the superior arcuate line and the vocal process (see Fig. 4.1B, point A).
    - If needed, a secondary site can be injected in the mid-portion of the true vocal fold along the superior arcuate line (see Fig. 4.1B, point B). I prefer to avoid this, when possible, to avoid extrusion of the injection material through the initial injection site.

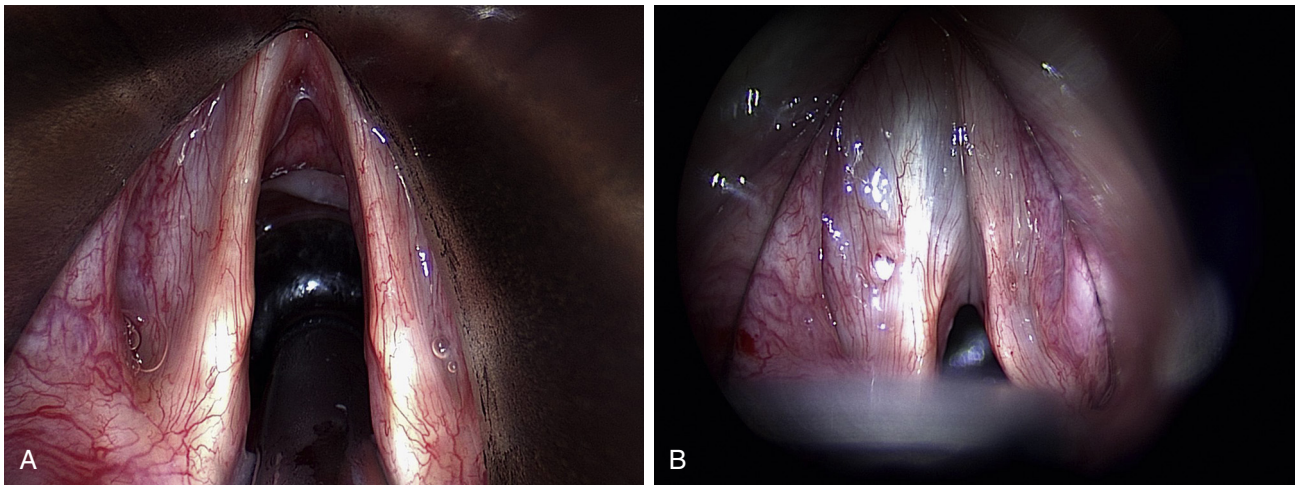

Fig. 4.2. Preoperative, **A,** and postoperative, **B,** photographs of a patient with right vocal fold paralysis who underwent bilateral deep vocal fold injection.

- Preparation of injection material
  - This depends on type of injection material
  - Prefabricated materials such as Prolaryn or Renu—follow directions in packaging
  - Collagen products such as Cymetra—follow directions in packaging
  - Adipose tissue
    - Briefly, abdominal adipose tissue is typically harvested (either via liposuction or through open harvest) for this purpose.
    - Prior to injection, I rinse the adipose tissue with 2 L of sterile lactated Ringer's solution and then soak it in an insulin bath for 5 minutes.
    - The reader is referred to items 3 and 4 under Additional Resources, at the end of this chapter, for further details.
  - Options
    - Xomed orotracheal injector needle (27 Ga)
    - Needle (24 Ga) is included with prefab package—could be Prolaryn or Renu.
    - Lipoinjection device (e.g. Instrumentarium) (14 to 16 Ga) for adipose tissue
- Slow, steady deployment of injection material
  - Look for infraglottic augmentation first.
  - This augmentation should then move "up" to the medial aspect of the true vocal cord (TVF).
  - The end result should be global augmentation (Fig. 4.2).
- Gently suction any extruded material from the opening.
- Any bleeding typically resolves spontaneously. However, if necessary, control bleeding with an epinephrine-soaked cottonoid pledget. I use epinephrine 1:10,000 and a ½- by 3-inch pledget.
- Laryngotracheal anesthesia (4% or 2% plain lidocaine spray)
- Orogastric tube suctioning of gastric contents if desired. I recommend this to decrease the risk of postoperative emesis.
- Remove laryngoscope, check teeth, and check tongue.
- Communicate with anesthesia personnel regarding the importance of quiet emergence and extubation. This type of direct communication is critically important and cannot be overemphasized.

Common Errors in Technique

1. Inadequate visualization of larynx/vocal folds
   a. Too much false vocal fold "show"
   b. Epiglottis flopped down
2. Superficial injection when deep augmentation is desired
3. "Bubbling up" of the superior surface of the TVF—seen particularly with patients with vocal fold atrophy
4. Injecting too far laterally—material going into the paraglottic space is wasted because it does not improve vocal fold augmentation and closure. Avoid this by checking to see in which direction the bevel of the needle is pointed—medial or anterior is better.
5. Injecting too far anteriorly—the goal is global augmentation

POSTOPERATIVE PERIOD

Postoperative Management

1. I counsel patients to undergo a period of voice rest after deep VFI. For lipoinjection, 3 days; for other materials, 24 hours
2. Same-day surgery—routine surveillance in the postanesthesia care unit (PACU), after which the patient is discharged to home as appropriate. Overnight observation will rarely be required.
3. No narcotics necessary. Acetaminophen (Tylenol, extra-strength) is permitted as needed.
   a. Caveat: patients may have abdominal discomfort and/or bruising after liposuction in cases of lipoinjection. These patients typically do not require narcotics but are more likely to require acetaminophen to address their discomfort. It is important to counsel patients regarding the possibility of postoperative abdominal pain related to the harvesting of adipose tissue.
4. No restrictions on eating/drinking once the patient has been cleared after anesthesia
5. Anticoagulant/antiplatelet drugs can usually be resumed the next day.

Complications

1. Inadequate augmentation versus premature extrusion of injection material
   a. Reassess symptoms, particularly dysphagia. Modified barium swallow if indicated
   b. Consider repeat injection if indicated.
   c. Consider evaluation for adjunctive treatments (swallowing therapy, voice therapy) to optimize symptoms in the event that a repeat injection is not desired.

2. Superficial injection
   a. Typically causes decreased vibration and can worsen voice quality
   b. Keep in mind that even temporary materials may have longer duration when injected superficially.
   c. Depends on material
      1) Calcium hydroxylaptite (CaHA)—typically results in a visible white mass under the epithelium (often described as a "chiclet" because of its resemblance to the small piece of candy-coated chewing gum)—may require surgical removal (typically microflap incision with removal vs. suction)[3]
      2) Clear materials (Prolaryn gel, Restylane) are difficult to visualize and therefore are typically not removed.
3. Too much augmentation
   a. Observation—some cases are associated with natural resorption initially (e.g., adipose tissue). Otherwise all temporary materials will resorb over time.
   b. If the patient is symptomatic from this, surgical excision and removal of excess material can be considered (degree of difficulty depends on the material).[4,5]
4. Persistent symptoms
   a. Look for underlying reason for persistent symptoms.
   b. Other measures may be required to address this.
      1) Voice therapy
      2) Swallowing therapy
      3) Respiratory retraining therapy
      4) Restructuring of patient expectations
5. Vocal fold hemorrhage
   a. Typically self-limited
   b. Additional voice rest may be helpful.
6. Airway compromise
   a. Look for underlying etiology.
      1) Laryngospasm
         a) Lidocaine IV push
         b) Positive pressure ventilation
         c) Reintubation—if this must be done, use as small a tube as possible. Often the patient may be observed in the recovery room for a short period of time (e.g., 1 hour) and then can often be extubated successfully. Less commonly, overnight intubation/observation may be required.
         d) Low-dose succinylcholine
      2) Edema of the airway
         a) Try to avoid this with an intraoperative dose of intravenous steroids.
      3) Overaugmentation
         a) If identified in the immediate postoperative period and causing airway symptoms, reintubation is an option.
         b) Surgical removal of excess material if necessary
      4) Anxiety
         a) The anesthetist may be able to administer anxiolytic medication.
7. Injury to the teeth
   a. Refer to family dentist or appropriate dental specialist.
   b. Prevention is key.
8. Temporomandibular joint dysfunction
   a. Soft diet, anti-inflammatory medication; a dental guard may help
   b. Expectant management
9. Tongue dysgeusia/numbness
   a. Conservative measures: passage of time and reassurance

Alternative Management Plan

1. VFI under local anesthesia
2. Evaluation of patient's candidacy for other treatments
   a. Voice therapy
   b. Swallowing therapy
3. Compensatory strategies to address dysphagia
   a. Head turn, chin tuck

DISCUSSION

Evidence-Based Medicine Question

What is the utility of trial VFI?

Initially described in 2010, trial VFI attempts to determine the degree of voice improvement that can be achieved following vocal fold augmentation when the anticipated results are not clear or predictable. Carroll and Rosen presented a cohort of 25 patients with vocal fold atrophy and/or paresis who underwent temporary vocal fold augmentation.[2] In their study, 76% (19/25) of the patient cohort had improvement and 24% (6/25) did not. Furthermore, 10 of these patients underwent further permanent augmentation and all had good results. These authors suggest that trial VFI may be helpful in situations where expectations following vocal fold augmentation are not clear, as in the case of vocal fold atrophy, paresis, scar, or combined communication difficulties (e.g., concurrent dysarthria).

In 2015, Young and colleagues sought to compare voice outcomes after trial VFI and long-term augmentation in patients with vocal fold atrophy.[6] They reviewed 19 patients and found that 42% (8/19) had a good response and 58% (11/19) had poor response to trial VFI. Among those with a good response, 75% (6/8) also had a good response to long-term treatment. Among those with a poor response to trial VFI, 55% (6/11) also had a poor response to long-term treatment. However, interestingly, 45% (5/11) of patients with poor response to trial VFI then went on to have a good response after long-term augmentation. The authors concluded that a good response to trial VFI appears to be predictive of a similar good response to long-term treatment. However, poor results following trial VFI are not necessarily suggestive of poor response following long-term augmentation and should be interpreted by the Otolaryngologist and patient with caution.

Based on these data, the predictive ability of trial VFI remains unclear, but trial VFI may still be useful in certain situations, such as those involving vocal fold atrophy, paresis, or scar. Appropriate expectations about the utility of results following trial VFI are critically important.

Editorial Comment

This chapter provides a very thorough discussion of a very important laryngologic procedure designed to reestablish vocal fold closure in cases of vocal fold paralysis, atrophy, paresis, or scar. In patients with vocal fold immobility, possibly due to paralysis versus cricoarytenoid joint pathology, cricoarytenoid joint palpation during microlaryngoscopy is extremely important. If mobilization is a major goal of the procedure, it is recommended that the surgeon perform cricoarytenoid joint palpation without endotracheal tube intubation at the start of general anesthesia and without suspending microlaryngoscopy. This avoids any confounding variables affecting assessment of the motion of the cricoarytenoid joint. For this aspect of the procedure, it is recommended that the patient undergo general anesthesia and then direct laryngoscopy with cricoarytenoid palpation, as in Chapter 5 describing the laryngoscope being purposely suspended manually high in the endolarynx, followed by a careful assessment of vocal fold motion when the vocal process of the arytenoid cartilage is displaced laterally.

When a patient with vocal fold paralysis causing dysphonia as well as dysphagia is considered for microlaryngoscopy and injection of the vocal fold, it may be prudent to proceed with vocal fold augmentation prior to a formal swallowing evaluation, given that history has demonstrated significant improvement of dysphagia following vocal fold augmentation. If dysphagia persists postoperatively, then proper swallowing evaluation is warranted.

Regarding intraoperative medication for microlaryngoscopy and vocal fold augmentation, it is important to note that intravenous steroid administration should be done with the patient sedated or in a very slow, controlled fashion to prevent a genital sensation from the IV push of the steroids. In addition, intravenous acetaminophen and intramuscular ketorolac are often very helpful for postoperative pain control. For individuals undergoing microlaryngoscopy with impaired dentition or dentition that has poor alignment, often a customized dental guard made by a dentist or one fabricated intraoperatively using nasal splint material (e.g., Aquaplast) can be very helpful in preventing dental injury in the face of pre-existing dental pathology.

It is important to note that overaugmentation of the vocal fold anteriorly will result in a severely strained voice and an unhappy patient; thus great care should be taken to avoid excessive augmentation of the anterior vocal fold.

Clark A. Rosen

Access the review questions and additional sources list online at http://www.expertconsult.com

REFERENCES

1. Sulica L, Rosen CA, Postma GN, et al. Current practice in injection augmentation of the vocal folds: indications, treatment principles, techniques, and complications. Laryngoscope 2010;120(2):319–325.
2. Carroll TL, Rosen CA. Trial vocal fold injection. J Voice 2010;24(4):494–498.
3. Chheda NN, Rosen CA, Belafsky PC, et al. Revision laryngeal surgery for the suboptimal injection of calcium hydroxylapatite. Laryngoscope 2008;118(12):2260–2263.
4. Sanderson JD, Simpson CB. Laryngeal complications after lipoinjection for vocal fold augmentation. Laryngoscope 2009;119(8):1652–1657.
5. Nakamura M, Tokashiki R, Issiki N, et al. Over-injection of autologous fat in the vocal fold: how to remove the excess? Eur Arch Otorhinolaryngol 2009;266(10):1589–1593.
6. Young VN, Gartner-Schmidt J, Rosen CA. Comparison of voice outcomes after trial and long-term vocal fold augmentation in vocal fold atrophy. Laryngoscope 2015;125(4):934–940.

REVIEW QUESTIONS

1. Reasons for persistent symptoms after VFI include all of the following *except*
   a. Insufficient augmentation
   b. Improperly placed augmentation
   c. Incorrect choice of augmentation material
   d. Underlying etiology of symptoms not addressed by VFI

2. The longest-lasting injection material is
   a. Calcium hydroxyapatite
   b. Hyaluronic acid
   c. Carboxymethylcellulose
   d. Autologous adipose tissue

3. The best landmarks to determine the location for VFI are the
   a. Superior arcuate line and anterior commissure
   b. Superior arcuate line and vocal process
   c. Intersection of vocal ligament and midpoint of membranous vocal fold
   d. Intersection of vocal ligament and vocal process

ADDITIONAL SOURCES

Lin RJ, Young VN, Rosen CA. Vocal fold lipoinjection. Csurgeries.com; accessed 01 February 2017.

Mallur PS, Rosen CA. Vocal fold injection: review of indications, techniques, and materials for augmentation. Clin Exp Otorhinolaryngol 2010;3(4):177–182.

Rosen CA, Amin MR, Sulica L, et al. Advances in office-based diagnosis and treatment in laryngology. Laryngoscope 2009;119(suppl. 2): S185–212.

Rosen CA, Simpson CB. Operative Techniques in Laryngology. New York, NY: Springer; 2008. p. 205–207.

5 Medialization Laryngoplasty and Arytenoid Adduction

R. Jun Lin, Clark A. Rosen

INTRODUCTION

Medialization laryngoplasty (type I thyroplasty) and arytenoid adduction are excellent surgical options for rehabilitation of the voice in patients suffering from glottic insufficiency. These are great options for surgical therapy to augment and reposition the vocal folds to improve vocal fold closure and thereby improve vocal function.[1,2] Glottic insufficiency may be caused by any combination of the following: vocal fold atrophy (presbylarynges), vocal fold scar, vocal fold paresis, or vocal fold paralysis. These procedures can also be used to address soft tissue deficits of the vocal folds after surgery or trauma.[3]

A variety of implant materials have been used to medialize the vocal folds in medialization laryngoplasty, including Silastic, hydroxylapatite block, and Gore-Tex. This chapter discusses the general approach to medialization laryngoplasty and does not discuss the different implants or the design of the shape of the implant, given that these are very personal choices for each surgeon and that medialization laryngoplasty can be done successfully with any of the aforementioned implant materials.

If the patient's dysphonia and/or dysphagia is related to a severe posterior glottic insufficiency, arytenoid adduction should be strongly considered because it is the only operation that consistently corrects glottic insufficiency in the posterior aspect of the glottis.[4-6] Neither injection laryngoplasty nor medialization laryngoplasty can address clinical issues related to posterior glottic insufficiency. Arytenoid adduction simulates the contraction of the lateral cricoarytenoid muscle by placing a suture in the muscular process of the arytenoid to rotate the arytenoid cartilage. This helps to medialize the posterior portion of the vocal fold, lengthen the vocal fold, close the posterior glottic gap, and change the height mismatch of vocal folds.[6,7]

KEY OPERATIVE LEARNING POINTS

- Identification of the entire aspect of the muscular tubercle located on the inferior border of the thyroid cartilage ala
- Slight overmedialization should be done during medialization laryngoplasty to account for intraoperative edema of the vocal fold and prevent undermedialization of the vocal fold postoperatively.
- Adjustment of implant based on findings of voice quality, vocal fold appearance, and vocal fold closure pattern. Intraoperative end results should include a slightly strained voice, medial augmentation of vocal fold, and complete glottal closure.

PREOPERATIVE PERIOD

History

1. History of presenting illness
   - Acute or gradual onset of hoarseness
   - Precipitating events such as surgery, endotracheal intubation, or upper respiratory infection
   - Voice quality weak, breathy, and effortful
   - Dyspnea with speaking
   - Coughing and choking, especially with drinking liquids
   - History of aspiration pneumonia
2. Pertinent past medical history
   - History of neck surgery (e.g., thyroid, parathyroid, carotid), cervical spine surgery, or thoracic/mediastinal surgery
   - History of malignancy (e.g., head and neck, thyroid, esophagus, lung)
   - History of cerebrovascular accidents
   - Underlying pulmonary disease (e.g., chronic obstructive pulmonary disease [COPD])—These patients have a smaller pulmonary reserve and thus will require more urgent intervention for vocal fold paralysis.

Physical Examination

- Complete examination of the head and neck
- Examination of the cranial nerves
- Transnasal flexible laryngoscopy to evaluate vocal fold motion, including mobility of the contralateral vocal fold, and overall airway status
- Stroboscopy to assess glottic closure pattern and vocal fold levels

Imaging

- Computed tomography (CT) or magnetic resonance imaging (MRI) scan from skull base to aortic arch (along the course of the recurrent laryngeal nerve) with contrast in vocal fold paralysis with no clear precipitating events

Indications

- Symptomatic glottic insufficiency (dysphonia, dyspnea on phonation, aspiration), especially if there is little or no chance of return of vocal fold motion

Contraindications

- Coagulopathy (relative)
- Malignancy involving the laryngotracheal complex
- Poor abduction of the contralateral vocal fold due to airway concern
- Presence of vocal fold lesions
- Intact vocal fold mobility (for arytenoid adduction)

Preoperative Preparation

- Review the patient's laryngeal examination.
- Counsel patients to stop anticoagulation agents, such as nonsteroidal anti-inflammatory medications (e.g., ibuprofen), Coumadin, antiplatelet agents (e.g., clopidogrel), and factor Xa inhibitors (e.g., rivaroxaban, apixaban, dabigatran). Management of patient's anticoagulants may be coordinated with his/her cardiologists and/or hematologists.
- Discuss with the patient regarding the environment in the operating room, given that the patient will be awake and only slightly sedated. It is best to prepare patients psychologically while they are awake for having surgery on their neck.

- Counsel the patient that there may be a need for a bilateral procedure and the addition of an arytenoid adduction procedure pending the intraoperative results of the medialization laryngoplasty. Often with experience, surgeons can determine preoperatively, based on the laryngeal examination and the patient's voice quality, whether he or she will require a unilateral or bilateral medialization laryngoplasty. However, certain situations do occur intraoperatively in which voice quality is only marginally improved with a medialization laryngoplasty, and it is determined that the patient would benefit significantly from a simultaneous arytenoid adduction.

OPERATIVE PERIOD

Anesthesia

- Before the patient comes into the operating room, nebulization of a 50:50 mixture of 4% lidocaine (2 mg/kg) and 1% tetracaine (0.5 mg/kg) is performed to provide topical anesthesia to the upper aerodigestive tract, which facilitates the patient tolerating the flexible laryngoscopy during the procedure.
- Robinul, an anticholinergic medication, should be administered, unless medically contraindicated, to minimize laryngeal secretions during the procedure.
- The patient will then undergo the procedure under monitored anesthesia care (MAC), which includes local anesthesia with sedation and analgesia.

Positioning

- Once in the operating room, the patient is placed in a supine position with a conservative shoulder roll to provide extension of the neck. Care should be taken to ensure that the patient is comfortable.

Perioperative Medications

- A prophylactic dose of intravenous antibiotics is given approximately 30 to 45 minutes before the skin incision, as per surgical prophylaxis guidelines.
- One dose of dexamethasone (10 mg) is given to minimize airway edema.

Monitoring

- The patient will be monitored by the anesthesia health care provider as per standard of practice.

Instruments and Equipment to Have Available

- Standard head and neck soft tissue set
- Cottle or Freer elevator
- Measuring caliper
- Drill with a 1- to 2-mm cutting burr
- Flexible laryngoscope
- C-mount camera with video tower/monitor
- Surgeon's preferred implant material
  - For Gore-Tex implants, select middle ear instruments (e.g., middle ear alligator, annulus elevator, middle ear curette), Woodson elevator, Kerrison rongeus (1- to 3-mm tips)
  - For Silastic implants, Netterville medialization set (Medtronic ENT, Jacksonville, FL), Silastic block
- For arytenoid adduction, 4-0 monofilament permanent suture (e.g., Mersilene by Ethicon, Medline Industries. Inc, Northfield, IL) and Kitner dissector (peanut)

Key Anatomic Landmarks

1. Medialization laryngoplasty
   - Inferior border of the thyroid cartilage
   - The entire aspect of the muscular tubercle located on the inferior border of the thyroid cartilage ala because the angulation of this process can cause incorrect orientation of the medialization window
2. Arytenoid adduction
   - Posterior border of the thyroid cartilage
   - Posterior lamina of the cricoid cartilage
   - Cricopharyngeus muscle
   - Posterior cricoarytenoid (PCA) muscle
   - Muscular process of the arytenoid, seen as "a grain of rice"

Prerequisite Skills

- Good understanding of laryngotracheal anatomy
- Basic soft tissue handling skills

Operative Risks

- Infection
- Bleeding/neck hematoma
- Violation of the pyriform sinus (arytenoid adduction)
- Implant migration
- Implant extrusion
- Airway obstruction
- Persistent dysphonia after surgery requiring revision surgery. Reasons for suboptimal results include persistent posterior glottic gap, undermedialization, implant malposition (anteriorly and/or superiorly), vocal fold height mismatch.

SURGICAL TECHNIQUE

Medialization Laryngoplasty (Type I Thyroplasty)

- Cotton pledgets soaked with 4% lidocaine and oxymetazoline decongestant are applied to the most patent nasal cavity.
- After intravenous sedation is obtained, 1% lidocaine with 1:100,000 epinephrine can be injected both superficially and deep in the area of the thyroid ala on the proposed side or sides of surgery. A superior laryngeal nerve block in the thyrohyoid space should be performed if arytenoid adduction is planned.
- A 4- to 5-cm incision is made in a curvilinear fashion along a normal skin crease near the inferior border of the thyroid ala. The incision is made on the side of the medialization laryngoplasty and may cross over the midline by approximately 1 cm.
- The platysma muscle is incised and subplatysmal flaps are elevated superiorly and inferiorly to approximately the level of the hyoid bone and the cricoid cartilage, respectively.
- The midline raphae is divided between the strap muscles, exposing the thyroid cartilage.
- Two self-retaining retractors or multiple fishhooks are used to retract the skin and the strap muscles to optimize exposure of the thyroid cartilage.
- The outer perichondrium of the thyroid cartilage is incised longitudinally along the midline. Subperichondrial elevation should be done widely to expose the thyroid ala approximately 5 mm posterior to the muscular tubercle. This is imperative because the posterior aspect of the muscular tubercle of the inferior aspect of the thyroid ala will identify the true inferior border of the thyroid cartilage, which determines the plane of the vocal fold and location of the thyroplasty implant.
- A caliper is used to measure approximately 5 to 7 mm posterior to the midline of the thyroid cartilage and 3 mm above the inferior border of the thyroid cartilage. This is the area where the proposed thyroplasty window will be made (Fig. 5.1).

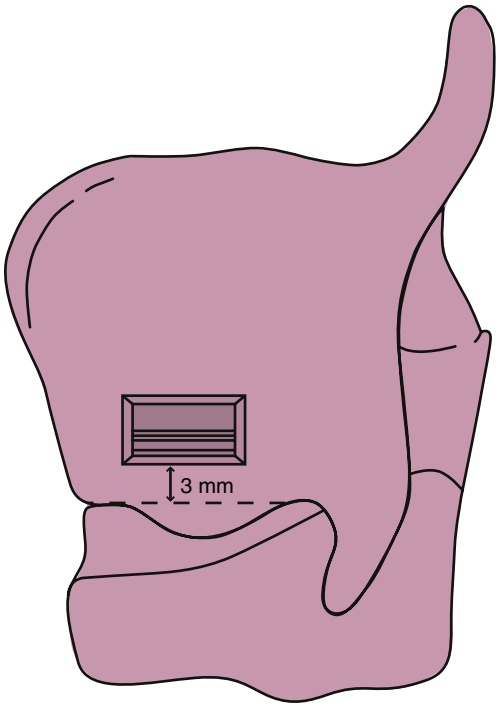

Fig. 5.1. Location of medialization laryngoplasty window.

- A 25-gauge needle can be placed through the thyroid cartilage in this area, confirming with simultaneous flexible laryngoscopy that the proposed thyroplasty window is appropriately positioned immediately lateral to the vocal fold and is not too posterior, anterior, or superior. If the thyroid ala is too ossified for the 25-gauge needle to pass through, a small hole can be drilled using a 1- to 2-mm cutting burr in the approximate location of the thyroplasty window, and a blunt instrument, such as the annulus elevator, can be passed through to confirm the position of the proposed window with flexible laryngoscopy.
- If a Gore-Tex medialization laryngoplasty is planned, then a window of 3 × 3 mm^2 at the previously determined optimal site can be made with a drill (if the thyroid cartilage is ossified) or with a no. 15 scalpel blade or a beaver blade.[8] For a Silastic medialization laryngoplasty, the thyroplasty window is typically 6 × 13 mm^2 in dimension and can be created with either a drill or a scalpel.
- After the thyroid cartilage has been removed from the window, it is wise to incise the perichondrium superiorly, posteriorly, and inferiorly, creating an anteriorly based inner perichondrium flap. The paraglottic space can then be elevated posteriorly and inferiorly in preparation for placement of the medialization laryngoplasty implant. Simultaneous flexible laryngoscopy and evaluation of the voice during the elevation of this pocket will determine the size, location, and nature of the implant and is extremely important to the success of the operation. Surgeons should take great care to avoid overmedialization of the vocal fold anteriorly and superiorly. These are the two most common mistakes made by surgeons doing medialization laryngoplasty. The implant is then inserted through the thyroplasty window with simultaneous flexible laryngoscopy monitoring and assessment of the patient's voice quality (Fig. 5.2).
- After the voice quality and vocal fold position are optimized, the implant can be secured to the adjacent thyroid cartilage with a permanent 4-0 Prolene suture. Hemostasis should be obtained, and a small drain, although not always necessary, may be placed in the dependent portion of the wound.

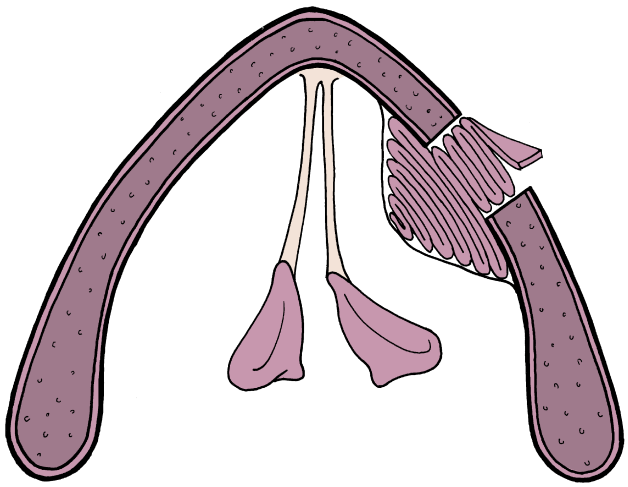

Fig. 5.2. Placement of Gore-Tex into paraglottic space to medialize the vocal fold.

- The perichondrium should be laid back over the thyroplasty window, and the strap muscles should be re-approximated in the midline. Finally, skin closure should include both dermal and epidermal closures to maximize the cosmetic results of the operative site.

Arytenoid Adduction

- The surgical approach to arytenoid adduction is the same as described earlier for medialization laryngoplasty.
- Approximately 1 cm of the medial aspect of the sternohyoid muscle is transected below its insertion onto the hyoid. This helps to improve posterior exposure for arytenoid adduction.
- After elevating the perichondrium off the anterior two-thirds of the thyroid ala as described for medialization laryngoplasty, the elevation should be continued to the posterior border, specifically skeletonizing the inferior cornu of the thyroid cartilage.
- Careful dissection around the posterior border of the thyroid ala from the inferior cornu superiorly up toward the greater cornu is then done, taking great care to adhere to the thyroid cartilage to avoid entering the pyriform sinus.
- For further exposure and rotation of the larynx, a hook can be placed on the greater cornu to rotate the larynx medially and expose its posterior aspect.
- Bipolar cautery can then be used to release the superior portion of the cricopharyngeus muscle as it attaches to the inferior cornu. This allows exposure of the pyriform sinus.
- The pyriform sinus lies directly over the posterior lamina of the cricoid cartilage, which is the location of the PCA muscle and is the main anatomic landmark for the surgical dissection. To fully evaluate the location of the pyriform sinus throughout this portion of the dissection, it is wise to have patients intermittently "puff out" their cheeks, which will inflate the pyriform sinus and outline its boundaries.
- Dissection of the pyriform sinus off of the cricoid cartilage should then be done in an inferolateral to superomedial direction until the PCA muscle is identified. The PCA muscle can be identified by the direction of the muscle fibers running from a medial-inferior to the lateral-superior direction and ending at the muscular process of the arytenoid cartilage.
- Following retraction of the inferior portion of the pyriform sinus, the PCA muscle is usually clearly identified and can be traced up to identify the ridge on the arytenoid cartilage, which is the muscular process of the arytenoid cartilage (Fig. 5.3).

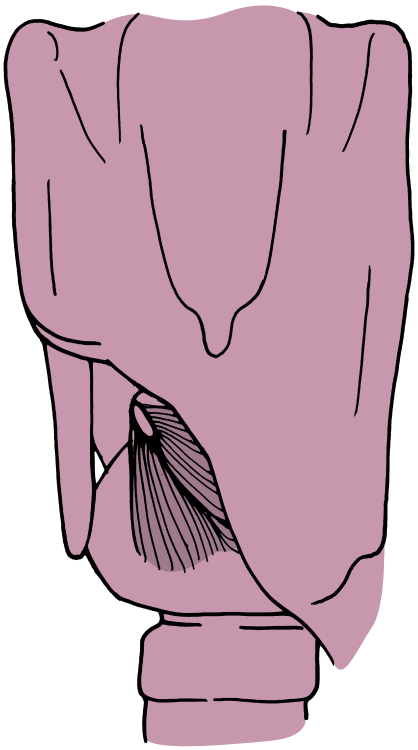

Fig. 5.3. Identification of the muscular process of the arytenoid cartilage.

- A small portion of the posterior border of the thyroid cartilage (a posterior thyroplasty window) can be removed with a rongeur to assist in finding and suturing the muscular process of the arytenoid cartilage (Fig. 5.4).
- After the muscular process of the arytenoid cartilage is identified, a figure-of-eight suture, using a 4.0 nonabsorbable suture (e.g., Mersilene), is placed through the arytenoid cartilage.
- Confirmation of proper placement of this suture is done with simultaneous flexible laryngoscopy. Control and manipulation of the arytenoid are now possible via the suture placed through the muscular process of the arytenoid cartilage.
- If the medialization laryngoplasty window has not yet been made, the two arms of the suture placed through the muscular process of the arytenoid cartilage can be clamped, and the larynx can be placed back into its anatomic location for creation of the medialization laryngoplasty window as described earlier.
- After the medialization laryngoplasty window is created, lateral paraglottic dissection posterior to the window can be done with an elevator to develop a tract that extends from the muscular process of the arytenoid cartilage to the medialization laryngoplasty window.
- After this path has been created, a middle ear alligator can be passed from the window posteriorly to the posterior aspect of the larynx and bring both arms of the arytenoid adduction suture forward through the window.
- After the sutures have been drawn forward, one suture can be placed anterior and inferior to the window through the cricothyroid membrane, and the second suture can be placed immediately anterior through the medialization laryngoplasty window through the thyroid cartilage. Gentle tension on this suture will rotate the arytenoid into an adducted position and significantly improve the vocal fold length and position of the paralyzed vocal fold.

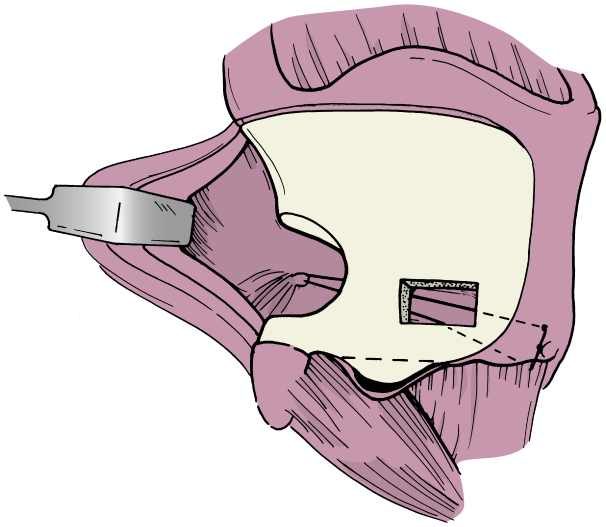

Fig. 5.4. A small portion of the posterior border of the thyroid cartilage can be removed with a rongeur to assist in finding and suturing the muscular process of the arytenoid cartilage.

- With gentle tension on the arytenoid adduction sutures and simulated medialization through the medialization laryngoplasty window, voice quality and vocal fold position can be evaluated via simultaneous flexible laryngoscopy to determine optimal suture tension and amount of medialization required (see Fig. 5.4).
- When medialization laryngoplasty is done in conjunction with arytenoid adduction, typically less medialization is required, and it is very rare that a significant amount of tension needs to be applied to the arytenoid adduction suture for optimal phonatory function.
- After the arytenoid adduction suture has been placed, the medialization laryngoplasty can be completed as described earlier. A small drain is placed in the dependent portion of the wound, and the wound can be closed the same way as the medialization laryngoplasty procedure (Video 5.1).

Common Errors in Technique

- Medialization laryngoplasty and arytenoid adduction should not be done when the preoperative airway is compromised with poor contralateral vocal fold abduction.
- Position of the implant is the key to successful medialization laryngoplasty, and great care should be taken to ensure that the implant is not placed too superior or too anterior.
- Great care should be taken not to violate the airway during placement of the implant (medialization laryngoplasty) and during elevation of the pyriform sinus (arytenoid adduction).
- A clear path must be created for the arytenoid adduction suture from the muscular process of the arytenoid to the medialization laryngoplasty window to ensure proper rotation of the arytenoid.
- Excessive tension on the arytenoid adduction suture can cause overrotation of the arytenoid and poor voice outcome.

POSTOPERATIVE PERIOD

Postoperative Management

- Same-day surgery or overnight 23-hour observation (for arytenoid adduction) depending on the patient's coexisting medical comorbidities

- Pain management
- Intravenous steroids at 8-hour intervals for 24 hours (Decadron 6 to 8 mg) if the patient is observed overnight
- If the patient had an arytenoid adduction, he or she should be discharged on a Medrol pack with a 6-day tapering dose.
- Elevation of the head of the bed
- No voice rest
- No empiric antibiotic therapy
- Follow up in clinic in approximately 4 weeks because it takes approximately 3 to 4 weeks for the edema of the vocal folds and the surrounding tissues to resolve before making a repeat laryngeal examination valid.

Complications

1. Medialization laryngoplasty
   - Implant malposition.[9] The implant can be inappropriately located in a variety of dimensions, although the most common implant malpositions include (1) too much medialization of the vocal fold by the implant and (2) too superior positioning of the implant.[5,10] The latter problem causes a ventricular prolapse and medialization of the false vocal fold, which impairs normal voice production. In addition, as mentioned earlier, excessive medialization of the vocal fold anteriorly can cause a pressed or strained voice quality.
   - Undermedialization of the vocal fold. This is often due to failure to account for intraoperative edema that occurs within the vocal fold throughout the surgical procedure and/or failure to recognize the need for contralateral augmentation. For this reason, the implant should be designed to induce a very slight amount of strain within the voice at the end of the procedure, knowing that a small amount of the strain in the voice is due to edema of the vocal fold. As the edema resolves in 2 to 3 weeks after surgery, the voice quality will be excellent.
   - Implant extrusion. Implants can extrude medially into the airway or laterally out into the skin. The former complication is severe and can become an airway emergency. This is believed to occur due to an unrecognized violation of the mucosa, usually of the ventricle, during placement of the implant.
2. Arytenoid adduction
   - Pharyngocutaneous fistula. This occurs from violation of the pyriform sinus during the dissection to identify the PCA muscle. If violation is identified intraoperatively, careful oversewing of the opening in the pyriform sinus is warranted.
   - Overrotation of the arytenoid cartilage. This can come from excessive tension placed on the arytenoid adduction suture. This is usually identified and corrected during the procedure and thus occurs rarely. It is important to note that excessive tension is rarely required for the arytenoid adduction procedure. The suture placed on the arytenoid cartilage is only to guide the arytenoid into a more favorable position for phonation and to keep it there; thus excessive tension on the suture is usually not required.

Alternative Management Plan

1. Observation alone if patient does not have vocal complaints and does not have dysphagia
2. Injection laryngoplasty with a long-term injectable material (e.g., calcium hydroxylapatite)
3. Injection laryngoplasty with autologous adipose tissue

DISCUSSION

Evidence-Based Medicine Question

1. Is medialization laryngoplasty safe in patients with previous neck radiation?
   - Studies have shown that there is no significant difference in subjective voice parameters and complications after medialization laryngoplasty in radiated versus nonradiated patients.

Editorial Comment

Medialization laryngoplasty is the most popular procedure of otolaryngologists treating glottal incompetence, especially due to vocal fold paralysis. Dr. Isshiki is honored for having reintroduced the procedure into the medical culture in 1974. Since then, there have been refinements to the procedure, but the concept remains the same: move the paralyzed vocal fold to a midline position so the mobile vocal fold can contact it.

The position of the thyroid ala window for placement of whatever type of implant the surgeon chooses is critical to the success of vocal fold medialization. If placing a solid block implant, the angle and position of the window is critical. If placing a Gore-Tex strip, it is important to keep the dissection within the inner perichondrium in the area where the implant will be placed. Aggressive undermining in these cases is not recommended because it could lead to migration of the implant to a less favorable position.

The addition of arytenoid adduction often varies upon surgeon training but can be critical in improving the patient's voice if there is a large posterior glottal gap, a foreshortened vocal fold (with decreased tension), or significant vertical height mismatch of the vocal folds. The arytenoid adduction procedure helps to correct these anatomic findings, resulting in increased generation of subglottic air pressure and therefore vocal intensity.

A different way to approach the arytenoid was conceived by Dr. Zietels et al., first described in 1998. This technique focuses on repositioning the arytenoid posteriorly, superiorly, and medially on the cricoid. Depending upon training, a clinician may feel more comfortable with one or the other of these two arytenoid repositioning techniques.[11,12]

Libby J. Smith

Access the review questions and additional sources list online at http://www.expertconsult.com



REFERENCES

1. Netterville JL, Billante CR. The immobile vocal fold. In: Ossoff RH, Shapshay SM, Woodson GE, et al., editor. The Larynx. Philadelphia: Lippincott Williams & Wilkins; 2004. p. 269–305.
2. Wanamaker J, Netterville JL, Ossoff RH. Phonosurgery: Silastic medialization for unilateral vocal fold paralysis. Oper Tech Otolaryngol Head Neck Surg 1993;4:207–217.
3. Zeitels SM, Mauri M, Dailey SH. Medialization laryngoplasty with Gore-Tex for voice restoration secondary to glottal incompetence: indications and observations. Ann Otol Rhinol Laryngol 2003;112:180–184.
4. McCulloch TM, Hoffman HT, Andrews BT, et al. Arytenoid adduction combined with Gore-Tex medialization laryngoplasty. Laryngoscope 2000;110:1306–1311.
5. Netterville JL, Stone RE, Luken ES, et al. Silastic medialization and arytenoid adduction: the Vanderbilt experience. A review of 116 phonosurgical procedures. Ann Otol Rhinol Laryngol 1993;102:413–424.
6. Woodson GE, Picerno R, Yeung D, et al. Arytenoid adduction: controlling vertical position. Ann Otol Rhinol Laryngol 2000;109:360–364.

7. Mortensen M, Carroll L, Woo P. Arytenoid adduction with medialization laryngoplasty versus injection or medialization laryngoplasty: the role of the arytenoidopexy. Laryngoscope 2009;119:827–831.
8. White JR, Orbelo DM, Noel DB, et al. Thyroplasty in previously irradiated neck: a case series and short-term outcomes. Laryngoscope 1849–1853;126(8).
9. Rosow ED, Al-Bar MH. Type I thyroplasty in previously irradiated patients: assessing safety and efficacy. Otolaryngol Head Neck Surg 2015;153(4):582–585.
10. McCulloch TM, Hoffman HT. Medialization laryngoplasty with expanded polytetrafluoroethylene. Surgical techniques and preliminary results. Ann Otol Rhinol Laryngol 1998;107:841–854.
11. Isshiki N, Morita H, OkamuraH, HiramotoM: Thyroplasty as a new phonosurgical technique. Acta Otolaryngologica 1974;78(5-6):451–457.
12. Zeitels SM, Hochman I, Hillman RE: Adduction arytenopexy: a new procedure for paralytic dysphonia with implications for implant medialization. Annals of Otology, Rhinology, and Laryngology 1998;173:2–24.

REVIEW QUESTIONS

1. How does the position of the thyroplasty window differ in males and females?
   a. Anterior border of the thyroplasty window is more anterior in males
   b. Anterior border of the thyroplasty window is more posterior in males
   c. Superior border of the thyroplasty window is more superior in males
   d. Superior border of the thyroplasty window is more inferior in males

2. What are the indications for arytenoid adduction?
   a. Large posterior glottic gap
   b. Vocal fold level mismatch
   c. Reposition the arytenoid
   d. All of the above

3. The direction of vocal fold augmentation that can be achieved with thyroplasty is:
   a. Medial
   b. Anterior
   c. Posterior
   d. Superior

ADDITIONAL SOURCES

Cohen JT, Bates DD, Postma GN. Revision Gore-Tex medialization laryngoplasty. Otolaryngol Head Neck Surg 2004;131:236–240.

Rosen CA, Simpson CB. Operative Techniques in Laryngology. New York: Springer; 2008.

Young VN, Zullo TG, Rosen CA. Analysis of laryngeal framework surgery: 10-year follow-up to a national survey. Laryngoscope 2010;120(8):1602–1608.

6 Intraoperative Medialization Laryngoplasty

Ricardo L. Carrau

INTRODUCTION

Medialization laryngoplasty or thyroplasty type I was first described and later popularized by Ishiki during the 1970s. Netterville first reported on the immediate medialization of the true vocal fold following skull base or head and neck surgeries involving the sacrifice of the vagus or recurrent laryngeal nerves.

- Glottic insufficiency affects all laryngeal functions and may be caused by vocal fold:
  - Atrophy (i.e., presbylarynx, neuromuscular degenerative disease)
  - Weakness (i.e., paresis)
  - Paralysis
- Glottic insufficiency impairs the function of the laryngeal sphincter leading to[1-5]:
  - Poor protection of the tracheobronchial airways during swallowing (i.e., aspiration)
  - Reduction of efficiency and strength of the cough reflex
  - Elimination of physiologic positive pressure on expiration (helps to inflate the lungs)
  - Wide range of dysphonia and vocal fatigue
  - Decrease in the efficiency of a Valsalva maneuver; thus patients may exhibit problems splinting the thoracoabdominal muscles, which help with lifting and facilitating bowel movements
- An immediate intraoperative thyroplasty is based on an empirical medialization of the true vocal fold. The patient's true functional deficit cannot be assessed reliably under general anesthesia; thus the need for a subsequent revision is higher than a secondary thyroplasty performed under awake sedation.
- The vast majority of patients will enjoy a satisfactory outcome resulting in adequate protection of the tracheobronchial tree against aspiration and normal or near-normal voice (vocal fatigue may be a persistent problem).
- Professional voice performers may require adjunctive procedures, such as arytenoid repositioning, to reach an optimal result.
- A seemingly adequate postoperative result may deteriorate in time due to re-accommodation of the implant (i.e., GORTEX strip) or vocal fold atrophy (more common in patients with a high-vagal lesion).
- Surgical medialization of a paralyzed cord displaces the affected vocal fold toward the midline and augments its bulk to improve the glottic closure (it facilitates neuromuscular compensation by the unaffected contralateral side).[1-10]

KEY OPERATIVE LEARNING POINTS

- A medialization laryngoplasty or thyroplasty type I involves the medialization of a paralyzed or paretic true vocal fold by the insertion of a paraglottic implant such as[1-7]:
  - Silicone (premade and custom implants)
  - Polytetrafluoroethylene (GOR-TEX; W.L. Gore and Associates, Newark, DE)
  - Titanium alloy
  - Hydroxyapatite
  - Cartilage
  - Fascia
  - Acellular dermis
  - Adjustable balloon
- Most frequently, an intraoperative thyroplasty involves implantation without the benefit of being able to be certain of the position of the window with respect to the position of the vocal fold or the immediate effect of the implantation upon the quality and strength of the voice or cough.[2,4,5,8]
- The surgeon creates a window in the thyroid cartilage and medializes the vocal cord using dimensions that have been determined to yield adequate results for most patients operated in the traditional way (Fig. 6.1A).
- 20%–30% of patients will require revision surgery.[4-6,8]

PREOPERATIVE PERIOD

History

This procedure may be planned preoperatively in the patient with a history of having a tumor originating in the vagus nerve (i.e., vagal schwannoma or a glomus vagale requiring removal of the vagus nerve) or requiring the sacrifice of the vagus nerve in removing an adjacent tumor (i.e., carotid body tumor). In such situations, this procedure must be discussed with the patient. There are also instances in which the need for intraoperative thyroplasty may not be anticipated, such as accidental transection of the recurrent laryngeal nerve during thyroid surgery in which the patient may not have been prepared for this additional procedure.

Physical Examination

- Examination of the neck must rule out the presence of masses, scars, or excessive subcutaneous adipose tissue, all of which may affect the choice and difficulty of the exposure.
- A preoperative flexible fiberoptic laryngoscopy ascertains:
  - The position of the vocal fold (VFs) and arytenoids (horizontal and vertical planes) during normal and forced ventilation, vocalization, and cough
  - The muscle tone of the vocal folds
  - The bulk of the vocal folds
  - The integrity of the mucosa
- Functional assessment of all lower cranial nerves is critical.

Imaging

Not necessary.

Indications

- The decision to perform an immediate intraoperative thyroplasty is multifactorial and includes such variables as the needs and desires of the patient (e.g., profession, fitness, hobbies and interests), age, premorbid laryngeal and pulmonary function, and presence of other cranial nerve deficits.
- An immediate intraoperative thyroplasty is indicated in patients who:

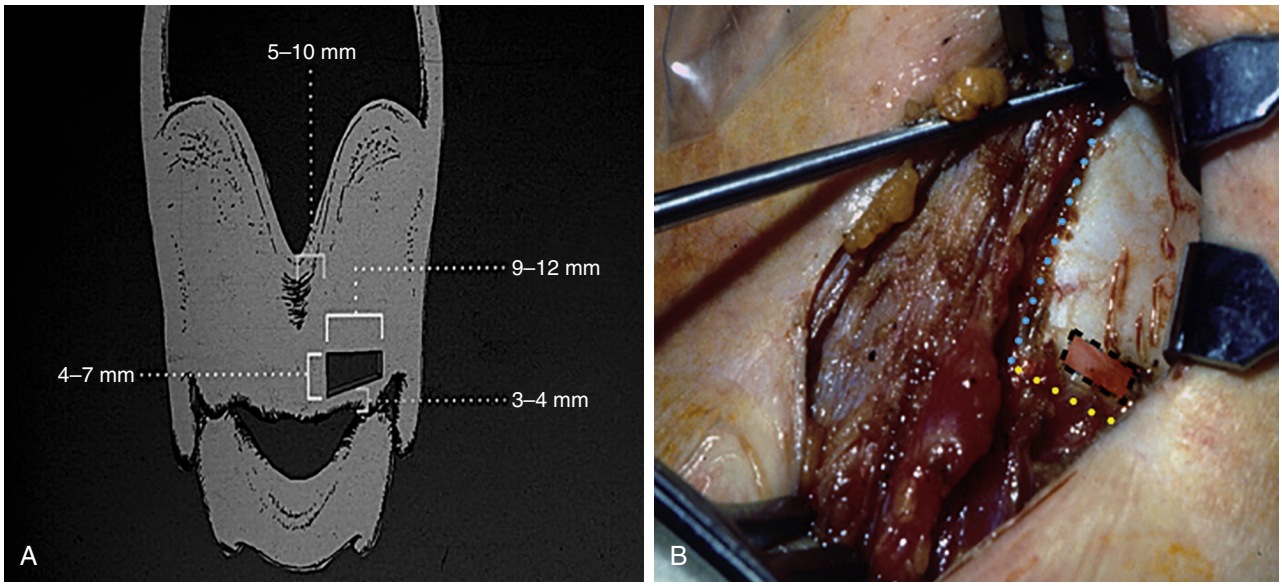

Fig. 6.1. A, Approximate dimensions and position of the thyroplasty window. During an immediate thyroplasty, the window is opened as close to the inferior edge of the thyroid ala as possible while still preserving an inferior strut. **B,** The strap muscles and the perichondrium of the thyroid cartilage were divided at the midline and are being retracted from the thyroid ala en bloc. Stabilization of the larynx with a single or double hook greatly facilitates this dissection and opening of the window.

- Undergo sacrifice of the vagus or recurrent laryngeal nerve during an oncologic resection
- Suffered iatrogenic or penetrating trauma to the neck with injury to the vagus or recurrent laryngeal nerves

Contraindications

- An immediate intraoperative thyroplasty is contraindicated in patients who show:
  - Glottic airway stenosis due to edema or abductor paralysis (or paresis) of the contralateral true vocal cord
  - Presence of a congenital or acquired coagulopathy (relative contraindication)
  - Strong aversion to accept the risks of the surgery or the possibility of needing a secondary revised procedure

Preoperative Preparation

- If the possibility of an intraoperative medialization is anticipated, the surgeon must ascertain the function of the contralateral vocal fold by indirect mirror or flexible laryngoscopy.

OPERATIVE PERIOD

Anesthesia

- Continue the type of anesthesia established by the primary procedure.

Positioning

- Position the neck in a neutral position or slightly extended. Type of anesthesia, neck positioning, and placement of the incision during an immediate intraoperative thyroplasty may be dictated by the needs of the oncologic surgery or the need to control the great vessels of the neck.

Perioperative Antibiotic Prophylaxis

- Administer broad-spectrum perioperative prophylactic antibiotics and systemic corticosteroids.

Monitoring

- Continue standard anesthesia monitoring.

Instruments and Equipment to Have Available

- Flexible laryngoscope
- Unipolar electrocautery with insulated tip
- Insulated bipolar electrocautery
- Single hook retractor
- Double hook retractor
- Senn retractor (dull)
- High-speed drill
- 2-mm cutting or hybrid burr
- 1- and 2-mm bone curettes
- Cottle or Freer periosteal elevator
- Duckbill elevator
- Medical grade silicone block (medium density) or premade silicone implant
- 0.4-mm thickness GOR-TEX patch (alternate)

Key Anatomic Landmarks

- Notch and midline of thyroid cartilage
- Inferior border of the thyroid ala

Prerequisite Skills

- Experience with laryngeal framework surgery

Operative Risks

- Airway compromise
- Misplacement of the prosthesis

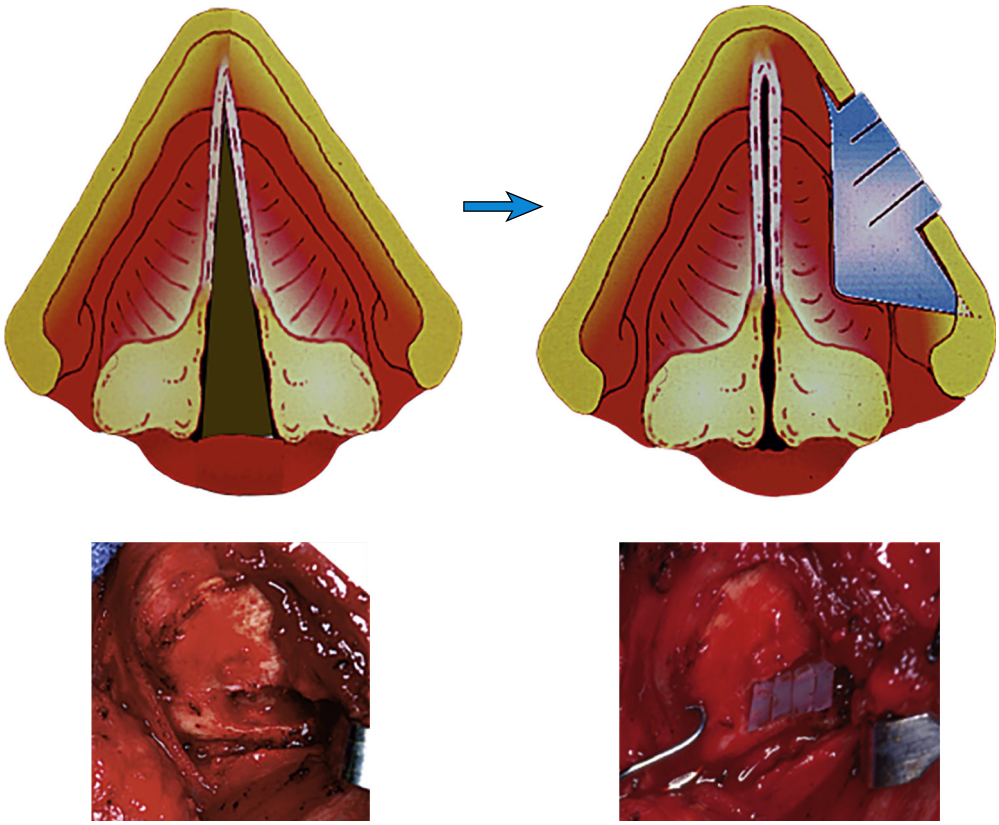

Fig. 6.2. Artistic representation of the effects of a paraglottic silicone implant medializing the vocal process and vocal fold and intraoperative photograph of the window before and after implantation. The implant adds bulk to the vocal fold and, in some cases, displaces the arytenoid posteriorly. The implant is adjustable, partially reversible, and associated with a relatively low degree of technical difficulty and low morbidity.

- Overcorrection or undercorrection
- Extrusion
- Dysphonia

Surgical Technique

- The intraoperative thyroplasty is usually accomplished through the oncologic incision or an extension.
- Divide the strap muscles and perichondrium of the thyroid cartilage at the midline.
- Stabilize the laryngotracheal complex using a single or double hook lodged at the inferior or superior border of the thyroid cartilage. This also facilitates the rotation of the thyroid cartilage, better exposing the thyroid ala. Elevate the ipsilateral strap muscles and perichondrium of the thyroid cartilage to expose its ala.
- Retract the perichondrium and strap muscles with a Senn retractor to expose the cartilage of the thyroid ala (see Fig. 6.1B).
- Transect the insertion of the sternothyroid muscle using a bipolar electrocautery, thus exposing the entire inferior border of the thyroid ala.
- The dimensions of the window vary according to the dimensions of the thyroid ala (in turn vary with height, gender, and age):
  - Ranges between 4 × 8 mm to 5 × 10 mm
  - Position the window 3 to 4 mm above the inferior border of the ala and 5 to 10 mm posterior to midline (for women and men respectively) (see Fig. 6.1A).
- A window may be opened with a 67 Beaver blade (for cartilage) or a high-speed drill with a 2-mm coarse diamond or hybrid burr (for calcified cartilage).
  - The latter is most commonly used because most adults have undergone some ossification of the inferior aspect of the thyroid ala.
  - Drill out the window at perpendicular angles (i.e., avoiding "saucerization") until the inner cortex of the thyroid ala is thin enough to be eggshell fractured, thus allowing its removal with a 1- to 2-mm bone curette.
  - When the cartilage is soft, it can be transected with a #67 Beaver blade and elevated with a middle ear spatula or Cottle elevator.
  - One must avoid saucerization or thinning of the lower strut, which could lead to fracturing and will destabilize the implant.
- Following exposure of the inner perichondrium, a bone curette, Cottle, or duckbill elevator is inserted between the alar cartilage and the inner perichondrium to widely dissect this space.
- Incise the inner perichondrium along the axis of the window.
  - This incision allows the implant to medialize just the area corresponding to the vocalis muscle (as opposed to medializing the entire inner perichondrium).
  - A small artery is commonly encountered at the posterior aspect of this incision, requiring control with a bipolar electrocautery.
- Choice of implant material is surgeon dependent; however, carving an implant from a medium-density medical grade silicone block allows customization, does not suffer compression like the polytetrafluoroethylene strip, and is more cost effective.
- Implants are carved so they are wider and longer than the window, thus avoiding extrusion of the implant through the window.
  - A "peg" that protrudes through the window prevents migration of the implant in the coronal or sagittal planes (Fig. 6.2).

- Extension of the implant for 4 to 6 mm posterior to the window places the point of maximal medialization (4 to 5 mm deep) close to the vocal process of the arytenoid cartilage, thus avoiding and sometimes correcting its anterior subluxation.
- Vertical incisions through the "peg," following the coronal plane and extending halfway into the implant, allow bending the silicone implant, thus facilitating its insertion (see Fig. 6.2).
- Re-approximate the strap muscles and perichondrium with interrupted absorbable sutures.
- Achieve complete hemostasis.
- Close the skin using a multilayer technique.

COMMON ERRORS IN TECHNIQUE

- Stabilization of the larynx with a hook retractor facilitates the completion of the alar window, as well as the insertion of the implant.
- Implantation must be as inferior on the thyroid ala as possible.
- A high-speed drill with a 2-mm burr is most effective in creating the window.
- Incising the inner perichondrium avoids medializing the entire hemilarynx; however, one must be cognizant of an artery that runs medial to the inner perichondrium close to the posterior aspect of the window.
- Point of maximal medialization should be as posterior as possible (close to the vocal process)
- Aim for absolute hemostasis.
- Beware of fracturing the remaining inferior strut.
  - A fracture can be repaired using wire or a 1.5-mm titanium adaptation plate.

POSTOPERATIVE PERIOD[1,6,9,10]

Postoperative Management

- Patients are advised to rest their voice as much as possible for 72 hours and to avoid activities that may require a Valsalva maneuver.
- Provide stool softeners.
- If needed, proton pump inhibitors or H_2 blockers may be prescribed to control gastroesophageal reflux (GER).
- Antitussive medications and humidified air can be provided as needed.
- Systemic corticosteroids may be continued for 24 to 48 hours (empirical).

Complications

- Common complications of an intraoperative thyroplasty type I are related to misplacement or misalignment of the implant.
  - Overmedialization or undermedialization of the vocal fold will fail to correct the glottic gap.
  - Similarly, inappropriate placement of the implant, either too high into the ventricle (or false cord) or too low into the subglottis, will result in an insufficient glottis.
  - Placement that is too anterior will lead to early contact and a very strained voice with increase of the posterior gap (i.e., greater risk of aspiration).
- Extrusion of the implant may occur if it is placed at, or if it migrates into, the ventricle.
- Infection and airway compromise are uncommon complications.

Alternative Management Plan

- An alternative to a medialization laryngoplasty is medialization by injecting the vocal fold with carboxymethylcellulose, hyaluronic acid, acellular dermis, or calcium hydroxyapatite.
- Doing a secondary laryngoplasty or injection if necessary

Evidence-Based Medicine Question

What is the value of medializing a paralyzed vocal fold?

Multiple studies have demonstrated the positive effects of a medialization laryngoplasty in correcting dysphonia and diminishing dysphagia. Cates et al. recently reported their experience with 44 patients with unilateral vocal fold paralysis, who significantly improved on their Eating Assessment Tool (EAT-10) scores after medialization. Similarly, Asik et al. noted statistically significant improvements in the maximum phonation time and in their dyspnea scales in 19 patients with unilateral vocal fold paralysis treated with medialization. In his seminal study, Netterville suggested that these effects are obtained immediately in patients undergoing an intraoperative medialization laryngoplasty, findings that we have encountered in our own experience.[2,3] Therefore, and considering the low morbidity of a medialization laryngoplasty, intraoperative implantation brings immediate benefits that helps the patient's recovery and avoids complications related to respiratory and swallowing deficits caused by glottic insufficiency.

Editorial Comment

Intraoperative medialization laryngoplasty can often provide a significant benefit to the oncologic patient who is undergoing a resection that includes the vagus and/or recurrent laryngeal nerve due to the oncologic resection. This procedure will provide significant, immediate improvement for the patient's pulmonary toilet and voice quality, which is a major safety and quality of life issue. Consent should include the elevated and increased need for revision of the medialization laryngoplasty, given that the procedure is done under general anesthesia. Furthermore, the surgeon planning the intraoperative medialization laryngoplasty should confirm, preoperatively, that the contralateral vocal fold has normal abduction. If this is not done, the patient could have significant airway embarrassment postoperatively due to the lack of preoperative identification of the contralateral vocal fold's decreased abduction. An alternative technique to intraoperative medialization laryngoplasty is to perform a temporary augmentation injection of the vocal fold using a material that will provide 1 to 3 months of vocal fold augmentation. This alternative surgical procedure can be done at the same time as the oncologic resection via direct laryngoscopy with a microscope, or a magnified endoscope, using a temporary vocal fold injection material, such as a collagen-based material, hyaluronic acid, or carboxymethylcellulose. This alternative option provides effective postoperative glottic closure to enhance voice quality and pulmonary toilet. Furthermore, after the temporary material is absorbed, the patient can undergo customized vocal fold closure rehabilitation, if necessary, using a more durable or permanent vocal fold augmentation material (adipose tissue or calcium hydroxyapatite) or undergo medialization laryngoplasty with or without arytenoid adduction.

Clark A. Rosen

Access the review questions and additional sources list online at http://www.expertconsult.com

REFERENCES

1. Siu J, Tam S, Fung K. A comparison of outcomes in interventions for unilateral vocal fold paralysis: a systematic review. Laryngoscope 2016;126(7):1616–1624. http://dx.doi.org/10.1002/lary.25739.
2. Pou A, Carrau R, Eibling D, et al. Laryngeal framework surgery for the management of aspiration in high vagal lesions. Am J Otolaryngol 1998;19:1–7.
3. Carrau R, Pou A, Eibling D, et al. Laryngeal framework surgery for the management of aspiration. Head Neck 1999;21(2):139–145.
4. Netterville JL, Jackson CG, Civantos F. Thyroplasty in the functional rehabilitation of neurotologic skull base surgery patients. Am J Otol 1993;14(5):460–464.
5. Jalisi S, Netterville JL. Rehabilitation after cranial base surgery. Otolaryngol Clin North Am 2009;42(1):49–56. viii.
6. Young VN, Zullo TG, Rosen CA. Analysis of laryngeal framework surgery: 10-year follow-up to a national survey. Laryngoscope 2010;120(8):1602–1608.
7. McCulloch TM, Hoffman HT. Medialization laryngoplasty with expanded polytetrafluoroethylene. Surgical techniques and preliminary results. Ann Otol Rhinol Laryngol 1998;107:841–854.
8. Parker NP, Jabbour N, Lassig AA, et al. Surgical resection of cervical schwannoma and paraganglioma: speech and swallowing outcomes. Ear Nose Throat J 2015;94(8):E1–E7.
9. Parker NP, Barbu AM, Hillman RE, et al. Revision transcervical medialization laryngoplasty for unilateral vocal fold paralysis. Otolaryngol Head Neck Surg 2015;153(4):593–598. http://dx.doi.org/10.1177/0194599815585091.
10. Iwahashi T, Ogawa M, Hosokawa K, et al. Computed tomographic assessment of the causal factors of unsuccessful medialization thyroplasty. Acta Otolaryngol 2015;135(3):283–289.

REVIEW QUESTIONS

1. Dysfunction of the vocal fold may lead to
   a. Poor protection of the tracheobronchial airways during swallowing (i.e., aspiration)
   b. Reduction of efficiency and strength of the cough reflex
   c. Elimination of physiologic positive pressure on expiration (helps to inflate the lungs)
   d. Dysphonia and vocal fatigue
   e. All of the above

2. An intraoperative medialization laryngoplasty strives to
   a. Displace the affected vocal fold toward midline
   b. Augment its bulk
   c. Improve glottic closure
   d. Facilitate neuromuscular compensation
   e. All of the above

3. A medialization laryngoplasty involves
   a. The medialization of the true vocal fold by the insertion of a paraglottic implant
   b. Implantation without being able to ascertain the immediate effect of the implantation upon the quality and strength of the voice or cough
   c. Opening a window and medialization of the true vocal fold the cord using empirical dimensions
   d. Revision surgery in 20%–30% of patients
   e. All of the above

4. Contraindications for an intraoperative medialization laryngoplasty include
   a. Glottic airway stenosis due to edema or abductor paralysis (or paresis) of the contralateral true vocal fold (TVF)
   b. Congenital or acquired coagulopathy
   c. Tongue paralysis
   d. All of the above
   e. a and b

5. The most common complication of an intraoperative medialization laryngoplasty is
   a. Hematoma
   b. Airway obstruction
   c. Overmedialization or undermedialization
   d. Wound infection
   e. Extrusion of the implant

ADDITIONAL SOURCES

Asik MB, Karasimav O, Birkent H, et al. Airway and respiration parameters improve following vocal fold medialization: a prospective study. Ann Otol Rhinol Laryngol 2015;124(12):972–977. http://dx.doi.org/10.1177/0003489415593558.

Cates DJ, Venkatesan NN, Strong B, et al. Effect of vocal fold medialization on dysphagia in patients with unilateral vocal fold immobility. Otolaryngol Head Neck Surg 2016;155(3):454–457. http://dx.doi.org/10.1177/0194599816645765.

7 Excision of Laryngocele

Tack-Kyun Kwon

INTRODUCTION

The ventricle ends in a blind pouch anteriorly called the sacculus or saccule, which is variously known as the appendix ventriculi larynges or Hilton's sac. Laryngocele refers to a pathologic cystic dilation and enlargement of the saccule of the laryngeal ventricle.[1] It is a rare and benign lesion of the larynx that may present with hoarseness, dyspnea, or dysphagia, depending on its size.

Laryngoceles are classified into three groups: the internal, external, and mixed type. In the internal type, the swelling is confined within the larynx. This may be seen as a swelling of the ventricle, hiding the true cord of the same side, and even extending across the midline to compromise the airway. The internal type may extend to the aryepiglottic fold and even to the base of the tongue, completely filling one vallecula.

The external type appears as a swelling in the neck, usually at about the level of the hyoid bone and just anterior to the sternocleidomastoid muscle, but can be found almost anywhere in the neck. The sacculus extends and perforates the thyrohyoid membrane where the superior laryngeal neurovascular bundle passes. This seems to be the weakest point of the membrane. In the mixed or combined type, the internal and external portions are joined by an isthmus that gives an hourglass appearance.[1]

DeSanto classified benign cystic lesions derived from the saccule into laryngocele, laryngeal mucocele, large saccules, and laryngeal saccular cyst, depending on the size of the saccule, the presence of a communication between the saccule and the laryngeal lumen, the presence of inflammation, and the presence of symptom.[2] They concluded that these lesions have a common pathology but show different manifestations in a developmental spectrum.

Surgical excision is indicated when the patient has apparent symptoms and a differential diagnosis is needed. A key issue is whether complete excision can be achieved without complications.

The author describes various approaches for safe surgical excision of laryngoceles.

KEY OPERATIVE LEARNING POINTS

- Diagnosis and differential diagnosis are critical.
- Identification of coexisting pathology is necessary.
- Airway compromise should be avoided.
- Temporary tracheostomy may be needed to prevent postoperative airway compromise.
- Care should be taken to prevent injury to the superior laryngeal neurovascular bundle.
- Careful selection of patients is important, as the surgical approach can vary according to the size and location of the laryngocele.

PREOPERATIVE PERIOD

It is important to know that not all laryngoceles induce symptoms and not all laryngoceles should be surgically removed. Most laryngoceles are asymptomatic at onset and do not produce symptoms until they are quite large. The most common symptom is hoarseness, but the patients may also present with dyspnea or dysphagia, depending on the size of the laryngocele, or may present with a mass in the neck depending upon the location of the external laryngocele.[1]

An asymptomatic laryngocele incidentally found on radiographic studies is not an indication for surgical treatment.[3] Office laryngoscopy is necessary to reveal a unilateral or bilateral bulge of the false vocal fold and/or aryepiglottic fold (Fig. 7.1). Examination of the ventricle is also necessary to identify synchronous pathologies that might have caused the laryngocele, but this is almost impossible to do in an office visit because the ventricular cavity is obscured by the laryngocele.

Several imaging techniques can be used to diagnose a laryngocele. Computed tomography (CT) is the gold standard, as it allows the visualization of the air-filled saccule and its anatomic relations (Fig. 7.2). CT scan has proven to be the most accurate imaging method in defining the spatial relationship between the laryngocele and the laryngeal structures and extralaryngeal soft tissues, in differentiating the laryngocele from other cystic formations, and in identifying the coexistence of a laryngeal cancer.[4]

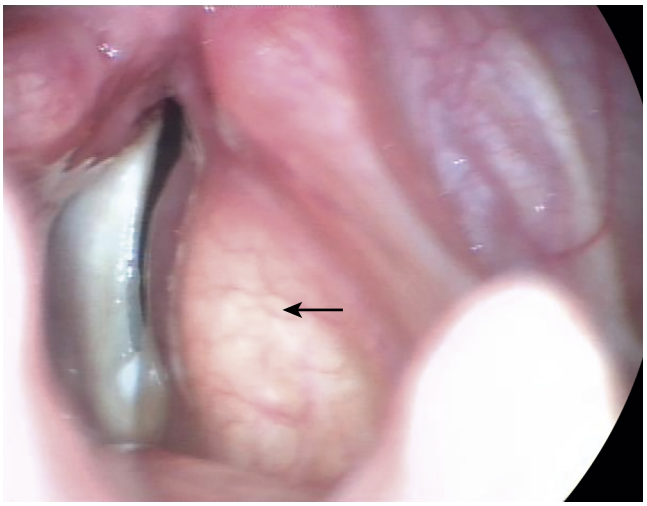

Fig. 7.1. Laryngoscopic view of internal laryngocele (black arrow).

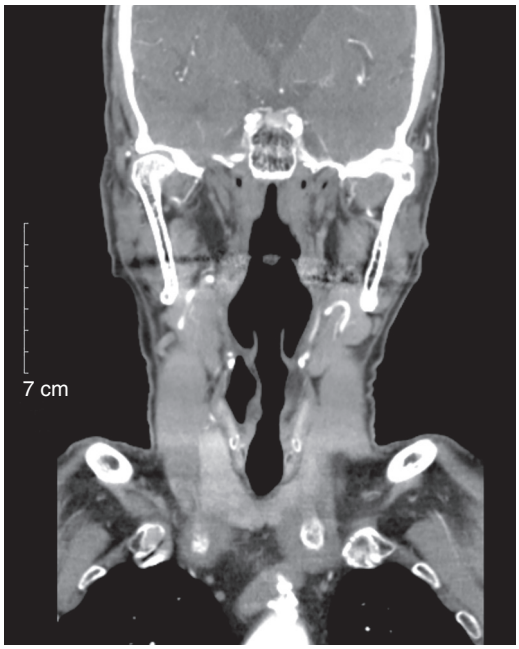

Fig. 7.2. A coronal computed tomography scan showing an internal laryngocele.

History

1. History of present illness
   a. Occupations: Trumpet/trombone player, glass blower, street hawker, and singer
   b. Risk factors for laryngeal cancer: Smoking, alcohol, human papilloma virus (HPV) infection
   c. Symptoms indicating the laryngocele status: Dyspnea, dysphonia, dysphagia, fever, pain, mass in the neck
2. Past medical history
   a. Previous surgical procedures on the larynx and neck
   b. Previous history of chronic laryngeal inflammation, such as tuberculosis and amyloidosis
   c. Previous history of trauma to the larynx or neck
3. Prior treatment of larynx or neck
   a. Previous endoscopic excision of a laryngeal mass
   b. Previous surgery for a mass in the neck
4. Medical illness
   a. Cardiopulmonary diseases
   b. Infectious diseases
   c. Immunosuppression, e.g., AIDS
   d. Alcoholism and/or other substance abuse
5. Medications
   a. Anticoagulants
   b. Alcohol (risk of perioperative alcohol withdrawal syndrome)
   c. Allergies to antibiotics
6. Mental and social status
   a. Ability to give informed consent
   b. Cosmetic consideration

Physical Examination

1. Neck
   a. Palpate both sides of the neck for the presence of a cervical mass.
   b. Identify external component of pathology
      1) Vertical location
         a) Cricothyroid area
         b) Thyrohyoid area
      2) Valsalva maneuver
         a) Observe size increase with/without a hissing noise.
      3) Gentle manual palpation over the mass
         b) Observe reduction in size with/without a hissing noise.
   c. Identify any evidence of previous surgery.
2. Laryngeal endoscopic examination
   a. Location of a bulging mass
      1) Unilateral/bilateral
      2) False vocal fold, ventricle, aryepiglottic fold
   b. Coexisting pathology
      1) Ventricular/vocal fold mass
      2) Signs of inflammation
   c. Vocal fold movement/mucosal lesions
3. General health
   a. Cardiovascular
   b. Respiratory
   c. Mental

Imaging

1. Chest radiograph
   a. Synchronous lung pathology
   b. Pulmonary and cardiac status
2. Esophagography: Only if dysphagia is present
3. Ultrasonography
   a. Useful method for screening
   b. Initial diagnostic method for a mass in the neck, differentiating the contents and location of cystic masses
4. CT scan
   a. Gold standard for diagnosis and differential diagnosis
   b. Confirms diagnosis and type of laryngocele
   c. Differential diagnosis from other cystic benign mass and neoplasm
5. Magnetic resonance imaging (MRI)
   a. Rarely indicated
   b. Offers detailed information on the boundaries of laryngoceles: Indicated for those cases associated with a tumor of the larynx

Indications

- Progressively symptomatic laryngocele
  - Hoarseness/breathing difficulties/swallowing difficulties
  - Frequent infection
  - Mass in the neck: Cosmetic concern
- Coexisting causative pathology, suspicious for malignancy

Contraindications

1. Patient factors
   a. Medically unfit for general anesthesia
   b. Inability to give informed consent
2. Disease factors
   a. Acute infection and inflammation
   b. Asymptomatic laryngocele found incidentally on radiography

Preoperative Preparation

1. Evaluations by
   a. Speech and swallowing therapist
   b. Anesthesiology
2. Discontinue antiplatelet drugs if possible.
3. Tracheostomy if patient has progressive dyspnea
4. Informed consent should include the possibility of a temporary tracheostomy.
   a. If endotracheal intubation fails
   b. For airway obstruction

OPERATIVE PERIOD

Anesthesia

- If endoscopic laser surgery is planned, ask the anesthesiologists to intubate the patient with a small (5 for female and 5.5 for male) laser-safe endotracheal tube.
- The surgeon should always be present during induction of anesthesia, as a large internal laryngocele may occlude the airway, and it may be difficult or impossible for the anesthesiologist to intubate the patient.
- Should the anesthesiologist be unable to intubate the larynx, the surgeon may have to intubate through an operating laryngoscope or do an emergency cricothyrotomy or tracheostomy.
- A temporary tracheostomy may be required for patients with a large internal laryngocele to prevent postoperative airway compromise due to edema.
- A large-bore suction device should be prepared during the intubation procedure to suction out fluid when a laryngocele with fluid content is accidentally ruptured.

Positioning

- For the endoscopic approach, the position of the patient is the same as with endoscopic laser surgery with suspension laryngoscopy. Suspension laryngoscopy is also necessary prior to an external approach.
- For the external approach, after suspension laryngoscopic examination, the patient is placed in the supine position with the patient's neck extended by placing a shoulder roll with the head rotated to the side opposite the lesion.

Perioperative Antibiotic Prophylaxis

- Clean contaminated surgery
- Antibiotics are administered during induction of anesthesia and continued for 24 hours.
- Choices
  - Clindamycin
  - Amoxicillin-clavulanate
  - Cephalosporin and metronidazole

Monitoring

- Routine anesthetic monitoring, including pulse oximetry

Operative Risks

- Infection
- Airway obstruction
- Injury to superior laryngeal nerve

Instruments and Equipment to Have Available

- Laser equipment
  - CO_2 laser
  - Micromanipulator with coupling device between microscope and laser
  - Proper laser safety precautions (i.e., endotracheal tube protection, oxygen content adjustment, and eye protection for patient and staff)
- Microsuspension laryngoscopy
  - High-quality operating microscope with 400 mm lens
  - Rigid laryngoscope with large caliber and suction channel
  - Hopkins telescope (0, 30, and 70 degree)
  - Suspension system
  - Operating chair with arm supports
  - Microscopic endolaryngeal surgical instruments
  - Electrocautery suction tip and vascular clip set
- Resection and neck dissections
  - Standard head and neck set
  - Powered drill (used for thyrotomy on calcified thyroid cartilage)
  - Tracheostomy tubes and anesthetic tubing

Key Anatomic Landmarks

- Endoscopic laser surgery
  - True vocal fold/false vocal fold
  - Ventricle/saccule
  - Aryepiglottic fold
  - Pharyngoepiglottic fold (superior laryngeal neurovascular bundle)
  - Pyriform sinus
- Lateral thyrotomy approach
  - Subplatysmal skin flap
  - Sternohyoid muscles
  - Thyrohyoid muscles
  - Thyrohyoid membrane
  - Superior laryngeal neurovascular bundle
  - Thyroid cartilage
  - Paraglottic space

Prerequisite Skills

- Microsuspension laryngoscopy
- Laser microlaryngoscopic surgery
- Lateral thyrotomy
- Tracheostomy

Surgical Technique

- ***Microsuspension laryngoscopy***
  - Microscopic and endoscopic evaluation of the larynx should be performed prior to either endoscopic laser excision or external approach.
  - Evaluation of the ventricle using angled telescopes (30 and 70 degree)
  - Careful examination of the ventricle to identify any coexisting ventricular pathology
- ***Endoscopic laser excision***
  - Using a large-diameter laryngoscope, such as the Lindholm or Werda type laryngoscope, expose the entire extent of the laryngocele, if possible.
  - The lower airway should be covered with saline-soaked cottonoids to prevent laser injury and aspiration of the contents of the laryngocele.
  - Using a focused laser beam, make an incision in the most prominent false vocal fold mucosa overlying the laryngocele (Fig. 7.3).
  - The incision is extended to the deeper layer until the surface of the laryngocele is reached. To identify the neck of the sac in the ventricle, a part of the false vocal fold mucosa can be resected with the sac.
  - With gentle retraction using forceps or suction, the sac is carefully dissected from the surrounding soft tissues using a microdissector or suction tip.
  - During dissection, minor bleeding can be controlled with a defocused laser, but electrocautery or vascular clips can be used if further hemostasis is needed.
  - During the laser procedure, great care should be taken to protect the underlying true vocal fold from laser injury.
  - After the laryngocele is removed, the redundant false vocal fold mucosa may be sutured or trimmed to prevent airway compromise.

- *External approach with thyrotomy*
  - A horizontal incision is made in a skin crease; the skin flaps are elevated in the subplatysmal plane down to the inferior border of the thyroid cartilage and superiorly to the hyoid bone.
  - The level of the horizontal skin incision depends upon the location and size of the external component of the laryngocele.
  - The strap muscle is divided in the midline, and the thyroid cartilage is exposed.
  - If necessary, the superior aspect of the sternothyroid, omohyoid, and thyrohyoid muscles may be divided along the inferior border of the hyoid bone for better exposure of the laryngocele.
  - The external component of the laryngocele is identified and carefully dissected off of the surrounding soft tissues up to the thyrohyoid area. The laryngocele may be retracted with forceps and dissected carefully to avoid injury to the superior laryngeal neurovascular bundle.
  - After identification of the superior laryngeal neurovascular bundle, the thyrohyoid membrane is sectioned along the superior border of the thyroid cartilage. The superior aspect of the internal laryngocele is now visualized through this incision.

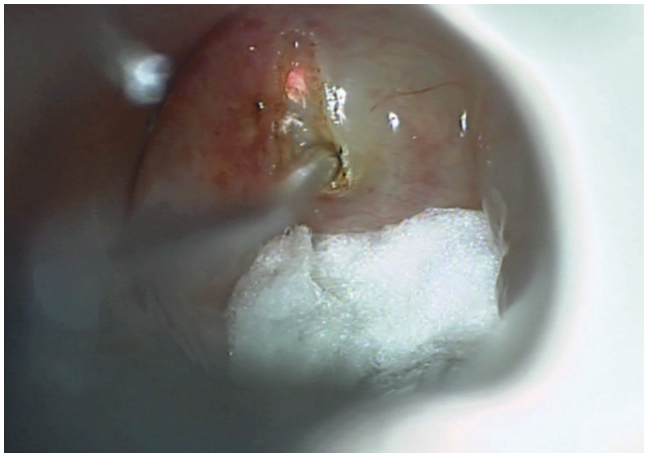

Fig. 7.3. An incision is made using a CO_2 laser during endoscopic excision of a laryngocele. Note the suction is being used for dissection.

  - Although several thyrotomy incisions have been reported, I prefer a lateral thyrotomy approach. This consists of a vertical incision at the junction of anterior and the middle third of the thyroid cartilage, splitting it in half, and retracting both sides for exposure of the paraglottis (Fig. 7.4A). Thome et al. reported V-shaped cuts in the superior half of the thyroid lamina, creating a triangular window through the thyroid cartilage.[5] Having made the thyrotomy incision, the laryngocele is dissected under direct vision through this incision (see Fig. 7.4B).
  - The thyrotomy incision can be made using #15 blade, but a power drill or oscillating saw is necessary when the thyroid cartilage is ossified.
  - After further dissection along the internal compartment of the sac, the most inferior limit of the laryngocele at the anterior aspect of the ventricle and its entry into the larynx is sutured in a figure-eight fashion with absorbable suture and the laryngocele is excised. If the base of the laryngocele is not clearly identified, the most inferior limit of the laryngocele may be clamped and ligated with silk ligature.
  - If a lateral thyrotomy incision has been made, the thyrotomy incision is approximated with 4-0 nylon suture. No reconstruction is needed after a V-shaped resection of the thyroid cartilage.
  - The strap muscles are anchored in their original position on the hyoid bone. After thorough irrigation, the skin incision is closed in layers over a closed suction drain.
  - A tracheostomy may be performed if postoperative edema of the airway is anticipated.

Common Errors in Technique

- When a lateral thyrotomy incision is made, be careful not to elevate the perichondrium off of the thyroid cartilage along the incision. Without perichondrial attachment to the thyroid cartilage, the cartilage tends to break easily during approximation with sutures.
- Laryngoceles are lined by thin respiratory mucosa. Soft tissue dissection around the laryngocele should be made until a glistening capsule is clearly seen to prevent unwanted injury to the surrounding structures.
- During dissection around the thyrohyoid membrane, great care should be taken not to injure the superior laryngeal neurovascular bundle.

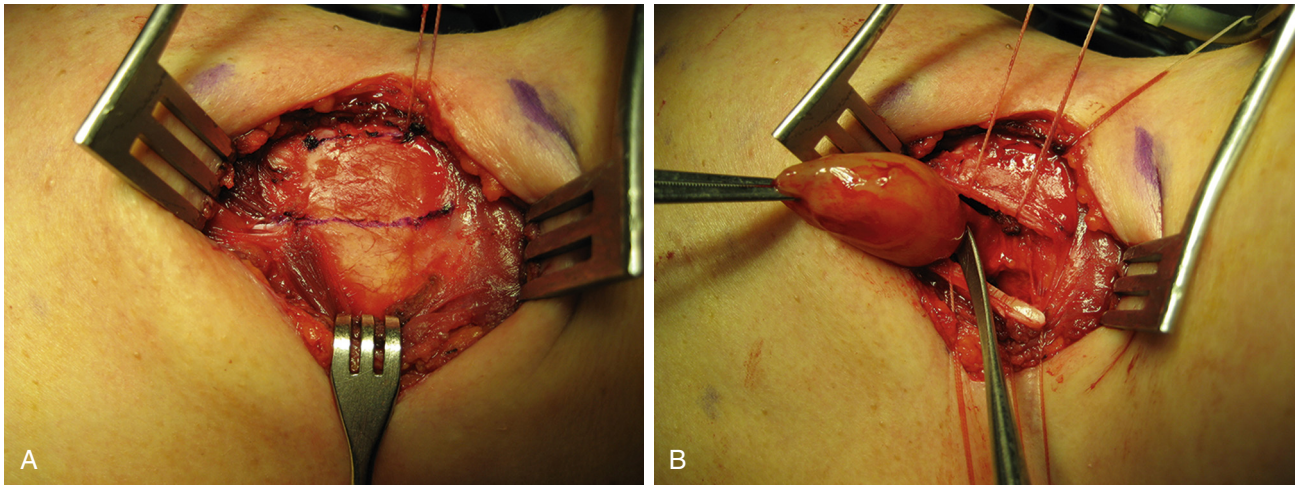

Fig. 7.4. A, A lateral thyrotomy incision is made at the junction of the anterior and the middle third of the thyroid cartilage. **B,** The laryngocele is retracted laterally and dissected free of the surrounding tissue.

- Incomplete excision of a laryngocele may result in recurrence; therefore the base of the saccule must be resected if possible.
- Without preoperative imaging studies, the external component of the laryngocele may be neglected, resulting in recurrence in the neck.

POSTOPERATIVE PERIOD

- The patient must be hospitalized overnight for observation for airway obstruction.

POSTOPERATIVE MANAGEMENT

- Perioperative antibiotics
- Routine intravenous steroid administration, intra- and postoperatively, every 8 hours for 24 hours
- Tracheostomy tube can be removed once follow-up examination reveals a patent airway
- Diet as tolerated

COMPLICATIONS

- Postoperative airway compromise due to edema in the wound, redundant mucosa, or hematoma
- Injury to the superior laryngeal nerve resulting in aspiration and dysphagia
- Bleeding
- Recurrence of the laryngocele

ALTERNATIVE MANAGEMENT PLAN

Selected patients in poor general condition for general anesthesia may be operated under local anesthesia. Asymptomatic patients with a small to moderate size laryngocele may just be observed.

DISCUSSION

Evidence-Based Medicine Questions

What is the function of the saccule and how does a laryngocele develop?

The laryngeal ventricle is a normal finding in man and is found only in mammals. It is a small elliptical recess located between the false vocal folds above and the true vocal folds below.[1] The laryngeal ventricle was first described by Galen; however, Morgagni described the anatomic features more completely, so it is also called the sinus of Morgagni.

In the roof anteriorly the ventricle ends in a blind pouch called the sacculus or saccule, which is variously known as the appendix ventriculi larynges or Hilton's sac.

Embryologically, the ventricle is formed by the thyroarytenoid sphincter splitting and forming the lower internal true vocal folds and the upper external false vocal folds. The recess left between them is the ventricle. Toward the end of the second month of intrauterine development, the saccule takes form and at birth is of relatively large size; this remains large until it begins to regress at the end of the sixth year.[6]

Laryngeal air sacs are normal anatomic findings in many animals. In some mammals, the air sacs extend out into the neck, even over the pectoral muscle onto the anterior chest wall. The purpose of such large sacs is to serve as a breathing apparatus, enabling the animal to hold its breath longer.[7]

Several factors contribute to the formation of a laryngocele. The two most common factors seem to be a prolonged increase in intraglottic pressure and associated long saccule.

The laryngeal mechanics of increased intraglottic pressure are as follows: Strenuous expiratory effort causes closure of the sphincters of the false cords and prevents air from escaping. The sphincters are the thyroarytenoid, thyroepiglottic, and aryepiglottic muscles. The true cords also close, but with any additional increase in pressure, air will escape through the true cords but not through the false cords. This causes a great increase in pressure in the ventricle and saccule, thereby causing dilatation of the saccule and the formation of a laryngocele in those who are predisposed. This is the reason why laryngoceles are not uncommonly seen in brass players and glassblowers.

It has also been reported that external laryngeal trauma, infectious diseases such as tuberculosis and syphilis, and tumors are associated with laryngoceles.[1]

Is laryngeal cancer correlated with laryngocele and how?

Many papers reported the correlation between laryngeal cancer and laryngocele.[5] Three possible explanations for this correlation have been proposed. The first theory is that distortion of the saccule may create a one-way valve with subsequent inflation and distention of the saccule. The second theory is that cancer may preferentially arise in the epithelium of the saccule. The third theory is that the cancer mass can alter laryngeal physiology and increase intralaryngeal pressure, resulting in dilation of the saccule.

The first theory does not explain the existence of contralateral or bilateral laryngocele, and the second theory provides no obvious scientific evidence to support it. The third theory is thought to be the most reliable so far.[5]

Editorial Comment

The presence of cancer in a laryngocele in North America is truly unusual. We cannot explain the relationship between cancer and a laryngocele based on our experience.

Jonas T. Johnson

Access the review questions and additional sources list online at http://www.expertconsult.com

REFERENCES

1. Wright Jr LD, Maguda TA. Laryngocele: case report and review of the literature. Laryngoscope 1964;74:396–412.
2. DeSanto LW. Laryngocele, laryngeal mucocele, large saccules, and laryngeal saccular cysts: a developmental spectrum. Laryngoscope 1974;84(8):1291–1296.
3. Isaacson G, Sataloff RT. Bilateral laryngoceles in a young trumpet player: case report. Ear Nose Throat J 2000;79(4):272–4.
4. Lancella A, Abbate G, Dosdegani R. Mixed laryngocele: a case report and review of the literature. Acta Otorhinolaryngol Ital 2007;27(5):255–7.
5. Thome R, Thome DC, De La Cortina RA. Lateral thyrotomy approach to the paraglottic space for laryngocele resection. Laryngoscope 2000;110(3 Pt 1):447–450.
6. Lane SL, Cohen B, Ippolito C. Coexisting internal and external laryngoceles: report of a case. Am J Surg 1958;96(6):810–4.
7. Kucera Jr WJ, Priest RE. Laryngocele; laryngeal air-sac of lower animals appearing in man; report of three cases. Minn Med 1956;39(3):137–140.

REVIEW QUESTIONS

1. Which of the following statements about laryngocele is TRUE?
   a. Laryngocele is the most common benign cystic lesion in the larynx.
   b. Laryngocele should be surgically removed if found in radiologic studies.
   c. Laryngocele usually originates from the posterior end of the ventricle.
   d. Laryngocele has the same pathology as a saccular cyst.

2. Which of the following statements on surgical treatment of laryngocele is TRUE?
   a. Marsupialization is one of the standard surgical approaches for laryngocele.
   b. Lateral thyrotomy should be made after a perichondrial flap is elevated.
   c. Microsuspension laryngoscopy should be done prior to both endoscopic and external approach.
   d. False vocal fold mucosa should be preserved during endoscopic resection of a laryngocele.

3. Which of the following statements about laryngocele is FALSE?
   a. Most laryngoceles are symptomatic.
   b. There is association with laryngeal cancer.
   c. A glassblower is more likely to develop a laryngocele than others.
   d. Laryngocele is lined with ciliated pseudostratified columnar epithelium.

ADDITIONAL SOURCES

Endoscopic excision of saccular cyst. In: Rosen CA, Simpson CB, editors. Operative Techniques in Laryngology. Berlin, Germany: Springer-Verlag; 2008. p. 155–158.

Excision of combined laryngocele. In: Rosen CA, Simpson CB, editors. Operative Techniques in Laryngology. Berlin, Germany: Springer-Verlag; 2008. p. 273–277.

8 Laryngeal Trauma

Apurva Thekdi, Clark A. Rosen

INTRODUCTION

Trauma to the larynx accounts for less than 1% of all trauma. This is explained in part by the fact that the larynx is relatively protected by the mandible, sternum, and flexion mechanism of the neck. An alternative perspective is the percentage of patients with laryngeal injuries who are dead on arrival at the emergency department. Line and associates[1] reported a series of 171 victims of blunt neck trauma (strangulation), of whom 112 persons (65%) did not survive. It has been estimated that the emergency departments in busy trauma centers will treat one patient with laryngeal trauma for every 5000 to 30,000 emergency department visits.[2]

A basic knowledge of the laryngeal anatomy and physiology is fundamental to understanding the principles established for the management of laryngeal trauma. The larynx is classically divided into three anatomic areas with different functions and characteristics (Fig. 8.1). The primary functions of the larynx are to serve as an airway conduit and to protect the lower respiratory tract. The production of voice, although extremely important for socioeconomic development, is of teleological secondary importance. Respiratory epithelium that is part of the mucociliary clearing system of the respiratory tract lines most of the larynx. The sensory innervation of the supraglottic larynx is supplied by the paired superior laryngeal nerves, which are also branches of the vagus nerves. The superior laryngeal nerves also innervate the cricothyroid muscle, which tightens the vocal folds and, accordingly, is responsible for pitch. The function of the larynx depends on a complex arrangement of intrinsic muscles innervated by the superior and recurrent laryngeal nerves, which are branches of the right and left vagus nerves. A framework composed of cartilage and ligaments supports the laryngeal soft tissue. The cartilaginous framework of the larynx relies on the blood supply provided by the perichondrium. This framework is then suspended on a sling between the mandible (via the hyoid bone) and sternum.

Trauma to the larynx may manifest in a wide variety of ways, reflecting a multitude of uncontrollable variables. Accordingly, evaluation and management of the patient with laryngeal trauma requires accurate assessment, a working understanding of the principles of laryngeal reconstruction, and an ability to accommodate unexpected findings at exploration in the operating room.

Children rarely suffer direct trauma to the larynx. This reflects the morphologic differences between children and adults. The larynx in children is relatively protected since it is high in the neck and generally shielded from direct trauma by the mandible. In addition, the soft, flexible cartilaginous structures of the pediatric laryngotracheal complex are more tolerant of blunt trauma.

The mechanism of trauma greatly influences the likelihood for associated injury and the need for multidisciplinary collaboration. In general, laryngeal trauma is classified as *blunt* or *penetrating*. The most common mechanism of injury is blunt trauma.[3] With a patient injured in a motor vehicle accident, a broad general assessment of the patient's overall well-being is clearly mandated.

Blunt trauma to the cervical region may produce serious and life-threatening injury, including total obstruction of the airway and significant life-threatening vascular disruption (Fig. 8.2). Cervical spine injuries occur in a significant percentage of patients and may not be appreciated initially because of the obvious soft tissue damage. Injuries to major structures are more clearly apparent when a sharp instrument or penetrating

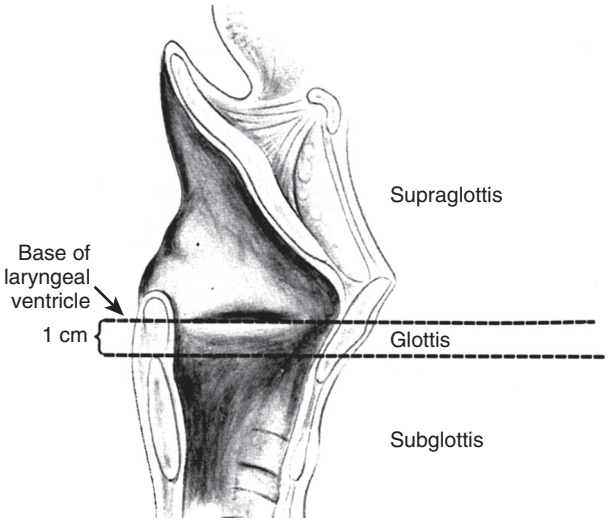

Fig. 8.1. Sagittal drawing of the larynx depicting the three anatomic areas. The glottic larynx extends from the free edge of the true vocal cord inferiorly 1 cm. This approximates the histologic observation of stratified squamous epithelium on the glottis changing to respiratory epithelium of the subglottis.

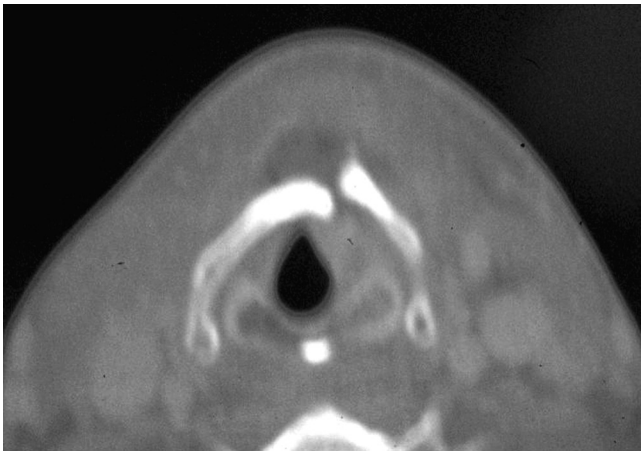

Fig. 8.2. Computed tomography demonstrates a displaced cartilage fracture of the thyroid cartilage. The integrity of the mucosa should be confirmed endoscopically. The cartilage requires reduction and fixation.

missile results in soft tissue wounds. Nevertheless, injury may be significant even with minimal signs of external wounds. Any type of blunt trauma may disrupt the laryngeal soft tissue or its cartilaginous framework, producing scarring, loss of support, and subsequent collapse of the airway and stricture. It may also dislocate the cricoarytenoid joint, leading to fixation of the vocal cord, or disrupt the laryngeal innervation, paralyzing the vocal cords. It is important to realize that significant laryngeal trauma may be possible in the absence of signs of external injury.

The larynx may also be involved in penetrating trauma to the neck. It is important to recognize that approximately 60% of the patients with penetrating trauma to the larynx will have other associated injuries, such as neurologic vascular or esophageal injuries.[2] Penetrating trauma includes a wide range of injuries, ranging from stab wounds to gunshot wounds. Although stab wounds usually follow a straight line or predictable path, bullets or other projectiles tend to follow planes of least resistance (e.g., fascial planes), producing less predictable injuries. Bullets cause injury both by direct contact as well as tissue distention caused by the abrupt displacement of the tissues produced by the bullet's shock wave (Fig. 8.3). The trauma caused by this shock wave increases as the square of the velocity, hence high-velocity weapons such as assault rifles cause much greater injury.

A peculiar injury is one produced by strangulation, which is a broad term that includes hanging, garroting (ligature strangulation), throttling (manual compression), and chokeholds. Strangulation accounts for 10% of the violent deaths in the United States.[1] Victims of strangulation most often die at the site of the incident, accounting for its infrequency as an emergency department visit.[4] Strangulation is characterized by the application of a static force over the laryngeal framework, which may fracture the cartilage and not disrupt the mucosa. This latter fact frequently leads the examiner to the false assumption that the victim has not suffered a significant injury. The classic injury in strangulation victims is a fracture of the superior thyroid cornu, which may be accompanied by cordal hematomas, petechiae of the endolaryngeal mucosa, or arytenoid dislocation. A history of significant bleeding that has spontaneously resolved or a hematoma that developed rapidly suggests a major vascular injury that will require evaluation. The Isadora Duncan syndrome consists of strangulation with carotid contusion, avulsion, or occlusion and laryngeal rupture.[5]



Fig. 8.3. This open laryngeal injury (gunshot wound) requires emergent establishment of a tracheostomy and then comprehensive repair of both mucosa and framework trauma.

KEY OPERATIVE LEARNING POINTS

- The glottis depends on cartilaginous support, mobility of the cricoarytenoid joint, and perfect neuromuscular coordination to perform its sphincteric and voice-producing functions.
- The adult airway is narrowest at the glottic level; therefore any decrease in the cross-sectional area of the airway at the level of the vocal cords may result in significant compromise of the airway (proportional to the square of the radius).
- The subglottis is supported by the cricoid cartilage, which is the only circular cartilage of the laryngotracheal complex.
- Penetrating laryngeal trauma requires endoscopic evaluation and repair of disrupted epithelium and cartilage.
- Voice change following blunt cervical trauma mandates evaluation of the laryngeal anatomy.
- All patients with significant laryngeal trauma should be considered at risk for an injury to the cervical spine.
- Penetrating airway trauma may be associated with significant neurovascular injury.
- Tracheostomy (or cricothyrotomy) may be required when laryngeal trauma results in stridor or cyanosis.
- Displaced fractures of the thyroid and cricoid cartilage require early reduction to improve long-term results.
- Keels and stents may facilitate epithelial regrowth and prevent scarring after major disruption of the laryngeal structures.
- Keels are preferred to stenting. If stenting is required for support, minimize the length of time the stent is in place to prevent scarring.
- Tracheostomy tubes must be secured in the presence of severe laryngeal trauma.
- Airway evaluation (often with flexible laryngoscopy) in the patient who is suspect for laryngeal trauma is vital prior to "elective" radiologic evaluations.
- When possible, awake transnasal flexible laryngoscopy is a vital tool in the evaluation of the injury.
- Lacerations of the cervical esophagus or pharynx may occur, primarily with penetrating injuries, and need to be ruled out. Failure to recognize and treat them can lead to serious infectious complications. Depending on the circumstances, evaluation with either contrast radiographic studies or endoscopy is appropriate.

PREOPERATIVE PERIOD

History

- The nature of the trauma is pivotal to assessment of laryngeal trauma.
- When evaluating patients with penetrating trauma, it is important to know the circumstances of the attack: factors such as angle of penetration, types of bullet and weapon, and distance of attack are all important to estimate the degree of trauma.
- Factors that may significantly affect subsequent patient care include patient age, mechanism of injury, velocity of injury, and cutaneous penetration.
- The integrity of the airway must be initially assessed. Cyanosis and stridor are indications for immediate intervention. Intubation of the acutely traumatized airway may be dangerous or impossible. Tracheostomy or, under some circumstances, cricothyrotomy should be initiated.[3]
- When the status of the cervical spine is either suspect or uncertain, manipulation of the neck and positioning of the patient for tracheostomy may be difficult and imprudent.

- Under extreme circumstances, insertion of a large-bore needle directly through the cricothyroid membrane or into the trachea with administration of oxygen may be lifesaving and "buy time" for definitive airway intervention.
  - Patients with laryngeal trauma almost invariably have primarily inspiratory obstruction owing to collapse of the soft tissues during inspiration.
  - Oxygen delivered directly into the trachea may be expired through the injured larynx in most patients.
  - Concurrent intrathoracic injury, including pneumothorax, fractured ribs with a flail chest, or a pulmonary contusion, may be the cause of respiratory distress and must be ruled out.

Physical Examination

- The principles (airway, breathing, circulation) of trauma care must be recalled and be kept primal.
- Even with trauma limited to the head and neck, the integrity of the cardiovascular system, potential for intracranial injury, and status of the cervical spine must always be assessed as an initial step of management.
- Airway assessment
- Cranial nerve assessment
- Flexible laryngoscopy, when possible, is a vital aspect of the physical examination to assess airway patency, mucosal integrity, and vocal fold motion.
- Dysphonia, hoarseness, dysphagia, or odynophagia in the setting of blunt trauma to the neck must be considered evidence of severe laryngeal injury until proven otherwise.
- The patient suspected of having trauma of the larynx must have an airway assessment (ideally, flexible laryngoscopy) prior to being sent out of the emergency department for radiologic testing.
- The finding of cervical subcutaneous emphysema warrants a presumptive diagnosis of a ruptured viscus.[6] It is incumbent on the emergency team to identify the injured area and make plans for subsequent management.
- The potential for injury to cranial nerves must be considered.
  - Neuropathy in the face of a sharp or penetrating injury is an indication for nerve exploration and neurorrhaphy as needed at the time of surgical exploration.
  - Neurorrhaphy may result in synkinesis, but some authors have reported useful return of motion or at least tone.[7]
- The potential for vascular injury must be considered. An expanding hematoma or continuing hemorrhage from an open wound is an indication for immediate operative exploration.
  - The presence of a bruit may be one indication of such an injury. The value of close collaboration with a vascular surgery team is critical.
- When circumstances permit, a careful physical examination followed by directed imaging studies will facilitate subsequent treatment planning and intervention.
- In one study of patients with laryngotracheal injury, the most prevalent findings on physical examination were subcutaneous emphysema (53%), hoarseness (47%), neck tenderness (27%), and stridor (20%).[8]
- Physical examination should include assessment of the airway and voice.
  - Dysphonia or hoarseness suggests laryngeal injury.
- The soft tissues of the neck should be carefully observed and palpated.
  - The loss of the prominent contours of the thyroid cartilage and cricoid ring may be significant observations.
  - Point tenderness should lead to suspicion of a fracture.
  - Soft tissue abrasion and ecchymosis help confirm the severity and direction of injury.
  - The presence of a mass often indicates vascular injury.
  - Soft tissue emphysema indicates perforation of an air-containing viscus.
- Examination of the oral cavity and oropharynx should be supplemented by direct visualization of the larynx and hypopharynx. This can be undertaken with either a rigid telescope or flexible laryngoscopy. The observer should note soft tissue disruption, lacerations, edema, or ecchymosis.
- Patency of the airway and vocal fold function should be ascertained.
  - Shortening of the anteroposterior diameter of the glottis is an indication of fracture and subluxation of the thyroid cartilage.
  - The arytenoid cartilage may be dislocated.
- Traumatic separation of the larynx from the trachea can occur even in blunt injuries and is frequently associated with bilateral vocal cord paralysis.

Imaging

- The airway must be secure. Flexible laryngoscopy must be done prior to any imaging.
- Cervical spine imaging is primal for most patients suspected of potential laryngeal trauma.
- Angiography or computed tomography (CT) angiogram should be done when vascular injury is suspected.
- Fine-cut CT scan of the larynx with contrast (coronal and axial) (Figs. 8.4 to 8.6)
- Presence or absence of laryngeal fracture
- Laryngeal fracture displaced or nondisplaced
- Esophagram should be considered for penetrating trauma near the esophagus.

Indications

- Displaced laryngeal fracture
- Foreshortened vocal fold
- Exposed cartilage
  - Arytenoid
  - Thryoid
  - Cricoid
- Narrowed airway due to cricoid fracture



Fig. 8.4. Computed tomography scan shows diffuse subcutaneous emphysema. Asymmetry of the laryngeal framework suggests a fracture of the larynx.

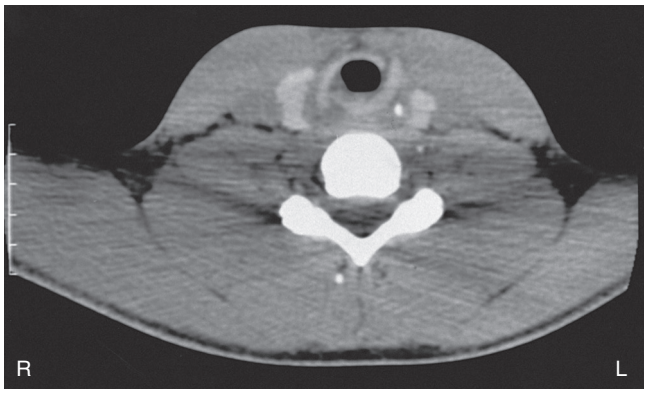

Fig. 8.5. This telescoping fracture of the cricoid cartilage was the result of strangulation.

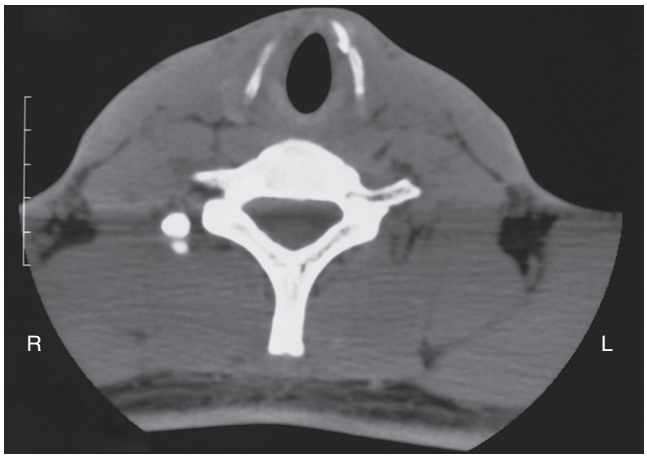

Fig. 8.6. Minimal displacement of the thyroid cartilage demonstrated on computed tomography scan.

- Displaced fractures or soft tissue disruption almost always requires surgical exploration and repair.
- Nondisplaced fractures should be treated only when obvious symptoms arise from the fracture.
- With soft tissue disruption, interval tracheotomy may need to be performed. Early exploration invariably results in easier reduction of cartilaginous injury and more accurate soft tissue repair.[9] Delay in the performance of the procedure leads to scarring, edema, local infection, and distortion of tissues that may result in a suboptimal outcome.
- When possible, laryngeal exploration within 24 to 48 hours is ideal if the patient's general condition permits.

Contraindications

- Unstable from a cardiovascular perspective
- Severe neurologic trauma
- Presence of vascular trauma

Preoperative Preparation

- Cervical spine clearance
  - Radiologic
    - Functional
- Cardiovascular clearance
- Neurosurgical clearance
- Trauma surgeon assessment is complete
- Coordination of surgical procedures and sequence of repairs between different surgical teams/specialties

OPERATIVE PERIOD

Anesthesia

- The first initiative in the management of patients who have trauma to the laryngotracheal complex is to establish a secure and safe airway.
- Under many circumstances, this is the most challenging and dangerous aspect of the entire procedure. The most experienced members of both the surgical and anesthetic teams must be present at this time. Delegation of this aspect of the case to the junior members of the team is a serious error in judgment.
- When preoperative assessment has indicated significant disruption of the laryngotracheal anatomy, an airway must be secured with a tracheostomy. When time permits, we prefer a tracheostomy between the second and third or third and fourth tracheal rings rather than cricothyrotomy. If a cricothyrotomy is performed, it should be changed to a tracheostomy if it will be needed for more than 7 days.
- The presence of a fracture of the cervical spine must be ruled out before any airway or endoscopic procedure in which the head is moved. If it cannot be ruled out, the safest choice is tracheostomy without extending the neck.

Positioning

- Supine
  - If patient is not in cervical spine precautions
    - Neck flexion
    - Head extension
- Head of the bed is elevated 15 degrees, which reduces intraoperative edema

Perioperative Antibiotic Prophylaxis

- No antibiotics are indicated if there is no mucosal disruption.
- If there is mucosal disruption, guidelines for clean-contaminated surgery should be followed.

Monitoring

- Routine anesthesia monitoring
- Muscle paralysis is required for direct laryngoscopy and helpful for the exploration of laryngeal fractures.

Instruments and Equipment to Have Available

- Direct laryngoscopy
- Microlaryngoscopy
  - Endoscopic suture equipment
  - Endoluminal stent (Montgomery laryngeal stent)
- Esophagoscopy (rigid)
- Bronchoscopy (rigid)
- Tracheostomy set
- Small miniplate system (midface, 1.0 to 2.0 mm)

Key Anatomic Landmarks

- Patent airway
  - Glottic
  - Subglottic
  - Tracheal
- Esophageal integrity
- Tracheal integrity
- Arytenoid position and motion to palpation
- Anterior commissure

Prerequistive Skills

- Direct laryngoscopy
- Microlaryngoscopy
- Laryngeal framework surgery
- Laryngofissure surgery
- Tracheostomy

Operative Risks

- Loss of airway during the induction of general anesthesia
- Separation of laryngotracheal complex with intubation
- Injury to recurrent laryngeal nerve(s)
- Incomplete reduction of laryngeal fractures
- Inadequate mucosal coverage

Surgical Techniques

- Following establishment of a secure airway, diagnostic endoscopy is almost always indicated. Again, the cervical spine must be "cleared" before endoscopic manipulation.
- The cervical esophagus and the larynx should be examined.
- Cartilage displacement without significant mucosal disruption may be successfully managed without formally entering the airway.
- Significant injury to the laryngeal skeleton with soft tissue disruption requires a direct approach that allows for soft tissue repair and reduction of the laryngeal fracture.
- The choice of incision must consider the need for exploration and repair of concurrent injuries, as well as the position of coexistent lacerations.
  - When a procedure is to be limited to the laryngotracheal complex, a transverse incision may be sufficient.
  - A superiorly based apron flap is appropriate. The inferior aspect of the apron will be the site of the tracheostomy.
  - The strap muscles are separated, allowing direct observation of the site of injury.
  - Fractures may be reduced by using small elevators and hooks, taking care to avoid further damage to the cartilaginous structures and underlying mucosa.
- When exploration of the mucosal surfaces is required, efforts should be made to place the cartilage incision directly through the midline at the level of the glottis, even if another paramedian fracture is present.
  - This is facilitated by incising the mucosa horizontally at the cricothyroid membrane, then cutting superiorly under direct visualization.
  - Entering the anterior commissure from either side is a serious technical error that will adversely affect the outcome of the repair. Mucosal repair then is undertaken using fine absorbable sutures. Attachment of the true vocal cord to the anterior commissure must be ensured (Fig. 8.7).
  - Use a fine nonabsorbable suture to fix the anterior-most portion of the vocal cord to the anterior commissure.
    - If available, the outer perichondrium thyroid cartilage can be used. Soft tissue avulsion injuries are unusual, so that repair is similar to assembling a puzzle.
  - Lacerations and flaps can be repaired and the anatomy restored. Rarely, denuding injuries are close to one another, especially with penetrating injuries; these may result in scar contracture and subsequent stenosis, so replacement of lost mucosa with mucosal grafts (typically buccal mucosa) or flaps and stenting may be required.
- Stents are typically soft and require stabilization with nonresorbable sutures passed through buttons. Wire tends to break and should be avoided.

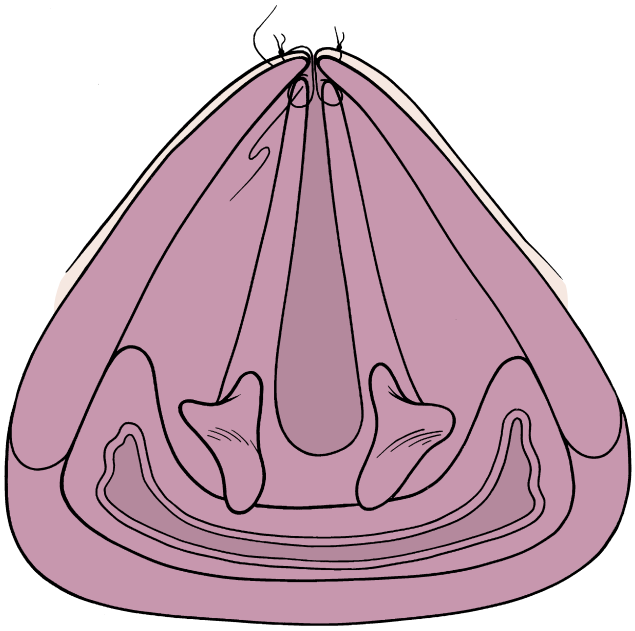

Fig. 8.7. When laryngofissure is used to expose the larynx, the surgeon must ensure that the anterior commissure is fixed at the completion of the case. This is best done by using fine nonresorbable suture.

- The use of stents in the lumen is controversial since the presence of a foreign body carries with it the potential for further trauma to the mucosal surfaces of the laryngotracheal complex.
- This potential disadvantage must be weighed against the need to support cartilaginous and soft tissue repairs. It is important to clearly distinguish the functional difference between a stent and a keel.
- A stent is designed to support 360 degrees of the airway, thereby providing support to the cartilaginous framework and mucosa. This is best thought of as "internal support" and is indicated when the injury and external framework repair will not provide adequate support, especially in an anteroposterior dimension.
- One should consider using female stents for males and child stents for females. Stents are removed within 2 to 4 weeks.
- In contrast, a keel is designed to keep the opposing surfaces of the two vocal folds from contracting, thereby allowing the surface to fully mucosalize to prevent web formation (Fig. 8.8).
- The presence of the keel inserted through a laryngofissure may lengthen the anteroposterior dimension of the larynx. The need for a keel to prevent webbing at the anterior commissure in patients with significant injury to the true vocal cord is far less controversial.
- Insertion of a keel allows migration of mucosa anteriorly and prevents the formation of an anterior commissure web.
- Repair of the cartilage must be meticulous and may be undertaken with nonresorbable suture, wire, or miniplating systems (Figs. 8.9 through 8.12).
- This is done with using small plates to repair injuries to the thyroid and cricoid cartilages.[10]
- Resorbable miniplates that are malleable in hot water are also available.
- The surgeon must be certain that the screws are properly sized such that they do not penetrate the mucosal surfaces. Younger patients may have nonossified cartilage, and great

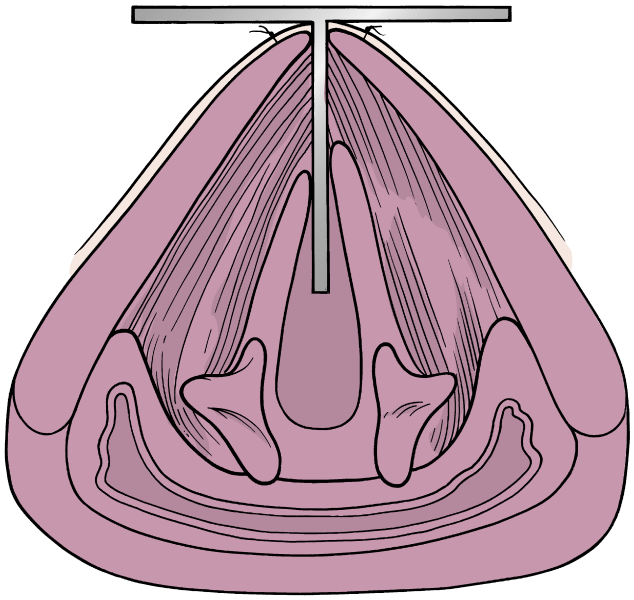

Fig. 8.8. The use of a keel is intended to allow the injured surface of the vocal cord to re-epithelialize to the anterior limit of the keel, thereby avoiding development of a side-to-side web.

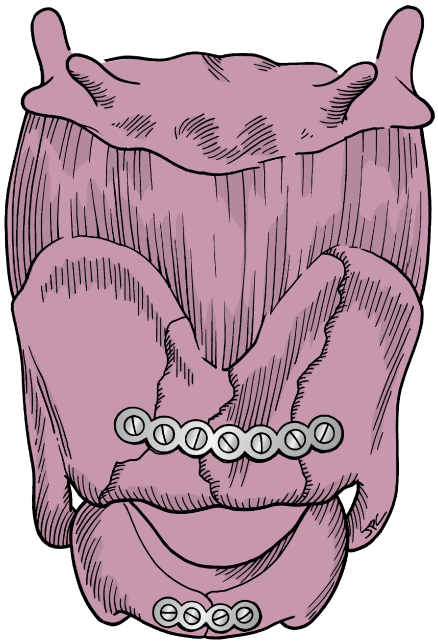

Fig. 8.9. This schematic demonstrates how miniplates can be used to repair fracture of the thyroid or cricoid cartilage.

care must be taken to avoid stripping the screw threads. Self-drilling, self-tapping screws are less likely to strip.

- Supporting the framework in an anatomic position often requires overcorrection of the thyroid cartilage because the natural vector of force tends to spread the alae, thereby shortening the anteroposterior dimension of the larynx. Rigid fixation of the laryngeal framework, in some cases, may prevent the need for stenting.
- Cricoid fractures can be elevated and either wired together or to a microplate.
- Soft tissues are returned to the anatomic position, and the wound is closed in layers.

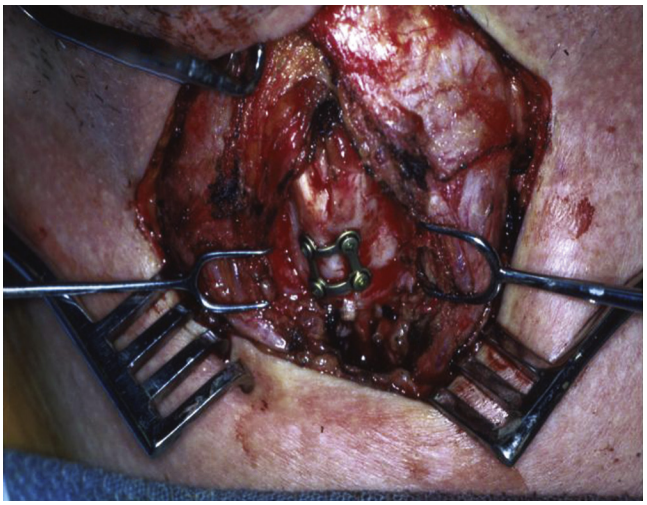

Fig. 8.10. Miniplates, with appropriate length screws, are ideally suited to repair and stabilize cartilage fractures.

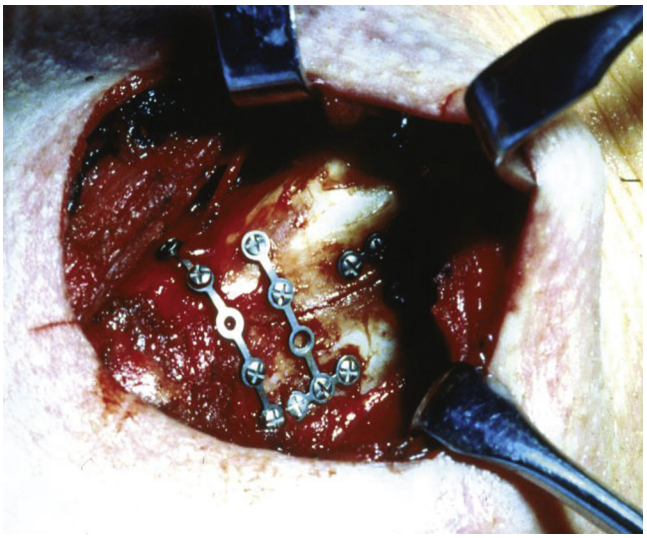

Fig. 8.11. Complex fractures may require more than one plate for fixation.

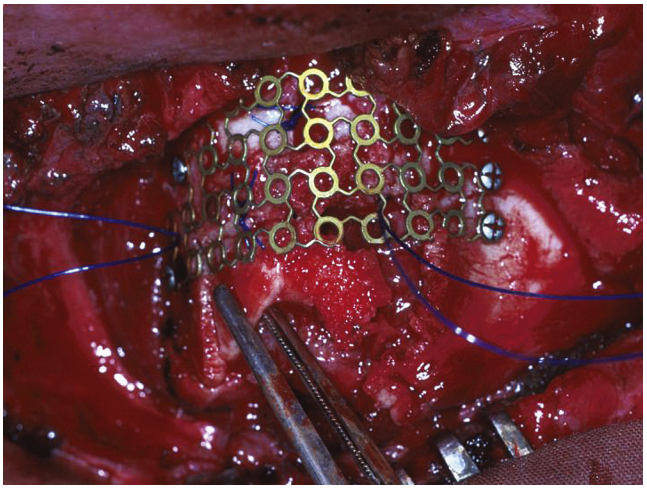

Fig. 8.12. Shattered laryngeal cartilage is supported by mesh framework. A Montgomery stent is fixed with translaryngeal-transcutaneous sutures.

- A passive drain (e.g., Penrose) should be used because a watertight mucosal closure is rarely possible. Accordingly, use of a suction drain is imprudent in that it will aspirate mucus into the wound.
- If the skin incision incorporates the tracheostomy, efforts must be made to seal the tracheotomy wound from the rest of the wound by approximating the subcutaneous tissues of the flap to the strap muscles. Use of a compressive dressing may be ill advised, especially in the face of cartilage injury. The administration of perioperative prophylactic antibiotics that are effective against oral flora is indicated.

Common Errors in Techniques

- Not providing complete mucosal coverage, which will result in granulation tissue formation and severe scarring
- Incomplete reduction of laryngeal fracture(s) resulting in foreshortened vocal fold and/or vocal fold level mismatch
- Not providing "internal" support for the severely injured laryngeal framework, which results in laryngeal stenosis that may not be able to ever be properly restored

POSTOPERATIVE PERIOD

Postoperative Management

- Patients undergoing surgery for laryngeal trauma should be observed postoperatively in an acute care setting.
- Routine use of oximetry is advisable.
- Nothing is given by mouth in the acute period.
  - In the face of injury to the hypopharynx or esophagus, the patient may be fed through a nasogastric tube until edema and pain have resolved enough to permit oral feeding.
  - Patients with injuries limited to the laryngotracheal complex can frequently be fed by the third or fourth postoperative day.
- Routine tracheostomy care includes the use of humidified air delivered to the tracheostomy with a tracheostomy mask.
  - A T-tube connector should be avoided because it may torque the tracheostomy, producing unnecessary damage.
  - The nursing service should begin regular tracheostomy care with suctioning and cleansing of the inner cannula.
- The neck plate of the tracheostomy tube should be sutured to the cervical skin. Ties around the neck are used as reinforcement.
- Recovery room and intensive care personnel must be advised of the nature of the injury. If intubation is not possible, these personnel, especially, must be briefed on the management of accidental tube displacement.
- Tube reinsertion can be facilitated by the placement of traction sutures through the tracheal ring above and below the tracheotomy site. These sutures are taped to the skin during the postoperative period.
  - The placement of a fresh tracheostomy tube is facilitated if the patient can be placed in a head-extended position.
  - Direct visualization of the tracheostomy site facilitates proper placement of the tube.
  - Blind insertion of the tube into the tracheostomy site may lead to placement in the peritracheal soft tissue anterior to the trachea, with subsequent efforts at ventilation associated with a high resistance and the development of subcutaneous emphysema or pneumothorax.
  - This disastrous circumstance can be prevented only by placing the tracheostomy cannula into the lumen of the trachea. Immediate access to proper lighting, suction, retraction instruments, and small-caliber replacement tubes may facilitate management under emergent situations.
- The tracheostomy tube can be removed when the airway is stable and the glottis is competent to prevent aspiration.
- Test for glottic competency by deflating the cuff of the tracheostomy tube.
  - Aspiration is an indication that the glottis is incompetent, and the continued use of a cuffed tracheostomy tube is necessary.
  - Continued cough may be a more subtle indication of aspiration.
- The adequacy of the airway can be ascertained through direct visualization with flexible endoscope.
  - The airway can be functionally assessed for integrity by changing the tracheostomy to a smaller uncuffed tracheotomy tube.
  - The tube is then plugged and the patient observed for respiratory distress.
  - Patients who tolerate the use of a plugged tracheostomy tube during a 24-hour day may be safely decannulated.
  - The tracheostomy site is allowed to heal by secondary intention.
- It may be advisable to prepare patients with significant laryngotracheal trauma for home tracheostomy care and to discharge them for subsequent follow-up and decannulation as an outpatient.

Complications

- Accidental decannulation may be life threatening in the case of acute repair of a laryngotracheal injury. This is especially true in patients in whom a stent has been inserted. Prevention is the first principle in the management of this complication.
- Failure to reduce a significant laryngeal fracture may result in permanent dysphonia.
- Failure to establish normal contour of the thyroid cartilage will result in poor voice and often requires rigid fixation.
- Failure to observe and document posttraumatic injuries may lead to patient dissatisfaction.
- An inadequately secured tracheostomy tube may lead to obstruction of the airway.
- Laryngeal stents and keels may obstruct the airway if poorly secured.
- Mucus or saliva coming from the drain is an indication of wound dehiscence and a fistula.
  - The drain should be maintained until soft tissues have had an opportunity to seal.
  - This usually takes 7 to 10 days, following which the drain can be advanced and the fistula tract will close.
  - Antibiotics may be administered to prevent the development of systemic sepsis.
  - Premature removal of the drain may result in a subcutaneous collection of fluid with subsequent elevation of the cervical skin flap.
  - Collections require opening of the wound and reinsertion of a drain.
- The most significant long-term complication of laryngotracheal repair is stenosis.
  - All healing tissue goes through a period of wound contracture.
  - Circular wounds are the most likely to lead to stenosis.
  - The medical literature is replete with a menu of secondary reconstructive techniques. Prevention of stenosis through gentle handling of tissue, accurate re-approximation of injured tissue, and judicious use of stents, keels, and other lumen-keepers seems to be the most reliable tactic.

- Long-term stenting may succeed in maintaining a lumen, but it will not prevent stenosis due to scar contracture. Eventual open exploration with adequate grafting may be necessary to create a permanent lumen.

Alternative Management Plan

- Tracheostomy alone may be an option for the critically ill trauma patient who may not survive over other injuries.

DISCUSSION

Evidence-Based Medicine Question

Females have a higher incidence of laryngeal trauma due to their longer and thinner necks compared with men. Yes or No?

Answer: No.

The ratio is approximately 3:1 (male to female) most likely because men participate in more "at-risk" sports and activities.

Editorial Comment

This chapter presents a concise yet comprehensive review of the evaluation and management of laryngeal fractures. As discussed in this chapter, laryngeal fractures are rare events, albeit with potentially lethal complications, due to the loss of airway, and long-term sequelae that affect all functions of the larynx. With the advent of laws mandating the use of safety belts, motor vehicle accidents have been replaced as the most common cause of a laryngeal fracture by violent altercations and sports.

Management of a patient suspected of having a laryngeal injury is geared to correct or prevent acute and future problems. First and foremost, the evaluation of such a patient pivots on establishing or minimizing the risk of losing the airway, and the initial assessment is composed of four main components: clinical assessment, fiberoptic laryngoscopy, noncontrasted CT scan of the laryngotracheal complex, and imaging to rule out concomitant cervical spine, esophageal, or vascular injuries.

Ascertaining the mechanism of injury is important because it will provide the examiner an idea of the potential magnitude and extent of the injury. By the way of illustration, a patient with a history of a clothesline injury may suffer a partial or complete laryngotracheal separation and recurrent laryngeal nerve avulsion. However, its range of injury and presentation varies widely, with most of these patients dying before adequate assistance can be provided, some surviving after establishing an emergency airway, and less commonly the patient may appear stable but suddenly lose the airway upon extension of the neck. Another example is a patient who has been the victim of a chokehold and who may look unaffected clinically, endoscopically, and by CT scan but may develop significant edema within hours of the event.

Surgical management of patients with laryngeal fractures strives to:

- reestablish the airway via tracheotomy (much preferred over a cricothyroidotomy but the latter perfectly acceptable in an emergency),
- reconstruct the cartilaginous external support (elegantly and most efficiently accomplished with titanium adaptation plates or mesh, although wiring or suture may be used when the former are not available),
- bolster extensive internal reconstruction (using soft stents to support extensive soft tissue repair or grafts),
- repair any other associated injury involving hypopharynx, esophagus, or vessels.

One should note that, although not universally accepted, surgical indications have evolved significantly. Conservative treatment is no longer advocated for patients presenting a complete fracture of the thyroid cartilage (displaced or not) or patients with more than one fracture line through the cricoid. A significant number of these will respectively develop chronic dysphonia or airway compromise as the fracture segments displace with the movement of the laryngeal and neck muscles.

Ricardo L. Carrau

Access the review questions and additional sources list online at http://www.expertconsult.com

REFERENCES

1. Line WS Jr, Stanley RB, Choi JH. Strangulation: a full spectrum of blunt neck trauma. Ann Otol Rhinol Laryngol 1989;4:542–546.
2. Schaefer SD. Acute management of external laryngeal trauma: a 27 year experience. Arch Otolaryngol Head Neck Surg 1992;118: 598–604.
3. Kleinsasser NH, Priemer FG, Schulze W, et al. External trauma to the larynx: classification, diagnosis, therapy. Eur Arch Otorhinolaryngol 2000;257:439–444.
4. Borowski DW, Mehrotra P, Tennant D, et al. Unusual presentation of blunt laryngeal injury with cricotracheal disruption by attempted hanging: a case report. Am J Otolaryngol 2004;25:195–198.
5. Gowens PA, Davenport RJ, Kerr J, et al. Survival from accidental strangulation from a scarf resulting in laryngeal rupture and carotid artery stenosis: the "Isadora Duncan syndrome." A case report and review of literature. Emerg Med J 2003;20:391–393.
6. Goudy SL, Miller FB, Bumpous JM. Neck crepitance: evaluation and management of suspected upper aerodigestive tract injury. Laryngoscope 2002;112:791–795.
7. Green DC, Ward PH. The management of the divided recurrent laryngeal nerve. Laryngoscope 1990;100:779–782.
8. Stassen NA, Hoth JJ, Scott MJ, et al. Laryngotracheal injuries: does injury mechanism matter? Am Surg 2004;70:522–525.
9. Mendelsohn AH, Sidell DR, Berke GS, et al. Optimal timing of surgical intervention following adult laryngeal trauma. Laryngoscope 2011;12:2122–2127.
10. De Mello-Filho FV, Carrau RL. The management of laryngeal fractures using internal fixation. Laryngoscope 2000;110: 2143–2146.

REVIEW QUESTIONS

1. Laryngeal trauma in the pediatric population occurs less often than in adults because
   a. In children, there is greater protection of the larynx from the mandible.
   b. In children, the larynotracheal complex has less calcification and thus is less likely to fracture in response to bulk force.
   c. Different seat belt placement for children
   d. Children do not sit in the front seats of cars.
   e. Both a & b

2. All of these statements are key aspects of head and neck trauma evaluation, except
   a. Prioritizing the ABCs of trauma care
   b. Asking the patient to produce a high-pitch voice to evaluate for superior laryngeal nerve injury
   c. Careful evaluation of the cervical spine
   d. Endoscopic airway evaluation of the nonintubated laryngeal trauma patient prior to sending the patient for radiologic evaluation

3. All of these statements apply to open repair of median and paramedian laryngeal fractures, except
   a. A minimal dissection of soft tissue away from the fracture line
   b. Careful multidimensional re-approximation of major laryngeal fractures
   c. Exploration of both recurrent laryngeal nerves
   d. Use an internal stent when the fractures are so severe that there is major loss of the anteroposterior dimension of the larynx

ADDITIONAL SOURCES

Bhanot S, Alex JC, Lowlicht RA, et al. The efficacy of resorbable plates in head and neck reconstruction. Laryngoscope 2002;112:890–898.

Jewett BS, Shockley WW, Rutledge R. External laryngeal trauma analysis of 392 patients. Arch Otolaryngol Head Neck Surg 1999;125:877–880.

Rosen CA, Simpson B. Operative Techniques in Laryngology. Springer Science & Business Media 2008. Chapter 44. Laryngeal Fracture, p. 279–282.

Sasaki CT, Marotta JC, Lowlicht RA, et al. Efficacy of resorbable plates for reduction and stabilization of laryngeal fractures. Ann Otol Rhinol Laryngol 2003;112(9 Pt 1):745–750.

9 Bilateral Vocal Fold Immobility

Libby J. Smith, Clark A. Rosen

INTRODUCTION

Bilateral vocal fold immobility (BVFI) is an uncommon condition with potentially significant negative effects on breathing and quality of life. Patients usually have symptoms of airway obstruction, such as biphasic stridor and dyspnea, with a normal or nearly normal voice. This is in contrast to patients with unilateral vocal fold immobility, who usually complain of a breathy voice and aspiration. Etiologies of BVFI include immobility from both neurogenic causes (vocal fold paralysis) and mechanical fixation of the cricoarytenoid (CA) joints.

Neurogenic causes of bilateral vocal fold paralysis (BVFP) may be due to (1) iatrogenic injury to the recurrent laryngeal nerve (e.g., thyroidectomy, anterior cervical disc surgery, carotid endarterectomy, esophageal surgery, cardiac surgery, mediastinal surgery), (2) progressive neurologic disorders (e.g., amyotrophic lateral sclerosis, Shy-Drager syndrome, syringomyelia, Guillain-Barré syndrome), or (3) idiopathic causes.

Mechanical fixation of the CA joints causing BVFI may be due to (1) fixation of the CA joint secondary to radiation therapy, rheumatoid arthritis and other connective tissue disorders, benign infiltrative disorders such as amyloidosis, granulomatous diseases; (2) trauma; or (3) posterior glottic stenosis (PGS).

PGS is a common cause of BVFI. It is typically associated with intubation, although extraesophageal reflux disease may be a cofactor. The development of PGS is characterized by progressive airway obstruction, usually 4 to 8 weeks after extubation. Granulation tissue can cover the arytenoid cartilages and interarytenoid cleft. If this is observed, prompt débridement, steroid injection, and antacid treatment may be associated with less scar tissue formation and consequently less airway stenosis. Laryngeal balloon dilation may also have a therapeutic role in the acute or subacute setting.

Bogdasarian and Olsen developed a classification system for PGS that is useful to characterize the nature and severity of the posterior laryngeal stenosis.[1] The least severe group of patients has an interarytenoid synechiae and posterior sinus tract. The next group includes those with a posterior glottic web that limits movement of the arytenoids, without fixation of the CA joints and no posterior sinus tract. The third group appears similar to the second; however, one CA joint is fixed. The most severe group and the most difficult to treat consists of patients with fixation of both CA joints (Fig. 9.1).

Correctly identifying the cause of BVFI (neurogenic or mechanical) is critical in guiding treatment and shaping the expectations of both the patient and surgeon. The aim of treatment is to improve the airway while minimizing adverse effects on the voice.

KEY OPERATIVE LEARNING POINTS

- Patients with BVFI secondary to mechanical fixation of the CA joints typically have more severe airway restriction and require more aggressive surgical enlargement of the glottis than patients with BVFP.
- Laryngeal electromyography (LEMG) is crucial in determining the presence of neurologic injury and may guide the surgeon in determining the operative side.
- Palpation of the arytenoid, either in the office or in the operating room, to confirm passive motion or immobility is critical information that helps guide treatment.
- Endoscopic techniques have replaced larger, more destructive surgery and have resulted in decreased morbidity.
- Granulation tissue formation is minimized by the use of perioperative antacid medications and the application of mitomycin-C to any mucosal defects.
- Only patients with realistic expectations of the balance between voice and airway improvement should undergo surgery to enlarge the glottic airway.
- Overly aggressive primary surgery will probably leave the patient with more severe breathy dysphonia and dysphagia than was necessary for airway improvement or decannulation.
- Posterior glottic airway surgery may worsen glottic protection during swallowing, thereby increasing the risk of aspiration.
- BVFP must be differentiated from PGS because the initial surgical options may be different.
- Exposure of arytenoid cartilage during transverse cordotomy may lead to the formation of granulation tissue and the need for further treatment.

PREOPERATIVE PERIOD

History

1. History of present illness
   a. What are the patient's symptoms (e.g., dyspnea, dysphonia, dysphagia)?
   b. When did their symptoms begin?
      1) Suddenly: After surgery where the recurrent laryngeal nerve is at risk? Remember that the endotracheal tube (ETT) cuff can also result in vocal fold paralysis, although bilateral paralysis is very rare from ETT cuff pressure itself.
      2) Progressive: Progressively worsening dyspnea 4 to 8 weeks after extubation suggests PGS as the more likely etiology for vocal fold immobility.
2. Past medical and surgical history
   a. Previous surgery where the recurrent laryngeal nerve is at risk. Was hoarseness present after surgery?
   b. Prolonged intubation? One to two days is sufficient to develop PGS in diabetic patients.
   c. Neurologic diseases such as stroke or progressive neurologic diseases?
   d. Previous external beam radiation to the head and neck region?
   e. Rheumatologic diseases? Rheumatoid arthritis can result in CA joint fixation.

Physical Examination

1. Flexible laryngoscopy is the most important part of the examination. It allows for evaluation of vocal fold motion during vocal fold adductory (saying /i/) and abductory (sniffing) tasks.

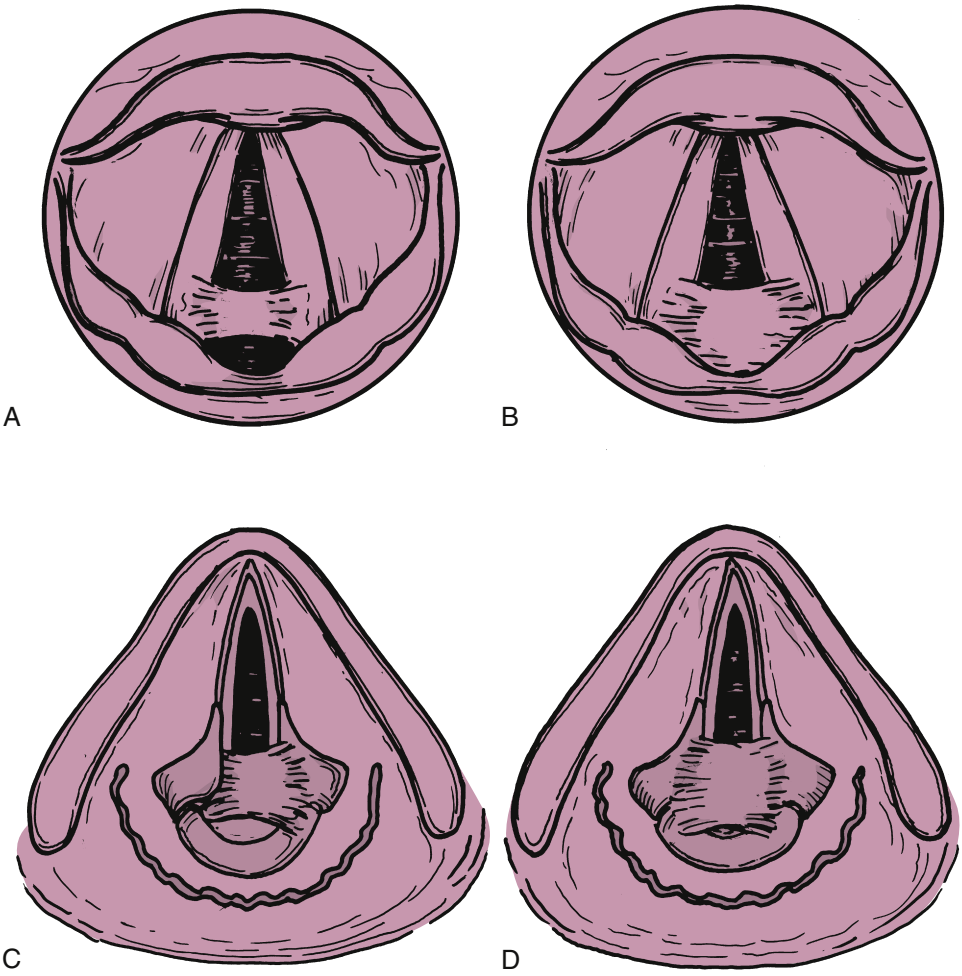

Fig. 9.1. Grading of posterior glottic stenosis. A, Interarytenoid synechia with a posterior sinus tract. **B,** Posterior glottic web with mobile arytenoid cartilage. **C,** Posterior glottic web with fixation of one arytenoid cartilage. **D,** Posterior glottic web with fixation of both arytenoid cartilages. *(Modified from Cotton RT, Manoukian JJ: Glottic and subglottic stenosis. In Cummings CW [ed]: Otolaryngology–Head & Neck Surgery. St Louis: CV Mosby; 1986, pp 2168).*

2. Manual palpation of the CA joints, either in the office or in the operating room, can further help detect the cause of BVFI and assist in guiding surgical planning. When both joints are impaired, palpation can determine the CA joint with the least range of motion. This is the optimal side for static, glottic enlargement surgery.

Imaging

1. Imaging studies can be important in evaluating a patient without obvious causes of vocal fold immobility.
2. Enhanced computed tomography (CT) or magnetic resonance imaging (MRI) of the skull base, neck, and upper part of the chest can help identify the site of a lesion in the brainstem, vagus nerve, or recurrent laryngeal nerves, which results in BVFI.
3. Enhanced CT with fine cuts through the larynx may be used to evaluate the CA joint for abnormalities or, in the case of PGS, the extent of stenosis, which may change the type of surgical intervention. Arytenoid subluxation or dislocation may also be identified.
4. MRI of the brain is needed when brain or brainstem causes are suspected, such as stroke or Arnold-Chiari malformation.

Laryngeal Electromyography

1. LEMG of both the thyroarytenoid–lateral cricoarytenoid (TA–LCA) muscle complexes is useful to determine the cause of BVFI.
2. If BVFP is present, there will be evidence of significant neurologic injury, with or without partial recovery. If the neurologic pattern shows a new injury with a chance of recovery, delaying destructive surgery is prudent.
3. The authors advocate that in an attempt to preserve the voice, surgery should involve the vocal fold with the worse neurologic status. This may improve voice outcomes by not altering the vocal fold that has a better neurologic status and thus possibly better muscle tone.
4. Patients with BVFI and PGS, in contrast to those with BVFP, will have normal electromyographic activity of the TA–LCA muscle complexes.
5. LEMG may also suggest a "mixed" etiology of the BVFI—one side neurogenic and the other mechanical.

Swallowing Studies

1. Swallowing studies are crucial in patients who complain of dysphagia. Because the incidence of aspiration is high after

many types of surgery to improve the airway, more conservative surgery or tracheostomy may be most appropriate for patients with dysphagia or compromised swallowing ability.

Indications

1. Patients with symptomatic airway obstruction due to BVFI
2. Patients desiring decannulation after tracheostomy to bypass airway obstruction due to BVFI

Contraindications

1. Contraindications to directly treating the laryngeal obstruction of BVFI, other than performing a tracheostomy, are the presence of aspiration or a rapidly progressive neurologic disorder.
2. Relative contraindications include compromised pulmonary status, uncontrolled diabetes, and previous radiation therapy.
3. Unrealistic expectations on the part of the patient are a relative contraindication to treating all types of BVFI.

Preoperative Preparation

1. Patients must understand and accept that to improve their glottal airway, the quality of their voice may be adversely affected. Therefore patients should expect to have worse vocal quality at the expense of an improved airway. Such counseling needs to be frank and well documented. A patient who is unwilling to accept any decrease in vocal function should be considered for tracheostomy and not glottic enlargement surgery.
2. The patient should understand that multiple procedures may be necessary to optimize the airway with the least potential impact on the voice. This allows the surgeon to enlarge the glottic airway in a staged, conservative fashion, which hopefully will minimize the negative impact on both voice and swallowing.

OPERATIVE PERIOD

Anesthesia

1. General anesthesia: The patient's airway is secured by one of the following, depending on the patient's airway restriction, comorbid conditions, the surgery to be performed, and surgeon preference or comfort level.
   a. Laser-safe ETT, if appropriate. A small ETT (i.e., 5.0 or 5.5 microlaryngeal tube) is needed if the ETT is to remain during surgical intervention.
   b. Jet ventilation is also a common modality used for glottal airway surgery. Subglottic jet ventilation with a Hunsaker catheter is effective. Supraglottic jet ventilation through the laryngoscope is possible but is hampered by subsequent laryngeal desiccation and motion from the air puffs. Jet ventilation should only be used by anesthesiologists who are familiar and comfortable with this technique, as there are risks of hypercapnia and pneumothorax.
   c. Intubation with intermittent extubation and subsequent apnea is less commonly used but is a good option for patients being treated with shorter duration procedures, such as dilation.
   d. Tracheostomy provides the most stable airway and leaves the glottis devoid of accessory instrumentation. However, if the patient is without a tracheostomy, the goal is often to avoid it. Possible placement of a tracheostomy at the time of glottic airway surgery needs to be openly discussed with the patient and listed on the surgical consent form.

Positioning

1. Supine: The patient is placed supine, with neck flexion and head extension. A shoulder roll does *not* help achieve this. Rather, the patient's head is placed on a "donut" pillow, and the head of the bed is flexed as needed.
2. If the patient is obese, then a "ramped" position may be needed. Blankets are placed below the patient's head and upper back such that the tragus is in-line horizontally with the manubrium. This helps achieve the proper "sniffing" position required for optimal laryngeal exposure in patients with a larger body habitus.
3. Proper surgeon ergonomic positioning is also important to reduce surgeon musculoskeletal injuries. After laryngeal exposure is achieved, the proper surgeon ergonomic position is achieved by moving the bed angle (usually Trendelenburg, "head down") so the laryngoscope is ~40 degrees off the horizontal plane. The surgeon's neck should be in a neutral position or slightly flexed but never extended. Sometimes lowering the height of the bed is needed to allow for more comfortable placement of the surgeon's arms and hands. Arm rest support while operating is also important.

Perioperative Antibiotic Prophylaxis

1. Perioperative antibiotics are not necessary unless the patient's medical history requires them—for instance, mechanical heart valves or stents.

Instruments and Equipment to Have Available

1. Various sizes of laryngoscopes: The largest laryngoscope that fits the patient's anatomy is best to provide optimal exposure.
2. Standard microlaryngeal surgical tray
3. Rigid telescopes (0-, 30-, and 70-degree; 30 cm length, 5 to 10 mm diameter): These are used to better visualize the extent of lateral extension of the surgical field.
4. Laser: CO_2 laser is the most common type of laser used for glottic airway surgery.
5. Airway dilators: Balloon and Jackson dilators

Key Anatomic Landmarks

1. True vocal folds and arytenoids: Depending upon the position of the arytenoids and true vocal folds, the glottis, which is defined as the space between the vocal folds, may be too small for the patient to breathe without restriction. Scarring between the arytenoids can range from mild to severe, with complete obliteration with scar of the respiratory glottis up to the vocal processes.
2. Cricoid cartilage: The cricoid cartilage is a complete cartilaginous ring located below the true vocal folds. There is no benefit to performing surgery outside the confines of the inner table of the cricoid cartilage.

Prerequisite Skills

1. Microsuspension laryngoscopy
2. Laser certification
3. Balloon dilation
4. Tracheotomy (see Chapter 19).

Operative Risks

1. Airway compromise: Inability to properly secure the airway prior to the start of surgery requires the placement of an emergent surgical airway.

2. Bleeding: Although bleeding is not usually a major concern, there is often increased bleeding experienced during the transverse cordotomy procedure. Defocused laser energy or suction cautery is usually sufficient for hemostasis.
3. Laser airway fire: It is critical that laser safety precautions be followed at all times when using the laser—optimally FiO_2 less than 40%, saline readily available if case of fire (preferably in a bulb syringe within reach of the surgeon), wet towels over the patient's head (avoiding air pockets under the towels), proper eye protection for the staff, laser-resistant ETT (or wrapped in tin foil) if applicable, and placement of a saline-soaked pledget over the ETT or tracheotomy tube cuff (if applicable). A laser operator is also to be in the room at all times while the laser is in use. All operating room staff must be trained on what to do in case of airway fire—turn off oxygen while removing the endotracheal, Hunsaker, or tracheotomy tube; place saline in the airway; use bronchoscopy to evaluate for injury; and reintubate. These types of laser surgeries should only be performed by surgeons who are comfortable performing airway laser surgery.

Surgical Technique

Surgical treatment of BVFI involves static enlargement of the glottic airway, given that no method exists presently to restore dynamic, purposeful motion of the vocal fold(s). A stepwise approach to create an adequate airway is prudent. The surgeon must integrate the patient's comorbid problems into the surgical decision-making process. In general, patients with rapidly progressive neurologic disorders or other serious comorbid conditions tend to be best treated with a tracheostomy. Most other causes of BVFI can be treated with conservative endoscopic techniques. Transverse cordotomy, medial arytenoidectomy, or a combination of these procedures are ideal conservative options because the airway is enlarged with fewer detrimental effects on vocal quality and possibly swallowing ability than occur with more extensive total arytenoidectomy procedures (endoscopic or open). Total arytenoidectomy creates a larger posterior airway but is more likely to lead to aspiration and a substantive decrease in vocal quality. Endoscopic suture lateralization is useful as a temporary measure when there is no loss of mucosa in the posterior glottis. This procedure can be done with glottal enlargement procedures or a permanent treatment. Treatment of PGS, specifically, may be achieved by endoscopic or open techniques and consists of lysis of the interarytenoid synechiae, creation of a microtrapdoor flap, balloon dilation with steroid injections, or the techniques mentioned earlier. If the patient already has a tracheostomy before arytenoid surgery, it should remain in place until a proper capping trial for decannulation can be conducted, approximately 2 months after surgery.

Surgical outcomes vary upon the extent of surgery, location of surgery (i.e., arytenoid involvement), and patient factors. Patients with reduced wound healing, such as with diabetes, may have a compromised surgical outcome. The addition of acid suppression, mitomycin-C, and steroids is to improve the outcome, though direct studies of their effects are unclear.

Prognosis of glottic airway enlargement surgery varies, depending upon the type and severity of the clinical situation. A patient with an interarytenoid adhesion usually has an excellent result from lysis of the fibrotic adhesion, usually with no further intervention needed as long as there is no concurrent CA joint fixation. Treatment of patients with BVFP can differ from those with BVFI, because the addition of arytenoid procedures and temporary suture lateralization procedures are viable options, whereas patients with severe PGS have more restricted options of glottal airway surgery (transverse cordotomy, microtrapdoor flap). Healing after these surgeries is effected by the surgery performed and the patient's general health status. If the patient is willing to have reduction in voice quality, and he or she does not have dysphagia complaints, the prognosis of tracheostomy tube decannulation is excellent after this type of surgery. However, sometimes the patient and surgeon decide that further glottal airway opening at the detriment of voice and swallowing quality is not acceptable. In those cases, the patients must be willing to accept long-term tracheostomy for airway management.

1. Palpation of the CA joint
   a. Place a sturdy instrument adjacent to the vocal process and push laterally. Both CA joints are evaluated to compare the degree of effort required to displace the vocal process and the speed of medial tissue recoil. If one CA joint displays better movement, surgery is initially performed on the contralateral (worse) side. If the interarytenoid region moves during this maneuver, then PGS is present.
      1) If the patient is awake and being evaluated with flexible laryngoscopy with the addition of topical anesthesia, an instrument such as an Abrams cannula can be used.
      2) If the patient is being evaluated under general anesthesia, a blunt laryngeal elevator or large cup forceps can be used to palpate the joint. During CA joint palpation under general anesthesia, the laryngoscope must be placed above the arytenoid to avoid artificial reduction in CA joint movement.
2. Tracheostomy
   a. This is a reasonable option for patients with BVFI, especially those with dysphagia or rapidly progressive neurologic disease, as well as for patients who do not want decreased vocal function (see Chapter 19).
3. Lysis of interarytenoid synechiae
   a. When a bridge of scar tissue exists between the vocal processes with the presence of a posterior sinus tract, the bridge of scar tissue can be excised.
   b. Suspension laryngoscopy with exposure of the posterior glottis is carried out after the airway is secured.
   c. The mucosal integrity of the posterior glottis is assessed with the aid of 0, 30, and 70-degree angled telescopes.
   d. The interarytenoid bridge of mucosa is excised using laser or cold knife technique.
   e. Mitomycin-C can be applied to the defect in the mucosa to reduce the risk of reformation of synechiae.
   f. Release of the bridge should restore at least some passive mobility of the arytenoid.
   g. If patients do not achieve long-term improvement with this procedure, injury to the CA joint (fixation) is likely. A more aggressive static glottic enlargement procedure is then necessary.
   h. Balloon dilation of the posterior larynx may further assist after the lysis of the synechiae.
4. Transverse cordotomy
   a. Described by Dennis and Kashima[2] in 1989 as a more conservative surgery than total arytenoidectomy
   b. The patient is intubated with a 5.0 or 5.5 laser-safe ETT if a pre-existing tracheostomy is not present.
   c. Usually, the ETT can be placed in the posterior glottis to allow exposure of the vocal process on the side to be operated. Alternatively, the ETT can be placed anterior to the laryngoscope, or jet ventilation can be used.
   d. The laryngoscope is suspended and angled toward the operative side.
   e. CO_2 laser precautions are implemented.

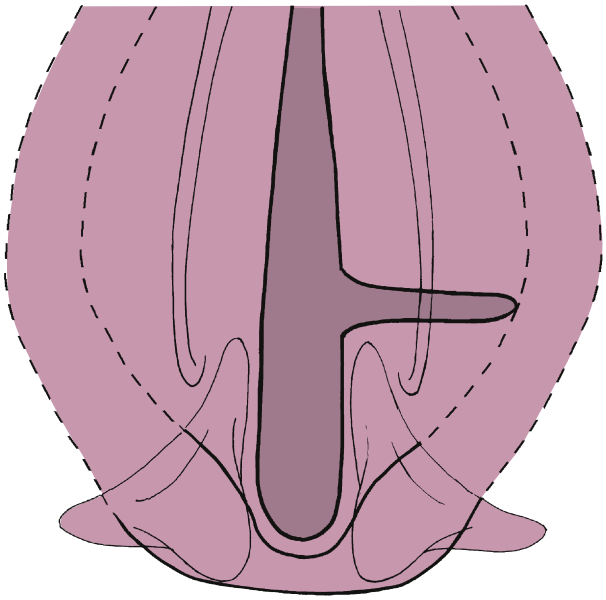

Fig. 9.2. CO_2 laser incision extending laterally to the cricoid ring for transverse cordotomy.

f. Typical CO_2 laser settings depend upon the type of CO_2 laser, but in general, the least amount of energy needed to complete the cordotomy is recommended. For example, CO_2 laser setting could be 4 W, superpulse, with a small (0.25 to 0.4 μm) spot size to minimize collateral thermal damage.
g. After confirming the location of the vocal process, an incision is made just anterior to it. Care is taken to not expose the arytenoid cartilage in order to avoid the formation of a granuloma. The cordotomy extends across the entire width of the true vocal fold, extending to the inner table of the lateral cricoid cartilage. This completely separates the vocal fold from the vocal process/arytenoid and allows scarring to retract the muscular portion of the vocal fold anteriorly and laterally, thus leaving a triangular-shaped glottal airway.
h. Endoscopic evaluation with a 30-degree telescope should confirm that the cordotomy is flush with the lateral wall of the cricoid cartilage.
i. The incision may also include the medial 3 to 4 mm of the false vocal fold (Fig. 9.2), if needed for proper visualization.
j. Hemostasis is achieved with the laser, suction cautery, bipolar cautery, and/or epinephrine-soaked (1:10,000 concentration) pledgets. There is often increased bleeding near the lateral extent of the cordotomy, but cordotomy beyond this area is needed to optimize the postsurgical glottic opening once it has healed.
k. The application of topical mitomycin-C (0.4 mg/mL) to the wound for 5 minutes or for 2 minutes repeated once is an optional adjunctive treatment in an attempt to decrease fibroblast formation and thus scar tissue at the operative site.
l. Laryngotracheal anesthesia with 4% topical lidocaine is used to minimize postoperative laryngospasm.

5. Medial arytenoidectomy
   a. Crumley (1993) described a more conservative version of total arytenoidectomy.[3]
   b. The patient is intubated with a laser-safe 5 or 5.5 ETT.
   c. CO_2 laser precautions are implemented.

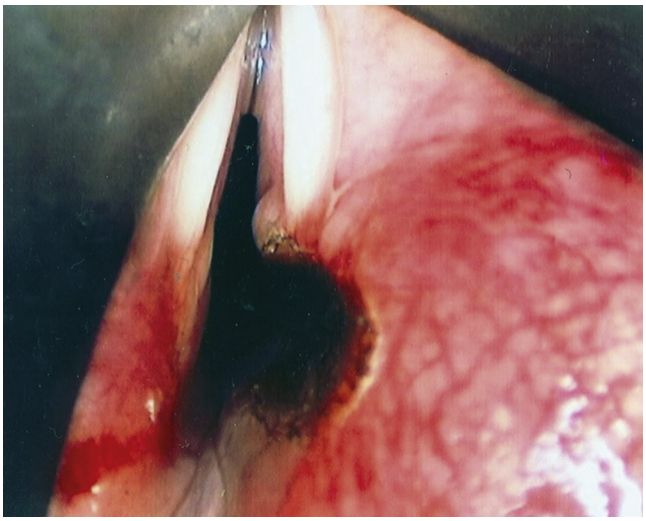

Fig. 9.3. Defect after medial laser arytenoidectomy.

   d. CO_2 laser ablation of the most medial 2 to 3 mm of the body of the arytenoid cartilage results in enlargement of the posterior glottic airway. The ablation begins posterior to the vocal process and at least 2 mm anterior from the posterior commissure (Fig. 9.3). If the posterior mucosa is disturbed, then PGS can occur. The amount of arytenoid cartilage obliterated is guided by the degree of airway compromise and tissue reaction.
   e. This surgery is not possible to complete in patients with severe PGS, since the medial aspect of the arytenoids is obscured with scarring.
   f. Hemostasis is achieved with the laser and/or epinephrine-soaked (1:10,000 concentration) pledgets.
   g. Application of mitomycin-C is optional.
   h. Laryngotracheal anesthesia with 4% topical lidocaine is used to minimize postoperative laryngospasm.
6. Transverse cordotomy with medial arytenoidectomy
   a. After failure of either transverse cordotomy or medial arytenoidectomy, the surgeon may choose to proceed with revision glottal surgery incorporating both of these procedures. This produces a larger glottal defect, though not as aggressively as an endoscopic total arytenoidectomy (discussed later).
   b. Since this surgery results in a greater glottal airway, increased dysphonia and swallowing difficulties are expected, and the patient should be counseled appropriately.
7. Total arytenoidectomy
   a. The classic total arytenoidectomy procedure was described by Ossoff et al. in 1983.[4] This surgery is usually reserved for patients with BVFI who have failed with more conservative surgeries (transverse cordotomy, medial arytenoidectomy). A more adverse effect on voice quality and swallowing is expected.
   b. The same initial steps are taken as with the medial arytenoidectomy procedure. CO_2 laser ablation of the entire body of the arytenoid is achieved by removing cartilage until the defect is flush with the wall of the cricoid ring (posteriorly and laterally; Fig. 9.4). This can be verified with a 70-degree telescope. There is no reason from an airway standpoint to remove more of the arytenoid than what is within the cricoid ring, as that would not improve the glottal airway.
   c. Modified versions of this surgery have been developed, with creation of arytenoid tissue defect after elevation of a lateral mucosal flap. The flap is sutured laterally

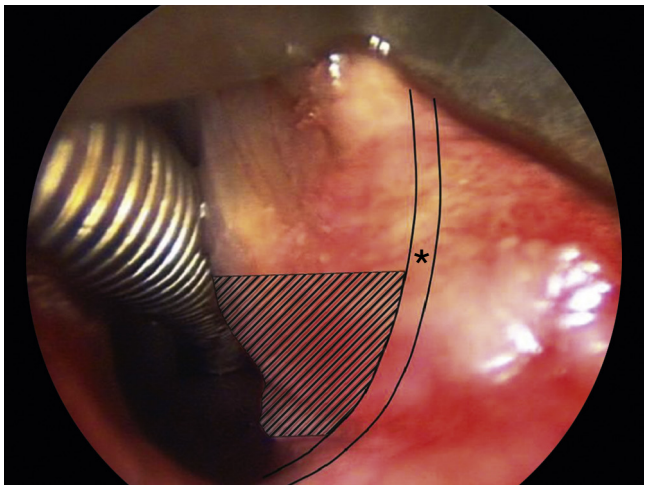

Fig. 9.4. Total arytenoidectomy results in the removal of arytenoid cartilage *(shaded region)* within the cricoid ring *(asterisk)*.

after laser tissue ablation, resulting in a mucosal lined triangular defect in the posterior glottis.

d. The laser and epinephrine-soaked pledgets (1:10,000 concentration) are used to achieve hemostasis.
e. Application of mitomycin-C is optional.
f. Laryngotracheal anesthesia with 4% lidocaine is used to minimize postoperative laryngospasm.

8. Open arytenoidectomy
   a. Reserved for patients in whom endoscopic procedures have failed or when adequate laryngeal exposure is impossible due to anatomic limitations
   b. A laryngofissure (see Chapter 69) or a lateral approach with resection of the posterior rim of thyroid cartilage and elevation of the piriform sinus mucosa may be used to expose and remove the arytenoid cartilage. However, with the advances in endoscopic techniques, these approaches are rarely necessary.
9. Posterior scar—microtrapdoor flap
   a. Dedo and Sooy[5] first described an endoscopic flap technique to treat PGS.
   b. A CO_2 laser or knife is used to make an incision over the less mobile arytenoid, from the vocal process into the interarytenoid cleft and extending up to the contralateral CA joint and for 4 to 5 mm below the vocal folds in the interarytenoid cleft.
   c. A mucosal and submucosal flap are elevated from the underlying scar. The scar tissue is excised or vaporized until mobility is restored or the limits of dissection are met.
   d. The flap is repositioned, and sutures or fibrin glue may be required to secure the flap in proper position.
   e. If joint mobility is not regained, additional glottic enlargement procedures may be necessary, as described earlier.
   f. Placement of an endolaryngeal stent may be necessary in patients who require revision surgery.
   g. Epinephrine-soaked pledgets (1:10,000 concentration) provide hemostasis.
   h. Mitomycin-C may be applied to the exposed CA joint.
   i. This procedure is not often used.
10. Temporary/reversible procedures
    a. Endoscopic suture lateralization
       1) This procedure is based on the technique of Lichtenberger and Toohill.[6]
       2) Temporizing measure in patients with early symptomatic BVFP who have an uncertain prognosis for vocal fold motion recovery

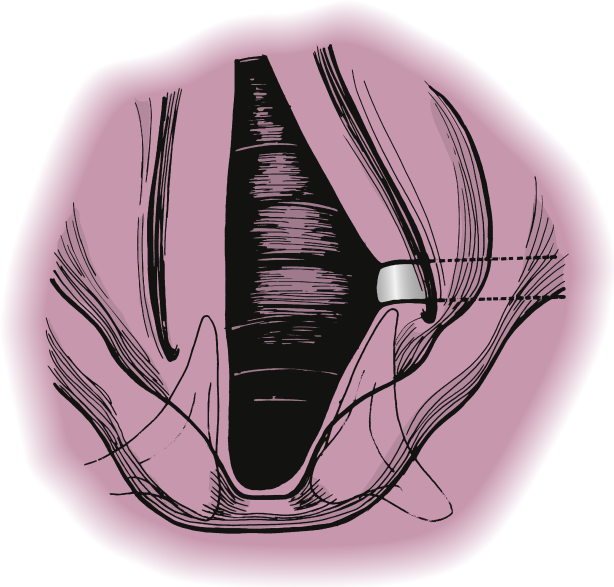

Fig. 9.5. Sutures are placed around the vocal fold and sutured over a button on the skin, thereby lateralizing the vocal fold.

       3) Contraindications to endoscopic suture lateralization are recent trauma to the posterior glottis from an ETT or if the patient is currently intubated.
       4) Under microscopic or telescopic visualization, an endo-extralaryngeal needle carrier device is loaded with 2-0 Prolene suture. The needle is driven through the skin and larynx, just anterior and below the vocal process of the most medialized vocal fold. The suture is secured outside the neck. The proximal end of the same suture is fed through the free needle designed to be used with the needle carrier. This needle is then driven through the larynx slightly superior to the vocal fold. Traction is placed on these two sutures to lateralize the vocal fold.
       5) The sutures are tied over a silicone button on the skin or over the strap muscles.
       6) This step is repeated, with placement of another lateralization suture 1 to 2 mm anterior to the first suture (Fig. 9.5).
    b. Laryngeal botulinum toxin injections
       1) Botulinum toxin injection into the TA/LCA muscle complex(s) results in the vocal fold becoming more flaccid. This may result in a small increase in the glottal airway during respiration. This technique has been shown to help reduce symptoms of dyspnea in patients with new onset BVFI. However, it is only meant to be a temporary treatment and is thus not often necessary.
    c. Glottal dilation
       1) The role for laryngeal balloon dilatation for the posterior glottis is not well established. However, Belafsky et al. explored a unique balloon dilatation technique in the treatment of upper esophageal stenosis.
       2) Anatomic studies of the exact geometric shape of the upper esophageal sphincter led to an altered balloon dilatation configuration resulting in improved dilatation results. To apply the same concept to laryngeal dilatation, one must recognize that the glottis has the shape of an upside-down ice cream cone.
       3) To apply affective balloon dilation to the posterior commissure, an anterior glottis spacer is required. This anterior laryngeal spacer (e.g., Jackson dilator)

will (1) prevent trauma to the membranous vocal folds and (2) direct the dilatory effect of balloon dilatation to the posterior commissure.

4) This procedure maybe useful in acute and subacute settings of PGS.
5) This procedure is often done in combination with steroid injections placed around the CA joints and posterior commissure. It can be repeated approximately every 3 to 4 weeks, for two to three different treatment sessions.

Common Errors in Technique

1. Improper airway management: Performing surgery on the glottal airway requires constant communication with the anesthesia team. These cases should be discussed prior to the patient arriving in the surgical suite. All possibilities of airway management must be candidly discussed and prepared for, including emergency tracheotomy. This is one of the most important components of the surgery, since "loss of the airway" is potentially catastrophic.
2. Improper use of the laser: It is critical that there is a laser operator present when the laser is in use. The surgeon needs to feel comfortable with using the laser, knowing appropriate settings, laser safety precautions, and what to do in the case of a laser airway fire. If an airway fire occurs, the outcome is poor.
3. Not using a large laryngoscope and not angling it toward the operative side: If the visualization is not optimal, then the surgeon may think he or she has adequately opened the glottis, although he or she has not. This problem is also mitigated by using angled telescopes periodically throughout the surgery to judge the progress of the procedure.

POSTOPERATIVE PERIOD

1. Postoperative management
   a. Patients are usually observed for 24 hours postoperatively for airway difficulties. However, patients with an established tracheostomy may be suitable for outpatient surgery.
   b. Voice rest is not necessary.
   c. Perioperative antacid medications are recommended in order to decrease exposure of the healing surgical site to potential acid reflux contents. Treatment of reflux continues until healing is complete.
   d. Pain medications are sometimes required.
   e. Antibiotics are used when deemed necessary by the surgeon.
   f. Patients will experience significant worsening of their voice in the immediate postoperative period because of the large posterior glottic defect and robust edema of the vocal folds seen after many of these surgeries. The quality of the voice should improve over the next 2 to 3 months, at which point it stabilizes.
   g. Frequent follow-up examinations will not only warn the surgeon of granulation tissue formation, which requires medical and/or surgical treatment, but also serve to reassure the patient.
   h. A small posterior glottic defect is expected when healing is complete.
   i. Decannulation, after a successful capping trial, is deferred until healing is complete and the airway is adequate, at least 6 to 8 weeks after surgery.
2. Complications
   a. Granulation tissue (usually after arytenoid surgery)
   b. Restenosis of the surgical site
   c. Dysphonia: Incomplete glottal closure during phonation is an expected "trade-off" for the improved glottal airway.
   d. Dysphagia: The risk of dysphagia after these surgeries exists due to the inability to protect the glottis during the pharyngeal phase of swallowing. Likewise, due to the reduced glottal closure (which is needed for improved breathing), cough efficiency is reduced. This places already at-risk patients at a higher risk of aspiration pneumonia.
   e. Premature decannulation: Premature tracheostomy tube decannulation can occur when the patient increases his or her physical requirements after decannulation, only to determine his or her current glottal airway is not adequate to support such activity. In those circumstances, revision glottic airway opening surgery is required. This risk is mitigated by stressing the importance of testing "desired level of physical activity" prior to the decannulation.
3. Alternative management plan
   a. Tracheostomy is the alternative to glottic opening surgeries. Depending upon the patient, this may be the best option. However, most patients strongly prefer to not have a tracheotomy.

DISCUSSION

Editorial Comment

The authors have undertaken a comprehensive review of the diagnosis and management of patients with BVFI. In addition to the most commonly observed sources such as bilateral injury to the recurrent laryngeal nerve, CA joint fixation, and PGS, I call attention to another, albeit rare, etiology of BVFI. This may be observed when an infiltrating carcinoma involves the postcricoid mucosa. This diagnosis should be considered when other etiologic entities have been reasonably ruled out. Certainly, endoscopy of the upper esophagus is required before posterior glottis stenosis can be attributed to some etiology such as esophageal reflux.

Management of patients with BVFI and resultant airway obstruction requires careful balance between airway, voice, and the patients' exercise requirements. Success is usually measured by degrees of improvement and is almost never absolute. Accordingly, careful shared decision making with the patient regarding his understanding of the problem and his goals for treatment is essential to avoid ultimate therapeutic disappointment with what the surgeon might otherwise have considered a reasonable success.

Jonas T. Johnson

Evidence-Based Medicine Question

Which glottic airway opening surgery is best for the patient in regard to decannulation rates, postoperative dysphonia, and postoperative dysphagia?

There is not one surgery that is best for all patients. The type of surgery is based upon multiple factors: patient history, medical history, laryngeal anatomy, and comfort of surgeon with various surgical techniques. Depending upon the severity of stenosis, decannulation rates are high, but at the expense of voice quality and possibly dysphagia. Patients have different goals in regard to giving up clearer voice quality for decannulation. It is important to candidly discuss with the patient about this trade-off and proceed with the surgical intervention both the patient and surgeon agree upon.

Access the review questions and additional sources list online at http://www.expertconsult.com

REFERENCES

1. Bogdasarian RS, Olson NR. Posterior glottic laryngeal stenosis. Otolaryngol Head Neck Surg 1980;88:765–772.
2. Dennis DP, Kashima H. Carbon dioxide laser posterior cordectomy for treatment of bilateral vocal cord paralysis. Ann Otol Rhinol Laryngol 1989;98:930–934.
3. Crumley RL. Endoscopic laser medial arytenoidectomy for airway management in bilateral laryngeal paralysis. Ann Otol Rhinol Laryngol 1993;102:81–85.
4. Ossoff RH, Karlan MS, Sisson GA. Endoscopic laser arytenoidectomy. Lasers Surg Med 1983;2:293–299.
5. Dedo HH, Sooy CD. Endoscopic laser repair of posterior glottic, subglottic and tracheal stenosis by division or micro-trapdoor flap. Laryngoscope 1984;94:445–450.
6. Lichtenberger G, Toohill RJ. Technique of endo-extralaryngeal suture lateralization for bilateral abductor vocal cord paralysis. Laryngoscope 1997;107:1281–1283.

REVIEW QUESTIONS

1. While performing a CO_2 laser transverse cordotomy, the landmark for the lateral extent of incision is the
   a. Conus elasticus
   b. Cricoid cartilage
   c. False vocal fold
   d. Thyroarytenoid muscle

2. What is the usual time frame of onset of symptomatic dyspnea after extubation when posterior glottic stenosis is the suspected etiology?
   a. 1 to 2 weeks
   b. 4 to 8 weeks
   c. 3 to 4 months
   d. 6 to 9 months

3. Which procedure to improve the glottal airway would be expected to have more postoperative dysphonia and dysphagia?
   a. Endoscopic arytenoidectomy
   b. Microtrapdoor flap
   c. Open arytenoidectomy
   d. Transverse cordotomy

ADDITIONAL SOURCES

Belafsky PC, Plowman EK, Mehdizdeh O, et al. The upper esophageal sphincter is not round: a pilot study evaluating a novel, physiology-based approach to upper esophageal sphincter dilation. Ann Otol Rhinol Laryngol 2013;122(4):217–221.

Bosley B, Rosen C, Simpson CB, et al. Medial arytenoidectomy versus transverse cordotomy as a treatment for bilateral vocal fold paralysis. Ann Otol Rhinol Laryngol 2005;114:922–926.

Ekbom DC, Garrett CG, Yung KC, et al. Botulinum toxin injections for new onset bilateral vocal fold motion impairment in adults. Laryngoscope 2010;120(4):758–763.

Hillel AT, Giraldez L, Samad I, et al. Voice outcomes following posterior cordotomy with medial arytenoidectomy in patients with bilateral vocal fold immobility. JAMA Otolaryngol Head Neck Surg 2015;141(8):728–732.

Krishna P, Rosen C. Office-based arytenoid palpation. Ear Nose Throat J 2006;85:520–522.

Munin MC, Rosen CA, Zullo T. Utility of laryngeal electromyography in predicting recovery after vocal fold paralysis. Arch Phys Med Rehabil 2003;84:1150–1153.

Rosen CA, Mau T, Remacle M, et al. Nomenclature proposal to describe vocal fold motion impairment. Eur Arch Otorhinolaryngol 2016;273(8):1995–1999.

Statham MM, Sukits AL, Redfern MS, et al. Ergonomic analysis of microlaryngoscopy. Laryngoscope 2010;120(2):297–305.

Yılmaz T, Süslü N, Günaydın RÖ, et al. Microtrapdoor flap technique for treatment of glottic laryngeal stenosis: experience with 34 cases. J Voice 2016;30(6):751–754.

10 Acquired Laryngeal Stenosis

Libby J. Smith, Ricardo Carrau

INTRODUCTION

Basic functions of the larynx include being the conduit for air, protecting the airway from aspiration, phonating, coughing, fixing the chest for straining activities, maintaining positive end-expiratory pressure, and swallowing. All these functions can be impaired in patients with laryngeal stenosis.[1,2]

Acquired laryngeal stenosis is a rare condition. It may be a result of external or iatrogenic trauma, systemic diseases, infections, and neoplasms. The degree of laryngeal dysfunction varies widely, with a diversity of treatment methods to address the physical abnormalities and associated symptoms.

Injury to the laryngeal soft tissue or its cartilaginous framework can lead to scarring and loss of support, with subsequent collapse of the airway and stenosis. The laryngeal cartilaginous framework depends on the perichondrium for its blood supply. Cartilage deprived of its blood supply necroses rapidly and acts as a foreign body that induces an inflammatory reaction and causes further tissue destruction and scarring. After injury, the soft tissue planes of the larynx are disrupted and filled with blood, which may develop into an organized hematoma and further fibrosis. The site of injury also influences the development of stenosis. Different areas of the larynx have intrinsic characteristics that protect or predispose to various injuries, as mentioned previously.

1. Surgical anatomy
   a. The larynx is composed of three distinct regions:
      1) Supraglottic
      2) Glottic
      3) Subglottic
   b. All of these regions are covered with mucosa, which is susceptible to injury from direct trauma, radiation, systemic diseases, or infections. Therefore any of these regions can become stenotic from different etiologies.
   c. In general, the supraglottis has more soft tissue and redundant mucosa, making it less dependent on external support than the glottis or subglottis. The supraglottic region includes:
      1) Epiglottis
         a) The epiglottis is a cartilaginous structure that acts like a rudder to deflect food and liquid away from the glottis and into the piriform sinuses during swallowing. The epiglottis has no muscle; therefore it inverts by the interaction of tongue base retraction and hyolaryngeal elevation during swallowing.
      2) Aryepiglottic folds
         a) Aryepiglottic folds are ligaments covered by mucosa that connect the epiglottis to the arytenoid cartilages.
      3) Arytenoids
         a) The cricoarytenoid joints allow for rotation of the arytenoids on the cricoid in three different axes, resulting in lengthening, foreshortening, abduction, and adduction of the vocal folds.
         b) The arytenoid mucoperichondrium is exquisitely sensitive to injury, induced when the capillary perfusion pressure of the overlying mucosa is overcome by the external compression of an endotracheal tube cuff.
      4) False vocal folds
         a) The false vocal folds are soft tissue structures, containing a superior fan of thyroarytenoid muscle.
   d. The glottis is defined as the area between the true vocal folds and is the narrowest portion of the adult airway. Thus the surrounding anatomic structures are responsible for maintaining a patent and functional air passage.
      1) The glottis depends on cartilaginous support, cricoarytenoid joint mobility, and neuromuscular coordination for normal function.
      2) The true vocal folds are multilayered, with the thyroarytenoid muscle and vocalis muscle (most medial aspect of the thyroarytenoid muscle) covered by the lamina propria and an external layer of mucosa.
      3) Intrinsic muscles of the larynx move the vocal folds to:
         a) adduct (lateral cricoarytenoid muscle, interarytenoid muscle, and thyroarytenoid muscle)
         b) abduct (posterior cricoarytenoid muscle)
      4) Primary innervation is by the recurrent laryngeal nerve with variable collateral innervation by Galen nerve, the human communicating nerve, and the interarytenoid plexus.
   e. The subglottis is defined as the area within 1 cm below the glottis.
      1) This is the narrowest segment of the pediatric airway.
      2) The subglottic region:
         a) includes the cricoid, the only complete ring within the human airway
         b) is lined with respiratory epithelium over a submucosa composed of loose areolar tissue
            i) Respiratory epithelium is easily disrupted and is thus not well suited to tolerate trauma.
      3) Subglottic injuries often heal by secondary intention and scarring.
         a) Therefore the subglottis is more susceptible to stenosis than any other region of the larynx.
   f. Outcomes
      1) Outcomes after surgery for acquired laryngeal stenosis vary greatly, depending upon the location, etiology, and severity of disease.
      2) The expected outcome of any of these surgeries is to achieve improvement of the stenosis and decannulation, if applicable.
      3) Complete resolution of stenosis is not expected. Fortunately, patients can tolerate a small amount of stenosis without adversely affecting breathing during normal activities.
      4) Each patient perceives airway restriction differently, so the surgeon must individualize the treatment plan and timing of surgery based upon each patient's unique needs, concerns, and medical comorbidities.
   g. Prognosis
      1) The prognosis for patients with acquired laryngeal stenosis depends upon location, etiology, and extent of disease.

a) Supraglottic stenosis from caustic ingestion or radiation therapy often recurs, requiring repeated surgeries.
b) In the case of an autoimmune etiology, treatment of the underlying autoimmune disease improves and sometimes reverses the stenosis (e.g., Wegener granulomatosis).

2) Anterior glottic webs often restenose to some extent after treatment, regardless of technique.
a) Placement of a keel improves the airway result.
b) Restoration of the mucosal wave is not expected after lysis of the web.

3) Treatment of posterior glottic stenosis (PGS) is fraught with challenges due to the compromise of voice quality and the possibility of aspiration when the posterior glottis is surgically opened.
a) Due to the nonreversible nature of the posterior glottic augmentation surgeries, conservative surgery is initially advocated, especially if the patient already has a tracheostomy tube for airway management.
b) The patient often needs to come to terms with the voice and swallowing repercussions from these surgeries because these functions may be less than normal.
c) Repeat surgery is often required, depending upon healing and airway requirements according to the patient's activity level.

4) Subglottic stenosis can also recur, thus requiring several surgical interventions. Gastric acid reflux should be considered as a contributing factor.

5) In general, open procedures to address laryngeal stenosis are more effective than endoscopic procedures.

6) However, open procedures have increased morbidity, including tracheostomy, and longer recuperation times.

7) Endoscopic "touch up" surgeries are sometimes needed even after open resection.

KEY OPERATIVE LEARNING POINTS

- Intraoperative control of the airway by either endotracheal intubation or tracheostomy is paramount in any surgery for laryngotracheal stenosis.
- Dilatation can be successfully used as primary treatment in select cases of thin congenital webs, as adjuvant therapy for endoscopic microsurgical techniques, or as palliation in patients who are medically unsuited for major reconstructive surgery.
- Endoscopic microsurgical techniques, with or without adjunctive procedures such as intralesional steroid injection or application of mitomycin C, are ideally suited for the management of thin webs or other less severe stenoses with good cartilage support.
- Anterior glottic webs less than 1 cm in height are usually amenable to endoscopic excision with subsequent placement of a stent or keel.
- Treatment success of the PGS depends on the degree and depth of scarring, mobility of the cricoarytenoid joints, and the patient's acceptance of dysphonia and dysphagia in turn for improved airway restriction.
- Endoscopic microsurgery for acquired laryngeal stenosis is likely to fail when used in patients with multiple stenotic sites, when the stenosis is associated with loss of cartilaginous support, when it is wider than 1 cm, when the lesion is circumferential, and when accompanied by the presence of bacterial infection.
- Failure to control gastroesophageal reflux in the perioperative period may contribute to persistent or recurrent laryngeal stenosis.
- Inadequate preoperative, intraoperative, and postoperative communication with the anesthesia and surgical and recovery room staff can result in catastrophic airway events.
- Changing to a cuffless tracheotomy tube too soon after laryngotracheal reconstruction may result in subcutaneous emphysema, contamination of the cervical wounds, and even a laryngocutaneous fistula.
- A persistent postoperative laryngocutaneous fistula usually signifies inadequate wound drainage and underlying infection.

PREOPERATIVE PERIOD

1. History
   a. Symptoms
      1) Shortness of breath
      2) Dyspnea on exertion
      3) Stridor
      4) Hoarseness
      5) Difficulty swallowing
      6) Aspiration
      7) Difficulty clearing secretions
      8) Any combination of these symptoms and signs
   b. Etiology
      1) External trauma
         a) Civilian violence and motor vehicle accidents have led to an increase in the incidence of posttraumatic laryngeal stenosis.
            i) The incidence of laryngeal stenosis after external trauma varies from 0% to 59%.
         b) Even when an adequate and immediate repair is accomplished, a severe disruption of supporting structures or laryngotracheal separation is accompanied by some degree of airway narrowing.[3]
      2) Intubation
         a) The incidence of laryngeal stenosis after prolonged or repeated intubation has been estimated to range from 3% to 8% in both adults and children. Figures as high as 44% have been cited for low-birth-weight neonates and those with respiratory distress syndrome. Higher rates of stenosis are expected after inhalation injury.
         b) Causes of laryngeal stenosis after intubation are multifactorial, including:
            i) Duration of intubation
            ii) Endotracheal tube size
            iii) Pressure and rubbing of the endotracheal tube against the larynx
            iv) Repeated intubation
            v) Foreign body reaction to the tube
            vi) Anatomic differences between the sexes
         c) An appropriately sized endotracheal tube for each patient's anatomy, correlating with patient height, is strongly recommended. An appropriately sized endotracheal tube should decrease the risk of laryngeal stenosis, which more frequently affects the posterior glottis.
         d) PGS results from disruption of the mucosa between the arytenoids.
            i) Patients often complain of slowly progressive dyspnea beginning 4 to 8 weeks after extubation.
            ii) Incidence of PGS increases with:
               (1) Uncontrolled diabetes
               (2) Excessively large diameter endotracheal tube in relation to the tracheal lumen

(3) Tube movement (especially if the patient is not sedated)
(4) Prolonged intubation
(5) Multiple medical comorbidities
iii) Therefore elective tracheostomy is recommended when intubation is expected to be needed for longer than 10 days.
e) Cuff pressure has been found to be more important than the duration of intubation.[4]
i) The use of high-volume, low-pressure cuffs has helped to prevent ischemic injury; however, maintenance of an appropriate cuff pressure is important.
ii) The microcirculation of the laryngeal mucosa is disrupted at cuff pressures greater than 22 mm Hg (30 cm H_2O), resulting in cartilage necrosis and eventual cricoid or tracheal stenosis or malacia.

3) Tracheotomy
a) A high tracheotomy may injure both the glottis and subglottis.
i) A high tracheotomy through the first tracheal ring or the cricoid cartilage leads to cricoid chondronecrosis with resultant fibrosis and stenosis.
ii) Ideally, a tracheotomy should be performed between the second and third tracheal ring; however, tracheal windows or Björk flaps are ideally performed through the third tracheal ring.
b) Similarly, a cricothyroidotomy has been associated with a higher incidence of laryngeal stenosis than tracheotomy.
i) The height of the cricothyroid membrane in adults ranges from 8 to 13 mm (average of 9 mm).
ii) Therefore tracheotomy tubes are poorly suited to intubate the subglottic larynx because the outer diameter of most tracheotomy tubes is larger than the normal height of the cricothyroid membrane.

4) Endoscopy
a) The effects of endoscopic instruments on the laryngeal airway reflect the care and skill of the operator.
b) Rough handling of tissue, overenthusiastic biopsies, inadvertent or inaccurate laser ablation, and oversized instruments all promote tissue fibrosis and stenosis.

5) Caustic burns
a) Caustic burns are characterized by extensive destruction of mucosa, submucosa, and muscles. The subsequent wound contracture and fibrosis may result in dysfunction.
b) The sphincteric action of the supraglottis often impedes contact of an ingested caustic agent with the glottis.
c) Consequently, severe caustic burns of the supraglottis usually occur without any involvement of the glottis.
d) However, the pharyngeal walls are commonly injured as the chemical passes into the cervical esophagus.

6) Radiation therapy
a) Radiation therapy and especially concurrent chemoradiation produce damage to the microcirculation with progressive death of the soft tissues and subsequent replacement by scar tissue.
i) Ensuing fibrosis of the mucosa, submucosa, and muscles can lead to both a mechanical and functional stenosis of the supraglottic and glottic areas.
ii) Severe mucositis leads to loss of the epithelium and fibrosis, sometimes resulting in severe pharyngolaryngeal stenosis.
(1) In severe situations, a patient may require a tracheostomy and gastrostomy.

7) Nasogastric intubation
a) Nasogastric tubes are an often overlooked source of trauma.
b) Nasogastric intubation produces inflammation secondary to:
i) A foreign body reaction to the tube
ii) Swallowing impairment with pooling of secretions
iii) Pressure necrosis
iv) Gastropharyngeal reflux
c) All these factors play a role in the development of postcricoid ulceration with resultant perichondritis and subsequent fibrosis and contracture.
d) The trauma associated with the nasogastric tube may be synergistic with the trauma induced by an endotracheal tube.
e) This is termed nasogastric tube syndrome, or Sofferman syndrome.

8) Infectious and granulomatous diseases
a) Tuberculosis, histoplasmosis, blastomycosis, leprosy, and syphilis are endemic in many areas of the world.
i) They share a common phase of erythema and edema that progresses to chondritis, necrosis, and scarring.[5]
ii) Laryngeal syphilis and tuberculosis (Fig. 10.1A), as well as diphtheria, although seldom encountered nowadays in the United States, were common causes of stenosis in the past.
b) Granulomatous polyangiitis (GPA; previously termed Wegener granulomatosis) (see Fig. 10.1B and C) and sarcoidosis (see Fig. 10.1D) may involve the larynx.
i) Subglottic stenosis occurs in 10% to 20% of patients with Wegener granulomatosis.
ii) The mainstay of treatment remains nonsurgical (e.g., cyclophosphamide, steroids). Surgical therapy, which usually consists of dilatation and adjuvant modalities, such as injectable steroids and topical mitomycin C, is typically reserved for patients who have failed medical treatment and is performed only during remission of the disease.

9) Autoimmune diseases
a) Autoimmune diseases, such as relapsing polychondritis, may destroy the cartilaginous framework, such as the cricoid, leading to collapse or stenosis of the airway, or affect the laryngeal joints resulting in cricoarytenoid joint fixation (Fig. 10.2).
i) Cricoarytenoid joint fixation may be the initial manifestation of rheumatoid arthritis.

10) Lymphoproliferative disorders
a) Amyloid of the larynx can also result in supraglottic stenosis, usually with deposition in the false vocal folds or aryepiglottic folds.
b) These patients require a complete evaluation for systemic causes of amyloid, such as multiple myeloma.

11) Gastropharyngeal reflux
   a) Repeated exposure to pepsin and acid from gastric reflux produces mucosal and submucosal injury and thereby leads to more scarring (Fig. 10.3).
   b) Prophylaxis with acid suppression medications is recommended after any injury to the larynx.
      i) Patients should be carefully monitored for gastroesophageal reflux, and those with recalcitrant stenosis must be assumed to be suffering from gastroesophageal reflux and be treated accordingly.
   c) With the recent concerns of adverse side effects from proton pump inhibitors (such as osteoporosis, heart disease, kidney disease, infections, and dementia), the risks and benefits of using these medications must be considered.
   d) Antireflux surgery is considered in high-risk patients.

c. Medical comorbidities
   1) The patient's medical comorbidities must be considered when planning for appropriate surgical treatment. This includes, but is not limited to, the following:
      a) Uncontrolled diabetes will result in poor wound healing. Hemoglobin A1C provides the surgeon information on the patient's serum glucose levels in the recent past. Optimizing this is required before surgery.

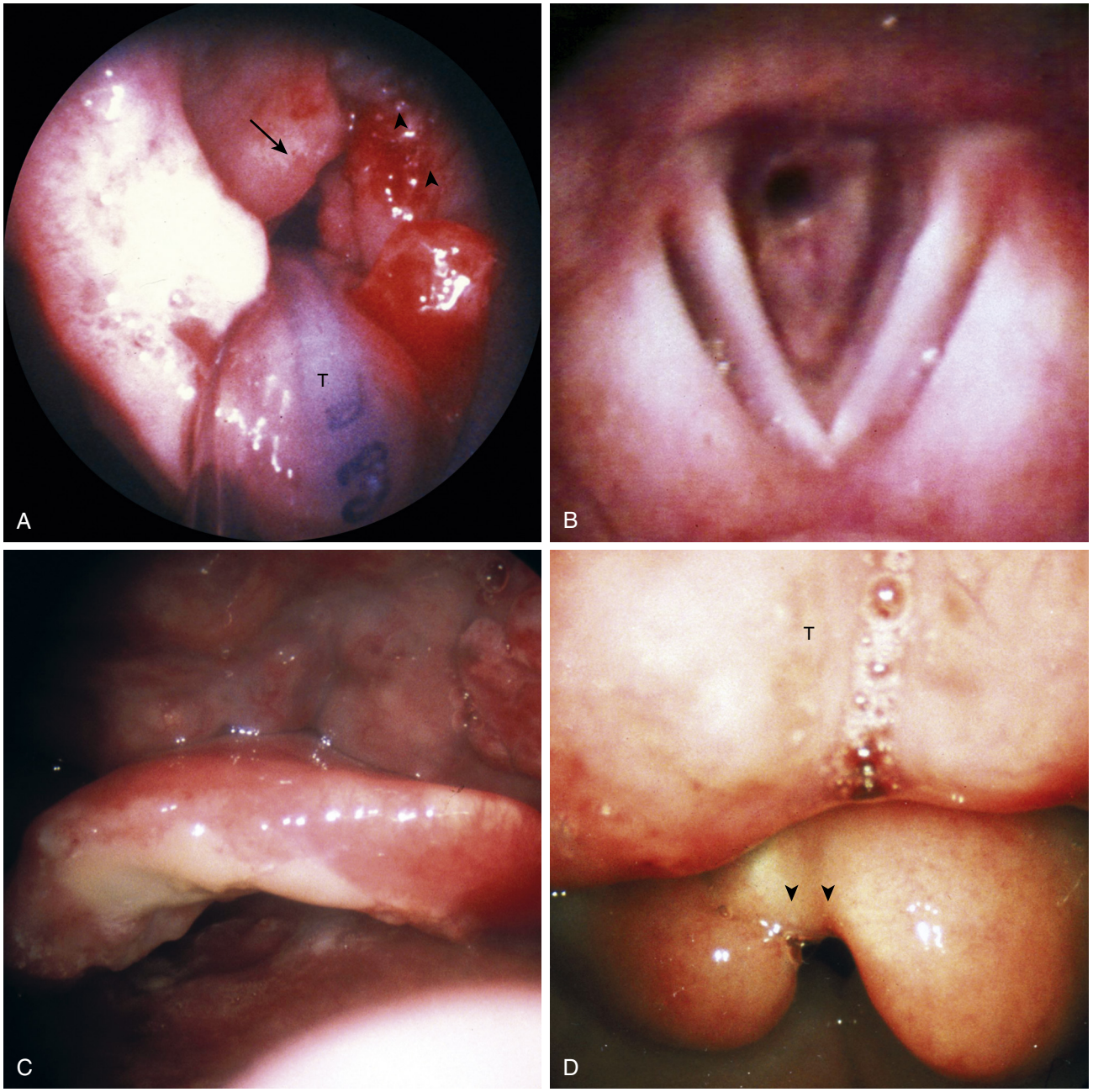

Fig. 10.1. Laryngeal involvement. A, Tuberculosis: ulceration and granulation tissue *(arrowheads)* in the right false vocal cord; edema *(arrow)* of the left false vocal cord. *T,* Endotracheal tube placed over the posterior glottis. **B,** Wegener granulomatosis: subglottic stenosis. **C,** Wegener granulomatosis: epiglottic ulceration. **D,** Sarcoidosis: epiglottic scarring *(arrowheads)*. *T,* Tongue.

b) Immunocompromised patients have a higher risk of infection and often slower wound healing. This must be considered for patients with immunosuppression for rheumatologic conditions.
c) Anticoagulation medication must be reversed before undergoing airway surgery. Hematoma within the surgical site can result in airway obstruction and the need for emergent airway management.
d) Pulmonary status can help guide appropriate surgical treatment. If patients have poor pulmonary clearance and require supplemental oxygen, this must be considered as a risk for the formation of mucus plugs. Providing a safe, patent airway is the goal of treatment.

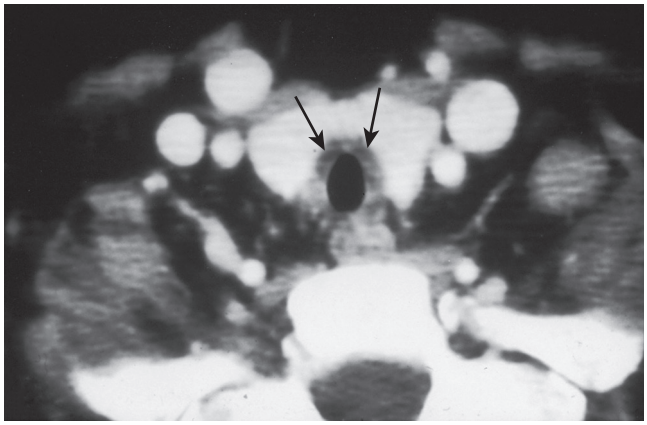

Fig. 10.2. Computed tomography scan of a patient with active relapsing polychondritis demonstrating edema of the perichondrium of the cricoid cartilage and resorption of the cartilage *(arrows)*.

2. Physical examination
   a. Office
      1) Flexible nasopharyngeal laryngoscopy is essential for evaluating the site and degree of stenosis, as well as vocal fold mobility.
      2) Videolaryngoscopy and still photographs provide objective documentation that can be discussed with the patient.
      3) Electromyography helps differentiate neuromuscular deficits from cricoarytenoid joint fixation or subluxation.
      4) An awake, flexible bronchoscopy can be performed in the office or surgical suite, with topical anesthesia.
         a) When performed in the office, this helps to characterize the stenosis before evaluation in the operating room.
         b) Visualization through the main stem bronchi is recommended to evaluate for synchronous areas of stenosis.
         c) This information helps the surgeon prepare for airway management when the patient is under general anesthesia.
         d) If there is a concern for tracheal or laryngeal malacia, which is a dynamic collapse of the airway, then fiberoptic laryngotracheal endoscopy must be performed with the patient breathing spontaneously.
            i) Distinction of malacia from stenosis is critical because it directly impacts treatment and prognosis.
   b. Operating suite
      1) Rigid direct laryngoscopic and bronchoscopic examination with rigid endoscopes, with the patient under general anesthesia, complements the office examination.

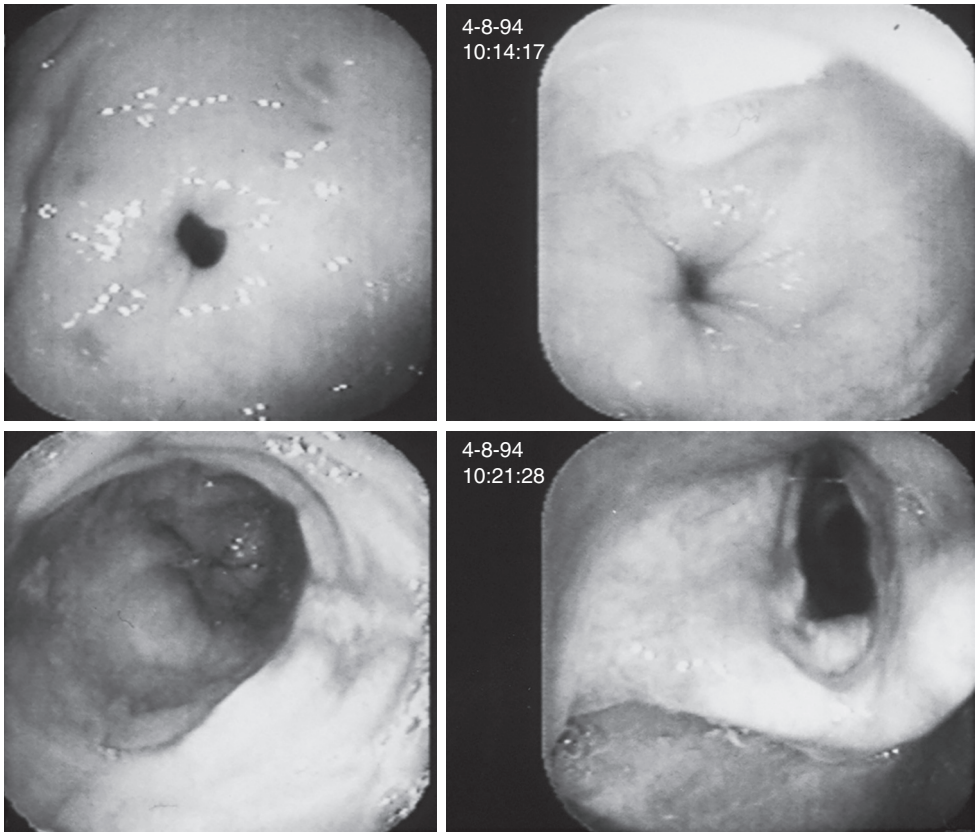

Fig. 10.3. Lower right, vocal cord edema, pachyderma laryngis, and granuloma at the vocal processes. The other photographs show punctate and erosive esophagitis at different levels of the esophagus.

2) Rigid direct laryngoscopy allows evaluation of the passive motion of the arytenoids and circumferential examination of the subglottis and provides an idea of the firmness of the scar tissue.

3. Imaging
   a. Although imaging is important to delineate the cartilaginous framework, it does not obviate the importance of both flexible and rigid endoscopy in determining appropriate treatment.
   b. Computed tomography (CT) is considered the standard imaging technique to corroborate the integrity of the cartilaginous framework (Fig. 10.4) and evaluate the cricoarytenoid joint.
   c. Other pertinent imaging modalities include magnetic resonance imaging (MRI), ultrasound, and fluoroscopy.
      1) MRI is useful in the evaluation of extensive laryngotracheal stenosis and does not involve any radiation exposure.
         a) However, a major limitation of MRI is that the patient must remain supine for a long time, which is not tolerated by patients with significant orthopnea due to airway obstruction.
      2) Ultrasound may provide a convenient, well-tolerated, noninvasive method of assessing subglottic airway diameter.
      3) Fluoroscopy is most helpful in evaluating areas of tracheomalacia that collapse on inspiration but look normal during rigid direct endoscopy performed under general anesthesia.
   d. Soft tissue radiographs are rarely used in the evaluation of adult acquired laryngeal stenosis.
4. Indications
   a. The most common indications for a surgical intervention to correct an acquired laryngeal stenosis are dyspnea and dysphagia.
   b. Patients with supraglottic stenosis often complain of difficulty swallowing and experience dyspnea only when it is severe.
   c. Conversely, patients with glottic and subglottic stenosis have complaints of dysphagia less frequently. In contrast, difficulty breathing drives the timing of surgical intervention.
5. Contraindications
   a. Uncontrolled anticoagulation
   b. Uncontrolled diabetes
   c. Current smoker
   d. Relative contraindications: immunosuppression, poor overall health
   e. There is no strict contraindication for performing an emergency tracheotomy.
6. Preoperative preparation
   a. The site and extent of the stenosis dictate appropriate surgical treatment.
   b. Occasionally, the patient's condition is so dire that a tracheostomy is required to bypass the stenosis.
   c. Administration of corticosteroids in the perioperative period, although their benefit has not been scientifically proven, may help minimize the postoperative edema, which is critical in patients without a tracheostomy.

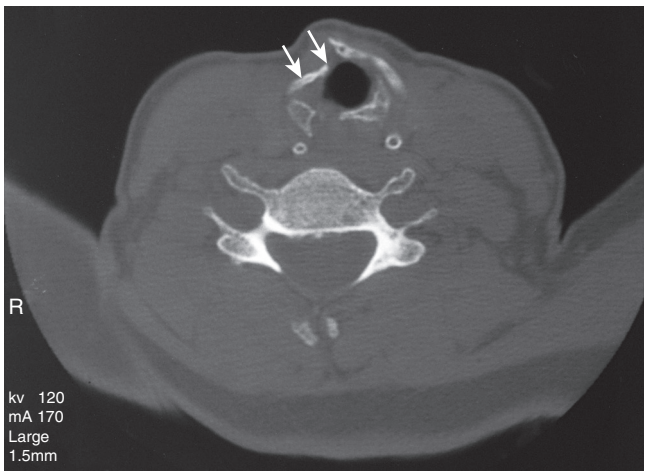

Fig. 10.4. Computed tomography scan, axial view, demonstrating fractures involving the thyroid and cricoid cartilage *(arrows)*.

OPERATIVE PERIOD

1. Anesthesia
   a. Establishing a secured airway is the keystone to all procedures in the correction of laryngeal stenosis.
      1) The airway may be secured with an endotracheal tube or a tracheostomy.
      2) A tracheostomy performed with the patient under local anesthesia is recommended for patients with significant airway compromise (e.g., stridor) and for those who require a transcervical approach.
      3) Select patients with supraglottic, glottic, and subglottic stenosis may be intubated.
         a) Intermittent removal of the endotracheal tube, with the patient apneic, is sometimes required to perform surgery.
   b. Jet pressure ventilation (e.g., Venturi system) can be used if there is enough air outflow; otherwise the patient is at risk for increased lung pressures and tension pneumothorax.
      1) Subglottic jet ventilation can often be used in the treatment of subglottic stenosis, delivered through the rigid laryngoscope.
      2) However, both the anesthesiologist and surgeon must be very familiar with the functionality and risks of jet ventilation.
      3) If there is limited exposure and familiarity with jet ventilation, then it should not be performed, and rather use endotracheal intubation or a tracheotomy.
2. Positioning
   a. For endoscopic procedures: The patient is placed in a supine "sniffing" position.
      1) Neck flexion, head extension
      2) Shoulder rolls are not used. Rather, a head "donut" is used to stabilize the head.
      3) "Ramp" position is sometimes used for obese patients. Blankets and/or towels are placed below the patients' shoulders and head such that the tragus is horizontal to the manubrium. This can facilitate proper laryngeal exposure.
   b. Surgeon positioning
      1) Important to reduce musculoskeletal injuries to the surgeon
      2) After the larynx is exposed, proper surgeon ergonomic position is achieved by moving the bed angle (usually Trendelenburg; "head down") so the laryngoscope is approximately 40 degrees off the horizontal plane.
      3) The surgeon's neck should be in a neutral position or slightly flexed but never extended.
      4) Arm rest support while operating is important.
      5) Sometimes lowering the height of the bed is necessary to allow for more comfortable placement of the surgeon's arms and hands.

c. For open procedures: The patient is supine with the neck extended. This brings the laryngotracheal complex into the cervical area.

3. Perioperative antibiotic prophylaxis
   a. Laryngeal surgery is classified as a clean-contaminated procedure, for which perioperative prophylactic antibiotics are recommended.
   b. A prolonged therapeutic course of antibiotics may be indicated in special circumstances (e.g., active chondritis).
      1) The theoretical value of a prolonged course of antibiotics is to control the infection, thus stopping a vicious cycle of chondritis, necrosis, granulation tissue formation, and scar deposition.
      2) There is a highly significant association between stent colonization with specific bacteria (*Staphylococcus aureus* and *Pseudomonas aeruginosa*) and the development of airway granulation.
      3) Azithromycin has been used not for its antimicrobial effects but rather its anti-inflammatory effects.[6]
   c. Nebulized ciprofloxacin/dexamethasone otologic preparation (5 drops/1 mL saline, twice daily) can also be used as an adjunctive treatment.
4. Instruments and equipment to have available
   a. Endoscopic surgery
      1) Laryngeal suspension device
      2) Various sizes of laryngoscopes
      3) Surgical microscope
      4) Microlaryngeal surgical set
      5) Rigid telescopes (0, 30, and 70 degrees; 30 cm length, 5 to 10 mm diameter): These are used to better visualize the extent of lateral extension of the surgical field.
      6) Orotracheal injector
      7) Fiber-based CO_2 laser with micromanipulator airway dilators
   b. Open surgery
      1) Head and neck or plastic surgery set
      2) Self-retaining retractors (e.g., Weitlander)
      3) Double prong retractors
      4) Insulated bipolar cautery
      5) Rib harvesting set
   c. Tracheostomy surgical set
5. Key anatomic landmarks
   a. Intimate knowledge of supraglottic, glottic, and subglottic anatomy, depending upon the type and location of the laryngeal stenosis
6. Prerequisite skills
   a. Endoscopic surgery skills
   b. Open surgery skills
   c. Laser certification
   d. Airway dilation
   e. Tracheostomy
   f. Comfort with complex airway manipulation before, during, and after surgery
7. Operative risks
   a. During CO_2 laser surgery, the safety of the patient and operating room personnel is a primary consideration. Laser safety precautions include the following:
      1) All operating room personnel should use protective eyewear.
      2) The patient's eyes are kept closed with adhesive dressing (e.g., Tegaderm) and then covered with eye pads soaked in saline solution or protective eye shields.
      3) The face, the upper part of the chest, and the laryngoscope are covered with surgical towels soaked in saline solution (Fig. 10.5). A saline-filled bulb syringe should be within reach of the surgeon in the event of an airway fire.

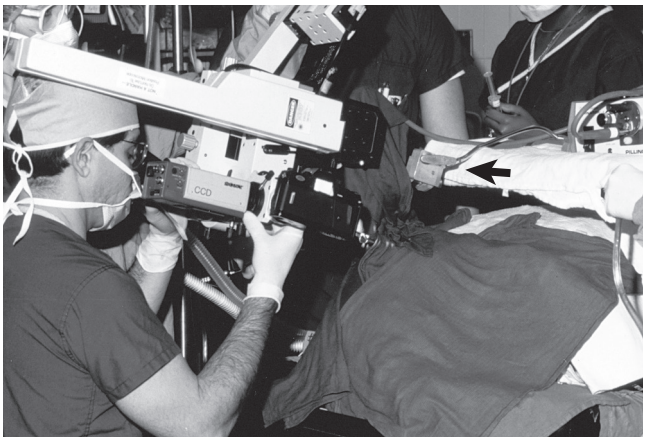

Fig. 10.5. Setup for laser microsurgery. The patient and the laryngoscope are covered with towels soaked in normal saline solution. The *arrow* indicates the suspension system.

      4) The laser-resistant endotracheal tube, exposed outside the mouth, should be covered with metal tape, foil, or wet towels. In the airway, the tube and cuff are protected with a wet cottonoid.
      5) The subglottis may be protected with a cottonoid soaked in normal saline solution or by using a nonreflecting platform below the free edge of the vocal fold receiving the laser beam.
      6) Communication with the anesthesia team is critical because the patient's fraction of inspired air (FiO_2) should be less than 40% and preferably less than 30%.
      7) Before beginning the surgery, the laser should be tested to ensure that the aiming beam is aligned (i.e., coaxial) to the laser beam.
      8) "Bouncing" of the laser beam against the laryngoscope during surgery should be avoided.
      9) The laser beam should not be allowed to hit the subglottis when the surgeon is working at the free edge of the vocal fold, to avoid unnecessary damage to the subglottis and increase the possibility of inadvertent endotracheal tube puncture and fire.
      10) Laser char should be removed frequently with pledgets soaked in normal saline.
      11) All these maneuvers complement but are not a substitute for good judgment and careful surgical technique.
   b. Certain risks are inherent to performing endolaryngeal surgery, including the following:
      1) Dental injury: Dental splints should be used for all patients with dentition. For edentulous patients, foam or gauze protection of the gingiva is used.
      2) Temporary change of sensation of the tongue and rarely reduced tongue motion may be the result of traction and/or compression of sensory and motor nerves.
      3) Mucosal injury: from mucosal manipulation with placement of laryngoscope
      4) Temporomandibular joint pain: due to prolonged mouth opening during a long procedure
   c. Loss of airway
      1) This risk should be mitigated by the surgeon's understanding of the patient's airway.
      2) The surgeon must be in constant communication with the anesthesia team.
      3) The surgeon must be ready to perform a tracheotomy when necessary.

8. Surgical Technique
   a. Three basic principles are fundamental to the successful outcome of any surgery for laryngeal stenosis:
      1) Adequate exposure
      2) Preservation of normal tissue
      3) Prevention of recurrence by promoting primary healing
   b. Treatment of laryngeal stenosis has evolved from the "wait-and-see" philosophy to dilatation and eventually to endoscopic procedures with microsurgery. Surgical approaches have been combined with the use of antibiotics, stents, corticosteroids, and lumen augmentation procedures with or without grafts. Unfortunately, none of these techniques offers a 100% resolution of airway obstruction in all patients.
   c. Wait-and-see approach
      1) This approach has been applied to children with congenital stenosis in the hope that the patient will outgrow the defect.
      2) When dealing with acquired laryngeal stenosis, the continuous process of scar maturation and contraction makes this outcome very unlikely.
         a) Therefore the wait-and-see philosophy is rarely justified for patients with acquired laryngeal stenosis.
         b) Symptomatic patients require treatment and cannot wait around to see what happens.
   d. Dilatation
      1) Dilatation is most successful when used for select cases of thin regions of stenosis.
      2) The probability for a successful dilatation increases when the technique is used for soft or immature scars of minimal thickness and when it is used as an adjunct to other techniques (e.g., radial incisions).
      3) Unfortunately, acquired stenosis is often characterized by hyalinization of the connective tissue and collagen cross-linking that translates into an incompressible, rigid scar resisting the effects of dilatation.
      4) It may offer palliation to patients in poor general medical condition.[7]
      5) A significant disadvantage of the technique is the need to repeat the procedure a number of times on each patient.
         a) Overall, approximately three-quarters of patients treated by dilatation as primary therapy will have recurrence of the stenosis and require a subsequent intervention.[8]
   e. Endoscopic microsurgery: cold instrumentation versus laser
      1) The outcome after endoscopic microsurgery depends upon:
         a) Etiology
         b) Site
         c) Extent of the stenosis
         d) Therefore appropriate patient selection is essential.
      2) Endoscopic microsurgery for acquired laryngeal stenosis is likely to fail in the presence of[7]:
         a) Multiple stenotic sites
         b) Associated loss of cartilaginous support
         c) Thickness of stenosis greater than 1 cm
         d) Circumferential stenosis
         e) Concurrent bacterial infection
      3) Laser surgery offers the unique advantages of a visual field not obscured by instruments and ease of hemostasis.
         a) Whether the laser is less traumatic than microsurgical instruments is controversial.
         i) Experimental data suggest that wounds produced by a laser beam show early re-epithelialization with slow fibroblast proliferation and collagen formation.
         ii) However, as a general rule, microsurgical instruments better preserve normal tissue.
         iii) Large defects heal by secondary intention (i.e., increased scarring) irrespective of the method of incision.[1,2]
      4) Currently, endoscopic management is the most frequently used method of treating supraglottic, glottic, and select subglottic stenoses.
   f. Corticosteroids
      1) Corticosteroids prevent intracellular sequestration and stabilize cell membranes, thereby preventing the release of lysosomes that produce swelling and tissue destruction.
      2) They also inhibit collagen synthesis, enhance collagen breakdown, and reduce mitosis and the active transport of fibroblasts.
      3) Although their clinical benefits for laryngeal stenosis are yet unproven, intralesional injections may be of benefit to soften scar bands and synechiae.
   g. Mitomycin C
      1) Mitomycin C is an alkylating agent that inhibits protein and DNA synthesis, impeding fibroblast proliferation, thus decreasing the probability of restenosis.
      2) It is generally accepted as a safe and cost-effective adjunct to laryngotracheal surgery.[9]
      3) Typical dosing is topical application of 0.4 mg/mL for 4 minutes in patients who have a tracheostomy or for 2 minutes repeated once (for a total of 4 minutes) for patients without a tracheostomy, due to the apnea period needed for application.
      4) Studies suggest that the use of topical mitomycin C during laryngeal airway procedures results in a significantly longer symptom-free interval than did those who underwent endoscopic treatment alone.[10]
   h. External procedures
      1) Basic transcervical approaches include the lateral pharyngotomy, direct resection of the stenotic segment with end-to-end anastomosis, and median thyrotomy.
      2) Advocates of transcervical procedures believe that these approaches allow precise excision of scar tissue, facilitate primary closure by allowing the advancement of mucosal flaps, and therefore decrease the need for revision surgery.
   i. Stenting
      1) Stenting aims to maintain the lumen while allowing the dynamics of wound healing to occur about a relatively inert object that resists scarring.
      2) A significant caveat to using a stent is its induction of a foreign body reaction with exacerbation of the inflammatory response, further destruction of tissue, and slow re-epithelialization.
      3) Stents have been molded with rigid and soft materials.
         a) Rigid stents are not recommended because they produce trauma that is similar to that of endotracheal tubes.
         b) The most popular stents are tubular or solid prefabricated Teflon or Silastic stents (Figs. 10.6 and 10.7).
      4) Stents are most useful in the postoperative setting as an adjunct to airway augmentation procedures, by supporting a free graft or a vascularized flap and to preserve the lumen.



Fig. 10.6. Prefabricated stents. Left to right are shown the Eliachar, Montgomery, and Aboulker stents.



Fig. 10.7. Different sizes of Montgomery laryngeal stents. Left to right: child, small adult, medium adult, and large adult stents.

5) The reported ideal period of stenting ranges from 2 weeks to 10 months.
   a) As a general rule, 2 to 4 weeks of stenting is sufficient. Stents need to be left in place longer if the patient has diabetes or is immunocompromised.
6) Stents can be problematic and require heightened attention to their potentially life-threatening complications.
7) Stented patients often require a tracheostomy.
8) T-tube stents can also be used as primary treatment of complex cases with stenoses at multiple sites or as a salvage effort in patients who have failed multiple attempts at airway reconstruction.
   a) Stent deterioration and foul odor, possibly from biofilm degradation, require that the T-tube stents be replaced periodically, usually approximately every 3 to 6 months.
   b) All patients with T-tubes must know how to emergently remove their T-tubes if it becomes blocked and they are unable to flush it.

j. Supraglottic stenosis
1) Supraglottic stenosis is amenable to endoscopic or open techniques.
2) Endoscopic laser resection and balloon dilation are commonly used.
   a) CO_2 laser incisions are created in "quadrants" after placement and suspension of a rigid laryngoscope.

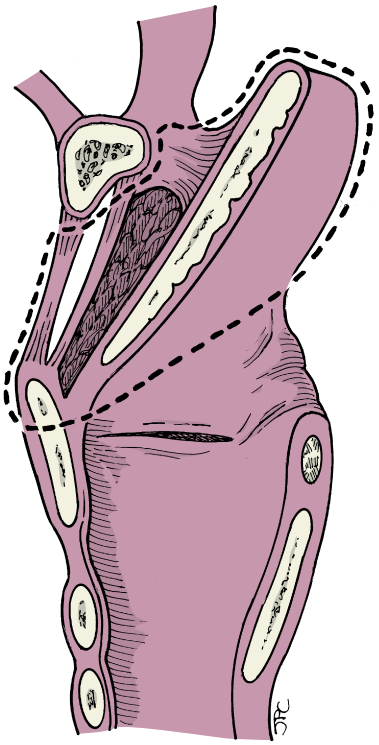

Fig. 10.8. Sagittal plane. The *dashed line* outlines the area to be resected during partial supraglottic laryngectomy.

   b) Care is made to avoid broad mucosal injury, as re-stenosis will occur.
   c) The goal is to make radial cuts, allowing the expected scar process after surgery to retract the tissue.
   d) This is often followed by serial balloon dilation. Rarely, retrograde balloon dilation through the tracheostoma is necessary.
3) In select cases, such as patients with poor general status, some temporary palliation may be achieved with a submucosal injection of corticosteroids and dilatation.
4) In severe cases not amendable or resistant to endoscopic techniques, open supraglottic laryngectomy is performed.
   a) As opposed to an oncologic supraglottic laryngectomy, this open procedure preserves the innervation of the superior laryngeal nerves, the hyoid bone, and the soft tissues adjacent to the scarred area.
   b) An incision is incorporated into a horizontal skin crease over the thyroid cartilage.
   c) Subplatysmal flaps are elevated superiorly to expose the insertion of the suprahyoid musculature and inferiorly to the level of the cricoid.
   d) The infrahyoid strap muscles are transected at their insertion to expose the portion of the hyoid bone medial to the lesser cornua (Fig. 10.8). The strap muscles are dissected from the thyroid cartilage and retracted laterally.
   e) The pharynx is entered as described for transhyoid pharyngotomy (see Chapter 35) (Fig. 10.9).
      i) This allows direct visualization of the stenosis.
   f) Incisions through the thyroid cartilage are performed with a no. 10 blade or an oscillating saw if the cartilage is calcified.
      i) The superior cornua of the thyroid cartilage, as well as the superior laryngeal neurovascular bundles, are spared.

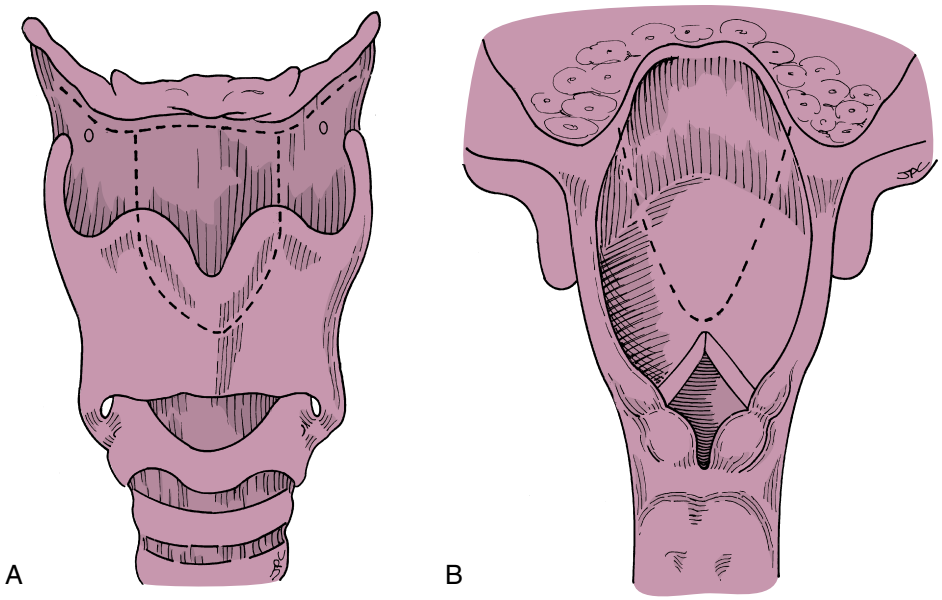

Fig. 10.9. Coronal plane. The *dashed lines* indicate the level of incisions through the thyrohyoid membrane and the thyroid chondrotomies, **A,** and the endolaryngeal incisions, **B.**

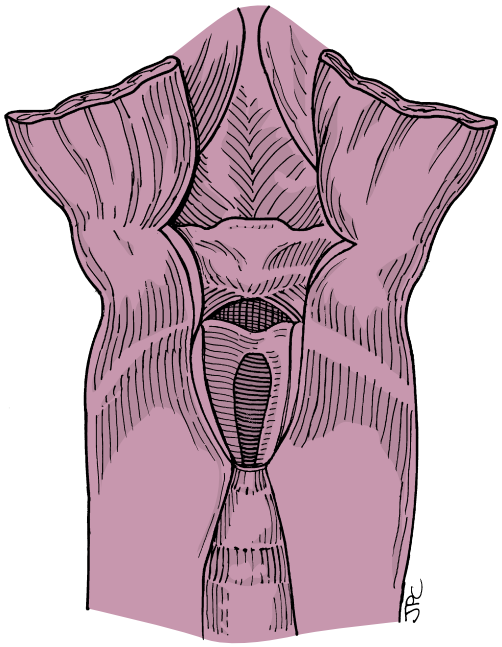

Fig. 10.10. Coronal plane. In a transcervical view after removal of the median supraglottis, the vocal cords can be seen through the defect. The hyoid bone has been preserved.

g) The soft tissue incisions include the stenotic area after the thyrotomy incisions are made (Fig. 10.10).
h) The defect is repaired by suturing the base of tongue to the perichondrium of the thyroid ala.
   i) If the epiglottis is not sacrificed, it is incorporated into the closure.
   ii) It is important to tack the epiglottis anteriorly to the remaining thyroid cartilage or the epiglottis will fold down and obstruct the view of the glottis posteriorly in the postoperative period.
i) The strap muscles are re-approximated to the hyoid bone and to each other at the midline. The wound is repaired with a multilayer technique. Suction drains are left in place.

k. Glottic stenosis
   1) Stenosis of the glottic area should be further classified as anterior, posterior, or combined lesions. This simple classification is important because the cause, treatment, and prognosis are very different for each location of stenosis.
   2) Anterior glottic stenosis
      a) Anterior glottic stenosis usually develops after disruption of the anterior commissure by external trauma (e.g., laryngeal fracture), endoscopic surgery (e.g., vocal cord stripping), or oncologic surgery (e.g., partial vertical laryngectomy).
      b) Anterior glottic stenosis causes foreshortening of the glottis and tethers the abduction of the true vocal cords (Fig. 10.11A and B).
      c) The method of resection, whether to use a laser or "cold" microsurgical instruments or to approach the lesion endoscopically or transcervically, is less important than good surgical technique to improve the airway and promote primary healing.
         i) Magnification of the surgical field with a microscope or loupes optimizes preservation of normal tissue.
         ii) Fine instrumentation is important to minimize tissue trauma.
      d) Invariably, correction of anterior glottic stenosis will result in two opposing surfaces with denuded epithelium. These two surfaces will tend to heal together and form a web (i.e., restenosis), although sometimes not as severely as before surgery.
         i) A stent or keel that separates these two denuded areas prevents this problem.
         ii) Alternatively, the web can be divided into superficial and deep layers based laterally at the anterior one-third of the free edge of the true vocal folds. These flaps are then rotated to cover the denuded areas of the vocal fold, thereby precluding the need for a keel.

e) Anterior glottic webs less than 1 cm in height are amenable to endoscopic incision under general anesthesia.
f) The patient is placed in a supine, "sniffing position" (neck flexion, head extension).
g) A large rigid laryngoscope is suspended, allowing binocular microscopic magnification of the anterior glottic stenosis.
h) The web may be lysed with a laser or "cold" microsurgical instruments (see Fig. 10.11A to C).
   i) Anterior webs usually require low power (e.g., 4 to 6 W) for vaporization and hemostasis.
   ii) Lysis of the web should extend to the thyroid cartilage but should not dissect through it.
i) When "cold" microsurgical instruments are used:
   i) Hemostasis is achieved with a topical 1:10,000 adrenaline solution applied with a 0.5 × 0.5-inch neurosurgical pledget.
      (1) It is important to remember that adrenaline will be absorbed into the circulation immediately.
      (2) The recommended maximal dosage should be observed, and anesthesia personnel should be notified before applying the solution.
   ii) The web is transected with upbiting microscissors, and granulation tissue is removed with microcup forceps.
j) Regardless of the mode of lysis of the web, topical application of mitomycin C (0.4 mg/mL solution for 4 minutes) should reduce scarring and may decrease the probability of recurrence.
k) If the surgeon decides to place a stent after lysis of an anterior glottic web:
   i) Stent is endoscopically secured in place with transcutaneous monofilament sutures (Fig. 10.12).
   ii) Stent is left in place for 10 to 14 days, after which the patient is taken back to the operating room for removal of the stent and inspection of the surgical site.
l) Webs thicker than 1 cm, those involving the subglottis, and those associated with PGS may require a laryngofissure approach (see Chapter 69).
   i) A silicone Montgomery umbrella is left in place after the web is divided (Fig. 10.13).
      (1) This prosthetic device remains in place for 2 to 4 weeks.
      (2) The optimal time for removal is when the anterior one-third of the true vocal cords shows complete epithelialization, which may be ascertained by flexible laryngoscopy.
      (3) Removal of the stent requires opening the incision with the patient under general anesthesia in the operating suite.
m) Loss of the anterior segment of the thyroid cartilage as a result of trauma or oncologic surgery requires reconstruction of the cartilaginous support.
   i) The preferred method for such reconstruction is the epiglottopexy described by Kambic et al.
   ii) This procedure involves a transcervical approach, similar to the one described for a laryngofissure (see Chapter 69).

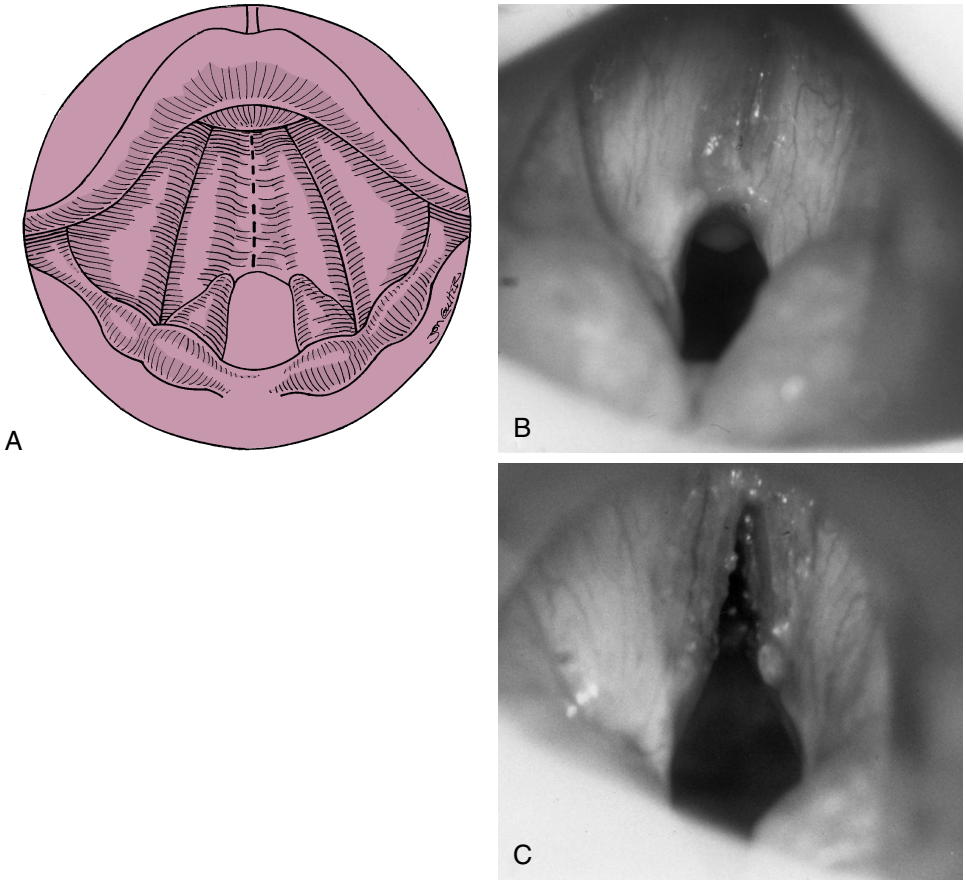

Fig. 10.11. A, Anterior glottic web involving the vocal folds. The *dashed line* indicates the ideal level for lysis of the web to re-create the free edge of both true vocal cords. **B,** Intraoperative view of an anterior glottic web. **C,** Intraoperative view after division of the web with a CO_2 laser.

(1) When feasible, the thyroid cartilage is transected at the midline, although the midline may be difficult to establish in the presence of scarring.
   (a) In these cases the midline of the anterior commissure may be estimated through the direct laryngoscope, before the transcervical procedure is started.
   (b) However, in most cases, this point is moot, because severe scarring and loss of tissue mandate reconstruction of the entire anterior laryngeal anatomy.
(2) The thyrohyoid membrane is incised between the lesser cornua to expose the superior pre-epiglottic space.
(3) The soft tissue of the pre-epiglottic space is dissected from the anterior surface of the epiglottis.
(4) The petiole of the epiglottis is then grasped and drawn inferiorly like a window shade to facilitate lysis of the median and lateral epiglottic ligaments (Fig. 10.14A).
(5) Continuity of the lateral and superior mucosa with the base of tongue and vallecula should be preserved (see Fig. 10.14B).
(6) A Montgomery laryngeal stent is placed and secured with transcutaneous, transcervical monofilament suture.
(7) Alternatively, an Eliachar laryngeal stent may be used.
(8) The epiglottic cartilage is split by midline while preserving the mucosa of the laryngeal surface of the epiglottis to produce a sharp-angled anterior commissure (Fig. 10.15).
(9) The lateral edges of the epiglottis are sutured to the anterior edges of the thyroid ala with interrupted absorbable suture.
(10) The petiole is also sutured, usually to the superior margin of the cricothyroid membrane.
   (a) Occasionally, the petiole may be mobilized low enough to augment the anterior cricoid arch, which may be necessary if the anterior subglottic stenosis involves the cricoid cartilage.

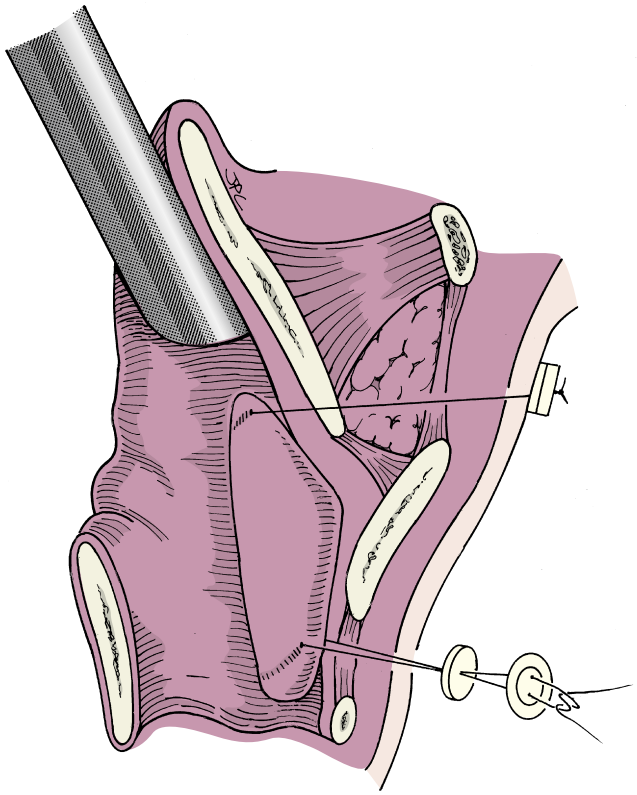

Fig. 10.12. Sagittal plane. An anterior glottis keel is inserted and secured with external monofilament (transcutaneous) sutures.

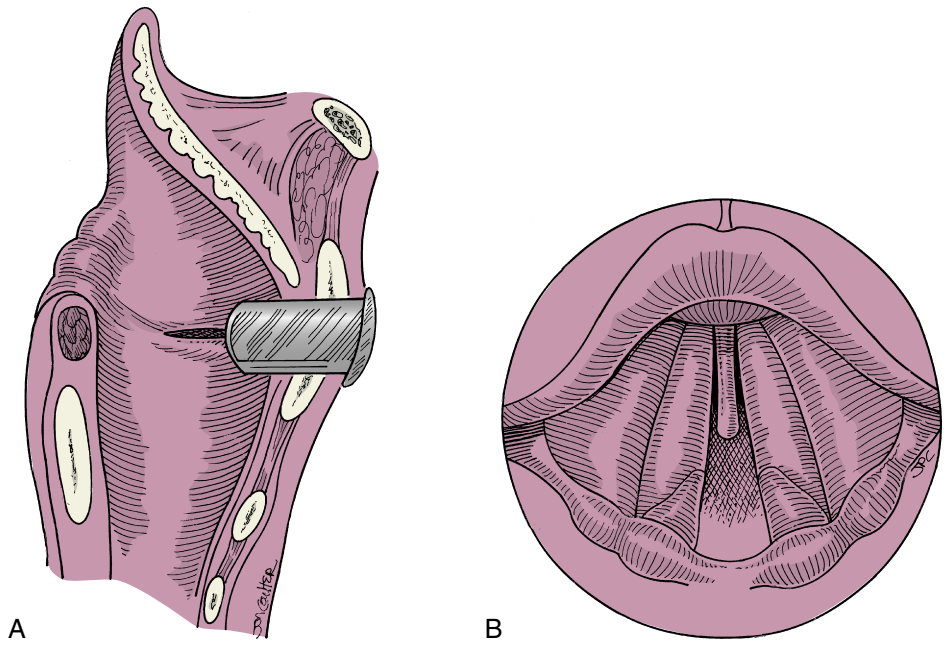

Fig. 10.13. A, Sagittal plane. Montgomery umbrella is in place after lysis of an anterior glottic web via laryngofissure. **B,** Axial plane. The anterior keel is in place.

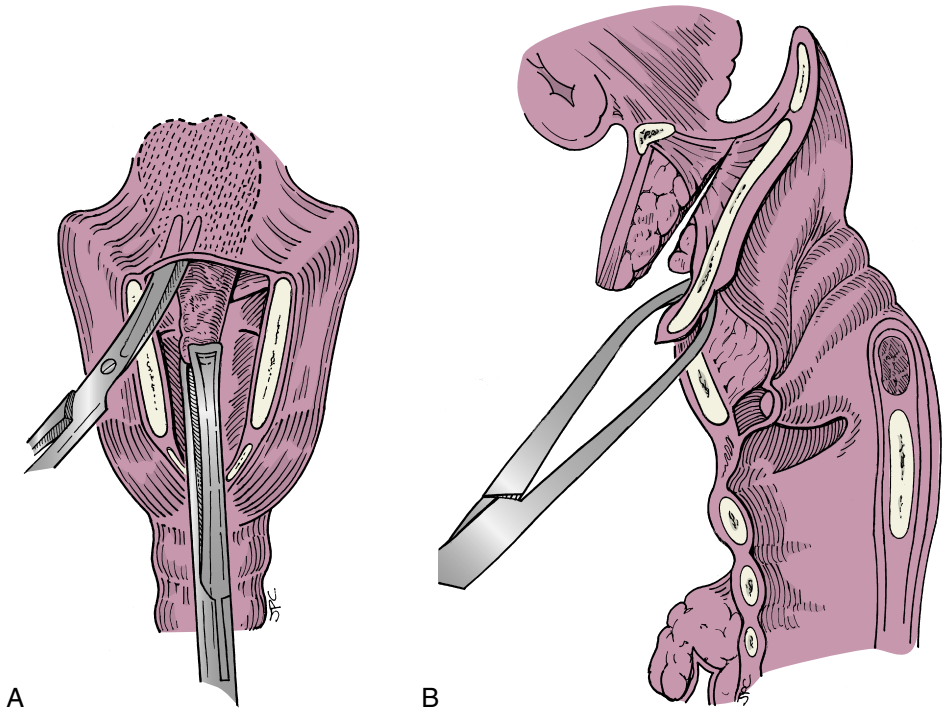

Fig. 10.14. (A) Coronal and **(B)** sagittal views. The petiole of the epiglottis is retracted inferiorly to facilitate dissection of the lingual surface of the cartilage from the surrounding soft tissue.

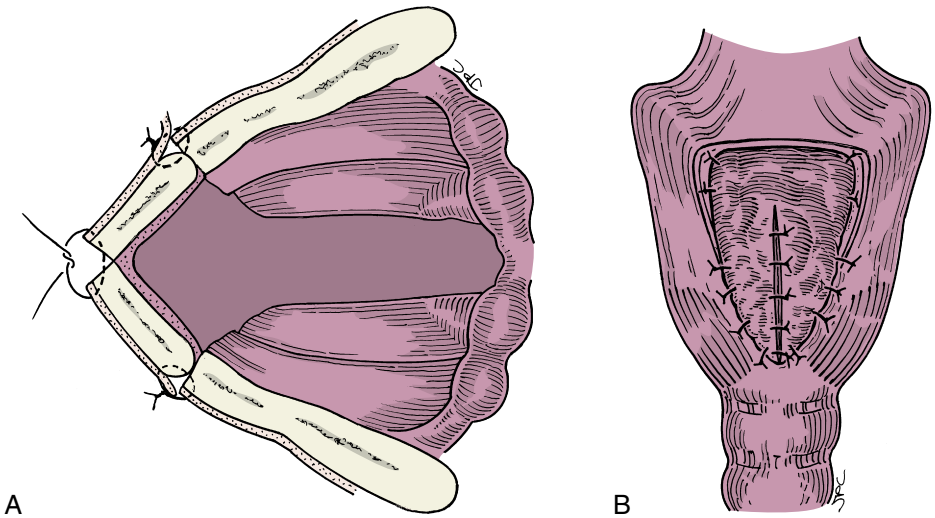

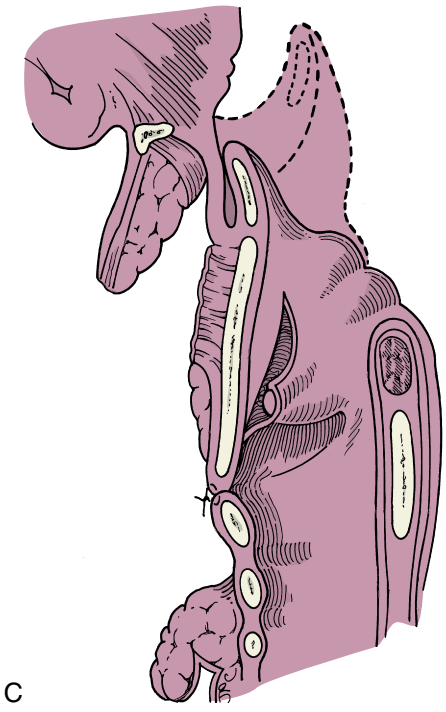

Fig. 10.15. A, Axial, **B,** coronal, and **C,** sagittal views. Reconstruction of the anterior thyroid cartilage has been completed. The epiglottic cartilage has been divided, with sparing of the muco-perichondrium on the laryngeal side of the epiglottis to re-create the V-shaped apex of the anterior commissure.

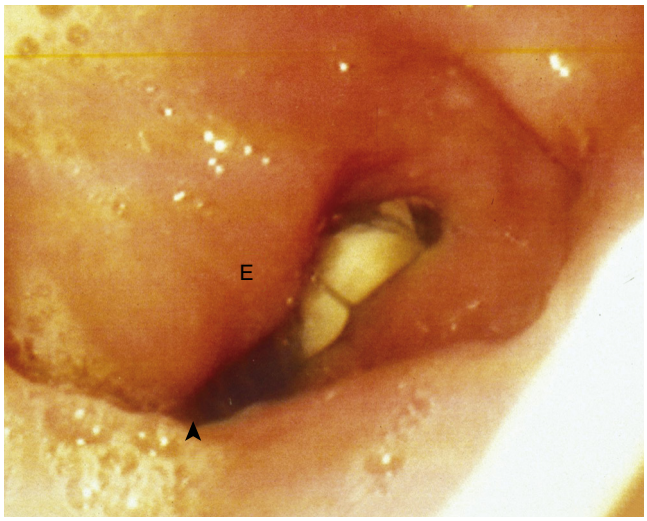

Fig. 10.16. The endolarynx after Kambic epiglottopexy for reconstruction of a glottic stenosis after right hemilaryngectomy. Notice the convex shape of the epiglottis *(E)*. The *arrowhead* indicates the anterior commissure.

(11) The strap muscles are approximated, and the wound is closed in multiple layers.
(12) A Penrose drain is left in place, and a compressive dressing is applied.

iii) This technique has the advantage of providing immediate reconstruction of the infrastructure, as well as the endolaryngeal lining, with local vascularized tissue, thereby expediting healing.
(1) Although the reconstruction is completed in one stage, the patient must be returned to the operating room for transendoscopic removal of the stent.

iv) This technique has the disadvantage of a tendency to produce a round anterior commissure, even with the described method (Fig. 10.16).

3) PGS
a) PGS is most commonly the result of interarytenoid scarring secondary to prolonged endotracheal intubation or trauma.
b) Regardless of the method or refined surgical technique, the success of the surgery depends on the degree and depth of the scarring.
c) Treatment of an interarytenoid adhesion requires transection of the scar band.
i) This is possible only if there is a posterior "port" of no scar between the scar band and posterior laryngeal mucosa.
ii) These patients have improved vocal fold motion after lysis, unless there is concurrent cricoarytenoid joint scarring.
iii) This highlights the importance of evaluating the cricoarytenoid joints before performing surgical intervention of PGS.
d) Unfortunately, severe posterior glottic scarring is common.
i) This involves scarring of the posterior commissure, often involving one or both cricoarytenoid joints.
ii) Surgery to improve their glottic airway comes at the expense of voice and swallowing ability.
iii) Treatment ranges from transverse cordotomy, medial arytenoidectomy, endoscopic total arytenoidectomy, microtrapdoor flap, or tracheotomy (see Chapter 9 for more details).
(1) Tracheostomy is the only procedure that can "bypass" the airway obstruction, leaving the patient with improved breathing and no change in voice quality.
(a) However, tracheostomy is often not a desirable option for patients.
(b) Therefore destructive endoscopic glottic airway procedures are the most common treatments for PGS.
(2) Transverse cordotomy consists of CO_2 laser transection of the posterior true vocal fold, just anterior to the vocal process.
(a) The cordotomy extends laterally to the inner table of the cricoid cartilage.
(b) A small triangle defect results from scarring of the vocal fold anteriorly and laterally.
(3) Medial arytenoidectomy is a surgical option when there is no significant posterior glottic scar, although this is uncommon in these circumstances.
(a) This creates a "half-moon" defect in the medial aspect of the arytenoid.
(b) There must be sufficient space between the posterior glottis scar and vocal process to perform this surgery.
(4) Total endoscopic arytenoidectomy is a combination of the transverse cordotomy and medial arytenoidectomy, with CO_2 laser ablation of arytenoid and muscle within those confines, extending to the inner table of the cricoid cartilage.
(5) Lastly, a microtrapdoor flap can be performed to reconstruct posterior stenosis caused by mucosal scarring.
(a) An inferiorly based flap is elevated from the interarytenoid area with the laser or, preferably, with microsurgical instruments.
(b) The submucosal scar is removed, and passive mobility of the arytenoids is tested.
(c) The flap is repositioned over the operated area to promote primary healing (Fig. 10.17).
(6) Open surgery through a laryngofissure is rarely necessary.

4) Subglottic stenosis
a) Acquired subglottic stenosis may be due to deposition of scar or malacia, or a combination of both.
b) Stenosis is characterized as thin or thick, partial or circumferential, and by the degree of stenosis.
c) The corrective procedure should strive to address the involved area while preserving the adjacent normal tissue.
d) Thin subglottic webs are amenable to endoscopic microsurgery.

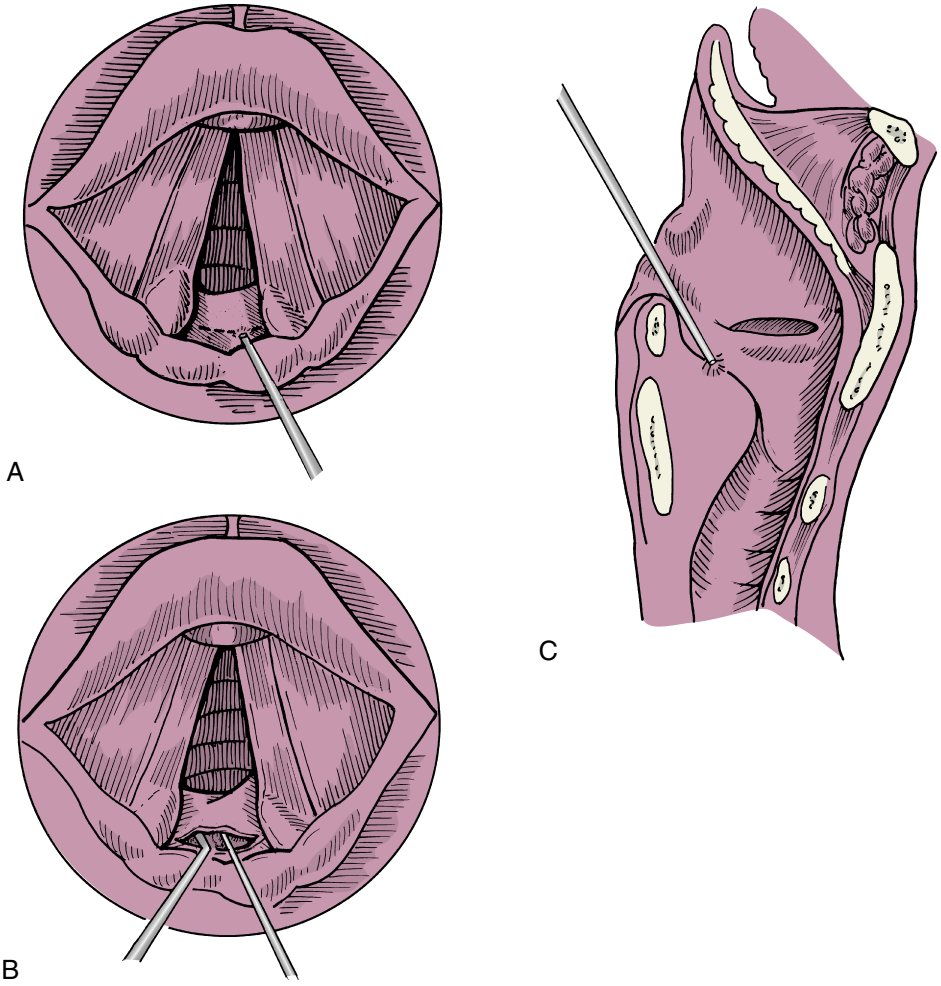

Fig. 10.17. A to **H,** Microtrapdoor flap to remove a posterior glottic web. Submucosal scar resection is completed with microsurgical instruments or laser vaporization while taking care to spare the overlying mucosa. *(From Bluestone CD, Stool SE [eds]: Atlas of Pediatric Otolaryngology. Philadelphia: WB Saunders; 1995, pp 498–499.)*

Continued

i) Jet ventilation or alternating intubation with apnea through a subglottiscope is useful to visualize the full extent of the lesion.
ii) Wedge excision with a laser or knife of the mucosal web at every quadrant or radial incisions augment the airway and preserve enough epithelium to prevent restenosis (Fig. 10.18).
iii) Balloon dilation is another treatment modality.
iv) Steroid injection is also often used because it may help to prevent restenosis and soften the stenosis that remains.
v) Application of mitomycin C is also performed (0.4 mg/mL × 4 minutes).
vi) Biopsy of the affected area is suggested at the time of the first surgery, especially if the etiology is unknown or suspicion for autoimmune or infectious causes exists.

e) When the stenosis is recurrent or resistant to endoscopic management, an external approach and cartilaginous augmentation procedure are necessary.
i) Cartilage from the nasal septum, thyroid ala, or rib may be harvested for use as a free graft.
ii) We prefer the latter because it is abundant, thicker, and easier to carve.
iii) A horizontal incision is performed in a skin crease over the cricoid cartilage.
iv) Subplatysmal flaps are elevated to expose the thyroid notch and upper trachea.
v) The strap muscles are separated in the midline and retracted to expose the laryngotracheal complex.
vi) A midline cricoidotomy is performed and extended into the upper two tracheal rings.
vii) The cricothyroid membrane is opened horizontally to facilitate lateral retraction of the cricoid chondrotomy segments.
viii) The mucosa is incised to expose the posterior mucosal surface of the larynx and trachea.
ix) A posterior cricoid chondrotomy is performed while preserving the integrity of the cricoarytenoid joints and postcricoid mucosa.

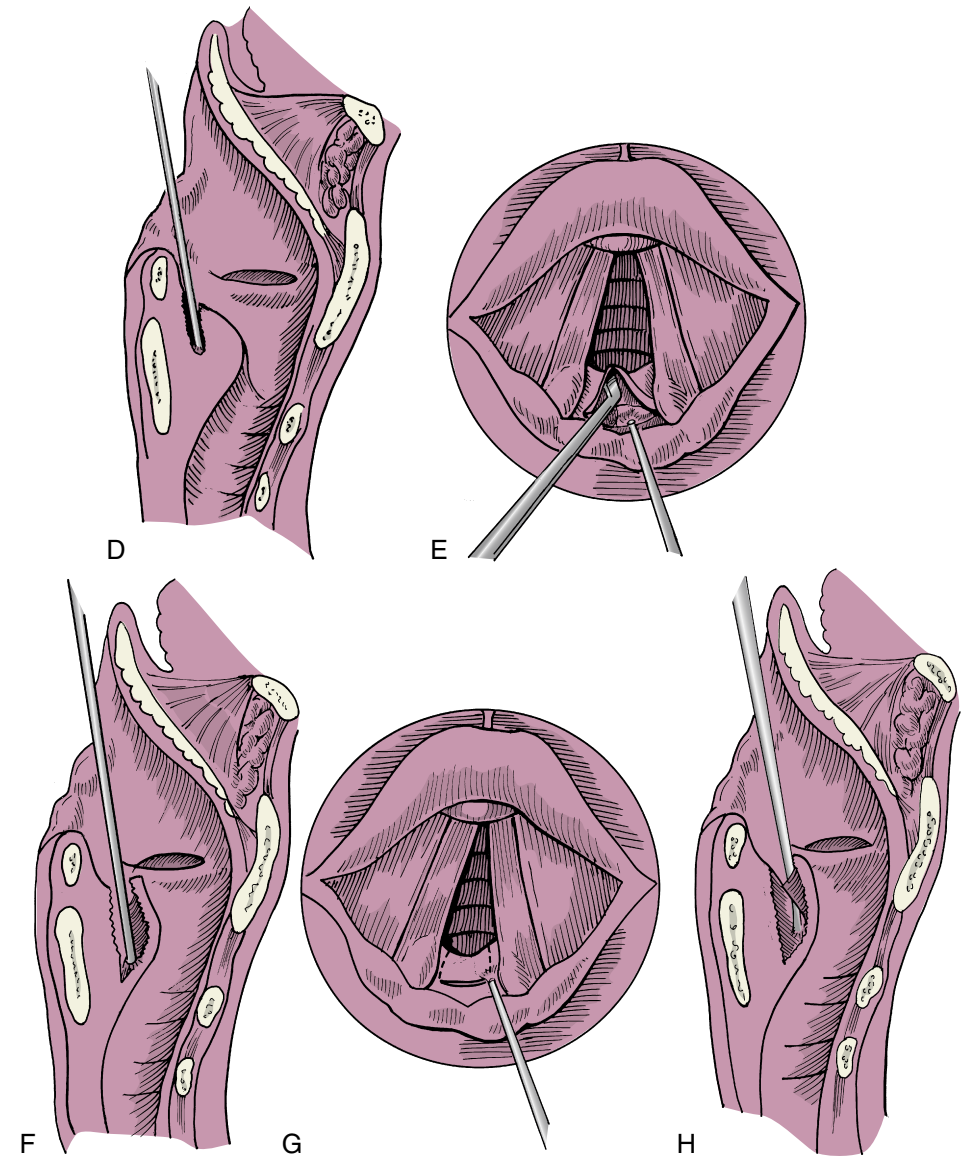

Fig. 10.17, cont'd.

x) When the posterior glottis is scarred and stenotic, submucosal excision of the scar is performed.
xi) A free cartilage graft is carved to fit the posterior cricoid area (Fig. 10.19). Kirschner wires are passed into the graft to fix it in place.
xii) The same maneuver is used anteriorly.
xiii) A rigid fixation plate may be used to fix the anterior graft in place, which has been carved in a lock-and-key fashion (Fig. 10.20).
(1) Alternatively, Kirschner wires (24 gauge) can be passed through the cartilage graft and inserted through the cartilage of the receiving site (Fig. 10.21).
(2) The ends of the wires are then bent and secured in place with 28-gauge wire (Fig. 10.22).
xiv) The strap muscles and platysma are reapproximated with absorbable suture.
xv) A Penrose drain is left in place.
xvi) The skin is closed with staples, and a compressive dressing is applied.

f) A sternocleidomastoid myoperiosteal flap, as described by Friedman and Colombo, is an alternative technique for augmentation of the anterior cricoid ring and cervical trachea. This surgical approach and exposure are similar to those already described.
i) The sternoclavicular origin of the left sternocleidomastoid muscle is exposed through the cervical incision and mobilization of subplatysmal flaps (Fig. 10.23).
ii) If necessary (e.g., in a patient with a long neck), a second horizontal incision is performed closer to the clavicle.
iii) The sternal head is transected.

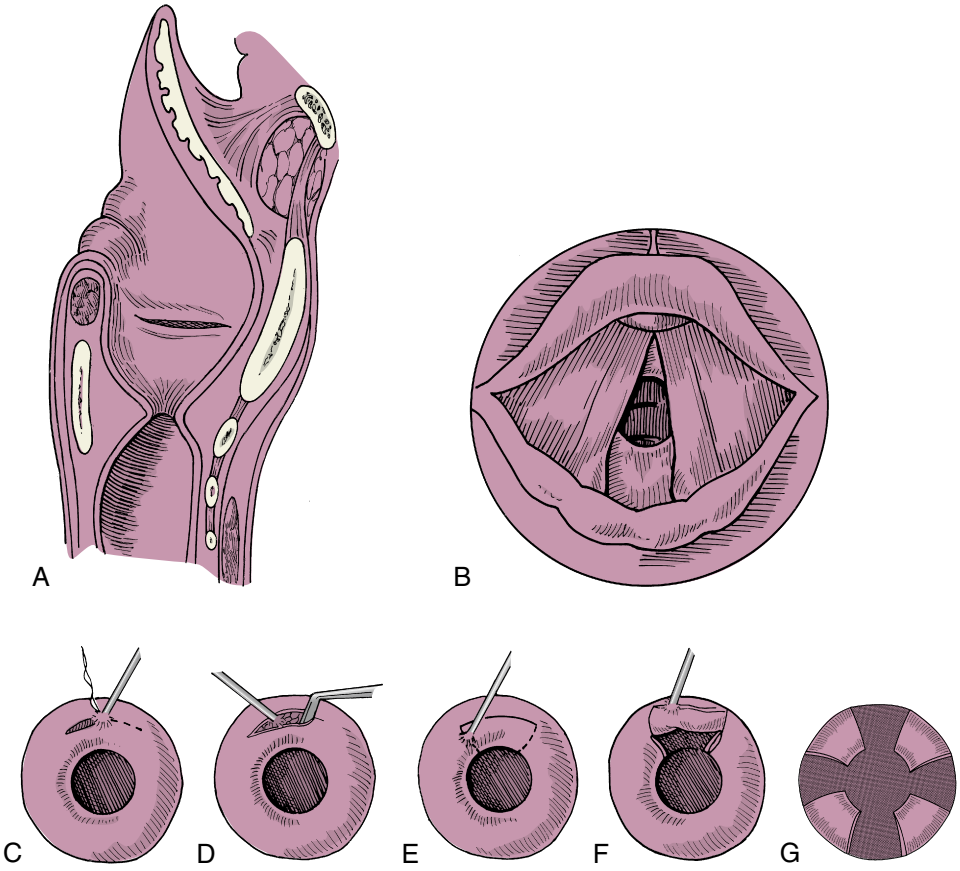

Fig. 10.18. A, Sagittal view of circumferential subglottic stenosis. **B** to **G,** Tracheal lumen after laser excision of a wedge-shaped area at four quadrants. It is not essential to excise four wedges; two or three wedges may be adequate for some patients. *(**B** to **F,** From Bluestone CD, Stool SE [eds]: Atlas of Pediatric Otolaryngology. Philadelphia: WB Saunders; 1995, p 509.)*

iv) The clavicular periosteum around the clavicular insertion is incised and elevated as a myoperiosteal flap (Fig. 10.24).
v) This flap is mobilized into the defect until tension-free closure can be achieved (Fig. 10.25).
vi) The flap is then sutured to the anterior edges of the cricoid and trachea over a Montgomery T-tube (Figs. 10.26 and 10.27).
vii) A Penrose drain is left in place.
viii) The wound is closed in multiple layers, and a compressive dressing is applied.

9. Common errors in technique
   a. Airway management
      1) Requires constant communication with the anesthesia team
      2) All possibilities of airway management are discussed and prepared for, including emergency tracheostomy.
      3) Avoids "loss of the airway"
   b. Laser use
      1) The surgeon needs to feel comfortable with using the laser, appropriate settings, laser safety precautions, and what to do in case of laser airway fire.
   c. Laryngeal exposure
      1) Optimal laryngeal exposure allows for improved understanding of the extent of stenosis and how much needs to be done.
         a) Use largest laryngoscope possible to accommodate the patient's anatomy.
         b) Use of angled telescopes provides a "three-dimensional" view of stenosis and surgical field.
   d. Common errors in technique
      1) Inadequate exposure of the laryngotracheal complex
      2) Inadequate mobilization into the cervical area
      3) Too much tension at the anastomosis
      4) Excessive use of electrocautery over the tracheal surface leading to thermal injury and malacia

POSTOPERATIVE PERIOD

1. Postoperative management
   a. Postoperative management of patients depends upon the type of surgery and the presence of a tracheostomy.
      1) If the patient has a pre-existing mature tracheostomy tube, outpatient surgery is a possibility.
      2) However, for all other patients undergoing airway surgery, close observation in an intermediate or intensive care unit is necessary.
      3) Patients with newly placed tracheostomy tubes will also require tracheostomy care and teaching.
   b. The head of the bed is kept elevated 30 degrees to diminish the possibility of gastric reflux and to facilitate ventilation.
   c. Humidified air is administered by face or tracheotomy mask, as appropriate.
   d. Delivery of oxygen through hoses with a T-attachment of the tracheostomy tube is not recommended because they exert traction on the tracheostomy tube and elicit pain and cough.
      1) Furthermore, such traction may break the peristomal sutures and lead to gross contamination of the wound with tracheal secretions.

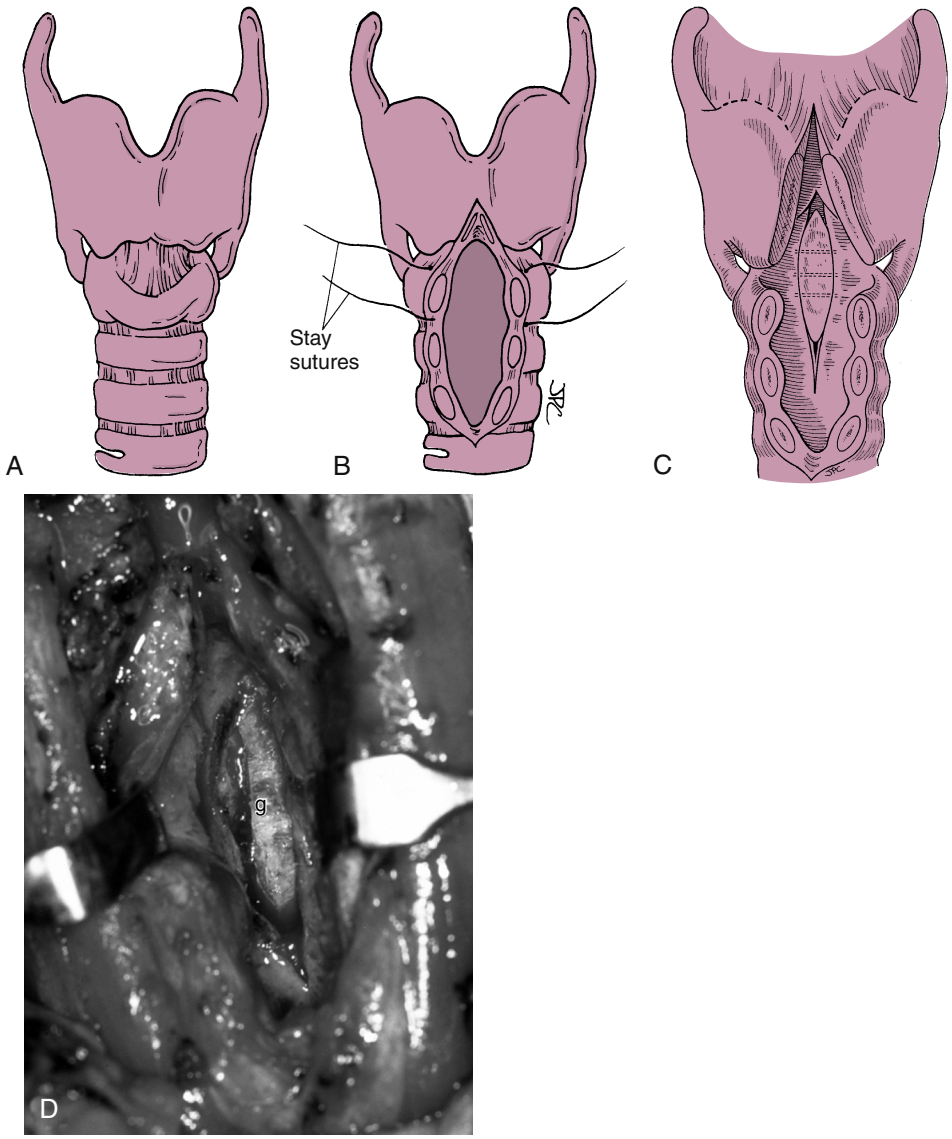

Fig. 10.19. A to **D,** Free cartilage graft (spindle shaped) to the posterior cricoid. The graft *(g)* is secured with Kirschner wires. *(**A** and **B**, From Bluestone CD, Stool SE [eds]: Atlas of Pediatric Otolaryngology. Philadelphia: WB Saunders; 1995, p 467.)*

e. If the patient requires an open surgical repair, he or she should not be fed for the first 24 hours after surgery to diminish the possibility of nausea and vomiting, which may stress the endolaryngeal repair.
   1) A nasogastric tube for suctioning of stomach contents during the initial postoperative period and subsequent feeding can be considered, but it is associated with its own trauma and induces gastroesophageal reflux.
f. If a newly placed tracheostomy tube was necessary for airway maintenance, it may be downsized or changed to a cuffless tube no less than 72 hours after the procedure.
   1) This allows the formation of a tract, which greatly facilitates insertion of the next tube.
g. When an external approach was used, such as a laryngofissure, it is prudent to keep a cuffed tracheostomy tube in place for 5 to 7 days to prevent massive subcutaneous emphysema and contamination of the cervical wounds when air and secretions are insufflated through the endolaryngeal wound.
h. The tracheostomy tube should not be removed until the patient can breathe with the tracheotomy tube capped and still able to complete the physical activities he or she wishes to perform without dyspnea or restriction of activities for at least 24 hours.
i. Flexible laryngoscopy is an invaluable tool to ascertain the adequacy of the airway, as well as to monitor the healing process.
j. Patients who need a long-term tracheotomy tube or T-tube stent should be trained in the care of these artificial airways.
k. The patient's family must be aware of the possible complications and be proficient in emergency maneuvers, such as removal and reinsertion of the tracheostomy tube. In the case of T-tube stents, the companions should be taught how to remove the stent and insert a tracheostomy tube.

2. Complications
   a. Airway
      - The most dreaded complication after any kind of laryngeal surgery is loss of the airway.

- Airway compromise may ensue secondary to edema or hematoma within the soft tissues of the larynx, as in patients managed with endolaryngeal surgery without a tracheostomy, or may be due to plugging or accidental decannulation of the tracheostomy tube or T-tube.

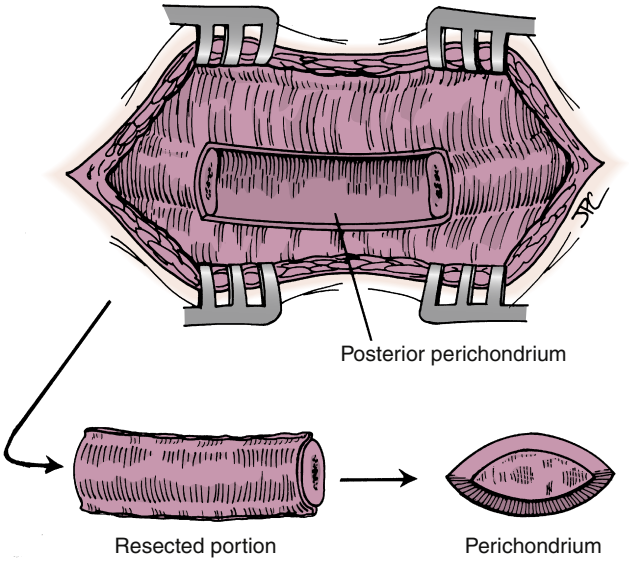

Fig. 10.20. Rib cartilage is carved to fit the anterior chondrotomy, as described by Zalzal and Cotton. *(From Bluestone CD, Stool SE [eds]: Atlas of Pediatric Otolaryngology. Philadelphia: WB Saunders; 1995, p 470.)*

  - The old dictum that prevention is the best treatment is most applicable during laryngeal surgery. Preventive measures have been addressed throughout this chapter.
- Patients in whom airway compromise develops after undergoing laryngeal surgery without a tracheostomy will benefit from humidified oxygen and should be provided with a surgical airway.
  - A tracheostomy is preferable to a cricothyroidotomy because the latter may produce more subglottic scar tissue and possibly complicate future management of the primary stenosis.
    - Nevertheless, if an emergency airway is needed, cricothyroidotomy is the most expedient procedure.
  - A mixture of 70% helium and 30% oxygen (heliox) may be used as a temporary measure.
    - Helium is less dense than nitrogen and flows with less friction and turbulence, thus diminishing the respiratory workload.
  - Select patients can be managed with corticosteroids, racemic epinephrine, and humidified oxygen or heliox, under close monitoring, until the swelling resolves.
- A plugged tracheostomy tube is managed by removing the inner cannula, which may produce a patent outer cannula, by displacing or perforating the plug with a suction catheter or, ultimately, by removing and replacing the tracheostomy tube.
- During the early postoperative period, reinsertion of the tracheostomy tube after accidental or therapeutic decannulation is facilitated by traction on the traction sutures (see Chapter 19 – tracheostomy chapter).

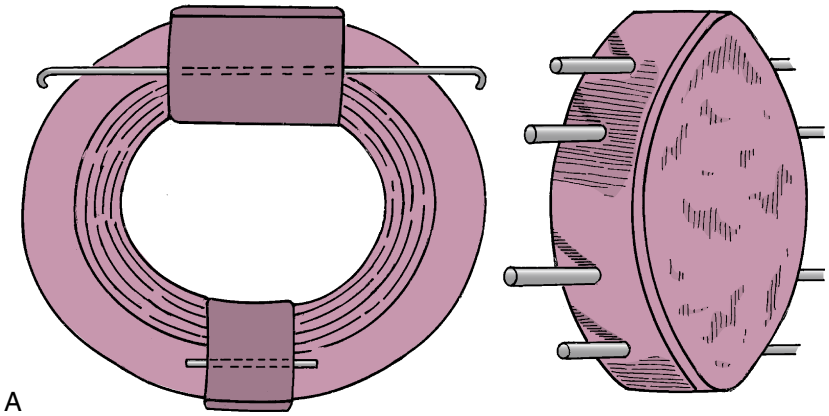



Fig. 10.21. A, Placement of wires through the free cartilage graft. An axial view of the anterior and posterior cartilage shows the graft in place. **B,** Placement of wires through the free cartilage graft.

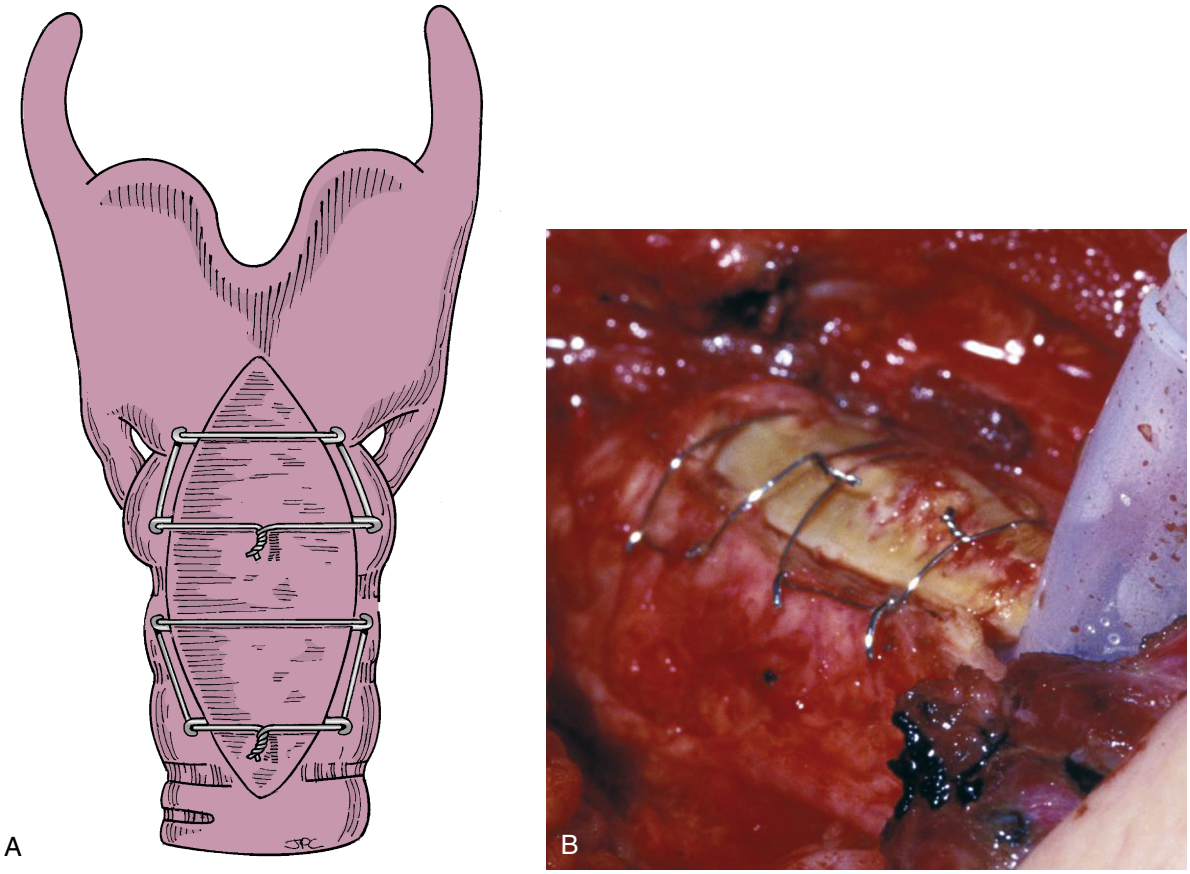

Fig. 10.22. A, Illustration and **B,** clinical photograph demonstrating the wiring technique on a free cartilage graft to reconstruct an anterior tracheal defect.

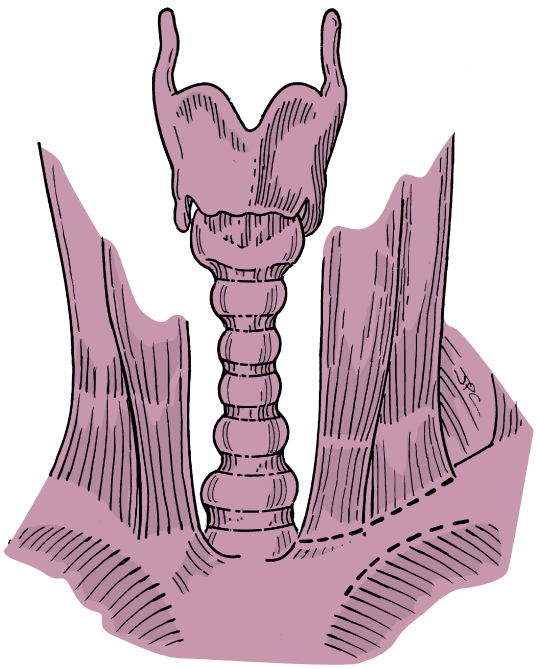

Fig. 10.23. Surgical exposure of the sternoclavicular head of the sternocleidomastoid muscle and the area of the stenosis.

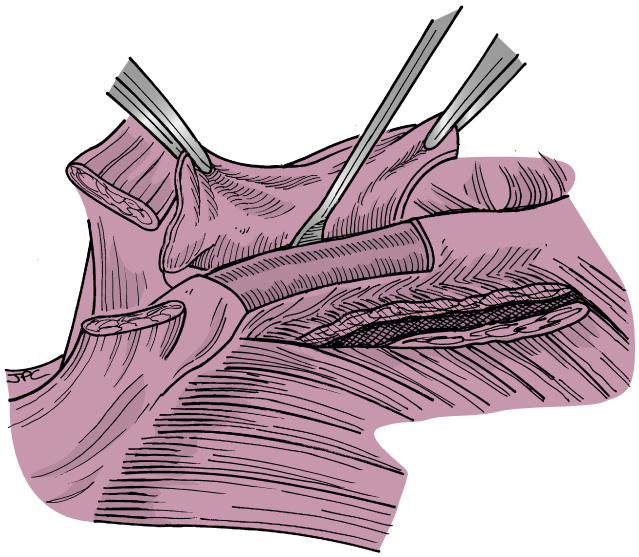

Fig. 10.24. The periosteum is elevated en bloc with the sternoclavicular head of the sternocleidomastoid muscle.

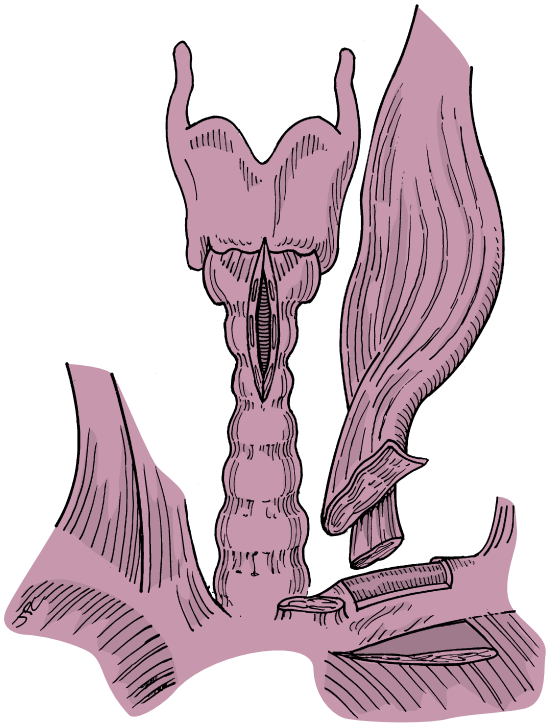

Fig. 10.25. The myoperiosteal flap is elevated. Branches of the thyrocervical trunk supplying the inferior aspect of the sternocleidomastoid muscles are usually sacrificed to enhance mobility of the flap.

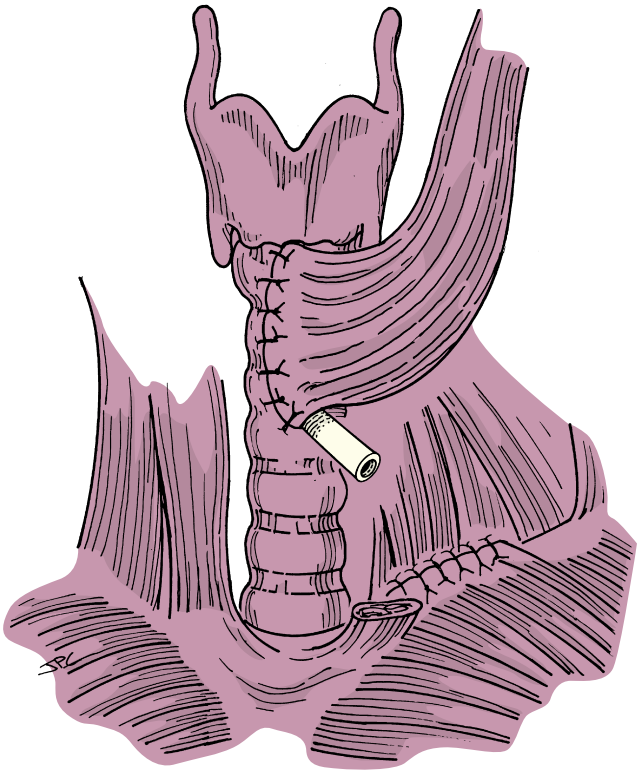

Fig. 10.27. The myoperiosteal flap has been sutured to the defect.

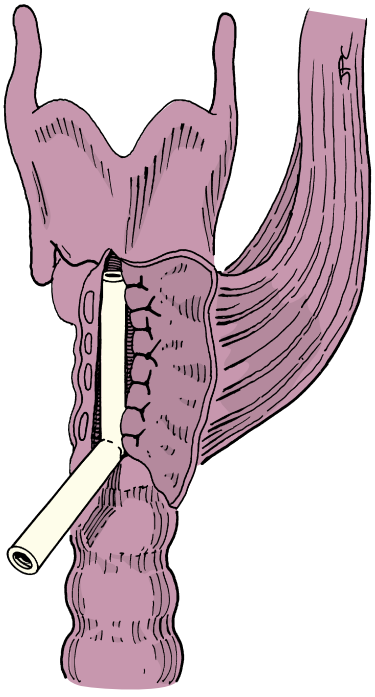

Fig. 10.26. The myoperiosteal flap is sutured to the defect. A Montgomery T-tube maintains the shape of the lumen and secures the airway.

- The stay sutures bring the tracheal window close to the skin and thus provide better visualization of the opening and prevent a false passage.
- A suction catheter or endotracheal tube introducer may be used as a guide if the traction sutures break or the patient has a very thick neck that impairs direct visualization of the tracheal window.
- If a flexible laryngoscope or bronchoscope is rapidly available, it provides direct visualization of the trachea and is a safer guide than any rubber catheter.

- Plugging of a T-tube stent with mucus deserves special consideration because it does not have the safety mechanism provided by a double cannula.
  - Even if the mucous plug can be displaced or perforated with a suction catheter, patency of the tube should be ascertained by direct examination with a flexible scope.
  - If the mucous plug cannot be removed with help of the laryngoscope, the T-tube should be removed and replaced with a tracheostomy tube, inserted as previously described.
  - The T-tube stent can be reinserted after the airway is stabilized.
    - Nevertheless, reinsertion has to be undertaken with the patient under general anesthesia and guided by visualization through a direct laryngoscope.

b. Subcutaneous emphysema

- Subcutaneous emphysema is the result of insufflation of air into the soft tissues through a laryngeal wound during exhalation.
  - The air is usually reabsorbed without consequence.
  - Nonetheless, it has to be remembered that this air may also be accompanied by secretions (i.e., contamination), so antibiotics are recommended to prevent wound infection.
- Subcutaneous emphysema may be massive and associated with pneumomediastinum.

- In infants, this may produce respiratory compromise, whereas in adults, subcutaneous emphysema, although unsightly, has no adverse consequences.

c. Infection
- Adequate wound drainage, via soft rubber drain or suction drain, is of utmost importance for the prevention of infection after open surgical procedures.
  - The drain should be kept in place until the tissue flaps have healed sufficiently to prevent accumulation of fluid.
- When postoperative wound infections occur, it may or may not be associated with a laryngocutaneous fistula.
  - The most significant factor influencing the outcome of any wound infection is adequate wound drainage.
  - If the rubber drain is still in place, it should be retained until there is minimal or no drainage.
  - Systemic antibiotics with a wide spectrum against oral flora (e.g., clindamycin) are administered to prevent sepsis.
- Bacterial tracheitis must be considered when patients exhibit increased productive cough or pain after surgery.
  - Diagnosis is confirmed with tracheoscopy.
  - Treatment options include nebulized antibiotics with or without steroid (e.g., ciprofloxacin/dexamethasone) and/or oral antibiotic to cover common oral flora, including methicillin-resistant *Staphylococcus aureus* (MRSA) (e.g., clindamycin).
    - If severe, close monitoring with in-patient treatment with intravenous clindamycin or ceftriaxone is needed.

d. Laser injury
- Adherence to the laser safety precautions outlined earlier in this chapter is paramount in preventing laser-related injuries.
- Airway fire is the most catastrophic complication, and multiple actions occur simultaneously:
  - Anesthesia gases are stopped, removing the oxygen source.
  - Endotracheal tube is removed.
  - A bulb syringe filled with saline solution should always be available during all laser cases and used to extinguish the fire.
  - Bronchoscopy is then performed to access tracheobronchial injury.
  - The patient is re-intubated and admitted to the intensive care unit for close observation.

e. Equipment malfunction
- Dilating balloon malfunction rarely occurs but could result in prolonged complete airway obstruction. In the case of inability to deflate the balloon, removal of the syringe from the insufflation device is recommended, with manual deflation.
  - Only as a last resort, the balloon can be punctured, allowing its deflation and removal.
    - If this is needed, the procedure should be followed by a bronchoscopy to confirm no portion of the balloon remains within the airway.
- There are different types of balloons, compliant and noncompliant. Noncompliant balloons can exert pressures that overcome the static resistance of the cricoid cartilage.
  - With inappropriate dilation diameter, cricoid fracture can occur.
- All balloons result in some degree of mucosa tear with inflation, as do rigid dilators.
  - Appropriate diameters will maximize treatment of stenosis while minimizing extent of mucosal injury.

3. Alternative management plan
   a. Advances in technology now allow for awake, in-office steroid injections for airway stenosis, particularly supraglotttic and subglottic. Repeated steroid injections may be helpful in decreasing the rate and severity of re-stenosis. Research in this area is ongoing.

DISCUSSION

Evidence-Based Medicine Question

What is the long-term risk of a tracheostomy, and what is the best paradigm to manage airway compromise after decannulation?

Most patients do well after tracheotomy decannulation; however, at times, a patient is dyspneic. This mandates evaluation, including a complete endoscopic evaluation of the glottis, subglottis, and trachea. It is preferable to complete the examination while the patient is awake, thus providing a "dynamic airway evaluation." This allows the surgeon to observe the motion of the tracheal walls during activities such as deep breathing and coughing, which may lead to tracheal collapse and worsen breathing.

A proper glottal airway should have been confirmed before capping trial and decannulation. This is easily achieved by flexible nasolaryngoscopy in the office. Visualization through the tracheostoma (if still present) is performed, both looking retrograde to the infraglottic region and caudally to the trachea. In the office, visualization of the area between the glottis and subglottis is most challenging. This is critical because granulation tissue is one of the most common causes of airway obstruction in this area. If this tissue is obstructing the airway, the treatment is to remove or cauterize the granulation tissue or recannulate with a tracheostomy tube and, if necessary, with subsequent treatment in the operating suite.

To best assess whether the tracheostomy itself has resulted in tracheal stenosis or tracheomalacia ("A-frame deformity"), one should perform a flexible bronchoscopy either in the office or in the operating suite. CT imaging is also helpful to ascertain whether the "stenosis" seen on endoscopy is due to thickening of the tracheal cartilage/mucosa (i.e., scar) or tracheomalacia. Imaging will provide more accurate information about the length of stenosis.

Tracheal stenosis presents as collapse or thickening of the cartilage and/or mucosa, which may occur after cuff overinflation with subsequent loss of capillary perfusion and tracheal cartilage sclerosis. This may be treated initially endoscopically as described in this chapter but may eventually require resection.

Tracheomalacia is more common than true tracheal stenosis after tracheostomy. It is the result of loss of the anterior tracheal wall through which the tracheotomy tube was placed, resulting in an A-frame deformity if the stenosis is at the level of the stoma. If the obstruction is distal, then it is more likely related to cuff overinflation and subsequent loss of capillary perfusion and thus cartilage necrosis/malacia. On imaging, the tracheal walls may appear to be of normal caliber. Treatment is challenging because endoscopic resection may not correct the problem, if the problem is related to weakness rather than the thickness of the wall. These patients may be treated with a tracheal T-tube, if they are amenable to having a stoma. If this is not feasible, then an open resection and anastomosis are usually required. Of note, there are no data showing that open or percutaneous tracheostomy has differing rates of tracheomalacia. Anecdotally, the incidence of tracheomalacia seems to be rising, but this may be due to more patients surviving their acute initial illness.

Editorial Comment

The management of laryngeal stenosis is complex and will depend on the presence and severity of symptoms, needs of the patient, age, and sites affected, among many other factors. Therefore its treatment ranges from observation, to dilatation (select cases of thin congenital webs), to endoscopic microsurgical techniques, or to major laryngeal reconstruction.

Jonas T. Johnson

Access the review questions and additional sources list online at http://www.expertconsult.com

REFERENCES

1. Olson NR. Wound healing by primary intention in the larynx. Otolaryngol Clin North Am 1979;12:735–40.
2. Toohill RJ, Duncavage JA, Grossman TW. Wound healing in the larynx. Otolaryngol Clin North Am 1984;17:429–36.
3. Snow JB. Diagnosis and therapy for acute laryngeal and tracheal trauma. Otolaryngol Clin North Am 1984;17:101–6.
4. Caldarelli DD, Friedberg SA, Harris AA. Medical and surgical aspects of the granulomatous diseases of the larynx. Otolaryngol Clin North Am 1979;12:767–81.
5. Alaani A, Hogg RP, Drake Lee AB. Wegener's granulomatosis and subglottic stenosis: management of the airway. J Otolaryngol Otol 2004;118:786–90.
6. Minni A, Gallo A, Croce A, et al. Leroux-Robert-Huet laryngectomy for supraglottic stenosis. Op Tech Otolaryngol Head Neck Surg 1992;3:194–8.
7. Kambic V, Radsel Z, Smid L. Laryngeal reconstruction with epiglottis after vertical hemilaryngectomy. J Laryngol Otol 1977;9:467–73.
8. Dennis DP, Kashima H. Carbon dioxide laser posterior cordectomy for treatment of bilateral vocal cord paralysis. Ann Otol Rhinol Laryngol 1989;98:930–4.
9. Crumley RL. Endoscopic laser medial arytenoidectomy for airway management in bilateral laryngeal paralysis. Ann Otol Rhinol Laryngol 1993;102:81–5.
10. Ossoff RH, Sisson GA, Duncavage JA, et al. Endoscopic laser arytenoidectomy for the treatment of bilateral vocal cord paralysis. Laryngoscope 1984;94:1293–7.

REVIEW QUESTIONS

1. Acquired laryngeal stenosis may result from
   a. External or iatrogenic trauma
   b. Systemic diseases
   c. Infections
   d. Neoplasms
   e. All of the above

2. The area of the larynx most susceptible to stenosis is
   a. Epiglottis
   b. False vocal folds
   c. Glottis
   d. Subglottis
   e. a and b

3. Patients with laryngeal stenosis may present with
   a. Difficulty swallowing or aspiration
   b. Hoarseness
   c. Shortness of breath or dyspnea on exertion
   d. Stridor
   e. All of the above

4. Factors associated with laryngeal stenosis after intubation include
   a. Anatomic differences between the sexes
   b. Duration of intubation
   c. Endotracheal tube size
   d. Foreign body reaction to the tube
   e. Mechanical pressure and friction
   f. All of the above

5. Contraindications for laryngeal reconstruction include
   a. Current smoker
   b. Poor overall health
   c. Uncontrolled anticoagulation
   d. Uncontrolled diabetes
   e. All of the above

7. The most common complication of tracheostomy is
   a. Hematoma
   b. Loss of airway
   c. Pneumonia
   d. Tracheal stenosis
   e. Tracheoesophageal fistula

8. The management of congenital stenosis includes
   a. Observation
   b. Reconstructive surgery
   c. Tracheostomy
   d. b and c
   e. All of the above

ADDITIONAL SOURCES

Alonso WA. Surgical management and complications of acute laryngotracheal disruption. Otolaryngol Clin North Am 1979;12:453–60.

Clement P, Hans S, de Mones E, et al. Dilatation for assisted ventilation-induced laryngotracheal stenosis. Laryngoscope 2005;115:1595–8.

Dedo HH, Sooy CD. Endoscopic laser repair of posterior glottic, subglottic and tracheal stenosis by division of micro-trapdoor flap. Laryngoscope 1984;94:445–50.

Gaynor EB. Gastroesophageal reflux as an etiologic factor in laryngeal complications of intubation. Laryngoscope 1988;98:972–9.

Hawkins DB, Luxford MW. Laryngeal stenosis from endotracheal intubation: a review of 58 cases. Ann Otol 1980;80:454–8.

Lakhal K, Delplace X, Cottier J, et al. The feasibility of ultrasound to assess subglottic diameter. Anesth Analg 2007;104:611–4.

Mair EA. Caution in using subglottic stents for Wegener's granulomatosis. Laryngoscope 2004;114:2060–1. author's reply 2061.

McCaffrey TV. Management of laryngotracheal stenosis on the basis of site and severity. Otolaryngol Head Neck Surg 1993;109:468–73.

Montgomery WW, Gamble JE. Anterior glottic stenosis: experimental and clinical management. Arch Otolaryngol 1970;92:560–7.

Morris LG, Zoumalan RA, Roccaforte JD, Amin MR. Monitoring tracheal tube cuff pressures in the intensive care unit: a comparison of digital palpation and manometry. Ann Otol Rhinol Laryngol 2007;116(9):639–42.

Nordin U, Lindholm CE. The trachea and cuff-induced tracheal injury: an experimental study on causative factors and prevention. Acta Otolaryngol 1977;96(Suppl. 345):1–71.

Papsidero HJ, Pashley NRT. Acquired stenosis of the upper airway in neonates. Ann Otol 1980;89:512–4.

Parkin JL, Stevens MH, Jung AL. Acquired and congenital subglottic stenosis in the infant. Ann Otol 1976;85:573–81.

Richardson MA. Laryngeal anatomy and mechanisms of trauma. J Ear Nose Throat 1981;60:346–51.

Schuller DE. Long-term stenting for laryngotracheal stenosis. Ann Otol 1980;89:515–25.

Seegobin RD, van Hasselt GL. Endotracheal cuff pressure and tracheal mucosal blood flow: endoscopic study of effects of four large volume cuffs. Br Med 1984;288(422):965–8.

Simpson CB, James JC. The efficacy of mitomycin-C in the treatment of laryngotracheal stenosis. Laryngoscope 2006;116:1923–5.

Simpson GT, Strong MS, Healy GB, et al. Predictive factors of success or failure in the endoscopic management of laryngeal and tracheal stenosis. Ann Otol Rhinol Laryngol 1982;91:384–8.

Sisk EA, Kim TB, Schumacher R, et al. Tracheotomy in very low birth weight neonates: indications and outcomes. Laryngoscope 2006;116:928–33.

Sofferman RA, Haisch CE, Kirchner JA, Hardin NJ. The nasogastric tube syndrome. Laryngoscope 1990;100(9):962–8.

Statham MM, Sukits AL, Redfern MS, Smith LJ, Sok JC, Rosen CA. Ergonomic analysis of microlaryngoscopy. Laryngoscope 2010;120(2):297–305.

Stell PM, Maran AG, Stanley RE. Chronic laryngeal stenosis. Ann Otol Rhinol Laryngol 1985;94:108–13.

Whited RE. A retrospective study of laryngotracheal sequelae in long-term intubation. Laryngoscope 1984;94:367–77.

Whited RE. A study of endotracheal tube injury to the subglottis. Laryngoscope 1985;95:1216–9.

SECTION 3 Larynx: Oncologic Surgery

11 Transoral CO_2 Laser Microsurgery for Cancer of the Larynx

Johan Fagan

INTRODUCTION

Transoral CO_2 laser microsurgery is a well-established treatment for cancer of the larynx, particularly for T_1 or T_2 glottic cancer. Alternative treatment options include radiation therapy or hemilaryngectomy for glottic cancer and supraglottic or supracricoid laryngectomy for supraglottic cancers. The advantages of using CO_2 laser with an operating microscope include microsurgical precision, excellent intraoperative detail, and a dry surgical field. Swallowing and speech outcomes exceed that of external surgical approaches and radiation therapy. Other advantages include patient convenience, savings both on direct and hidden patient costs, reserving radiation as potential therapy for recurrence or for second primaries, and that patients who recur are more likely to have larynx preservation.

Surgeons must familiarize themselves with the laser machine, its settings and delivery system, and its tissue effects before attempting to use it clinically and should hone their skills on animal tissue and then small tumors. They must also understand the safety aspects relating to CO_2 laser surgery.[1,2]

KEY OPERATIVE LEARNING POINTS

- Surgeons without prior experience using a laser should start with simpler cases (e.g., smaller cancers of the aryepiglottic fold, supraglottis, or medial wall of the piriform fossa).
- Spot size, focus, power, and mode (super pulse [SP]/pulsed/continuous) are important to achieve the desired effects and may be altered during an operation for different tissues or to achieve coagulation, cutting, or vaporization effects.
- Check the alignment of the aiming beam with the laser beam.
- Avoid past-pointing, as this may cause laser fires. Be aware of reflection of the laser beam off of instruments and scopes, and ensure that the backstop is correctly positioned to protect the endotracheal tube.
- Apply constant traction to tissues to define dissection planes and facilitate dissection.
- Maintain a relatively slow, smooth hand-speed.
- Use Ligaclips, not diathermy, for large vessels to avoid postoperative bleeding.
- Minimize tissue injury by employing super pulse (SP) as opposed to continuous mode.
- One may have to resect structures (e.g., suprahyoid epiglottis) to improve access.
- Debulking the cancer allows one to create space within which to move tissues around.
- Distinguish the cancer from normal tissue by transecting it and checking pliability (cancer tissue is rigid) and colors of tissues (cancer chars and is brown/black when transected) (Fig. 11.1).
- Bread slice (Fig. 11.2; see also Fig. 11.1) the cancer to determine its depth and to ensure an adequate deep resection margin.
- Do not lose orientation of specimens; pin specimens to cork that is placed in formaldehyde and make a detailed drawing for the pathologist and in the patient's notes of the precise location of resected specimens.
- What constitutes an adequate resection margin is controversial and might determine whether to return a patient to the operating room for an additional resection, whether to advise close surveillance, or whether to recommend adjuvant radiation therapy. Factors include tumor site, size, function (voice and swallowing), patient fitness, extent of the initial resection (e.g., onto cartilage or carotid), not knowing precisely where the positive or close margin is located, and reliability of follow-up.
- Pathologists are reticent to do frozen sections on very small resections (e.g., T_1 glottic cancer).
- A surgeon's impression of the adequacy of a resection as seen through the microscope is important; one may adopt a watchful waiting approach even when the cancer is reported to be "present at the margin" with the knowledge that cells are denatured and killed at the margin by the laser.
- Follow laser safety procedures (Table 11.1).

PREOPERATIVE PERIOD

Preoperative assessment is directed at the patient's general fitness for surgery, counseling about risk factors, the ability to cope with a degree of aspiration (supraglottic cancer resections), and to determine whether the cancer is amenable to endoscopic laser resection.

History

1. History of present illness
   a. Risk factors: Smoking
   b. Pulmonary status: Aspiration, smoking
   c. Pointers to synchronous primaries
2. Past medical history
   a. Previous squamous cell carcinomas
   b. Previous radiation to head and neck
3. Medical illness
   a. Ability to deal with aspiration and dysphagia
   b. Fitness for surgery
4. Medications
   a. Anticoagulants
   b. Allergies to antibiotics
5. Mental and social status
   a. Ability to overcome challenges related to speech and swallowing
   b. Ability to give informed consent
   c. Employment and hobbies: May be affected by speech or swallowing impairment

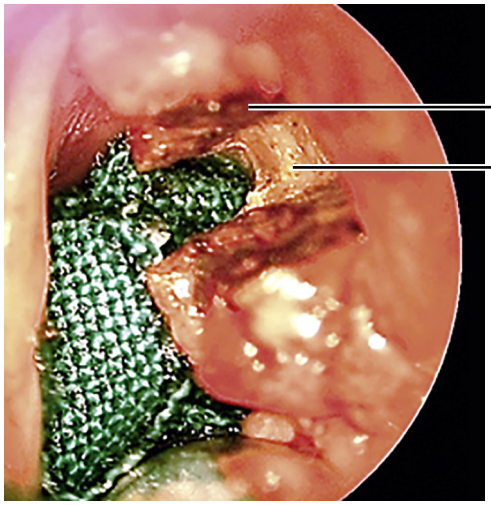

Fig. 11.1. Transected cancer of vocal cord; note clear demarcation between dark brown transected cancer and pale-colored normal tissue of paraglottic space. *(With permission from Fagan JJ, Steiner W: Transoral CO_2 laser microsurgery for cancers and other pathology of the upper aerodigestive tract. Available at https://vula.uct.ac.za/access/content/group/ba5fb1bd-be95-48e5-81be-586fbaeba29d/CO2%20laser%20transoral%20microsurgery%20_TLM_.pdf)*

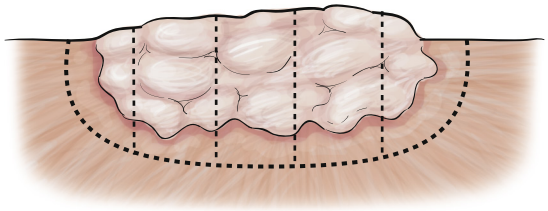

Fig. 11.2. Bread slicing the cancer. *(With permission from Fagan JJ, Steiner W: Transoral CO_2 laser microsurgery for cancers and other pathology of the upper aerodigestive tract. Available at https://vula.uct.ac.za/access/content/group/ba5fb1bd-be95-48e5-81be-586fbaeba29d/CO2%20laser%20transoral%20microsurgery%20_TLM_.pdf)*

Physical Examination

1. Primary cancer
   a. Extension to subglottis, pyriform fossa, pre-epiglottic space, base of tongue
   b. Invasion of thyroid cartilage
   c. Cervical metastases
2. General health
   a. Cardiovascular
   b. Respiratory
   c. Mental

Imaging

1. Chest radiograph
   a. Metastases
   b. Pulmonary and cardiac status
2. CT scan (selected cases only)
   a. Thyroid cartilage invasion
   b. Pre-epiglottic space invasion
   c. Through cricothyroid membrane
3. MRI (selected cases only)
   a. Complements CT scan

TABLE 11.1 Laser Safety Precautions and Management of Laser Fires

Safety Precautions (Surgical)—Develop a Check List Which Includes

- Place laser warning signs outside the operating room.
- Cover windows and securely close doors while the laser is "on" or in "standby" mode.
- Personnel and patients must use eye protection specific for CO_2 laser; it should also be available at entrances to the room; standard prescription eyeglasses are sufficient for CO_2 laser; side-guards are recommended.
- Tape the patient's eyes shut and cover them with moist pads.
- Do not use alcohol or flammable cleaning prep solutions in the operating room.
- Use flame retardant materials and drapes.
- Keep an open container filled with water or saline immediately available to douse a laser fire.
- Place moistened swabs/sponges adjacent to the path of the laser beam to protect surrounding tissues and structures.
- Minimize the possibility of a "blow-torch effect" by carefully protecting endotracheal tubes with wet cloth or neuro patties.
- The locking key to laser machine should be accessible only to persons trained in the use of laser; it should not be stored in or on the laser machine but kept in secure location; some lasers have electronic keypads.
- Keep the laser turned off or in "standby" mode unless in use.
- Instruments should have brushed, beaded, or sand-blasted surfaces to prevent reflection of the laser beam.

Safety Precautions (Anesthetic)

- "Nonflammable" endotracheal tubes may be used. (All tubes are flammable.)
- Fill the cuff of the endotracheal tube with saline colored with methylene blue.
- Maintain inspired oxygen (FiO_2) as low as clinically feasible (<30% FiO_2).
- Wait a few minutes for the oxygen concentration in the airways to drop before approving activation of the laser.
- Avoid nitrous oxide if possible.

Laser Airway Fire

- Turn off laser at emergency switch.
- Turn off all anesthetic gases.
- Remove swabs and flammable materials from the airway.
- Immediately remove the endotracheal tube.
- Pour saline into the airway.

With permission from Apfelbaum JL, Caplan RA, Barker SJ, et al: Practice advisory for the prevention and management of operating room fires: an updated report by the American Society of Anesthesiologists Task Force on Operating Room Fires. Anesthesiology 118(2):271-290, 2013.

Indications

- Biopsy and debulking of cancer causing airway obstruction
- Biopsy cancer located deep in ventricle or false vocal cord by cutting through false vocal cord
- Resect cancer of the larynx
- Treat sequelae of CO_2 laser or radiation (e.g., laryngeal stenosis, edema, glottic web).

Contraindications

1. Patient factors
   a. Medically unfit
   b. Inability to give informed consent
   c. Inability to overcome challenges relating to speech and swallowing
2. Tumor factors
   a. Unresectable (e.g., invading thyroid cartilage)
   b. Distant metastases
   c. Unacceptable morbidity

3. Surgical factors
   a. Inadequate expertise
   b. Inadequate surgical access

Preoperative Preparation

1. Evaluations by
   a. Surgeon
   b. Anesthesiology (if airway is compromised)
   c. Speech and swallowing therapist
2. Discontinue anticoagulation drugs (except for minor resections, e.g., T_1 glottic cancers).

OPERATIVE PERIOD

Anesthesia

The surgeon and anesthesiologist must agree on how to maintain an airway for the specific patient. The principal challenges are to use an endotracheal tube that permits the surgeon to work in the confined space of the larynx and to eliminate the risk of laser fires.

- Airway options
  - Endotracheal intubation (nasal or oral)
  - Intermittent jet ventilation
  - Intermittent extubation with lasering during apneic intervals
  - Open airway
  - Spontaneous breathing with anesthetic gases administered through the suction port of the laryngoscope
  - Intravenous anesthesia
  - Tracheostomy
- Endotracheal tube: All tubes are flammable; therefore the problem is not the type of tube but perforating the tube when the O_2 concentration in the tube is too high. I use a regular plastic tube but protect it with a strip of wet cloth (Fig. 11.3) or with neuro patties. The cuff is filled with saline to flood the airway if the cuff is punctured.
- Avoid nitrous oxide if possible.
- Maintain inspired oxygen FiO_2 less than 30%.

Positioning

- Position the anesthetic machine at the patient's feet to create space at the patient's head.
- Position the patient supine with neck extended.
- Insert a gum guard to protect the upper teeth.

Perioperative Antibiotic Prophylaxis

- No antibiotics are necessary.

Monitoring

- Implement routine anesthesia monitoring.
- Maintain FiO_2 at less than 30%.

Instruments and Equipment to Have Available (Fig. 11.4)

Adequate exposure of the cancer is critical; hence a variety of laryngoscopes and pharyngoscopes with integrated suction channels to remove smoke is essential. Instruments must have mat or black surfaces to prevent reflection of the laser. Two suction systems are required, one attached to the laryngoscope to extract smoke from the surgical field and the other attached to the handheld suction tube.

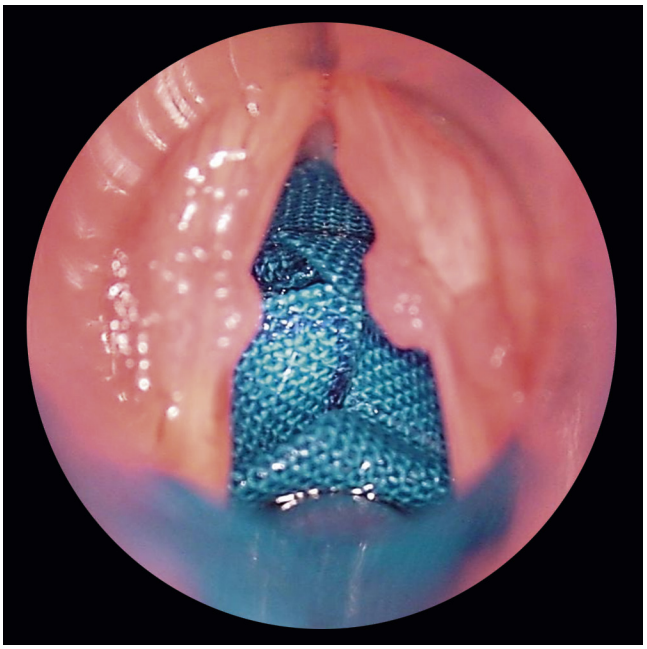

Fig. 11.3. Tube protected by strip of wet cloth. *(With permission from Fagan JJ, Steiner W: Transoral CO_2 laser microsurgery for cancers and other pathology of the upper aerodigestive tract. Available at https://vula.uct.ac.za/access/content/group/ba5fb1bd-be95-48e5-81be-586fbaeba29d/CO2%20laser%20transoral%20microsurgery%20_TLM_.pdf)*

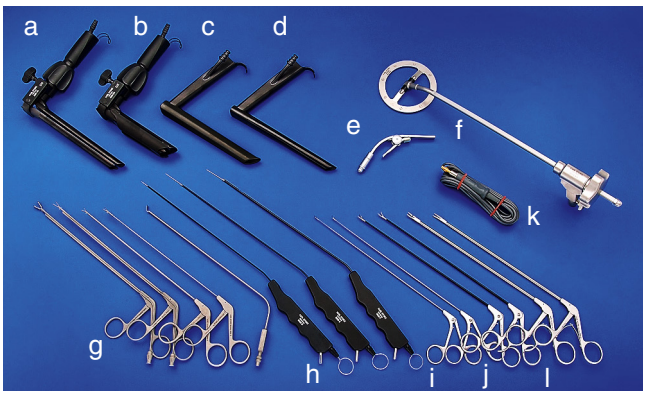

Fig. 11.4. Basic set for CO_2 laser microsurgery: Laryngopharyngoscope (a), oropharyngoscope (b), laryngoscopes (c and d), light carrier (e), laryngoscope holder (f), graspers (g), insulated suction (h), microforceps (i), coagulation forceps (j), diathermy lead (k), and Ligaclip applicators to left and right (l). *(Courtesy of Karl Storz.)*

- Operating microscope with fitting for micromanipulator
- CO_2 laser machine with micromanipulator
- Rigid 0 degree endoscope to examine the subglottis if microscopic view is inadequate
- Safety glasses
- Distending laryngopharyngoscope to access the hypopharynx and supraglottic larynx
- Large laryngoscope to access endolaryngeal, upper tracheal, and hypopharyngeal lesions
- Small laryngoscope for difficult exposures such as anterior commissure, subglottis, and upper trachea
- Light carrier
- Laryngoscope holder

- Grasping forceps (different sizes)
- Microforceps (small vocal fold lesions)
- Coagulation forceps
- Suction tubes (insulated for diathermy)
- Diathermy cable
- Ligaclip applicators (left and right)
- Adjustable supporting plate for laryngoscope holder (not essential)

Key Anatomic Landmarks (Depends on Surgical Approach)

- Endoscopic (inside-out) laryngeal anatomy
- For cancer of the glottis
  - Vocal ligament
  - Thyroarytenoid muscle
  - Inner lamina of thyroid cartilage
  - Vocal process of arytenoid cartilage
- For anterior commissure ± subglottic cancer
  - Vocal ligament
  - Thyroid perichondrium
  - Inner lamina and inferior margin of thyroid cartilage
  - Cricothyroid membrane
  - Superior margin of cricoid cartilage
  - First tracheal ring
- For supraglottic cancer
  - Vallecula
  - Epiglottis
  - Pre-epiglottic adipose tissue
  - Superior laryngeal arteries
  - Superior rim of thyroid cartilage
  - Arytenoids
  - Aryepiglottic fold
  - Pharyngoepiglottic fold

Prerequisite Skills

- Endoscopic anatomic knowledge of larynx
- Gain adequate access
  - Selection of appropriate laryngoscopes
  - Positioning of laryngoscopes
- Obtaining hemostasis
- Familiarity with CO_2 laser microsurgery techniques and safety
- Familiarity with operating microscope
- Anesthetist familiar with laser techniques (discussed later)

Operative Risks

- Dental, mucosal, and spinal hyperextension injury
- Airway fires
- Laser burns to face (if not properly covered with wet drapes)

Surgical Technique

- Place patient in supine position with neck extended.
- Check that the head is resting on the bed and not suspended in mid-air.
- Check for loose or crowned teeth.
- Insert gum guard.
- Panendoscopy
- Insert, position, and suspend laryngoscope.
  - Surgical exposure is critical, and it may prove impossible to proceed due to poor access.
  - Insert laryngoscope/laryngopharyngoscope/oropharyngoscope and expose the cancer.
  - Different scopes may be required during an operation.
  - Suspend scope with laryngoscope holder.
  - It may be necessary for the assistant to press on the larynx, or to place tapes attached to the operating table across the neck to displace the larynx posteriorly for maximum exposure.
- Surround laryngoscope with moistened towels or cotton to avoid fire or burns to the patient's face.
- Bring in the microscope with focal length set at 400 mm.
- Detailed examination of laryngeal cancer (may need to use endoscope)
- Make a decision as to whether access is adequate, whether the cancer is resectable, and whether an endoscopic approach is appropriate.
- Attach the micromanipulator and focus the laser beam.
- Set the CO_2 laser according to the type of tissue to be lasered, the desired depth of the cut, the need for hemostasis, and the need to avoid excessive heating of tissue.
  - Laser power density (PD)
    - Watts
    - Laser spot size
  - Total duty cycle (time that laser interacts with tissues)
    - Continuous wave: Continuous emittance of laser energy
    - Pulsed settings: Discrete pulses; lengths, frequencies, and time intervals between pulses can be selected.
      - Single pulse: Single energy bursts every time foot pedal depressed
      - Repeat pulse: Repeated energy bursts while foot pedal depressed
      - Super pulse (SP): Several thousand energy bursts of very high peak power laser pulses per second while foot pedal depressed. Bursts are spaced apart for tissue cooling between pulses and to reduce thermal damage.
- Keep in "safe mode" until ready.
- Attach suction to suction port of laryngoscope.
- Pack wet protective linen or neuro patty around the endotracheal tube.
- Plan surgical approach.
- Perform surgery under high magnification.
- Debulk if required.
- Bread slice. (Fig. 11.2).
- Resect the cancer in a piecemeal fashion.
- Orientate specimens for pathologist.

Glottic Cancer

The challenge is to strike the correct compromise between adequate resection and quality of the voice. Voice rest is not required after surgery except for superficial defects of the membranous cord.

TABLE 11.2 European Laryngological Society Classification of Endoscopic Cordectomy

Cordectomy	Type	Resected Tissue
Subepithelial	I	Epithelium
Subligamental	II	Epithelium, Reinke's space, vocal ligament
Transmuscular	III	Through vocalis muscle
Total	IV	—
Extended	Va	Contralateral vocal fold, anterior commissure
	Vb	Arytenoid
	Vc	Subglottis
	Vd	Ventricle

With permission from Remacle M, Eckel HE, Antonelli A, et al: Endoscopic cordectomy. A proposal for a classification by the Working Committee, European Laryngological Society. Eur Arch Otorhinolaryngol 257(4):227-231, 2000.

Classification of Laser Cordectomy

The European Laryngological Society proposed a useful classification of endoscopic cordectomy in 2000 (Table 11.2, Fig. 11.5).[3]

One can anticipate an excellent speaking voice following Type I or subepithelial resection of T_{1s} and T_1 cancers of the membranous vocal fold. Following Type II cordectomy a "new cord" is formed by a scar band and results in a good, though not quite normal, quality voice, whereas Type III cordectomy generally leads to an adequate speaking voice. Type IV cordectomy, which extends onto thyroid cartilage, has a less predictable voice outcome, with some patients phonating using the false vocal cords.

Superficial Lesions of the Membranous Cord

Resection margins of less than 1 mm are acceptable; as with close follow-up, recurrences can be resected without adversely affecting oncologic outcome. Set the laser at its smallest spot size, low power (1.5 to 3 W) and continuous SP mode; this allows a very precise dissection with minimum lateral thermal injury to the tissues. Following the initial incision, the cut edge of the epithelium is grasped with microforceps, and the cancer is dissected off of the vocal ligament.

Deeper Lesions of Membranous Cord

With deeper cancers requiring Types II to IV resections, the objective is to do an adequate resection (>1 mm margin) and to maintain a speaking voice. Set the laser at its smallest spot size, power of 3 to 5 W, and SP mode. Use the bread-slice technique to determine the depth of the cancer and the deep resection plane, and remove it in sections (Figs. 11.6 to 11.8). It is generally easiest to remove the posterior segment first, especially if access to the anterior commissure is poor.

Bleeding may be encountered, especially when dissecting adjacent to or below the anterior commissure and lateral to the vocal process. Small vessels may be coagulated by defocusing the laser beam. Brisk bleeding is controlled using monopolar or bipolar coagulation forceps.

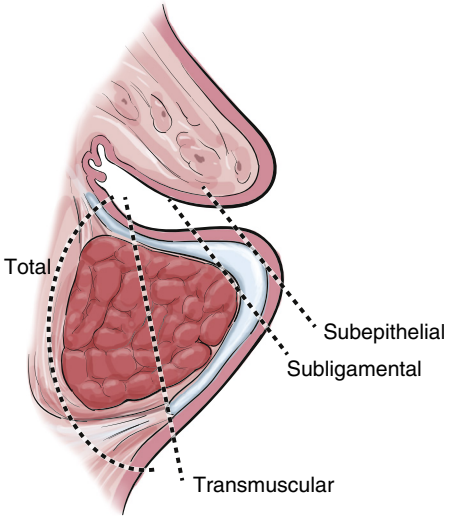

Fig. 11.5. Classification of cordectomy. *(With permission from Remacle M, Eckel HE, Antonelli A, et al: Endoscopic cordectomy. A proposal for a classification by the Working Committee, European Laryngological Society. Eur Arch Otorhinolaryngol 257(4):227-231, 2000.)*

Anterior Commissure

Although some surgeons consider involvement of the anterior commissure to be a contraindication for laser resection, I do not consider all anterior commissure cancers to be a contraindication for laser excision. The following need to be considered when managing cancers of the anterior commissure with the laser:

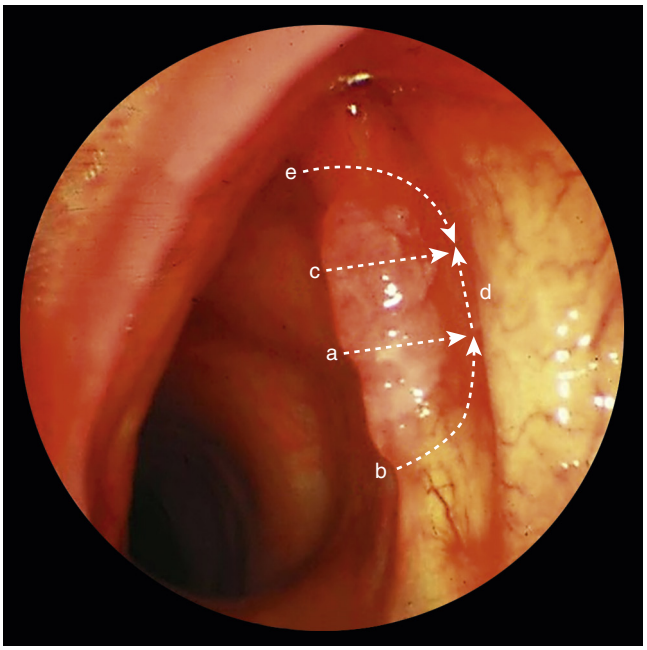

Fig. 11.6. Example of sequence of incisions for a partial cordectomy. a-e indicates example of sequence of laser incisions. *(With permission from Fagan JJ, Steiner W: Transoral CO_2 laser microsurgery for cancers and other pathology of the upper aerodigestive tract. Available at https://vula.uct.ac.za/access/content/group/ba5fb1bd-be95-48e5-81be-586fbaeba29d/CO2%20laser%20transoral%20microsurgery%20_TLM_.pdf)*

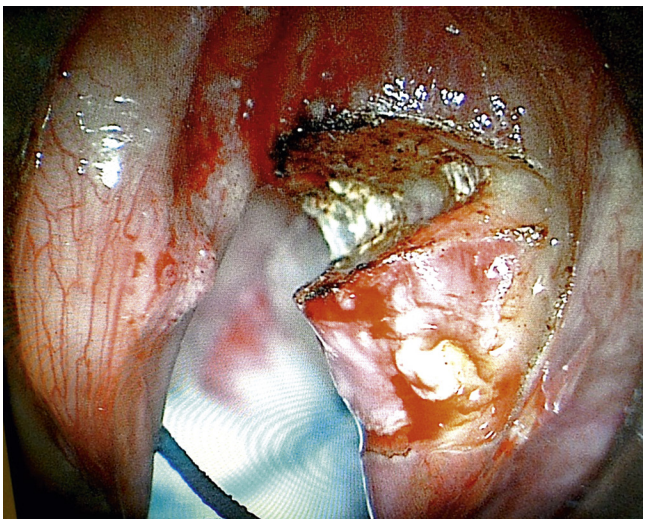

Fig. 11.7. The cancer has been transsected to determine the interface between the cancer *(charred)* and normal tissue *(white)*. *(With permission from Fagan JJ, Steiner W: Transoral CO_2 laser microsurgery for cancers and other pathology of the upper aerodigestive tract. Available at https://vula.uct.ac.za/access/content/group/ba5fb1bd-be95-48e5-81be-586fbaeba29d/CO2%20laser%20transoral%20microsurgery%20_TLM_.pdf)*

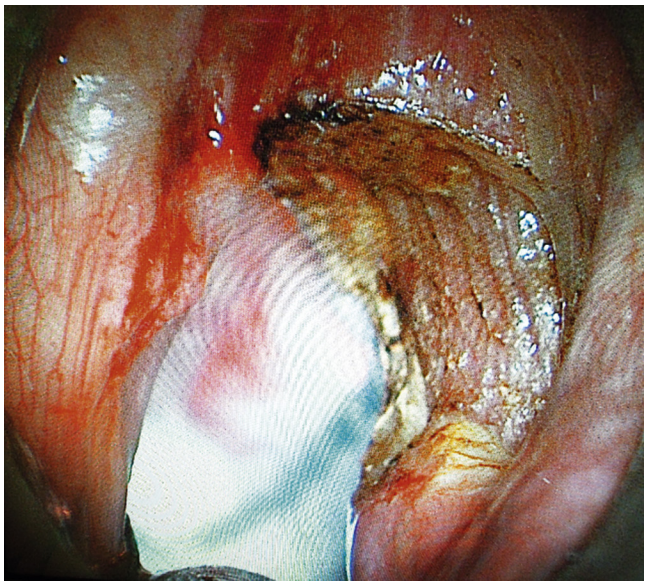

Fig. 11.8. Completed type 3 resection of posterior half of the cancer. *(With permission from Fagan JJ, Steiner W: Transoral CO_2 laser microsurgery for cancers and other pathology of the upper aerodigestive tract. Available at https://vula.uct.ac.za/access/content/group/ba5fb1bd-be95-48e5-81be-586fbaeba29d/CO2%20laser%20transoral%20microsurgery%20_TLM_.pdf)*

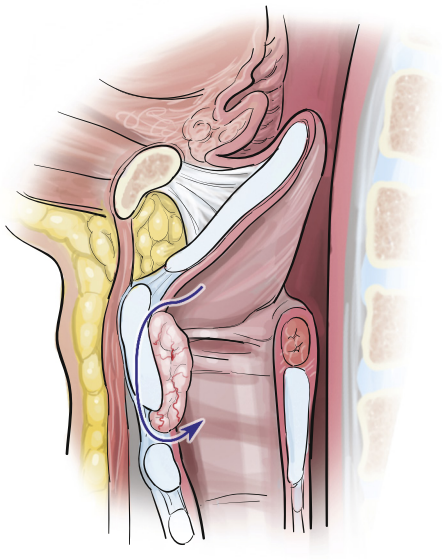

Fig. 11.10. Subglottic cancer extending through cricothyroid membrane; endoscopic resection *(blue arrow)*. *(With permission from Fagan JJ, Steiner W: Transoral CO_2 laser microsurgery for cancers and other pathology of the upper aerodigestive tract. Available at https://vula.uct.ac.za/access/content/group/ba5fb1bd-be95-48e5-81be-586fbaeba29d/CO2%20laser%20transoral%20microsurgery%20_TLM_.pdf)*

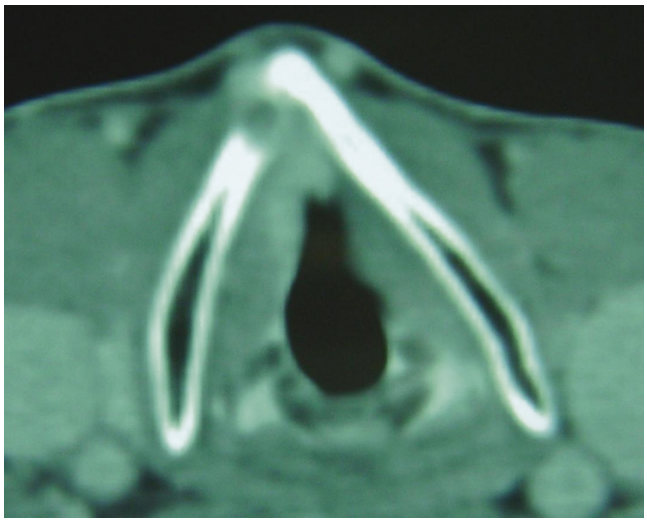

Fig. 11.9. Extension through the thyroid cartilage.



Fig. 11.11. Tissues stripped off of the thyroid cartilage in a subperichondrial plane and cartilage "sterilized" of cancer cells. *(With permission from Fagan JJ, Steiner W: Transoral CO_2 laser microsurgery for cancers and other pathology of the upper aerodigestive tract. Available at https://vula.uct.ac.za/access/content/group/ba5fb1bd-be95-48e5-81be-586fbaeba29d/CO2%20laser%20transoral%20microsurgery%20_TLM_.pdf)*

- Proximity to the thyroid cartilage: This raises the possibility of cartilage invasion and makes it impossible to obtain wide margins (Fig. 11.9). I do not routinely obtain imaging but follow the tumor during the resection and even resect cartilage with the CO_2 laser if necessary (Fig. 11.10). Once the vocal ligaments have been freed from the cartilage with the laser, the surgeon strips the tissues in a plane deep to perichondrium up to the inferior margin of the cartilage and then defocuses the laser and "sterilizes" the cartilage of any residual cancer cells (Fig. 11.11).
- Webbing of the anterior commissure: This results in poor voice quality and occurs when the anterior ends of both vocal cords are denuded of mucosa or resected. This can be avoided by doing a two-stage resection, initially resecting only up to the midline and completing the resection of the second vocal cord cancer approximately a month later. It may be difficult to correct a web. Simply dividing the web with laser invariably leads to a new web. One can divide the web with the laser and endoscopically place a silastic keel between the vocal cords to allow the cut edges to reepithelialize.

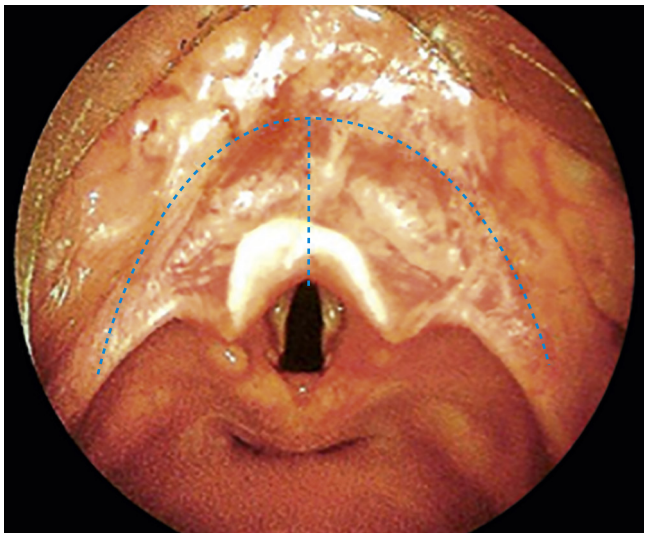

Fig. 11.12. Initial incision in the valleculae and through the epiglottis as indicated by blue lines. *(With permission from Fagan JJ, Steiner W: Transoral CO_2 laser microsurgery for cancers and other pathology of the upper aerodigestive tract. Available at https://vula.uct.ac.za/access/content/group/ba5fb1bd-be95-48e5-81be-586fbaeba29d/CO2%20laser%20transoral%20microsurgery%20_TLM_.pdf)*

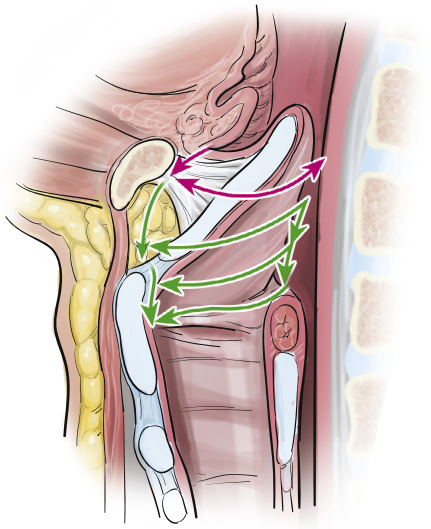

Fig. 11.13. Supra- *(purple)* and infrahyoid *(green)* incisions for laser supraglottic laryngectomy. *(With permission from Fagan JJ, Steiner W: Transoral CO_2 laser microsurgery for cancers and other pathology of the upper aerodigestive tract. Available at https://vula.uct.ac.za/access/content/group/ba5fb1bd-be95-48e5-81be-586fbaeba29d/CO2%20laser%20transoral%20microsurgery%20_TLM_.pdf)*

Supraglottic Cancer

Supraglottic cancer is resected using a distending laryngopharyngoscope (see Fig. 11.6), graspers, and Ligaclip applicators to clip the superior laryngeal vessels that traverse the pharyngoepiglottic folds. The laser is set at higher power (>5 W), slightly larger spot size, and on SP mode to both cut and coagulate. Surgery is done under high magnification, maintaining a distance of >5 mm from the edge of the cancer. Antibiotics are not required. Resecting the suprahyoid epiglottis is associated with only transient and minor difficulty with swallowing and aspiration that improve once the postoperative pain resolves. With cancer of the infrahyoid epiglottis and false vocal cords, aspiration is minor when compared to open supraglottic laryngectomy. The nasogastric tube is generally removed within a few days.

- Insert a distending laryngopharyngoscope with the anterior blade in the vallecula, and open it widely.
- Determine the extent of the cancer and the adequacy of access, and plan the resection.
- Excise the suprahyoid epiglottis for exposure and to remove the suprahyoid component of the cancer.
  - Make a curved incision in the vallecula (Figs. 11.12 and 11.13).
  - Bisect the suprahyoid epiglottis in the midline in a sagittal plane, cutting through the cancer if necessary (requires higher power setting to cut through the epiglottis).
  - Cut transversely across the epiglottis at the level of the hyoid.
  - Remove the left and/or right segments of the suprahyoid epiglottis.
- Readjust the position of the distending laryngopharyngoscope to improve access to the infrahyoid cancer.
- Incise the pharyngoepiglottic folds, taking care to identify the branches of the superior laryngeal vessels. Resist the temptation to coagulate the superior laryngeal artery with electrocautery; rather, apply two Ligaclips before dividing the vessel with the laser.
- Pre-epiglottic dissection
  - Cut transversely into the avascular pre-epiglottic adipose tissue, preserving a layer of adipose tissue over the anterior aspect of the cancer as a margin.
  - Palpate with the suction to determine the position of the hyoid bone and the superior edge of the thyroid cartilage.
  - Cut down onto and expose the thyroid cartilage.
- Bisect the infrahyoid epiglottis in a sagittal plane, cutting through the cancer if necessary. (Use a high power setting to cut through the epiglottis.)
- Follow the cancer (e.g., through the thyrohyoid membrane); thyroid cartilage may also be resected.
- Remove the cancer in as many segments as is required, taking care to maintain their orientation for the pathologist.
- A frozen section may be used.
- Secure hemostasis with monopolar suction cautery or coagulation forceps, preferably with bipolar.

Cancer of the Hypopharynx

Cancer of the piriform fossa may extend medially into the paraglottic space, cricoid, and cricoarytenoid joint; anteriorly into pre-epiglottic space; and laterally to invade thyroid cartilage and behind the posterior edge of the thyroid lamina to the soft tissues of the neck and the carotid sheath.

At diagnostic endoscopy, assess:

- Depth and mobility of the cancer
  - Cancers clearly limited to mucosa are easily resected.
  - Deeply invasive cancers of the lateral wall need additional CT and/or MRI imaging, as cancer invading soft tissue around the carotid artery is not amenable to laser excision.
- Whether cancer on the lateral wall extends behind the thyroid lamina
  - Proximity of carotid sheath
  - Delay neck dissection by 2 weeks to avoid thru'-and-thru' defect into the neck.
- Distal extent, as one must avoid circumferential resection at the narrow cricopharyngeus region because this may cause a stricture.

Resection Technique

- Use high magnification through laryngoscopes and a distending laryngopharyngoscope (see Fig. 11.6) using graspers and Ligaclip applicators to clip the superior laryngeal vessels that traverse the pharyngoepiglottic folds.
- Maintain a distance of 5 to 10 mm from the mucosal edge of the cancer.
- Set the laser at a higher power (>5 W), slightly larger spot size, and on CW mode so as to both cut and coagulate. Reduce power when dissecting posterior to the thyroid lamina in the region of the carotid sheath.
- If the carotid artery is exposed, the vessel is either left uncovered or sealed with fibrin tissue glue.
- The cancer is excised in segments, taking care to orientate the specimens for histology.
- With major resections, insert a nasogastric feeding tube under direct vision to avoid the tube transgressing the cancer bed and entering the soft tissues of the neck, or arrange for a percutaneous endoscopic gastrostomy (PEG)
- Provided a neck dissection is not done simultaneously, antibiotics are not required.

Common Errors in Technique

- Inadequate access: Access is all-important and requires the employment of a range of laryngoscopes, repositioning the patient during the procedure, and external manipulation of the larynx by an assistant.
- Attempting to remove the cancer as a single tissue block: Because one is working within a very cramped space, the cancer must first be debulked if necessary and then removed piecemeal to ensure adequate deep resection margins.
- Losing orientation of tissue fragments

POSTOPERATIVE PERIOD

Postoperative Management

- The principal risks in the initial 24 hours are airway obstruction, bleeding, and aspiration.
- Airway management is a matter of clinical judgment. If in any doubt, the patient should be admitted to a high care unit. If the patient was difficult to intubate in the operating room, then high-risk patients should have a tracheostomy.
- Analgesia
- Feeding: This may require nasogastric tube feeding until swallowing is possible without aspiration.

Complications

Patients have surprisingly little pain but commonly have to clear their throat for a few weeks due to secretions from the surgical bed.

Early

- *Dental:* Protect the teeth with a gum guard, check for crowns or implants, and explain the risks to the patient.
- *Oropharyngeal trauma:* Minor tears of the tonsillolingual mucosa are common.
- *Lingual nerve:* Prolonged upward traction on the tongue can cause transient sensory change due to traction lingual nerve injury.
- *Bleeding:* This is most likely to emanate from the superior laryngeal arteries following resection of supraglottic cancer. To avoid this, always apply Ligaclips to the vessels, rather than relying on electrocautery. Should bleeding occur, then the patient should be returned to the operating room. Apply Ligaclips to the superior laryngeal vessels; do not cauterize major vessels.
- *Surgical emphysema:* This occurs mainly in the setting of surgery in the subglottic region and is treated conservatively.
- *Airway obstruction:* This is uncommon; hence prophylactic tracheostomy is rarely indicated.
- *Aspiration:* This does not occur with cordectomies but may complicate supraglottic laryngectomy and resection of the base of the tongue. It is most likely to occur in the elderly and infirm or following resection of supraglottic cancers. It is unusual to be long-standing and generally is managed with effective analgesia, chest physiotherapy, dietary modification (avoiding liquids), and involving a speech and language therapist. Initial management includes pain control, thickened foods (rather than liquids), and temporary nasogastric tubes or PEG feeding.
- *Laser burns:* This occurs when the tissues are not properly protected with wet drapes.
- *Airway fire:* This is an extremely rare event and is entirely preventable.

Late

- Poor voice quality
- Granuloma: This occurs particularly where cartilage is exposed (e.g., anterior commissure and vocal process).
- Chondronecrosis: This rarely occurs when cartilage is exposed, especially after chemoradiation.
- Pharyngeal stricture: This occurs very rarely but may occur following circumferential excision of cancer of the hypopharynx.

ALTERNATIVE MANAGEMENT PLAN

Always discuss with patients the nonsurgical options such as (chemo)radiation therapy. Consider open surgical approaches (e.g., laryngofissure, vertical hemilaryngectomy, supraglottic, supracricoid, and total laryngectomy) in patients with anatomic problems that preclude the use of laser resection and in patients who have failed (chemo)radiation or previous laser surgery.

EVIDENCE-BASED DISCUSSION

After Billroth, in Vienna, 1864, described his technique of total laryngectomy, the operation became entrenched as the only way of curing cancer of the larynx. When Justo Alonzo, of Montevideo, introduced partial laryngeal surgery in the United States in 1947, the operation was not accepted by the academic leaders largely due to the influence of Halstead at the Johns Hopkins Hospital and the concept that unless the cancer and its underlying organ were excised "en bloc," the cancer would recur.

When Stuart Strong and Geza Jako, in Boston, 1972, adapted the Zeiss microscope (which had been previously used in otologic surgery) for use in laryngeal surgery and then found a way through clever engineering to attach a CO_2 laser, a very successful means of operating on early lesions of the glottis was introduced. This approach eliminated the laryngofissure from surgeons' thoughts when confronted with a patient with an early cancer of the vocal cord. It also proved to be an inexpensive and equally successful alternative to radiation therapy both oncologically and functionally.

Wolfgang Steiner, then of Gőttingen, introduced yet another application of CO_2 laser surgery when he used the laser to successfully resect cancers involving the supraglottis and the hypopharynx. Heinrich Rudert, then of Kiel, was also a pioneer in the field. Steiner and Rudert taught these techniques to scores of surgeons from all parts of the world, with the hands-on and live surgery courses they gave in their departments.

While many ENT surgeons from the United States have studied with surgeons from the "German School," the technique of laser supraglottic surgery has not been embraced as widely or as enthusiastically as its application for cancer of the glottis.

Eugene N. Myers

Editorial Comment

Transoral CO_2 laser microsurgery requires experience, surgical aptitude, careful case selection, and clinical judgment as to whether adjuvant radiation therapy is indicated in cases of questionable or close surgical margins to achieve good results.

Johan Fagan

Access the review questions online at http://www.expertconsult.com

REFERENCES

1. Fagan JJ, Steiner W. Transoral CO_2 laser microsurgery for cancers and other pathology of the upper aerodigestive tract. Available at https://vula.uct.ac.za/access/content/group/ba5fb1bd-be95-48e5-81be-586fbaeba29d/CO2%20laser%20transoral%20microsurgery%20_TLM_.pdf
2. Apfelbaum JL, Caplan RA, Barker SJ, et al. Practice advisory for the prevention and management of operating room fires: an updated report by the American Society of Anesthesiologists Task Force on Operating Room Fires. Anesthesiology 2013;118(2):271–290.
3. Remacle M, Eckel HE, Antonelli A, et al. Endoscopic cordectomy. A proposal for a classification by the Working Committee, European Laryngological Society. Eur Arch Otorhinolaryngol 2000;257(4):227–231.

REVIEW QUESTIONS

1. In CO_2 laser excision of glottic cancer
   a. Anterior commissure cancer is a contraindication
   b. Close margins always require adjuvant radiation
   c. Paraglottic space invasion is a relative contraindication
   d. Type III resections generally have a normal voice
   e. Aspiration is a common complication

2. In CO_2 laser transoral microsurgery
   a. The cancer should be resected in one tissue block
   b. A frozen section is useful to check margins for T_1 glottic cancers
   c. Maintain inspired oxygen at FiO_2 less than 30%
   d. A preoperative CT scan is always indicated with glottic cancer
   e. The superior laryngeal artery can be cauterized for hemostasis

3. Nerves potentially at risk with CO_2 laser transoral microsurgery include all of the following, *except*
   a. Lingual nerve
   b. Superior laryngeal nerve
   c. Recurrent laryngeal nerve
   d. Hypoglossal nerve
   e. Accessory nerve

12 Horizontal Partial Laryngectomy

Jonas T. Johnson, Meghan T. Turner

INTRODUCTION

Cancer of the larynx arises from three subsites in the larynx: the supraglottis, glottis, and subglottis. Subglottic primaries comprise less than 5% of cancers of the larynx. The incidence of supraglottic versus glottic primaries varies, depending on the relative prevalence of alcohol and tobacco abuse and by geographic area. The optimal treatment of cancer of the larynx depends on primary tumor staging and the functional status of the larynx at the time of diagnosis. It is widely accepted that early stage (T1 and T2) cancers are treated equally well by either primary radiation or surgery. Advanced staged cancers, however, were originally thought to be best treated with total laryngectomy along with adjuvant chemoradiotherapy when indicated.[1]

However, in the 1980s a paradigm shift evolved in the treatment of advanced cancer of the larynx. Many began advocating for "organ preservation therapy" (OPT) with definitive radiotherapy versus concurrent chemoradiotherapy in order to improve laryngectomy-free survival, following the results of the VA Laryngeal Cancer Group Study.[1] Hoffman et al. analyzed the effects of this paradigm shift on outcomes and found that OPT has resulted in decreased overall survival for patients with cancer of the larynx in recent decades, particularly for those with T3 cancers.[2] Consequently, it is now recognized that certain patients are better treated with primary surgery. The desire to preserve the functions of the larynx and improve survival has fueled a renewed interest in conservation surgery of the larynx.

Conservation partial laryngectomy is defined as the removal of a portion of the larynx with preservation of its respiratory, sphincteric, and vocal functions. Both endoscopic and open techniques have been developed for highly selected patients. Endoscopic techniques are discussed in Chapter 11. Open techniques are separated into two categories: horizontal partial laryngectomy and vertical partial laryngectomy. Vertical partial laryngectomy is discussed in Chapter 13. This chapter focuses on horizontal partial laryngectomy techniques.

For half a century, the only type of horizontal laryngectomy was supraglottic partial laryngectomy, which could only be performed on rare cancers confined only to the supraglottic larynx. In 1990, Laccourreye et al. described a new type of horizontal partial laryngectomy that removed both the true vocal cords and the entire thyroid cartilage.[3] Since then, several modifications of horizontal partial laryngectomy have been described to remove glottic and supraglottic cancer. These modifications allow for resection of the superior, inferior, and lateral extensions of the cancer into the base of the tongue, piriform sinus, paraglottic space, and subglottis, as well as the use of remnant structures in the reconstruction.[4] Surgeons must understand these techniques, as well as the indications and contraindications, in order to provide optimal treatment for patients with cancer of the larynx, who are likely to fail OPT and who are better treated by surgery.

Today, supracricoid partial laryngectomy (SCPL) with cricohyoidopexy (CHP) or cricohyoidoepiglottopexy (CHEP) is the most widely performed horizontal partial laryngectomy procedure because of to its reproducible oncologic and functional results in carefully selected patients.[3-5] Supratracheal partial laryngectomy has been described; however, the results are less reproducible.[4] This chapter will focus on supraglottic and supracricoid partial laryngectomy. If properly selected, most patients are decannulated, tolerate a regular diet, and enjoy improved overall and laryngectomy-free survival.

KEY OPERATIVE LEARNING POINTS

1. Supraglottic laryngectomy has application limited to cancers of the supraglottic larynx and exophytic cancers of the base of the tongue confined to the vallecula (Fig. 12.1).
2. The hyoid bone, at least one functional (innervated) cricoarytenoid unit, the cricoid cartilage, the recurrent laryngeal nerves, and the internal branches of the superior laryngeal nerves must be preserved for successful restoration of phonation and swallowing.
3. The ability to preserve the epiglottis determines the type of reconstruction: CHEP is performed for limited glottic cancers when the suprahyoid epiglottis can be preserved, and CHP is performed for glottic and supraglottic cancers where the epiglottis is involved and must be removed.
4. Extension to the base of the tongue, subglottis, or hypopharynx can make resection with negative margins impossible without an extended procedure, which downgrades function.

PREOPERATIVE PERIOD

History

1. History of present illness
   a. Presenting symptom
      1) What was the initial presenting symptom: dysphonia, dysphagia, or odynophagia?
   b. Assess the current functional status of the larynx.
      1) Respiration
         a) Does the patient have dyspnea at rest or orthopnea?
         b) Does the patient have dyspnea on exertion?
      2) Phonation
         a) Does the patient communicate well or is he or she difficult to understand?
      3) Deglutition
         a) Does the patient experience aspiration with liquids or solids?
         b) Has the patient had pneumonia in the past year?
         c) Has the patient lost more than 10 pounds in the past year?
2. Past medical history
   a. Prior treatment
      1) Has the patient had prior direct laryngoscopy with biopsy, CO_2 laser excision, surgery, radiotherapy, or chemotherapy?
   b. Medical illness
      1) Does the patient have recurrent bronchitis, pneumonias?
      2) Does the patient have chronic obstructive pulmonary disease (COPD) or a cardiac history?

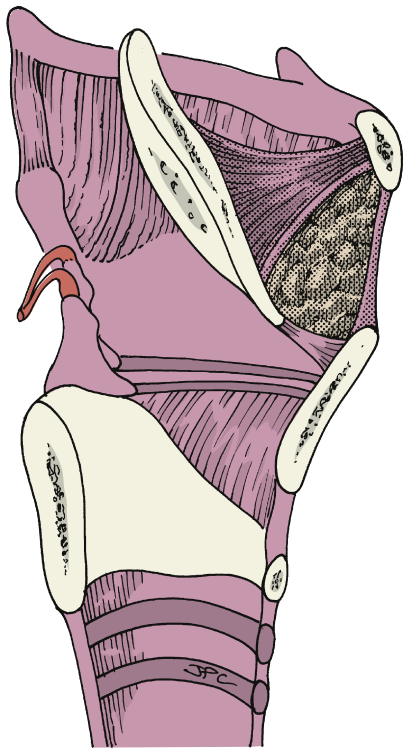

Fig. 12.1. The pre-epiglottic space *(shaded area)* is bounded anteriorly by the thyrohyoid membrane. Superiorly, it is contained by the hyoepiglottic ligament. Cancer limited to the pre-epiglottic space is not a contraindication to supraglottic laryngectomy. However, extension of the cancer anterior to the pre-epiglottic space must be recognized and satisfactorily excised to ensure clear surgical margins.

3) Does the patient have cirrhosis with bleeding varices or other gastrointestinal bleeding?
4) Consider using the Charleston Comorbidity Index or the Karnofsky Performance Status to identify those patients suited for surgery.[4,5]
5) What is the patient's respiratory reserve; can the patient climb two flights of stairs?

c. Surgery
1) Is there a history of thyroidectomy or anterior cervical discectomy and fusion (possible superior laryngeal nerve injury)?
2) Is there a history of prior neck surgery?

d. Family history
1) Do any first-degree relatives have cancer?

e. Social history
1) Tobacco use
a) Assessment of pack-year history and current use
b) Prior attempts to stop smoking and pharmacologic interventions
2) Alcohol use
a) Daily volume versus drinks per week, alcohol abuse, and current use?
b) Prior attempts to stop drinking, symptoms of withdrawal/seizures?
3) Occupation
4) Does the patient rely on his or her voice at work?

f. Medications
1) Daily inhalers and/or oxygen for COPD?
2) Does the patient take heart failure or antiplatelet medications?

PHYSICAL EXAMINATION

1. Flexible laryngoscopy
   a. This is the most important part of the examination. It allows for detailed evaluation of the primary cancer, including the subsites and key anatomic structures involved. It also allows for assessment of the effect of the cancer on laryngeal function and helps screen for synchronous second primary cancers.
   b. Cancer extending to the anterior commissure should be evaluated. If present, the surgeon should suspect invasion of the thyroid cartilage, which makes the patient unlikely to be cured by primary radiation therapy (RT).
   c. Careful assessment of the true vocal folds and cricoarytenoid joint mobility helps determine the patient's candidacy for surgery. Atrophy of the true vocal fold suggests involvement of the ipsilateral cricoarytenoid joint and/or recurrent laryngeal nerve.
   d. Subglottic extension is best assessed in the operating room through direct laryngoscopy using angled telescopes.
2. Videostroboscopy
   a. This is indicated for cancer involving the true vocal cords and identifies the extent of mucosal involvement. Stroboscopy may help in planning the margins of resection and predict which patients will require removal of an arytenoid cartilage.
3. Behavior
   a. Assessment of patient compliance with postoperative surveillance and rehabilitation is crucial. Patients who do not participate in intense swallowing therapy are unlikely to overcome the expected postoperative aspiration and may require placement of a percutaneous gastrostomy tube and/or prolonged tracheostomy.
4. Assessment of voice quality, respiration, and aspiration
5. Oral cavity and oropharynx
   a. Screen for synchronous primaries and look for extension of the cancer that may be a contraindication to horizontal partial laryngectomy.
6. Laryngotracheal complex
   a. Fixation to the anterior soft tissues suggests extra-laryngeal spread and requires a total laryngectomy.
   b. Fixation to the spine makes the cancer unresectable.
7. Palpation of the thyroid gland
   a. Extension to the thyroid gland requires a total laryngectomy with thyroid lobectomy or total thyroidectomy.
8. Presence of cervical lymphadenopathy
   a. Clinically detectable lymphadenopathy may require a comprehensive neck dissection, depending on the extent of metastasis, whereas the clinically negative neck requires a selective neck dissection.

IMAGING

1. CT
   a. Larynx
      1) Thin-cut 1 mm axial CT scan through the larynx with coronal and sagittal reconstructions can detect extension of the cancer to pre-epiglottic and paraglottic spaces (see Figs. 12.1 and 12.2) as well as thyroid cartilage invasion with 75% accuracy. Adding analysis of gross radiographic signs of anterior commissure involvement (GRACI) signs improve accuracy in staging to 96%.
   b. Neck
      1) CT evaluation of cervical lymph node metastases is more sensitive than physical examination. Lymph

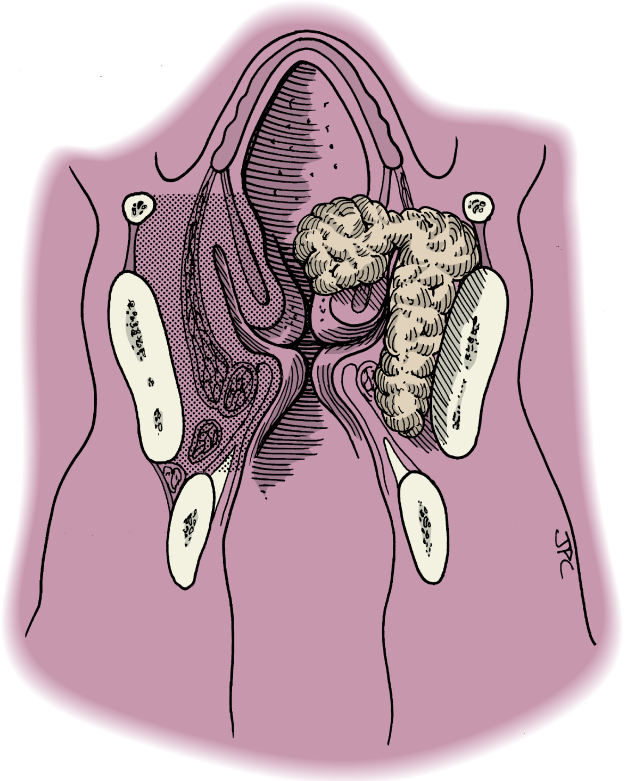

Fig. 12.2. The paraglottic space *(shaded area)* describes the submucosal soft tissue of the larynx contained by the thyroid cartilage externally. Cancer of the supraglottic larynx may spread submucosally through the paraglottic space. If the cancer extends inferior to the plane of the true vocal cord, as demonstrated in this illustration, supraglottic laryngectomy would be contraindicated because the surgeon would cut across the cancer at the level of the vocal cord.

nodes greater than 1 cm in the axial dimension that are round, hypodense, or demonstrate loss of the fatty hilum are considered suspicious for metastatic cancer.

c. Chest
   1) This is the most sensitive test to rule out synchronous cancers of the lung, the most common second primary in patients who have cancer of the larynx.

2. MRI
   a. Neck
      1) MRI can evaluate the extent of involvement of the base of the tongue and identify which patients will require extended horizontal partial laryngectomy versus total laryngectomy.

INDICATIONS

1. Treatment of highly selected glottic cancer with the following characteristics:
   a. T1-T3 glottic cancer that extends onto the supraglottis or entirely involves both vocal folds, but spares one arytenoid
   b. T3 glottic cancers that have infiltrated the paraglottic space, causing vocal fold fixation without fixation of the cricoarytenoid joint
2. Treatment of highly selected supraglottic cancers with the following:
   a. T2 supraglottic cancers that extend to the true vocal fold
   b. T3 cancers that have infiltrated the paraglottic space, causing vocal fold fixation without fixation of the cricoarytenoid joint
3. Treatment of highly selected cancers with subglottic extension:
   a. T2 or T3 cancers with less than 10 mm of anterior subglottic extension are unlikely to invade the cricoid cartilage and will still allow for negative margins. These patients remain candidates for SCPL with CHP or CHEP.[4,5]
4. T3 glottic and supraglottic cancers with suspected invasion of the inner cortex of the thyroid cartilage.[5]
5. Patients who failed primary RT and meet all of the previously noted criteria.

CONTRAINDICATIONS

1. Patients with general medical comorbidity, who are unable to undergo anesthesia or withstand postoperative aspiration
   a. Inability to climb two flights of stairs
   b. Karnofsky Performance Status less than 80[4]
2. Primary characteristics of the cancer making horizontal partial laryngectomy impossible:
   a. Interarytenoid/posterior commissure involvement
   b. Involvement of both arytenoid cartilages
   c. Cricoarytenoid joint involvement
   d. Cricoid cartilage involvement
   e. Subglottic extension greater than 10 mm
   f. Massive invasion of the inferior paraglottic space extending to the apex of the piriform sinus or piriform sinus involvement
   g. Greater than 2 cm of base of tongue involvement
   h. Extralaryngeal spread of the cancer

Note that advanced age was previously a relative contraindication to horizontal partial laryngectomy. However, recent literature indicates that age is of limited importance.[4,5]

PREOPERATIVE PREPARATION

1. Preoperative pulmonary function tests and arterial blood gases (ABG) can help in evaluating the severity of COPD; however, there is no defined parameter by which patients are selected for horizontal partial laryngectomy. Weber et al. report using the patient's ability to climb two flights of stairs as helpful in selecting appropriate candidates.
2. Perform operative direct laryngoscopy with biopsy using angled telescopes (30- and 70-degree), with palpation of the cricoarytenoid joint to assess mobility. Fixation is a contraindication to horizontal partial laryngectomy. Biopsy should also be performed in order to provide the histologic diagnosis of cancer. Operative examination and biopsy can be performed prior to the day of surgery or immediately prior to surgery with frozen section diagnosis (if one has a reliable pathologist). Biopsies done at outside institutions should be reviewed by in-house pathologists to confirm the diagnosis.

Consider preoperative evaluation of speech and swallowing as well as nutritional evaluation. This is not essential and can be done successfully in the immediate postoperative period by the appropriate team.

POSITIONING

1. The patient should be in the supine position.
2. The patient's head should be centered and at the very top of the OR table.
3. Tape the endotracheal tube to the left lower lip for laryngoscopy.
4. Place a shoulder roll for neck dissections.
5. Make sure the upper lip, mastoid process, border of trapezius, and the clavicles are visible.

PERIOPERATIVE ANTIBIOTIC PROPHYLAXIS

1. Augmented penicillins are recommended for prophylaxis in cases of clean-contaminated head and neck surgery. Perioperative (24 hours) dosing is adequate in those cases where the aerodigestive tract is entered as in open partial laryngeal surgeries.
2. Clindamycin is an alternative in patients who have a history of penicillin allergy.

MONITORING

- The decision to use intraoperative nerve monitoring (IONM) is based on the surgeon's preference, as there is no evidence for or against nerve monitoring in partial laryngeal surgery.
- Disposable electromyography probes or IONM can be used to confirm identification and preservation of the hypoglossal nerve, the external branches of the superior laryngeal nerve, the recurrent laryngeal nerves, or the spinal accessory nerve.

INSTRUMENTS AND EQUIPMENT TO HAVE AVAILABLE

- Direct laryngoscopy set with Lewy arm
- Video tower with 30- and 70-degree laryngeal endoscopes
- Basic neck dissection set
- Headlight
- Reinforced endotracheal and tracheostomy tubes
- Three 2-0 nonabsorbable sutures on large diameter, tapered needles for pexy sutures

KEY ANATOMIC LANDMARKS

- Epiglottis
- Vocal cords
- Base of the tongue
- Thyroid cartilage
- Piriform sinuses

PREREQUISITE SKILLS

- Transoral CO_2 laser excision (see Chapter 11). The ability to offer less invasive endoscopic resection of early glottic and supraglottic cancers should be a requisite skill for surgeons performing open conservation laryngeal surgery. In this way, patients will not be overtreated and develop aspiration if less radical techniques would suffice.
- Selective, comprehensive, and radical neck dissection (see Chapters 63–66). Definitive treatment of the neck should be performed at the time of surgery as indicated.
- Paratracheal lymph node dissection (see Chapter 67). The ability to perform this procedure is of absolute necessity for patients with cancers that have subglottic extension.
- Total laryngectomy (see Chapter 16). Some patients may not be candidates for partial laryngeal surgery based on operative examination of the cancer. For patients who have had prior radiation treatment, the borders of the cancer may be indistinct due to radiation changes to the mucosa, submucosal spread, multifocal nests of a persistent tumor, or deep soft tissue extension of a tumor that requires subtotal or total laryngectomy. These patients may be better treated with total laryngectomy and, if offered partial laryngeal surgery, should understand that they may require salvage with total laryngectomy when doubt exists as to the extent of the cancer. Patients undergoing partial laryngectomy must consent to the possibility of converting the operation to a total laryngectomy.

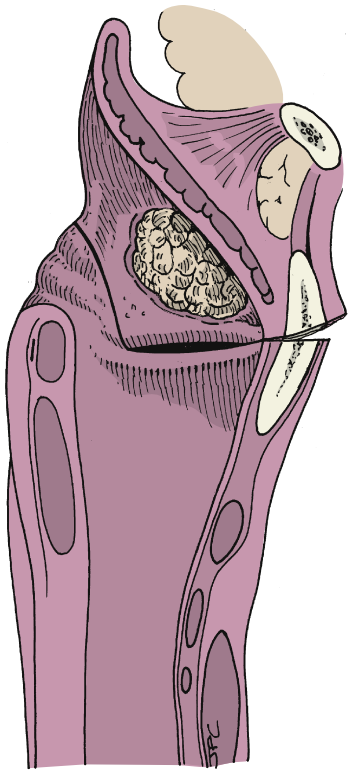

Fig. 12.3. Mucosal incisions in the larynx are made under direct visualization. Inferiorly, the incision is made directly through the ventricle at the level of the true vocal cord. Posteriorly, the mucosal incision is made across the face of the arytenoids, unless extension of the cancer requires an extended procedure.

OPERATIVE RISKS

1. Injury to the internal branch of the superior laryngeal nerves
2. Injury to the recurrent laryngeal nerve
3. Injury to the hypoglossal nerve
4. Injury to the lingual artery

SURGICAL TECHNIQUE

Supraglottic Laryngectomy (Via *Transhyoid or **Lateral Pharyngotomy Approach)

- Tracheostomy (transverse incision incorporated into the apron incision)
- Apron flap
- Neck dissections as indicated
- Identify and free the hyoid bone laterally.
- Transect the strap muscles.
  - Transect the infrahyoid strap muscles (if the lingual surface of the epiglottis is free of cancer).*
  - Transect the mylohyoid and infrahyoid strap muscles to include the hyoid bone in the specimen (if the lingual surface of the epiglottis is involved).**
- Open the vallecula (Fig. 12.3).
  - Traverse the pre-epiglottic space, enter the pharynx in the midline, and identify the epiglottis (if the lingual surface of the epiglottis is free of cancer).*
  - Enter the pharynx opposite to the cancer (if the lingual surface of the epiglottis is involved).
- Incise and elevate the perichondrium along the superior edge of the thyroid cartilage.

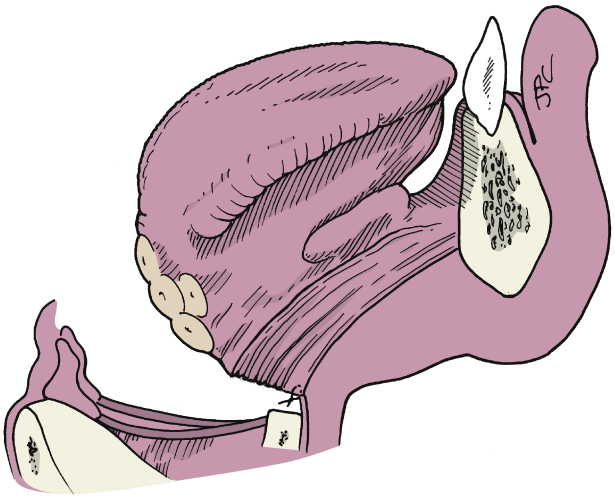

Fig. 12.4. The external perichondrium of the cricoid cartilage is reapproximated to the fibroaponeurotic layer of the base of the tongue. This positions the base of tongue posteriorly over the glottis.

- Incise the aryepiglottic fold at the level of the ventricle (see Fig. 12.3).
  - Do not cut the true vocal cords or arytenoid cartilages!
- Connect the endolaryngeal incision to the cartilage incision, and incise the thyroid cartilage at the ventricle under direct vision.
  - Do not disrupt the attachment of the anterior commissure to the thyroid cartilage.
- Remove the specimen, examine the margins, and take frozen sections as necessary.
- Place the nasogastric tube into the pharynx.
- Reconstruct the pharynx (Fig. 12.4).
  - Place three sutures from the perichondrium of the cricoid cartilage to the fibroadipose layer 12-15 mm anterior to the base of the tongue.
  - Do not suture to the tongue mucosa!
- With tension relieved, tie the sutures firmly and close the lateral aspects of the pharyngotomy mucosa separately.
- Irrigate the wound, and place suction drains.
- Suture the strap muscles to the platysma of the apron flap around the tracheostomy to prevent postoperative subcutaneous emphysema and contamination of the dissected neck(s) (Fig. 12.5).

1. Common errors in technique
   a. Positive margins
      1) This occurs more often with unrecognized invasion of the base of the tongue, piriform sinus, pre-epiglottic space, or subglottic extension. It is prevented with up-to-date imaging, direct laryngoscopic examination immediately prior to surgery, careful planning of the pharyngotomy to allow for endolaryngeal incisions to be made under direct visualization, and intraoperative frozen section analysis.
   b. Inappropriate approximation of the mucosa of the base of the tongue to the glottis
      1) The base of the tongue must be "set back" over the larynx by suturing the cricoid perichondrium to the fibroadipose aponeurosis of the tongue 12 to 15 mm deep to the mucosa. This creates a "roof" over the glottic larynx and reduces postoperative aspiration (see Fig. 12.5).
   c. Recurrence in the contralateral neck
      1) All patients with supraglottic cancers should undergo bilateral neck dissection. Recurrence rates in the contralateral neck can be reduced from 20% to 9%, with bilateral selective neck dissections in the clinically N0 neck.

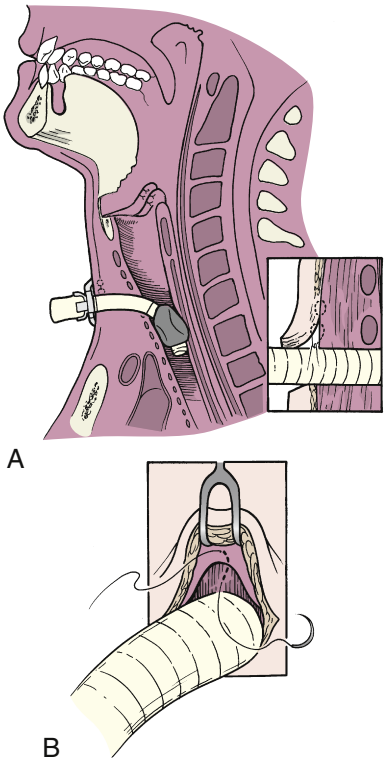

Fig. 12.5. (A) At the completion of the procedure, the tracheostomy site must be isolated from the potential dead space created through flap elevation and neck dissection. **(B)** Failure to isolate the tracheostomy from the potential space created by the neck dissection may result in transmission of contaminated air or secretions from the trachea underneath the cervical flap, resulting in subcutaneous emphysema and wound infection.

POSTOPERATIVE PERIOD

Postoperative Management

1. Patients are transferred to a monitored hospital bed managed by staff skilled in immediate postoperative tracheostomy and wound care.
2. Continuous pulse-oximetry is routine.
3. Patients are kept NPO, with the nasogastric tube kept on low wall suction initially. Once bowel sounds are detected, feedings and medications can be administered via the nasogastric tube.
4. Avoidance of postoperative emesis is crucial, because vomiting may disrupt the reconstruction. This is done with cautious advancement of feeding and antiemetic medication.
5. Deflating the cuff of the tracheostomy is attempted on postoperative day 3. Aspiration signifies that laryngeal edema is decreasing, and the cuff is often reinflated. The patient is then encouraged to expectorate secretions.
6. Flexible laryngoscopy is then performed with the cuff deflated on postoperative day 5 to assess laryngeal edema and aspiration. If edema is improved and aspiration not severe, an uncuffed no. 4 tracheostomy tube is placed. If aspiration is evident, the cuffed tube is replaced.

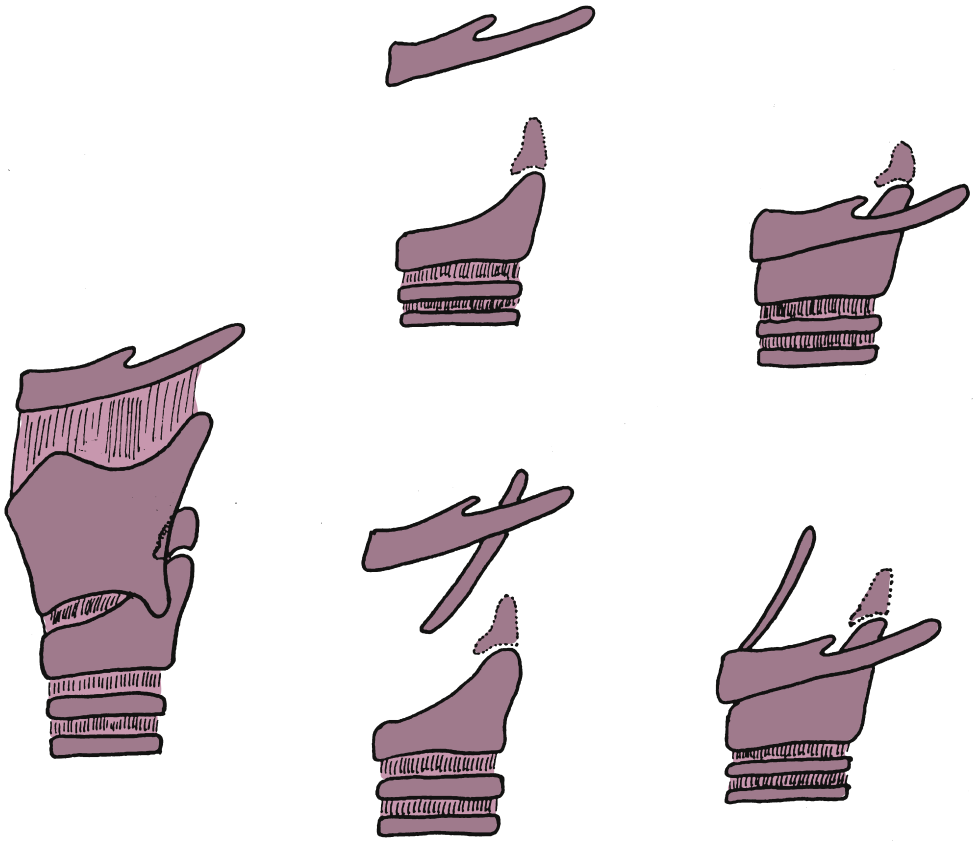

Fig. 12.6. The impaction sutures are tied tightly so that they approximate the cricoid complex to the hyoid bone. Care is taken to ensure adequate impaction and that the space previously taken by the thyroid cartilage and thyroid membrane is obliterated. *(Reprinted with permission from Pinel J, Cachin Y, Laccourreye H, editors. Cancers du Larynx [Indications, Thérapeutiques, Résultats]. Paris: Librairie Arnette, SFORL; 1980.)*

7. Once an uncuffed tracheostomy tube is tolerated in periods of recumbence and overnight, the tracheostomy tube is capped. If capping is tolerated for more than 24 hours, a laryngoscopy is performed to assure airway patency, and the patient is decannulated (usually postoperative days 12 to 14).
8. Swallowing therapy begins with placement of the speaking valve or cap. It includes exercises related to elevation of the base of the tongue, laryngeal elevation, and adduction. Therapy then includes supraglottic swallow techniques and the swallow/cough technique.
9. Registered calorie counts are begun with resumption of oral feeding. Approximately 2 to 3 days of therapy are necessary to resume adequate feeding, allowing patients to return home with assurance of adequate hydration and alimentation for healing.
10. Wasserman et al. found that aggressive inpatient dysphagia management and swallowing therapy achieve safe and functional swallowing prior to discharge without the excessive costs of PEG placement and home health services that are required with earlier discharge.

COMPLICATIONS OF SUPRAGLOTTIC LARYNGECTOMY

1. Acute complications
   a. Medical complications
      1) These include cardiac ischemia, bleeding ulcer, delirium tremens, and pneumothorax secondary to ruptured pulmonary blebs and are averted with proper patient selection and preoperative preparation.
   b. Aspiration pneumonia
      1) This is the most frequent complication. All patients are expected to aspirate.
      2) Aspiration can be minimized with proper surgical technique, offsetting the tongue base when closing the supraglottic laryngectomy, and placing well-approximated pexy sutures in CHP/CHEP.
      3) Proper patient selection, constant expectoration, aggressive pulmonary toilet, early ambulation, regular coughing, and intense swallow therapy with pre- and postswallow maneuvers to eliminate aspiration from autodigestive tract are crucial for prevention.
   c. Hemorrhage
      1) This complication is most often the result of inadequate hemostasis along the musculature and mucosa of the base of the tongue. Careful attention to hemostasis in this poorly visualized area should prevent this complication.
      2) Hemorrhage due to vessel blowout is prevented by the placement of active suction drains in the neck and early recognition of salivary fistulae. Contamination of major vessels by saliva requires urgent surgical intervention.
   d. Subcutaneous emphysema
      1) Poor reapproximation of the strap muscles to the subplatysmal flaps around the tracheostomy site results in buildup of subcutaneous emphysema and secretions in the wound when the patient coughs, resulting contamination of the dissected neck.
      2) This complication may be prevented by meticulous closure of the wound and the application of pressure dressings (Fig. 12.6).
   e. Neck infection
      1) This complication can be prevented by administering perioperative antibiotic prophylaxis for all patients and by carefully closing the dead space between the apron flap and the strap muscles (see Fig. 12.6).

f. Ruptured pexy sutures
   1) This complication has been described in patients with postoperative nausea or uncontrolled acid reflux. It is treated by returning the patient to the operating room and revising the closure.

2. Late complications
   a. Airway obstruction with failure to decannulate
      1) Arytenoid edema is the most common cause. It is managed with steroids and observation. Edema often resolves with time, allowing the patient to be decannulated at the first postoperative office visit.
      2) Mucosal flaps created during resection can scar and obstruct the neolarynx. Some surgeons describe treating this with endoscopic CO_2 laser excision of obstructing mucosa.[4]
   b. Delayed deglutition
      1) Most often this occurs due to poor patient selection or poorly performed surgery.
      2) Patients at greater risk include patients of advanced age with pre-existing dysphagia and aspiration, noncompliant patients, and previously radiated patients. Patients undergoing extended procedures that involve removal of some of the base of the tongue also have this problem. Such patients may benefit from early PEG tube placement.
   c. Regional recurrence
      1) This complication occurs when there has been a failure to adequately treat the neck. Bilateral neck dissection should be performed in patients with supraglottic cancers or supraglottic extension of glottic cancer. Central neck dissection with removal of paratracheal nodes should be performed for cancers with involvement of the subglottis.
   d. Delayed decannulation
      1) Some patients cannot tolerate decannulation prior to discharge and are not managed with aggressive inpatient swallowing therapy. The majority of these patients have significant postoperative edema after supracricoid laryngectomy, as detected on flexible laryngoscopy. Such patients are discharged to rehabilitation facilities with a nasogastric tube in place. These patients are then reevaluated at their first office visit with fiberoptic laryngoscopy. Most can be decannulated, are seen the same day by the swallowing therapy team, and are sent home on an oral diet.

Alternative Management Plan

1. Radiation is considered an alternative to surgery for early laryngeal cancer.
2. Transoral partial laryngeal resection has replaced horizontal partial laryngectomy in most centers.

DISCUSSION

Evidence-Based Medicine Questions

What is the overall survival and laryngectomy-free survival difference between conservation horizontal laryngeal surgery and organ preservation therapy for early T1–T2 cancers and T3 cancers, respectively?

In the VA laryngeal cancer study, 332 patients with advanced stage laryngeal cancer were randomized to treatment with chemoradiation therapy (CRT) and surgery with adjuvant RT. The majority of patients had T3 primaries. The 2-year overall survival was 68% in both groups, when patients who failed CRT were treated with salvage laryngectomy. The laryngeal preservation rate was 64%.[1] Surgical series show improved overall- and laryngectomy-free survival. Dufour et al. studied a series of 118 patients with T3 cancers treated by SCPL. The 3-year and 5-year actuarial-survival rates were 84% and 74%, respectively. The rate of local control at 3 and 5 years was 93.5% and 91.4%, respectively. Survival was significantly linked to local control. The laryngeal preservation rate was 89.8%.[5] Rizzotto et al. reported 5-year overall and disease-free survival rates of 95.6% and 90.9%, respectively, in a series of 399 patients.[4]

Editorial Comment

The primary objectives of treating patients with laryngeal cancer are to offer the best chance of cure and to preserve function relating to speech, swallowing, and airway. Even though total laryngectomy offers all of these benefits, it does have the major drawback of a permanent laryngostoma and having to manage and pay for speaking valves. Therefore, a surgeon should always consider conservation horizontal laryngeal surgery before simply opting for total laryngectomy in suitable patients.

Eugene N. Myers

Access the review questions and additional sources list online at http://www.expertconsult.com



REFERENCES

1. The VA Laryngeal Study Group. Induction chemotherapy plus radiation compared with surgery plus radiation in patients with advanced laryngeal cancer. N Engl J Med 1991;324:1685–90.
2. Hoffman H, Porter K, Karnell L, et al. Laryngeal cancer in the United States: changes in demographics, patterns of care, and survival. Laryngoscope 2006;116:1–13.
3. Laccourreye H, Laccourreye O, Weinstein G, et al. Supracricoid laryngectomy with cricohyoidopexy: a partial laryngeal procedure for selected supraglottic and transglottic carcinomas. Laryngoscope 1990;100:735–41.
4. Rizzotto G, Crosetti E, Lucioni M, et al. Subtotal laryngectomy: outcomes of 469 patients and proposal of a comprehensive and simplified classification of surgical procedures. Eur Arch Otorhinolaryngol 2012;269(6):1635–46.
5. Dufour X, Hans S, De Mones E, et al. Local control after supracricoid partial laryngectomy for "advanced" endolaryngeal squamous cell carcinoma classified as T3. Arch Otolaryngol Head Neck Surg 2004;130:1092–9.

REVIEW QUESTIONS

1. For which TNM stage cancers has mortality risen most drastically since the initiation of organ preservation therapy with concurrent chemoradiotherapy?
   a. T3N0M0
   b. T2N1M0
   c. T1N2M0
   d. T4N1M0

2. When performing selective treatment of the ipsilateral neck for supraglottic cancers, what is the recurrence rate in the untreated contralateral neck? What is the recurrence rate in those necks treated by bilateral selective neck dissection?
   a. 20% and 9%, respectively
   b. 40% and 20%, respectively
   c. 40% and 10%, respectively
   d. 30% and 15%, respectively

3. What amount of involvement of the base of the tongue contraindicates horizontal partial laryngeal procedures?
   a. 1 cm
   b. 2 cm
   c. 3 cm
   d. 0.5 cm

4. What amount of subglottic extension can be accommodated by supracricoid laryngectomy?
   a. 15 mm
   b. 20 mm
   c. 10 mm
   d. 5 mm

5. What maneuver is necessary in preventing intractable aspiration after supraglottic laryngectomy?
   a. Preservation of the epiglottis
   b. Preservation of the hyoid bone
   c. Creating a roof for the neolarynx
   d. Approximation of the mucosa of the base of the tongue to the perichondrium

ADDITIONAL SOURCES

Barbosa M, Araújo Jr VJ, Boasquevisque E, et al. Anterior vocal commissure invasion in laryngeal carcinoma diagnosis. Laryngoscope 2005;115:724–73.

Medina J, Ferlito A, Robbins K, et al. Central compartment neck dissection in laryngeal cancer. Head Neck 2011;33:746–52.

Spriano G, Pellini R, Romano G, et al. Supracricoid partial laryngectomy as salvage surgery after radiation failure. Head Neck 2002;24(8):759–65.

Wasserman T, Murry T, Johnson J, et al. Management of swallowing in supraglottic and extended supraglottic laryngectomy patients. Head Neck 2001;23(12):1043–8.

Weber P, Johnson J, Myers E. The impact of bilateral neck dissection on pattern of recurrence and survival in supraglottic carcinoma. Arch Otolaryngol Head Neck Surg 1994;20:703–6.

13 Vertical Partial Laryngectomy

David Eibling

INTRODUCTION

Vertical partial laryngectomy (VLP) is used for cancers extending to or crossing the anterior commissure. Hence the resection as typically performed entails removal of several millimeters of the contralateral vocal cord as well as the midline portion of the thyroid cartilage. This procedure is not actually a "hemi" laryngectomy as it has been termed traditionally, since: the cricoid ring remains intact, the hyoid bone is uninvolved, and usually typically only a portion of the arytenoid is resected.

"Frontolateral partial laryngectomy" or "vertical partial laryngectomy" is a more accurate designation for the procedure. The procedure removes all or a portion of one vocal cord, usually in continuity with the anterior commissure and its ligamentous attachment to the thyroid cartilage. The removal of at least the vocal process (or even the entire) ipsilateral arytenoid is required. In addition, sufficient tissue must be retained or brought in as local flaps to maintain an adequate airway, and the voice is always adversely affected.

The technique was popularized in the United States by Dr. Joseph Ogura's group in the early 1970s (see Additional Sources for original references). At that time, imaging and radiotherapy techniques were not as precise as they are currently; hence many surgeons preferred surgical excision to radiotherapy for cancers encroaching on the anterior commissure. Detection of persistent disease following radiotherapy is often delayed, requiring a total laryngectomy. A report from our department indicated that more larynges were preserved by initial partial laryngectomy for early glottic cancer than with radiotherapy with surgical salvage.[1]VPL is performed for bulky or extensive early-stage glottic carcinoma, which have a reduced chance of cure with radiotherapy.[2]

The widespread use of transoral endoscopic laser surgery, increased numbers of surgeons competent in performance of supracricoid laryngectomy, improved imaging, precise targeting of radiation therapy, and more recently the introduction of robotic surgery have decreased the use of VPL in the treatment of glottic cancer.

Laccourreye et al. compared outcomes of a series of patients with early glottic carcinoma managed with supracricoid laryngectomy with VPL, noting improved disease-free and survival benefit with the group treated with supracricoid laryngectomy.[3]

As noted previously, many recently trained otolaryngologists have no experience with VPL in their residency. Nonetheless, the procedure remains standard in locales that do not have access to these newer modalities or for surgical salvage in selected cases following laser resection or radiation for early glottic cancers.

KEY OPERATIVE LEARNING POINTS

1. VLP for early glottic cancer has largely been replaced by endoscopic laser excision or supracricoid laryngectomy.
2. It is ideal for bulky glottic cancers that involve the anterior commissure and are confined to no more than one-third of the contralateral vocal cord with less than 1 cm of subglottic extension (Fig. 13.1).
3. As in other partial laryngectomy surgical procedures, accurate staging and careful attention to details of the procedure are paramount, especially if it is to be used as a salvage procedure.

PREOPERATIVE PERIOD

History

1. History of present illness
   a. Hoarseness is almost always the presenting symptom for early glottic cancer. Symptoms of otalgia, dyspnea, or dysphagia suggest a more advanced stage, and prompt careful evaluation is needed to ensure that the appropriate surgical procedure is selected.
   b. The history, laryngeal photographs, and imaging from referring otolaryngologists are helpful but do not replace real-time examination in both the clinic and the operating room.
   c. Diagnosis is achieved with appropriate examination and biopsies. If a biopsy was performed at another institution, most surgeons require that the pathology slides be obtained for re-review by in house pathologists.
   d. The site and stage of the cancer must be accurately determined.
2. Past medical history
   a. Prior treatment: Was this cancer previously treated by endoscopic excision or radiation therapy? Prior radiation therapy is not a contraindication, although postoperative wound complications may be more likely.[4]
   b. Medical illnesses: Many patients with cancer of the head and neck have significant comorbidities, which must be identified prior to scheduling surgery.
      1) Is the patient able to tolerate a surgical procedure?
      2) Is the patient able to tolerate aspiration; a common consequence of the surgery?
   c. Surgery—particularly any prior laryngeal or tracheal surgery
   d. Eliciting a history of substance abuse is important, particularly a history of alcohol dependence, which may lead to postoperative alcohol withdrawal syndrome if not recognized preoperatively. Smoking has been demonstrated to impair healing; hence patients should be encouraged to stop smoking.[5] Nicotine withdrawal can be managed with transdermal nicotine release patches in the perioperative period.

Physical Examination

1. Awake fiber-optic or telescopic laryngeal endoscopy: Awake endoscopy is the most important part of the examination, as it affords accurate assessment of vocal cord mobility as well as an estimate of the location, size, and extent of the cancer.
2. Oral cavity: It is important to rule out second primary cancers.
3. Neck: Palpation of the neck may reveal adenopathy or direct extension of cancer into the soft tissue anteriorly.

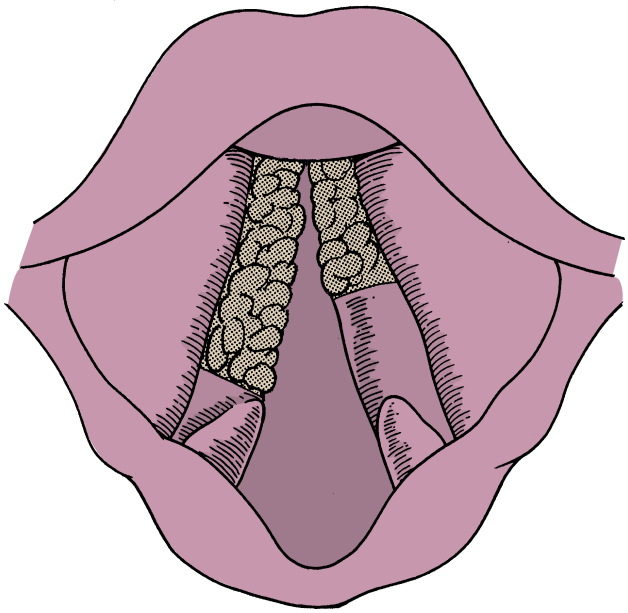

Fig. 13.1. Maximal size of a cancer that can be removed by frontolateral hemilaryngectomy involving entire left vocal cord and the anterior third of the right cord.

Imaging

1. Although theoretically not necessary, most surgeons favor imaging to assist with staging the patient with a bulky cancer of the glottis, particularly since more than one-third of clinically staged T2 glottis cancers are found to be more extensive on pathologic examination.[6]
2. Thin-cut axial computed tomographic images of the larynx may provide important information regarding tumor extension beyond the confines of the endolarynx. A chest radiograph or computed tomography (CT) scan is required to rule out a second primary cancer of the lung.

Indications

1. T1-2 cancer of the glottis
2. Impaired mobility or fixation of the vocal cord suggests invasion into the vocalis muscle and possibly a higher stage. Extension to the arytenoid and anterior commissure may require resection of additional tissue, such as more than half of the contralateral vocal cord, which may impair adequate glottic reconstruction (see Fig. 13.1).
3. The cancer does not extend onto the cricoid cartilage (1 cm anteriorly, 0.5 cm posteriorly).
4. Vertical partial laryngectomy (VPL) is an ideal salvage procedure for early cancers not controlled by primary radiotherapy or CO_2 laser. However, extensions of the standard procedure may lead to undesirable morbidity, particularly in previously treated patients.

Contraindications

1. Medical comorbidities with increased risk relating to general anesthesia and inability to tolerate mild aspiration. In these situations radiation therapy would likely be the preferred modality.
2. Cancer extending beyond the limits of resection to involve more than one-third of the contralateral vocal cord, entire ipsilateral arytenoid, or mucosa on cricoid cartilage.

Preoperative Preparation

1. Discontinue anticoagulants 3 to 5 days preoperatively.
2. Mark the side of the cancer on the skin, and confirm with preoperative endoscopy prior to incising the skin.
3. Administer perioperative antibiotics.

Consent

1. The patient must understand that the quality of his or her voice will never be normal, and that it may be substantially worse than preoperatively.
2. VPL may lead to swallowing impairment due to inadequate laryngeal closure during deglutition. Patients must know that swallowing function may worsen with time due to age-associated loss of pharyngeal muscle tone and lung function.[7]
3. If excessive tissue is removed, the airway may be borderline or inadequate, even to the extent of requiring a long-term tracheostomy.
4. Many surgeons specify in the consent process that if the extent of the tumor is found to be greater than anticipated at the time of surgery, a total laryngectomy will be performed at the same sitting.

OPERATIVE PERIOD

Anesthesia

General anesthesia is preferred.

Positioning

Supine: The patient is positioned the same as any anterior neck procedure, with the head extended on a shoulder roll.

Perioperative Antibiotic Prophylaxis

First generation cephalosporin if not allergic to penicillin
Clindamycin if allergic to penicillin

Monitoring

Routine EKG, pulse oximetry, capnography, Foley catheter for monitoring

Instruments and Equipment to Have Available

1. Basic head and neck set
2. Cuffed tracheostomy tube: Some surgeons place a temporary flexible endotracheal tube through the tracheostomy site and replace it with the tracheostomy cannula at the end of the procedure. Others place a cuffed tracheostomy tube initially to avoid changing tubes later.
3. Oscillating or sagittal power saw to cut cartilage

Key Anatomic Landmarks

1. Thyroid cartilage midline: The incision through the cartilage is usually several millimeters lateral to the midline on the side *opposite* to the cancer.
2. The anterior commissure is a critical landmark for partial laryngeal surgery, as well as its relationship to the cancer being key for surgical planning.
3. Cricothyroid membrane: The inferior margin of the resection is the superior edge of the cricoid; hence the inferior edge of the cricothyroid membrane must be identified early.
4. Posterior edge of the thyroid ala: A strip of cartilage is retained posteriorly that connects the inferior and superior cornua of the thyroid cartilage.

BOX 13.1 Steps in Hemilaryngectomy

INDICATIONS

T1 and T2 bulky cancers of the membranous true vocal cord
T1 and T2 cancers that cross the anterior commissure
Normal or slightly impaired vocal cord mobility
No or minimal involvement of the supraglottis
Subglottic extension less than 5 mm posteriorly and 10 mm anteriorly

CONTRAINDICATIONS

Extensive involvement of the body of the arytenoid
More than one-third of the contralateral vocal cord involved (consider supracricoid partial laryngectomy)

TECHNICAL POINTS

Administer perioperative antibiotics.
Re-endoscope the patient; make endoscopic incisions across the vocal cords if possible to accurately define the margin of resection.
Use a headlight.
A tracheostomy may be made before or after anesthesia is induced.
Make a horizontal skin incision over the thyroid ala.
Elevate flaps superiorly and inferiorly while avoiding the tracheostomy tract.
Incise the perichondrium from the thyroid notch down the midline over the cricothyroid membrane.
Elevate the perichondrium with the attached overlying strap muscles.
Mark the cartilage incisions while retaining a 3- to 5-mm posterior strip.
Cut the cartilage with a sagittal saw.
Incise the perichondrium along the superior border of the thyroid ala.
Incise across the petiole of the epiglottis. This will provide a panoramic view of the glottis.
Incise the cricothyroid membrane along the superior aspect of the cricoid cartilage.
Extend the incision(s) across the contralateral true vocal cord (at previously marked margin). Be careful to preserve adequate contralateral vocal cord for reconstruction.
Using hooks, open the thyroid ala like a book.
STOP, and carefully evaluate the lesion and determine the area to be excised.
Excise the tumor and ipsilateral vocal cord by incising along the apex of the aryepiglottic fold down around the arytenoid or through the vocal process of the arytenoid, depending on the posterior extent of the tumor.
Orient and examine the surgical specimen, and select sites for frozen section examination of the margins. Mark the specimen to orient it for the pathologist.
Obtain hemostasis.
Suture the contralateral vocal cord to the anterior end of the remaining cartilage or to the external perichondrium.
Pull pyriform mucosa over posterior cricoid to add bulk to posterior glottis if arytenoidectomy is required.
If excessive resection of contralateral vocal cord is required, reconstruct by doing an epiglottopexy.
Insert a nasogastric tube for feeding.
Close the perichondrium with absorbable sutures.
Inferiorly based or bipedicled muscle flaps may be used to reconstruct the glottis to improve voice quality but are probably not necessary.
A cricopharyngeal myotomy is not required.
Close the wound in layers over a drain, making sure that the tracheostomy wound is separated from the primary incision site.
Apply a neck dressing.

POSTOPERATIVE CARE

Antibiotics are continued for 24 h postoperatively.
Nasogastric feedings can begin as soon as the patient has bowel sounds.
The tracheostomy tube cuff can be deflated when the patient tolerates his/her secretions.
Initiate swallowing when patient swallows saliva, often following decannulation.
The larynx will appear abnormal, with areas of granulation tissue for 4 to 6 weeks, so repeat biopsies should be delayed until re-epithelization is complete.

Prerequisite Skills

1. Endoscopic as well as open head and neck surgical skills
2. Knowledge of the three-dimensional anatomy of the larynx and particularly the anterior glottis

Operative Risks

1. Airway risks are minimized by the routine placement of a tracheostomy.
2. Failure to recognize that the cancer has extended beyond the limits of resection is problematic, since extending the resection may result in an inadequate airway or chronic aspiration. The most likely preferred solution in most cases is to convert to either supracricoid laryngectomy or total laryngectomy.

Surgical Technique

- The side of the cancer should be marked on the skin of the neck before induction of anesthesia, noted at the preoperative briefing, and confirmed again at endoscopy.
- I often make an incision under endoscopic control in the contralateral vocal cord at the point of the contralateral margin, as this location may be difficult to visualize accurately when the larynx is open.
- I perform a tracheostomy at the beginning of the procedure in all patients. The tracheostomy should be placed sufficiently inferiorly in the neck to avoid contamination of the surgical wound with tracheal secretions during the postoperative period. The tracheostomy stabilizes the patient and eliminates having to work around an endotracheal tube in the operative field. It should be noted that Laccourreye's group has not routinely used a tracheostomy and has reported no untoward consequences in 25 years of experience, although their surgical technique differs.[3]
- The steps in the procedure are presented in Box 13.1. The technique illustrated is that of thyroid cartilage resection, which is my preferred technique and also the preferred technique of our group.
- A horizontal incision is placed in a major skin crease over the thyroid ala (Fig. 13.2). An apron incision is not generally used because the likelihood of extending the procedure to a total laryngectomy is exceedingly low.
- Subplatysmal flaps are elevated superiorly and inferiorly while avoiding entry into the tracheostomy tract. If the surgical wound communicates with the tracheostomy, it should be separated with several absorbable sutures placed between the strap muscles and the subcutaneous tissue at the completion of the procedure to avoid contamination of the laryngectomy wound with tracheal secretions.

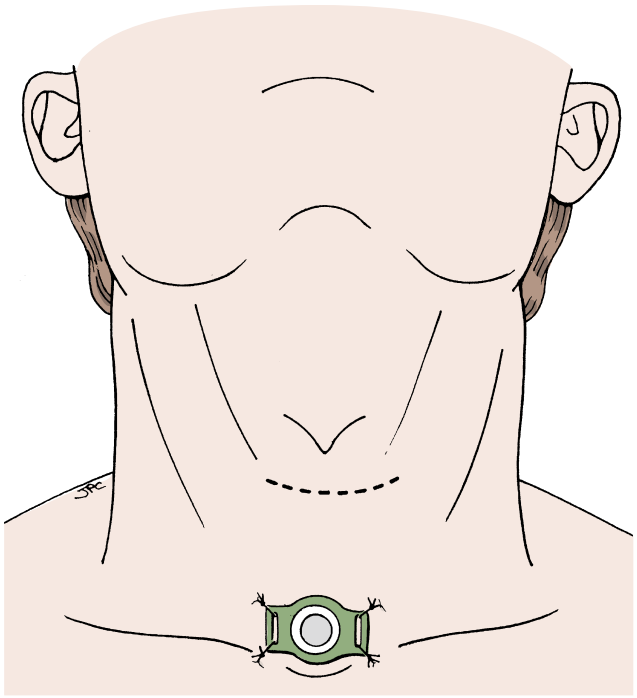

Fig. 13.2. Incision for VLP. Care should be taken to ensure separation of the tracheostomy incision from that required for the partial laryngectomy.

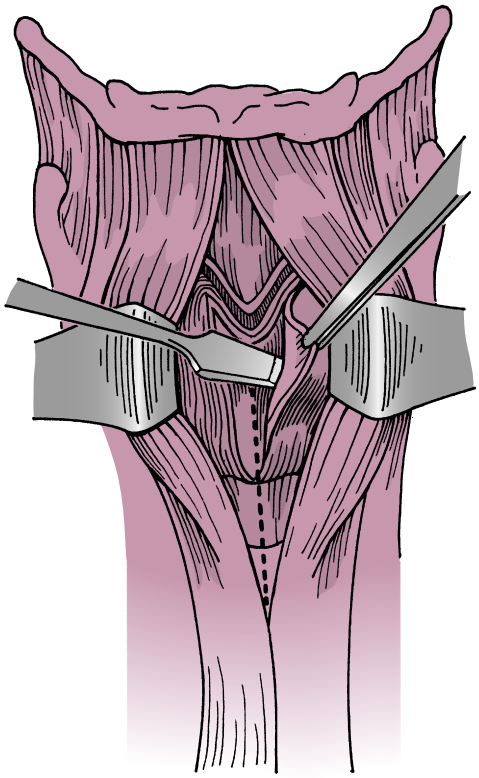

Fig. 13.3. Elevation of the perichondrium with the overlying strap muscles.

- The fascia is incised in the midline between the strap muscles and carried down to the level of the thyroid cartilage and inferiorly over the cricoid cartilage.
- The perichondrium is incised along the superior margin of the thyroid cartilage and then elevated with the attached overlying strap muscles to the posterior margin of the thyroid ala on the side of the tumor (Fig. 13.3). The perichondrium is incised along its attachment to the inferior portion of the thyroid ala to permit elevation laterally. Every attempt should be made to preserve the perichondrium because it is a component of the reconstruction.
- The cancer usually extends at least as far as the anterior commissure; hence the vertical incision in the thyroid cartilage must be made just lateral to the midline on the side *opposite* the cancer to ensure adequate resection of the anterior commissure as a deep margin of resection with the specimen.
- A posterior vertical cartilage cut is made on the side of the tumor, retaining a 3- to 5-mm-wide bridge of cartilage between the inferior and superior cornua of the thyroid cartilage (Fig. 13.4).
- The saw cuts should be made using a powered oscillating saw with a small right-angled blade through cartilage only and not through the underlying mucosa.
- Entering the ventricle on the contralateral side through the cartilage cut (immediately deep to the cartilage cut), the larynx is exposed by cutting across the petiole of the epiglottis. This maneuver facilitates visualization of the entire glottis and of the incision in the vocal cord made at endoscopy to mark the limits of resection (Fig. 13.5).
- The cricothyroid membrane is then incised just above the cricoid cartilage (Fig. 13.6). The true vocal cord is transected to connect the inferior and superior incisions. The contralateral vocal cord is cut at right angles (Fig. 13.7A and B) to avoid sacrificing excessive tissue.
- Once the contralateral vocal cord (or the anterior commissure) has been divided, the cartilage halves are spread open like a book, and, using scissors, the incision is extended across the false vocal cord on the involved side. This is done by placing one blade of heavy Mayo scissors within the lumen and above the ipsilateral thyroid ala; several incisions are made to open the larynx for visualization of the posterior extent of the cancer.
- The inferior incision is extended posteriorly along the superior margin of the cricoid cartilage on the side of the cancer while taking care to ensure that an adequate margin has been resected inferior to the cancer (Fig. 13.8).
- The incisions are extended, and the specimen is resected. The entire arytenoid may need to be included with the resection. There will be some bleeding in this part of the procedure, and it is important to achieve hemostasis for complete visualization of the lesion.
- At the completion of the resection, hemostasis is obtained and the specimen is carefully oriented and marked for the pathologist and examined using frozen sections to confirm negative margins.
- Pyriform mucosa should be advanced over the posterior portion of the cricoid to resurface the posterior larynx, particularly if the arytenoid has been resected.
- The contralateral true vocal cord (TVC) must be reattached to the anterior surface of the cartilage with nonabsorbable sutures, except in the unlikely situation in which the ligamentous attachment of the contralateral anterior commissure has been left intact (Fig. 13.9).
- If it is apparent that much of the least involved vocal cord required resection, the surgeon has a number of options. One is to convert the procedure to a supracricoid laryngectomy

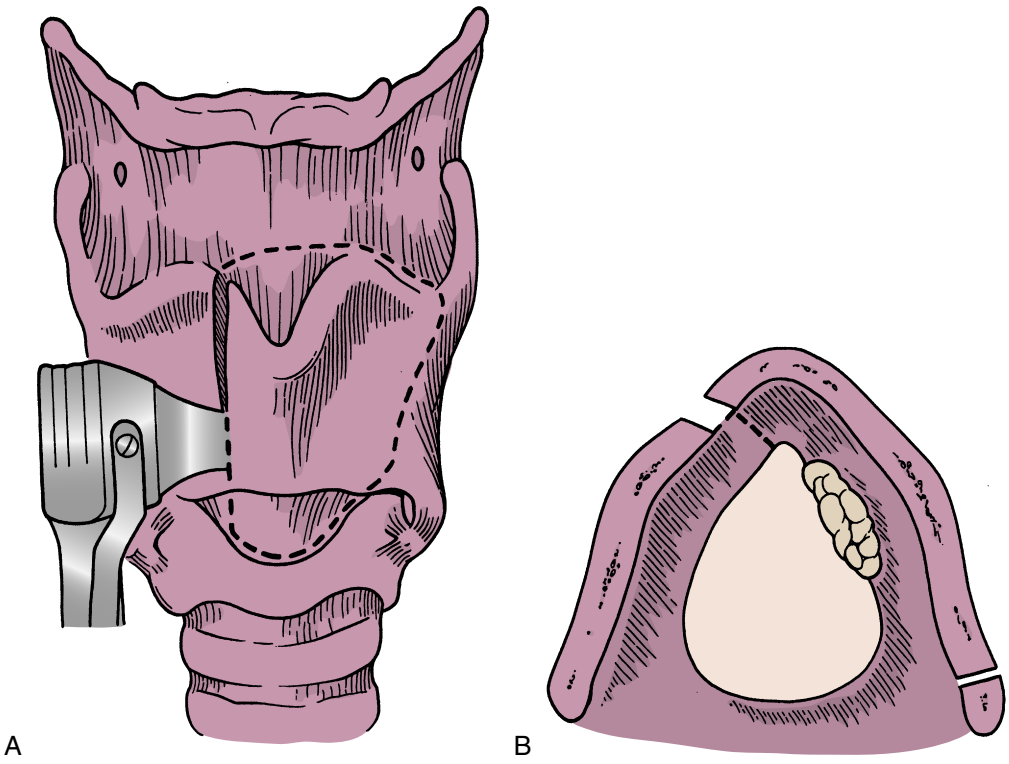

Fig. 13.4. A, Incision of cartilage for a left frontolateral hemilaryngectomy and **B,** the planned incision in the vocal cord. To remove the entire anterior commissure, note the incision in the cartilage just to the right of the midline. A 3- to 5-cm-wide strip of cartilage is maintained posteriorly. *(Redrawn from Pearson BW, Donald PJ: Larynx. In Donald PJ [ed]: Head and Neck Cancer: Management of the Difficult Case. Philadelphia, PA, WB Saunders, 1984, pp 93-148.)*

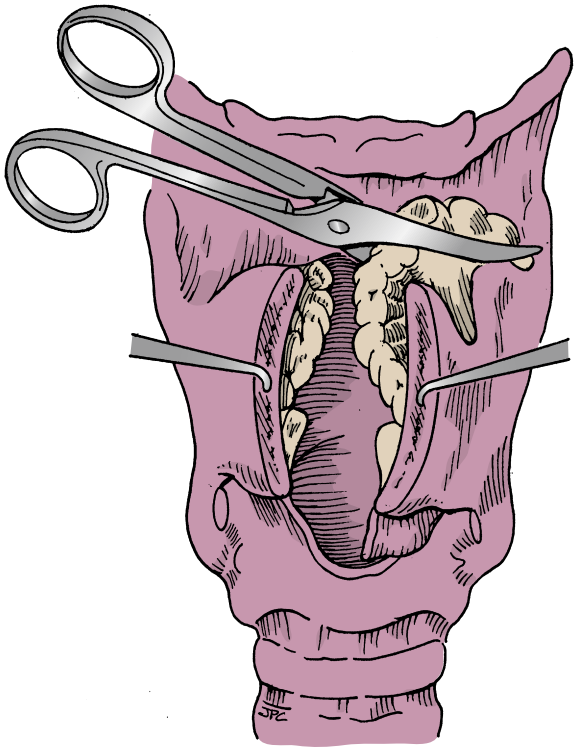

Fig. 13.5. Scissors are used to extend the incision across the preepiglottic space and the false vocal cord to expose the cancer.

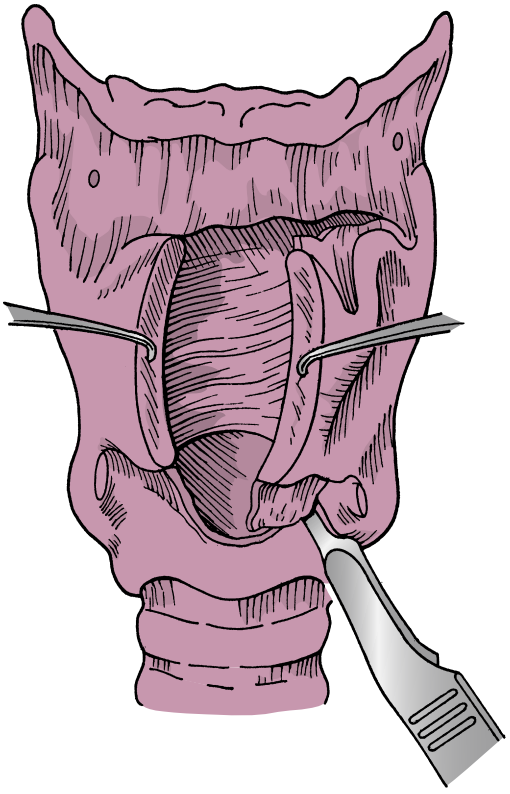

Fig. 13.6. The cricothyroid membrane is opened just superior to the cricoid cartilage to verify that the cricoid is not involved.

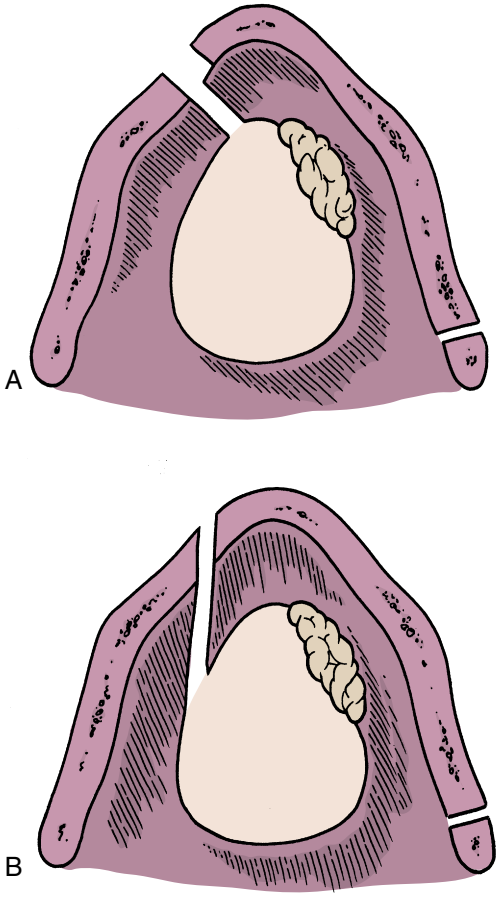

Fig. 13.7. Proper **(A)** and improper **(B)** angles of the cut through the vocal cord. Note the excess sacrifice of tissue caused by improper angulation of the incision through the vocal cord.

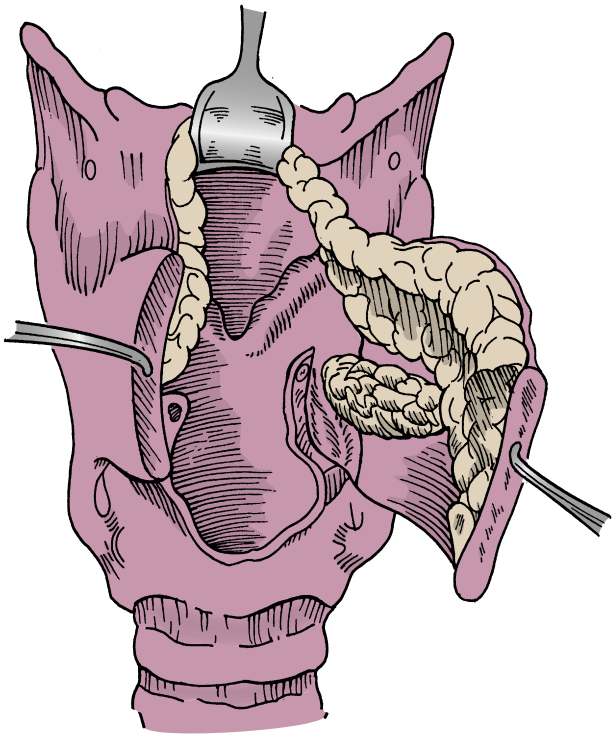

Fig. 13.8. Resection of the cancer by continuing the incision superiorly through the vocal process and vocal cord posterior to the cancer. The arytenoid may be taken at this step.

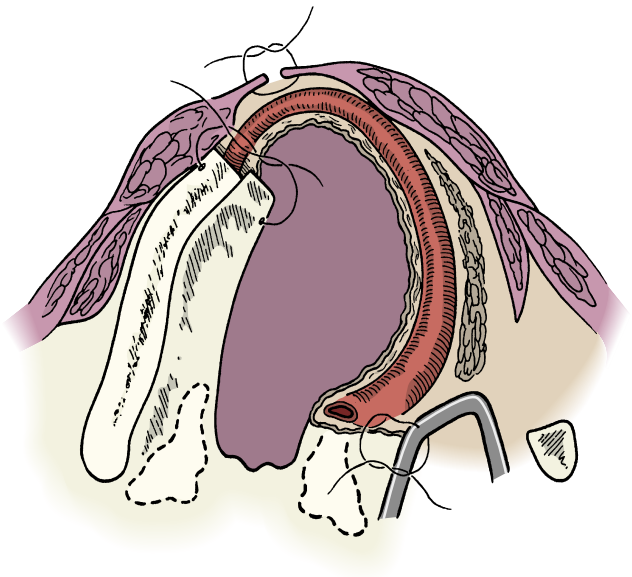

Fig. 13.9. Reattachment of the vocal cord remnant to the thyroid ala.

(see Chapter 12). Our favorite option is to use the epiglottis to reconstruct the larynx (epiglottopexy) (Fig. 13.10A and B); the epiglottis provides both structural support to prevent glottic stenosis as well as a mucosalized anterior glottis. Although this technique preserves an adequate glottic airway, it results in a breathy voice and occasionally unacceptable aspiration. A third alternative is to use a keel, a technique with which I have no experience. The final option is a total laryngectomy. A nasogastric tube is inserted and secured for postoperative feeding.

- The anterior perichondrium and the strap muscles are closed with absorbable sutures.
- A suction drain is placed subcutaneously in the neck.
- The neck incision is closed, with care taken to ensure that the wound does not communicate with the tracheostomy incision.

Common Errors in Technique

1. Wrong-side surgery: Since the cancer is not visualized until after the larynx is opened, there is a risk of opening the wrong side. As a precaution, the skin of the neck should be marked preoperatively on the correct side, and the side should be confirmed by laryngoscopy prior to the procedure. Posting preoperative photographs also may be helpful to ensure proper orientation.
2. Cutting the cartilage and vocal cord at an incorrect angle: This error sacrifices excessive normal vocal cord tissue and creates substantial difficulties in reconstruction (see Fig. 13.7).
3. Failure to advance pyriform mucosa over the posterior glottis in cases where the entire arytenoid is resected will lead to increased aspiration.
4. Inadvertent communication between the tracheostomy wound and the surgical site will lead to soiling of the partial laryngectomy wound with tracheal secretions, prolonged healing, and possible loss of cartilage due to infection.

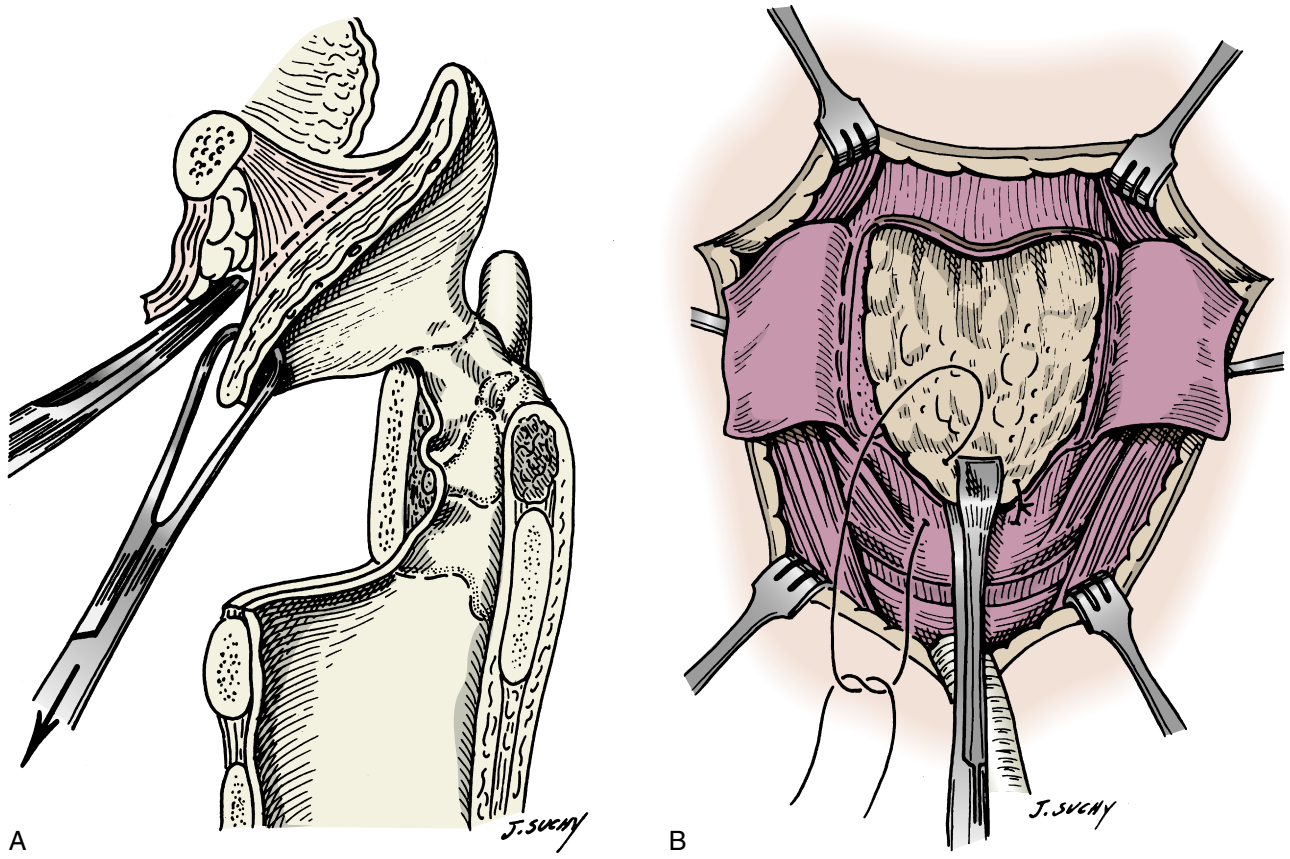

Fig. 13.10. Epiglottopexy to reconstruct anterior glottis. A, The lingual surface of the epiglottic cartilage is undermined in the subperichondrial plane and pulled inferiorly. **B,** The epiglottis is sutured to the cricoid cartilage to reconstruct the anterior lumen of the larynx. This creates an open anterior glottis with a suboptimal and breathy voice.

POSTOPERATIVE PERIOD

Postoperative Management

1. The tracheostomy cuff should remain inflated for several days to reduce aspiration of secretions. Thereafter, test deflation of the cuff with downsizing, plugging, and decannulation can occur in an orderly sequence.
2. Nasogastric (NG) tube feeding should be administered until the patient has been decannulated and can swallow without aspirating.
3. Resumption of anticoagulants/antiplatelet drugs is required.

Complications

1. Hemorrhage: Although unusual, this can occur from larger vessels entering the posterior endolarynx. If bleeding occurs, the wound will need to be opened and the perichondrial closure taken down to access the bleeding site.
2. Wound infection: This is best prevented by isolating the tracheostomy incision from the surgical wound as described previously.
3. Vocal cord paralysis: Preservation of the posterior strip of thyroid cartilage and avoidance of dissection near the entry point of the recurrent laryngeal nerve posterior to the cricothyroid joint will prevent this complication

Alternative Management Plan

1. Endoscopic transoral laser excision of early glottic cancer has largely replaced VPL.
2. Total laryngectomy
3. Radiation therapy
4. Newer, more precise radiotherapeutic techniques enhance the ability of radiotherapy to control early glottic cancer that involves the anterior commissure. Accurate staging is a prerequisite, and close cooperation between the head and neck surgeon and radiotherapist is critical. If voice quality is a concern, radiotherapy is most likely the optimal choice.
5. Supracricoid partial laryngectomy with cricohyoidoepiglottopexy is used for more advanced cancer involving both vocal cords. Recovery is more delayed; however, the airway is better than that obtained following extensive resection of both vocal cords. Long-term swallowing function may be better than that obtained by extended VPL reconstructed with epiglottopexy.
6. In the future robotic VPL may be feasible utilizing newer flexible surgical robot devices that facilitate laryngeal surgical approaches that were not feasible with traditional multiarm robotic instrumentation.[8]

DISCUSSION

Evidence-Based Medicine Question

Is vertical partial laryngectomy as effective as supracricoid partial laryngectomy in the management of advanced T2 glottic cancer?

In 2000 Laccourreye et al. compared outcomes of a series of patients with early glottic cancer managed with supracricoid partial laryngectomy with a group managed with VPL. He reported improved disease-free survival with the group treated with supracricoid laryngectomy.

Editorial Comment

Vertical partial laryngectomy (VPL), although now seldom used since the introduction of transoral CO_2 laser microsurgery, remains an important procedure for early glottic cancers in centers that lack radiation or laser facilities, and for surgical salvage of radiation or laser failures.

Johan Fagan

Access the review questions and additional source list online at http://www.expertconsult.com

REFERENCES

1. Rothfield RE, Johnson JT, Myers EN, et al. The role of hemilaryngectomy in the management of T1 vocal cord cancer. Arch Otolaryngol Head Neck Surg 1989;115:677–680.
2. Gilbert RW, Birt D, Shulman H, et al. Correlation of tumor volume with local control in laryngeal carcinoma treated by radiotherapy. Ann Otol Rhinol Laryngol 1987;96:514–518.
3. Laccourreye O, Laccourreye L, Garcia D, et al. Vertical partial laryngectomy versus supracricoid partial laryngectomy for selected carcinomas of the true vocal cord classified as T2N0. Ann Otol Rhinol Laryngol 2000;109:965–971.
4. Yiotakis J, Stavroulaki P, Nikolopoulos T, et al. Partial laryngectomy after irradiation failure. Otolaryngol Head Neck Surg 2003;128:200–209.
5. Fiorini FR, Deganello A, Larotonda G, et al. Tobacco exposure and complications in conservative laryngeal surgery. Cancers (Basel) 2014;6:1727–1735.
6. Pillsbury HRC, Kirchner JA. Clinical vs. histopathologic staging in laryngeal cancer. Arch Otolaryngol 1979;105:157–159.
7. Bagwell K, Leder SB, Sasaki CT. Is partial laryngectomy safe forever. Am J Otolaryngol 2015;36(3):437–441.
8. Friedrich DT, Scheithauer MO, Greve J, et al. Potential advantages of a single-port, operator-controlled flexible endoscopic system for transoral surgery of the larynx. Ann Otol Rhinol Laryngol 2015;124:655–662.

REVIEW QUESTIONS

1. Landmarks for the position of the anterior commissure are
   a. 1 cm superior to the inferior border of the cricoid
   b. Halfway between the inferior border of the thyroid cartilage and the thyroid notch
   c. 3 cm anterior to the posterior edge of the thyroid cartilage
   d. 1 mm below the inferior aspect of the thyroid notch
   e. 1 mm above the inferior edge of the thyroid cartilage

2. The maximal subglottic extent of a tumor amenable to VPL is
   a. 1 cm anteriorly and 0.5 cm posteriorly
   b. At the superior margin of the first tracheal ring
   c. 3 mm
   d. 1 cm on the side of the tumor and 0.5 cm on the contralateral side
   e. 6 cm above the carina

3. Early glottic cancer can be managed by
   a. VPL
   b. SPL
   c. Transoral laser excision
   d. Radiotherapy
   e. All of the above

ADDITIONAL SOURCE

Biller HF, Ogura JH, Pratt LL. Hemilaryngectomy for T2 glottic cancers. Arch Otolaryngol 1971;93:238–243. (This is the classic article describing the procedure as presented in this chapter).

14 Supracricoid Partial Laryngectomy

Miriam N. Lango

INTRODUCTION

Historically, a variety of partial laryngectomies have been developed to preserve speech and avoid the permanent stoma associated with the classical total laryngectomy. The supracricoid partial laryngectomy was developed to manage selected glottic and/or supraglottic cancers.[1,2] The procedure can be modified based on the extent of supraglottic involvement; otherwise, supracricoid laryngectomy is distinguished by a standardized approach that has been associated with exceptionally low rates of local cancer recurrence.[1-4] However, proper patient selection is critical. Careful preoperative mapping of the extent of the cancer is necessary to determine whether this operation is appropriate. This procedure may not be undertaken without the patient providing consent for a total laryngectomy should it be needed based on intraoperative frozen section assessment of the resection margins, because as in all cancer operations, it is not acceptable to perform the operation and knowingly leave cancer behind.

Although a permanent tracheostomy is not needed, a tracheotomy is required for several weeks during the postoperative period. During the recovery, patients experience copious secretions through the tracheostomy, some of which lodge in the lungs potentially causing pneumonia. Patients with chronic obstructive lung disease from a long history of smoking may not be suitable candidates for this operation. Over time, the secretions lessen, as patients heal and swallowing function improves, and the copious secretions that were previously expelled through the tracheostomy are swallowed. Once the tracheostomy is removed, patients learn to use a voice, which although it does not resemble their voice prior to the cancer, is understandable. Ultimately, patients with a partial supracricoid laryngectomy report a better quality of life than those who had their entire larynx removed. The final outcome makes the difficult road to recovery well worthwhile.

However, an alternative to a supracricoid partial laryngectomy should be strongly considered for patients with an active mental health or substance abuse issue or lack of motivation that would impede recovery and preclude rehabilitation therapy compliance. The recovery period after a total laryngectomy is usually far less arduous or protracted. Often, an oral diet may be resumed, without aspiration, within a matter of weeks. In addition, some patients favor an unrestricted oral diet over lung-powered vocalization. Such priorities and preferences should be considered in making treatment recommendations.

KEY OPERATIVE LEARNING POINTS

1. T1-T2, selected T3N0 glottic and/or supraglottic squamous cell carcinomas with involvement of the anterior commissure or petiole of the epiglottis are often good candidates for a supracricoid partial laryngectomy.
2. Glottic cancer with limited supraglottic extension may be reconstructed using a cricohyoidepiglottopexy (CHEP); cancers requiring resection of the epiglottis are reconstructed using a cricohyoidopexy (CHP).
3. Patients with cancer of the larynx after failure of narrow field radiation may be effectively salvaged using a supracricoid partial laryngectomy; however, the swallowing function of patients who received definitive wide field radiation or chemoradiation for cancer of the larynx is poor, and a total laryngectomy should be recommended for salvage.
4. The function of the residual larynx following a supracricoid partial laryngectomy depends on the preservation of at least one cricoarytenoid unit, which opposes the arytenoid against the residual epiglottis or base of the tongue during deglutition, thus protecting the airway.
5. Although select T3 laryngeal cancers with vocal cord fixation are suitable for supracricoid partial laryngectomy, concomitant fixation to the cricoid is a contraindication due to the inability to both preserve a functional cricoarytenoid unit and obtain negative surgical resection margins.
6. Reapproximation of the cricoid to the epiglottis or the base of the tongue is a key technical step and is contingent upon the proper placement of pexy sutures around the cricoid and hyoid; the repair is reinforced by the meticulous closure of the strap muscles.
7. A supracricoid partial laryngectomy is not undertaken in the absence of consent for a total laryngectomy, should it be come necessary.

PREOPERATIVE PERIOD

History

1. History of present illness
   a. Hoarseness
   b. Stridor
   c. Shortness of breath
   d. Mass in the neck
   e. Weight loss
   f. History of pneumonia
2. Past medical history
   a. Prior treatment, especially radiation, and tumor stage
   b. Medical illness and functional status
   c. Prior laser surgery does not preclude supracricoid partial laryngectomy (SCPL)
   d. Social history of smoking and/or alcohol use; history of other substance use
   e. Family history
   f. Medications
      1) Antiplatelet drugs, thyroid hormone replacement
   g. Exercise tolerance

Physical Examination

A complete preoperative assessment is necessary to determine whether the patient is an appropriate candidate for a supracricoid partial laryngectomy. This assessment is necessary for patient counseling and involves a careful preoperative physical examination, including laryngoscopy, imaging, and mapping biopsies obtained during a laryngoscopy performed under general anesthesia. Nevertheless, intraoperative findings during the partial laryngectomy such as positive intraoperative frozen resection margins may require conversion to a total laryngectomy. An evaluation for a supracricoid partial laryngectomy starts initially with a careful physical examination.

A complete examination of the head and neck should be performed with particular attention to the following:

1. General health, vitality, appropriate and cooperative behavior, and evidence of frailty should be noted.
2. Pulmonary status should be assessed, as the patient has to cope with some aspiration
3. Voice quality, articulation, hoarseness, or stridor are noted.
4. In the oral cavity, exclude second primary cancers, and evaluate the mobility of the tongue
5. In the pharynx, exclude tonsil and base of tongue involvement by cancer
6. Evaluate the neck for the presence of cervical metastases
7. For laryngeal examination, laryngoscopy is mandatory.

Assess the following:

- Mobility of the vocal cords
- Mobility of the arytenoids
- Supraglottic and subglottic extension
- Arytenoid involvement

Imaging

1. Computed tomography (CT) scan with intravenous (IV) contrast, magnetic resonance imaging (MRI) of the neck with gadolinium
2. 18F-fluorodeoxyglucose positron emission tomography-computed tomography (PET CT scan)

Although the accuracy of CT scans and MRI scans is limited in defining mucosal extension, they reliably demonstrate findings considered contraindications to supracricoid partial laryngectomy, such as extralaryngeal spread. The PET CT scan is more useful in restaging recurrent larynx cancers after radiation, providing important information regarding the presence of nodal disease and distant metastases.

Indications

1. T1, T2, selected T3, N0-1 glottic and supraglottic squamous cell carcinoma
2. Recurrent T1-T2, selected T3, N0-1 SCC after narrow field radiation
3. Motivated patient, able to participate in swallowing rehabilitation

Contraindications

1. Medical comorbidities with increased risk for general anesthesia
2. Inadequate pulmonary reserve
3. Prior wide field radiation for cancer of the head and neck
4. Preoperative dysphagia due to prior treatment or medical comorbidities
5. Anticipated need for postoperative radiation or chemoradiation
6. Anatomic contraindications
   a. Vocal cord immobility with arytenoid fixation
   b. Subglottic extension
   c. Invasion of the cricoid
   d. Invasion of the hyoid
   e. Extralaryngeal spread
7. Active mental health issues including anxiety or depression
8. Active substance abuse
9. Lack of motivation to participate in recovery and rehabilitation
10. Lack of support systems

Select glottic and supraglottic cancers classified as T3 stage may be effectively treated with a supracricoid partial laryngectomy. Cancers with pre-epiglottic space invasion may be managed with an SCPL, provided that the pre-epiglottic space involvement is not extensive. Vocal cord fixation alone is not a contraindication to SCPL, unless associated with arytenoid fixation. Paraglottic space invasion by a cancer of the larynx will usually produce fixation of the vocal cord, but the adjacent arytenoid will retain mobility. Resection of the arytenoid will usually yield a negative resection margin. In contrast, vocal cord immobility associated with arytenoid fixation is frequently a result of cricoarytenoid joint invasion by cancer; resection of the involved arytenoid rarely yields a negative surgical resection margin. Following radiation or chemoradiation, there may be fixation of the cricoarytenoid joint, even in the absence of direct invasion of the cricoarytenoid joint by cancer. Functional rehabilitation following SCPL is critically dependent on the well-preserved mobility of at least one cricoarytenoid unit.

Preoperative Preparation

1. Medical consultations as necessary
2. Consultation with radiation and/or radiation oncology if indicated
3. Review imaging
4. Informed consent including consent for total laryngectomy
5. Speech and swallowing therapy evaluation
6. Intraoperative examination with mapping biopsies

OPERATIVE PERIOD

Anesthesia

1. General anesthesia

Positioning

1. Supine

Perioperative Antibiotic Prophylaxis

1. Ancef and Flagyl
2. Clindamycin if allergic to penicillin

Monitoring

1. Routine for general anesthesia

Instruments and Equipment to Have Available

1. Standard laryngectomy set
2. Standard tracheostomy set

Key Anatomic Landmarks

1. Relationship between the recurrent laryngeal nerve and the cricothyroid articulation (Fig. 14.1). The cricothyroid articulation is not well visualized until the cricopharyngeus and inferior constrictor are elevated off the posterior thyroid cartilage lamina and inferior cornu. The recurrent laryngeal nerve is immediately posterior to the cricothyroid articulation and is at risk of injury during disarticulation of the joint.
2. Relationship of the external and internal branches of the superior laryngeal nerve and the thyrohyoid membrane (see Fig. 14.1). For carcinoma of the glottis, entry into the larynx through the thyrohyoid membrane, below the level of the internal branch of the superior laryngeal nerve, will preserve sensation to the residual epiglottis and enhance swallowing postoperatively.

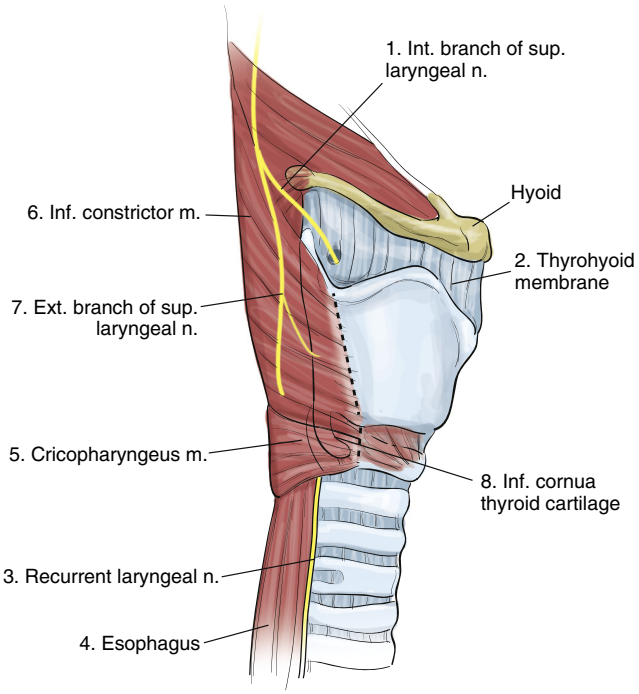

Fig. 14.1. Right side of the thyroid cartilage and trachea. The inferior constrictor and cricopharyngeus muscle must be released from the posterior thyroid cartilage lamina and inferior thyroid cornu to expose the cricothyroid articulation. The recurrent laryngeal nerve is located just posterior to this articulation.

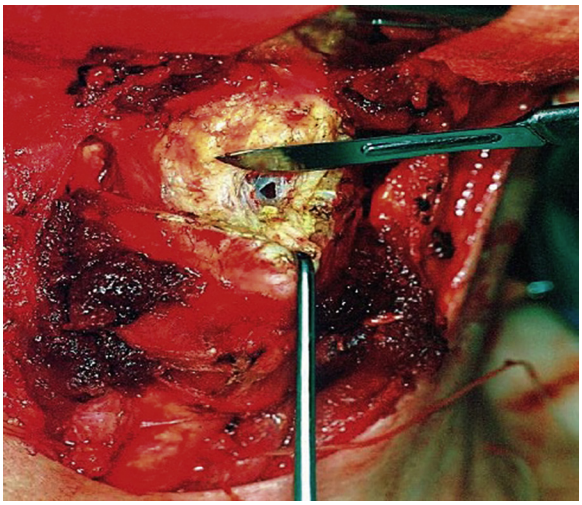

Fig. 14.2. For laryngeal carcinomas with minimal supraglottic involvement, entry into the larynx is accomplished by means of dissection through the pre-epiglottic space. An incision started just above the thyroid notch is extended through the pre-epiglottic space. The infrahyoid epiglottis is incised, resulting in laryngeal entry and direct visualization of the glottis. Placing a Deaver retractor in the mouth against the infrahyoid epiglottis may be helpful.

Prerequisite Skills

1. Expertise in performing total laryngectomy and thyroid surgery

Operative Risks

1. Intraoperative hemorrhage
2. Injury to recurrent laryngeal nerves
3. Injury to the superior laryngeal nerves
4. Injury to the hypoglossal nerves
5. Fracture of the cricoid
6. Dislocation of the arytenoid cartilage

Meticulous surgical technique and a working knowledge of the anatomy of the larynx will prevent most intraoperative complications. Great care is used to disarticulate the cricothyroid joint. Sutures placed to approximate the cricoid to the residual supraglottis or hyoid must be secured snugly to prevent dehiscence but not too tightly so as to damage the cricoid. The cricoid is susceptible to injury during manipulation, particularly after radiation. During the resection, the surgical incision anterior to the arytenoid will preserve a fully functional cricoarytenoid unit necessary for airway protection; inadvertent dislocation of the arytenoid cartilage cannot be salvaged. If both arytenoid cartilages are resected as part of the procedure, conversion to a total laryngectomy is necessary. Preservation of the strap muscles will help bolster the closure and provide the extra tissue used to separate the tracheostomy from the rest of the neck.

Surgical Technique

Prior to a definitive operation, a pan-endoscopy with biopsies should be performed to map out the extent of the cancer. Direct laryngoscopy and tracheoscopy and biopsy may demonstrate subglottic extension of cancer that was not appreciated on imaging studies and represent a contraindication to SCPL. Pan-endoscopy may be performed in a staged fashion or just prior to the open procedure. Pathologic review of biopsy specimens performed elsewhere requires pathologic confirmation prior to definitive surgery.

An apron incision, centered on the cricoids, is designed and subplatysmal flaps are elevated to 1 cm superior to the hyoid bone. Neck dissections are performed as indicated. The strap muscles are separated in the midline. The sternohyoid and omohyoid muscles are transected at the superior edge of the thyroid laminae. The deeper sternothyroid muscles are transected over the thyroid cartilage, and strap muscle flaps are elevated and retracted laterally. The thyroid isthmus is divided in the midline, and the thyroid lobes are dissected off of the trachea, preserving the superior thyroid neurovascular pedicle. Anterior pretracheal cervicomediastinal finger dissection is performed down to the carina. The inferior pharyngeal constrictor muscles are mobilized off the posterior edge of the thyroid cartilage. Transecting the superior cornua of the thyroid cartilage at their bases facilitates mobilization and delivery. The mucosa of the piriform sinus is mobilized from the inner aspects of the thyroid laminae. The cricothyroid joint is disarticulated sharply using a 15 blade angled medially and superiorly just beneath the inferior cornua of the thyroid cartilage to preserve the recurrent laryngeal innervation of the cricoarytenoid units. At least one functional cricoarytenoid unit is a prerequisite for a functional larynx (see Fig. 14.1).

The cricothyroid membrane is incised along the cricoid. The subglottic region is inspected to rule out the possibility of subglottic extension, which would preclude a supracricoid partial laryngectomy. Cancer may extend up to the level of the cricoid but not below this level to be considered operable using this technique. Frozen section margins must be negative. The endotracheal tube is passed through the cricothyroidotomy.

The means of entry to the larynx depends on the extent of supraglottic involvement by cancer. For cancers with minimal supraglottic involvement, infrahyoid entry into the larynx through the pre-epiglottic space enables the epiglottis to be

preserved (Fig. 14.2). Supracricoid partial laryngectomy is followed by impaction of the cricoid against the residual epiglottis and hyoid for the purpose of reconstruction. For supraglottic or combined supraglottic and glottis cancers, hyoid dissection (usually immediately below the hyoid) yields entry into the vallecula. The pre-epiglottic space is resected with the partial laryngectomy. Reconstruction is accomplished by means of impacting the cricoid and the residual hyoid.

Supracricoid Partial Laryngectomy With CHEP for Glottic Carcinoma

For glottic cancers with minimal extension to the supraglottis, entry into the larynx is achieved through the pre-epiglottic space (see Fig. 14.2). A Deaver retractor inserted into the mouth positioned against the infrahyoid epiglottis, can help prevent disorientation in the pre-epiglottic space. The cartilage of the infrahyoid epiglottis is then transected, and the airway is entered through the petiole. This opening is then extended laterally on the less involved side behind the superior aspect of the thyroid cartilage.

The incision is extended inferiorly to the cricothyrotomy, through the aryepiglottic fold, posterior aspect of the false and true vocal cords, but anterior to the ipsilateral arytenoid (Fig. 14.3). Once the thyrohyoidotomy and cricothyrotomy are connected, the thyroid cartilage may be fractured vertically at the level of the thyroid notch, opening the larynx "like a book." The final incisions are made under direct visualization. The paraglottic space is resected. The contralateral arytenoid may be resected as needed, but the mucosa over the posterior commissure and interarytenoid region must be preserved to prevent arytenoid fixation or glottic stenosis.

After frozen section margin clearance is secured, the arytenoid cartilages are repositioned in an anterior position using 4.0 Vicryl suture. Usually, the arytenoid mucosa does not reach the anterior cricoid arch, and the sutures securing the arytenoid in an anterior position are air knotted. The cricoid is then impacted against the hyoid using three submucosal 1 Prolene sutures with a TP-1 needle. The initial suture is passed submucosally under the midline of the cricoid, looping around the hyoid under the epiglottis and the mucosa of the base of the tongue. Two additional sutures are placed 1 cm off the midline, taking care to avoid the hypoglossal nerves, and tied securely (Fig. 14.4). A low tracheostomy is only now created at the level of the neck incision, creating a tracheostomy that will not place tension on the impacted cricohyoid repair. During closure, skin flaps are advanced over the stoma and secured to isolate the neck contents from the tracheostoma. A 4.0 Vicryl suture is used to pull the piriform sinus mucosa anteriorly into a more physiologic position. A cricopharyngeal myotomy is not performed. The strap muscles are used to reinforce the pexy. The neck is closed in layers over suction drains.

Nutritional supplementation will require a nasogastric tube or a temporary gastrostomy. Typically, patients undergo decannulation prior to removal of the feeding tube. The cuff is deflated the day following surgery, and an uncuffed tracheostomy tube is placed during the first tracheostomy tube change. A decline in the volume of tracheal secretions suggests that the swallowing function is returning. When the patient is able to swallow saliva, a thickened liquid diet may be started, and a swallowing rehabilitation program is instituted.

Supracricoid Partial Laryngectomy With Cricohyoidopexy for Supraglottic Carcinoma

The management of a supraglottic squamous cell carcinoma or a glottic carcinoma extending to involve the supraglottis requires resecting the epiglottis and pre-epiglottic space to ensure complete removal of the cancer. Instead of entering the airway through the pre-epiglottic space, entry into the vallecula is accomplished by dissecting immediately below the hyoid. Placement of a Deaver retractor into the vallecula can assist with this maneuver. The epiglottic and inferior incisions across the aryepiglottic fold, posterior false, and true cords (Figs. 14.5 and 14.6) proceed in a fashion similar to that described previously. The repair impacts the cricoid and

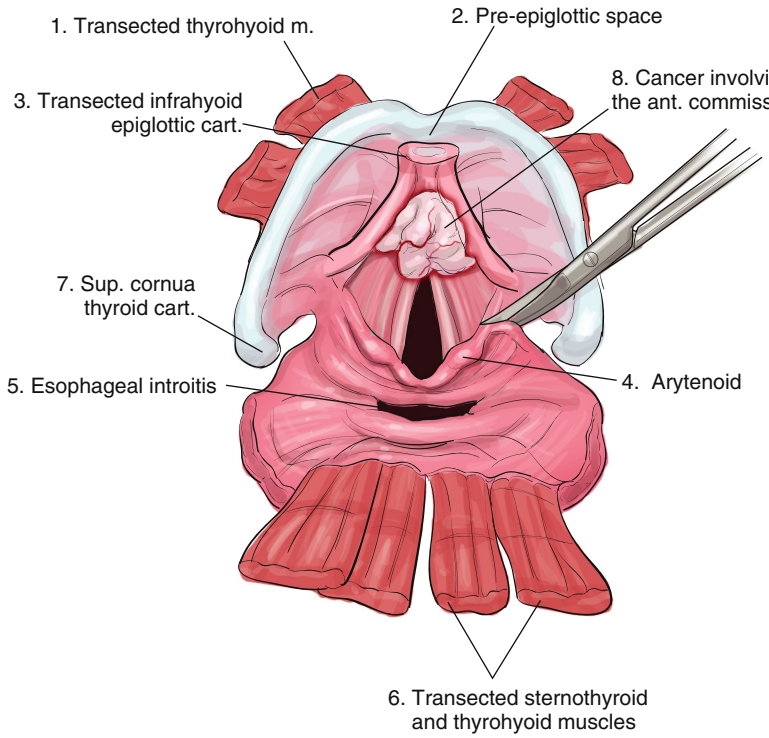

Fig. 14.3. Surgical view from the head of the table. The infrahyoid epiglottis has been transected. The suprahyoid epiglottis is not visible under the superior edge of the wound. Surgical incisions are made just anterior to the arytenoid, through the aryepiglottic fold, false and true vocal cord. *1,* Transected thyrohyoid muscle; *2,* Pre-epiglottic space; *3,* Transected infrahyoid epiglottic cartilage; *4,* Arytenoid; *5,* Esophageal introitus; *6,* Transected sternothyroid and thyrohyoid muscles; *7,* Superior cornua thyroid cartilage; *8,* Cancer involving the anterior commissure.

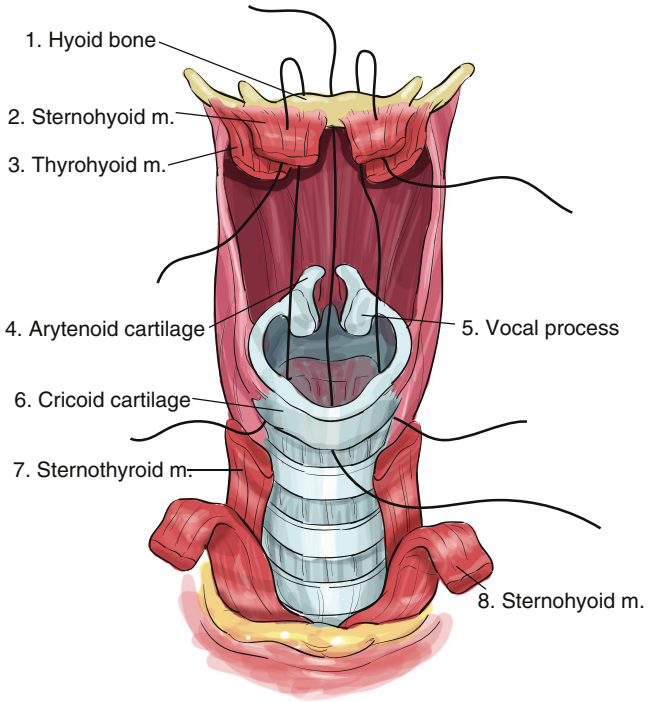

Fig. 14.4. Reconstruction of the larynx: CHP with three submucosal sutures placed around the hyoid bone and cricoid cartilage. *1,* Hyoid bone; *2,* Sternohyoid muscle; *3,* Thyrohyoid muscle; *4,* Arytenoid cartilage; *5,* Vocal process; *6,* Cricoid cartilage; *7,* Sternothyroid muscle; *8,* Sternohyoid muscle. *(Reprinted with permission Brasnu DF: Supracricoid partial laryngectomy with cricohyoidopexy in the management of laryngeal carcinoma. World J Surg 27[7]:817-823, 2003.)*

arytenoids against the base of tongue, rather than the residual epiglottis (see Fig. 14.4).

Common Errors in Technique

1. Failure to save the strap muscles for use in reconstruction
2. Failure to save at least one cricoarytenoid unit
3. Improper placement of pexy sutures
4. Incorrect tension on pexy sutures
5. Incorrect placement of tracheostomy with tension on the impaction
6. Failure to separate the neck contents from the tracheostoma

POSTOPERATIVE PERIOD

Postoperative Management

1. Antibiotics should be continued postoperatively for 24 hours.
2. Diligent tracheostomy care
3. Encourage cough, deep breathing, and ambulation
4. Speech rehabilitation

Complications

1. Subcutaneous air
2. Wound infection
3. Dehiscence of pexy
4. Aspiration pneumonia
5. Tracheotomy dislodgement
6. Laryngeal stenosis
7. Cricoid fracture

Most complications may be avoided with meticulous surgical technique. Subcutaneous air is seen when the tracheostomy is not sutured to the muscle and skin flaps,

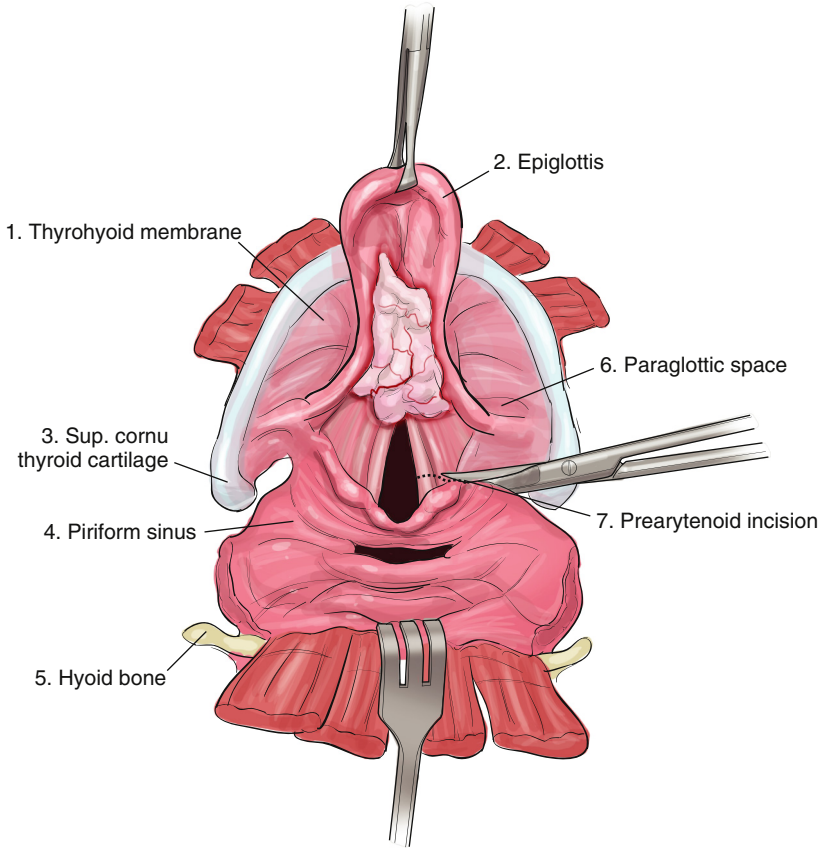

Fig. 14.5. Surgical view from the head of the table. The infrahyoid epiglottis will be resected with the specimen. Surgical cuts are made just anterior to the arytenoid, through the aryepiglottic fold, false and true vocal cord. *1,* Thyrohyoid membrane; *2,* Epiglottis; *3,* Superior cornu thyroid cartilage; *4,* Piriform sinus; *5,* Hyoid bone; *6,* Paraglottic space; *7,* Prearytenoid incision. *(Reprinted with permission Brasnu DF: Supracricoid partial laryngectomy with cricohyoidopexy in the management of laryngeal carcinoma. World J Surg 27[7]:817-823, 2003.)*

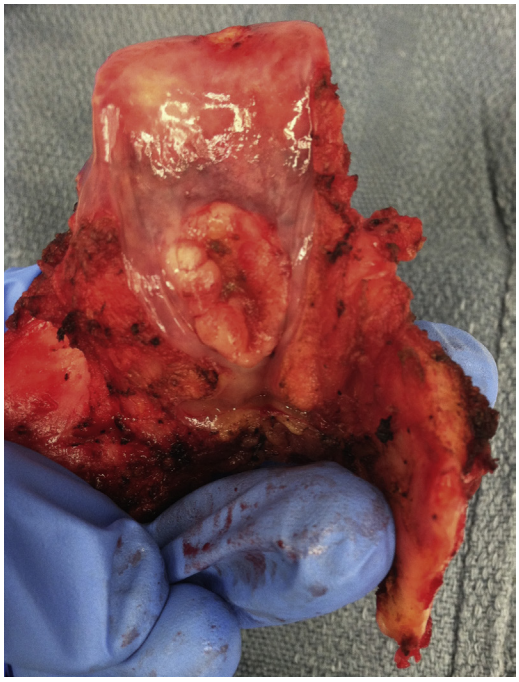

Fig. 14.6. Infrahyoid dissection with resection of the supraglottis and glottis along with the paraglottic space and pre-epiglottic space. This defect will be reconstructed with a CHP.

allowing the entry of tracheal secretions into the neck. This results in wound infection. Proper placement of pexy sutures prevents dehiscence. Dysphagia after this procedure is common and expected. Patients with poor pulmonary reserve may develop aspiration pneumonia. Proper patient selection is necessary to decrease the frequency of this complication. Tracheostomy tubes should be secured with sutures and ties for 5 days prior to the first tracheostomy tube change. Inability to replace a dislodged tracheostomy tube is an emergency; oral intubation may be challenging due to swelling, profuse secretions, and limited extension of the neck. Laryngeal stenosis may follow dehiscence of a pexy or an extended resection of an arytenoid. Damage to the cricoid will lead to wound infection and rupture of the pexy, for which conversion to a total laryngectomy is usually necessary.

Alternative Management Plan

1. Total laryngectomy
2. Radiation or chemoradiation

Long-Term Outcomes

Long-term complications include neck fibrosis and a variable degree of dysphagia. The vast majority of patients do not require a gastrostomy long term. However, patient selection is important. The local cancer control rates following a supracricoid partial laryngectomy for laryngeal cancer are extremely favorable relative to radiation alone. Indeed, the indications for SCPL have been expanded to include selected glottis and supraglottic squamous cell carcinomas classified as T3 and recurrent cancers after failure of radiotherapy. Local control and disease-related survivals remain favorable in several large series.[3-5]

The supracricoid partial laryngectomy procedure is a highly effective procedure to manage early stage and select T3 larynx cancers. The SCPL is also effective in managing recurrent early stage larynx cancers after failure of radiotherapy. Judicious and careful patient selection followed by flawless surgical technique and postoperative management will ensure optimal results (Video 14.1).

Editorial Comment

Selection of treatment of cancer of the larynx should be based on the approach that is most likely to result in prolonged, cancer-free survival. Larynx conservation surgery, which preserves speech and swallowing function, may be undertaken in selected patients. Even though total laryngectomy offers all of these benefits, it does have the major drawback of a permanent tracheostoma and having to manage and pay for speaking valves. Therefore a surgeon should always consider conservation laryngeal surgery in suitable patients before simply opting for total laryngectomy.

Eugene N. Myers

Access the review questions and additional sources list online at http://www.expertconsult.com

REFERENCES

1. Laccourreye H, Laccourreye O, Weinstein G, et al. Supracricoid laryngectomy with cricohyoidoepiglottopexy: a partial laryngeal procedure for glottic carcinoma. Ann Otol Rhinol Laryngol 1990;99(6 Pt 1):421–426.
2. Laccourreye H, Laccourreye O, Weinstein G, et al. Supracricoid laryngectomy with cricohyoidopexy: a partial laryngeal procedure for selected supraglottic and transglottic carcinomas. Laryngoscope 1990;100(7):735–741.
3. Sperry SM, Rassekh CH, Laccourreye O, et al. Supracricoid partial laryngectomy for primary and recurrent laryngeal cancer. JAMA Otolaryngol Head Neck Surg 2013;139(11):1226–1235.
4. Dufour X, Hans S, De Mones E, et al. Local control after supracricoid partial laryngectomy for "advanced" endolaryngeal squamous cell carcinoma classified as T3. Arch Otolaryngol Head Neck Surg 2004;130(9):1092–1099.
5. Brasnu DF. Supracricoid partial laryngectomy with cricohyoidopexy in the management of laryngeal carcinoma. World J Surg 2003;27(7):817–823.

REVIEW QUESTIONS

1. Indications for a supracricoid partial laryngectomy include all the following laryngeal squamous cell carcinomas *except*
   a. T2N0 supraglottic squamous cell carcinoma
   b. Transglottic squamous cell carcinoma
   c. Squamous cell carcinoma involving the anterior commissure
   d. Squamous cell carcinoma involving the posterior commissure
   e. rT1N0 glottic squamous cell carcinoma after radiation

2. Potential complications of a supracricoid partial laryngectomy include all of the following *except*
   a. Dehiscence of the pexy sutures
   b. Cricoid fracture
   c. Recurrent laryngeal nerve paralysis
   d. Dysphagia
   e. Aspiration pneumonia

3. Contraindications for a supracricoid partial laryngectomy include all the following *except*
   a. Prior wide field neck radiation
   b. Vocal cord immobility with arytenoid fixation
   c. Oxygen dependent chronic obstructive lung disease
   d. Involvement of the cricoid cartilage
   e. Prior stroke with dysphagia

ADDITIONAL SOURCES

Benito J, Holsinger FC, Perez-Martin A, et al. Aspiration after supracricoid partial laryngectomy: incidence, risk factors, management, and outcomes. Head Neck 2011;33(5):679–685.

Castro A, Gavilán J. Supracricoid laryngectomy in The Open Access Atlas of Otolaryngology Head and Neck Operative Surgery. Available at https://vula.uct.ac.za/access/content/group/ba5fb1bd-be95-48e5-81be-586fbaeba29d/Supracricoid%20laryngectomy.pdf.

Lewin JS, Hutcheson KA, Barringer DA, et al. Functional analysis of swallowing outcomes after supracricoid partial laryngectomy. Head Neck 2008;30(5):559–566.

Weinstein G, Lacourreye O, Brasnu D, et al. Organ Preservation Surgery for Laryngeal Cancer. 1st ed. New York, NY: Singular; 1999.

15 Supraglottic Transoral Robotic Surgery

J. Kenneth Byrd, Umamaheswar Duvvuri

INTRODUCTION

Early supraglottic squamous cell carcinoma may be treated with either surgery or radiation as a single modality with equal results, based on retrospective evidence and extrapolation from larger studies comparing radiation to total laryngectomy. As treatment modalities shifted toward "organ preservation therapy" after the Veterans Affiars Larynx trial, both surgical innovation and a noted decrease in survival have prompted the resurgence of conservation surgical procedures, both open and endoscopic. Although open supraglottic partial laryngectomy (SGPL) is an excellent oncologic technique, it has been supplanted by endoscopic partial laryngectomy. Endoscopic laser partial laryngectomy has been shown to provide equivalent disease control compared with the open procedure[1], with good functional outcomes.

Transoral robotic surgery (TORS) was popularized in the mid-2000s by Weinstein and colleagues, who first reported TORS in a canine model and shortly thereafter published a series of three patients who underwent the procedure successfully.[2] Since then, the technique has been widely adopted and reported in the literature with success rates comparable to both open surgery and laser microsurgery.[3-7] Compared with open surgery, authors cite shorter operative times and lengths of hospitalization and avoidance or shortened duration of tracheostomy and enteral feeding. Compared with transoral laser microsurgery (TLM), TORS may also be associated with shorter operative times, provided that the patient's anatomy allows adequate exposure with available retractors and instrumentation.[8]

KEY OPERATIVE LEARNING POINTS

- Superiorly based T1/T2 supraglottic tumors may be efficiently resected using TORS as an alternative to TLM, provided that the patient's anatomy allows adequate exposure.
- Careful patient selection is important to ensure that swallowing and airway are not compromised by surgery.
- The superior laryngeal artery must be controlled with cautery or clips when dissecting in the lateral pre-epiglottic space.
- Dissection becomes more restricted inferiorly.

PREOPERATIVE PERIOD

Candidates for TORS supraglottic laryngectomy should undergo preoperative in-office laryngoscopy to assess vocal cord mobility and mucosal extent of the cancer. Contrasted computed tomography (CT) may be helpful to evaluate the base of tongue, pre-epiglottic space, laryngeal framework, and cervical lymph nodes. The classification system proposed by Remacle et al. for the european laryngological society (ELS) endoscopic laser supraglottic laryngectomy is applicable for TORS SGPL.[9] Patients with significant lung disease or poor performance status may be poor candidates for partial laryngeal surgery, especially more extensive ELS types, due to the probability of postoperative dysphagia and aspiration.

Robotic supraglottic laryngectomy is contraindicated in the presence of extralaryngeal spread, major invasion of the base of the tongue, and fixation of the arytenoid. Patients with significant involvement of the pre-epiglottic space or glottis may be better treated with an open approach to remove adjacent laryngeal framework as a margin and reposition the arytenoids, when necessary.

Patients should be counseled about the possible need for postoperative radiation or chemoradiation (CRT) due to cancer that may be found after neck dissection. In a large, multi-institutional European study, 51% of patients treated with TORS SGPL and neck dissection required adjuvant therapy.[7] Patients with N2 or N3 metastasis or obvious extracapsular spread on imaging should be counseled that long-term swallowing outcomes will be poorer if concurrent chemoradiotherapy is necessary after SGPL. These patients may be better served with definitive chemoradiation, rather than surgery as a primary modality.

History

1. History of present illness
   a. A thorough history should be taken to assess for pain, dyspnea, dysphonia, stridor, dysphagia, and aspiration.
   b. The duration of symptoms is important to determine the rapidity of growth and impending airway compromise.
   c. The patient's ability to take adequate nutrition and any recent weight loss should be noted.
   d. Any prior treatment for the cancer should be elicited, including prior surgery, radiation, or chemotherapy.
2. Past medical history
   a. Other malignancies
      1) Prior cancer of the head and neck
      2) Cancer of the lung
   b. Comorbidities
      1) Chronic obstructive pulmonary disease or asthma
      2) Heart disease
      3) Other systemic disease: diabetes, renal disease
   c. Prior surgery of the head and neck, including carotid endarterectomy, tracheostomy
   d. Medications
      1) Aspirin
      2) Anticoagulants
      3) Nebulizers or steroids
   e. Social history
      1) Tobacco use—how much, how long?
      2) Marijuana
      3) Alcohol or other substance dependence—how much, how long?

Physical Examination

1. General: Ambulatory status, dyspnea, overall health assessment
2. Oral cavity: Note the presence of factors that would prevent adequate transoral exposure
   a. Trismus
   b. Mallampati/tongue size
   c. Dentition
   d. Micrognathia

3. Neck
   a. Cervical lymph nodes
   b. Previous incisions
   c. Hyomental distance
   d. Range of cervical motion/extension
4. Voice/respiratory
   a. Stridor
   b. Wheezing
   c. Hoarseness
5. Flexible laryngoscopy
   a. Extent of tumor
      1) Suprahyoid versus infrahyoid epiglottis
      2) False vocal fold
      3) Glottis
      4) Hypopharynx
      5) Base of the tongue/vallecula
   b. Vocal cord movement should be assessed because fixation is a contraindication to TORS supraglottic laryngectomy.
   c. Examine for synchronous primary cancers

Imaging

1. CT of the neck with contrast
   a. Pre-epiglottic space and/or extralaryngeal extension of tumor
   b. Cervical lymph nodes
2. CT of the chest
   a. Metastases or second primary lung cancer
   b. Evidence of COPD
   c. Superiorly located brachiocephalic artery should be noted if tracheostomy is planned
3. Positron emission tomography-computed tomography (PET/CT): For stage III/IV cancer, PET/CT may be performed to screen for distant metastatic disease in lieu of CT chest
4. Magnetic resonance imaging (MRI): Limited indication but may be useful if tongue base involvement is a concern

Indications

1. T1/T2 squamous cell carcinoma (SCC) of the supraglottis
2. Selected recurrent supraglottic or hypopharyngeal SCC
3. Glottic SCC
   a. Has been reported in small case series
   b. May be more widely adopted if smaller instruments become available

Contraindications

1. Inadequate intraoperative exposure
2. Fixation of the vocal cord
3. Extralaryngeal soft tissue involvement
4. Cartilage destruction
5. Bilateral glottic involvement
6. Poor cardiopulmonary reserve
7. Advanced neck disease necessitating postoperative concurrent chemoradiation (relative contraindication)

Preoperative Preparation

1. Swallowing evaluation
   a. Assess for dysphagia/aspiration.
   b. Significant dysphagia predicts poor postoperative swallowing.
   c. Instruction in supraglottic swallow preoperatively reduces postoperative dysphagia.
2. Dental evaluation if adjuvant therapy is likely to be needed
3. Anesthesiology
4. Discontinue aspirin and anticoagulants 1 week prior to surgery.
5. Continue respiratory medications for patients with COPD.

OPERATIVE PERIOD

1. Anesthesia
   a. Plan for securing airway should be discussed prior to induction
   b. A small endolaryngeal tube is used to minimally obstruct working space.
   c. Nasotracheal intubation is not always necessary but may improve exposure.
   d. Bulky supraglottic tumors may require fiberoptic intubation or intubation by an Otolaryngologist
   e. Paralytic agents may aid in exposure of the larynx.
   f. An arterial line may be necessary to safely monitor blood pressure due to positioning if significant comorbidities are present.
2. Positioning
   a. Supine
   b. Bed is turned 180 degrees from anesthesia
   c. Arms are tucked to allow robotic docking and suspension
   d. The da Vinci robot is docked at 30 degrees to the head of bed
   e. A 0-silk suture is placed through the junction of the anterior and middle thirds of the oral tongue for anterior retraction.
3. Perioperative antibiotic prophylaxis is not routinely indicated.
4. Routine anesthetic monitoring
5. Instruments and equipment to have available
   a. Feyh-kastenbauer (FK) retractor or Crowe-Davis retractor
   b. The 8-mm 0-degree endoscope is used with 5-mm instruments.
      1) Maryland retractor
      2) Monopolar cautery
      3) Alternatively, a needle driver may be used with a CO_2 laser fiber carrier.
   c. Bedside assistant aids in dissection, suctioning, and hemostasis
      1) Pediatric Yankauer and laryngeal suctions
      2) Bipolar cautery
      3) Endoscopic clip applicator

KEY ANATOMIC LANDMARKS

- The supraglottis is the region of the larynx that extends from the laryngeal ventricle superiorly to the tip of the epiglottis.
- Subsites include the suprahyoid and infrahyoid epiglottis, the aryepiglottic folds, arytenoid, corniculate, and cuneiform cartilages, and the false vocal folds.
- The quadrangular membrane, epiglottic cartilage, and hyoepiglottic ligament act as barriers to prevent spreading to adjacent sites, but tumors may quickly involve the glottis via spread through the paraglottic space, which is continuous with the pre-epiglottic space.
- Cancer that penetrates the epiglottic cartilage may extend into the vallecula and base of tongue musculature, and evaluation of the pyriform sinuses for spread is important when the aryepiglottic fold is involved.
- The superior laryngeal artery runs deep to the nerve from the transoral perspective, deep to the mucosa near the pharyngoepiglottic fold in the pre-epiglottic space. The artery may be sizable and should be addressed definitively with clips or bipolar cautery.

PREREQUISITE SKILLS

- Transoral robotic surgery
- Endoscopic laryngeal surgery

SURGICAL TECHNIQUE

- A tooth guard should be placed on the upper dentition. We have found that a thermoplastic splint cut and molded to the dentition is less bulky and more durable than the standard rubber or plastic tooth guard.
- Direct laryngoscopy is performed to map the cancer.
- If retraction of the oral tongue with a suture is needed for exposure, the lower teeth should also be covered with a tooth guard to prevent maceration of the ventral tongue.
- The FK retractor with the laryngeal or flat base of the tongue blade is inserted into the vallecula. Depending on the patient's anatomy, the 0- or 30-degree endoscope may be used.
- The Crowe-Davis retractor may be used in some patients as an alternative.
- The base of the da Vinci robot is brought in at 30 to 45 degrees to the foot of the operating table.
- A Maryland retractor and the monopolar cautery or laser manipulator are used for dissection, placed on either side of the camera to form an isosceles triangle of 30 to 45 degrees. The black lines on the ports, marking the pivot axes, should be near the level of the oral commissures.
- Fig. 15.1 demonstrates a tumor of the epiglottis appropriate for TORS resection.
- Dissection begins by making mucosal incisions 5 mm to 1 cm away from the tumor (Fig. 15.2).
- An incision into the vallecula to improve mobility of the tumor and for resection of the pre-epiglottic space, if necessary (Fig. 15.3)
- Rotation of the epiglottis back and forth may be necessary to make circumferential mucosal and deep incisions to avoid bisecting the specimen (Fig. 15.4). Alternatively, large cancers may be removed in several pieces with careful orientation for the pathologist.
- Repeated regrasping of the epiglottis should be avoided to limit disruption of the mucosa and cartilage.
- Laterally the superior laryngeal arterial supply should be positively identified and controlled with bipolar cautery or clips.

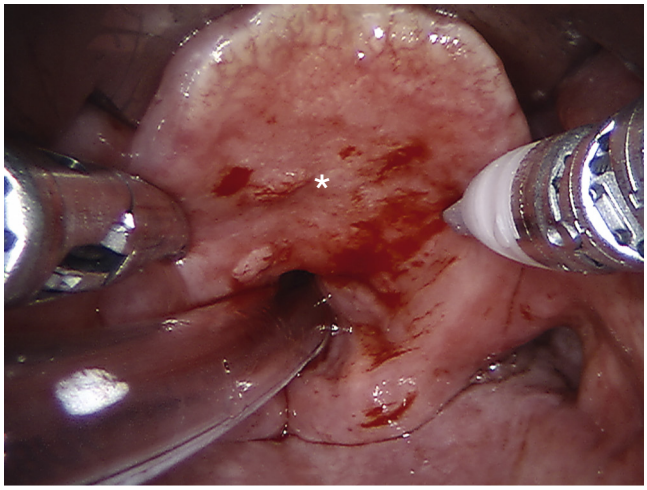

Fig. 15.1. A supraglottic squamous cell carcinoma involving the midline suprahyoid and infrahyoid epiglottis. The asterisk *(*)* denotes the center of the tumor.

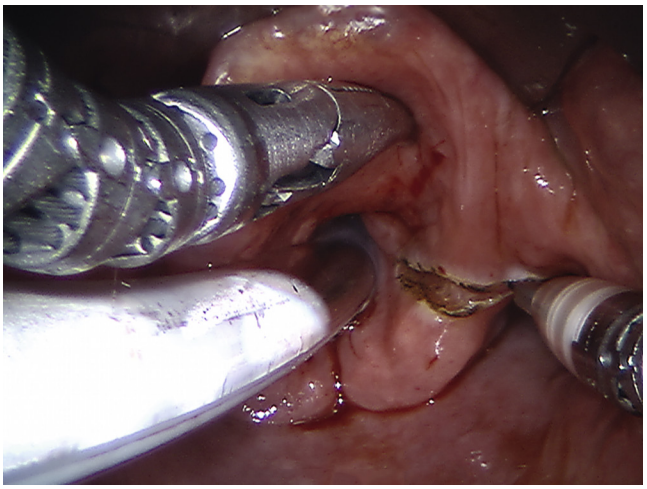

Fig. 15.2. The monopolar cautery is used to incise the right aryepiglottic fold and pharyngoepiglottic fold a suitable distance from the visible tumor.

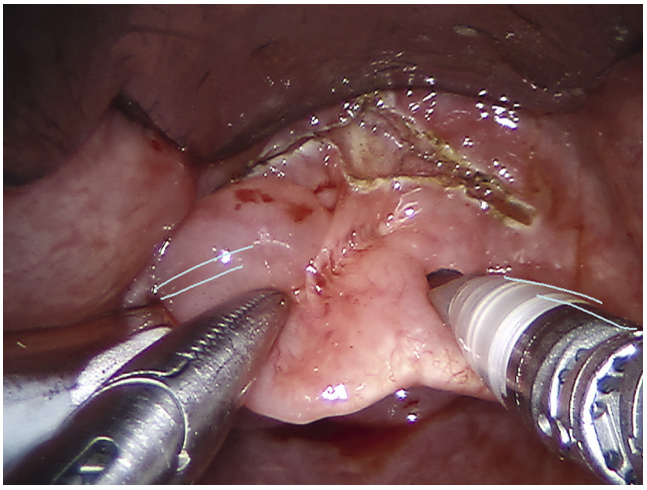

Fig. 15.3. The incision is continued into the vallecula to further mobilize the tumor and to resect the pre-epiglottic space to the hyoid bone, if necessary.

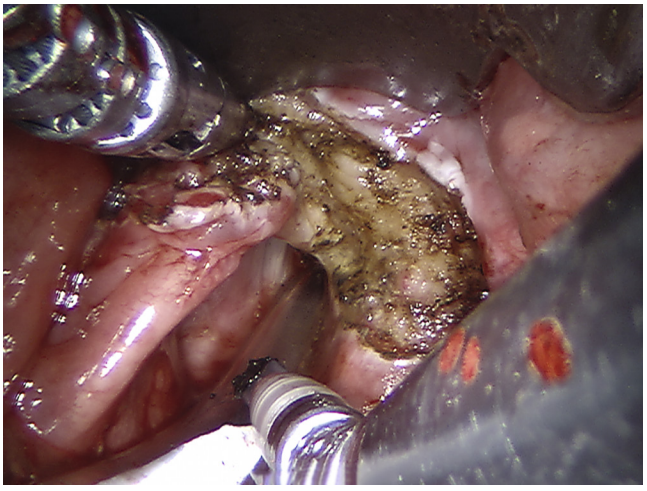

Fig. 15.4. The epiglottis is grasped and rotated to facilitate further dissection with the mucosal surfaces visualized.

- The anterior and ipsilateral incisions facilitate visualizing the full extent of the tumor (Fig. 15.5).
- When the specimen is fully mobilized superiorly and laterally, the inferior incision is made (Fig. 15.6).
- Communication with the bedside assistant is important to maintain orientation, particularly for small specimens.
- Circumferential frozen section margins are taken and analyzed by the pathologist while the patient is still in the operating room.
- The field is irrigated and inspected after a Valsalva maneuver to ensure hemostasis (Fig. 15.7). Hemostatic agent may be applied.

COMMON ERRORS IN TECHNIQUE

- The endotracheal tube may become dislodged by the robotic arms if not adequately secured.
- Improper docking causes arm collisions.
- Failure to identify and control the superior laryngeal artery leads to brisk intraoperative or postoperative bleeding.
- Inadequate exposure due to positioning or anatomic factors may result in incomplete tumor resection and positive margins.
- The internal branch of the superior laryngeal nerve should be preserved for laryngeal sensation if tumor resection does not require sacrifice.

POSTOPERATIVE CARE

- Perioperative steroids are useful to prevent airway edema, particularly when the false vocal folds are involved.
- A single perioperative dose of steroids may suffice for epiglottectomy; however, consideration may be given to a full 24 hours of postoperative steroids if airway edema is a concern.
- Postoperative antibiotics are advocated by some but are not routinely used at our institutions.
- Most patients are kept in the hospital for observation and swallowing evaluation.
  - If the patient is managing his or her secretions the following day, a speech and language pathologist may assess swallowing at the bedside, with a modified barium swallow study, or Fiberoptic Endoscopic Evaluation of Swallowing (FEES).
  - If the patient is intolerant of secretions or is unable to sustain enough oral intake, a nasogastric tube is placed until follow-up.
- For limited resections, the surgeon may consider discharging a reliable patient without significant cardiopulmonary comorbidities after monitoring in recovery.
- The patient should be aware that delayed laryngeal edema may develop rarely and that prompt attention should be sought.

COMPLICATIONS

- Airway bleeding: return to operating room for intubation and operative control
- Dental injury
- Lingual nerve neuropraxia: temporary
- Delayed airway compromise due to edema
  - Intubation
  - Tracheostomy
- Aspiration
- Prolonged dysphagia
  - Nasogastric feeding up to 2 to 3 weeks
  - Gastrostomy if prolonged enteral feeding needed
- Airway stenosis

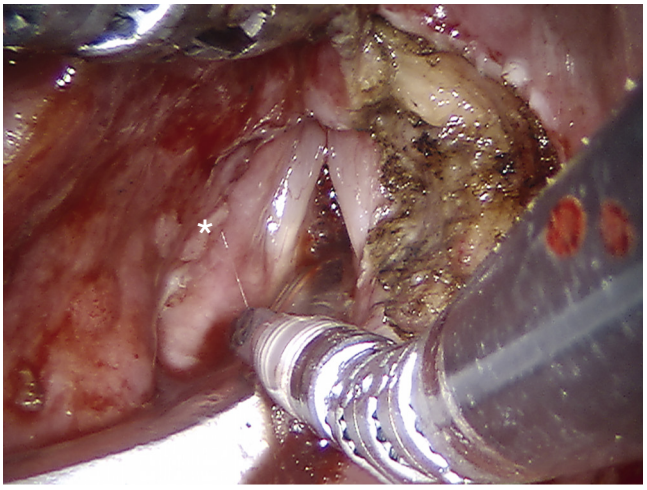

Fig. 15.5. With the epiglottis freed by right-sided and vallecular incisions, the extent of left-sided tumor *(*)* is visualized.

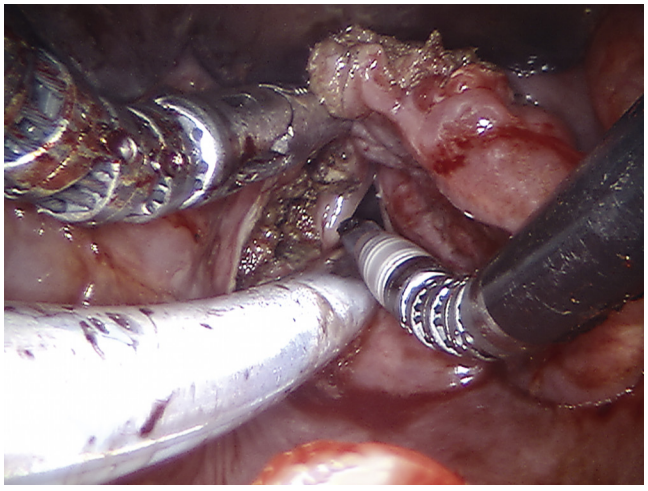

Fig. 15.6. The contralateral inferior mucosal incision is made to further mobilize the tumor.

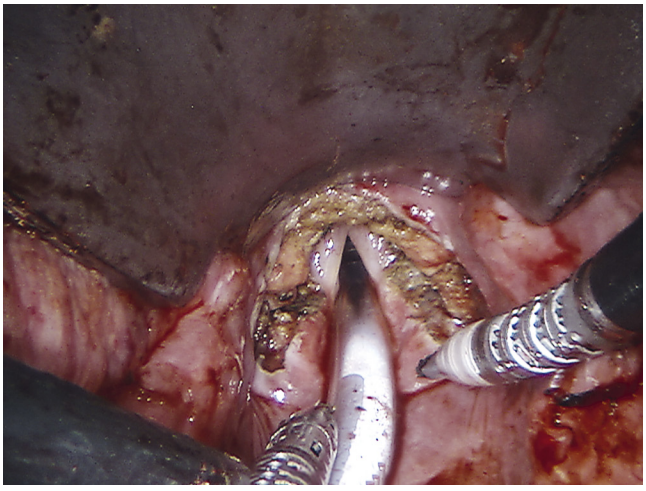

Fig. 15.7. Resultant defect from supraglottic partial laryngectomy involving the suprahyoid and infrahyoid epiglottis to the level of the laryngeal ventricles.

ALTERNATIVE MANAGEMENT PLAN

Patients with early stage supraglottic cancer may be treated with TLM, open partial laryngeal surgery, total laryngectomy, or (chemo)radiation therapy.

DISCUSSION

Evidence-Based Medicine Question

What are the outcomes for TORS supraglottic laryngectomy?

Patients with T1-T2 N0 SCC of the supraglottis treated surgically had 81% to 86% disease-specific survival in the surveillance, epidemiology, and end results program (SEER) study of more than 2600 patients by Arshad et al.[10] Although no prospective trials compare TORS SGPL to TLM SGPL or open partial laryngectomy, oncologic outcomes in retrospective studies have been equivalent. In the literature, tracheostomy and enteral feeding practices vary greatly from study to study and likely depend on patient selection. When tracheostomy is performed, decannulation is generally possible within 2 weeks.[7] Temporary enteral feeding is typically accomplished with a nasogastric tube, rather than a gastrostomy; the largest published series of TORS-SGPL, a multi-institutional European collaboration, reports a 9.5% incidence of gastrostomy, which is comparable with other smaller series.[4,7] Early consultation with a speech and language pathologist and initiation of the supraglottic swallow may shorten the duration of temporary dysphagia. Preoperative speech evaluation may help to identify patients with pre-existing dysphagia who may benefit from early gastrostomy placement. Similarly the rate of complications varies based on report from 0% to 28% and includes bleeding, delayed airway compromise, and aspiration pneumonia.[4-7] Superior laryngeal artery bleeding can result in rapid loss of airway, requires a return trip to the operating room, and is best prevented by deliberate control at the time of resection.

Editorial Comment

TORS-SGPL has all the benefits of transoral CO_2 laser microsurgery, as well as improved access in patients in whom anatomic factors preclude good visualization of the tumor with the microscope. However, the high initial cost and recurrent costs of TORS are still a barrier to its introduction outside the developed world.

Johan Fagan

Access the review questions online at http://www.expertconsult.com

REFERENCES

1. Rodrigo JP, Suarez C, Silver CE, et al. Transoral laser surgery for supraglottic cancer. Head Neck 2008;30(5):658–666.
2. Weinstein GS, O'Malley Jr BW, Snyder W, et al. Transoral robotic surgery: supraglottic partial laryngectomy. Ann Otol Rhinol Laryngol 2007;116(1):19–23.
3. Olsen SM, Moore EJ, Koch CA, et al. Transoral robotic surgery for supraglottic squamous cell carcinoma. Am J Otolaryngol 2012;33(4):379–384.
4. Ozer E, Alvarez B, Kakarala K, et al. Clinical outcomes of transoral robotic supraglottic laryngectomy. Head Neck 2013;35(8):1158–1161.
5. Park YM, Kim WS, Byeon HK, et al. Surgical techniques and treatment outcomes of transoral robotic supraglottic partial laryngectomy. Laryngoscope 2013;123(3):670–677.
6. Mendelsohn AH, Remacle M, Van Der Vorst S, et al. Outcomes following transoral robotic surgery: supraglottic laryngectomy. Laryngoscope 2013;123(1):208–214.
7. Razafindranaly V, Lallemant B, Aubry K, et al. Clinical outcomes with transoral robotic surgery for supraglottic squamous cell carcinoma: experience of a French evaluation cooperative subgroup of GETTEC. Head Neck 2015;38(Suppl. 1):E1097–1101.
8. Ansarin M, Zorzi S, Massaro MA, et al. Transoral robotic surgery vs transoral laser microsurgery for resection of supraglottic cancer: a pilot surgery. Int J Med Robot 2014;10(1):107–112.
9. Remacle M, Lawson G, Hantzakos A, et al. Endoscopic partial supraglottic laryngectomies: techniques and results. Otolaryngol Head Neck Surg 2009;141(3):374–381.
10. Arshad H, Jayaprakash V, Gupta V, et al. Survival differences between organ preservation surgery and definitive radiotherapy in early supraglottic squamous cell carcinoma. Otolaryngol Head Neck Surg 2014;150(2):237–244.

REVIEW QUESTIONS

1. Which of the following stage cancers is not a potential candidate for TORS?
   a. T1N0M0 suprahyoid epiglottis
   b. T2N1M0 epiglottis and aryepiglottic fold
   c. T3N2cM0 supraglottis with vocal cord fixation
   d. T2N0M0 aryepiglottic fold and pyriform sinus

2. What is an advantage of monopolar cautery over CO_2 laser for TORS SGPL?
   a. Less thermal scatter
   b. Shorter operative time
   c. More working space
   d. Smaller instruments

3. In TORS SGPL, which of the following arteries is commonly encountered and must be addressed?
   a. Lingual artery
   b. Superior laryngeal artery
   c. Facial artery
   d. External carotid artery

16 Total Laryngectomy

Anna Pou

INTRODUCTION

The most common location of laryngeal cancer is the glottis, followed by the supraglottis, with the least common site being the subglottis. The American Cancer Society estimates that more than 14,000 new cases of laryngeal cancer will occur in the United States in 2016, resulting in about 3620 deaths.[1] It occurs more frequently in males. Tobacco (cigarette smoking) is the primary risk factor for laryngeal cancer, and the incidence is falling about 2% to 3% per year because fewer people are smoking. Other causes include alcohol, human papilloma virus (HPV), and environmental factors, such as exposure to asbestos. The most common histologic type is squamous cell carcinoma and the prognosis depends upon the stage at the time of diagnosis. Treatment has changed over the past 25 years to include conservation laryngeal surgery—for example, endoscopic techniques such as transoral laser microsurgery, transoral robotic surgery, and organ preservation protocols. Total laryngectomy is employed primarily in patients with advanced laryngeal cancer, in cases of failed organ preservation treatment, and in those who cannot undergo conservation laryngeal surgery due to medical comorbidities. Depending on the stage of a tumor, patients may require adjuvant (chemo) radiation therapy. Total laryngectomy has a significant psychologic impact related to changes in voice, swallowing, and olfaction, in addition to living with a permanent stoma.[2]

KEY OPERATIVE LEARNING POINTS

1. Accurate tumor staging is paramount for successful treatment.
2. Unilateral or bilateral neck dissections may be indicated, depending on the staging of the neck and the location and extent of the tumor.
3. Control of the airway is of utmost importance. Some patients may require a preoperative tracheostomy for airway obstruction. If this is not required, intubation can generally be performed by direct laryngoscopy or flexible fiberoptic intubation.
4. Mapping of the tumor is required to plan the surgical approach so that the cancer is removed with appropriate margins.
5. Cover the edges of the tracheostoma by approximating skin to tracheal cartilage with half vertical mattress suture.
6. Identify the hypoglossal nerves bilaterally to avoid inadvertent injury to the nerves.
7. A watertight pharyngeal closure is required to prevent a pharyngocutaneous fistula.
8. If a tracheoesophageal puncture (TEP) is performed, a pharyngeal constrictor myotomy is necessary to prevent spastic speech.
9. Flap reconstruction is not a contraindication to primary TEP, provided that the party wall is not separated.

PREOPERATIVE PERIOD

History

1. History of present illness
   a. Hoarseness is one of the most common presenting symptoms.
   b. Patients may also complain of pain in the throat, odynophagia, dysphagia, otalgia, and weight loss.
   c. If previously treated, the patient may have a recurrence of his or her initial presenting symptoms.
2. Past medical history
   a. Prior treatment with conservation laryngeal surgery, radiation therapy, or organ preservation protocol
   b. Medical illness: Severe chronic obstructive pulmonary disease (COPD), cardiac disease, history of deep vein thrombosis (DVT)
   c. Past surgical history
   d. Family history of cancer of the head and neck
   e. Social history: Tobacco use, alcohol abuse, environmental exposure to asbestos, marijuana use
   f. Medications: Antiplatelet drugs, Warfarin
   g. Allergies

Physical Examination

1. Voice quality
2. Dyspnea, stridor
3. Laryngeal examination with a mirror or a flexible fiberoptic laryngoscope. The latter is especially helpful, as it can be used as an educational tool and to follow a patient's progress. The location of the tumor and the mobility of the vocal cords are documented, as well as the presence or absence of aspiration and pooling of secretions.
4. Complete examination of the head and neck for second primaries
5. Neck: Presence of lymph node metastases; involvement of overlying skin of the anterior neck by tumor
6. Nutritional status; cachexia

Imaging

1. Computed tomography (CT) scan of the neck with contrast in selected cases to determine the extent of the tumor, including involvement of the pre-epiglottic space, thyroid cartilage, and lymph node metastasis
2. Chest x-ray (CXR) or CT to evaluate for lung metastases: Some may obtain a positron emission tomography–computed tomography (PET-CT) scan to evaluate for distant metastases and the extent of the primary tumor and the presence of lymph node metastasis.

Indications

1. Relative indications:
   a. Whether T3 laryngeal cancer should be treated by total laryngectomy or by chemoradiation is a matter of debate.
   b. Patients unfit for chemoradiation therapy
   c. Life-threatening aspiration due to neurologic disease
   d. Severe COPD precluding conservation laryngeal surgery
2. Absolute indications
   a. Most T4 tumors
   b. Invasion of the thyroid cartilage
   c. Extension of tumor into soft tissues of the neck
   d. Salvage laryngectomy for failed nonsurgical treatment
   e. Chondroradionecrosis refractory to conservative management

3. Contraindications
   a. Tumors amenable to conservation laryngeal surgery, radiation, or chemoradiation
   b. Medical comorbidities precluding general anesthesia
   c. Patient's refusal for total laryngectomy

Preoperative Preparation

1. Endoscopy under general anesthesia for tumor mapping and biopsy and to exclude a second primary cancer
2. If a biopsy was obtained at an outside institution, slides are reviewed at the treating institution to confirm the diagnosis.
3. If PET-CT was not obtained previously, one may be obtained as a baseline to follow treatment results and to rule out distant metastasis.
4. Patient is evaluated by medical and radiation oncology, and the case is presented at a multidisciplinary tumor board for consensus opinion
5. Referrals are sent to dental oncology, nutrition, speech therapist, social worker, and patient advocate as necessary.
6. Referral for spiritual and/or psychologic support if needed and patient agrees

OPERATIVE PERIOD

Anesthesia

1. General anesthesia
2. The type of intubation depends on the tumor size and location and is discussed with the anesthesiologist prior to surgery: Oral endotracheal intubation (ETT), awake flexible fiberoptic ETT, local awake tracheotomy.

Positioning

1. Supine with shoulder roll to extend the neck
2. Arms are tucked at patient's sides
3. Bed is turned 90 or 180 degrees from the anesthesiologist to create space for the surgeons around the head of the bed

Perioperative Antibiotic Prophylaxis

The first dose should be given prior to the skin incision:

1. Clindamycin 900 mg IV plus gentamicin 5 mg per kg IV × 1 dose; followed postoperatively with clindamycin 900 mg IV q 8 hours × 3 doses (particularly in penicillin allergic patients)
2. Unasyn 3 gm IV q 6 hours × 4 doses

Monitoring

1. Continuous monitoring of blood pressure, pulse, and oxygen
2. Arterial blood gas when indicated
3. Hemoglobin and hematocrit when indicated

Instruments and Equipment to Have Available

1. Routine head and neck set with retractors
2. Monopolar and bipolar electrocautery
3. 14F red rubber catheter if primary tracheoesophageal puncture is to be performed
4. 1% lidocaine to inject into adventitia of carotid bulb if the patient develops profound bradycardia due to manipulation of the carotid artery

Key Anatomic Landmarks

1. Thyroid notch
2. Cricoid cartilage
3. Sternal notch
4. Carotid sheath
5. Esophagus

Prerequisite Skills

1. Knowledge of the anatomy of the anterior neck
2. Proficiency in soft tissue surgery
3. Understanding appropriate oncologic resection
4. Understanding intraoperative complications and how to address them

Operative Risks

1. Profound bradycardia due to manipulation of the carotid artery
2. Injury to the contents of the carotid sheath
3. Injury to cranial nerves, particularly cranial nerve 12
4. Positive surgical margins
5. Inadequate pharyngeal closure with resultant pharyngocutaneous fistula
6. Bleeding

Surgical Technique

1. Outline an apron (U-shaped) incision that starts at the level of the greater horn of the hyoid bone bilaterally and extends inferiorly to about 2 cm above the sternal notch, to incorporate the tracheostomy incision if present. The lateral limbs of the incision are placed along the anterior border of the sternocleidomastoid muscles (SCMs). Injecting the skin incision with 1% lidocaine with 1:100,000 epinephrine for hemostasis is optional.
2. Incise the platysma muscle along the above incision and raise a subplatysmal flap superiorly above the level of the hyoid bone and inferiorly to the level of the clavicles and sternal notch.
3. If neck dissection is to be performed, complete the neck dissection before proceeding to the laryngectomy operative steps below.
4. Using electrocautery, incise the fascia along the anterior border of the SCM.
5. The SCM is retracted laterally, and the contents of the carotid sheath are identified (Fig. 16.1).
6. The tissue anterior and medial to the carotid sheath is dissected down to the prevertebral fascia separating the laryngotracheal complex from the lateral neck; this is done along the entire length of the muscle (Fig. 16.2).
7. The omohyoid muscle is seen at this point, as well as the superior thyroid artery and superior laryngeal neurovascular bundle, which are clamped, ligated, and transected (see Fig. 16.2).
8. The infrahyoid strap muscles are transected inferiorly at the level of the stoma and elevated superiorly. This exposes the thyroid lobes and the thyroid isthmus, which is divided (Fig. 16.3).
9. If a thyroid lobe is to be preserved, the thyroid is dissected off the lateral aspect of the trachea using electrocautery; if the thyroid lobe is to be removed with the specimen, the fascia overlying the capsule is transected and dissected posteriorly and laterally to preserve the blood supply to the parathyroid glands.
10. The hypoglossal nerves are identified bilaterally in order to avoid inadvertent injury.

11. The suprahyoid muscles are transected off of the body of the hyoid bone until the level of the mucosa of the vallecula is reached.
12. The greater horns of the hyoid are freed; it is useful to grasp the body of the hyoid with a penetrating towel clip or an Allis clamp for stabilization during this dissection (Fig. 16.4).
13. The larynx is rotated using double-pronged skin hooks, and the middle and inferior constrictor muscles are transected and mobilized off the posterior lateral aspect of the thyroid cartilage.
14. Using a cottle elevator, the pyriform sinus mucosa is elevated from the inner aspect of the cartilage and preserved. If this mucosa is involved with the tumor, it is not elevated.

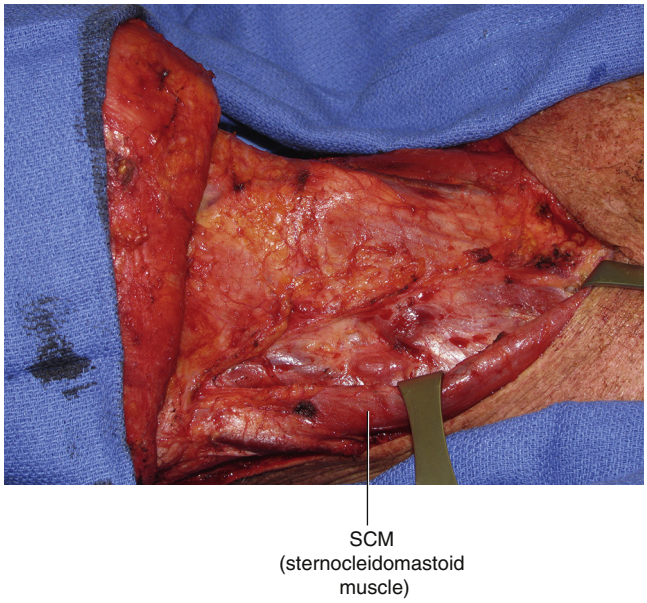

Fig. 16.1. The fascia along the entire length of the SCM has been incised and the muscle is retracted laterally.

15. The thyrohyoid ligament is transected in order to free the superior cornu of the thyroid cartilage.
16. The distal trachea is then mobilized by bluntly dissecting along its anterior aspect; this allows it to be pexied to the clavicular heads later in the procedure.
17. The trachea is transected between the anterior tracheal rings inferior to the tumor.
18. Using heavy curved Mayo scissors, the lateral aspect of the trachea is beveled to enlarge the stoma.
19. The stoma is secured to the anterior neck skin, and a reinforced ETT is placed in the distal trachea and connected to the anesthetic circuit in a sterile fashion.
20. The posterior membranous trachea is transected until the party wall is reached; care is taken not to separate the party wall inferiorly.
21. The proximal trachea is then bluntly elevated to the level of the cricoid cartilage (Fig. 16.5).
22. The surgeon then goes to the head of the bed to make the incisions in the larynx; a head light is needed at this point.
23. The pharynx is entered through the vallecula, pyriform sinus, or postcricoid mucosa, depending on tumor location and the surgeon's preference (Fig. 16.6).
24. The vallecula is entered by transecting the hyoepiglottic ligament, which leads one to the epiglottis, or by placing a suction tip into the vallecular mucosa and cutting down onto it.
25. The tip of the epiglottis is grasped with an Allis clamp (see Fig. 16.6).
26. After visualizing the tumor, mucosal incisions including a 1-cm margin are made with scissors. Care is taken to preserve the pyriform sinus mucosa if it is uninvolved.
27. If the mucosa of the pyriform sinus is entered instead of the vallecula, a suction tip is placed into the pyriform sinus and an incision is made down through the mucosa; the larynx is more typically opened like a "book."
28. The specimen is examined for adequate margins by opening the larynx and fracturing it after incising through the posterior cricoid cartilage. Additional margins are taken when necessary.
29. The neck is copiously irrigated, and hemostasis is obtained.
30. Gowns and gloves are changed and clean instruments are used for the remainder of the case.

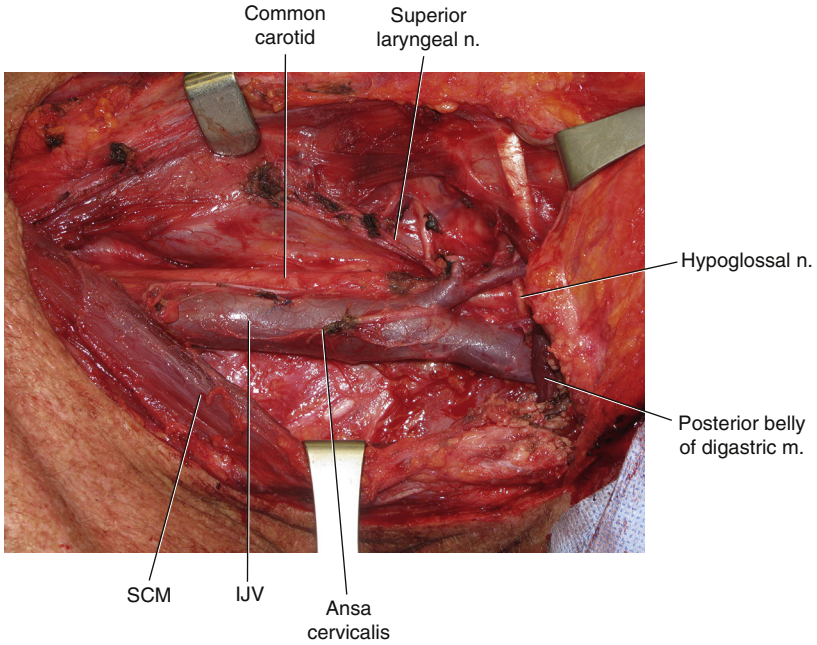

Fig. 16.2. The SCM is retracted laterally and the strap muscles are retracted medially with the laryngotracheal complex. The contents of the carotid sheath, hypoglossal nerve, part of the ansa cervicalis, and superior laryngeal nerve can be seen. During laryngectomy the carotid sheath contents are retracted laterally with the SCM.

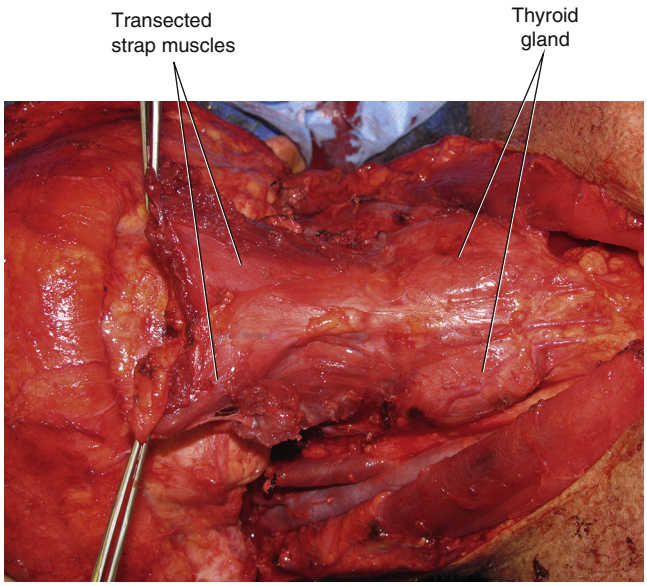

Fig. 16.3. The strap muscles are transected inferiorly and elevated exposing the thyroid gland.

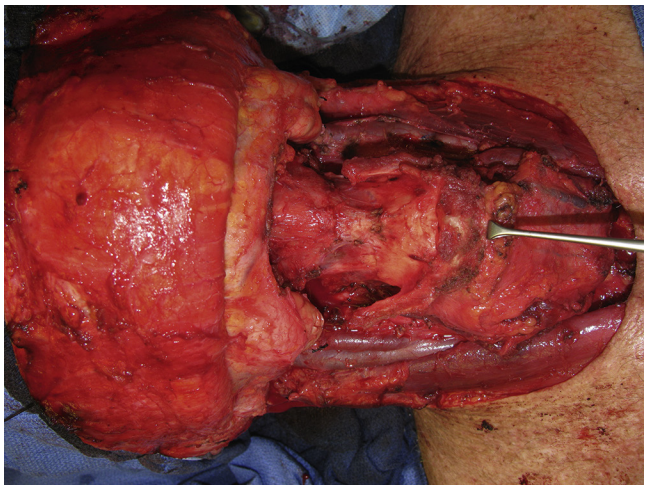

Fig. 16.4. The hyoid bone is skeletonized and freed from the surrounding tissue. It is grasped with an Allis clamp for stability.

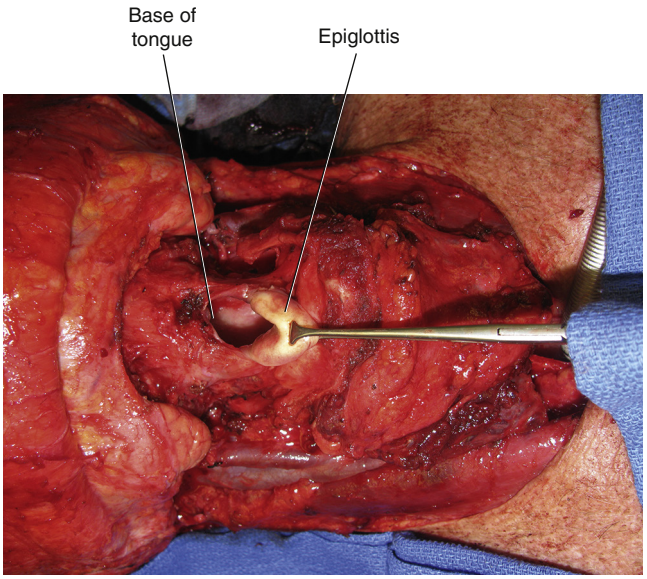

Fig. 16.5. After incising the trachea, it is dissected in the plane of the party wall to the level of the posterior aspect of the cricoid. The party wall and the remaining lobe of the thyroid are also visualized here.

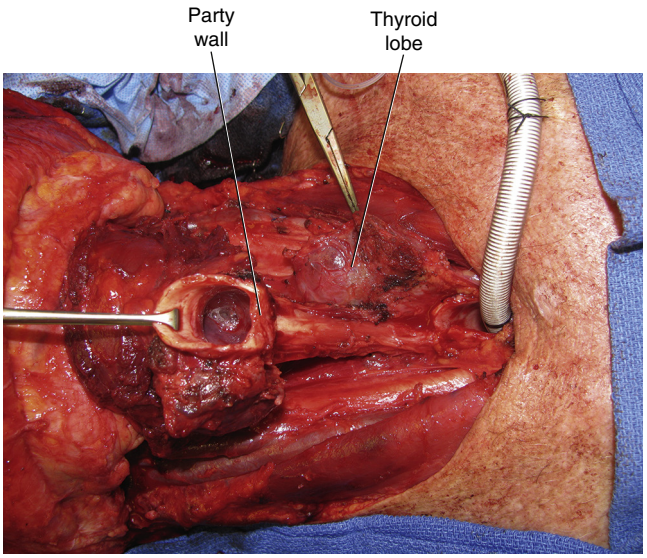

Fig. 16.6. After entering the valleculae, the epiglottis is grasped and tumor incisions are made under direct visualization.

31. An 18F nasogastric tube (NGT) is placed through the nose, through the pharynx, and into the esophagus. It is secured with a suture through the columella.
32. The proximal stoma is pexied to the clavicular heads bilaterally using a 2-0 Vicryl suture. The sutures are placed along the lateral aspect of the trachea 2 to 3 rings distal to the cut edge. This prevents the stoma from "falling" into the chest.
33. The anterior aspect of the stoma is sewn to the skin using half vertical mattress sutures of 2-0 Vicryl to cover the edge of the cartilage (Fig. 16.7). The stoma should be 3 cm in size to prevent microstomia.
34. If a primary tracheoesophageal puncture is to be made, additional steps are done at this time.[3]
    a. The party wall is buttressed to the back of the membranous trachea at its cut edge using 4-0 Vicryl sutures. Separation of the party wall is an absolute contraindication to a primary TEP.
    b. A pharyngeal constrictor myotomy is performed by the surgeon placing a finger into the pharyngeal defect and cutting the muscles (middle and inferior constrictors and upper cervical esophageal) from the esophageal inlet to the base of tongue in a vertical fashion until the mucosa is reached. If an inadvertent pharyngotomy is made, it is closed with interrupted sutures inverting the mucosa.
    c. To perform the puncture, a right-angled hemostat is placed in the pharyngeal defect against the posterior membranous trachea about 1 to 1.5 cm below the cut edge (Fig. 16.7). A #15 scalpel blade is used to make an incision over the tip of the right angle. The tips are pushed through the puncture, and a Foley catheter or red rubber catheter is grasped, pulled into the pharynx, and directed into the esophagus (Fig. 16.8A, B, C). It is secured to the skin with a 2-0 silk stick tie. The patient can be fed through the puncture site in lieu of a NGT.
    d. The voice prosthesis can be primarily placed immediately following the TEP using a kit.

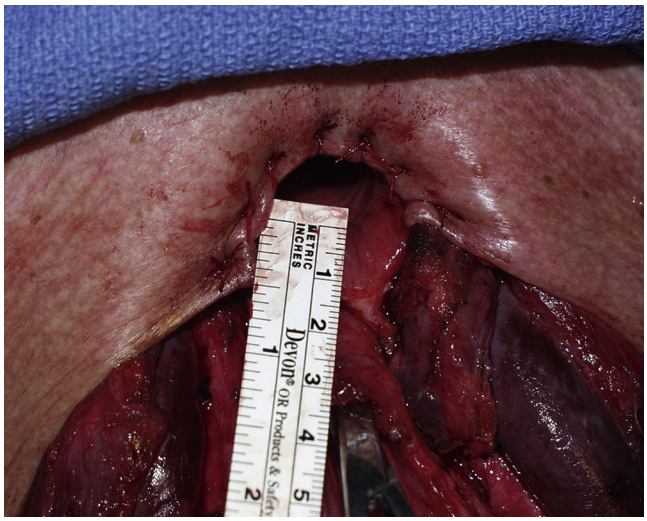

Fig. 16.7. The anterior stoma is then secured with half vertical mattress sutures and the pharyngeal constrictor myotomy is performed; the tracheoesophageal puncture is made 1 to 1.5 cm below the cut edge of the posterior membranous trachea.

35. The pharyngeal mucosa is closed using a running inverted suture of 3-0 Vicryl.[3] The mucosa can be closed in a vertical, horizontal, or "T" fashion, depending on the surgeon's choice and the amount of remaining mucosa (Fig. 16.9).
36. The pharyngeal closure is tested by introducing a bulb syringe filled with half-strength hydrogen peroxide into the mouth and filling the pharynx. Bubbles of hydrogen peroxide will be seen along the suture line if a leak is present.
37. 10-mm Jackson Pratt drains are placed on either side of the neck.
38. The superior skin flap is returned to its natural position, and the posterior aspect of the stoma is sewn to the skin using simple interrupted sutures of 2-0 Vicryl.
39. The platysma muscle is closed, and the incision is stapled.
40. A laryngectomy tube may be placed at the end of the case in order to maintain patency of the stoma if needed.
41. The patient is extubated in the operating room if in stable condition.

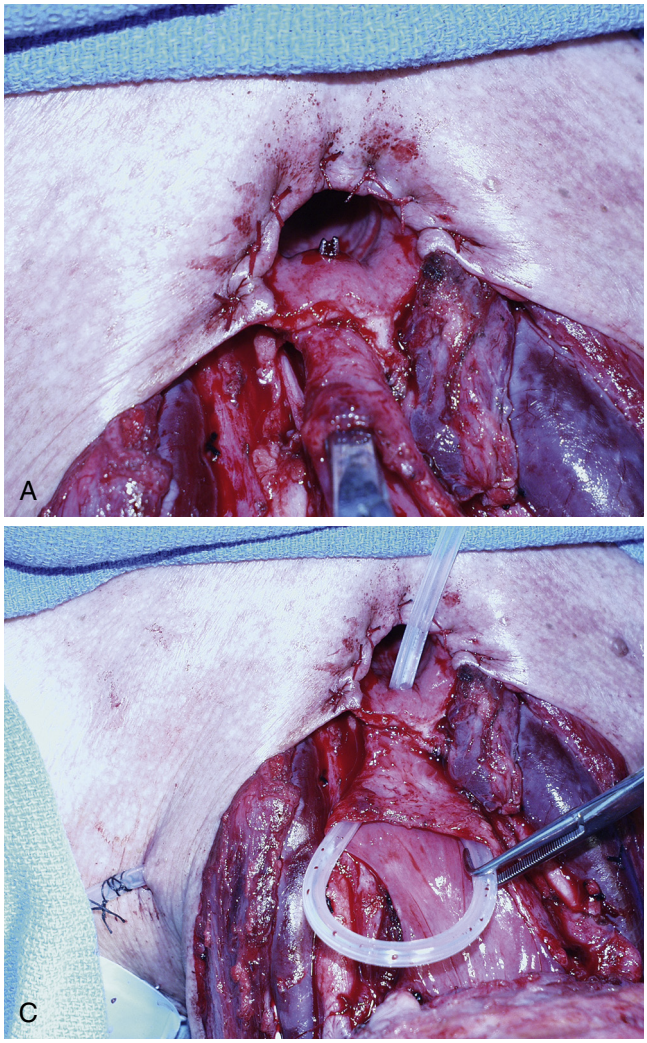

Fig. 16.8. A, #15 scalpel blade is used to make a horizontal cut over a right angled hemostat whose tips are pushed through the posterior wall. **B** and **C,** A red rubber catheter or a Foley catheter is grasped and pulled through the puncture site into the pharyngeal defect and then directed inferiorly into the esophagus.

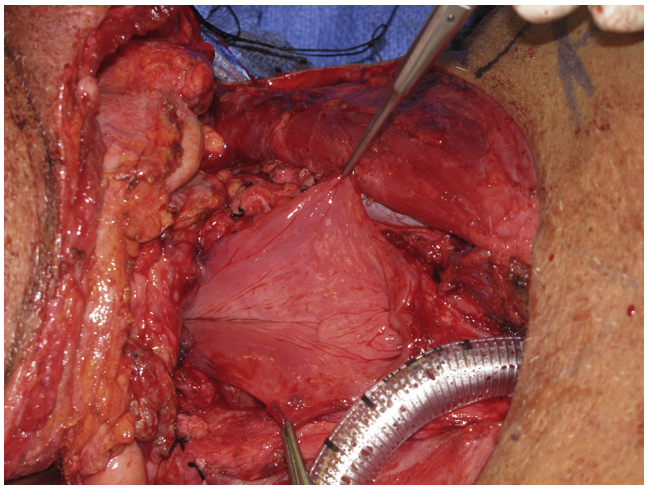

Fig. 16.9. The remaining pharyngeal mucosa is then closed by inverting the edges with a watertight closure to prevent fistula formation. If a primary TEP is performed, it is done prior to pharyngeal closure.

Common Errors in Technique

1. Inadequate perioperative antibiotic coverage
2. Understaging the cancer
3. Removal of excess pyriform sinus mucosa
4. Suboptimal pharyngeal closure, resulting in a fistula or stenosis
5. Inadequate size of stoma
6. Separation of the party wall when performing a TEP

POSTOPERATIVE MANAGEMENT

1. Patient is to be admitted to a step-down unit or to the intensive care unit for monitoring
2. Antibiotics are administered for 24 hours.
3. Continuous humidified room air or oxygen to stoma per tracheostomy collar
4. Regular tracheal suctioning
5. Clean crusts from stoma
6. Use laryngectomy tube if needed to keep stoma patent.
7. Antiemetics as required
8. Pain medication via Patient Controlled Anesthesia pump or routinely scheduled (morphine or dilaudid); oral pain medication when tolerating tube feeds and pain is better controlled
9. Start tube feeds per protocol.
10. Physical therapy to start day 1; refrain from neck extension until 10 days postoperatively
11. Stoma care teaching to patient and family to start postoperative day 1
12. Speech therapy to start teaching with electrolarynx prior to discharge if indicated
13. Barium swallow on postoperative days 5 to 7 to evaluate for small fistula; if negative, start a liquid diet and advance as tolerated
14. If a fistula is present, continue tube feeds and start antibiotics.

Complications

1. Hematoma/seroma
2. Wound infection
3. Fistula formation
4. Dehiscence of stoma or neck incision
5. Pharyngeal stricture
6. Deep vein thrombosis
7. Chest infections
8. Complications regarding primary TEP

Alternative Management Plan

1. Primary radiation therapy or chemoradiation
2. Referral to palliative care for those refusing treatment

Evidence-Based Medicine Question

Does the use of pectoralis major myofascial flap (PMMF) in salvage total laryngectomy reduce the incidence of pharyngocutaneous fistula?

The use of PMMF in salvage total laryngectomy does reduce the incidence of pharyngocutaneous fistula. The incidence of postoperative pharyngocutaneous fistula is about 30%. In a recent study patients undergoing PMMF following salvage total laryngectomy had a 22% decrease in risk of fistula compared with the control group. In addition, there was no significant difference in fistula rate in those undergoing total laryngectomy, compared with those undergoing pharyngolaryngectomy.[4]

Editorial Comment

Total laryngectomy is an excellent oncologic procedure for laryngeal cancer, and quality of life studies show similar outcomes compared with chemoradiation therapy. However, a favorable quality of life outcome requires attention to surgical detail to optimize speech and swallowing and attention to speech rehabilitation. In order to optimize speech outcome, patients need to be counseled preoperatively by the speech and language therapist. A capacious and relaxed pharynx should be created by doing a cricopharyngeal myotomy, avoiding a vertical pharyngeal closure, and having low threshold for augmenting a narrow pharynx with a pectoralis major flap, and the tracheoesophageal fistula should be correctly sited; the sternal heads of the sternocleidomastoids should be divided to create a flat tracheostoma.

Johan Fagan

Access the review questions and additional sources list online at http://www.expertconsult.com



REFERENCES

1. American Cancer Society. Cancer Facts and Figures 2016. Atlanta, GA: American Cancer Society; 2016. Available at http://www.cancer.org/acs/groups/content/@research/documents/document/acspc-047079.pdf.
2. Loehn BC, Kundak M, McWhorter A. Advanced laryngeal cancer. In: Johnson JT, Rosen CA, editors. Bailey's Head and Neck Surgery-Otolaryngology. 5th ed. Philadelphia, PA: Lippincott Williams and Wilkins Publishing; 2012. Chapter 124.
3. Hamaker RC, Singer MI, Blom ED, et al. Primary voice restoration at laryngectomy. Arch Otolaryngol 1985;111(3):182–186.
4. Guimaraes AV, Aires FT, Dedivitis RA, et al. Efficacy of pectoralis major muscle flap for pharyngocutaneous fistula prevention in salvage total laryngectomy: a systematic review. Head Neck 2016;38(Suppl. 1):E2317–2321.

REVIEW QUESTIONS

1. Otalgia is a common complaint in patients with laryngeal cancer due to referred pain from
   a. Jacobsen nerve
   b. Arnold nerve
   c. Hypoglossal nerve
   d. Pharyngeal plexus

2. Indications for total laryngectomy include
   a. Vocal cord paralysis
   b. Laryngocele
   c. T4 cancer with extension of the cancer into the muscles of the neck
   d. T1 to T2 tumors

3. The most likely cause of fever, elevated white count, and erythema of neck skin postoperatively is
   a. Chyle leak
   b. Infected hematoma
   c. Pharyngocutaneous Fistula
   d. Inappropriate antibiotic use

4. The cranial nerve most at risk for injury during a total laryngectomy is the
   a. Hypoglossal nerve
   b. Spinal accessory nerve
   c. Marginal mandibular nerve
   d. Vagus nerve

5. Humidification to the stoma is important to prevent
   a. Mucous plug
   b. Crusting
   c. Tracheitis
   d. All of the above

6. A tight pharyngeal closure can lead to
   a. Pharyngeal stricture
   b. Fistula
   c. Dysphasia
   d. All of the above

ADDITIONAL SOURCES

Forastiere AA, Weber RS, Trotti A. Organ preservation for advanced laryngeal cancer: issues and outcomes. J Clin Oncol 2015;33(29):3262–3268.

Khoueir N, Matar N, Farah C, et al. Survival of T4aN0 and T3^{+} laryngeal cancer patients: a retrospective institutional study and systematic review. Am J Otolaryngol 2015;36(6):755–762.

Sandulache VC, Vandelaar LJ, Skinner HD, et al. Salvage total laryngectomy after external beam radiotherapy: a 20-year experience. Head Neck 2016;38(Suppl. 1):E1962–8. http://dx.doi.org/10.100/hed.24355.

Serbanescu-Kele CM, Halmos GB, Wedman J, et al. Early feeding after total laryngectomy results in shorter hospital stay without increased risk of complications: a retrospective case-control study. Clin Otolaryngol 2015;40(6):587–592.

Timmermans AJ, Lange CA, deBois JA, et al. Tumor volume as a prognostic factor for local control and overall survival in advanced laryngeal cancer. Laryngoscope 2016;126(2):E60–7.

17 Total Laryngopharyngectomy

Benjamin L. Hodnett, Karen Pitman

INTRODUCTION

Total laryngopharyngectomy is employed for cancer of the hypopharynx. The hypopharynx forms the inferior part of the pharynx and is located immediately behind the larynx. It has three subsites—that is, postcricoid, posterior pharyngeal wall, and pyriform sinuses bilaterally. Total laryngopharyngectomy may also be performed for primary laryngeal tumors with extension to the aforementioned sites.

Total laryngopharyngectomy includes removal of the larynx as well as the hypopharynx and posterior pharyngeal wall, resulting in a circumferential defect. More extensive cancers involving the cervical esophagus require total laryngopharyngoesophagectomy. A laryngopharyngeal reconstructive procedure is required. Options include myocutaneous flaps (pectoralis major or latissimus dorsi) or fasciocutaneous free flaps (anterolateral thigh, radial forearm), jejunal free flaps, and gastric pull-up procedures.[1]

Lymphatic drainage is typically to levels II and III; however, retropharyngeal and bilateral drainage can occur. Paratracheal and paraesophageal metastases may also be present. Contralateral nodal metastases may occur in cancer of the medial wall of the pyriform sinus and bilateral nodal metastases may occur with cancer of the postcricoid region.[2] Therefore laryngopharyngectomy is generally accompanied by bilateral neck dissections.

KEY OPERATIVE LEARNING POINTS

- Extent of resection should be determined preoperatively to plan for adequate reconstruction.
- 2-cm mucosal resection margins should be obtained due to the risk of submucosal spread.
- 3 cm of pharyngeal mucosa in the transverse plane is required for closure without flap reconstruction.

PREOPERATIVE PERIOD

History

- Hypopharyngeal cancer may present at an advanced stage, as few symptoms may be present until the cancer is advanced.
- Presenting symptoms include progressive pain in the throat, dysphagia, odynophagia, dysphonia, referred otalgia, throat clearing, globus sensation, weight loss, and/or a mass in one or both necks.
- Dyspnea and hoarseness may represent invasion of the larynx or the recurrent laryngeal nerve.
- Dysphagia for solids and liquids implies an advanced cancer.
- Risk factors include the use of tobacco and alcohol, gastroesophageal reflux, and Plummer-Vinson syndrome.
- Plummer-Vinson syndrome is a rare condition generally appearing in women between the ages of 30 and 50. This syndrome consists of iron deficiency anemia, esophageal webs, dysphagia, weight loss, angular stomatitis, and atrophic glossitis.
- Preoperative nutritional evaluation should be performed on patients with hypopharyngeal or cervical esophageal cancer. Prealbumin, albumin, thyroid stimulating hormone, and iron levels provide information regarding nutritional status in conjunction with complete blood counts and basic chemistry. Referral to a nutritionist or dietician may be indicated preoperatively, as well as placement of enteral feeding access. Reconstructive options must be evaluated prior to placement of feeding access, as stomach and jejunum are potential donor sites.

Physical Examination

- Evaluation of the larynx and pharynx with flexible laryngoscopy is mandatory.
- Cancer may represent direct extension from the larynx or be a primary cancer of the hypopharynx.
- Vocal fold motion, patency of the airway, and pooling of secretions in the hypopharynx should be noted.
- Examination of the neck may reveal a mass either from regional metastasis or from direct extension of the cancer.
- Stridor is suggestive of involvement of the larynx.
- Poor nutritional status should be noted.
- Examination of the oral cavity and oropharynx should be performed to rule out synchronous primary cancers.
- Examination of the cranial nerves (hypoglossal, accessory) should be performed to evaluate extension of the cancer from the primary site or regional metastases.
- Paralysis of the vocal folds can occur as a result of invasion of the paraglottic space or cricoarytenoid joint or involvement of the recurrent laryngeal nerve.
- The chest wall, extremities, and abdomen should be examined to note prior surgery or chemoport placement that might affect potential reconstructive options.

Imaging

- Cross-sectional imaging with computed tomography (CT) or magnetic resonance imaging (MRI) with contrast is used to determine the extent of the primary cancer and the presence of regional metastasis. Contrast-enhanced CT imaging is highly sensitive for evaluation of pre-epiglottic and paraglottic space involvement by laryngeal cancer. MRI is more sensitive for detecting pathologic involvement of cartilage.
- Imaging of the lungs is recommended to evaluate for metastasis. CT of the chest is preferable to chest radiographs, given its higher sensitivity and specificity for detecting metastasis. Evidence of restrictive lung disease should be noted, as this may be a relative contraindication for pectoralis major flap reconstruction with a large skin paddle.
- Abdominal imaging may be indicated in patients with a history of prior abdominal surgery and in whom gastric pull-up or jejunal free flap is being considered as a reconstructive option.
- 18-fluorodeoxyglucose positron emission tomography (PET) allows for evaluation of whole-body distant metastatic disease.
- Barium swallow esophagram can evaluate esophageal involvement either from direct extension of a laryngeal or hypopharyngeal primary cancer or a second primary cancer of the esophagus. It may also be useful in evaluating possible invasion of the prevertebral fascia.

Indications (Table 17.1)

- Advanced stage cancers of the hypopharynx (T3-T4)
- Advanced stage laryngeal cancers with involvement of the postcricoid mucosa, posterior hypopharyngeal wall, or the pyriform sinus with extension across the midline posteriorly
- Salvage surgery following primary chemoradiation in patients who fail organ preservation protocols

Contraindications

- Significant comorbidities precluding primary surgery and reconstruction
- Irresectable cancer such as encasement of the carotid artery or invasion of the prevertebral fascia
- Distant metastases

Preoperative Preparation

- Preoperative evaluation should note whether the patient may be intubated in a standard fashion or whether fiberoptic intubation is indicated. In patients with a large obstructive cancer, awake tracheostomy under local anesthesia may be the safest choice.
- Pan-endoscopy should be performed to map the cancer, obtain tissue for pathologic examination and diagnosis, and to evaluate for involvement of the cervical esophagus. Tumor mapping allows for better prediction of planned cancer resection and coordination with the reconstructive surgeon.

OPERATIVE PERIOD

Anesthesia

- General anesthesia

Positioning

- Bed turned 180 degrees and both arms tucked in
- Additional arterial and venous lines may be placed by the anesthesia team, with care taken to ensure that radial and/or femoral vessels are protected if reconstruction with radial forearm or anterolateral thigh free flaps is planned.
- Chest wall should be prepped if a pectoralis major myocutaneous flap is planned.
- Abdomen should be included in the field if there is a need for a jejunal free flap or mobilization of the stomach is required for a gastric pull-up.

TABLE 17.1 Staging of Hypopharyngeal Cancer

T1	Cancer limited to one subsite of hypopharynx and/or 2 cm or less in greatest dimension
T2	Cancer invades more than one subsite of hypopharynx or an adjacent site, or measures more than 2 cm but not more than 4 cm in greatest diameter without fixation of hemilarynx
T3	Cancer more than 4 cm in greatest dimension or with fixation of hemilarynx or extension to esophagus
T4a	Moderately advanced cancer Cancer invades thyroid/cricoid cartilage, hyoid bone, thyroid gland, or central compartment soft tissue (includes prelaryngeal strap muscles and subcutaneous adipose tissue)
T4b	Cancer advanced locally Cancer invades prevertebral fascia, encases carotid artery, or involves mediastinal structures

Used with permission of the American Joint Committee on Cancer (AJCC), Chicago, Illinois. The original and primary source for this information is the AJCC Cancer Staging Manual, Seventh Edition (2010) published by Springer Science+Business Media.

Perioperative Antibiotic Prophylaxis

- Perioperative antibiotics are started prior to the surgical procedure and continued for 24 hours postoperatively.
- Organisms covered include gram-positive microbes as well as anaerobes.

Instruments and Equipment to Have Available

- Standard head and neck surgical set
- Microvascular equipment—Sterile tourniquet, microvascular forceps (Jeweler's forceps), micro needle holders, arterial and venous frame and single clamps, vascular bulldog clamps, 8-0 or 9-0 nylon suture, microvascular anastomosis couplers, microscope or loupe magnification, heparinized saline, implantable Doppler

Key Anatomic Landmarks

- The hypopharynx consists of the pyriform sinuses, the postcricoid mucosa, and the posterior pharyngeal wall.
- The carotid sheaths lie immediately lateral to the hypopharynx.
- Sensory innervation is provided by the glossopharyngeal nerve (CN IX) and internal branches of the superior laryngeal nerve (CN X).
- The hyoid bone is the superior boundary of the hypopharynx, and the inferior boundary is at the lower border of the cricoid cartilage. This border is contiguous with and narrows at the upper end of the esophagus. The postcricoid region is from the arytenoid cartilages to the inferior border of the cricoid cartilage and forms a connection between the bilateral pyriform sinuses. Thus the postcricoid region is the anterior wall of the hypopharynx. The pyriform sinuses extend from the pharyngoepiglottic folds to the superior aspect of the cervical esophagus and are bound medially by aryepiglottic fold, the arytenoid cartilages, and the cricoid cartilage and bound laterally by the thyroid cartilage.

Prerequisite Skills

- Microvascular reconstructive surgeon for free tissue transfer
- General surgeon if gastric pull-up or a jejunal free flaps is indicated

Operative Risks

- Bleeding, infection, injury to accessory/hypoglossal nerves, pharyngocutaneous fistula, wound healing, and flap failure

Surgical Technique—Total Laryngopharyngectomy

1. An apron incision is planned with incorporation of the tracheostomy site with extension laterally to allow for bilateral neck dissection.
2. Subplatysmal flaps are elevated to the level of the hyoid bone superiorly and laterally, exposing both sternocleidomastoid muscles.
3. The cervical fascia is incised along the anterior border of the sternocleidomastoid muscles.
4. The fascia on the inferior border of the submandibular gland is incised to identify the posterior belly of the digastric muscle and connected to the fascial incision at the superior border of the sternocleidomastoid muscle.
5. Outer tunnels are developed between the strap musculature and the sternocleidomastoid muscles.

6. Bilateral neck dissections are performed with removal of lymph node levels II-IV. Neck dissection may be performed separately or left in continuity with the main specimen.
7. Arterial stumps including lingual, facial, superior thyroid, and transverse cervical arteries are preserved to allow for microvascular anastomosis.
8. Venous stumps including external jugular, anterior jugular, and interior jugular branches such as common facial and transverse cervical veins should be maintained, unless oncologic resection requires sacrifice of the internal jugular vein.
9. Strap muscles are divided superior to the tracheostoma, if present, or above the manubrium.
10. Dissection is continued superiorly along the trachea to the thyroid isthmus. Selected cancers may allow for sparing one or both lobes of the thyroid gland. In these cases, the thyroid isthmus is divided and the lobes are freed from their attachment to the trachea. Certain cancers may require removal of one or both lobes of the thyroid gland with the main specimen. Dissection is continued superiorly to the first or second tracheal ring.
11. Inner tunnels are developed between the carotid sheath and larynx along the prevertebral fascia. The superior laryngeal neurovascular bundle is ligated. Parathyroid glands are preserved, if possible.
12. The hyoid bone is exposed and the suprahyoid musculature is incised and dissected off of the superior aspect of the hyoid bone. The central portion may be grasped with a towel clamp and retraced laterally in either direction to expose the lateral cornua. Each cornu is retracted medially to rotate the hyoid away from the hypoglossal nerve and lingual artery. Dissection is continued bilaterally along the hyoid until each cornu can be freed using the finger loops of a hemostat for retraction.
13. Depending on the location of the cancer, the larynx may or may not be skeletonized as in a total laryngectomy. If limited circumferential resection is indicated, the larynx may be rotated and the pharyngeal constrictor muscles incised along the lateral border of the thyroid cartilage contralateral to the cancer. The pyriform sinus mucosa is reflected off the thyroid lamina using a Freer elevator. The mucosa is elevated on the side contralateral to the cancer. Alternatively, the deep cervical fascia may be divided medial to the carotid artery along the prevertebral fascia and the pharynx bluntly mobilized off the prevertebral fascia, assessing for tumor extension past the buccopharyngeal fascia. This allows for resection of a larger section of pharynx. Invasion of the prevertebral fascia indicates that the cancer is unresectable. If circumferential mobilization is performed, the pharynx may be entered above the hyoid contralateral to the site of most superior extent of the cancer.
14. Pharyngeal mucosal incisions are made horizontally along the posterior pharyngeal wall to free the upper pharynx and entire larynx. Typically a 2-cm margin superior to the highest extent of the lesion is required. Large cancers of the pyriform sinus may require resection of a portion of the base of the tongue as a superior margin.
15. Tracheal incisions are performed next, typically between the first and second tracheal rings. The anterior tracheal wall is sutured to the skin to prevent retraction of the distal trachea into the mediastinum. An endotracheal tube is placed and sutured to the skin. Scissors are used to extend the tracheostomy superiorly.
16. If cervical esophageal resection is indicated, incisions are made below the cancer. If total esophagectomy is performed, blunt dissection is performed superiorly along the esophagus, with dissection of the esophagus through an abdominal approach.
17. Surgical margins are sent for frozen specimen analysis. Wide margins should be taken, as hypopharyngeal cancers may have submucosal spread with diffuse local spread a common finding at surgery.[3] Fig. 17.1 illustrates intraoperative defect from total laryngopharynectomy.
18. Some cancers may necessitate mediastinal tracheotomy or manubrial resection for removal of superior mediastinal lymphadenopathy.
19. Tracheoesophageal puncture is typically delayed until healing is complete.
20. The medial heads of the sternocleidomastoid muscle are released from the sternum. The inferior aspect of the tracheal stoma may be completed prior to reconstruction. Half-vertical mattress sutures are placed, taking care to drape the skin over exposed cartilaginous rings.
21. Circumferential pharyngeal reconstruction is then completed by the reconstructive team (Table 17.2). Nasogastric tubes are placed prior to pharyngeal reconstruction in the absence of gastrostomy or jejunostomy tubes. Figs. 17.2 to 17.4 illustrate reconstruction with a tubed anterolateral thigh free flap with a salivary bypass tube.

Common Errors in Technique

- Accurate preoperative assessment of the surgical defect is critical for planning the reconstruction.
- Staging endoscopy is an important adjunct to imaging and allows for localization of the cancer disease and evaluation of esophageal extent.
- Cancers with less than 15 cm of cervical esophageal extent can be reconstructed with a jejunal free flap. Cancers with greater than 15 cm of cervical esophageal extent or those for which distal esophageal extent is intrathoracic require total esophagectomy with gastric pull-up.

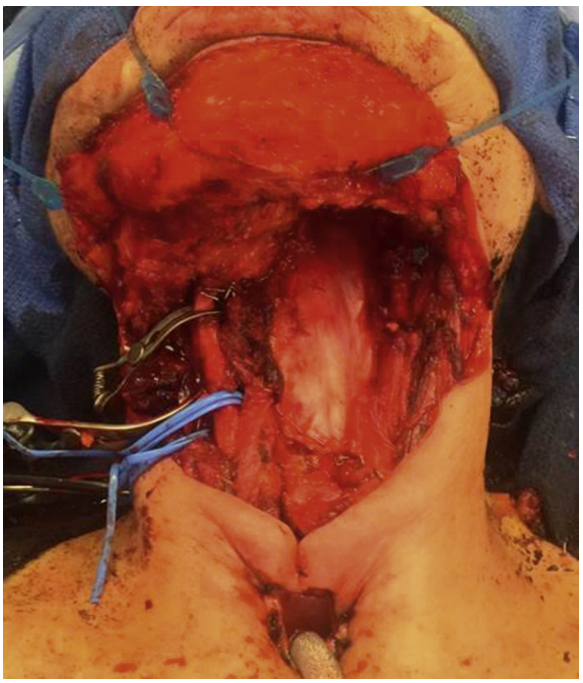

Fig. 17.1. Intraoperative photograph of total laryngopharyngectomy defect. Circumferential pharyngectomy defect is present. *(Courtesy of Dr. Steven Cannady.)*

TABLE 17.2 Reconstructive Options for Total Laryngopharyngectomy Defect

Reconstructive Technique	History/Physical Examination Pearls	Indications	Contraindications	Uses/Key Points
Pectoralis major myocutaneous flap	1. Prior chest wall surgery or vascular port 2. Restrictive lung disease may limit chest excursion following tight skin closure.	1. Failed previous reconstruction 2. Vessel-depleted neck 3. Lack of available donor sites 4. Medical comorbidities limiting lengthy surgery	1. Previous surgery involving pectoralis major muscle 2. Previous skin elevation over pectoralis major muscle may result in loss of myocutaneous perforators. 3. Previous surgery in subclavicular region may have affected vascular pedicle. 4. Extension to nasopharynx may require free flap due to shorter pedicle length 5. Significant bulk of the pectoralis major muscle may hinder placement in neck (obese patients, women with large breasts).	1. Complete skin-lined tubed flap for creation of neopharynx 2. 270-degree partial tubed flap with suturing of flap to prevertebral fascia 3. Salivary bypass tube recommended
Anterolateral thigh free flap	1. Injury or prior surgery may limit anterolateral thigh donor site as an option. 2. Patients with previous history of gait disturbance may require alternative flap harvest sites. 3. Presence of excessive subcutaneous adipose tissue in thigh may result in bulky flap, limiting circumferential repair	1. Partial or circumferential defects 2. External skin defects 3. Limited esophageal mucosal defect above thoracic inlet not requiring gastric pull-up 4. Reconstruction of combined mucosal and skin defects	1. Prior injury to donor site 2. Severe atherosclerotic changes to profunda femoris or superficial femoral artery (being bypassed by descending branch of lateral femoral circumflex artery) may limit selection of the flap.	1. Patch flap for hypopharyngeal defects with sufficient posterior pharyngeal wall mucosa 2. Tubed flap with sufficient cervical esophagus for anastomosis (see Fig. 17.2) with salivary bypass tube (see Figs. 17.3 and 17.4) 3. Combined mucosal and external skin defects
Radial forearm free flap	1. Injury or prior surgery to forearm may limit radial forearm as donor site. 2. Prior cervical esophageal injury/surgery 3. Preoperative swallowing assessment to evaluate for cervical esophageal involvement/extent	1. Reconstruction of partial or circumferential defects where anterolateral thigh free flap is overly bulky 2. Cervical esophageal reconstruction	1. Inadequate ulnar arterial flow to the hand via Allen test or ultrasound	1. Defects in which thin, pliable tissue is indicated 2. Tubed pharyngeal reconstruction with salivary bypass tube 3. Limited cervical esophageal involvement
Jejunal free flap	1. History of abdominal surgeries (e.g., prior jejunostomy tube placement) 2. Length and location of esophageal defect	1. Short esophageal defects (<15 cm) with accessible distal esophagus through the neck	1. Defects greater than 15 cm 2. Distal esophagus inaccessible 3. Prior extensive abdominal or jejunal surgery	1. Short esophageal defects—jejunal segments are limited by segmental blood supply
Gastric pull-up	1. Pulmonary status 2. Prior abdominal surgery (e.g., prior percutaneous gastrostomy tube placement, prior laparotomy) 3. Pre-existing gastrointestinal disorders (e.g., peptic ulcer disease)	1. Complete defect of cervical and upper thoracic esophagus	1. Advanced pulmonary disease 2. Stomach involvement with previous abdominal or gastric surgery	1. Vascular supply is right gastroepiploic and right gastric arteries 2. Proximal portion of stomach is at high risk—submucosal blood supply from gastroepiploic artery

POSTOPERATIVE PERIOD

Postoperative Management

Patients are typically managed in the intensive care unit in the immediate postoperative period. Aggressive pulmonary management is advocated especially in high-risk patients, such as those undergoing gastric pull-up procedures. Routine stoma care is provided. Regular calcium monitoring is indicated with supplementation as required. Perioperative antibiotics are continued for 24 hours. Tube feedings may begin on postoperative day 1 with slow rates and close monitoring for reflux. Proton-pump inhibitors are recommended following total laryngopharyngectomy reconstruction. Drains are closely monitored for salivary leakage and removed typically when the output is less than 20 mL/day. Free flaps are monitored every hour while in the intensive care unit and may be supplemented by portable Doppler. Pricking the flap with a needle to assess for blood flow may also be appropriate. Swallowing assessment varies per reconstructive technique and team. Salivary bypass tubes are removed prior to assessment for a leak. Barium swallow may be used as early as 7 to 10 days to assess the suture line, and patients may be advanced to a clear liquid diet if the suture lines are intact. Some reconstructive surgeons keep patients NPO for 1 month. Voice rehabilitation is via electrolarynx until tracheoesophageal perforation is performed.

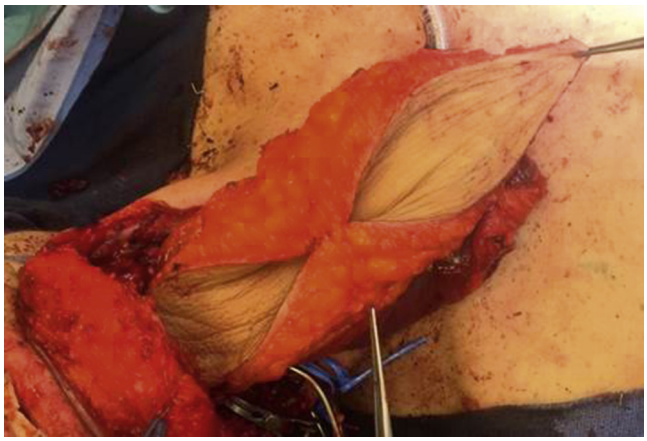

Fig. 17.2. Intraoperative photograph of a tubed anterolateral thigh free flap used for reconstruction of a total laryngopharyngectomy defect. *(Courtesy of Dr. Steven Cannady.)*

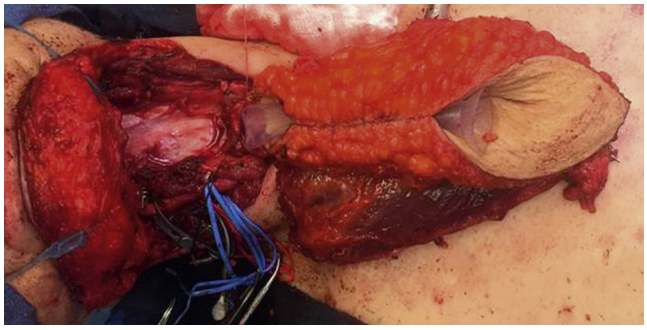

Fig. 17.3. Intraoperative photograph of a tubed anterolateral thigh free flap with salivary bypass tube prior to inset. *(Courtesy of Dr. Steven Cannady.)*



Fig. 17.4. Intraoperative photograph of inset of a tubed anterolateral thigh free flap with salivary bypass tube. *(Courtesy of Dr. Steven Cannady.)*

Complications

- Hypocalcemia is common following laryngopharyngectomy and has been reported to be as high as 45% in a large surgical series.[4]
- The same series reported a pharyngocutaneous fistula rate of 33% with wound complications in 25% of cases. Early fistulas may require opening the wound and packing, given the risk of mediastinitis. Packing is directed away from the carotid arteries or microvascular pedicles. Pharyngeal or esophageal anastomoses with leaking jejunal or gastric secretions may warrant return to the operating room to create a pharyngostome or repair with vascularized, nonirradiated tissue such as a pectoralis muscle flap.
- Strictures may occur at the inferior aspect of the reconstruction at the esophageal inlet and may occur weeks to months following surgery or after completion of radiotherapy. Repeat endoscopy to assess for recurrence followed by dilation may be performed on an outpatient basis.
- Jejunal free flaps may maintain enteric contractility and may result in functional dysphagia due to circumferential contractions during bolus transport.
- Gastric pull-up may result in regurgitation due to the loss of normal gastric reservoir or pyloric narrowing.
- The same large surgical series reported a late complication rate of 26% and a stricture rate of 15%. Permanent gastrostomy tube requirement was 16% and tracheoesophageal puncture for voice restoration was performed in 44%.

Alternative Management Plan

- Prognosis for hypopharyngeal cancer is poor. Rates of regional metastasis at presentation are between 60% and 80%, with 40% occurring contralateral. Distant metastatic rates are up to 60% at presentation or at follow-up.[5] A large epidemiological study noted 50% recurrence rate within 12 months, with a 50% distant metastatic rate.[3]
- Radiotherapy alone has a worse prognosis when compared with surgery and radiotherapy combined.[6-8]
- Induction chemotherapy with definitive radiation therapy is an alternative treatment option for hypopharyngeal cancer to surgery with adjuvant radiotherapy with comparable disease-free survival rates.[9,10]

Evidence-Based Medicine Question: What Is the Most Common Staging of Hypopharyngeal Carcinoma at Presentation?

Patients with hypopharyngeal squamous cell carcinoma typically present with advanced stage disease. Hall et al. reported TNM staging of 595 patients presenting with hypopharyngeal squamous cell carcinoma.[3] The most common T stage was T2 (34%) and the most common nodal stage was N0 (35%). Advanced T stage disease was T3—29%, T4a—20%, and T4b—4%. Advanced N stage disease was N2c—8% and N3—5%. The most common overall combination was T3N2 (13%). Overall stage IV presentation was 57%, with 20% of patients presenting with irresectable disease. Buckley et al. reviewed nodal metastasis in laryngeal and hypopharyngeal squamous cell carcinoma.[2] In the hypopharyngeal subset, 9/25 were N+ on clinical staging. Clinically staged N0 patients had 9/16 ipsilateral and 7/15 contralateral pathologic nodes. All 12 clinically staged N+ patients had bilateral nodal metastasis on pathologic examination. Patients with squamous cell carcinoma of the hypopharynx are at high risk of advanced tumor staging and bilateral nodal metastasis at presentation.

Editorial Comment

Because of the propensity of cancer of the hypopharynx to spread submucosally, wide surgical margins are required with frozen section control. Predicting the correct reconstructive option is important so that the correct surgical team is at hand. A critical step in the evaluation is to determine whether a cervical esophagectomy is required and that the lower anastomosis can be done in the neck or whether the distal resection margin is in the mediastinum and that a total esophagectomy is required with a gastric pull-up. A tubed pectoralis major or latissimus dorsi flap is a good alternative to a jejunal free flap.

Johan Fagan



Access the review questions and additional sources list online at http://www.expertconsult.com

REFERENCES

1. Richmon JD, Brumund KT. Reconstruction of the hypopharynx: current trends. Curr Opin Otolaryngol Head Neck Surg 2007;15(4):208–212.
2. Buckley JG, MacLennan K. Cervical node metastases in laryngeal and hypopharyngeal cancer: a prospective analysis of prevalence and distribution. Head Neck 2000;22(4):380–385.
3. Hall SF, Groome PA, Irish J, et al. The natural history of patients with squamous cell carcinoma of the hypopharynx. Laryngoscope 2008;118(8):1362–1371.
4. Clark JR, Gilbert R, Irish J, et al. Morbidity after flap reconstruction of hypopharyngeal defects. Laryngoscope 2006;116(2):173–181.
5. Takes RP, Strojan P, Silver CE, et al. Current trends in initial management of hypopharyngeal cancer: the declining use of open surgery. Head Neck 2012;34(2):270–281.
6. Pingree TF, Davis RK, Reichman O, et al. Treatment of hypopharyngeal carcinoma: a 10-year review of 1362 cases. Laryngoscope 1987;97(8 Pt 1):901–904.
7. Kim S, Wu HG, Heo DS, et al. Advanced hypopharyngeal carcinoma treatment results according to treatment modalities. Head Neck 2001;23(9):713–717.
8. Sewnaik A, Hoorweg JJ, Knegt PP, et al. Treatment of hypopharyngeal carcinoma: analysis of nationwide study in the Netherlands over a 10-year period. Clin Otolaryngol 2005;30(1):52–57.
9. Lefebvre JL, Chevalier D, Luboinski B, et al. Larynx preservation in pyriform sinus cancer: preliminary results of a European Organization for Research and Treatment of Cancer phase III trial. EORTC Head and Neck Cancer Cooperative Group. J Natl Cancer Inst 1996;88(13):890–899.
10. Gourin CG, Terris DJ. Carcinoma of the hypopharynx. Surg Oncol Clin N Am 2004;13(1):81–98.

REVIEW QUESTIONS

1. Approximately what percentage of patients with hypopharyngeal squamous cell carcinoma of the hypopharynx will have occult nodal metastasis at the time of presentation?
   a. 25%
   b. 50%
   c. 75%
   d. 90%

2. A patient presents with postcricoid squamous cell carcinoma of the hypopharynx. On staging endoscopy, 17 cm of cervical esophageal extent is noted. What would be the best reconstructive option following total laryngopharygectomy for this patient?
   a. Tubed pectoralis major myocutaneous flap
   b. Gastric pull-up
   c. Radial forearm free flap
   d. Anterolateral thigh free flap

3. Which of the following syndromes is associated with increased risk of squamous cell carcinoma of the hypopharynx?
   a. Plummer-Vinson syndrome
   b. Familial adenomatous polyposis
   c. Li-Fraumeni syndrome
   d. Birt-Hogg-Dubé syndrome

ADDITIONAL SOURCES

Genden E. In: Myers EN, Genden EM, editors. Master Techniques in Otolaryngology—Head and Neck Surgery. Reconstructive Surgery. Philadelphia, PA: Lippincott; 2015.

Fagan J. Total laryngectomy. In: Fagan JJ, editor. Open Access Atlas of Otolaryngology, Head & Neck Operative Surgery. Available at https://vula.uct.ac.za/access/content/group/ba5fb1bd-be95-48e5-81be-586fbaeba29d/Total%20laryngectomy.pdf.

18 Operative Otolaryngology: Bronchoscopy

Neil A. Christie

INTRODUCTION

Bronchoscopy is an important diagnostic tool that can also be used therapeutically. Both rigid (Fig. 18.1) and flexible bronchoscopes (Fig. 18.2) can be used, and both techniques have relative advantages and disadvantages. Although flexible bronchoscopy has largely replaced rigid bronchoscopy for diagnostic procedures, rigid bronchoscopy remains an important modality for therapeutic procedures.[1] The newer technologies of navigational bronchoscopy[2] and endobronchial ultrasound[3] have extended the diagnostic utility of bronchoscopy to include the assessment of peripheral lung nodules and peribronchial lymph nodes.

Bronchoscopy can allow for pathologic diagnosis of endobronchial lesions; peribronchial mediastinal and hilar lymphadenopathy; and now for peripheral lung lesions. It also is an effective tool for diagnosis and management of hemoptysis, airway obstruction, tracheobronchomalacia, and foreign bodies in the airway.[1]

KEY OPERATIVE LEARNING POINTS

1. Flexible bronchoscopy can be done with local anesthetic and spontaneous respiration and allows evaluation down to the segmental and subsegmental airways. However, the diameter of the working channel for biopsy and suction is small.
2. Rigid bronchoscopy is stimulating and requires general anesthesia, and the scope can reach down only to the trachea and the main stem bronchi. However, the diameter of the scope is large and allows for better suctioning and doing biopsies and other procedures.
3. Electromagnetic bronchoscopy allows virtual bronchoscopy and the passage of a directable catheter out in to the lung parenchyma to allow biopsies of peripheral lung lesions to be undertaken.
4. Endobronchial ultrasound allows visualization and real-time imaging for biopsy of mediastinal and hilar lymph nodes via bronchoscopy (Fig. 18.3).

PREOPERATIVE PERIOD

History

1. Hemoptysis
   a. What is the volume of the blood expectorated?
   b. Is the blood bright red or dark in color?
   c. Is it associated with any pneumonic symptoms or excessive mucous production?
   d. Is the patient taking any anticoagulants?
   e. Where there any preceding episodes?
   f. Is the patient a past or present cigarette smoker?
   g. Does the patient have a history of lung cancer or any risk factors for lung cancer?
2. Airway obstruction
   a. The degree of dyspnea present; at rest or only with exertion?
   b. The onset and duration of dyspnea
   c. Is the dyspnea positional?
   d. Any history of airway intervention in the past, such as oral tracheal intubation and mechanical ventilation (and for how long) or tracheostomy
   e. Any history of Wegener disease?
   f. Any history of foreign body aspiration?

Physical Examination

1. The patient's cardiorespiratory status should be evaluated, including cardiovascular stability and the degree of respiratory insufficiency.
2. Patient's body habitus should be evaluated, as well as the patient's degree of neck extension for oral tracheal intubation.
3. Evaluate for inspiratory or expiratory stridor, as well as the presence of distal airway wheezing (either unilateral or bilateral).
4. Evaluate for palpable cervical lymphadenopathy.
5. Evaluate the patient's dentition and oral cavity, checking for any loose teeth.

Imaging

1. Plain chest radiograph can be useful to evaluate tracheal narrowing, tracheal deviation, and lung parenchymal collapse or infiltrate. Gross mediastinal adenopathy and peripheral lung masses may also be apparent.
2. Computed tomography (CT) scan of the neck and chest can better evaluate the diameter of the airway, as well as the detection of lesions compressing the airway, either intrinsic airway lesions or lesions causing extrinsic compression. Will also demonstrate the presence and location of an aspirated foreign body. Any potentially pathologic lymph nodes or lesions of the lung parenchyma will be visualized. A CT scan may also show evidence of aspirated blood. If intravenous (IV) contrast is given, one can also evaluate for a potential pseudoaneurysm or the site of active bleeding.
3. Intraoperative fluoroscopy can be undertaken with bronchoscopic procedures, such as deployment of an airway stent and transbronchial biopsy of the lung.

Indications

1. Evaluation of patients with unexplained cough who do not have an obvious explanation, such as reactive airways disease or respiratory infection
2. Diagnosis of malignant disease. It could include biopsy of an endobronchial tumor, transbronchial aspiration of



Fig. 18.1. Rigid bronchoscope with light source attached.



Fig. 18.2. Flexible bronchoscopes from top to bottom: endobronchial ultrasound bronchoscope, therapeutic bronchoscope, regular adult bronchoscope, pediatric bronchoscope.

a mediastinal or hilar lymph node with the aid or endobronchial ultrasound, or biopsy of a more distal lesion in the lung parenchyma with electromagnetic navigational bronchoscopy.

3. Bronchoscopy can be used in patients who have hemoptysis to evaluate for the source of bleeding (either identification of an endobronchial lesion or, if the bleeding source is more distal, evaluation for which lobe or segment the blood is emanating from). Therapy can also be accomplished for hemoptysis with removal of blood clots from the airway, laser ablation of bleeding endobronchial tumors, or placement of balloon catheters to isolate bleeding portions of the lung.
4. Bronchoscopy can identify the site and degree of airway obstruction (diameter of residual airway and length of obstructing lesion). Interventions include débridement of obstructing endobronchial tumor with forceps or laser ablation and/or placement of endobronchial airway stents.
5. Bronchoscopy can also be used to evaluate and retrieve foreign bodies from the airway.
6. Lung washings and random transbronchial biopsies can be performed using bronchoscopy in the evaluation of patients with interstitial lung disease and infiltrates of unclear etiology in immunocompromised patients or patients who have undergone lung transplantation.
7. For patients with pulmonary abscess, occasionally bronchoscopy can be useful in establishing internal drainage of the abscess cavity to the airway.
8. Bronchoscopy can be used for clearing secretions for pulmonary toilet in patients with hypoxia and/or lung collapse not responding to more conservative respiratory measures.

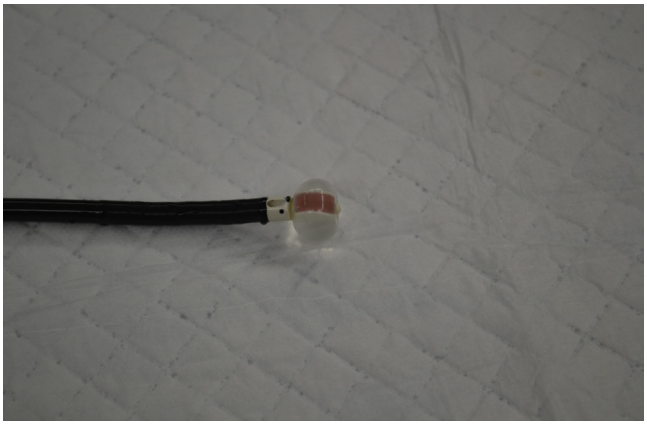

Fig. 18.3. Ultrasound probe on endobronchial ultrasound bronchoscope.

9. Mediastinal lymph nodes can be affected by a spectrum of pathologic conditions, both benign and malignant. Although the overall clinical situation in addition to imaging may be suggestive of a diagnosis, in most cases pathologic confirmation by tissue diagnosis of mediastinal or hilar lymph nodes is usually required for a definitive diagnosis. Real-time bronchoscopic endobronchial ultrasound-guided visualization of intrathoracic lymph nodes can be accompanied by transbronchial needle aspiration for diagnosis. This technique can be useful for diagnosing infectious diseases, sarcoidosis, and lymphoma and for staging lung cancers or other cancers metastatic to the mediastinal lymph nodes (see Fig. 18.3).
10. Peripheral lung nodules located distal to the segmental and subsegmental airways can now also be biopsied bronchoscopically using electromagnetic navigational bronchoscopy. The patient is on a table that emits electromagnetic waves that are detected by a miniature receptor located at the tip of a directable catheter, which is introduced via the bronchoscope. The system is linked to a computer where the patient's preloaded fine-cut CT scan serves as a virtual roadmap for the procedure. The probe on the end of the catheter can be directed to lesions that have been identified on the CT imaging. After the navigatable catheter has been moved into position the probe is removed, and biopsies can be obtained through the catheter.
11. Bronchoscopy can be used for placement of endobronchial catheters for brachytherapy.
12. Bronchoscopy can be used to facilitate placement of oral or nasal endotracheal tubes, particularly in patients with a difficult airway due to upper airway abnormalities or limited neck flexion or in patients who need to undergo an awake intubation. Bronchoscopy is also routinely used to confirm the correct positioning of double-lumen endotracheal tubes.

Contraindications

1. Patients undergoing rigid bronchoscopy need to be able to tolerate general anesthesia.
2. Patients with limited neck flexion may not be able to be positioned adequately to allow safe passage of the rigid bronchoscope.
3. In patient with hypoxia requiring high concentrations of oxygen, laser ablation of endobronchial lesions is contraindicated due to the risk of airway fire.
4. In patients with massive hemoptysis, flexible bronchoscopy is contraindicated because the capacity for blood aspiration through the small-diameter suction channel of the scope will not allow effective management.
5. Flexible bronchoscopy is contraindicated in patients with high-grade obstruction due to tracheal lesions, bilateral

main stem bronchial lesions, or large extrinsically compressing mediastinal masses for which the surgeon is not confident that one can safely bag ventilate the patient after the induction of anesthesia.

Preoperative Preparation

1. The patient needs to be fluid resuscitated and hemodynamically stable for anesthesia.
2. Any coagulopathy needs to be treated with vitamin K and blood factors, as appropriate, prior to intervention.
3. Appropriate imaging needs to be performed and immediately available for review in the operating room during the procedure.
4. Depending on the diagnosis, the patient and his or her family need to be aware of the gravity of the situation, potential morbidity or mortality associated with the procedure, and potential need for postoperative ventilation.

OPERATIVE PERIOD

Anesthesia

Flexible bronchoscopy can be undertaken with local anesthesia and IV sedation and spontaneous respiration or via an oral endotracheal tube under general anesthesia. Rigid bronchoscopy is very stimulating and requires general anesthesia.

1. Local anesthesia may include nebulized lidocaine, Cetacaine spray to the oropharynx, and direct installation of 1% lidocaine in the piriform sinus, on the vocal cords and into the trachea and main stem bronchi via the bronchoscope as it is advanced. A percutaneous intratracheal injection of lidocaine may also be useful. In addition to pharyngeal and airway topicalization, IV sedation with propofol, fentanyl, or Versed may also be administered. In patients undergoing bronchoscopy for retained secretions and respiratory insufficiency when one is attempting to avoid intubation, usually local treatment alone is undertaken. Similarly, in patients with high-grade airway obstruction in whom we are not confident that we could ventilate them on anesthetic induction, evaluation of the patients with local anesthesia alone and no sedation is indicated.
2. Rigid bronchoscopy requires general anesthesia, and several options of ventilation are available.
   a. Spontaneous ventilation. In cases of obstruction caused by high-grade endobronchial obstruction or very significant extrinsic compression, it is much safer to keep the patient breathing spontaneously until the bronchoscope is passed safely and a secure airway is established. In such cases, anesthesia is kept light enough that the patient is spontaneously breathing until such time as the rigid scope is in place in the airway. The disadvantage is the lack of muscular relaxation, which may preclude safe atraumatic passage of the rigid scope.
   b. Intermittent ventilation. With this technique the ventilatory circuit is intermittently attached to the scope to ventilate the patient. If a large air leak is present, one may need to occlude the mouth and nose with a hand or pack the oropharynx with moist gauze packing. While the patient is being ventilated, the surgeon cannot visualize the airway through the scope or perform any interventions (Fig. 18.4).
   c. Continuous ventilation. The viewing end of the scope is covered with a glass lens, and the ventilatory circuit is attached to a side port on the scope. Packing of the pharynx and/or nose and mouth occlusion may be required. It allows for uninterrupted viewing through the scope, but opening the port for interventions will interrupt the ventilation as it opens the ventilatory circuit.

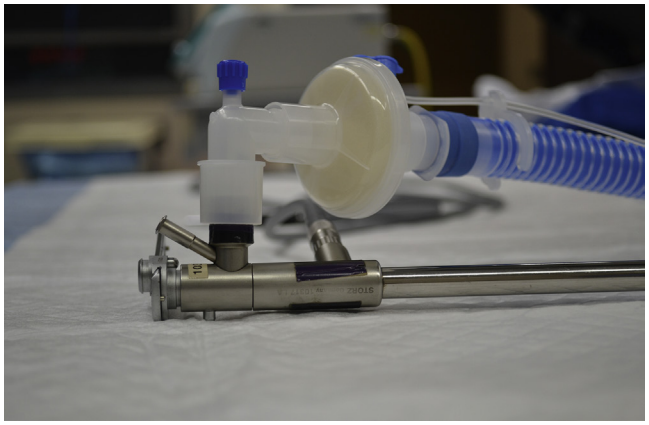

Fig. 18.4. Connection of rigid scope to ventilator circuit with occluding window on the end of the bronchoscope.



Fig. 18.5. Connection of High Frequency (JET) ventilator to rigid bronchoscope.

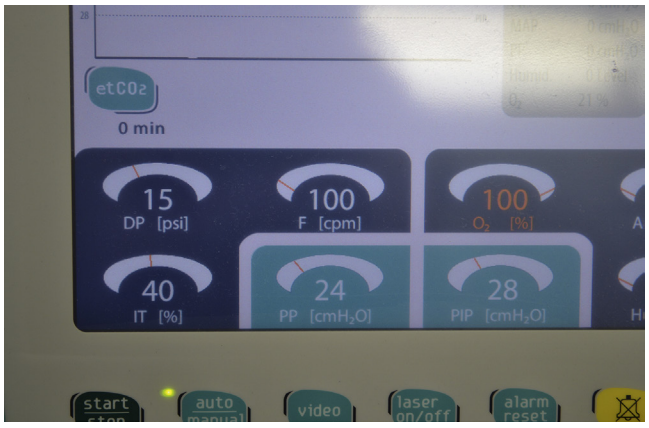

Fig. 18.6. High Frequency (JET) ventilator controls showing rate (usually 100 to 120 cpm), driving pressure (usually 15 to 25 psi), and inspiratory time (usually 40%).

   d. High Frequency (JET) ventilation. This is the preferred and the most common mode of ventilation during the performance of rigid bronchoscopy. It allows for continuous intervention in the airway because a closed airway circuit is not required for High Frequency (JET) ventilation. The respiratory rate, inspiratory time, and driving pressure can be adjusted to maintain adequate oxygenation and ventilation during the procedure (Figs. 18.5 and 18.6).

In the case of airway obstruction in which the airway is still narrow at the end of the procedure and will not accommodate an endotracheal tube, or if a proximal endobronchial airway stent has been placed, or if one has concerns about obstruction at the level of the larynx, it may be necessary to maintain the patient with the rigid scope and JET ventilation until such time as the anesthetic has been reversed and the patient is breathing spontaneously.

For endobronchial ultrasound in which the scope is relatively large and stimulating and patient movement and coughing can challenge the ability to do safe transbronchial lymph node aspirates, it is generally preferable to do this procedure under general anesthesia. Likewise for electromagnetic navigational bronchoscopy where patient movement can disrupt the catheter, it is also preferable to perform this procedure under general anesthesia; however, both procedures have been also performed successfully with conscious sedation.

Positioning

- Patients are positioned supine.
- For electromagnetic navigational bronchoscopy, patients have to be placed and centered on a detector plate that lies underneath them.
- For patients in severe respiratory distress, flexible bronchoscopy can be undertaken with the patient sitting up.
- Initiation of rigid bronchoscopy can be undertaken with the patient sitting up and then gradually placed supine when the airway is secure.
- For rigid bronchoscopy the patient's head is placed on a donut pillow, and the neck is extended such that the chin points vertically to facilitate the introduction of the bronchoscope.

Preoperative Antibiotic Prophylaxis

Prophylactic antibiotics are generally not required.

Monitoring

1. Continuous oximetry
2. Continuous electrocardiogram
3. Bispectral Index (BIS) monitor and nerve stimulator if rigid bronchoscopy is being done under general anesthesia

Instruments and Equipment to Have Available

1. Suction
2. Mouth guard protector and eye protector
3. Rigid bronchoscopes of several sizes (Fig. 18.7)
4. Flexible bronchoscope, including pediatric bronchoscope, regular adult scope, and therapeutic flexible bronchoscope (see Fig. 18.2)
5. Laryngoscope with a variety of blades. Video laryngoscope may also be of benefit in assessing the airway.
6. An assortment of endotracheal tubes
7. Lidocaine and a slip tip syringe for airway topicalization and aerosolization of the pharynx
8. Suction catheters and biopsy forceps and graspers for the rigid bronchoscope. If appropriate for the procedure, olive tip tracheal dilators should also be available.
9. An assortment of graspers and retrieval baskets for removal of foreign bodies
10. Flexible biopsy forceps for the flexible bronchoscope
11. Adjustable height stool on wheels for rigid bronchoscopy
12. Laser and laser fiber for cases of hemoptysis
13. Fluoroscopy equipment for cases of endobronchial stent deployment or electromagnetic navigational bronchoscopy

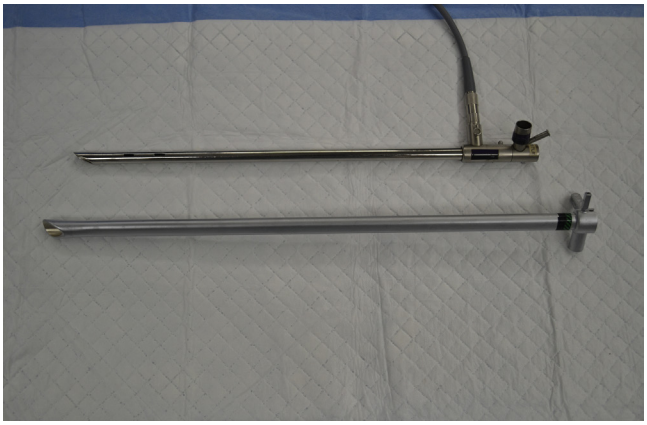

Fig. 18.7. Small and large rigid bronchoscope.

Key Anatomic Landmarks

1. Epiglottis
2. Vocal cords
3. Glottic opening

Prerequisite Skills

1. For flexible bronchoscopy, one must be facile with operation of a flexible endoscope.
2. For endobronchial ultrasound, one must be familiar with the ultrasound appearance of mediastinal lymph nodes and adjacent vascular structures.
3. For rigid bronchoscopy, one should be facile with laryngoscopy and oral tracheal intubation.

Operative Risks

1. Flexible bronchoscopy
   a. Risk of hemorrhage with endobronchial biopsy that may overwhelm the limited suction capacity of the flexible bronchoscope. Possibly leading to oxygen desaturation
   b. With electromagnetic navigational bronchoscopic biopsy of a parenchymal lesion there is risk of a pneumothorax.
2. Rigid bronchoscopy
   a. Injury to the teeth
   b. Pharyngeal injury
   c. Laceration, contusion, or edema of the tongue
   d. Laryngeal injury
   e. Tracheal injury, particularly if dilating the airway, which could produce a pneumothorax or pneumomediastinum

Surgical Technique

1. Flexible bronchoscopy
   Simply need to be facile with the endoscopic controls
2. Endobronchial ultrasound
   Need to be familiar with endoscopic ultrasound visualization of the mediastinal structures, as well as passing the needle sheath apparatus and aspirating
3. Electromagnetic navigational bronchoscopy
   Need to be facile with driving the directable catheter to the site of interest with the aid of the program software. Also need to be competent in passing the various biopsy needles, brushes, and forceps through the directable catheter once locked in place
4. Rigid bronchoscopy
   a. Apply eye protection and rubber tooth guard over upper teeth or gums (Fig. 18.8).
   b. Place the patient's head on a donut pillow, and extend the chin such that it is pointing vertically (see Fig. 18.8).



Fig. 18.8. Passage of the rigid scope through the mouth with protection of the upper teeth with the thumb.

c. Using a Yankauer suction, the pharynx is cleansed of any saliva that may obscure visualization of the epiglottis and the vocal cords.
d. Place the examiner's thumb over the upper teeth or gums to guide the rigid bronchoscope and to protect those structures from injury.
e. With the bronchoscope oriented vertically, and while viewing through the end of the bronchoscope, advance it down posterior to the tongue in the midline and elevate the tongue by dropping the proximal end of the scope down to visualize the epiglottis (see Fig. 18.8).
f. Advance the bronchoscope posterior to and distal to the epiglottis and then lift the bronchoscope anteriorly to visualize the arytenoids and the vocal cords and the glottic opening. At this juncture, the rigid bronchoscope will be horizontally orientated. External pressure can be placed on an anteriorly placed larynx to facilitate visualization of the vocal cords.
g. An alternative technique is to visualize the vocal cords with a handheld laryngoscope in the left hand and then pass the rigid bronchoscope with the laryngoscope in place with the right hand.
h. After the glottis is in view, the rigid bronchoscope is advanced toward the glottic opening.
i. Prior to passing the bronchoscope through the cords, it is rotated 90 degrees to align the vertically oriented glottic opening with the tip of the bronchoscope.
j. The bronchoscope is passed through the larynx into the trachea and rotated back to the proper orientation.
k. The operating table and the examiner's stool are adjusted so the examiner is comfortably situated.
l. Ventilation is then initiated through the bronchoscope by connecting either the ventilatory circuit to a side port of the scope or the High Frequency (JET) ventilator onto the Luer-Lok connector on the bronchoscope.
m. A rigid telescope may be passed through the rigid bronchoscope for better visualization, or alternatively the flexible bronchoscope may be passed through the rigid bronchoscope for better visualization of the distal airway.
n. It may be necessary to temporarily hold ventilation to avoid movement of foreign bodies while grasping them with forceps. Small foreign bodies less than the diameter of the rigid scope may be drawn out through the lumen of the scope. Larger foreign bodies require withdrawal of the rigid scope while holding the foreign body at the tip of the scope with grasping forceps.
o. On conclusion of the procedure, the patient can be ventilated using the rigid bronchoscope until such time as the anesthetic agent is cleared and the patient is breathing spontaneously, and then the bronchoscope can be safely removed.
p. While drawing back the rigid bronchoscope on termination of the procedure, the proximal trachea, larynx, and pharynx may be examined.

Common Errors in Technique

1. Levering the rigid scope off the upper teeth and in so doing causing injury to the teeth (see Fig. 18.8)
2. Not adequately topicalizing the pharynx and cords with peroral bronchoscopy prior to introduction of the bronchoscope
3. Inadequately sedating the patient prior to attempting to introduce the rigid bronchoscope

POSTOPERATIVE PERIOD

Postoperative Management

1. Patients should be monitored postoperatively in the recovery room or the intensive care unit, if indicated, for any signs of airway compromise due to laryngeal edema or pharyngeal or lingular injury secondary to introduction of a rigid bronchoscope.
2. A chest radiograph should be performed to rule out pneumothorax or pneumomediastinum following instrumentation with the rigid bronchoscope.

Complications

1. Injury to the teeth
2. Lacerations, contusions, or edema of the pharynx or tongue
3. Damage to the vocal cords or dislocation of the arytenoid
4. Massive hemorrhage that may overwhelm the ability to clear endobronchial blood, causing secondary hypoxemia. Particularly in the case of flexible bronchoscopy
5. Airway injury with secondary pneumothorax, pneumomediastinum, or subcutaneous emphysema

Alternative Management Plan

In patients with very severe and extensive airway compromise in significant respiratory distress, it may not be safe to administer any sedation to allow safe passage of the rigid scope. An alternative in such cases would be vascular cannulation for veno-venous extracorporeal membrane oxygenation or femoral arterial and venous cannulation for cardiopulmonary bypass. The patient could be thus supported until such time as a secure airway could be established either by stenting the airway or débriding endobronchial tumor.

DISCUSSION

Evidence-Based Medicine Question

Is a patient with high-volume hemoptysis best evaluated with flexible or rigid bronchoscopy?

When managing a patient with massive hemoptysis, it is far safer to evaluate the airway with a rigid bronchoscope in place. It allows the operator a much greater capacity for suction to clear blood from the airways. It also allows the passage of occlusion balloon catheters to isolate a bleeding lung to allow ventilation via the contralateral lung until such time as definitive treatment of the source of the bleeding can be undertaken.

Editorial Comment

The first bronchoscopy is attributed to Professor Gustav Killian, in 1897, who used a rigid bronchoscope under

local anesthesia to extract a foreign body from the tracheobronchial tree of an adult. Dr. Chevelier Jackson, who was born, raised, educated, and trained in Pittsburgh, refined the rigid bronchoscope in the 1920s by placing the light at the distal tip of the bronchoscope, which provided enhanced illumination. He is regarded as the "Father of Endoscopy."

Rigid bronchoscopes were used exclusively until Professor Sigato Ikeda of Japan invented the flexible bronchoscope in 1966 using fiberoptic bundles as a light source. More recently fiberoptic scopes have been replaced by bronchoscopes with a video chip located at the distal extremity of the scope. Bronchoscopy has come a long way since Dr. Jackson's time, but technological innovations have not altogether eliminated rigid bronchoscopy. Flexible bronchoscopy has largely replaced rigid bronchoscopy for diagnostic purposes, which can now be done as an office procedure, whereas rigid bronchoscopy remains the technique of choice for therapeutic procedures, such as extraction of foreign bodies, diagnosis and management of hemoptysis, and lower airway obstruction. The newer technological advances, including endobronchial ultrasound and navigational bronchoscopy, have extended the diagnostic utility of rigid bronchoscopy to include the assessment of peribronchial lymph nodes and peripheral lung nodules.

The evolution of this instrumentation has made bronchoscopy an area of overlapping interests for thoracic surgeons, otolaryngologists, and pulmonologists carrying out diagnostic bronchoscopy. Thoracic surgeons and otolaryngologists use both rigid and flexible bronchoscopes, and pulmonologists use flexible bronchoscopes exclusively. As the old saying goes "It ain't the engine, it's the engineer." Hands-on training in the use of these techniques is of utmost importance to ensure the accuracy of the procedure and the safety of the patient.

Eugene N. Myers

Access the review questions online at http://www.expertconsult.com



REFERENCES

1. Walter DM, Wood DE. Operative endoscopy of the airway. J Thorac Dis 2016;8(Suppl. 2):S130–S139.
2. Kalajers S, Gildea TR. Electromagnetic navigational bronchoscopy for peripheral pulmonary nodules. Thorac Surg Clin 2016;26(2):203–213.
3. Bade B, Furukawa B, Tanner NT. Convex probe endobronchial ultrasound. Semin Respir Crit Care Med 2014;35(6):636–644.

REVIEW QUESTIONS

1. Rigid bronchoscopy is the preferred approach over flexible bronchoscopy in all circumstances, except
   a. Massive hemoptysis
   b. Low-volume intermittent hemoptysis
   c. Severe airway compromise with extrinsic compression of the trachea due to a large mediastinal mass
   d. A large aspirated foreign body

2. Which technique would allow for best yield in diagnosing the cause of mediastinal adenopathy?
   a. Flexible bronchoscopy with blind transbronchial biopsy
   b. Flexible bronchoscopy with endobronchial ultrasound-guided aspiration
   c. Electromagnetic navigational bronchoscopic biopsy

3. What is the preferred mode of patient ventilation during the conduct of rigid bronchoscopy?
   a. Spontaneous ventilation
   b. Intermittent positive pressure ventilation
   c. Continuous positive pressure ventilation
   d. JET ventilation

4. In a patient in severe respiratory distress secondary to high-grade extrinsic compression of the airway, which anesthetic technique should be used prior to introduction of the rigid bronchoscope?
   a. Topicalization of the throat and larynx with lidocaine only until such time as the scope is in position
   b. Rapid induction of general anesthesia with intravenous (IV) propofol
   c. Rapid administration of general anesthesia with IV propofol and muscular relaxation with succinylcholine
   d. Topicalization of the throat and larynx with lidocaine and IV conscious sedation with propofol

19 Open Tracheostomy

David M. Johnson, David Eibling

INTRODUCTION

- Tracheostomy is essentially a "shortcut" into the airway that "bypasses" the upper airway.
- Most tracheostomies are performed for ventilator support in critically ill patients or as a temporary airway to accompany surgical procedures on the oral cavity, pharynx, or larynx (Fig. 19.1).
- Less common indications include sleep apnea, chronic lung disease, primary alveolar hypoventilation syndrome (Ondine curse), and conditions requiring prolonged mechanical ventilation.[1]

KEY OPERATIVE LEARNING POINTS

- Performance of a tracheostomy is substantially easier than making the decision to perform the procedure and where, when, and how to perform it.
- Most adverse outcomes from tracheostomy occur in the postoperative period, not intraoperatively.
- Cricothyroidotomy is the preferred procedure in emergency airway settings where seconds count.

PREOPERATIVE PERIOD

History

- Why does this patient need a tracheostomy?
- How soon will it be necessary?
- How long will it be required?
- Will the patient be on mechanical ventilation?
  - If so, for how long?
- Are there any alternatives?
- Where and by whom will the tracheostomy be managed?

Past Medical History

- Has the patient undergone prior tracheostomy or other neck surgery?
- Can the patient tolerate general anesthesia?
- Is the patient anticoagulated? If so, can it be stopped for the procedure?
- If on mechanical ventilation, what are the peak pressures?

Physical Examination

- Position of cricoid cartilage and trachea in the neck
- Presence of overlying masses or open wounds
- Evidence of blood dyscrasias (bleeding from puncture sites, gums)
- Ability of the patient to extend the neck

Imaging

Not required

Indications

1. Relief of upper airway obstruction (both acute and chronic)
2. Provide a means for assisted mechanical ventilation
3. Facilitate efficient tracheobronchial toilet

Contraindications

There are almost no absolute contraindications to tracheostomy. Those most commonly encountered are uncorrectable coagulopathies such as in patients with end-stage liver failure and extremely high ventilation pressures that may lead to flash pulmonary edema if the pressure is relieved suddenly for the time required for a tracheostomy.

Preoperative Preparation

- Decide whether a tracheotomy is indicated.
  - The decision to proceed with a tracheostomy is complex. Factors to consider include the following:
    - Relative advantages and risks of tracheostomy
    - Expected duration of endotracheal intubation
    - Capabilities of the institution and its personnel
    - Unique features of the patient's airway and respiratory physiology
    - Specific disorder or disease process and its likely course
- Every effort should be made to ensure that the patient's condition is optimized before the tracheostomy. Coagulopathies should be corrected and aspirin or other nonsteroidal anti-inflammatory medications stopped if possible.
- Patients presenting with stridor require that a safe airway be established as rapidly as possible.
  - Often, emergency control of the airway can be most rapidly accomplished with endotracheal intubation with or without endoscopic guidance.
  - Inability to intubate due to pharyngeal or laryngeal edema or tumor, or severe facial or laryngeal trauma, may mandate awake tracheostomy or cricothyroidotomy.
  - In an emergency, when seconds count, most surgeons would choose to perform cricothyroidotomy. Although it avoids the thyroid isthmus, cricothyroidotomy is not bloodless.
- Location: Tracheostomy in many institutions is routinely performed in the operating room (OR), whereas in others it is safely performed in the intensive care unit. Adequate instrumentation, lighting, suction, and assistance are required.
- Anesthesia or critical care teams should be present to manage the patient's cardiorespiratory function during tracheostomy. Patients with chronic respiratory insufficiency may require assisted ventilation and even cardiopulmonary resuscitation once obstruction is relieved.
- Preoperative planning should consider appropriate tracheostomy tube selection.
  - The tube must provide an adequate airway, facilitate artificial positive pressure ventilation if necessary, seal the trachea to reduce aspiration of material from above, and provide a means of suctioning the tracheobronchial tree.
  - Aspects of tube selection include the length, diameter, and shape of the tube and the neck plate. Typically, cuffed tubes are placed in adults to reduce aspiration of

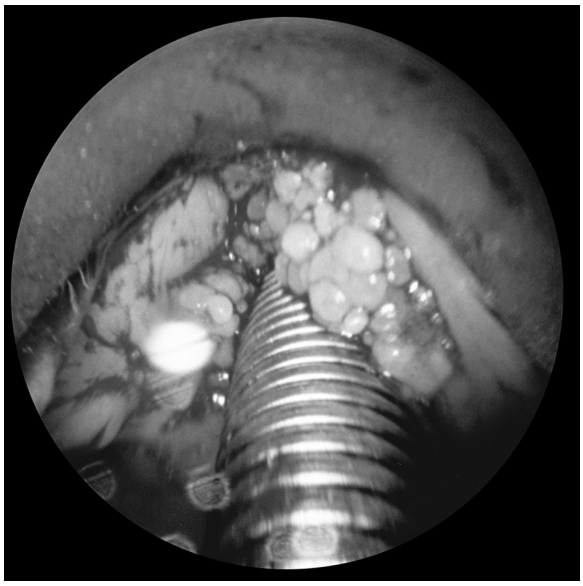

Fig. 19.1. Large-volume papilloma obstructing the airway in a young child.

secretions. Tubes with an inner cannula provide an added safety dimension because the inner cannula can be quickly removed in case there is a mucous plug, leaving the outer cannula in situ and the airway protected.
- Obese patients with thick pretracheal soft tissues may require extended-length tubes to decrease the risk of accidental decannulation or tube displacement.
- Extended-length tracheostomy tubes with proximal or distal extensions are available, as are tubes with adjustable flanges and length.
- Surgeon protection: All personnel in the OR should wear masks with face shields because splattering of purulent tracheal secretions commonly occurs at the time the cannula is inserted into the trachea.

OPERATIVE PERIOD

Anesthesia

- Tracheostomy may be performed under general, local, or awake sedation.
  - The choice of local or general anesthesia is dictated by the circumstances.
  - Patients with a marginal airway and respiratory distress must be managed with local anesthesia alone without sedation, which may suppress respiratory drive.
  - In children, the procedure is usually carried out under general anesthesia.
- When performing the procedure under local anesthesia, additional plain lidocaine is injected into the pretracheal tissues as the dissection deepens, because early airway injection may precipitate panic with subsequent obstruction.
- The surgeon should always stand by during intubation because adverse airway events can occur unexpectedly.
- Decisions and discussions regarding oxygen saturation should occur before starting the procedure. If the patient requires higher than 30% oxygen to maintain saturation, then electrocautery should not be used when the trachea is opened. Many teams routinely switch to 100% oxygen at this point due to the risk of desaturation from loss of airway pressure.

Positioning

- Position the patient supine with the neck extended.
- Usually the patient is placed on the operating table with a rolled towel or sheet under the shoulders to extend the neck, unless the patient has documented or suspected cervical spine injuries.
- Adults with airway obstruction may not be able to lie flat, and the tracheostomy may need to be performed with the patient sitting up at 45 degrees.
- Patients with severe cervical osteoarthritis, kyphoscoliosis, or other conditions in which the neck cannot be hyperextended present a formidable surgical challenge.

Perioperative Antibiotic Prophylaxis

- Although considered a "clean contaminated" procedure, tracheostomy is often performed in the presence of purulent tracheal secretions.
- If the patient is not already on antibiotics, they must be administered during induction of anesthesia and continued for a minimum of 24 hours.
- Antibiotic choices are typically driven by prior cultures in ill patients.
  - Clindamycin
  - Amoxicillin-clavulanate
  - Cephalosporin and metronidazole

Monitoring

- Routine anesthesia monitoring is needed with careful attention to oxygen saturation.

Instruments and Equipment to Have Available

- Routine tracheostomy set
- Confirm the presence of a "trachea hook" in the set.
- Tube should be selected and the cuff tested and then deflated

Key Anatomic Landmarks

- Thyroid notch
- Cricoid cartilage
- Sternal notch

Prerequisite Skills

- Basic surgical skills
- Experience with anterior neck surgery
- Familiarity with the anatomy of the cricoid, thyroid, and trachea and the accompanying venous structures

Surgical Technique

- Lidocaine 1% with 1:100,000 epinephrine is injected into the skin and subcutaneous tissue where the incision will be made. The neck, face, and upper chest are prepared with a suitable solution, and a drape is placed to allow easy access to the neck and oral cavity.
- A transverse incision is made in a skin crease approximately 1 cm above the suprasternal notch or 2 cm below the cricoid cartilage.
- Sharp dissection is carried through the subcutaneous tissue. Small rake retractors are used to provide good exposure. The anterior jugular veins should be identified and retracted laterally (Fig. 19.2); they need not be ligated unless inadvertently cut.

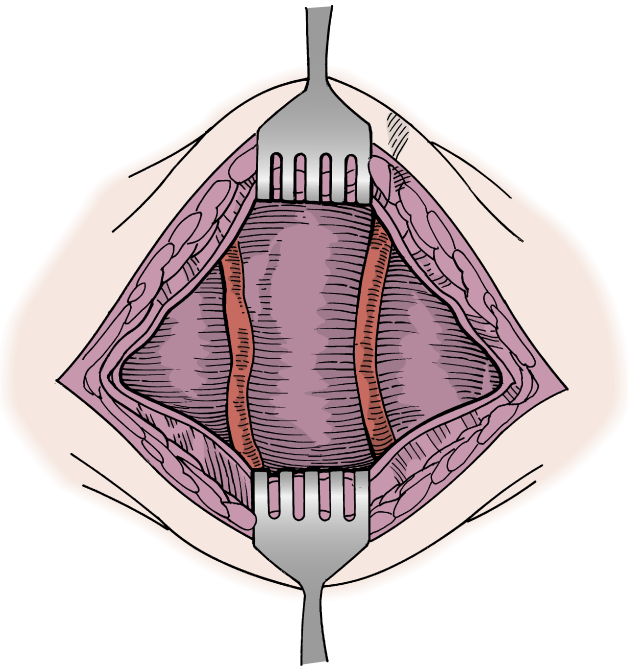

Fig. 19.2. The anterior jugular veins do not need to be sacrificed if uninjured.

- The strap muscles are split in the midline and retracted laterally (Fig. 19.3A).
- The thyroid isthmus is visualized and the anterior wall of the trachea identified (see Fig. 19.3B). Some surgeons routinely divide the thyroid isthmus, whereas others routinely retract it superiorly (see Fig. 19.3C). Ligation of the isthmus is facilitated by first incising the fascia inferiorly to the cricoid, exposing the trachea, then undermining the isthmus, which is then clamped, transected, and suture-ligated.
- Once the trachea is identified, a tracheal hook is placed under the cricoid or at the second tracheal ring and held by an assistant to immobilize the trachea.
- In infants and children, a vertical incision is made between the second and the third or the third and the fourth tracheal rings without removing any cartilage. Traction sutures are then placed just lateral to the incision (Fig. 19.4).
- In adults, the trachea is opened transversely between the second and third or third and fourth rings. Caution should be exercised when using electrocautery close to the trachea because of the risk of airway fire.
- Resection of the anterior portion of a tracheal ring may facilitate insertion of the tracheostomy tube. In older patients, the tracheal ring is calcified, and heavy scissors or a Kerrison rongeur must be used to excise the anterior portion of the tracheal ring.
- Traction sutures are placed in the midline around the inferior and superior rings with a ligature carrier (Fig. 19.5) or curved needle. Traction is applied to both sutures to exteriorize the stoma and retract the wound edges.
- The endotracheal tube or bronchoscope can be withdrawn to a point above the stoma at this point.
- Once the traction sutures have been satisfactorily placed and the endotracheal tube withdrawn, the tracheal cannula, with the obturator inserted, may be introduced into the stoma (Fig. 19.6A). Introduction of the tube is facilitated by beginning with the cannula at right angles to the trachea; then, as the cannula is inserted, it is rotated so that its axis is parallel to that of the trachea. Once the cannula is properly placed in the trachea, the obturator is removed and the inner cannula inserted. When the tracheostomy tube is in place and adequate ventilation through the tracheostomy tube is assured, the endotracheal tube or bronchoscope used to stabilize the airway may be removed.
- The tracheostomy tube is secured by suturing the neck plate to the skin (see Fig. 19.6B) and by a Velcro strap or tracheostomy tapes tied securely with the neck flexed. In patients undergoing head and neck surgery, the tape is not used if it crosses the cervical flap incision or causes constriction of the blood supply of a flap brought up through the neck. The stay sutures are taped to the neck.
- It is important to secure all bleeding points with ligatures or electrocautery to prevent bleeding postoperatively. The incision should not be sutured or packed to prevent subcutaneous emphysema. The wound may be left open or a very light dressing applied.

Special Considerations for the Obese Patient

- Obstructive airway pathology is commonly comorbid with obesity and can complicate both the initial procedure (flash pulmonary edema) and decannulation plans (poor tolerance of capping due to sleep apnea). Patients and family should be counseled accordingly.
- Removal of excessive subcutaneous tissue is advisable to create a shorter tract between skin and trachea, and it assists in creating skin flaps to mature the stoma.
- Maturation of the stoma with half-mattress sutures between skin and trachea is a valuable adjunct in obese patients and will reduce the chances of a false passage should the tube become dislodged in the early postoperative period. However, eventual closure will require a secondary surgical procedure.
- Extended-length tracheostomy tubes (e.g., Shiley XLT) are available to better match the patient's anatomy (Fig. 19.7).

Special Considerations for Pediatric Tracheostomy

Airway misadventures are potentially catastrophic consequences in children. Pediatric tracheostomy tubes (Shiley #3 or smaller) do not have inner cannulas. As a result, the following technical modifications should be considered:

- Naso- and orogastric tubes are removed prior to tracheostomy so that they are not mistaken for the trachea during palpation.
- A vertical skin incision may be preferred (despite its cosmetically less desirable nature) for ease of extending the incision if necessary and because transverse skin flaps may obscure tract visualization.
- Repeated palpation to ensure midline dissection is paramount.
- The thyroid isthmus is always divided so it does not obstruct the tract in case of accidental decannulation.
- Nondissolvable monofilament traction sutures are placed lateral to the proposed tracheal incision to facilitate exposure; they are labeled LEFT and RIGHT, taped securely to the chest, and removed following successful first tube change.
- The stoma can be matured by tacking the skin and tracheal incisions together in half-mattress fashion using dissolvable suture.
- Flanges are securely tied around the neck using shoestring-style ties. In children, the flange is not sutured to the skin, which would hinder replacement in case of accidental decannulation or plugging, particularly when the tracheostomy tube does not have an inner cannula.

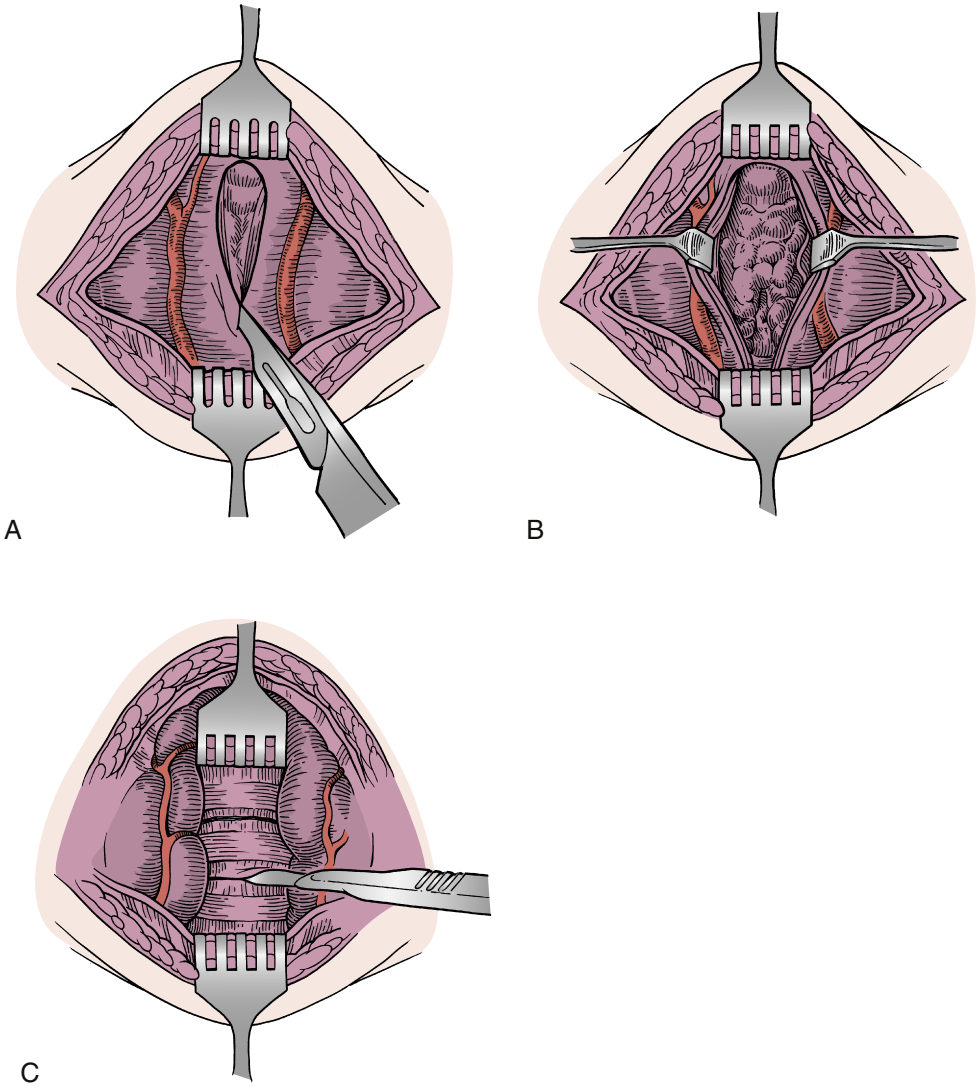

Fig. 19.3. A, The strap muscles are split in the midline and retracted laterally. **B,** The trachea and thyroid isthmus are identified. **C,** The trachea is entered through an incision between the second and third tracheal rings as the thyroid isthmus is retracted superiorly, or divided, as required.

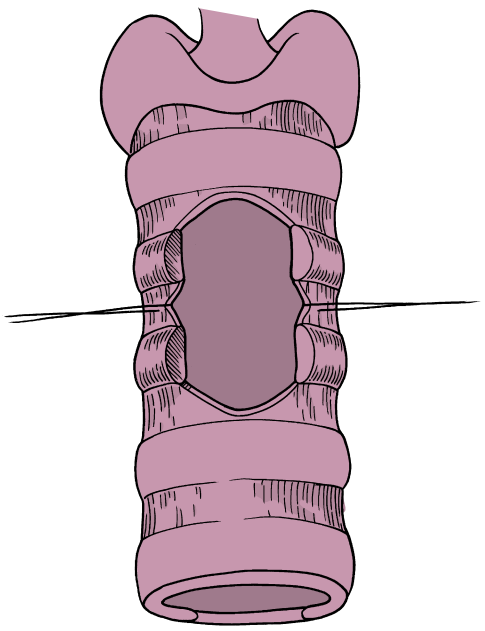

Fig. 19.4. Traction sutures are placed lateral to the stoma in children. No cartilage is removed.

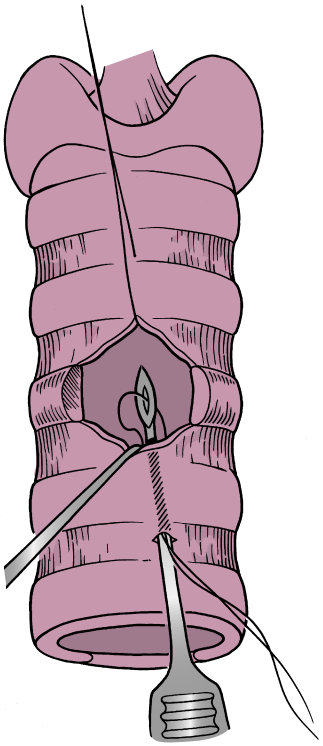

Fig. 19.5. Traction sutures are placed superior and inferior to the stoma in adults.

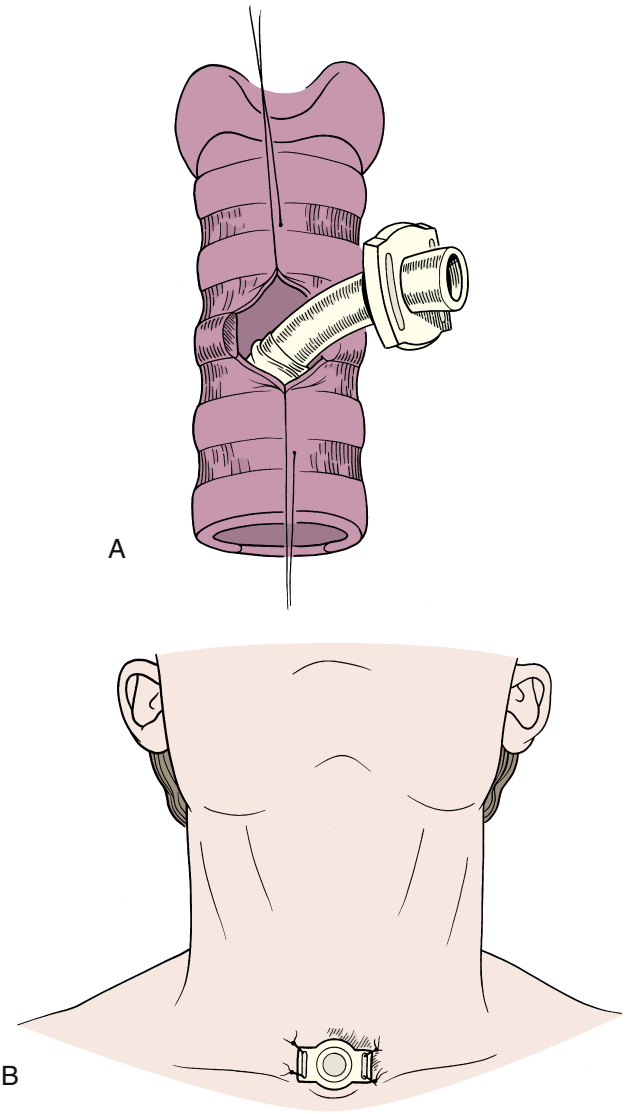

Fig. 19.6. A, The tracheostomy tube is inserted into the trachea. **B,** The neck plate of the tracheostomy tube is sutured to the skin. The use of tapes is optional.

Common Errors in Technique

Intraoperative Complications

Hemorrhage.

- Bleeding during tracheostomy may be minimized by careful attention to the details of the procedure. Bleeding is usually minimized by staying in the midline with the dissection, being cautious to dissect layer by layer, and maintaining adequate light and assistance with retraction of the soft tissues for adequate exposure.
- Bleeding from transection of the anterior jugular vein, the thyroid isthmus, or a high innominate artery are all possible and should be dealt with appropriately by identifying, ligating, or cauterizing the injured vessel.

Intraoperative Tracheoesophageal Fistula.

- Intraoperative tracheoesophageal fistula may occur when the tracheal wall has been injured inadvertently, usually during an "urgent" tracheostomy with overpenetration of the trachea itself.
- An open neck exploration and repair may be necessary once the airway has been established. The wounds in the trachea and the esophagus must be closed separately.

Pneumothorax and Pneumomediastinum.

- Entrainment of air into neck tissues is most likely to occur in a patient suffering from air hunger when the patient is struggling to breathe against an obstructed airway. Entrained air is then "pulled" into the mediastinum.
- Pneumothorax may occur due to direct puncturing of the pleura by the surgeon; this is most common in children, in whom the apex of the lung protrudes into the lower neck.
- Pneumothorax may also occur if the tracheostomy tube is inadvertently inserted into a "false passage" (Fig. 19.8).
- Pneumomediastinum is most common in children and is usually noted on routine chest radiographs.
  - Air can be forced from the open tracheostomy into the deeper planes of the neck by excessive coughing or positive pressure ventilation.
  - Patients with pneumomediastinum are generally asymptomatic, and no therapy is required.

Cardiopulmonary Complications.

- Cardiopulmonary arrest may occur after an obstruction is resolved in patients who have had chronic air hunger and elevated CO_2 levels. The anesthesia team should be alerted to this possibility in the event that cardiopulmonary resuscitation is necessary.
- Sudden release of endobronchial pressure may also result in flash pulmonary edema or congestive heart failure due to extravasation of fluid into alveoli in response to reduction of obstruction-induced positive end-expiratory pressure.

Fire.

- Fire during tracheostomy is a rare but catastrophic event. Fire requires fuel, oxidizer (enriched oxygen/nitrous), and a source of ignition.
- Fire risk should be discussed prior to any surgical procedure as part of the preprocedure briefing, especially tracheostomy, and plans regarding oxygen delivery reviewed with the team.
- External burns may result from the use of electrocautery shortly after prepping the skin with alcohol-containing solutions (fuel).
  - This is of particular concern in hirsute patients, in whom body hair interferes with the drying of the solution.
  - Every effort should be made to ensure that the operative field is completely dry before electrocautery is used. Alcohol-based solutions should be avoided.
- Fire may occur any time electrocautery is used in the presence of high concentrations of oxygen, whether delivered by mask (as in local procedures) or via the endotracheal tube under general anesthesia. In the latter case, the endotracheal tube is the fuel. Oxygen concentrations should be kept at a minimum safe concentration for the patient, and cautery should never be used to enter the airway, especially in unstable patients in whom reducing the oxygen concentration represents unacceptable risk.
- In the unfortunate instance of an airway fire, the immediate response includes the following:
  - Disconnect the oxygen supply.
  - Remove and replace the endotracheal tube.
  - Flood the field with water.
  - Perform bronchoscopy to assess the extent of injury.
  - Treat medically with antibiotics and steroids, and observe in the ICU.

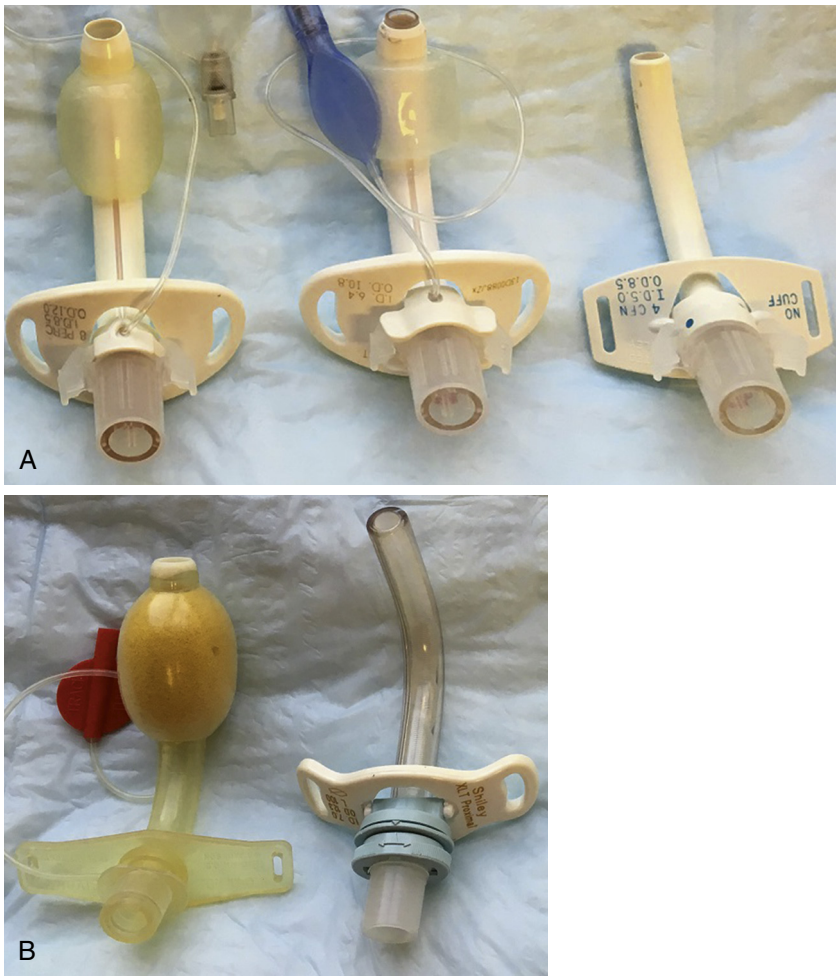

Fig. 19.7. A, Three common tracheostomy tubes. *Top to bottom*: #4 uncuffed Shiley, #6 cuffed Shiley, #8 cuffed percutaneous tracheostomy tube (note the tapered distal end). The smaller-diameter tubes are also shorter. **B,** Two specialized tubes. *Top*: uncuffed #7 Shiley XLT (extra length). This tube is termed "proximal" because the extra length is the proximal portion of the tube before the bend to accommodate a deeper neck incision. *Bottom*: Bivona Fome-Cuf tube, typically used for patients requiring chronic ventilator support.

POSTOPERATIVE PERIOD

Postoperative Management

Most adverse events occur in the first postoperative week, so care of the tracheostomy is critical in assuring a safe outcome for the patient.

- Nursing staff must be aware of the unique needs of the patient with a fresh tracheostomy. Family counseling and highly skilled nursing care are extremely important to support the patient during this time.
- Postoperative care is greatly facilitated through preoperative teaching. This helps allow both children and adults undergoing tracheostomy to adjust to this new way of breathing. Evidence indicates that patients undergoing tracheostomy experience reductions in their quality of life.[2]
- Patients are placed in a semi-Fowler position in the initial postoperative period to maximize the ease of coughing and deep breathing, to facilitate suctioning, and to minimize discomfort.
- Vital signs must be monitored carefully because changes in blood pressure, respiratory rate, or pulse rate may indicate that there is a new or ongoing respiratory problem or that the tube may be plugged or has been displaced out of the trachea. Agitation, anxiety, and restlessness may all indicate hypoxia.
- Tracheal suctioning is performed as necessary to clear pulmonary secretions and aspirated oral secretions and to verify patency of the tracheostomy tube.
- Humidification is required to facilitate mucociliary transport of secretions and to prevent crusting, accumulation of secretions, and eventual obstruction of the airway. Humidification is usually delivered through a tracheal mask. The use of a T-piece is avoided because the torque exerted on the tracheostomy tube traumatizes the tissue with movement.
- The inner cannula is removed frequently and cleaned or replaced to assure that obstruction with insipated mucus does not occur.
- The tracheostomy site should be cleaned as often as necessary with normal saline or hydrogen peroxide but at least 3 or 4 times daily. The skin under the tracheostomy neck plate should be kept dry with a thin nonadherent dressing such as Telfa to prevent maceration.
- In the absence of complications, the tube should not be changed until adhesions form between the overlying soft tissues and the trachea, typically 5 to 7 days postoperatively.
- Changing the tracheostomy tube requires some finesse and should not be required unless the patient is to be changed from a cuffed to an uncuffed tube or if the cuff fails. Tube replacement in the first 48 hours requires the following:
  - Optimal patient positioning

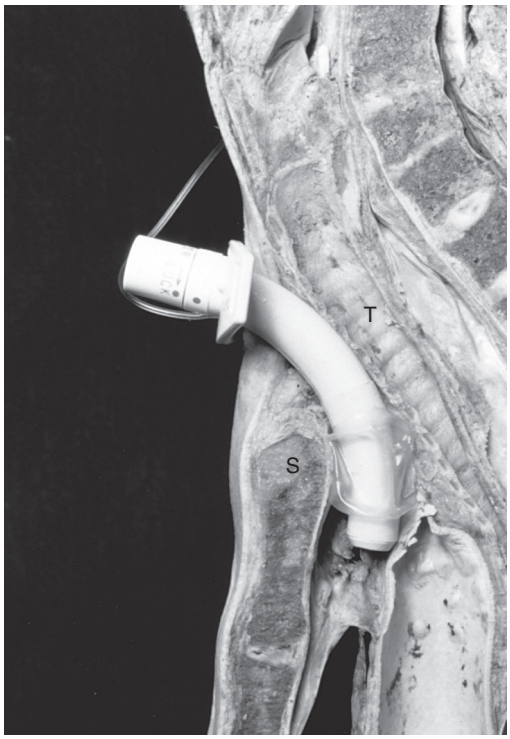

Fig. 19.8. Mechanism of false passage between the sternum (S) and the trachea (T). *(From Myers EN, Stool SE, Johnson JT: Complications in tracheostomy. In Myers EN, Stool SE, Johnson JT [eds]: Tracheostomy. New York: Churchill Livingstone; 1985, p 150.)*

  - Assistance
  - Adequate light
  - Tracheal hook
  - Suction
- The use of a tube exchanger, a long semiflexible tube with a central lumen through which ventilation is possible, may be useful in difficult tracheostomy tube changes.

Decannulation

- Decannulation in adults can be safely accomplished by following a few simple steps.
  - Indirect or flexible endoscopy should be used to ensure that the upper airway is adequate and the larynx is competent.
  - The tracheostomy tube is then downsized and plugged during waking hours. The patient must be instructed to remove the plug in the event of dyspnea or shortness of breath.
  - If the patient tolerates the plug for 24 hours, the cannula can be removed and the stoma covered with a light dressing and occlusive tape. The period of plugging allows for adequate evaluation of airway adequacy. If the plug is not tolerated, the nature of the obstruction must be investigated.
- Children should undergo endoscopy before decannulation. Often a granuloma in the stomal site is found; removing the granulomas enhances successful decannulation.

Postoperative Complications

Unfortunately, complications following tracheotomy are not rare. Most occur hours, days, or weeks following the procedure, rather than intraoperatively.[3,4] A recent collaborative study has been established to maintain a database on post-tracheotomy events (www.globaltrach.org), and instructional videos and teaching materials are available on a website (www.tracheostomy.org.uk).

Immediate Postoperative Complications

Tube Obstruction.

- The tube may be obstructed by thick or dried mucus or blood clots.
- Prevention includes attentive nursing care, proper humidification, and frequent suctioning.
- When possible, a tracheostomy tube with an inner cannula should be selected to facilitate regular inspection, cleansing, and suctioning.
- If an obstructed tube cannot be cleared, it should be removed and replaced.

Displaced Tracheostomy Tube.

- Displacement of the tracheostomy tube may occur at any time and is potentially fatal.
- Accidental decannulation in the early postoperative period can be catastrophic because the tract has not formed. After the tube is removed, the tissues collapse, sealing off the airway and making tube replacement difficult or impossible.
- Attempts to replace the tube blindly can lead to a false passageway, leading to death (see Fig 19.8).
- Patient factors that may predispose to displacement of the tube include the following:
  - Obesity
  - Excessive coughing
  - Agitation
  - Physical factors include the following:
    - Incorrect tube selection (usually too short)
    - Incorrect location of the opening into the trachea (usually too low)
    - Creation of a false passage (see Fig. 19.8)
    - Loosened or inadequately tied tracheostomy tapes
    - Use of bulky dressings under the neck flange: Such situations are largely preventable by selection of the correct tube and suturing the neck plate to the skin.
- Displacement of the tracheostomy tube should be suspected when a patient with a recent tracheostomy develops respiratory distress or is suddenly unable to speak.
- It is important to avoid positive pressure ventilation through a displaced tube because pneumomediastinum and tension pneumothoraces may lead to patient demise within minutes.
- Replacement of the tube is facilitated in the early postoperative period by using the traction sutures.
- If tube reinsertion fails, or in a patient with known difficult insertion, it may be best to reintubate the patient from above and identify the tracheostomy tract once the airway is secured.
- Identifying the tracheal opening with a flexible endoscope or a suction catheter and inserting the tracheostomy tube using the Seldinger technique is an alternative method of restoring the airway.

Postoperative Hemorrhage.

- Postoperative bleeding may occur as in any surgical procedure.
- Treatment requires identification and ligation of the offending vessels.
- For "oozing," use of a hemostatic packing such as Surgicel may be helpful.
- Coagulopathies should be identified and corrected.

- If bleeding is significant, the patient should be returned to the OR, the wound explored, and hemostasis achieved.
- Packing an actively bleeding tracheostomy site should be avoided because the packing can divert air into the subcutaneous tissues and blood into the tracheal lumen.

Wound Infection.

- The tracheal wound is colonized within 24 to 48 hours by many species of organisms, including *Pseudomonas* and *Escherichia coli*, as well as gram-positive cocci such as *Staphylococcus epidermidis.*
- Antibiotics do not prevent colonization of the wound and the biofilm on the tube itself.
- The longer the tube is in place, the heavier the load of biofilm. Regular tracheostomy tube changes every 2 weeks have been shown to decrease the incidence of granulation tissue and biofilm formation.[5]
- Tracheobronchitis may be due to underlying disease, aspiration, or both. Treatment is suctioning, vigorous pulmonary exercise (blow bottles, cupping and clapping, ambulation), and judicious administration of antibiotics.
- Rarely, necrotizing stomal infections may occur with substantial loss of soft tissue down to and including the tracheal wall. Rarely, local flaps may be necessary to provide soft tissue coverage of vital structures.

Subcutaneous Emphysema.

- Air may be forced into the subcutaneous tissues during or shortly after tracheostomy. Factors predisposing to this complication include the following:
  - Excessive coughing
  - Use of an uncuffed tracheostomy tube
  - Tight suturing of the wound around the tracheostomy tube
  - Packing of the wound
- If the subcutaneous emphysema is severe, the wound should be opened and any packing removed.
- If mild and not progressing, no treatment is necessary because the air will eventually be absorbed from the tissues.

Late Postoperative Complications

Granulation Tissue.

- Considered to be a late complication or sequela of tracheostomy, variably reported as occurring in 3% to 80% of cases
- Commonly seen in children, especially those in whom a fenestrated tube has been used
- May lead to bleeding, difficult tube changes, delayed decannulation, and even completely obstruct the tracheostomy tube
- Factors believed to favor formation of granulation tissue include the following:
  - Bacterial infection
  - Gastroesophageal reflux
  - Suture material
  - Powder from surgical gloves
- Treatment
  - Topical treatments such as steroid creams, antibiotic ointments, and silver nitrate may be beneficial.
  - Larger amounts of granulation tissue, particularly when obstructive, may require surgical excision, with or without the use of the laser.
- The prolonged presence of the same indwelling tracheostomy tube elicits an inflammatory tissue response favoring the growth of granulation tissue, increased secretions, and bacterial colonization with biofilm production.[5] Regular tube changes, on a schedule of every 2 to 3 weeks, have been shown reduce the incidence of granulation tissue.

Late Tracheoesophageal Fistula.

- Rare complication
- May result from an overinflated or improperly fitted cuff or malpositioned tracheostomy cannula pushed to the posterior wall of the trachea against an indwelling nasogastric tube
- Often a misdiagnosis because appearance of food through the tracheostomy is more likely to represent aspiration rather than a tracheoesophageal fistula
- Modified barium swallow will distinguish between these diagnoses.

Innominate Artery Rupture.

- Rare
- Usually occurs within the first 3 weeks after tracheostomy
- May occur in patients of any age
- Predisposing factors include the following:
  - Placing the tracheostomy low in the neck below the third tracheal ring where the inferior concave surface of the cannula may erode the artery
  - Aberrant course of the innominate artery such that it crosses the trachea at an abnormally high level
  - Selection of an excessively long or curved tube, the tip of which may erode the trachea and the vessel wall deep to it
  - Overextending the neck during the tracheostomy procedure
  - Prolonged excessive pressure on the tracheal wall by an inflated cuff
  - Tracheal infection
- Recognition and treatment
  - Rupture of the innominate artery is usually heralded by a "sentinel bleed," which may stop and be followed a few days later by a catastrophic hemorrhage. The patient coughs up bright red blood from the tracheostomy tube.
  - If recognized, the cuff of the tracheostomy tube should immediately be overinflated and suprasternal pressure applied in an attempt to control the hemorrhage long enough to transport the patient to the OR for emergency thoracotomy.

Tracheal Stenosis and Tracheomalacia.

- Late complications due to overinflation of the tracheostomy tube cuff with resultant necrosis of mucosal and ultimately the underlying cartilage rings
- Prevention requires careful monitoring of tracheostomy cuff pressures by nursing staff.

Tracheocutaneous fistula, *depressed scar*, and *laryngotracheal stenosis* are discussed elsewhere.

ALTERNATIVE MANAGEMENT PLAN

Decision making typically includes tracheostomy versus intubation versus observation. In selected terminal cases, decisions to forego airway intervention may be appropriate.

DISCUSSION

Evidence-Based Medicine Question

Which patients with tracheostomy are at the highest risk?

It is usually assumed that the riskiest period for patients undergoing tracheostomy is during the procedure. However, several recent studies refute this and point out that adverse outcomes, including death, are much more common in the postoperative period. Halum et al.[4] in a large series of 1175 tracheostomy procedures performed in multiple institutions in a 2-year period observed that only 1.4% of the patients in the series suffered an intraoperative complication, whereas 5.6% suffered a complication in the first week and 7.1% suffered some sort of late complication. Of their series, 22% died during their hospital stay; however, only a small minority died of complications due to the tracheostomy. See also Das.[3]

Editorial Comment

Although the earliest reference to tracheostomy dates back to Egyptian tablets from about 3600 BC,[6] the most dramatic was attributed to Alexander the Great (356–323 BC), who is said to have performed a tracheostomy with the tip of his sword on one of his soldiers who was choking.[7]

The use of tracheostomy has increased during the last 2 centuries, and the indications have broadened. The most common indications have changed in more recent years from urgent airway establishment as a result of obstruction due to inflammation, foreign body, trauma, sleep apnea, and neoplasm to the use of mechanical artificial respiration in patients in intensive care units.

Endolaryngeal endotracheal intubation dates back to Avicenna (AD 980–1037), who bent tubes of gold and silver and used them to cannulate the larynx and trachea in patients with airway distress. This means of establishing and maintaining an airway has certain limitations in long-term usage such as damage to the vocal cords, subglottis, and trachea. The use of a tracheostomy in the near term for patients who will require long-term ventilatory assistance will prevent such problems.

A tracheostomy can be the simplest or the most difficult operation that the surgeon may need to perform. Because the procedure is done frequently and may be considered rather simple, its performance may be delegated to entry level residents who, especially if they are unsupervised or do not have proper lighting, suction, and assistance—all prerequisites for a successful tracheostomy—may lose a patient or have complications that may be deadly or at least quite problematic. Therefore the tracheostomy should be given a lot of respect for the great benefits of its use and for the complexity of the indications and the proper surgical techniques.

Barry Schaitkin

Access the review questions and additional sources list online at http://www.expertconsult.com

REFERENCES

1. Zeitouni A, Kost K. Tracheostomy. A retrospective review of 281 patients. J Otolaryngol 1994;23:61–6.
2. Gilony D, Gilboa D, Blumstein T, et al. Effects of tracheostomy on well-being and body image perceptions. Otolaryngol Head Neck Surg 2005;133:366–71.
3. Das P, Zhu H, Shah RK, Roberson DM, et al. Tracheotomy-related catastrophic events: results of a national survey. Laryngoscope 2012;122(1):30–7.
4. Halum SL, Ting JY, Plowman EK, et al. A multi-institutional analysis of tracheotomy complications. Laryngoscope 2012;122(1):38–45.
5. Yaremchuk K. Regular tracheostomy tube changes to prevent formation of granulation tissue. Laryngoscope 2003;113:1–10.
6. Wright J: Tracheostomy. In A history of Laryngology and Rhinology, 2nd ed. Philadelphia, PA, Lea and Febiger, 1914, pp 152–158.
7. Goodall EW: The story of tracheostomy. Br J Child Dis 31:167-176, 253–272, 1934.

REVIEW QUESTIONS

1. A patient presents to the emergency department with airway obstruction. Fiberoptic examination reveals a massive supraglottic tumor, and the patient is assessed as impossible to intubate. During evaluation, his CO_2 rises over 100, and he becomes somnolent and is observed not to be moving air. Which option describes the most effective intervention?
   a. Take him to the OR when the next room becomes available, and perform a tracheostomy below the third tracheal ring.
   b. Call a team meeting with the family, palliative care, social work, and the hospital care manager to map out an appropriate treatment course.
   c. Do an immediate cricothyroidotomy and revise after the airway is stabilized.
   d. Make a vertical incision from chin to sternum, and try to find an airway somewhere.

2. A woman with a massive, rapidly enlarging thyroid tumor presents with stridor. Fiberoptic examination reveals normal vocal cords and an urgent computed tomography (CT) demonstrates marked tracheal compression. Which option is the safest treatment?
   a. Intubate her in the OR and then establish an airway by resecting the tumor if possible or performing a tracheostomy.
   b. Perform a tracheostomy at the bedside under local anesthesia.
   c. Perform a percutaneous dilatational tracheostomy.
   d. Place her on extracorporeal membrane oxygenation (ECMO) and arrange for transfer.

3. An obese patient on high-dose steroids for idiopathic thrombocytopenic purpura (ITP) undergoes a tracheostomy for respiratory failure following splenectomy. One week later she is off the ventilator, her tracheostomy tube is downsized, and the stay sutures are removed. An hour later, the code team responds to a Condition A and after a brief attempt to resuscitate her, she is pronounced dead. Which option describes the most likely cause of death?
   a. Dislodged tracheostomy tube in a false passage, forcibly ventilated with an Ambu bag with resultant pneumomediastinum and bilateral pneumothoraces
   b. Bleeding from her splenectomy bed
   c. Pulmonary embolus
   d. Hypoxia due to obesity
   e. Diabetic coma

4. Open surgical tracheostomy, compared to percutaneous tracheostomy, is:
   a. A much less morbid procedure
   b. Associated with much less bleeding and infection
   c. The most appropriate choice in a patient with an unprotected airway
   d. The most appropriate choice in a patient with a history of previous tracheostomy
   e. Associated with easier postoperative nursing care

ADDITIONAL SOURCES

Eibling DE, Roberson DM. Tracheostomy complications: time to look beyond hospital discharge. Laryngoscope 2012;122(1):23–4.
Editorial to accompany the Das, Halum, and reports of other authors in the January 2012 issue of Laryngoscope *pointing out that the riskiest time period for patients undergoing tracheostomy is in the first week and that some risk persists even after hospital discharge.*

Frost EAM. Tracing the tracheostomy. Ann Otol 1976;85:618.
A classic history of tracheostomy over the ages of recorded history.

Jackson C. High tracheostomy and other errors. The chief causes of chronic laryngeal stenosis. Surg Gynecol Obstet 1923;32:392.
An early treatise on errors in the performance of tracheostomy.

Jackson C, Jackson CL. The Larynx and Its Diseases. Philadelphia: WB Saunders; 1937.
The classic description of tracheostomy.

20 Percutaneous Tracheostomy

Karen M. Kost

INTRODUCTION[1]

Endoscopic percutaneous dilatational tracheostomy (PDT) is a safe and simple bedside procedure that is particularly well suited to patients in the intensive care unit (ICU). Almost two-thirds of tracheostomies are performed in ICU patients. These critically ill patients, usually with multisystem disease are at high risk for complications. Moving these patients with their monitors and endotracheal tubes (ETTs) to the operating room (OR) for an open surgical tracheostomy (ST) carries several risks during transport. These risks include accidental extubation and vital sign changes requiring pharmacologic intervention.

Standard ST at the bedside in the ICU requires transporting instrument trays, adequate suction, extra lighting, and electrocautery from the OR. The procedure may be compromised by the lack of trained OR nurses and assistants. Risks include inadequate or difficult exposure and spontaneous ignition with the use of electrocautery in the presence of oxygen concentrations exceeding 30%.

Interest in a bedside percutaneous tracheostomy procedure led to the early development of several techniques, most of which were quickly abandoned. The development of a reliable bedside percutaneous dilatational technique in 1985 generated ongoing interest. The "blind" aspect of the procedure was later addressed by the addition of continuous endoscopic guidance. Endoscopic PDT requires no special lighting, no special equipment, and no electrocautery, and there is no need to move patients. My experience with more than 1500 of these procedures has demonstrated that, with bronchoscopic visualization and attention to technical detail, endoscopic PDT is a safe, cost-effective alternative to ST in the OR with comparable or lower complication rates.

1. Technique based on progressive dilatation of a tracheal puncture
2. Always performed with endoscopic guidance
3. Only performed in adult, intubated patients in the ICU
4. At least as safe as open ST

KEY OPERATIVE LEARNING POINTS

1. Always performed with endoscopic guidance
2. Instruments should be held like a pen.
3. Forceful dilatation is never indicated and usually means that there is a problem.
4. Bleeding during the procedure is usually tamponaded by the tracheostomy tube.

PREOPERATIVE PERIOD

History

1. What is the nature of the current illness?
   a. Why is the patient intubated?
   b. What organ systems are involved?
   c. Is there trauma to the neck?
   d. Is the cervical spine stable?
   e. Has the patient had a recent thoracotomy?
   f. What is the patient's physical status classification as per the American Society of Anesthesiology (ASA)?
   g. Is the patient currently on anticoagulants (e.g., nonsteroidal anti-inflammatory drugs [NSAIDs], antiplatelet agents, Coumadin)?
2. Is tracheostomy indicated?
   a. Expected intubation for greater than 10 days
   b. Upper airway obstruction (e.g., trauma, neoplasms, subglottic stenosis)
   c. Prolonged mechanical ventilation (e.g., stroke, central nervous system [CNS] disorders, respiratory failure)
   d. Tracheobronchial toilet (e.g., chronic obstructive pulmonary disease, adult respiratory distress syndrome)
3. Past medical history
   a. Previous tracheostomy
   b. Previous surgery, radiotherapy, or trauma to the neck/cervical spine, all of which may make the procedure more difficult
   c. Difficult or abnormal neck anatomy (e.g., kyphoscoliosis, cricoid cartilage at the sternal notch)
   d. History of midline neck masses, high innominate artery, large thyroid gland, or goiter
   e. Other comorbidities
   f. Medications, in particular anticoagulants, and herbal products that affect coagulation

Physical Examination

1. Is the patient intubated?
2. Body habitus: Obesity with a body mass index (BMI) greater than 30 is more technically challenging and associated with a higher complication rate.
3. Neck extension: Are there limitations from anatomic abnormalities (e.g., kyphoscoliosis) or an unstable cervical spine? If so, an open ST should be performed in the OR.
4. Anatomic landmarks: The thyroid and cricoid cartilages as well as the sternal notch must be palpable.
5. Are the anatomic landmarks midline? If not, why?
6. A low-lying cricoid cartilage makes the procedure more technically challenging.
7. Are there any masses in the neck, neoplastic or otherwise, in the operative field? If so, an open ST should be performed in the OR.
8. A high innominate artery in or very close to the operative field is an indication for an open ST in the OR.

Imaging

1. A recent chest radiograph is useful in indicating a tracheal shift, lung abnormalities, or other anatomic aberrations that may affect the procedure.

Indications

1. Adult intubated patients in a monitored setting: ICU, coronary care unit (CCU), or postoperative recovery room
2. Percutaneous tracheostomy can be safely performed:
   a. In obese patients
   b. In patients with a prior history of tracheostomy, whether it was performed percutaneously or open

Absolute Contraindications

1. Inability to palpate the cricoid cartilage above the sternal notch
2. The presence of a midline mass in the neck (e.g., large thyroid) or goiter
3. A high innominate artery
4. Positive end-expiratory pressure requirement of greater than 15 cm H_2O
5. Children
6. Airway emergency, unsecured airway

Relative Contraindications

1. Inability to correct the International Normalized Ratio (INR) to ≤1.5
   Many ICU patients are on anticoagulants and for medical reasons cannot have their anticoagulation completely corrected preoperatively. Others have liver failure with associated coagulation defects. Percutaneous tracheostomy is the preferred procedure in these situations because of the small incision, blunt dissection, and tamponade effect of the tube.
2. Inability to correct the platelet count to ≥50,000

Preoperative Preparation

1. Comorbidities should be optimized.
2. Preoperative testing is minimal and includes hemoglobin levels, INR, prothrombin time, partial thromboplastin time, and platelets. INR should be corrected to ≤1.5, and platelets should be corrected to ≥50,000 functioning platelets, whenever possible. Because blood loss tends to be minimal, a preoperative crossmatch is unnecessary, unless hemoglobin levels are extremely low (≤7). Similarly, preoperative transfusions are also unnecessary, even in the presence of low hemoglobin levels.
3. Required personnel: surgeon, endoscopist (resident, ICU physician), nurse to administer medications, and a respiratory therapist to regulate ventilator settings
4. Prepare the instruments on a Mayo stand in the order in which they are to be used.
5. Consider the type/size of the tracheostomy tube:
   a. For most patients a size 6 internal diameter (I.D.) tracheostomy tube with an inner cannula works well.
   b. A size 8 I.D. tube may be necessary in patients with copious secretions.
   c. In obese patients or those with a "deep" trachea, a proximally extended tube will prevent accidental decannulation.

OPERATIVE PERIOD

Anesthesia

1. Intravenous sedation with or without muscle relaxants. Frequently used combinations include midazolam, fentanyl, and propofol.
2. Topical anesthesia: One or two milliliters of 2% to 4% lidocaine can be injected into the ETT or through the bronchoscope to suppress the cough reflex.
3. Local anesthesia: 1% or 2% lidocaine with 1:100,000 epinephrine is used to infiltrate the incision site to decrease cutaneous bleeding.

Positioning

1. Supine: The patient is positioned as for conventional tracheostomy with the neck extended.

Perioperative Antibiotic Prophylaxis

1. None: Within 24 to 48 hours, tracheostomy sites are colonized with a variety of organisms, including *Pseudomonas, Escherichia coli,* and gram-positive cocci. Tracheostomy tubes are frequently colonized by bacteria, such as *Staphylococcus epidermidis,* which are imbedded in a biofilm. Antibiotics do not prevent colonization and simply select out resistant organisms. Meticulous local hygiene and frequent tracheostomy tube changes control bacterial loads and provide the best defense against true infection.

Monitoring

1. Continuous monitoring of vital signs: particularly important in this very ill ICU patient population. Vital signs may be volatile and require pharmacologic intervention.
   a. Heart rate
   b. Blood pressure
   c. Oxygen saturation
   d. Ventilator settings are set to deliver 100% oxygen.

Instruments and Equipment to Have Available

1. Percutaneous tracheostomy kit: Currently, there are several kits available based on the principle of dilatation of an initial tracheal puncture. The most thoroughly evaluated kit is the Ciaglia Blue Rhino Percutaneous Introducer Kit (Cook Critical Care Inc., Bloomington, Indiana). This kit includes:
   a. Scalpel
   b. Introducer needle
   c. Curved J-wire
   d. Introducer dilator
   e. Guiding catheter
   f. Loading dilators
   g. Sharply tapered single dilator
2. Other instruments: scalpel (if not in the kit), curved hemostat or mosquito, straight scissors, needle driver, nonresorbable sutures, water-based lubricant, a small bowl of sterile saline to activate the hydrophilic tip of the single dilator, and three 10-mL syringes.
3. All instruments should be placed on a Mayo stand in the order in which they are to be used.
4. Appropriately sized tracheostomy tube with an inner cannula. An inner cannula facilitates care and hygiene and adds an element of safety. In the event of obstruction by secretions, the inner cannula can be removed and replaced.
5. A proximally extended tracheostomy tube should be planned for patients with an obese neck.
6. Bronchoscope: preferably with a tower and screen, allowing the surgeon to visualize the intratracheal portion of the procedure. A smaller diameter or pediatric bronchoscope should be used when the ETT is ≤7.5 I.D. to allow for adequate ventilation.
7. Crash cart nearby with necessary equipment for intubation

Key Anatomic Landmarks

1. Lower border of the cricoid cartilage
2. Suprasternal notch
3. Estimate of pretracheal soft tissue thickness, especially in obese patients

Prerequisite Skills

1. Surgical skills
2. Thorough knowledge of the procedure
3. Having attended a training workshop

4. Ability to use a bronchoscope
5. Ability to establish an emergency airway
6. Ability to manage complications, such as bleeding

Operative Risks

1. Accidental extubation
2. Volatile vital signs
3. Bleeding
4. Injury to posterior esophageal wall
5. Creation of a false passage

Surgical Technique

The Incision

- Prepare the instruments on a Mayo stand in the order they will be used (Fig. 20.1).



Fig. 20.1. Instruments are laid out on a Mayo stand in the order in which they are to be used. From left to right: (1) hemostat with sponge for prepping the skin, (2) syringe with local anesthesia, (3) scalpel, (4) curved hemostat, (5) syringe with introducer needle, (6) J-wire, (7) 14F introducer dilator, (8) guiding catheter positioned within single dilator, and (9) tracheostomy tube with loading dilator, inner cannula, and syringe attached to pilot balloon. Top left to right: (1) prep solution, (2) gauze, (3) silk suture, needle driver, and scissors, and (4) saline to activate the hydrophilic coating of the single dilator.

- Prefit the tracheostomy tube with the appropriate loading dilator.
- Prep and drape the surgical site as for a conventional tracheostomy.
- Plan the incision site one to two fingerbreadths below the cricoid cartilage.
- A skin incision is made, 1.5 to 2 cm, just long enough to accommodate the tracheostomy tube.
- Spread the subcutaneous tissue and strap muscles laterally with a curved mosquito clamp or a hemostat.
- The thyroid isthmus is not manipulated.
- Palpate the cricoid and the first and second tracheal rings.

Inserting the Bronchoscope

- The endoscopist (ICU physician, or resident, or anesthetist) prepares for insertion of the bronchoscope: The ETT is suctioned, 1 ml of 4% lidocaine is instilled into the ETT, and tapes holding the ETT are loosened.
- Insert the lubricated bronchoscope through the adapter and into the ETT, advancing until the tip of the bronchoscope lies flush with the ETT. The light will be seen through the incision as the bronchoscope is advanced.
- Hold the ETT securely during all manipulations to avoid accidental extubation.
- Partially deflate the ETT cuff.
- Slowly withdraw the ETT and bronchoscope as a unit until the incision is transilluminated/and or digital compression of the trachea is visualized.
- The remaining surgical steps are visualized by the endoscopist and surgeon on the screen with the endoscopic view.

Creating a Tracheal Aperture

- Place the 16-gauge introducer needle between the first and second or second and third tracheal rings. An intertracheal position is verified endoscopically.
- Advance the J-tipped guidewire through the needle until resistance is encountered (Fig. 20.2).
- Remove the needle, and thread the 14F introducer dilator over the J-wire into the trachea (Fig. 20.3).
- Dip the tip of the guiding catheter/single dilator assembly in saline.
- Remove the introducer dilator, and dilate the tracheal aperture by advancing the guiding catheter/single dilator assembly over the guidewire into the trachea until the 36F marking on the dilator is seen endoscopically (Fig. 20.4).

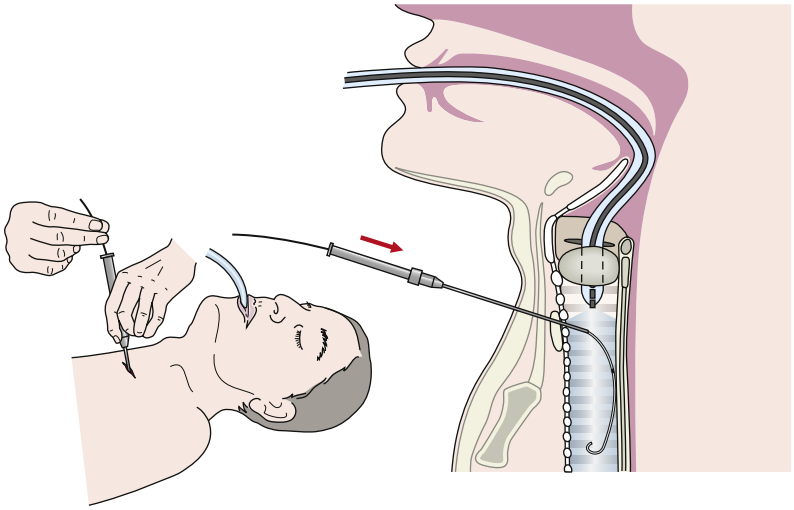

Fig. 20.2. The guidewire is advanced through the introducer needle.

- Overdilatation facilitates insertion of the tracheostomy tube.
- Expect some collapse of the anterior tracheal wall during this maneuver.
- In patients with calcification of the tracheal rings, fracture of a ring may occur. It is not a cause for concern.
- Remove the single dilator, leaving the guidewire and guiding catheter in place.

Inserting the Tracheostomy Tube

- Thread the tracheostomy tube with the loading dilator over the guidewire/guiding catheter and into the trachea (Fig. 20.5).
- Expect two points of resistance: the interface between the loading dilator and the tracheostomy tube and upon insertion of the balloon.
- Remove the dilator, guiding catheter, and guidewire, and position the inner cannula.
- Inflate the cuff and ventilate through the tracheostomy tube.
- Secure the tracheostomy tube with four corner sutures and tape ties.
- Remove the ETT only when adequate ventilation is ensured.

Common Errors in Technique

1. Failure to securely hold the ETT, resulting in accidental extubation
2. Puncturing the posterior wall of the trachea on insertion of the needle. Withdraw the needle into the lumen, and proceed.
3. If the puncture site is lost by accidentally removing the guidewire, restart the procedure.
4. Excessive force should never be used and is likely to lead to complications. Resistance to any step always indicates a problem. Stop and evaluate the situation, find the source of resistance, and resolve the problem. Possible causes include the following:
   a. The size of the incision and soft tissue "tunnel" should be verified. As a general rule, the surgeon's index finger should fit comfortably in the incision and soft tissue tunnel, without "pulling" on the skin when it is removed. Extending the incision and/or additional spreading in the soft tissue tunnel will correct the problem.
   b. If the needle is inserted through a tracheal ring rather than between rings, dilatation will be difficult. The needle should be repositioned between two rings.
   c. Resistance to dilatation occurs in some cases because of calcified rings. Repeated "short" dilatations with *gentle pressure* will lead to adequate dilatation.
5. The tracheostomy tube should never be forced. Repeat the dilatation, overdilate, and try again. This may be necessary when using tubes with a rounded distal edge because of the large step at the interface between the loading dilator and the tracheostomy tube.
6. Failure to place a proximally extended tracheostomy tube in an obese patient

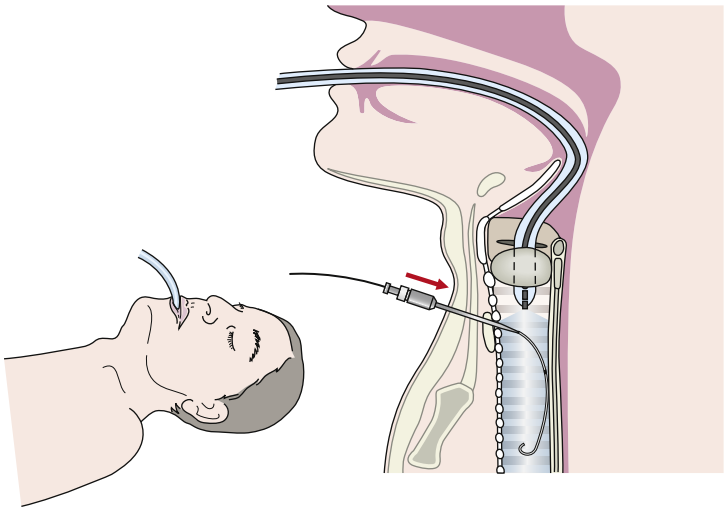

Fig. 20.3. The introducer needle is replaced by the 14F introducer dilator. This facilitates further dilatation of the trachea.

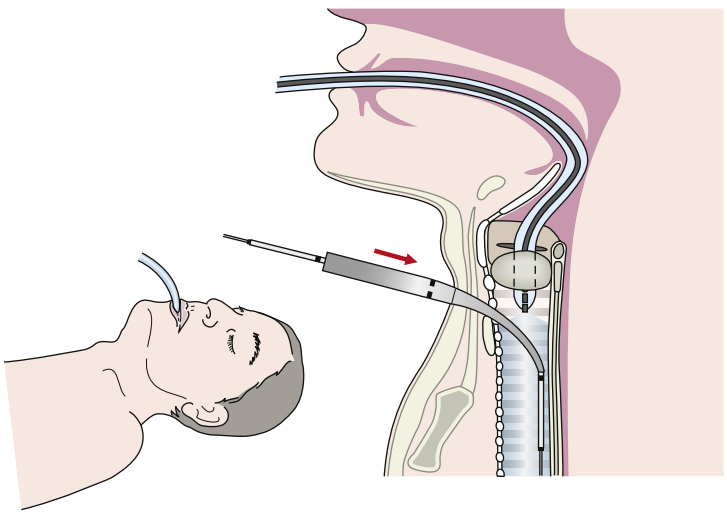

Fig. 20.4. The single dilator/guiding catheter unit is dipped in saline to activate the hydrophilic coating of the dilator. The dilator is held like a pen and introduced over the J-wire into the trachea. Overdilatation facilitates insertion of the tracheostomy tube.

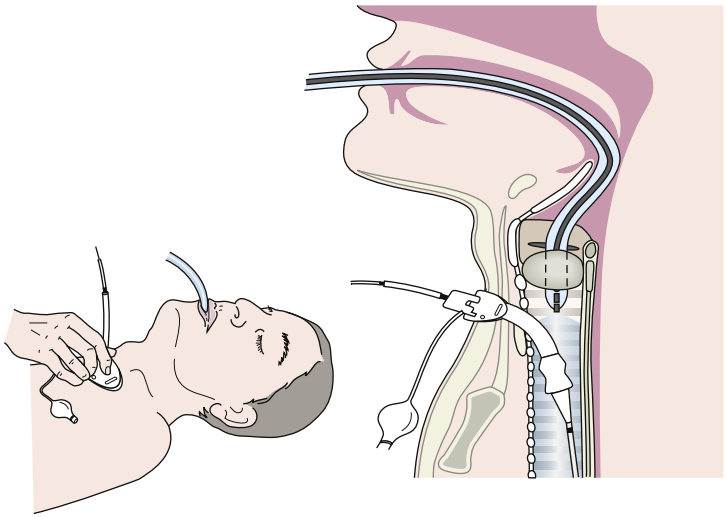

Fig. 20.5. The single dilator is removed, leaving the J-wire/guiding catheter in situ. The tracheostomy tube, prefitted with the loading dilator, is advanced over the J-wire/guiding catheter into the trachea.

POSTOPERATIVE PERIOD

Postoperative Management

1. In the minutes following the end of the procedure, be alert for changes in vital signs, such as hypotension and tachycardia, which may occur when the intense stimulation of the procedure is over. Pharmacologic correction may be required.
2. Suction the trachea free of any blood or secretions.
3. A postoperative chest radiograph is ordered to rule out pneumothorax and pneumomediastinum, although it is probably necessary only in more difficult cases or where the anatomy is unusual.
4. This technique is dilatational, resulting in a small tract with a tight-fitting tracheostomy tube. Traction sutures cannot be placed. In the event of accidental decannulation within the first 7 days, the patient should be reintubated orally. Attempting to re-insert the tracheostomy tube could result in bleeding, creation of a false passage, pneumomediastinum, subcutaneous emphysema, hypoxia, and even death.
5. Elevate the head of the bed to 30 degrees to facilitate coughing, deep breathing, and suctioning.
6. High humidity delivered via a collar is extremely important to:
   a. Facilitate mucociliary transport
   b. Prevent crusting, accumulation of secretions, and tube obstruction
7. Changes in vital signs later in the postoperative period may indicate a new respiratory problem, exacerbation of an existing problem, tube obstruction, or displacement.
8. Agitation, anxiety, and restlessness almost always indicate a problem and are frequently signs of hypoxia. Tube obstruction or displacement are frequent causes.
9. Tracheal suctioning must be performed as often as required to maintain:
   a. Pulmonary toilet
   b. Tube patency
10. Suctioning should be performed as follows:
    a. Aseptically
    b. For patients on mechanical ventilation, give at least five breaths of 100% oxygen before and after suctioning to prevent hypoxia and cardiac arrhythmias.
    c. Apply suction a maximum of 12 seconds at a time.
    d. Alternatively, a closed, multiple-use suction catheter within a sheath may be used.
11. Meticulous wound care is essential in preventing complications, such as:
    a. Skin breakdown
    b. Progression from bacterial colonization to infection
    c. Tube obstruction
12. Major principles of wound care include:
    a. Clean the wound as often as needed. Initially, this may be 3 to 4 times daily.
    b. Use normal saline or peroxide.
    c. Change the tracheostomy tube ties when wet or soiled.
    d. Keep the skin under the neckplate clean and dry—use a dry, thin, nonadherent dressing.
13. The inner cannula should be cleaned or changed frequently to prevent accumulation of secretions.
14. Tracheostomy tube replacement within the first 7 to 10 days requires special precautions because of the tight tract. Guidelines include:
    a. Optimal patient positioning
    b. Assistance
    c. Adequate light
    d. Tracheal hook
    e. Suction
    f. Tracheostomy tube exchanger: essential because it has a central lumen through which ventilation is possible, and it fits within the tracheostomy tube, serving as a "guide," over which the tube may be changed

Complications

1. Potential intraoperative and postoperative complications are similar to those reported for open tracheostomy (see Chapter 19), except for fire, which does not occur with PDT, because no cautery is used. Notable differences are discussed next.
   a. Desaturation: inconsistently reported for both PDT and ST. In PDT, it may occur briefly at the time of tracheostomy tube insertion, particularly in patients with compromised pulmonary function.
   b. Bleeding: occurs less frequently than with ST and tends to be less severe with PDT because of the small tight tract and tamponade effect of the tube. Bleeding can almost always be controlled by local measures. Surgicel can be very useful for localized bleeding.
   c. Infection: occurs less frequently than with ST because of the smaller surface area available for colonization
   d. Accidental extubation: true incidence unknown because it is inconsistently reported for both ST and PDT. The risk

can be reduced by loosening ETT ties only upon insertion of the bronchoscope and having only the physician (with help from the respiratory therapist, if needed) manipulate the ETT.

e. Injury to the posterior wall: usually limited to overzealous needle insertion and easily corrected by withdrawing the needle. Serious injury to the posterior wall should not occur with continuous endoscopic visualization and attention to technical detail. Proper positioning or layering of the guidewire, guiding catheter, and single dilator is very important in this regard.
f. Accidental decannulation: occurs infrequently because of the tight tract. Obese patients and those with a short, thick neck are at highest risk because the increased thickness of the pretracheal tissue effectively shortens the intratracheal portion of the tube. Anticipating this problem and using a proximally extended tracheostomy tube at the outset largely obviates the issue.
g. False passage, pneumothorax, and pneumomediastinum: These potentially fatal complications can be almost completely avoided by continuous endoscopic visualization from beginning to end.

Alternative Management Plan

1. Open ST should be used when:
   a. PDT is contraindicated.
   b. The surgeon does not have the necessary skills/training for PDT.
   c. The required instruments are not available.
   d. The required personnel are not available.
   e. The surgeon is uncomfortable because of the patient's anatomy (thick neck) or personal factors (inexperience).

DISCUSSION

Evidence-Based Medicine Question

Is percutaneous tracheostomy as safe as open tracheostomy in the OR?

ICU patients account for almost two-thirds of currently performed tracheostomies. It is recognized that the risk of surgical complications is higher in this patient population because of multisystem disease and multiple comorbidities. The overall complication rate for endoscopic PDT is approximately 9%. This compares favorably with complication rates of 14% to 66% in ICU patients undergoing open ST in the OR and to complication rates of 4% to 41% in ICU patients undergoing open ST at the bedside.

There has been much debate in the literature over the need for continuous endoscopic guidance during PDT. Opponents argue that it lengthens the procedure and complicates adequate ventilation during the procedure. These suggestions are largely unsupported by evidence. However, there is a highly statistically significant relationship between the risk of complications and the use of bronchoscopic guidance. Indeed, the risk of serious complications, which includes pneumothorax, pneumomediastinum, and false passage, doubles when bronchoscopic guidance is not used. I have not had a single case of pneumothorax, pneumomediastinum, or false passage in more than 1500 PDTs.

Obese patients in the ICU with a BMI ≥30 are at higher risk for complications. This is true whether they undergo PDT or standard open tracheostomy. For those obese patients undergoing PDT, the most common complication is accidental decannulation due to the thickness of the subcutaneous tissues. Use of a proximally extended tracheostomy tube prevents this problem.

As with most other minimally invasive techniques, there is a learning curve with PDT, which is often evident in the first 30 to 40 cases. Reducing complications or mishaps associated with the learning curve is possible by obtaining adequate "hands-on" training, careful selection of patients with anatomically favorable necks, and attention to technical detail.

Comparative data indicate that endoscopic PDT is at least as safe as standard open tracheostomy. The overall incidence of bleeding and infection is likely lower in PDT because of the small tract, the tamponade effect of the tube, and the smaller surface area for bacterial colonization.

Editorial Comment

Endoscopic PDT provides an attractive alternative to open ST in adult, intubated ICU patients. With appropriate training and attention to detail, it is a safe and simple procedure. PDT is significantly faster to perform compared with ST, and, from a training perspective, residents consider endoscopic PDT to be easier than open ST.

David Eibling

Access the review questions online at http://www.expertconsult.com

REFERENCE

1. Kost KM. Endoscopic percutaneous dilatational tracheotomy: a prospective evaluation of 500 consecutive cases. Laryngoscope 2005;115(10 Pt 2):1–30.

REVIEW QUESTIONS

1. Percutaneous tracheotomy is absolutely contraindicated in which of the following situations?
   a. Unpalpable cricoid cartilage
   b. Airway emergency
   c. Children
   d. Nonintubated patient
   e. All of the above

2. Which of the following statements is true?
   a. Bleeding is a more frequent complication of percutaneous tracheotomy compared with open tracheotomy.
   b. The use of bronchoscopy significantly decreases the risk of serious complications.
   c. Obese ICU patients have fewer complications if they undergo an open ST.
   d. Accidental decannulation within the first 7 days following percutaneous tracheostomy should be treated by simply reinserting the tracheostomy tube.
   e. Perioperative antibiotics prevent wound infection.

3. Which of the following statements is false?
   a. Postoperative high humidity is important to prevent tube obstruction.
   b. Tracheostomy tubes with an inner cannula confer an element of safety.
   c. Sudden anxiety and agitation postoperatively indicate the need for an anxiolytic.
   d. 100% oxygen should be administered before suctioning mechanically ventilated patients.
   e. Extended-length tracheostomy tubes should be used on obese patients to prevent accidental decannulation.

21 Operative Otolaryngology: Laryngotracheal Separation

David Eibling

INTRODUCTION

1. Airway protection is the most fundamental role of the mammalian larynx. (See Additional Sources for in-depth discussion.)
2. For some patients, laryngeal function is compromised by disease processes to the extent that its airway protection role becomes inadequate in preventing aspiration.
3. Chronic aspiration can be managed in most patients with alternative feeding, tracheostomy for pulmonary toilet, and oral care (Box 21.1).
4. Occasionally patients cannot be managed satisfactorily by conservative measures. A variety of surgical strategies can be used (see Box 21.1).
5. Among the surgical strategies, the most definitive, straightforward, and acceptable procedure is laryngotracheal separation (LTS) (Fig. 21.1).[1]

KEY OPERATIVE LEARNING POINTS

1. Decision making regarding surgical intervention with LTS is more difficult than the procedure itself.
2. The anatomy of the tracheoesophageal party wall facilitates the safe performance of LTS in that a layer of loose areolar tissue separates the membranous posterior wall of the trachea from the esophagus.
3. The posterior wall of the trachea is a fibrous layer contiguous with the perichondrium of the tracheal rings and the inter-ring connective tissue that permits circumferential dissection of the trachea.
4. Removing and weakening tracheal rings permits closure of the proximal stump of the trachea.

PREOPERATIVE PERIOD

History

1. History of present illness
   a. Etiology of aspiration (See Falestiny in Additional Sources for more in-depth discussion.)
      Temporary or long-term?
      Treatable primary disease process?
      Local (laryngopharyngeal) or neuromuscular?
   b. Episodes of pneumonia?
      Minimal (mild pneumonitis) or severe
      Number of episodes?
      Courses of antibiotics? Colonized with resistant organisms?
   c. Prior or current tracheostomy?
   d. Feeding strategies?
   e. Weight loss/inanition?
2. Past medical history
   a. Onset and progression of primary illness
   b. Comorbidities
   c. Anticipated progression of primary illness and comorbidities
   d. Current admission status (hospital, long-term care, nursing home)
   e. Expected survival duration?
   f. Patient and family goals of care for remaining life

Physical Examination

1. General—degree of frailty, nutritional and cognitive status, communication skills, open wounds in head and neck region
2. Laryngopharyngeal endoscopic examination
   Vocal cord mobility—is there any motion?
   Glottic closure—Can the glottis close to protect the airway?
   Is there an alternative strategy based on enhancing closure?
   Pooling of secretions. Often extent of secretions precludes examination
3. Oral cavity
   Is the patient able to handle his or her secretions?
   Tongue and palate mobility. Even if aspiration is controlled inability to move tongue or absence of the tongue may prevent swallowing.
4. Neck
   Prior tracheostomy?
   Position of tracheostomy?
   Is there adequate trachea available above stoma for closure?

Imaging

Not required for this procedure

Indications

1. Morbid aspiration with recurrent episodes of pneumonia not adequately managed by conservative measures
2. No acceptable alternative
3. Patient and family desire the procedure
   Patient, family, and other stakeholders need to recognize that most patients lose their ability to speak, if able to speak preoperatively, and less than ½ of patients who undergo LTS are able to swallow postoperatively. Some, but not all, patients are able to be discharged after aspiration has been controlled.

Contraindications

1. Absolute:
   a. Family and patient refuse the procedure
   b. Technically impossible due to very high tracheotomy—particularly if future reanastamosis is considered a possibility. Consider narrow-field laryngectomy as an alternative.
2. Relative:
   a. Duration of anticipated survival
   b. Aspiration managed successfully with conservative strategies
   c. High tracheotomy (will require removal of portion of cricoid ring to gain sufficient mucosa for closure)

BOX 21.1 Treatment of Morbid Aspiration

NONSURGICAL STRATEGIES

Nasoenteric tube feeding (or gastrostomy)
Nothing by mouth
Postural feeding technique
Swallowing therapy

ADJUNCTIVE SURGICAL PROCEDURES

Cricopharyngeal myotomy
Gastrostomy/feeding jejunostomy
Tracheostomy
Vocal cord injection or thyroplasty for vocal cord medialization

DEFINITIVE SURGICAL PROCEDURES

Glottic closure
Laryngotracheal separation
  Laryngeal stenting
Narrow-field laryngectomy
  Supraglottic closure
Tracheal flap closure
Tracheoesophageal diversion

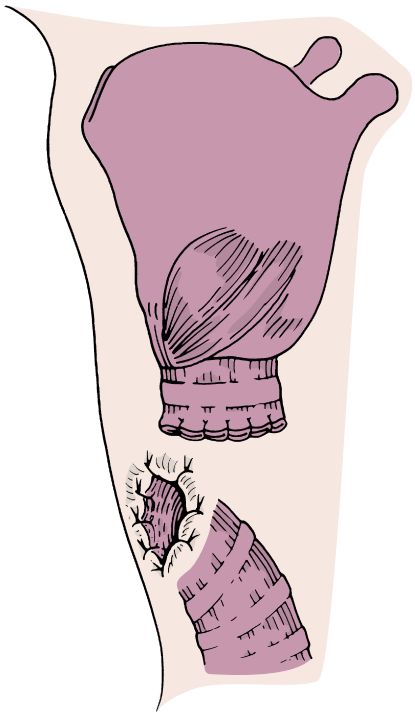

Fig. 21.1. Laryngotracheal separation. The proximal trachea is closed as a blind pouch. *(From Eibling DE, Bacon GW, Snyderman CH: Surgical management of chronic aspiration. Adv Otolaryngol Head Neck Surg 6:108, 1992.)*

Preoperative Preparation

1. Extensive discussion with patient (if able to understand), family, and other stakeholders. Assessment of goals, recognition of the futility of additional treatment and likely progression of primary disease, likelihood that the patient may not be able to swallow or be discharged even if the procedure is performed successfully
2. Optimize medical status to ensure safe surgical performance and healing. In addition to assessing the current status of anticoagulation and cardiac systems, some assessment of healing ability is necessary, especially because most patients have suffered considerable weight loss with a drop in standard measures of nutritional status. Typically this is not feasible, and surgery must be performed in less than ideal circumstances.
3. Determine whether the patient is a candidate for general anesthesia.

OPERATIVE PERIOD

Anesthesia

General: Although this procedure can be performed under local with awake sedation, general anesthesia is preferred for patient comfort, particularly when transecting the trachea, removing rings, and closing the proximal stump.

Positioning

Supine: The patient is positioned as for tracheotomy, with the neck extended over a shoulder roll. Anesthesiologist may remain at the head of the table to facilitate airway management.

Perioperative Antibiotic Prophylaxis

First-generation cephalosporin if not allergic to penicillin. Choice depends on the current status of the patient's bacterial load and virulence. Patients undergoing LTS are often in an intensive care unit and colonized with multiple resistant organisms, so antibiotic choices must be made accordingly.

Second-generation cephalosporin—may be required if cultures indicate necessity

Clindamycin is an ideal choice if allergic to penicillin.

Monitoring

None required except routine EKG, pulse-oximetry, and capnography

Instruments and Equipment to Have Available

1. Basic tracheostomy set
2. Woodson elevator
3. Extra endotracheal tube as well as cuffed tracheostomy tube
4. Sutures to close the proximal stump and create a permanent stoma (2-0 and 3-0 Vicryl or similar)

Key Anatomic Landmarks

1. Cricoid cartilage
2. Sternal notch

Prerequisite Skills

1. Ability to discuss "bad news" and options for palliation with patient and family
2. Standard tracheotomy skill set

Operative Risks

1. Intraoperative fire—similar to any tracheostomy (see Chapter 19). If fuel (tracheostomy or endotracheal tube) and ignition source (electrocautery) are adjacent in the presence of high levels of oxygen, fire is a distinct possibility.
2. Inability to close the proximal stump due to short remaining trachea. In these situations the anterior arch of the cricoid can be removed to free sufficient mucosa for closure. If the mucosa is still insufficient, consideration must be given to performing a narrow-field laryngectomy.

Surgical Technique

- If a tracheotomy has previously been performed, the incision is widened laterally, and the previous tracheotomy scar and granulation tissue are excised from the skin down to the level of the trachea.
- Patients who have not undergone tracheotomy previously are approached as they would be for a routine tracheotomy—via a horizontal incision with dissection through subcutaneous tissue and splitting of the strap muscles to expose the trachea.
- Division of the thyroid isthmus (if not performed previously) is necessary to gain adequate exposure for closure of the proximal stump of the trachea.
- The location for the separation is identified at the site of the previous tracheotomy or at the interspace of the third or fourth tracheal ring.
  - In older patients with an increased anteroposterior dimension of the chest, the larynx may be located more inferiorly and be resistant to retraction superiorly. In these patients the trachea may need to be divided more superiorly, at the second interspace.
  - The higher levels of tracheal division may make the procedure easier; however, the short stump dramatically increases the difficulty of reanastomosis if attempted later.
  - In most patients who have previously undergone tracheotomy, the proximal trachea will usually consist of only one or two rings above the level of the stoma.
- Dissection is carried laterally around the trachea at the site of the stoma.
- The trachea is opened if the patient does not have an indwelling tracheostomy.
- An endotracheal tube is passed into the distal trachea for ventilation throughout the remainder of the procedure.
- The trachea is then transected, with care taken to maintain the dissection next to the wall of the trachea to avoid injury to the recurrent laryngeal nerves.
  - The posterior wall is then transected, exposing the loose areolar tissue within the party wall, with care taken to not enter the esophagus. This is usually performed by continuing the tracheal incisions through the lateral walls bilaterally and across the posterior wall until they meet. Care should be taken to maintain this line of transection in a straight transverse plane to avoid tapering superiorly such that closure of the proximal stump becomes problematic.
- After the trachea has been divided, it is dissected free with blunt dissection in both a superior and an inferior direction.
  - Care should be taken to avoid extending the dissection too far into the soft tissues laterally to prevent injury to the recurrent laryngeal nerve.
- An incision is made in the tracheal perichondrium to expose the inferior-most ring(s) in the superior stump.
  - The ring is then dissected free using a small periosteal elevator. Care should be taken to avoid injury to the underlying perichondrium and mucosa. Removing this ring frees the internal mucoperichondrium and permits closure of the mucosa (Fig. 21.2).
- Collapse of the superior stump is facilitated by dividing the ring(s) superiorly to allow the ring to collapse on itself and reduce tension on the mucosal closure Fig. 21. 3).
  - In cases of a prior high tracheotomy with insufficient remaining trachea, the anterior arch of the cricoid itself may be resected. Unfortunately this effectively eliminates the possibility of future reanastomosis.
- The mucosa is then closed with a running inverting suture similar to a pharyngeal closure in a laryngectomy.
- The mucosal closure is reinforced by additional interrupted sutures placed through the remaining but divided tracheal ring. This effectively reinforces the closure and helps to prevent postoperative leaks (Fig. 21.4).

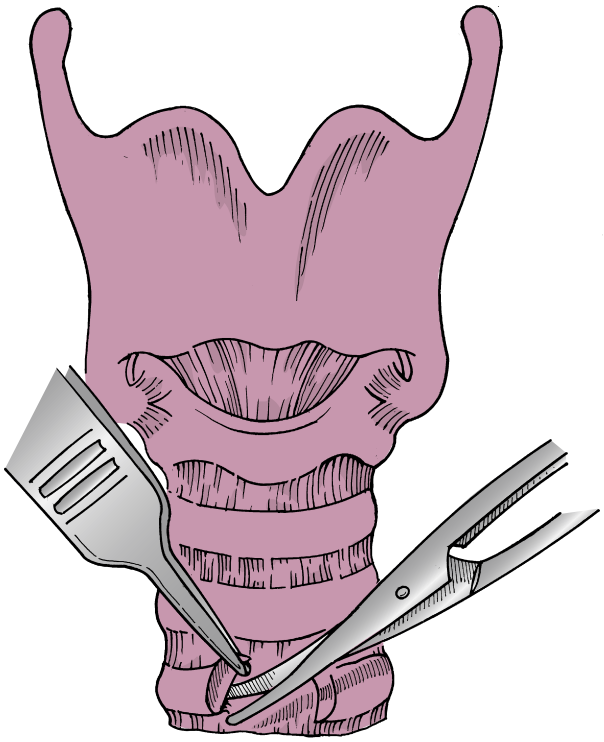

Fig. 21.2. After the trachea is divided, a ring is removed by dissecting the cartilage away from the mucosa. This provides mucosa for closure.

- Some surgeons routinely reinforce the closure with a flap of strap muscle sewn below the proximal tracheal closure. Unfortunately, this maneuver does not always prevent a fistula. An adequate inverting mucosal closure performed without tension appears to be the most critical step in this part of the procedure.
- The distal trachea is then brought to the skin, and a stoma is formed in a manner identical to that for a laryngectomy stoma. Half-mattress sutures are used to advance skin from the lateral to the medial aspect as would be done in a total laryngectomy (Fig. 21.5).
- A small Penrose drain is brought out from one corner of the wound, and any remaining skin lateral to the tracheostoma is then closed.
- A cuffed tracheostomy tube is inserted to help prevent aspiration of any wound drainage that seeps from the skin edges.

Common Errors in Technique

- Selecting the procedure for an aspirating patient unlikely to benefit is the most common error of novice surgeons.
- Attempting to close a stump that is too short dooms the procedure to failure. This is best rectified by removing the anterior arch of the cricoid or converting to a narrow field laryngectomy.
- Tearing the tracheal mucosa makes it impossible to close the mucosa in an inverted manner.
- Failure to collapse the superior ring will place excessive tension on the stump mucosal closure.
- Failure to drain the space below the stump will lead to a collection of fluid and inevitable wound infection.

POSTOPERATIVE PERIOD

Postoperative Management

- Expect some leakage from the drain.
- Continue perioperative antibiotics for 24 hours.

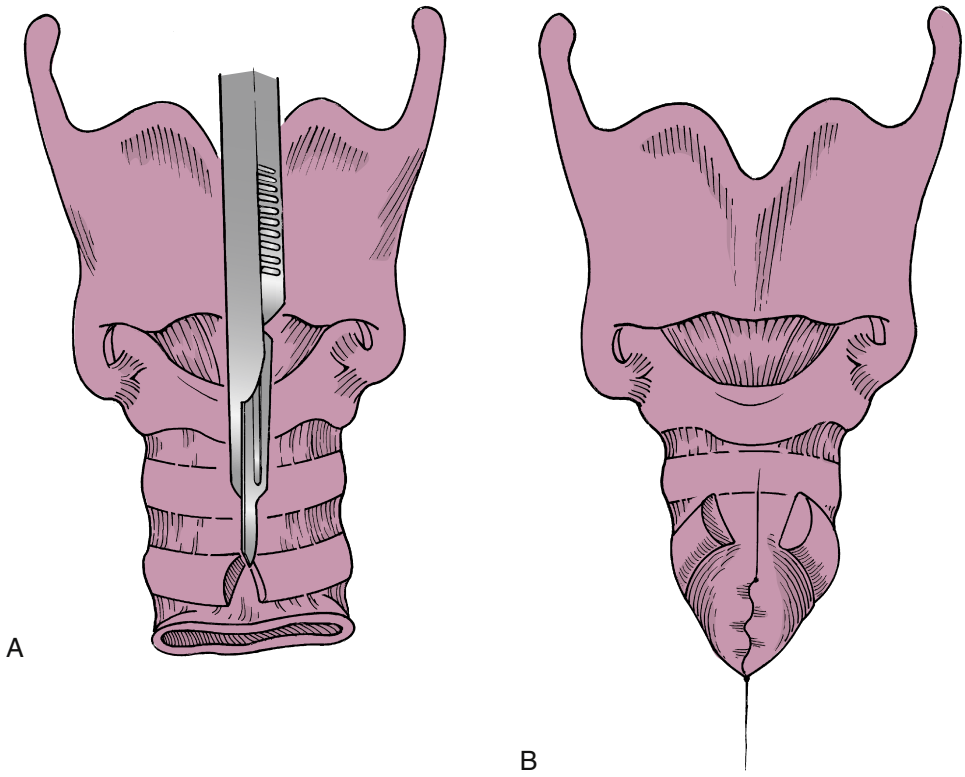

Fig. 21.3. Stump closure. **A**, The next ring above is then divided. **B**, The mucosa is closed in a watertight fashion with inverting continuous suture.

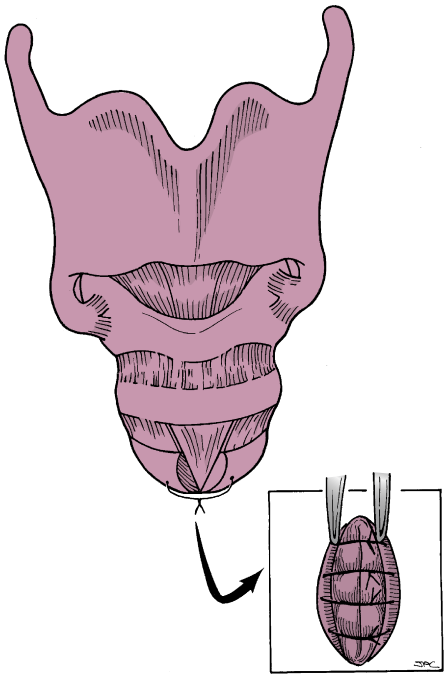

Fig. 21.4. The divided ring is then collapsed with a clamp, and an additional layer of reinforcing sutures is placed to reinforce the closure.

- Leave tube in place until the risk of fistula formation has passed and peristomal edema has resolved.
- Instruct the patient and the family in stomal care.
- Wait several days before initiating swallowing trials.

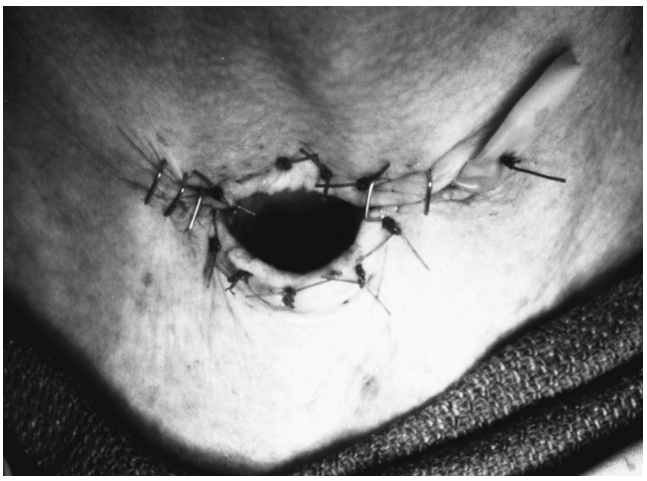

Fig. 21.5. Stoma created similar to that of a laryngectomy. Note the Penrose drain left in place for 24 hours to avoid subcutaneous collection of fluid.

Complications

1. Wound infection—associated with collection of fluid adjacent to the stump. Risk can be minimized by drainage of secretions.
2. Fistula: A temporary fistula can be expected to occur in approximately ⅓ of patients.[1] Usually does not impact pulmonary status and usually will resolve spontaneously in several weeks if nutrition is adequate

Alternative Management Plan

1. Tracheostomy and gastrostomy. This is the most common strategy for the aspirating patient. It is preferred over LTS

for patients in whom the process is expected to resolve in several weeks to months. However, the requirement for frequent tracheal suctioning, even with an inflated tracheostomy tube cuff, mandates that the patient stay in a special care unit.
2. Laryngeal stenting. In conjunction with tracheostomy and gastrostomy a laryngeal stent can dramatically reduce aspiration and reduce the requirement for intensive nursing care. Unfortunately, stenting is only effective for several weeks to months.
3. Laryngeal closure. Several procedures have been described; none are as simply performed or as reliable as LTS.
4. Laryngotracheal diversion. The first procedure reported by Lindeman, it is now seldom used because retention of food in the closed proximal pouch has been shown not to result in infection or other difficulties.
5. Narrow-field laryngectomy. An effective solution, although technically more demanding than LTS. May also be more prone to wound complications in the setting of poor nutritional status. Also more likely to be rejected by patients and family due to the finality of the procedure, even though reanastamosis is exceptionally uncommon

DISCUSSION

Evidence-Based Medicine Question

Does LTS achieve its intended goal of preventing pneumonia?

- Control of aspiration. Numerous surgeons have reported their experience with LTS, with uniform control of aspiration.[1-5] The largest series, 56 patients over an 18-year period, was that of Cook published as a Triological Thesis in 2009.[5] All of the patients in all of the series had either elimination or dramatic reduction in episodes of aspiration pneumonia and, for those who monitored tracheostomy care, reductions in the need for suctioning.
- Intensity of nursing care. In a series of 11 children with severe neurologic disorders undergoing LTS reported by Takamizawa et al., the frequency of performing suction fell from an average of once every 30 minutes to once every 4.5 hours.[4]
- Health care costs. Cook reported substantial reductions in cost of care following the procedure due to reduced admissions for aspiration pneumonia.[5]
- Loss of voicing. Although the procedure entails giving up voice, the majority of patients with advanced neuromuscular disease leading to intractable aspiration are unaffected due to the fact they did not have usable speech preoperatively due to their primary disease process. A few surgeons (see list of Additional Sources) have reported successful speech rehabilitation in selected patients using tracheoesophageal puncture following LTS.

Editorial Comment

Laryngotracheal separation is the most satisfactory way of definitively managing intractable aspiration with recurrent episodes of pneumonia. Most patients with intractable aspiration will have already had a tracheostomy and conservative measures, such as dietary modification and postural changes, without relief.

An astonishing statistic was pointed out by Broniatowski et al.[6] that approximately 500,000 patients per year in the United States are affected by stroke-related dysphagia. Approximately 50% of these patients experience pneumonia and death. However, stroke patients are not the only ones who benefit from LTS. Patients with central nervous system disease and advanced cancer of the tongue or larynx are another potential group of candidates for this procedure. In these patients there is usually no chance that the underlying cause of the aspiration will improve.

There is another group of patients in which the aspiration may be temporary, such as those patients with multiple sclerosis. I have personally used this as a lifesaving procedure in several such patients and have been able, when their aspiration dissipated as they went into remission, to take down the laryngotracheal separation and reestablish normal voice and swallowing.

In patients who have not had radiation therapy to the inferior aspect of the neck, voice can be reestablished using the tracheoesophageal puncture technique. In those who have had radiation therapy, the risk of poor healing following the puncture makes this additional procedure too risky.

I performed a total glossectomy and bilateral modified neck dissection in a relatively young healthy man who had been a heavy smoker and had been exposed to Agent Orange during service in the Vietnam War. Although he was, in my judgment, a good candidate for this procedure, he immediately experienced severe aspiration that was not controlled with conservative measures and the tracheostomy that I had carried out during the surgical procedure. The patient had pneumonia that could not be controlled by antibiotics because the tracheobronchial tree was constantly soiled by the aspiration. After serious discussion with the patient and his family, I carried out a laryngotracheal separation using the technique described in our department by Snyderman and Johnson[3] (see section on "Surgical Technique"). Although the aspiration was completely controlled, he did not regain his ability to swallow. A gastrostomy was performed to restore a means of delivering nourishment. The patient had more than 40 cervical lymph nodes positive for metastatic cancer, many with extracapsular spread, so he was treated with chemoradiation. Unfortunately the radiation to the lower neck was a contraindication for tracheoesophageal puncture and insertion of a speaking valve. The patient is now 20 years postoperative without evidence of recurrent cancer despite his heavy tumor burden and has supported his family, including five children, working as a landscaper.

Eugene N. Myers

Access the review questions and additional sources list online at http://www.expertconsult.com



REFERENCES

1. Eibling DE, Snyderman CH, Eibling C. Laryngotracheal separation for intractable aspiration: a review of 34 patients. Laryngoscope 1995;105:1–3.
2. Lindeman RC, Yarington CT, Sutton D. Clinical experience with the laryngotracheal anastomosis for intractable aspiration. Ann Otol Rhinol Laryngol 1976;85:609–612.
3. Snyderman CH, Johnson JT. Laryngotracheal separation for intractable aspiration. Ann Otol Rhinol Laryngol 1998;97:466–470.
4. Takamizawa S, Tsugawa C, Nishijima E, et al. Laryngotracheal separation for intractable aspiration pneumonia in neurologically impaired children: experience with 11 cases. J Pediatr Surg 2003;38:975–977.
5. Cook SP. Laryngotracheal separation in neurologically impaired children: long-term results. Laryngoscope 2009;119(2):390–395.
6. Broniatowski M, Grundfest-Broniatowski S, Tyler DJ, et al. Dynamic laryngotracheal closure for operation: a preliminary report. Laryngoscope 2001;111:2032–2040.

REVIEW QUESTIONS

1. Which of the following is the most critical point in the performance of LTS?
   a. Patient indications for procedure
   b. Patient and family goals and expectations
   c. Health care costs
   d. Presence of a prior tracheotomy
   e. Comorbidities

2. Performance of LTS results in:
   a. Restoration of swallowing function in nearly all patients
   b. Elimination of voicing for all patients
   c. Dramatic reduction in number of episodes of pneumonia
   d. Minimal change in care requirements

3. A temporary pouch fistula following LTS
   a. Is not uncommon and will usually resolve
   b. Is rare and indicates poor technique
   c. Should not be discussed with patient and family preoperatively

ADDITIONAL SOURCES

Falestiny MN, Yu VL. Aspiration pneumonia. In: Carrau RL, Murry T, editors. Comprehensive Management and Swallowing Disorders. San Diego, CA: Singular Publishing Group; 1998. p. 383–388.
A review of the pathophysiology of aspiration pneumonia and its relationship to swallowing dysfunction.

Lindeman RC. Diverting the paralyzed larynx. A reversible procedure for intractable aspiration. Laryngoscope 1975;85:157–180.
This is the original report of Lindeman that proceeded by a year his report of LTS.

Lombard LE, Carrau RL. Tracheo-tracheal puncture for voice rehabilitation after laryngotracheal separation. Am J Otolaryngol 2001;22:176–178.
These and other authors point out that it is possible to perform a tracheal-esophageal puncture on selected patients following LTS.

Ninomiya H, Yasuoka Y, Inoue Y, et al. Simple and new surgical procedure for laryngotracheal separation in pediatrics. Laryngoscope 2008;118:958–961.
A similar procedure that avoids dividing the trachea. The authors present a functional LTS that is performed utilizing a tracheal flap rather than complete division of the trachea. They point out that the procedure they describe may be more acceptable to families of neurologically impaired children than total division of the trachea.

Sasaki CT, Weaver EM. Physiology of the larynx. Am J Med 1997;103(Suppl. 1):S9–18.
This is an exhaustive review of laryngeal physiology, emphasizing the three critical roles of the larynx: airway protection, respiration, and voicing.

22 Tracheal Resection

Neil A. Christie

INTRODUCTION

Tracheal resection may be undertaken for tracheal strictures and tracheal tumors. Most commonly the trachea is exposed through a cervical incision, but for distal tracheal or carinal access either a sternotomy or a right thoracotomy may be required. Up to half the trachea may be resected with construction of a primary tracheal anastomosis. For the extensive resections, release techniques will be required. Preoperative planning is important to precisely define the tracheal lesion and always includes imaging and bronchoscopy.

KEY OPERATIVE POINTS

1. Preoperatively one must accurately assess the length and location of the lesion that is being resected.
2. The tracheal resection must include all of the diseased airway so that the anastomosis can be done with healthy trachea.
3. Neck flexion and release procedures should be done as required in order to minimize tension on the anastomosis.
4. Circumferential mobilization of the airway should be minimized to maintain the circulation of the trachea.
5. The recurrent laryngeal nerves are located in the tracheaesophageal groove and should be preserved to prevent vocal cord palsy.

PERIOPERATIVE PERIOD

History

1. History of diabetes, previous external beam radiation, or steroid use, which can impair the healing of the trachea
2. Previous tracheostomy or oral tracheal intubation and, if so, the duration of intubation
3. History of Wegener disease or sarcoidosis, which can lead to tracheal stenosis
4. A history of cigarette smoking
5. Dyspnea and, if so, the duration and severity
6. Cough

Physical Examination

1. Overall body habitus
2. Examination of the neck, including length, ability to extend the neck, and presence of kyphosis
3. Cervical lymph adenopathy
4. Audible stridor or wheezing

Imaging

Imaging is important to fully define the nature of the tracheal lesion for preoperative planning of the operation, with regard to location of the incision and the need for any tracheal release procedures.

1. Chest and neck radiograph may show evidence of airway obstruction in the proximal trachea and would also detect gross mediastinal adenopathy or lesions in the lungs.
2. Computed tomography (CT) scan is the most informative imaging study.
   a. It provides information regarding both the intraluminal and extraluminal extent of tracheal lesions.
   b. Evaluation of spread of tracheal cancers to the regional lymph nodes or the pulmonary parenchyma
   c. Allow for assessment of any other underlying pathology in the lung parenchyma.

Indications

1. Airway intubation injury is the most common cause of tracheal strictures. It can occur from placement of oral endotracheal tubes or from previous tracheostomy. Most intubation injuries are relatively proximal and short and best managed with tracheal resection.[1]
   a. Strictures that occur after tracheostomy may be located either at the site of the tracheal stoma or at the site of the cuff on the tracheostomy tube.
   b. Stenosis resulting from oral tracheal intubation usually follows a period of prolonged intubation for ventilator support. The level of injury can be the glottis, the subglottic segment, or the trachea.
2. Idiopathic tracheal stenosis is a circumferential fibrotic lesion that involves the subglottic area as well as the proximal trachea.[2]
3. Tracheal tumors may be benign or malignant. In children, the majority of tumors are benign, whereas in adults, most are malignant.[3]
   a. The most common benign tumors are carcinoid tumors and chondromas.
   b. The most common malignant tumors are squamous cell carcinoma and adenoid cystic carcinoma. Many malignant tracheal tumors are either locally advanced at presentation or have metastasized and as such are not treated with tracheal resection.

Contraindications

1. The maximum length of trachea that can be resected with a primary anastomosis is 5 to 6 cm or roughly half the length of the trachea. Unless the surgeon is planning on a prosthetic tracheal replacement, longer lesions are not amenable to tracheal resection.
2. Tracheal resection is generally not indicated in patients whose tracheal tumors have metastasized, although occasionally adenoid cystic metastases can progress extremely slowly and resection of an obstructing primary tracheal tumor may be appropriate.
3. Patients need to be physiologically fit for surgery, although most patients can tolerate a transcervical operation well.
4. Relative contraindications include:
   a. Diabetes
   b. Previous high-dose radiation to the trachea
   c. Current high-dose steroid use
   d. Active ongoing inflammation in the tracheal stricture

Preoperative Preparation

1. An acutely inflamed tracheal stricture should not be operated on; the surgeon should wait until the inflammatory phase has resolved with treatment and the stricture has matured.
2. Wean off of high-dose steroids prior to surgery.
3. Pulmonary function tests can give an objective measure of the degree of airflow obstruction. Flow volume loops will demonstrate the degree of airflow obstruction during both the inspiratory and expiratory phase of respiration. Typically intrathoracic lesions cause obstruction of airflow during expiration, whereas lesions that are more proximal (or extrathoracic) will cause airflow obstruction during inspiration. With severe advanced, both inspiratory and expiratory airflow obstruction may be present.
4. Bronchoscopy is used to accurately characterize the tracheal lesion prior to resection. That includes biopsy for histologic diagnosis of tracheal tumors. It also allows the surgeon to measure the longitudinal extent of tracheal lesions, document their precise location relative to the vocal cords and the carina, and evaluate the degree of obstruction of the airway. All of these factors are very important in establishing a patient treatment plan. In patients with severe airway obstruction and respiratory distress, endobronchial therapy via the bronchoscope can be used to relieve the obstruction and stabilize the patient until such time as definitive resection can be undertaken. That could include laser débridement or mechanical débridement of an endobronchial tumor or dilation of a benign stricture. Bronchoscopy is also useful to document vocal cord function prior to surgery.

OPERATIVE PERIOD

Anesthesia

Anesthetic management for tracheal resection is complex and requires close cooperation and communication between the surgeon and the anesthesiologist. The surgeon should always be present at the time of induction of anesthesia.

A rigid bronchoscope may be required to initially secure the airway, and dilation of a narrowed trachea may be required in order for an oral endotracheal tube to be passed at the beginning of the procedure.

Once the trachea has been exposed and the lesion identified, the trachea is divided distal to the lesion, and the distal trachea thus exposed is intubated with a cuffed endotracheal tube, which is then connected to a sterile ventilatory circuit that has been passed onto the operative field.

Performance of the tracheal anastomosis may require intermittent interruption of ventilation with removal of the endotracheal tube. Alternatively, jet ventilation may be used, which does not require a closed circuit and will not interrupt the conduct of the anastomosis in order to remove and replace the endotracheal tube.

Ideally at the end of the procedure the patient will no longer require positive pressure ventilation and be breathing spontaneously so that they can be extubated in the operating room.

Positioning

The patient is placed in the supine position. An inflatable bag is placed under the upper back, which is inflated to provide extension of the neck and then deflated during the operation to facilitate neck flexion for the conduct of the anastomosis.

For carinal resections, where one chooses to approach the operation transthoracically, the patient will be positioned in the left lateral position for a right fourth interspace thoracotomy.

Perioperative Antibiotics

One or two grams of Ancef are given intravenously preoperatively, and two doses are given postoperatively. Alternatively, 600 mg of clindamycin can be substituted in the patient who is allergic to penicillin.

Monitoring

1. Continuous electrocardiogram
2. Oxygen saturation monitor
3. Bispectral index (BIS) monitor for depth of anesthesia
4. Intraoperative monitoring of the recurrent laryngeal nerve
5. Blood pressure monitoring with an arm cuff should be adequate (unless the patient requires a thoracotomy).

Instruments and Equipment to Have Available

1. Rigid bronchoscopes of various sizes
2. Gum-tipped tracheal dilators for rigid bronchoscope
3. High Frequency (JET) ventilator and catheters for High Frequency (JET) ventilation
4. Nerve conduction monitoring apparatus and special endotracheal tube for nerve conduction monitoring of the recurrent laryngeal nerves
5. Sterile ventilatory circuit for cross table ventilation of distal trachea in the operative field
6. Several sizes of endotracheal tubes on the sterile field
7. Bipolar cautery
8. Inflatable bag for positioning behind the patient's back to facilitate neck extension and flexion during the procedure

Key Anatomic Landmarks

1. Cricoid cartilage
2. Anatomic location of the recurrent laryngeal nerves (Fig. 22.1)

Prerequisite skills

1. One must be facile with rigid (and flexible) bronchoscopy and oral tracheal intubation.
2. Familiarity with the setup and function of the High Frequency (JET) ventilator

Operative Risks

1. Failure to secure the airway at the time of anesthetic induction in a patient with significant tracheal obstruction due to tumor or stricture
2. Failure to accurately localize the upper and lower extent of the tracheal lesion on external examination of the trachea at the time of tracheal resection
3. Damaging one or both recurrent laryngeal nerves with attendant vocal cord palsy
4. Failure to protect the innominate artery from a tracheal anastomosis
5. Producing a tracheal anastomosis that is under tension by not using tracheal mobilization procedures or by resecting too much trachea
6. Excessive circumferential mobilization of the trachea, resulting in devascularization of the trachea and ischemic breakdown of the anastomosis (Fig. 22.1)
7. Damage to the esophagus during dissection of the posterior tracheal wall
8. Inadequate ventilation of the patient during the conduct of the procedure, with secondary hypoxemia and/or hypercarbia

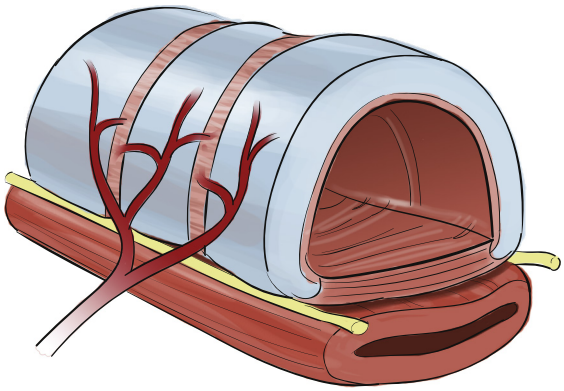

Fig. 22.1. Segmental arterial blood supply of trachea coming in laterally. Course of recurrent laryngeal nerves in tracheoesophageal groove.

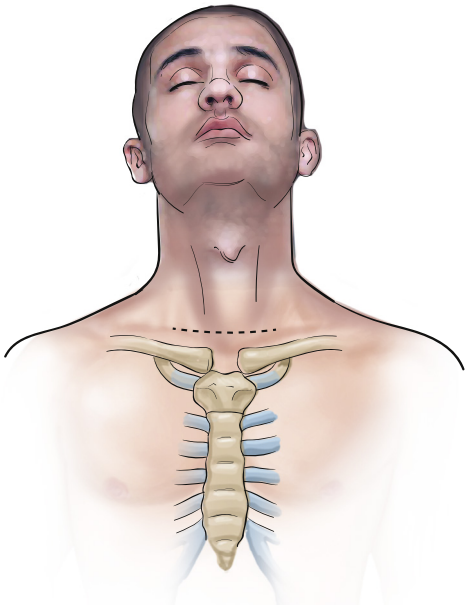

Fig. 22.2. Location of collar incision on the neck for proximal and mid-tracheal resections.

SURGICAL PROCEDURE

Tracheal Resection and Tracheal Anastomosis

1. A cervical collar incision is made transversely, in a natural skin fold approximately 2 cm above the suprasternal notch (Fig. 22.2, Fig. 22.3). This incision should allow for exposure of the upper two-thirds of the trachea. The incision can be extended inferiorly into a partial or a complete sternotomy as required. Alternatively, lesions in the distal third of the trachea may be approached via a right posterolateral thoracotomy through the fourth interspace.
2. Wide sterile prep of the patient from above the chin to the upper abdomen to allow for laryngeal release procedures above or extension, if necessary, to median sternotomy below
3. The dissection is taken down through the platysma muscle, and then subplatysmal skin flaps are raised to the level of the inferior aspect of the thyroid cartilage superiorly and the suprasternal notch inferiorly.
4. The thyroid isthmus is divided if necessary, to expose the underlying trachea.
5. If the lesion is not obvious on external examination of the trachea, the location may be determined based on bronchoscope measurements of the distance of the lesion from certain anatomic landmarks such as the thyroid cartilage or the cricoid cartilage. Alternatively, a needle may be placed through the trachea externally and viewed internally with intraoperative bronchoscopy to determine the appropriate level for tracheal transection.
6. When resecting a tracheal stricture, the circumferential dissection of the trachea should be close to the trachea to avoid damage to the recurrent laryngeal nerves that run in the tracheoesophageal grooves. In the case of neoplastic lesions, the recurrent laryngeal nerves should be identified both above and below the tumor. They can then be safely mobilized off of the tumor or even resected if that is what is required for complete resection of the tumor. Intraoperative nerve conduction monitoring is also helpful in preserving the recurrent nerves (Fig. 22.1).
7. Excessive circumferential mobilization greater than 1 cm above and below the tracheal lesion should be avoided, as it will lead to devascularization of the trachea at the level of the tracheal anastomosis, with subsequent poor healing.
8. The initial division of the trachea is distal to the lesion (Fig. 22.4). The initial incision should be carefully placed to avoid resecting normal trachea. If abnormal tissue has been cut through, additional trachea should be resected until such time as there is normal tracheal tissue at the margin of resection. It is important to obtain histologic confirmation of negative margins with intraoperative frozen sections in cases of tracheal tumors.
9. Traction sutures should be placed in the distal trachea laterally at the junction between the cartilaginous and membranous portion of the trachea, as well as anteriorly. These sutures facilitate stabilization of the distal trachea for placement and replacement of the endotracheal tube, as well as for exposure of the airway for performance of the airway anastomosis.
10. Once the trachea has been divided distal to the lesion, the peroral endotracheal tube is pulled back proximally and a second sterile armored cuffed endotracheal tube is passed across the sterile field into the distal segment of the trachea for cross table ventilation (Fig. 22.4).
11. The trachea is then divided proximal to the lesion, and the specimen is removed. Traction sutures are then placed in the upper end of the transected trachea.

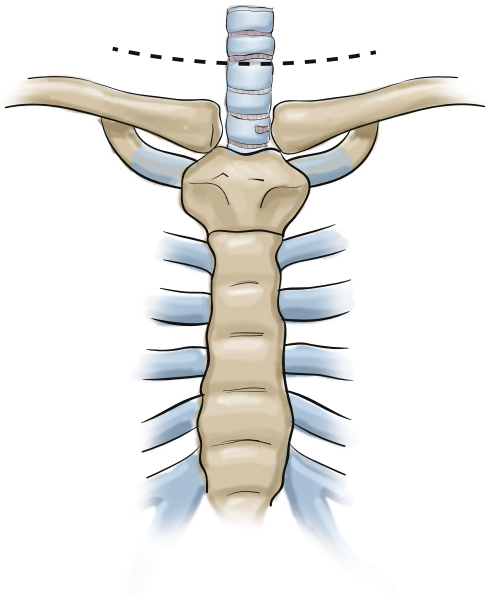

Fig. 22.3. Relationship of cervical incision to clavicles and sternum.

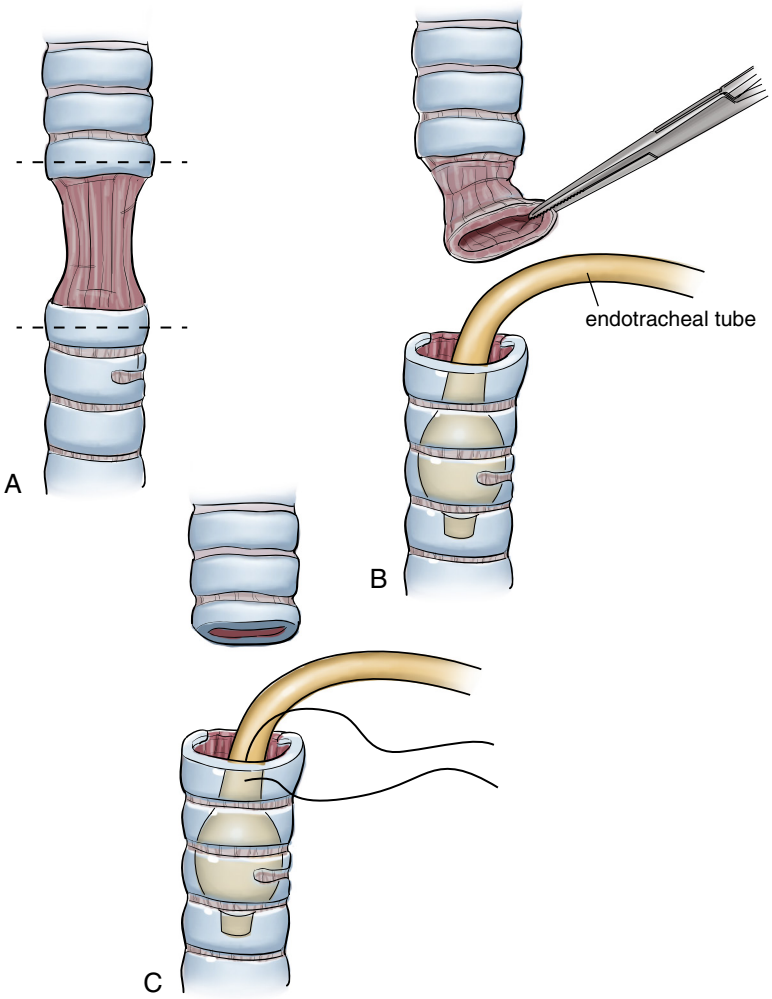

Fig. 22.4. A, Sites of division of trachea above and below the stricture to ensure complete resection of all abnormal tissue. **B,** Intubation of distal tracheal segment for cross table ventilation after initial division of the tracheal. **C,** Complete excision of all the tissue from the stricture in the trachea.

12. Prior to beginning the anastomosis, the patient's neck should be flexed, by deflating the inflatable bag beneath the patient's shoulder blades.
13. The anastomosis is started with the membranous trachea (Fig. 22.5). The cartilaginous traction sutures are used to approximate the cut ends of the trachea and keep tension off of the suture line. The endotracheal tube in the distal trachea is removed as necessary to visualize the membranous trachea for placement of the sutures. Alternatively, High Frequency (JET) ventilation can be used to allow for continuous visualization of the membranous trachea during performance of the membranous tracheal anastomosis. The membranous trachea is sutured with running 3-0 maxon or polydioxanone (PDS) suture (Fig. 22.5).
14. Once the membranous tracheal anastomosis is complete, the endotracheal tube is removed and the peroral tube is advanced distally across the anastomosis, and ventilation is now continued with the oral endotracheal tube.
15. The anterior tracheal anastomosis is completed with interrupted sutures, with the knots tied on the outside of the trachea. Interrupted 3-0 Vicryl suture is used to perform the anterior tracheal anastomosis.
16. When the tracheal anastomosis is completed, the cuff to the endotracheal tube is deflated and the lungs hyperinflated. One can thus check for air leak by placing the airway under saline. If necessary the oropharynx may be temporarily packed with saline-soaked gauze while ventilating the lung with the cuff deflated.
17. If the innominate artery is in apposition to the tracheal anastomosis, a strap muscle should be interposed between them.
18. After placing a drain adjacent to the trachea, the thyroid and strap muscles are reapproximated in the midline.
19. At the conclusion of the operation, a heavy silk suture is placed from the skin of the chin to the skin of the anterior chest to encourage the patient to keep the neck flexed during the immediate postoperative period (Fig. 22.6).

Median Sternotomy and Transpericardial Approach to Distal Trachea

In order to reach the distal third of the trachea or the carina anteriorly, this approach may be taken.

1. Full median sternotomy is performed.
2. An anterior division of the pericardium from the innominate artery above down to the right main pulmonary artery inferiorly
3. The ascending aorta and the superior vena cava are then mobilized and reflected laterally (superior vena cava to the right and aorta to the left).
4. The posterior pericardium is then divided, thus exposing the distal trachea and carina.

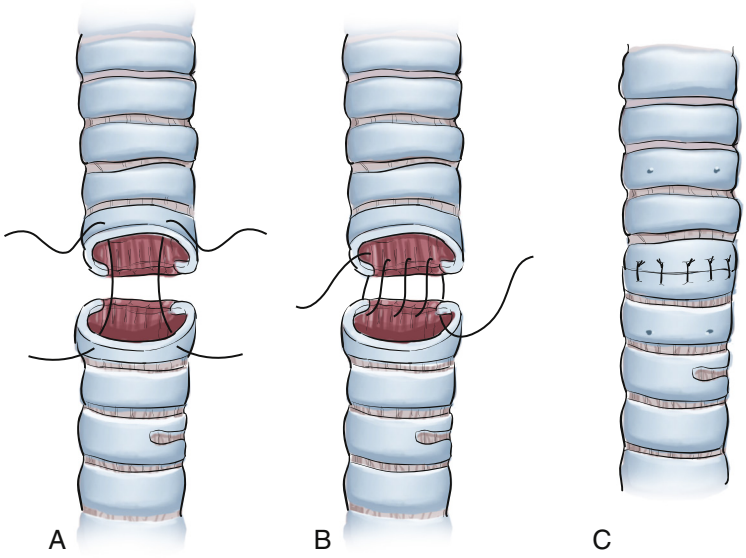

Fig. 22.5. A, Lateral stay sutures for positioning of trachea for airway anastomosis. **B,** Running posterior membranous tracheal anastomosis. **C,** Interrupted anterior cartilaginous tracheal anastomosis.

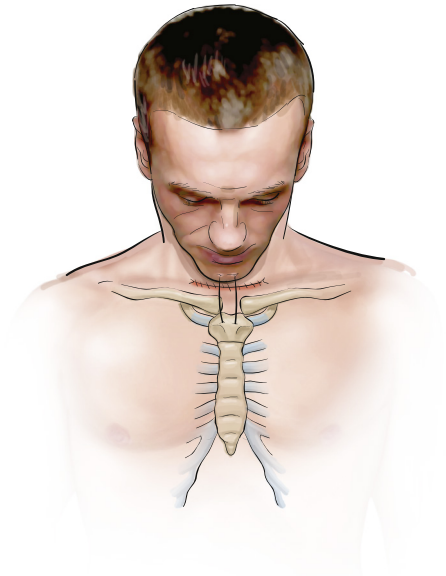

Fig. 22.6. Suture chin to presternal area to keep neck in flexion in order to keep tension off the tracheal anastomosis postoperatively.

Procedures Used to Lessen Tension on the Tracheal Anastomosis

If an extended tracheal resection (up to half the length of the trachea) is anticipated, or if at the time of the conduct of the tracheal anastomosis, the proximal and distal ends cannot be re-approximated, there are several options to try to relieve the tension:

1. Flexion of the neck
2. Blunt dissection anterior to the trachea as far as to the carina. This is the same plane that is routinely dissected bluntly during the performance of a mediastinoscopy.
3. Intrapericardial hilar release
4. Laryngeal release procedures. These can allow for an additional 2 or 3 cm of tracheal mobilization by allowing the larynx to descend inferiorly. It is associated with some degree of postoperative swallowing difficulty, which is usually transient.
   a. Suprathyroid laryngeal release. Requires division of the soft tissue attachments between the inferior border of the hyoid bone above and the superior border of the thyroid cartilage below
      1) The upper skin flap of the transverse cervical incision is dissected up to the level of the hyoid bone.
      2) The sternohyoid muscles are retracted laterally from the midline.
      3) The underlying thyrohyoid muscles are dissected out and divided transversely.
      4) The underlying thyrohyoid membrane and thyrohyoid ligament thus exposed are transversely divided between the superior cornua of the thyroid cartilage. Care is taken not to damage the underlying submucosa of the anterior pharyngeal wall.
      5) The tips of the superior cornua are amputated, avoiding the paired superior laryngeal nerve and artery, which lie laterally.
      6) Having separated the thyroid cartilage from the hyoid bone above, the larynx can now drop down 2 to 3 cm, relieving tension on the tracheal anastomosis.
   b. Suprahyoid release. Is purported to cause a lower incidence of uncoordinated swallowing postoperatively.
      1) The skin flap is dissected to the suprahyoid region. (An alternate approach is to use a second transverse incision directly over the hyoid bone.)
      2) The muscular attachments of the superior aspect of the hyoid bone, the mylohyoid, geniohyoid, and genioglossus muscles are detached from the hyoid bone over its central portion, thus exposing the pre-epiglottic space.
      3) The lesser cornua and the hyoid bone itself are divided anterior to the tendinous attachments of the digastric muscles bilaterally.
      4) Having thus separated the hyoid bone from the thyroid cartilage, the larynx can descend down 2 to 3 cm, relieving tension on the tracheal anastomosis.
5. Tracheal replacement with the use of prosthetic material

COMMON ERRORS IN TECHNIQUE

1. Failure to correctly identify the proximal and distal margins of the tracheal lesion to be resected
2. Failure to preserve the recurrent laryngeal nerves, resulting in vocal cord palsy or airway obstruction if bilateral
3. Inadequate tracheal mobilization, resulting in a tracheal anastomosis under tension

4. Excessive circumferential mobilization of the trachea proximally and/or distally, resulting in an ischemic tracheal anastomosis
5. Failure to leave the patient's neck flexed adequately at the end of the procedure with resultant tracheal anastomotic tension
6. Failure to confirm histologically negative margins with intraoperative frozen section when resecting tracheal tumors

POSTOPERATIVE PERIOD

Postoperative Management

1. The patient's head must be kept flexed, with the use of positioning and the heavy suture from the chin to the anterior chest.
2. If possible, the patient should be extubated at the end of the procedure. This is important to:
   a. Prevent pressure on the anastomosis with a cuffed endotracheal tube, which may impair mucosal circulation at the anastomosis.
   b. Avoid subjecting a distal tracheal anastomosis to positive ventilator pressure.
   c. Prevent pooling of the secretions adjacent to the anastomosis above a cuffed endotracheal tube.
3. Patients should be given humidified oxygen to inhale. If there is edema and stridor (most likely due to laryngeal edema), patients may receive heliox (80% helium, 20% oxygen), nebulized racemic epinephrine or steroids, or systemic steroids.
4. Patients should receive a daily chest radiograph.
5. Patients are started on a clear liquid diet on the first postoperative day, and the diet is advanced as tolerated. If there is a question of intraoperative recurrent nerve injury, or if the patient has undergone a laryngeal release procedure, a bedside swallowing assessment by a speech language pathologist should be undertaken, with initiation of diet under their supervision. Swallowing difficulties, which are almost universally transient, are typically worse with liquids than with solids.
6. The head of the bed should be elevated 30 degrees to prevent edema in the upper airway.
7. A flexible bronchoscopic examination to directly evaluate the tracheal anastomosis should be performed under conscious sedation prior to discharging the patient or earlier if there are clinical signs of tracheal anastomotic narrowing or disruption.

Complications

1. Airway obstruction or edema:
   a. Can be treated by elevation of the head of bed, heliox, inhaled steroids, racemic epinephrine, or systemic steroids
   b. Reintubation or even tracheostomy may be required in severe cases.
2. Anastomotic leak with anastomotic breakdown and cervical abscess. If there is any question of anastomotic breakdown, evaluation using a flexible bronchoscopy, under copious sedation, should be undertaken immediately.
   a. Small areas of disruption will generally heal spontaneously and not result in tracheal anastomotic stricture.
   b. If there is an abscess adjacent to a tracheal anastomotic disruption the wound should be widely opened for drainage and packed with gauze.
   c. If more than a third of the circumference of the airway anastomosis is disrupted, the anastomosis should be stented open with the placement of a Montgomery T-tube.
3. Tracheal re-stenosis is usually a delayed complication occurring 4 to 6 weeks after surgery.
   a. Initially treat with tracheal dilation, which can be repeated multiple times if necessary.
   b. If the tracheal stricture recurs despite multiple dilations, tracheal re-resection is undertaken, if technically feasible.
   c. If the stricture recurs and the patient cannot undergo re-resection, then a permanent tracheal stent will be required.
4. Granulation tissue at the anastomosis, which may bleed or cause obstruction, can be treated using a bronchoscope with mechanical débridement +/– YAG laser ablation (being careful to use the minimal amount of energy possible).
5. Bleeding in the neck. Neck re-exploration if required
6. Air leak and subcutaneous emphysema
   a. At the conclusion of the surgical procedure and prior to extubation, the tracheal anastomosis should be examined under water by hyperinflating the lungs with the endotracheal cuff down (20 to 30 cm H_2O). Leaks thus identified should be surgically repaired by placing more sutures and/or buttressing with some vascularized tissue (usually strap muscle).
   b. Small postoperative air leaks will usually heal spontaneously, particularly if the patient is not on postoperative positive pressure ventilation.
   c. If the subcutaneous emphysema is severe, it can be decompressed by opening the wound.
   d. If a pneumothorax is seen on a postoperative chest radiograph, then a chest tube is placed in the appropriate hemithorax.
7. Uncoordinated swallowing and aspiration. This is usually seen following laryngeal release procedures (the suprathyroid procedure more so than the suprahyoid procedure). It is usually transient but can be prolonged and is more often an issue in elderly patients. Can also be associated with intraoperative recurrent nerve injury and vocal cord paralysis
   a. Speech therapy, bedside evaluation, and monitored advancement of diet
   b. In severe and prolonged cases, a temporary nasal duodenal feeding tube may be required.
8. Recurrent nerve injury and vocal cord palsy
   a. With careful surgery, permanent inadvertent recurrent nerve injury should be an uncommon occurrence.
   b. Temporary palsy may result from intraoperative mobilization of the nerve.
   c. Intraoperative recurrent laryngeal nerve monitoring with electromyography should be undertaken to minimize the risk of injury to the recurrent nerve.
   d. If vocal cord palsy does not resolve with time, then peroral medialization of the vocal cord can be undertaken.
   e. In a patient with poor postoperative pulmonary toilet and a documented vocal cord paralysis, then it may be appropriate to medialize the vocal cord in the immediate postoperative period.
9. Tracheoinomminate fistula. If the artery lies near the completed tracheal anastomosis, it should be protected with a muscular or omental pedicle interposed between the artery and the airway anastomosis.
10. Tracheoesophageal fistula. If an esophageal repair is part of the procedure, some vascularized tissue should be placed between the esophagus and the airway anastomosis.
11. Pneumonia. Patient should undergo aggressive postoperative pulmonary toileting and attention to pain control to facilitate good expectoration of secretions. If the vocal cord is paralyzed and there is a problem clearing sections, early vocal card medialization may be undertaken.

12. Deep venous thrombosis and pulmonary embolus. Risks minimized by early mobilization of the patient and prophylactic subcutaneous heparin 5000 units tid

Alternative Management Plan

1. Tracheal dilation may be effective to relieve airway obstruction, particularly in the case of a benign stricture. While it may be useful as a temporizing measure to relieve airway obstruction in order to allow for surgical planning or to allow time for resolution of inflammation in a tracheal lesion, it is generally not of durable benefit. For very short airway strictures or webs less than one-half centimeter, dilation alone may be successful as definitive therapy.
2. Tracheal stents may be placed to maintain an airway in patients with malignancy. They are particularly effective in the cases of extrinsic compression, often due to malignant mediastinal adenopathy. They may also be used for obstructing endobronchial tumors, typically after some endobronchial débridement. Tracheobronchial stents can also be used to maintain an airway in a patient with a benign stricture who cannot undergo tracheal resection.[4,5]
   a. Wire metal stents may be covered or uncovered. They are relatively easy to deploy with flexible bronchoscopy and fluoroscopy and have a wide diameter. Once deployed, however, they may become incorporated into the airway and are thus difficult to remove. They also may cause an excessive amount of granulation tissue.
   b. Silicone stents are more difficult to deploy than metal stents and require rigid bronchoscopy. Passing large tracheal stents across a narrow glottis may be difficult. They are also more prone to migration than metal stents. They are relatively nonreactive, however, and more easily removed than metal stents. They are more suitable for benign strictures than metal stents.
   c. Montgomery T-tube. These are silicone stents that have an external limb that projects through the trachea and neck. They can be placed through a pre-existing tracheostomy stoma, or a tracheostomy can be performed at the time of placement. Custom-made Y shaped T tubes can be made, which have limbs that extend into the main stem bronchi. They are introduced through a tracheal stoma and as such are good alternatives for patients with a small glottic opening that will a not allow atraumatic passage of a rigid scope loaded with a silastic tracheal stent. The side arm secures the stent, eliminating the risk of migration.
3. Tracheostomy. A tracheostomy tube may be inserted with the distal opening placed beyond the tracheal stricture. If the tracheal stricture is located distally, extended-length tracheostomy tubes should be used. This allow for mechanical ventilation, which cannot be easily done in patients with silastic stents (usually a metals stent will allow passage of an oral endotracheal tube under bronchoscopic guidance, if necessary, for mechanical ventilation). As opposed to tracheal stents, the uncapped tracheostomy tube does not allow for airflow through the nasopharynx and across the larynx, so phonation is not possible, and the patient also does not get filtration and humidification of inspired air. Uncuffed tracheostomy tubes, or cuffed tubes with the cuff deflated, may allow for translaryngeal airflow; however, the resistance to breathing around the tracheostomy tube may be significant (fenestrated tracheostomy tubes may be used to decrease this resistance to flow by allowing flow through the lumen of the tracheostomy tube).
4. Endobronchial mechanical removal or YAG laser therapy of tracheal tumors. While these therapies offer good palliation of endotracheal tumors, typically they are extending into the trachea, or may even be extending full thickness through the trachea, and will not be cured with such endobronchial therapy, so it is not recommended in patients with technically resectable tumors.
5. Radiation or chemoradiation
   a. Malignant tumors have often metastasized at time of presentation and as such are not appropriate for resection.
   b. Alternatively they may be locally advanced and not technically resectable for a cure.

DISCUSSION

Evidence-Based Medicine Question

Is endobronchial ablative or resective therapy a comparable but less invasive method of managing resectable tracheal tumors?

Endobronchial therapy for tracheal tumors, while potentially effective for palliation, offers essentially no chance of long-term cure, as it will not address tumors invading through the full thickness of the tracheal wall. It should therefore not be offered to patients with resectable tracheal tumors who are physiologically fit for surgery.

Editorial Comment

Head and neck surgery is the ultimate expression of teamwork. Thoracic surgeons play an important role as members of our team, helping us provide the best care for our patients. However, head and neck and thoracic surgery are, in fact, areas of overlapping interest, since surgeons of both specialties carry out bronchoscopies, retrieve foreign bodies, and do tracheal resections for tracheal stenosis or tumors of the upper trachea.

Tracheal stenosis, caused by endotracheal tubes (especially in the pediatric population), and stenosis secondary to improperly done tracheostomies, as well as from endotracheal tubes in ventilator patients in the adult population, require the resection of a relatively short segment of the trachea. Head and Neck Surgeons have been trained to carry out these procedures in adults, and Pediatric Otolaryngologists have designed a number of rather sophisticated procedures to manage the vexing problem of the stenotic airway in children.

We are grateful to our colleagues in thoracic surgery who are a great help to our patients in the management of extensive tracheal stenosis and neoplasms of the lower tracheal bronchial tree and the many patients who have synchronous or metacronous secondary primary squamous cell carcinoma of the lungs. This chapter, by one of my dear colleagues, Dr. Neil Christie, takes us step-by-step through the details of the surgical technique necessary to overcome the challenging airway problems that are a result of tracheal strictures. His description of the techniques of the resection of the stricture segment and primary anastomosis, as well as the laryngeal release technique necessary for more extensive resections, is clear and concise. While Head and Neck Surgeons will not be doing these more extensive procedures, it is important for us to have a clear understanding of what is available and appropriate for our patients and the knowledge and skill sets involved.

Eugene N. Myers

REFERENCES

1. Andrews MJ, Pearson FG. The incidence and pathogenesis of tracheal injury following cuffed tube tracheostomy with assisted ventilation. Ann Surg 1971;173:249.
2. Grillo HC, Mark EJ, Mathisen DJ, Wain JC. Idiopathic laryngotracheal stenosis and its management. Ann Thorac Surg 1993; 56:80.
3. Grillo HC, Mathisen DJ. Primary tracheal tumors: treatment and results. Ann Thorac Surg 1990;49:69–77.
4. Puma F, Ragusa M, Avenia N, et al. The role of silicone stents in the treatment of cicatricial tracheal stenosis. J Thorac Cardiovasc Surg 2000;120:1064–1069.
5. Saad CP, Murthy S, Krizmanich G, Mehta AC. Self-expandable metallic airway stents and flexible bronchoscopy: long term outcomes analysis. Chest 2003;124:1993.

REVIEW QUESTIONS

1. How much of the trachea can be resected and still allow for a tracheal anastomosis?
   a. 1 cm
   b. One-fourth of tracheal length
   c. One-half of tracheal length
   d. Two-thirds of tracheal length

2. All of the following decrease tracheal anastomotic complications, except
   a. Keeping tension off the tracheal anastomosis
   b. Perioperative systemic steroids
   c. Resecting all of the diseased trachea before performing the airway anastomosis
   d. Avoiding excessive circumferential tracheal mobilization above and below the airway anastomosis

3. All of the following techniques may be used to avoid tracheal anastomotic tension, except
   a. Suprahyoid release
   b. Suprathyroid release
   c. Dissection in the pretracheal plane
   d. Postoperative neck extension
   e. Perihilar pericardial release

4. Resection and reconstruction of lesions in the distal trachea can be best accomplished by which of the following approaches?
   a. A generous collar incision
   b. A collar incision with a partial upper sternotomy
   c. A right fourth interspace thoracotomy
   d. A left fourth interspace thoracotomy

23 Management of a Tracheocutaneous Fistula and Depressed Scar

William G. Albergotti, Eugene N. Myers

INTRODUCTION

A tracheocutaneous fistula (TCF) is a sequela of a tracheostomy and is usually associated with an unsightly depressed tracheostomy scar (Fig. 23.1). Formation of this fistula is predicated on squamous epithelium migrating from the skin into the trachea, forming an epithelial interface with the mucosa of the trachea, and thereby creating a true fistula that cannot close spontaneously. Marked separation of the strap muscles associated with a prolonged indwelling cannula, infection, and wasting of subcutaneous tissue due to poor nutrition and weight loss are important factors predisposing to the development of a depressed scar and fistula. These features facilitate epithelial migration toward the tracheal mucosa along the tract formed by the tracheostomy cannula. White and Smitheringale suggest that epithelial migration of skin into the trachea and extensive cicatricial resolution of chronic granulation tissue result in the formation of a dense connective tissue sleeve based around the entire opening of the tracheal stoma.[1]

During the performance of a tracheostomy, the strap muscles are retracted laterally, and the cannula is inserted. In a patient who has had a cannula in place for a prolonged period, infection and fibrosis occur and the strap muscles are scarred into a position lateral to the tracheostomy. When the patient is eventually decannulated and the stoma heals by secondary intention, the skin heals directly to the trachea, thus forming a depressed scar due to the separation of the strap muscle with or without a TCF. The relationship between the duration of tracheostomy and the development of a persistent fistulous tract has been well established, with a fistula rate of 50% identified in patients with a cannulation time of longer than 1 year.[2,3] Other risk factors proposed include previous neck radiation or tracheostomy. Interestingly, stomal maturation has not been found to be a risk factor for formation of a TCF.[4]



Fig. 23.1. A tracheocutaneous fistula and depressed scar as a result of long-term placement of a tracheostomy cannula.

Persistence of a TCF may lead to increased morbidity, particularly in patients with limited pulmonary reserve, which is of particular concern in children.[1,5] Eaton and colleagues[6] stated that a persistent TCF may be a source of considerable morbidity because of problems with poor hygiene, aspiration, respiratory infection, and associated difficulty with voicing. In addition to functional problems with the TCF, unsightly scars often follow tracheostomy decannulation. With the skin directly adherent to the trachea at the site of the TCF, every time the patient swallows the skin moves up and down, which attracts unwanted attention. Many emergency tracheostomies are still carried out through a vertical incision, which itself may result in an unsightly scar or a keloid.

Several methods for closure of a TCF have been described, including primary closure, fistulectomy with primary closure in layers, and fistulectomy with healing by secondary intention. When a fistula is too large to close by secondary intention, a surgical procedure is necessary. Closure of a TCF was reported as early as 1934 by Jackson and Babcock.[7] They used a lined bipedicled flap reinforced with conchal cartilage. Pressman described the repair of a depressed tracheostomy scar by detaching and transposing the origins of the sternocleidomastoid muscle into the defect.[8] Others have suggested the use of sternohyoid muscle rotational flaps, subcutaneous Z-plasty, turnover flaps, and V-Y advancement flaps.[9,10] For very small fistulas without concern for cosmesis, chemical or electrocautery has been described.[6]

Our technique for correction of the depressed scar emphasizes restoring the natural anatomic position of the strap muscles in the midline. This key feature has eliminated the need for the aforementioned procedures. Kulber and Passy have described a similar technique that prevents reattachment of the skin to the trachea by reapproximation of the strap muscles in the midline.

KEY OPERATIVE LEARNING POINTS

- Patients should be evaluated endoscopically to ensure that the airway is patent before closure of a TCF.
- The key feature of the operation is dissecting the strap muscles free of scar tissue and the trachea and restoring the normal anatomy by reapproximating the strap muscles in the midline. This reinforces the closure in patients with a TCF and eliminates the depressed scar in all patients.
- Failure to thoroughly free the strap muscles from scar tissue and the trachea and to reapproximate the muscles in the midline will result in persistence of the depressed scar.
- Failure to provide airtight closure of the fistulous tract and provision of an inner epithelial lining will result in recurrence of the fistula.
- TCFs are colonized by bacteria, so perioperative antibiotics should be given to prevent infection.
- Patients, particularly those in the pediatric age group, may experience respiratory distress after closure of a TCF.
- Children undergoing closure of a TCF should be monitored in the intensive care unit after the procedure, because airway distress may be a complication of this procedure.
- Adult patients should be observed in the hospital overnight to ensure that the airway is stable.

PREOPERATIVE PERIOD

History of Present Illness

- Indication for and duration of the tracheostomy
  - With particular attention to whether it was emergent or planned
- Amount of time since decannulation
- Previous attempts at repair
  - Previous attempts may decrease the likelihood of success with the currently planned repair. The surgeon will also need to be mindful of the likely presence of increased scar tissue.
- Associated symptoms
  - Shortness of breath
  - Difficulty with voicing
  - Productive cough
  - Saliva coming through the fistula
  - Dysphagia and/or pneumonia
  - Fistula site infections
  - Cosmetic concerns
- Past medical history
  - With particular attention to associated cardiopulmonary dysfunction, the need for positive pressure ventilation at baseline for obstructive sleep apnea or other cardiopulmonary disease
  - History of radiation of the neck, diabetes mellitus, and vascular disease may place patients at risk for poor wound healing or persistent fistula
- Past surgical history
  - Particularly including history of tracheostomy, previous attempts at repair and other surgeries within the neck
- Social history
  - Tobacco use will impair wound healing and could contribute to the incidence of postoperative subcutaneous or mediastinal emphysema if there is coughing on emergence from inhaled anesthesia

Physical Examination

- Complete examination of the head and neck
  - Attention to TCF or depressed scar site (vertical or horizontal tracheostomy)
    - Presence and size of TCF
    - Presence of associated keloid or granulation tissue
  - Examination of the neck
    - Other scars within the neck
    - Thyromental distance
  - Examination of the oral cavity and oropharynx may suggest risk factors for obstructive sleep apnea or difficult airway perioperatively.
    - High, arched palate
    - Glossoptosis
    - Mallampati score
- Flexible laryngoscopy and tracheoscopy should be performed to assess the entirety of the upper airway to the level of the carina to ensure that there are no sources of obstruction.
  - Complications may occur after closure of a TCF, particularly in children, so it is of utmost importance to ensure that the caliber of the trachea is satisfactory before closure. One reason for persistence of the fistula may be that the patient does not have an adequate airway, and the fistula serves as an auxiliary airway. The concern is that once the fistula is closed in such patients, the airway might not be patent enough to permit adequate air exchange.
  - During airway endoscopy, particular attention should be paid to the suprastomal trachea and subglottis, as this is the most common site of granulation formation and stenosis in children.
  - Awake transnasal bronchoscopy can also be performed in-office using a combination of nebulized and topical 4% lidocaine to assess the complete airway dynamically.
  - In children who will not tolerate in-office endoscopy, formal airway endoscopy should be performed at the time of repair.
- Patients should be able to tolerate occlusion of the TCF for at least 24 hours.

Imaging

- Computed tomography of the neck (noncontrast) can be considered to evaluate the adequacy of the tracheal lumen, particularly if endoscopy is inadequate.

Indications

- Patients selected for this procedure have symptoms associated with the fistuous tract or scar, including difficulty with voicing, productive cough, saliva coming out of the fistula, dysphagia and/or pneumonia, fistula site infections, ineffective cough, or cosmetic concerns.
- The fistula should have been present at least 3 months after decannulation to allow for an adequate opportunity to heal secondarily.

Contraindications

- Inability to tolerate occlusion of the TCF or airway obstruction noted on endoscopy
- Active infection at the fistula site
- Chronic cough
- Need for positive pressure ventilation (relative contraindication)
  - Polysomnogram should be obtained preoperatively with occluded stoma for patients with known or suspected obstructive sleep apnea (OSA) to assess the degree of OSA. Patients with OSA should be counseled regarding the need for long-term positive pressure ventilation if TCF is closed.

OPERATIVE PERIOD

Anesthesia

- May be performed under general or local anesthesia with intravenous sedation
  - Our preference in adults is local anesthesia with intravenous sedation in order to avoid the need for positive pressure ventilation during closure or coughing during emergence. In a patient with a difficult airway, general anesthesia is preferred.
  - General anesthesia is essential for children.
  - Given the potential use of electrocautery near the airway, an airway fire is a risk. The anesthesiologist should be made aware, and the fraction of inspired oxygen should be kept at a minimum.

Positioning

- The patient is placed in the supine position with the head extended. We use a shoulder roll to establish maximal extension of the head.

Perioperative Antibiotic Prophylaxis

- Perioperative antibiotics are administered to prevent infection, because the fistula is potentially colonized by pathogenic organisms. First-generation cephalosporin is administered prior to the skin incision.

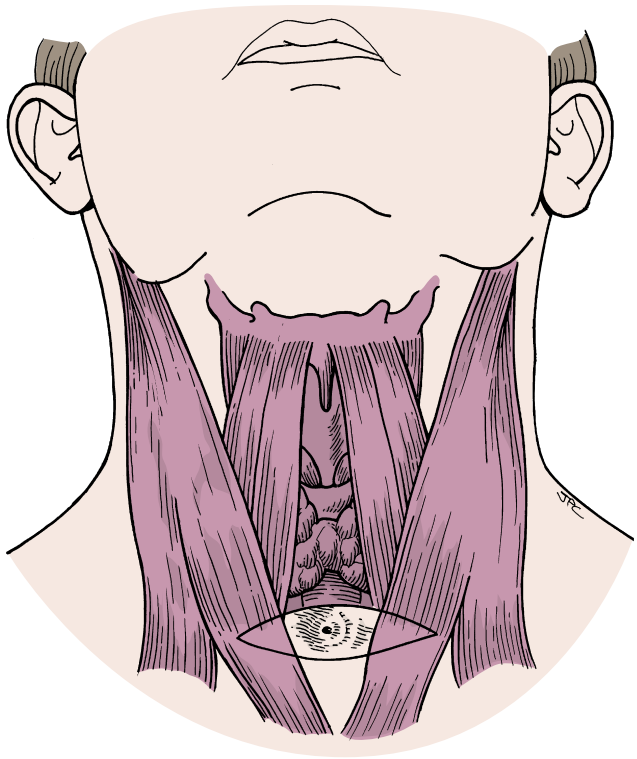

Fig. 23.2. The scar from the tracheostomy is excised almost down to the fistulous tract.

Instruments and Equipment to Have Available

- Standard neck dissection or tracheotomy instrument set
- Bovie electrocautery
- Suction
- Cuffed endotracheal tube or tracheostomy tube in case of need for urgent positive pressure ventilation

Key Anatomic Landmarks

- Thyroid notch of thyroid cartilage
- Cricoid cartilage
- Sternum

Prerequisite Skills

- Ability to perform a tracheostomy

Surgical Technique

- A transverse elliptical incision is made at the level of and extending somewhat lateral to the TCF (Fig. 23.2).
- The skin flaps are widely undermined. The scar between the skin and the fistula should then be released.
- Dissection is carried down along the fistula to the level of the trachea. The tract should then be excised, with just enough skin left to close the fistula by inverting the squamous epithelium as a "trapdoor" flap to form the inner epithelial surface of the anterior wall of the trachea (Fig. 23.3).
- The strap muscles will be found incorporated in dense scar tissue and adherent to the lateral aspect of the trachea. The strap muscles are then dissected free from the scar tissue and repositioned over the trachea to restore them to their normal anatomic position.
- The muscles are sutured together in the midline with absorbable suture (Fig. 23.4). This maneuver effectively sepa-

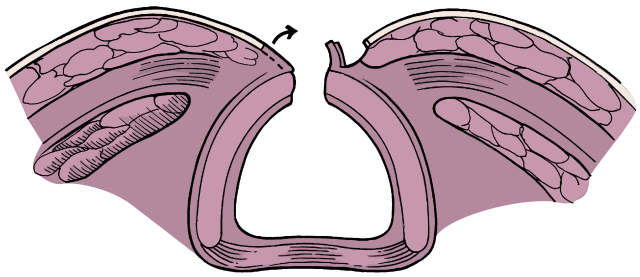

Fig. 23.3. Dissection is carried down to the surface of the fistula, and the skin of the fistulous tract is used as a skin flap. It is turned in to restore the anterior epithelial lining of the trachea.

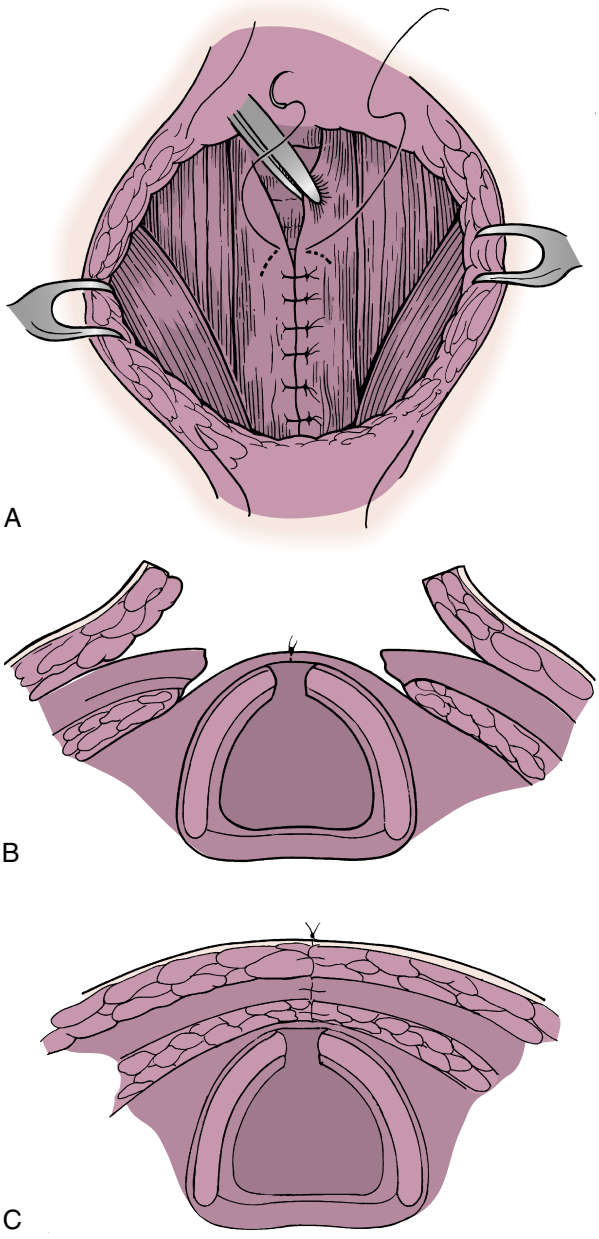

Fig. 23.4. A to **C,** The strap muscles are repositioned in the midline and sutured together. The subcutaneous tissue and skin are then closed.

rates the trachea from the skin, eliminates the depression, and prevents reformation of the depressed scar.
- A small rubberband or Penrose drain is left just deep to the strap muscles to allow for air egress through the lateral aspect of skin closure. The drain is removed on postoperative day 1.
- The subcutaneous tissue is closed without tension. The skin incision is then closed with 6-0 chromic suture. A Z-plasty or a geometric broken-line skin closure may be used if necessary to produce a small, smooth scar. Steri-Strips are applied to the wound to minimize tension.
- A modification of this technique is also used for patients who have a depressed tracheotomy scar without a TCF. The mechanism of the depressed scar with adherence to the trachea is similar; the only step that is unnecessary is excision of a fistula. The procedure results in an acceptable scar (Fig. 23.5). Returning the strap muscles to their anatomic position eliminates the depression and prevents its recurrence.
- Potential complications of repair include pneumomediastinum, pneumothorax, and respiratory insufficiency requiring tracheotomy. Complications typically occur in patients who undergo single-stage excision and closure of the TCF associated with large defects of the anterior tracheal wall. Therefore, for larger defects, the authors modified their technique as follows:
  - The TCF and scar are dissected out through a horizontal elliptical incision.
  - The fistulous tract is dissected down to the anterior tracheal wall and excised. If the defect in the anterior wall is greater than 4 mm, a no. 3 or 4 metal Pilling tracheotomy tube is inserted into the previous tracheotomy site.
  - The strap muscles are elevated and closed in the midline around the tracheotomy tube with 4-0 polyglactin. This eliminates the depressed scar.
  - The skin edges are widely undermined and then closed around the tracheostomy tube with a 5-0 nylon suture.
  - The tracheostomy tube is capped in the recovery room or on the first postoperative day, and the patient is decannulated on day 2. The small central area is allowed to heal by secondary intention.
- In children, this procedure is performed under general anesthesia by using the least complex method of closing a TCF, which consists of excising the epithelium of the fistulous tract and allowing the tract to close by secondary intention.
  - Such closure occurs rapidly and results in a watertight seal that will allow the patient to swim and bathe.
  - This method is recommended for young children, in particular because more extensive procedures may require lengthy anesthesia, and manipulation of the trachea may lead to edema and airway obstruction.
  - If the scar is not satisfactory, it may be revised later.
  - Several studies have shown no difference in outcomes or complications between primary and secondary closure in children. Thus secondary closure is the preferred choice of closure in children.

Common Errors in Technique

- Failure to free the strap muscles thoroughly from scar tissue and the trachea and to reapproximate the muscles in the midline will result in the persistence of the depressed scar.
- Failure to provide airtight closure of the fistulous tract and provision of an inner epithelial lining will result in recurrence of the fistula.

Postoperative Management

- Adult patients are hospitalized overnight for observation of the airway and discharged the next day.

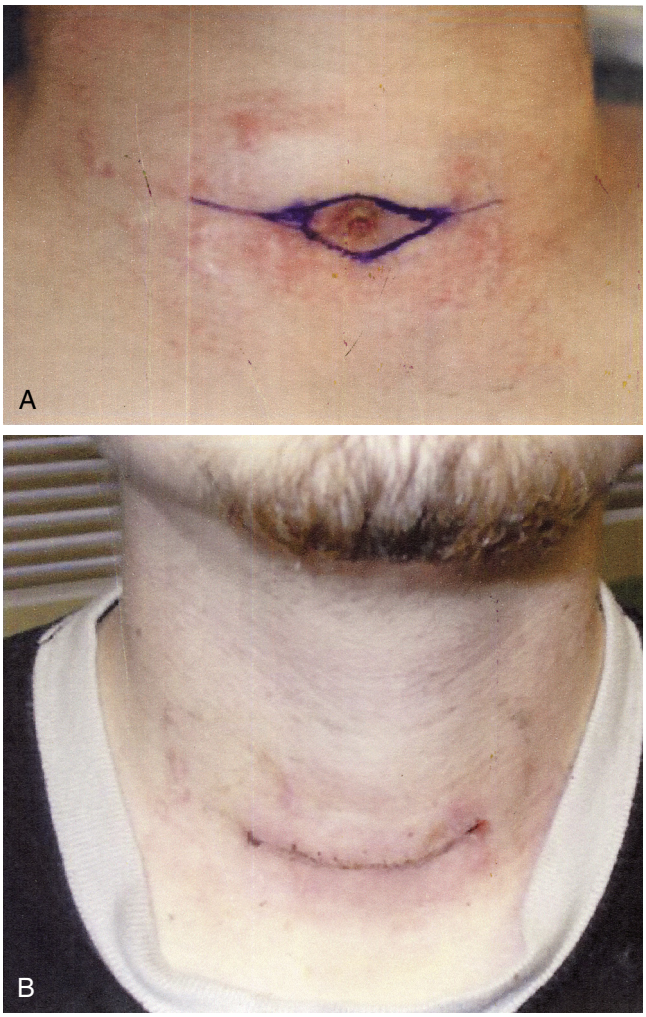

Fig. 23.5. A, Markings for planned excision of tracheocutaneous scar and **B,** postoperative appearance at one week after excision of tracheocutaneous scar.

- Infants or children who undergo this procedure are best monitored in an intensive care unit overnight to ensure adequacy of the airway.
- If a drain is kept in place, it is removed on postoperative day 1. If a tracheostomy tube is left in place, it is removed after an adequate trial of capping, usually by postoperative day 2.
- Care of the wound is minimal because the skin is closed with absorbable 6-0 catgut skin sutures and Steri-Strips, which are removed in 7 to 10 days.
- A tracheotomy set should be kept at the bedside in the unlikely event of airway obstruction.
- If positive pressure ventilation is required, it is started 2 weeks after surgery, unless severe obstructive sleep apnea (OSA) in which positive pressure is restarted the evening of surgery, knowing there is an increased risk of airway complications.

Complications

- The primary concern postoperatively is the development of subcutaneous emphysema, pneumothorax, or pneumomediastinum due to air escape from tracheal closure. This complication occurs in up to 3% of cases and may be exacerbated by the use of positive pressure, coughing, or other increases in intrathoracic pressure. Admission and observation in a monitored patient unit are mandatory for adult patients and intensive care for pediatric patients.

- If this occurs, the wound should be opened at the bedside and a cuffed tracheostomy tube placed through the tracheostoma, with positive pressure provided through this route if needed. Positive pressure should not be applied via a face mask, as this can exacerbate the problem.
- In patients with chronic cough or pulmonary disease who may be at risk for this complication, it is advantageous to perform excision of the tract with allowance of closure by secondary intention.

- Wound infection or dehiscence

Alternative Management Plan

- Observation
- Excision of tract with healing by secondary intention (see previous sections)

DISCUSSION

Evidence-Based Medicine Question

Is there a difference in the success rate between primary closure of TCF and healing by secondary intention?

- Among pediatric patients, a systematic review has found no difference in closure rates between primary and secondary closure (95.7% vs. 92.3%, respectively). Airway complications occur in 3.8% and 3.6%, respectively. Similarly, there was no difference found on meta-analysis in infection, fistula, and revision surgery. Excision of the tract alone has been shown to require less surgical time, however.
- Among adults, there is little evidence to support one technique above another; however, primary closure is preferred for cosmesis.

Editorial Comment

Many years ago, when Elizabeth Taylor and her then lover, Richard Burton, were in London, she became seriously ill with pneumonia. A life-saving tracheostomy was performed at her bedside by Sir Terrance Cawthorne, a distinguished otolaryngologist whose specialty was problems of the vestibular system. Fortunately, she survived but at the cost of an unsightly scar. Since no surgeon was ever brave enough to revise the scar, the beautiful actress hid the scar behind a series of especially designed diamond necklaces.

The depressed tracheotomy scar is a purely cosmetic issue. However, when combined with a tracheocutaneous fistula, the cosmetic defect is magnified by the leakage of saliva expelled through the fistula when coughing and the movement of the skin of the neck up and down during swallowing.

The solution to the problem is a simple one: Restore the anatomy to its normal state. This requires the following steps: Excise the scar and the fistulous tract saving enough skin to create a trap door flap closure of the stoma, providing the necessary inner epithelial lining; undermine the surrounding skin to release it from the trachea and the strap muscles; reapproximate the strap muscles in the midline; and perform a multiple layer closure of the wound.

In the pediatric age group, however, the solution to this problem is not so simple, primarily due to the size of the patient, the size of the structures, and the often tenuous state of the airway. Although a recent meta-analysis revealed that there was no difference in closure rates between the primary closure and secondary closure, the overall condition of the patient and circumstances leading up to the tracheotomy and the request for closure of the fistula should be considered when deciding which path to take in solving this vexing cosmetic problem.

Eugene N. Myers

Access the review questions and additional sources list online at http://www.expertconsult.com



REFERENCES

1. White AK, Smitheringale AJ. Treatment of tracheocutaneous fistulae in children. J Otolaryngol 1989;18:49–52.
2. Joseph HT, Jani P, Preece JM, et al. Paediatric tracheostomy: persistent tracheo-cutaneous fistula following decannulation. Int J Pediatr Otorhinolaryngol 1991;22:231–236.
3. Wetmore RF, Handler SD, Potsic WP. Pediatric tracheostomy. Experience during the past decade. Ann Otol Rhinol Laryngol 1981;91:628–632.
4. Levi JR, Topf MC, Mostovych NK. Stomal maturation does not increase the rate of tracheocutneous fistulas. Laryngoscope 2016;126(10):2395–2398.
5. Licameli GR, Marsh BR, Tunkel DE. A simple method for closure of tracheocutaneous fistula in children. Arch Otolaryngol Head Neck Surg 1997;123:1066–1068.
6. Eaton DA, Brown OE, Parry D. Simple technique for tracheocutaneous fistula closure in the pediatric population. Ann Otol Rhinol Laryngol 2003;112:17–19.
7. Jackson C, Babcock WW. Plastic closure of tracheocutaneous fistula. Surg Clin North Am 1934;14:199–221.
8. Pressman JJ. The repair of depressed tracheostomy scars. Arch Otolaryngol 1961;74:150–152.
9. Bishop JB, Bostwick J, Nahai F. Persistent tracheostomy stoma. Am J Surg 1980;140:709–710.
10. Lewis VL, Manson PN, Stalnecker MC. Some ancillary procedures for correction of depressed adherent tracheostomy scars and associated tracheocutaneous fistulae. J Trauma 1984;27:651–655.

REVIEW QUESTIONS

1. Risk factors for persistent tracheocutaneous fistula include all of the following, except
   a. Stomal maturation
   b. Duration of tracheotomy
   c. Infection
   d. Neck radiation

2. Indications for closure of tracheocutaneous fistula include all of the following, except
   a. Cosmesis
   b. Aspiration
   c. Subglottic stenosis
   d. Weak voice

3. Absolute contraindications to closure of a tracheocutaneous fistula include all of the following, except
   a. Inability to tolerate occlusion of the fistula
   b. Active infection
   c. Proximal airway obstruction
   d. Obstructive sleep apnea

ADDITIONAL SOURCES

Kulber H, Passy V. Tracheostomy closure and scar revisions. Arch Otolaryngol 1972;96:22–26.

Lee BJ, Goh EK, Wang SG, et al. Closure of large tracheocutaneous fistula using turn-over hinge flap and V-Y advancement flap. J Laryngol Otol 2002;116:627–629.

Lewis S, Arjomandi H, Rosenfeld R. Systematic review of surgery for persistent pediatric tracheocutaneous fistula. Laryngoscope 2017;127(1):241–246.

Myers EN, Stool SE. Complications of tracheotomy. In: Myers EN, Stool SE, Johnson JT, editors. Tracheotomy. New York: Churchill Livingstone; 1985. p. 147–169.

Wheeler WB, Kurachek SC, Lobas JG, et al. Respiratory complications of tracheocutaneous fistula closure. Crit Care Med 1991;19(4):580–582.

Wine TM, Simons JP, Mehta DK. Comparison of 2 techniques of tracheocutaneous fistula closure: analysis of outcomes and health care use. JAMA Otolaryngol Head Neck Surg 2014;140(3):237–242.

Wolter NE, Anderson J. Polysomnography: assessment of decannulation readiness in chronic upper airway obstruction. Laryngoscope 2014;124:2574–2578.

24 Stenosis of the Tracheostoma Following Total Laryngectomy

Eugene N. Myers, Mark Mims

INTRODUCTION

Stenosis of the tracheostoma following laryngectomy is an infrequent but distressing complication that may occur despite meticulous attention to the construction of the tracheostoma. Stenosis can result from a variety of factors and usually occurs in the early months following laryngectomy.[1] However, stenosis may also occur years later despite the type of closure performed at initial surgery.[2] Wax et al. defined tracheal stenosis as a narrowing of the stoma that requires the patient to wear a stent (usually a laryngectomy cannula) for longer than 3 months after surgery or requires revision of the tracheal stoma.[3] Giacomarra et al. defined tracheostomal stenosis as respiratory insufficiency at rest or during exercise or if there is difficulty in clearing tracheal secretions because of nonlaminar flow, or both.[4] Although the patient with relatively good pulmonary function may maintain adequate exercise tolerance, many patients with emphysema or chronic obstructive lung disease may encounter respiratory insufficiency when stenosis of the tracheostoma occurs.[5] Adequate mucociliary transport may be impeded by stomal stenosis and may result in stagnation of mucus and the potential for recurrent pulmonary infection. Severe stenosis is potentially dangerous because complete obstruction may occur in the presence of crusting or a mucous plug, particularly during an episode of tracheitis or tracheobronchitis.[3] Stomal stenosis may also interfere with the proper insertion and use of a tracheoesophageal puncture speech prosthesis. Stenosis can occur regardless of the type of closure or reconstruction. A wide variety of techniques have been described to address stenosis ranging from noninvasive techniques, such as serial dilation or excision of peristomal adipose tissue, to more invasive techniques, such as Z-plasties, local or advancement flaps, and even free flaps for recalcitrant stenosis. The common features for all techniques are (1) to eliminate circular forces of contraction and (2) to provide for healing by primary intention (e.g., skin to mucosa) (Fig. 24.1).

KEY OPERATIVE LEARNING POINTS

1. Stenosis of the tracheostoma is a potential complication of total laryngectomy despite the type of closure performed at the initial creation of the stoma.
2. The goals of surgery are to eliminate circular forces of contracture and allow for healing by primary intention.
3. Care must be exercised if patient has received, or is planning on receiving, radiation therapy to the stoma site; however, previous radiation therapy does not preclude revision of the tracheostoma, provided the stoma was not included in the radiation portal.

PREOPERATIVE PERIOD

History

1. The patient may present with any or all of the following symptoms:
   a. Increasing shortness of breath at rest or with exercise
   b. Inability to clear tracheal secretions
   c. Recurrent pulmonary infections
   d. Inability to properly use a tracheoesophageal puncture speech prosthesis
2. Patient history
   a. Timing of laryngectomy to onset of symptoms
      1) Stenosis typically occurs in the first several months after surgery, although it may present years later.
   b. Extent of primary surgery
      1) Extensive resection of tracheal rings may lead to excessive tension on the stoma if not carefully designed.
   c. Type of primary closure
   d. Local wound care at home
   e. History of radiation therapy
      1) Radiation involving the stoma increases the risk of stenosis as is seen in patients with subglottic extension of the tumor.
   f. Trial of serial dilation by increasing laryngectomy tube size
3. Risk factors for tracheostomal stenosis
   a. Peristomal recurrence of cancer
   b. Radiation therapy
   c. Wound dehiscence with healing by secondary intention
   d. Inadequate excision of peristomal skin and adipose tissue at the time of initial stomal construction
   e. Devascularization of the trachea
   f. Infection after surgery
   g. Hypertrophic scarring
   h. Diabetes mellitus
   i. Poor nutritional status

Physical Examination

1. Recurrence of cancer must be excluded first as a cause for the above-mentioned symptoms.
   a. This may include careful inspection, imaging, and/or biopsy.
2. Careful note of the diameter of the stoma must be made.
   a. Markedly obese patients may have bulging of tissues into the stoma, resulting in a form of pseudostenosis.
3. Examine surrounding soft tissue for breakdown of skin edges.
4. Palpate for the presence of a high-riding innominate artery.
5. Ensure that the trachea inferior to the concentric scar band is of adequate caliber.

Imaging

1. Imaging is not typically required prior to correction of stenosis of the laryngostoma.

Indications

1. Symptomatic dyspnea at rest or with activity
2. Inability to clear secretions
3. Inability to provide adequate pulmonary toilet
4. Inability to use tracheoesophageal puncture speech prosthesis

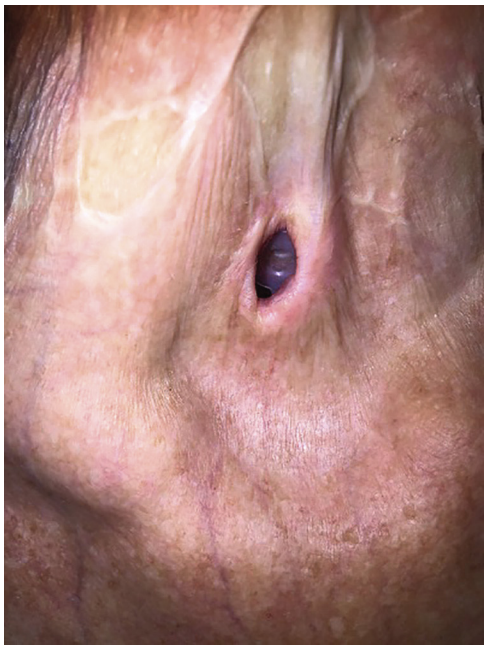

Fig. 24.1. Tracheostomal stenosis.

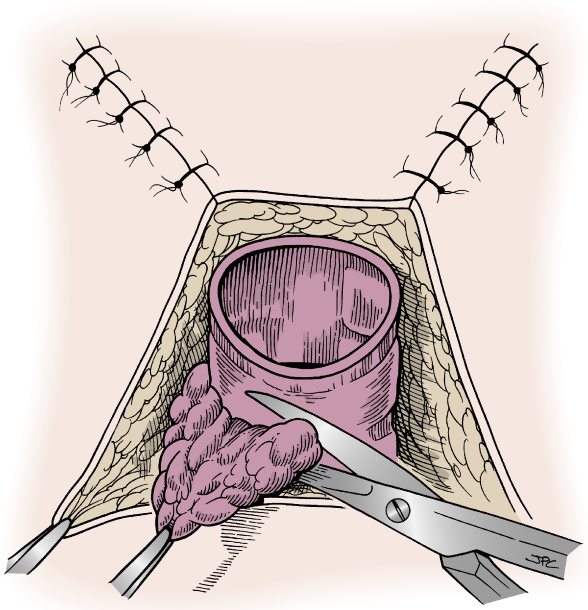

Fig. 24.2. Excision of the peristomal skin and adipose tissue.

Contraindications

1. No absolute contraindications other than severe comorbidities
2. Radiation is a relative contraindication.
   a. Patients who have had radiation therapy in which the radiation portals include the stoma should be treated by nonsurgical means.
   b. Operative repair can still be performed if meticulous technique is used in patients in whom the radiation portals did not include the stoma.

Preoperative Preparation

1. Patients who had a tracheostomy prior to their laryngectomy often develop local inflammatory response and colonization with bacteria in the peristomal skin.
   a. The peristomal skin and a tracheal ring below the stoma should be excised in these patients to prevent postoperative infection.
2. A review of the radiation portals must be undertaken to be sure that the stoma has not been radiated.
3. Careful planning must be undertaken to not damage a preexisting tracheo esophageal puncture (TEP).
4. Imaging is not typically required prior to correction of tracheostomal stenosis.

OPERATIVE PERIOD

Anesthesia

1. Procedure may be undertaken either under local or general anesthesia
2. General anesthesia involves intubation through the tracheostoma, which requires that the surgical and anesthesia teams share the airway.
   a. Communication with the anesthesia team is important as revision of the stoma will require repositioning the endotracheal tube throughout the case.
3. We prefer to carry out this procedure under local anesthesia and intravenous sedation, which provides the surgeon with constant exposure of the field in the absence of the endotracheal tube.

Positioning

1. Patient is placed supine position with a shoulder roll to provide adequate neck extension

Perioperative Antibiotic Prophylaxis

1. First-generation cephalosporin is given preoperatively.

Monitoring

1. No special monitoring is required.

Instruments and Equipment to Have Available

1. General head and neck set

Key Anatomic Landmarks

1. Tracheal rings
2. Manubrium of the sternum

Prerequisite Skills

1. Airway management in a total laryngectomy patient
2. Local flap techniques
3. General soft tissue handling

Operative Risks

1. Airway compromise
2. Bleeding

Surgical Technique

1. An incision is made around the periphery of the tracheostoma, which encompasses any scar tissue present.
2. Clamps are applied to the tissue to be excised and the trachea is pulled up into the wound.
3. The trachea is skeletonized 1 to 2 cm inferior to the stoma.

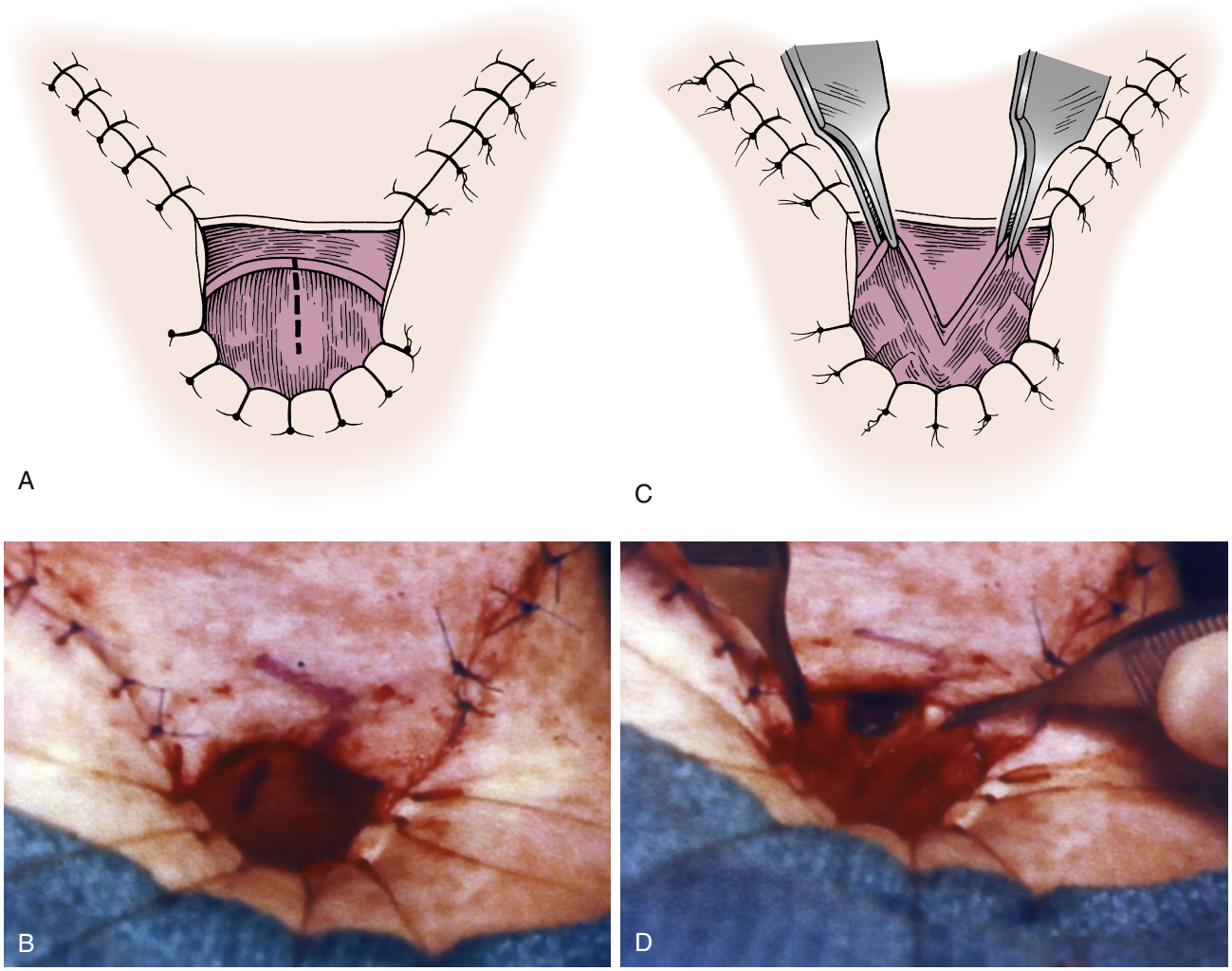

Fig. 24.3. A and **B,** An incision is made in the posterior wall of the trachea. **C** and **D,** The defect is opened.

4. The skin inferior to the tracheostoma and overlying the sternum is undermined approximately 2 to 3 cm.
   a. Excise any excess subcutaneous and adipose tissue.
   b. Remove excess skin to promote some tension on the inferior aspect of the tracheostoma, thus widening the stoma (Fig. 24.2).
5. Completely excise the concentric band of scar tissue, which is typically the primary cause of the stenosis.
6. The skin surrounding the stoma is sutured to the trachea using interrupted 3-0 chromic sutures.
   a. Take particular care to ensure that the skin overlaps any raw edges of the cartilage and is in contact with the tracheal mucosa.
   b. Suturing is carried out inferiorly to 3 and 9 o'clock positions on the tracheostoma.
7. Undermine the skin of the neck surrounding the posterior aspect of the stoma.
   a. Remove any adipose tissue and redundant skin.
8. Make an approximately 1-cm vertical incision in the membranous posterior wall of the trachea, thereby expanding the tracheal lumen (Fig. 24.3).
9. Continue suturing the skin to the trachea.
   a. At this point, the circumference of the tracheostoma has been widened considerably.
10. A small incision is made in the redundant skin posterior to the stoma and a small skin flap is developed (Fig. 24.4).
    a. The flap is transposed, inset, and sewn into the incision in the posterior tracheal wall with 3-0 chromic suture (Fig. 24.5).
    b. This modified Z-plasty breaks up the circle, preventing future stenosis, and is one of the most important aspects of this technique.
    c. If this procedure is carried out at the time of total laryngectomy and a tracheoesophageal puncture is to be performed, the flap should be based inferiorly at the 6 o'clock position and inset into an incision made in the inferior aspect of the trachea through the cartilaginous rings (Fig. 24.6).

Common Errors in Technique

1. Inadequate release or excision of concentric scar band
2. Failure to create a flap to inset into the posterior tracheal wall

POSTOPERATIVE PERIOD

Postoperative Management

1. The patient should keep the peristomal area clean and free of crusts by using hydrogen peroxide on cotton applicators.

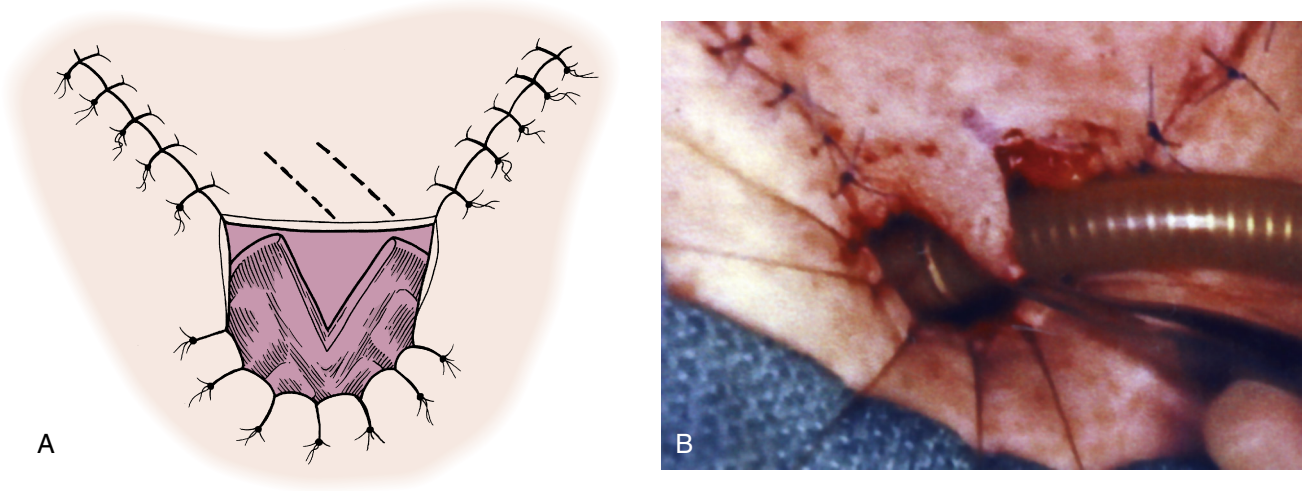

Fig. 24.4. A and B, A flap is formed from redundant skin posterior to the trachea.

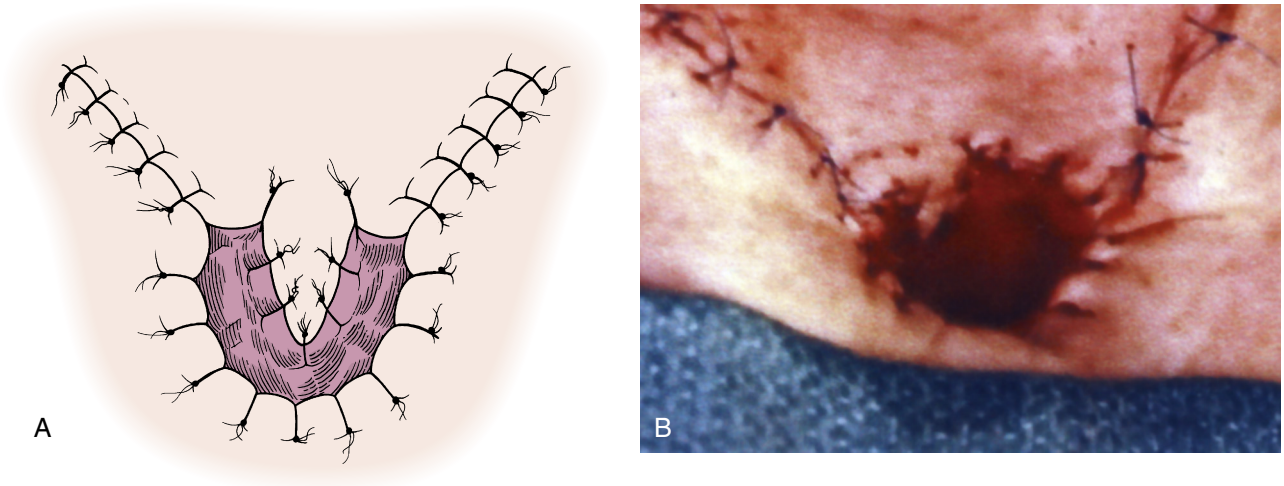

Fig. 24.5. A, The skin flap is transposed into the tracheal incision and inset. **B,** The stomal skin closure is completed.

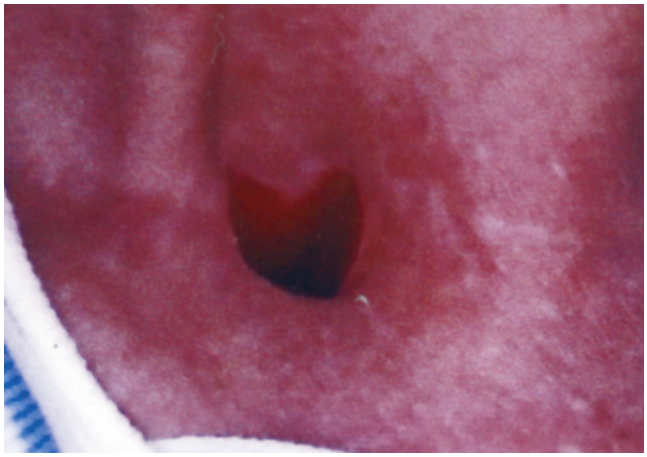

Fig. 24.6. Stomal revision using a superficial-based skin flap.

   a. Following application of hydrogen peroxide every several hours, an antibiotic ointment should be applied to the area.
   b. This is carried out for several weeks until the sutures have been absorbed and the tracheostoma healed.
2. Following complete healing, the patient should wear a laryngectomy tube only at night during sleep and remove it during the remainder of the day.
   a. If there is evidence of shrinkage of the stoma, the laryngectomy tube may be worn for longer periods of time.

Complications

1. Loss of peristomal skin or breakdown
   a. Particularly in patients who have received high-dose radiation in the peristomal area
2. Recurrence of stenosis
3. Peristomal infection

Alternative Management Plan

1. This repair may be performed at the time of total laryngectomy if stenosis is anticipated.
2. Serial dilatation of the trachea by the insertion of increasing-diameter laryngectomy tubes
   a. May be performed in patients with radiation to the peristomal area and at high-risk for peristomal breakdown

DISCUSSION

Evidence-Based Medicine Questions

1. What other techniques have been described to address tracheostomal stenosis after total laryngectomy? (Answer: Many other techniques have been described to address tracheostomal stenosis, including various local flaps, as well as revisions using Z-plasty or V-to-Y plasty. Some techniques, such as described by Giacomarra, combine multiple techniques into one repair to correct the stenosis. This approach combines radial incisions, V-shaped flaps, and interposing flaps to address a patient's tracheostomal stenosis.)
2. What are some different definitions of tracheostomal stenosis? (Answer: Wax et al.[3] define tracheostomal stenosis as a narrowing of the stoma requiring the patient to wear a stent for longer than 3 months after surgery or stenosis requiring revision. Giacomarra et al.[4] define it as presence of respiratory insufficiency at rest or during exercise or if there is difficulty clearing tracheal secretions.)

Editorial Comment

Stenosis of the tracheostoma following total laryngectomy is a vexing and at times a life-threatening problem. There is no completely accepted etiology for this problem, which can occur in the first few months following laryngectomy or years later. The most common site of the stenosis is a concentric scar at the skin-mucosa interface, whereas the remaining trachea is of normal caliber. Less frequently there may be concentric narrowing of the superior aspect of the residual tracheal rings and even less frequently there may be a combination of the two.

The solution to the stenosis should be surgical unless the patients have comorbidities that contraindicate a visit to the operating room or have a history of having radiation to the stomal area. Radiation to the stoma is usually given to patients who are at high risk for stomal recurrence of cancer that is transglottic or subglottic in origin. Glottic or supraglottic cancers have little to no chance for periostomal recurrence. The poor healing associated with a radiated stoma leaves the patient worse off than he or she was in the preoperative period.

The invention of the Blom-Singer valve introduced a potential pitfall in how to treat stomal stenosis in patients who were successful satisfied users of a TEP. If the TEP puncture is a centimeter or more inferior to the mucocutaneous junction in the posterior superior aspect of the stoma, incising the posterior wall of the trachea to insert a flap is not technically possible, although it may be possible to make the incision and insert the flap at the 6 o'clock position.

Eugene N. Myers

Access the review questions and additional sources list online at http://www.expertconsult.com



REFERENCES

1. De Virgilio A, Greco A, Gallo A, et al. Tracheostomal stenosis clinical risk factors in patients who have undergone total laryngectomy and adjuvant radiotherapy. Eur Arch Otorhinolarngol 2013;270:3187–3189.
2. Sweeney L, Golden JB, White HN, et al. Incidence and outcomes of stricture formation postlaryngectomy. Otolaryngol Head Neck Surg 2012;146:395–402.
3. Wax MK, Touma J, Ramadan HH. Tracheostoma stenosis after laryngectomy: incidence and predisposing factors. Otolaryngol Head Neck Surg 1995;113:242–247.
4. Giacomarra V, Russolo M, Tirelli G, et al. Surgical treatment of tracheostomal stenosis. Laryngoscope 2001;111:1281–1284.
5. Bain J. Late complications of tracheostomy and prolonged endotracheal intubation. Int Anesthesiol Clin 1972;10:225–244.

REVIEW QUESTIONS

1. What causes tracheostomal stenosis after total laryngectomy?
   a. Radiation therapy
   b. Hypertrophic scar
   c. Recurrence of tumor
   d. All of the above

2. What is a relative contraindication to this procedure?
   a. Radiation involving the stoma
   b. Radiation not involving the stoma
   c. Diabetes
   d. a and b

3. Which step is critical in preventing recurrence of the stenosis?
   a. Undermining the peristomal skin
   b. Transposition of a skin flap
   c. Vertical incision in the posterior tracheal wall
   d. Covering raw cartilage edges with skin

ADDITIONAL SOURCES

Barbosa JF. Surgical Treatment of Head and Neck Tumors. New York: Grune & Stratton; 1974.

Converse JM. An operation for relief of stenosis of the stoma following total laryngectomy. Arch Otolaryngol 1950;52:950–951.

Montgomery W. Stenosis of tracheostoma. Arch Otolaryngol 1962;75:76–9.

Myers EN, Gallia LJ. Tracheostomal stenosis following total laryngectomy. Ann Otol Rhinol Laryngol 1982;91:450–453.

Trail M, Chambers R, Leonard J. Z-plasty of tracheal stoma at laryngectomy. Arch Otolaryngol 1968;88:110–112.

25 Voice Restoration After Total Laryngectomy

Vikas Mehta

INTRODUCTION

Although nonsurgical methods such as electrolarynx and esophageal speech are available for patients, tracheoesophageal puncture (TEP) is considered the best means of voice restoration after total laryngectomy (TL). A TEP allows a patient to channel air from the lungs through a puncture site in the posterior wall of the trachea, into the esophagus up through the pharynx, where the mucosa acts as a vibrating apparatus and into the oral cavity, where the air is modulated by articulatory mechanisms to produce phonation. TEP has gained in popularity over the past several decades due to the superior speech produced when compared with other methods of communication for laryngectomy patients. Studies in numerous patients who have had a TL reveal that functional indwelling voice prostheses greatly improve the quality of life for the patient, possibly even to a level higher than for those who undergo organ-preservation protocols.[1] Currently, there are several companies that manufacture the prostheses, with InHealth (Carpinteria, CA) making the Blom-Singer device, which is the most widely used in the United States, and Atos Medical (Malmo, Sweden) manufacturing the Provox devices, which are more widely used internationally.

The procedure can be performed either primarily during the TL or secondarily after the patient has healed well, each carrying its own advantages. Primary TEP, performed at the time of the TL, avoids a second operation and allows for more rapid return of phonation. Secondary TEP is often chosen if the patient is considered at high risk for postoperative fistula formation or wound breakdown, which can be complicated by the insertion of an indwelling foreign body into the fistula tract in the newly created stoma. Often, the considerations are multifactorial and depend on the comfort level and guiding practices of the surgeon, speech language pathology (SLP) team, and patient.

Historically, the TEP was performed as a secondary procedure under anesthesia with the insertion of a catheter to establish the tract, followed by the prosthesis being inserted a week or two late, after the fistula had sufficiently matured. However, techniques have evolved, with well-established evidence supporting primary and secondary insertion of the prosthesis immediately at the time of puncture and the ability to perform a secondary puncture in an office setting to avoid anesthesia and save costs. Thus there are few TEP exclusion criteria for TL patients: (1) physical limitations (i.e., stroke, musculoskeletal disorders, amputations) that preclude manipulation and covering the stoma during phonation, (2) financial considerations with reimbursement and care/maintenance of the prosthesis, (3) access to an speech language pathologist (SLP) who is comfortable with TEP voicing instruction, teaching care for the puncture site, and replacing the prosthesis, and (4) need for concomitant total glossectomy. The author believes that TEP should be offered to all TL patients who do not meet the exclusion criteria because voice restoration with TEP is superior to both electrolarynx and esophageal speech and can dramatically improve the TL patient's quality of life (QOL), function, and psychosocial well-being.

KEY OPERATIVE LEARNING POINTS

- TEP can be done primarily or secondarily.
  - The primary approach is preferred if the patient is undergoing primary surgical management for advanced-stage cancer.
  - Secondary can be used if there are concerns for healing in patients who have had radiation therapy to the neck.
- Insertion of the prosthesis at the time of puncture allows for immediate voicing and avoids the possible dislodgement of the catheter used to keep the fistula patent.
- SLP consultation is essential to achieving and sustaining functional phonation with the TEP.
- Direct visualization of the puncture or placement of a pharyngeal protector is important for avoiding inadvertent violation of the posterior esophageal wall.

PREOPERATIVE PERIOD

TEP was traditionally performed as a secondary procedure after the patient had healed from the TL because of concern for increased fistula formation and wound breakdown with a primary puncture. Healing issues are especially prevalent in the salvage setting, where pharyngocutaneous fistula rates can be as high as 33%.[2] However, recent data suggest that the placement of vascularized tissue as part of the pharyngeal reconstruction can reduce fistula formation.[3] More current studies have suggested there are not increased complications with primary TEP placement, regardless of whether the surgery is being performed primarily or in a salvage setting[4,5] and that TEPs can be used and are still effective when microvascular tissue or rotational flap reconstructions are used.[6] However, if the surgeon and his or her team are more comfortable with secondary placement, the procedure can easily be performed in the operating room or office, depending on the availability of equipment, anesthetic risk due to medical comorbidities, and patient financial/travel constraints. For the office setting, a transnasal esophagoscope (TNE) is an absolute requirement to obtain adequate visualization via insufflation. To perform the procedure in the operating room, the patient must be able to tolerate general anesthesia from a cardiopulmonary standpoint.

The first step in decision making should involve an assessment by both the surgeon and the SLP regarding the patient's candidacy. If the patient will be unable to care for and/or use his or her prosthesis due to physical or financial limitations, a TEP should not be undertaken. Although the need for using the thumb to occlude the stoma can be avoided with a secondary valve that covers the stoma, the patient needs to have the ability to adequately clean and care for his or her prosthesis and stoma. The procedure does carry a minimal chance of significant complications, including the risk of aspiration and death from an enlarging, nonhealing fistula and should be avoided if the patient is not a good candidate. Although changing prostheses can be done by either the surgeon or the SLP, having an SLP who is trained in working with TEPs and TL patients is tantamount to achieving phonation. Before the TL itself, having the SLP meet with the patient and discuss what is involved

with using and maintaining the prosthesis is essential for obtaining informed consent. In addition, showing patients pictures and a video helps to establish realistic expectations and eases anxiety about having the larynx removed.

The next step is to decide whether a primary or secondary puncture will be performed. I prefer to perform primary TEP insertion for all TL patients and strongly supports using this approach when a primary TL is being done, as opposed to the salvage setting where the decision can be left to surgeon preference. For a secondary puncture, if the patient is at high risk for complication from general anesthesia or has poor access secondary to trismus, poor neck extension, or other anatomic limitations, then an in-office procedure has been demonstrated to be very effective. If the surgeon does not have a TNE scope available or the patient cannot tolerate the in-office procedure due to anxiety, then performing the procedure in the operating room (OR) can be undertaken. I prefer to place the actual prosthesis at the time of the puncture, regardless of whether in the primary or secondary setting, because this decreases the risk of dislodgement and need for a repeat procedure.

History

1. History of present illness
   a. Interest in obtaining TEP
   b. If secondary TEP, time since laryngectomy and additional procedures performed at the time of surgery (i.e., free flap or rotational flap reconstruction, cricopharyngeal myotomy, glossectomy, pharyngectomy)
   c. Preference regarding in-office versus operating room
   d. Reasonable expectations regarding phonation
   e. Dysphagia
   f. Prior use of electrolarynx or esophageal speech
   g. History of pharyngocutaneous fistula after laryngectomy
2. Past medical history
   a. Previous neck surgery
   b. Previous radiation to the head and neck
   c. Prior esophageal disease
   d. History of severe gastroesophageal reflux disease
3. Medical illness
   a. Cardiopulmonary disease precluding general anesthesia
4. Medications
   a. Anticoagulants
   b. Alcohol (risk of perioperative alcohol withdrawal syndrome)
   c. Allergies to antibiotics
5. Mental and social status
   a. Ability to give informed consent and care for the prosthesis
   b. Financial ability/health insurance status to pay for supplies and replacement prostheses

Physical Examination

1. Primary TEP
   a. Determine primary site and extent of the tumor
      1) Larynx
         a) Extension to subglottis and/or trachea
         b) Extension into pharynx that may require extensive reconstruction
         c) Involvement of the base of the tongue that may require sacrifice of one or both hypoglossal nerves
      2) Trachea
         a) If there has been a prior tracheostomy, need to identify where the tracheostomy was placed to determine adequate length and to plan for stomal placement
      3) Cranial nerve function
2. Secondary TEP
   a. Stoma
      1) Adequate size and patency for placing, changing, and cleaning TEP
      2) Ability to perform digital occlusion of the stoma
      3) Wound healing from laryngectomy
      4) Presence of additional soft tissue from reconstructive procedures that may make digital occlusion challenging
   b. Examination of the head and neck
      1) Perform a transnasal esophagoscopy if in-office secondary TEP being considered
      2) Trismus and neck extension if secondary TEP being considered
3. General health
   a. Nutrition
   b. Cardiovascular
   c. Respiratory
   d. Mental—ability to use and maintain the TEP is key to the success of the procedure

Imaging

1. Chest radiograph
   a. Metastases
   b. Synchronous lung cancer
   c. Pulmonary and cardiac status
2. Computed tomography (CT) scan of the neck with contrast
   a. Only in the setting of primary TEP to determine the extent of the laryngeal cancer
3. Modified barium swallow study
   a. With concurrent dysphagia, rule out cricopharyngeal dysfunction

Indications

- Primary TL for advanced stage laryngeal cancer
- History of TL for secondary TEP

Contraindications

1. Patient factors
   a. Physical limitations (i.e., stroke, musculoskeletal disorders especially advanced rheumatoid arthritis, amputations of digits) that preclude manipulation and occluding the stoma during phonation
   b. Mental limitations that will prevent informed consent and/or impair the use and care of the TEP
   c. Financial limitations that will prevent the patient from obtaining new prostheses/supplies or attending scheduled appointments
   d. Secondary TEP in the OR may not be possible due to severe trismus or limited extension of the neck.
   e. Significant stenosis of the neopharynx
2. Tumor factors
   a. Surgery will require total glossectomy in addition to TL because understandable speech will not be produced.
   b. Gastric pull-up required
3. Surgical factors
   a. In-office TEP requires the use of a TNE.

Preoperative Preparation

1. Evaluations by
   a. Surgeon
   b. SLP
   c. Anesthesiologist (if the procedure is done in the OR)
2. Discontinue antiplatelet drugs if possible.

OPERATIVE PERIOD

Primary Tracheoesophageal Puncture

Anesthesia

- General anesthesia will be used for a TL.
- For further specification, please refer to the TL chapter.

Positioning

- See TL chapter.

Perioperative Antibiotic Prophylaxis

- See TL chapter.

Monitoring

- Routine anesthesia monitoring

Instruments and Equipment to Have Available

- Various insertion kits are available (Fig. 25.1).
  - Puncture needle with catheter
  - Guidewire
  - Prosthesis—16 French, 10 mm in length
  - 2-0 silk suture
  - Pharyngeal protector if available

Key Anatomic Landmarks

- Trachea—puncture site should be approximately 5 mm to 1 cm below the superior portion of the tracheostoma
- Esophagus
- Cricopharyngeal muscle

Operative Risks

- False passage
- Injury to cervical esophagus
- Placing the TEP too close to the superior edge of the stoma

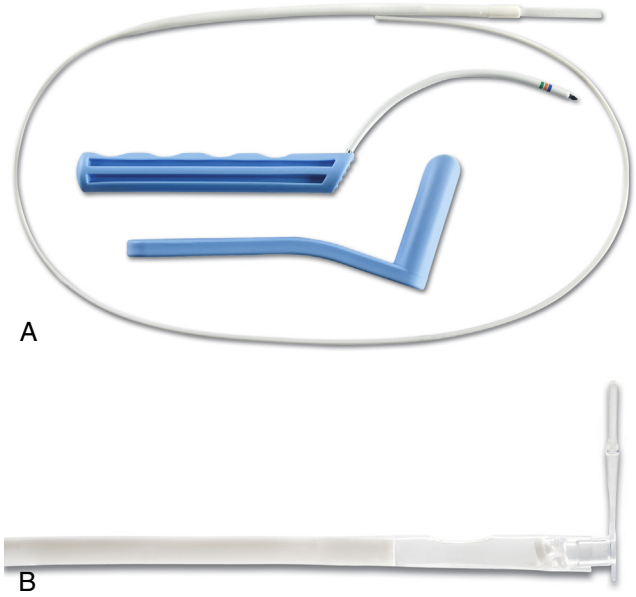

Fig. 25.1. A, The contents of a typical insertion kit are displayed. **B,** the prosthesis is loaded and ready for deployment.

Prerequisite Skills

- TL

Surgical Technique

- After TL and neck dissections have been performed but before neopharyngeal closure (Fig. 25.2).
- Insert nasogastric feeding tube if patient does not have a gastrostomy tube.
- Identify the cricopharyngeal muscle on the upper esophageal inlet, and transect the muscle with a #15 blade in several places, taking care not to violate the esophageal mucosa.
- Secure the prosthesis to the guidewire either by suture or use the prefabricated mechanism provided with the kit. If the guidewire is attached to a feeding tube, it will need to be cut about midway up the feeding tube, and the prosthesis is sutured to the feeding tube in two points to ensure that it is secured to the tube.
- Place the pharyngeal protector or an instrument within the esophagus from the opened pharynx.
- Puncture the trachea approximately 0.5 to 1 cm below the superior edge and pass through the party wall, taking care to not enter the posterior esophageal wall.
- Remove the needle, leaving the catheter in place within the puncture site.
- Pass the guidewire through the catheter from the pharyngeal side into the esophagus and then out the tracheal side of the puncture.
- Gently tease the phalange of the prosthesis out on the tracheal side of the puncture, taking care to not pull the entire prosthesis through.
- Confirm that the prosthesis phalanges are present on the esophageal side by either visualization or palpation.

Common Errors in Technique

- Failure to transect the cricopharyngeus muscle
- Pulling too hard on the guidewire and accidentally pulling the prosthesis all the way through
- Improperly securing the prosthesis
- Passing the guidewire from the wrong side
- Puncturing the posterior wall of the esophagus
- Placing the TEP either too close to the superior edge of the stoma or too deep within the trachea impairing the function or making the prosthesis difficult to access for maintenance and changing purposes

Secondary Tracheoesophageal Puncture in the Operating Room

Anesthesia

- General anesthesia is given (Fig. 25.3).
- The anesthesiologist should be advised that the endotracheal tube will periodically be removed during the procedure.

Positioning

- The bed can be turned 90 or 180 degrees from the anesthesia cart, facilitating access to the patient's mouth and keeping the anesthesia tubing out of the way.

Perioperative Antibiotic Prophylaxis

- None necessary

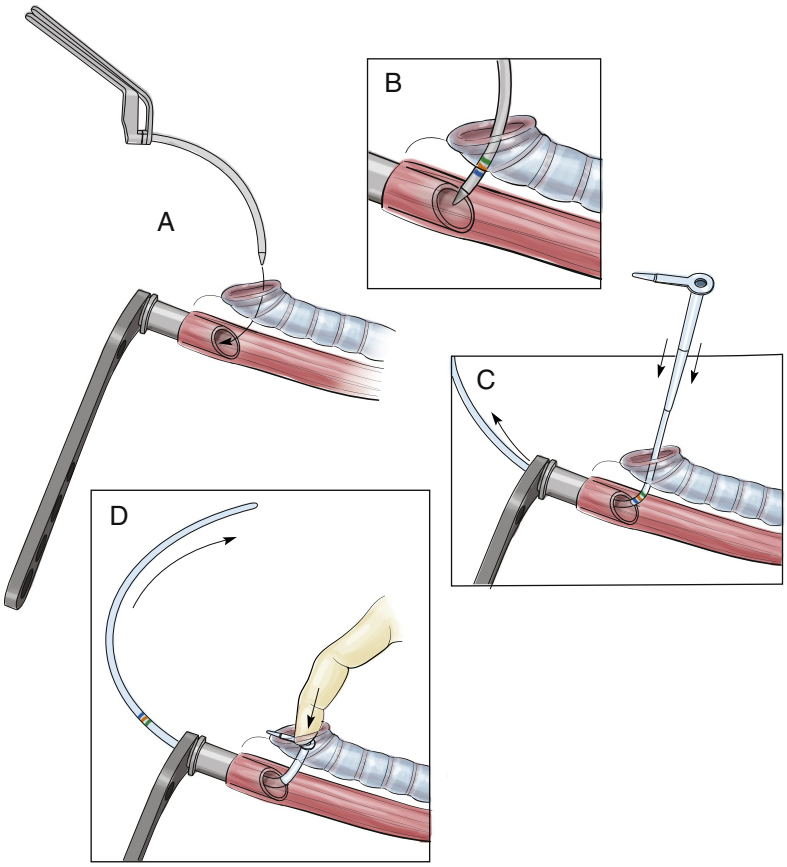

Fig. 25.2. Drawings demonstrating the steps of a primary insertion. A, Pharyngeal protector is placed inside the upper esophagus, and the needle/catheter is inserted from the trachea into the esophagus/pharyngeal protector. **B,** The colored bands help determine the width of the party wall and can guide in selecting the size of the prosthesis. Typically, 16-Fr 10 mm is chosen in the primary tracheoesophageal puncture setting. **C,** The prosthesis is loaded onto the guidewire. The needle is withdrawn, and the wire is passed into the catheter. **D,** The prosthesis is deployed within the puncture site.

Monitoring

- Routine anesthesia monitoring
- The patient can be paralyzed if necessary to gain access.

Instruments and Equipment to Have Available

- Rigid esophagoscope of sufficient length to reach the stoma
- Long grasper capable of extending beyond the length of the esophagoscope
- Tooth guard
- Puncture kit
  - Puncture needle with catheter
  - Guidewire
  - Prosthesis—16 French, 10 mm in length
  - 2-0 silk suture

Key Anatomic Landmarks

- Esophageal inlet
- Stoma

Prerequisite Skills

- Rigid esophagoscopy

Surgical Technique

- Place the tooth guard on the maxillary dentition, or if the patient is edentulous place a moistened sponge on the upper alveolar ridge.
- Introduce the rigid esophagoscope into the patient's mouth, with the bevel facing down, and advance it until the assistant sees the light and/or palpates the scope at the level of the stoma.
- Turn the bevel of the esophagoscope so that the bevel faces up to allow the longer end of the scope to protect the posterior wall of the esophagus.
- Have the assistant palpate the esophagoscope from the trachea and place pressure at the spot where he or she will place the TEP. The surgeon at the head of the OR table should be able to view the spot where the TEP will be placed through the esophagoscope.
- The assistant then places a needle with the catheter through the back of the tracheal wall, approximately 0.5 to 1 cm below the superior edge of the stoma.
- The surgeon will visualize the needle entering the esophageal mucosa and will direct the assistant to advance into the lumen of the esophagoscope.
- The assistant then withdraws the needle, leaving the catheter in place. The guidewire is then passed through the catheter, and the surgeon visualizes it coming into the esophagoscope.
- The surgeon then grasps the wire and pulls it out through the mouth.
- If the kit used has a mechanism in place for attaching the prosthesis to the guidewire, it can be deployed into the puncture site from the tracheal side.
- If the kit used simply has a feeding tube attached the wire, the wire is cut off the feeding tube outside the mouth, and the prosthesis is secured to the tube using a 2-0 silk suture at two points and then placed from the esophageal side with the phalanges gently teased out of the tracheal side, as with the primary TEP.
- Placement is confirmed by direct visualization of the prosthesis.

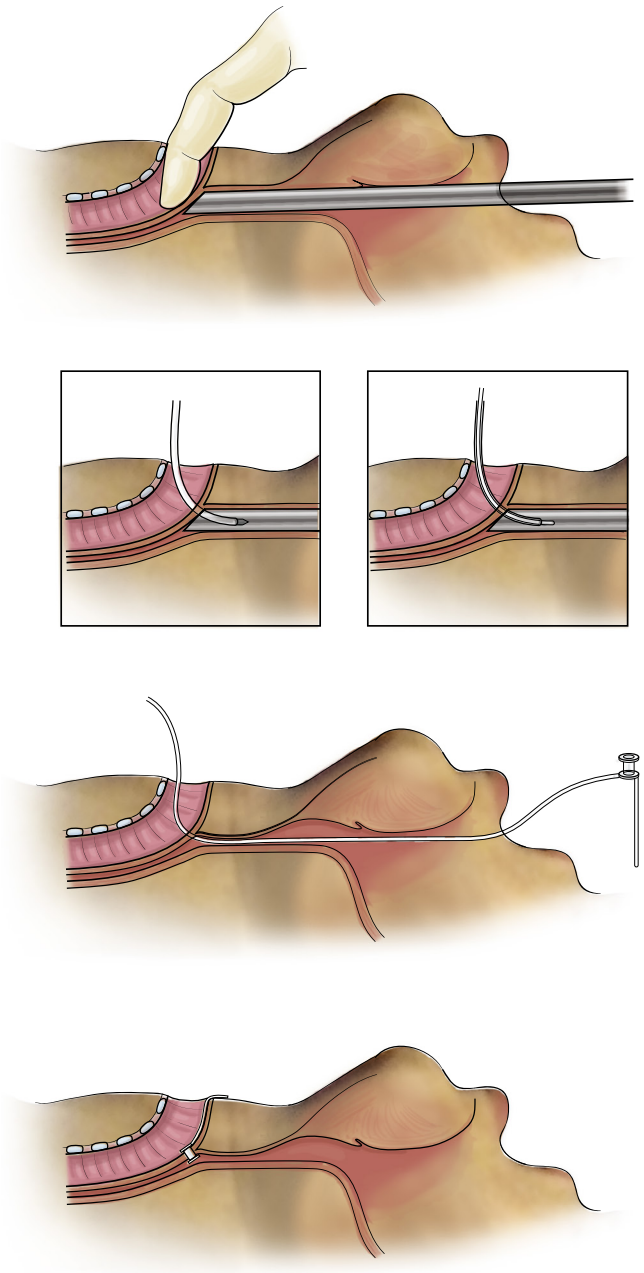

Fig. 25.3. Figure depicting the insertion of the esophagoscope and introduction of the needle into the esophagoscope. The steps of insertion are then similar to the primary technique.

Common Errors in Technique

- Failure to visualize the potential spot of placement prior to introduction
- Accidentally withdrawing the catheter with the needle creating a fistula
- Injuring the posterior wall of the esophagus

Secondary Tracheoesophageal Puncture (In-Office)

Anesthesia

- The nasal cavity is anesthetized and decongested with topical 4% lidocaine and 1% neosynephrine (Fig. 25.4).
- The tracheostoma is also sprayed with topical 4% lidocaine solution.
- Less than 1 mL of 1% lidocaine with 1:100,000 parts epinephrine is injected into the posterior wall of the trachea at the proposed puncture site.
- Five milliliters of viscous 2% lidocaine is also applied to the base of the tongue for several minutes and then swallowed by the patient. Nebulized lidocaine can also be used if available.

Positioning

- The surgery is performed with the patient sitting in the examination chair.

Perioperative Antibiotic Prophylaxis

- Not indicated

Monitoring

- Not indicated

Instruments and Equipment to Have Available

- TNE
- 22-gauge needle
- A scalpel with a #11 blade
- Hemostat
- 18-Fr TEP dilator
- Prosthesis sizer
- Standard insertion system present in TEP changing kits

Key Anatomic Landmarks

- Stoma
- Esophageal inlet

Prerequisite Skills

- Transnasal esophagoscopy

Surgical Technique

- After applying the anesthesia as detailed previously, the TNE is passed from the nasopharynx into the cervical esophagus.
- The esophagus is insufflated.
- The 22-gauge needle is placed through the proposed puncture site into the esophagus under direct TNE visualization.
- The #11 blade is then used to make a stab incision next to the needle and can be turned 180 degrees to enlarge the opening.
- The hemostat is then passed through the stab incision and spread widely.
- The puncture site is then dilated, and the sizer is used to estimate the appropriate size prosthesis to be placed.
- The voice prosthesis is then placed using the introducer contained within the kit.

Common Errors in Technique

- Failure to properly visualize the puncture site
- Wrong sizing of TEP
- Inadequate topical anesthesia
- Injury to the posterior wall of the esophagus
- Creating a false tract due to poor visualization of the puncture site/instrumentation

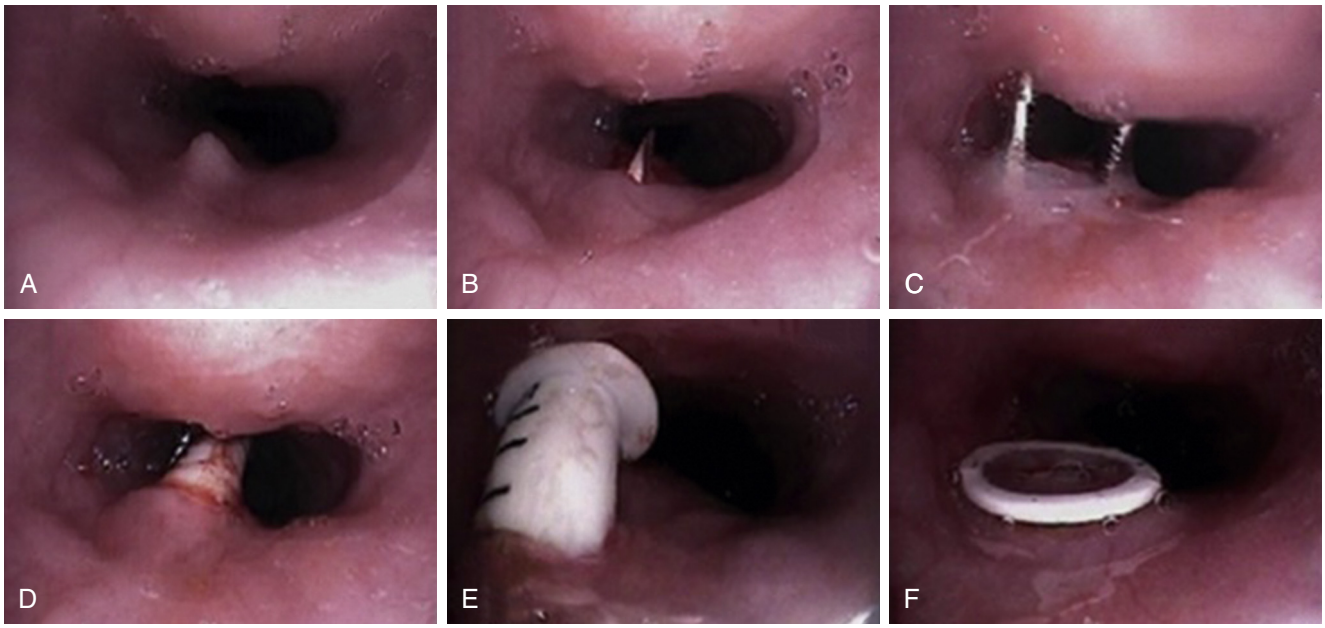

Fig. 25.4. View of surgical steps as seen from the transnasal esophagoscope. A, A 22-gauge needle is placed at proposed tracheoesophageal puncture (TEP) site. **B,** A #11 blade is passed through the party wall into esophageal lumen. **C,** Hemostat is spread widely within puncture site. **D,** 18-French TEP dilator is passed through puncture site. **E,** TEP prosthesis sizer is placed to determine the size of prosthesis. **F,** Prosthesis is placed and visualized.

POSTOPERATIVE PERIOD

- Antibiotics are not indicated for the TEP.
- The patient can be discharged on a regular diet if a secondary TEP is placed.
- The patient may start using the prosthesis immediately if a secondary TEP is placed.
- If primary TEP, I suggest waiting until the wounds are fully matured before attempting speech because the extra pressure can place undue strain on the pharyngeal closure.
- SLP consultation is essential to the success of the TEP and should be used immediately.

Complications

- False tract
- Cricopharyngeal spasm—should be identified preoperatively, if possible, and can be avoided if a cricopharyngeal myotomy is performed at the time of the laryngectomy. If cricopharyngeal dysfunction is noted, it can be addressed with an endoscopic myotomy or an injection of botulinum toxin.
- Enlarging of the fistula tract—occurs in approximately 7% of patients.[7] This can be addressed by inserting a larger prosthesis or injecting collagen into the enlarging area to shrink the fistula tract. Provox tends to make larger prostheses that can be used for this purpose. If this is not possible, the fistula may need to be closed with a rotational or microvascular flap reconstruction. Failure to address a tracheoesophageal fistula can lead to severe aspiration and death.
- Migration of the prosthesis/overgrowth of the mucosa. This can be caused by a contact granuloma on the esophageal or tracheal side and can result in dislodgement of the prosthesis. Careful attention should be paid to any granulomatous changes seen on examination and should be addressed with cauterization/removal.
- Esophageal injury during placement—can lead to mediastinitis
- If the TEP falls out, it may not be replaced in time, resulting in closure of the fistula. Often, if the patient realizes it has been removed within 24 hours, the tract can be dilated and a catheter or prosthesis can be reinserted to establish the fistula tract. However, if the tract closes fully, the patient may require another puncture.
- Occasionally, the TEP dislodges and becomes inhaled into the trachea or bronchial tree, requiring bronchoscopy for removal.

Alternative Management Plan

The patient can learn to use an electrolarynx or esophageal speech. Esophageal speech is difficult to learn and occurs successfully in only a minority of patients. As mentioned previously, TEP speech consistently performs better than the other modalities in terms of function and effect on patient QOL.

DISCUSSION

Evidence-Based Medicine Question

What are the risks and benefits of inserting a TEP at the time of laryngectomy?

Primary TEP is a safe and successful procedure that is generally preferable in patients receiving TL as the initial treatment for cancer of the larynx. Historically, TEP speech-outcome success rates were reported to be greater than 80%, with primary TEP speech-outcome success rate reported as high as 93% to 96% and secondary TEP speech-outcome success rate listed as 78% to 83%.[8,9] More recently, the success rates of TEPs have been overall lower, likely due to the increase in the relative percentage of salvage laryngectomies performed. However, primary TEP still maintains a slightly higher success rate with equivalent complication rates.[5] In larger series, primary TEP has not been shown to increase the rates of pharyngocutaneous fistula,[10] and it has been successful in both the salvage setting[4,5] and when free flap reconstruction is used.[6] The benefits of performing the TEP at the time of the TL are that the patient

avoids a second operation and the patient experiences a more rapid return of phonation.

Editorial Comment

When I was a resident, esophageal speech was the only means of voice restoration following TL. The technique was usually taught by laryngectomies who volunteered their services. Unfortunately, few of the patients learned to speak intelligibly. The study carried out by Dr. George Gates[11] on esophageal speakers indicated that less than 20% of laryngectomies were successful in using esophageal speech to communicate, thereby relegating the remainder of laryngectomy patients to a lifetime of communicating by writing (if they knew how), gesticulating, and using buccal speech, which was not very understandable.

Over the years several forms of vibrating devices, such as the electrolarynx, were developed, which when held against the neck and activated produced relatively understandable speech. A variation on this theme was a device called the "Talking Teeth," which incorporated the vibrating element in an upper denture. The voice was judged to be like Darth Vader and never became popular. The Cooper Rand device used a different mechanism, in which a small tube was inserted into the mouth and, when activated by a handheld device, air was blown into the mouth when the patient was articulating, thereby producing reasonably understandable speech.

It was a real "game changer" for laryngectomies when more than three decades ago Eric Blom, Ph.D., a SLP, and Mark Singer M.D., an otolaryngologist, introduced the voice prosthesis that is known as the Blom-Singer valve.[2] A small hollow tube is introduced through the posterior wall of the trachea and into the cervical esophagus after the larynx has been removed. By occluding the tracheostoma with the thumb, a voice is produced by pulmonary-driven air, resulting in highly understandable speech and thereby restoring the patient's ability to communicate. The quality of life was remarkably enhanced through this simple mechanism of forcing pulmonary driven air into the mouth through the pharynx. TEP speech consistently performs better than any of the mechanical devices. The importance of the participation of the SPL in this process cannot be overestimated. They provide help in improving articulation and in teaching the patient to be able to install the valve him or herself.

Blom and Singer originally described this procedure as a secondary one, performed several months after the laryngectomy wound had healed. In my practice, I followed this same scheme until a patient was referred to me for a laryngectomy, and when I described the benefit of having the second operation to install the TEP he said, "Dr. Myers, my wife is an invalid and I'm the sole source of her care and I need my voice right away when I go home so why can't you just put the valve in when you take out my voice box?" I could not think of any reason why I could not, so I did successfully, and the primary TEP was born. The obvious benefits of the primary TEP are that it avoids a second operation, and it provides the patient with a rapid return of his or her ability to communicate vocally.

Eugene N. Myers

REFERENCES

1. Tang CG, Sinclair CF. Voice restoration after total laryngectomy. Otolaryngol Clin North Am 2015;48:687–702.
2. Weber RS, Berkey BA, Forastiere A, et al. Outcome of salvage total laryngectomy following organ preservation therapy: The Radiation Therapy Oncology Group Trial 91-11. Arch Otolaryngol Head Neck Surg 2003;129:44–49.
3. Withrow KP, Rosenthal EL, Gourin CG, et al. Free tissue transfer to manage salvage laryngectomy defects after organ preservation failure. Laryngoscope 2007;117:781–784.
4. Johnson A, Grammer T, Medina J. Primary tracheoesophageal puncture in salvage laryngectomy patients. Laryngoscope 2013;123:1227–1230.
5. Moon S, Raffa F, Ojo R, et al. Changing trends of speech outcomes after total laryngectomy in the 21st century: a single-center study. Laryngoscope 2014;124:2508–2512.
6. Sinclair CF, Rosenthal EL, McColloch NL, et al. Primary versus delayed tracheoesophageal puncture for laryngopharyngectomy with free flap reconstruction. Laryngoscope 2011;121:1436–1440.
7. Hutcheson KA, Lewin JS, Sturgis EM, et al. Enlarged tracheoesophageal puncture after total laryngectomy: a systematic review and meta-analysis. Head Neck 2011;33:20–30.
8. Chone CT, Gripp FM, Spina AL, et al. Primary versus secondary tracheoesophageal puncture for speech rehabilitation in total laryngectomy: long-term results with indwelling voice prosthesis. Otolaryngol Head Neck Surg 2005;133:89–93.
9. Kao WW, Mohr RM, Kimmel CA, et al. The outcome and techniques of primary and secondary tracheoesophageal puncture. Arch Otolaryngol Head Neck Surg 1994;120:301–307.
10. Dowthwaite SA, Penhearow J, Szeto C, et al. Postlaryngectomy pharyngocutaneous fistula: determining the risk of preoperative tracheostomy and primary tracheoesophageal puncture. J Otolaryngol Head Neck Surg 2012;41:169–175.
11. Gates G, Ryan W, Cantu E, Hearne E: Current status of laryngectomee rehabilitation: II. causes of failure. Am Jour Otolaryn. 1982; 3(1):8-14.
12. Blom ED, Singer MI, Hamaker RC. Laryngectomy with preservation of voice. In Fried MP, editor. The Larynx, A Multidisciplinary Approach. Boston: Little Brown and Company; 1988..

Access the review questions online at http://www.expertconsult.com

REVIEW QUESTIONS

1. Which of the following methods of voice restoration would be best for a patient who has a history of a total laryngectomy (TL) for advanced laryngeal cancer with a mouth opening of 2.5 cm?
   a. Secondary TEP in the OR
   b. Secondary TEP in-office
   c. Electrolarynx
   d. Esophageal speech

2. All of the following are contraindications to performing a tracheo-esophageal puncture (TEP), except
   a. Partial pharyngectomy requiring free flap reconstruction
   b. History of stroke with poor upper limb function/strength
   c. Total glossectomy
   d. History of severe schizophrenia preventing care of the prosthesis

3. All of the following are complications of performing a TEP, except
   a. Enlarging tract causing aspiration
   b. Posterior esophageal wall injury leading to mediastinitis
   c. Tumor seeding of the esophagus
   d. Overgrowth of the esophageal mucosa preventing phonation

26 Closure of the Tracheoesophageal Fistula Site

Phillip Huyett, Eugene N. Myers

INTRODUCTION

Speech restoration is of great significance for the social and economic welfare of patients who undergo total laryngectomy.[1] As outlined in Chapter 75, Voice Restoration After Total Laryngectomy, speech restoration is most often accomplished with the use of the electrolarynx or by placement of a primary or secondary tracheoesophageal puncture (TEP), allowing for esophageal speech. More than 80% of patients with a TEP develop intelligible speech and voice restoration with a TEP, and is of superior quality to that of the electrolarynx.[2-4] Although most patients do well with their tracheoesophageal speech, there are certain problems associated with the valve[5-7]:

- Poorly fitting valve leading to frequent displacement
- Spontaneous closure of the fistula following loss of the valve
- Aspiration of the valve into the tracheobronchial tree
- Leakage of saliva and food into the tracheobronchial tree
- Aspiration pneumonia from severe leakage, which could be life threatening in patients with pre-existing chronic lung disease
- Yeast infection of the valve[8]
- Lack of patient acceptance of the valve

Many of these problems can be successfully managed with medical therapy, adjustment of the prosthesis itself, or by narrowing the tracheoesophageal fistula with injectable materials. In the minority of patients, the decision is made to remove the TEP due to continued complications related to the valve or fistula or simply patient preference. Given that a well-formed tracheoesophageal fistula is epithelialized circumferentially, the tract does not necessarily close spontaneously after prosthesis removal, especially when the fistula is large or in the patient who has been radiated, is malnourished, or continues to smoke heavily. This chapter describes the technique for definitive closure of the fistula after valve removal.

KEY OPERATIVE LEARNING POINTS

- Conservative measures of closure for salivary leakage such as TEP site injections and size adjustments of the prosthesis should be tried before definitive surgical closure.
- Efforts to improve swallowing and voicing by pharyngoesophageal dilation, cricopharyngeus myotomy, or Botox treatment should be exhausted before closing the TEP in patients who are dissatisfied with their voice or swallowing ability.
- Patients need to be counseled about alternative methods of communication such as the electrolarynx and esophageal speech.

PREOPERATIVE PERIOD

History

History of Present Illness

- The patient who has had a total laryngectomy generally has long-term care with the head and neck surgeon and speech language pathologist.
- The patient will often present in follow-up with speech or swallowing problems, a prosthesis that repeatedly becomes dislodged, or a history of recurrent aspiration pneumonias.

Past Medical History

- Past medical history
  - Prior interventions for improvement of speech, swallowing, and leakage
  - Serious comorbidities
- Cancer treatment history
  - Date of total laryngectomy and TEP placement
  - Use of radiation therapy before or after total laryngectomy
- Social history
  - Continued alcohol and tobacco use
  - Assess voice use goals in social and professional settings.
- Medications
  - Use of anticoagulants
  - Use of herbal products

Physical Examination

- A complete examination of the head and neck is performed to rule out peristomal recurrence or second primary malignancies as a cause for TEP site complications.
- Evaluation of the fit of the TEP, often performed in conjunction with the speech language pathologist
- Evaluate the size of the laryngectomy stoma and the relative location of the TEP.
- Assess the quality of the peristomal tissues, especially in the radiated patient.

Imaging/Diagnostics

- No imaging is indicated if the patient is undergoing closure of the tracheoesophageal fistula for leakage.
- A fluoroscopic evaluation of the pharynx and esophagus may be useful in evaluation of the total laryngectomy patient with difficulty voicing and/or swallowing.

Indications

- The absolute indication for closure of the TEP is severe leakage with aspiration. Most salivary leakage responds to conservative measures such as reduction in the size of the valve to allow shrinkage of the fistulous tract. Cauterization of the fistula has also been used to promote shrinkage of the tract.[9]
- Another indication for surgical closure of a TEP is poor voicing refractory to optimal teaching, therapy, and treatment of underlying etiologies. Poor voicing may be caused by spasm of the cricopharyngeus muscle or pharyngeal stenosis. Treatment for these conditions includes Botox injection of the cricopharyngeus muscle, cricopharyngeal myotomy, cervical neurectomy, dilation, and pharyngoplasty (Chapter 54).
- We have also encountered a few patients who have none of the previously listed problems but simply wanted the fistula closed because they either did not like the idea of a fistula and the valve or just did not like the quality of their voice.

- We have been doing primary TEPs at the time of total laryngectomy since shortly after the introduction of the Singer-Blom valve. We try to carefully select patients who we feel would not succeed with a Singer-Blom valve, such as those who have poor manual dexterity (e.g., rheumatoid arthritis), low level of motivation, chronic neurologic syndrome, and inability to maintain the prosthesis.

Contraindications

- Proceeding to closure of the TEP without prior attempts to troubleshoot leakage, speech, and swallowing problems more conservatively. Patients whose stoma has been heavily radiated

Preoperative Preparation

- Patients who are candidates for closure of the TEP should be counseled by the speech language pathologist about the use of alternative methods of communication, such as the electrolarynx or esophageal speech.
- If the stoma is quite small, then stomaplasty should be included at the time of the closure of the TEP. The technique of stomaplasty, which includes creation of a small local flap in the superior aspect of the stoma, is described in Chapter 83.[10] If the size of the fistula is quite large or the TEP is located superiorly near the cutaneous junction, then stomaplasty with a flap is not feasible. Patients who have a stoma that has been heavily radiated present a unique problem. These patients do not tend to do well when stomaplasty is performed and have marked difficulty in healing.

OPERATIVE PERIOD

Anesthesia

- Local anesthesia
- General anesthesia with small flexible endotracheal tube (anode tube)

Positioning

- Supine, shoulder roll to improve visualization
- Prep and drape the neck.

Perioperative Antibiotic Prophylaxis

- No antibiotics are indicated.

Monitoring

- No routine monitoring is indicated.

Instruments and Equipment

- Standard head and neck set

Key Anatomic Landmarks

- Tracheostoma
- Tracheoesophageal party wall
- Tracheoesophageal fistula tract
- Esophagus

Prerequisite Skills

- Total laryngectomy
- TEP (Chapter 25)

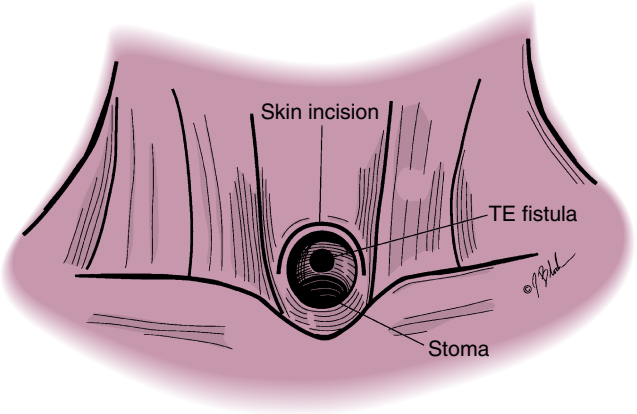

Fig. 26.1. Incision from the 9-o'clock to the 3-o'clock position at the mucocutaneous junction. *(Reprinted with permission from Hosal SA, Myers EN: Closure of tracheoesophageal puncture site. Head Neck 23:215, 2001.)*

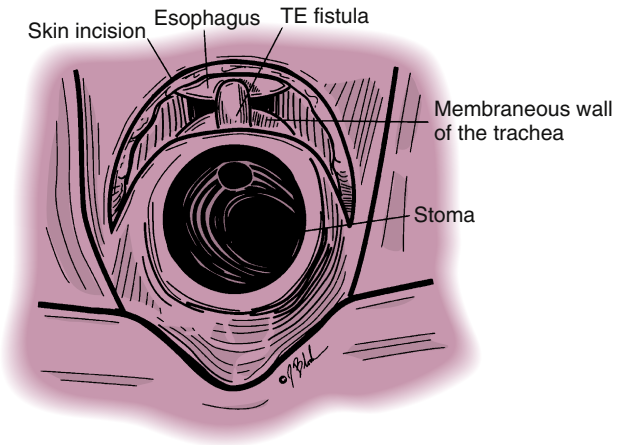

Fig. 26.2. Exposure of the fistula. *(Reprinted with permission from Hosal SA, Myers EN: Closure of tracheoesophageal puncture site. Head Neck 23:215, 2001.)*

Operative Risks

- Failure of closure to heal, especially in the radiated patient

Surgical Technique

- The area that surrounds the superior aspect of the tracheostoma is infiltrated with 1% lidocaine with epinephrine 1:100,000.
- An incision is made in the mucocutaneous junction of the tracheal stoma from the 9-o'clock to the 3-o'clock position (Fig. 26.1).
- The posterior wall of the trachea is undermined inferiorly and separated from the esophagus down to and just beyond the tracheoesophageal fistula (Fig. 26.2).
- The tracheoesophageal tract is divided and the mucosa of the esophagus is closed with inverted interrupted sutures using 4-0 absorbable Vicryl on a P-2 (small circle) lacrimal needle (Figs. 26.3 and 26.4).
- A multiple-layer closure of the esophageal fistula is carried out to prevent leakage.
- Subsequently, the mucosa of the tracheal lumen is freshened and closed with everted sutures in a single layer with

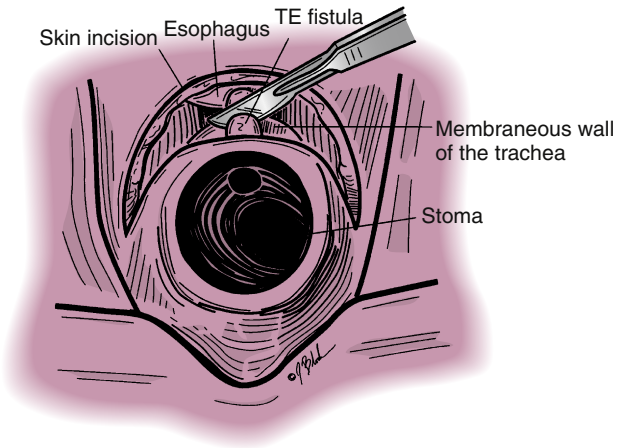

Fig. 26.3. Division of the fistula. *(Reprinted with permission from Hosal SA, Myers EN: Closure of tracheoesophageal puncture site. Head Neck 23:215, 2001.)*

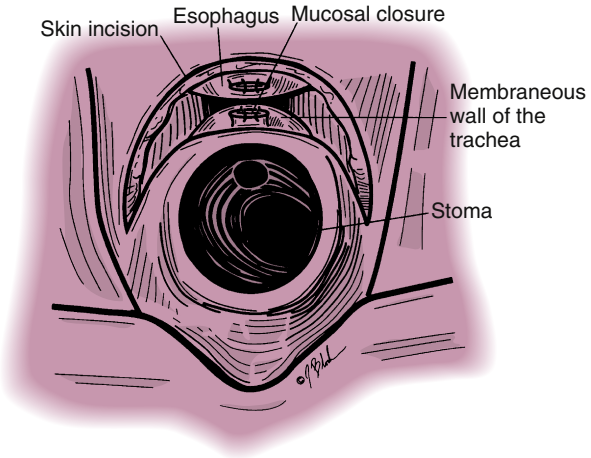

Fig. 26.4. Closure of the tracheal and esophageal mucosa. *(Reprinted with permission from Hosal SA, Myers EN: Closure of tracheoesophageal puncture site. Head Neck 23:215, 2001.)*

the same suture material. After the complete closure, the stomal incision is closed without a drain.

- Rosen et al. describe a technique for closure of TEP, which is performed under general anesthesia with a small flexible endotracheal tube.[1] A 34F dilator is introduced into the esophagus to elevate the tracheoesophageal party wall. A circumferential circular incision is made in the tracheal mucosa 2 to 3 mm lateral to the fistula. The tracheal mucosa is undermined toward the center of the fistula and then inverted into the esophageal lumen and sutured closed. A tracheal mucosal flap is created. A 3- × 3-cm thin dermis graft from the thigh is trimmed to size and sutured in to resurface the trachea.
- Issing et al. followed up on 103 patients with total laryngectomy and voice rehabilitation, three of whom eventually required closure of the TEP because of severe leakage. The authors state that the TEP was closed with muscle skin flaps, but details of the surgical technique were not described.
- Annyas and Escajadillo described a technique in which an interposition dermal graft was placed between the trachea and the esophagus, with separate skin incisions just superior to the stoma.
- Various soft tissue flaps have been described in the closure of a TEP site, including deltopectoral flap, sternocleidomastoid muscle flap, and radial forearm free flap. These techniques are particularly useful in the radiated total laryngectomy patient.

Common Errors in Technique

- Every effort should be made to ensure proper patient selection so that the degree of satisfaction with the valve is as high as possible.
- Patients with only a mild degree of difficulty in voicing may also be dissatisfied with closure because they will have no voice at all.
- Patients who have been heavily radiated to the stoma have a major risk of not healing and may require major reconstructive surgery if this is carried out.
- Patients should not return to a regular diet immediately, because this may disrupt the wound.
- Patients who have been heavily radiated may undergo closure of the TEP fistula, but muscle should be interposed between the trachea and esophagus because the radiation interferes with healing and an even larger fistula may be produced. This unfortunate complication would require major reconstructive surgery.

POSTOPERATIVE PERIOD

Postoperative Management

- The patients are usually discharged the day of the surgery.
- The patient is encouraged to keep the area of the stoma clean and apply antibiotic ointment to the incision.
- The patient is encouraged to eat a puréed diet for 1 week and then progress to a normal diet over the next few weeks.

Complications

- Failure of tracheoesophageal fistula closure

Alternative Management Plan

- The TEP site can be temporarily closed with the placement of a septal button. This will simulate aphonia for the patient, but in the long term the epithelialized tract is maintained and may lead to continued problems.

DISCUSSION

Evidence-Based Medicine Question

What is the incidence of enlarging TEP site following total laryngectomy and TEP placement?

A systematic review conducted by Hutcheson and co-authors (5) in 2011 found the mean incidence of TEP site enlargement after total laryngectomy and TEP to be 7.2% (range 1-29% across 23 primary articles). TEP diameter and timing of the TEP were not found to be statistically predictive of TEP site enlargement. The use of radiation therapy was not reported consistently in the articles reviewed which ranged from 1978 to 2008. In the same year, the MD Anderson group published their 5-year experience and found that 18.6% of patients (36/194) had enlargement of the TEP site (6). The most common resulting complications were pneumonia and aspiration of the TEP device. Two patients eventually required complete TEP site closure, the remainder were managed successfully with conservative measures including upsizing of the prosthesis, TEP site injection or temporary device removal.

Editorial Comment

Eric Blom and Mark Singer introduced the "Surgical Prosthetic Approach for Post-Laryngectomy Voice Resto ration" in 1979 and changed the world for laryngectomy

patients. Prior to this innovation, which requires the establishment of a tracheoesophageal fistula with the insertion of a tiny valve, the patient with a laryngectomy only had the choice of learning esophageal speech or using an electrolarynx. Less than 20% of patients are able to communicate satisfactorily with esophageal speech, and while most could communicate satisfactorily with an electrolarynx, it had the significant downside of the patient having to hold the device in one hand, thereby presenting the problem of being aphonic while working with two hands. The quality of the voice was poor and described by patients as sounding like a robot.

More than 80% of patients using the Singer-Blom valve develop intelligible speech, producing results superior to the electrolarynx in terms of the quality of the voice. However, there are certain problems associated with the valve directly or indirectly and with the tracheoesophageal fistula. These are listed in the introduction to this chapter. Otolaryngologists and speech language pathologists, who work most directly with these patients, have become quite nimble in being able to solve these problems as they arise.

There are a small percentage of patients who for one reason or another no longer want to use the valve. Since the tracheoesophageal fistula is epithelialized circumferentially, it usually does not close spontaneously when the valve is removed. The technique described here was developed by the senior author as a solution to the problem. It is simple and addresses closure of the fistula in a straightforward manner by restoring the normal anatomy of the trachea and esophagus. We have had good results with this technique but offer a word of caution in patients who have had radiation to the stomal area. These cases require bringing in fresh tissue to strengthen the closure in order to avoid tissue necrosis and the creation of a larger fistula.

Eugene N. Myers


Access the review questions and additional sources online at http://www.expertconsult.com

REFERENCES

1. Rosen A, Scher N, Panje WR. Surgical closure of persisting failed tracheoesophageal voice fistula. Ann Otol Rhinol Laryngol 1997;106(9):775–778.
2. Blom ED, Singer MI, Hamaker RC. A prospective study of tracheoesophageal speech. Arch Otolaryngol Head Neck Surg 1986;112(4):440–447.
3. Singer MI, Blom ED, Hamaker RC. Further experience with voice restoration after total laryngectomy. Ann Otol Rhinol Laryngol 1981;90(5 Pt 1):498–502.
4. Wetmore SJ, Johns ME, Baker SR. The Singer-Blom voice restoration procedure. Arch Otolaryngol 1981;107(11):674–676.
5. Hutcheson KA, Lewin JS, Sturgis EM, et al. Enlarged tracheoesophageal puncture after total laryngectomy: a systematic review and meta-analysis. Head Neck 2011;33(1):20–30.
6. Hutcheson KA, Lewin JS, Sturgis EM, et al. Outcomes and adverse events of enlarged tracheoesophageal puncture after total laryngectomy. Laryngoscope 2011;121(7):1455–1461.
7. Jiang N, Kearney A, Damrose EJ. Tracheoesophageal fistula length decreases over time. Eur Arch Otorhinolaryngol 2016; 273(7):1819–1824.
8. Izdebski K, Ross JC, Lee S. Fungal colonization of tracheoesophageal voice prosthesis. Laryngoscope 1987;97(5):594–597.
9. Ward PH, Andrews JC, Mickel RA, et al. Complications of medical and surgical approaches to voice restoration after total laryngectomy. Head Neck Surg 2006;10(S2):124–128.
10. Myers EN, Gallia LJ. Tracheostomal stenosis following total laryngectomy. Ann Otol Rhinol Laryngol 1982;91(4 Pt 1):450–453.

REVIEW QUESTIONS

1. Which of the following is not an appropriate first step in the management of a leaking TEP without evidence of aspiration pneumonia?
   a. Upsizing the TEP device
   b. Injection of calcium hydroxyapatite or micronized Alloderm
   c. Immediate surgical closure of the TEP site
   d. Temporary closure with a septal button

2. What percentage of patients will not achieve satisfactory voicing with a TEP prosthesis in place?
   a. 0%
   b. 20%
   c. 60%
   d. 80%

3. Which of the following is not an appropriate initial option in the management of a patient with a TEP and poor voicing and swallowing?
   a. Injection of Botox to the cricopharyngeus muscle
   b. Pharyngoesophageal dilation
   c. Cricopharyngeus myotomy
   d. Immediate surgical closure of the TEP site

4. Which method of speech rehabilitation following total laryngectomy results in the best voice quality?
   a. Esophageal speech
   b. Tracheoesophageal speech
   c. Esophageal speech
   d. American sign language

ADDITIONAL SOURCES

Annyas AA, Escajadillo JR. Closure of tracheoesophageal fistulas after removal of the voice prosthesis. Laryngoscope 1984;94(9):1244–1245.

Balasubramanian D, Iyer S, Thankappan K. Tracheoesophageal puncture site closure with single perforator-based deltopectoral flap. Head Neck 2013;35(2):E60–63.

Dewey EH, Castro JR, Mojica J, et al. Reconstruction of expanding tracheoesophageal fistulae in post-radiation therapy patients who undergo total laryngectomy with a bipaddled radial forearm free flap: report of 8 cases. Head Neck 2016;38(Suppl. 1):E172–78. http://dx.doi.org/10.1002/hed.23966.

Hosal SA, Myers EN. How I do it: closure of tracheoesophageal puncture site. Head Neck 2001;23(3):214–216.

Issing WJ, Fuchshuber S, Wehner M. Incidence of tracheo-oesophageal fistulas after primary voice rehabilitation with the Provox or the Eska-Herrmann voice prosthesis. Eur Arch Otorhinolaryngol 2001;258(5):240–242.

Jaiswal D, Yadav P, Shankhdhar VK, et al. Tracheoesophageal puncture site closure with sternocleidomastoid musculocutaneous transposition flap. Indian J Plast Surg 2015;48(3):278–282.

Unsal O, Akpinar M, Turk B, et al. Total closure of enlarged tracheoesophageal puncture with septal button: long-term results. ORL J Otorhinolaryngol Relat Spec 2015;77(5):268–272.

Wasano K, Suzuki N, Kawasaki T, et al. Closure of tracheoesophageal puncture with pedicled fascia flap of the sternocleidomastoid muscle. Auris Nasus Larynx 2015;42(4):318–321.

SECTION 5 Oral Cavity

27 Cancer of the Lip

Jeffrey A. Steitz, Paul Tennant

INTRODUCTION

The lip is the most common site of origin for squamous cell carcinoma of the oral cavity. Unlike other cancers of the oral cavity, the etiology and clinical outcomes of squamous cell carcinoma more closely resemble squamous cell carcinoma of the skin. Cancer of the lips accounts for 0.6% of all malignancies diagnosed in the United States. The primary risk factor for cancer of the lip is sun exposure. As with other skin malignancies, fair skin complexion increases the risk for lip cancer. A study of Canadian farmers showed that these sun-exposed workers had a threefold increased risk of cancer of the lip compared with people with indoor occupations after controlling for smoking history. Also implicating the powerful role of sun exposure in development of cancer of the lip is the finding that cancer of the lip is 40 times more prevalent on the external than the inner lip.[1,2]

The risk of cancer of the lip increases with age; the average age at diagnosis is in the sixth decade of life. The lower lip is 12 times more likely to be affected than the upper lip, as it sustains greater exposure to sunlight. Of all cancers of the lip, squamous cell carcinoma represents the vast majority. A large epidemiological analysis revealed that up to 95% of nonmelanoma cancers of the lower lip are squamous cell carcinoma. Basal cell carcinoma, the second most common nonmelanoma cancer of the lip, is more likely to be found on the external upper lip and in females. Other types of cancer occur less commonly on the lip, including malignant melanoma and malignant tumors of minor salivary gland origin, such as adenoid cystic carcinoma and adenocarcinoma.[2]

The role of human papillomavirus in the development of squamous cell carcinoma of the head and neck continues to be clarified, but no evidence has been found to date that implicates this virus as a cause of lip cancer. Immunosuppressed populations are at significantly increased risk for lip cancer. Patients who have undergone kidney transplant have a 30-fold increased risk on account of immunosuppressive antirejection drug regimens. The degree of immunosuppression appears to be important, as patients on higher doses demonstrate a higher risk of skin cancer than patients on low-dose regimens. Patients with HIV infection also have a greater risk for development of lip cancer.[3]

Patients with lip cancers generally present at an early stage, as the location is a cosmetically obvious area. Tumors less than 2 cm in size (T1 stage) account for 75% to 80% of lip cancer diagnoses. The staging guidelines for cancer of the lip follow the guidelines for cancer of the oral cavity. These patients generally do well, and surgical excision is curative. In the current literature, the reported 5-year survival rates in patients with squamous cell cancer of the lip without lymph node metastases are between 85% and 99%. A small number of patients present with more advanced primary cancers, characterized by invasion into deeper structures.

While patients with cancer of the lip without cervical metastasis can expect excellent rates of survival, the prognosis is guarded for patients who have lymph node metastasis; the survival rate for these patients decreases to 25% to 50%. Therefore, identification and management of occult neck metastasis are critical. A number of prognostic factors for lymph node metastasis for squamous cell carcinoma of the lip have previously been reported: tumor size/T-stage, tumor grade, depth of invasion, perineural invasion, extreme mitotic activity, positive surgical margins, commissure involvement, and local recurrence.

Management of the N0 neck is controversial; the recent literature has suggested that "high-risk" patients should receive consideration for management of the regional lymphatic basin. Sentinel lymph node biopsy is a surgical option already widely applied as a tool to assess the at-risk lymph node basin in skin cancer. Its role in treatment of squamous cell carcinoma of the oral cavity is also gaining acceptance. This option is especially attractive in lip cancer, as the primary tumor is readily accessible for injection of radioisotope and small neck incisions minimize interference with reconstructive options for the lip.

A chapter on cancer of the lip is incomplete without addressing reconstructive techniques. Reconstruction of defects of the lip can be complex, especially when resection involves the vermillion border or oral commissure. Reconstructive techniques are used to minimize microstomia, retain oral competence, and optimize the cosmetic result. While reconstruction of the lip can be complex, there are several basic principles to guide the surgeon toward the appropriate technique.[4,5]

- Defects amounting to one-half of the lip can and should be closed primarily.
- Meticulous reapproximation of the vermillion border should be achieved.
- If greater than one-half of the lip is resected, consideration should be given to advancement flaps or "lip-switch" procedures (described later).
- If resection involves the oral commissure, the Estlander flap can be used.
- For larger resections (greater than two-thirds), local tissue rearrangement is possible with the Karapandzic flap; however, consideration should be also given to free tissue transfer techniques.

Surgical technique is described as follows for the aforementioned types of lip reconstruction.

KEY OPERATIVE LEARNING POINTS

1. Discuss ablative techniques for removal of cancer of the lip with consideration of optimal reconstruction.
2. Understand the reconstructive ladder and how it may be used in reconstruction of the lip.

3. For full-thickness reconstruction of the lip involving greater than two-thirds of the lip, consideration of the use of free tissue transfer should also be given.

PREOPERATIVE PERIOD

History

1. History of present illness
   a. Approximate date of onset of lesion
      1) Many patients present early in the course of the disease; a smaller number of patients may present with deep invasion and ulceration present.
   b. Skin changes elsewhere on the face, neck, or body
      1) History of severe sunburns or radiation exposure
      2) History of chronic sun exposure (e.g., farmers)
   c. Numbness/hypesthesia of the lip or chin
2. Past medical history
   a. Medical illness
      1) Medical or immunologic immunosuppression
      2) Prior history of other head and neck malignancy
   b. Surgery
      1) Previous head or neck surgery
         a) Primarily focusing on the lower face and neck
      2) History of organ transplant, especially renal transplants indicating immunosuppression
      3) Any other surgeries that may indicate a patient may be high risk for operative intervention
   c. Family history
      1) Cutaneous malignancies
      2) Coagulopathy
   d. Medications
      1) Anticoagulation with antiplatelet agents or NSAID use
      2) Herbal supplementation
      3) Alcohol use
      4) Immunosuppressive medications

Physical Examination

1. Palpation and examination of the lip lesion
   a. Location
      1) Involvement of the upper or lower lip
      2) Involvement or extension beyond the vermillion border
      3) Involvement of the oral commissure
   b. Characteristics of the lesion
      1) Ulceration
      2) Depth of invasion
         a) Extension into surrounding subcutaneous tissues or muscle
         b) Perineural involvement of the mental nerve may present as hypesthesia/paresthesia of the chin or lower lip
   c. Examination of the neck
      1) Assess for lymphadenopathy in the neck
         a) Upper lip with primary lymphatic drainage patterns to levels Ia and Ib
         b) Lower lip with primary lymphatic drainage patterns to levels Ia, Ib, and jugulodigastric chain
         c) Cancers involving the upper lip or oral commissure are more likely to have lymphatic spread.
         d) Most lymphatic metastases to the neck are isolated to levels I–III (Fig. 27.1).
      2) Any previous surgical incisions

Imaging

None—Routine imaging is not recommended for early stage cancers.

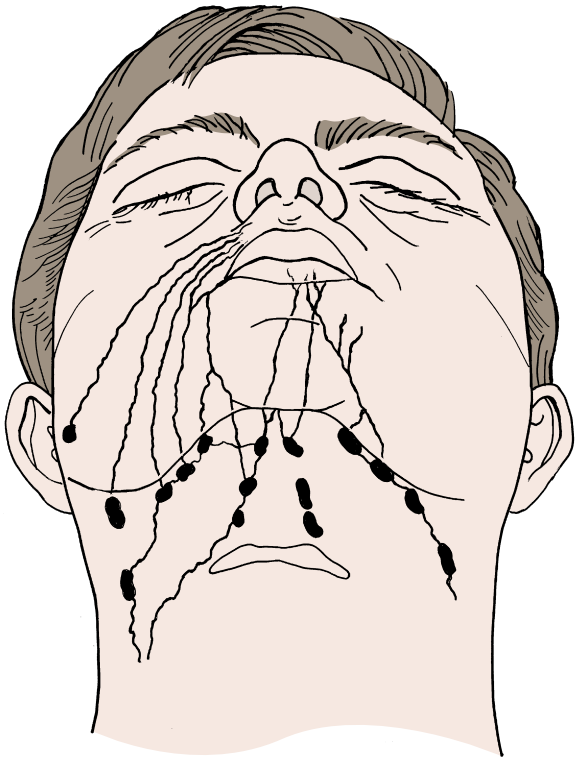

Fig. 27.1. Lymphatic drainage pathways of the lip.

Computed tomography (CT) scan is a commonly performed imaging modality for advanced stage cancer not only to assess characteristics of the primary site but also to assess for lymphadenopathy within the neck.

Magnetic resonance imaging (MRI) has similar ability to detect pathologic cervical lymphadenopathy as CT and ultrasound. If there is concern for perineural or bony invasion, MRI is a more sensitive study.

Positron emission tomography CT scan—Ultrasound has been shown to be equally effective in identifying pathologic cervical lymphadenopathy as CT scan and MRI. In some centers, it is the study of choice due to lower cost and lack of radiation exposure.

Indications

1. Biopsy proven malignancy of the upper or lower lip
2. Sentinel lymph node biopsy or elective neck dissection may be considered in patients who have risk factors for regional metastasis.
3. Therapeutic neck dissection is indicated when clinical evidence of regional metastasis is prevent.

Contraindications

1. Distant metastatic disease
2. Prohibitive medical risk

Preoperative Preparation

1. Adequate assessment of lymphadenopathy and surgical planning regarding whether and how to address the at-risk lymphatic basin
2. Appropriate patient counseling regarding risk of microstomia and oral competence

OPERATIVE PERIOD

Anesthesia

General: Preferred method for patient comfort and protection of the airway if there is active bleeding
Monitored anesthesia care (MAC)
Local anesthesia

Positioning

Supine: In addition to supine positioning, proper neck extension and shoulder roll placement are important if sentinel lymph node biopsy or neck dissection is to be performed in conjunction with excision of the primary.

Perioperative Antibiotic Prophylaxis

First-generation cephalosporin: We prefer cefazolin, 1 mg if under 75 kg, 2 mg if greater than 75 kg.
Second-generation cephalosporin
Clindamycin if allergic to penicillins

Monitoring

If neck dissection is performed in conjunction, avoid long-acting paralytic agents until all pertinent cranial nerves are identified.

Instruments and Equipment to Have Available

1. Basic head and neck surgery set
2. Plastic surgery set
3. If sentinel lymph node biopsy is performed, gamma probe would be necessary, and injectable dye such as isosulfan blue is optional.

Key Anatomic Landmarks

1. Superior and inferior labial arteries lie deep to the vermillion border of the upper and lower lip.
   a. This is especially important when resection is performed. These vessels should be manually compressed to minimize hemorrhage as the incision is carried through the lip.
2. Vermillion border—The junction between the squamous mucosa of the upper/lower lip and the stratified squamous epithelium of the epidermis. This border is especially important in reconstruction for optimal cosmesis.
3. Wet-dry line—The junction between the keratinized squamous mucosa of the body of the lip and the nonkeratinized labial mucosa

Prerequisite Skills

1. General skin and soft tissue dissection
2. Sentinel lymph node excision techniques (if performed)
3. Selective or therapeutic neck dissection (if performed)

Operative Risks

1. Intraoperative bleeding
2. Postoperative infection
3. Microstomia
4. Loss of oral competence, which may lead to drooling
5. Hypesthesia or paresthesia of the lower face, depending on the extent of resection
6. Poor cosmetic outcome

Surgical Technique

Ablative Surgery

- Lip resection
  - Degree of lip resection is dependent upon the pathologic basis of disease.
    - Squamous cell carcinoma is the predominant malignancy of the upper and lower lip. Unlike other sites in the oral cavity, margins of less than 1 cm are routinely planned. Many surgeons rely on frozen section analysis for intraoperative margin assessment. The lip is a cosmetically sensitive area, but the malignancy must be removed with adequate surgical margins.
    - Basal cell carcinoma is the second most common malignancy of the lip; 3-mm margins are usually sufficient for this type of malignancy.
    - Melanoma may occur, though rarely, on the lip. The management of melanoma is dependent on tumor thickness and other pathologic characteristics, similar to other subsites of the head and neck.
  - When planning resection, it is important to consider options for reconstruction, which are discussed at length later. Design will focus on the shape of resection, whether it be wedge shaped or rectangular.
  - First the incision is inked with a marking pen taking into consideration adequate margins of resection. The vermillion border is then scratched with the back of a #15 blade scalpel for later reapproximation.
  - Incisions are made through the skin and subcutaneous soft tissue with a #11 or #15 blade scalpel.
  - Once the skin incisions are made, the upper or lower lip is manually grasped lateral to the incision to tamponade bleeding. Bovie or 3-0 silk ties can be used for hemostasis.
  - Frozen sections may be sent either from the specimen itself or from selected margins taken from the patient.
- Lymphadenectomy
  - Degree of cervical lymphadenectomy will be dependent on presence of pathologic lymphadenopathy as well as the characteristics of the primary lesion.
  - Usually a selective neck dissection of levels 1 to 3 will be adequate, but this is dependent on site of lymphatic metastases. The lower lip has bilateral lymphatic drainage pattern, and cancers of the lip involving the midline occur commonly.

Lip Reconstruction

- Defects less than half of the lip
  - If the resection is less than half of the lower or upper lip, this defect can be reapproximated primarily (Fig. 27.2A to C).
  - Any necessary undermining and hemostasis should be obtained prior to reapproximation.
  - First step should be to reapproximate the vermillion border of the lip. We prefer a simple 6-0 prolene suture for reapproximation.
  - A multilayer closure is then performed, first reapproximating the orbicularis oris muscle to recreate the oral sphincter, followed by the subcutaneous tissue and skin. We prefer a horizontal mattress suture for adequate eversion of the skin and mucosa of the lip to optimize long-term cosmetic outcome. Alternatively a vertical mattress technique can be used.
- Defects affecting one-half to two-thirds of the lip
  - Advancement flaps
    - For advancement flaps, the resection bed should have a rectangular configuration.
    - For the lower lip, horizontal releasing incisions are made from the inferior aspect of the resection. Wide

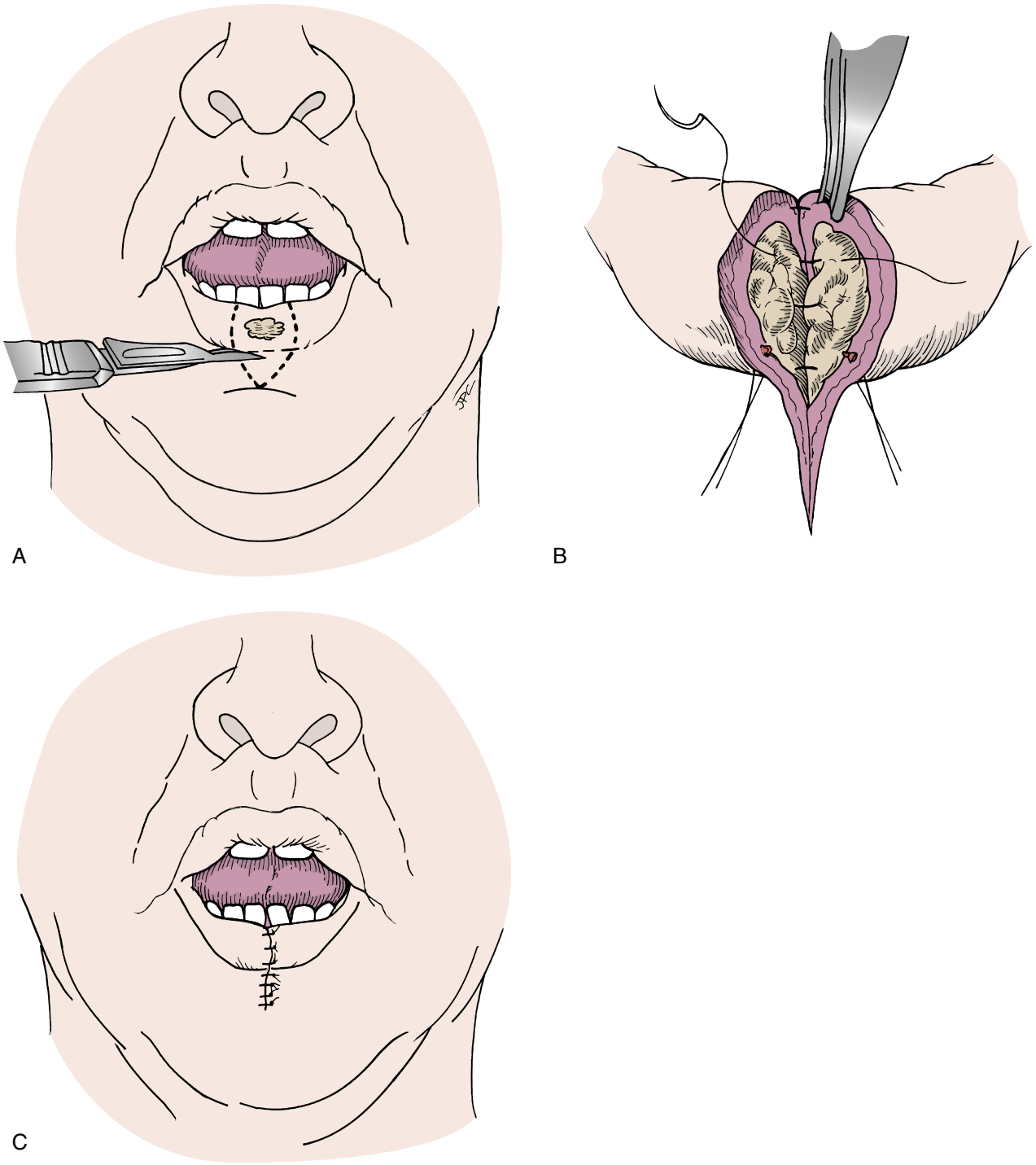

Fig. 27.2. A, Wedge incision is used for excision of lower lip lesion. **B,** The skin, muscle, and mucosa are closed, minimizing tension. **C,** Closure includes accurate reapproximation of the vermillion border and eversion of skin and lip edges.

undermining performed overlying the orbicularis oris muscle. Burrow's triangles are then excised for an optimal result (Fig. 27.3A to C).
- Undermining the mucosa is often necessary for closure.
- Once undermining is complete, a multilayer closure is performed as described previously.
- Similarly, bilateral advancement flaps may be used in upper lip reconstruction. Incisions are carried from the edge of the resection in the perialar region, remaining mindful of the facial subunits. This allows for cheek advancement for closure of defect. This technique is used in lesions that involve the central upper lip as opposed to lateral lip. The use of Burrow's triangles is mandatory in upper lip excisions.

- Abbe flap (Fig. 27.4A to D)
  - The Abbe flap is a "lip switch" flap from the unaffected to the affected lip. The neurovascular supply is based on branches of the superior and inferior labial arteries, which lie immediately deep to the vermillion border.

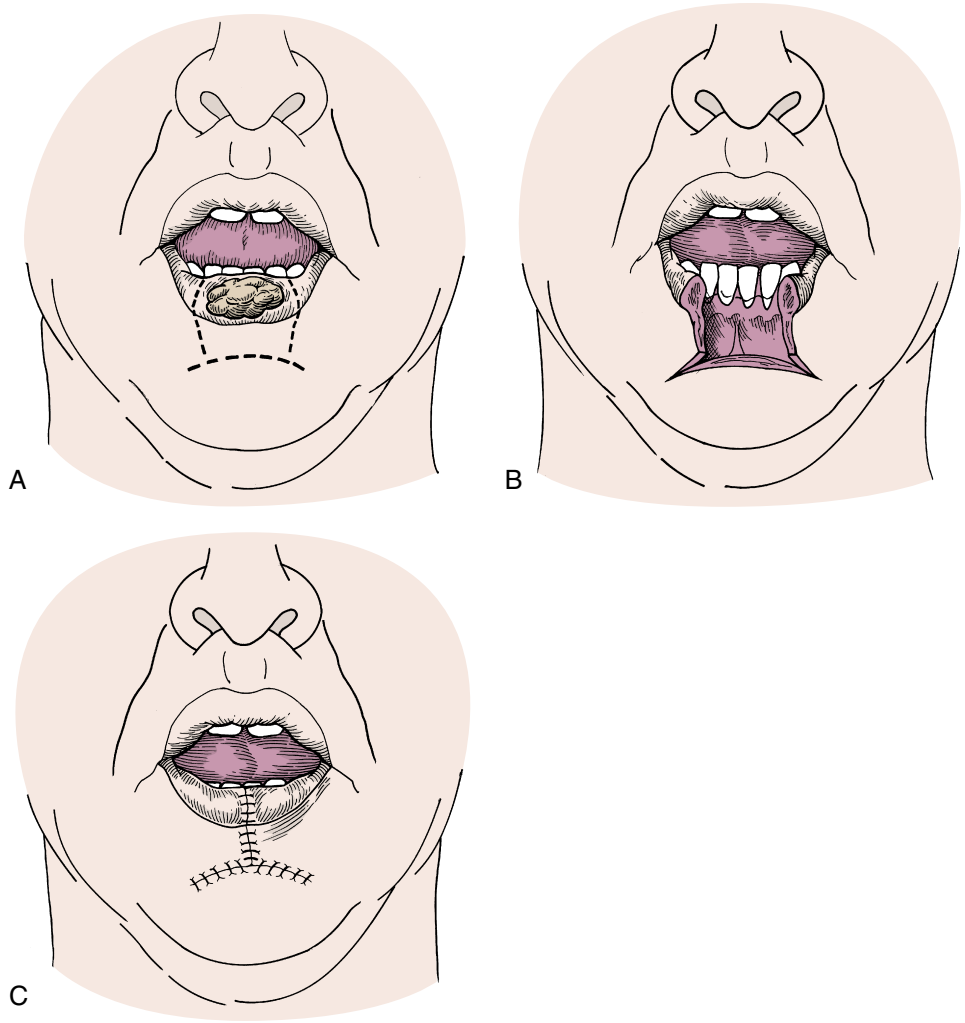

Fig. 27.3. A, Rectangular resection designed in preparation for horizontal advancement flaps. **B,** Relaxing incisions are made horizontally (not shown would be Burrow's triangle excisions). **C,** Wound closure.

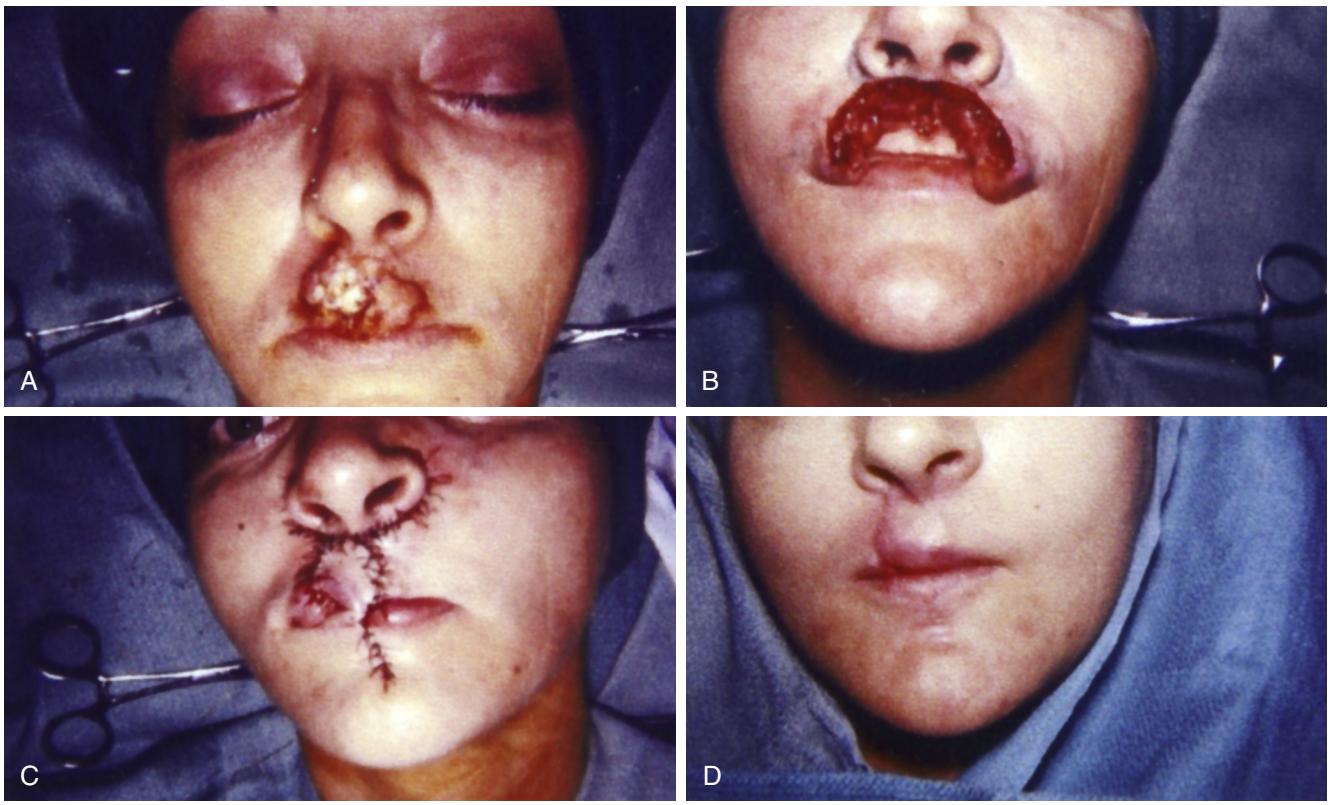

Fig. 27.4. A, Extensive cancer of the upper lip. **B,** Defect following excision. **C,** Defect reconstructed with an Abbe flap and cheek advancement flaps facilitated by use of Burrow's triangles. **D,** Appearance after release and inset of the Abbe flap.

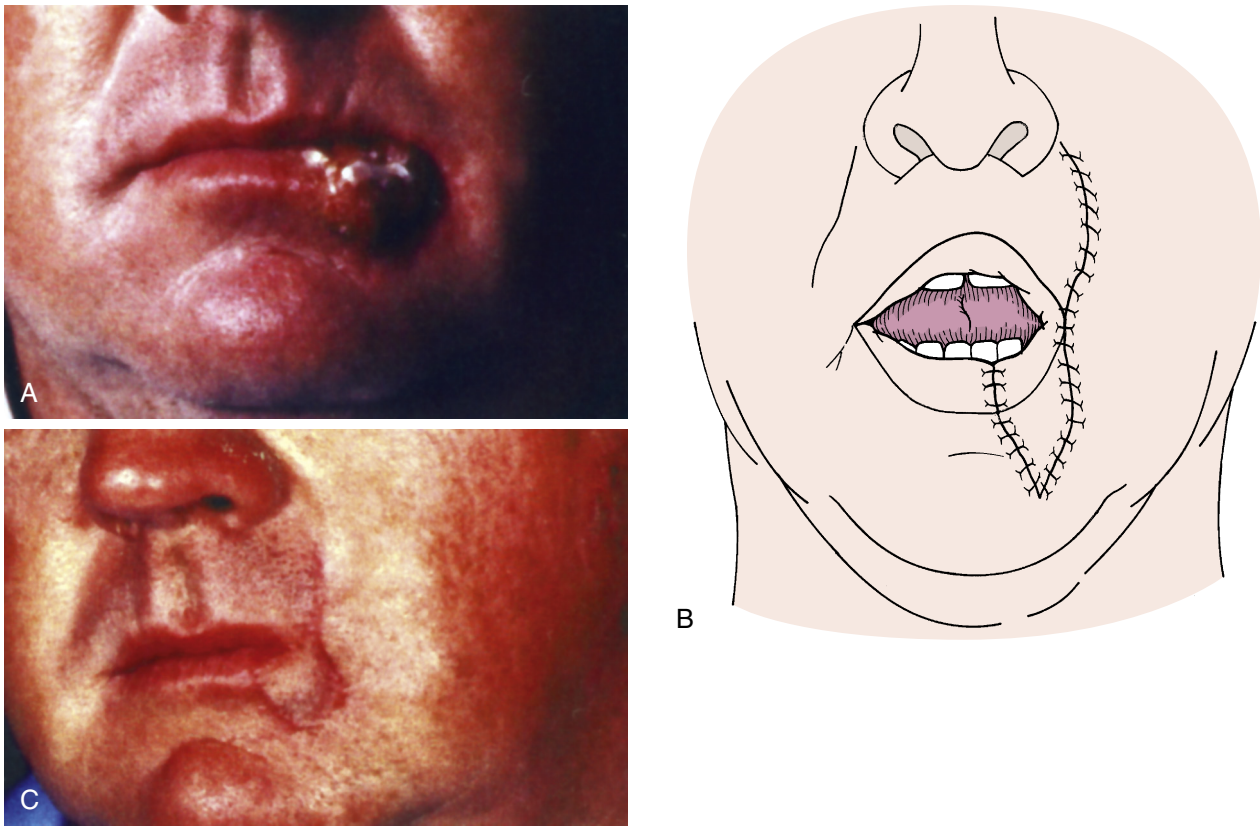

Fig. 27.5. A, Recurrent squamous cell carcinoma of the lower lip involving oral commissure. **B,** Scheme for an Estlander flap. **C,** Acceptable cosmetic and functional results at the commissure with an Estlander flap.

- In harvesting the flap, the height of the defect should determine the height of the harvested flap. If undermining can be performed of the skin surrounding the defect, this should be performed to minimize the amount of soft tissue required to fill the defect.
- The width of the flap should be half the size of the defect, reducing the length of each lip equally.
- Once the flap has been appropriately designed and marked on the skin, incisions are made through skin, lip, and mucosa, leaving an attachment to the lip laterally. The lateral attachment will serve as the vascular supply to the flap.
- The superior and inferior labial arteries lie deep to the vermillion border, and care must be taken to preserve this vessel at the base of the flap.
- Once the flap has been harvested, it is repositioned into the resection bed, and a multilayer closure is performed with careful attention given to reapproximation of the vermillion border.
- The pedicle is then divided after 2 to 3 weeks, erring on the longer side in active smokers.

- Estlander flap (Fig. 27.5A to C)
  - The Estlander flap is another "lip switch" flap from the unaffected to the affected lip. This flap is laterally based and utilizes the oral commissure.
  - Similar to the Abbe flap, the vascular pedicle is based on branches of the superior or inferior labial arteries.
  - The height of the flap should match the height of the defect. The width should approximate half of the defect of the recipient site.
  - Once the flap design is complete, incisions are made through skin, lip, and mucosa in order to elevate the flap. Care is taken to the leave attachment to the unaffected lip, as this is the attachment to the vascular pedicle. Hemostasis is obtained with bipolar cautery.
  - Once the flap has been raised and rotated into the defect, multilayer closure is performed, paying close attention to reapproximation of the vermillion border.
  - While pedicle division is not required, as this flap is laterally based, some rounding of the oral commissure may occur, which may require commissuroplasty. The authors recommend waiting at least 3 months before to performing commissuroplasty.
- Karapandzic flap (Fig. 27.6A to E)
  - While theoretically suitable for both upper and lower lip reconstruction, the Karapandzic flap is most suitable to central, rectangular defects of the lower lip. This may produce profound microstomia, but by maintaining neurovascular supply to the orbicular oris muscle, oral competence is usually maintained.
  - This is a rotation-advancement cheek flap based on the superior or inferior labial arteries.
  - Curvilinear incisions are made toward the base of the alae in the nasolabial fold, encompassing the superior or inferior labial arteries. The orbicularis oris and skin paddle are then undermined toward the base of the flap. Care is taken not to disturb the neurovascular attachments of the skin paddle to the orbicularis oris muscle.
  - Minor undermining and elevation of the mucosa may be necessary.
  - The flaps are then rotated toward midline and reapproximated centrally. A multilayer closure is performed with close attention paid to reapproximation of the vermillion border.



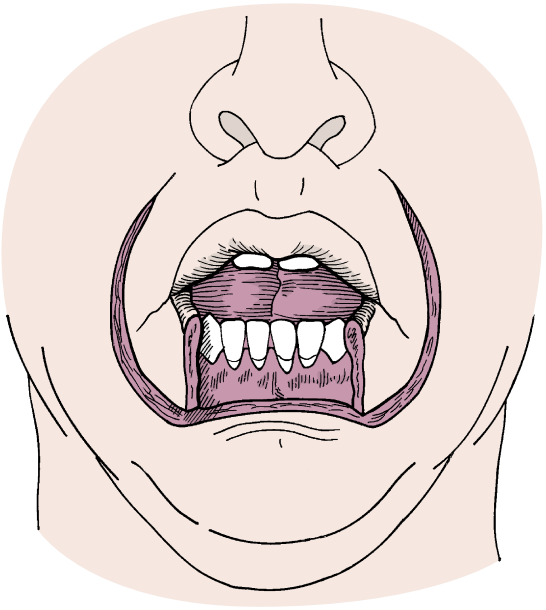

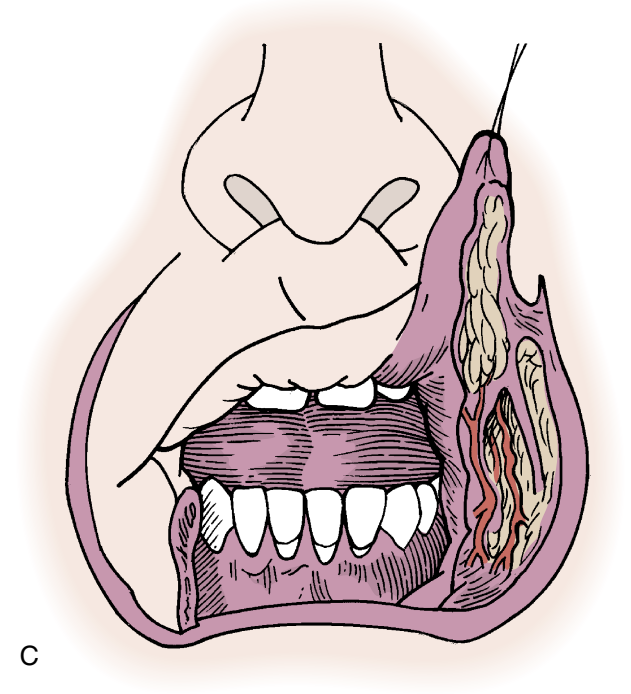

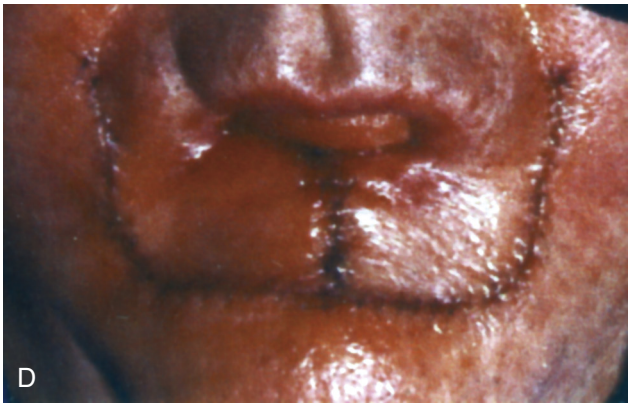



Fig. 27.6. A, Defect after excision of a cancer of the lower lip. **B,** Karapandzic flaps incised. **C,** Flaps incorporate new vascular components. **D,** The flaps are advanced and closed in multiple layers. **E,** Long-term result after Karapandzic flap reconstruction.

- Defects greater than two-thirds of the lip
  - Bernard-Burrow-Webster flap
    - The Bernard-Burrow-Webster flap is another cheek advancement flap for large defects of the lower lip. It is most suitable for central, rectangular defects with the oral commissures intact.
    - Horizontal incisions are extended from the oral commissure out laterally, as well as from the inferior aspect of the defect. The length of each incision should approximate 50% of the size of the defect for adequate closure.
    - Once the horizontal incisions are made, Burrows triangles are excised at the superior incisions for adequate mobilization of cheek tissue. Burrows triangles may be removed from the inferior incisions, but usually this is not necessary due to mobility of lower cheek skin.
    - The skin and subcutaneous soft tissue are then undermined without lifting or removing the orbicularis oris muscle.
    - Similarly, horizontal incisions are made in the mucosa for advancement of the mucosal edges. Undermining of the mucosa is performed in order to close it primarily in the midline. This may not be necessary if used in smaller defects.
    - A multilayer closure is then performed.
    - The vermillion border can be recreated the using a mucosal advancement flap.
  - Full thickness nasolabial transposition flap
    - Nasolabial transposition flaps can be used for large defects of the upper or lower lip. A unilateral flap can be used for reconstruction of a laterally based defect of the upper or lower lip. Bilateral flaps can be harvested in order to reconstruct subtotal defects.
    - This is an axial flap based on branches of the angular artery.
    - Incisions are designed in the nasolabial groove of the affected side of the face. The nasolabial flap can be superiorly or inferiorly based, whichever best suits the reconstruction.
    - The incision is carried down through the skin and subcutaneous soft tissue, taking care not to incise the orbicular oris or other facial mimetic muscles. Undermining is then performed, and the nasolabial flap is rotated into the surgical defect.
    - Multilayer closure is then performed.
    - The vermillion border can be recreated using a mucosal advancement flap.
  - Free tissue transfer
    - With refinements in technique and success rates greater than 95% with free tissue transfer, consideration may be given toward free flap reconstruction of large full-thickness lip defects.
    - In surgical planning for free tissue transfer, the radial forearm free flap has the most appropriate tissue match for lower lip defects. The thickness of the flap as well as the ability to cover both the mucosal and skin surfaces makes it an excellent donor site for full-thickness defects (Fig. 27.7A and B).
    - The palmaris longus tendon can be harvested with the fasciocutaneous paddle as a composite flap. This tendon can then be secured to the orbicularis oris muscle bilaterally, which restores oral competence.
    - Further discussion on free tissue transfer and reconstruction is outside the scope of this chapter. Refer to Chapter 162 for details on free tissue transfer.



Fig. 27.7. A, Large cancer of the lip marked with ink pen including frozen section margins. **B,** Postoperative result from radial forearm free tissue transfer.

Common Errors in Technique

1. Direct pressure should be placed over the superior or inferior labial artery while incisions are made. If this is not done, there will be an increase in intraoperative blood loss as well as staining of tissues.
2. Consideration toward reconstruction should be done prior to making incisions, as the shape of the defect created will alter reconstructive technique utilized.

POSTOPERATIVE PERIOD

Postoperative Management

1. A single dose of intraoperative antibiotics is used. No long-term antibiotic is necessary. Some surgeons advocate for 24 hours of antibiotics following surgery, due to contamination with oral flora.
2. Chlorhexidine mouthwash used for 7 to 10 days following surgery, 3 times daily
3. The incisions should be cleaned with a 50:50 mixture of peroxide and water twice daily. Bacitracin should be applied to the incisions twice daily for 3 to 5 days.
4. Sutures are removed 1 week after the procedure.

5. Patients will be kept on a full liquid diet for up to 48 hours postoperatively, followed by advancement to a soft diet for 7 to 10 days. Patients who undergo a lip-switch procedure will require a liquid diet until division of the pedicle takes place.

Complications

1. Bleeding, less than 1% risk
2. Infection, less than 1% risk if intraoperative antibiotics are given
3. Skin/lip necrosis

Alternative Management Plan

While surgery is the mainstay of management, consideration can be given toward radiation therapy for patients who are not surgical candidates, though outcomes are not as good compared with surgery.

DISCUSSION

Evidence-Based Medicine Question

What is the incidence of occult nodal metastasis in lip cancer?

While the incidence of nodal metastasis is dependent on tumor grade and pathologic characteristics of the primary site, several easily identified factors contribute significantly to occult nodal metastasis in the neck. It has been shown that occult metastases are much more likely in T3 and T4 tumors, especially with involvement of the oral commissure. The overall incidence approaches just over 20%. In these cancers, it is recommended to perform a supra-omohyoid (level 1 to 3) neck dissection due to the high risk of occult metastasis.

Editorial Comment

Paramount to the appropriate management of lip cancers is attaining tumor-free margins, having a reconstructive plan that optimizes form and function, appropriate assessment and management of the neck, and risk factor–driven application of adjuvant radiation and chemotherapy. Intraoperative frozen section examination of margins improves confidence in securing negative margins. Reconstruction, in principle, should attempt to retain or restore the sphincteric function of the lip and oral competence. Primary reconstruction with local, regional, or microvascular free flaps may need to be supplemented with secondary commisuroplasty operations in order to enhance oral competence and appearance. Surgical attention to detail is imperative in optimizing cosmesis. Additional scar revision procedures may complement primary reconstructive efforts. In general, squamous cell carcinoma with limited depth of invasion (less than 4 mm) has a lower risk of nodal involvement in the N0 neck. Recurrent cancers, cancers with greater than 4 mm depth of invasion, and cancers with ulceration have higher rates of occult nodal disease. Level Ia, Ib, and the jugular chain nodes of levels II and III are the most common nodal basins involved in lip cancer. Selective node dissection of these basins provides important prognostic information in high-risk cases. Sentinel lymph node biopsy using radiopharmaceuticals such as Technetium 99m-sulfur colloid and supravital dyes (i.e., lymphazuran) may be particularly useful in lip cancers, due to the technical ease of injection in these anterior lesions. Sentinel lymph node biopsy should be used judiciously and may be less reliable in larger T3 and T4 lesions. Adjuvant radiation therapy should be delivered in cases in which final margins are positive or close (within 2 mm), lymphovascular or perineural invasion are present, or multiple lymph nodes are positive. Chemotherapy is indicated in cases exhibiting positive margins or extracapsular spread in nodal disease. Tumor surveillance and survivorship issues are vitally important. Close follow-up with physical examination for local and regional recurrence is of greatest value. Patients with lip cancer may require psychologic and social support after management, due to changes in appearance and function.

Jeffrey Bumpous

Access the review questions and additional source list online at http://www.expertconsult.com

REFERENCES

1. Young Jr JL, Percy CL, Asire AJ, et al. Cancer incidence and mortality in the United States, 1973-77. Natl Cancer Inst Monogr 1981;(57):1–187.
2. Abreu L, Kruger E, Tennant M. Lip cancer in Western Australia, 1982-2006: a 25-year retrospective epidemiological study. Aust Dent J 2009;54:130–135.
3. Grulich AE, van Leeuwen MT, Falster MO, et al. Incidence of cancers in people with HIV/AIDS compared with immunosuppressed transplant recipients: a meta-analysis. Lancet 2007;370:59–67.
4. Lubek JE, Ord RA. Lip reconstruction. Oral Maxillofac Surg Clin North Am 2013;25(2):203–214.
5. Ishii LE, Byrne PJ. Lip reconstruction. Facial Plast Surg Clin North Am 2009;17(3):445–453.

REVIEW QUESTIONS

1. For a central lower lip defect that involves less than 50% of the lip, sparing the oral commissure, what is the ideal reconstruction?
   a. Radial forearm free flap
   b. Karapandzic flap
   c. Primary closure
   d. Estlander flap

2. For a laterally based upper lip defect that approximates 50% of the upper lip, abutting the philtrum but sparing the oral commissure, what is the ideal reconstruction?
   a. Nasolabial transposition flap
   b. Perialar crescentic advancement flaps
   c. Primary closure
   d. Abbe flap

3. For a centrally based upper lip defect that involves the philtrum and approximates 50% of the upper lip, what is the ideal reconstruction?
   a. Primary closure
   b. Perialar crescentic advancement flaps
   c. Bilateral transposed nasolabial flap
   d. Abbe flap

ADDITIONAL SOURCE

Karapandzic M. Reconstruction of lip defects by local arterial flaps. Br J Plast Surg 1974;27(1):93–97.

28 Partial Glossectomy

Miriam N. Lango

INTRODUCTION

Cancer of the tongue is most common in 60- to 70-year-old male drinkers and smokers but is also encountered in much younger and older individuals without a history of smoking or ethanol use. Most cancers of the tongue are squamous cell carcinomas, which arise on the lateral aspect of the tongue and exhibit a propensity for early spread to the lymph nodes of the neck. Early stage cancers (stages 1 and 2) are equally well controlled with surgery or radiation; however, surgery is associated with less long-term side effects. For advanced cancer, multiple treatment modalities, most commonly surgery followed by radiation, are usually necessary.

In evaluating a patient with a newly diagnosed cancer of the tongue, several questions must be addressed prior to surgery: (1) How extensive is the cancer, and can it be removed through the mouth? (2) Has the cancer spread to the lymph nodes of the neck, and what type of neck dissection, if any, should be undertaken? (3) After the cancer is removed, should the defect be reconstructed?

The office examination and selected radiographic studies are important in assigning an initial tumor stage. The physical examination provides important information regarding the local extent of the cancer, both in its size and depth. Lymph node metastases can often be detected by careful palpation of the neck. Imaging studies such as computed tomography (CT) scans or magnetic resonance imaging (MRI) may identify invasion of the deep muscles of the tongue and small cervical lymph node metastases not appreciated on office examination alone, improve the accuracy of the initial tumor staging, and facilitate the development of a treatment plan.

Most early stage cancers of the tongue can be managed by means of a partial glossectomy and a neck dissection (Fig. 28.1A and B).[1] A larger, deeply infiltrating cancer may require greater exposure than that achieved through the mouth alone. A transcervical delivery or mandibulotomy may be necessary for an oncologically sound extirpation. Larger resections are also more likely to require surgical reconstruction, most often with microvascular transfer of soft tissue from the forearm or thigh to enhance healing and postoperative function. A neck dissection may be omitted in small tongue cancers with minimal invasion but is recommended for thicker cancers even in the absence of clinical or radiographic evidence of lymph node metastases, due to the high frequency of micrometastatic disease.[2-4] In a large randomized study, patients without detectable metastases prior to surgery who underwent elective neck dissection at the time of the surgery for cancer of the tongue had improved overall and cancer-related survival than those who waited until signs of metastatic disease became clinically evident.[5] Neck dissection is more effective earlier in the course of the disease.[6] Additional treatment such as radiation and chemotherapy is added based on the final pathologic review of the resected surgical specimen. Lymphoscintigraphy with sentinel lymph node biopsy effectively identifies micrometastases when performed by experienced surgeons and may be considered as an alternative to a selective neck dissection for cN0 oral cancer in some cases. However, while the survival benefit of selective neck dissection in this setting has been confirmed in a randomized clinical trial, the equivalence of sentinel lymph node biopsy to neck dissection has not.

The overall recurrence rate and survival after surgery for early stage cancer are favorable, with 85% to 90% 5-year rates of cancer-free survival reported. The presence of metastasis to lymph nodes in the neck decreases cancer-free survival rate by 50%, providing justification for additional treatment to improve outcome.[7]

KEY OPERATIVE LEARNING POINTS

1. Preoperative staging helps in developing a suitable surgical treatment plan. Patients with stage 1 to 2 cancer of the tongue are usually managed with a partial glossectomy and selective neck dissection, including levels I, II, III, and possibly IV. Sentinel lymph node biopsy may be considered as an alternative in select cases, as noted previously.
2. Inspection and palpation usually differentiate thin, minimally invasive cancers of the tongue (and those less than 2 to 3 mm thick) from more deeply infiltrating cancers that are associated with higher rates of cervical lymph node metastases.
3. Locally advanced cancers, particularly those classified as T4, with deep muscle invasion often require greater exposure than that afforded by a transoral approach. Transcervical delivery or manibulotomy may be needed. Bone invasion by cancer is an indication for a segmental mandibulectomy.
4. Imaging with CT or MRI scan confirms deep infiltration of tongue muscles (Fig. 28.2B) and is more accurate than clinical examination alone in identifying cervical metastases. The presence of metastatic cancer on imaging clinically upstages the cancer and requires a comprehensive rather than a selective neck dissection.
5. Infiltrative cancers may be more extensive than appreciated on inspection alone. Intraoperatively, the use of palpation to define the clinical extent of the cancer is critical in achieving an adequate resection margin and preventing incising into the cancer and a positive margin.
6. Most T1 and many T2 cancers of the oral tongue may be left open to heal without specific reconstruction (see Fig. 28.1B). Significant extension onto the ventral tongue and floor of the mouth suggests the need for reconstruction with a radial forearm fasciocutaneous flap or a split-thickness skin graft. For larger cancers requiring a hemiglossectomy or a subtotal glossectomy, microvascular soft tissue transfer is usually employed to enhance long-term function.
7. A close or positive margin is best managed if identified at the time of the initial surgery. Suspicion of a close or positive margin should prompt a complete, circumferential, peripheral, and deep margin assessment. Blue dye is used to ink the surgical defect on the patient side. An additional layer of soft tissue measuring 2 to 4 mm thick is excised and oriented, representing the new margin. A complete margin assessment will diminish the likelihood of a false negative margin and improve local control.
8. Careful ligation of the lingual artery at the posterior lateral glossectomy wound site may diminish the likelihood of a severe postoperative hemorrhage.



Fig. 28.1. A, Irregular plaque with raised edges suggests the depth of invasion is at least 2 to 3 mm. Palpation provides additional information regarding the depth of invasion. **B,** A partial glossectomy involves removing an adequate margin of mucosa and muscle. A partial glossectomy of the posterior oral tongue frequently does not require a formal reconstruction.



Fig. 28.2. A, Deviation of the tongue should raise concerns about deep infiltration of the cancer into the muscles of the tongue. **B,** CT scan confirms extension to involve the deep muscles of the tongue.

PREOPERATIVE PERIOD

History

1. History of present illness
   a. The duration of an abnormal lesion on the tongue is a key element in the patient history. Was the abnormality found by the patient, a dentist, or on routine clinical examination? Has a biopsy been done?
   b. Associated symptoms and signs provide additional information about the abnormality.
      1) Is the ulcer or mass tender? The quality, timing, and duration of pain should be described. Cancer-related pain is dull and persistent over weeks or months, often described as "a sore." Is there associated otalgia, suggesting referred pain from deep infiltration
      2) Is there associated dysphagia? Has there been a change in the consistency of the diet? Has there been weight loss? Cancers associated with a greater symptom burden prior to treatment are associated with worse survival, independent of initial tumor staging.[8]

3) Presence of dysarthria
4) Presence of a neck mass

c. Prior therapies or treatments and use of pain medication
d. Risk factors for tongue cancer, including current and prior smoking and ethanol use—particularly the amount

2. Past medical history

A complete past medical, surgical, and social history is a mandatory part of any preoperative assessment. Medical comorbid conditions can affect a patient's tolerance for surgery. In particular, symptoms of pulmonary and cardiac disease must be elicited. Detailed history of alcohol and tobacco use must be carefully reviewed. The social support available to a patient must also be assessed, as this will have a great impact on the patient's rehabilitation after surgery.

Physical Examination

1. Oral cavity (see Fig. 28.1A)
   a. Size and depth of the cancer
   b. Exophytic, infiltrative. or ulcerated cancer
   c. Deviation of the tongue (see Fig. 28.2A)
   d. Cancer extension to the floor of mouth
   e. Presence and condition of dentition
   f. Presence of trismus
   g. Invasion of the mandible—via direct extension or by means of tooth sockets
2. Oropharynx
   a. Base of tongue extension on palpation
3. Nasal cavity and nasopharynx
   a. Mirror examination or endoscopy
4. Larynx and hypopharynx
   a. Mirror examination or endoscopy
5. Neck
   a. Cervical lymphadenopathy, including nodal size and level

Cancer of the tongue may appear as a beefy red patch or ulceration but can also originate in an area of leukoplakia (see Fig. 28.1A). Finger palpation of the area may suggest submucosal infiltration and extension. Deviation of the tongue suggests infiltration of the hypoglossal nerve or deep extrinsic muscle invasion (see Fig. 28.2A and B). A hard mass may be palpable under normal appearing mucosa of the ventral area and base of the tongue. Larger size and greater depth of invasion are associated with a higher risk of nodal metastases. Lateralized tongue cancers usually spread to the ipsilateral neck; however, as the cancer approaches the midline, the risk of contralateral metastases increases. Involvement of the anterior floor of mouth and base of tongue involvement are associated with higher frequencies of bilateral or contralateral lymph node metastases and prompt bilateral neck dissection.

Imaging

1. Chest radiograph
2. CT scan with intravenous contrast or MRI with gadolinium is indicated if deep muscle (extrinsic) muscle involvement or cervical metastatic disease is suspected. CT scans should be obtained if there is a concern about bone invasion.

Indications

1. T1-T2 oral tongue squamous cell carcinoma
2. Other tumors or cancers originating in the oral tongue

Contraindications

1. Patient does not consent
2. Locally advanced cancer—most T3 to T4 cancers require a hemiglossectomy or subtotal glossectomy
3. Unacceptable medical comorbidities
4. Poor functional status
5. Lack of social support

Preoperative Preparation

1. Chest radiograph and neck imaging as indicated
2. Evaluate alcohol use history and consider formal detoxification for patients with a high alcohol intake and a history of delirium tremens.
3. Tobacco cessation counseling for active smokers.
4. Discontinue antiplatelet drugs if possible.
5. Type and screen is not usually necessary.
6. Medical or anesthesia preoperative evaluation
7. Dental evaluation with extraction as needed
8. Review all medical records, especially biopsy and scans from outside hospitals
9. Consent

Speech and swallowing outcomes are best if patients adhere to speech and swallowing exercises after surgery. Consent for surgery should include counseling regarding the need for postoperative rehabilitation. Exercises to prevent trismus and preserve tongue mobility as well as neck and shoulder mobility are most effective if started prior to the development of chronic dysfunction. Routine perioperative consultation with speech pathology and physical therapy may enhance adherence with standard postoperative rehabilitation recommendations.

OPERATIVE PERIOD

Anesthesia

Under a general anesthesia the patient is placed in the supine position.

Positioning

None necessary

Perioperative Antibiotic Prophylaxis

None necessary

Antibiotics may be withheld if no communication between the oral cavity and the neck is anticipated.

Monitoring

None necessary

Instruments and Equipment to Have Available

1. Neck dissection soft tissue set
2. Side mouth retractor/bite block
3. Guarded Bovie tip

Key Anatomic Landmarks

1. Lingual artery
2. Lingual nerve

Prerequisite Skills

1. Experience with diagnostic endoscopy
2. Experience with anatomy of oral cavity
3. Experience with neck dissection

Operative Risks

Intraoperative

1. Intraoperative hemorrhage from the lingual artery
2. Inadvertent communication with the neck dissection
3. Edema of the tongue

Intraoperative hemorrhage is rarely severe enough to require transfusion. Nevertheless, hemorrhage can hamper visualization. Early identification and ligation of the lingual artery is recommended. Electrocautery alone is usually not sufficient for hemostasis. Suspected communication with the neck contents should be managed with repair, antibiotics, and drain placement. Edema of the residual tongue is rare after partial glossectomy without reconstruction. An elective tracheostomy is recommended if a skin graft or microvascular reconstruction is planned.

Surgical Technique

Oral or nasal intubation by the anesthesia service may be used, depending on the need for exposure, the presence of dentition, the location and extent of the cancer, and the preference of the surgeon. Tracheostomy is rarely needed in the absence of skin grafts or microvascular soft tissue transfer reconstruction.

If microvascular reconstruction is planned, in which the oral cavity is in continuity with the neck, antibiotics with coverage against oral flora are indicated. Having the patient fully relaxed during this procedure is helpful in mouth opening and limiting tongue movement during electrocauterization.

Direct laryngoscopy and esophagoscopy are performed to evaluate the upper aerodigestive tract for synchronous primary cancers.

Retractors are used to keep the mouth open and retract the cheek. Headlights provide added illumination. A suture in the midline of the anterior tongue may be used to maximally expose the tongue. Finger palpation along the cancer approximates a 1-cm margin of normal tongue muscle around the cancer during the initial incisions. A silk suture placed on the anterior aspect of the specimen facilitates retraction intraoperatively and orientation of the specimen postoperatively. Posterolaterally in the tongue, the lingual artery is encountered, clamped, and ligated. Placement of deep sutures in the posterior tongue musculature looping around the lingual artery diminishes the likelihood of a severe postoperative hemorrhage. Primary closure of the residual tongue does not decrease the risk of postoperative hemorrhage and has little impact on subsequent tongue function.

Following excision of the cancer, the glossectomy specimen may be inked and transected with the pathologist, providing valuable information regarding the adequacy of the gross tumor-free margin. A close gross margin (<5 mm) should prompt additional resection. In order to avoid sampling error, blue dye may be used to mark the residual tongue on the patient side, and an additional layer of soft tissue encompassing the mucosal surface as well as the deep tongue muscle may be excised, providing another 2 to 4 mm of soft tissue as the true resection margin. Once the specimen is sent for frozen section, the neck dissection may be performed.

With substantial resection of the floor of mouth mucosa, tethering of the tongue may contribute to dysarthria. A split-thickness skin graft or fasciocutaneous free flap diminishes contracture during wound healing and ameliorates this problem. A split-thickness skin graft harvested from the thigh (0.016 to 0.018 inches) is firmly secured over a bolster.[9,10] Skin-grafting techniques have even been proven effective in reconstructing mandibulectomy defects.[9] Currently microvascular reconstruction is more commonly employed. If reconstruction is planned, the tracheotomy is completed prior to the resection to enhance exposure. Securing an endotracheal tube to the skin of the neck keeps tubing tucked out of the way during the subsequent procedures.

Common Errors in Technique

1. Improper diagnosis or inadequate preoperative staging
2. Inadequate margins or positive margins, tumor cut-through
3. Inadequate hemostasis
4. Injury to lips, dentition

A diagnosis of cancer should be confirmed prior to undertaking a glossectomy. A resection with a close or positive margin is not an uncommon technical error, and the patient should be readmitted for further resection to provide clear margins. Intraoperative hemorrhage may contribute to suboptimal resection by decreasing visualization. Such problems may be avoided by using an index finger over the palpable abnormality to guide the initial incisions. Frequent palpation, not simply visualization, is necessary to confirm an adequate tumor-free margin on the specimen. In the face of a questionable margin, a re-resection of an additional 2- to 4-mm slice of soft tissue may be helpful in achieving a true negative margin. Clamping and ligating the lingual artery is more effective hemostasis than extensive cauterization and associated with less postoperative pain and dysphagia. The use of protected Bovie tips prevents cautery-related lip injuries.

POSTOPERATIVE PERIOD

Postoperative Management

1. Diet
2. Pain medication:
   a. Narcotics
   b. Nonsteroidal anti-inflammatory drugs (NSAIDs)
3. Nutritional supplementation
4. Speech therapy rehabilitation

In the absence of reconstruction, most patients can resume a modified oral diet shortly after a partial glossectomy, provided that adequate pain control is provided. High-calorie shakes can supplement nutrition and prevent excessive weight loss. Patients who have undergone reconstruction with a split-thickness skin graft or microvascular reconstruction require temporary nasogastric tube feedings until the wound is healed well enough for the patient to start an oral diet. Narcotics are usually employed to diminish the bleeding risk associated with the use of nonsteroidal anti-inflammatory agents. A routine follow-up speech evaluation is helpful in identifying swallowing-related problems early and instituting a speech and swallowing program as needed.

Complications

1. Edema of the tongue
2. Postoperative hemorrhage
3. Neck infection
4. Aspiration pneumonia
5. Dehydration, weight loss
6. Pain, dysphagia
7. Dysarthria
8. Constipation
9. Other medical complications—cardiac event, deep venous thrombosis

Significant edema of the tongue following glossectomy is uncommon in the absence of reconstruction. A temporary tracheostomy should be performed at the time of the glossectomy if reconstruction is planned or edema of the tongue

is encountered. Edema of the tongue can interfere with swallowing and engender an aspiration pneumonia. An elective temporary tracheostomy will facilitate pulmonary toilet in the postoperative period.

Postoperative hemorrhage from the tongue may occur within 2 to 3 weeks of surgery. Patients who call from home and report that they are spitting up bright red blood or clots should be instructed to call the ambulance to take them to the nearest emergency room. Hemorrhage often requires operative management. With good visualization of the bleeding site in a cooperative, stable patient, suture ligation may occasionally be performed without the need to return to the operating room. However, ligation of a bleeding vessel in the operating room with an established airway is typically the safest and most effective approach.

The tongue is rarely the site of a significant infection; however, unintended communication of the oral cavity with the neck may lead to an infection in the neck. Exploration of the wound and deliberate placement of drains may be needed.

Pain, dysphagia, and dysarthria following partial glossectomy are expected. Narcotics may ease discomfort but should be used with a bowel regimen, including stool softeners, adequate hydration, and laxatives, to prevent constipation. Long-term dysphagia and dysarthria may be minimized by early implementation of a speech and swallowing rehabilitation program.

Alternative Management Plan

1. External beam radiation
2. Supportive or palliative care

In some patients, the use of external radiation or supportive or palliative care may be preferred to a partial glossectomy.

DISCUSSION

Evidence-Based Medicine Question

Under what circumstances can a neck dissection for a tongue cancer be safely omitted?

Neck dissection has been shown to improve disease-free and overall survival in a large randomized study of patients with stage 1 to 2 tongue cancer.[5] Nevertheless, the risk of metastases has repeatedly been linked to the depth of invasion of the cancer, suggesting that elective neck dissection may not be necessary in thin tongue cancers, because the frequency of occult metastatic disease is very low. In the large study reported by D'Cruz et al., the frequency of metastatic cancer in the neck decreased from 16.9% in tongue cancers with a depth of invasion of 4 mm to 5.6% in 3-mm deep tongue cancers. The authors suggest that patients with a minimal depth (≤3 mm) of invasion of the primary tumor may not benefit from elective neck dissection, but additional study is warranted.

Editorial Comment

Squamous cell carcinoma of the oral tongue generally occurs in males in the 60- to 70-year age range who have smoked two to three packs of cigarettes per day and consumed a great deal of alcohol over a long period of time. In the past, these patients have been treated by local excision and a neck dissection only if the patient had a clinically positive neck. If the patient did not have any clinically positive nodes, then a "watch and wait" policy was adopted.

There were two problems associated with this policy. One problem was that 30% to 40% of these patients returned with obvious metastasis, usually to levels I/II, and these patients received a classic radical neck dissection and postoperative radiation therapy. In our department, since the early 1990s, all patients with squamous cell carcinoma of the tongue (including T1) receive an elective neck dissection with findings of approximately 30% to 40% node positivity. Indications for adjunctive therapy include chemoradiation for lymph nodes exhibiting extracapsular spread (ECS), even in one node, and radiation alone for more than two positive lymph nodes or perineural invasion in the primary.[1]

The second problem associated with this "watch and wait" policy was that some of the patients returned with lymph node metastases, fixed and inoperable, or metastasis to the lungs, or both. Adapting the systematic use of the elective neck dissection instead of the "watch and wait" has eliminated this problem.

We include level IV in all elective neck dissections for patients with cancer of the lateral aspect of the tongue. Byers et al. at MD Anderson Cancer Center described a small percentage of patients who had "skip" metastasis. This situation includes metastasis to level IV without positive nodes at level I to III. If this level is not included, recurrence at this level may be expected.

Eugene N. Myers

Access the review questions and additional source list online at http://www.expertconsult.com



REFERENCES

1. Myers EN, Cunningham MJ. Treatments of choice for early carcinoma of the oral cavity. Oncology (Williston Park) 1988;2(2):18–24, 27–28, 31.
2. Spiro RH, Spiro JD, Strong EW. Surgical approach to squamous carcinoma confined to the tongue and the floor of the mouth. Head Neck 1986;9(1):27–31.
3. Byers RM, El-Naggar AK, Lee YY, et al. Can we detect or predict the presence of occult nodal metastases in patients with squamous carcinoma of the oral tongue? Head Neck 1998;20(2):138–144.
4. Ganly I, Patel S, Shah J. Early stage squamous cell cancer of the oral tongue—clinicopathologic features affecting outcome. Cancer 2012;118(1):101–111.
5. D'Cruz AK, Vaish R, Kapre N, et al. Elective versus therapeutic neck dissection in node-negative oral cancer. N Engl J Med 2015;373(6):521–529.
6. Tsang RK, Chung JC, To VS, et al. Efficacy of salvage neck dissection for isolated nodal recurrences in early carcinoma of oral tongue with watchful waiting management of initial N0 neck. Head Neck 2011;33(10):1482–1485.
7. Thiagarajan S, Nair S, Nair D, et al. Predictors of prognosis for squamous cell carcinoma of oral tongue. J Surg Oncol 2014;109(7):639–644.
8. Lango MN, Egleston B, Fang C, et al. Baseline health perceptions, dysphagia, and survival in patients with head and neck cancer. Cancer 2014;120(6):840–847.
9. Schramm Jr VL, Myers EN. "How I do it" – head and neck: a targeted problem and its solution. Skin graft reconstruction following composite resection. Laryngoscope 1980;90(10 Pt 1):1737–1739.
10. Qureshi SS, Chaukar D, Dcruz AK. Simple technique of securing intraoral skin grafts. J Surg Oncol 2005;89(2):102–103.

REVIEW QUESTIONS

1. A 54-year-old smoker who developed a 1.5-cm squamous cell carcinoma of the posterior right oral tongue, at 4 mm depth, will require all of the following, except
   a. A neck dissection
   b. A right partial glossectomy
   c. Postoperative radiation therapy
   d. A preoperative chest radiograph
   e. Smoking cessation counseling for active smokers

2. Potential complications of a partial glossectomy include all of the following, except
   a. Hemorrhage
   b. Neck infection
   c. Aspiration pneumonia
   d. Dysarthria
   e. Oral pain

3. A 54-year-old male with a 70 pack per year smoking history presents with a tender ulcerated mass on the right oral tongue associated with tongue fixation and extrinsic tongue muscle involvement on imaging. He requires all of the following, except
   a. Chest imaging
   b. Free tissue transfer
   c. Partial glossectomy
   d. Neck dissection
   e. Subtotal glossectomy

ADDITIONAL SOURCE

Byers RM, Weber RS, Andrews T, et al. Frequency and therapeutic implication of "skip metastases" in the neck from squamous carcinoma of the oral tongue. Head Neck 1997;19:14–19.

29 Total Glossectomy

Johan Fagan

INTRODUCTION

Total glossectomy is used for advanced cancers of the tongue, mostly squamous cell, either as a primary surgical resection or as salvage following previous (chemo)radiation when partial glossectomy will not achieve adequate resection margins. A key clinical decision is whether a laryngectomy is required. This decision is based on whether a patient is likely to cope with some degree of aspiration and whether extension of cancer into the pre-epiglottic space requires a laryngectomy to achieve an adequate margin. Total glossectomy may incur significant morbidity relating to speech, mastication, swallowing, and in some cases, aspiration. Therefore many centers elect to treat advanced cancers of the tongue with chemoradiation and to reserve surgery for treatment failures.

I consider total glossectomy to be a good primary treatment for advanced cancer of the tongue, provided that patients are carefully selected and that the surgical and reconstructive steps described in the following text are followed to optimize function and quality of life.

Patient selection is critical, both for favorable oncologic and functional outcomes. The majority of patients require a combination of surgery and postoperative (chemo)radiation; hence there is little point in embarking on surgery if a patient is unlikely to complete postoperative adjuvant therapy. To give properly informed consent, patients must have the ability to consider the potential oncologic benefits of surgery against the morbidity relating to speech, dietary modification, mastication, deglutition, and aspiration. If the larynx is to be preserved, then patients must have sufficient cardiopulmonary reserve to cope with some aspiration. As many such patients are malnourished, patients should be assessed from a nutritional perspective to determine whether they are suitable to undergo such surgery. Synchronous primaries or cervical and distant metastases must be excluded by clinical examination, chest radiograph or computed tomography (CT) scan of the lungs, panendoscopy, and PET-CT.

Before contemplating total glossectomy, the surgeon must be confident of being able to achieve clear surgical margins, especially if doing a salvage operation, and the patient should not have known distant metastases. Determine whether the cancer of the tongue is resectable; it may be difficult to assess the extent of the primary cancer due to pain, tenderness, and trismus. If in doubt about resectability, then proceed to image the cancer with CT and/or magnetic resonance imaging (MRI) or even examination under anesthesia.

A number of major nerves are in close proximity to the tongue; examine the patient for neurologic deficits of the hypoglossal, mental, inferior alveolar, and lingual nerves caused by perineural invasion. Widening of the inferior alveolar canal on mandibular orthopantomography (panorex) may suggest involvement of the inferior alveolar nerve. MRI may demonstrate perineural invasion. Should there be evidence of perineural invasion, then the affected nerve must be resected proximally until a clear surgical margin is obtained on frozen section.

Preoperative planning relating to the mandible is important because the cancer may extend across the floor of the mouth to involve the periosteum, invade the inner cortex, or involve the medullary bone. If only the periosteum is involved, then a marginal mandibulectomy (removal of cortical bone) may suffice. After the cortex is invaded, then segmental mandibulectomy is required. However, after the medulla is invaded, then segmental or hemimandibulectomy is done that includes at least a 2-cm length of mandible on either side of visible cancer. Although panorex or CT scan will show gross bony destruction, MRI is preferred to assess involvement of medullary bone. Should marginal mandibulectomy be considered, then the vertical height of the mandible should be assessed clinically or by panorex to predict whether a free composite flap is required.

The next major decision to make is whether total laryngectomy is required. Laryngectomy is indicated in patients who are unlikely to tolerate a degree of aspiration and when the cancer extends to the pre-epiglottic space and/or epiglottis (Fig. 29.1). Whether a patient can tolerate aspiration depends on his or her physical fitness, pulmonary reserve, cognitive function, and attitude, all of which should be considered when selecting patients for total glossectomy, especially if it is to be followed by chemoradiation. Pre-epiglottic space involvement is diagnosed radiologically on CT or MRI (sagittal views) or intraoperatively by palpating for thickening of the pre-epiglottic space between a finger placed in the vallecula and a finger placed on the skin of the neck just below the hyoid bone (Fig. 29.2). If in doubt, the patient has to be consented for possible total laryngectomy based on intraoperative surgical and frozen section findings.

Patients with advanced cancer of the tongue generally have poor dentition and should have preoperative dental radiographs done and either be referred to a dentist or have carious teeth removed at the time of surgery to prevent subsequent osteoradionecrosis.

Finally, the reconstructive team must plan how best to reconstruct the tongue defect and possibly the mandible. Although many techniques are used, it is essential to select a bulky flap to create a convex floor of mouth that bulges up to the hard palate to avoid pooling of secretions and to facilitate articulation and swallowing.

KEY OPERATIVE LEARNING POINTS

- Careful patient selection is the key to maximizing oncologic and functional outcomes.
- Intubation may be difficult.
- Temporary tracheostomy is essential.
- Perform panendoscopy to rule out synchronous primaries.
- Marginal mandibulectomy is done for both oncologic and functional reasons.
- The mylohyoid muscle forms the floor of the mouth; this muscle and its attachment to the mandible along the mylohyoid line is resected to ensure adequate margins.
- Frozen section is advisable, particularly at the base of the tongue, where it may be difficult to distinguish between tumor and the thick, irregular normal mucosa.
- Total laryngectomy is required when the cancer extends to the pre-epiglottic space and/or epiglottis.
- Optimize function by
  - Preserving as much base of tongue tissue as is possible

- Ensuring that the reconstructive flap has sufficient bulk to create a convex floor of mouth that permits contact between the flap and the palate during phonation to facilitate articulation, to assist deglutition, and to avoid pooling of secretions
- Suspending the hyoid bone from the anterior arch of the mandible to facilitate breathing and swallowing
- Considering using a sensate flap
- Preserving the superior laryngeal nerves
- Performing total laryngectomy in patients who are unlikely to tolerate some degree of aspiration

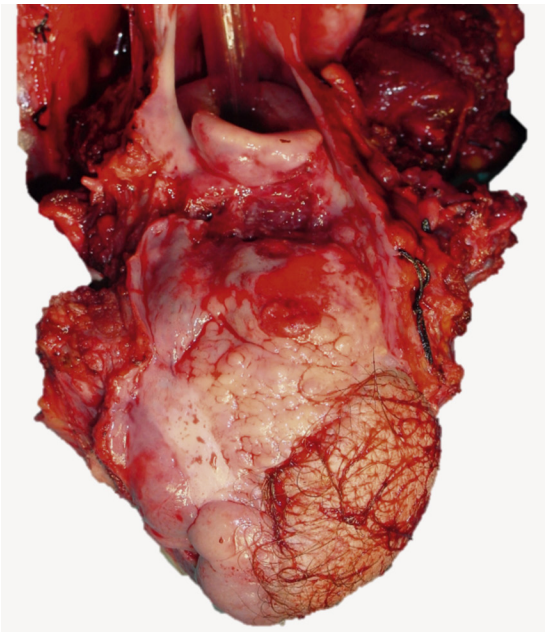

Fig. 29.1. Second primary tongue cancer involving vallecula and epiglottis and requiring total glossectomy with laryngectomy. *(From Fagan JJ: Total glossectomy for tongue cancer. In Fagan JJ (ed): The Open Access Atlas of Otolaryngology Head and Neck Operative Surgery. Available at https://vula.uct.ac.za-/access/content/group/ba5fb1bd-be95-48e5-81be-586fbaeba29d/Total%20glossectomy%20for%20tongue%20cancer.pdf.)*

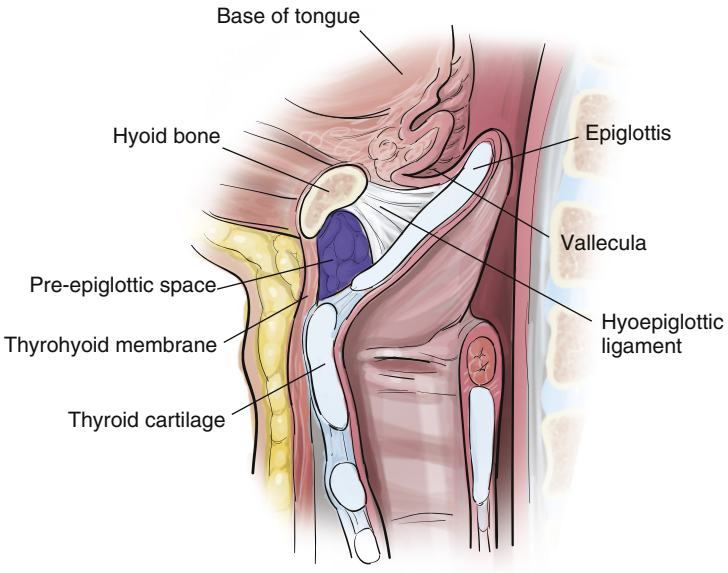

Fig. 29.2. Relations of hyoid, epiglottis, vallecula, and pre-epiglottic space.

- Bilateral neck dissection (elective or therapeutic) is essential due to the high likelihood of harboring cervical nodal metastases.

PREOPERATIVE PERIOD

History

1. History of present illness
   a. Risk factors: smoking, alcohol, human papilloma virus (HPV) infection
   b. Weight loss, nutritional status
   c. Is pain control adequate?
   d. Pointers to synchronous primaries
   e. Pulmonary status—aspiration, smoking
   f. Neurologic deficits of lingual, hypoglossal, and mental nerves
   g. Pointers to extension to larynx (e.g. dysphonia, stridor)
2. Past medical history
   a. Previous squamous cell carcinomas
   b. Previous radiation to the head and neck
   c. Past surgery, trauma, or claudication that may affect the choice of reconstructive flap
3. Prior treatment of tongue or neck
   a. Previous (chemo)radiation
   b. Previous surgery
4. Medical illness
   a. Cardiopulmonary disease: ability to walk up a flight of stairs
   b. Immunosuppression (e.g. acquired immunodeficiency syndrome [AIDS])
   c. Alcoholism and substance abuse
5. Medications
   a. Anticoagulants
   b. Alcohol (risk of perioperative alcohol withdrawal syndrome)
   c. Allergies to antibiotics
6. Mental and social status
   a. Ability to overcome challenges related to speech and swallowing
   b. Ability to give informed consent
   c. Social support
   d. Employment (unlikely to return to full employment)

Physical Examination

1. Cancer of the tongue
   a. Pain, salivary pooling, bleeding, and trismus may hamper assessment; therefore consider administering morphine prior to examination to improve examination.
   b. Determine the extent of the cancer.
      1) Posterior margin
         a) Vallecula
         b) Supraglottic larynx
      2) Floor of mouth
      3) Mandible: free/abutting/adherent/invading
      4) Deep margins
         a) Extrinsic tongue muscles
         b) Suprahyoid strap muscles
      5) Invasion of major nerves
         a) Lingual (loss of sensation of anterior tongue and floor of mouth)
         b) Inferior alveolar (loss of sensory function of mental nerve)
         c) Hypoglossal (may be difficult to assess due to pain and cancer)
2. Mandible
   a. Thickness/height: Thin mandible may preclude marginal mandibulectomy and require segmental mandibulectomy and free fibula flap
   b. Dentition
3. Necks
   a. Palpate both necks for cervical metastases.
   b. Examine necks for previous surgery and scars that may affect surgery.
4. Examine oral cavity, pharynx, and larynx for synchronous primaries.
5. Potential donor sites for flaps
   a. Anterolateral thigh and rectus abdominis: Obesity may preclude their use.
   b. Free fibula (Leg vein harvest and peripheral vascular disease may preclude its use.)
   c. Pectoralis major
   d. Latissimus dorsi
6. General health
   a. Nutrition
   b. Cardiovascular
   c. Respiratory
   d. Mental

Imaging

1. Chest radiograph
   a. Metastases
   b. Synchronous cancer of the lung
   c. Pulmonary and cardiac status
2. Contrast swallow: if there is a suspicion of cancer of the esophagus
3. Panorex
   a. Dentition
   b. Bone invasion
   c. Height of mandible
      1) To plan marginal mandibulectomy
      2) To determine whether segmental mandibulectomy is required
   d. Perineural invasion of the inferior alveolar nerve may cause widening of the inferior alveolar canal.
4. CT scan
   a. Not required in all
   b. If concern that mandible is invaded
   c. Is pre-epiglottic space involved?
   d. Not required for cervical metastases as elective neck dissection is always done
   e. If chest radiograph is inconclusive to exclude pulmonary metastases
5. MRI
   a. Not required in all
   b. If concerned about invasion of extrinsic muscles of tongue and suprahyoid straps muscles
   c. Mandibular marrow space invasion
   d. Perineural invasion
6. PET-CT
   a. To exclude distant metastases
   b. Not required in all

Indications for Surgery

- Advanced cancers of the tongue (primary surgical resection)
- Partial glossectomy will not achieve adequate resection margins.
- Salvage following previous (chemo)radiation

Contraindications to Surgery

1. Patient factors
   a. Medically unfit
   b. Malnourished
   c. Inability to give informed consent
   d. Inability to overcome challenges related to speech and swallowing
   e. Inadequate social support
   f. Inability to complete adjuvant therapy
2. Tumor factors
   a. Unable to achieve clear margins (especially with salvage surgery)
   b. Distant metastases
3. Surgical factors
   a. Inadequate surgical expertise
   b. Inadequate reconstructive surgical expertise

Preoperative Preparation

1. Evaluations by
   a. Oncologic surgeon
   b. Oncologist
   c. Reconstructive surgeon
   d. Speech and swallowing therapist
   e. Anesthesiology
2. Postoperative intensive care
3. Discontinue antiplatelet drugs if possible.

OPERATIVE PERIOD

Anesthesia

- Ask anesthesiologist to insert a nasal endotracheal tube.
- Surgeon should always stand by during induction of anesthesia because bulky cancers may preclude elevation of the tongue to visualize the larynx and make it difficult or impossible to intubate the patient without fiberoptic intubation.
- Should the anesthesiologist still be unable to intubate the larynx, the surgeon may have to intubate through an operating laryngoscope or do an emergency tracheostomy or cricothyroidotomy.
- A temporary tracheostomy is always done during the course of the operation for potential airway compromise due to bleeding, soft tissue swelling, a bulky flap, and loss of anterior laryngeal suspension following division of the mylohyoid, geniohyoid, and digastric muscles.
- Insert a nasogastric tube for postoperative feeding.

- The anesthetic machine is positioned at the foot of the table to create space around the head for the surgeons.

Positioning

- Position the patient so that both the resection and reconstruction surgical teams can work simultaneously to reduce the length of the surgery.
- The surgery is done with the patient in a supine position with neck extended.
- The lower face, neck, and selected donor site for the flap are sterilized and appropriately draped.

Perioperative Antibiotic Prophylaxis

- Clean contaminated surgery
- Antibiotics are administered during induction of anesthesia and continued for 24 hours.
- Choices
  - Clindamycin
  - Amoxicillin-clavulanate
  - Cephalosporin and metronidazole

Monitoring

- Patient should not be paralyzed to facilitate preserving the spinal accessory and marginal mandibular nerves.
- Routine anesthesia monitoring
- Optimize conditions for a free microvascular transfer flap by regulating core temperature, hydration, and hemoglobin.
- Insert a Foley catheter and rectal thermometer.

Instruments and Equipment to Have Available

- Two sets of monopolar and bipolar electrocautery for the two surgical teams
- Resection and neck dissections
  - Standard head and neck cancer surgery set
  - Oscillating saw for marginal mandibulectomy or osteotomies
  - Mandibular plating set (if required)
  - Powered drill
  - Tracheostomy tubes and anesthetic tubing for tracheostomy
- Reconstructive surgery (microvascular)
  - Microvascular instrument set
  - Microvascular sutures
  - Ligaclips
  - Heparin-saline solution
  - Operating loupes and/or operating microscope
  - Tourniquet (if free fibula flap used)

Key Anatomic Landmarks

- Neck dissection: See neck dissection chapters.
- Laryngectomy: See laryngectomy chapter.
- Total glossectomy
  - Mylohyoid line
  - Insertion of genioglossus onto superior genial tubercle (Fig. 29.3)
  - Insertion of geniohyoid onto inferior genial tubercle (see Fig. 29.3)
  - Insertion of anterior belly of digastric onto mandible (see Fig. 29.3)
  - Sublingual salivary glands between submandibular duct and mandible
  - Lingual arteries emerge behind hyoglossus to enter the tongue posterolaterally
  - Pre-epiglottic space
  - Hyoid bone
  - Superior laryngeal nerves traverse thyrohyoid membrane
  - Mental nerve is at risk, especially in edentulous older patients where it exits the mental foramen.

Prerequisite Skills

- Neck dissection: selective levels 1 to 4; modified; and radical
- Total laryngectomy
- Mandibulectomy: marginal or segmental
- Reconstruction of tongue defect
  - Pedicled flap: pectoralis major or latissimus dorsi
  - Free microvascular transfer flap: anterolateral thigh, rectus abdominis
- Reconstruction of mandible
  - Plating
  - Free fibula flap
- Tracheostomy

Surgical Technique

- Intraoperative evaluation after patient has been intubated
  - Panendoscopy to exclude synchronous cancers in upper aerodigestive tract
  - Reassess extent of primary cancer, especially posterior and lateral limits.
  - Reassess the neck for cervical metastases.

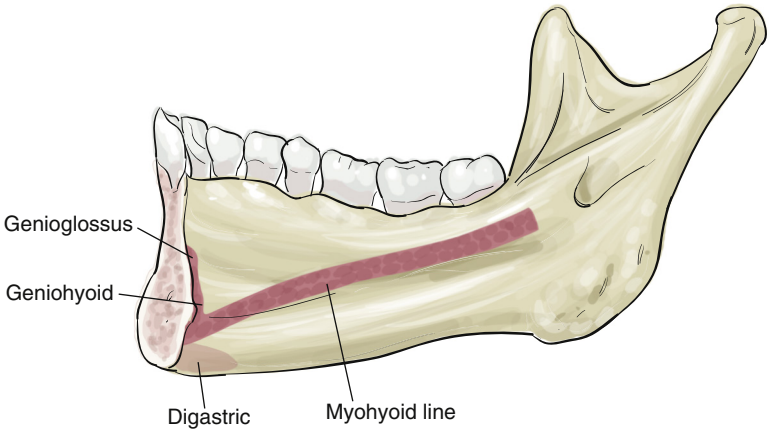

Fig. 29.3. Mylohyoid line and attachments of geniohyoid and genioglossus to inferior and superior genial tubercles and insertion of digastric muscle.

- Surgical approach
  - Good access is essential to attain adequate resection margins, to control bleeding, and for reconstruction.
  - Open the necks bilaterally along incisions as indicated in Fig. 29.4.
  - My preference to resect the tongue by a combination of transcervical and transoral approaches will be described. Others prefer a midline lip-split incision with median or paramedian mandibulotomy.
- Neck dissections
  - Advanced cancers of the tongue are highly likely to harbor clinically apparent or occult cervical nodal metastases, therefore bilateral selective (levels 1 to 4) or comprehensive neck dissections are routinely performed as indicated.
    - Neck dissections are completed prior to resecting the primary cancer (Fig. 29.5).
- Total glossectomy: cervical dissection
  - Incise the periosteum along the inferior margin of the mandible from angle to angle (Fig. 29.6).
  - Transect the anterior bellies of digastric and divide the mylohyoid with electrocautery (see Fig. 29.6).
  - Free them from the mandible.
  - Strip the soft tissues off the inner aspect of the mandible in a subperiosteal plane with a periosteal elevator.
  - If the cancer extends to the lateral floor of the mouth, then strip the periosteum from the bone up to the mylohyoid line (Fig. 29.7).
  - Divide and free the insertion of the geniohyoid muscle at the inferior mental spine (see Fig. 29.7).
- Total glossectomy: transoral dissection
  - When tumor abuts the mandible, first do a marginal mandibulectomy because this greatly facilitates subsequent tongue resection.
  - Incise the gingiva along the alveolar ridge (Fig. 29.8).
  - Strip the soft tissue off the outer aspect of the mandible without exposing the inferior half of the mandible to maintain its blood supply.
  - Take care not to injure the mental nerves where they exit the mental foramina.
  - Perform a marginal mandibulectomy along the superior aspect of the horizontal ramus of the mandible, as indicated in Figs. 29.7 and 29.9.
  - Angle the osteotomy obliquely to include the mylohyoid line; this is especially important if the cancer extends to the lateral floor of mouth and abuts bone.
  - Not only does the marginal mandibulectomy have oncologic relevance in terms of resection margins, but it avoids

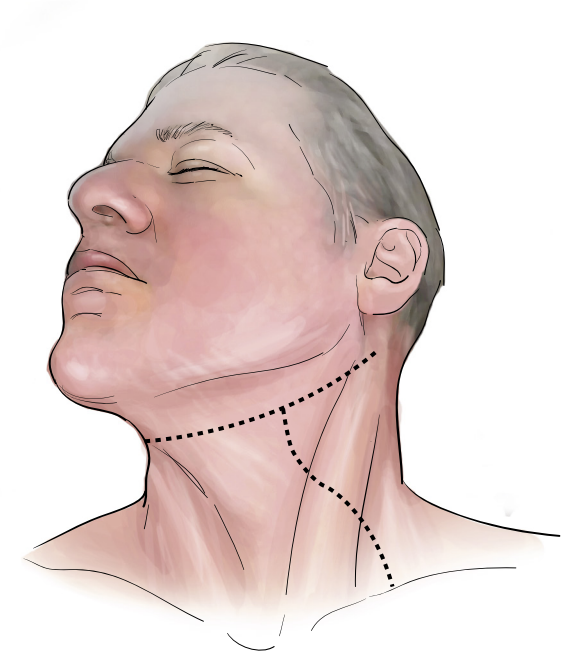

Fig. 29.4. Skin incisions (on both sides of the neck).

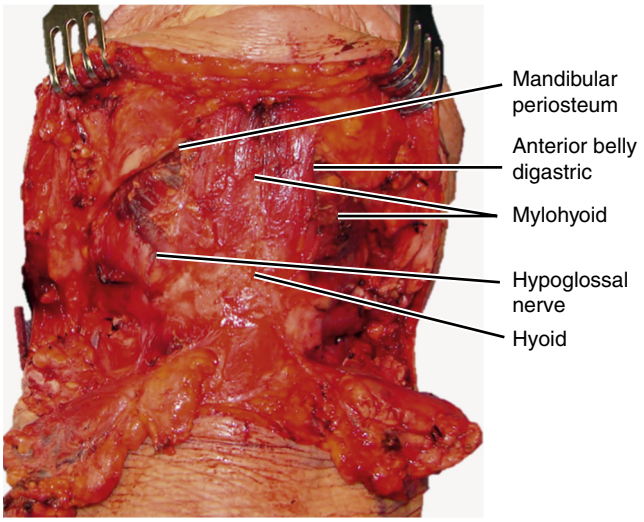

Fig. 29.5. Exposure following completed bilateral selective neck dissections *(From Fagan JJ: Total glossectomy for tongue cancer. In Fagan JJ (ed): The Open Access Atlas of Otolaryngology Head and Neck Operative Surgery. Available at https://vula.uct.ac.za/access/content/group/ba5fb1bd-be95-48e5-81be-586fbaeba29d/Total%20glossectomy%20for%20tongue%20cancer.pdf.)*

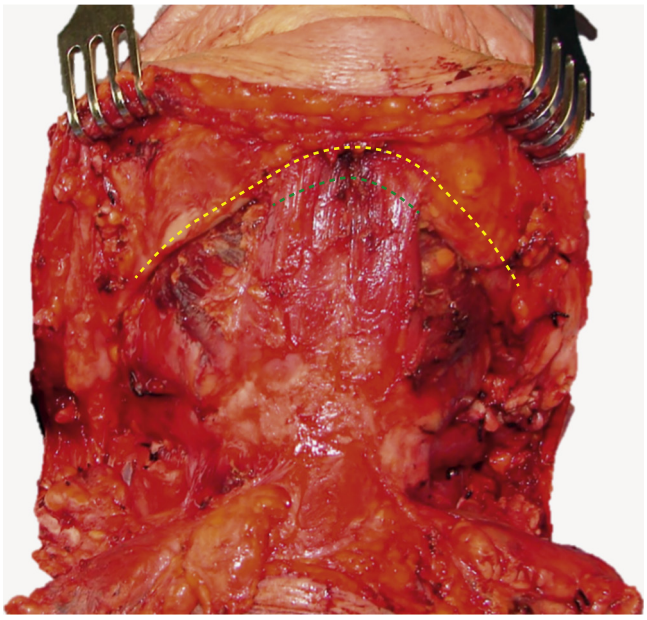

Fig. 29.6. Incise periosteum along inferior margin of mandible from angle to angle *(yellow line)*, and transect anterior belly of digastric muscle *(green line)*. *(From Fagan JJ: Total glossectomy for tongue cancer. In Fagan JJ (ed): The Open Access Atlas of Otolaryngology Head and Neck Operative Surgery. Available at https://vula.uct.ac.za/access/content/group/ba5fb1bd-be95-48e5-81be-586fbaeba29d/Total%20glossectomy%20for%20tongue%20cancer.pdf.)*

a sump effect of having a concavity along the medial border of the mandible, as will become apparent later.

- Glossectomy
  - Deliver the marginal mandibulectomy, floor of mouth, and tongue into the neck as a unit (Fig. 29.10).
  - This permits excellent exposure of the entire tongue, vallecula, and epiglottis.
  - Resect the cancer with sufficient margins, using monopolar electrocautery (Fig. 29.11).
  - Preserve as much base of tongue mucosa as possible to facilitate swallowing.
  - Preserve the superior laryngeal nerves during resection to facilitate swallowing.
  - Ligate the lingual arteries as they are encountered posterolaterally during the dissection.
  - Carefully examine the specimen for adequacy of margins (Fig. 29.12).
  - Send the specimen for frozen section (if available) to determine the adequacy of the margins.
- Laryngectomy
  - If laryngectomy was preplanned, the larynx is resected in continuity with the tongue.
  - If it was not preplanned, then assess the need for total laryngectomy intraoperatively.
  - Examine the posterior resection margin; should the epiglottis and pre-epiglottic adipose tissue be uninvolved and if the patient is mentally and physically fit enough to tolerate some aspiration, omit the laryngectomy and proceed to reconstructing the defect (Fig. 29.13).
- Reconstruction
  - Reconstructing the defect is key to optimizing function.
  - Important elements from a functional perspective
    - To avoid a sump that collects food and saliva in the mouth, I favor the marginal mandibulectomy technique described previously, which allows one to suture the edges of the flap to the gingivobuccal and gingivolabial mucosae with continuous absorbable sutures (Figs. 29.14 and 29.15).

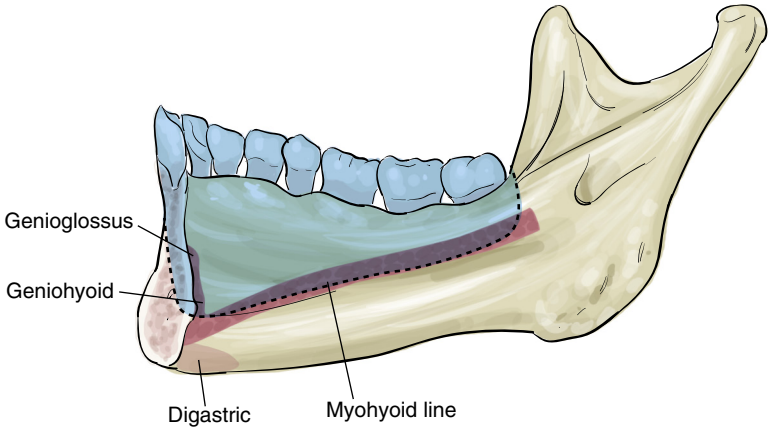

Fig. 29.7. Mylohyoid line and attachments of geniohyoid and genioglossus to inferior and superior mental spines; *broken line* indicates marginal mandibulectomy.

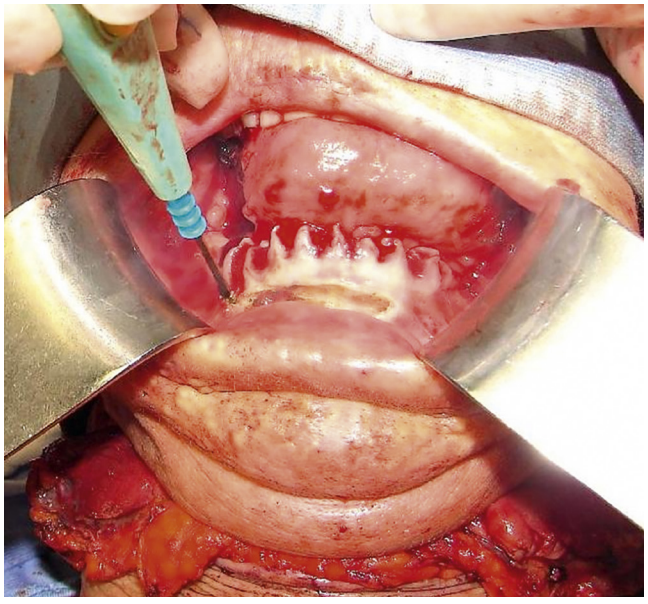

Fig. 29.8. Incise along gingival margin. *(From Fagan JJ: Total glossectomy for tongue cancer. In Fagan JJ (ed): The Open Access Atlas of Otolaryngology Head and Neck Operative Surgery. Available at https://vula.uct.ac.za/access/content/group/ba5fb1bd-be95-48e5-81be-586fbaeba29d/Total%20glossectomy%20for%20tongue%20cancer.pdf.)*

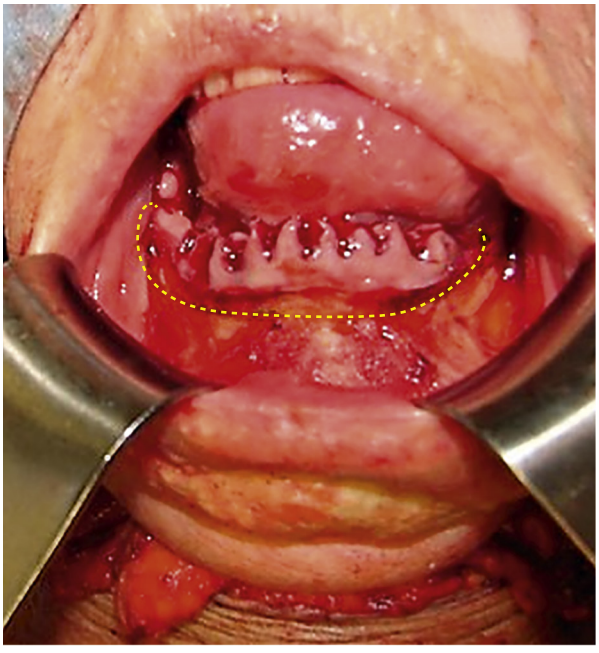

Fig. 29.9. Osteotomy along *dotted line* using a power saw. *(From Fagan JJ: Total glossectomy for tongue cancer. In Fagan JJ (ed): The Open Access Atlas of Otolaryngology Head and Neck Operative Surgery. Available at https://vula.uct.ac.za-/access/content/group/ba5fb1bd-be95-48e5-81be-586fbaeba29d/Total%20glossectomy%20for%20tongue%20cancer.pdf.)*

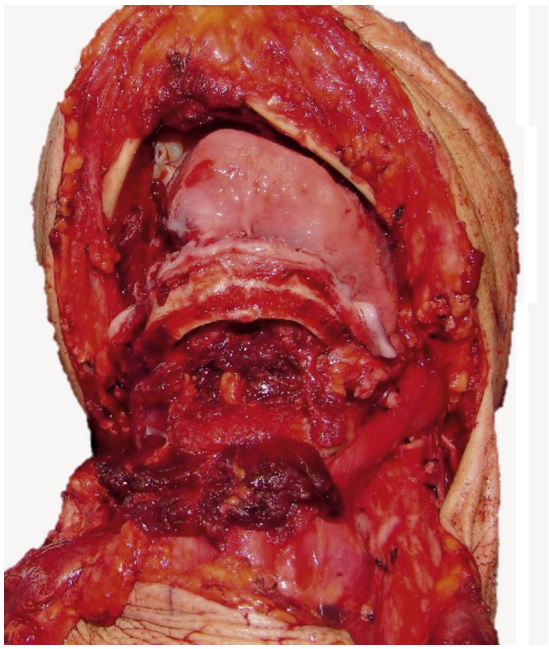

Fig. 29.10. Marginal mandibulectomy, floor of mouth and tongue dropped into neck. *(From Fagan JJ: Total glossectomy for tongue cancer. In Fagan JJ (ed): The Open Access Atlas of Otolaryngology Head and Neck Operative Surgery. Available at https://vula.uct.ac.za/access/content/group/ba5fb1bd-be95-48e5-81be-586fbaeba29d/Total%20glossectomy%20for%20tongue%20cancer.pdf.)*



Fig. 29.12. Total glossectomy with marginal mandibulectomy. *(From Fagan JJ: Total glossectomy for tongue cancer. In Fagan JJ (ed): The Open Access Atlas of Otolaryngology Head and Neck Operative Surgery. Available at https://vula.uct.ac.za-/access/content/group/ba5fb1bd-be95-48e5-81be-586fbaeba29d/Total%20glossectomy%20for%20tongue%20cancer.pdf.)*

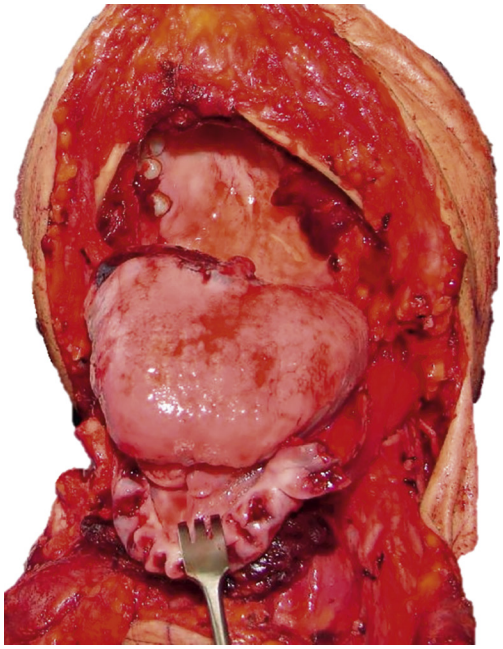

Fig. 29.11. Transcervical resection using excellent exposure. *(From Fagan JJ: Total glossectomy for tongue cancer. In Fagan JJ (ed): The Open Access Atlas of Otolaryngology Head and Neck Operative Surgery. Available at https://vula.uct.ac.za-/access/content/group/ba5fb1bd-be95-48e5-81be-586fbaeba29d/Total%20glossectomy%20for%20tongue%20cancer.pdf.)*

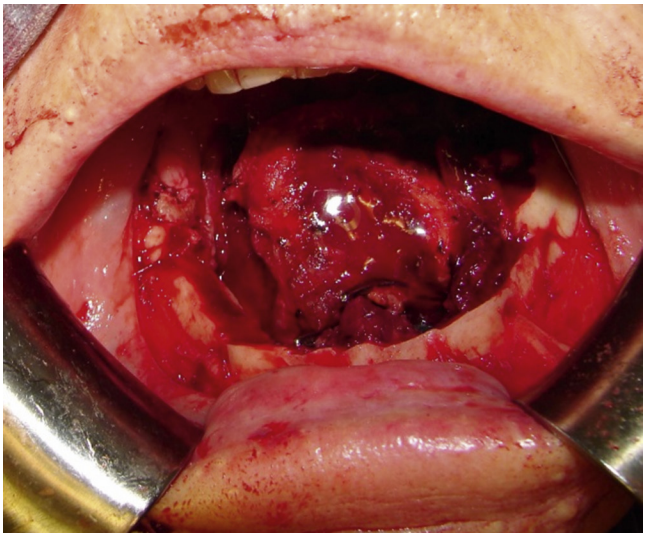

Fig. 29.13. Completed resection with small amount of residual base of tongue. *(From Fagan JJ: Total glossectomy for tongue cancer. In Fagan JJ (ed): The Open Access Atlas of Otolaryngology Head and Neck Operative Surgery. Available at https://vula.uct.ac.za/access/content/group/ba5fb1bd-be95-48e5-81be-586fbaeba29d/Total%20glossectomy%20for%20tongue%20cancer.pdf.)*

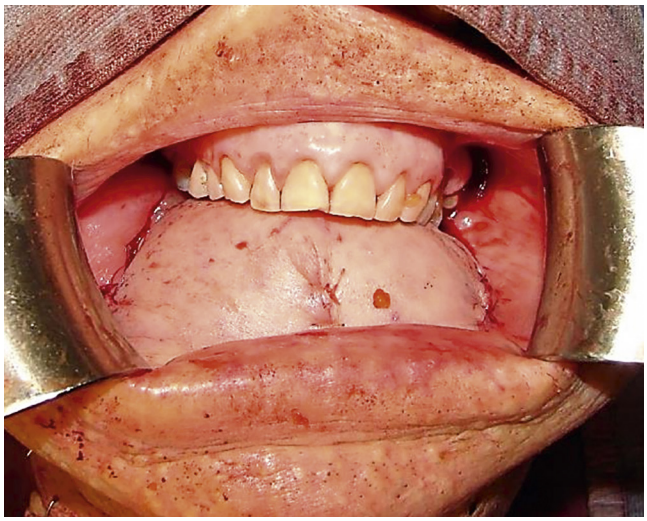

Fig. 29.14. Large flap creates convex floor of mouth. *(From Fagan JJ: Total glossectomy for tongue cancer. In Fagan JJ (ed): The Open Access Atlas of Otolaryngology Head and Neck Operative Surgery. Available at https://vula.uct.ac.za-/access/content/group/ba5fb1bd-be95-48e5-81be-586fbaeba29d/Total%20glossectomy%20for%20tongue%20cancer.pdf.)*



Fig. 29.15. Long-term result of pectoralis major flap used to create a convex floor of mouth without sump caused by retaining the lower teeth. *(From Fagan JJ: Total glossectomy for tongue cancer. In Fagan JJ (ed): The Open Access Atlas of Otolaryngology Head and Neck Operative Surgery. Available at https://vula.uct.ac.za-/access/content/group/ba5fb1bd-be95-48e5-81be-586fbaeba29d/Total%20glossectomy%20for%20tongue%20cancer.pdf.)*

  - The flap should have sufficient bulk to create a convex floor of mouth that permits palate-neoglossal contact during phonation and deglutition to facilitate articulation and to avoid pooling of secretions.
  - The flap should be large enough that it bulges up to the hard palate with the knowledge that it will both descend and lose some muscle bulk and hence flatten out with time (see Figs. 29.14 and 29.15).
  - A variety of flaps provide sufficient tissue volume (i.e., pectoralis major and latissimus dorsi pedicled flaps or anterolateral thigh and rectus abdominis free microvascular transfer flaps).
  - Radial free forearm flaps should be avoided because they provide insufficient bulk and result in a concave floor of mouth and a sump that interferes with deglutition, causes pooling and spillage of saliva and food, and poor articulation, because the flap cannot abut the palate on elevation of the mandible.
  - Mandibulectomy may require free fibula flap reconstruction, but like the forearm flap, the soft tissue component is generally inadequate.
  - Consider using a sensate flap.
- Laryngeal suspension
  - Dividing all the attachments of the larynx to the mandible (anterior bellies of digastrics, mylohyoids, geniohyoids, and genioglossi) promotes aspiration, impairs swallowing, and may cause obstructive sleep apnea.
  - Therefore the hyoid bone is suspended from the anterior arch of the mandible by two strong nonabsorbable sutures passed between the hyoid and the anterior arch of the mandible (Fig. 29.16).
- Closure
  - The neck is closed over two suction drains.
  - A temporary tracheostomy is done.

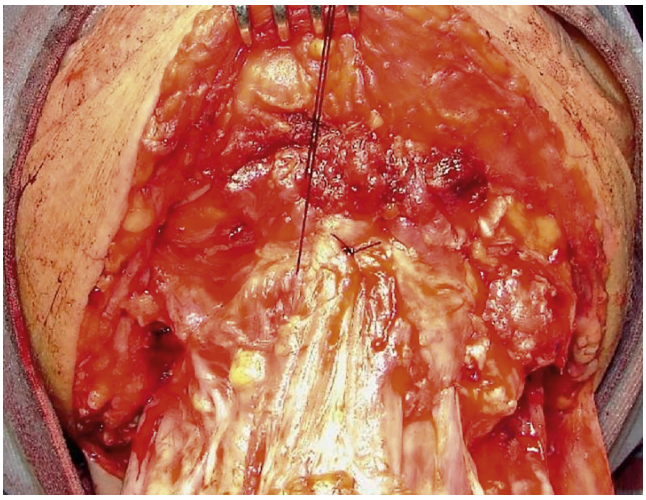

Fig. 29.16. Laryngeal suspension with nonabsorbable sutures. *(From Fagan JJ: Total glossectomy for tongue cancer. In Fagan JJ (ed): The Open Access Atlas of Otolaryngology Head and Neck Operative Surgery. Available at https://vula.uct.ac.za-/access/content/group/ba5fb1bd-be95-48e5-81be-586fbaeba29d/Total%20glossectomy%20for%20tongue%20cancer.pdf.)*

Common Errors in Technique

- Omitting a marginal mandibulectomy and preserving the lower teeth: The aesthetic benefit of preserving the lower teeth needs to be weighed against the fact that the teeth have limited functional value in the absence of a functioning tongue and that the lateral floor of the mouth will serve as a sump for saliva and food.
- Insufficient bulk of the flap: The flap should virtually touch the palate at conclusion of surgery.

POSTOPERATIVE PERIOD

- Antibiotics for 24 hours
- Monitor viability of the flap.
- Remove suction drains when less than 50 mL drainage/24 hours.
- Tracheostomy
  - Maintain until certainty that patient does not need to be returned to the operating room for surgical complications (e.g., ischemia of the flap)

- After there is thought to be an adequate airway
  - Cork tracheostomy overnight
  - Remove if airway is maintained
- Feeding
  - Enteral feeding via nasogastric tube the morning after surgery
  - Oral feeding
    - Delay until decannulated
    - Speech and swallowing therapist assists the patient with swallowing
    - Because of impairment of the oral phase of swallowing, this initially involves placing thickened liquids and pureed food in the back of the mouth with a syringe or spoon until the patient learns to throw the head back and use gravity to assist with the oral phase of swallowing.
- Postoperative (chemo)radiation generally started within 6 weeks of surgery

COMPLICATIONS

- Hematoma: Return the patient to the operating room as soon as possible to avoid failure of flap.
- Alcohol withdrawal syndrome
  - Onset on days 2 and 3
  - Causes additional morbidity and mortality and prolongs hospitalization
  - Involve internist or intensivist in care
  - May require sedation and ventilation
- Tracheostomy
  - Occlusion
  - Dislodgement
  - Delayed decannulation if very bulky flap
- Flap
  - Loss due to perfusion failure
  - Too bulky: delayed decannulation
  - Too small: poor articulation and pooling of saliva and food in mouth
- Dysphagia and aspiration
- Omitting a laryngectomy in a patient that subsequently aspirates significantly

ALTERNATIVE MANAGEMENT PLAN

Patients with advanced cancer of the tongue should always be offered nonsurgical treatment options.

DISCUSSION

Evidence-Based Medicine Question

What are the quality of life and survival benefits of total glossectomy for advanced tongue cancer?

Patients with advanced cancers of the tongue generally have severe pain and impaired speech, have lost a great deal of weight, and may be cachectic. This might partly explain why Dziegielewski et al. (2013) reported favorable speech and swallowing outcomes compared with patients' preoperative status in a study of objective functional outcomes and a systematic review of the literature relating to total glossectomy.[1] This is similar to my own experience in which eight of eight patients returned to a full oral diet.[2] Dziegielewski et al. also reported that postoperative quality of life scores were only marginally reduced despite swallowing and speech function having deteriorated; the authors attributed this to "improved pain control, peace of mind after tumor ablation or due to strong social supports."[1] Van Lierop et al. reported oncologic outcomes of primary total glossectomy with postoperative radiation therapy on eight patients with stage 4 tongue cancers; at 2, 3, and 5 years, 63%, 38%, and 25% of patients, respectively, were alive without disease. Navach et al. reported 5-year overall and disease-free survivals of primary total glossectomy of 79% and 61% in a review of a number of studies.[3] However, case series are small, and the reported oncologic outcomes may be skewed by patient selection.

Editorial Comment

The decision to proceed with a total glossectomy for advanced tongue cancer is never taken lightly. In particular, complete surveillance for both locoregional and potential distant metastatic disease must be carefully attended to preoperatively. After the decision is made to proceed with total glossectomy, the surgeon must have considered carefully whether laryngeal preservation with the glossectomy is either possible or desirable. In my opinion, if significant amounts of the supraglottic larynx require resection or the patient has poor pulmonary reserve that would make tolerance of aspiration poor, total laryngectomy should be performed in conjunction with the glossectomy. The decision to perform a laryngectomy (or not) will also influence the decision regarding the type of flap reconstruction. Bulk of flap becomes of less concern in the patient who has a laryngectomy performed in conjunction with the total glossectomy. If the larynx is preserved, free tissue transfer is the preferred reconstructive technique, whereas pectoralis major myocutaneous flaps represent a viable strategy in appropriately selected patients. The pectoralis flap is less desirable in female patients due to donor site appearance, as well as a potentially less reliable skin flap than in males. Because of the long donor pedicle length and high reliability of the flap, coupled with potentially less donor site morbidity (hernias and closure issues in obese patients), the anterior lateral thigh flap is quickly eclipsing the rectus abdominus and latissimus dorsi flap in our practice.

Jeffrey Bumpous

Access the review questions and additional source list online at
http://www.expertconsult.com

REFERENCES

1. Dziegielewski PT, Ho ML, Rieger J, et al. Total glossectomy with laryngeal preservation and free flap reconstruction: objective functional outcomes and systematic review of the literature. Laryngoscope 2013;123:140–145.
2. van Lierop AC, Basson O, Fagan JJ. Is total glossectomy for advanced carcinoma of the tongue justified? S Afr J Surg 2008;46(1):22–25.
3. Navach V, Zurlo V, Calabrese L, et al. Total glossectomy with preservation of the larynx: oncological and functional results. Br J Oral Maxillofac Surg 2013;51(3):217–223.

REVIEW QUESTIONS

1. Total glossectomy for cancer of the tongue
   a. Always is combined with laryngectomy
   b. Markedly reduces quality of life
   c. Can be done without using a flap
   d. May be considered in adenoid cystic carcinoma with distant metastases

2. Appropriate flaps following total glossectomy include
   a. Anterolateral thigh
   b. Radial forearm
   c. Pectoralis major
   d. Latissimus dorsi

3. Contraindications for primary total glossectomy include
   a. Unable to achieve clear margins
   b. Inability to complete adjuvant therapy
   c. Poor social support
   d. Cervical metastases

ADDITIONAL SOURCE

Fagan JJ. Total glossectomy for tongue cancer. In Fagan JJ, editor. The Open Access Atlas of Otolaryngology Head and Neck Operative Surgery. Available at https://vula.uct.ac.za/access/content/group/ba5fb1bd-be95-48e5-81be-586fbaeba29d/Total%20glossectomy%20for%20tongue%20cancer.pdf

30 Excision of Cancer of the Floor of the Mouth

David D. Walker, Elizabeth A. Blair

INTRODUCTION

Cancer of the floor of the mouth accounts for approximately one-third of all cancers of the oral cavity, with squamous cell carcinoma accounting for more than 95% of cases. Affected patients tend to reflect many of the epidemiologic features that have come to define squamous cell carcinoma of the head and neck as a whole, including a male predilection, advanced age at the time of diagnosis, and a well-established etiologic association with tobacco, alcohol, and human papillomavirus (HPV) (Fig. 30.1). Despite these similarities, cancers of the floor of the mouth distinguish themselves from other cancers of the head and neck in several key ways. Perhaps most notable is its propensity for early occult metastasis to the cervical lymph nodes. Although positive nodal status is anticipated and even expected with advanced-stage cancers (T3/T4), occult nodal metastasis is a relatively common finding, even with early-stage cancer of the floor of the mouth (T1/T2). Retrospective reviews have demonstrated that as many as 30% of patients with a cancer of the floor of the mouth have evidence of occult nodal metastasis following elective neck dissection. This unique finding makes the treatment of the clinically negative neck a pivotal decision. Advanced-stage cancers of the floor of the mouth pose further challenges, as the intimate anatomic relationship between the floor of mouth and adjacent structures—namely the tongue and mandible—increases the risk of locoregional invasion. As the extent of the cancer increases, so does the associated morbidity of surgical intervention, including compromise of speech, mastication, and oral competence. Together, these distinct oncologic features combine to make cancer of the floor of the mouth one of the more aggressive and potentially lethal neoplasms of the oral cavity.

KEY OBJECTIVE LEARNING POINTS

1. Patient selection and careful preoperative planning are essential for optimizing oncologic and functional outcomes.
2. Reconstructive efforts should aim to provide reasonable cosmesis while restoring competent physiologic function to both speech and swallowing.
3. Airway planning, both at the time of surgery and during the postoperative recovery, is critical for limiting morbidity and mortality.
4. The role of the elective neck dissection remains controversial but appears to offer a survival benefit.

PREOPERATIVE PERIOD

A careless preoperative evaluation can compromise even the most elegantly performed surgery. Thus a systematic approach to patient selection is critical not only for determining surgical candidacy but also for maximizing oncologic and functional surgical outcomes. The foundation of the preoperative evaluation is the history and physical examination. The information obtained here should form a complete appreciation of the patient's overall condition and thus his or her ability to undergo surgery safely. Although age itself is not a contraindication to surgery, numerous studies have demonstrated a relationship between the severity of medical comorbidities and postoperative survival.[1] Those patients with numerous comorbidities will require medical evaluation and clearance as well as risk stratification. Thus assessment of surgical candidacy typically requires a multidisciplinary approach, which includes evaluations by internal medical specialists, medical and radiation oncologists, speech and swallow therapists, nutritionists, and anesthesiologists.

For those deemed fit enough to undergo surgical resection, the surgeon must next assess the resectability of the cancer. The history and physical examination along with a panorex computed tomography (CT), and magnetic resonance imaging (MRI) should allow for accurate staging of the tumor. Particular attention is paid to the presence of local invasion into surrounding structures of the oral cavity. An accurate assessment of the relationship of the cancer to the lingual surface of the mandible helps to define surgical planning and approach. Conversely, failure to recognize periosteal or cortical involvement preoperatively can not only compromise the primary ablative surgery but also drastically alter the plan for reconstruction.

In the immediate preoperative setting, clear and concise communication between surgeon and anesthesiologist is paramount for safe airway management. A retrospective review of 320 patients with cancer of the floor of the mouth by Shaha et al. attributed half of the postoperative mortalities to airway compromise.[2] This underscores the importance of a coordinated approach between the anesthesiologist and the surgeon to provide the safest airway plan possible both at the time of initial induction and in the postoperative setting.

Approaching patient selection as a perfunctory preoperative exercise is a grave disservice to the patient. Such efforts risk poor oncologic control or compromised reconstruction. However, a diligent history and physical examination, along with a multidisciplinary approach toward surgical optimization, can position the patient for a successful surgical outcome.

History

1. History of present illness
   a. Characterization of lesion: size, onset, growth, pain
   b. Complaint of an ill-fitting lower denture
   c. Assessment of speech, swallowing, and mastication
   d. Evidence of perineural invasion: immobility of the tongue, dysgeusia, numbness
   e. Screen for odynophagia, dysphagia, otalgia, oral bleeding
   f. Weight loss, malnutrition
   g. History of recent biopsy of an intraoral lesion
2. Past medical history
   a. History of oral cavity leukoplakia, dysplasia, or lichen planus
   b. History of obstructive sleep apnea or cardiopulmonary disease
   c. History of radiation therapy
   d. History of cancer of the head and neck
   e. History of previous treatment to the area of the primary cancer, ipsilateral or contralateral neck



Fig. 30.1. Squamous cell carcinoma of the floor of the mouth is highly associated with the consumption of tobacco and alcohol.

   f. History of immunosuppression
3. Past surgical history
   a. History of surgical intervention of the oral cavity
   b. History of surgical intervention of the neck
   c. History of dental surgery
   d. History of mandibular fracture with reconstruction
   e. History of prior tracheostomy
4. Family history
   a. History of difficulty with anesthesia
   b. History of bleeding diathesis
5. Medications
   a. Anticoagulants
   b. Herbal products
   c. Immunosuppressants
   d. Allergies
6. Social
   a. Alcohol
   b. Tobacco use
   c. Betel quid
   d. Review of occupational demands, particularly of those in the culinary industry, and of speech requirements
   e. Social support structure
   f. Jehovah's Witness

Physical Examination

1. General appearance
   a. Malnutrition, cachexia
      1) Present in 50% of head and neck cancer patients[3]
      2) Independent predictor of survival[4]
2. Complete examination of the head and neck
   a. Oral cavity
      1) Observation
         a) Exophytic
         b) Deep infiltration
         c) Ulcerations
         d) Papillary
      2) Thorough assessment of the location and extent of the cancer
         a) Proximity or invasion of intrinsic tongue musculature
            i) Midline or unilateral
            ii) Anterior or lateral
         b) Assessment of tongue mobility
         c) Diameter—measure for staging (e.g., T1–T4)
      3) Relationship between cancer margin and ductal papilla
      4) Dental evaluation, including evidence of carious or loose teeth
   b. Mandible
      1) Bimanual palpation of the cancer and mandible has been demonstrated to be superior to imaging in predicting cortical invasion.[5]
      2) Proximity of cancer to the lingual surface of the mandibular periosteum
      3) Evidence of invasion through the mandibular cortex
      4) Evidence of cancer on the alveolar ridge or the buccal surface of the mandible
      5) Presence of a pathologic fracture
      6) Assess dimensions including mandibular height and anteroposterior thickness
      7) Involvement of the skin (Fig. 30.2)
      8) Presence of previous reconstruction/plating
   c. Cranial nerves
      1) Evidence of intraoral perineural invasion including
         a) Mental nerve hypoesthesia
         b) Numbness of the tongue
         c) Dysgeusia
         d) Impaired mobility of the tongue
      2) Complete assessment of cranial nerves II to XII
   d. Neck
      1) Palpation of both necks in the evaluation of nodal metastasis
      2) Postradiation skin changes, which may indicate the presence of neck fibrosis
      3) Previous neck incisions, which may indicate prior surgeries
   e. Evidence of synchronous primary (Fig. 30.3)
      1) Unilateral otitis media with effusion
      2) Stridor
      3) Dysphonia
3. Potential donor site
   a. Fibula
   b. Radial forearm
   c. Supraclavicular region
   d. Pectoralis/anterior chest wall
4. General physical examination
   a. Cardiovascular
   b. Pulmonary
   c. Mental

Imaging

1. CT scan with contrast enhancement
   a. First-line examination with high reliability and ease of testing
   b. High-resolution, fine-cut, multiplanar CT to assess the integrity of the mandibular cortex
2. MRI
   a. Improved soft tissue delineation
   b. Rarely indicated
3. 18-F-fludeoxyglucose positron emission tomography (18F-FDG PET CT)
   a. Reveals cervical metastasis
   b. Reveals distant metastasis



Fig. 30.2. A, Advanced cancer of the floor of the mouth. **B,** Invasion of the mandible and the skin of the mentum.

4. Panorex
   a. Dentition
   b. Invasion of the mandible
5. Chest CT
   a. Cardiopulmonary evaluation
   b. Pulmonary metastasis
   c. Second primary in the lungs
6. 18-F-fludeoxyglucose positron emission tomography (18F-FDG PET CT)
   a. More accurate at detecting metastatic lymph nodes and distant metastasis than either CT or MRI
   b. Unfortunately its high cost prohibits 18F-FDG PET CT from being a frontline screening tool.

Indications

1. Wide local three-dimensional excision of soft tissue only; cancer not approaching or involving the mandible
2. Marginal mandibulectomy
   a. Cancer involving mandibular periosteum but not invading cortex
   b. Cancer in close proximity to the mandibular periosteum with no evidence of bone invasion
   c. Cancer abutting healthy dentition without involvement of the periodontal ligament
3. Segmental mandibulectomy
   a. Cancer invasion into the medullary matrix
   b. Cancer invasion to the occlusal surface of the mandible in an edentulous patient



Fig. 30.3. Patient referred for laryngectomy. Routine examination of the oral cavity revealed an early cancer of the floor of the mouth. This was managed by excision of the cancer and reconstruction with a split-thickness skin graft at the time of the laryngectomy.

   c. Edentulous patient with hypoplastic mandible with cancer that would otherwise meet criteria for marginal mandibulectomy
   d. Cancer abutting diseased dentition with involvement of the periodontal ligament
4. Mandibulotomy
   a. Improved access to the anteriorly based cancer of the floor of the mouth

Contraindications

1. Patient factors
   a. Medical comorbidities
2. Marginal mandibulectomy
   a. Invasion of the mandible
   b. Gross invasion of bone marrow
   c. Cancer recurrence after radiation
   d. Hypoplastic mandible
   e. Planned remnant of bone less than 1 cm
3. Segmental mandibulectomy
   a. To improve surgical exposure
4. Mandibulotomy
   a. Atrophic mandible

Preoperative Preparation

1. Consultations
   a. Anesthesia
   b. Reconstructive Surgeon
   c. Speech and Swallow Therapist
   d. Medical Oncologist
   e. Radiation Oncologist
   f. General surgeon if a feeding tube is anticipated
2. Preoperative pathology
   a. Ultrasound-guided fine-needle aspiration of suspicious cervical lymph node
   b. Biopsy of primary lesion
   c. Independent institutional review of biopsy performed at an outside hospital
3. Further preoperative preparation
   a. Panendoscopy—can be performed at the time of ablative surgery
   b. Extraction of carious teeth—may be extracted at time of ablative surgery
   c. Preoperative laboratory testing

1) Nutrition
   a) Gross abnormalities may delay surgery or restructure postoperative nutrition planning.
   b) Albumin: surrogate marker of long-term nutritional status, half-life of 20 days
   c) Prealbumin: surrogate marker of recent nutritional status, half-life of 8 days
2) Hemoglobin/hematocrit:
   a) If comorbidities such as anemia or significant cardiopulmonary history are present

OPERATIVE PERIOD

Anesthesia

1. Airway management
   a. Nasotracheal intubation—better exposure without the endotracheal tube in the oral cavity
   b. Tracheostomy

Positioning

1. The bed is turned 180 degrees.
2. A shoulder roll is placed, and the head is positioned on a foam pillow.
3. The patient's neck, lower face, and skin graft, free flap, or rotational flap sites are prepped and draped.

Perioperative Antibiotic Prophylaxis

1. Administered at the beginning of the operation and redosed every 6 hours
2. Continued for a full 24 hours postoperatively
3. Ampicillin/sulbactam
4. Clindamycin if the patient is allergic to penicillin

Monitoring

1. Muscle paralysis must be avoided during the neck dissection.
2. A nondepolarizing neuromuscular agent is usually required in order to gain appropriate access to the floor of mouth.

Instruments and Equipment to Have Available

1.
   a. Major head and neck set
   b. Oral retractor set
   c. Saw with both reciprocating blade and oscillating blade
   d. Tracheostomy set
   e. Free flap set
   f. Dental extraction set
   g. Otologic drill for bone contouring
2. Medications
   a. 1% lidocaine with 1:100,000 epinephrine
   b. Decadron 10 mg administered at the beginning of the operation
3. Other equipment
   a. Headlight
   b. Loupe magnification
   c. Operating microscope

Key Anatomic Landmarks

1. Extrinsic tongue muscles
   a. Hyoglossus muscle
   b. Geniohyoid muscle
2. Floor-of-mouth contents
   a. Mylohyoid muscle
      1) Forms the diaphragm of the floor of mouth
   b. Salivary glands
      1) Submandibular glands
      2) Sublingual glands
   c. Nerves
      1) Lingual nerve
      2) Hypoglossal nerve
      3) Mental nerve
   d. Vasculature
      1) Lingual artery
   e. Mandible

Prerequisite Skills

1. Neck dissection
   a. Selective—levels 1 to 4
   b. Modified radical
   c. Radical
2. Skin graft harvest
3. Reconstruction of mandible
   a. Plating
   b. Fibula free flap
   c. Scapular flap
4. Local rotational flaps
   a. Supraclavicular island flap
   b. Submental island flap
   c. Platysma flap
   d. Pectoralis major myocutaneous flap
5. Tracheostomy

Surgical Technique

1. The neck dissection first
2. Soft tissue resection only
   a. Dental bite block placed
   b. Plastic cheek retractor placed to retract buccal mucosa
   c. 2-0 silk suture placed through the tip of the tongue to provide dynamic traction of the tongue
   d. Bimanual palpation of the cancer is performed to confirm staging and (Fig. 30.4A) the operative plan.
   e. Marking pen used to draw at least a 1-cm margin of normal mucosa surrounding the cancer
   f. 1% lidocaine with 1:100,000 epinephrine is injected in the line of the incision only after bimanual palpation and planning of incision
   g. If the submandibular gland is not included with the neck dissection, care is taken to identify the opening of Wharton's duct and to plan the incision appropriately.
   h. If the papilla is within the area marked for surgical resections, the duct can be canalized with a lacrimal probe to aid in successful rerouting of the ductal architecture.
   i. After adequate time for the local vasoconstriction to take place, the mucosa is incised with either monothermy or needle-tip cautery.
   j. A 2-0 silk suture is placed in the anterior edge of the specimen to mark the anterior margin.
   k. The soft tissue is sharply dissected in an anteroposterior direction.
   l. The deep margin of resection is established at the level of the sublingual glands. The specimen is removed and sent to pathology for frozen section analysis (see Fig. 30.4B).
   m. Bleeding is addressed as it is encountered, and meticulous hemostasis is obtained either by way of individual vessel ligation or bipolar cautery (monothermy is to be avoided).
   n. If the submandibular gland is to be removed with the neck dissection, no attempt is made to preserve or reconstruct Wharton's duct.



Fig. 30.4. A, A 2- by 2-cm ulcerated exophytic squamous cell cancer. **B,** The specimen is removed, and complete hemostasis is obtained. **C,** A split-thickness skin graft is used to resurface the floor of the mouth. Some 2-0 silk sutures are left long as tie-overs to secure the Xeroform bolster. A few tacking sutures are placed through the graft to secure it to the defect. **D,** The skin graft healed to the floor of the mouth. **E,** Full dentures can be accommodated by the healed operative site.

o. If the submandibular gland is preserved and the proximal ductal architecture is contained within the resection, ductal rerouting should be performed.
p. This is most easily achieved by following the lacrimal probe placed in the duct at the beginning of the case.
q. The end of the transected duct is then sutured to the remnant floor of the mouth mucosa.
   1) An 8- to 10-mm incision is then made along the length of the duct.
   2) The ductotomy is then brought cephalad toward the floor of the mouth mucosa and marsupialized to the surrounding tissue using 4-0 chromic sutures.
r. Reconstruction
   1) Split-thickness skin graft (see Fig. 30.4C)
   2) Xeroform packing is used as a bolster and secured to the surrounding mucosa with 2.0 silk sutures.
s. An orogastric tube is used to remove stomach contents.
t. A Dobhoff feeding tube is then passed and secured with a 3-0 silk secured to the nasal septum.
u. The procedure is terminated.

3. Transoral soft tissue resection plus marginal mandibulectomy
   a. A dental bite block is placed.
   b. A disposable plastic cheek retractor is placed to retract the buccal mucosa.

c. The mucosal margins of resection are outlined at the beginning of the case with a surgical marker.
d. The lateral margins of resection should include 1.0 to 1.5 cm of normal bone.
e. Although the primary cancer can be resected separately from the mandible, every effort should be made to resect both the mandible and soft tissue en bloc to aid in the orientation for the pathologist.
f. If the patient is dentulous, the tooth adjacent to the planned margin is extracted in preparation for vertical osteotomies, which are carried out in the tooth socket, preserving as much bone as possible to support the residual tooth without compromising the surgical margins.
g. A needle-tip bovie is used to make the index incisions through the mucosa and carried down through periosteum onto the mandibular cortex.
h. The incisions are extended over the alveolar ridge and connected anteriorly.
i. A Freer or periosteal elevator is used to gently elevate the mucoperiosteum to expose the mandibular cortex.
j. The osteotomies are then drawn on the bone with a marking pen.
k. A horizontal reciprocating saw is positioned at the anterior aspect of the canine extraction site in preparation for the vertical osteotomy.
l. In planning the inferior extent of the vertical osteotomy, care is taken to remove only the alveolar process while preserving at least 1.0 cm of residual bone along the inferior margin of the mandible.
m. The horizontal osteotomy is then created to connect the two vertical osteotomies.
n. It is important that the buccal and lingual plates of bone be cut all the way through so as to prevent splintering or fracturing the bone.
o. Once the lingual cortex is cut through and the mandibular fragment is freed, the bone is retracted superiorly and posteriorly along with the soft tissue and the rest of the resection is then carried out.
p. The bony margins of the mandible are smoothed with a cutting bur to remove any spicules of bone or sharp corners.
q. A split-thickness skin graft can be used to resurface both the soft tissue and the residual mandibular bone.
r. Reconstruction
   1) Split-thickness skin graft (Fig. 30.5)
   2) Submental island flap
   3) Supraclavicular island flap
   4) Radial forearm free flap (Fig. 30.6)
s. An orogastric tube is passed to remove the stomach contents.
t. A Dobhoff feeding tube is then passed and secured to the nasal septum with a 3-0 silk.
u. The procedure is terminated.

4. Extensive lesions of the floor of the mouth without bone involvement
   a. The tracheostomy is performed, and the patient is prepared and draped.
   b. Bilateral neck dissections are performed.
   c. Two main surgical approaches are available: intraoral/cervical "pull through" or mandibulotomy.
   d. Intraoral/transcervical "pull through"
      1) The lateral margins surrounding the cancer are established with a monothermy needle tip and extended with sharp dissection.
      2) At the level of the sublingual glands, the cancer is then reached via a cervical approach.
      3) A subplatysmal anterior cervical facial flap is raised to the level of the inferior mandible.
      4) The mylohyoid and digastric muscles are transected to enter the deep aspect of the floor of the mouth.

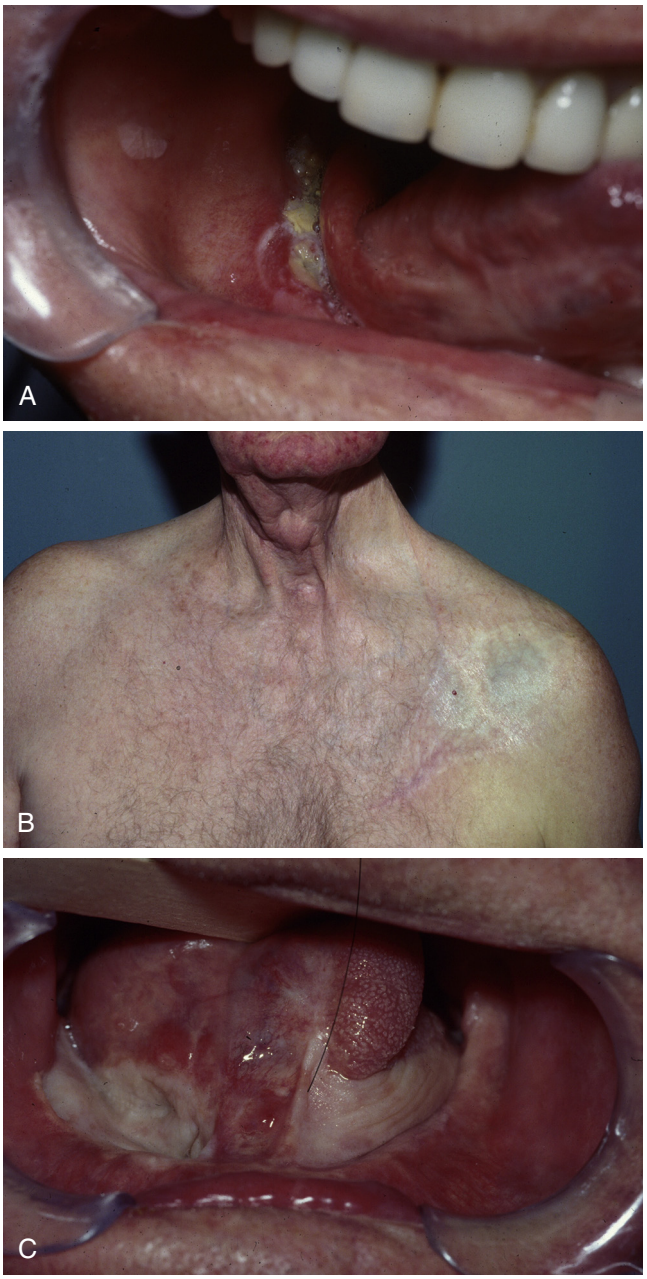

Fig. 30.5. A, Patient with a second primary cancer of the floor of the mouth. A first primary cancer had been excised elsewhere from the left floor of the mouth 25 years before this second primary appeared. The defect had been reconstructed with a deltopectoral flap. **B,** Photo revealing the previous donor site of the deltopectoral flap. **C,** Left: Floor of mouth reconstructed with deltopectoral flap. Right: Floor of mouth reconstructed with split-thickness skin graft.

      5) The floor-of-mouth specimen is then delivered into the neck, and the cancer is resected.
      6) The hypoglossal and lingual nerves, which were identified during the neck dissection, can be safely protected and preserved as long as this does not compromise ultimate oncologic control.
      7) Reconstruction
         a) Pectorals major myocutaneous flap
         b) Radial forearm free flap
         c) Supraclavicular island flap
      8) An orogastric tube is passed to remove stomach contents.

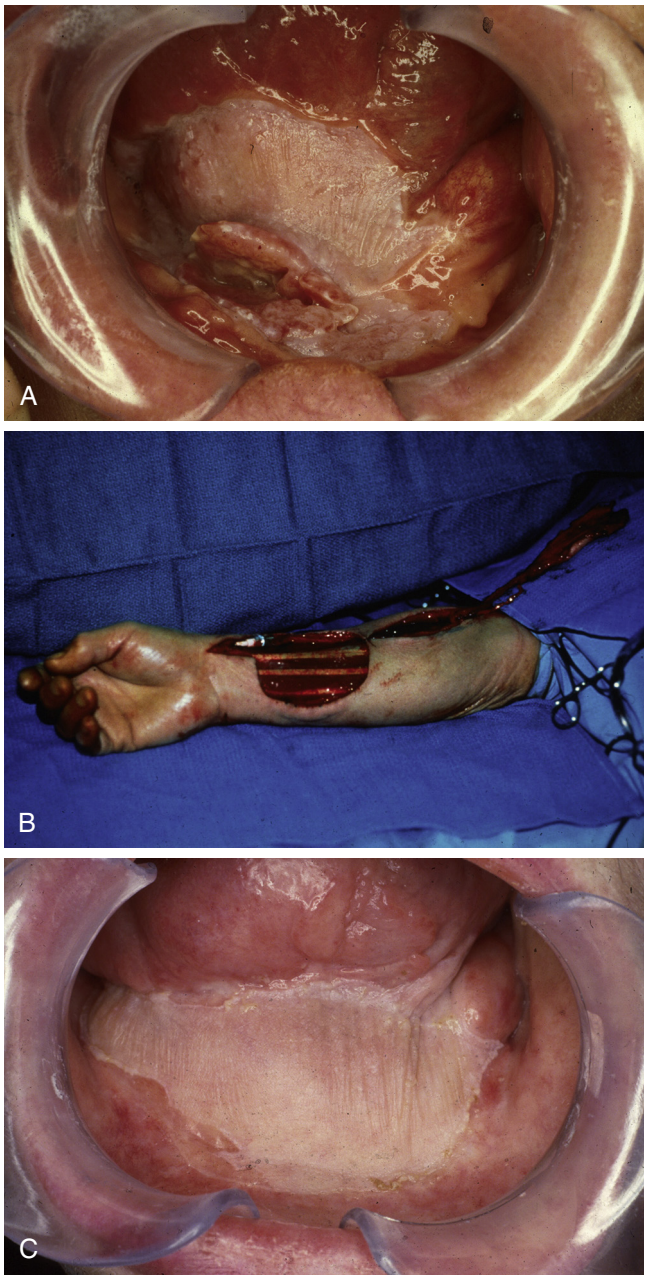

Fig. 30.6. A, Patient with recurrent squamous cell cancer. The remains of the skin graft are seen posterior to the recurrent cancer. Excision of the recurrent cancer and a marginal mandibulectomy of the anterior segment of the mandible were carried out en bloc. **B,** A radial forearm free flap being harvested. **C,** The radial forearm flap is soft and pliable; it does not restrict the mobility of the tongue.

9) If g-tube is not present, a Dobhoff feeding tube is then placed and secured to the nasal septum with 3-0 silk.
10) The procedure is terminated.

e. Mandibulotomy
1) Visor flap
a) A superior cervical facial flap is elevated up to the level of the inferior mandible
b) The gingival-buccal sulcus is incised using needle-tip monothermy cautery 1 cm away from the mandible.
c) Care is taken to avoid removing the periosteum off of the anterior table of the mandible or to injure the mental nerves.
d) The cervical facial flap is then connected to the gingival-buccal sulcus incision.
e) The periosteum on the anterior tables of the mandible is then incised to expose the underlying cortex.
2) Lip split
a) A notched incision is designed within the midline of the lower lip to aid in aesthetic camouflage.
b) The incision is extended inferiorly until it meets the underlying neck dissection incision.
c) The plane is dissected toward the periosteum, which is then incised to expose the cortex of the underlying mandible.
3) After exposure of the mandible, the reconstruction plate is prebent over the native contour of the mandible.
a) An oscillating Stryker saw is then used to perform a midline mandibulotomy through both the anterior and posterior tables.
b) This exposes the cancer anteriorly, at which point the cancer can be resected completely.
4) Reconstruction
a) Mandibular plating
b) Split-thickness skin graft
c) Pectoralis major myocutaneous flap
d) Radial forearm free flap
e) Supraclavicular island flap

5. Segmental mandibulectomy
a. A visor flap or lip-split procedure is performed for access. Some patients will have destruction of the anterior segment of the mandible with infiltration of the skin of the chin, which is taken with the specimen.
b. Dental extractions are performed in the dentulous patient at the site of osteotomy.
c. Vertical osteotomies are planned at least 1 cm from the tumor edge.
d. The mucosa is incised with monothermy cautery.
e. A periosteal or Freer elevator is used to free the periosteum from the underlying mandibular cortex.
f. Osteotomies are made with a reciprocating saw positioned at the anterior aspect of the tooth extraction site.
g. The cancer, the mandible, and overlying skin, if necessary, can then be resected en bloc as previously described (Fig. 30.7).

Common Errors in Technique

1. Failure to properly orient the specimen
2. Overly aggressive marginal mandibulectomy, leaving an inferior alveolar ridge of less than 1 cm of remaining bone
3. Failure to fully release both the buccal and lingual surfaces of the mandible with the osteotomies, leading to splintering or fracture of the surrounding remnant bone
4. Placement of the vertical osteotomy on the posterior aspect of the tooth extraction socket, leaving poor bone support for residual teeth

POSTOPERATIVE PERIOD

Postoperative Management

1. Skin graft or rotational flap
a. Bolster removed on day 5
b. 15 mL oral rinse 4 times daily for 1 week
c. Trickle tube feedings via nasogastric tube started on postoperative day 1
d. PO regimen
1) Clear liquids at 1 week for nonirradiated patients
2) Clear liquids at 2 weeks for irradiated patients

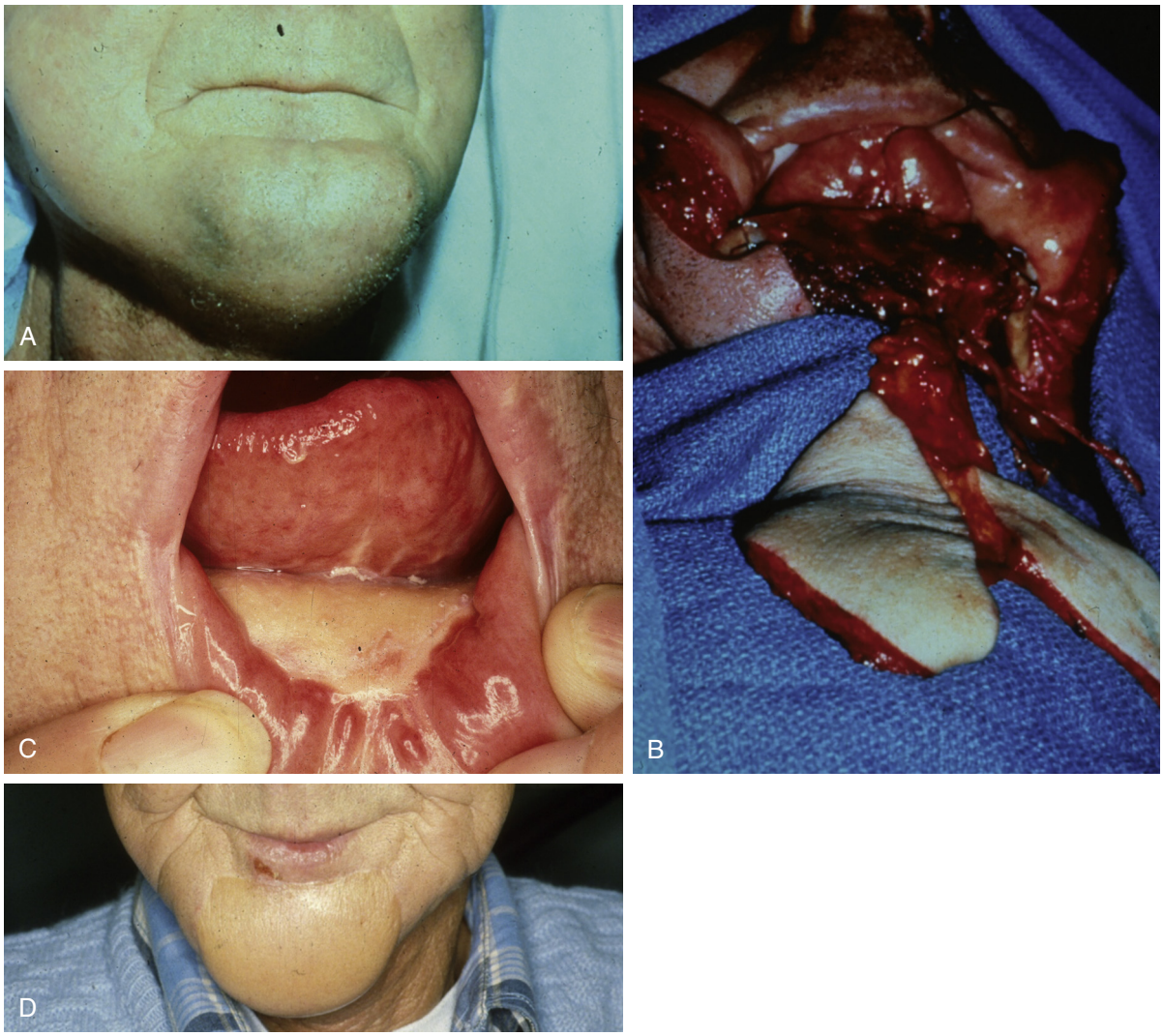

Fig. 30.7. A, Patient with a squamous cell cancer of the floor of the mouth, which destroyed the anterior segment of the mandible and infiltrating the skin of the chin. **B,** A scapular osteocutaneous free flap was bivalved, and the bone used to replace the resected anterior segment of the mandible. **C,** One skin flap was used to resurface the floor of the mouth. **D,** The other flap was used to resurface the chin.

   e. Drain in place until less than 30 mL collected in a 24-hour period
   f. Speech and swallow rehabilitation consult
   g. Pain control
   h. Skin graft healed and full dentures fabricated (see Fig. 30.4). Patients who have had a marginal mandibulectomy may need dental implants to stabilize the lower dentures.
2. Free flap
   a. Intensive care unit (ICU) for 48 hours postoperatively with hourly flap checks
   b. Routine tracheostomy care
   c. Soft tissue postoperative management as above
   d. After 1 week of clear liquid diet, 6 weeks of soft diet
   e. Drain in place until less than 30 mL is collected in 24 hours
   f. ICU for 48 hours postoperatively with hourly flap checks
   g. Drain in place until less than 30 mL is collected in 24 hours

Complications

1. Orocutaneous fistula
   a. Monitor drain output.
   b. Examination of suture line and surrounding skin
2. Hematoma
   a. Monitor for soft tissue swelling intraorally and in the neck.
   b. Monitor for changes in skin color.
3. Wound infection
   a. Monitor drain output for purulence.
   b. Monitor skin incision for erythema and discharge.
4. Systemic infection
   a. Monitor vital signs.
5. Damage to hypoglossal nerve
   a. Postoperative examination of tongue for midline and lateral mobility
6. Damage to lingual nerve
   a. Postoperative assessment of tongue sensation
7. Pathologic mandibular fracture
   a. Bimanual palpation of mandible
   b. Postoperative Panorex with increased clinical suspicion
8. Mandibular nonunion
   a. Bimanual palpation of mandible
   b. Postoperative Panorex with increased clinical suspicion

Alternative Treatment Regimens

1. Radiation
2. Chemoradiation
3. Brachytherapy

DISCUSSION

Evidence-Based Medicine Question

How should the clinically negative neck (cN0) be addressed in early-stage cancers of the floor of the mouth?

In advanced-stage cancers (T3–T4), bilateral neck dissections have become the standard of care. Likewise, early-stage (T1–T2) floor-of-mouth cancers with either clinical or radiologic evidence of cervical metastasis will receive an ipsilateral neck dissection at the time of surgery. However, in early-stage cancers (T1–T2) with a cN0 neck, the role of neck dissection remains a controversial topic. There are currently three competing options for these patients: active surveillance, sentinel lymph node biopsy, and elective neck dissection. For many practitioners and patients, active surveillance is a seductive treatment option. It avoids the high cost of unnecessary treatment and complications associated with surgical intervention. Moreover, nearly 70% of patients who choose watchful waiting will ultimately require no further intervention.[6] Unfortunately the remaining 30% of patients will eventually develop cervical lymph node metastasis.[6] The development of nodal relapse is devastating, as only about half of these patients can be successfully salvaged.[6] Sentinel lymph node biopsy (SLNB) is a relatively new method of addressing the neck. The primary advantage of SLNB, like active surveillance, is the avoidance of the morbidity associated with an elective neck dissection. In many oral cavity cancers, the utility of SLNB is promising. However, conflicting results have been reported for its role within the management of early floor-of-mouth carcinoma. Ross et al. demonstrated that the sensitivity of SLNB in floor-of-mouth cancer was only 80%, greatly decreased from other oral cavity subsites (near 100%).[7] The same study found that nearly 4% of patients treated with SLNB developed metastatic neck disease within 24 months, casting doubt on its efficacy with floor-of-mouth neoplasms.[7] The final treatment option is elective neck dissection. Patients within this treatment arm are subject to higher treatment costs, longer hospitalizations, and increased morbidity. However, a prospective randomized control trial of T1–T2 oral cavity cancers demonstrated a survival benefit of 23.6% by undergoing elective neck dissection at the time of surgery.[8] The study found that eight patients would have to undergo elective neck dissection to prevent one death, while four patients would have to be treated to prevent one nodal relapse.[8] The findings of this study support our own institutional practice of performing elective neck dissection for all early-stage cancers of the floor of the mouth.

Editorial Comment

Cancers of the floor of the mouth are particularly challenging due to the anatomic proximity to the mandible, the lingual and hypoglossal nerves, and a rich lymphatic network extending to both sides of the neck. Careful surgical planning must account for all of these structures. Furthermore, due to tongue suspension to the mandible by the genioglossus muscles at the genial tubercle and the need for bilateral lymph node assessment, edema and structural loss of natural airway support must be acknowledged, with a low threshold for tracheostomy. Assessment of the lymphatics surgically is typically done by selective neck dissections bilaterally of levels I to III for the clinically negative neck (N0), especially for primary cancers with greater than 4 mm depth of invasion. SLNB is emerging as a potentially effective minimally invasive assessment of the neck for these cancers. The positive neck may require additional levels of dissection depending on the extent of nodal disease, but with an emphasis on preservation of uninvolved nonlymphatic structures. Reconstruction should be predicated upon maximizing speech and swallowing function, principally by reestablishing the anterior mandibular contour, anterior tongue suspension, and supporting maximal tongue mobility. Skin grafts and pliable, thin free flaps provide the best opportunity to achieve these reconstructive goals.

Careful orientation of the primary specimen and neck dissection/nodal specimens is of critical importance. Margin-negative resection with greater than 18 lymph nodes in each selective neck dissection represents a quality resection that enhances the predictive value of pathologic prognostic information. Close or positive margins, multiple cancer-positive lymph nodes, perineural invasion, and lymphovascular invasion are indications for postoperative adjuvant radiotherapy. Chemotherapy should be added in the adjuvant setting if margins are positive and extracapsular spread is present in the positive lymph nodes.

Jeffrey Bumpous

Access the review questions online at http://www.expertconsult.com



REFERENCES

1. Ribeiro K, Kowalski L, Latorre M. Perioperative complications, comorbidities, and survival in oral or oropharyngeal cancer. Arch Otolaryngol Head Neck Surg 2003;129:219–228.
2. Shaha AR, Spiro RH, Shah JP, et al. Squamous carcinoma of the floor of the mouth. Am J Surg 1984;148:455–459.
3. Hammerlid E, Wirblad B, Sandin C, et al. Malnutrition and food intake in relation to quality of life in head and neck cancer patients. Head Neck 1998;20:540–548.
4. Mick R, Vokes EE, Weichselbaum RR, et al. Prognostic factors in advanced head and neck cancer patients undergoing multimodality therapy. Otolaryngol Head Neck Surg 1991;105:62–73.
5. Shaha AR. Preoperative evaluation of the mandible in patients with carcinoma of the floor of mouth. Head Neck 1991;13:398–402.
6. McGuirt Jr WF, Johnson JT, Myers EN, et al. Floor of mouth carcinoma: the management of the clinically negative neck. Arch Otolaryngol Head Neck Surg 1995;121:278–282.
7. Ross G, Soutar D, Gordon MacDonald D, et al. Sentinel node biopsy in head and neck cancer: preliminary results of a multicenter trial. Ann Surg Oncol 2004;11:690–696.
8. D'Cruz AK, Vaish R, Kapre N, et al. Elective versus therapeutic neck dissection in node-negative oral cancer. N Engl J Med 2015;373:521–529.

REVIEW QUESTIONS

1. Which of the following is an indication for rim mandibulectomy?
   a. Invasion of periosteum and cortex in an edentulous patient
   b. Invasion of cortex in a dentulous patient
   c. Invasion of periosteum without invasion of cortex
   d. Submental lymphadenopathy noted on CT

2. Which of the following is a reasonable method of treating the neck in early stage (T1/T2) cancer of the floor of the mouth with a clinically negative neck cN0?
   a. Ipsilateral elective neck dissection
   b. Watchful waiting
   c. Sentinel lymph node biopsy
   d. All of the above

3. Appropriate preoperative workup for all patients includes all of the following, except
   a. Assessment of malnutrition
   b. Swallowing study
   c. CT scan
   d. Tissue biopsy

4. Which of the following describes an accurate location of the mental nerve?
   a. In a vertical plane beneath the second incisor
   b. In a vertical plane beneath the first molar
   c. In a vertical plane beneath the central incisors
   d. Midway between the first molar and second incisor

31 Operative Otolaryngology: Excision of Buccal Carcinoma

Donovan Eu, Chwee M. Lim

INTRODUCTION

The buccal mucosa is an uncommon site for oral cavity cancer (SCC) and comprises 5% to 10% of all intraoral squamous cell carcinoma (IOSCC) in North America and Europe. However, it is more commonly seen among Taiwanese Chinese and in India, where betel nut chewing is prevalent in these communities. Among the published reports, buccal SCC was found to comprise between 23% and 37% of all IOSCC in a Taiwanese cohort.[1] Most patients with buccal SCC are in the fifth to sixth decade of life, and other risk factors, such as smoking and alcohol consumption, are also commonly encountered in these patients.

Treatment of buccal SCC is primarily wide surgical excision with negative margins, followed by adjuvant radiation or chemoradiation, depending on adverse clinicopathologic features. In patients with gross local disease that is unresectable (e.g., involvement of internal carotid artery), treatment is usually palliative radiation. Complete excision of buccal SCC lies in the thorough understanding of the three-dimensional surgical anatomy of the buccal space and its relevant surrounding areas, so as to anticipate possible spread of the cancer and avoid leaving microscopic disease behind in the surgical field.

KEY OPERATIVE LEARNING POINTS

1. Buccal SCC is in close proximity to the underlying buccal space, which can potentially lead to subclinical infiltration of the masticator space, infratemporal fossa, and pterygopalatine fossa.
2. Surgery for buccal SCC requires a thorough three-dimensional understanding of the related surgical anatomy so as to achieve complete surgical extirpation.
3. Due to the proximity of the buccal space to the retromolar trigone and the inferior and superior alveolar ridges marginal mandibulectomy and/or inferior maxillectomy may be necessary to achieve wide surgical margins. Similarly, excision of the skin of the cheek may be necessary for deep infiltration of the tumor to the dermis.
4. Reconstruction of the surgical defect is necessary to reconstitute both form and function of the oral cavity. Specifically, reconstitution of the oral commissure may be necessary to prevent drooling in the postoperative period.

PREOPERATIVE PERIOD

History

1. History of presenting illness
   a. The duration and progression of the buccal primary should be ascertained.
   b. Local complications such as bleeding should be assessed. Speech and swallowing impairment may also occur due to fixation of the tongue by the cancer.
   c. Trismus should be assessed because it may signify posterior extension into the pterygoid muscles, or it may result from submucosal fibrosis from chronic betel nut chewing among these patients.
   d. Risk factors such as alcohol ingestion, smoking, and betel nut chewing should be sought.
2. Past medical history
   a. Previous history of cancer of the head and neck and previous treatment with either surgery or radiotherapy are important for management.
   b. The patient's overall medical condition should be thoroughly evaluated for assessment of perioperative anesthetic risks.
   c. Antiplatelet agents may increase perioperative bleeding and should be omitted before surgery. The decision to either stop or bridge the need of anticoagulation should be made with the patient's primary medical physician.

Physical Examination

1. Examination of the oral cavity
   a. All oral cavity subsites should be examined for possible synchronous cancers or premalignant lesions.
   b. The patient's ability to open his or her mouth should be evaluated for trismus and its severity. This may be a sign of medial pterygoid muscle involvement by the cancer. This may either represent unresectability or signify the need of a combined skull base approach to have complete tumor extirpation.
   c. Intraoral extension to the tongue, gingival, superior or inferior alveolar ridge, and retromolar trigone (Fig. 31.1) is evaluated.
   d. The mobility of the tongue is assessed for involvement of the extrinsic tongue muscles.
   e. The distance of the cancer from the oral commissure should be measured. This allows the surgeon to identify whether some form of oral competence reconstitution will be necessary following resection.
   f. Bimanual palpation should be also performed to identify possible fixation of the cancer to the overlying dermis. A peau d'orange appearance of the cheek skin, if present, is an accurate indicator of subdermal lymphatic infiltration by the cancer.
   g. Facial nerve function should be assessed, in particular the function of the buccal branch with regard to upper lip elevation and symmetry of the nasolabial fold.
2. Nasoendoscopy
   a. Nasoendoscopy is performed to evaluate for extension of the cancer to the nasal cavity in instances when the hard palate is involved.
   b. The upper airway should be evaluated, especially in patients with trismus, so as to anticipate a possible difficult airway during induction of general anesthesia.
   c. Possible second primary cancers of the head and neck should be excluded.
3. Head and neck examination
   a. The neck is examined for possible cervical lymph node metastasis.
   b. The sensation of the lower teeth is assessed as it may be affected due to involvement of the inferior alveolar nerve.



Fig. 31.1 Right buccal squamous cell carcinoma with involvement of retromolar trigone.

Imaging

Computed Tomography (CT) Scan

CT gives reliable information on extension into bone, especially if involvement of the mandible is suspected. CT has been shown to achieve 100% sensitivity and 88% specificity for assessment of invasion of the mandibular cortex.

Magnetic Resonance Imaging (MRI)

MRI is frequently used to evaluate the deep extension of the buccal SCC because it gives excellent visualization of the masticator space, infratemporal fossa, and pterygopalatine fossa. Features of masticator space involvement include extension of soft tissue mass to the masticator space, effacement of the masticator adipose tissue, infiltration of the muscles of mastication, such as the pterygoid muscles, and destruction of the ramus of the mandible. Displacement of adipose tissue by cancer within the pterygopalatine fossa on noncontrasted T1-weighted imaging is a sign of posterior extension into the pterygopalatine fossa.

MRI imaging also carries a higher sensitivity in detecting perineural spread as compared with CT.[2] MRI features of perineural invasion include enhancement of the nerve, nerve enlargement, and widening of the respective neural foramina.

Angiography

Angiography is seldom required unless there is suspicion of encasement of the internal carotid artery.

Indications

1. T1-T4a buccal SCC
2. Select T4b cancer (masticator space involvement that is inferior to the mandibular notch)

Involvement of the masticator space is classified as T4b disease by the American joint consensus committee (AJCC) 2002 staging system. This classification is defined as such because any involvement of the masticator space will imply incomplete surgical eradication of cancer due to the free communications to the deeper infratemporal and pterygopalatine fossa. In this instance, a compartmentalized resection of cancer will be unachievable.

However, clinical studies suggest that selected cancers with limited invasion of the masticator space might benefit from surgical extirpation. In a retrospective study performed by Liao et al., 45 patients with T4b oral cavity SCC (majority buccal SCC) underwent surgical resection. Patients with involvement of the masticator space that was inferior to the mandibular notch achieved improved disease-free survival than did patients with extension beyond the mandibular notch.[3]

3. Surgery is rarely performed for palliation, although it may be necessary to palliate a fungating cancer that is bleeding.

Contraindications

1. Involvement of the masticator space that is superior to the mandibular notch
2. Involvement of the infratemporal fossa, pterygopalatine fossa, and encasement of internal carotid artery by cancer
3. Preexisting medical conditions that carry significant perioperative anesthetic risks

Preoperative Preparation

1. Three-dimensional perception of the buccal SCC should be appreciated with clinical examination and radiologic assessment
2. The defect following surgery should be anticipated and communicated with the reconstructive surgeon.

OPERATIVE PERIOD

Surgery is the mainstay of treating buccal SCC, and it aims to completely resect the tumor with negative margins. A wide 2-cm margin surrounding the tumor is mapped out prior to resection.

Anesthesia

General Anesthesia

General anesthesia is typically used in order to control the upper airway during surgery. An orotracheal tube is typically used and with the tube positioned opposite to the side to be resected. Alternatively, a nasotracheal tube may be used, and the advantage is that it allows a fuller visualization of the oral cavity. In locally advanced cancers, a planned tracheostomy is often created for the purpose of airway control postoperatively. This is often performed when a bulky flap is anticipated for reconstruction of the buccal space defect.

Positioning

Supine

The patient is placed supine, and a shoulder roll is placed for mild neck extension. When a free microvascular flap or a pedicled muscle flap is required, the donor site is exposed to allow for concurrent surgery.

Preoperative Antibiotic Prophylaxis

Antibiotics with appropriate anaerobic coverage are ideally chosen for perioperative antibiotic prophylaxis. A broad-spectrum antibiotic, such as amoxicillin with clavulanate, may be used. In patients with penicillin allergy, clindamycin is a good alternative.

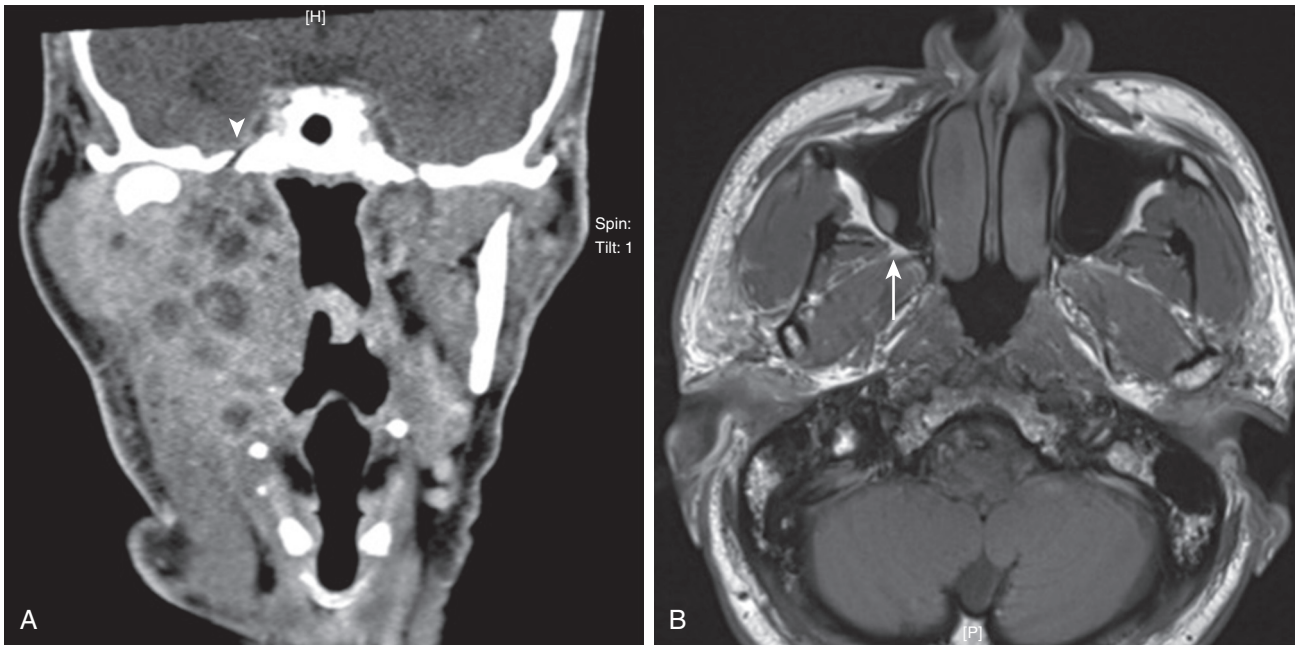

Fig. 31.2 A, Coronal computed tomography of buccal tumor with extension to masticator space and infratemporal fossa. *White arrowhead* demonstrating foramen ovale. [H] is a radiological marking representing the position of the head. **B,** T1 magnetic resonance imaging of buccal space with *white arrow* demonstrating extension to pterygomaxillary fissure. [P] is a radiological marking that indicates posterior direction on the axial plane.

Instruments and Equipment to Have Available

1. A mouth gag (e.g., Jennings gag) is useful to expose the entire buccal mucosa.
2. An oscillating saw should be available when a mandibulectomy is anticipated.

Key Surgical Anatomy and Clinical Implications

Buccal Space

The buccal mucosa is composed of nonkeratinizing squamous epithelium, which is where SCC arises. Deeper to this mucosal layer lies the buccinator muscle, which forms the medial boundary of the buccal space. The buccal space and adjacent masticator space are important anatomic spaces because they communicate with the infratemporal fossa and pterygopalatine fossa via the foramen ovale and pterygomaxillary fissure, respectively (Fig. 31.2). Therefore involvement of these spaces by the cancer may be associated with extension into these deeper anatomic spaces.

The contents of the buccal space includes the buccal adipose tissue pad, parotid duct, minor salivary glands, the facial artery and its branches, and lymphatic channels and branches of the facial and mandibular division of the trigeminal nerve (V3) (Fig. 31.3). Cancer infiltration of this space should alert the surgeon to possible perineural spread along V3, either proximally into the foramen ovale or distally along the inferior alveolar nerve through the mandibular foramen. In this regard, sacrifice of V3 may be necessary in locally advanced buccal SCC involving the buccal space. Frozen section evaluation of V3 may allow the surgeon to trace the resection margins within the surgical limits and allow adjuvant radiation to be delivered postoperatively.

Anterolateral to the buccal space lies the superficial layer of the deep cervical fascia and the muscles of facial expression. The superficial musculoaponeurotic system (SMAS) is just superficial to this, and the superficial adipose tissue compartment lies between the SMAS and the external skin. Because the distance from the cheek skin to the buccal space is often small, clinical evaluation of "dimpling" of the subdermis may suggest early involvement of the skin of the cheek and requires a wide excision of the cheek skin in order to avoid a close surgical margin.

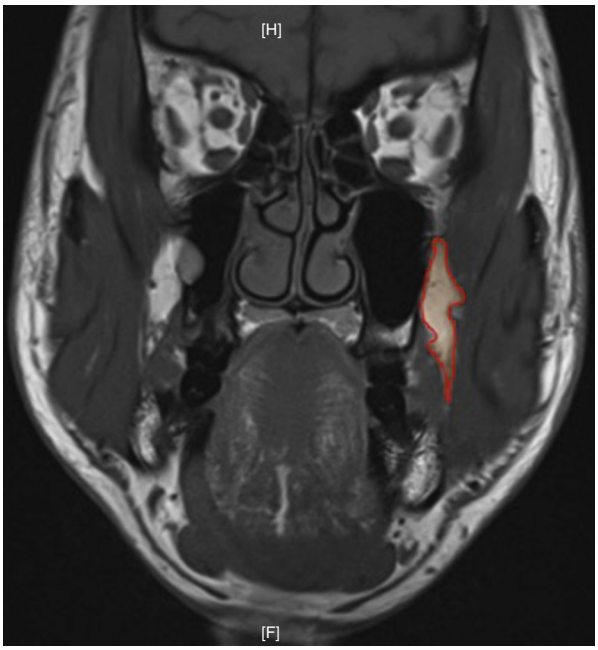

Fig. 31.3 Left buccal space highlighted in *red*. [H] is a radiological marking that represents the direction of the head, while [F] represents the direction of the feet.

Masticator Space

Posterolateral to the buccal space lies the masticator space and the deep lobe of the parotid gland. The masticator space is contiguous with the buccal space, and it lies in the potential space between the lower border of the mandible and the

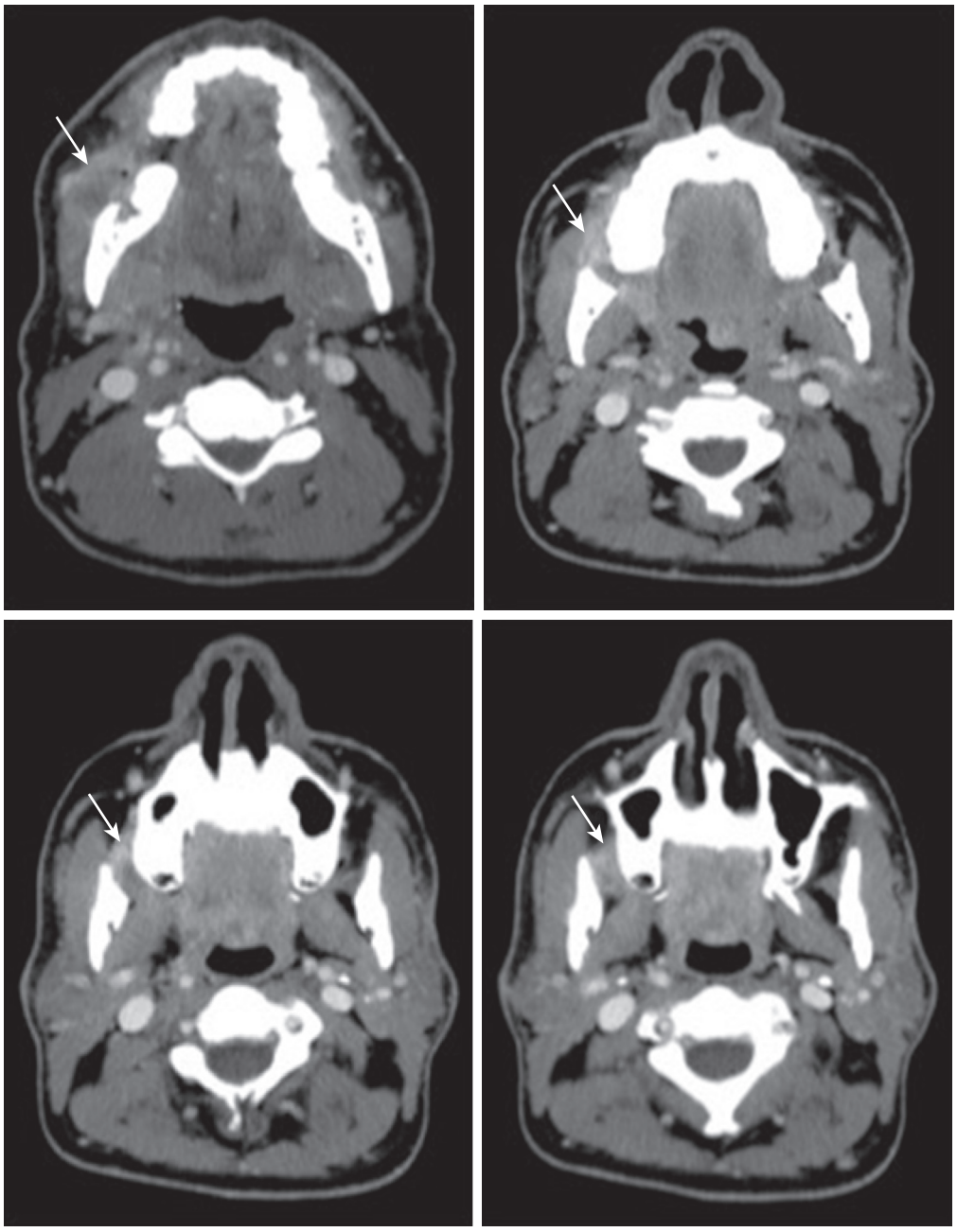

Fig. 31.4 Carcinoma of the right buccal space *(white arrows)* extending from masticator space to infratemporal fossa.

medial pterygoids. The medial aspect of the masticator space communicates freely with the infratemporal fossa and the pterygopalatine fossa, as described earlier (Fig. 31.4).

Cancer of the buccal mucosa may extend contiguously within the oral cavity to involve the other subsites, as follows (Table 31.1).

Depending on the local extent, surgery will need to encompass these subsites so as to achieve a wide en bloc resection. Specifically, considerations for inferior maxillectomy and/or marginal mandibulectomy must be anticipated if the tumor encroaches onto the superior alveolar ridge and retromolar trigone, respectively. Correspondingly, the resultant defect needs to be addressed appropriately with a suitable flap reconstruction. Specifically, achieving a good oral competence to avoid drooling, as well as sealing off the oronasal communication (in the instance of partial inferior maxillectomy), is an important consideration for a good functional outcome.

TABLE 31.1 Extension Into Other Oral Cavity Subsites

Direction of Extension	Oral Cavity Subsites Involved
Anteriorly	Oral commissure
Posteriorly	Retromolar trigone
Posterosuperiorly	Maxillary alveolus
	Hard palate
Caudally	Mandibular cortex
	Alveolus
	Floor of mouth

Prerequisite Skills

Sound knowledge and understanding of the anatomy of the buccal space, masticator space, and the pterygopalatine fossa are necessary.

Surgical Technique

Airway Control

Methods of securing the airway before induction depend largely on patient and disease factors. The size of the oral cavity tumor, presence of teeth, neck stiffness, retrognathia, and the modified Mallampati scores are important considerations to predict a difficult airway. Disease factors such as the size of the tumor, its extension into the oral cavity, and the infiltration of the pterygoid muscles leading to trismus further contribute to difficulties with intubation. In patients with an anticipated difficult airway, an awake fiberoptic intubation can be performed by an experienced anesthesiologist. Nasal intubation, whenever feasible, should be performed so as to allow for greater visualization and maneuverability in the surgical field.

A tracheostomy under local anesthesia is another option if awake fiberoptic intubation is not feasible due to patient or physician factors. It is our practice to perform a temporary tracheostomy in patients with locally advanced disease where a bulky flap reconstruction is planned. This will facilitate airway protection in the immediate postoperative period.

Surgical Approach

Transoral. Transoral resection is an ideal approach in patients with T1 and most T2 cancers. Resection can be safely accomplished when the tumor is anteriorly based and minimally infiltrative and when there is no associated trismus. The oral cavity is widely exposed using a Jennings mouth gag, and the lesion is excised with a 2-cm margin. The depth of excision is typically at the plane before the buccal adipose tissue pad. Frozen sections are used to ensure negative surgical margins upon completion of resection.

Cheek Flap. A lower cheek flap is usually performed in patients with more extensive cancer because this approach affords a greater exposure for wide excision of the cancer. This is particularly so for cancers that extend posteriorly toward the retromolar trigone. When the cheek skin is clinically involved (indicated by induration or dimpling of the skin or on MRI evaluation demonstrating dermal infiltration), the cheek skin will be sacrificed for oncologic purpose and an inferior cheek flap is not indicated.

In elevating a cheek flap, the lip is split in the midline down to the cortex of the mandible and continued laterally along the submandibular skin crease on the medial aspect. The mandibular periosteum is elevated up to the mental foramen so as to preserve the mental nerve. This foramen is usually directly inferior to the mandibular second premolar. If a mandibulectomy is planned due to cortical involvement of the mandible, sacrifice of the mental nerve is often necessary in order to rule out perineural involvement along the proximal inferior alveolar nerve. Frozen section of both proximal inferior alveolar nerve and distal mental nerve margins is required in this setting.

In instances in which the mental nerve is preserved, the inferior cheek flap is retracted laterally by incising the alveolar mucosa with an adequate cuff (at least 5 mm) to facilitate primary closure. With the flap elevated to the mental foramen, a good exposure of the posterior aspect of the oral cavity is usually obtained.

Mandibulotomy. A mandibulotomy approach may be necessary in more extensive T4 cancers that encroach medially onto the floor of the mouth or ventral tongue or when posterior extension to the base of the tongue along the glossotonsillar sulcus is encountered. In these instances, en bloc resection of these cancers may be difficult with an cheek flap approach, and greater exposure may be necessary through a mandibulotomy.

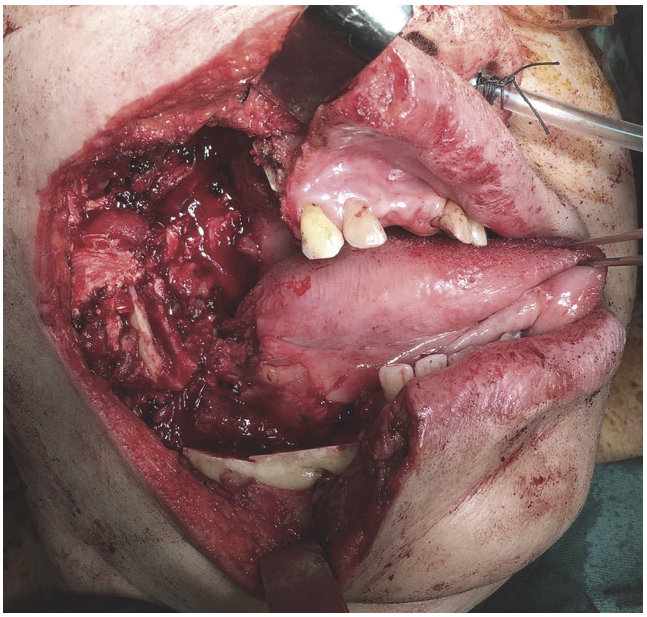

Fig. 31.5 Right inferior maxillectomy, marginal manidbulectomy, and excision of overlying skin with the oral commissure.

If mandibulectomy is necessary as part of the resection, the surgeon should plan the site of the mandible split so as to avoid two separate osteotomies, which may result in devascularization of the intervening mandibular segment. For example, if a posterior marginal mandibulectomy is planned, the surgeon should perform the mandibulotomy at the body of the mandible where the intended bone margin is anticipated and plate the osteotomy sites after resection. In patients with thin mandibular cortices, a segmental mandibulectomy may be a more appropriate option.

Extension to the Inferior Maxilla/Masticator Space. Buccal SCC that extends posterosuperiorly to the maxillary gingiva will require a partial inferior maxillectomy (Fig. 31.5). This resection can be achieved transorally, especially in a small cancer. In this instance, the upper gingival incision is incised onto the premaxilla and a maxillotomy is performed to ensure that there is no extension of the cancer into the maxillary sinus. An osteotomy is made over the lateral maxillary buttress to release the lateral attachment. Similarly, the hard palate is partially resected depending on the extent of the cancer to release the medial attachment.

When a subtotal maxillectomy is planned, a lateral rhinotomy approach is added to improve the exposure for complete surgical extirpation. Care is taken as one performs the posterior osteotomy on the pterygoid plate so as to ensure that there is no spillage of cancer through the posterior maxillary wall. Furthermore, brisk bleeding from the internal maxillary artery and the pterygoid plexus may be encountered. Suture ligation using a figure-of-eight silk suture is often effective in securing hemostasis in this setting.

In a select group of patients with masticator space involvement (T4b cancer), surgical resection can be undertaken with equivalent oncologic outcome as T4a tumors.[4] This form of resection should be undertaken by experienced head and neck surgeons in high-volume centers. In addition, a thorough evaluation for resectability using preoperative MRI assessment is mandatory. A key feature on MRI evaluation is to ascertain if a 1-cm margin from the masticator space is achievable during resection. This level corresponds approximately at the level of the mandibular notch. Therefore extension of the cancer

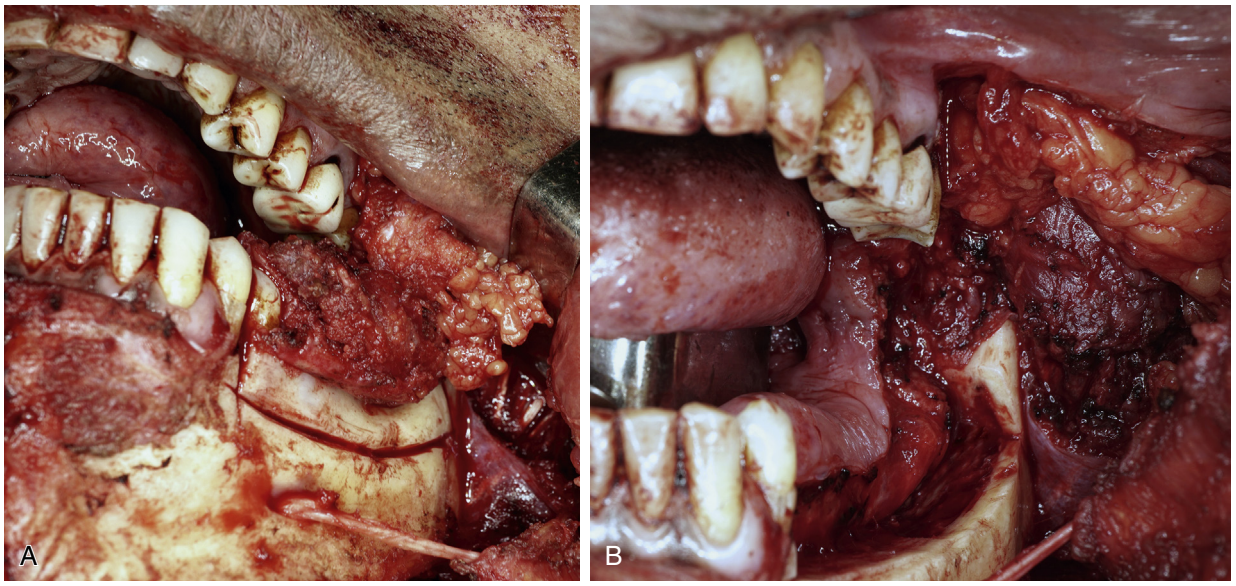

Fig. 31.6 A, Left marginal mandibulectomy. **B,** Defect following left marginal mandibulectomy.

beyond the mandibular notch is not resectable, as it represents extension beyond the masticator space.[3] Care needs to be exercised as one proceeds to dissect more medially at the level of the mandibular condyle as the internal carotid artery lies medial to this mandible at this level.

Extension to the Retromolar Trigone/Ascending Ramus. Posterior extension toward the retromolar trigone is of particular concern because it is separated from the mandibular cortex by the thin pterygomandibular raphe. Thus it is not surprising that cancers extending to the retromolar trigone have a high predilection for invading the cortex of the ascending ramus. Therefore, depending on the extent of mandibular involvement, a marginal mandibulectomy (Fig. 31.6) or segmental mandibulectomy of the ascending ramus is necessary. In addition, cancers that extend to the retromolar trigone may also spread via the pterygomandibular raphe superiorly to involve the maxilla.[5] As such, careful preoperative evaluation of the maxilla is critical, and a maxillectomy may be required to achieve adequate margins.

Neck Dissection

Elective neck dissection (END) is usually performed on patients with early T1-T2 oral SCC with a clinically N0 neck. This is based on the results of a prospective clinical trial published in 2015,in which superior clinical outcomes were reported in patients who had undergone END compared with those who were observed clinically.[6] However, most of these patients had oral tongue SCC and only a small subset (13.7%) had primary SCC of the buccal mucosa.

In other published retrospective reports, the overall rate of occult metastasis for early buccal cancers (T1 and T2) was 7.3%. Occult metastasis was present in 1.8% of cT1 lesions and 10.6% of cT2 lesions.[7] This same study also demonstrated improved 5-year disease-free survival (82.09% vs. 59.09%) and 5-year neck control rates (92.6% vs. 68.2%) in patients who received END. We typically perform selective neck dissection encompassing level I to III for clinically T1/T2 buccal SCC because the nodal basins harboring occult disease are usually located in level I and II. The risk of skip nodal metastasis in buccal SCC, unlike oral tongue SCC, is uncommon.

TABLE 31.2 Reconstructive Options for Buccal Space Defects

Reconstruction Method	
Primary closure	Primary closure may be performed in small defects.
Skin grafts	A full-thickness skin graft may be used to cover a superficial buccal defect.
Buccal adipose tissue pad	Local flaps, such as the buccal fat pad flap, have been reported to fill the surgical defect following resection.
Pedicled flaps	Reconstruction of larger defects may require the use of rotational pedicled flaps. The pectoralis major or a submental island flap may be used in this setting.
Microvascular free flaps	Depending on the extent of the defect, various free flaps may be used. Defects of the buccal space and retromolar trigone may be covered by free radial forearm flaps. This is an ideal flap where large tissue bulk may impede patient's swallowing and speech functions.
	An anterolateral thigh flap may be used in cases where large bulk of tissue is required to reconstruct a large defect (e.g., when the external cheek skin is excised).
	Reconstruction following segmental mandibulectomy would necessitate an osseocutaneous flap, such as the free fibular flap.

Patients with clinically positive lymph nodes (N+) are treated with modified radical neck dissection. However, there are some data demonstrating the low risk of occult disease (approximately 1%) to level V, and hence level V may be omitted in patients with limited N+ disease (N1/N2a).[8]

Reconstruction

The multiple methods of reconstruction of the surgical defect are beyond the scope of this chapter. The principle of reconstruction ladder is helpful to determine the optimal reconstructive option (Table 31.2).

POSTOPERATIVE PERIOD

Postoperative Management

Management of Wound/Flap

After surgery, it is imperative to ensure good oral hygiene so as to promote healing of the oral wound. Regular mouth rinses using antiseptic mouth gargles is helpful in this regard. The patient may be placed on a short period (5 to 7 days) of nasogastric tube feeding before commencing on an oral diet.

When a flap is used for reconstruction, regular flap monitoring is important to identify early free compromise so that early flap salvage may be possible. This is achieved by regular examination of the flap's color, turgor, capillary refill, and presence of vascular congestion. When a microvascular free flap is deployed, vascular flow may be monitored using a transcutaneous ultrasound Doppler to ascertain patency of the microvascular anastomoses. The donor site is also examined for any possible donor site complications.

Complications

The main surgical complication following excision of buccal SCC is related to the wound healing of the buccal defect. Wound dehiscence, infection, and flap failure may occur and may be treated with approximate antibiotics and wound care. The key toward preventing these wound complications lies in tension-free closure of the defect and ensuring good oral hygiene in the postoperative period.

Alternative Management Plan

In patients who are not surgical candidates, radiotherapy or chemoradiation may be considered. Radiation therapy for curative intent may be a viable alternative in patients with early cancer because the results of a retrospective study demonstrate a 3-year disease-free survival of 85% and 63% in patients with stage 1 and 2 cancer, respectively.[9] Nevertheless, superior 5-year overall survival and locoregional control were far superior in the surgical cohort compared with radiotherapy alone in a published result from a single center.[10]

Evidence-Based Medicine Question

Is buccal carcinoma associated with poorer survival/functional outcomes compared with cancers of the other subsites of the oral cavity?

Buccal carcinomas have been traditionally reported to have a significantly poorer outcome compared with the other subsites of the oral cavity. Previously published data from Memorial Sloan Kettering Cancer Center reported a 58% 5-year disease-specific survival for buccal carcinoma compared with 72% to 82% from the other subsites. However, this does not appear to be consistent throughout all centers. More recent publications demonstrated no differences in 5-year disease-specific survival of buccal cancers (70%) compared with that of other subsites of the oral cavity (75%). The 5-year overall survival of buccal carcinoma is reported to be 63% to 73%,[1] and locoregional recurrences are reported to occur in 26.5% to 57% of patients.[10] The higher propensity of locoregional recurrences compared with oral tongue cancer is possibly due to the increased risk of close to positive surgical margins resulting from the complex three-dimensional anatomy of the buccal space, which facilitates subclinical spread of cancer. In a large series of buccal cancers comprising 394 patients, poor prognostic factors for survival included positive surgical margins, positive nodal metastasis, and locally advanced tumor disease.[1]

The functional outcome after surgery for buccal cancer is dependent on the extent of resection and appropriate reconstruction efforts. In general, most patients achieved good swallowing and speech outcomes in cases of small T1-T2 tumors. Consideration of achieving good oral competence and sealing any oronasal communication are crucial even in small cancers. In larger cancers in which part of the ventral tongue, soft palate, or tongue base is resected, a period of swallowing and speech rehabilitation is necessary to achieve good functional outcomes.

Editorial Comment

Cancers of the buccal mucosa have among the most aggressive behavior of any oral cavity malignancy. Early detection and early aggressive management offer the best opportunities for locoregional control and survival. The proximity of these cancers to the parotid, masticator, pterygomaxillary, and infratemporal fossa spaces provides complex opportunities for local cancer progression by either direct extension or perineural invasion. Appropriate imaging techniques such as CT and/or MRI scans are of paramount importance in surgical planning. Surgery is the preferred initial management for these cancers where resection is possible and distant metastatic cancer has been excluded. Surgical efforts may include transoral excision, infrastructure or total maxillectomy, skull base resections, parotidectomy, and neck dissection. Margin clearance should be a primary objective and confirmed with frozen sections where possible. Neck dissection should be performed for all N-positive cases, and elective neck management for the clinically N0 neck should be considered in cases that are T2 or greater. The reconstruction of smaller intraoral defects can be achieved with skin grafts or local flaps in select cases. More formidable defects are best reconstructed with microvascular free tissue transfer, in particular "through and through," defects of the cheek. In complex cases a combination of flaps, such as free flaps and cervicofacial rotation flaps, may be required to achieve acceptable closure to maximize postoperative function and cosmesis. Postoperative adjuvant radiation therapy is necessary in cases with close or positive margins (less than 5 mm), multiple positive lymph nodes, extracapsular extension in lymph nodes, perineural invasion, lymphovascular invasion, and advanced stage. Chemotherapy should be considered in cases in which margins are positive and in cases with extracapsular extension of lymph node metastases. Postoperative surveillance and survivorship include careful periodic examination, speech and swallowing rehabilitation, nutritional education and support, and psychosocial support, as required.

Jeffrey Bumpous

Access the review questions and additional sources list online at http://www.expertconsult.com

REFERENCES

1. Jan JC, Hsu WH, Liu SA, et al. Prognostic factors in patients with buccal squamous cell carcinoma: 10-year experience. J Oral Maxillofac Surg 2011;69(2):396–404.
2. Nemzek WR, Hecht S, Gandour-Edwards R, et al. Perineural spread of head and neck tumors: how accurate is MR imaging? AJNR Am J Neuroradiol 1998;19(4):701–716.
3. Liao CT, Ng SH, Chang JT, et al. T4b oral cavity cancer below the mandibular notch is resectable with a favorable outcome. Oral Oncol 2007;43(6):570–579.
4. Liao CT, Chang JT, Wang HM, et al. Surgical outcome of T4a and resected T4b oral cavity cancer. Cancer 2006;107(2):337–344.
5. Hao SP, Tsang NM, Chang KP, et al. Treatment of squamous cell carcinoma of the retromolar trigone. Laryngoscope 2006;116(6):916–920.

6. D'Cruz AK, Vaish R, Kapre N, et al. Elective versus therapeutic neck dissection in node-negative oral cancer. N Engl J Med 2015;373(6):521–529.
7. Huang SF, Chang JT, Liao CT, et al. The role of elective neck dissection in early stage buccal cancer. Laryngoscope 2015;125(1):128–133.
8. Pandey M, Shukla M, Nithya CS. Pattern of lymphatic spread from carcinoma of the buccal mucosa and its implication for less than radical surgery. J Oral Maxillofac Surg 2011;69(2):340–345.
9. Nair MK, Sankaranarayanan R, Padmanabhan TK. Evaluation of the role of radiotherapy in the management of carcinoma of the buccal mucosa. Cancer 1988;61(7):1326–1331.
10. Lin CS, Jen YM, Cheng MF, et al. Squamous cell carcinoma of the buccal mucosa: an aggressive cancer requiring multimodality treatment. Head Neck 2006;28(2):150–157.

REVIEW QUESTIONS

1. Buccal carcinomas that have invaded the masticator space may extend to the pterygopalatine fossa via the
   a. Formaen ovale
   b. Infraorbital nerve
   c. Pterygomaxillary fissure
   d. Greater palatine foramen

2. In the management of buccal carcinoma with limited invasion to the retromolar trigone the preferred approach would be
   a. Transoral resection
   b. Inferior cheek flap and marginal mandibulectomy
   c. Mandibulotomy and marginal mandibulectomy
   d. Segmental mandibulectomy

3. Patients with gross invasion of the masticator space are amendable to surgical resection with improved survival outcomes if the cancer lies
   a. Inferior to the mandibular notch
   b. Superior to the mandibular notch
   c. Anterior to the mandibular notch
   d. Posterior to the mandibular notch

4. The role of elective neck dissection in cN0 buccal carcinomas has been shown to
   a. Be unnecessary as there is usually submucosal fibrosis
   b. Significantly improve disease-free survival
   c. Improve overall 5-year survival
   d. Be beneficial for diagnosis of skip metastasis

5. Magnetic resonance imaging (MRI) is often the preferred imaging of choice because it
   a. Allows for accurate evaluation of the mandibular cortex
   b. Is essential to determine invasion of the maxilla
   c. Allows excellent evaluation of the infratemporal fossa and pterygopalatine fossa
   d. Shows invasion of the maxillary sinus

6. The main cause of mortality in buccal carcinomas is secondary to
   a. Malnutrition
   b. Distal metastasis
   c. Locoregional failure
   d. Secondary malignancies

ADDITIONAL SOURCES

Diaz Jr EM, Holsinger FC, Zuniga ER, et al. Squamous cell carcinoma of the buccal mucosa: one institution's experience with 119 previously untreated patients. Head Neck 2003;25(4):267–273.

Hao SP. Reconstruction of oral defects with the pedicled buccal fat pad flap. Otolaryngol Head Neck Surg 2000;122(6):863–867.

Iyer SG, Pradhan SA, Pai PS, et al. Surgical treatment outcomes of localized squamous carcinoma of buccal mucosa. Head Neck 2004;26(10):897–902.

Shah JP, Johnson NW, Batsakis JG. Oral Cancer. London, New York, NY: Martin Dunitz; 2003. p. 496 (Distributed in the United States by Thieme New York).

Shaw RJ, McGlashan G, Woolgar JA, et al. Prognostic importance of site in squamous cell carcinoma of the buccal mucosa. Br J Oral Maxillofac Surg 2009;47(5):356–359.

Sieczka E, Datta R, Singh A, et al. Cancer of the buccal mucosa: are margins and T-stage accurate predictors of local control? Am J Otolaryngol 2001;22(6):395–399.

32 Transoral Inferior Maxillectomy

Peter S. Vosler, Eugene N. Myers

INTRODUCTION

The hard palate is the site of origin of benign and malignant tumors.[1,2] The most common tumor of minor salivary gland origin in this site is pleomorphic adenoma, a benign tumor that appears as a smooth submucosal mass. Approximately 5% of cancers of the oral cavity involve the hard palate and maxillary alveolus.[3] Squamous cell carcinoma accounts for approximately 90% of malignancies of the hard palate and the upper alveolar ridge (Fig. 32.1).[4] Cancers arising in the minor salivary glands are the most prevalent non–squamous cell cancers of the hard palate. Adenoid cystic carcinoma is the most common of the cancers of minor salivary gland origin, followed by mucoepidermoid carcinoma, malignant mixed tumor, acinic cell carcinoma, and other adenocarcinomas.[2] Lymphoma and plasmacytoma also arise on the hard palate. Polymorphic reticulosis (formerly called lethal midline granuloma) commonly involves the hard palate and upper alveolus. Necrotizing sialometaplasia and pseudoepitheliomatous hyperplasia have an appearance similar to squamous cell carcinoma.[2] Malignant melanoma may also occur in the mucosa of the hard palate. Sarcomas of bone and soft tissue have likewise been reported in the hard palate and upper alveolus, more commonly in children.[4]

Evidence of a direct cause-and-effect relationship between tobacco, alcohol, and cancer of the hard palate is not as clear-cut from an epidemiologic point of view as it is with cancer in other upper aerodigestive tract sites. An exception is the high incidence of cancer of the hard palate in parts of India and the Philippines, where reverse smoking is practiced. Poor oral hygiene, mechanical irritation, ill-fitting dentures, syphilis, and even mouthwash have been suggested as other possible causative relationships.[2]

KEY OPERATIVE LEARNING POINTS

1. A thorough examination of the oral cavity, nasal endoscopy, examination of the neck, imaging with maxillofacial computed tomography (CT) scan, and biopsy are essential to fully characterize the lesion, devise a plan of management, and determine the extent of the resection.
2. Comprehensive understanding of the three-dimensional anatomy and surrounding structures will facilitate resection and help to avoid complications.
3. Reconstruction of smaller palatal defects with a prosthesis is sufficient, whereas larger defects will require a local, regional or even microvascular free tissue flap.

PREOPERATIVE PERIOD

History

1. History of present illness:
   a. How was the mass discovered?
      1) Incidentally by a dentist or by the patient
   b. How long has the mass been present?
   c. Associated signs and symptoms
      1) Pain
      2) Numbness of the palate and face
      3) Bleeding from the mass
      4) Epistaxis
      5) Dental infections, tooth extraction/removal, loose teeth, poorly fitting dentures
      6) Trismus
      7) Voice change
      8) Neck mass
      9) Weight loss
2. Past medical history:
   a. Prior oral lesions removed?
   b. History of periodontal disease
   c. Medical history
      1) Diabetes, immunosuppression, coronary artery disease, thrombosis, hypertension
   d. Prior head and neck surgery or radiation
   e. Social history
      1) Smoking and alcohol consumption
   f. Family history
      1) History of cancer of the head and neck or other malignancies
   g. Medications
      1) Anticoagulation/antiplatelet therapy
      2) Insulin
      3) Homeopathic products

Physical Examination

1. Oral cavity: Using a bright light, tongue depressors, and suction; a thorough examination of the oral cavity is paramount in determining the extent and characteristics of the mass.
   a. Location
      1) Involvement of the hard or soft palate, involvement of lingual or buccal alveolus
   b. Size of mass: Map the area of the tumor including areas of swelling suggestive of subepithelial spread of the tumor.
   c. Characteristics of the mass:
      1) Leukoplakia or erythroplakia lesion
      2) Endo- or exophytic mass. Palpation of the mass is clinically the best way of evaluating thickness and depth of infiltration.
      3) Submucosal lesion
   d. Dentition: Evaluate for loose dentition, ill-fitting dentures, and gingivitis.
   e. Examine loose dentition for the possibility of malignant involvement of the tooth sockets and underlying bone.
   f. Sensation of palate: Numbness of the palate may indicate involvement of the palatal foramina and skull base.
2. Nasal endoscopy: Detailed inspection of the floor of the nasal cavity, inferior meatus, and lateral nasal wall is essential to determine the presence of intranasal extension of the cancer.
3. Neck: The neck should be examined for the presence of a mass because many patients will present with metastasis to the neck. Evidence of prior surgery should be noted.
4. Cranial nerve examination: Specifically evaluate the distributions of the trigeminal nerve to evaluate for neural involvement by the cancer.

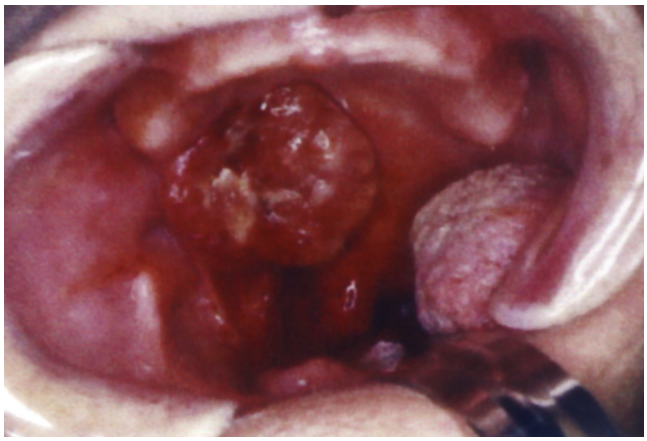

Fig. 32.1. Squamous cell carcinoma is the most commonly encountered cancer of the hard palate.

5. Flexible fiberoptic laryngoscopy: Evaluation of the remainder of the upper aerodigestive tract is performed to exclude the possibility of a second primary cancer, because second primaries may occur in 20% to 25% of patients with squamous cell carcinoma of the oral cavity and oropharynx.

Imaging

1. Maxillofacial, neck, and chest CT scan with and without contrast: Identify the size and extent of infiltration of the tumor, any areas of bone invasion, involvement of the nasal cavity and maxillary sinuses, and the presence of metastases to the lymph nodes. CT is also very helpful in diagnosing distant metastases, which occur most commonly in the lung.
2. Positron emission tomography (PET)/CT: This technique is not helpful in the evaluation of the primary cancer, but it may be very helpful in evaluating the neck for metastatic lymph nodes because they may be involved in up to 50% of patients with squamous cell carcinoma of the hard palate.[4] PET/CT scanning is also valuable in detecting the presence of distant metastasis.

Indications

1. Surgery is the first-line treatment of all benign and malignant tumors of the palate.
   a. Benign tumors may be removed without resecting bone and there is no requirement for reconstruction.
   b. Malignant tumors will require resection of part or all of the hard palate or maxillary alveolus (or both) to remove bone that is obviously involved along with at least a 1-cm margin. These defects will require some form of reconstruction.
   c. Adjuvant chemoradiation is beneficial when there is bone invasion, perineural invasion, two or more positive lymph nodes, or extracapsular spread.
2. Ipsilateral selective neck dissection, levels I to III, should be performed for tumors that do not involve the midline. Bilateral selective neck dissections should be performed for tumors involving the midline.

Contraindications

1. Presence of distant metastasis in the lung
2. Very advanced local disease (T4b) involving the masticator space, pterygoid plates, skull base, or encasement of the carotid artery
3. Severe medical comorbidities

Preoperative Preparation

1. Map out the extent of the tumor based on physical examination and imaging findings.
   a. Anticipate the extent of the defect to determine whether the patient will require restoration of oral-nasal separation with a dental prosthesis, local pedicle flap, or free flap reconstruction.
   b. If the dimensions and site of the tumor, whether benign or malignant, require resection of the maxillary alveolus or palatal bone, or both, a plan must be made to achieve oral-nasal separation. In most circumstances this can best be accomplished through the use of an obturator.[5,6] A prosthodontist should always be consulted preoperatively so that the appropriate dental records and impressions can be taken and a surgical splint fabricated for use following resection of the tumor.
2. Biopsy: A definitive biopsy is necessary to plan surgical management. Benign and malignant tumors of salivary gland origin may be covered by mucosa, and incisional biopsy is usually necessary in such cases for accurate diagnosis.
3. In the presence of a malignant tumor, determine the need for ipsilateral or bilateral neck dissection.
4. Preoperative medical clearance must be secured for patients with significant medical comorbidities.
5. Counsel the patient regarding the risks of the procedure. Informed consent should include: bleeding; infection; need for local, regional, or microvascular reconstruction; possible use of a dental prosthesis; evaluation by a prosthodontist; and potential cosmetic deformity.
6. Discontinue use of anticoagulation and antiplatelet therapies prior to surgery.
7. Early admission is recommended for detoxification in patients with known alcohol abuse.

OPERATIVE PERIOD

Anesthesia

1. General anesthesia is indicated for most procedures involving the maxilla for airway protection and patient comfort.

Positioning

1. The patient is placed in the supine position with the head of the bed turned 90 or 180 degrees away from the anesthesiologist.
2. The use of a local or regional flap should not modify patient positioning. Microvascular free tissue transfer may require repositioning based on the donor site of the flap and will be governed by the reconstructive surgeon.

Perioperative Antibiotic Prophylaxis

1. Antibiotics covering for oral flora (gram positive, gram negative, and anaerobic bacteria) such as ampicillin-sulbactam or clindamycin for penicillin-allergic patients

Monitoring

1. No specific neural monitoring is necessary for this surgery. Monitoring of hemodynamics, body-fluid homeostasis, and oxygen saturation should be performed per the anesthesiologist's preferred protocol based on the patient's medical comorbidities.

Instruments and Equipment to Have Available

1. Basic head and neck or plastic surgery set
2. Monopolar and bipolar cautery
3. Microtome for split-thickness skin graft (STSG)
4. Surgical splint made by a prosthodontist prior to surgery
5. Saw or drill (reticulating or sagittal saw or Midas Rex pneumatic drill), and osteotomes
6. Dental tray

Key Anatomic Landmarks

1. The hard palate and alveolar ridge form the superior boundary of the oral cavity.
2. The hard palate separates the oral cavity from the nasal cavity and maxillary sinuses.
3. The pterygopalatine and infratemporal fossae are located posterior to the maxilla.

Prerequisite Skills

1. Three-dimensional understanding of the anatomy of the maxilla
2. Neck dissection (see Chapter 87)

Operative Risks

1. Intraoperative hemorrhage from palatine and internal maxillary arteries
2. Neurovascular injury from the neck dissection (see Chapter 87)
3. Creation of defects larger than anticipated without proper preoperative preparation

Surgical Technique

1. Approaches to the surgical management of cancer limited to the hard palate and alveolar ridge include:
   a. Excision of benign tumors
   b. Partial lateral maxillectomy: Surgical approach for tumors of the hard palate that involve the maxillary sinus and nasal cavity
   c. Inferior maxillectomy: Surgical approach for tumors of the hard palate that do not involve the floor of the maxillary sinus and nasal cavity
   d. Complete maxillectomy (see Chapter 15)
2. **Approach to benign mucosal tumors of the palate** (Biopsy-confirmed benign tumors only involving the mucosa (i.e., pleomorphic adenoma, necrotizing sialometaplasia, etc.))
   a. Incise with electrocautery or scalpel with 0.5-cm margins of the lesion.
   b. The deep margin should be the periosteum of the hard palate.
      1) If there is concern for tumor involvement deep to the periosteum, the surface of the hard palate is drilled with a burr to remove the superficial layer of bone.
   c. Reconstruction
      1) A palatal island rotational flap or rotational flap based on either the greater palatine or ascending palatine arteries is used to cover the site of the defect.
3. Partial transoral lateral maxillectomy
   a. Hands-free cheek retractor, a bite block, or a side-biting mouth gag is placed to gain access to the oral cavity.
      1) Use of a sweetheart retractor aids in retracting the tongue.
   b. Mark the margins of the resection with a marking pen or electrocautery.
      1) Margins should be a minimum of 1 cm for any lesion suspicious for malignancy or biopsy-proven malignancy.

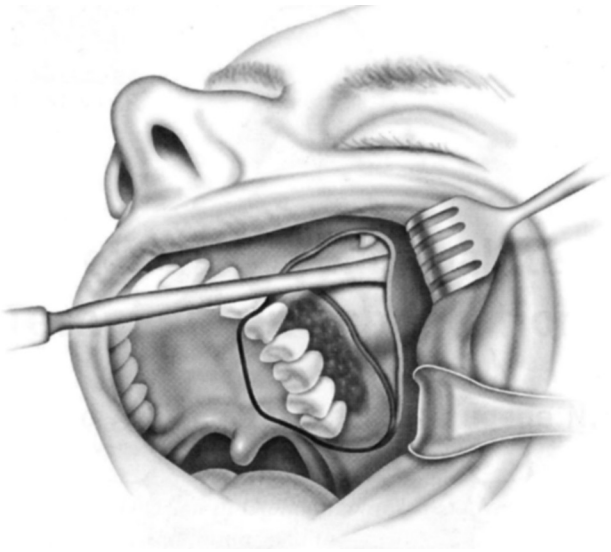

Fig. 32.2. Gingivobuccal incision and anterior maxillotomy with visualization of the maxillary sinus floor and infraorbital rim. *(Reprinted with permission from Simental AA Jr, Myers EN: Cancer of the hard palate and maxillary alveolar ridge: technique and applications. Oper Tech Otolaryngol Head Neck Surg 16:30, 2005.)*

   c. Incise the mucosa with electrocautery for improved hemostasis.
   d. Elevate the soft tissue in the subperiosteal plane of the front and lateral walls of the maxillary antrum to the level of the infraorbital nerve with a Freer elevator or a 9 Molt periosteal elevator.
      1) Identification of the infraorbital nerve helps prevent permanent anesthesia of the soft tissues of the face (Fig. 32.2).
   e. Enter the maxillary antrum using a small osteotome and remove the anterior wall with a Kerrison rongeur sparing the infraorbital nerve.
      1) This allows for sufficient visualization of the maxillary antrum to evaluate the extent of resection.
   f. A sagittal saw with reciprocating or sagittal blades is used to make osteotomies with at least 1-cm bony margins from the edge of the tumor along the frontal and lateral walls of the antrum.
   g. Transect the palate into the maxillary sinus with care to avoid entering the nasal cavity if the tumor margins allow.
      1) If the nasal cavity is entered, the inferior turbinate is resected to facilitate fitting of the obturator made by the prosthodontist.
   h. Place a large, curved osteotome posterior to the last molar at a 90-degree angle to cut the hard palate in a superomedial direction (Fig. 32.3).
   i. Once the pterygoid plates are fractured, brisk bleeding is expected from the pterygoid plexus and internal maxillary artery.
      1) Use heavy curved Mayo scissors to complete transection of the soft tissues of the pterygopalatine fossa and soft palate and remove the tumor en bloc.
      2) The posterior osteotomy is the final cut due to concern of hemorrhage from the internal maxillary artery and its branches in the pterygopalatine fossa. Performing this cut last allows for removal of the tumor, and hemorrhage from the pterygopalatine fossa cannot be adequately controlled until the tumor is removed.



Fig. 32.3. Posterior osteotomy created by aiming superomedially. Great care is taken not to violate the orbital floor. *(Reprinted with permission from Simental AA Jr, Myers EN: Cancer of the hard palate and maxillary alveolar ridge: technique and applications. Oper Tech Otolaryngol Head Neck Surg 16:31, 2005.)*

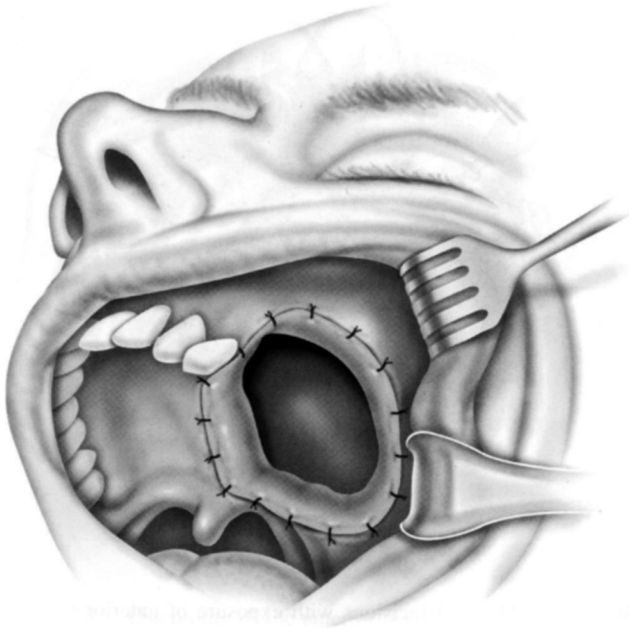

Fig. 32.4. A split-thickness skin graft is used to line the cheek flap. The maxillary sinus mucosa is removed entirely. *(Reprinted with permission from Simental AA Jr, Myers EN: Cancer of the hard palate and maxillary alveolar ridge: technique and applications. Oper Tech Otolaryngol Head Neck Surg 16:31, 2005.)*

3) Control bleeding with clamp and ligature technique.

j. Obtain frozen section analysis from the left tissue margins of the specimen that are concerning for residual tumor or are too close to be oncologically sound.
   1) Unfortunately, there is no way to evaluate bone margins by frozen section.

k. Remove the entire mucosa from the maxillary sinus to avoid contamination by oral cavity microorganisms and prevent resultant edema and inflammation that can interfere with the fit of the oral splint.
   1) Remove any sharp edges of bone with a drill or file.

l. An STSG is harvested at a thickness of 0.018 inch and it is sutured into place to line the cheek defect (Fig. 32.4).

m. Pack the defect tightly with Xeroform gauze to close off dead space and compress the skin graft to the underlying tissue to ensure graft survival.

n. Place the previously formed surgical splint over the defect and secure it with a screw drilled into the remaining hard palate or suture it into place (Fig. 32.5).
   1) In patients who have residual dentition, clips placed by the prosthodontist can also be used to further stabilize the splint. The presence of the surgical splint allows the patient to swallow and speak during the immediate postoperative period.

4. Inferior maxillectomy
   a. Retract the lips with a hands-free cheek retractor, a bite block, or a side-biting mouth gag to gain access to the oral cavity.
   b. Mark the margins of the resection with a marking pen or electrocautery.
      1) Margins should be a minimum of 1 cm for any lesion suspicious of malignancy or biopsy-proven malignancy.
   c. Incisions are made in a manner similar to that described for tumors of the alveolar ridge.
   d. The maxillary sinus is entered and the inferior aspect of the maxillary sinus is thoroughly evaluated (Fig. 32.6).
   e. A sagittal saw is used to make precise osteotomies.
   f. The osteotomy is usually completed with the osteotome at the level of the pterygoid plates.
   g. The nasal cavity is entered and the septum is transected with heavy curved Mayo scissors 1 to 2 cm superior to the floor of the nose.
   h. The soft palate is transected with electrocautery, and any residual soft tissue attachments are transected with scissors.
   i. After the mucosa of the maxillary antrum is removed as previously described, the inferior turbinate is also removed to prevent infection and edema, which would interfere with the application of a palatal prosthesis.
   j. More extensive tumors limited to the hard palate and alveolar ridge can be removed by simply extending the osteotomies.
   k. Once the specimen is removed, it is sent to the pathology laboratory for frozen section diagnosis and assurance of clear surgical margins.

5. Management of the neck in squamous cell carcinoma of the hard palate and alveolar ridge
   a. A high incidence of cervical metastasis (30%) in the subsites of tongue and floor of the mouth cancer has been well documented.[7] Our observed data of squamous cell carcinoma originating in the maxillary alveolus suggest the rate of metastasis to the neck from squamous cell carcinoma of the hard palate and alveolar ridge to be 37%, which is similar to that in other sites in the oral cavity.[7]
   b. Dissect the neck before the oral cavity because resection of the neck is considered clean.
   c. If the primary tumor does not involve the midline, we perform a unilateral selective neck dissection. Midline lesions or lesions involving the entire hard palate require bilateral neck dissections.
   d. If metastasis in the neck is present, N1 to N2, a selective neck dissection is performed. An N3 neck requires a modified or radical neck dissection. Once the neck dissection is completed, we re-drape and isolate the neck dissection wound from the oral cavity procedure.

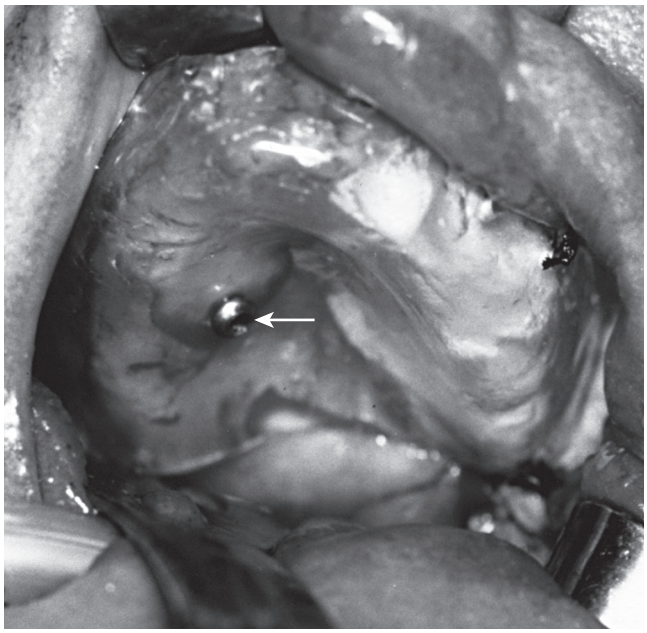

Fig. 32.5. A lag screw *(arrow)* facilitates fixation of the acrylic splint.

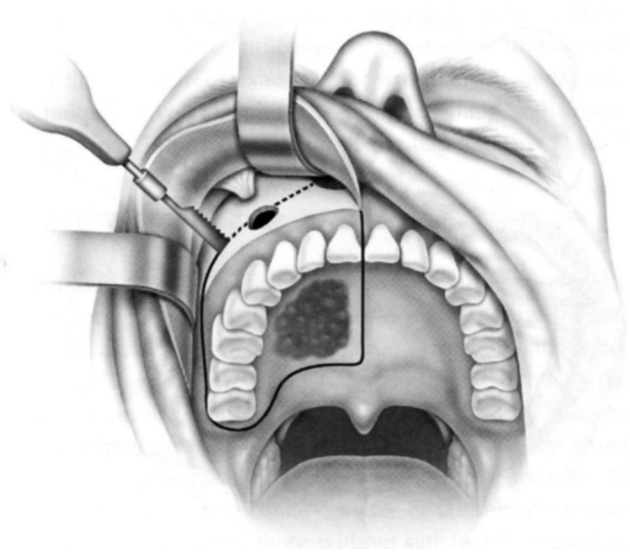

Fig. 32.6. An anterior maxillotomy is made to visualize the entire floor of the maxillary sinus. *(Reprinted with permission from Simental AA Jr, Myers EN: Cancer of the hard palate and maxillary alveolar ridge: technique and applications. Oper Tech Otolaryngol Head Neck Surg 16:32, 2005.)*

Common Errors in Technique

1. Inadequate exposure
2. Positive margins

Postoperative Management

Rehabilitation of a Patient With Loss of Oral-Nasal Separation

Patients treated by inferior maxillectomy require a means of restoring the oral-nasal separation lost by removal of the palate and alveolar bone. Not doing so results in patients who can neither speak nor swallow, which gives rise to an unacceptable quality of life.

A comprehensive midface and maxilla classification system has been established incorporating both vertical and horizontal defects.[8] The defects are categorized into classes I to VI vertical defects based on involvement of the maxillary alveolus, nasal cavity, and orbit and horizontal defects based on the extent of the palatal defect (Fig. 32.7). Based on their experience, the use of obturation was reserved for class I to IIa-c defects, whereas free tissue transfer was preferred for more extensive defects of the maxillary alveolus (class IId) and defects with nasal and orbital involvement (classes III to VI).[8]

1. The four major means of rehabilitation include:
   a. Dental prosthetic management: A patient with a limited lesion of the alveolar ridge alone or the alveolar ridge and palate that does not involve more than half the hard palate can be rehabilitated relatively easily.[3]
      1) Preoperative dental impressions are made and a surgical splint is fashioned and inserted at the time of resection as described earlier.
      2) A lag screw is inserted through a hole in the prosthesis into the remaining palatal bone to hold the prosthesis in place (see Fig. 32.5).
      3) On the fifth postoperative day the screw is removed and the prosthesis is taken out and the packing is removed. The skin graft is healed by that time and the sutures holding the skin graft are removed (Fig. 32.8).
      4) Prostheses are designed according to the Aramany classification.[6] The permanent prosthesis will have teeth similar to a denture; it can be removed and cleaned by the patient (Fig. 32.9). It is essential for the surgeon and prosthodontist to coordinate their efforts in restoring the patient's voice and ability for adequate oral intake.
   b. Local flaps: The palatal island flap for reconstruction of palatal lesions is a single-stage mucoperiosteal flap that is a reliable source of regional vascularized soft tissue that obviates the need for prosthetic rehabilitation.
   c. Regional flaps: The temporalis flap allows for immediate reconstruction with minimal morbidity for patients who have undergone total inferior maxillectomy (Fig. 32.10). The temporalis muscle is an attractive option for reconstruction for the following reasons:
      1) The donor site and the defect are within the same operative field and therefore the need for more complex free tissue transfers can be avoided.
      2) Considerable tissue is available.
      3) Well-vascularized flap
      4) Negligible functional defect
      5) The cosmetic deformity is limited to a mild concavity in the area of the temporalis fossa, which in women is covered by hair.
      6) The flap can be used to correct unilateral and total defects.
      7) Reconstruction can be carried out in less time than a free flap.
      8) Limitations
         a) No prosthetic rehabilitation with dental implants to improve cosmetic outcome
         b) Lack of direct vision to tumor area to monitor for recurrent tumor. This has been largely overcome with the use of PET/CT scanning and nasal endoscopy.
   d. Microvascular free tissue transfer: Reconstruction of defects after inferior maxillectomy are well summarized under the theme of functional palatomaxillary reconstruction.[9] Larger defects (classes III to VI) require reconstruction with composite free flap reconstruction to close off the defect and restore natural facial contour.

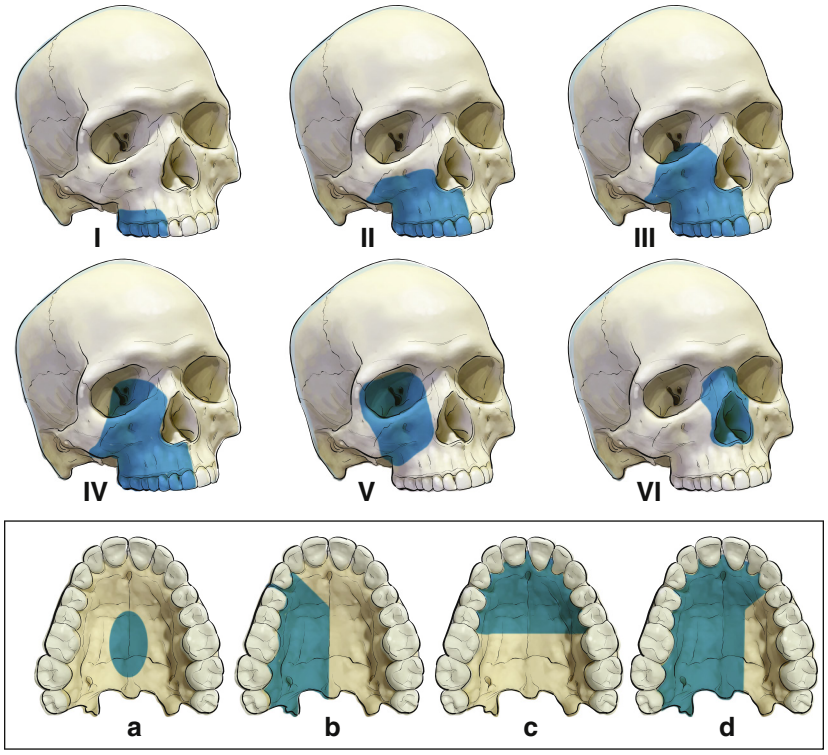

Fig. 32.7. Classification of vertical and horizontal maxillectomy and midface defect. Vertical classification: I—maxillectomy not causing an oronasal fistula; II—not involving the orbit; III—involving the orbital adnexa with orbital retention; IV—with orbital enucleation or exenteration; V—orbitomaxillary defect; VI—nasomaxillary defect. Horizontal classification: a—palatal defect only, not involving the dental alveolus; b—less than or equal to ½ unilateral; c—less than or equal to ½ bilateral or transverse anterior; d—greater than ½ maxillectomy. Letters refer to the increasing complexity of the dentoalveolar and palatal defect and qualify the vertical dimension. *(Reprinted with permission from Brown JS, Shaw RJ: Reconstruction of the maxilla and midface: introducing a new classification. Lancet Oncol 11:1002, 2010.)*

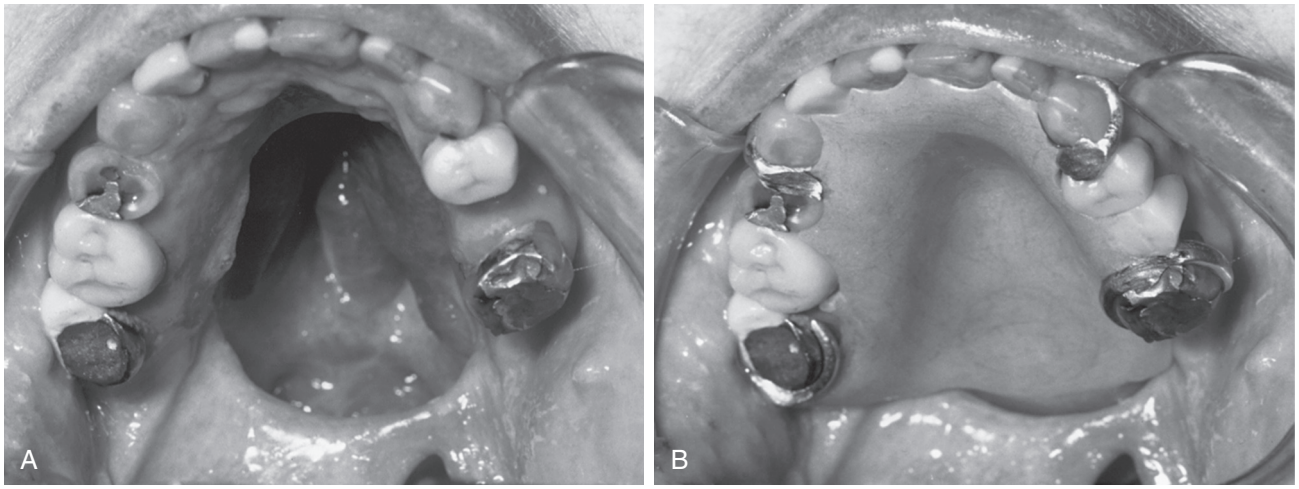

Fig. 32.8. A, This patient underwent resection of an adenocarcinoma of the hard palate. The defect is demonstrated. **B,** Retention of the prosthesis is facilitated by residual dentition. The final prosthesis achieves good oral-nasal separation.

1) The free flap must include vascularized bone and soft tissue from the radial forearm, fibula, iliac crest, or scapula.
2) Free tissue transfer is superior to prostheses in larger defects with regard to improved speech and swallowing; however, placement of dental implants may be delayed or impossible based on the type of flap used.
3) Prosthesis placement allows for immediate restoration of speech and swallowing but requires multiple revisions if the patient requires radiation therapy or surgical revision.[8]
4) Soft tissue free flap reconstruction[10]:
   a) Lateral upper arm flap
   b) Rectus abdominus
   c) Radial forearm
   d) Latissimus dorsi
5) Osseocutaneous free flap reconstruction[10]:
   a) Fibula
   b) Iliac crest
   c) Radial forearm
   d) Thoracodorsal angular artery scapula tip

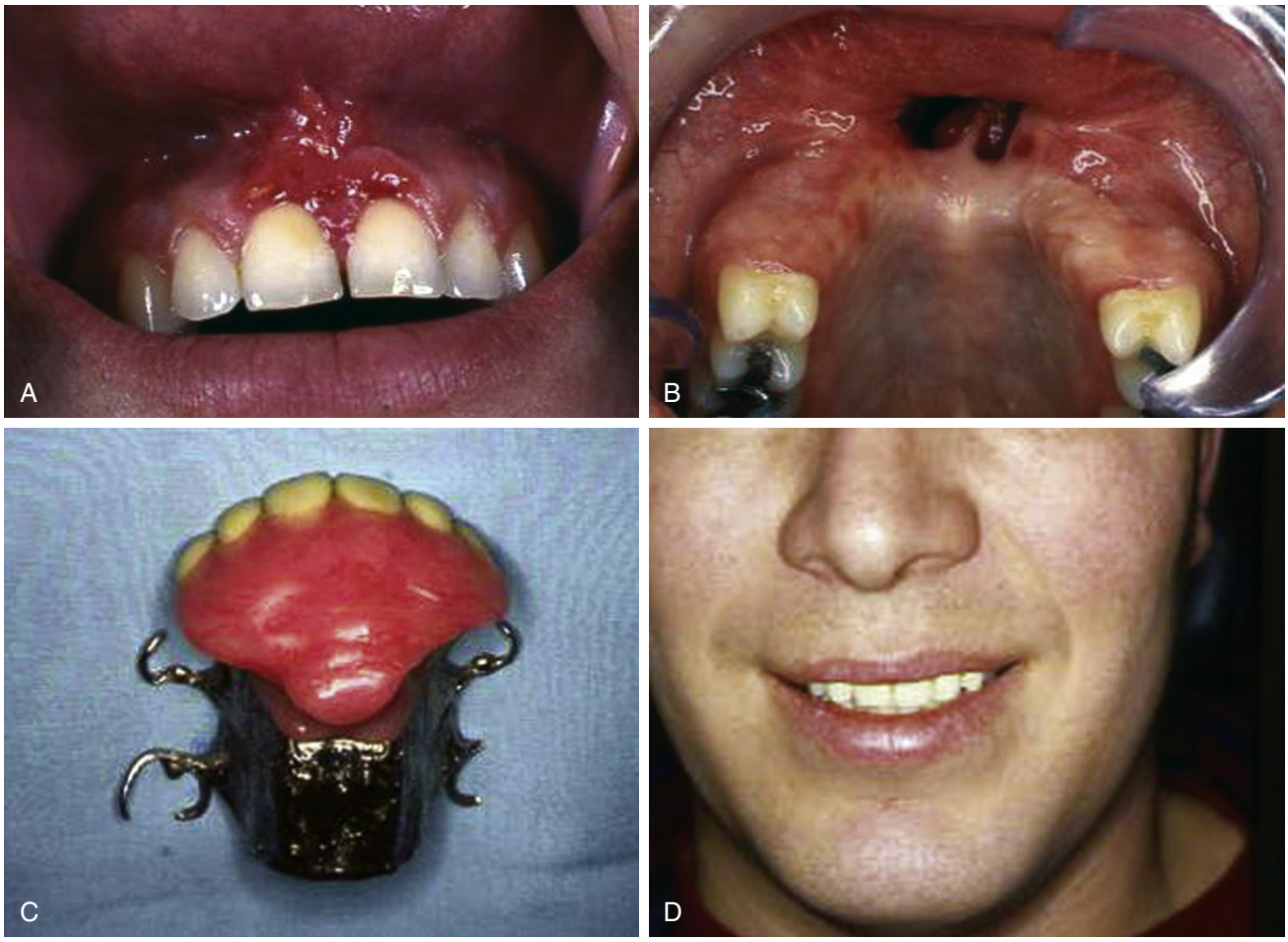

Fig. 32.9. Patient with a removable denture that restores good oral-nasal separation and provides for a good cosmetic appearance. **A,** Preoperative appearance. **B,** Surgical defect. **C,** Removable prosthesis with clasps. **D,** Good cosmetic result with restoration of oral-nasal separation.

6) Free flap reconstruction of the palate provides reliable permanent oronasal separation in one stage with restoration of masticatory function and normal phonation. In addition, the potential for dental rehabilitation exists. The choice of flap is tailored to specific palatal defects and patient needs.

POSTOPERATIVE PERIOD

Postoperative Management

1. Transfer to a dedicated head and neck cancer unit with nurses trained in the care of head and neck patients. There is usually no need for intensive care unit–level of care for this surgery unless microvascular reconstruction is employed. If microvascular reconstruction is performed, the reconstructive surgeon dictates the level of care.
2. Check hematocrit in cases of large-volume intraoperative blood loss.
3. Pain medication: Opioid pain medication such as oxycodone 5 to 10 mg every 4 hours as needed should provide adequate analgesia in the perioperative period. Acetaminophen may suffice in elderly patients.
4. Meticulous oral hygiene with chlorhexidine mouthwash swish-and-spit after every meal is essential to help prevent infection.
5. Diet
   a. Benign or low-grade malignant lesions where bone was preserved
      1) Soft diet starting on postoperative day 1
   b. Prosthetic rehabilitation and local or regional flap
      1) Full liquid or pureed diet starting on postoperative day 1
   c. Microvascular free flap
      1) Based on reconstructive surgeon's postoperative protocol
6. Remove the prosthesis and bolster on postoperative day 5. Excess STSG is removed.
7. The temporary obturator is installed by the prosthodontist. This is used in the interim while the final prosthesis is delayed until the maxillectomy cavity matures. If there are plans for adjuvant radiation therapy, the final prosthesis may have to be delayed until after completion of radiation to ensure a proper fit.
8. Early ambulation with or without physical therapy is essential for postoperative rehabilitation.
9. Patients who have undergone neck dissection in conjunction with resection of the primary cancer will have the neck wound managed as described in the chapter on neck dissection (see Chapter 87).
10. Patients with bone invasion (T4 lesions) or with high-grade salivary gland cancers are referred for postoperative radiation therapy. Patients who have perineural involvement in their primary tumor or positive resection margins should always be referred for radiation therapy. Similarly, patients who have more than two positive nodes or extracapsular spread in one or more nodes will be referred for chemoradiation therapy.

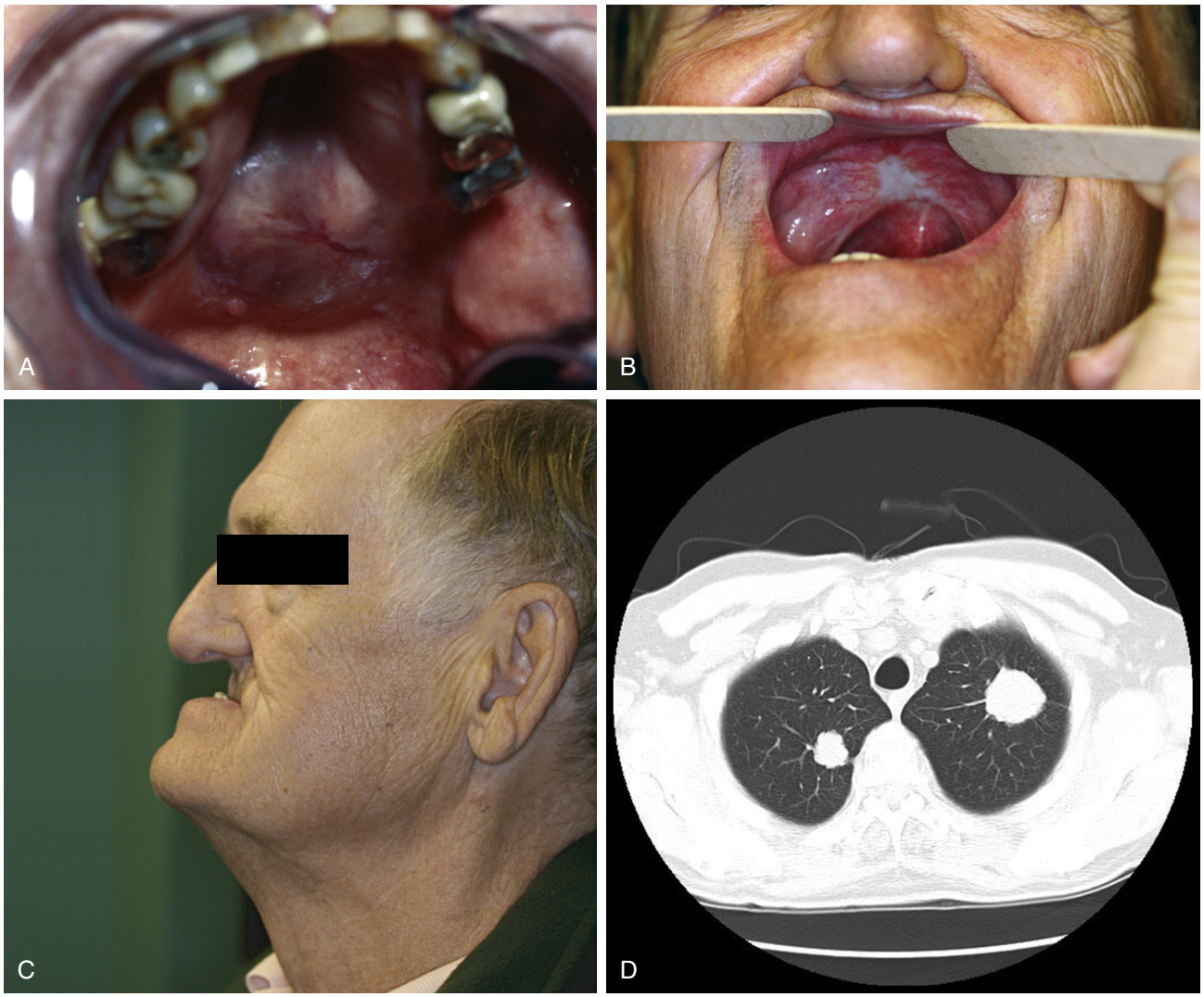

Fig. 32.10. A, Patient with adenoid cystic carcinoma of the palate. **B,** After total inferior maxillectomy, the defect was reconstructed with a temporalis muscle flap, which quickly became mucosalized. Complete healing was followed by a full course of radiation therapy. **C,** Removal of the maxilla resulted in recession of the upper lip. **D,** CT scan disclosing multiple metastatic nodules that were discovered 13 years after the surgery and radiation therapy and were treated with radiation therapy. It has now been 15 years since the patient completed his surgery, and he is asymptomatic despite the stable lung metastasis.

Complications

1. Creation of an oral-nasal fistula in removal of a benign tumor
   a. Perforation of soft tissue on the nasal side of the palate with removal of palatal bone as a deep margin
   b. Repair intraoperatively with soft tissue via a prosthesis, local, regional, or microvascular free flap.
2. Contraction of buccal mucosa
   a. Resurface the upper lip and buccal mucosa with an STSG to avoid contraction deformity.
   b. Resurfacing of soft tissue defects with an STSG when the hard palate is intact is rarely necessary. The defect will heal by secondary intention.
3. Hemorrhage
   a. Focal pressure will usually provide adequate hemostasis.
   b. Return to the operating room (OR) for site control if focal pressure does not resolve the bleeding.
4. Infection
   a. Meticulous oral hygiene and perioperative antibiotic prophylaxis will prevent most infections.
   b. Local wound care
   c. Treat with postoperative antibiotics covering for oral flora (gram-positive, gram-negative, and anaerobic bacteria) such as ampicillin-sulbactam or clindamycin for penicillin-allergic patients with pus and systemic signs of infection (fever or leukocytosis)

Alternative Management Plan

1. Nonsurgical management: The patient who is not a surgical candidate due to the site of the tumor or due to medical comorbidities can be referred for radiation therapy.
2. Palliative care: The option of palliation is offered to our patients based on the extent of tumor involvement, the patient's medical comorbidities, and the wishes of the patient and family. The palliative care physicians discuss issues such has symptom management (pain, hunger, thirst) and the details of hospice care.

DISCUSSION

Evidence-Based Medicine Question

Is selective neck dissection indicated for squamous cell carcinoma of the maxilla?

Occult metastasis occurs at a rate of 34.6% in squamous cell carcinoma of the palate and alveolar ridge.[7] Selective neck dissection is indicated for T3 and T4 lesions. Lower stage lesions (T1 and T2) without concerning features such as perineural invasion (PNI) or extracapsular spread (ECS) can be observed, just as with other oral cavity sites.

Editorial Comment: Inferior Maxillectomy

The hard palate and alveolar ridge give rise to a wide variety of conditions ranging from necrotizing sialometaplasia, a benign condition, to squamous cell carcinoma, which is the most frequently encountered malignant tumor. Malignant tumors and most benign conditions are treated surgically because radiation applied to bone structures can result in osteoradionecrosis.

When I was first introduced to the inferior maxillectomy it was carried out through a lateral rhinotomy approach, which provides wide exposure but at the price to the patient of a conspicuous scar. I soon realized that most tumors arising in the area of the palate could be removed successfully through a transoral approach, and I abandoned the lateral rhinotomy incision.

Loss of oronasal separation, which is fundamental to both swallowing and speaking, was managed with a prosthesis except in cases of a total inferior maxillectomy, which was reconstructed with a temporalis muscle flap. Reconstruction of the palate with free tissue transfer introduced more recently was not embraced fearing that closing the defect would preclude cancer surveillance. This concern has been overcome with the introduction of the PET/CT scanner, which is used to detect recurrent cancer.

Another major step forward in the management of patients with squamous cell carcinoma is the management of the neck. It was believed that cancers of the hard palate and alveolar ridge, which occurred much less frequently than cancer in other sites such as the tongue and the floor of the mouth, had a different pattern of metastasis. I became aware of a study done at the University of Virginia in which the members of the Department of Otolaryngology observed a rate of metastasis of approximately 35%, which is the same as in other sites in the oral cavity.

A subsequent study performed in our department[7] validated the findings of the aforementioned study. Based on this study, we adapted the use of the selective neck dissection, bilateral or unilateral based upon the location and extent of the primary. When combined with radiation or chemoradiation, depending on the presence or absence of extracapsular spread, we have been able to establish excellent local regional control in patients undergoing inferior maxillectomy.

Eugene N. Myers

Access the review questions and additional sources list online at http://www.expertconsult.com

REFERENCES

1. Shah JP. Oral cavity and oropharynx. In: Shah JP, editor. Head and Neck Surgery and Oncology. 3rd ed. Chicago, IL: CV Mosby; 2003. p. 73–233.
2. Myers EN, Simental AA. Cancer of the oral cavity. In: Myers EN, Suen JY, Myers JN, Hanna EYN, editors. Cancer of the Head and Neck. 4th ed. Philadelphia, PA: WB Saunders; 2003. p. 279–319.
3. Persky MP. Carcinoma of the palate. News from SPOHNC 2005;14(8):1–3.
4. Simental AA, Myers EN. Cancer of the hard palate and maxillary alveolar ridge: technique and applications. Oper Tech Otolaryngol Head Neck Surg 2005;16:28–35.
5. Aramany MA. Basic principles of obturator design for partially edentulous patients. Part I: classification. J Prosthet Dent 1978;40(5):544–557.
6. Aramany MA, Myers EN. Maxillofacial prosthetic rehabilitation. In: Suen JY, Myers EN, editors. Cancer of the Head and Neck. Endinburgh: Churchill Livingstone; 1981. p. 165–184.
7. Simental Jr AA, Johnson JT, Myers EN. Cervical metastasis from squamous cell carcinoma of the maxillary alveolus and hard palate. Laryngoscope 2006;116(9):1682–1684.
8. Brown JS, Shaw RJ. Reconstruction of the maxilla and midface: introducing a new classification. Lancet Oncol 2010;11(10):1001–1008.
9. Urken ML. Advances in head and neck reconstruction. Laryngoscope 2003;113:1473–1476.
10. Futran ND, Haller JR. Considerations for free-flap reconstruction of the hard palate. Arch Otolaryngol Head Neck Surg 1999;125(5):665–669.

REVIEW QUESTIONS

1. Management of the neck in a patient with squamous cell carcinoma involving the left maxillary alveolus extending to midline includes which levels?
   a. Left level IA and B
   b. Left levels I to III
   c. Bilateral levels IA and B
   d. Bilateral levels I to III

2. According to the Brown and Shaw maxillary defect classification, a maxillary defect involving the orbital **rim,** but preserving the eye and involving greater than half of the palate falls into which of the following classes?
   a. Ia
   b. IIb
   c. IIId
   d. IVc

3. A maxillary defect not involving the orbit and less than half of the hard palate is best reconstructed with which of the following?
   a. Local flap
   b. Prosthesis
   c. Regional flap
   d. Microvascular free flap

ADDITIONAL SOURCES

Aramany MA. Basic principles of obturator design for partially edentulous patients. Part II: design principles. J Prosth Dent 1978;40(6):656–662.

Blot WJ, Winn DM, Fraumeni Jr JF. Oral cancer and mouthwash. J Natl Cancer Inst 1983;70(2):251–253.

Browne JD, Holland BW. Combined intraoral and lateral temporal approach for palatal malignancies with temporalis muscle reconstruction. Arch Otolaryngol Head Neck Surg 2002;128(5):531–537.

Chepeha DB, Khariwala SS, Chanowski EJ, et al. Thoracodorsal artery scapular tip autogenous transplant: vascularized bone with a long pedicle and flexible soft tissue. Arch Otolaryngol Head Neck Surg 2010;136(10):958–964.

Clark JR, Vesely M, Gilbert R. Scapular angle osteomyogenous flap in postmaxillectomy reconstruction: defect, reconstruction, shoulder function, and harvest technique. Head Neck 2008;30(1):10–20.

Cooper JS, Pajak TF, Forastiere AA, et al. Postoperative concurrent radiotherapy and chemotherapy for high-risk squamous-cell carcinoma of the head and neck. N Engl J Med 2004;350(19):1937–1944.

Gellrich NC, Schramm A, Hara I, et al. Versatility and donor site morbidity of the lateral upper arm flap in intraoral reconstruction. Otolaryngol Head Neck Surg 2001;124(5):549–555.

Genden EM, Lee BB, Urken ML. The palatal island flap for reconstruction of palatal and retromolar trigone defects revisited. Arch Otolaryngol Head Neck Surg 2001;127(7):837–841.

Genden EM, Wallace D, Buchbinder D, et al. Iliac crest internal oblique osteomusculocutaneous free flap reconstruction of the postablative palatomaxillary defect. Arch Otolaryngol Head Neck Surg 2001;127(7):854–861.

Graham S, Dayal H, Rohrer T, et al. Dentition, diet, tobacco, and alcohol in the epidemiology of oral cancer. J Natl Cancer Inst 1977;59(6):1611–1618.

Gullane PJ, Arena S. Palatal island flap for reconstruction of oral defects. Arch Otolaryngol 1977;103(10):598–599.

Inagi K, Takahashi H, Okamoto M, et al. Treatment effects in patients with squamous cell carcinoma of the oral cavity. Acta Otolaryngol 2002;547(Suppl):25–29.

Kurokawa H, Yamashita Y, Takeda S, et al. Risk factors for late cervical lymph node metastases in patients with stage I or II carcinoma of the tongue. Head Neck 2002;24(8):731–736.

Mahboubi E. The epidemiology of oral cavity, pharyngeal and esophageal cancer outside of North America and Western Europe. Cancer 40(Suppl. 4):1879-1886.

Moore BA, Magdy E, Netterville JL, et al. Palatal reconstruction with the palatal island flap. Laryngoscope 2003;113(6):946–951.

Petruzzelli GJ, Myers EN. Malignant neoplasms of the hard palate and upper alveolar ridge. Oncology 1994;8(4):43–48.

Pimenta Amaral TM, Da Silva Freire AR, Carvalho AL, et al. Predictive factors of occult metastasis and prognosis of clinical stages I and II squamous cell carcinoma of the tongue and floor of the mouth. Oral Oncol 2004;40(8):780–786.

Reddy CR. Carcinoma of hard palate in India in relation to reverse smoking of chuttas. J Natl Cancer Inst 1974;53(3):615–619.

Sparano A, Weinstein G, Chalian A, et al. Multivariate predictors of occult neck metastasis in early oral tongue cancer. Otolaryngol Head Neck Surg 2004;131(4):472–476.

Wynder EL, Kabat G, Rosenberg S, et al. Oral cancer and mouthwash use. J Natl Cancer Inst 1983;70(2):255–260.

SECTION 6 Oropharynx

33 Transoral Excision of Oropharyngeal Malignancy

Sefik A. Hosal, Canset Aydin

INTRODUCTION

The most favorable management of oropharyngeal cancer is still controversial. In the past, oropharyngeal cancers were treated with surgery followed by radiation. Surgical resection usually required mandibulectomy or mandibulotomy and removal of pharyngeal musculature, which resulted in significant morbidity. Because of the functional and cosmetic impairments and current development of organ preservation regimens, chemoradiation has become the treatment of choice in many patients with cancer of the oropharynx. Furthermore, studies have demonstrated an increased incidence of human papilloma virus (HPV)-related cancer of the oropharynx, particularly among young adults who have a better prognosis. There are emerging data that less aggressive treatment can be performed in this group of patients without sacrificing the good cure rate.

The oropharynx is the middle part of the throat that extends from the junction of the soft and hard palate superiorly to the superior edge of the epiglottis and the hyoid bone inferiorly, circumvallate papillae of the tongue anteriorly, and pharyngeal wall posteriorly. It includes the base of the tongue, the soft palate, the lateral and posterior pharyngeal walls, the tonsils, and tonsil pillars. The function of this region is crucial in swallowing, respiration, and speech. It is noteworthy that the swallowing function is adversely affected both by surgical resections and chemoradiation. Dysphagia and poor speaking may result in social problems, but aspiration may cause life-threatening complications. Therefore appropriate selection of the type of surgical approach is quite important in the management of cancer of the oropharynx.

The prognosis and treatment of cancer of the oropharynx are strongly related to the involvement of cervical lymph nodes. The incidence of lymphatic metastasis is relatively high, depending on the subsite. Even in patients with no adenopathy at the time of diagnosis, elective ipsilateral or bilateral neck treatment is required either through a neck dissection or by radiation therapy. In addition, the tonsillar fossa and base of the tongue are known as the most common potential mucosal sites in unknown primaries. There is also a risk for metastasis to the retropharyngeal lymph nodes in cancer of oropharynx, particularly in those patients in whom the posterior pharyngeal wall or the soft palate is involved. These nodes are beyond the classical neck dissection. The majority of those patients are required to have adjuvant radiotherapy. In such instances, radiation therapy is rational as a single treatment modality for primary and lymphatic metastasis, as well. Otherwise, transoral surgery is a feasible option in selected early limited cancer, in which the need for adequate exposure is fundamental.

Transoral resection of cancer of the oropharynx was first described by Huet in 1951.[1] This technique eliminates the morbidity created by the mandibular swing or composite resection. In addition, this minimally invasive surgery may avoid adverse consequences of chemoradiation with comparable outcome. Moreover, it provides pathologic staging for further adjuvant treatment.[2] Transoral surgery is generally indicated in early-stage cancer of the oropharynx. This can be done either via transoral robotic surgery or endoscopy-based transoral laser microsurgery. The transoral approach has been expanded with the development of transoral robotic surgery. This technological improvement provides three-dimensional visualization for precise dissection and safety of margins. There are some advantages of robotic surgery, including shorter hospitalization, rapid functional recovery, avoidance of tracheostomy, and reduced need for nasogastric tube feeding. We favor transoral robotic surgery in carefully selected patients.

KEY OPERATIVE LEARNING POINTS

- Careful patient selection
- Accurate assessment of tumor extension and lymph node involvement
- Surgical anatomy of the carotid artery and association pharyngeal structures
- Special training for robotic surgery if transoral robotic surgery is preferred
- Ipsilateral or bilateral neck dissection is necessary. It can be done either simultaneously or separately. We prefer concurrent neck dissection following transoral resection.

PREOPERATIVE PERIOD

History

- History of present illness
  - Persistent sore throat, throat discomfort
  - Neck mass
  - Odynophagia, referred otalgia with swallowing, globus sensation
  - Trismus, dysphagia, bleeding, difficulty moving the tongue
- Past medical history
  - Tobacco use, alcohol consumption, betel quid chewing
  - HPV exposure
  - Radiation exposure
  - Comorbid diseases, including systemic diseases and hemorrhagic diatheses
  - Medications and herbal products being used

Physical Examination

- Oral cavity—oropharynx
  - Must include all mucosal surfaces to evaluate a second primary or extension of the primary tumor to surrounding structures

  - Any dentures should be removed during the inspection.
  - Palpation for size, deep fixation, and mobility of the lesion
  - Assessment of cranial nerves, particularly cranial nerve IX, X, and XII
- Endoscopy
  - Both flexible and rigid endoscopic evaluation
  - Endoscopy under general anesthesia. This is preferred before definitive treatment in order to evaluate for the adequate exposure and availability of the tumor for transoral approach.
- Neck
  - Palpation of the both necks
  - Recording of the levels of lymph node involvement

Imaging

- Computed tomography (CT), for bony invasion of the skull base, mandible, and status of the lymph nodes, particularly retropharyngeal lymph nodes
- Magnetic resonance imaging (MRI) for the depth of tumor invasion, perineural infiltration, and association with vital structures, particularly the carotid artery
- Positron emission tomography–computed tomography (PET-CT) to discover distant metastasis, especially in cases of advanced cancer. Not required in all cases

Indications

- Primary or recurrent cancer of the oropharynx, which can be excised transorally depending on the surgeons' experience and patients' condition and wishes
- Generally indicated in T1 and T2 cancers of the soft palate (Fig. 33.1), posterior pharyngeal wall, tonsil and anterior pillar, the base of the tongue, and uvula (Fig. 33.2)

Contraindications

- Trismus
- Inadequate exposure
- In robotic surgery, cancer requiring resection of more than 50% of the base of the tongue or more than 50% of the posterior pharyngeal wall (Fig. 33.3)[3]
- Close association of the tumor with carotid artery
- Invasion into the parapharyngeal space[4]
- Bone invasion
- Tumor fixation of prevertebral fascia
- Invasion of the vital structures by the primary cancer
- Unresectable lymph node metastasis regardless of the primary cancer

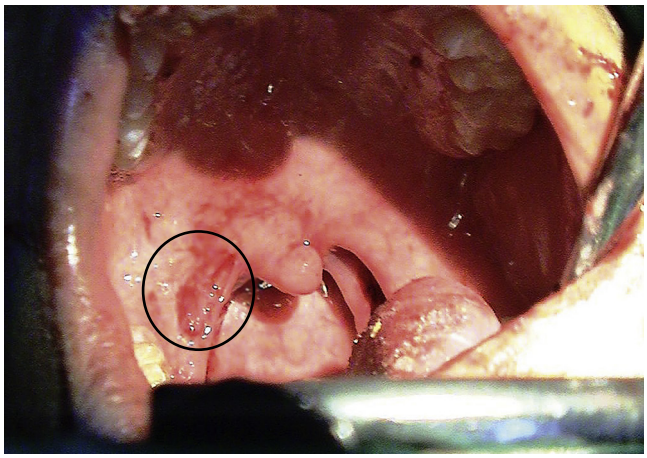

Fig. 33.1. Superficial carcinoma of the soft palate.

- Poor exposure due to patients anatomic situation, such as micrognathia, cervical spine injury, macroglossia
- Inability to convert to open surgery intraoperatively
- Patients preference for another treatment modality
- Comorbid diseases with increased risk for general anesthesia
- Distant metastasis. Adenoid cystic carcinoma with limited pulmonary metastasis may be an exception.

Preoperative Preparation

- Biopsy to confirm the diagnosis
- Review any biopsies or tissue from previous surgery
- Routine laboratory tests and preparation of red blood cell suspension for probability of transfusion during surgery

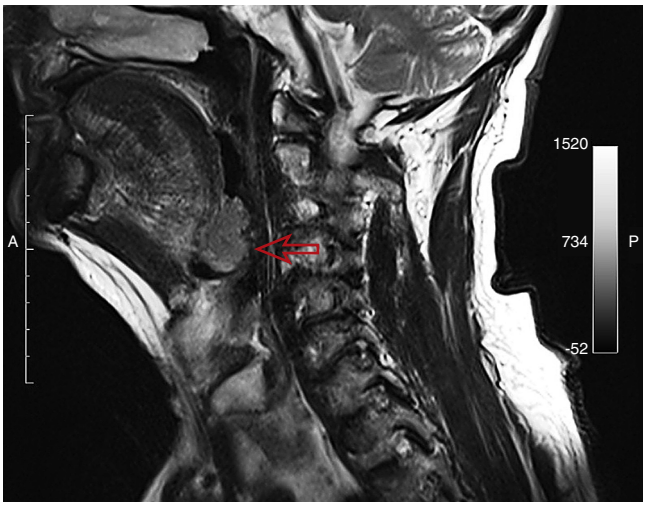

Fig. 33.2. T2 sagittal section of magnetic resonance imaging showing the tumor of the base of the tongue (arrow) accessible for transoral surgery.

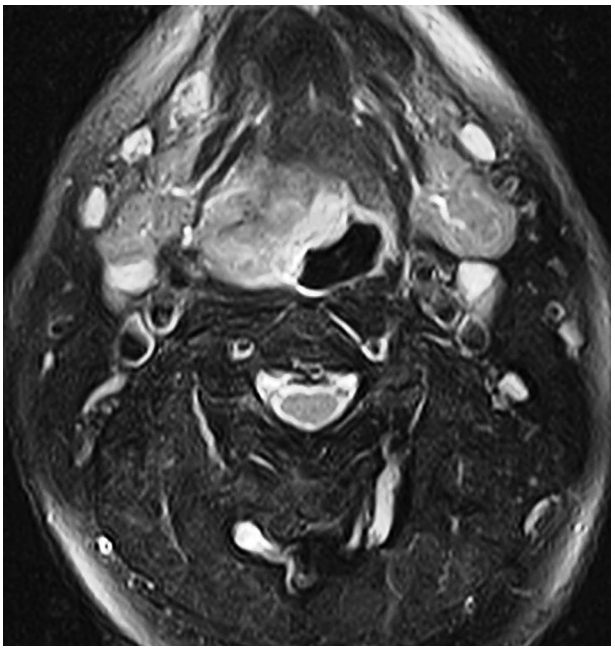

Fig. 33.3. Tumor invasion with more than 50% of the base of the tongue is a contraindication for transoral surgery.

- Cessation of antiplatelets/anticoagulant drugs
- Evaluation of the patient's dentition is essential to prevent osteoradionecrosis due to probable postoperative radiotherapy.
- Dental consultation with prosthodontist for temporary postoperative palatal prosthesis in patients who need partial resection of the palate
- Counseling of the patient about the probable needs for temporary tracheostomy and/or nasogastric tube
- Cervical lymph node dissection is a part of the treatment of cancer of the oropharynx even in N0 neck; thus the patient should be informed about neck dissection.

OPERATIVE PERIOD

Anesthesia

- General anesthesia with orotracheal, nasotracheal intubation or a tracheostomy

Positioning

- Supine position with neck extended with shoulder roll

Perioperative Antibiotic Prophylaxis

- Ampicillin sodium/sulbactam sodium

Monitoring

- Routine anesthesia monitoring

Instruments and Equipment to Have Available

- Standard tonsil surgery set
- Standard neck dissection set
- Mouth retractors (Crowe Davis or Feyh-Kastenbauer)
- Teeth-protecting molds
- Headlight
- Bipolar cautery
- Monopolar electrocautery
- A CO_2 laser device if transoral laser microsurgery is preferred
- A robotic system if transoral robotic surgery is preferred

Key Anatomic Landmarks

- Keep thin adipose tissue and fascia layer in the posterolateral parapharyngeal region to protect the carotid artery and to prevent communication into the neck (Fig. 33.4).
- Branches of the lingual artery

Prerequisite Skills

- Experience in locating and protecting the carotid artery
- Robotic surgery requires special training and a learning curve.
- The surgical team must set up for conversion to open surgery.

Operative Risks

- Intraoperative bleeding
- Injury of the nerves
- Injury to the teeth

Surgical Technique

- Provide sufficient exposure with mouth gag (Figs. 33.5 and 33.6).
- Palpate and confirm that the cancer is mobile, not fixed to the deep structures.
  - Posterior pharyngeal wall
    - Mark incisions by making dots with monopolar electrocautery (Fig. 33.7).
    - Keep at least 1-cm safety margin around the cancer.
    - Grasping and retraction of the cancer provide extending the incisions through the submucosal plane (Fig. 33.8).
  - Tonsillar region

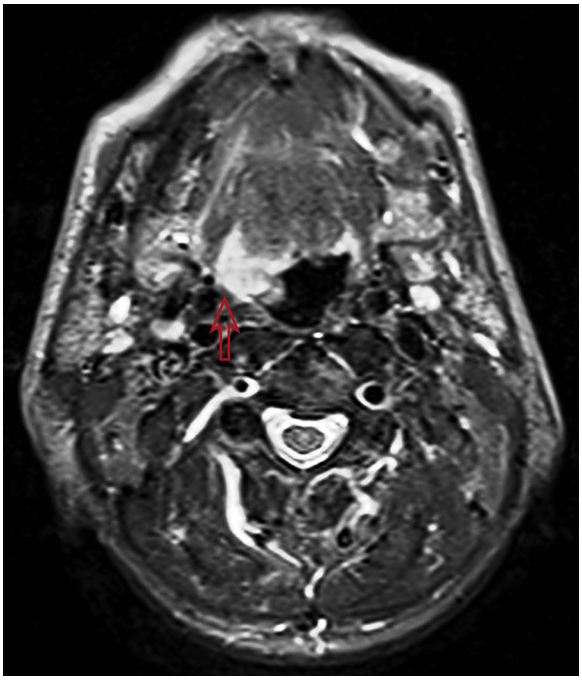

Fig. 33.4. T1 axial scan, arrow demonstrating thin adipose tissue and fascia layer in the posterolateral parapharyngeal region.



Fig. 33.5. Adequate exposure with standard mouth retractor for cancer of the right tonsil.

  - Excision starts at the retromolar trigone extending to the pterygomandibular raphe that is the lateral and superior aspect of the cancer (Fig. 33.9).
  - Dissection proceeds in the superior to inferior direction.
- Base of the tongue
  - Outline all incisions with dotted lines by cautery. This is particularly useful for the deep inferior margin. Starting incision may begin at the anterior aspect of the lesion to pull the cancer posteriorly. Alternatively, a deep horizontal incision may be done at first for the safety of the inferior margin.
- Bleeding from small veins and arteries is controlled by cautery. Branches of the lingual artery may require vascular clips (Fig. 33.10).
- Inspect for pulsation of the carotid artery posterolaterally, which is covered by fascia and adipose tissues.
- Palpate the depth of the lesion during excision that helps to obtain negative tumor margins; however, this is not likely with robotic surgery.
- Resect the cancer en block, and mark the specimen with a suture so the pathologist can orient the specimen.
- Frozen sections must be obtained from all sides and the deep aspect. Free margins are mandatory for local control and survival.
- The surgical field is left open for healing by second intention.
- The patient is prepared for unilateral or bilateral neck dissection.

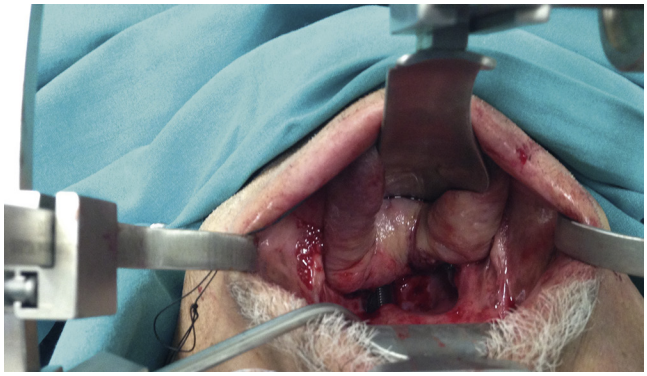

Fig. 33.6. Exposure with FK retractor in robotic surgery.

Common Errors in Technique

- Inadequate exposure
- Starting with the anterior incision without marking the inferior margin may cause disorientation at the inferior or posterior part of the cancer, which may risk safe margins.
- Inaccurate preoperative evaluation for the extent of the cancer
- Inaccurate evaluation of the status of retropharyngeal lymph nodes
- Failure in assessment of surgical margins
- Poor positioning of robotic arms if robot is used

POSTOPERATIVE PERIOD

Postoperative Management

- Local wound care with mouth rinses and gargles
- Prophylactic broad-spectrum antibiotics for 5 to 7 days
- Oral feeding in the first postoperative day unless tracheostomy and nasogastric tube placement
- Elevation of the head to prevent edema
- Nonsteroidal anti-inflammatory drugs are usually used to control pain. If pain is not relieved with these drugs, narcotic analgesics can also be used in the early postoperative period.
- Proton pump inhibitors for antireflux treatment or stress ulcers
- If tracheostomy is present, decannulate as soon as there is an adequate airway.
- If a nasogastric tube is present, removal of the tube is delayed until decannulation of the tracheostomy.
- Rehabilitation for swallowing

Complications

- Airway edema
  Patients should be monitored and treated with intravenous steroids. The risk of swelling is usually in the first 24 hours. If there are significant edema and airway compromise, a temporary tracheotomy may be necessary.
- Unplanned tracheostomy
  Related to airway edema
- Tongue swelling and tongue numbness
  Related to the mouth retractors. Prolonged retraction in longer surgery may increase the risk. Tongue numbness is generally transient and resolves in time.

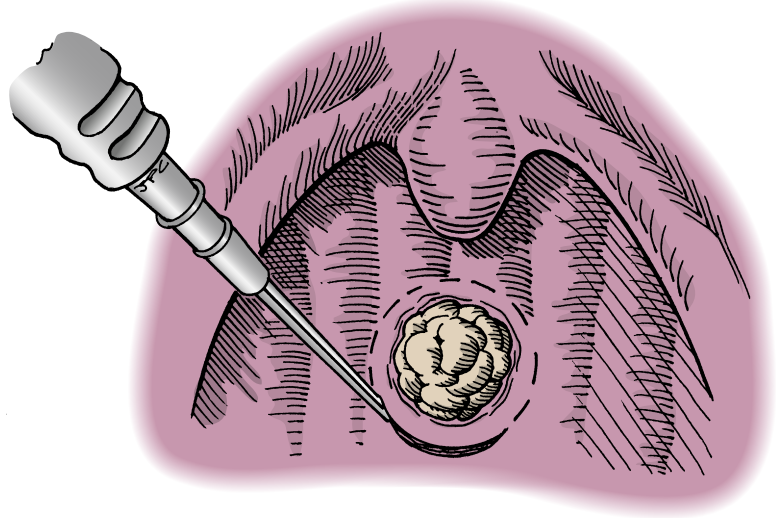

Fig. 33.7. Marking the incision by making dots with monopolar electrocautery. The portion of the mucosal incision that is most difficult to visualize should be made first.

- Bleeding
  Occurs mostly in the first 2 weeks. Minor bleedings require observation only. Major bleeding may be sometimes catastrophic. Exploration of the neck and ligation of the external carotid system should be done under general anesthesia. Alternatively, the bleeding vessel can be identified by angiography, and endovascular embolization can be performed.
- Aspiration and aspiration pneumonia
  There may be some degree of aspiration due to swallowing dysfunction. Swallowing therapy is recommended. Significant aspiration requires nasogastric tube placement.
- Fistula formation between neck and pharynx
  Some surgeons prefer to delay the neck dissection for a few weeks after the transoral surgery for avoidance of this problem. The probability increases with previous radiation therapy. Daily wound dressing in the neck, stopping oral feeding, or placing a drain to divert the saliva away from vascular structures can be done. This may heal on its own, or sometimes additional surgical procedures may be necessary to close the fistula.
- Nerve injuries
  Neuropraxia may occur, mostly in the hypoglossal nerve. Usually transient and secondary to retractor pressure
- Wound breakdown
  Associated with concurrent neck dissection in previously radiated necks. Treated with antibiotics and wound dressing
- Rhinolalia
  Results from excessive resection of the soft palate. Pharyngoplasty with suturing pillars is recommended.

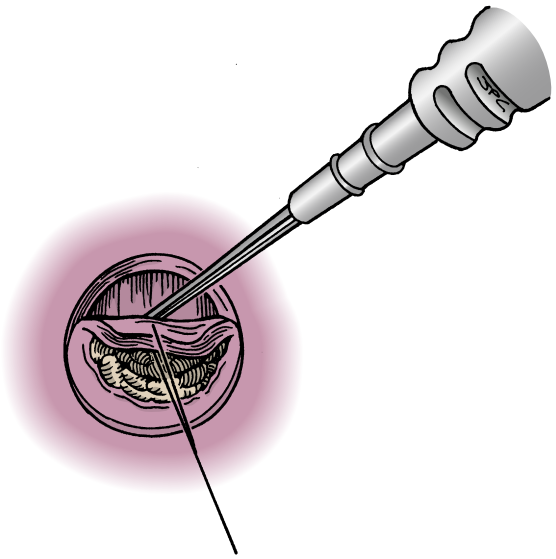

Fig. 33.8. Grasping and retraction of the tumor provide extending the incisions through submucosal plane. A suture is placed for retraction, as well as orientation of the specimen for the pathologist.



Fig. 33.9. Marking incisions in robotic surgery for carcinoma of the tonsil.

Alternative Management Plan

- Nonsurgical treatment with chemoradiation
- Open surgical approaches
  - Transmandibular
    - Mandibulotomy
    - Mandibular swing
  - Transcervical transpharyngeal
    - Transhyoid pharyngotomy
    - Lateral pharyngotomy

DISCUSSION

Evidence-Based Medicine Question

Does transoral surgery for cancer of the oropharynx provide better outcome than open conventional surgery or chemoradiation?

There is no randomized controlled trial of surgical or nonsurgical management of oropharyngeal cancer. Furthermore, there are no randomized studies comparing transoral surgery with open surgery. However, recently there is increasing evidence suggesting the efficacy of transoral robotic surgery for oropharyngeal cancer. A prospective analysis of small case studies and few larger studies indicates encouraging results on safe marginal control, few complications, short hospital stay, less swallowing dysfunction, and fewer tracheotomies.[4-6] Better quality of life scores have also been reported in nonrandomized clinical studies.[2] Current data on robotic surgery support promising favorable outcome in selected cases of cancer of the oropharynx. However, oncologic results have not been validated with controlled studies yet.

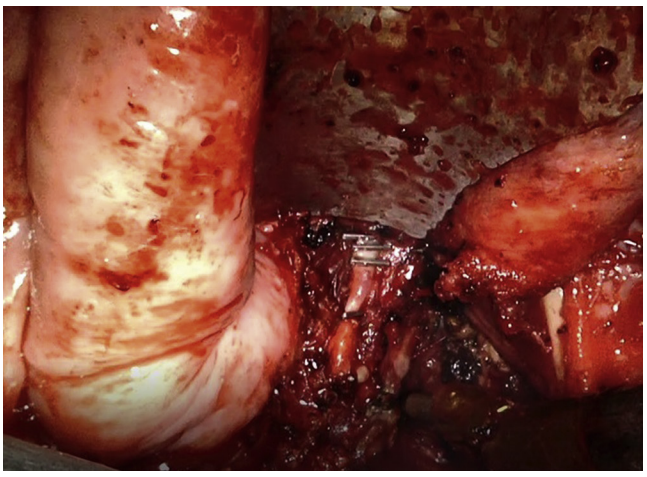

Fig. 33.10. Vascular clips on the lingual artery during robotic surgery for the base of the tongue cancer.

Editorial Comment

This is a nicely written and concise chapter that provides an overview of transoral surgery for cancer of the oropharynx. Although chemoradiation remains a viable alternative to surgical approaches for oropharyngeal cancer, the immediate and late side effects are real and affect patients for their lifetime. Despite these significant consequences, there has been a prevailing practice to avoid the destructive effects of classic open mandibulotomy approaches in favor of chemoradiation. However, this paradigm is shifting with the resurgence of transoral laser microsurgery (TLM) and the advent of transoral robotic surgery (TORS). Although current data as to the value of transoral surgery versus chemotherapy come from only published cohort studies, there are large controlled national studies that are ongoing and that may eventually provide the definitive support for primary surgery instead of chemoradiation for cancer of the oropharynx.

Bert O'Malley, Jr.


Access the review questions online at http://www.expertconsult.com

REFERENCES

1. Holsinger FC, McWhorter AJ, Menard M, et al. Transoral lateral oropharyngectomy for squamous cell carcinoma of the tonsillar region: I. Technique, complications, and functional results. Arch Otolaryngol Head Neck Surg 2005;131:583–591.
2. Karatzanis AD, Psychogios G, Waldfahrer F, et al. Surgical management of T1 oropharyngeal carcinoma. Head Neck 2012;34:1277–1282.
3. Weinstein GS, O'Malley BW, Rinaldo A, et al. Understanding contraindications for transoral robotic surgery (TORS) for oropharyngeal cancer. Eur Arch Otorhinolaryngol 2015;272:1551–1552.
4. Moore EJ, Olsen KD, Kasperbauer JL. Transoral robotic surgery for oropharyngeal squamous cell carcinoma: a prospective study of feasibility and functional outcomes. Laryngoscope 2009;119:2156–2164.
5. Weinstein GW, O'Malley BW, Magnuson JS, et al. Transoral robotic surgery: a multicenter study to assess feasibility, safety, and surgical margins. Laryngoscope 2012;122:1701–1707.
6. Hans S, Delas B, Gorphe P, et al. Transoral robotic surgery in head and neck cancer. Eur Ann Otorhinolaryngol Head Neck Dis 2012;129:32–37.

REVIEW QUESTIONS

1. Which of the following is NOT a contraindication for transoral resection of oropharyngeal cancer?
   a. Trismus
   b. Recurrent tumor of the base of the tongue
   c. Involvement of the parapharyngeal space
   d. Bone invasion

2. Which of one the following is FALSE for transoral robotic surgery for oropharyngeal cancer?
   a. Short hospitalization
   b. Less swallowing dysfunction
   c. Indicated in advanced stage
   d. Less tracheostomy

3. All of the following statements for transoral resection in oropharyngeal cancers are TRUE, except
   a. Frozen section is not necessary
   b. Neck dissection can be done simultaneously or staged
   c. Experience is needed to locate and protect the carotid artery
   d. Adequate exposure is required

34 Transoral Laser Microsurgery of the Base of the Tongue

Guy Petruzzelli

INTRODUCTION

The base of the tongue (BOT) is the most anterior-superior portion of the oropharynx bounded anteriorly by the circumvallate papillae, laterally by the paired glosso-palatine sulci, and inferiorly by the vallecula. The BOT is formed from the medial fusion of elements from the first and second and is composed of both the endoderm and ectoderm. The branchial arch hypobranchial prominence, a specialized region of second branchial pouch mesoderm, is located posteriorly on the rudimentary tongue. This structure will eventually differentiate into the thyroid primordium and descent via the foramen cecum into the neck. Embryology provides the basis for the development of the benign tumors (lingual thyroid, hemangioma, dermoid) that are observed in this region. The BOT is histologically complex, with nonkeratinizing stratified squamous epithelium covering lymphoid aggregates (lingual tonsils), minor salivary glands, and striated muscle accounting for the multiple epithelial (squamous cell carcinoma, lymphoepithelioma) and nonepithelial (lymphoma, sarcoma, minor salivary gland) malignancies in this location. Transoral resection of the BOT can be used for definitive excision of low-grade and benign neoplasms, definitive resection of high-grade malignancies prior to adjuvant treatment, assessing the BOT in the survey for the occult primary, and volume reduction of the BOT in cases of obstructive sleep apnea.

Specialized retractor systems provide improved transoral exposure and access to tumors of the BOT, and the development of laser fibers and enhanced optics have provided greater surgical visualization and operative ability in this region. These elements have contributed to a renewed interest in primary surgical treatment for selected malignancies of the BOT. Since transoral laser microsurgery resections heal by re-epithelization reconstruction, flaps are not used, thereby eliminating donor site morbidity. Transoral resection of tumors obviates the need for a pharyngotomy, thus significantly reducing the likelihood of salivary contamination of the neck and wound infection. In selected patients, tracheostomy can also be avoided, thus providing an earlier return of speech and deglutition. Finally, data obtained from histologic analysis of surgical specimens can more precisely identify patients for appropriate adjuvant treatment. Clinical trials are currently being carried out that, based on human papilloma virus status, are looking to "deintensify" adjuvant chemotherapy and radiation, thus decreasing late toxicity and improving return of function and overall quality of life.

It is important that the head and neck surgeon understand that TLM resection of the tongue base is one technique in the armamentarium of surgical exposures to the oropharynx. The surgeon must consider not just the anatomic location but the biology of the tumor, the risks to surrounding structures, vascular control, airway protection, reconstructive options, and most critically the goals and wishes of the patient in making treatment recommendations.

KEY OPERATIVE LEARNING POINTS

1. TLM procedures are tedious and require extreme patience.
2. Formal staging endoscopy and examination under anesthesia may be necessary to determine if transoral resection is feasible.
3. Multiple oral retractor systems and/or fixed bore and bivalve laryngoscopes may all be needed to provide safe and complete resection of the tumor.
4. Retractors may need to be repositioned several times during the resection.
5. Multiple frozen sections may be needed.
6. Suction cautery to supplement the laser for hemostasis
7. The line of sight laser micromanipulator is not adequate in all cases. Laser fibers are needed to work on an upward angle into the BOT.
8. Standard tonsillectomy instruments are too short to reach deep into the vallecula. Modified 22-cm working distance specialized insulated instruments are necessary.

PREOPERATIVE PERIOD

History

1. Medical and surgical history including active medical problems and comorbidities, current medications, allergies, and complete review of systems
2. Otalgia in the normal appearing ear
3. Social history should include a history tobacco and alcohol use and risk factors for exposure to the human papilloma virus.
4. Prior environmental, history occupation of therapeutic exposure to low-dose ionizing radiation, particularly as a child
5. Chief complaint and review of systems positive for otalgia, dysphagia, dysarthria, foreign body sensation, oral of pharyngeal pain, voice changes, worsening snoring or exacerbation of sleep apnea syndrome, foul breath (from necrotic tumor)
6. Other factors that should be considered include history of obstructive sleep apnea, morbid obesity, prior head and neck surgery, and/or radiation therapy to the head and neck.
7. Treatment with oral antibiotics for cervical lymph adenopathy without a history of symptoms of infection (no fever, malaise, pain)
8. Asymptomatic mass in the neck
9. "Hot potato" voice

Physical Examination

1. Assessment of comorbidities with appropriate cardiac and pulmonary risk stratification
2. Evaluate tongue motion, protrusion, fixation, and fasiculations.
3. Fiberoptic naso-pharyngoscopy, inspection, and palpation of the base of the tongue
4. Examination of the base of the tongue with a magnified angled Hopkins telescope
5. Careful attention to the epiglottis should be performed as well. Cancer of the BOT may involve the supraglottis either by superficial extension or deep infiltration.
6. Detailed palpation and office ultrasound of the neck. In our own experience approximately 85% of patients treated for cancer of the BOT will present with a mass in the neck on initial physical examination.

Imaging

1. Initial imaging with contrast enhanced computed tomographic (CT) scanning
   - Imaging cervical metastases is best performed with contrast-enhanced CT scan.
   - Diameter greater than 15 mm, central necrosis, round shape, and loss of a clear margin of the node borders and obscured adipose tissue planes indicating extracapsular extension all indicate metastatic adenopathy.
2. Contrast-enhanced magnetic resonance imaging (MRI)
   - MRI acquires data in a multiplanar fashion and better visualization of subtle soft tissue details.
   - Visualization of local extension of the cancer into the intrinsic muscles of the tongue, perineural spread, submucosal extension of the tumor, inferior extension into the preepiglottic space, and lateral extension into the parapharyngeal and carotid spaces
3. PET-CT scan
   - Patients with stage IV disease or those at increased risk of harboring metastatic cancer
   - Patients with unknown primary carcinomas
   - Restaging patients prior to aggressive salvage treatment

Indications

1. Lingual tonsillectomy for chronic lingual tonsillitis or hypertrophy or biopsy of suspected lymphoma arising in Waldeyer ring
2. Volume reduction of the tongue base for obstructive sleep apnea
3. Management of obstructing lingual thyroid or other benign neoplasm of the base of the tongue
4. Staging the patient with an occult primary of the head and neck—excisional biopsy of the lingual tonsils and base of the tongue
5. Definitive resection of oropharyngeal (base of the tongue, tonsil, soft palate uvula, posterior pharyngeal wall) squamous cell carcinoma
6. Definitive resection of minor salivary gland neoplasms of the base of the tongue

Contraindications

1. Trismus—Reduced mandible-maxilla excursion with inability to place appropriate retractors
2. Teeth—Visualization obscured by dentition
3. Tumor—Bulky, friable, and/or hemorrhagic tumor obscuring visualization or a tumor with a depth of infiltration into the tongue base that precluded obtaining a satisfactory deep oncologic margin
4 Tori—Large obstruction maxillary or mandibular tori
5. Tongue—Relative macroglossia and redundant tongue tissue that cannot be satisfactorily retracted by the blades of the operating oropharyngoscope, thus collapsing into lumen
6. Tummy—Morbid obesity is frequently associated with a narrow oropharyngeal passage and poor visualization of the cancer.
7. Tonsils (lingual)—Lingual tonsillar hypertrophy obscuring the view of the tumor and making differentiation from tumor challenging
8. Throat—Elongated thin neck with narrow mandibular arch
9. Tilt—Limitations in neck extension from fibrosis from prior radiotherapy, degenerative disease of the cervical spine, or morbid obesity with unfavorable body habitus
10. Therapy—Prior surgical or nonsurgical therapy can limit exposure and make differentiation of normal from abnormal tissue difficult.

Preoperative Preparation

1. Complete history and physical examination as noted above
2. Fiberoptic laryngoscopy with careful assessment of airway anatomy, neck extension, intubation risks
3. Review of imaging studies
4. Pretreatment biopsy prior to TLM is essential in patients with a lesion of the base of the tongue to rule out lymphoreticular or other tumors not treated with primary surgery.
5. Discussion at multidisciplinary tumor planning conference as indicated
6. Careful informed consent included discussion of emergency airway management, including tracheostomy, postoperative hemorrhage requiring operative or angiographic control, dental injury, tongue numbness or paralysis, taste disturbance, and need for delayed extubation.
7. Panendoscopy and biopsy as needed prior to TLM resection definitive resection
   - Fine-needle aspiration of suspicious cervical masses
   - Transoral biopsies of the tongue base when feasible
   - Obtain definitive histopathologic biopsy material prior to definitive resection.
   - Assess for synchronous primary head and neck malignancies.
   - Determine anatomic constraints for access to the tumor.
   - Evaluate the transoral exposure of the tongue base, microscopic visualization of the tumor, and ultimate suitability for transoral laser microsurgery.

OPERATIVE PERIOD

Anesthesia

Close frequent communication between the head and neck surgeon and the anesthesia teams is imperative in safely managing patients undergoing TLM. Postprocedure airway management (extubation, overnight intubation, or tracheostomy) must be discussed with the anesthesia team prior to the conclusion of the operation. Information gleaned from the preoperative endoscopy and ease of initial intubation should all be considered in formulating the plan for postprocedure airway management.

1. TLM is performed under general anesthesia.
2. Orotracheal intubation using laser-approved endotracheal tubes
   - T1 or T2 lateral cancer undergoing
   - Unilateral neck dissection
3. Indications for tracheostomy
   - Exophytic friable lesion or obstruction of true vocal folds
   - Bilateral neck dissections in the event of venous or lymph edema of the larynx
   - Resection involves portion of supraglottis, thereby reducing the patients' ability to protect the airway
   - Higher risk for secondary hemorrhages (significant operative hemorrhage or large exposed surface area)

Positioning

TLM is performed with the patient in the supine position with the head placed in extension. A shoulder roll may not always be needed to facilitate exposure of the oropharynx and the base of the tongue.

Preoperative Antibiotic Prophylaxis

One of the principal advantages of the TLM approach is obviating the need for a pharyngotomy or mandibulotomy

approach. Therefore TLM with a neck dissection can be classified as clean uncontaminated surgery, requiring only one dose of parenteral antibiotics with a first-generation cephalosporin. However, in many cases the neck can be contaminated from the following:

1. Inadvertent pharyngotomy during tumor resection
2. Micropharyngotomy (which can be unrecognized) at the time of tumor resection
3. Planned pharyngotomy to facilitate resection and margin control for a larger tumor

For those reasons, we treat all TLKM cases as clean contaminated procedures and use ampicillin-sulbactam 3 g IV every 6 hours intraoperatively and for 48 hours postoperatively. In penicillin-sensitive patients we use clindamycin 600 mg IV every 8 hours intraoperatively and for 48 hours postoperatively. Patients requiring either a pedicle or free flap reconstruction have their antibiotic coverage extended to 5 days postoperatively.

Monitoring

Routine anesthesia monitoring, appropriate for the patients comorbidities and expected length of the procedure, are all that are required for TLM. Cranial nerves are not routinely monitored.

Instruments to Have Available

1. Carbon dioxide laser with capability for micromanipulator and fiber delivery systems as needed
2. Microscope
3. Retractor systems—Bivalve oropharyngeal retractors (Karl Storz), modified FK oropharyngeal retractor, Davis retractor blades with integrated suction ports (Fig. 34.1)
4. Laser plume and cautery smoke evacuation systems
5. Insulated suction cautery
6. Large caliber laryngeal suction
7. Endoscopic clip appliers curved and straight working length 22 cm
8. Insulated grasping forceps working length 22 cm
9. Large oval grasping forceps with integrated suction working length 22 cm
10. Cotton pledgets with topic hemostatic agent
11. Suspension system for bivalve laryngoscopes and oral retractors
12. Standard head and neck surgical instruments for neck dissection and conversion to transcervical pharyngotomy for complete tumor resection

Key Anatomic Landmarks

Transoral laser microsurgery requires a paradigm shift in understanding the anatomy of the head and neck from

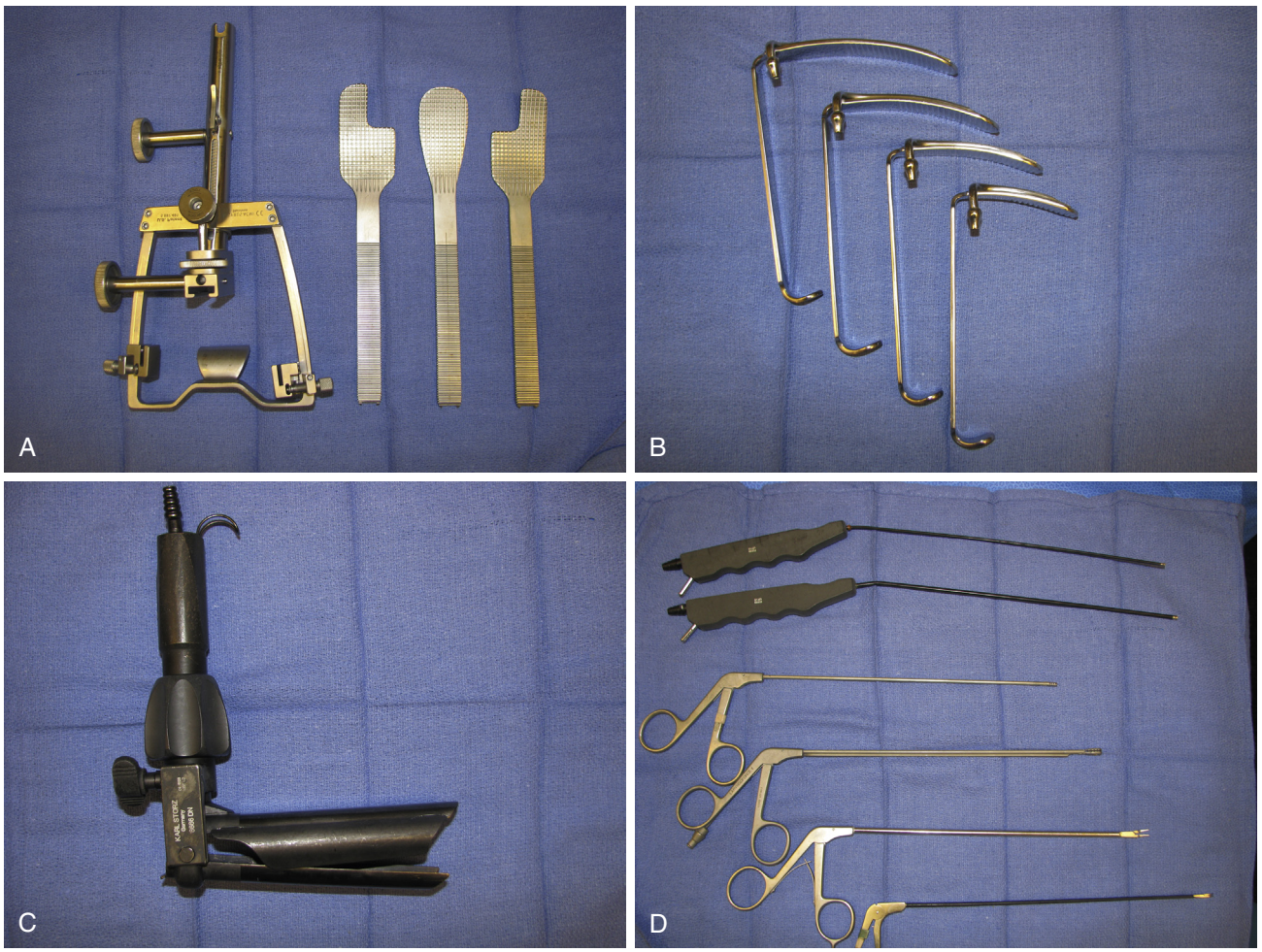

Fig. 34.1. Instrumentation for TLM. **A,** FK retractor system with notched blades. **B,** Davis blades with integrated suction for Crowe-Davis retractor. **C,** Steiner self-retaining oropharyngoscope with integrated suction. **D,** Steiner instrumentation with graspers, clip appliers, and suction cautery.

the traditional superficial to deep ("outside-in") orientation learned in the anatomy laboratory to an "inside-out" approach. Critical landmarks are:

1. Identification of the circumvallate papillae defining the junction of the base of the tongue and the oral tongue
2. Dorsal lingual branch of the lingual artery
   a. Originates deep to the hyoglossus muscle
   b. Courses superior to the lateral surface of the genioglossus muscle
   c. Tortuous vessel with convoluted course
   d. Will be encountered deep to hyoid bone with deep and inferior resections
3. Hypoglossal nerve courses lateral to the carotid artery and can be encountered in the anterior aspect of tongue base

Prerequisite Skills

Carcinomas of the base of the tongue represent one of the greatest challenges for the transoral laser microsurgeon. According to Steiner, "the base of the tongue is the most unfavorable area for endoscopic surgery, especially if the exposure through the distending laryngoscope is not optimum." Transoral laser surgery should not be attempted without prior experience with:

1. Careful office assessment of the base of the tongue and ability to perform staging endoscopy if needed
2. Transoral laser laryngeal microsurgery
3. Laser or cautery palatine and lingual tonsillectomy
4. Ability to control intraoperative and postoperative hemorrhage
5. Neck dissection
6. Ability to convert to open resection of the tongue base by transcervical (suprahyoid or lateral) pharyngotomy
7. Close working relationship with pathologists
8. Patience

Operative Risks

1. Airway or operative field fire
2. Dental injury
3. Lingual or hypoglossal neuropraxia due to pressure from the retractor with resulting anesthesia of the tongue, paralysis, and disturbance of taste
4. Lingual, facial, or ascending pharyngeal artery hemorrhage
5. Inadvertent and unrecognized pharyngotomy
6. Failure of visualization and incomplete tumor resection
7. Facial burn
8. Laser injury to the operative team or the surgeon

Description of the Technique

1. Set the CO_2 laser at 10 to 15 watts continuous super pulse mode for dissection.
2. If a tracheostomy is anticipated, perform it now to maximize visualization.
3. Place dental protectors—Dental injury can be prevented by carefully placing any one of a number of commercially available plastic tooth protectors. Custom thermoplastic teeth guards can be fabricated from sheaths of Aquaplast external nasal splint.
4. An appropriately sized retractor is placed just anterior to the foramen cecum, the microscope is positioned, and the initial curvilinear incision is made at the level of the circumvallate papillae. A temporary retention suture placed in the anterior tongue is helpful in establishing and maintaining optimum tongue position.
5. If the cancer is centrally located, this anterior incision is carried across the entire base of the tongue; for more laterally located cancers the incision is terminated at the midline and extends posteriorly. Frozen sections are obtained as the margins are established.
6. Deep resection margins are established by changing the trajectory of the laser into the base of the tongue. The surgeon must reposition or continually adjust *both* the microscope and the retractor system to maintain appropriate visualization and control depth of dissection.
7. Insulated grasping forceps are used to manipulate the surgical specimen as it is developed, to maintain tension between the specimen and the residual tissue to allow for the most efficient cutting of the laser and to cauterize bleeding within the tongue base.
8. Segmental tumor resection may be necessary—that is, larger cancers are can split into several segments with perpendicular laser cuts to facilitate resection.
9. Control posterior margins in the vallecula with the epiglottis retracted inferiorly. Frozen sections of the base of the laryngeal surface of the epiglottis can be obtained at this point.
10. Multiple frozen sections are required during TLM tongue base resection; therefore close cooperation with the frozen section surgical pathologist is necessary. In our own experience an average of 6 to 7 frozen sections are required for the typical resection of the base of the tongue.
11. Definitive hemostasis. Suction cautery, defocused laser. Clip any pulsatile branches of lingual artery; use thrombin-gelfoam hemostatic material or topical fibrin-based spray. Angled rigid Hopkins telescopes can be placed into the mouth both during and at the conclusion of the procedure to inspect the defect for bleeding and sites of residual cancer
12. Neck dissection as indicated:
    a. Opportunity to convert to open procedure (lateral or transhyoid pharyngotomy) to complete cancer resection if necessary
    b. Ligation of the at-risk branches of the lingual artery
    c. Bilateral neck dissections are performed for centrally located or any T3
    d. Pharyngeal perforations or intention pharyngotomy is closed and oversewn and bolstered with local tissue such as the strap muscles or the platysma. Carefully placed suction drains are then used to facilitate coaptation of the neck flap to the neck wound.

COMMON ERRORS IN TECHNIQUE

1. Attempting to proceed with TLM without detailed preoperative anatomic assessment of the patient and review of imaging data
2. Using existing instrumentation possibly ill-suited for correct exposure
3. Assuming cancer of the tongue base can be excised without repositioning microscope or changing retractors
4. Inadequate frozen sections to control margins
5. Failure to realize that TLM of the base of the tongue is technically very challenging and requires an extreme amount of patience

POSTOPERATIVE PERIOD

Postoperative Management

1. Observed overnight in the surgical intensive care unit to monitor airway
2. Monitor for postoperative hemorrhage.

3. Continue IV antibiotics for 24 hours if there was no pharyngotomy.
4. Continue antibiotics for 3 days if pharyngotomy was closed primarily or with local flap and 5 days if reconstruction was more extensive (pedicle flap or microvascular free tissue transfer).
5. Begin enteral feeding via NG tube or gastrostomy as soon as possible.
6. If resection was extensive, speech and swallowing evaluation may be needed prior to resuming oral alimentation.
7. Topical cyclohhexidine gluconate 0.12% mouth rinses are begun as soon as possible.
8. Wound and suction drain care are used for patients undergoing neck dissection.
9. Patients requiring a tracheostomy can usually be decannulated prior to discharge.

Complications

1. Retractor related due to excessive extension of retractor blades and prolonged pressure on the tongue
   a. Edema and hematoma of the tongue, laceration of the dorsum and lateral tongue, and delayed airway obstruction
   b. Compression of the lingual nerve between the retractor blade and the inferior border of the mandible, resulting in permanent or temporary disturbance of taste and anesthesia of the tongue
   c. Compression of the hypoglossal nerve between the retractor blade and the hyoid bone, resulting in paralysis of the tongue
   d. Other retractor-related complications include dental injury and lip lacerations.
2. Complications related to the resection include:
   a. Laser thermal injury
   b. Endotracheal tube fire and operative field fire
   c. Hemorrhage and aspiration of blood
   d. Airway obstruction
   e. Delayed recovery of speech and swallowing
   f. Life-threatening and potentially fatal hemorrhage following TLM is rare (<2%).
   g. Careful attention to hemostasis by judicious use of the suction cautery, transoral clip hemostasis of identified bleeding vessels, and elective transcervical ligation of at-risk branches of the lingual, facial, and ascending pharyngeal arteries have been advocated.
3. Infectious complications—Micro- or intentional pharyngotomy in the neck can result in salivary contamination of the neck with subsequent infection, abscess, or pharyngocutaneous fistula. Delaying neck dissection after transoral laser resection can avoid this complication (Fig. 34.2).

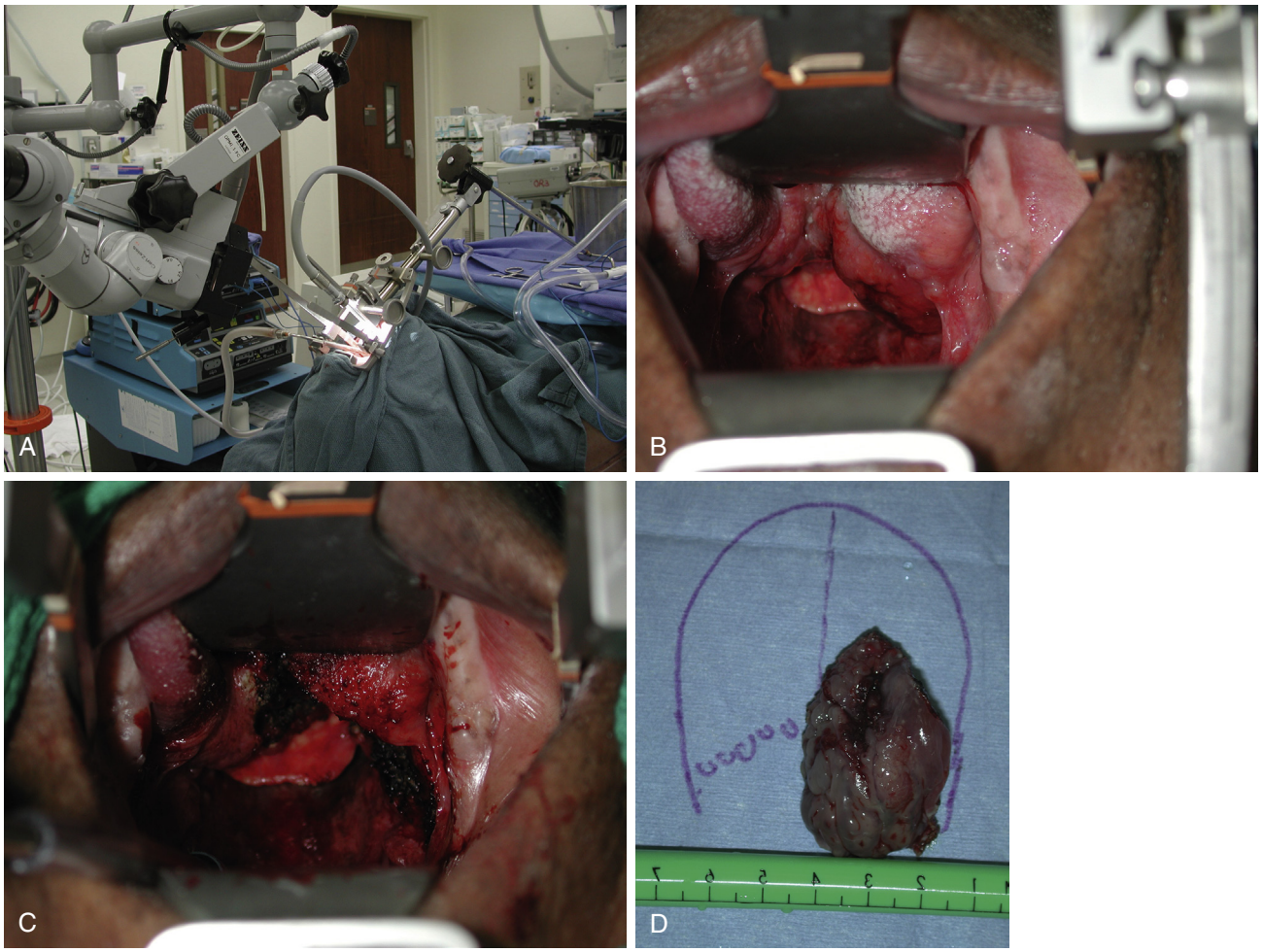

Fig. 34.2. Case example. **A,** Patient prepared for TLM of carcinoma of the base of the tongue. **B,** Patient in surgical position prior to TLM excision of squamous cell carcinoma of the left base of the tongue. **C,** Surgical defect in the same patient following TLM resection. **D,** Oriented surgical specimen.

Alternative Management Plans

1. Primary nonsurgical therapy with definitive concurrent chemoradiation protocols
2. Planned transhyoid or lateral pharyngotomy
3. Midline or parasymphyseal mandibulotomy

Evidence-Based Medicine Question

Which of the follow statements is *false*?

1. TLM resection of the tongue base increases identification of the primary site in patients with occult primary head and neck malignancies.
2. TLM is only suited for early-stage T1 or low-volume T2 tumors.
3. Following TLM resection of p16 positive tongue base tumors, dose reduction of external beam radiation therapy is possible without compromising oncologic outcomes.
4. In certain patients, staging panendoscopy may be necessary to ensure adequate exposure prior to TLM resection.
5. TLM resection of tongue base minor salivary gland tumors of the BOT is an oncologically sound approach.

Editorial Comment

As the section editor would like to comment on a few of the many important points and concepts presented in this chapter. One key issue in TLM or any other technique for transoral surgery of the base of the tongue is the risk of postoperative bleeding. The author notes the principal source of intraoperative bleeding in TLM of the tongue base to be the dorsal lingual branch of the lingual artery. While I fully agree with this comment across the collective spectrum of small to larger tongue base procedures, there are more components to the lingual artery that come into play with larger resections. For resection of cancer of the base of the tongue with endophytic cancer or those that have some endophytic component, it is not uncommon to encounter both the dorsal lingual branches as well as the actual main lingual artery trunk as it courses over the hyoid into the intrinsic tongue musculature. This is a much larger diameter artery with significant anterograde and retrograde blood flow. Ideally this vessel would be identified and dissected proximally and distally with clip ligature prior to inadvertent transection. In addition, there is a suprahyoid branch of the lingual artery that can also course through the vallecula as it supplies to suprahyoid musculature. This vessel has anastomoses with the contralateral suprahyoid artery and can prove to be a significant source of postoperative bleed if it was not adequately controlled during the resection of the base of the tongue.

It is also important to emphasize the risk of traction or compression injury to either or both the hypoglossal and lingual nerves from using the various options of transoral retractors for base of tongue resections, regardless of the technique. Release of the retractor for short periods of time may be considered as an option to reduce this risk during prolonged base of tongue resections.

Ryan Soose

Access the review questions and additional sources list online at http://www.expertconsult.com

REFERENCES

1. Camp AA, Fundakowski C, Petruzzelli GJ, et al. Functional and oncologic results following transoral laser microsurgical excision of base of tongue carcinoma. Otolaryngol Head Neck Surg 2009;141:66–69.
2. Chin RI, Spencer CR, DeWees T, et al. Re-evaluation of postoperative radiation dose in the management of human papillomavirus-positive oropharyngeal cancer. Head Neck 2016;38:1643–1649.
3. Dullan I, Seccia V, Faggioni L, et al. Anatomical landmarks for transoral robotic tongue base surgery: comparison between endoscopic, external, and radiologic perspective. Surg Radiol Anat 2013;35:3–10.
4. Grant DG, Salassa JR, Hinni ML, et al. Carcinoma of the tongue base treated by transoral laser microsurgery, part one: untreated tumors, a prospective analysis of oncologic and functional outcomes. Laryngoscope 2006;116:2150–2155.
5. Grant DG, Hinni ML, Salassa JR, et al. Oropharyngeal cancer. A case for single modality treatment with transoral laser microsurgery. Arch Otolaryngol Head Neck Surg 2009;135:1225–1230.
6. Gun R, Durmus K, Kucur C, et al. Transoral surgical anatomy and clinical considerations of lateral oropharyngeal wall, parapharyngeal space, and tongue base. Otolaryngol Head Neck Surg 2016;154:480–485.
7. Haughey BH, Hinni ML, Salassa JR, et al. Transoral laser microsurgery as primary treatment for advanced-stage oropharyngeal cancer: a United States multicenter study. Head Neck 2011;33:1683–1694.
8. Prader O, Christiansen H, Schmidberger H, et al. Adjuvant radiotherapy after transoral laser microsurgery for advanced squamous carcinoma of the head and neck. Int J Radiat Oncol Biol Phys 2005;63:1368–1377.
9. Rich JT, Milov S, Lewis JS, et al. Transoral laser microsurgery ± adjuvant therapy for advanced stage oropharyngeal cancer: outcomes and prognostic factors. Laryngoscope 2009;119:1709–1719.
10. Salassa JR, Hinni ML, Grant DG, et al. Postoperative bleeding in transoral laser microsurgery for upper aerodigestive tract tumors. Otolaryngol Head Neck Surg 2008;139:453–459.
11. Steiner W, Fierek O, Ambrosch P, et al. Transoral laser microsurgery for squamous cell carcinoma of the base of the tongue. Arch Otolaryngol Head Neck Surg 2003;129:36–43.
12. Wilke MD, Upile NS, Lau AS, et al. Transoral laser microsurgery for oropharyngeal squamous cell carcinoma: a paradigm shift in therapeutic approach. Head Neck 2016;38:1263–1270.

REVIEW QUESTIONS

1. What is the principal source of intraoperative arterial bleeding in TLM of the tongue base?
   Dorsal lingual branch of the lingual artery

2. What are the complications associated with prolonged retractor time and excess pressure?
   Lingual and hypoglossal nerve paresis or paralysis

3. What are the three most important technical factors associated with successful visualization during TLM surgery?
   Meticulous hemostasis, retractor and microscope repositioning, patience

4. What are the three important benefits of TLM resection?
   Reduced rate of infection due to reduced need for pharyngotomy
   Superior functional results due to mucosal re-epithelization, maintained sensory and motor function, and reduced need for flap reconstruction

5. What is the principal oncologic benefit of the TLM approach?
   Earlier initiation of adjuvant treatment because of more rapid recovery

ADDITIONAL SOURCES

Hinni ML, Lott DG, Moore EJ. Transoral endoscopic anatomy (inside-out) anatomy. In: Hinni ML, Lott DG, editors. Contemporary Transoral Surgery for Primary Head and Neck Cancer. San Diego, CA: Plural Publishing, Inc; 2015. p. 11–23. Copyright Mayo Clinic Foundation.

Steiner W, Ambrosch P, Ulrich B, et al. Endoscopic Laser Surgery of the Upper Aerodigestive Tract: With Special Emphasis on Cancer Surgery. Stuttgart: Thieme; 2000.

Note: This surgical atlas is required for anyone seriously considering incorporating transoral laser microsurgery into his or her head and neck practice. It is clearly written, well-illustrated, and reflects the wealth of experience gained by the true pioneers in the fields of transoral laser surgery for benign and malignant disease.

35 Transoral and Robotic Tonsil Surgery for Cancers of the Base of the Tongue and Pharynx

Alexandra Kejner, Jason G. Newman

INTRODUCTION

Almost 50,000 people develop oral and oropharyngeal cancers each year with almost 9000 deaths annually. When diagnosed and treated in its early stages, 5-year survival rates can exceed 83%.[1]

Oropharyngeal cancer is on the rise, and in particular, human papilloma virus (HPV)–related cancers have increased in the United States by 225% since 1998.[2] Historically, open surgery of the oropharynx was fairly morbid and invasive and was noted to have comparable outcomes to primary chemoradiotherapy.[1] In the mid 2000s, with the advent of the surgical robot and its use by Drs. Weinstein and O'Malley, oropharyngeal surgery was revolutionized, making it less morbid and allowing for the potential of de-escalation therapy.[3,4]

Having a standardized set of techniques (similar to laryngectomy) allows for consistent margin control in a safe and effective manner and follows Halstedian principles of en bloc resection.

Patient selection is of the utmost importance because margin-negative resection is highly predictive of overall survival in head and neck cancers.[5-7]

KEY OPERATIVE LEARNING POINTS

1. Knowledge of inside-out anatomy is key to a safe and effective operation, particularly when approaching the oropharynx transorally.
2. Halstedian principles of oncologic surgery must be maintained when removing tumors, allowing for adequate margins and decreased tumor spillage.
3. Ligating feeding vessels to the oropharynx during the neck dissection can aid in prevention of postoperative hemorrhage.
4. In cases of the unknown primary with HPV+ squamous cell carcinoma, the most commonly affected site is the oropharynx and can be easily sampled en bloc for pathologic analysis.
5. Reconstruction is important when addressing this area because it is vital in the functions of speech, breathing, and deglutition.

PREOPERATIVE PERIOD

History

1. History of present illness
   a. Many patients will present initially with a mass in the neck; in these cases, questions regarding onset, location, duration, exacerbation, and any treatments may give insight into the underlying etiology of the mass (vascular, infectious, autoimmune, neoplastic).
   b. The patient should be questioned regarding dysphagia, odynophagia, otalgia, weight loss, hemoptysis, hoarseness, dysgeusia, and dyspnea, because these are most likely to be seen in patients with underlying malignancy.
   c. Current treatment with antibiotics or other medications.
2. Past medical history
   a. Prior treatment: Any antibiotics or recent viral illnesses
   b. Medical illness: History of other head and neck cancers (which can be seen in more than 36% of patients who smoke),[8,9] history of lung cancer, history of cervical cancer,[10] previous surgery in the oropharynx
      1) Any illnesses that would be contraindications for surgical intervention including significant cardiovascular, pulmonary, or other end-stage cancers
      2) Hypercoagulable disorders requiring chronic anticoagulation
      3) Coagulopathy including von Willebrand disease or other
      4) Stents requiring antiplatelet therapy
      5) Significant sleep apnea (to understand postoperative risk of flash pulmonary edema and/or need for tracheostomy)
      6) History of aspiration events
      7) History of autoimmune disorders or transplantation requiring long-term antirejection therapy
   c. History of radiation to the head or neck area (including for Hodgkin, treatment of acne)
   d. Surgery
      1) Previous tonsillectomy or sleep apnea surgery
      2) Any neck surgery
      3) Arm and leg surgery (in case the patient may require free flap reconstruction)
   e. Family history
      1) History of head and neck cancers
      2) Autoimmune disorders
      3) Cervical cancer in significant other (Data from the Swedish Cancer Registry (1958–1996) showed that spouses of patients with cervical cancer had a significantly elevated risk of development of tongue or tonsil cancer.)[10]
   f. Medications
      1) Antiplatelet drugs or anticoagulant medications
      2) Immunosuppressive medications
      3) Herbal products (fish oil, valerian root)
   g. Social History
      1) Alcohol
      2) Smoking tobacco
      3) Illicit or recreational drugs
      4) Support system at home
      5) Current occupation

Physical Examination

1. Overall appearance and breathing
   a. Note quality of breathing—mouth breathing or stridor; signs of obstruction, drooling or dry mouth
   b. Examine for cachexia, temporal wasting
   c. Some patients will have a characteristic foul odor of the breath, particularly those with larger cancers.
2. Examination of the cranial nerves
   a. In particular, lower cranial nerves (IX, X, XI, XII), because involvement indicates a significant disease process

3. Oral cavity/oropharynx
   a. Examine lips, gums, teeth, floor of mouth, tongue, and visible oropharynx with two tongue blades.
   b. Bimanual palpation of lips, floor of mouth, tongue, base of the tongue, cheeks, and hard palate
   c. Mirror examination if patient tolerates; flexible endoscopy if not
4. Nasal cavity
   a. Anterior rhinoscopy can be performed to evaluate for intranasal growths. Topical anesthetic and decongestant can also be applied at this time in preparation for nasal endoscopy.
5. Neck
   a. Palpation of the lymph node basins of the neck from level Ia to level V
      1) Any lymph nodes need to be assessed for fixation, mobility in certain directions
   b. Palpation of the thyroid gland

Imaging

Computed tomography (CT): CT with contrast should be done to better characterize the remaining neck for occult disease that is not felt on physical examination. It can also provide information regarding involvement of vessels or local structures. Special attention should be paid to the location of the carotid artery to ensure that it does not have a retropharyngeal course **as this is a contraindication for radical tonsillectomy.**

Magnetic resonance imaging (MRI): MRI is particularly useful for lesions of the base of the tongue or unknown primaries, because it can detect subtle changes in soft tissue.

Staging scans: Positron emission tomography (PET) CT can evaluate from the brain to the upper thighs for metastatic cancer. At the least, a chest CT should be performed to evaluate for metastatic cancer to the lungs.

Indications

1. Patients with primary T1, T2, T3, and select T4 lesions of the oropharynx with possible reconstruction
2. Patients with recurrent cancer of the oropharynx; to be performed in conjunction with a reconstructive surgeon
3. Metastatic cancer to the neck from an unknown primary as a part of the evaluation and treatment

Contraindications

1. Medical comorbidities with increased risk for general anesthesia: End-stage cardiac disease (Preoperative risk assessment by a cardiologist is necessary.)
2. End-stage cancer
3. Involvement of the carotid artery
4. Retropharyngeal carotid
5. Relative contraindication: Prevertebral fascia involvement
6. Relative contraindication: Pterygoid involvement (will require extensive reconstruction as part of planning)

Preoperative Preparation

Procedures

1. Nasopharyngolaryngoscopy
   a. Allows examination of the mucosa from the nasal cavity to the larynx
      1) This is often helpful for assessing the extent of palate involvement and the status of the airway in anticipation of a visit to the operating room (OR).
      2) Predicting possibly problematic airways is very important. Often, pictures or video can be shared with the anesthesia team.
2. Fine-needle aspiration (FNA) biopsy
   a. FNA can be performed on easily palpated cervical lymph nodes with or without ultrasound guidance as long as there is no evidence of involvement of the carotid artery.
   b. Some patients will tolerate biopsy of the oropharynx in the office.
   c. HPV typing should be done on the specimens.
   d. In patients for whom transoral robotic surgery (TORS) is to be considered, staging endoscopy is often necessary to determine the resectability of the tumor. Mobility of the tumor, involvement of adjacent structures, and exposure are all evaluated at the time of this endoscopy. If the tumor cannot be reached in the office setting, pan endoscopy with biopsy should be performed in the OR. This also gives the surgeon an idea of how well the cancer can be exposed, particularly if transoral resection is being planned or if the patient will require extensive reconstruction (in which case, a mandible split or a robotic approach may be necessary).
3. Preoperative imaging
4. Preoperative clearance
5. Panendoscopy results with HPV testing
6. Airway assessment
7. Staged or concomitant neck dissection with ligation of vessels

OPERATIVE PERIOD

Anesthesia

General anesthesia with full paralysis. Relaxation is of the utmost performance during transoral surgery because this aids in visualization, dissection, and in reducing the risk of the patient moving during surgery.

Positioning

Supine: The patient is positioned supine, without a shoulder bump. The eyes and teeth are protected. This allows for full range of motion by the surgeon. Additionally, if the surgical robot will be used, this allows maximization of the robotic camera and instrument mobility.

Perioperative Antibiotic Prophylaxis

First-generation cephalosporin and metronidazole: Due to the typical flora of the oral cavity, dual coverage with a cephalosporin and metronidazole are warranted.

Clindamycin: Can be used as an alternative in patients with penicillin allergy because it covers the majority of oral flora. The caveat with this medication is its association with *Clostridium difficile* as a complication.

Monitoring

Monitoring for continued neuromuscular paralysis

Instruments and Equipment to Have Available

For a nonrobotic procedure:

1. Loupe magnification and surgical headlight
2. Cautery unit (set at 15 to 20 W for COAG) with Bovie pedal and bipolar pedal—one pedal next to the assistant for suction cautery

3. Two Bovie pads (one for standard monopolar cautery and one for suction cautery)
4. Reusable bipolar cord
5. Crowe-Davis mouth gag
6. Extended tip Bovie
7. Extra-long DeBakey or Blue Burner forceps
8. Weder retractor or Minnesota retractor
9. Pediatric Yankauer suction
10. Tonsil sponges soaked with Afrin
11. Herd retractor
12. Fine dissector (Krile, Schnidt)
13. Surgical clip applier
14. Medications/pharmacologicals:
    a. Methylene blue for marking margins on specimen
    b. Topical phenylephrine for topical application transorally
    c. Topical hemostatic agent
15. Optional: Can use a 30-degree endoscope to evaluate the base of the tongue if not well visualized transorally. Alternatively, this area may be visualized with a laryngeal mirror.

If using the surgical robot:

16. Intuitive Surgical high-magnification camera head (45-degree field of view [FOV])
17. Intuitive Surgical wide-angle camera head (60-degree FOV)
18. Ikegami high-definition 3D imaging system (da Vinci S only)
19. 30-degree Intuitive Surgical endoscope
20. 0-degree Intuitive Surgical endoscope
21. Three chairs that have a foot pedal for adjusting up and down, two at the bedside (for the nurse and the bedside surgical assistant) and one at the surgeon console
22. Three rectangular OR instrument carts and one small square OR instrument cart
    a. Recommended 5-mm EndoWrist Instrumentation:
       1) Monopolar cautery
       2) Maryland forceps

Key Anatomic Landmarks

1. Laterally: Carotid artery, glossotonsillar sulcus
2. Posteriorly: Prevertebral fascia
3. Anteriorly: Base of the tongue
4. Medially: Uvula

Prerequisite Skills

1. Knowledge of inside-out anatomy
2. **If using robot:** Transoral robotic training

Operative Risks

1. Intraoperative hemorrhage from lingual artery, branches of facial artery, veins. Best prevented by preoperative or intraoperative transneck ligation of branches of the external carotid system, including superior laryngeal, facial, and lingual
   a. The blood supply to the tonsil is the dorsal lingual branch (of the lingual artery), ascending palatine artery (of the facial artery), tonsillar branch (of the facial artery), ascending pharyngeal artery (of the external carotid artery), and the lesser palatine artery (of the descending palatine artery).
2. Fistula: Communication between the oropharynx and the neck. This can be prevented by leaving the submandibular gland intact, resecting only a portion of it, and/or rotating an anterior digastric flap to bolster this area. Staging surgery to allow for the region to granulate may also reduce this risk.
3. Injury to the carotid artery: Rare but possible if the surgeon dissects too far laterally. If the adipose tissue surrounding the carotid is not involved, this can be safely retracted laterally after identifying the pterygoids.

Surgical Technique: [include narrated videos online]



General anesthesia with paralysis is necessary when approaching from a transoral technique. This allows for maximal mouth opening and minimizes muscular contraction when using monopolar cautery. After induction, the patient is intubated orally with a reinforced tube, which is sutured into position in the nasolabial fold. The eyes are protected using a plastic shield or thick towels. The bed should be lowered completely and the patient should not be placed on a shoulder roll. Preoperative steroids are given for a total of three doses.

TRANSORAL TECHNIQUE

Pearl

A key point to understand prior to beginning surgery is that the overall oncologic goal of radical tonsillectomy is to complete an en bloc resection approach to ensure widely negative margins (as is feasible based on the anatomy, i.e., base of the tongue, soft palate, medial and lateral mucosal margins) and to minimize positive or close margins at the level of the constrictor muscles.

- A mattress suture is placed through the tongue using a silk suture. This is used to displace the tongue anteriorly.
- The Crowe-Davis retractor is placed using the appropriately sized tongue blade and opened as wide as is feasible for the patient.
- The Crowe-Davis retractor is placed so that 1 cm of the base of the tongue can be resected en bloc to minimize the likelihood of a close margin at the inferior aspect of the tonsil. All of this area is exposed at one time to decrease the need for replacing the mouth gag.
- The Crowe-Davis retractor can then be further stabilized using a Mayo stand or using a Storz scope-holder stabilizing arm.
- The endotracheal tube is positioned laterally and sutured between the oral tongue and the retromolar trigone (Fig. 35.1).
- This positions the tube out of the operative field and reduces the need for the assistant to reposition the tube throughout the case.

If using the robot: The robot is brought into position with the camera positioned directly in the mouth between two arms at 30-degree angles to the tumor. The spatula tip Bovie cautery is positioned ipsilateral to the tumor. The assistant, using two pediatric Yankauer suctions, retracts the cheek laterally and suctions smoke and blood. The assistant is extremely important during this case, not only for suctioning blood, smoke, and mucus but also for retraction to accomplish a four-handed surgical technique. The assistant is also charged with applying surgical clips as directed by the console surgeon.

- The assistant surgeon retracts the ipsilateral cheek laterally.
- The surgeon, using the extended tip **(or in the case of the robot, the spatula tip)** monopolar cautery, designs an index incision of the palate in the shape of a question mark (Fig. 35.2): superiorly at the level of the soft palate, laterally at the mucosa overlying the pterygomandibular raphe and extending inferiorly to the tongue base.

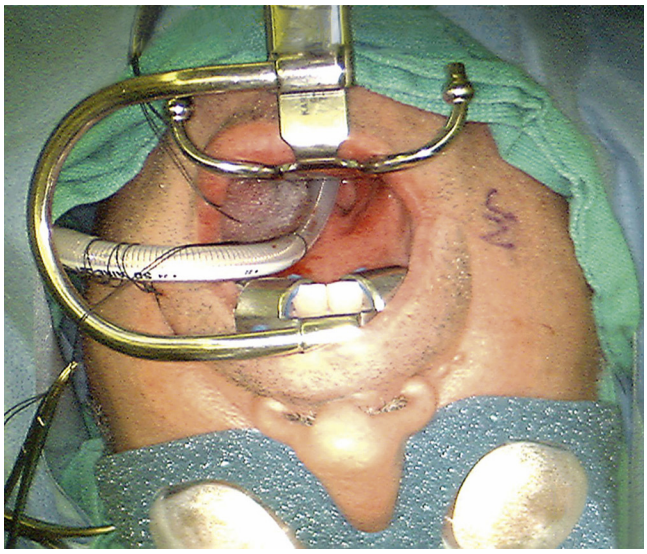

Fig. 35.1. Exposure is achieved using a Crowe-Davis mouth gag. Note that the tube is secured with silk suture to the melolabial crease and the tube is lateralized with a suture through the tongue to the retromolar trigone on the side contralateral to the tumor. This positions the tube out of the operative field and reduces the need for the assistant to reposition the tube throughout the case.

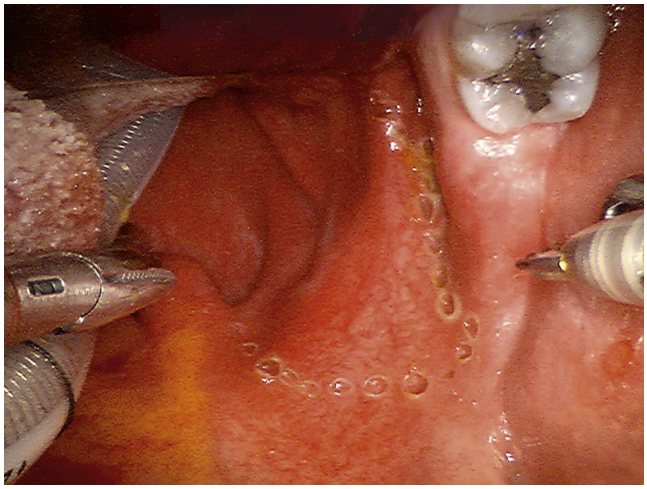

Fig. 35.2. The surgeon, using the extended tip (**or in the case of the robot, the spatula tip**) monopolar cautery, designs an index incision of the palate in the shape of a question mark: superiorly at the level of the soft palate, laterally at the mucosa overlying the pterygomandibular raphe, and extending inferiorly to the tongue base.

- The incision is deepened to the level of the medial pterygoid muscle, which can be identified as a white band (Fig. 35.3).
- A dissector or a DeBakey, **(or in the case of the robot),** the Maryland forcep attachment, is then used as a hook retractor to hold the mucosal edge medially while the spatula tip Bovie is used as a dissector to push the lateral pharyngeal adipose tissue pad laterally and away from the constrictors.

Establishing the correct plane is vital because the carotid artery is just lateral to this adipose tissue pad and dissecting too laterally can cause bleeding or stroke.

- An index incision is made medially to ensure that excessive posterior pharyngeal mucosa is not removed and to define the medial-most aspect of the resection (Fig. 35.4).

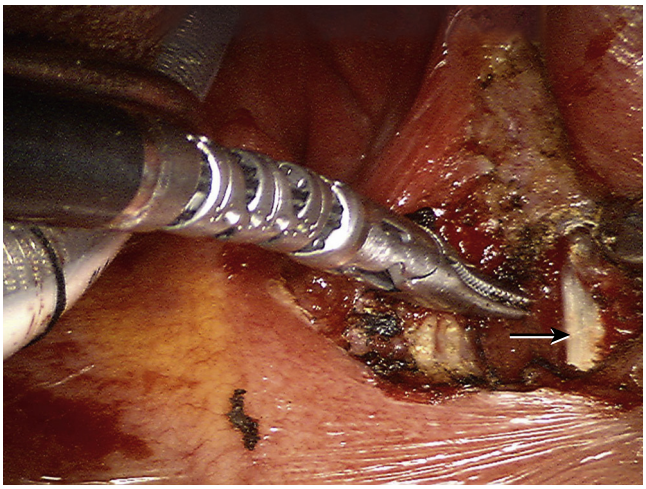

Fig. 35.3. The incision is deepened to the level of the medial pterygoid muscle, which can be identified as a white band *(black arrow)*.

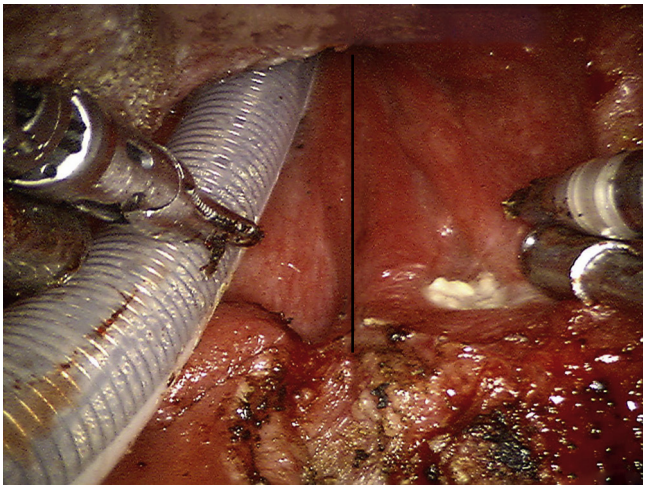

Fig. 35.4. An index incision is made medially *(solid black line)* to ensure that excessive posterior pharyngeal mucosa is not removed and to define the medial-most aspect of the resection.

- Once the incision is deepened to the level of the constrictor muscles, it is continued inferiorly toward the base of the tongue.
- The superior soft palate margin is outlined and joined to the previous incision at the level of the pterygoids (Fig. 35.5).
- The styloglossus and stylopharyngeus muscles are identified and the inferior dissection is temporarily halted (Fig. 35.6).
- "Connect the dots" between the medial mucosal incision and the lateral pterygomandibular raphe incision. This is extended posteriorly to the level of the shiny, avascular plane of the prevertebral fascia overlying the longus coli muscle (Fig. 35.7).
- The specimen is elevated and then blunt dissection sweeps the specimen anteriorly, sweeping the medial constrictors off of the prevertebral fascia.
- The constrictors can then be grasped with the Maryland (in the case of the robot) or with a Schnidt in a plane parallel to the spine. The constrictors are divided along the edge of the instrument, taking care to avoid clamping perpendicularly or too far laterally because this can cause inadvertent injury to the internal carotid artery.

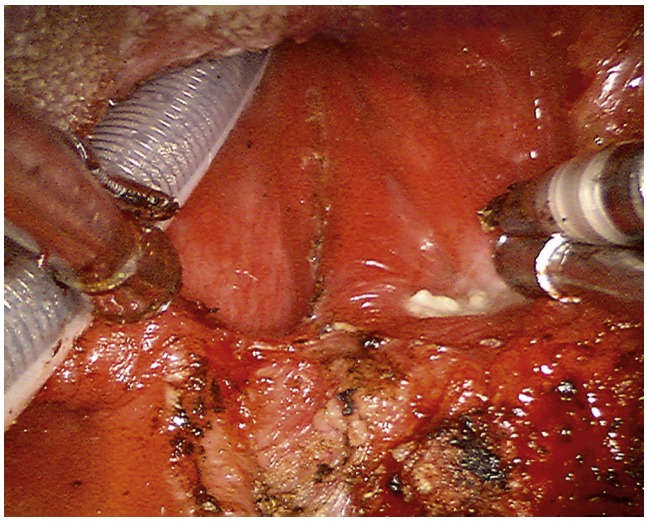

Fig. 35.5. The superior soft palate margin is outlined and joined to the previous incision at the level of the pterygoids.

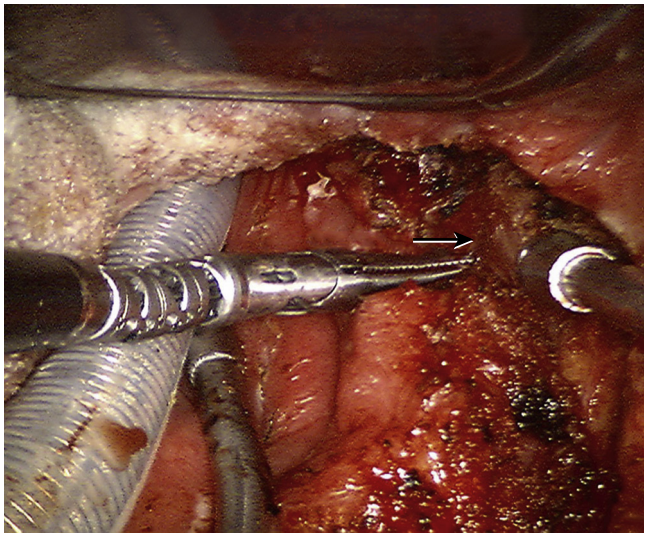

Fig. 35.6. The styloglossus and stylopharyngeus muscles are identified and the inferior dissection is temporarily halted *(black arrow)*.

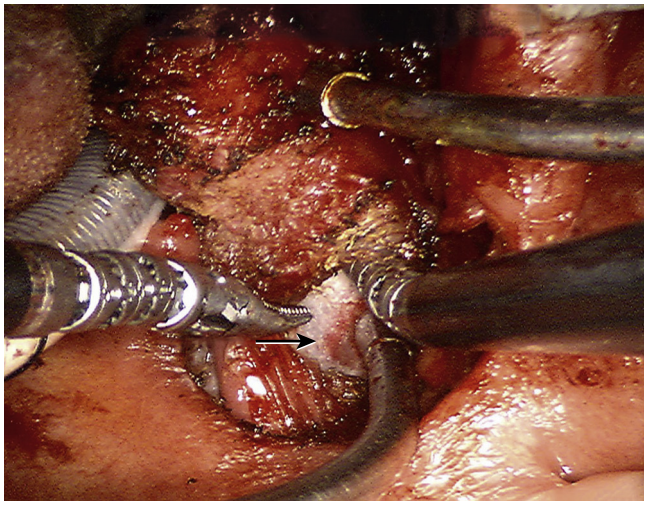

Fig. 35.7. Demonstration of the prevertebral fascia, a relatively avascular plane under which the robotic surgeon places the spatula tip Bovie to bluntly dissect it off *(black arrow)*.

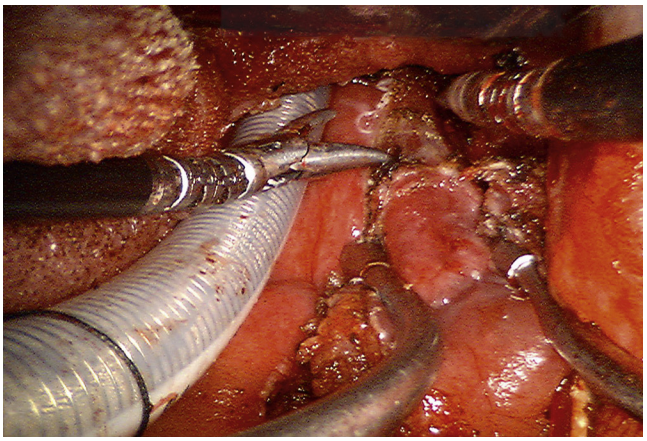

Fig. 35.8. Final posterior pharyngeal and tongue base incisions.

TONGUE BASE INCISIONS

- Outline the tongue base incision to the area of the glossotonsillar sulcus as well as a small portion of the mucosa of the floor of mouth.
- Blunt dissection can be undertaken in this area to isolate and control smaller contributory arteries and veins in this area (this may be assisted by the assistant holding an endoscope or laryngeal mirror to better visualize this area) (Fig. 35.8).
  - Alternatively, the surgeon may switch to a Lindholm laryngoscope to visualize this area and complete the incisions in the tongue base this way. Small vessels can be controlled with surgical clips or laparoscopic coagulation instruments (Dolphin).
  - A 1-cm margin is advised for cancers with no obvious invasion of the base of the tongue.
  - If there is invasion of the base of the tongue, more base of the tongue should be resected to ensure widely negative margins. This can include one-half of the base of the tongue if necessary. This has not been shown to have significant adverse effects on swallowing.
- Identify and clip the proximal and distal aspects of the artery when in close proximity to it, to achieve wide surgical margins.
- After completing the incisions into the base of the tongue and main dissection, attention returns to the styloglossus and stylopharyngeus muscles, which are dissected and Bovie transected leaving a margin of muscle around the junction of the tongue and constrictors.
  - In this region, there are multiple veins and arteries that are encountered and can be controlled using bipolar cautery or clipped.
  - In addition, the glossopharyngeal nerve may be encountered deep to the styloglossus. It may be necessary to resect this nerve if significant dissection and exposure are required to achieve wide margins around the cancer.
- The parapharyngeal adipose tissue plane is preserved to protect the great vessels.
  - If frozen section analysis identifies penetration of the cancer through the constrictor muscle, these planes may be further resected to achieve clear surgical margins.
- The resection is then completed by bringing the base of the tongue incisions and dissection to the lateral oropharyngeal wall just inferior to the stylopharyngeus muscle.
- The specimen can be removed en bloc upon the final through-and-through incisions into the constrictor muscle along the remaining course of the medial pharyngeal index incision.

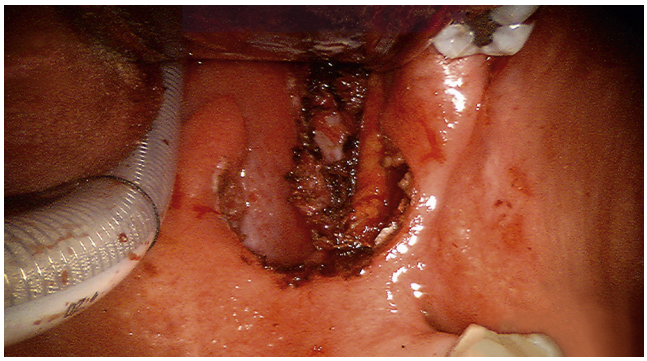

Fig. 35.9. The wound is inspected to assess the extent of soft palate resection and the risk of nasopharyngeal regurgitation and incompetence postoperatively.

- The surgical specimen is then taken to the surgical pathology suite for inking and orientation is performed with both the surgeon and pathologist present.
- Frozen sections of mucosal or muscular margins are performed where the margins are deemed clinically close as determined by sectioning into the tumor and by palpation.
- The wound is inspected to assess the extent of soft palate resection and thus the risk of nasopharyngeal regurgitation and incompetence postoperatively (Fig. 35.9).
- In general, no or minimal reconstruction is needed if the lateral mucosa at the junction of the soft palate and the posterior pharyngeal wall remains intact.
- For buccal adipose pad reconstruction, the same exposure may be used without changing the retractor.
  - The pad is mobilized by dissecting superior and lateral to the medial pterygoid muscle into the buccal space.
  - The adipose tissue is then gently mobilized medially and sutured to both exposed musculomucosal surfaces of the pharynx and soft palate. If a neck dissection is planned, reinforcement from below may be created using the posterior belly of the digastric muscle or a sternocleidomastoid rotational flap.
  - The wound is inspected for bleeding and mild oozing can be controlled with bipolar cautery.
  - Have the anesthesiologist perform a Valsalva maneuver with the bag to confirm that there is no active bleeding.
  - Apply a thin layer of Tisseel Fibrin Sealant (Baxter Healthcare) or other hemostatic agent to the surgical site.
  - A nasogastric feeding tube should be inserted under direct visualization and secured with a nasal sill suture to optimize nutrition during postoperative healing.
  - The patient is extubated in the OR if the airway is considered safe.

Common Errors in Technique

1. Patient selection: At the time of panendoscopy, prior to definitive surgery, examination of the mobility of the tumor (especially with regard to the carotid artery) should be noted. Additionally, issues with mouth opening should be noted at this time because they may preclude the use of the mouth gag/visualization.
2. Poor exposure: Placing the mouth gag in the best configuration for exposure of the palate, the tonsil, and about 1 cm of the base of the tongue. This involves pulling the oral tongue toward the contralateral side and using a tongue blade long enough to expose the base of the tongue. Failure to do this can result in the need for repositioning midway through the case or increasing the risk of positive margins.
3. Excessive resection of the soft palate without reconstruction can result in nasopharyngeal insufficiency with nasal regurgitation and rhinolalia. This can be prevented by performing a local pharyngoplasty or buccal adipose tissue pad flap placement.
4. Resecting tissue to the level of the contralateral lingual artery or through the hyoid. This can lead to dysphagia postoperatively that can be persistent and can result in the need for a feeding tube.
5. Control of the lingual artery: To prevent postoperative bleeding, we advise clipping the lingual artery both where it comes over the hyoid bone and its distal extension. Clipping the lingual and facial branches of the external carotid artery during the neck dissection can also help to prevent postoperative hemorrhage.
6. Failure to resect the tumor en bloc: Data have shown that having to re-resect margins can lead to worse local control than if the margins are sampled from the specimen (i.e., sufficient tissue taken at the time of resection to allow for adequate margin sampling).

POSTOPERATIVE PERIOD

Postoperative Management

1. The patients should be monitored in a step-down unit with monitoring including pulse oximetry and readily available nursing in case of postoperative hemorrhage, which can lead to devastating airway complications if not addressed immediately.
2. Postoperatively, pain management is very important. We have used standard opioids, typically with a patient-controlled device as well as scheduled gabapentin and a short course of steroids (three doses are recommended).
3. Nasogastric feeds can be started on postoperative day 1. Oral feeding can be attempted on postoperative day 1 and can be advanced as tolerated. A speech-language pathology consultation may be necessary in certain situations.
4. Ambulation is encouraged to prevent pulmonary thromboembolism and pneumonia.
5. Incentive spirometry is an extremely important adjunct.
6. Patients can usually be discharged on postoperative day 3 or 4 on a soft diet.

Complications

1. Hemorrhage: The most common and typically the one complication that results in rehospitalizations and need for reoperation
2. Dehydration
3. Injury to the teeth
4. Injury to the lingual nerve
5. Injury to the hypoglossal nerve
6. Death

Alternative Management Plan

1. Chemoradiation
2. Open surgery

DISCUSSION

Evidence-Based Medicine Question

What is the role of TORS for HPV-related cancers?

For small tumors (T1 and T2) with resectable neck metastases, there is a functional benefit from a margin-negative resection that may not require radiation or a postoperative

dose alone. With the Eastern cooperative oncology group (ECOG) 3311 surgical trial, de-escalation may possibly become the standard of care.

Editorial Comment

It is important to pay attention to the position of the endotracheal tube while dissecting medially with the pharynx and the base of the tongue, so as to prevent the risk of contact and potential for an airway fire. We use a wire reinforced endotracheal tube for all of these procedures. The surgical assistant provides retraction of the endotracheal tube to the contralateral side as needed during the operation. The bedside assistant plays a key role in providing countertraction that will facilitate the safe and effective dissection and en bloc resection. For cancers that invade the base of the tongue, the lingual artery is typically encountered while performing resection of the lateral base of the tongue. It lies lateral to the intrinsic muscles of the tongue and medial to the hyoglossus muscle, coursing superior to the hyoid bone. Should the surgeon inadvertently enter the lingual artery, control is aided by suctioning from the bedside assistant as well as external pressure being applied to the neck by the assistant above the ipsilateral greater cornu of the hyoid. The artery can then be ligated from below during the neck dissection if planned. In cases where there is a soft tissue defect and gap, then a pharyngoplasty is performed by suturing the posterior lateral aspect of the soft palate mucosa to the side of the superior pharyngeal muscle and mucosal incision. It is important to include some palate and constrictor musculature in the horizontal mattress suturing or the mucosal approximation will likely tear and the lateral tissue gap may reopen. In cases where there remains a lateral tissue gap and communication with the nasopharynx after the pharyngoplasty, the recommendation is to use a pedicled pad of buccal adipose tissue for final closure.

Special thanks to Dr. Kyle Hatten, MD for compiling video footage.

Bert O'Malley, Jr.



Access the review questions and additional sources list online at http://www.expertconsult.com

REFERENCES

1. Ang KK, Harris J, Wheeler R, et al. Human papillomavirus and survival of patients with oropharyngeal cancer. N Engl J Med 2010;363:24–35.
2. Chaturvedi AK, Engels EA, Pfeiffer RM. Human papillomavirus and rising oropharyngeal cancer incidence in the United States. J Clin Oncol 2011;29:4294–4301.
3. Weinstein GS, O'Malley Jr BW, Magnuson JS, et al. Transoral robotic surgery: a multicenter study to assess feasibility, safety, and surgical margins. Laryngoscope 2012;122:1701–1707.
4. Weinstein GS, Quon H, O'Malley Jr BW, et al. Selective neck dissection and deintensified postoperative radiation and chemotherapy for oropharyngeal cancer: a subset analysis of the University of Pennsylvania transoral robotic surgery trial. Laryngoscope 2010;120:1749–1755.
5. McMahon J, O'Brien CJ, Pathak I, et al. Influence of condition of surgical margins on local recurrence and disease-specific survival in oral and oropharyngeal cancer. Br J Oral Maxillofac Surg 2003;41:224–231.
6. Wong LS, McMahon J, Devine J, et al. Influence of close resection margins on local recurrence and disease-specific survival in oral and oropharyngeal carcinoma. Br J Oral Maxillofac Surg 2012;50:102–108.
7. Jones AS, Bin Hanafi Z, Nadapalan V, et al. Do positive resection margins after ablative surgery for head and neck cancer adversely affect prognosis? A study of 352 patients with recurrent carcinoma following radiotherapy treated by salvage surgery. Br J Cancer 1996;74:128–132.
8. Schoenberg BS, Myers MH. Statistical methods for studying multiple primary malignant neoplasms. Cancer 1977;40(Suppl. 4):1892–1898.
9. Begg CB, Zhang ZF, Sun M. Methodology for evaluating the incidence of second primary cancers with application to smoking-related cancers from the Surveillance, Epidemiology, and End Results (SEER) program. Am J Epidemiol 142(6):653. [Oxford University Press. 09 Nov 2015.]
10. Andrews E, Shores C, Hayes DN, et al. Concurrent human papillomavirus-associated tonsillar carcinoma in 2 couples. J Infect Dis 2009;200(6):882–887.

REVIEW QUESTIONS

1. The boundaries of the standard radical tonsillectomy include all of the following except which option?
   a. The soft palate
   b. The prevertebral fascia
   c. The base of the tongue
   d. The digastric muscle

2. What is a definite contraindication to TORS radical tonsillectomy?
   a. Obese patient
   b. T2 tumors
   c. Retropharyngeal carotid
   d. Lateral location of the pterygoid tendon

3. What is the blood supply to the pharynx?
   a. Facial artery, lingual artery, ascending pharyngeal artery, maxillary artery
   b. Facial artery, lingual artery, ranine artery, palatine artery
   c. Lingual artery, hypoglossal artery, tonsil artery, palatal artery
   d. Meningeal artery, superficial temporal artery, lingual artery

ADDITIONAL SOURCES

Weinstein GS, O'Malley Jr BW, Snyder W, et al. Transoral robotic surgery: radical tonsillectomy. Arch Otolaryngol Head Neck Surg 2007;133(12):1220–1226.

Weinstein GS, Quon H, Newman HJ, et al. Transoral robotic surgery alone for oropharyngeal cancer: an analysis of local control. Arch Otolaryngol Head Neck Surg 2012;138:628–634.

Weinstein GS, Quon H, O'Malley Jr BW, et al. Selective neck dissection and deintensified postoperative radiation and chemotherapy for oropharyngeal cancer: a subset analysis of the University of Pennsylvania transoral robotic surgery trial. Laryngoscope 2010;120:1749–1755.

Wong LS, McMahon J, Devine J, et al. Influence of close resection margins on local recurrence and disease-specific survival in oral and oropharyngeal carcinoma. Br J Oral Maxillofac Surg 2012;50:102–108.

36 Transoral Robotic Surgery for Neoplasms of the Base of Tongue

Raymond Chai, Bert O'Malley, Jr., Jason G. Newman

INTRODUCTION

Carcinoma of the base of the tongue can be managed with either surgical or nonsurgical approaches. Historically, most surgical resections in this region have involved open approaches, such as suprahyoid pharyngotomy or lip-split mandibulotomy. Given the morbidity of these approaches, organ preservation protocols initially developed for cancer of the larynx were adapted to the oropharynx.[1] However, primary chemoradiation is not without serious toxicity. Long-term treatment-related sequelae from chemoradiation, particularly pertaining to swallowing dysfunction, have become increasingly recognized over time.[2] Transoral robotic surgery (TORS) was developed as a minimally invasive approach through a natural orifice to allow for precision oncologic resections while preserving function.[3–5]

A major advantage of a primary surgical approach to neoplasms of the base of the tongue is that it provides a pathologic specimen. Accurate staging and assessment of histologic risk factors can thus be definitively determined, rather than relying on imaging alone. With comprehensive pathologic staging, patients can then be risk stratified to receive appropriate adjuvant therapy, if indicated.

Two of the most challenging aspects of the procedure are appropriate patient selection and maximizing exposure during the resection.

KEY OPERATIVE LEARNING POINTS

1. Appropriate docking and setup of the surgical robot, along with proper selection and then positioning of the retractor, are the keys to optimizing exposure.
2. The dorsal lingual branch of the lingual artery is typically encountered in the lateral aspect of the resection and must be managed appropriately to prevent postoperative hemorrhage.
3. The bedside assistant plays a crucial role in the success of the procedure. Appropriate suctioning, traction, and countertraction greatly facilitate surgical access and visualization.

PREOPERATIVE PERIOD

History

1. History of present illness
   a. Age of the patient
   b. Elicitation of symptoms including dysphagia, otalgia, odynophagia, aspiration, weight loss, and dyspnea. Symptoms can help to guide whether or not a patient is a candidate for TORS.
      1) Pre-existing dysphagia and/or gross aspiration may indicate the need for prolonged enteral feeding. In addition, these symptoms may suggest deep submucosal infiltration of the cancer that may not be clinically apparent.
      2) Referred pain such as otalgia may suggest extensive perineural invasion or involvement of the epiglottis.
2. Past medical history
   a. History of prior radiation therapy. Although salvage TORS has been described in the literature, the normal interface between tissue and tumor is often obliterated in these patients and may preclude a minimally invasive resection. In addition, wound healing and vascularity are compromised, and these patients may take many months to heal by secondary intention.
   b. Cardiopulmonary fitness and bleeding disorders need to be assessed. Patients with severe cardiac or pulmonary disease may not be able to tolerate major surgery and postoperative rehabilitation. These patients may be better suited for primary chemoradiation. Likewise, patients with known hereditary coagulopathies are predisposed to postoperative bleeding. Given the open wound and healing by secondary intention inherent to TORS, these patients may not be appropriate surgical candidates.
3. Past surgical history
   a. Prior surgical intervention or biopsies for cancer
   b. Prior surgery on cervical spine or temporomandibular joint
4. Family history
   a. Bleeding disorders or adverse reaction to anesthesia
5. Social history
   a. Smoking and extensive use of alcohol
6. Medications
   a. Anticoagulants including Coumadin, Plavix, and aspirin should be discontinued preoperatively and ideally for at least 2 weeks after surgery. It should be recognized that the use of supplements such as Ginkgo biloba, fish oil, and vitamin E may pose an increased risk for postoperative bleeding.
   b. Long-term use of steroids may inhibit wound healing by secondary intention.

Physical Examination

1. Evaluation of the base of the tongue is performed by both direct examination and flexible laryngoscopy. The glossotonsillar sulcus, vallecula, and epiglottis are assessed for grossly visible cancer. Extension of the cancer to the midline is also assessed. Palpation, if tolerated, is critical to estimate depth of invasion into the tongue.
2. Palpation of the neck is performed. Care is taken to note the number of lymph node metastases and whether obvious contralateral metastasis is present. Lack of mobility of the lymph nodes may imply extracapsular extension.
3. Oral aperture along with mandibular dimensions and positioning, tongue size and shape, and dentition are evaluated to determine if sufficient transoral exposure is possible.

Imaging

1. Magnetic resonance imaging (MRI) or computed tomography (CT) is performed to evaluate lymph node status, presence or absence of gross extracapsular extension, and extent

of tumor invasion. Obvious involvement of deep parapharyngeal space structures, extrinsic tongue musculature, and the hyoid bone may preclude transoral resection. Sagittal sections are helpful in defining anterior extension of the cancer. From our evolving experience with imaging and TORS, it appears that MRI may be the best imaging study to provide more detail with respect to depth of invasion into both intrinsic and extrinsic tongue musculature.
2. Positron emission tomography–CT–computed tomography (PET-CT) is typically performed for initial staging and metastatic evaluation.

Indications

1. TORS can be performed for all tumors of the base of the tongue that are deemed resectable from a transoral approach. However, the ideal candidates are those who are anticipated from preoperative evaluation to be able to avoid either adjuvant chemotherapy or concurrent chemoradiation, as well as maintaining articulation and swallowing function.

Contraindications

1. Deep involvement of more than one-half of the base of the tongue. These patients are at risk for significant functional deficits after resection or risk of devascularizing the tongue from bilateral lingual artery sacrifice.
2. Invasion of the skull base, hyoid bone, great vessels, or mandible
3. Deep involvement of the extrinsic tongue musculature
4. Large cancers of the glossotonsillar sulcus that risk exposure of the carotid artery

Preoperative Preparation

1. If exposure or resectability is indeterminate, patients should be brought to the operating room for an initial staging direct laryngoscopy with examination under anesthesia. The FK-WO retractor can be used at this time to determine if adequate exposure can be obtained.
2. Neck dissection can be performed either concurrently or in a staged fashion. Our protocol is to perform a staged surgery with the neck dissections done before the TORS resection. The lingual artery, facial artery, and the superior laryngeal artery are ligated during the neck dissection as a prophylaxis against potential catastrophic postoperative hemorrhage. This staged neck dissection approach also minimizes edema of the tongue and airway and prevents potential pharyngocutaneous fistula if extensive resection of the glossotonsillar sulcus is anticipated.

OPERATIVE PERIOD

Anesthesia

1. Communication with the anesthesiologist needs to be thorough and may be aided by reviewing imaging or providing a video of preoperative fiberoptic laryngoscopy. Our preference is for transoral intubation with GlideScope assistance (Verathon, Bothell, WA) to maximize visualization of the airway. Awake fiberoptic intubation is occasionally necessary if there are concerns for a difficult airway. A wire-reinforced endotracheal tube is used to prevent kinking and allows for appropriate mobility of the tube with retraction. The endotracheal tube is then secured contralateral to the tumor side with a suture through the nasolabial fold.
2. Airway fire is a potentially life-threatening complication of oropharyngeal surgery. Fraction of inspired oxygen should be kept less than 30%, and an appropriate sized endotracheal tube must be placed to prevent leakage around the cuff.
3. All patients require full neuromuscular paralysis to facilitate placement of the retractor and allow for maximum exposure.
4. Protective goggles are placed over the patient's eyes to prevent injury.

Positioning

1. The operating table is rotated 180 degrees and lowered to the maximum extent to accommodate placement of the robotic arms. The patient is positioned so that the crown of the patient's head is at the very edge of the operating table.
2. The surgical robot (Intuitive Surgical da Vinci Si) is docked to the right and positioned at a 30-degree angle to the operating table, making sure that the robotic foot is touching the base of the table. The robot is positioned so that the pivot point of the camera arm is approximately at the level of the oral commissure.
3. Collisions are minimized if the instrument's arms are placed as high as possible. The pivot point of the central scope arm is rotated inwards and then lifted up to its maximum height. The scope is then lowered as far as it will go into the oral cavity. At this point, the scope arm is moved down until the camera touches the posterior pharyngeal wall. The scope is then adjusted upwards as needed for an optimum view. This ensures that the scope arm is positioned at a maximum height.
4. The instrument's arms are then positioned in a "V" configuration and lowered until the tip of the instrument cannula is approximately at the level of the frame of the retractor. The instruments are then advanced until they are in the field of view of the scope (Fig. 36.1).
5. A shoulder roll is not necessary for this procedure.

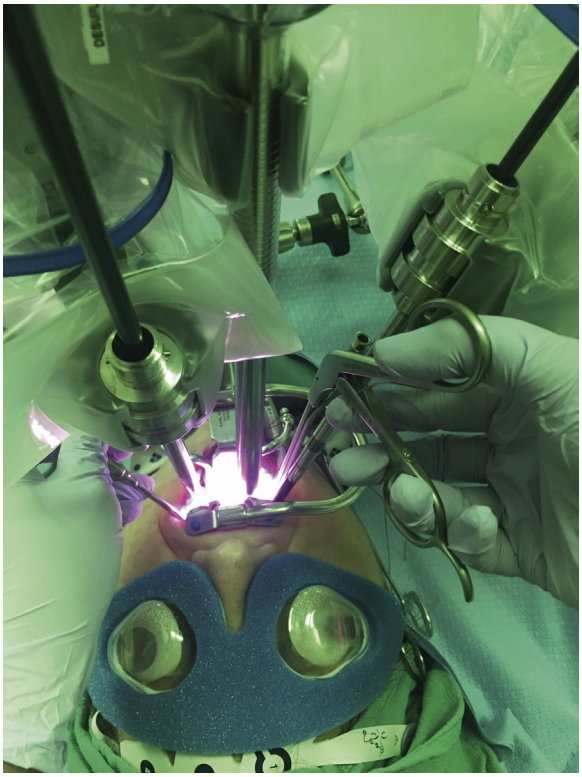

Fig. 36.1. FK-WO retractor with curved retractor blade.



Fig. 36.2. Proper orientation of robotic arms with usage of laryngeal clip applier.

Perioperative Antibiotic Prophylaxis

Our antibiotics of choice are intravenous cefazolin and metronidazole. Clindamycin is given to patients who are penicillin allergic. Antibiotics are typically given intravenously 1 hour before the incision.

Instruments and Equipment to Have Available

1. Feyh-Kastenbauer laryngopharyngoscope retractor (FK-WO) (Fig. 36.2)
2. Curved laryngeal clip appliers
3. Pediatric Yankauer suctions
4. Robotic 5-mm spatula electrocautery tip and robotic Maryland dissector
5. 0- and 30-degree 12-mm robotic endoscope. Although use of the 8.5-mm endoscope has been described, it is shorter than the 12-mm endoscope and will tend to collide with the other robotic arms outside the oral cavity.

Key Anatomic Landmarks

1. Glossotonsillar sulcus
2. Vallecula
3. Epiglottis
4. Hyoid bone
5. Dorsal lingual branch of the lingual artery
6. Lingual artery

Prerequisite Skills

1. Completion of a formal training program along with appropriate hospital credentialing and proctoring for robotic surgery is critical before performing TORS resection of the base of the tongue.

Operative Risks

1. Intraoperative hemorrhage, particularly from the lingual artery or its dorsal lingual branch
2. Close or positive margins on the resection specimen

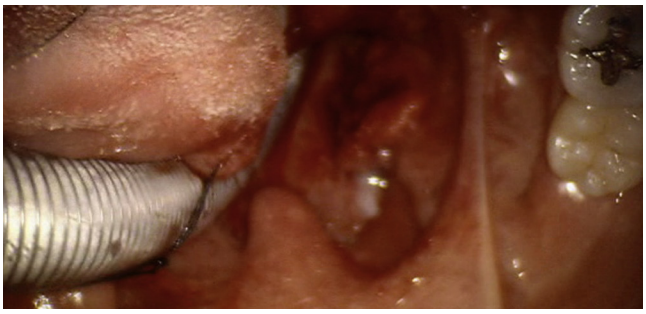

Fig. 36.3. Lateralization of the endotracheal tube after placement of the retraction suture.

3. Pharyngocutaneous fistula with concurrent neck dissection if extensive glossotonsillar resection is performed
4. Airway compromise due to edema of the tongue from prolonged retraction

Surgical Technique

A thorough examination under general anesthesia is performed, including digital palpation to confirm the location, size, and mobility of the tumor. For endophytic cancers, it can be helpful to paint the surface with methylene blue because these lesions may become obscured when retraction is applied.

The procedure is typically started with a 0-degree scope, with the 30-degree scope reserved if needed for visualization.

For this procedure, 5-mm instruments are optimal. The monopolar spatula cautery is placed ipsilateral to the tumor, and the Maryland dissector is initially positioned contralateral.

A suture is then placed in the midline of the tongue to allow for retraction. A tooth guard is used to protect the maxillary dentition. While maintaining gentle anterior traction on the tongue, the FK-WO retractor is placed. The lateral tongue is slid under the straight edge of the retractor blade, and the slotted edge is kept medial. The retractor is opened, and the cancer is exposed. A small cuff of normal tongue is maintained between the tip of the retractor blade and the tumor to provide room to obtain an adequate anterior margin of resection. The retractor is suspended with both chest support suspension and laterally with an endoscope holder.

The endotracheal tube is positioned contralateral to the tumor and is secured in place with a suture placed between the lateral tongue and the retromolar trigone (Fig. 36.3).

With the primary surgeon at the console, the assisting surgeon sits at the head of the bed using two baby Yankauer suctions to retract, suction smoke, and help to achieve hemostasis.

If there is no significant invasion of the cancer into the glossotonsillar sulcus, the initial incision is made in the tonsillar fossa and extended to the lateral aspect of the base of the tongue to incorporate mucosa for a lateral margin (Fig. 36.4). If cancer is present at the glossotonsillar sulcus, the constrictor muscles and the styloglossus should be resected with the specimen.

A horizontal anterior incision is then made immediately below the tip of the retractor to allow the cancer to fall posteriorly into the operative field. This initial incision is performed to a depth of approximately 1 cm (Fig. 36.5).

The instrument's arms are then switched, with the monopolar cautery now placed contralateral to the cancer. A midline vertical incision is then made from the medial aspect of the horizontal incision to the level of the vallecula to establish the depth of the resection (Fig. 36.6). To facilitate this, the bedside assistant must provide strong lateral and medial retraction with the Yankauer suctions in the depths of the incision as it is made. Typically, there is no significant bleeding encountered in this location. The epiglottis should now be completely in view.

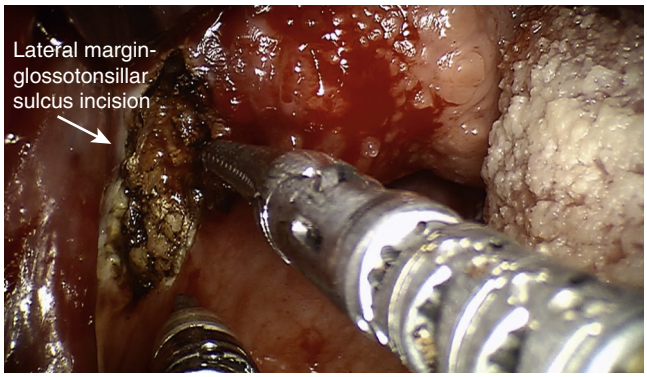

Fig. 36.4. Initial incision through the glossotonsillar sulcus to establish lateral margin.

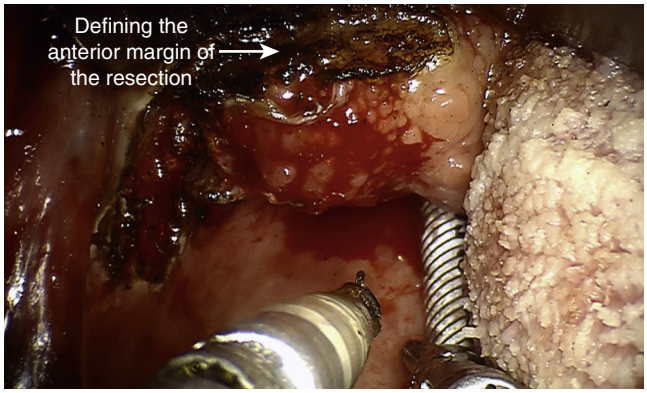

Fig. 36.5. Horizontal incision at the anterior margin to allow the tumor to drop into the operative field.

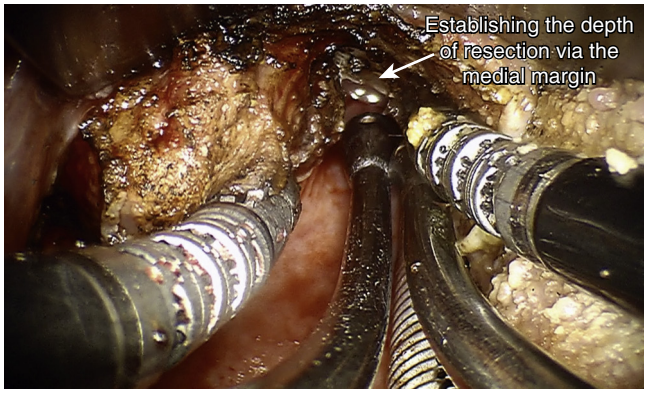

Fig. 36.6. Midline vertical incision to establish the depth of resection.

The resection is then performed from medial to lateral following the previously made horizontal incision. It is important to angle the instruments anteriorly in an imaginary line from the plane of the retractor blade to the hyoid because the tendency is to prematurely truncate the specimen here. Angling the vector of the resection appropriately facilitates a wide anterior margin of muscle.

At the lateral aspect of the base of the tongue, the lingual artery and its dorsal lingual branch will be encountered at a depth of approximately 1 to 2 cm. When the artery is encountered, it should be isolated, and a string of hemoclips are placed along the exposed portion of the vessel to prevent postoperative hemorrhage (Fig. 36.7). If significant bleeding is encountered here from an inadvertently transected artery, external neck pressure at the greater cornu of the hyoid applied by the bedside assistant can be helpful.

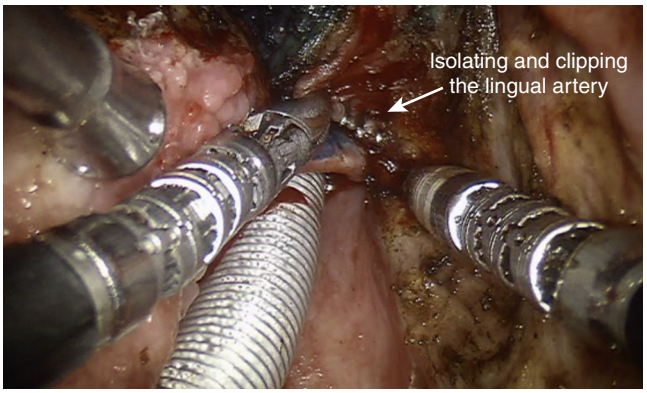

Fig. 36.7. Exposure and control of the lingual artery and its dorsal lingual branches.

The specimen is removed and brought to the pathology department for orientation and margin analysis. Equivocal margins are assessed with frozen sections. If the margins are deemed close or positive, methylene blue is used to ink the region of concern on the patient, and re-resection is performed.

Multiple Valsalva maneuvers are performed, and meticulous hemostasis is obtained with electrocautery and hemoclips, as needed. Arista absorbable hemostatic powder (Davol, Providence, Rhode Island) is applied to the resection bed.

A nasogastric tube is placed under direct visualization and secured contralateral to the operative field for enteric access. If significant edema of the tongue is anticipated, patients may be kept intubated. In this situation, the wire-reinforced endotracheal tube is exchanged for a Hi-Lo Evac Endotracheal Tube with evacuation lumen (Covidien, Mansfield, MA). This is important because irreversible compression and potential airway compromise may occur if the patient inadvertently bites a wire-reinforced tube while intubated.

Common Errors in Technique

1. Poor exposure from inadequate positioning of the robot and/or retractor
2. Undercutting the cancer at the horizontal anterior resection line instead of angling the instruments forward toward the hyoid bone
3. Mismanagement of the lingual artery or its dorsal lingual branch. These arteries are usually exposed during the resection and should be ligated at multiple positions to prevent potential major postoperative hemorrhage. In addition, ligating the lingual artery in the neck at the time of staged or concurrent neck dissection should be performed.

POSTOPERATIVE PERIOD

Postoperative Management

1. If the patient is felt to be at risk for postoperative airway compromise based on the extent of cancer resection or notable residual edema of the tongue or pharynx, he or she is typically kept intubated for 24 to 48 hours; otherwise he or she may be extubated. We had previously administered intravenous dexamethasone 6 mg every 6 to 8 hours until discharge followed by a Medrol Dose Pack upon discharge. However, we are shifting our protocol toward a single dose of intraoperative intravenous dexamethasone of 10 mg with subsequent steroids only if edema of the airway or tongue is noted.
2. A prophylactic nasogastric feeding tube (Dobhoff) is placed while the patient is in the operating room for enteral access. Patients are evaluated by a speech language pathologist, and

a bedside swallow evaluation is performed. Most patients are then started on a diet of clear liquids and advanced to a mechanical soft diet as tolerated. If caloric intake is adequate, the feeding tube is removed prior to discharge. If swallowing assessment demonstrates significant dysphagia and/or aspiration, patients are discharged with tube feeds at home. A repeat swallowing evaluation is then repeated as an outpatient in 1 to 2 weeks.

3. If there is concern for malnutrition, a consultation with a nutritionist is obtained to guide appropriate caloric supplementation.
4. Significant postoperative pain is expected after resection of the base of the tongue. Patients are started on a patient controlled analgesia pump and transitioned to oral narcotics as tolerated. Nonsteroidal anti-inflammatory drugs are typically avoided within the first 2 weeks post operative given the risk for bleeding.
5. Patients are instructed to swish and spit with Peridex at least 4 times/day to maintain oral hygiene and increase comfort.

Complications

1. Postoperative bleeding occurs in 3% to 8% of patients.[6] This can range from minor oozing to potentially life-threatening hemorrhage. We routinely ligate the lingual, facial, and superior thyroid arteries preoperatively during the neck dissection. In our experience, this maneuver not only decreases intraoperative bleeding that can obscure visualization but also minimizes the risk for catastrophic bleeding. All vessels greater than 2 mm that are encountered during the resection are clipped in multiple locations. The lingual artery or its dorsal lingual branch is typically encountered at the lateral aspect of the resection. When identified, multiple clips are placed along the exposed portion of the artery.
   The danger with postoperative bleeding is the risk of aspiration and subsequent airway compromise rather than exsanguination. In the event of major hemorrhage, care is taken to place the patient's head in the dependent position to prevent aspiration. External pressure is held near the greater cornu of the hyoid bone. The patient is then intubated, and the oropharynx is packed with a gauze roll. The patient is then brought to the operating room immediately to explore the wound and control the bleeding. If transoral intubation is unsuccessful, a cricothyrotomy should be performed.
2. Inadvertent injury to the teeth can occur from retractor manipulation during surgery. Care is taken to place a tooth guard to protect the maxillary dentition prior to transoral exposure. If teeth are loosened during the procedure, they are removed to prevent aspiration. In the event of chipped or avulsed teeth, the patient is referred for dental care.

Alternative Management Plan

1. Primary chemoradiation
2. Open surgical approaches such as lip-split mandibulotomy or transhyoid pharyngotomy

DISCUSSION

Evidence-Based Medicine Question

Do oncologic outcomes differ between traditional open approaches versus TORS?

In 2014 Ford et al. performed a retrospective review of 130 cases comparing TORS with open surgical approaches. Cases were matched with respect to TNM staging and adjuvant therapy. No difference in Human papillomavirus status was seen between the two groups. The authors demonstrated a statistically significant improvement in recurrence-free survival (RFS) favoring TORS (89% RFS vs. 73% at 3 years).[7]

Editorial Comment

Until the advent of TORS in 2004, surgery of the base of the tongue required either complex open approaches that had associated significant morbidity or transoral laser microsurgery that has its own set of challenges. Although these approaches were used by some, the majority of cancers of the base of the tongue were treated with combined chemotherapy and radiation. The application of robotic surgery and TORS has changed this paradigm dramatically. Current estimates place transoral surgery, and in particular TORS, as the most common approach to T1 and T2 cancers of the base of the tongue. In addition to making this a more feasible and widely used technique, there is growing support in the literature for both the quality of life and cost benefit of including TORS in the treatment paradigm for cancer of the base of the tongue.

Another major benefit of using robotic technology and the development of defined TORS procedural steps has been in the realm of teaching. The use of dual or teaching robot consoles allows experienced surgeons to train residents and fellows the defined steps of TORS procedure in a safe and effective manner. Overall, TORS and its national and now global acceptance and application have changed the way head and neck surgeons treat cancer of the base of the tongue.

Bert O'Malley, Jr.

Access the review questions online at http://www.expertconsult.com



REFERENCES

1. Calais GA, Alfonsi M, Bardet E, et al. Randomized trial of radiation therapy versus concomitant chemotherapy and radiation therapy for advanced-stage oropharynx carcinoma. J Natl Cancer Inst 1999;91(24):2081–2086.
2. Machtay M, Moughan J, Trotti A, et al. Factors associated with severe late toxicity after concurrent chemoradiation for locally advanced head and neck cancer: an RTOG analysis. J Clin Oncol 2008;26(21):3582–3589.
3. O'Malley Jr BW, Weinstein GS, Snyder W, et al. Transoral robotic surgery (TORS) for base of tongue neoplasms. Laryngoscope 2006;116(8):1465–1472.
4. Genden EM, Desai S, Sung CK. Transoral robotic surgery for the management of head and neck cancer: a preliminary experience. Head Neck 2009;31(3):283–289.
5. Iseli TA, Kulbersh BD, Iseli CE, et al. Functional outcomes after transoral robotic surgery for head and neck cancer. Otolaryngol Head Neck Surg 2009;141(2):166–171.
6. Asher SA, White HN, Kejner AE, et al. Hemorrhage after transoral robotic-assisted surgery. Otolaryngol Head Neck Surg 2013;149(1):112–117.
7. Ford SE, Brandwein-Gensler M, Carroll WR, et al. Transoral robotic versus open surgical approaches to oropharyngeal squamous cell carcinoma by human papillomavirus status. Otolaryngol Head Neck Surg 2014;151(4):606–611.

REVIEW QUESTIONS

1. In the event of major postoperative hemorrhage, all of the following should be performed, except
   a. Immediate transoral intubation or cricothyrotomy
   b. Packing the oropharynx once an airway is established
   c. Placing external pressure over the neck
   d. Placing the patient supine

2. Tumor contraindications to transoral robotic surgery (TORS) tongue base resection include
   a. Major invasion of the genioglossus muscle
   b. Tumor encasement of the internal carotid artery
   c. Deep involvement of more than half of the tongue base
   d. All of the above

3. Intraoperative robotic collisions can be minimized with
   a. Elevating the camera arm to its maximum height
   b. Placing the instruments arms in a "V" configuration
   c. Positioning the pivot point of the camera arm at the level of the oral commissure
   d. All of the above

37 Surgery of the Soft Palate

Jeffrey Hotaling, David M. Cognetti

INTRODUCTION

The soft palate is a subsite of the oropharynx. Its axial plane defines the superior boundary of the oropharynx, incompletely separating it from the nasopharynx above. The soft palate comprises approximately one-third of the palate, with the more anteriorly positioned hard palate making up the remainder; the junction between the hard and soft palates also separates the oral cavity from the more posteriorly located oropharynx. In contrast to the hard palate, the soft palate is a mobile structure that is suspended from the posterior aspect of the hard palate via the palatine aponeurosis. This aponeurosis is formed by the expanded tendon of the tensor veli palatini. The thicker, anterior portion of this tendon constitutes the majority of the anterior soft palate, whereas the posterior aspect of the soft palate is mainly comprised of muscle (levator veli palatine, tensor veli palatini, palatoglossus, palatopharyngeus). At its most posteroinferior extent, the free margin of the soft palate contains a conical muscular projection, the uvula. Functionally, the soft palate is a dynamic structure that is critical for velopharyngeal competence. Elevation of the soft palate puts it into contact with the posterior pharyngeal wall, sealing it off from the nasopharynx (e.g., when swallowing), and its depression puts it in contact with the tongue base, sealing the oral cavity from the nasal passage (e.g., when breathing exclusively through the nose). In this way, function of the soft palate is critical to velopharyngeal competence.[1]

Neoplasms of the soft palate may arise from any of the individual, constituent parts of the soft palate (muscle, lymphatics, mucosa, connective tissue), encompassing a broad variety of benign and malignant tumors (Table 37.1). Importantly, benign tumors of the soft palate are extremely rare, and any soft palate lesion should be considered malignant until proven otherwise. Squamous cell carcinoma is the most common neoplasm of the soft palate, and the oropharynx in general, accounting for more than 90% of all malignant tumors in the oropharynx (Fig. 37.1). Etiologic factors contributing to squamous cell carcinoma are alcohol and tobacco.[2] Although the human papillomavirus (HPV) has more recently been established as an etiologic and positive prognostic factor for oropharyngeal squamous cell carcinoma, a recent review has suggested that significantly less soft palate squamous cell carcinomas are HPV positive than other subsites (22% vs. 70%).[3]

A tumor of salivary gland origin represents the next most commonly encountered tumor of the soft palate, originating in the many minor salivary glands distributed throughout the soft palate. Although the most common benign salivary gland tumor of the soft palate is pleomorphic adenoma, it is estimated that nearly 50% of minor salivary gland tumors in the oropharynx are malignant. The most common of these malignancies are adenoid cystic carcinoma and mucoepidermoid carcinoma.[4] In contrast to the mucosal disruption caused by typical squamous cell carcinomas, minor salivary gland tumors are frequently submucosal.

Lymphatic drainage of the soft palate is primarily to the superior jugulodigastric chain (level II) with subsequent drainage inferiorly to levels III and IV.[5] Importantly the retropharyngeal lymph nodes also receive significant drainage from the soft palate, with one study demonstrating retropharyngeal node involvement of carcinoma in 56% of cancers of the soft palate.[6] Cancers of the soft palate also have a high incidence of metastases to the cervical lymph nodes, with one study demonstrating that 48% of patients with cancer of the soft palate present with metastases to the neck and another 40% who initially presented with an N0 neck who eventually went on to develop cervical lymph node metastases.[7] Because of this, all patients with clinically negative necks still require treatment with either an elective neck dissection or radiation, with bilateral neck dissection required for lesions involving or approaching the midline.

KEY OPERATIVE LEARNING POINTS

1. The soft palate is a dynamic structure whose function is critical for velopharyngeal competence.
2. There is a high incidence of cervical lymph node metastasis associated with cancer of the soft palate (particularly with squamous cell carcinoma). Treatment of both necks is recommended for squamous cell cancers involving or approaching the midline.
3. Reconstruction of the soft palate is complex, and reconstitution of a functional velopharyngeal sphincter is key.

PREOPERATIVE PERIOD

History

1. History of present illness
   a. Symptoms range widely from asymptomatic to odynophagia, dysphagia, otalgia, airway compromise, oral bleeding, weight loss, changes in speech, and a mass in the neck.
   b. Early lesions are often found incidentally due to dental examinations, ill-fitting dentures, and office physical examinations but also may present at more advanced stages.
   c. Patients may have hearing loss due to middle ear effusion secondary to Eustachian tube dysfunction.
2. Past medical history
   a. Prior history of malignancies and treatment
   b. Anticoagulant medications
3. Social history
   a. Tobacco use history (all types)
   b. Alcohol use history

Physical Examination

1. All patients should undergo a comprehensive examination of the head and neck.
   a. Thorough inspection and palpation of the oral cavity and oropharynx
   b. Neck: assessment for cervical lymph node metastases
   c. Laryngoscopy/pharyngoscopy: assessment posterior/inferior extent of lesion, evaluation of larynx/hypopharynx, evaluation for second primary malignancy, evaluation of airway patency
   d. Cranial nerve examination: evaluation of palatal elevation (CN X)
2. The primary tumor should be evaluated with respect to location and extension into surrounding structures.

TABLE 37.1 Common Tumors of the Soft Palate

Benign	Malignant
Fibroma	Adenocarcinoma
Hemangioma	Adenoid cystic carcinoma
Lipoma	Lymphoma
Papilloma	Mucoepidermoid carcinoma
Pleomorphic adenoma	Mucosal melanoma
Schwannoma	Squamous cell carcinoma

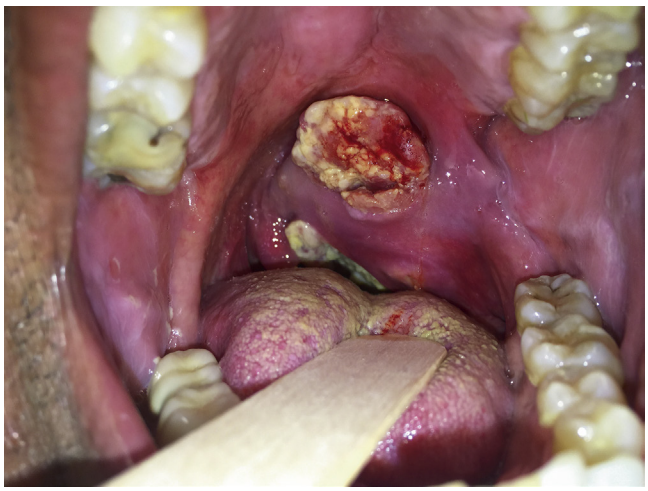

Fig. 37.1. Advanced-stage squamous cell carcinoma of the soft palate.

a. Size of the lesion, local extent (e.g., involvement of adjacent subsites), firmness to palpation, mobility, endophytic versus exophytic, oral airway obstruction
b. A neoplasm isolated to the posterior/nasopharyngeal surface of the soft palate is exceedingly rare.
c. Mouth opening should be evaluated because trismus and oral airway obstruction by tumor may preclude a transoral resection or intubation.

Imaging

Computed tomography (CT) and magnetic resonance imaging (MRI) are frequently used for delineation of local extent of tumor (T-stage) and evaluation for cervical metastases; (Fluorodoxyglucose-Positon Emission Tomography/Computerized Tomography FDG PET/C) is used to evaluate for distant metastases.

1. CT with contrast: primary imaging modality for head and neck cancer; gives excellent delineation of involvement of adjacent bony structures (palate, mandible)
2. MRI with contrast: enhanced soft tissue resolution allowing better delineation of depth of invasion and evaluation of perineural invasion. Although MRI has a greater potential for motion artifact, dental artifact is usually significantly less than with CT.[8]
3. FDG PET/CT: improved sensitivity over CT or MRI alone in detecting metastases greater than 5 mm. The negative predictive value of PET/CT is nearly 100% for second primary tumors and metastatic disease.[9]

Indications

1. Early-stage (T1-T2) squamous cell carcinoma with minimal involvement of soft palate musculature
2. Advanced (T3-T4) cancer of salivary gland origin
3. Salvage surgery for persistent/recurrent cancers (salvage is typically successful in only ⅓ of patients)[10]

Contraindications

1. Advanced (T3-T4) lesions requiring resection of a significant portion of the soft palate musculature (exception: patients who are not candidates for or who have already received definitive radiation)
2. Patients with distant metastases or large/unresectable cervical lymph node metastases
3. Proximity to large vessels to or involvement of primary tumor (i.e., medialized course of carotid artery or tumor adjacent to carotid artery)
4. Patients with significant trismus or oral contractures limiting access for a transoral resection (transcervical resection may still be possible)
5. Patients medically unfit to undergo general anesthesia (rare)

Preoperative Preparation

1. Biopsy of the lesion should be performed for adequate diagnosis prior to any definitive resection.
2. Evaluation for metastasis should be completed preoperatively.
3. Discussion of surgery with a complete explanation of risks/benefits/alternatives
   a. Risks: bleeding, infection, need for additional surgery and/or adjunctive treatments, velopharyngeal incompetence
   b. Benefits: tumor excision, pathologic staging, possibility of avoiding radiation therapy and/or chemotherapy in some cases
   c. Alternatives: Radiation ± chemotherapy depending on tumor stage. Not effective in tumors of salivary gland origin.
4. Patients should be aware of the possibility and expected duration of a tracheostomy and/or placement of a feeding tube.
5. Patient should be seen in consultation with a Maxillofacial Prosthodontist with possible fabrication of a prosthesis.

OPERATIVE PERIOD

Anesthesia

General anesthesia is typically required for patient comfort and airway protection.

Positioning

Supine with shoulder roll placement reserved for concurrent neck dissection or the rare transcervical approach

Perioperative Antibiotic Prophylaxis

Clean-contaminated surgery with recommendation for ampicillin/sulbactam or clindamycin, cefazolin which should be given prior to skin incision and then continued for no more than 24 hours[11]

Monitoring

Although muscle relaxant (i.e., paralysis) is often required for transoral resections, some surgeons prefer the patient nonparalyzed during concurrent neck dissection or the rare transcervical approach to enable nerve assessment.

Instruments and Equipment to Have Available

1. Mouth retractor: Crowe-Davis, McIvor, Dingman, and Feyh-Kastenbauer can all be used depending on patient factors (mouth opening, dentition, tumor location) and surgeon's preference.

2. Standard head and neck and oral surgery set
3. Cautery: Bovie electrocautery may be used for excision with suction cautery, and/or bipolar cautery is often required for hemostasis.
4. Adjunctive equipment:
   a. Robotic platform (da Vinci System) for transoral robotic surgery (TORS)
   b. CO_2laser (±microscope) for transoral laser microsurgery (TLM)

Key Anatomic Landmarks

1. Tonsillar pillars: Formed by the paired palatoglossus (anterior) and palatopharyngeus (posterior) muscles, these muscles form lateral connections of the soft palate to the tongue base and pharynx, respectively. These also serve as routes of extension of tumor onto the pharyngeal wall, tonsil, and base of tongue, which is important in surgical planning.
2. Hard/soft palate junction: defines the anterior boundary of the oropharynx and serves as the attachment point for the palatine aponeurosis, into which all four paired muscles of the soft palate insert (palatoglossus, palatopharyngeus laterally; levator veli palatini and tensor veli palatini centrally)
3. Lesser palatine artery: paired arteries arising from the lesser palatine foramina in the posterior hard palate that supply the soft palate
4. Uvula: conical, muscular projection from the free margin of the posteroinferior extent of the midline soft palate

Prerequisite Skills

If undertaking TLM or TORS, the surgeon must be experienced with these modalities.

Operative Risks

1. Bleeding
2. Infection
3. Dysphagia
4. Velopharyngeal incompetence
5. Need for additional procedures or treatment modalities

Surgical Technique

1. Ablation: Transoral resection is the rule for most isolated cancers of the soft palate. Extended, transcervical approaches to the oropharynx (i.e., cheek flap, mandibulotomy with lip split) are rarely required for isolated cancer of the soft palate but may be necessary for larger/composite resections or in patients with severe trismus limiting transoral exposure. It is critical to have a three-dimensional (3D) understanding of the tumor, and larger tumors require margins to be achieved in both the oropharynx and the nasopharynx. Ideally, the posterior nasopharyngeal margins are directly visualized. Resection of the cancer should be performed with at least 1-cm margins of normal tissue with margins verified by frozen section. The incisions in the oropharyngeal mucosa are made first with any deeper, muscular or nasopharyngeal mucosal resection dictated by the extent of the tumor. Larger cancers will often require a through-and-through defect, whereas in more superficial lesions, the posterior soft palate can be preserved. Given the high prevalence of regional metastasis, all patients with squamous cell carcinoma should undergo unilateral neck dissection (levels II to IV), with bilateral neck dissection performed for patients with larger cancers in or approaching the midline. The transoral resection may be performed with multiple modalities according to patient factors and surgeon's preference:
   a. Transoral electrocautery: traditional method using handheld electrocautery; access and visualization may be limited by short working distance of the instruments
   b. TLM: improved visualization enabled by the use of a microscope and longer working distance of the laser. This modality has been shown to be effective in both primary and salvage resections.[12]
   c. TORS: affords 3D visualization with 10-fold magnification and an operation using two fully articulated instruments; outcomes are reliant on surgeon experience, but the modality has been proven effective with high local control and low morbidity[13,14]
   d. Transcervical/transmandibular approaches: rarely used for isolated defects of the soft palate; may be required for larger, composite defects of the oropharynx or in salvage situations in patients with significant trismus
2. Reconstruction: Functional reconstruction of the soft palate is complex, owing to its important role in speech and swallowing. The best results are obtained with small defects wherein the musculature of the soft palate is minimally resected and can be reapproximated. If the defect extends beyond the midline of the soft palate, reconstruction typically involves reducing the cross-sectional area of the velopharynx.[15]
   a. *Primary closure:* best for smaller, superficial defects (commonly submucosal cancer of minor salivary gland origin). Accomplished by approximating oropharyngeal mucosa to posterior/nasopharyngeal mucosa on either side of the defect (similar to a uvulopalatopharyngoplasty). Healing by secondary intention is also possible for small defects but may result in wound contraction and velopharyngeal insufficiency (VPI).
   b. *Obturation:* best suited to smaller defects of the central palate. Adequate remaining dentition is necessary to anchor the prosthesis. It is also an option for patients who are not candidates for large reconstructive efforts. The prosthesis allows nasal breathing at rest but contacts the posterior pharyngeal wall to enable velopharyngeal closure during swallowing. Studies have shown equivalent speech outcomes between obturation and free flap reconstruction for extensive soft palate defects.[16,17]
   c. *Local flaps:* The uvulopalatal flap, pharyngeal flap (Fig. 37.2), palatal island flap, and the superior constrictor

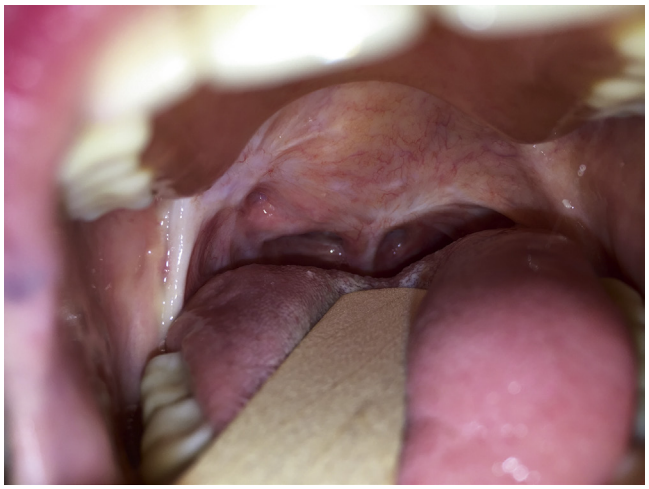

Fig. 37.2. Well-healed pharyngeal flap reconstruction of the soft palate defect.



Fig. 37.3. Well-healed radial forearm reconstruction of the soft palate defect.

flap have all been described and are best for defects of less than 50% of the lateral palate.

d. *Regional flaps:* Although the pectoralis major flap remains the most frequently used pedicled flap for large/composite oropharyngeal defects, the temporalis muscle flap is another option for larger, isolated defects of the soft palate.[18]
e. *Microvascular free flaps:* Often necessary for defects encompassing greater than 50% of the soft palate and composite defects of the oropharynx, both the radial forearm free flap (Fig. 37.3) and anterolateral thigh free flap have been successfully used.[19] These are often combined with a muscular velopharyngoplasty, which entails suturing the cut edges of the soft palate and posterior pharyngeal wall musculature together to reconstitute a functional velopharyngeal sphincter.[17]

Common Errors in Technique

1. Inadequate transoral exposure with resulting poor surgical outcome
2. Inability to appreciate 3D nature of the cancer/soft palate with resulting positive margins (Fig. 37.4)
3. Failure to ensure hemostasis along the posterior/nasopharyngeal edge of the soft palate, leading to postoperative hemorrhage

POSTOPERATIVE PERIOD

Postoperative Management

1. Intensive care unit (ICU)/stepdown with continuous pulse oximetry recommended following larger resections requiring reconstruction given the potential for edema of the airway
2. Larger resections may require feeding tube given high potential for dysphagia and pain limiting oral intake; percutaneous endoscopic gastrostomy PEG tube placement should be considered for patients undergoing more extensive resections in which long-term dysphagia and adjuvant therapy are anticipated.
3. Pain medication is often necessary for 7 to 14 days postoperatively.
4. Prosthetic rehabilitation (obturation) may enable improved velopharyngeal closure, and placement of an obturator at the time of resection may enable early oral feeding.

Complications

1. Bleeding: Any significant postoperative bleeding requires a return to the operating room to achieve complete hemostasis.

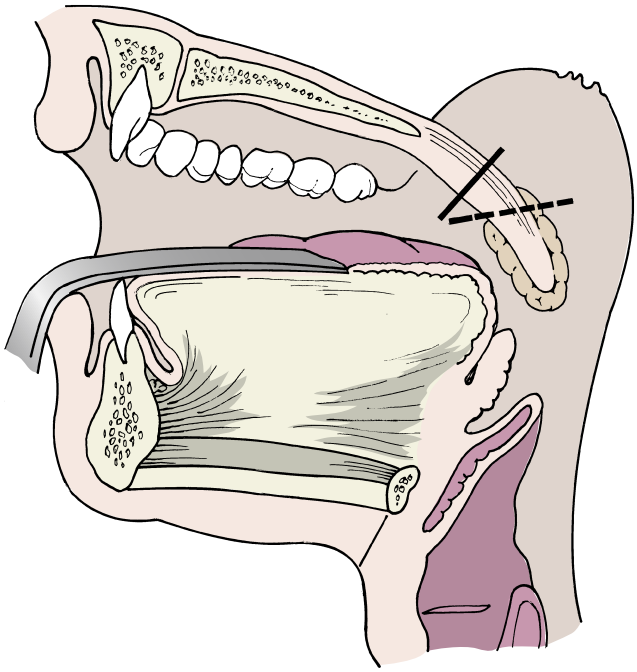

Fig. 37.4. In resecting tumors involving the soft palate, the surgeon must be careful to achieve clear surgical margins in both the oropharynx and the nasopharynx.

2. Airway obstruction/compromise: typically due to postoperative edema or bulky flap reconstruction; prophylactic tracheostomy for patients requiring flap reconstruction
3. Velopharyngeal incompetence: often improves with time after small/moderate resections, but may require obturation or secondary procedure (pharyngeal flaps) if severe or persistent

Alternative Management Plan

1. Radiation versus chemoradiation depending on the stage with possible surgical salvage
2. Palliation

DISCUSSION

Evidence-Based Medicine Question

What is the evidence for primary transoral surgical resection of early-stage squamous cell carcinoma of the soft palate (Fig. 37.5)?

Early-stage oropharyngeal cancers can be treated with either surgery or radiation therapy. A large review by Iyer et al. from Memorial Sloan Kettering in 2011 demonstrated no difference in outcomes in treatment of early-stage (T1-T2) soft palate squamous cell carcinoma with surgical or nonsurgical modalities.[20] Recently, there has been an increased interest in primary surgical management in patients with cancer of the oropharynx. The reason for this lies mainly in the advent of new transoral resection technique, including TORS and TLM, which are less morbid and may allow improved functional results when compared with previous open surgical resection.

Another argument in favor of primary surgical management for early-stage cancer of the soft palate lies in the ability to more accurately stage tumors, thereby more appropriately selecting adjuvant radiation or chemoradiation. A recent article by Smith et al. evaluated adjuvant therapy in patients with oropharyngeal squamous cell carcinoma undergoing TORS and neck dissection. This study found that in 43% of the patients, TORS and neck



Fig. 37.5. Early-stage squamous cell carcinoma of the soft palate.

dissection resulted in a change in the patient's stage, with 50% of these stage changes resulting in alterations in the treatment plan.[13] This improved staging enabled by primary surgery may enable deintensification or even elimination of adjuvant therapy in patients with early-stage soft palate lesions with limited neck metastasis.

Lastly, there has traditionally been concern that patients with soft palate resection suffered from suboptimal reconstruction resulting in poor functional outcomes with respect to speech and swallowing. However, recent studies have demonstrated that the size of the defect is the most important determinant of postoperative function. In fact, a recent study by Lv et al. studied at postoperative speech and swallowing function in 45 consecutive patients undergoing soft palate resections with immediate flap reconstruction. They obtained normal to near-normal function in patients with defects consisting of less than 50% of the soft palate, regardless of the particular type of flap used for reconstruction.[15] As most early-stage lesions of the soft palate require less than 50% resection of the soft palate, it follows that resection of these lesions does not result in poor postoperative function.

Surgical resection of early-stage lesions of the soft palate has results at least on par with nonsurgical treatment, enables more accurate staging and the possibility of deintensification or avoidance of adjuvant therapy with its attendant side effects, and does not preclude good postoperative speech and swallowing function given our current reconstructive armamentarium.

Editorial Comment

Although radiation is a very acceptable primary therapy for T1 and T2 cancers[20] there is a movement toward primary surgery given the popularization of TORS and TLM over the past 5 years. This is occurring for multiple reasons, one of which is that the use of advanced imaging technology coupled with less invasive surgical techniques and improved local reconstruction has allowed head and neck surgeons to perform transoral palatal surgery with low morbidity. In addition, the authors make a very important point about the advantages of having both primary cancer and lymph node pathology results to guide the decision making and targeting of adjuvant therapy. Smith et al.[13] demonstrated that almost half of all patients treated with TORS and neck dissection had a change in staging after the postsurgical pathology results were known. Of these 50% of patients with revised staging, half received subsequent alterations in their overall treatment plan. The authors state that the ability to have surgical pathology and thus truly accurate staging may enable deintensification or even elimination of adjuvant therapy in patients with early-stage cancer of the soft palate with limited metastasis in the neck. This is a very important concept and one that is aligned with the broader interest and evolution of personalized medicine and therapy.

Bert O'Malley, Jr.

Access the review questions, additional references and additional sources list online at http://www.expertconsult.com

REFERENCES

1. Moore KL, Anne MR. Essential Clinical Anatomy. Baltimore, Agur Lippincott Williams & Wilkins; 2007. p. 549–553.
2. Blot WJ, Mclaughlin JK, Winn DM, et al. Smoking and drinking in relation to oral and pharyngeal cancer. Cancer Res 1988;48(11): 3282–3287.
3. Frandsen VL, Grønhøj LC, Von BC. Prevalence of human papillomavirus in squamous cell carcinomas of the soft palate. J Clin Pathol 2015;68(11):942–943.
4. Eveson JW, Cawson RA. Tumours of the minor (oropharyngeal) salivary glands: a demographic study of 336 cases. J Oral Pathol Med 1985;14(6):500–509.
5. Lindberg R. Distribution of cervical lymph node metastases from squamous cell carcinoma of the upper respiratory and digestive tracts. Cancer 1972;29:1446–1449.
6. Bussels B, Hermans R, Reijnders A, et al. Retropharyngeal nodes in squamous cell carcinoma of the oropharynx: incidence, localization, and implications for target volume. Int J Radiat Oncol Biol Phys 2006;65(3):733–738.
7. Har-El G, Shaha A, Chaudry R, et al. Carcinoma of the uvula and midline soft palate: indication for neck treatment. Head Neck 1992;14:99–101.
8. Wippold FJ II: Head and neck imaging: the role of CT and MRI. J Magn Reson Imaging 2007;25(3):453–465.
9. Johnson JT, Branstetter BF IV. PET/CT in head and neck oncology: state-of-the-art 2013. Laryngoscope 2014;124(4):913–915.
10. Gourin CG, Johnson JT. A contemporary review of indications for primary surgical care of patients with squamous cell carcinoma of the head and neck. Laryngoscope 2009;119(11):2124–2134.

REVIEW QUESTIONS

1. Velopharyngeal competence can be defined as:
   a. Dynamic separation of the oropharynx from the nasopharynx
   b. Patent nasal airway
   c. A lack of communication between the nasal cavity and the oropharynx
   d. A patent oropharynx

2. The most common minor salivary gland malignancy of the soft palate is:
   a. Polymorphous low-grade adenocarcinoma
   b. Mucoepidermoid carcinoma
   c. Adenoid cystic carcinoma
   d. Acinic cell carcinoma

3. True or false: Most soft palate tumors are benign.
   a. True
   b. False

4. Indications for treatment of the neck in patients with cancers of the soft palate are based primarily on:
   a. Lesion T-stage
   b. Clinical or radiographic evidence of neck disease
   c. Tumor type (pathology)
   d. Lesion location

REFERENCES

11. Koshkareva YA, Johnson JT. What is the perioperative antibiotic prophylaxis in adult oncologic head and neck surgery? Laryngoscope 2013;124(5):1055–1056.
12. Melong JC, Rigby MH, Bullock M, et al. Transoral laser microsurgery for the treatment of oropharyngeal cancer: the Dalhousie University experience. J Otolaryngol Head Neck Surg 2015;44:39.
13. Smith RV, Schiff BA, Garg M, et al. The impact of transoral robotic surgery on the overall treatment of oropharyngeal cancer patients. Laryngoscope 2015;125(Suppl. 10):S1–S15.
14. Weinstein GS, Quon H, Newman J, et al. Transoral robotic surgery alone for oropharyngeal cancer: an analysis of control. Arch Otolaryngol Head Neck Surg 2012;138(7):628–634.
15. Lv M, Shen Y, Li J, et al. Immediate reconstruction of soft palate defects after ablative surgery and evaluation of postoperative function: an analysis of 45 consecutive patients. J Oral Maxillofac Surg 2014;72(7):1397–1406.
16. Rieger J, Bohle Lii G, Huryn J, et al. Surgical reconstruction versus prosthetic obturation of extensive soft palate defects: a comparison of speech outcomes. Int J Prosthodont 2009;22(6):566–572.
17. Old M, Teknos TN. Pharynx, cervical esophagus, and hypopharynx reconstruction. In: Genden EM, editor. Reconstruction of the Head and Neck: A Defect-Oriented Approach. New York: Thieme; 2012; 92–109.
18. Wong TY, Chung CH, Huang JS, et al. The inverted temporalis muscle flap for intraoral reconstruction: its rationale and the results of its application. J Oral Maxillofac Surg 2004;62(6):667–675.
19. Tsuchiya S, Nakatsuka T, Sakuraba M. One-sided soft palatal reconstruction with an anterolateral thigh fasciocutaneous flap: report of two cases. Microsurgery 2011;31(2):150–154.
20. Iyer NG, Nixon IJ, Palmer F, et al. Surgical management of squamous cell carcinoma of the soft palate: factors predictive of outcome. Head Neck 2012;34(8):1071–1080.

ADDITIONAL SOURCES (5 CLASSIC REFERENCES AND OTHER SOURCES OF INFORMATION WITH BRIEF SYNOPSIS OF EACH)

1. Chera BS, Amdur RJ, Hinerman RW, et al. Definitive radiation therapy for squamous cell carcinoma of the soft palate. Head Neck 2008;30:1114–1119.
2. Harris JR, Seikaly H, Urken ML, et al. Oropharyngeal reconstruction. In: Urken ML, editor. Multidisciplinary Head & Neck Reconstruction: A Defect-Oriented Approach. Philadelphia: Lipincott Williams & Wilkins; 2010.
3. Mourad WF, Hu KS, Choi WH, et al. Cancer of the oropharynx. In: Harrison LB, Sessions RB, Kies MS, editors. Head and Neck Cancer: A Multidisciplinary Approach. Philadelphia: Lippincott Williams & Wilkins; 2014.
4. Uli H. Chapter 100: Malignant neoplasms of the oropharynx. In: Paul WF, Bruce HH, Valerie LJ, John KN, Mark AR, Robbins KT, Regan JT, editors. Cummings Otolaryngology Head and Neck Surgery. 5th ed. vol. 2. Philadelphia: Mosby Elsevier; 2010. p. 1358–1374.
5. Weber RS, Peters LJ, Wolf P, Guillamondegui O. Squamous cell carcinoma of the soft palate, uvula, and anterior faucial pillar. Otolaryngol Head Neck Surg 1988;99:16–23.

38 Transoral Removal of Elongated Styloid Process

Carl H. Snyderman

INTRODUCTION

The association of an elongated styloid process with pharyngeal and cervical pain is known as Eagle syndrome and was first described in 1937.[1] Eagle syndrome is characterized as a dull, aching pain localized to one or both sides of the throat with referred otalgia.[2] Some pain may occur on swallowing or protrusion of the tongue or on rotating the head, and some patients complain of a foreign body sensation in their throat.

The etiology of styloid elongation and ossification of the stylohyoid ligament complex is unclear.[2] Elongation of the styloid process occurs in approximately 4% of the population, but only a small percentage of patients with this finding are symptomatic (<10%). Eagle syndrome occurs more frequently in women than in men and is usually found in patients older than 30 years. Symptoms are often unilateral despite bilateral elongation.

The pathophysiology of Eagle syndrome is generally thought to be secondary to compression by the abnormal styloid of vascular and nervous structures, in particular the glossopharyngeal nerve and carotid artery.[2] "Classic Eagle syndrome" is associated with tonsillectomy or pharyngeal trauma. "Stylocarotid syndrome" is characterized by compression of the carotid artery by an elongated styloid process that deviates medially.

The differential diagnosis of this condition includes cranial nerve neuralgias (e.g., trigeminal, glossopharyngeal, sphenopalatine, superior laryngeal, and primary geniculate neuralgias), temporomandibular joint disease, chronic pharyngotonsillitis, unerupted or impacted molar teeth, cervical osteoarthritis, and tumors in the oropharynx.

KEY OPERATIVE LEARNING POINTS

- The diagnosis of Eagle syndrome is a diagnosis of exclusion.
- A transoral approach is preferred if the styloid process is palpable intraorally.
- A transcervical approach is preferred if there is complete calcification of the stylohyoid ligament.
- Intraoral visualization can be enhanced with endoscopy (nasal endoscope).
- Injury to the carotid artery and facial nerve can be avoided by maintaining the plane of dissection on the styloid process.
- A bone rongeur is used to resect the styloid process close to its origin at the skull base.

PREOPERATIVE PERIOD

History

- Unilateral (or bilateral) pain in the throat or neck
- Dull, nagging pain that may be exacerbated by swallowing or turning the head
- Lack of other symptoms associated with cranial nerve deficits

Physical Examination

- Inspection of the oral cavity and pharynx (including nasopharynx and hypopharynx) is normal with no mucosal lesions.
- Palpation of the tonsillar fossa reveals a hard thin mass in the area of the tonsillar fossa and reproduces the patient's symptoms.
- Cranial nerve function is intact.
- Infiltration of lidocaine in the region of the tonsillar fossa may abolish the symptoms.

Imaging

- Plain film radiograph. Individual styloid processes can be difficult to view due to superimposition of the surrounding structures.
- Panorex. Both styloid processes can be seen in detail.
- Computed tomography (CT) scan. CT provides excellent visualization of bony detail. If performed with contrast, CT also screens for other pathology in the differential diagnosis. A CT angiogram demonstrates the relationship of the carotid artery to the styloid process.
- Three-dimensional (3D) reconstruction of CT scan (Fig. 38.1). Superb visualization of the styloid processes and calcified stylohyoid ligaments and their relationship to other structures is provided by a 3D reconstruction. This study is helpful in planning the surgical approach.

Indications

- Unilateral or bilateral throat or neck pain that does not respond to conservative measures (analgesics)
- Palpable styloid process with reproduction of symptoms
- Infiltration of lidocaine abolishes symptoms
- Absence of other pathology
- Radiographic evidence of enlarged or angulated styloid process

Contraindications

- Limited opening of the mouth
- Complete calcification of the stylohyoid ligament

Preoperative Preparation

- Preoperative imaging with CT scan
- Discussion with the patient that removal of the elongated styloid process does not always abolish the pain. There are other causes of these symptoms.

OPERATIVE PERIOD

Anesthesia

- General anesthesia with muscle relaxants.
- Oral RAE tube to prevent kinking; positioned in the midline to accommodate retractors.

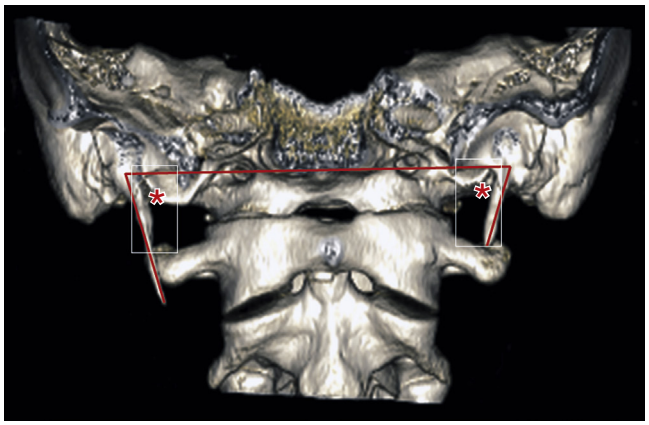

Fig. 38.1. Three-dimensional computed tomography of patient with Eagle syndrome demonstrates elongated styloid processes (right greater than left). Medial angulation *(asterisks)* may also be associated with Eagle syndrome. *(Reprinted with permission from: Kent DT, Rath TJ, Snyderman CH. Conventional and 3-dimensional computerized tomography in Eagle's syndrome, glossopharyngeal neuralgia, and asymptomatic controls. Otolaryngol Head Neck Surg 2015;153(1):41–47.)*

- Nasotracheal intubation through the contralateral nasal cavity is an excellent alternative to keep the tube out of the surgical field.

Positioning

- Supine with head and neck extended (Rose position)
- Reverse Trendelenburg position (15 degrees) to decrease bleeding

Perioperative Antibiotic Prophylaxis

- Penicillin
- If the patient is allergic to penicillins, use clindamycin.

Monitoring

- Facial nerve monitoring is optional.
- Navigation system. Image-based navigation (CT angiogram) can be helpful to localize the styloid process and the adjacent internal carotid artery.

Instruments and Equipment to Have Available

- McIvor or Dingman mouth retractor
- Zero-degree Hopkins rod endoscope (optional)
- Extended needle tip electrocautery
- Bipolar electrocautery
- Yankauer tonsil suction
- Cottle elevator
- Hurd or malleable retractors
- Kerrison bone rongeur (2 to 3 mm)
- "Needle-nose" bone rongeur (straight fine-tip rongeur)

Key Anatomic Landmarks

- The styloid process is anterior to the stylomastoid foramen.
- The stylopharyngeus, stylohyoid, and styloglossus muscles all take their origin from the styloid process of the temporal bone.
- The facial nerve is posterior and lateral to the styloid process.
- The internal carotid artery is medial to the styloid process.
- An elongated styloid process is palpable in the tonsillar fossa and posterior floor of mouth.

Prerequisite Skills

- Tonsillectomy (see Chapter 192).

Operative Risks

- Injury to the facial nerve. Excessive use of electrocautery or aggressive resection of the styloid process to its attachment at the skull base risks injury to the facial nerve.
- Injury to the carotid artery. Dissection of the soft tissues medial to the styloid process risks injury to the internal carotid artery.

Surgical Technique

- The mouth retractor is placed with the tongue and the endotracheal tube in the midline. The tongue can be placed slightly to the contralateral side to provide greater access to the posterior floor of mouth.
- If tonsils are present, a tonsillectomy is performed on the surgical side.
- The tonsillar fossa is palpated to identify the elongated styloid process. The surrounding tissues are infiltrated with several milliliters of 0.5% xylocaine with 1:200,000 epinephrine.
- Using the suction tip or Hurd retractors, the soft tissues are pushed laterally and posteriorly to tent the tissues over the styloid process (Fig. 38.2). The constrictor muscle is then incised with electrocautery down to the styloid process.
- A 0-degree Hopkins rod endoscope may be used to enhance visualization, especially when an assistant is retracting.
- After the styloid process is identified (Fig. 38.3), the tendinous attachments are also incised and the styloid process is skeletonized with a sharp Cottle elevator or a ring curette. It is important to maintain a subperiosteal plane of dissection on the styloid process to avoid injury to the internal carotid artery and facial nerve.
- A Kerrison rongeur is then inserted and the styloid process is removed as far superior as possible (Fig. 38.4).
- The wound should be palpated to make sure that most of the styloid has been removed and that a sharp point does not remain.
- Hemostasis is obtained with bipolar electrocautery and the wound is irrigated.
- A single-layer closure is performed with a chromic suture. No drains are required.

Common Errors in Technique

- Inadequate exposure. This may result from a limited incision, incision in the wrong location, or inadequate retraction of soft tissues.
- Fracture of styloid. If the styloid is fractured before it is completely exposed, it is difficult to dissect the periosteum. If that happens, grasp it with a clamp while dissecting.
- Incomplete excision of styloid. The Kerrison rongeur can be used to remove additional bone without injury to surrounding tissues.

POSTOPERATIVE PERIOD

Postoperative Management

- Perioperative intravenous antibiotics are administered for 1 to 2 doses. Oral antibiotics are not necessary.
- The patient is observed for several hours for edema and may be discharged the same day if able to take oral fluids.

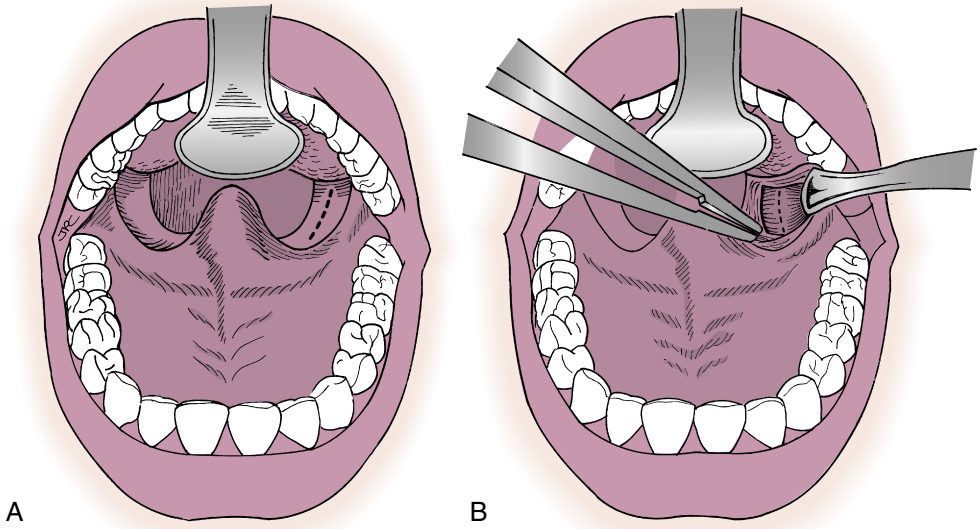

Fig. 38.2. **A** and **B**, Hurd retractors tenting the constrictor muscles over the styloid process and the incision carried down onto the styloid process under direct vision.

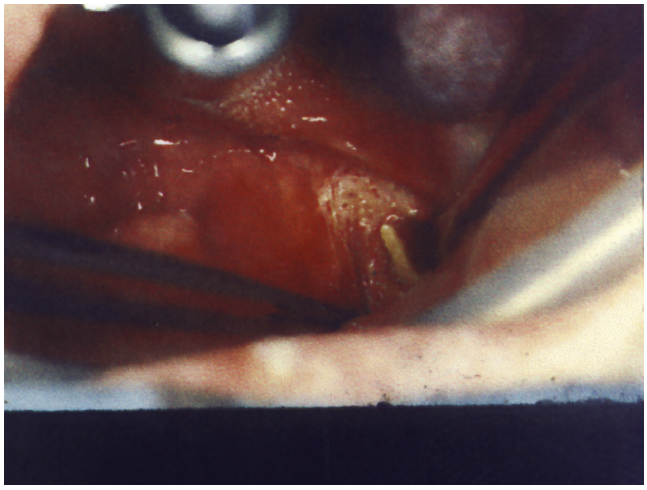

Fig. 38.3. The styloid process is exposed.

- Mild analgesics are prescribed.
- Chlorhexidine solution may be prescribed to rinse the oral cavity.
- The diet may be advanced as tolerated.
- Although most patients experience immediate improvement in symptoms, some pain from the surgery is to be expected.
- Observe for postoperative hematoma or infection.

Complications

- Beware of the possibility of an incorrect diagnosis. There are many cranial nerves in this area, each of which may have its own neuralgia with or without an elongated styloid process.
- Bleeding from the operative site may be encountered. Every effort should be made to prevent bleeding by the use of bipolar cautery.
- Injury to the carotid artery, which lies medial to the styloid process, is a potential complication. The surgeon's detailed knowledge of the anatomical structures in relation to the styloid process, including the ICA, will alert the surgeon to limit the dissection to the elongated styloid process, which can be helped by retraction of the soft tissues accurately displaying the styloid process.

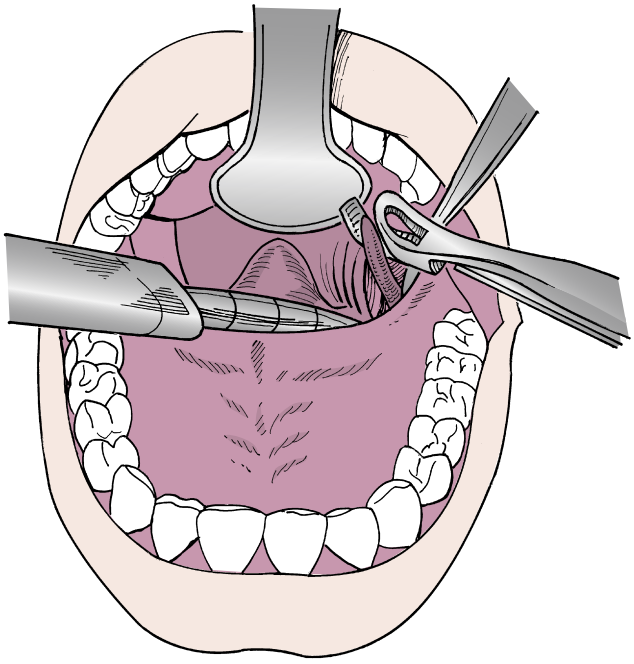

Fig. 38.4. The styloid process removed piecemeal with rongeurs.

- Injury to the glossopharyngeal nerve is possible.
- Incomplete removal of the styloid process may result in the patient's symptoms not being relieved.

Alternative Management Plan

- In patients with atypical presentation, the confirmation of Eagle syndrome is difficult. Medical management with analgesics, antidepressants, or anticonvulsants (gabapentin) may be considered first. Patients with long-standing pain are less likely to have complete resolution of symptoms with surgery.
- A transcervical approach may be used instead of a transoral approach.[3,4]
- Manual fracture of the styloid process without resection is not recommended due to risk of vascular injury.

DISCUSSION

Evidence-Based Medicine Question

What are radiographic correlates of Eagle syndrome?

Eagle's original work considered an elongated styloid to be greater than 3 cm. In asymptomatic individuals, there is a wide range in the length of the styloid process (1.5 to 6.0 cm), and only a small percentage of patients with an elongated styloid process become symptomatic (4% to 10%).

The angulation of the styloid process may also be important. Variable results have been reported with increased anterior and medial angulation in some patient groups compared with controls. Using 3D-CT to make measurements, Kent et al. were unable to demonstrate a difference in styloid angulation but discovered a shorter distance between the tip of the styloid and the tonsillar fossa in patients with Eagle syndrome (12.7 ± 8.2 mm vs. 24.8 ± 4.9 mm).[5] This supports the hypothesis that pain results from compression of the glossopharyngeal nerve. The absolute length or angulation of the styloid process may be less important than its proximity to surrounding soft tissue structures.

Editorial Comment

Although Eagle syndrome is an uncommon problem and a potentially challenging diagnosis, our surgical team has personally made this diagnosis in three patients during the past 5 years. I want to stress the importance of a thorough preoperative evaluation because of the rarity of this diagnosis. Careful counseling of the patient and the setting of realistic expectations is important because of the risk of failure to resolve symptoms after surgery. With respect to my surgical team's vast experience in transoral surgery, in each of the patients that were referred to us, a thorough preoperative evaluation in the manner outlined in this chapter was performed, followed by successful resolution of symptoms after completing the procedure as nicely outlined here. Although I do not believe it is a must, our team has used optical magnification in each of the cases. In our experience in this limited number of patients, we feel that this significantly enhances the surgical view in particular for the identification and then control of both small arteries and veins as the dissection is carried lateral to the tonsillar pillars and constrictor muscles into the parapharyngeal space. With respect to the optical enhancement, we have evaluated both loupes magnification with a headlight or transoral robotic surgery (TORS). Each of these provided good visualization, but we have a preference for TORS, although we may have bias in this regard.

Bert O'Malley, Jr.

Access the review questions and additional sources list online at http://www.expertconsult.com



REFERENCES

1. Eagle WW. Elongated styloid process. Arch Otolaryngol 1937;25:584–587.
2. Rinaldi V, Salvinelli F, Casale M, et al: Eagle syndrome. Medscape, WebMD, LLC, May 6, 2016. <http://emedicine.medscape.com/article/1447247-overview?pa=Og%2BPS6l4z9WQS8xxNFjGLqKqDVnn7trFCpcnTAhOMAB%2FOoU4tCkzcjSSOVd9MK6lvDiUDCzauyeFLwddhCHDQmoJls9WfyZninzoyGTER64%3D>; Accessed 23.10.16.
3. Strauss M, Zohar Y, Laurian N. Elongated styloid process syndrome: intraoral versus external approach for styloid surgery. Laryngoscope 1985;95:976–979.
4. Müderris T, Bercin S, Sevil E, et al. Surgical management of elongated styloid process: intraoral or transcervical? Eur Arch Otorhinolaryngol 2014;271(6):1709–1713.
5. Kent DT, Rath TJ, Snyderman CH. Conventional and 3-dimensional computerized tomography in Eagle's syndrome, glossopharyngeal neuralgia, and asymptomatic controls. Otolaryngol Head Neck Surg 2015;153(1):41–47.

REVIEW QUESTIONS

1. Eagle syndrome is characterized by all of the following except:
   a. Episodic, tic-like pain in the throat
   b. Styloid process greater than 3 cm
   c. Shorter distance between the styloid tip and tonsillar fossa
   d. Palpable styloid process in the tonsillar fossa

2. All of the following are helpful in establishing a diagnosis of Eagle syndrome except:
   a. Three-dimensional computed tomography (3D-CT) scan
   b. Injection of anesthetic into the tonsillar fossa to relieve pain
   c. Palpation of the tonsillar fossa
   d. Facial nerve electroneuronography

3. Contraindications for a transoral approach for Eagle syndrome include all of the following except:
   a. Trismus
   b. Complete calcification of the stylohyoid ligament
   c. Prior tonsillectomy
   d. Symptoms consistent with glossopharyngeal neuralgia

4. Which of the following structures has the least risk of injury with a transoral approach:
   a. Facial nerve
   b. Hypoglossal nerve
   c. Internal carotid artery
   d. Glossopharyngeal nerve

ADDITIONAL SOURCES

Todo T, Alexander M, Stokol C, et al. Eagle syndrome revisited: cerebrovascular complications. Ann Vasc Surg 2012;26:729. e1–e5.

This article emphasizes that individuals with an elongated styloid process may present with cerebrovascular symptoms. Compression of the carotid artery by the styloid may cause ischemic symptoms and cervical manipulation risks injury to the vessel wall with intimal dissection.

39 Transcervical Pharyngotomy

Garret Choby, Eugene N. Myers

INTRODUCTION

The transcervical approach to the oropharynx and hypopharynx provides excellent exposure for the removal of a variety of lesions. The lateral pharyngectomy approach was first described by Cheever in 1878 and was popularized later by Trotter in the UK and Orton in the United States, who added their own modifications. This technique has been used most frequently as an effective approach to early stage squamous cell cancer of the oropharynx and hypopharynx and for tumors of salivary gland origin of the base of the tongue. It has also been used for access to arteriovenous malformations, removal of a complex foreign body, treatment of severe pharyngeal stenosis, and excision of a lingual thyroid.

The suprahyoid pharyngotomy was first described by Vidal de Cassis in 1826, and modifications have been described by several surgeons down through the years. Fairbanks Barbosa, in 1974, included the description of this technique in his classic textbook. This technique is used in situations similar to the lateral pharyngotomy, including the management of benign and malignant tumors of the base of the tongue, hypopharynx, and posterior pharyngeal wall, and excision of lingual thyroid. This technique has been used in our department for many years in the management of T1/T2 squamous cell cancer. It has provided a safe and efficient approach to the oropharynx and provides an excellent cure rate, normal speech, good cosmesis, and swallowing without clinical evidence of aspiration.[1] Similar reports from Moore and Calcaterra[2] regarding the successful use of this technique in the management of T3 lesions of the base of the tongue and by Zeitels[3] for limited lesions of the base of the tongue mirror our own experience.

Both the transhyoid and lateral pharyngotomy techniques offer a means of creating a corridor to the oropharynx and hypopharynx, which provides excellent exposure for the excision of a variety of lesions. It appears that over the years the lateral pharyngotomy approach has been more popular based upon the notion that it provides better exposure. In our own experience, the suprahyoid technique provides excellent exposure through a more direct route with less work involved. When more exposure is necessary, the suprahyoid approach may be extended to include a lateral pharyngotomy.

In the past several decades there has been an evolutionary change in the management of cancers of the oropharynx, largely driven by medical and radiation oncologists. They were inspired by the results of a VA trial for advanced cancer of the larynx, published in the *New England Journal of Medicine* in 1993, which revealed that chemoradiation had a cure rate similar to surgery/radiation.[4] The most appealing aspect of this study was that those patients cured with chemoradiation retained their voice. This nonsurgical approach acquired a new audience in the form of a generally healthier, younger group of patients whose oropharyngeal cancer is caused by human papillomavirus (HPV). They were attracted to chemoradiation as a potential cure for their cancer that did not require external surgery with a tracheotomy, scarring and potential deformity, and decreased functionality. This, of course, resulted in a dramatically reduced market for the classical transcervical pharyngotomy.

More recently the introduction of robotic surgery using the daVinci surgical robot offers a very successful means of excising oropharyngeal cancer with acceptable swallowing results and involving lower doses of adjunctive radiation, if at all.[5] This management scheme also includes neck dissections, since the majority of these patients will have cervical lymph node metastasis. This is an attractive management plan since it provides the patient with a high rate of curability and a low rate of disability in comparison with chemoradiation, which leaves a substantial number of patients with dysphagia and a permanent gastrostomy.

There are many patients in the United States and other countries who have cancer of the oropharynx and do not have access to chemoradiation or robotic surgery. These patients will find that the use of the established surgical techniques of transcervical pharyngotomy will offer them an opportunity for cure without downgrading their form or function.

KEY OPERATIVE LEARNING

1. The transcervical pharyngotomy approach remains a viable option for resection of selected tumors of the oropharynx and hypopharynx.
2. The selection of the surgical approach should be properly tailored to the size, extent, and location of the patient's tumor.
3. A thorough examination of the head and neck, along with evaluation and palpation of the tumor under anesthesia, is essential for proper patient selection.
4. Care must be taken to avoid injury to the hypoglossal nerves (suprahyoid pharyngotomy approach) and superior laryngeal nerve (lateral pharyngotomy approach) to limit postoperative morbidity.
5. Aspiration in the immediate postoperative period is predictable and may adversely affect outcomes in the patient with severe chronic obstructive pulmonary disease (COPD).
6. A pharyngocutaneous fistula that fails to close with conservative management may require a tissue flap for reconstruction.

PREOPERATIVE PERIOD

History

1. History of present illness
   a. Primary symptoms
      1) Pain
      2) Dysphagia
      3) Odynophagia
         a) May suggest invasion of deeper planes of the oropharynx
      4) Otalgia
      5) Weight loss
      6) Hemoptysis
      7) Mass in the neck
      8) Trismus
      9) Dysarthria (hot potato voice)
         a) May suggest invasion of muscles of mastication or a bulky tumor
   b. Duration of symptoms

c. Previous assessment
   1) Biopsy
      a) All outside pathology slides should be reviewed at your own institution, especially if human papillomavirus (HPV) testing has not been completed.
   2) Imaging—All prior imaging studies should be reviewed at your own institution.
      a) CT
      b) MRI
      c) PET/CT
2. Past medical history
   a. Comorbidities
      1) General medical history
         a) Previous history of cancer of the head and neck
      2) Cardiovascular disease
         a) Patients requiring long-term anticoagulation due to cardiac or thromboembolic history may be at increased risk for bleeding in the postoperative period.
         b) Preoperative evaluation by a cardiologist is warranted in select patients with a known cardiac history.
      3) Pulmonary disease
         a) Many patients with cancer of the head and neck have a significant smoking history and usually have concomitant COPD.
         b) Temporary aspiration is a predictable postoperative occurrence. Patients who cannot tolerate this due to impaired pulmonary function may be considered for laryngotracheal separation or laryngectomy to prevent life-threatening aspiration.
   b. Social history
      1) Tobacco use
         a) Most patients in the older age group have a significant history of heavy smoking. These patients may undergo withdrawal symptoms similar to delirium tremens.
      2) Alcohol abuse
         a) Alcohol withdrawal is associated with increased perioperative morbidity in patients undergoing surgery of the head and neck, including increased risk of delirium tremens, aspiration, ventilator dependence, and death.
         b) If heavy alcohol use is admitted or suspected preoperatively, consideration should be given to preoperative admission to the hospital or detoxification center to allow detoxification to take place prior to surgery.
      3) Information regarding sexual activities should be elicited as part of a thorough history in those patients with an HPV etiology, since this is thought to be a sexually transmitted disease.
   c. Medications
      1) Anticoagulants/Aspirin/NSAIDs
      2) Supplements that can increase the risk of bleeding

Physical Examination

1. Examination of the head and neck
   a. Direct and indirect visualization of the oral cavity to assess for trismus, examination of the base of the tongue, larynx, and pharynx is essential. It is also important to evaluate the lateral and posterior extent and bulk of the mass as well as involvement of adjacent structures.
      - Indirect mirror laryngoscopy
      - Flexible or rigid fiberoptic pharyngolaryngoscopy
   b. Direct laryngoscopy under anesthesia is the most important examination to evaluate tumor extent and infiltration.
   c. Bimanual palpation of tumors at the base of the tongue is essential to most accurately assess the extent of the disease and differentiate the tumor from the lingual tonsils.
      - Palpation also assists in determining the mobility of the tumor and invasion of underlying and adjacent tissues.
   d. Pay special attention to palpation for cervical lymphadenopathy.

Imaging

1. CT scan
   a. CT scan of the head and neck helps delineate the extent of the primary lesion and is especially helpful in evaluating bony anatomy, such as invasion of the cortex of the mandible.
   b. Excellent in determining suspicious cervical lymphadenopathy
   c. May also be used to screen the chest for metastatic cancer
2. MRI
   a. MRI is able to better define the extent of soft tissue invasion of the cancer into the deep musculature of the tongue or prevertebral tissues.
   b. Drawbacks to MRI include increased cost, longer time of the examination, and potential patient intolerance due to claustrophobia.
   c. The inability of the pharynx to elevate during deglutition suggests invasion of the prevertebral fascia in patients with cancer of the posterior pharyngeal wall.
3. PET/CT
   a. Valuable study to evaluate the primary cancer and to evaluate for the presence of metastatic cancer
4. Barium esophagram
   a. This study may be used in cases of cancer of the posterior pharyngeal wall in which invasion of the prevertebral fascia is suspected.
   b. Limited laryngeal elevation during the bariumm esophagram may suggest invasion of the prevertebral fascia

Indications

1. Suprahyoid pharyngotomy approach
   a. Early stage cancer of the base of the tongue (T1/T2)
      1) Ideally, these cancers should be limited to the base of the tongue, posterior to the circumvallate papillae.
      2) May be combined with the lateral pharyngotomy approach for cancers involving the lateral pharyngeal wall or tonsil
      3) Usually combined with neck dissection
   b. Excision of cancer of the posterior wall of the oropharynx or hypopharynx
   c. May be used without neck dissection for benign lesions or low-grade cancers of salivary gland origin
   d. Useful for excision of a lingual thyroid
2. Lateral pharyngotomy approach
   a. Benign and malignant tumors arising from the lateral and posterior walls of the oropharynx or hypopharynx, postcricoid area, or base of the tongue (with involvement of the tonsil or lateral wall of the oropharynx)
      1) Depending on the extent and location of tumor, many of these lesions may also be amenable to endoscopic approaches, pending the availability of technology and equipment.

Contraindications

1. Suprahyoid pharyngotomy approach
   a. Cancer of the vallecula that involves the lingual surface of the epiglottis

1) Excision of the epiglottis may lead to considerable postoperative complications with delayed deglutition and chronic aspiration.
b. Cancer of the base of the tongue that extensively involves the tonsil or lateral pharyngeal wall
c. Cancer involving the tongue anterior to the circumvallate papillae
1) Cancers with this anterior extent are difficult to close primarily, may compromise the anterior surgical margin, and result in disability in swallowing.
d. Patients with decreased pulmonary function who would not tolerate aspiration in the immediate postoperative period

2. Lateral pharyngotomy approach
a. Patients with cancer that involves more than one-third of the pharyngeal circumference
b. Patients with cancer who would be better suited for suprahyoid or total laryngectomy due to comorbidities
c. Patients with decreased pulmonary function who would not tolerate aspiration in the immediate postoperative period

Preoperative Preparation

1. Imaging studies and any studies from previous biopsies or surgical procedures done elsewhere should be obtained and reviewed during surgical planning.
2. Patients who have not had a biopsy should undergo a direct laryngoscopy, biopsy of the tumor, and esophagoscopy.
3. Surgery for those patients with nutritional depletion should be delayed to bring the patient into positive nitrogen balance.
4. Patients should be seen by medical consultants and cleared for surgery.
5. Patients should stop taking aspirin, nonsteroidal anti-inflammatories, other anticoagulants, and supplements at least 7 days preoperatively. If there is a history of bleeding with prior surgery or trauma, then a coagulation profile is obtained.
6. Preoperatively, patients are counseled regarding the procedure, risks, and complications. The informed consent should be detailed and include the following risks: infection, bleeding, need for prolonged tracheostomy, dysphagia, aspiration, wound breakdown, and salivary fistula.

OPERATIVE PERIOD

Anesthesia

1. Transcervical pharyngotomy is always carried out under general anesthesia.
2. Tracheostomy is generally performed as the first step in the surgery to secure the airway and to keep the endotracheal tube out of the operative field.
a. Close communication with the anesthesia team during this portion of the surgery is critical to ensure a smooth transition in airway management.
b. The technique for open tracheostomy is described in Chapter 78.
3. Many surgeons prefer to avoid long-acting paralytic agents during the surgery, especially during dissection along cranial nerves. This need should be communicated to the anesthesia team prior to the outset of surgery.

Positioning

1. The patient is positioned supine on the operating table.
2. A shoulder roll is helpful in extending the neck during tracheostomy, pharyngotomy, and neck dissection.
3. Intermittent pneumatic compression devices should be applied to the lower legs to prevent formation of deep vein thromboses.

Perioperative Medications

1. Standard perioperative antibiotics should be administered intravenously prior to incision.
a. Contamination of the neck by the upper aerodigestive tract is expected during the operation; therefore, we typically administer ampicillin-sulbactam or clindamycin if the patient is allergic to penicillin.

Monitoring

1. Standard hemodynamic monitoring is required by anesthesia during surgery.
2. A Foley catheter should be inserted to monitor fluid dynamics and a rectal thermometer inserted to track the patient's temperature.
3. Although no nerve monitoring devices are typically used, many surgeons prefer the ability to directly stimulate nerves during the surgery. Therefore, long-acting paralytic agents are to be avoided.

Instruments and Equipment to Have Available

1. Laryngoscopy and esophagoscopy sets
2. Standard tracheostomy set with cannulas
3. Standard neck dissection set

Key Anatomic Landmarks

1. Suprahyoid pharyngotomy:
- Hyoid bone
- Vallecula
- Epiglottis
- Hypoglossal nerves
- Lingual arteries

2. Lateral pharyngotomy:
- Thyroid cartilage
- Carotid sheath
- Pharyngeal constrictor muscles
- Superior laryngeal nerve
- Hypoglossal nerve

Prerequisite Skills

1. Experience with neck dissection
2. Experience with airway management
3. Familiarity with the anatomy of the larynx and pharynx

Operative Risks

1. Bleeding
2. Infection
3. Dysphagia
4. Aspiration
5. Formation of a salivary fistula
6. Need for long-term tracheostomy

Surgical Technique

Suprahyoid Pharyngotomy

- Suprahyoid technique
  - A tracheostomy is carried out under endotracheal anesthesia; the endotracheal tube is removed and placed in the tracheostoma.

- The neck and face are prepped and draped, with the face and both sides of the neck exposed.
- In cases of squamous cell cancer, an apron flap incorporating the tracheostomy incision is elevated and bilateral neck dissections are carried out.
- Damp sponges are applied to the raw surface of the cervical flap, which is fixed to the drapes.
- The hyoid bone is identified and grasped with a tenaculum and brought into the wound. The suprahyoid muscles are sharply separated from the entire extent of the hyoid bone using electrocautery. As the dissection around the greater cornu is begun, the cornu is stabilized with the finger loop end of a hemostat, with traction exerted medially. This maneuver protects the hypoglossal nerve from injury. Dissection is completed medially along the cornu until the body of the hyoid bone is reached. The same procedure is carried out on the contralateral side.
- The suprahyoid musculature is retracted superiorly, revealing the hypoepiglottic ligament, which is transected.
- The mucosa of the vallecula is completely elevated off of the lingual surface of the epiglottis as far as its tip. This provides an additional margin of resection in the vallecula.
- An incision through the mucosa 1 to 2 mm superior to the tip of the epiglottis enables entrance into the pharynx (Fig. 39.1).
- A broad right-angled retractor is inserted into the pharynx superior to the base of the tongue. The base of the tongue is grasped with a tenaculum. Downward traction is exerted on the tenaculum and the base of the tongue drawn into the wound to provide tension on the mucosa to complete the pharngotomy incisions.
- The hypoglossal nerves and the lingual arteries are identified and mobilized using sharp and blunt dissection. Vessel loops are placed around these structures to aid in identification and retraction of these structures (Fig. 39.1).
- The tumor is identified and the resection margins marked with methylene blue (Fig. 39.2).
- Prior to excising the tumor, a black silk suture is placed into the anterior margin of resection in order to orient the specimen for the pathologist.
- The lesion is then excised using electrocautery to prevent blood obscuring these incisions. If the cancer extends into the tonsil fossa, the mucosal incision can be extended in order to adequately excise the tumor.
- After removing the tumor and obtaining clear surgical margins with frozen section control, a nasogastric tube is placed and stabilized by placing a black silk suture into the angle between the upper lip and columella.
- A primary multilayer closure of muscle and mucosa is carried out (Fig. 39.3). In our series it has not been necessary to use a skin graft, regional, or vascularized flap.
- Copious irrigation of the wound is carried out, followed by the insertion of suction drains.
- As part of the closure of the skin flaps, the subcutaneous tissue must be sutured to the strap muscles in order to isolate the stoma from the neck wound to prevent contamination of the cervical wound when the patient coughs.
- The endotracheal tube is removed from the tracheostoma, and the tracheostomy tube is inserted. The breastplate of the tracheostomy tube is sutured to the skin of the tracheostoma to prevent dislodgement.

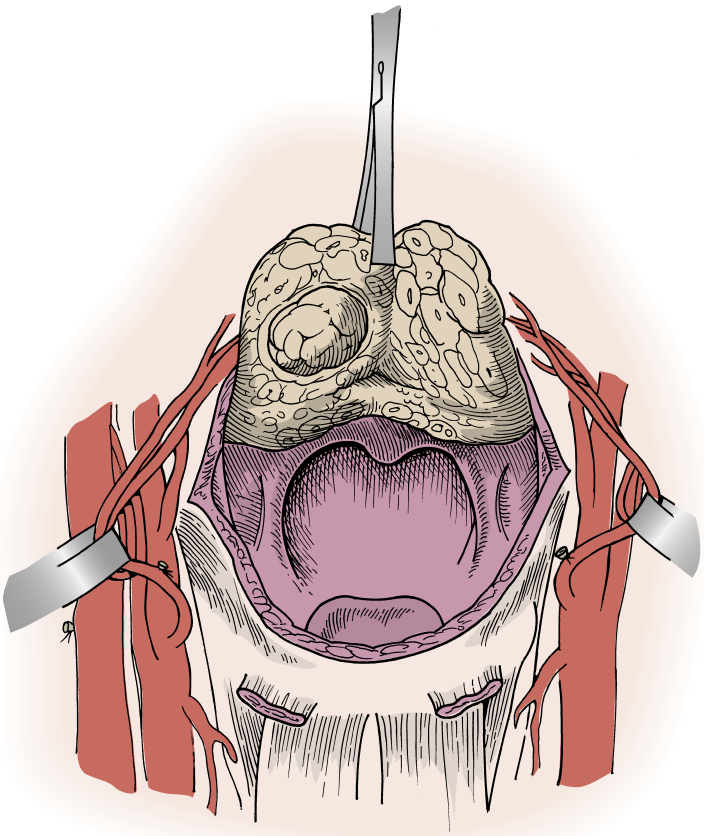

Fig. 39.1. Excellent exposure of tumors limited to the base of the tongue is achieved with this technique.

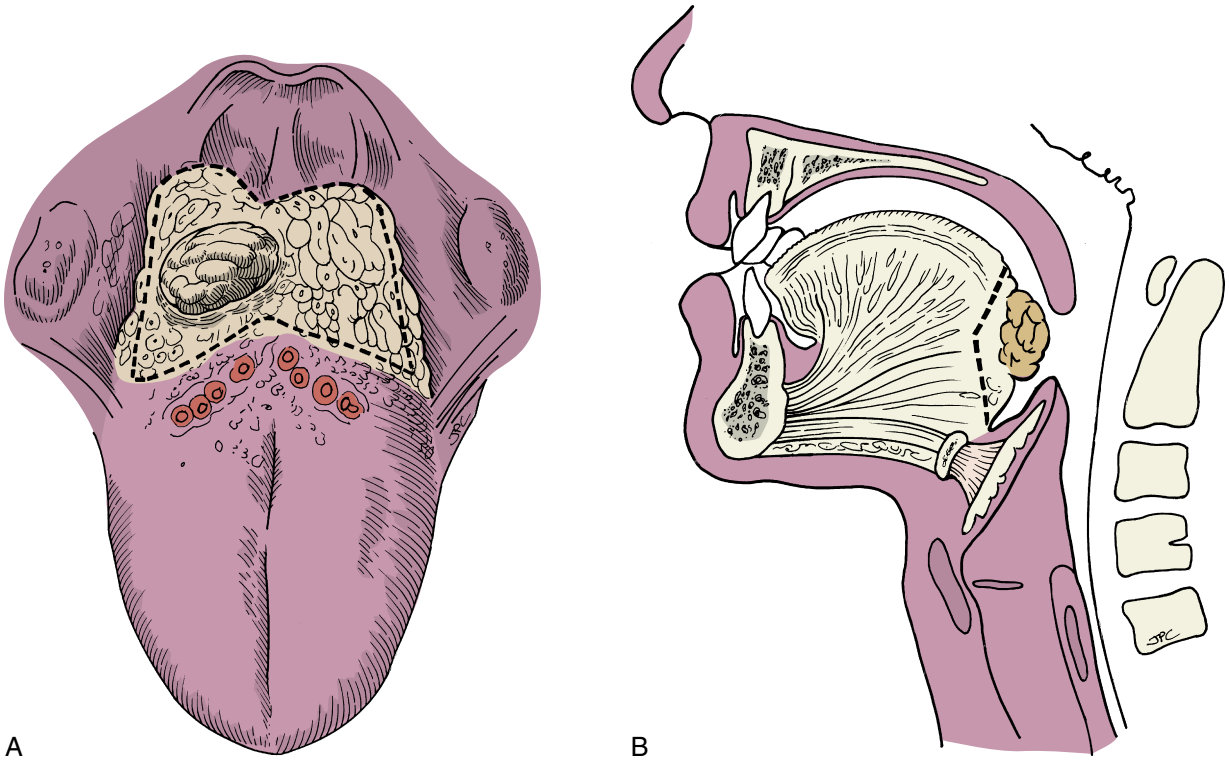

Fig. 39.2. **(A)** Schematic drawing demonstrating the tissue to be excised. **(B)** Lateral schematic drawing of the area to be excised.

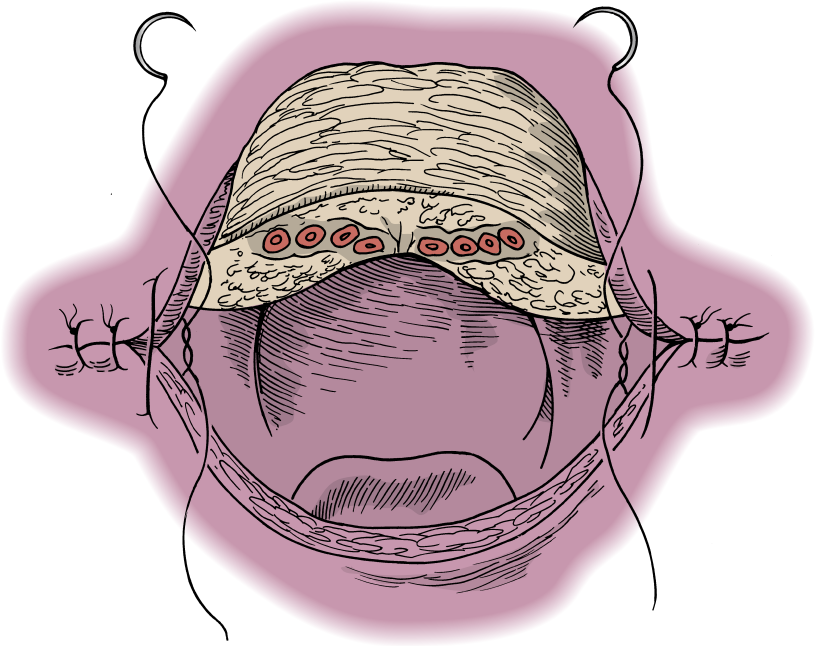

Fig. 39.3. The defect can be closed primarily.

Posterior Pharyngeal Wall

- After the pharyngotomy is completed, the cancer of the posterior pharyngeal wall is identified. The surgical margins are marked with methylene blue, and an incision is made in the superior aspect of the incision line. A black silk suture is inserted in the superior aspect of the specimen to orient the pathologist. The cancer is then excised, including the underlying constrictor muscles, as a deep margin of resection. Hemostasis is obtained with electrocautery, while clearance of the surgical margin is obtained using frozen section control (Fig. 39.4).
- Since primary closure is not possible, the application of a split thickness skin graft or dermal graft sewn to the prevertebral fascia provides rapid resurfacing of the wound; however, these grafts must be immobilized by a gauze bolus, requiring a return to the operating room and another general anesthesia to remove the bolus.

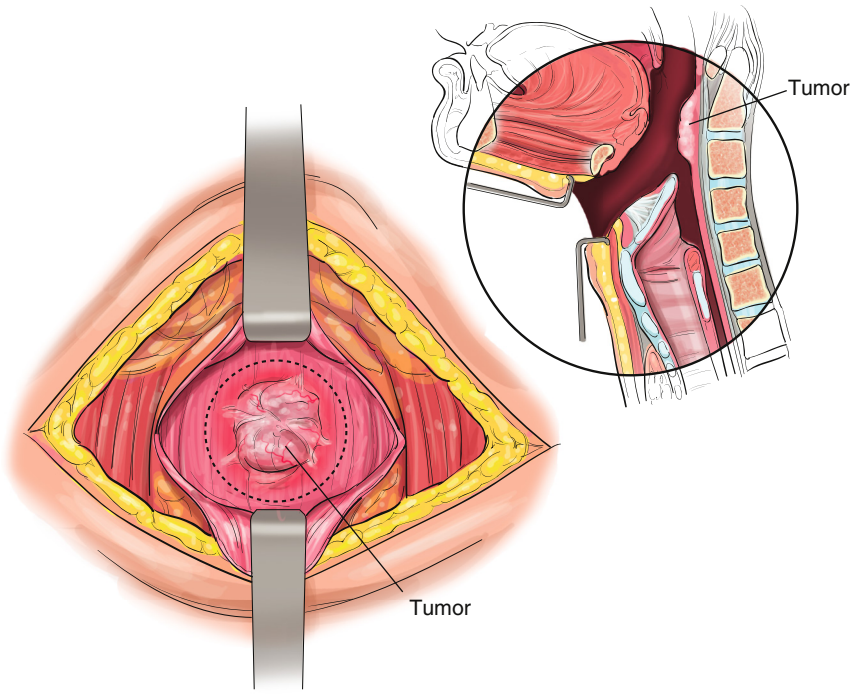

Fig. 39.4. The position of the tumor and line of excision.

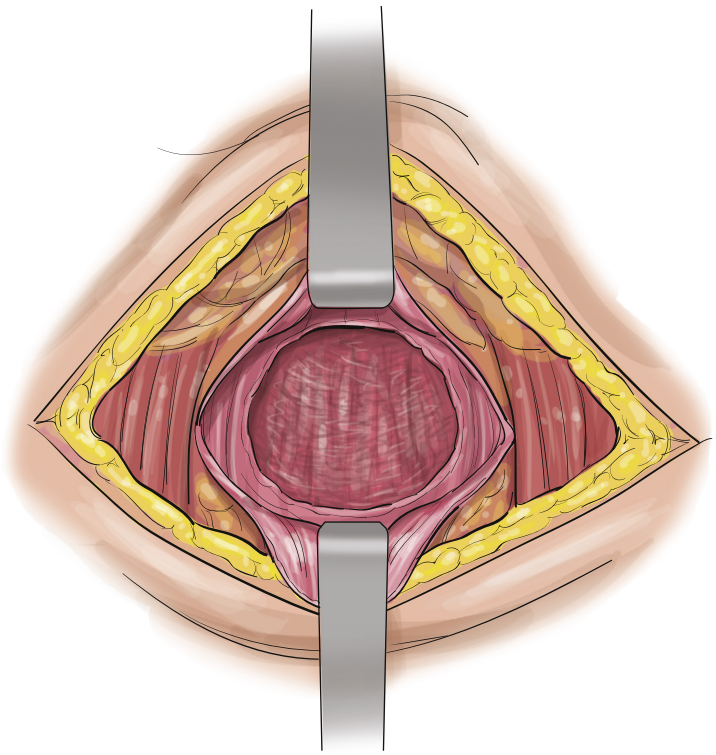

Fig. 39.5. Appearance of the wound after excision of the cancer.

- We have found that instead of using a skin graft, simply sewing the mucosal edges of the defect to the prevertebral fascia results in healing by second intent and rapid re-epithelization of the wound (Fig. 39.5).

Lateral Pharyngotomy

- Tracheotomy and neck dissections are carried out as described previously.
- The sternocleidomastoid muscle is retracted to expose the carotid sheath.
- The carotid sheath and its contents are retracted laterally in order to allow identification of the inferior constrictor muscle as well as the superior pole of the thyroid gland and its vascular pedicle.
- A double-pronged retractor is placed in the posterior edge of the thyroid ala, and the inferior constrictor muscle is incised along the length of the thyroid cartilage. Blunt dissection of the muscle off of the cartilage exposes the mucosa of the piriform sinus (Fig. 39.6).
- Dissection is carried superiorly to identify the origin of the superior thyroid and superior laryngeal artery.

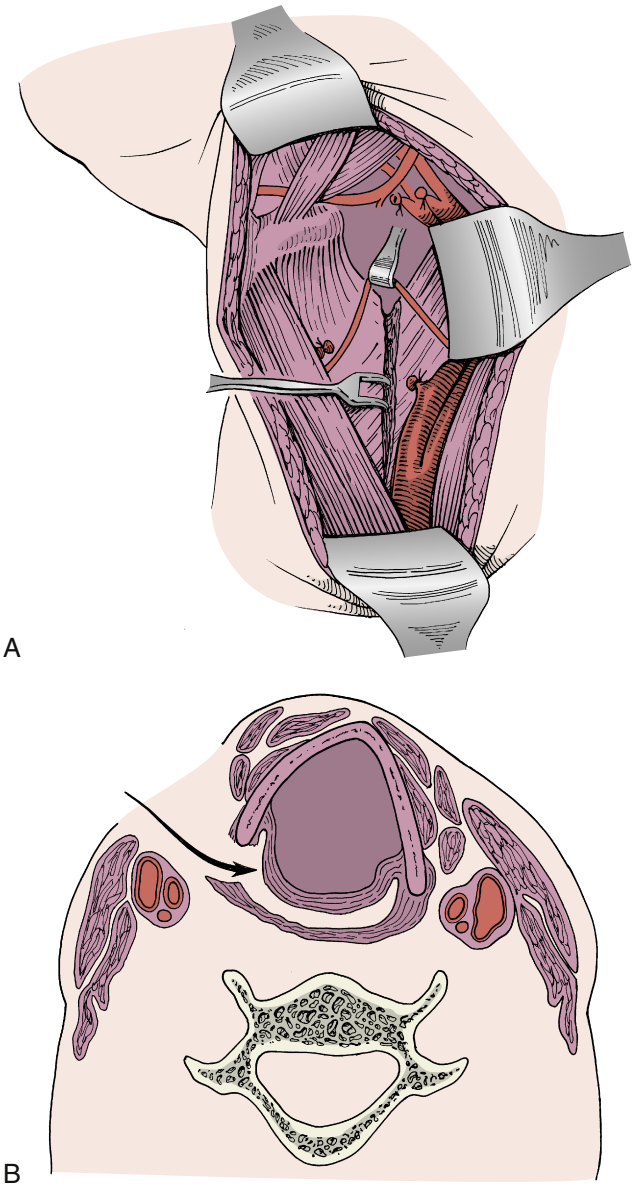

Fig. 39.6. (A) The superior laryngeal nerve is retracted upward and an inferior constrictor myotomy is performed to expose the mucosa of the piriform sinus and the lateral hypopharynx. **(B)** Axial view showing the surgical route *(arrow)* after myotomy.

- Retraction of the carotid bulb allows identification of the superior laryngeal nerve.
- The posterior belly of the digastric muscle is retracted.
- The hypoglossal nerve is identified cephalad to the superior laryngeal nerve as it enters into the submandibular triangle.
- Lesions of the oropharynx require a higher lateral pharyngotomy than lesions of the hypopharynx. The lateral pharyngotomy can be extended superiorly to the nasopharynx or inferiorly to expose the hypopharynx.
- To enter the oropharynx, the incision is best carried out by placing the index finger along the base of the tongue, inferior and posterior to the tonsillar fossa, and away from the tumor.
- The finger tenses the mucosa, thereby facilitating performance of the pharyngotomy, and ensures that the incision is not carried through the tumor.

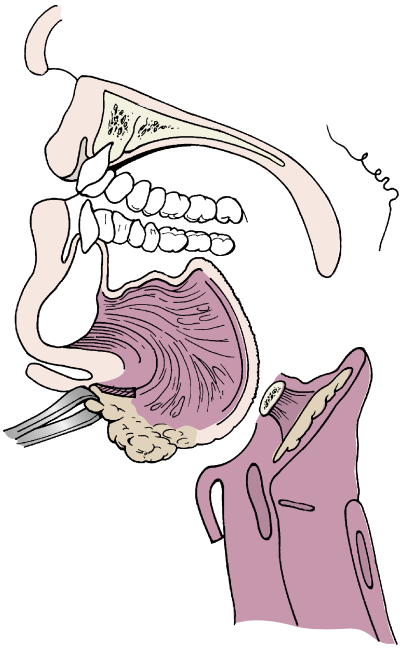

Fig. 39.7. The lesion of the base of the tongue exposed through a lateral pharyngotomy.

- The pharyngotomy is opened with sharp instruments or electrocautery as the surgeon and his assistant keep the mucosa under tension.
- Lesions located in the superior aspect of the hypopharynx may require inferior extension of the pharyngotomy.
- The tumor is then identified and excised, marking the specimen prior to excision to ensure proper orientation of surgical margins (Fig. 39.7).
- The wound is closed primarily as described for transhyoid pharyngotomy once assurance of clear surgical margins is obtained.

Common Errors in Technique

1. Injury to the hypoglossal nerves and lingual arteries may occur.
2. Injury to the superior laryngeal nerve may also occur.
3. Underestimating the extent of the tumor may lead to positive surgical margins and inability to perform a primary closure.
4. Lack of frozen section control may lead to positive margins.

POSTOPERATIVE PERIOD

Postoperative Management

1. Patients at our institution are transferred to a dedicated head and neck unit and do not require admission to the intensive care unit.
   a. The head of the bed is elevated to 30 degrees to diminish edema in the wound and to decrease the risk of gastropharyngeal reflux.
   b. Proton pump inhibitors may also be given intravenously to decrease the acidity of any gastropharyngeal reflux.
   c. Broad spectrum prophylactic perioperative antibiotics are continued for 24 hours postoperatively.
   d. Suction drains are maintained to gentle suction and remain in place until the output is less than 20 mL in 24 hours.

e. Patients receive routine postoperative tracheostomy care (Chapter 78) and care of the neck dissection wound (Chapter 87).
f. Patients are fed via nasogastric tube for 7 to 10 days postoperatively.

2. In most instances, decannulation is achieved prior to removal of the nasogastric tube and initiation of oral feeding by downsizing to an uncuffed tube, which is plugged and removed when normal swallowing without aspiration takes place.
   a. A speech language pathologist (SLP) trained in evaluating and managing patients with head and neck cancer postoperatively is vital in initiating postoperative oral feeding.
   b. The SLP evaluates and instructs the patient on swallowing strategies.
   c. When indicated, a fiberoptic endoscopic examination of swallowing (FEES) or modified barium swallow (MBS) may be used to better evaluate the swallowing function.

Complications

1. Wound infection
   a. Any sign of erythema of the skin or purulent exudate in the drains should be noted, and appropriate antibiotics should be administered.
   b. If the suction drains remain in place, the wound does not necessarily need to be opened unless an abscess has formed.
   c. If the drains have been previously removed, the wound should be opened in a manner that promotes external drainage.
2. Pharyngocutaneous fistula
   a. The surgeon should maintain a high degree of suspicion of fistula formation if the output in the suction drains appears purulent or saliva-like. The appearance of edema, erythema, and drainage may also be suggestive of a fistula.
      1) Although most fistulas should be diagnosed clinically, the presence of a high level of amylase in the drain output confirms a salivary fistula.
   b. The majority of salivary fistulas will heal with conservative management. Perhaps the most important aspect of managing a fistula is diverting the saliva away from the carotid arteries and out of the wound. This may be accomplished with maintenance of the suction drains or packing.
   c. If the fistula does not resolve with conservative management, other contributing factors should be investigated, including persistent cancer, tension on the mucosal closure, malnutrition, epithelialization, foreign body, or inadequate blood supply from previous surgery or radiation.
      1) If none of these factors exist, it may be necessary for the patient to undergo a more complex reconstructive procedure such as pectoralis major myocutaneous flap (Chapter 174) or microvascular free flap (Chapter 169).
3. Aspiration
   a. Postoperative initiation of swallowing should be instituted under the supervision of a well-trained SLP, as noted previously.
   b. Aspiration events can lead to pneumonia or aspiration pneumonitis, potentially requiring ventilator assistance.

Alternative Management Plan

1. Nonsurgical management
   a. Depending on the tumor type, location, and extent, nonsurgical therapy may be an acceptable alternative to surgery. The National Comprehensive Cancer Network (NCCN) outlines treatment options for patients with cancer of the head and neck. Radiation therapy or a combination of chemotherapy and radiation therapy may be an option.
2. Robotic surgery
   a. Transoral robotic surgery (TORS) has been gaining in popularity since its introduction in 2004. In properly selected patients with limited disease, TORS has proved to be a safe and effective method of surgical resection, potentially sparing patients the need for radiation therapy. TORS offers acceptable short- and long-term quality of life outcomes and may help avoid the long-term morbidity of primary chemoradiotherapy.[5,6] An effective TORS program requires significant monetary investment and advanced surgical training and is therefore not available in all situations.
3. Palliative care
   a. The patient's age, medical comorbidities, and wishes play a vital role in treatment decisions. Palliative care is an option for patients who do not wish to pursue curative therapy or whose age and medical status may preclude curative options.
   b. At our institution, a supportive palliative care specialist is a vital member of our tumor board discussion team, as well as the inpatient and outpatient treatment team.
      1) He or she offers insight into symptom management (e.g., pain, thirst, xerostomia) and end-of-life decision making such as hospice care.

DISCUSSION

Evidence-Based Medicine Question

What is the evidence supporting suprahyoid pharyngotomy for squamous cell carcinoma of the base of the tongue?

The suprahyoid pharyngotomy approach has historically been criticized for providing perceived limited exposure of the tumor and the belief that violating the pre-epiglottic space may increase the risk of tumor seeding. A retrospective study was published at our institution of 13 patients who presented with T1 or T2 squamous cell carcinoma of the base of the tongue who underwent a suprahyoid pharyngotomy approach with neck dissection. Adjuvant therapy was provided according to NCCN guidelines. At the time of the publication, all patients remained cancer free without regional or local recurrence.[1] The transcervical pharyngotomy approach remains an important technique for the head and neck surgeon to address pathology, especially when more advanced technologies such as surgical robots and lasers may not be readily available.

Editorial Comment

Until recently squamous cell carcinoma of the oropharynx was almost exclusively a disease of males (with a male-to-female ratio of 2.5:1); it is alcohol and tobacco driven with a peak incidence between 55 and 75 years. The combination of tobacco and alcohol also gives rise to significant comorbidities, especially COPD.[7] Tobacco use is on the rise in low-income countries and in many middle-income countries, especially among those countries in which large numbers of the population live in poverty. This addiction causes many very poor families to spend substantial amounts on tobacco, leaving less for food, health, and education, which results in malnutrition.[8] Research shows that individuals who avoid smoking in adolescence or young adulthood are unlikely to become smokers.[8] The risk of surgical complications was studied in a cohort of 100 consecutive patients, with cancer of the head and neck undergoing extensive

ablative and reconstructive surgery.[7] In this study, 83% of the patients had some form of comorbidity and the majority of cases were cardiovascular, respiratory, or previous coexistent morbidity. Patients with advanced comorbidity developed a clinically important complication in 55% of cases. Naturally there is an association between complications and duration of hospital stay and its associated costs. Many of these complications were swallowing problems, usually due to COPD. The inclusion of swallowing therapists to the head and neck team has proved to be invaluable in mitigating this problem and preserving this aspect of the quality of life for this group of patients.

In recent decades this pattern has changed, driven by a decrease in numbers of smokers—at least in the United States—and a near epidemic of HPV-related squamous cell cancer of the oropharynx. The victims of this newly found cancer tend to be much younger, healthier nonsmoker/drinkers and are more curable, even with nonsurgical treatments.[9]

Based on the VA study in 1991 in which chemotherapeutic Cisplatin/5FU combined with radiation therapy was successful in being curative and preserving the voice in 67% of study patients with advanced cancer of the larynx,[4] this treatment was adapted for cancer of the oropharynx. Those in the younger nonsmoker group tended to have a far better cure rate than the older smoker and alcohol-using group. However, many of the cured had a poor quality of life due to swallowing difficulties caused by pharyngeal strictures requiring a permanent gastric feeding tube.

The TORS procedure, which uses the daVinci robot to successfully excise tumors of the base of the tongue, also reduced the number of patients who had previously been treated by transcervical pharyngotomy.[5] In the United States and Western Europe where these surgical robots are available, transcervical pharyngotomy for squamous cell carcinoma is rarely performed as a primary procedure. This of course impacts our ability to teach this procedure, which may still be useful for benign and malignant tumors of the base of the tongue and for limited cancers of the posterior wall of the pharynx.[10] In countries in which patients do not have access to modern chemotherapy and radiation units are scarce, transcervical pharyngotomy still plays an important role in the treatment of oropharyngeal neoplasms.

Bert O'Malley, Jr.

Access the review questions and additional sources list online at http://www.expertconsult.com

REFERENCES

1. Weber PC, Johnson JT, Myers EN. The suprahyoid approach for squamous cell carcinoma of the base of the tongue. Laryngoscope 1992;102(6):637–640.
2. Moore DM, Calcaterra TC. Cancer of the tongue base treated by a transpharyngeal approach. Ann Otol Rhinol Laryngol 1990;99:300–303.
3. Zeitels SM, Vaughn CW, Ruh S. Suprahyoid pharyngotomy for oropharynx cancer including the tonge base. Arch Otolaryngol Head Neck Surg 1991;117:757–60.
4. The VA Laryngeal Study Group. Induction chemotherapy plus radiation compared with surgery plus radiation in patients with advanced laryngeal cancer. N Engl J Med 1991;324:1685–1690.
5. O'Malley BW, Weinstein GS, Snyder W, et al. Transoral robotic surgery for base of tongue neoplasms. Laryngoscope 2006;116(8):1465–1472.
6. Choby GW, Kim J, Ling DC, et al. Transoral robotic surgery alone for oropharyngeal cancer: quality of life outcomes. Otolaryngol head Neck Surg 2015;141(6):499–504.
7. Borggreven PA. Surgical Treatment with Microvascular Reconstruction of Oral and Oropharyngeal Cancer. Amsterdam: Ponsen and Looyen; 2005. p. 10.
8. Esson KM, Leeder SR. The Millennium Development Goals and Tobacco Control. France: World Health Organization; 2004.
9. Maxwell JH, Grandis JG, Ferris RL. HPV-associated head and neck cancer: unique features of epidemiology and clinical management. Ann Rev Med 2016;14(67):91–101.
10. Gross ND, Holsinger FC, Magnuson JS, et al. Robotics in otolaryngology and head and neck surgery: a report of the 2015 AHNS education committee. AAO-HNS robotic task force and AAO-HNS sleep disorders committee. Head Neck 2016;38(Suppl. 1): E151–8.

REVIEW QUESTIONS

1. The suprahyoid pharyngotomy approach is ideal for all of the following tumors, except
   a. T1/T2 squamous cell carcinoma of the base of tongue
   b. Early stage tumors of the posterior oropharyngeal wall
   c. Early stage salivary gland tumors of the base of the tongue
   d. Tumors of the base of the tongue involving the lateral pharyngeal wall

2. All oropharyngeal squamous cell carcinoma biopsy specimens should routinely be tested for
   a. HPV
   b. EBV
   c. HHV-8
   d. HIV

3. What portion of the physical examination is most critical to assess for tumor extent?
   a. Flexible fiberoptic pharyngolaryngoscopy
   b. Palpation
   c. Examination of the cranial nerves
   d. Palpation of the neck

4. Barium esophagram can be a helpful adjunctive imaging study in cases of suspected
   a. Metastasis to cervical lymph nodes
   b. Invasion of the prevertebral fascia
   c. Deep invasion of the base of tongue musculature
   d. Lateral pharyngeal wall tumor involvement

5. If a salivary fistula is nonhealing, which of the following should be suspected as underlying causes:
   a. Persistent tumor
   b. History of radiation
   c. Foreign body
   d. Epithelialization
   e. All of the above

ADDITIONAL SOURCES

Carrau RL, Soose R. Lateral pharyngotomy. In: Myers EN, editor. Operative Otolaryngology – Head and Neck Surgery. Philadelphia, PA: Saunders; 1997. p. 247–251.

Ferris RL. Suprahyoid pharyngotomy. In: Ferris RL, editor. Master Techniques in Otolaryngology – Head and Neck Surgery, vol. 6. Philadelphia, PA: Wolters Kluwer/Lippincott Williams and Wilkins; 2014. p. 73–79.

Kraus DH. Transcervical pharyngotomy. In: Ferris RL, editor. Master Techniques in Otolaryngology – Head and Neck Surgery, vol. 1. Philadelphia, PA: Wolters Kluwer/Lippincott Williams and Wilkins; 2014. p. 81–89.

Martin H. Surgery of Head and Neck Tumors. 4th printing. New York: Hoeber—Harper; 1964. p. 143–4. 391–395.

Myers EN. Suprahyoid pharyngotomy. In: Myers EN, editor. Operative Otolaryngology – Head and Neck Surgery. 2nd ed. Philadelphia, PA: Saunders; 1997. p. 229–234.

40 Pharyngectomy

Jessica H. Maxwell, Seungwon Kim

INTRODUCTION

A hollow viscus located immediately posterior to the larynx, the hypopharynx is related to the oral pharynx superiorly and the cervical esophagus inferiorly. It is divided into three anatomic sites: the pyriform sinuses (bilateral), the postcricoid mucosa, and the posterior pharyngeal wall. The postcricoid mucosa is the mucosa lying on the posterior aspect of the cricoid cartilage, which is also the anterior wall of the hypopharynx. The hypopharynx plays an important role in deglutition, as well as respiration. Coordinated activity in this laryngopharyngeal segment is essential for swallowing and protecting the airway from aspiration.

Squamous cell carcinoma of the hypopharynx accounts for only 3% to 5% of all head and neck squamous cell carcinomas.[1] Development of carcinoma of the hypopharynx is closely associated with the use of both tobacco and alcohol products.[2,3] Cancer of the hypopharynx has a dismal prognosis with the majority of patients initially diagnosed with stage IV cancer.[2,4] Treatment is dependent on the stage at presentation and often involves a combination of surgery, radiation, and chemotherapy.[5,6] Unfortunately, recurrence rates are high, approaching 50%, demonstrating the difficult task faced by head and neck surgeons in managing cancer of this unique subsite.[1]

KEY OPERATIVE LEARNING POINTS

1. Squamous cell carcinoma of the hypopharynx has a propensity for regional metastases, and the majority of patients are diagnosed with stage IV cancer.
2. The standard approach to treatment of cancer of the hypopharynx is either partial or total pharyngectomy, often combined with total laryngectomy, followed by adjuvant chemoradiation.
3. Involvement of the prevertebral fascia and/or the common carotid artery is considered to be inoperable.

PREOPERATIVE PERIOD

History

1. History of present illness
   a. Common presenting signs and symptoms include dysphagia, odynophagia, referred otalgia, and a mass in the neck.
      1) The duration, severity, and quality of these symptoms should be elicited.
      2) Choking or coughing with meals may indicate aspiration.
   b. Hoarseness or stridor suggests laryngeal involvement.
2. Past medical and surgical history
   a. A thorough past medical history should be obtained, including the patient's pulmonary function and cardiac history.
   b. Has the patient been diagnosed with cancer of the head and neck in the past or previously been treated with radiation therapy?
   c. Is there a history of immunosuppression?
3. Family history of cancer of the head and neck cancer or blood dyscrasias should be obtained.
4. Medications
   a. A full list of medications should be obtained, including the use of anticoagulants, antiplatelets, or herbal products.
5. Social history
   a. Determine the patient's smoking and alcohol history, as these are the most common risk factors for hypopharyngeal cancer.[3]
   b. Current alcohol use places the patient at risk for postoperative alcohol withdrawal.

Physical Examination

1. Vital signs
   a. Basic vital signs, including oxygen saturation and body mass index (BMI)
2. Examination of the head and neck
   a. Ears
      1) Referred otalgia is common with cancer of the hypopharynx.
   b. Oral cavity/oropharynx
      1) A thorough examination of the oral cavity and oropharynx is important to rule out synchronous primary cancers in these patients who typically have a history of heavy tobacco and alcohol consumption.
      2) Dental evaluation is important for pretreatment planning. Patients with poor dentition may need to have dental extractions prior to radiation therapy preferably at the time of surgery.
   c. Neck
      1) Lymphatic drainage of the hypopharynx is directed toward the superior deep cervical lymph nodes (zones II and III); however, some cancers of the hypopharynx may drain to the retropharyngeal lymph nodes, and bilateral drainage is also possible.
      2) Cancer involving the pyriform sinus has an approximately 20% risk of contralateral lymph node metastasis.[7] The lateral wall of the pyriform is less likely than the medial wall to metastasize to the contralateral lymphatics.
3. Flexible fiberoptic laryngoscopy
   a. A key portion of the examination is direct fiberoptic laryngoscopy to confirm the presence of a hypopharyngeal lesion, and to determine its extent.
   b. Does the cancer involve the endolarynx, post-cricoid region, or posterior pharyngeal wall?
   c. Does the cancer obstruct the airway? If the tumor causes significant obstruction of the larynx, an awake flexible fiberoptic intubation or an awake tracheostomy must be considered.
4. Cardiac and pulmonary examination
   a. The status of these is a critical component of preoperative planning.
   b. Candidates for organ-preservation surgery require excellent pulmonary function status. Preoperative pulmonary function studies are usually adequate for this assessment.

Imaging

1. Computed tomography (CT)
   a. CT of the neck with contrast is a quick, easy, and cost-effective method for evaluating the extent of cancer of the hypopharynx.
   b. Cervical lymph node metastases can be readily determined with CT. Metastatic cancer develops in 60% to 80% of patients with hypopharyngeal cancer.[8] Occult lymph node metastases are present in at least 20% to 40% of patients.[8] The risk is bilateral in patients with cancer involving the postcricoid mucosa, the medial wall of the pyriform sinus, or the posterior wall of the pharynx.
   c. CT of the chest is important to evaluate for pulmonary metastases in patients with advanced stage cancer.
2. Magnetic resonance imaging (MRI)
   a. Compared to CT, MRI provides better visualization of soft tissue planes.
   b. MRI is useful in determining whether there is tumor involvement of the prevertebral fascia; a contraindication to surgery.
3. Barium esophagram
   a. Fixation to the prevertebral fascia or bone can be ascertained preoperatively with video fluoroscopy when fixation of the pyriform sinus is recognized during swallowing.
4. Positron emission tomography (PET)
   a. Because most patients present with advanced stage cancer, the risk of distant metastases at presentation is substantial. PET, often combined with CT, provides reliable pretreatment evaluation of distant metastatic spread.

Indications

1. Partial laryngopharyngectomy
   a. This procedure is appropriate for patients with cancer limited to the aryepiglottic fold, the medial wall of the pyriform sinus, and the anterior wall of the pyriform sinus, as long as they have adequate pulmonary function. Extension to the apex or lateral wall of the pyriform sinus is a contraindication to this procedure.
2. Total laryngectomy and partial pharyngectomy
   a. This procedure is most commonly performed in patients with carcinoma of the pyriform sinus that extends to involve the larynx medially, the apex of the pyriform sinus inferiorly, or the lateral wall of the hypopharynx laterally.
3. Total laryngopharyngectomy
   a. Cancer involving the postcricoid mucosa, advanced cancer of the posterior hypopharyngeal wall, and cancer involving the pyriform sinus with extension across the midline posteriorly require total laryngopharyngectomy. More extensive cancers that extend into the cervical esophagus are resected via total laryngopharyngoesophagectomy.

Contraindications

1. Extension of the cancer to the prevertebral fascia
   a. This can be evaluated with preoperative MRI and/or barium esophagram.
2. Encasement of the common carotid artery
   a. While significant extension is visible on a preoperative CT scan, occasionally carotid artery involvement can only be determined intraoperatively. If carotid artery involvement is suspected but not confirmed preoperatively, we suggest starting with the neck dissection on the affected side in the event that the case must be aborted.
3. Distant metastases
   a. It is imperative that these patients be discussed at a multidisciplinary conference for treatment options, including palliative care.

Preoperative Preparation

1. Preoperative medical clearance, particularly with regard to cardiac and pulmonary status
2. Laboratory tests should include a prealbumin and thyroid-stimulating hormone as these are correctable causes of delayed wound healing.
3. Consider a gastrostomy tube if the patient is unable to swallow and is malnourished.
4. Discontinue antiplatelet and anticoagulant medications if possible.
5. Have any biopsy or imaging studies done at another hospital reviewed by in-house experts.

OPERATIVE PERIOD

Anesthesia

General

Positioning

Supine with a shoulder roll for neck extension and both arms tucked in at the patient's side

Perioperative Antibiotic Prophylaxis

1. Surgery involving the upper airway is classified as clean-contaminated. Antibiotic prophylaxis should target pathogens found in the upper aerodigestive tract.
   a. Ampicillin-sulbactam is the first choice.
   b. For patients who are allergic to penicillin, either clindamycin or ciprofloxacin combined with metronidazole is a reasonable alternative.

Monitoring

Standard anesthesia protocol for major surgery

Instruments and Equipment to Have Available

1. Direct laryngoscopy set with rigid esophagoscope
2. Major head and neck set
3. Operative microscope if free tissue transfer is necessary for reconstruction
4. Tracheoesophageal puncture kit with prosthesis

Key Anatomic Landmarks

1. Hyoid bone
   a. Must be identified and skeletonized. The pharynx is entered superior to the hyoid bone on the side contralateral to the cancer.
2. Hypoglossal nerve
   a. Identified deep to the greater cornu of the hyoid bone. Preservation of this cranial nerve is key to functional deglutition following surgery.
3. Pyriform sinuses
   a. For partial pharyngectomy, the pyriform sinus contralateral to the tumor should be carefully dissected off of the lateral lamella of the thyroid cartilage and entirely preserved if possible (Figs. 40.1 and 40.2).

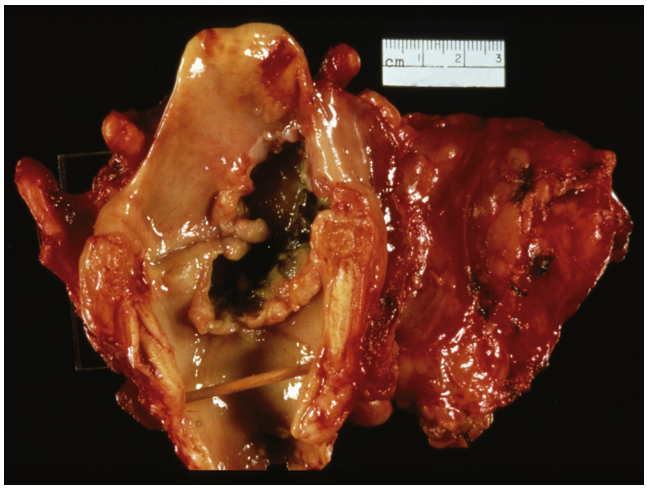

Fig. 40.1. This patient has advanced cancer of the larynx. Most of the cancer is confined to the intrinsic larynx; however, resection of the medial wall of the ipsilateral piriform sinus is required to obtain a deep margin. Preservation of the contralateral piriform sinus, as well as the ipsilateral lateral wall, will allow primary closure.

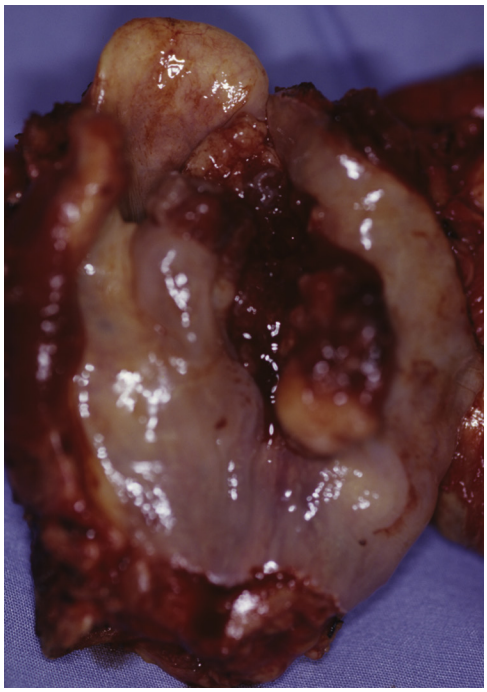

Fig. 40.2. This cancer of the piriform sinus extends to involve the entire lateral wall. During resection, the contralateral piriform sinus was carefully preserved.

Prerequisite Skills

1. Neck dissection
2. Laryngectomy

Operative Risks

1. Injury to the hypoglossal nerve
   a. The hypoglossal nerve is at risk during the laryngectomy portion of the case when the hyoid bone is dissected free from surrounding tongue musculature. The nerve runs just lateral and deep to the greater horn of the hyoid bone.
   b. Care must be taken to avoid injury to the hypoglossal nerve so that the patient has optimal swallowing function postoperatively.
   c. Injury to the hypoglossal nerve can be avoided by identifying the nerve during the neck dissection portion of the case. Once identified laterally, the nerve can be traced medially until its relationship with the hyoid bone is clearly delineated.
2. Lack of preoperative identification of inoperability, either by involvement of the common carotid artery or prevertebral fascia
   a. Preoperative contrast-enhanced MRI provides excellent anatomic detail to determine whether there is involvement of the prevertebral fascia.
   b. We recommend obtaining preoperative staging CT scans within 1 month of surgery to avoid the risk of missing cancer invading into critical structures.
3. Injury to major vascular structures
   a. This may lead to significant hemorrhage intraoperatively, which requires immediate identification and repair.
   b. Delayed postoperative hemorrhage may be related to the displacement of a poorly secured vascular clip, a wound infection causing tissue breakdown, or persistent cancer.
   c. Carotid artery blowout is the most feared and devastating complication. This is more common in patients who undergo a radical neck dissection, have radiated tissues, and a postoperative pharyngeal leak.
      1) Tissue coverage with either a pectoralis flap or free tissue transfer can help to prevent this devastating outcome.
4. Pharyngeal leak
   a. Small leaks are managed conservatively by avoiding an oral diet, diverting the leak with a drain, and providing local wound care.
   b. Persistent large leaks require returning the patient to the operating room for repair and possibly local or free tissue reconstruction to prevent recurrence.
   c. Risk factors that predispose to pharyngeal leak include previous radiotherapy and hypothyroidism.[9]

Surgical Technique

1. Partial laryngopharyngectomy
   a. A direct laryngoscopy and esophagoscopy should be performed both prior to surgery for diagnosis and again at the start of the pharyngectomy for surgical planning.
   b. Neck dissection using an apron flap is accomplished bilaterally for cancer involving the medial wall of the pyriform sinus. Elective unilateral neck dissection may suffice for patients with cancer isolated to the lateral wall.
   c. The surgeon proceeds to perform a supraglottic laryngectomy.
   d. The supraglottic larynx is removed with the adjacent hypopharyngeal carcinoma in an effort to achieve at least a 15-mm mucosal margin in all directions.
   e. Reconstruction is accomplished by impacting the base of the tongue into the residual larynx.
   f. Prior to closure, a nasogastric tube is inserted in patients who have not had a gastrostomy.
   g. Closure of the residual hypopharyngeal mucosa is indirect and requires a second layer consisting of the residual strap muscles and digastric muscle.
   h. All wounds are drained with negative pressure.

2. Total laryngectomy and partial pharyngectomy (Fig. 40.3)
   a. Prepare the patient for a total laryngectomy and start with a superiorly based apron flap through the level of the stoma.
   b. Bilateral neck dissections of levels II to IV are performed in most instances.
   c. After completion of the neck dissection, the pharynx is entered through the vallecula contralateral to the cancer.
   d. Effort is made to preserve 100% of the uninvolved pyriform mucosa, which can be accomplished by releasing the pyriform sinus after having first incised the overlying constrictor muscles along the lateral lamella of the thyroid cartilage. The pyriform sinus is then gently dissected free from the endolarynx.
   e. The resection is next carried from the vallecula down along the aryepiglottic fold to the lateral aspect of the arytenoid contralateral to the cancer. The remaining incisions in the mucosa are made under direct visualization so that the surgeon can ensure an adequate (15 to 20 mm) mucosal margin around the cancer.
   f. At the completion of the resection, frozen section assessment of margins is mandatory.
   g. Patients with 3 cm of residual pharyngeal mucosa in the transverse dimension can usually be closed primarily. If less than 3 cm of mucosa remains, a pedicle flap or free flap reconstruction may be required (Fig. 40.4). Prior to closure, a nasogastric tube is inserted in patients who have not had a gastrostomy.
   h. If primary closure of the pharynx is successful, a primary tracheoesophageal puncture (TEP) is performed. Patients with a pedicle or free flap reconstruction typically benefit from secondary TEP after healing and adjuvant treatment are complete.
      1) The stoma is matured and wounds are closed over bilateral suction drains.
3. Total laryngopharyngectomy (Fig. 40.5)
   a. Prepare the patient for a total laryngectomy and start with a superiorly based apron flap through the level of the stoma.
   b. Bilateral neck dissections are always performed.
   c. Enter the pharynx in the vallecula contralateral to the side of the cancer.
   d. Depending on the location of the cancer, release the uninvolved pyriform mucosa.
   e. Carry the dissection from the vallecula down along the lateral aspect of the epiglottis until the cancer is visualized.
   f. Obtain a 15- to 20-mm superior margin and then dissect a plane inferiorly between the posterior pharyngeal wall and the prevertebral fascia.
   g. Under direct visualization, ensure an adequate inferior margin and transect the larynx and pharynx inferiorly.

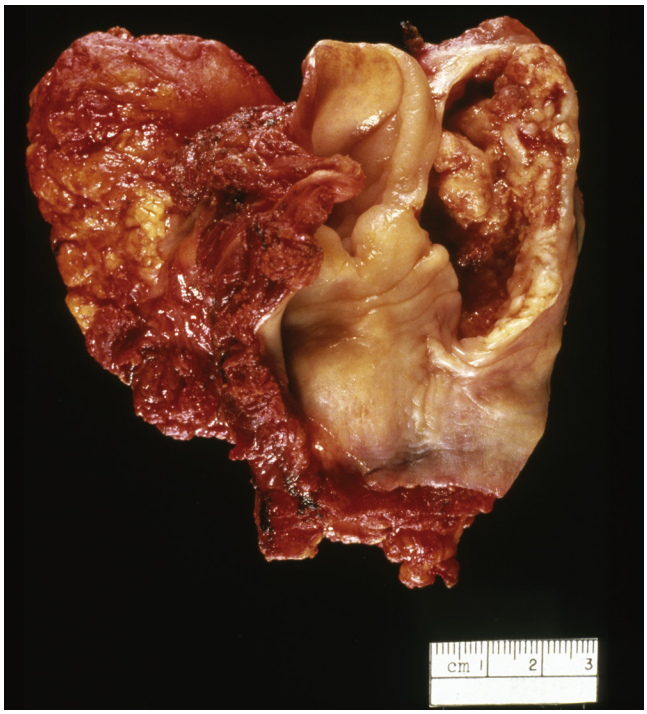

Fig. 40.3. This extensive hypopharyngeal cancer crossed the midline posteriorly. Laryngectomy and near-total pharyngectomy were required.

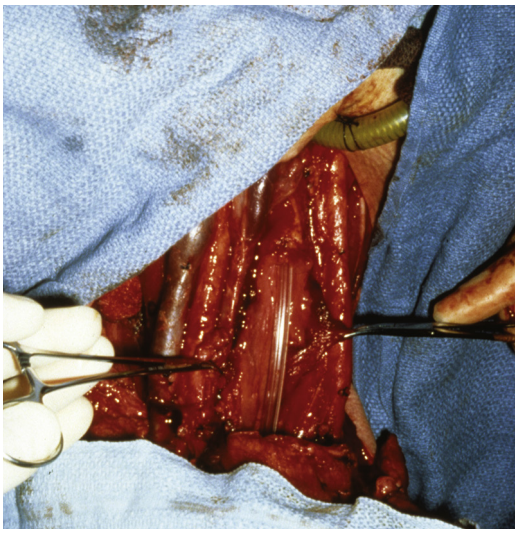

Fig. 40.4. This narrow island of residual hypopharynx cannot be closed primarily. It must be supplemented with a pedicle flap or free tissue transfer or resected and replaced with regional or distant tissue.



Fig. 40.5. This circumferential postcricoid lesion required total laryngopharyngectomy followed by appropriate reconstruction.

h. Reconstruction requires free tissue transfer, such as a tubed radial forearm free flap (Fig. 40.6 and Fig. 40.7). Free flap reconstruction using the jejunum is a viable option for large defects (Fig. 40.8); however, it has largely been replaced by free flaps from other sites. Prior to closure, a nasogastric tube is inserted in those patients who have not had a gastrostomy.
i. When cancer extends into the cervical esophagus, total laryngoesophagectomy is required.
j. The stoma is matured and wounds are closed with bilateral suction drains.

Common Errors in Technique

1. Inadequate visualization of the cancer and its extent during initial laryngoscopy
   a. Because entry into the pharynx is blind, a good understanding of the location of the cancer is essential to avoid cutting through it.
2. Inadequate skeletonization of the hyoid bone
   a. The release of the attachments to the hyoid bone assists in the rotation of the larynx. This is helpful when releasing the constrictor muscles from the thyroid lamella and the subsequent release of the pyriform sinuses.
   b. Full exposure of the hyoid bone protects the hypoglossal nerve from injury.

POSTOPERATIVE PERIOD

Postoperative Management

1. Continue perioperative antibiotics for 24 hours.
2. If a total laryngectomy is performed, the stoma should be left open to air with humidification and frequent cleaning. If the stoma is obstructed by edema or by tissue reconstruction, then a soft Silastic laryngectomy tube can be placed.

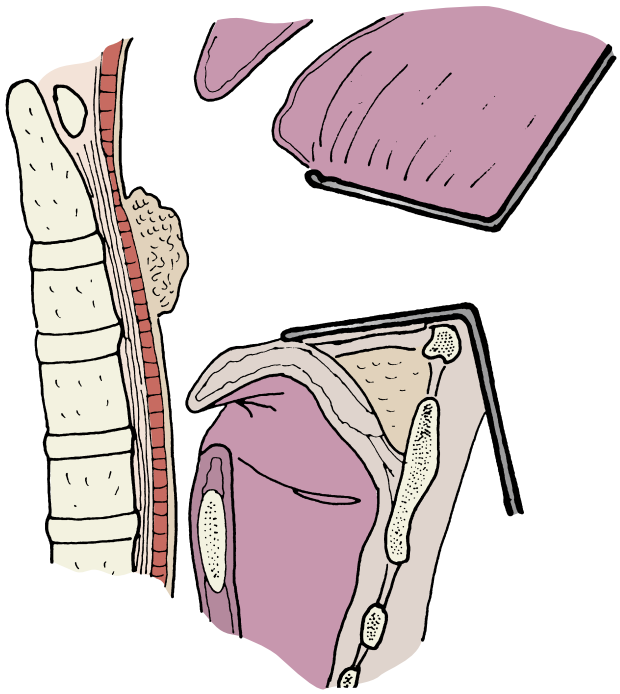

Fig. 40.6. A posterior pharyngeal wall cancer often requires free flap reconstruction. A radial forearm free flap provides thin pliable tissue for posterior pharyngeal wall reconstruction.



Fig. 40.7. The radial forearm free flap can be used for partial pharyngeal reconstruction. It can also be tubed for total reconstruction of the pharynx.



Fig. 40.8. The jejunum has vascular arcades, each serving approximately 25 cm of small intestine. This offers an ideal donor site for free tissue transfer.

3. Most patients temporarily require narcotic pain medications either through a feeding tube or peripheral IV.
4. Resumption of anticoagulants/antiplatelet medications depends on whether the patient had free tissue reconstruction. Patients with primary closure or local flap reconstruction may restart antiplatelet therapy on postoperative day 1.
5. Feeding through the nasogastric or gastrostomy tube is initiated when bowel sounds are present.
6. The integrity of the mucosal suture lines can be determined by contrast barium esophagram between 7 and 10 days postoperatively. If the suture lines are intact, oral alimentation with clear liquids is initiated and the nasogastric tube is removed. The diet can be advanced gradually as tolerated.

Complications

1. Hypothyroidism
   a. This increases the risk of delayed wound healing and pharyngeal leak.
   b. This should be managed with levothyroxine and close follow-up.
   c. A thyroid panel should be ordered 5 to 7 days after surgery.
2. Pharyngeal leak
   a. Small leaks are managed conservatively, keeping the patient NPO, diverting the leak with a drain, and providing local wound care.
   b. Leaks that fail conservative management require operative repair.
   c. Persistent leaks or leaks in patients with radiated tissues often require local or free tissue reconstruction to stop the leak and heal the wound.
3. Pharyngeal stenosis
   a. This is a late complication of pharyngectomy, which can be diagnosed with a barium esophagram. These patients often benefit from esophageal dilatation.
4. Carotid blowout
   a. The most devastating complication of surgery, which often occurs in patients who have been radiated, have a pharyngeal leak, and have a postoperative wound infection
   b. Immediate return to the operating room is paramount for the patient's survival.

Alternative Management Plan

1. Radiation therapy (RT)
   a. For patients with early stage cancer of the hypopharynx, definitive RT offers a good chance for local control and survival.
   b. The decision to use RT versus surgery depends on tumor accessibility, the patient's functional status, and the availability of expertise.
2. Radiation therapy in conjunction with chemotherapy (CRT)
   a. This is a reasonable alternative to surgery in patients with advanced cancer of the hypopharynx.
   b. Organ-sparing approaches, such as CRT, offer larynx preservation but do not confer a survival advantage to total laryngectomy.[10]
   c. If the patient has impaired organ function at baseline, then surgical management is preferred over CRT.
3. Palliative chemoradiation
   a. This is for patients with inoperable cancer or distant metastases.

DISCUSSION

Evidence-Based Question

Does definitive chemoradiation confer a survival advantage over surgery followed by adjuvant radiation in patients with advanced hypopharyngeal cancer?

Functional organ-preserving approaches using a combination of chemotherapy and radiation therapy have largely replaced laryngopharyngectomy plus adjuvant radiation for patients able to withstand prolonged treatment with associated toxicities. Although definitive chemoradiation can permit the preservation of the larynx, it does not confer a survival advantage over surgery plus adjuvant radiation.[10] A multidisciplinary expert panel of the American Society of Clinical Oncology developed clinical practice guidelines for the treatment of laryngeal and hypopharyngeal cancer. They recommend that when feasible, most patients should be offered organ preservation approaches to manage hypopharyngeal cancer. However, in older patients with poor performance status or significant cancer involvement of the thyroid cartilage, laryngopharyngectomy plus adjuvant radiation is often recommended over organ-preserving approaches.

Editorial Comment

Squamous cell cancer of the hypopharynx often presents at a very late stage due to a paucity of symptoms and therefore carries a dismal prognosis. Treatment options rely on a combination of surgery, radiation, and chemotherapy and carry high rates of complications and toxicities. Because of the close proximity of the hypopharynx to the larynx, these two subsites are often combined in both clinical trial investigations and treatment guidelines. It is paramount that all patients with advanced cancer of the hypopharynx are discussed prior to treatment by a multidisciplinary team with expertise in the treatment of cancer of the head and neck. Patient and family goals also must be taken into account when determining the optimal treatment regimen for each patient. Although functional organ preserving treatment approaches are widely recommended for most patients, potential toxicities and the possible need for salvage surgery must be adequately addressed with the patient and their family prior to treatment.

Seungwon Kim

Access the review questions online at http://www.expertconsult.com



REFERENCES

1. Hall SF, Groome PA, Irish J, et al. The natural history of patients with squamous cell carcinoma of the hypopharynx. Laryngoscope 2008;118:1362–1371.
2. Mahalingam S, Srinivasan R, Spielmann P. Quality of life and functional outcomes following pharyngolaryngectomy: a systematic review of the literature. Clin Otolaryngol 2016;41:25–43. http://dx.doi.org/10.1111/coa.12466.
3. Menvielle G, Luce D, Goldberg P, et al. Smoking, alcohol drinking and cancer risk for various sites of the larynx and hypopharynx. A case-control study in France. Eur J Cancer Prev 2004;13:165–172.
4. Ries LAG, Young JL, Keel GE, et al. SEER survival monograph: cancer survival among adults: U.S. SEER Program, 1988–2001, Patient and tumor characteristics. National Cancer Institute, SEER Program; 2014.
5. Takes RP, Strojan P, Silver CE, et al. Current trends in the initial management of hypopharyngeal cancer: the declining use of open surgery. Head Neck 2012;34(2):270–281.

6. Chu PY, Wang IW, Chang SY. Surgical treatment of squamous cell carcinoma of the hypopharynx: analysis of treatment results, failure patterns, and prognostic factors. J Laryngol Otol 2004;118:443–449.
7. Koo BS, Lim YC, Lee JS, et al. Management of the contralateral N0 neck in pyriform sinus carcinoma. Laryngoscope 2006;116(7):1268–1272.
8. Buckley JG, MacLennan K. Cervical node metastases in laryngeal and hypopharyngeal cancer: a prospective analysis of prevalence and distribution. Head Neck 2000;22(4):280–285.
9. White HN, Golden B, Sweeny L, et al. Assessment and incidence of salivary leak following laryngectomy. Laryngoscope 2012;122(8):1796–1799.
10. Pfister DG, Laurie SA, Weinstein GS, et al. American Society of Clinical Oncology clinical practice guideline for the use of larynx-preservation strategies in the treatment of laryngeal cancer. J Clin Oncol 2006;24(22):3693–3704.

REVIEW QUESTIONS

1. Bilateral cervical lymph node metastases are *least* likely to occur in which primary subsite?
   a. Posterior pharyngeal wall
   b. Posterior wall of the pyriform sinus
   c. Lateral wall of the pyriform sinus
   d. Postcricoid region
   e. Medial wall of the pyriform sinus

2. Which of the following is true regarding hypopharyngeal cancer?
   a. Metastasis to retropharyngeal lymph nodes are often seen.
   b. Metastasis to level I occurs frequently.
   c. CT is better than MRI in determining whether the prevertebral fascia is involved by the cancer or not.
   d. A margin of 5 to 10 mm is adequate when resecting a hypopharyngeal cancer.
   e. Advanced cancer of the hypopharynx has a less than 10% risk of occult cervical metastases.

3. Which of the following is *true?*
   a. The majority of patients with hypopharyngeal cancer present with early stage disease.
   b. Patients treated successfully for all stages of hypopharyngeal cancer have a recurrence rate of less than 30%.
   c. Surgery followed by adjuvant radiation is standard of care for early stage hypopharyngeal cancer.
   d. Definitive chemoradiation therapy does not confer a survival advantage over primary surgery for patients with advanced cancer of the hypopharynx.
   e. Cancer involvement of the prevertebral fascia is not a contraindication to surgery.

SECTION 7 Nasopharynx

41 Endoscopic Nasopharyngectomy

Sheng-Po Hao

INTRODUCTION

Certain ethnogeographic groups have been found to have an increased risk of developing nasopharyngeal carcinoma (NPC). Studies have shown that among the Chinese, there is a very high incidence of NPC affecting 10 to 20 per 100,000 for men and 5 to 10 per 100,000 for women, causing NPC to sometimes be called the "Cantonese cancer." Most of these NPCs originate in the epithelial lining of the fossa of Rosenmüller, an area located posteromedially to the medial crura of the opening of the Eustachian tube.[1]

Screening, diagnosing, and monitoring NPC can now be done using several serological markers after studies demonstrated that a close relationship existed between NPC and the Epstein-Barr virus (EBV), a double-stranded DNA virus. Most NPCs carry the clonal EBV genomes and express EBV proteins. To screen the general population, serological markers such as EBC VCA IgA and DNase are used. RT-PCR methods that measure EBV DNA copy numbers in plasma are used to monitor the response to treatment and for early detection of local recurrence.[2]

Currently, radiation therapy (RT), chemotherapy, or combinations of both are the primary available modalities for treating NPC. More than 80% local control can be achieved through RT because of the high radiosensitivity of NPC, giving patients with early NPC a good possibility for cure. However, for patients with advanced-stage locoregional NPC, the standard treatment is Cisplatin-based chemoradiotherapy with or without neoadjuvant chemotherapy. In spite of its high radiosensitivity, patients with advanced NPC still have a 10% to 30% risk of local failure after the initial RT treatment. If local recurrence is suspected, performing a biopsy under nasopharyngoscopy should be done.[1]

KEY OPERATIVE LEARNING POINTS

- Perform medial maxillectomy and posterior septectomy to improve exposure and increase the working space area.
- Use the two nostrils/four hands technique.
- Resection with LASER on a curved applicator.
- Mark the deep margin of resection as the pharyngobasilar fascia and remove the Eustachian tube cartilage as far laterally as possible.
- Involvement of the bone of the skull base will require a navigation-guided endoscopic resection.

PREOPERATIVE PERIOD

NPC patients who are monitored using the EBV serological markers typically do not complain of any symptoms. When there is a local recurrence, the NPC patient may experience the same symptoms experienced at the initial presentation of the cancer. The presence of a mass in the fossa of Rosenmüller or even from the nasopharynx should be investigated further for rNPC. However, there are some patients with whom careful nasopharyngeal examination does not reveal any obvious mucosal lesion. Some may appear as a small submucosal swelling beneath an intact mucosa. Therefore, performing a biopsy under nasopharyngoscopy is mandatory to establish the diagnosis of local recurrence.

The surgeon must evaluate the extent of the cancer by endoscopic examination as well as imaging studies. Magnetic resonance imaging (MRI) is superior in demonstrating soft tissue involvement compared with computed tomography (CT) scan. MRI is able to identify local recurrence, perineural invasion, skull base involvement, suspicious retropharyngeal lymph nodes, and cervical metastasis as well as early cancers that produce mild thickening of the mucosa. These advantages provide important information for good surgical planning and tumor mapping for endoscopic nasopharyngectomy.[3] Salvage surgery is relatively contraindicated for patients who have distant metastasis.

A complete examination of the head and neck must be carried out, particularly in the nasal cavity and nasopharynx, to detect the presence of metastatic lymph nodes, including examination of the cranial nerves. Other important preoperative preparation includes ascertaining any anatomical variation, intraoperative navigation (in selected cases), blood-group matched packed red cells, and preoperative antibiotic. Patients with preexisting significant comorbidities should receive special attention. Anticoagulants or antiplatelet medications should be withheld (if possible) prior to endoscopic nasopharyngectomy.

History

- History of present illness
  - Nasal symptoms: nasal obstruction, blood-stained nasal discharge
  - Aural symptoms: ear blockage, hearing loss, otorrhea
  - Mass in the neck
- Skull base and cranial nerve involvement
  - Intractable headache
  - Sixth cranial nerve involvement which will be discovered by the presence of abducens nerve palsy
  - Unilateral facial numbness from involvement of the fifth cranial nerve
- Trismus
- Symptoms suggesting distant metastasis
- Weight loss, nutritional status
- Smoking
- Past medical history
  - Previous radiotherapy with or without chemotherapy
  - Previous surgery for NPC

- Pulmonary disease, hypertension, diabetes, or ischemic heart disease
- Immunosuppression; for example, AIDS
- Medications
  - Anticoagulants
  - Allergies to antibiotics or analgesia

Physical Examination

- Nasal cavity and nasopharyrnx
  - Endoscopic examination of the nasopharynx may reveal a mass in the fossa of Rosenmüller and sometimes a small submucosal swelling
  - Determine extent of the tumor
    - Lateral extension
      - Eustachian tube
      - Torus tubarius
  - Roof of nasopharynx and posterior choanae
  - Inferior extension to oropharynx
- Examination of the neck
  - Palpate both necks for the presence of cervical metastases
  - Is the mass fixed or mobile?
  - Is there bilateral cervical metastasis?
- Examination of the skull base and cranial nerve
  - Is there evidence of sixth nerve palsy?
- Trismus
  - Anticipate difficult intubation and may require tracheostomy
- Examination of the ears
  - Middle ear effusion
- Examine oral cavity, pharynx, and larynx for synchronous primaries
- General health
  - Nutrition
  - Cardiovascular
  - Respiratory
  - Abdominal

Imaging

- MRI
  - Superior soft tissue resolution and tumor delineation
    - Parapharyngeal space or infratemporal fossa
    - Intracranial extension
    - Perineural invasion
    - Deep invasion to the vertebra body
    - Vascular involvement (carotid artery, cavernous sinus)
  - Presence of cervical metastasis
- PET CT scans
  - Restaging
  - To exclude distant metastasis (bone, lung, and liver)
  - To exclude cervical metastasis
- CT scan
  - Not required in all cases
  - MRI is preferred if available
- Chest radiograph
  - Metastases
  - Pulmonary and cardiac status
- Ultrasound of the liver

Indications

- Mainstay of treatment after radiotherapy failure[4]
- Lesions of the central, roof, or floor of the nasopharynx with minimal lateral extension
- Recurrent NPC with skull base bone involvement with the aid of navigation[5]

Contraindications

- Parapharyngeal space or infratemporal fossa involvement
  - Not a good candidate for salvage surgery, as it is difficult to achieve oncologically safe surgical margins in these areas[6]
- Significant dural involvement and intracranial extension
- Internal carotid artery or cavernous sinus involvement
- Medically unfit for surgery

Preoperative Preparation

- Evaluations
  - Otorhinolaryngologist—head and neck surgeon
  - Oncologist
  - Anesthesiologist
  - Nutritionist (if necessary)
  - Internal Medical Specialist optimizing medical illness (cardiopulmonary disease) if required
- Treat sinusitis if present
  - Not rare in rNPC patients
  - Bacterial culture of nasal secretion is obtained and culture-directed antibiotics prescribed for at least 7 days
  - Perform frequent nasal douching with saline before surgery
- Intraoperative navigation (if required)
- Postoperative high-dependency care (depending on the center)
- Discontinue antiplatelet drugs if possible

OPERATIVE PERIOD

Anesthesia

- General anesthesia
- Oral endotracheal tube
- In patients who have trismus, intubation under fiberoptic guidance may be necessary. Temporary tracheostomy should be considered in patients who have severe trismus.
- The endotracheal tube is positioned away from the surgeon so as not to interfere with the operative site.

Positioning

- The patients are placed in the supine position with the neck slightly extended and the head resting on a donut.
- The nasal cavity is decongested for 15 minutes with cotton pledgets saturated with epinephrine 1:100,000.
- Careful inspection of the nasopharynx with a rigid endoscope: Inspection of the cancer and its extent is mandatory in order to formulate a good surgical plan.
- Lidocaine 1% mixed with 1:80,000 epinephrine is used to infiltrate the mucoperichondrium of the nasal septum, middle, and inferior turbinates, and around the cancer.

Perioperative Antibiotic Prophylaxis

- Clean contaminated surgery.
- Prophylactic intravenous antibiotics based on previous available bacterial culture data or antibiotic with good CSF penetration (intravenous clindamycin).
- Additional intraoperative doses of antibiotic can be given every 6 hours in longer surgery.

Monitoring

- Routine anesthesia monitoring
- Hypotensive anesthesia (to reduce intraoperative bleeding that will obscure operative field)

- Intraoperative heating blanket to prevent hypothermia
- Maintain hydration and hemoglobin

Instruments and Equipment to Have Available

Endonasal skull base surgery set including:

- Navigation system
- Sinuscope set using the 0-degree and 30-degree Hopkins' scopes
- Kerrison rongeurs, suctions, forceps, curettes, tru-cutting instruments, and dissectors
- Cutting and diamond burrs
- Contact LASER set with curved applicator
- Bipolar cauterization set

Key Anatomic Landmarks

- Most cephalad portion of the upper aerodigestive tract
- Measuring nearly 4 cm in transverse diameter and 2 cm in its anterior-posterior dimension
- Boundaries:
  - Superior: sphenoid sinus and upper clivus
  - Posterior: lower clivus and body of the first cervical vertebra
  - Lateral: medial pterygoid plate
  - Anterior: communicates with the posterior nasal choanae
  - Inferior: communicates with the oropharynx
- Posterior and lateral walls lined by the pharyngobasilar fascia
  - Tough fibrotic layer
  - Inserts superiorly to the basosphenoid and laterally to the medial pterygoid plate
  - Continuing downward it becomes the buccopharyngeal fascia
- Between the roof and the lateral wall of the nasopharynx is a recess that is located superior to the torus tubarius where most NPC tumors are located. This area is called the fossa of Rosenmüller.
- Inferolateral wall is the Sinus of Morgagni, an incomplete cartilaginous ring through which the Eustachian tube and tensor veli palatini muscle travels.
- Tensor veli palatine muscle
  - Attached to Eustachian tube on its lateral side and to the scaphoid fossa floor
  - Muscle fibers converge into a tendon that curves around the pterygoid hamulus
  - Inserts into the palatine aponeurosis of the soft palate
  - Contracture of this muscle facilitates opening of the Eustachian tube lumen
- Levator veli palatine muscle
  - Originates from the petrous temporal bone's inferior surface
  - Traverses through the Sinus of Morgagni
  - Inserts into the palatine aponeurosis[4]

Prerequisite Skills

- Experience in skull base surgery and familiarity with the complex anatomy.
- Open approach (see Chapter 43).
  - Cancer involving the carotid artery or unexpected extension, not amenable to endoscopic surgery and the patient may require conversion to an open approach.

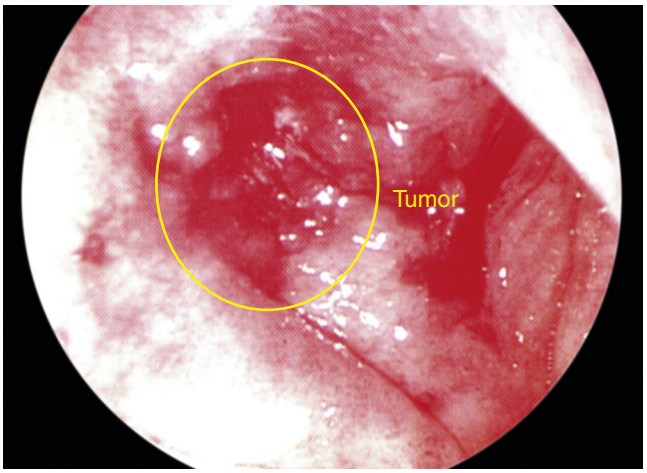

Fig. 41.1. Preoperative sinoscopy demonstrating rNPC over the right fossa of Rosenmüller.

Operative Risks

The major operative risk of endoscopic nasopharyngectomy is similar to any skull base surgery such as:

- Intracranial hemorrhage
- Pneumocranium or tension pneumocephalus
- CSF leak

Surgical Technique

- *Intraoperative evaluation after patient has been intubated*
  - Ensure the nose is properly decongested and anesthetized
  - Reassess the extent of the primary cancer (Fig. 41.1)
- *Surgical approach*
  - Good surgical access and good nasal decongestion is essential to attain adequate resection margins and to control bleeding.
  - Posterior septectomy is first performed to provide an unobstructed access to the nasopharynx. This allows the use of different instruments in each nostril, the so-called two nostrils, four-handed technique.
  - Ipsilateral middle and inferior turbinates are selectively removed.
  - Endoscopic medial maxillectomy can be carried out if more space is needed, especially in cases with some lateral extension.[7]
- *Endoscopic nasopharyngectomy*[6]
  - Dissection can be carried out using electrocautery or laser.
  - Continuous wave, contact diode laser (Diomed Co., Cambridge, UK) mounted on an angled applicator can be used to achieve a bloodless surgical field.
  - Visualization by 4-mm diameter, 0-degree, and 30-degree endoscopes (Karl-Storz, Tuttlingen, Germany) allow the widely exposed cancer to be resected with adequate surgical margins.
  - Incision usually begins along the ipsilateral sphenoethmoidal recess (Fig. 41.2).
  - Incision deepened to the bone, transversely connecting the septum above the nasopharyngeal roof to the ipsilateral fossa of Rosenmüller.
  - Ipsilateral sphenoid sinus ostium is identified and widened medially.
  - The face of the sphenoid sinus and rostrum are removed.

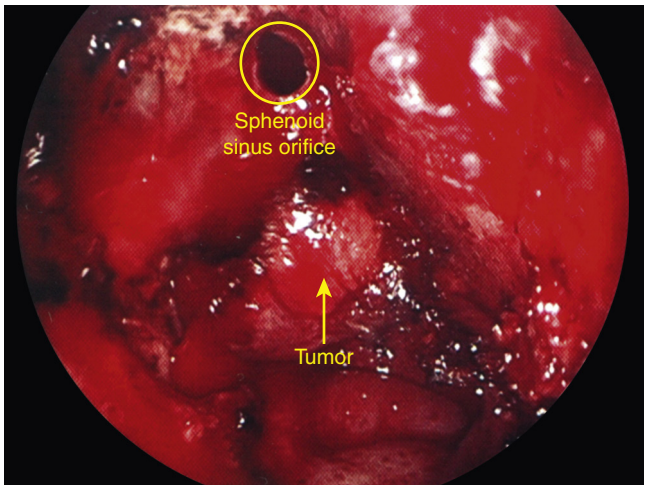

Fig. 41.2. Dissection of the cancer inferiorly using LASER dissection technique from sphenoethmoidal recess across to Eustachian tube cartilage exposing the sphenoid sinus.

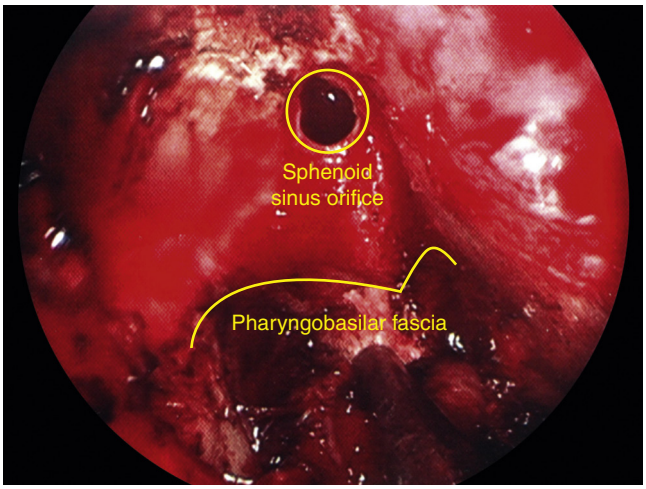

Fig. 41.3. Pharyngobasilar fascia deep to the pharynx and rNPC.

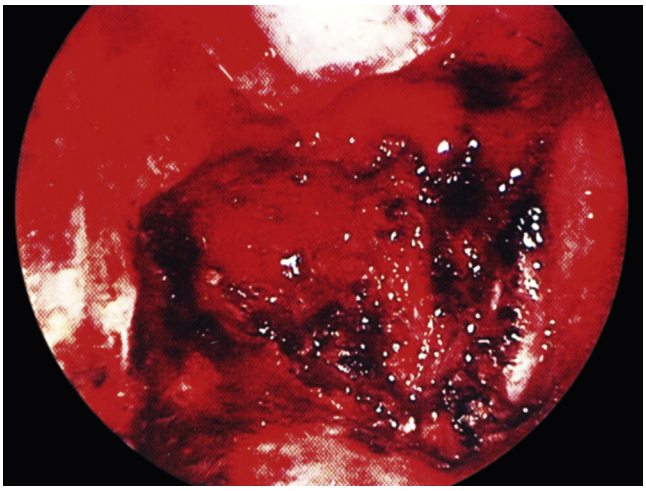

Fig. 41.4. Raw surgical defect after nasopharyngectomy on endoscopic view.

- Nasopharyngeal mucosa is elevated away from the face of the sphenoid sinus in superior-to-inferior direction.
- The floor of the sphenoid sinus is then removed using a combination of Kerrison rongeur and cutting burrs.
- The mucoperiosteum is then elevated downward to the sphenoclival junction to expose the pharyngobasilar fascia.
- Electrocautery or laser is applied to separate the attachment of the tough pharyngobasilar fascia from the bone.
- The thick, tough fascia prevents invasion by the cancer and can be used as the deep margin.
- Lateral margin of the cancer is defined using cautery along the posterior edge of the ipsilateral Eustachian tube.
- Dissect laterally until the ipsilateral cartilaginous portion of the Eustachian tube is reached. Transect as laterally as possible.
- The bone of the base of the pterygoid plate can be removed for better exposure laterally.
- The mucosa is incised deep to the bone and then elevated medially. The lateral surgical margin should be assessed at this point.
- A vertical incision from the ipsilateral roof to the inferior border of the cancer is carried out.
- Medial and inferior mucosal incisions are carried out based on the extent of the cancer.
- The medial incision usually reaches the medial border of the orifice of the contralateral Eustachian tube.
- The contralateral lateral margin usually includes the contralateral fossa of Rosenmüller.
- The inferior incision is usually made at the level of the superior surface of the soft palate.
- Finally, the cancer is completely excised after careful dissection using the pharyngobasilar fascia as a deep margin. This strong fascia often offers an effective barrier for spread of the cancer and can be used as a deep margin (Fig. 41.3).
- A cutting burr is then used to remove some of the residual soft tissue and the clivus and sphenoid ridge in order to obtain additional clear surgical margins.
- The superior and medial portion of the pterygoid plate can also be removed for margin control.
- Frozen sections are obtained to ensure clear margins.[7]
- A raw surgical defect is left for secondary epithelization (Fig. 41.4).

Common Errors in Technique

- Small exposure field.
- Performing posterior septectomy, lower middle turbinectomy, medial maxillectomy, and/or medial pterygoid plate and muscle removal provide better exposure and more working space for two nostrils/four handed technique.

POSTOPERATIVE PERIOD

Postoperative Management

- The patient is monitored for any complications.
  - Bleeding
  - Intracranial hemorrhage
  - Meningitis
  - Pneumocranium or tension pneumocephalus
  - CSF leak
- Intravenous antibiotic is continued for at least 3 days.
- Nasal packing and Foley catheter are removed between 24 and 48 hours.
- Patient may be discharged at postoperative day 3.
- Patient is instructed to irrigate the nasal-nasopharyngeal space with warm saline every day.

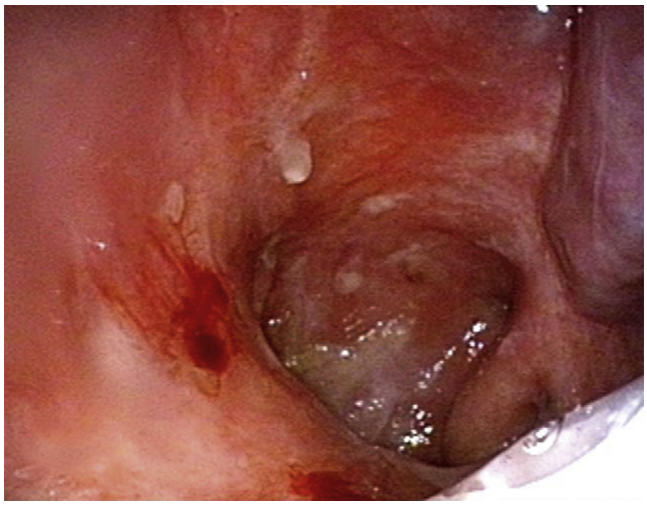

Fig. 41.5. Re-epithelized mucosa after 3 months postendoscopic nasopharyngectomy without evidence of recurrence or residual tumor.

- Endoscopic examination and diligent debridement of the defect every week are crucial until the wound heals satisfactorily, which usually occurs within 3 to 6 months (Fig. 41.5).

Complications

- Operative complications are rarely encountered in endoscopic nasopharyngectomy.
- Most common perioperative complication are:
  - Bleeding
    - Branches of the sphenopalatine artery. Time spent on meticulous hemostasis will prevent this problem.
  - Wound infection
    - Excessive accumulation of crust, and thus, frequent self-cleaning by irrigation or manual endoscopic debridement of crusts is extremely important.
  - Osteoradionecrosis (ORN) of the nasopharynx[8]
    - Surgical bed has been heavily radiated and there is no local well-vascularized flap outside the radiation field.
    - Nasal septal flap is a good option for skull base or nasopharynx reconstruction.
    - Ipsilateral pedicle, or even from the contralateral sphenopalatine artery, is usually difficult to preserve during the nasopharyngectomy for surgical margin reasons, and the pedicle is usually also within the previous radiation field.
  - Ascending meningitis
  - Chronic headache

Alternative Management Plan

Patient can be offered transfacial nasopharyngectomy or a second course of concurrent chemoradiotherapy.

DISCUSSION

Evidence-Based Medicine Question

What are the prognostic factors and survival for NPC patient treated with endoscopic nasopharyngectomy?

The primary treatment for NPC is radiotherapy with or without chemotherapy. However, 15% to 58% of the NPC patients experience recurrence.[9] Endoscopic nasopharyngectomy is a safe option for salvage treatment apart from re-radiation or palliative chemotherapy. Hsu et al. (2001) reported that the overall survival and locoregional relapse-free survival were 56% and 60% at 2 years, and were 30% and 40% at 5 years, respectively.[10] The results concur with the our own report in which the 5-year overall survival for stage I, 64.8%; stage II, 38.1%; stage III, 25.9%; stage IV, 46.9%; and all stages, 48.7%.[7] Zou et al. (2015) in their series of 92 patients with rT1-T2 who underwent endoscopic nasopharyngectomy showed a remarkable 5-year overall survival and distant metastasis-free survival of 78.1% and 88.6%, respectively. The prognostic factor of local control are gender, margin status, adjuvant treatment type, and parapharyngeal space involvement, whereas dura or brain involvement, local recurrence, and adjuvant treatment type were significant impact factors of survival.[7] Zou et al. (2015) reported that the recurrent T staging is a significant prognostic factor for overall survival and distant metastasis-free survival.

Editorial Comment

Endoscopic Nasopharyngectomy

This section of our book includes four chapters on surgery of the nasopharynx. Professor Hao's chapter on Endoscopic Nasopharyngectomy features laser excision of recurrent NPC. Professor William Wei and Dr. Raymond Chang describe the latest technologic advances in their chapter entitled Robotic-Assisted Nasopharyngectomy. Professor Sheng-Po Hao presents an extensive, purely surgical technique using the Expanded Maxillary Swing Approach for Nasopharyngectomy and Professor Daniel Nuss has described the Facial Translocation Approach to the Nasopharynx.

Dr. Sheng-Po Hao, one of the outstanding authorities in the management of nasopharyngeal carcinoma (NPC), and has authored a well-organized, highly detailed chapter on Endoscopic Nasopharyngectomy. Most of the patients diagnosed with cancer of the nasopharynx are treated with a regime including platinum-based chemotherapy and radiation therapy. One of the main reasons for this has been the difficulty in achieving adequate exposure in this deeply seated anatomic site to be able to resect these cancers with a clear surgical margin. This chapter provides details on using the laser to resect these recurrent cancers.

The management of recurrent NPC is a vexing problem because despite the difficulties in adequately resecting the recurrent cancer, the alternative treatment is a second course of radiation therapy. The downside of this choice is using a treatment modality that was not successful the first time. Retreatment may also result in unpleasant and dangerous sequelae such as severe trismus and ORN of the skull base.

We anticipate that NPC will become a technologically driven field which may change the treatment paradigm especially for early cases of NPC which may be managed by primary surgery. Advances such as the FLEX Robot, which has the ability to provide excellent exposure of the nasopharynx, may replace chemoradiation with its unpleasant side effects as the primary treatment of NPC.

Eugene N. Myers

Access the review questions and additional source list online at http://www.expertconsult.com

REFERENCES

1. Hao SP, Tsang NM. Nasopharyngeal carcinoma. In: Petruzzelli GJ, editor. Practical Head and Neck Oncology. San Diego: Plural Publishing; 2008. p. 175–190.
2. Lin JC, Wang WY, Chen KY, et al. Quantification of plasma Epstein-Barr virus DNA in patients with advanced nasopharyngeal carcinoma. N Engl J Med 2004;350:2461–2470.
3. King AD, Kew J, Tong M, et al. Magnetic resonance imaging of the Eustachian tube in nasopharyngeal carcinoma: correlation of patterns of spread with middle ear effusion. Am J Otol 1999;20:69–73.
4. Hao SP, Tsang NM, Chang CN. Salvage surgery for recurrent nasopharyngeal carcinoma. Arch Otolaryngol Head Neck Surg 2002;128:63–67.
5. Hao SP, Tsang NM. Surgical management of recurrent nasopharyngeal carcinoma. Chang Gung Med J 2010;33:361–369.
6. Hao SP. Endoscopic nasopharyngectomy. In: Ferris R, Myers EN, editors. Master Techniques in Otolaryngology—Head and Neck Surgery: Head and Neck Surgery: Volume 1: Larynx, Hypopharynx, Oropharynx, Oral Cavity and Neck. LWW, Philadephia 2013. p. 271–277. Wolters Kluwer, BA, Alphen aan den Rijn, The Netherlands.
7. Hao SP, Tsang NM, Chang KP, et al. Nasopharyngectomy for recurrent nasopharyngeal carcinoma: a review of 53 patients and prognostic factors. Acta Otolaryngol 2008;128:473–481.
8. Chang KP, Tsang NM, Chen CY, et al. Endoscopic management of skull base osteoradionecrosis. Laryngoscope 2000;110:1162–1165.
9. Yang TS, Ng KT, Wang HM, et al. Prognostic factors of locoregionally recurrent nasopharyngeal carcinoma—a retrospective review of 182 cases. Am J Clin Oncol 1996;19(4):337–343.
10. Hsu MM, Ko JY, Sheen TS, et al. Salvage surgery for recurrent nasopharyngeal carcinoma. Arch Otolaryngol Head Neck Surg 1997;123:305–309.

REVIEW QUESTIONS

1. Which of the following statements is true? The indication for endoscopic nasopharyngectomy:
   a. Recurrence limited to nasopharyngeal mucosa
   b. Recurrence involving the sphenoid sinus floor bone lateral to the foramen ovale
   c. Recurrence involving around the petrous part of the carotid artery
   d. Recurrence involving the brain parenchyma

2. Which of the following anatomical structures which does not form a natural barrier to the spread of NPC:
   a. Prevertebral fascia
   b. Pharyngobasilar fascia
   c. Sinus of Morgagni
   d. Floor of sphenoid sinus

3. What is NOT the technique performed to improve the view during endoscopic nasopharyngectomy:
   a. Posterior septectomy
   b. Medial Maxillectomy
   c. Inferior, middle, and superior turbinectomy
   d. Lateral pterygoid plate and muscle removal

ADDITIONAL SOURCE

Zou X, Han F, Ma WJ, et al. Salvage endoscopic nasopharyngectomy and intensity-modulated radiotherapy versus conventional radiotherapy in treating locally recurrent nasopharyngeal carcinoma. Head Neck 2015;37(8):1108–1115.

42 Robotic-Assisted Nasopharyngectomy

William I. Wei, Raymond K. Tsang

INTRODUCTION

While radiotherapy with or without chemotherapy has been the mainstay of treatment for primary nasopharyngeal carcinoma (NPC), surgical resection of the recurrent cancer with the adjacent mucosal wall (nasopharyngectomy) has been established as an efficacious salvage treatment. Various open surgical approaches for nasopharyngectomy have been described in Chapter 43 and Chapter 44. With advancement in technology and endoscopic endonasal surgical techniques, it is now feasible to perform endoscopic resection in selected cases of patients who have recurrent NPC using an endoscopic endonasal approach. The endoscopic approach remains a challenging operation since the limited space in the nasal cavities and nasopharynx does not provide adequate exposure, which hampers instrumentation and reduces the dexterity of the surgeon. Alternatively, a transoral robotic-assisted approach allows a minimally invasive resection of a small NPC without resorting to major incisions and osteotomies. The surgical robot is a machine designed to assist the surgeon to perform complex surgical maneuvers in confined spaces of the body cavity. It has been successfully applied to the head and neck area for minimally invasive surgery for early cancers of the oropharynx, larynx, and hypopharynx.

The application of the surgical robot has several distinct advantages when applied to minimally invasive nasopharyngectomy. The 3D magnified view and stable endoscopic camera platform allow the surgeon to visualize the anatomy and pathology with unprecedented detail and clarity. The wristed instruments with multiple degrees of freedom allow for complex surgical maneuvers to be performed with dexterity in a narrow space such as the nasopharynx.

Unfortunately the current generation of surgical robots is not designed primarily for use in the head and neck area, and there are certain restrictions and limitations when applied to nasopharyngectomy, which we will discuss in this chapter. Note that the surgical robot discussed in this chapter is restricted to the da Vinci S or da Vinci Si model by Intuitive Surgical Inc. (Sunnyvale, California).

KEY OPERATIVE LEARNING POINTS

- The major benefit of the surgical robot is from the wrist of the robotic arms that increases the surgical dexterity previously lost in endoscopic instruments. The use of the surgical robot allows traction and counter-traction of tissue during dissection.
- The major disadvantage of the surgical robot is the loss of tactile sensation, and this sense needs to be substituted by vision. An example is observing denting of tissue by surgical instruments to determine if it is hard or soft.
- The anatomy of the internal carotid artery in the parapharyngeal space (PPS) is highly variable. Trace the artery on the cross-sectional images carefully. Patients with a retropharyngeal internal carotid artery or the artery too close to the tumor are not suitable for robotic nasopharyngectomy.
- Recurrent NPC frequently arising from the fossa of Rosenmüller involved the Eustachian tube cartilage. Enbloc resection of the involved fossa of Rosenmüller and ipsilateral Eustachian tube cartilage is necessary for complete resection of the disease.
- Coverage of the raw bone of the clivus, preferably with vascularized tissue, is mandatory to minimize the risk of postoperative osteoradionecrosis.

PREOPERATIVE PERIOD

History

1. History of present illness
   a. History of previous NPC
   b. History of treatment of NPC with radiation or chemoradiation
   c. Diagnosis of local recurrence in the nasopharynx
   d. Diagnosis of other malignant lesion in the nasopharynx
   e. Benign lesions in the nasopharynx requiring resection
   f. Presence of a mass in the neck
2. Past medical history
   a. Details of prior treatment of NPC
   b. Prior endoscopic nasal surgeries
   c. Comorbid medical conditions that increase anesthetic risks
   d. Presence of velopharyngeal incompetence/hypernasality—transpalatal surgery may exacerbate the velopharyngeal incompetence
   e. Presence of trismus and mastication problems—a common problem following radiation to the nasopharynx precluding a transoral approach
   f. Presence of loose teeth or teeth with radiation caries—teeth may be damaged during a transoral procedure
3. Medication history
   a. Concurrent use of antiplatelet drugs—carotid stenosis is common in NPC patients after radiation
   b. Use of herbal medicine—increase bleeding tendency
   c. Allergies, especially to antibiotics
4. Mental and social status
   a. Ability to give informed consent
   b. Preference for surgical salvage over salvage radiotherapy

Physical Examination

1. Examination of the nasal cavities and nasopharynx
   a. Identify the site and extent of the recurrent cancer with an endoscope.
   b. The fossa of Rosenmüller should be inspected with a 30-degree endoscope.
   c. Presence of intranasal adhesions
   d. Presence of radionecrosis of the skull base
2. Examination of the oral cavity
   a. Presence of trismsus—dental gap should be more than 3.5 cm for transoral robotic surgery (TORS)
   b. Condition of the teeth, any loose teeth, or teeth with radiation caries
   c. Velopharyngeal closure
3. Examination of the neck
   a. Presence of metastasis to the neck
   b. Adequate flexion and extension of neck
4. Histological diagnosis

Imaging Studies

- Cross-sectional imaging with contrast-enhanced computed tomography (CT) and magnetic resonance imaging (MRI) should be also performed before the operation.
- The location, extent, and relationship of the cancer to the internal carotid artery (ICA) are better appreciated with MRI while CT can better demonstrate the bony anatomy and any invasion of bone.
- The course of the internal carotid artery in the PPS should be identified. Retropharyngeal ICA is a contraindication to robotic resection.
- Positron emission tomography (PET)-CT scan is also useful in recurrent cancer as some posttreatment changes may mimic active tumor infiltration.
- PET-CT can also help to rule out distant metastasis that made cure impossible.

Indications

- Small central NPC recurrent after radiotherapy/chemoradiation
- Other cancers of the nasopharynx
- Small benign lesions in the nasopharynx
- Minimal extension to the PPS
- Minimal erosion of the cortex of the clivus
- Cancer invading the prevertebral muscles or the floor of the sphenoid sinus

Contraindications

- Cancer with lateral extension beyond the lateral pterygoid plate
- Cancers invading the posterior or lateral wall of the sphenoid sinus
- Large rT3 tumors with gross invasion of the clivus
- rT4 tumors with intracranial extension
- Cancers abutting or close to ICA (<1 cm)
- Cancers with anterior extension to the nasal cavity or pterygopalatine fossa. Most cancers with nasal extension will require endonasal endoscopic approach.
- Ectatic ICA located close to the lateral or posterior wall of the nasopharynx
- Presence of metastatic retropharyngeal lymph nodes adherent to the ICA
- Patient with trismus (for transoral approach)

The indications for selecting the robotic approach for nasopharyngectomy are similar to selecting an endoscopic approach. The operation is usually performed for small local recurrence of NPC after radiotherapy, though it can also be used to resect other benign and malignant tumors in the nasopharynx. The tumor should preferably be centrally located and small. The most lateral aspect of the cancer should be medial to the lateral pterygoid plate as the current generation of surgical robot prohibits lateral access without extensive removal of the pterygoid process and pterygoid plates. As the current generation of robots lacks tactile sensation, intraoperative identification of the ICA may be difficult, and inadvertent injury is possible. Cancer with close proximity (<1 cm distance) to the ICA should not be operated on with a surgical robot.

Occasionally the local recurrence may be associated with recurrence in the superior retropharyngeal lymph nodes, or the patient may present with metastasis to an isolated retropharyngeal lymph node. Unlike in radiation-naïve patients, these retropharyngeal lymph nodes are usually adherent to or even partially encase the ICA. Removal of these lymph nodes will require sharp dissection of the lymph nodes from the ICA. Since the surgical robot lacks tactile feedback, this type of dissection should not be performed with a surgical robot.

Preoperative Preparation

- Otitis media with effusion frequently occurs after nasopharyngectomy. A preoperative pure tone audiogram as a baseline is useful for future reference.
- Plasma Epstein-Barr virus (EBV) DNA titer has prognostic implications in NPC and is useful for monitoring the response to treatment. A preoperative titer should be obtained for future reference.
- Dental consultation—loose or carious teeth should be removed prior to the operation
- The diagnosis of recurrent cancer should be confirmed with a biopsy prior to the definitive operation.
- The implications of operating without a positive histological diagnosis should be discussed with the patient.

OPERATIVE PERIOD

Anesthesia

- The procedure is usually performed under general anesthesia. The patient should be intubated orally with a Ring-Adair-Elwyn (RAE) tube. The tube should be taped to the midline of the lower lip.
- Alternatively, tracheostomy can be performed first if prolonged edema in the upper aero-digestive tract is expected or if severe trismus prevents adequate opening of the mouth.
- Blood products should be readily available during the operation.

Positioning

- Patient is placed supine with neck slightly extended. The patient cart of the surgical robot will be docked at the head end of the patient. The bedside surgeon can be positioned on either side of the patient.

Perioperative Antibiotics Prophylaxis

- Standard antibiotics prophylaxis regime for intraoral surgery should be employed.

Monitoring

- Invasive and noninvasive monitoring for blood pressure, urine output, and central venous pressure should be employed during the operation.

Instruments to Have Available

- A Dingman retractor or Crowe-Davis retractor for opening the mouth
- Endoscopic holder or similar device to hold the mouth retractor in position
- Five-millimeter Maryland and 5-mm monopolar cautery spatula robotic instruments. Occasionally an 8-mm bipolar cautery scissor can be used in lieu of the 5-mm monopolar cautery for dissection.
- Zero-degree and 30-degree robotic telescopes
- Yankauer suction or similar metal suction device for the bedside surgeon to evacuate smoke and blood from the operative field

Key Anatomic Landmarks

- The nasopharynx is situated posterior to the nasal cavities, about 9 to 10 cm behind the nostril. It is a box-shaped cavity surrounded by bony walls on all sides except the inferior aspect where it opens to the oropharynx. Fig. 42.1 is a line drawing showing the cross-section anatomy of the nasopharynx and adjacent structures.

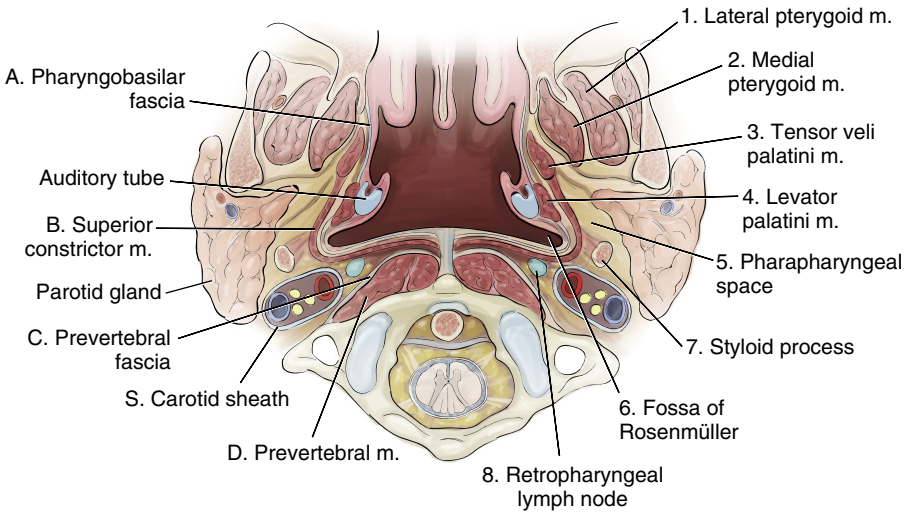

Fig. 42.1. Cross-section anatomy of the nasopharynx and the adjacent structures. A, Pharyngobasilar fascia; B, Superior constrictor muscle; C, Prevertebral fascia; D, Prevertebral muscles; S, Carotid sheath; 1, Lateral pterygoid muscle; 2, Medial pterygoid muscle; 3, Tensor veli palatini muscle; 4, Levator palatini muscle; 5, Parapharyngeal space; 6, Fossa of Rosenmüller; 7, Styloid process; 8, Retropharyngeal lymph node.

- The floor of the sphenoid sinus forms the roof and slants downward posteriorly as the clivus to form the posterior wall.
- The inferior aspect of the posterior wall is formed by the vertebral bodies of C1 and C2, with prevertebral muscles covering it. The roof and superior aspect of the nasopharynx are covered by mucosa and periosteum with no muscular layer.
- Posterior edge of the vomer denotes the midline and the anterior extent of resection
- The cartilaginous Eustachian tube penetrates the lateral nasopharynx wall to open into the nasopharynx. A recess, the fossa of Rosenmüller, is formed by the posterior crus of the Eustachian tube cartilage and the posterior nasopharyngeal mucosa. NPC frequently arises from this fossa.
- Fossa of Rosenmüller—recurrent cancers are often found deep in the fossa. The entire ipsilateral fossa and the ipsilateral Eustachian tube cartilage should be resected enbloc to ensure completeness.
- Medial pterygoid plate—the buccopharyngeal fascia should be detached from the medial pterygoid plate to remove the entire lateral nasopharyngeal wall.
- Prevertebral fascia—Resection should always include the prevertebral fascia as the deep margin. If imaging shows that the cancer has invaded the prevertebral muscles, then part of the muscles would need to be resected enbloc with the tumor.
- Lateral to the lateral nasopharyngeal wall is the PPS. NPC frequently extends to this area.
- The lymph nodes in the retropharyngeal space are the first echelon of lymphatic spread.
- The anatomy of the ICA in the PPS is highly variable. The ICA can abut on the fossa of Rosenmüller and travel in a medial course just deep to the mucosa of the lateral nasopharynx. It is imperative to trace the course of the ICA on imaging studies and ascertain that the ICA is not in close proximity with the intended resection area to avoid inadvertent injury.

Prerequisite Skills

- Basic transoral robotic surgical skills—certification for console surgeon in TORS. Experience with TORS will facilitate docking of the robot and manipulation of the robotic arms.
- Endoscopic endonasal surgery skills—It is not uncommon to perform the superior resection with endoscopic endonasal approach. A nasoseptal flap (NS) is frequently required for coverage of the raw area after resection. Proficiency in endoscopic endonasal surgery is required to perform both procedures.

Surgical Technique

The surgical robot can be deployed by either the transoral, transnasal, or a combined transnasal and transoral route.[1] For the transoral route, the soft palate will be an obstacle for the robotic arms in approaching the nasopharynx. In the transnasal approach, bones of the medial wall of the maxilla and nasal septum need to be removed to increase the space for deployment of the robotic instruments.[2] There is more experience with the transoral route in the literature so that the discussion in this chapter will focus on the transoral route.

- A Dingman or Crowe-Davis retractor is placed to open the mouth and retract the tongue inferiorly. A plastic lip retractor is placed around the upper and lower lips to prevent injury to the lips by the robotic instruments.
- There are generally three techniques to manage the soft palate in deploying the surgical robot via a transoral approach: (1) midline palatal split, (2) palatal suspension, and (3) lateral palatal flap technique. The approach used most commonly includes the midline palatal split technique.[3]
- Midline palatal split approach
  - An incision is made extending from the incisor foramen to the uvula. The mucosa of the hard palate is incised down to the bony hard palate, and the soft palate is divided.
  - The soft palate is detached from the hard palate, and sutures are placed in the mucosa of the hard palate and through the entire soft palate. Using these sutures, the palate can be retracted laterally, thereby exposing the nasopharynx.
  - The approach is ideal for centrally located cancers, but the lateral reach of the instruments can be blocked by the retracted soft palate. Figs. 42.2 and 42.3 demonstrate the midline palate split incision and the view of the nasopharynx from the telescope of the da Vinci robot.
  - A 12-mm, 0-degree, or 12-mm 30-degree upward facing telescope can be used for visualization.
  - There is a slight risk of a postoperative palatal fistula formation.
- Lateral palatal flap approach[4]
  - More suitable for laterally positioned tumor
  - From the anterior midline, an incision is placed in the inner aspect of the hard palate extending to the posterior hard palate, just medial to the alveolar mucosa. The incision is extended through the soft palate toward the superior pole of the tonsil (Fig. 42.4).

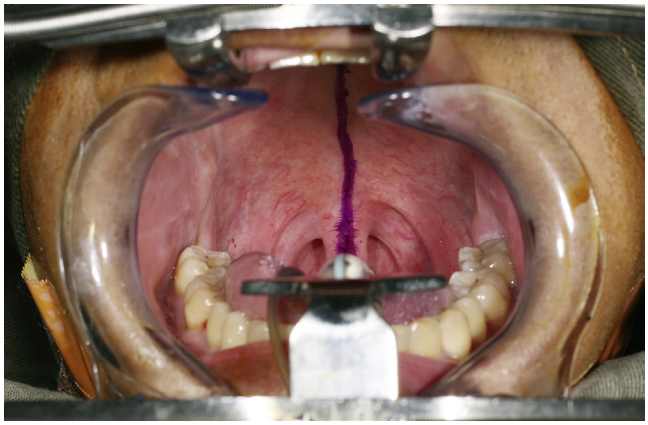

Fig. 42.2. Incision for the midline palatal split approach.

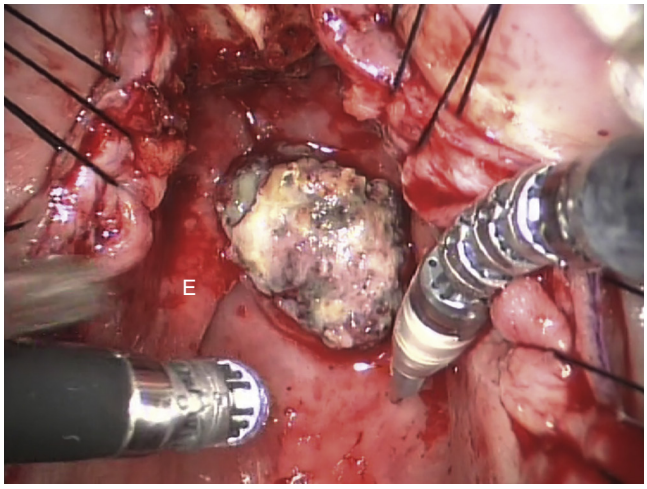

Fig. 42.3. View of the nasopharynx with the tumor in the central part after the soft palate was split in the midline. E denotes the right eustachian tube cushion.

- The entire mucosa of the hard palate is then elevated from the bone, and the greater palatine vessels are ligated and divided.
- The soft palate is detached from the hard palate and retracted toward the contralateral side using silk sutures. Care must be taken not to injure the contralateral greater palatine vessels as they are now the sole blood supply to the palatal mucosa.
- The entire ipsilateral nasopharynx and PPS can now be exposed and reached by the robotic instruments.
- A 12-mm 30-degree upward facing telescope is usually used since the angled telescope that can be turned 90 degrees laterally to visualize the PPS posterior to the medial pterygoid plate (Fig. 42.5).
- The disadvantage of this approach is the risk of palatal dysfunction due to division of the tensor veli palatini muscle, the risk of a palatal fistula, and middle ear effusion.

- Palatal suspension technique
  - Suitable for centrally and inferiorly located cancers
  - The approach does not divide the entire soft palate; instead the soft palate is elevated anteriorly using silk sutures.
  - To increase the extent of elevation, incisions are made in the superior aspect of the posterior pillar of the tonsils (Fig. 42.6).

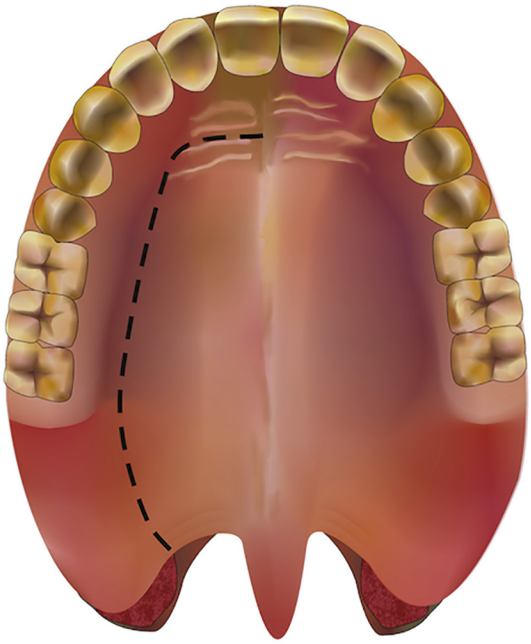

Fig. 42.4. Diagram demonstrating the incision for a left lateral palatal flap approach. *(From Tsang RK, Mohr C: Lateral palatal flap approach to the nasopharynx and parapharyngeal space for transoral robotic surgery: a cadaveric study. J Robot Surg 7:119-123, 2013.)*

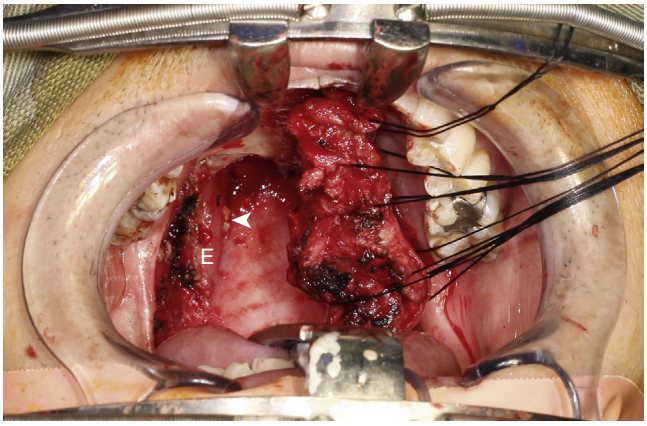

Fig. 42.5. View of the nasopharynx with the right lateral palatal flap approach. E denotes the right eustachian tube cushion and the *white arrowhead* points to the tumor in the right fossa of Rosenmüller.

  - A 30-degree telescope facing upwards can then be inserted transorally to visualize the nasopharynx. Robotic instruments with the Endowrist can then reach the nasopharynx when deployed though the mouth.
  - Unfortunately the view of the nasopharynx is constrained, and the reaches to the upper nasopharynx superiorly and to the PPS laterally are difficult (Fig. 42.7).
  - The advantage is that there is minimal disturbance of palatal function.
- Resection of the cancer
  - After exposure of the nasopharynx, the patient cart of the surgical robot is docked in the head end of the patient with robotic arms deploying in the oral cavity from inferior to superior direction.
  - The telescope arm is deployed in the midline and the two robotic instrument arms from the left and right sides. Fig. 42.8 is the floor plan of the operating room showing head docking of the patient cart, and Fig. 42.9 is the view of the mouth after deployment of the telescope and robotic arms.

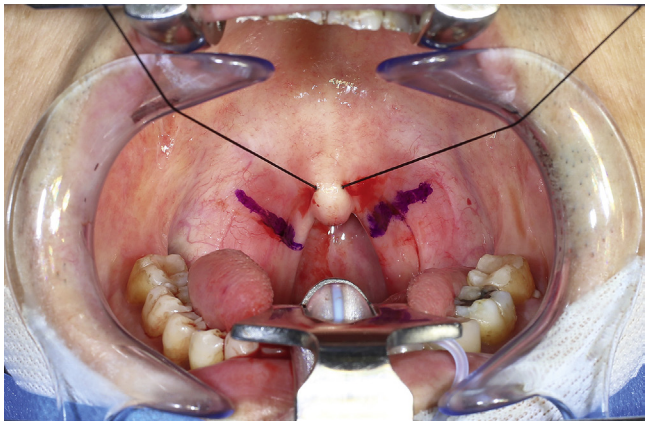

Fig. 42.6. Incisions in the posterior tonsillar pillars for the palatal suspension approach. The soft palate and uvula are suspended anteriorly with sutures.

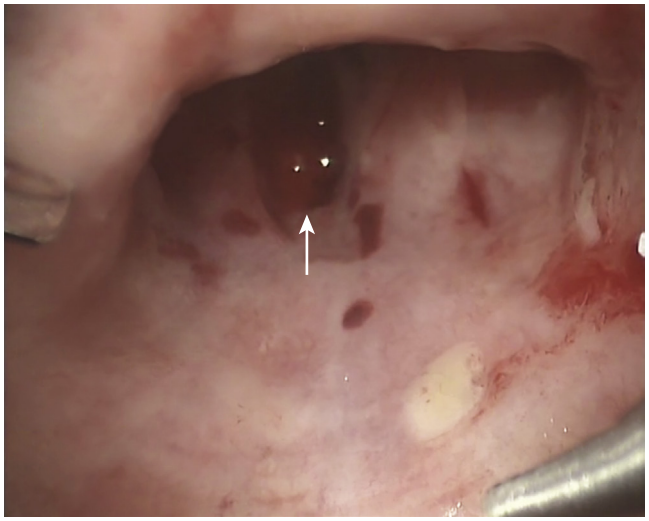

Fig. 42.7. View from a 30-degree telescope of the nasopharynx using the palatal suspension approach. *Arrow* points to the recurrent cancer in the inferior aspect of the posterior nasopharynx.

- Resection is usually performed with 5-mm robotic instruments due to space constraints. Five-millimeter Maryland forceps and 5-mm monopolar diathermy spatula are the usual choices.
- Alternative instruments included the 5-mm monopolar cautery hook, 8-mm monopolar scissors, or 8-mm bipolar Maryland forceps.
- A one centimeter mucosal margin is first marked with the cautery.
- Dissection usually proceeds from inferior to superior.
- The mucosa and superior constrictor are incised down to the prevertebral fascia. Depending on the findings on imaging, a cuff of prevertebral muscles or just the prevertebral fascia is resected with the mucosa of the nasopharynx.
- The Maryland forceps is used to grasp the resection specimen and provide counter-traction for the dissection to proceed from an inferior to superior direction. Fig. 42.10 demonstrates the dissection of the mucosa of the nasopharynx from inferior to superior.
- Depending on the cancer involvement of the fossa of Rosenmüller, the entire cartilaginous Eustachian tube or only the part of the posterior crus is resected enbloc.

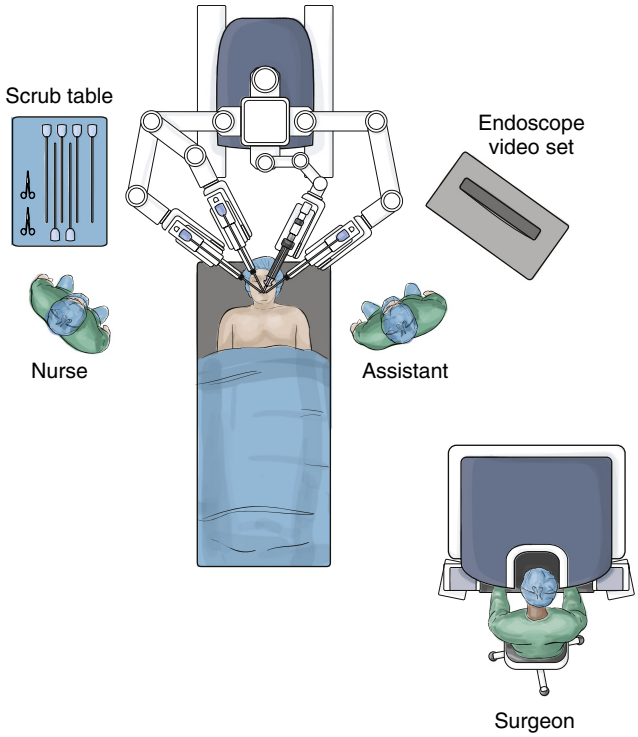

Fig. 42.8. Floor plan of the operating room showing docking of the patient cart from the head end of the patient. *(Modified from Cho HJ, Kang JW, Min HJ, et al: Robotic nasopharyngectomy via combined endonasal and transantral port: a preliminary cadaveric study. Laryngoscope 125:1839–1843, 2015.)*



Fig. 42.9. Docking of the patient cart from the head end with robotic instruments deployed.

- For cancers involving the entire fossa of Rosenmüller, the entire cartilaginous Eustachian tube should be resected.
- Alternatively, for cancers that just reach the fossa, only the posterior crus should be removed as a lateral margin.
- To resect the entire cartilaginous Eustachian tube, the mucosa and pharyngobasilar fascia are incised over the attachment of the medial pterygoid plate. The Maryland forceps is then used to grasp the Eustachian tube cartilage, retracting it medially.
- Care must be taken not to extend the dissection too far laterally and posteriorly, as this may injure the ICA.
- Dissection in the PPS may cause bleeding from the pterygoid venous plexus, and this bleeding may require bipolar cautery coagulation applied by the bedside surgeon.

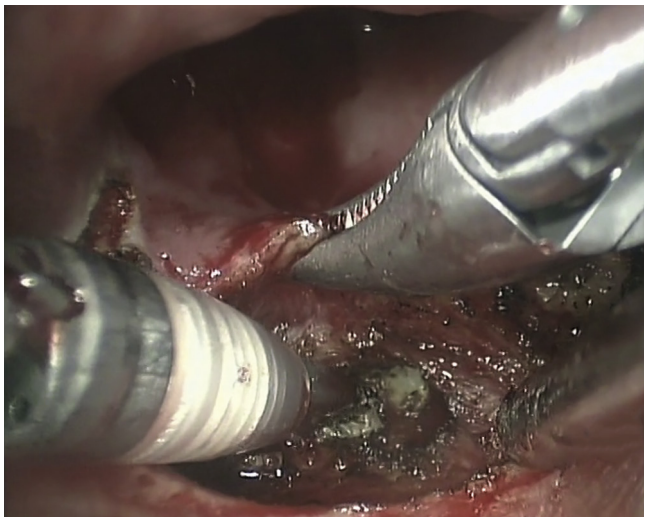

Fig. 42.10. Dissection of the nasopharynx mucosa with the surgical robot proceeding from inferior to superior fashion.

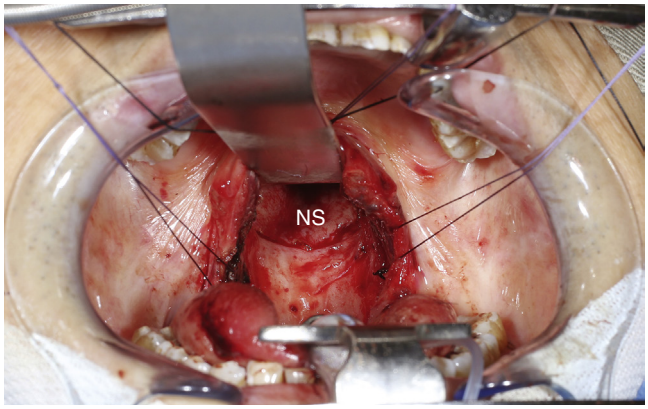

Fig. 42.11. The raw area of the nasopharynx was reconstructed with a nasoseptal flap. NS, nasoseptal flap.

  - Once the parapharyngeal tissue is mobilized medially, the Eustachian tube cartilage can be divided close to the bony canal.
  - Care must be taken not to bring the dissection too far laterally, as the ICA is located only a few millimeters lateral to the bony Eustachian canal.
  - If a 30-degree telescope is used, it can be rotated to improve the lateral view when dissecting in the PPS.
  - The prevertebral muscles insert into the inferior aspect of the clivus and in the superior aspect of the nasopharynx. The mucosa of the nasopharynx attaches directly to the periosteum of the clivus bone. The Maryland forceps are used to grasp the edge of the incision in the mucosa of the nasopharynx, and the monopolar spatula can be used to mobilize the mucosa of the nasopharynx off the clivus using blunt and sharp dissection down toward the cancer.
  - The dissection converges toward the center of the resection specimen, and the entire specimen can be delivered through the oral cavity.
- Combined with endoscopic resection
  - Cancers situated in the roof of the nasopharynx or extending to the sphenoethmoidal recess will require removal of the floor and anterior wall of the sphenoid sinus.
  - This part of the resection is performed with endoscopic instruments. The inferior dissection is performed with the surgical robot, and the specimen is left attached to the roof of the nasopharynx. The surgical robot is then undocked, and conventional endoscopic endonasal instruments are used for the second part of the dissection.[5] The anterior wall of the sphenoid sinus and the rostrum is then removed using a Kerrison rongeur or endoscopic bur until the specimen is freed from its superior attachment and removed.
  - Mucosal margins should be harvested from the edge of the resection and sent for frozen section analysis. Further resection should be attempted if the frozen section analysis reports suspicious or positive margins.
- Coverage of the surgical field
  - Coverage of the nasopharynx is important in order to prevent osteoradionecrosis. Osteoradionecrosis is difficult to manage and severely impacts the patient's quality of life. Conventionally, the raw areas are covered with a free graft using mucosa of the inferior turbinate.
  - To improve the reliability of the coverage, an NS flap can be harvested and rotated inferiorly to cover the raw clivus bone.[6] Fig. 42.11 demonstrates the nasopharynx reconstructed with an NS.
  - The flap should be secured in place with a nasal tampon or urinary catheter balloon placed in the post-nasal space for 3 to 5 days.
- Closure of palatal wound
  - Closure of the palatal wound is important to restore normal function of the palate and to prevent formation of a palatal fistula.
  - Holes should be drilled in the posterior edge of the hard palate and sutures placed through them so that the soft palate can be reattached to the hard palate. The palatal wound should be closed with absorbable sutures in three layers, the nasopharyngeal mucosal layer, the muscular layer, and the soft palate mucosal layer.
  - For the lateral palatal flap technique, the tensor veli palatini muscle should be re-approximated carefully to restore the muscular function of the soft palate. A feeding tube should be inserted for nutritional support. Fig. 42.12 shows the closure of the palatal incision at the conclusion of the operation.

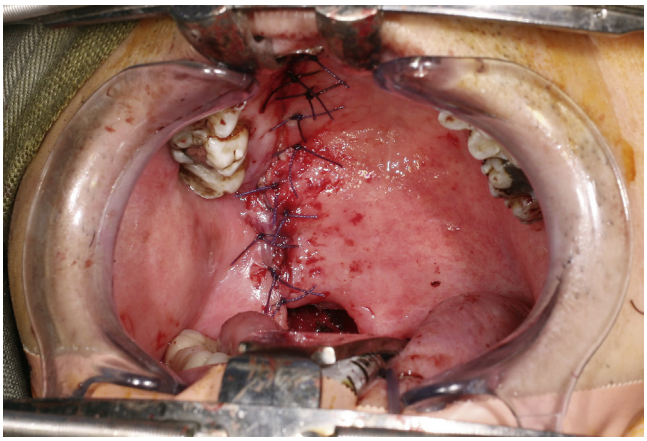

Fig. 42.12. The appearance of the palate following the right lateral palatal flap approach.

Operative Risks

- Bleeding from pterygoid venous plexus—Bleeding from the venous plexus is better controlled with bipolar cautery from the bedside surgeon. Alternatively, temporary packing and use of hemostatic agents can stop the bleeding.

- Injury to ICA—If ICA injury is suspected or has occurred, the procedure should be terminated, and an angiogram should be performed. The carotid injury is then managed by angiographic approach by the interventional radiologist.
- Upper airway obstruction from soft tissue swelling—The patient should not be extubated immediately after the procedure. Instead, the upper airway should be observed for any signs of swelling. If swelling is present, a tracheostomy should be performed. Alternatively, the patient can be left intubated and observed in the ICU for a period of time before extubation.

Common Errors in Technique

- Failure to employ a split palate approach—Although it is tempting to perform the surgery without splitting the palate, a palatal suspension technique is only feasible in very favorable anatomy and a central cancer in the inferior aspect of the nasopharynx. A split palate approach will markedly improve the visualization of the cancer and increase the space for the manipulation of the robotic arm.
- Failure to use a 30-degree telescope—0-degree telescope gives a more direct view and is easier for the less experienced in manipulating the robotic instruments. The 30-degree telescope offers visualization around the corners like the viewing around medial pterygoid plates. Be prepared to switch to a 30-degree telescope when operating in the PPS.
- Failure to close the palatal incision properly in three layers—Careful closure of the soft palate incision in three layers (both mucosal layers and the muscle layer) is important to restore the palatal movement and prevent palatal fistula formation. The patient should also have nothing by mouth for 7 to 10 days to allow the wound in the palate to heal.

POSTOPERATIVE PERIOD

Postoperative Care

- Patients whose soft palate has been divided should be kept Nil per oral (NPO) and fed through a feeding tube for 7 to 10 days until the soft palate has healed completely.
- Antibiotics are given until the nasal packing is removed.
- After the nasal packing is removed, the patient should be instructed to perform nasal irrigations regularly using normal saline.
- Gentle endoscopic cleaning of the nasopharynx should be performed by the surgeon every 1 to 2 weeks until the nasopharynx has completely epithelized.
- Dissection around the medial pterygoid muscle can lead to fibrosis and trismus. Mouth opening exercise should be started in the early postoperative period. An assistive device like Therabite (Atos Medical Inc., Sweden) can help patients to achieve optimal mouth opening.

Complications

Intraoperative Complications

- Injury of the ICA is the one of the most serious complications. It will be impossible to control bleeding from the ICA with robotic techniques, and the surgeon has to rely on packing and angiographic techniques to control the bleeding. Conversion to an open nasopharyngectomy approach is also time consuming.
- As the surgeon is unable to palpate for the ICA in the PPS, identifying the location of the ICA in robotic nasopharyngectomy is more difficult than open nasopharyngectomy. Therefore, to prevent inadvertent ICA injury, in cases selected for robotic nasopharyngectomy, the cancer should not be in proximity to the ICA, preferably more than 1 cm away.
- The other source of bleeding is venous bleeding from the pterygoid plexus in the medial pterygoid muscles. This type of venous bleeding can be troublesome to control and can give rise to significant blood loss. Bipolar cautery by the bedside surgeon or with the 8-mm bipolar Maryland forceps can usually stop the bleeding.
- Alternatively, packing with adrenaline-soaked gauze can reduce the blood flow and allow accurate application of cautery. Application of hemostatic agents such as fibrin glue can also be helpful in stopping venous bleeding.
- Inadvertent injuries to the structures in the oral cavity such as the teeth and the lips can occur if the surgeon is not careful during the procedure. The bedside surgeon should also be vigilant in observing any movements of the robotic instruments that can cause injury and warn the console surgeon as the console surgeon would not be aware of the movements of the robotic instruments outside of the oral cavity.
- Edema of the airway and tongue is a potential life-threatening complication in any transoral robotic procedure. Patients undergoing a robotic nasopharyngectomy are especially at risk as they usually have had prior radiation therapy and the procedure typically takes 3 to 4 hours, longer than robotic oropharyngectomy.
- Retraction on the tongue should be released during procedures that do not require tongue retraction such as elevating NS or drilling out the sphenoid sinus.
- At the conclusion of the procedure, the surgeon and the anesthetist should inspect the airway together and decide whether or not to proceed to extubation. If there is any concern about the adequacy of the airway, the patient should be kept intubated overnight, or a tracheostomy should be performed.

Long-Term Complications

- Palatal wound dehiscence and fistula formation. To prevent the formation of a palatal fistula, the soft palate wound should be carefully approximated in a three-layer, tension-free closure. The patient should be kept NPO and avoid excessive swallowing for a period of time to prevent dehiscence of the palatal wound.
- If the dehiscence is detected early, it can be repaired primarily; otherwise, a palatal fistula may need a rotational mucosal flap to repair it after the palate has healed.
- Even in the absence of a palatal fistula, patients may experience minor velopharyngeal incompetence especially when drinking fluids. This is due to the retraction of the soft palate during the surgery.
- Osteoradionecrosis of the skull base is a serious complication after nasopharyngectomy in patients who have had radiation to the nasopharynx. Osteoradionecrosis of the skull base is difficult to treat, and every effort should be made to prevent its occurrence.
- Exposing bone during the resection should be avoided, and a cuff of prevertebral muscles should be left covering the inferior aspect of the clivus and C1-C2 if the tumor has not grossly invaded the prevertebral muscles.
- Coverage of the raw surface of the clivus with an NS is better than coverage with a free soft tissue graft.
- The surgeon should clean the operative site regularly and débride the necrotic tissue and crusts in the nasopharynx to prevent local infection.
- Otitis media with effusion can occur if the Eustachian tube is resected.

Alternative Management Plan

- Nasopharyngectomy via endoscopic endonasal approach—Cases suitable for robotic nasopharyngectomy are also amendable to extended endoscopic resection. The advantages of robotic surgery will be lost, but the cost would also be lower. This approach requires a team of surgeons experienced in extended endoscopic nasal surgery.
- Nasopharyngectomy via various open approaches—For recurrent cancers that are contraindicated for robotic surgery, the cancers may still be amendable to resection via open approaches. The major advantage of open approaches is the better localization of the internal carotid artery and control of bleeding in case of catastrophic hemorrhage.
- Second course of radiotherapy—A second course of radiotherapy for treatment of recurrent NPC is possible with tolerable toxicities especially if the patient was treated more than 1 year previously and was treated with advanced three-dimensional techniques such as intensity-modulated radiotherapy (IMRT). The complication of a second course of radiotherapy is increased radiation toxicities. One wonders about the propriety of using a treatment modality for a second time that did not cure the cancer the first time. Surgical treatment avoids the additional radiation toxicities and thus should be considered unless the patient is not suitable for surgery.

Evidence-Based Question

How does robotic nasopharyngectomy compare with endoscopic nasopharyngectomy in terms of local control and morbidities?

Robotic surgery in the head and neck should be considered an extension of endoscopic head and neck surgery, in which the surgical robot improves the dexterity of the endoscopic surgeon by adding back the degrees of freedom of movements lost in conventional endoscopic surgery. This is the same for robotic nasopharyngectomy. There are no randomized trials comparing robotic versus endoscopic nasopharyngectomy, and there is only one case series reporting the early results of robotic nasopharyngectomy.[7] The local control rate in either operation is comparable.

In terms of morbidities, both operations should be similar except for the complications from a palate split that may be necessary in some transoral robotic approaches. Robotic nasopharyngectomy tends to be faster as the robotic arms confer additional dexterity.

These operations are not mutually exclusive. The transnasal endoscopic approach is complementary to the transoral robotic approach in most cases as the superior aspect of the cancer is better approached from the nasal cavities, and bone removal tools are only available for the endoscopic approach. The robotic approach then can be used to remove the inferior and lateral part of the cancer with the additional advantages offered by the surgical robot.

Editorial Comment

The case selection of robotic nasopharyngectomy is similar to endoscopic nasopharyngectomy, and the survival outcome should be comparable. As robotic nasopharyngectomy is a relatively new procedure, and there are limited cases suitable for robotic nasopharyngectomy, the literature on outcomes of robotic nasopharyngectomy is rare. There is only one case series of 12 patients with short follow-up. The estimated 2-year local control rate was 86% and 2-year overall survival was 83%.[7] This is similar to the results of most endoscopic nasopharyngectomy series.[8]

The current generation of surgical robots is not designed for head and neck surgery and is too bulky to work in the head and neck area. A surgical robot called the Medrobotic Flex System has recently become available. It is designed with flexible and smaller arms that may be adapted for head and neck surgery application, including robotic nasopharyngectomy. To date, early preclinical trials of these new generation robots have shown promising results.[9,10] In the future, with smaller flexible robots, a robotic nasopharyngectomy may be performed without the need to split the soft palate, reducing the morbidity of the operation.

Raymond K. Tsang

Access the review questions online at http://www.expertconsult.com



REFERENCES

1. Dallan I, Castelnuovo P, Montevecchi F, et al. Combined transoral transnasal robotic-assisted nasopharyngectomy: a cadaveric feasibility study. Eur Arch Otorhinolaryngol 2011;269(1):235–339.
2. Cho HJ, Kang JW, Min HJ, et al. Robotic nasopharyngectomy via combined endonasal and transantral port: a preliminary cadaveric study. Laryngoscope 2015;125(8):1839–1843.
3. Wei WI, Ho WK. Transoral robotic resection of recurrent nasopharyngeal carcinoma. Laryngoscope 2010;120(10):2011–2014.
4. Tsang RK, Mohr C. Lateral palatal flap approach to the nasopharynx and parapharyngeal space for transoral robotic surgery: a cadaveric study. J Robot Surg 2013;7(2):119–123.
5. Tsang RK, Ho WK, Wei WI. Combined transnasal endoscopic and transoral robotic resection of recurrent nasopharyngeal carcinoma. Head Neck 2012;34(8):1190–1193.
6. Tsang RKY, Ho WK, Wei WI, et al. Transoral robotic assisted nasopharyngectomy via a lateral palatal flap approach. Laryngoscope 2013;123(9):2180–2183.
7. Tsang RK, To VS, Ho AC, et al. Early results of robotic assisted nasopharyngectomy for recurrent nasopharyngeal carcinoma. Head Neck 2015;37(6):788–793.
8. Ho AS, Kaplan MJ, Fee WE, et al. Targeted endoscopic salvage nasopharyngectomy for recurrent nasopharyngeal carcinoma. Int Forum Allergy Rhinol 2012;2(2):166–173.
9. Richmon JD. Transoral palate-sparing nasopharyngectomy with the Flex® system: preclinical study. Laryngoscope 2015;125(2):318–322.
10. Tsang RK, Holsinger FC. Transoral endoscopic nasopharyngectomy with a flexible next-generation robotic surgical system. Laryngoscope 2016;126:2257–2262.

REVIEW QUESTIONS

1. Which of the following is not an indication for robotic nasopharyngectomy?
   a. Small recurrent NPC in the midline but invading the sphenoid floor
   b. Small recurrent NPC confined in the left fossa of Rosenmüller
   c. Two-centimeter benign salivary gland tumor in the nasopharynx without extending to the PPS space
   d. Recurrent NPC in the left PPS involving the foramen rontondum

2. Which of the following is a complication after robotic nasopharyngectomy?
   a. Palatal fistula
   b. Nasal obstruction
   c. Ectropion
   d. Nonunion of osteotomy

3. Which of the following investigations is NOT necessary before deciding for robotic nasopharyngectomy for recurrent NPC?
   a. Contrast CT scan of the nasopharynx
   b. Contrast MRI scan of the nasopharynx
   c. HPV status of the original cancer
   d. Biopsy of the suspected lesion

43 Maxillary Swing/Transpalatal/Midface Degloving With Le Fort I Osteotomy Approach for Nasopharyngectomy

Sheng-Po Hao

INTRODUCTION

Nasopharyngeal carcinoma (NPC) is a squamous cell carcinoma of an undifferentiated type. This cancer is endemic among Chinese, having the highest incidence of 10 to 20 per 100,000 for men and 5 to 10 per 100,000 for women. It is sometimes called the "Cantonese Cancer" because of its prevalence as one of the most common cancers of the head and neck among Chinese. The most common site of origin of NPC is from the epithelial lining of the area posteromedial to the medial crura of the Eustachian tube opening in the nasopharynx, which is also called the fossa of Rosenmüller.[1]

Several serologic markers have become useful as a means of screening, diagnosing, and monitoring NPC after establishing that it is closely related to the Epstein-Barr virus (EBV), a double-stranded DNA virus. NPC has since become a model for EBV viral carcinogenesis after studies showed that most NPC cancer cells express EBV proteins and carry the clonal EBV genomes. Screening in the general population can now be done using serologic markers, such as EBV VCA immunoglobulin A (IgA) and DNase, whereas reverse transcription polymerase chain reaction (RT-PCR) methods measure EBV DNA copy numbers in plasma to monitor treatment response and early detection of local recurrence.

To summarize:

1. For general population screening, serologic diagnosis can be made using EBV VCA IgA.
2. For early detection of local recurrence, a nasopharyngeal swab should be taken for LMP-1 gene detection.
3. For monitoring treatment response and to detect possible recurrence, RT-PCR–based plasma cell–free EBV DNA detection should be used.
4. Currently available therapeutic modalities for NPC are radiation therapy (RT), chemotherapy, or a combination of both. Effective local control is more than 80% using the current RT techniques because of the high radiosensitivity of NPC. A high cure rate is seen among patients with early-stage cancer who undergo RT. Cisplatin-based chemoradiotherapy with or without neoadjuvant chemotherapy has demonstrated significant survival improvement and is currently the standard treatment strategy for patients with advanced locoregional disease.[1]

Despite being a radioresponsive tumor, 10% to 30% of NPC patients develop local failure in the nasopharynx after the initial RT treatment. Whether it is persistence or recurrence after the initial radiation therapy (RT)/concurrent chemoradiation therapy (CCRT), salvage nasopharyngectomy is the treatment of choice. Proceeding with a second course of RT will only expose the patient to the risk of developing osteoradionecrosis (ORN) of the skull base, a potentially fatal complication of high-dose RT, without any assurance that the previously treated NPC cells will respond. Salvage nasopharyngectomy results in better outcomes than most of the published literature on re-radiation.

However, nasopharyngectomy requires skill and training and has posed a real challenge for head and neck surgeons. With the advances in skull base surgery, it is now possible to effectively control NPC recurrence or persistence using salvage nasopharyngectomy with acceptable mortality and morbidity.[2]

KEY OPERATIVE LEARNING POINTS

- Try to preserve or reestablish the blood supply to the bone when performing a facial bone disassembly.
- Perform a medial maxillectomy and posterior septectomy to improve exposure and increase the area of working space.
- During resection, the deep margin is marked by the pharyngobasilar fascia while making sure to remove as lateral as possible including the Eustachian tube cartilage.
- Depending on the extent of the cancer, several different approaches may be used.
- The use of rigid three-point bone segment fixation may prevent nonunion or ORN.

PREOPERATIVE PERIOD

Local failure (persistence and recurrence in the nasopharynx) occurs in 16% to 48% of patients with NPC after initial RT. Salvage nasopharyngectomy has become the mainstay of treatment after RT failure, and the key to a successful surgery is proper patient selection. Preoperative period is essential to ensure that the patient is eligible for salvage nasopharyngectomy.

Before proceeding with nasopharyngectomy, all patients require thorough medical history including medical status, physical examination, as well as endoscopic examination. Firstly, it must be established that (1) these patients do have local recurrence or persistent NPC by performing biopsy(s) of the primary site, (2) ultrasound and possible guided fine-needle aspiration biopsy for any suspicious regional recurrence should be used, and (3) there is no distant metastasis. It is advisable to use Positron emission tomography–computed tomography (PET-CT) to exclude the possibility of distant metastasis. MRI with its excellent soft tissue resolution may also be used to evaluate the extent of the cancer and help to plan the surgical approach accordingly.

Other important preoperative preparation includes blood group and matched packed cells and preoperative antibiotic. Patients with pre-existing significant comorbidities should receive special attention. Anticoagulants or antiplatelet medications should be withheld (if possible) before salvage nasopharyngectomy.

History

1. History of present illness
   a. Nasal symptoms: blood-stained nasal discharge, nasal blockage
   b. Aural symptoms: ear blockage, hearing loss, and otorrhea

c. Mass in the neck
d. Skull base and cranial nerve involvement
   1) Intractable headache
   2) Sixth cranial nerve involvement, which will result in abducens palsy
   3) Unilateral facial numbness from involvement of the fifth cranial nerve
e. Symptoms suggesting distant metastasis
f. Weight loss, nutritional status
g. Smoking

2. Past medical history
   a. Previous radiotherapy with or without chemotherapy
   b. Previous surgery for NPC
   c. Pulmonary disease, hypertension, diabetes, or ischemic heart disease
   d. Immunosuppression (e.g., acquired immunodeficiency syndrome [AIDS])
3. Medications
   a. Anticoagulants
   b. Allergies to antibiotics or analgesia

Physical Examination

1. Nasal cavity and nasopharynx
   a. Endoscopic examination of the nasopharynx may reveal a mass in the fossa of Rosenmüller and sometimes a small submucosal swelling.
   b. Determine extent of the cancer.
      1) Lateral extension
         a) Eustachian tube
         b) Torus tubarius
      2) Roof of nasopharynx and posterior choanae
      3) Inferior extension to oropharynx
2. Examination of the neck
   a. Palpate both sides of the neck for the presence of cervical metastases.
3. Examination of the skull base and cranial nerves
4. Trismus
   a. Anticipate difficult intubation. May require a tracheostomy
5. Examination of the ears
   a. Middle ear effusion
6. Examine oral cavity, pharynx, and larynx for synchronous primaries.
7. General health
   a. Nutrition
   b. Cardiovascular
   c. Respiratory
   d. Abdominal

Imaging

1. Magnetic resonance imaging (MRI)
   a. Superior soft tissue resolution and tumor delineation
      1) Parapharyngeal space or infratemporal fossa
      2) Intracranial extension
      3) Perineural invasion
      4) Deep invasion to the vertebral body
      5) Vascular involvement (carotid artery, cavernous sinus)
   b. Presence of cervical metastasis
2. PET-CT scans
   a. Restaging
   b. Exclude cervical metastasis.
   c. Exclude distant metastasis (bone, lung, liver).
3. CT scan
   a. Not required in all cases
   b. MRI is preferred, if available
4. Chest radiograph
   a. Lung metastases
   b. Pulmonary and cardiac status
5. Ultrasound of the liver

Indications

- Recurrent cancer confined to the nasopharynx
- Modified/classical facial translocation for cancer with lateral extension medial to the foramen ovale
- Combined preauricular infratemporal subtemporal approach together with a transfacial/facial translocation approach for rNPC extend lateral to the foramen ovale and into the parapharyngeal space. (It is usually difficult to achieve a sound oncologic resection [no safety margin], and thus a second course of combined chemoradiation therapy might be a better option.)[3]

Contraindications

- Patients with proven distant metastasis
- Cancer involving the dura.
- Encasement of the petrous part of the internal carotid artery

Preoperative Preparation

1. Multidisciplinary team evaluation
   a. Otolaryngologist—head and neck surgeon
   b. Oncologist
   c. Anesthesiologist
   d. Nutritionist (if necessary)
2. Physician
   a. If required optimizing medical illness (cardiopulmonary disease)
3. Confirm the histopathologic report before definitive surgery.
4. Review the radiologic imaging (PET-CT and MRI) for planning of resection of the cancer and surgical approach.
5. Treat sinusitis if present.
   a. A bacterial culture of nasal secretion is obtained and culture-directed antibiotics prescribed for at least 7 days.
   b. Perform frequent nasal douching with saline before surgery.
6. Postoperative high dependency care (depending on the center)
7. Discontinue antiplatelet drugs if possible.

OPERATIVE PERIOD

Anesthesia

- All salvage nasopharyngectomy operations are performed under general anesthesia.
- Endotracheal intubation through the oral cavity
- Fiberoptic-guided intubation may be needed for patients presenting with trismus.
- In rare circumstances, tracheostomy should be considered in patients with severe trismus.

Positioning

- The patient is placed in the supine position.
- The head is turned to the contralateral side and slightly extended.

Perioperative Antibiotic Prophylaxis

- Clean-contaminated surgery
- Prophylaxis intravenous antibiotics should be administered 2 hours before surgery based on the bacterial culture result (if available).

- Choice of intravenous antibiotic may differ among surgeons, but a broad-spectrum antibiotic with good cerebral spinal fluid (CSF) penetration is recommended.
- Succeeding doses of intravenous antibiotics can be given every 6 hours if the surgery lasts longer.

Monitoring

- Routine anesthesia monitoring
- Hypotensive anesthesia (to reduce intraoperative bleeding that will obscure operative field)
- Prevent hypothermia by using intraoperative warm-air blanket.
- Maintain fluid balance and hemoglobin level.

Instruments and Equipment to Have Available

The different open approaches to the nasopharynx require dissection through soft tissue and facial bones. The instruments and equipment required to carry out a successful surgery are:

1. Excision set
2. Sinuscope set (0- and 30-degree Hopkins telescopes)
3. Osseous set with oscillating saw, burr, and reconstructive plate and screws
4. Skull base set including Kerrison rongeurs, forceps, curettes, tru-cutting instruments, and dissectors
5. Cutting and diamond burrs
6. Contact LASER set with curved applicator
7. Bipolar cauterization set

Surgical Anatomy

- The nasopharynx, a hollow cubic space above the soft palate and posterior to the nasal cavity
- The most cephalad portion of the upper aerodigestive tract
- Lined by pseudostratified ciliated columnar epithelium
- Boundaries:
  - Superior: sphenoid sinus and upper clivus
  - Posterior: lower clivus and the body of the first cervical vertebra
  - Lateral: medial pterygoid plate (formed by an incomplete cartilaginous ring with a natural defect inferolaterally called the sinus of Morgagni).
  - Anterior: communicates with the posterior nasal choanae
  - Inferior: communicates with the oropharynx
- The posterior and lateral wall of the nasopharynx are demarcated by the pharyngobasilar fascia, a dense and tough fascia that originates from the pharyngeal tubercle of the occipital bone posteriorly and inserts anteriorly into the posterior sharp end of the medial pterygoid plate (serves as a good barrier to the spread of NPC).
- It continues inferiorly as the buccopharyngeal fascia.
- The spread of NPC
  - Superiorly: floor of the sphenoid sinus and invades the sphenoid sinus and skull base
  - Laterally: through the sinus of Morgagni, extending along the Eustachian tube toward the base of the pterygoid plate and into the parapharyngeal space, eventually gaining access into the area of the foramen ovale
- NPC that spreads laterally to the foramen lacerum may involve or encase the petrous internal carotid artery, which would then prevent complete resection of the recurrent cancer.[3]

Prerequisite Skills

- Surgeons should be familiar with development and elevating a skin flap, as well as osteotomies.
- Basic skills to manage intraoperative bleeding in a relative narrow and deep space are mandatory.

Operative Risks

Because the nasopharynx is closely related to the cavernous sinus, internal carotid artery, and dura, iatrogenic injury to these vital structures can be life threatening and render the nasopharyngectomy some operative risks with potentially devastating consequences.

Surgical Technique

Salvage nasopharyngectomy has been the mainstay of treatment after radiation failure. Various surgical approaches to the nasopharynx have been developed, such as transpalatal, midface degloving/Le Fort I osteotomy, transfacial/facial translocation/transmaxillary, mandibulotomy, transpterygoid, and infratemporal fossa approaches.

Intraoperative Evaluation and Preparation After Patient Has Been Intubated

- Ensure that the nasal cavities are properly decongested and anesthetized using cotton pledgets soaked in epinephrine with a 1:100,000 dilution for 15 minutes.
- Inspect the nasopharynx carefully using a rigid endoscope to examine the entire cancer and make a good surgical plan.
- Infiltrate the planned facial incisions, mucoperichondrium of the nasal septum, middle and inferior turbinates, and the area around the cancer using a combined solution of 1% lidocaine and 1:80,000 epinephrine.

Le Fort I Osteotomy via Midfacial Degloving Operative Technique

The steps for this technique are as follows:

1. Standard transfixion incision from the tip of the nose inferiorly to the nasal floor
2. An intercartilaginous incision is placed and extends laterally beyond the margin of the upper lateral cartilages and connects medially with the transfixion incision. Circumvestibular release is completed with a full-thickness incision at the pyriform aperture and nasal floor up to the periosteum.
3. Separate the dorsum of the nose and upper lateral cartilages by dissecting through the intercartilaginous incisions using a Freer elevator.
4. Make a horizontal incision above the gingivobuccal sulcus from one maxillary tuberosity to the other then elevate the periosteum, exposing the anterior and lateral maxillary walls.
5. Extend the dissection to the edge of the piriform aperture and to the incisions placed intranasally to allow elevation of the upper lip together with the tip of the nose. Maintain a cuff of mucosa to allow easy closure of the gingiva.
6. Dissect the soft tissues up to the infraorbital rim, exposing and identifying the infraorbital nerve, lateral maxillary wall, piriform aperture, and the zygomatic pillar of the maxilla. The infraorbital nerve is preserved unless it is involved by the cancer. Mobilization of the soft tissues can be extended superiorly up to the nasofrontal angle and glabellar area.
7. Place titanium miniplates over the bony maxilla, prefolded; then screw holes are made.
8. Perform a horizontal maxillary osteotomy starting anteriorly from the piriform aperture toward the lateral wall of the maxilla and the zygomatic pillar.

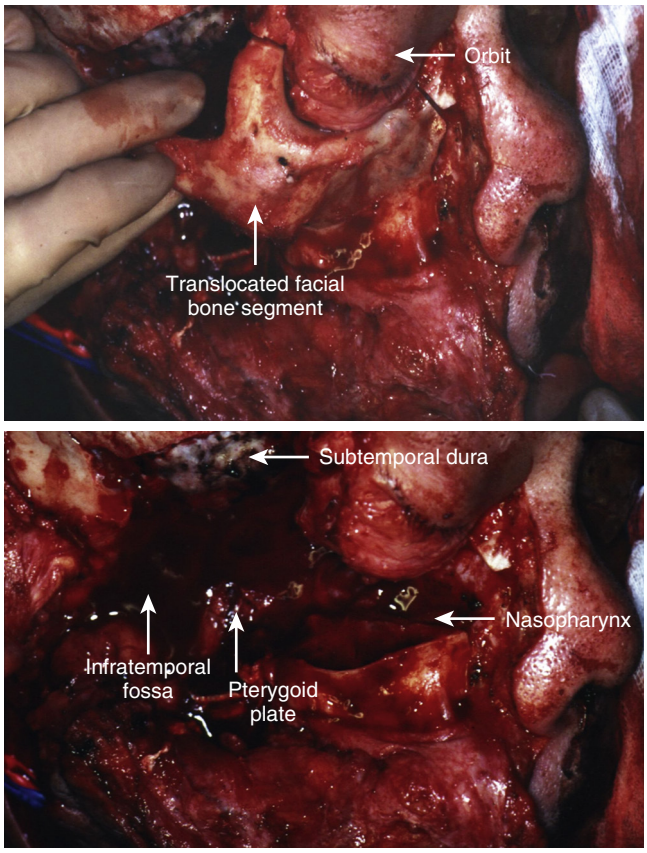

Fig. 43.1. With elective temporary disassembly of the facial skeleton, the facial translocation approach provides an excellent surgical exposure of the nasopharynx and skull base, to facilitate extensive resection of tumors. Upper arrows indicate orbit and translocated facial bone segment. Lower arrows indicate horizontal: upper-subtemporal, dura, lower-nasopharynx; vertical: lateral-infratemporal fossa, medial-pterygoid plate.

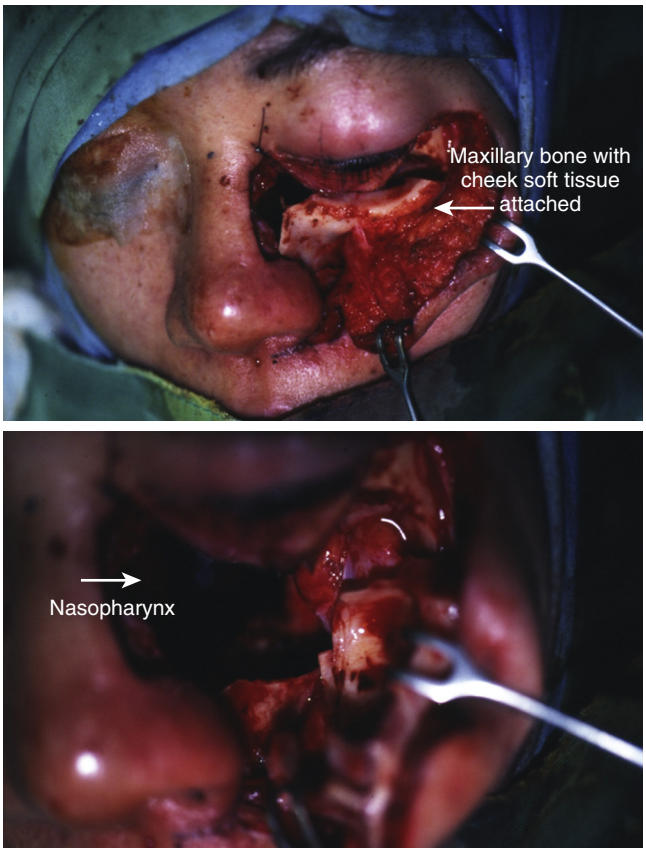

Fig. 43.2. In the maxillary swing approach, the maxilla is left attached to the cheek soft tissue to retain its blood supply, and the facial soft tissue and bone are swung laterally to expose the paranasal sinuses, nasopharynx, and skull base. Upper arrows indicate maxillary bone with cheek soft tissue attached. Lower arrows indicate nasopharynx.

9. Separate the nasal septum from the anterior nasal spine and maxillary septal crest using a sharp osteotome while avoiding laceration of the nasal mucosa.
10. An osteotomy is then performed to separate the maxilla using a sharp chisel from the piriform aperture posteriorly to the pterygoid plates and palatine canal vessels passing through the inferior meatus.
11. Finally, downfracture the maxilla.
12. Dissection is limited laterally by the pterygoid and temporal muscles; posteriorly by the clivus, posterior wall of the sphenoidal sinus, and the greater wing of the sphenoid bone; and superiorly by the anterior cranial fossa.
13. After excision of the tumor, the bony buttresses are approximated using wiring or titanium plates and 4 weeks of intermaxillary fixation.

Facial Translocation Approach

The technique of developing a lateral nasal wall mucoperiosteal flap in the modified facial translocation approach:

1. Infiltrate the nasolabial groove using a solution of 1% lidocaine mixed with 1:100,000 epinephrine and proceed with a lateral rhinotomy incision.
2. The incision is placed along the nasal ala without involvement of the nostril and is carried down in a stepwise fashion.
3. As the incision is developed, stop first at the medial edge of the maxillary bone, making sure to preserve the mucoperiosteum of the lateral nasal wall. Do not transect the full thickness of the lateral nasal wall while gaining access into the nasal chamber and dividing the feeding vessels.
4. Using a Cottle elevator, gently elevate the mucoperiosteum of the lateral nasal wall from the lateral bony wall of the maxilla. Continue elevating the mucoperiosteum posteriorly toward the posterior end of the inferior turbinate, superiorly toward the middle turbinate until the natural orifice of the maxillary sinus is reached, and inferiorly to the nasal floor (Figs. 43.1, 43.2).
5. Perform an osteotomy along the nasal bone, anterior wall of the maxilla, and possibly the lateral wall of the maxilla and orbital floor. Temporarily remove the facial bone segment and proceed with a medial maxillectomy (see Fig. 43.3).
6. Remove the medial bony maxillary wall to access the maxillary sinus. After removing the posterior wall of the maxillary sinus, further exploration of the nasopharynx and skull base can now be done (Fig. 43.4).
7. The anteriorly based lateral nasal wall mucoperiosteal flap is developed after dividing the mucosal attachment with the surrounding soft tissues. Ensure that the neck of the developed mucoperiosteal flap that connects it to the anterior nasal soft tissues is as broad as possible (Fig. 43.5).
8. The lateral nasal wall mucoperiosteal flap is then delivered anteriorly for better exposure. After removing the inferior turbinate mucoperiosteum off the concha, partially remove the inferior turbinate bone.
9. After the skull base tumor is excised, this lateral nasal wall mucoperiosteal flap is transferred to cover the

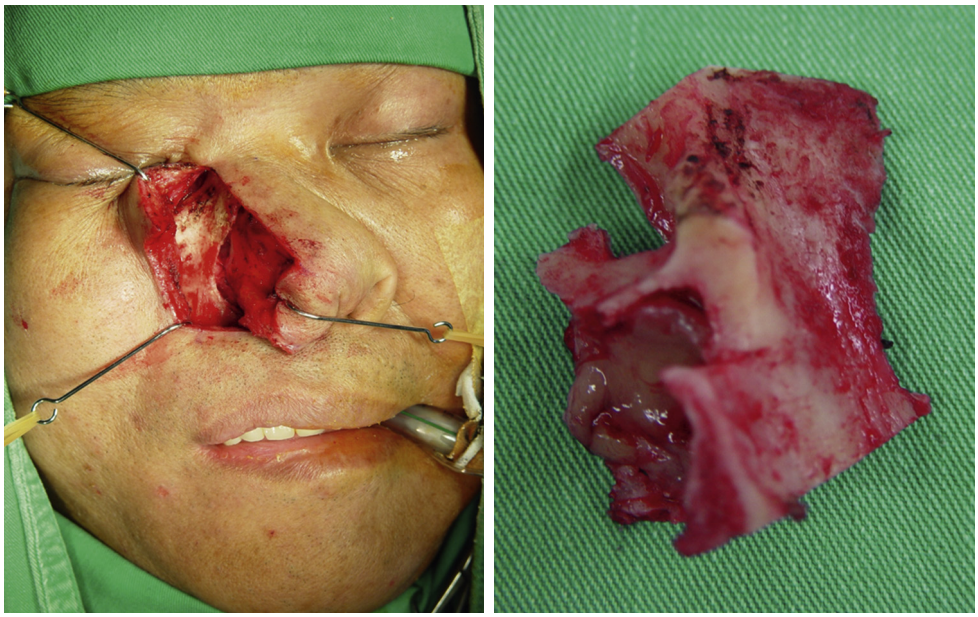

Fig. 43.3. Modified facial translocation I: lateral rhinotomy incision and facial osteotomy.

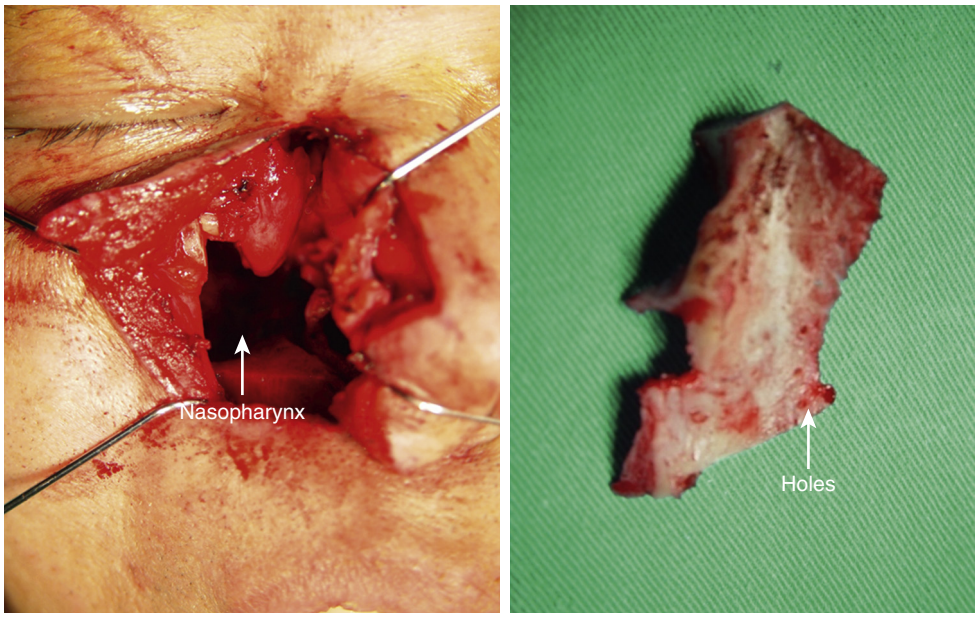

Fig. 43.4. Modified facial translocation II: medial maxillectomy to approach nasopharynx. Holes are created along the free edge on the temporary removed bone segment, ready to suture the flap against the bone. Left: arrows indicate nasopharynx and right: arrows indicate drilling hole.

defect and placed against the inner surface of the translocated bone graft.

10. Attach the flap to the translocated facial bone segment using meticulous suturing via drilled holes placed in the bone graft. Reassemble the translocated bony segment with the remaining facial skeleton using fixation with microplates (see Fig. 43.5).
11. Close the lateral rhinotomy incision.
12. Place a Foley catheter into the hollow sinoparanasal space and inflate to provide additional support to the mucoperiosteum flap against the translocated facial bone segment.
13. Remove the Foley catheter after two days.

By using the soft tissues of the cheek and the transposed lateral nasal wall mucoperiosteal flap to cover the translocated facial bone segments, this method of the modified facial translocation technique will assist in the revascularization of the bone segments and prevent necrosis even during RT. This modification allows resurfacing of the bone segments' inner defect, improving its viability even in rNPCs that have been heavily irradiated, without interfering with the detection of early local recurrence.

Common Errors in Technique

Viability of the Translocated Facial Bone Graft

- The vascular supply of the disassembled bone fragments is maintained by keeping the osteotomized bone fragment attached to the soft tissues of the cheek, similar to the maxillary swing approach.
- Devascularized free bone graft, after the soft tissue is elevated, increases the risk of developing ORN after RT.
- Preserving the attachment of the bony fragments to the soft tissues might be technically difficult, especially after removal of the anterior wall of the maxillary sinus in the previous lateral rhinotomy or Caldwell-Luc surgery. In addition, accidental injury to the internal maxillary artery may occur during the osteotomy of the lateral wall that is usually performed in

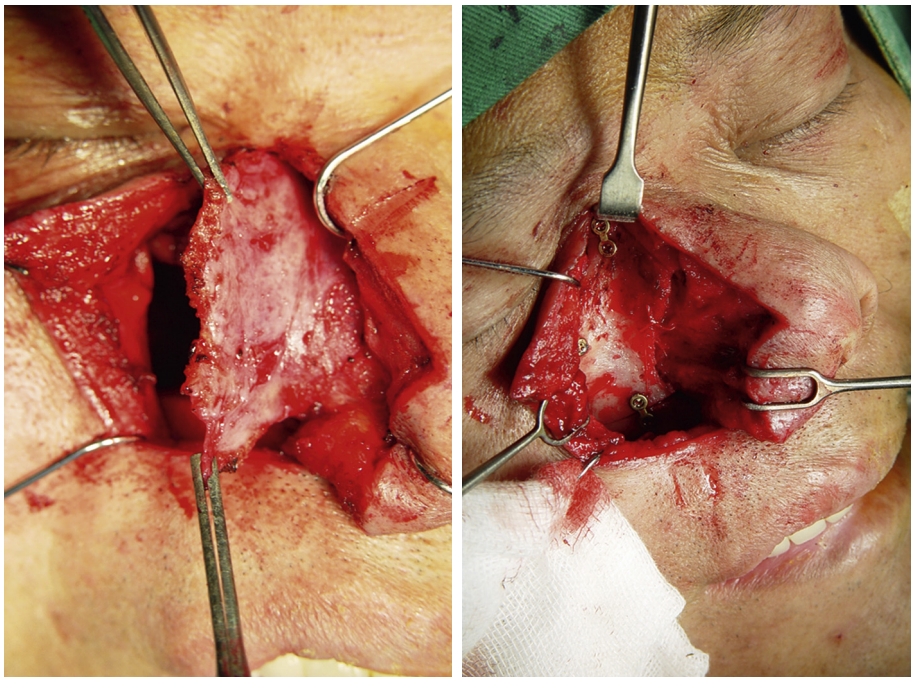

Fig. 43.5. Lateral nasal wall flap is developed and transposed to reconstruct the inner defect of the translocated bone. The bone segment is secured with a three-point fixation to the remaining facial bone.

a blind method. Injuring the internal maxillary artery causes profuse bleeding that may be difficult to control unless the translocated facial bones are removed as a free bone graft.
- The inner defect of the translocated bone segment may be reconstructed using a vascularized soft tissue flap to decrease the risk of developing bone graft necrosis after RT.

Modified Facial Translocation

- Several technical modifications to the facial translocation approach have been improved to avoid bone graft necrosis, such as:
  - Three-point fixation to secure and immobilize the facial bone graft to avoid microtrauma that would interfere with bone union
  - The facial bone unit is secured to the facial soft tissue by suturing the cheek soft tissue flap to the drilling holes of the facial bone unit in free bone graft technique.
  - The lateral nasal wall can be preserved and transposed to resurface the inner aspect of the translocated facial bone unit if it is far away from the tumor and remains free of disease.

POSTOPERATIVE PERIOD

- The patient is monitored for any complications.
  - Bleeding
  - Intracranial hemorrhage
  - Meningitis
  - Pneumocranium or tension pneumocephalus
  - CSF leak
- Usually no need for intensive care unit (ICU) care unless a combined neurosurgical resection is carried out
- A compression dressing should be applied to the facial incisions for 24 hours to prevent postoperative edema.
- The inflated Foley catheter can be removed after 24 to 48 hours.
- Intravenous antibiotics should be continued for at least 48 hours, after which it may be shifted to the oral form.
- The patient can be discharged from the hospital after 48 hours if there are no complications.
- Careful instructions are given to the patients regarding irrigation of the nasopharyngeal cavity after the seventh postoperative day.
- Nasal irrigation should be continued for 3 to 6 months to allow the mucosa to re-epithelialize.

COMPLICATIONS

- There was nearly no surgical mortality, and the immediate surgical morbidity is reported between 13.2% and 22%.
- Common complications encountered are:
  - Bleeding
  - Infection
  - ORN
    - Bone necrosis of the nasopharynx, facial bones, and skull base
    - Self-irrigation to keep a good local hygiene is mandatory to prevent the ORN.

ALTERNATIVE MANAGEMENT PLAN

Re-irradiation with or without chemotherapy

DISCUSSION

Evidence-Based Medicine Questions

The maxillary swing or the midface degloving provides excellent anterior approaches to the nasopharynx. Both approaches are suitable for cancer confined to the nasopharynx with limited extension to the parapharyngeal space. The maxillary swing approach, introduced in 1991, allows the anterior and lateral part of the cancer to be visualized clearly. The contralateral nasopharynx can also be approached by removing the posterior part of the nasal septum. With such adequate exposure, en bloc removal of the cancer with wide margins is feasible. At the same time, the petrosal part of the internal carotid artery can be controlled if necessary. The midface degloving approach involves degloving the midface, bilateral medial maxillectomies, and

dislocation of the nasal septum without any facial incision needed.

In both midface degloving, as well as the maxillary swing, the superior exposure of the cancer is lacking and limited inferiorly by the hard palate. Cancer involvement to the pterygoid plate or the foramen ovale area requires a combined neurosurgical approach, such as subfrontal approach for superior exposure of the cribiform plate, fovea ethmoidalis, and planum sphenoidale.[4] When combined with a subtemporal approach, a lateral extension of NPC to the sphenoid ridge and foramen ovale area can be resected.[2]

For both the approaches, there is no significant difference in 5-year local progression-free survival, locoregional progression-free survival, and overall survival rates. However, for subgroup T1 and T2 tumors, the maxillary swing approach is associated with better survival rates than the midfacial degloving approach when used to perform a salvage nasopharyngectomy.[5]

Editorial Comment

Le Fort I Osteotomy via Midfacial Degloving Operative Technique

Midfacial degloving was first introduced in an attempt to preserve as much functional tissue as possible without cosmetic deformity while still allowing adequate exposure of bilateral maxillary and lower nasal cavity. It was first introduced as a facial degloving procedure by Portmann in 1927 but was used for excision of neoplastic diseases by Conley and Price. It is a versatile technique with the advantage of allowing excellent bilateral exposure of the bony structures of the midface, while avoiding any skin incisions, and with a low complication rate. It also tolerates better the ischemic and cicatrizing effects of radiation because it allows preservation of the vascular and lymphatic vessels of the soft tissues of the face. Midfacial degloving approach can be combined with the following Le Fort I osteotomy approach for nasopharyngectomy.

The Le Fort I osteotomy is a procedure that provides safe exposure for cancers located in the nasopharynx and skull base while providing superior cosmetic results by avoiding facial scars. Von Langenbeck first described it in 1861 and in 1867 by Cheever for a pterygopalatine fossa tumor and nasopharyngeal tumor, respectively. Several complications include malocclusion, hemorrhage, and subcutaneous emphysema, as well as the small possibility of palatal necrosis. However, it has been shown that if the periosteum is preserved after maxillary osteotomy, there is no need to preserve the incisive canal vessels, descending palatine arteries, and superior alveolar arteries. The prevention of complications entails adequate knowledge of the anatomy and surgical technique, as well as observing procedures that promote good postoperative vascularization, such as avoiding excessive traction on the vascular pedicles or detachment of the palatine mucosa. Closure of the soft palate should be done in layers to lessen the risk of postoperative velopharyngeal incompetence.

Facial Translocation Approach

Facial translocation is a concept that originated from the facial compartment disassembly and is considered as one of the best surgical approaches to the nasopharynx and skull base. Temporarily disassembling the facial skeleton provides excellent exposure and the most direct approach to the nasal cavity, paranasal sinuses, orbital cavity/apex, nasopharynx, frontal bone, and infratemporal fossa. It also allows the surgeon to access rNPC tumors that have developed lateral extension outside to the nasopharynx but medial to the foramen ovale.

Facial translocation allows extensive resection of cancers while still allowing preservation and reliable reconstruction of critical structures through approximation and fixation of the facial fragments at the end of the procedure. The entire anterior and middle cranial base may also be accessed by combining the facial translocation approach with elective craniofacial osteotomies and, optionally, with neurosurgical subfrontal or subtemporal approaches. Another advantage of the facial translocation approach is that it avoids the formation of bony defects that downgrades the cosmetic effect postoperatively, such as in the conventional lateral rhinotomy approach wherein part of the maxilla is removed without reconstruction, thereby creating a bony defect that results in a paranasal depression.

There are certain modifications of the facial translocation. For example, Dr. William I. Wei used the maxillary swing as a new approach to the nasopharynx. Dr. P.J. Catalano described an extended osteoplastic maxillotomy approach as a new procedure for wide access to the central skull base and infratemporal fossa. As a rule, in the facial translocation approach, the facial osteotomy can be electively carried out according to the anatomic location and the extent of the cancer.

Eugene N. Myers

Access the review question and additional sources list online at http://www.expertconsult.com



REFERENCES

1. Hao SP, Tsang NM. Nasopharyngeal carcinoma. In: Petruzzelli GJ, editor. Practical Head and Neck Oncology. San Diego: Plural Publishing; 2008. p. 175–190.
2. Hao SP, Tsang NM, Chang KP, et al. Nasopharyngectomy for recurrent nasopharyngeal carcinoma: a review of 53 patients and prognostic factors. Acta Otolaryngol 2008;128:473–481.
3. Hao SP, Tsang NM. Surgical management of recurrent nasopharyngeal carcinoma. Chang Gung Med J 2010;33:361–369.
4. Wang CC, Hao SP, Chen YL, et al. Transcranial resection of olfactory neuroblastoma. Skull Base 2005;15:163–171.
5. Vlantis AC, Brian KH, Kam MK, et al. Nasopharyngectomy: does the approach to the nasopharynx influence survival? Otolaryngol 2008;139(1):40–46.

REVIEW QUESTION

1. Which is the structure that passes through the sinus Morgagni?
   a. Internal maxillary artery
   b. Levator veli palatini
   c. Ascending palatine artery
   d. Eustachian tube

ADDITIONAL SOURCES

Hao SP. Modified facial translocation technique to prevent necrosis of bone graft. Laryngoscope 2002;112:1691–1695.

Hao SP, Tsang NM, Chang CN. Salvage surgery for recurrent nasopharyngeal carcinoma. Arch Otolaryngol Head Neck Surg 2002;128:63–67.

Hao SP, Tsang NM, Chang KP. Screening nasopharyngeal carcinoma by detection of LMP-1 gene from nasopharyngeal swab. Cancer 2003;97:1909–1913.

Hao SP, Pan WL, Chung TC, et al. Lateral nasal wall mucoperiosteal flap: a versatile new reconstruction of the inner defect of translocated facial bone segments. Ann Plast Surg 2004;52:343–348.

Lin JC, Wang WY, Chen KY, et al. Quantification of plasma Epstein-Barr virus DNA in patients with advanced nasopharyngeal carcinoma. N Engl J Med 2004;350:2461–2470.

Naraghi M, Bayat M, Yahyavi SH, et al. Le Fort I osteotomy approach for advanced nasopharyngeal angiofibroma with intracranial extension: report of a case. Acta Med Iran 2002;40:256–260.

Padgham N, Vaughan-Jones R. Cadaver studies of the anatomy of arterial supply to the inferior turbinates. J R Soc Med 1991;84:728–730.

Wei WL, Lam KH, Sham JS. New approach to the nasopharynx: the maxillary swing approach. Head Neck 1991;13(3):200–207.

44 Facial Translocation Approach to the Nasopharynx

Meghan N. Wilson, Neal M. Jackson, Daniel W. Nuss

INTRODUCTION

The facial translocation approach (FTA) for access to the cranial base was first described in the late 1980s by Dr. Ivo P. Janecka and colleagues at the University of Pittsburgh.[1–3] The FTA was one of a number of landmark approaches described in the early days of the evolving new discipline of skull base surgery. At that time—before intraoperative imaging and image-guided navigation were widely available—most skull base approaches were based on the premise of obtaining broad anatomic exposure for the purposes of safe recognition and protection of critical skull base neurovascular structures and obtaining enough space in which to achieve complete tumor removal and repair. The FTA used the concept of modular "craniofacial disassembly" to achieve these goals. Over time, the utility, indications, and technical adaptations of the FTA have evolved, and although many other less invasive approaches have since been described, the FTA still has unique advantages in the management of certain skull base tumors,[4,5] especially those involving the nasopharynx (NP) and adjacent compartments.

Historically the NP was considered a difficult anatomic target for extirpative surgery because of its central location in proximity to critical anatomy of the brain, brainstem, carotid and basilar arteries, orbits, and multiple cranial nerves. The FTA is a versatile approach (actually a system of approaches)[3] that gives extremely broad exposure of the NP and these adjacent structures. Tumor location and pathology will guide the surgeon to tailor the most appropriate approach. A multidisciplinary discussion for surgical planning is valuable and may include Otolaryngology, Neurosurgery, Vascular surgery, and Reconstructive surgery teams, as well as Interventional Radiology and Radiation and Medical Oncologists.

KEY OPERATIVE LEARNING POINTS

1. The surgeon must have detailed knowledge of the vital structures of the NP, the face, and the adjacent compartments (infratemporal fossa [ITF], orbit, paranasal sinuses, and cranial vault).
2. The best approach is decided upon after assessing tumor location, tumor pathology, and the surrounding structures involved. If there is intracranial extension, consultation with an experienced Neurosurgeon is essential.
3. A thorough conceptual understanding of the sequence of steps in the FTA is essential for a safe, successful application (Figs. 44.1–44.6).
4. When cranial nerves (in particular the distal branches of the trigeminal and facial nerves) must be displaced in the FTA, sharply transecting the nerves and carefully re-approximating them at the end is preferred over vigorous or prolonged stretching of the nerves and results in better functional outcomes.
5. Orienting the horizontal incision at the level of the zygoma will protect the orbicularis oculi innervation as it enters the muscle below this level.
6. Temporary tarsorrhaphy at the end of the surgical procedure is important to prevent scar contracture and eversion/ectropion of the lower eyelid.
7. It is helpful to use a drill to mark the attachment point of the medial canthal tendon on the nasolacrimal bone to facilitate accurate reattachment.
8. Transection of the coronoid process increases the mobility and reach of the temporalis muscle transposition, which

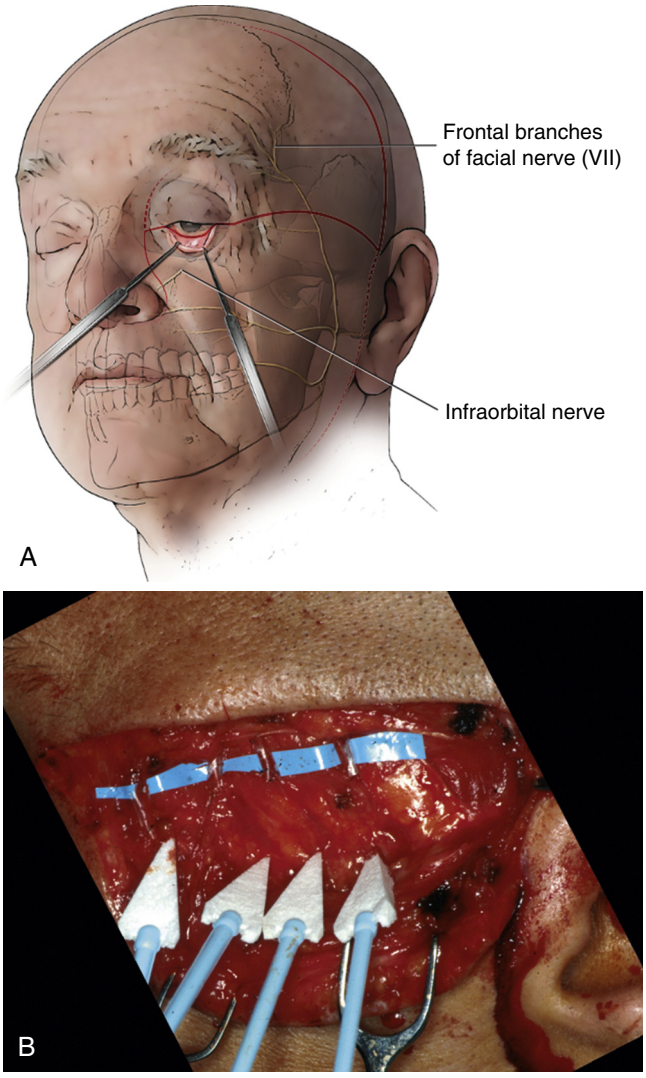

Fig. 44.1. A, Incision design for facial translocation (see text for details). **B,** Surgical view of zygomatic-temporal portion of the incision, with multiple frontal-temporal branches of the facial nerve identified and tagged prior to division. These nerves will be repaired at the end of the procedure. *(Reproduced with permission from Fig. 20.5 from Myers EN, Snyderman CH, Gardner P (eds). Master Techniques in Otolaryngology–Head and Neck Surgery: Skull Base Surgery; Nuss DW: Facial translocation approach to the central cranial base. Lippincott Wolters Kluwer: Philadelphia, PA; 2015).*

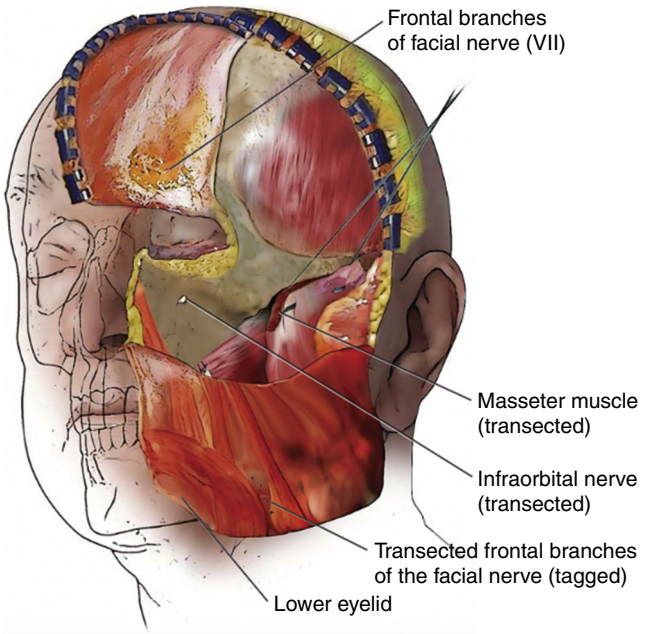

Fig. 44.2. Exposure of the craniofacial skeleton after reflection of the soft tissue envelope (see text for details). *(Reproduced with permission from Fig. 20.6 from Myers EN, Snyderman CH, Gardner P (eds). Master Techniques in Otolaryngology–Head and Neck Surgery: Skull Base Surgery; Nuss DW: Facial translocation approach to the central cranial base. Lippincott Wolters Kluwer: Philadelphia, PA; 2015.)*

can be accomplished easily as long as there is due care to avoid compromising the blood supply.

9. When considering reconstruction, the most important concerns are closure of the dura and protection of the carotid artery.

PREOPERATIVE PERIOD

History

1. History of present illness
   a. Ask about any neurologic deficits, emphasizing dysfunction of any cranial nerves.
      1) Dysfunction of cranial nerve V, the trigeminal nerve, is common in tumors of this area. This may present as unilateral sensory loss, facial dysesthesia, and/or mastication dysfunction (including malocclusion or deviation of the jaw).
      2) Dysfunction of cranial nerve VI is also common with tumors of the NP, where there is ready access to the cavernous sinus and the orbital apex; this is manifested by diplopia and limited lateral gaze.
      3) Dysfunction of cranial nerve VII is uncommon with nasopharyngeal tumors. However, the facial nerve will be manipulated in the FTA, and it is important to counsel patients that the innervation to the forehead will be disrupted and will require 6 to 9 months after neurorrhaphy before brow elevation function will return.
      4) Tumors from the NP may spread laterally to involve the jugular foramen and thus may result in deficits of the lower cranial nerves (IX to XII), and tumors invading the temporal bone or posterior fossa may lead to sensorineural hearing loss and vestibular dysfunction.
      5) Patients with preoperative dysphagia and aspiration should be counseled that surgery may worsen these

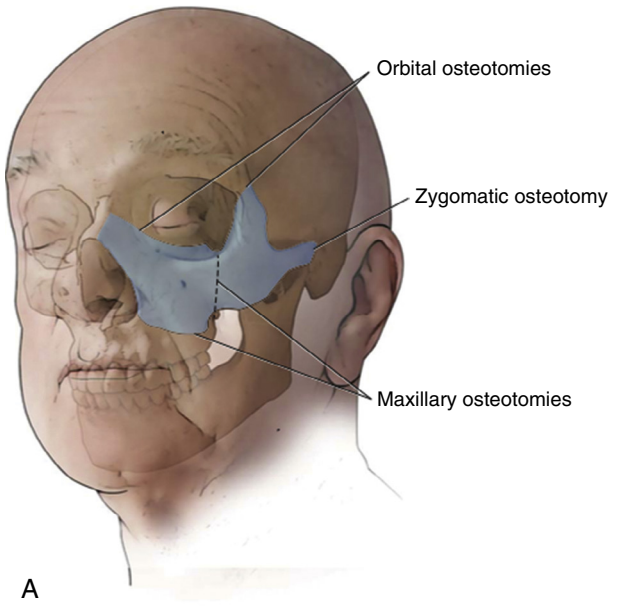

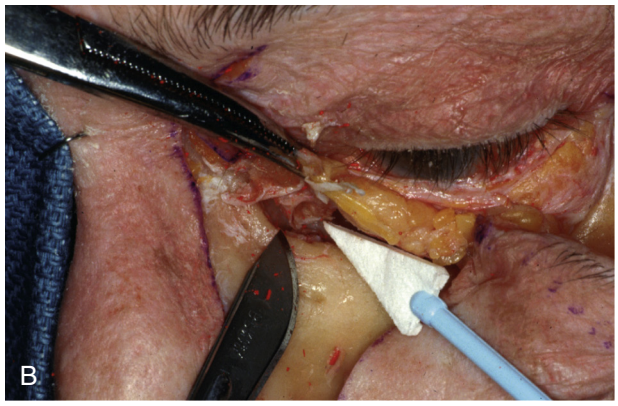

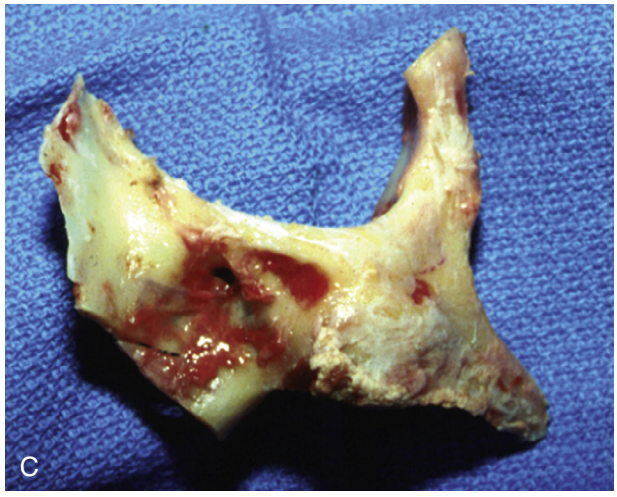

Fig. 44.3. A, Diagram of osteotomies of the orbital-zygomatico-maxillary skeleton. **B,** Lab dissection of medial orbit after subperiosteal exposure of the nasal-maxillary skeleton, release of the lower eyelid, showing nasolacrimal duct (pointer) prior to transection. **C,** Operative photo of orbito-zygomatico-maxillary segment after temporary removal; note that the infraorbital foramen has been enlarged and V2 has been released from the bone prior to explantation of the bony segment. *(Reproduced with permission from Fig. 20.11 from Myers EN, Snyderman CH, Gardner P (eds). Master Techniques in Otolaryngology–Head and Neck Surgery: Skull Base Surgery; Nuss DW: Facial translocation approach to the central cranial base. Lippincott Wolters Kluwer: Philadelphia, PA; 2015.)*

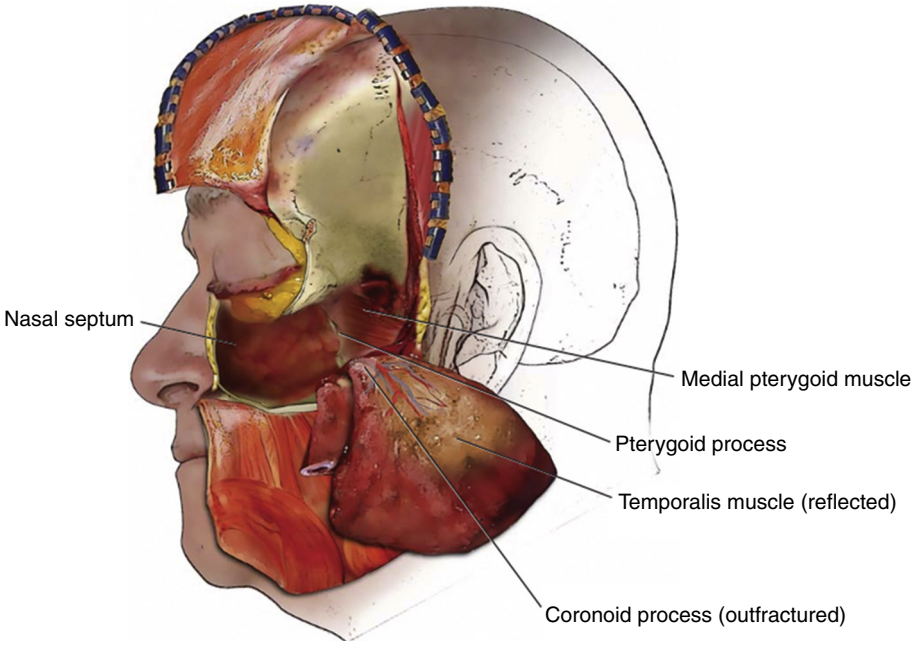

Fig. 44.4. Exposure achieved after orbital-zygomatico-maxillary osteotomies and reflection of temporalis muscle from the skull, revealing the view through the infratemporal fossa toward the nasopharynx (NP). At this point, resection of the pterygoid process will provide comprehensive access to both sides of the NP. *(Reproduced with permission from Fig. 20.12 from Myers EN, Snyderman CH, Gardner P (eds). Master Techniques in Otolaryngology–Head and Neck Surgery: Skull Base Surgery; Nuss DW: Facial translocation approach to the central cranial base. Lippincott Wolters Kluwer: Philadelphia, PA; 2015.)*

problems, and consideration may be given to the placement of a feeding tube.

6) Conductive hearing loss with middle ear effusion may indicate compression of the Eustachian tube (ET) by tumor mass effect.

b. Ophthalmologic history is important, including any visual losses or diplopia.

2. Past medical history
   a. Some patients being considered for FTA will have a history of nasopharyngeal carcinoma (NPC). It is important to note that primary NPC is initially treated (after confirmatory biopsy) with chemoradiation in almost all cases. Surgery is usually reserved for recurrences. FTA is reserved for extensive recurrences requiring very broad access.
   b. Any history of prior head and neck surgery or radiation must be taken into consideration with regard to tissue vascularity and viability; these factors may affect the incision design and the selection of reconstructive methods.
   c. The medical health and functional status of the patient are important, as surgery via the FTA may be lengthy, depending on the pathology and reconstructive needs.
   d. If the patient smokes, counseling and cessation are important both for perioperative healing and long-term survival.

Physical Examination

1. The NP must be carefully evaluated by endoscopy prior to surgical planning. Pathology in the NP can often spread to the ITF, which is relatively inaccessible to direct visualization and palpation on physical examination. However, important signs of ITF pathology can be elicited with a thorough examination of the head and neck, with special attention to the function of the cranial nerves as outlined above.
2. Assess for trismus; this will provide information about a possible invasion into the pterygoid musculature and is essential for the preoperative planning of airway management.
3. Evaluate visual function and document visual acuity.
4. Obtain audiometry to document hearing status, as either conductive or sensorineural hearing loss may result from skull base lesions.
5. Rarely, extensive tumors of the NP may involve the pituitary fossa or affect its regional blood flow, resulting in endocrine imbalance. Endocrinopathies may be variable, but the physical examination should look in particular for evidence of hypothyroidism or cortisol-related dysfunction, as these in particular may be detrimental to healing and thus cause significant perioperative complications.

Imaging

1. With nasopharyngeal diseases, imaging plays an essential role in precise tumor location and may suggest the type of pathology. Computed tomography (CT) and magnetic resonance imaging (MRI) are complementary and both are needed. Demonstration of bony involvement and widening of the foramina is best seen on CT, while the evaluation of soft tissue planes and tumor extension along neural structures is best seen on MRI.
2. It is critical to assess the functional status of the internal carotid artery (ICA) and its precise anatomic relationship to tumors of the NP, as this will influence details of the approach. If there is concern for ICA involvement following CT and MRI imaging, a Magnetic Resonance Angiography (MRA), computed tomography angiography (CTA), or formal angiogram should be considered. If intraoperative manipulation of the ICA is likely, the team should consider preoperative evaluation of collateral cerebral blood flow with a balloon occlusion test. Consultation with a Vascular Surgeon (or vascular neurosurgeon) may be warranted if intraoperative vascular bypass is a possibility.
3. Evaluation of regional and distant metastatic cancer is dictated by the histology and stage of the tumor. CT/positron emission tomography (PET) scanning is warranted to detect evidence of distant metastases.

Indications

Prior to FTA, tissue biopsy with pathologic confirmation of histology is desirable, as with any major extirpative cases. Open or transnasal endoscopic biopsy is usually straightforward, but if transnasal biopsy is inconclusive, an image-guided fine-needle aspiration of the tumor beyond the NP (e.g., in the ITF) may be considered. Biopsy is not indicated for highly

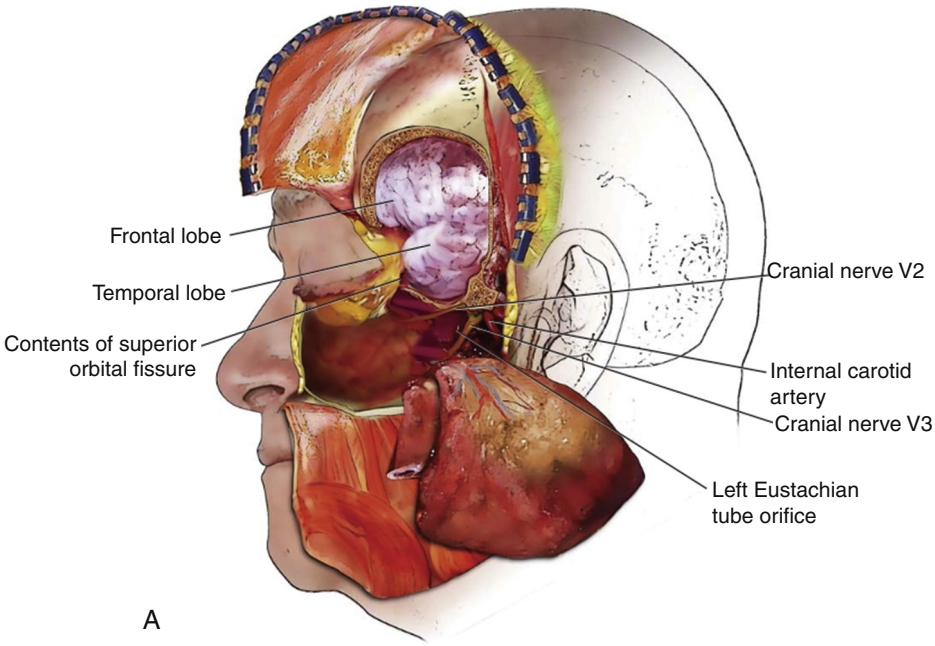

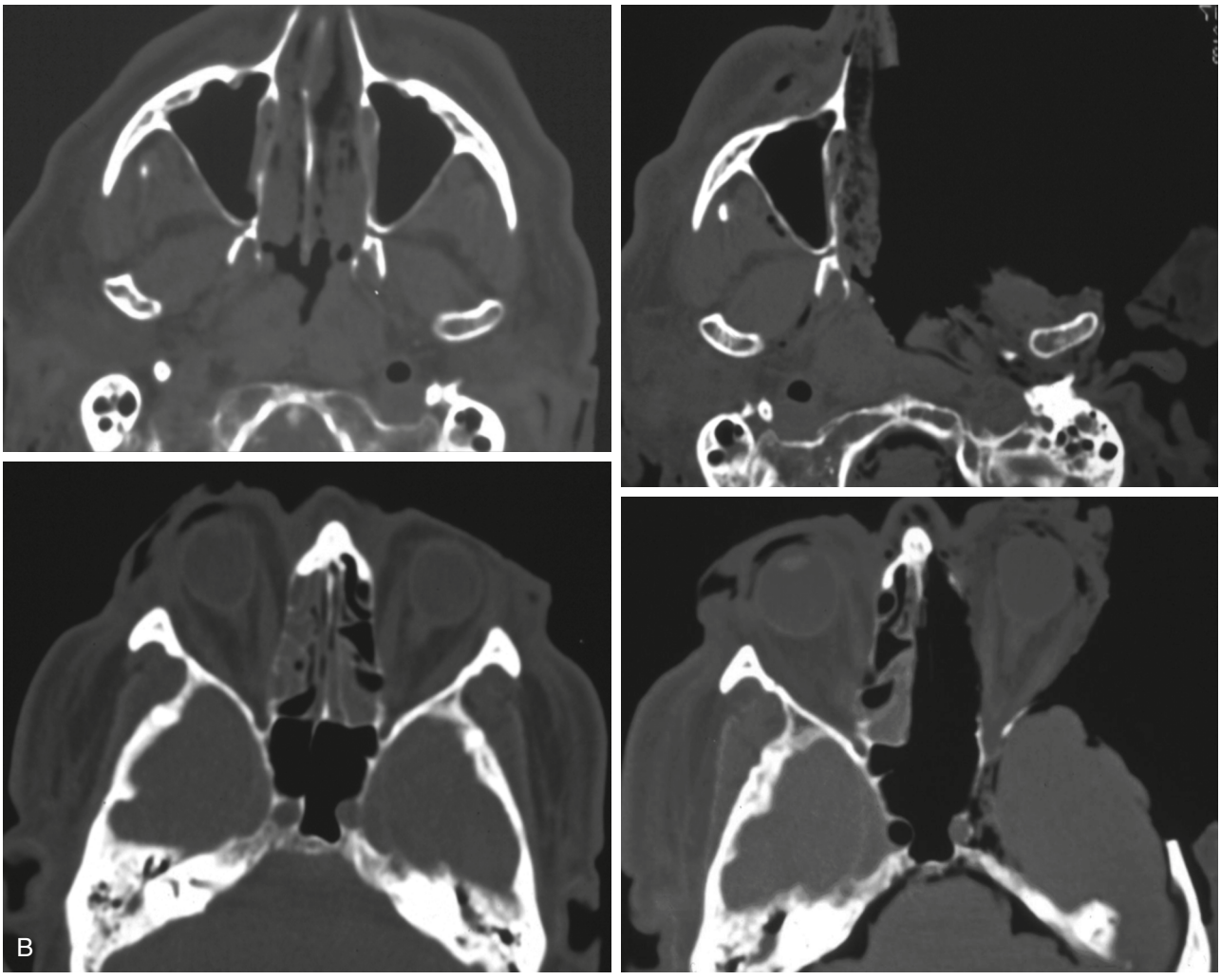

Fig. 44.5. A, Frontotemporal craniotomy provides additional access to intracranial compartments. For extensive nasopharyngeal tumors, this additional access will enable extirpation of tumor extensions involving the foramen ovale, the foramen spinosum, and the orbital apex, as well as drilling of the clivus if needed. **B,** Axial computed tomography sections of the dissected specimen showing the extent of anatomy accessible with the facial translocation approach (FTA). *Top row*: at the level of maxillary sinuses, before and after FTA. *Bottom row*: at the level of orbits, before and after FTA. *(Reproduced with permission from Fig. 20.13 from Myers EN, Snyderman CH, Gardner P (eds). Master Techniques in Otolaryngology–Head and Neck Surgery: Skull Base Surgery; Nuss DW: Facial translocation approach to the central cranial base. Lippincott Wolters Kluwer: Philadelphia, PA; 2015.)*

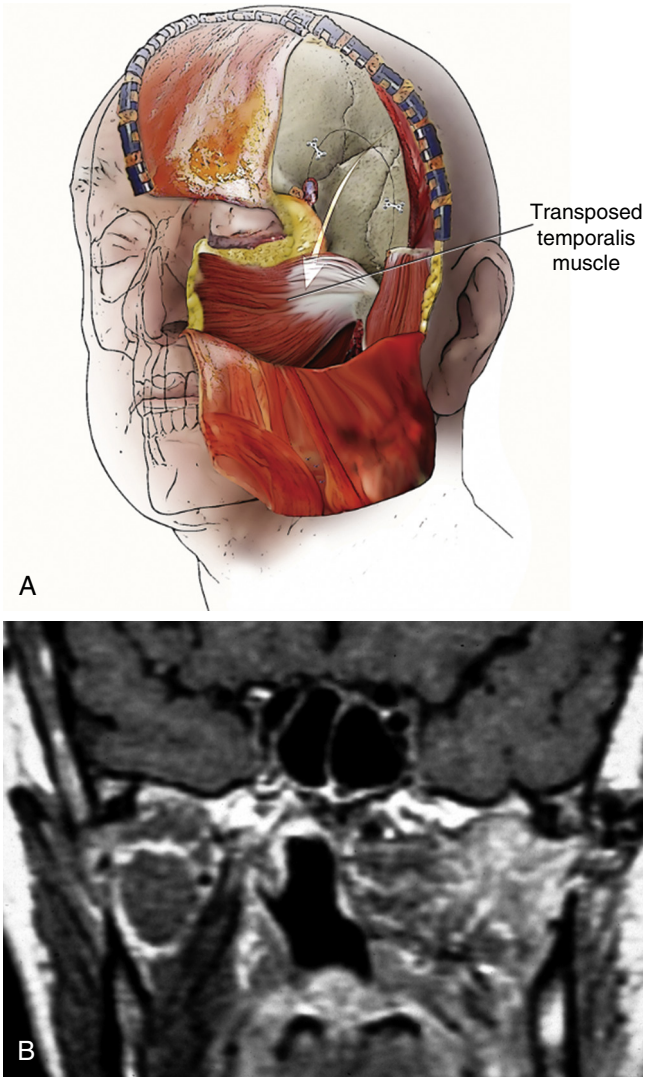

Fig. 44.6. Temporalis muscle transposed for reconstruction of cranial base defect after facial translocation approach. **A,** Diagram of the flap inset. **B,** Magnetic resonance imaging showing transposed flap in place, reconstituting the lateral nasopharyngeal wall and isolating the cranium from aerodigestive contamination. *(Reproduced with permission from Fig. 20.14 from Myers EN, Snyderman CH, Gardner P (eds). Master Techniques in Otolaryngology–Head and Neck Surgery: Skull Base Surgery; Nuss DW: Facial translocation approach to the central cranial base. Lippincott Wolters Kluwer: Philadelphia, PA; 2015.)*

vascular lesions with characteristic imaging findings, such as juvenile nasopharyngeal angiofibroma (JNA).

Listed below are examples of indications for the FTA for lesions involving the NP.

1. Extensive JNA extending through the skull base to the orbit, middle cranial fossa, and cavernous sinus, which are not amenable to purely endoscopic or less invasive approaches
2. Carcinomas of the NP originating primarily on the lateral wall of the NP that have not responded to, or recurred after, radiation or chemoradiation
3. Chordomas of the clivus and the surrounding structures, especially those with extension across the midline and to the craniovertebral junction
4. Sarcomas of the NP, pterygoid, and sphenoid region
5. Extensive transcranial lesions, such as meningiomas, nerve sheath tumors, and congenital tumors involving the NP and extending to the ITF, orbit, and cranium
6. Minor salivary gland neoplasms of the NP or adjacent areas, with intracranial, ITF, or lateral pharyngeal extent
7. Certain non-neoplastic disorders including complex encephaloceles, cerebrospinal fluid (CSF) leaks, and advanced infectious processes of the central skull base

Contraindications

There are no absolute contraindications to the FTA. Relative contraindications are as follows:

1. Medical comorbidities with an increased risk for general anesthesia
2. A failed balloon occlusion test in tumors involving the ICA raises concerns and the need for additional planning and discussions with the patient. In some cases, extracranial to intracranial bypass surgery may be an option. Some of these discussions will depend on the pathology and expected outcome.
3. Extensive invasion of brain parenchyma by a malignant tumor is another relative contraindication. In many tumors, resection of the brain is not an acceptable treatment; however, in some cases, such as an aggressive meningioma, resection of some brain tissue may be reasonable. Multidisciplinary planning with a Neurosurgeron is needed to discuss and plan treatment options and surgical techniques in these cases.
4. Smaller tumors often can be addressed through less invasive approaches. This is particularly true in well-defined central skull base lesions that may be amenable to an endoscopic endonasal approach. Quantitative analysis of relative advantages of different methods of access to the skull base can be helpful in selecting the best approach[6]; ultimately, each surgeon or surgical team must select approaches based on their own experience and results.
5. Not all lesions are appropriate for surgical therapy. Biopsy-proven hematologic lesions such as lymphoma and plasmacytoma are best treated with nonsurgical therapy. Consideration for surgical therapy for metastatic cancer is limited to decompression.

Preoperative Preparation

1. Both CT and MRI scans should be reviewed and available in the operating room. If any endoscopic approach is planned as an adjunct to FTA for tumor removal, image-guided navigation is recommended.
2. Blood products should be available, especially when dealing with highly vascular lesions.
3. Reconstructive considerations should be discussed prior to the start of the surgery and additional team members prepared to participate if necessary.

OPERATIVE PERIOD

Anesthesia

1. General anesthesia is required. Preoperative assessment of the airway is critical to the safe induction of anesthesia. Depending on the patient, traditional induction and laryngeal exposure may be possible. In other cases (e.g., patients with trismus), fiberoptic intubation may be needed, or if postoperative airway compromise is expected, a tracheostomy may be advisable.

2. FTA surgery can be lengthy. If an orotracheal endotracheal tube is used, it should be secured using either a dental wire to the teeth or a circum-mandibular wire on the contralateral side. This will prevent accidental dislodgment as the head is turned and repositioned throughout the case.
3. If neural or electromyography (EMG) monitoring will be performed, it is important to communicate to the anesthesia team the need to avoid paralytic agents.

Positioning

1. The patient should be positioned supine. The head should be supported on an appropriate, padded headrest. Mayfield pins are usually reserved for cases in which intracranial microneurovascular work is anticipated. The patient must be sterilely prepped and draped to allow exposure of the entire head and neck. Access to the neck for proximal control is important if the ICA is at risk.
2. Anithromboembolism stockings should be applied to the legs and the body properly padded to prevent pressure-related ischemia.

Perioperative Antibiotic Prophylaxis

1. Antibiotic prophylaxis should provide coverage against the skin flora and upper aerodigestive tract flora. If intracranial surgery is anticipated, the use of an antibiotic with good penetration of the blood-brain barrier should be considered.

Monitoring

1. EMG monitoring of the frontalis branches of the ipsilateral facial nerve is routinely performed. Select cranial nerve monitoring (e.g., vagus nerve via laryngeal EMG endotracheal tube) is indicated for some cases.
2. Electrophysiologic monitoring (somatosensory evoked potentials or electroencephalography) is initiated in select cases depending on what neural and vascular territories are at risk.
3. A lumbar drain is sometimes helpful if significant intradural dissection is anticipated.

Instruments and Equipment to Have Available

1. Nerve integrity monitoring system
2. Magnifications (surgical loupes and/or microscope)
3. Fine dissection scissors
4. Periosteal elevators
5. Rainey clips
6. Reciprocating and oscillating saws
7. Rongeurs
8. 7-0 or 8-0 nylon sutures
9. Crawford nasolacrimal tubes
10. Midface/cranial plating system
11. Vascular instrument set if the carotid artery is at risk

Key Anatomic Landmarks

1. During elevation of the scalp flap, one must incise down to the deep temporalis fascia at a level above the superior orbital rim and follow this plane inferiorly to prevent injury to the frontal (a.k.a. temporal) branch of the facial nerve.
2. Knowledge of the location and course of each neurovascular structure is important, particularly cranial nerves VII, V, and IX to XII; the internal maxillary artery; and the carotid artery.
3. The blood supply to the temporalis muscle is located deep in the muscle (deep temporal branches of the internal maxillary artery).
4. To identify skull base foramina, the lateral pterygoid plate can be followed posteriorly to identify the foramen ovale, foramen spinosum, and the spine of the sphenoid bone. These structures all have a fixed relationship to the ICA.

Prerequisite Skills

1. Hemi- or bi-coronal incision and flap elevation
2. Parotidectomy techniques including facial nerve dissection
3. Maxillectomy or additional facial skeletal osteotomies
4. Midface/cranial plating
5. Experience with incisions and closure of eyelid lacerations
6. Regional muscle flap elevation
7. Abdominal adipose tissue harvest

Operative Risks

1. Temporary or permanent dysfunction of cranial nerves (especially frontalis paralysis and V2 numbness)
2. CSF leak
3. Orbital injury resulting in diplopia, ocular dystopia, blurring, or blindness
4. ICA injury or other vascular injury and resultant cerebrovascular accident, death

Surgical Technique

1. Ensure functionality of EMG monitoring of the frontalis branch of the ipsilateral facial nerve.
2. Carefully mark incisions and inject with Xylocaine and epinephrine (1 : 100,000). Incisions will include a lateral rhinotomy incision and a hemicoronal incision extending preauricularly. A connecting horizontal incision will be drawn along the level of the zygoma to the lateral canthus and then through the inferior fornix of the eyelid (Fig. 44.1A).
3. An incision can be extended into the neck if necessary for management of metastases in the neck or control of the carotid artery.
4. When making the horizontal incision across the zygoma, first incise just through the skin and superficial subcutaneous tissues, and then identify the frontalis branches of the facial nerve. Loupe magnification and EMG confirmation should be used to identify the nerve branches. There are between three and six separate branches of the facial nerve that cross the zygoma; each should be preserved if possible (Fig. 44.1B).
5. Each frontalis branch should be sharply transected and a 7-0 nylon suture attached to each of the transected ends to facilitate locating each end and reapproximating them at the end of the procedure.
6. Extend the dissection deeply to the temporal adipose tissue pad, then through this adipose tissue to the zygomatic arch.
7. The lower facial soft tissue flap can then be released and retracted inferiorly dissecting in the plane of the parotid-masseteric fascia. This is deep to the parotid gland and branches of the facial nerve. The masseter muscle as well as the coronoid process should be exposed (Fig. 44.2).
8. Next, the lateral rhinotomy incision is made, up to the level of the medial canthus. The depth of this incision should extend to the periosteum of the nasal and maxillary bones.
9. The palpebral conjunctiva of the lower lid is then incised, extending medially to divide the medial canthus and meet the lateral rhinotomy incision. The incision is then extended through the lateral canthus to connect to the temporal incision.

10. The eyelid incision should be dissected deeply down to the orbital rim, freeing the eyelid from the surrounding maxilla and orbital rim in a subperiosteal plane.
11. The nasolacrimal duct must be divided. This should be done as distally as possible at the medial orbital floor (Fig. 44.3).
12. When the medial canthal ligament is released, it is helpful to mark the location to enable exact reattachment at the end of the case. We recommend marking this with a small drill bit.
13. The lower face flap is further released by dissecting the premaxillary soft tissue in a subperiosteal plane. The infraorbital nerve (V2) will be identified and transected, and it too will be tagged for re-approximation at the end of the procedure.
14. The infraorbital nerve is mobilized by using a fine elevator to slightly widen the foramen and push the proximal nerve end through the foramen, and then it is released from attachments at the floor of the orbit. At this stage, its point of emergence from the foramen rotundum is easily found.
15. The premaxillary soft tissue is now mobilized down to the Le Fort I line, and the skeleton of the lower orbit, nose, maxilla, and zygoma should now be fully exposed.
16. At this time, the hemicoronal incision is made, and the frontotemporal soft tissues are elevated from the underlying temporalis muscle, staying deep to the tagged frontalis branches.
17. The periorbita is released from the medial and lateral walls of the orbit as well as the orbital floor to protect the orbit during osteotomies. The ethmoidal arteries should be tied, clipped, or cauterized if the tumor extends to the anterior cranial fossa or ethmoids.
18. The last step in preparation for osteotomies is to release the masseter muscle from the zygomatic arch.
19. It is now time to complete osteotomies to mobilize the orbito-zygomatico-maxillary (OZM) skeleton using a reciprocating saw or side-cutting drill bits.
20. An ipsilateral Le Fort I osteotomy extending laterally from the pyriform aperture is performed, followed by osteotomies at the medial orbital wall, nasal bone, frontozygomatic suture line, and posterior zygomatic arch at the attachment to the temporal bone (Figs. 44.2–44.3).
21. Osteotomies can be extended or customized as needed depending on the extent of the lesion.
22. The bone should be placed in a saline solution to preserve it for later reconstruction. Mucosa from the maxillary sinus should be removed, as the sinus will be obliterated during closure and reconstruction.
23. To access the infratemporal space, the temporalis muscle should be detached in its entirety from its origin on the skull and reflected inferiorly. It is essential to use due caution near the inferomedial aspect of the muscle, where its blood supply originates (Fig. 44.4).
24. An osteotomy of the coronoid process of the mandible can now be performed, if needed, to increase inferior rotation of the temporalis muscle. Again, the vascular pedicle must be protected.
25. The posterior and lateral walls of the maxilla can be removed with rongeurs.
26. The internal maxillary artery branches (sphenopalatine branches) are ligated.
27. An osteotomy is performed at the pterygoid plates at the skull base with a reciprocating saw or rongeurs.
28. At this point, the surgeon should be able to see the entire maxillary floor, nasal cavity, ipsilateral sinuses, NP, ETs, clivus, the orbital contents with periorbita still intact, ITF, and foramen rotundum.
29. If there is intracranial tumor, a craniotomy can now be performed by the neurosurgical team. Depending on the location of the tumor, a frontotemporal or temporal craniotomy will be performed (Fig. 44.5A).
30. Tumor resection will now include involved segments of the NP, together with any involved portions of the ET, pterygoid plates and muscles, sphenoid floor, and adjacent skull base, as dictated by the extent of the disease. The extent of open, three-dimensional access achievable by the FTA is quite broad (Fig. 44.5B).
31. Once the tumor resection is complete, attention is turned to the reconstruction.
32. Bony reconstruction of the middle fossa floor is not necessary; however, it is necessary to have well-vascularized tissue against the dura to separate the cranium from the aerodigestive tract below. The temporalis muscle is well suited for this purpose (Fig. 44.6). If this flap is not viable for any reason, or was part of the resection, vascularized tissue must be brought via free tissue transfer.
33. If the carotid artery has been exposed, it must also be covered with well-vascularized tissue.
34. The osteotomized OZM bone segment can now be replaced and fixated to adjacent healthy bone. It is important to ensure rigid fixation with a craniofacial plating system. All mucosa should be removed prior to replacement.
35. Once the temporalis muscle is translocated for reconstruction or removed with tumor resection, the temporalis donor site must be reconstructed to prevent concavity and cosmetic deformity. Autologous free adipose tissue grafting is well tolerated and usually satisfactory for reconstruction. A variety of implants for this purpose are available, but in our experience adipose tissue is a better choice in the acute setting.
36. The infraorbital nerve is now reapproximated. Neurorrhaphy is performed with 6-0 nylon suture.
37. The nasolacrimal duct should be redirected to its natural canal into the nose and stented using a Crawford stent for 6 to 8 weeks.
38. Soft tissue re-approximation should be performed carefully to ensure proper positioning without tension. Medial and lateral canthal placement must be precise, especially in affixing the medial canthal ligament at the previously marked location.
39. A temporary tarsorrhaphy is recommended to decrease scar contracture and the risk of ectropion.
40. The frontalis branches are now re-approximated with neurorrhaphy sutures (7-0 or 8-0 nylon) or entubulation techniques.
41. Meticulous soft tissue closure in layers will lead to minimal scar formation.

Common Errors in Technique

1. Improper placement of facial incisions or improper re-approximation, resulting in increased scar visibility
2. Improper reconstruction leading to facial asymmetry
3. Improper re-approximation of nerve endings, leading to poor functional healing
4. Failure to secure the bone graft may result in non-union and subsequent infection or deformity.
5. Compression of periorbita when replacing the OZM bone graft may result in entrapment of orbital soft tissues leading to diplopia.

POSTOPERATIVE PERIOD

Postoperative Management

1. Saline nasal spray is used to minimize nasal crusting. Periodic nasal endoscopy and débridement of crusts are needed until mucosalization of the transposed temporalis muscle is complete (6 weeks to several months).
2. Antiseptic rinse is used intraorally.

3. Antibiotics are continued 24 to 48 hours postoperatively.
4. Trismus may result from dissection of the masticator space and can be treated with a bite appliance (i.e., TheraBite) and stretching exercises.
5. A temporary tarsorrhaphy and traction stent are maintained for 1 to 2 weeks.
6. A nasolacrimal stent is maintained for 1 to 2 months.
7. In cases in which the dura is opened, early recognition for signs of CSF leak in the postoperative period is important as a lumbar drain or reoperation may be indicated.

Complications

Outcomes after FTA have been generally acceptable, but because of the magnitude of the procedure, there is the potential for significant morbidity.[7] Complications of the FTA can be understood in the context of the anatomy dissected during the FTA.

1. A major morbidity relates to the trigeminal nerve. Sacrifice of the trigeminal nerve or any of its branches may be required for tumor resection, so some of these complications may be unavoidable. Facial anesthesia puts the patient at risk for self-inflicted injury, especially when chewing food. V1 anesthesia carries a high risk of corneal ulcer and must be managed aggressively.
2. The transection and re-attachment of the frontalis (facial) nerve branches will lead to forehead paralysis that can be expected to resolve within 6 to 9 months when careful neurorrhaphy is done. If other branches of cranial nerve VII have been dissected or weakened, eye closure may be affected. It is essential to protect the eye from exposure keratitis in these cases to prevent further morbidity.
3. Trismus is common postoperatively both immediately due to pain and chronically due to pterygoid musculature scarring/fibrosis. Beginning 2 to 3 weeks after surgery, patients should regularly perform jaw opening and stretching exercises to prevent trismus.
4. Osteomyelitis of the OZM bone graft can occur with poor fixation of the bone or inadequate soft tissue coverage, especially with a history of irradiation.
5. Vascular complications can be severe, especially during or following dissection along the ICA. Bleeding is a risk and can be difficult to control. In the cases of ICA occlusion, ischemic brain injury is possible even with a satisfactory preoperative balloon occlusion test. These patients must be diligently managed to minimize neurologic complications.
6. Intradural dissection places the patient at risk of an immediate or delayed postoperative CSF leak.
7. Cosmetic deformities may arise even with careful planning of incisions and reconstruction. Facial scarring is generally acceptable, especially if placed along the margins of facial subunits. If the temporalis muscle is sacrificed or transposed, this leads to a depression in the temple that should be reconstructed with a free graft or implant at the time of surgery or at a secondary procedure.
8. Poor alignment of the medial canthus will result in facial asymmetry.
9. Ectropion can occur.
10. Conductive hearing loss and middle-ear effusion almost always results. Tympanostomy tube placement is usually deferred for 2 to 3 months after surgery because of concern for CSF leakage.
11. Velopharyngeal insufficiency may result if extensive pterygoid resection and disruption of the tensor veli and levator veli palatine muscles have taken place. Appropriate supportive care with speech pathology input is required.

Alternative Management Plan

Some neoplasms in this area are amenable to treatment with external beam radiation with or without chemotherapy. Discussion at a multidisciplinary tumor board will assist in deciding the best and alternate treatment plans.

DISCUSSION

Evidence-Based Medicine Question

What is the role for FTA in the era of endonasal skull base surgery?

Endonasal endoscopic skull base surgery has produced excellent functional and oncologic outcomes in recent years, and endoscopic surgery conducted in expert hands can now address some of the problems for which FTA was originally designed. However, for extensive tumors and tumor-like conditions involving the NP and extending to the central skull base, and especially recurrent tumors, open-access surgery, such as FTA, is still sometimes needed. The anatomy of each patient as well as the pathology and extent of the tumor requires careful evaluation prior to selecting an approach for resection.

Editorial Comment

The FTA provides unparalleled access to the nasopharynx, central skull base and infratemporal skull base in the coronal plane. When properly performed, the morbidity is acceptable. In order to avoid transection of the temporal branches of the facial nerve, I prefer to omit the skin incision from the lateral canthus to the preauricular incision. By working on both sides of this bridge of skin, visualization and tumor dissection are adequate in most cases.

With the advent of endoscopic techniques, the FTA is rarely used anymore for pathology of the NP and central skull base. Combined anterior approaches (endoscopic endonasal and transmaxillary) provide adequate visualization and room for instrumentation. Nevertheless, familiarity with the FTA is important when other approaches are not providing adequate access or when resources are limited.

Carl H. Snyderman

Access the review questions online at http://www.expertconsult.com



REFERENCES

1. Janecka IP, Sen CN, Sekhar LN, et al. Facial translocation for cranial base surgery. Keio J Med 1991;40:215–220.
2. Arriaga M, Janecka I. Surgical exposure of the nasopharynx: anatomical basis for a transfacial approach. Surgical Forum 1989;40:547–549.
3. Janecka IP. Classification of facial translocation approach to the skull base. Skull Base Surgery 1994;112:579–585.
4. Carrau R, Vescan A, Snyderman C, et al. Surgical approaches to the infratemporal fossa. In Myers EN (ed). Operative Otolaryngology/Head and Neck Surgery, 2nd ed. Elsevier, Philadelphia 2008.
5. Nuss D. Facial translocation approach to the central cranial base. In: Myers EN, Snyderman CH, Gardner PA, editors. Master Techniques in Otolaryngology—Head and Neck Surgery: Skull Base Surgery Wolters Kluwer Philadelphia. 2014.
6. Kuriakose MA, Sorin A, Sharan R, et al. Quantitative evaluation of transtemporal and facial translocation approaches to infratemporal fossa. Skull Base 2008;18:17–27.
7. Kekatpure VD, Rajan GP, Patel D, et al. Morbidity profile and functional outcome of modified facial translocation approaches for skull base tumors. Skull Base 2011;21:255–260.

REVIEW QUESTIONS

1. During elevation of a bicoronal scalp flap, which plane is correct for dissection?
   a. On the temporalis muscle
   b. On the deep temporalis fascia
   c. On the temporoparietal fascia
   d. In the subcutaneous tissue

2. During dissection, it is important to know the location of all cranial base foramina and neural structures. In relationship to the lateral pterygoid plate, where is the foramen ovale?
   a. Superior
   b. Inferior
   c. Medial
   d. Lateral

3. What is the main blood supply for the temporalis, and where does it travel in relation to the muscle?
   a. Superficial temporal artery, medial to the muscle
   b. Superficial temporal artery, superficial to the muscle
   c. Deep temporal artery branches, medial to the muscle
   d. Deep temporal artery branches, deep to the muscle

4. For which tumor scenario should the Facial Translocation Approach be considered when planning surgical options?
   a. Esthesioneuroblastoma extending through the cribriform plate with intracranial extension as well as posterior extension of tumor into the sphenoid sinus
   b. T3N1M0 Nasopharyngeal carcinoma that was just diagnosed with no previous treatment
   c. T3N1M0 Nasopharyngeal carcinoma recurrent 2 years following radiation treatment
   d. Juvenille nasopharyngeal Angiofibroma filling the right nasal cavity, tumor filling the nasopharynx, and tumor extending through the pterygopalatine fissure into the infratemporal fossa

SECTION 8 Hypopharynx and Esophagus

45 Esophagoscopy and Hypopharyngoscopy

Sameep Kadakia, Raymond Chai

INTRODUCTION

Disorders of the esophagus present a challenge to the otolaryngologist owing to the broad variety of pathology and oftentimes nonspecific nature of patient complaints. Using a mirror, Bozzini in 1809 was credited with the first attempts to evaluate the esophagus.[1] Initially described in 1868 by Kussmaul, the straight esophagoscope underwent multiple refinements until the early 1900s when Chevalier Jackson introduced the technique and instrumentation of modern rigid esophagoscopy.[2,3] After fiberoptic illumination was pioneered for this technique in the 1930s, flexible endoscopy was introduced in the 1960s and eventually led to the creation of the transnasal endoscope in the 1990s.[4-6] The evolution of the technique and instrumentation reflects the challenges associated with evaluating the esophagus. The advent of flexible and rigid endoscopy has afforded the modern day practitioner several methods for conducting a thorough patient-specific assessment.

The diagnosis and management of esophageal disorders requires a thorough understanding of esophageal anatomy. The esophagus is a muscular conduit extending from the inferior portion of the pharynx to the superior portion of the stomach. At the approximate level of the sixth cervical vertebra, the esophagus begins at the pharyngoesophageal junction in the hypopharynx and descends to the level of the 11th thoracic vertebra, where it enters the cardia portion of the stomach.[7,8] Shortly after its takeoff, the esophagus has a gentle leftward curvature until the level of the fifth thoracic vertebra, at which point it resumes its midline course. A second leftward curve of the esophagus can be appreciated as it crosses the descending aorta prior to entering the esophageal hiatus of the diaphragm; however, some sources have also noted the thoracic esophagus to have a right curvature due to the main stem bronchus.[9,10]

The esophagus measures 22 to 25 cm in total length and can be divided into cervical, thoracic, and abdominal portions.[10] The cervical esophagus begins at the cricopharyngeus and extends to the suprasternal notch, the thoracic portion from the suprasternal notch to the diaphragm, and the abdominal portion from the diaphragm to the stomach.[7,8] Throughout its length, there are three constrictions of the conduit that the endoscopist should be familiar with. Approximately 16 cm from the upper incisors, the first and narrowest constriction occurs at the cricopharyngeal sphincter. At 23 to 27 cm from the upper incisors, the second constriction occurs at the level of the left main stem bronchus. The final constriction occurs at the gastroesophageal sphincter, 38 to 40 cm from the upper incisor teeth.[7,8,10]

Histologically, the esophagus is composed of four circular layers: mucosa, submucosa, muscular layer, and adventitia. The esophagus lacks a serosa, a unique characteristic that differentiates it from the rest of the gastrointestinal tract.[7,8]

KEY OPERATIVE LEARNING POINTS

1. Flexible and rigid esophagoscopy allow for visualization and instrumentation of the esophagus under specific situations. Understanding both techniques allows the practitioner to perform a safe and thorough evaluation depending on the patient's general medical condition, ability to tolerate the procedure, and suspected diagnosis.
2. Understanding esophageal anatomy allows the endoscopist to safely perform esophagoscopy while minimizing the potential for complications such as perforation.

PREOPERATIVE PERIOD

History

- History of present illness
  - Age of the patient
  - Description of dysphagia or pain
    - Onset, provocation, progression, duration of episodes
    - Is this the first time or has this been repetitive/ongoing?
    - What maneuvers or interventions has the patient tried to combat the problem?
    - Is there dysphagia to solids, liquids, or both?
    - Any accompanying symptoms—postnasal drip, heart burn, globus sensation, hoarseness, weight loss, weakness, lethargy, night sweats, hemoptysis, cough, neck masses?
- Past medical history
  - History of cancer
  - History of radiation to the head or neck
  - Cardiac or pulmonary disease
  - Rheumatologic conditions such as scleroderma
  - Arthritis or vertebral problems that would limit motion of the neck
- Past surgical history
  - What surgery has the patient had in the past?
    - Any spinal fusion surgery?
    - Any chest, abdominal, or mediastinal procedures?
- Family history
  - Rheumatologic conditions in the family
  - History of cancer of the head and neck
  - Family history of dysphagia
- Social history
  - Very important to collect detailed history of smoking and alcohol use because these are risk factors for cancer
- Medication
  - Many medications can cause dryness and lead to a sensation of difficulty swallowing.

Physical Examination

- Always undertake a thorough examination of the head and neck.
- Examination/observation of the head and neck
  - Look for obvious deformities, masses, ulcerations, and gross abnormalities.
- Palpation of the head and neck
  - Carefully inspect the neck for masses and adenopathy; also palpate to see if any pain can be elicited.
  - Assess range of motion of the neck to assess for fibrosis and ability to extend or flex neck.
- Nasal endoscopy
  - Should routinely be performed on patients with dysphagia related to the laryngopharyngeal complex or the cervical esophagus (Fig. 45.1)
  - The nasal mucosa should be sprayed with a topical anesthetic/decongestant, such as lidocaine with phenylephrine.
  - Nasal endoscopy will help assess for dynamic movement of the laryngopharyngeal complex.
  - Evaluate the patency of the airway and the mobility of the vocal folds.
  - Evaluate for the presence of masses or mucosal abnormalities.

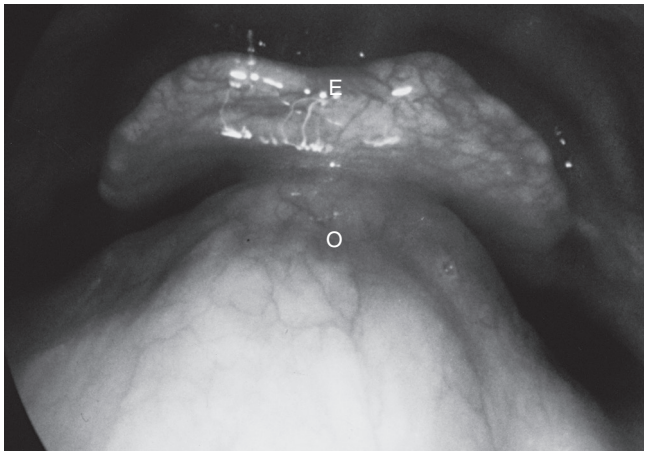

Fig. 45.1. Transnasal endoscopy showing a cervical osteophyte *(O)* displacing the epiglottis anteriorly *(E)*.

Imaging

- Not required but may be helpful to determine elements of disease pathology. Oftentimes, patients may be referred for a swallow evaluation with a speech-language pathologist to identify salient features of the dysphagia not reported by the patient. This evaluation can also be helpful to identify the potential location of pathology, as well as to begin swallowing therapy for the patient if needed. A modified barium swallow can also shed light on the dynamic process of swallowing and point to areas of concern.
- A preoperative contrast-enhanced esophagram may be helpful in diagnosing certain conditions, especially when dysmotility, mass effect, stricture, or diverticulum is suspected (Fig. 45.2). An esophagram can also identify foreign bodies not visualized on plain film.
- Barium is generally recommended as the contrast agent except when esophageal injury is suspected. In cases of suspected esophageal perforation, a water-soluble agent, such as gastrografin, is recommended because it does not induce

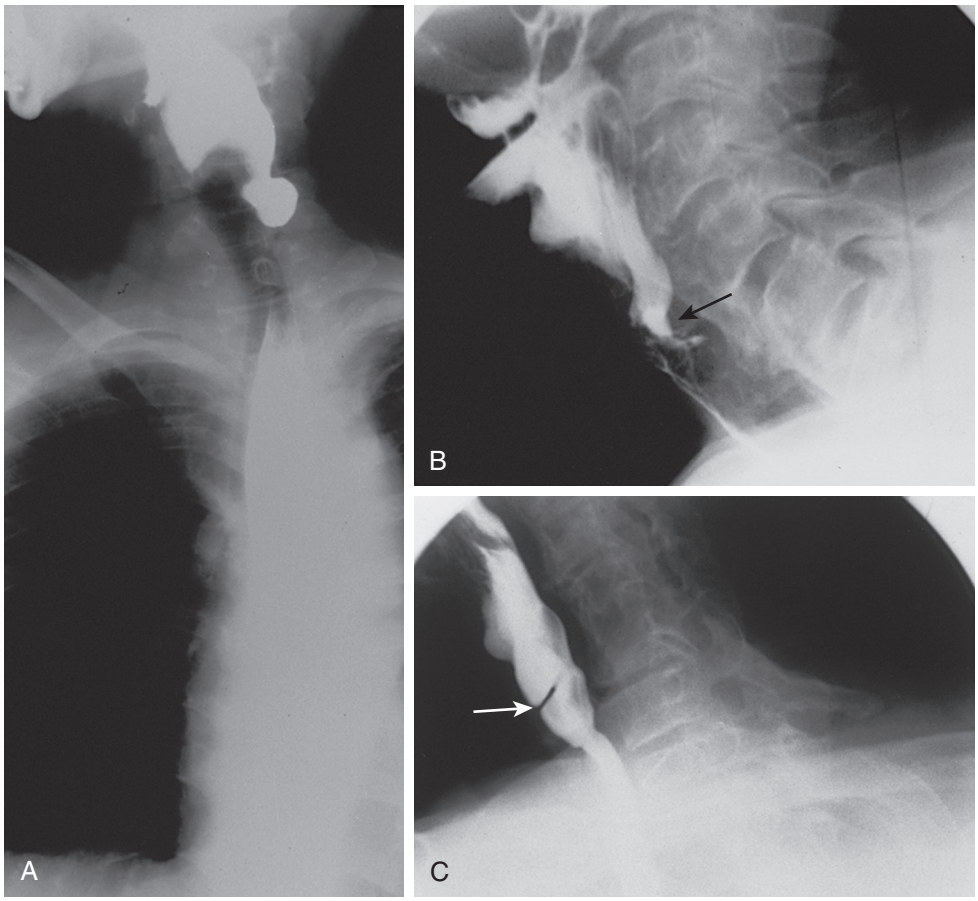

Fig. 45.2. **A**, Barium esophagram demonstrating a Zenker diverticulum. **B**, Barium esophagram of a patient with dysphagia and a large anterior cervical osteophyte *(black arrow)*. **C**, Barium esophagram demonstrating an esophageal web *(white arrow)*.

an inflammatory reaction with extravasation, which can be seen with barium. Barium is typically used if a perforation is not suspected because it does not induce the same inflammatory reaction as gastrograffin if aspirated into the lower respiratory tract.
- Important to note that masses identified on esophagram may require computed tomography (CT) imaging for further characterization

Indications for Rigid and Flexible Esophagoscopy

- Rigid or flexible esophagoscopy can be a diagnostic tool for the evaluation of suspected masses, trauma, strictures, or inflammatory conditions. It allows for visualization and the ability to take biopsies if needed.
- In the case of esophageal foreign body, rigid esophagoscopy can be used to visualize and extract the foreign body.
- Rigid esophagoscopy can be used as a surgical approach for dilation of strictures, placement of a stent, cricopharyngeal myotomy for diverticula, and laser procedures.

Contraindications

- Hemodynamic instability
- Poor general health
- Lack of patient and family understanding inhibiting informed consent
- Esophageal perforation

Preoperative Preparation

- The preoperative evaluation is minimal in these patients and typically requires only medical clearance to ensure safety for tolerating anesthesia. In some cases a cardiology clearance may be needed for patients with significant cardiopulmonary history.

OPERATIVE PERIOD

The general condition of the patient, purpose of intervention, and patient compliance are three factors that determine whether patients should undergo rigid esophagoscopy or flexible esophagoscopy. Flexible esophagoscopy can be performed either transorally or transnasally. Flexible esophagoscopy allows for visualization of the gastroesophageal junction and improved instrumentation in patients with limited range of motion at the neck or obstructing osteophytes. Transoral esophagoscopy is typically performed under sedation and topical anesthesia, whereas transnasal esophagoscopy is performed with topical anesthesia only. Transnasal esophagoscopy is well suited for the office setting, is of minimal risk, and allows for patients to return home without need for observation. This procedure can be performed with relatively little patient discomfort and is associated with mostly minor complications, such as epistaxis. It is imperative that prior to any procedure, a full discussion of the risks and benefits be discussed with patients in a manner suited to their level of understanding. Overall, flexible esophagoscopy is a viable option for patients that cannot tolerate general anesthesia; however, it is important to note that it has limitations and should be reserved for specific situations. According to recent studies, transnasal esophagoscopy can be helpful in changing the course of management in male patients, obese patients, and especially those patients with a history of dysphagia associated with head and neck cancer.

Rigid esophagoscopy is more advantageous in evaluating the hypopharynx, cricopharyngeal sphincter, and cervical esophagus. Oftentimes, redundant mucosal folds can hide pathology which can be readily missed with flexible esophagoscopy. Rigid instrumentation also confers the advantage of allowing larger suction cannulas and larger caliber instruments to be used for retrieval of foreign bodies.

Flexible Transnasal Esophagoscopy

- *Anesthesia*: topically sprayed 4% lidocaine and 0.05% oxymetazoline, followed by cotton pledgets with 0.5% tetracaine, followed by oral 2% lidocaine gel
- *Positioning*: patient kept sitting in the upright position or reclined
- *Antibiotics*: not needed on a routine basis
- *Monitoring*: no cardiac monitoring necessary if patient is not sedated

Instruments and Equipment to Have Available

- Transnasal esophagoscope (TNE)
- Video monitor
- Flexible suction
- Flexible biopsy instrument
- Flexible grasping instrument

Key Anatomic Landmarks

- Nasal passage, nasopharyngeal inlet, laryngeal inlet, piriform sinus, postcricoid area, endolarynx, superior esophageal constrictor, and gastric inlet

Prerequisite Skills

- Transnasal endoscopy

Operative Risks

- Esophageal perforation, mucosal injury (less likely than with rigid)

Surgical Technique

- The patient is placed into the sitting position either upright or slightly reclined.
- Nasal cavity is sprayed with lidocaine and oxymetazoline spray. After decongestion, cotton pledgets with tetracaine are placed for further anesthesia. Patient is then given 2% lidocaine gel to gargle and swallow. At this time, the nasal cavity and pharynx should be well anesthetized.
- Under direct visualization, the TNE should be introduced into the larger nasal passage and advanced to the pharynx, taking the largest pathways with care not to injure the mucosa of the septum or turbinate.
- Prior to advancing into the hypopharynx, an overall view of the laryngopharyngeal complex can be appreciated.
- The scope is then used to examine each piriform sinus.
- The scope is then placed into the left piriform sinus and, while the patient swallows, is advanced into the esophagus through the cricopharyngeal inlet.
- As the scope is advanced, insufflation can be performed to evaluate the esophageal mucosa. The lower esophageal sphincter and gastroesophageal junction should be assessed before entering the stomach.
- After entering the stomach, the scope is used to evaluate the lining of the stomach. The scope is retroflexed to evaluated the gastric cardia.
- While the scope is being withdrawn, the walls of the esophagus are again examined.

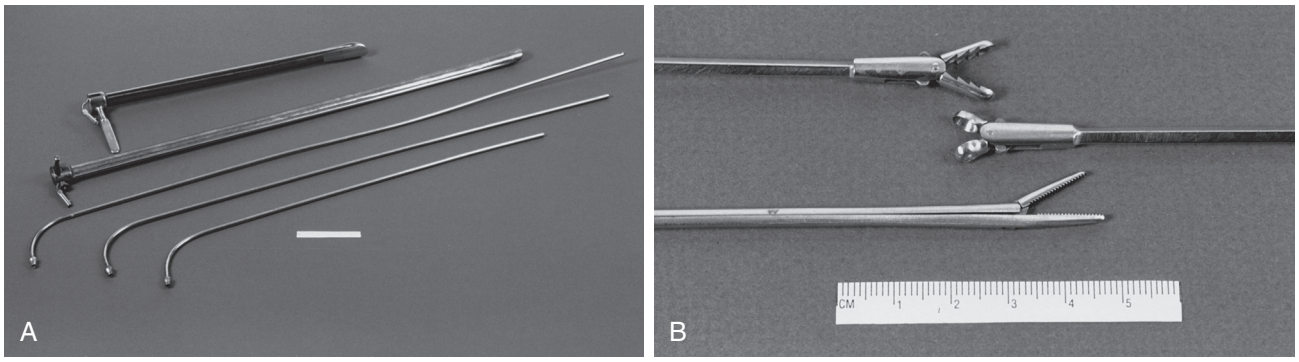

Fig. 45.3. **A**, Esophagoscopes and long suction cannulas; instruments available in variety of sizes. **B**, Esophagoscopy forceps. From top to bottom are forceps with serrated edges, cup forceps, and alligator forceps. A cup forceps is most suitable for biopsies, whereas the other two are most useful for the retrieval of foreign bodies.



Fig. 45.4. The thumb of the left hand is used as a fulcrum for the instrument to prevent pressure over the incisors and is used to advance the instrument while the right hand is used only to guide the esophagoscope by changing the angle of entry.

Common Errors in Technique

- Inadequate anesthesia leading to patient discomfort and poor cooperation
- Passing the scope through narrow portions of the nasal cavity, causing the patient significant pain
- Failure to evaluate the esophageal mucosa while withdrawing the scope

Rigid Esophagoscopy

- *Anesthesia*: General anesthesia with endotracheal intubation
- *Positioning*: Neutral position without head extension. Extension with techniques such as a shoulder roll can make passage of the esophagoscope more difficult
- *Antibiotics*: Not needed on routine basis
- *Monitoring*: standard cardiacpulmonary monitoring with pulse oximetry

Instruments and Equipment to Have Available

- Rigid esophagoscope
- Grasping forceps
- Biopsy forceps
- Cannula suction
- Camera head
- 0-degree long endoscope
- Optical forceps (Fig. 45.3)

Key Anatomic Landmarks

- Oropharynx, teeth, laryngeal inlet, piriform sinus, postcricoid area, endolarynx, superior esophageal constrictor, and gastric inlet

Prerequisite Skills

- Direct laryngoscopy, manipulation of oral cavity structures, ability to avoid dental trauma

Operative Risks

- Esophageal perforation, mucosal injury

Surgical Technique

- Following anesthesia, the patient is positioned with the neck extended
- A tooth guard or wet sponge is used to protect the teeth
- Using a scissor-like maneuver, the mouth is opened and the endoscope is inserted into the oral cavity
- Endoscope held between thumb and index finger of the nondominant hand (Fig. 45.4)
- Scope advanced to posterior pharyngeal wall, and then follows posterior pharyngeal wall down to hypopharynx (Fig. 45.5)
- The scope is further advanced through the cricopharyngeal inlet. The nondominant hand always remains on the scope to stabilize it while the dominant hand can be used to change angle of movement.
- If resistance is met, muscle relaxants, deflation of the endotracheal tube, or the use of a smaller esophagoscope can circumvent the obstruction.
- The instrument is advanced to the gastroesophageal junction with care not to injure the esophageal mucosa. Care must be taken to never advance the scope when pressure is encountered because this could increase the risk of perforation.
- An esophageal suction can be used to remove secretions from the field.
- After scope reaches junction, it is slowly withdrawn while reinspecting the walls of the esophagus.
- It is best to biopsy lesions at the end of the procedure to prevent bleeding from obscuring the view. Multiple biopsies are often required to obtain a sufficient sample of the lesion.



Fig. 45.5. Insertion of the esophagoscope. The tip of the instrument is advanced over the posterior pharyngeal wall. The base of the tongue and the larynx are displaced anteriorly until the axis of the endoscope is parallel to the longitudinal axis of the lumen.

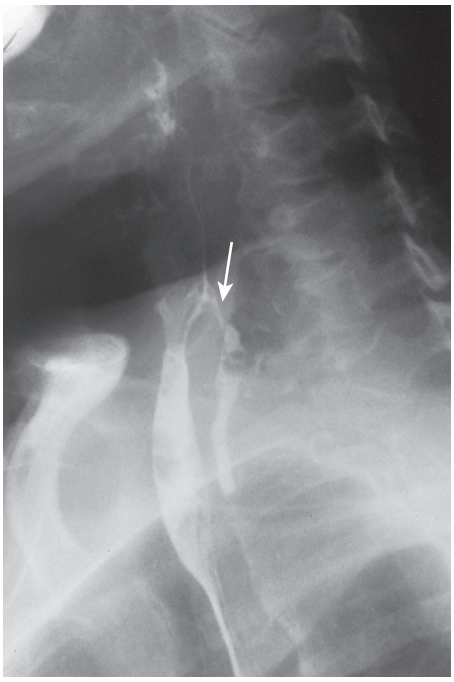

Fig. 45.6. Gastrografin esophagogram, lateral view, demonstrating an esophageal perforation *(arrow)* with extravasation of contrast material into the mediastinum.

POSTOPERATIVE PERIOD

Postoperative Management

- Usually performed as an out-patient procedure
- Patients generally observed for several hours, during which clear liquids can be administered
- Patients are monitored for signs of mediastinitis, such as fever, tachycardia, odynophagia, chest pain, and crepitus on examination of the neck
- If recovery period is uneventful, patients can be discharged home with instruction to return promptly if any of the aforementioned symptoms occur.

Complications

- Dental trauma
  - Chipped tooth, avulsion of tooth
  - With a tooth fracture or avulsion, urgent consultation with a dentist or oral surgeon is warranted. Often, the tooth can be replaced with interdental wire fixation.
- Perforation of the esophagus
  - Most commonly occurs from aggressive movement from the scope against resistance, or from dilation or instrumentation during the procedure
  - The endoscopist can use a lumen finder or guidewire to help with finding the true esophageal lumen.
  - If a perforation is suspected, the patient should be admitted for intravenous broad-spectrum antibiotic care. A nasogastric tube should be placed and the patient should be kept NPO. Again, the patient should be closely monitored for signs of mediastinitis.
  - The surgeon and anesthesiologist should also evaluate for signs of pleural injury, such as diminished breath sounds, high ventilator peak pressure, and subcutaneous emphysema. A chest radiograph should be obtained if any of the signs are present.
  - When the patient is awake and stable, a gastrograffin esophagram should be performed to evaluate for a leak (Fig. 45.6).
  - Large perforations should be explored and repaired as soon as possible. Small perforations can be managed conservatively by leaving a nasogastric tube, continuing intravenous antibiotics, using H_2 blockers, and keeping the patient NPO.
- Arrhythmia or hypotension
  - Usually from vasovagal reflexes and may be self-limited
  - Removal of instrument is helpful in returning arrhythmia to baseline rhythm
  - If arrhythmia is repetitive or if patient experiences hemodynamic compromise, an anticholinergic agent such as atropine can be administered.

Alternative Management Plan

- Imaging including esophagram and/or CT scan

Evidence-Based Question

What is the rate of esophageal perforation after esophagoscopy?

Esophageal perforation is a potentially devastating complication after either rigid or flexible esophagoscopy. According to the literature, the rate of esophageal perforation is approximately 1%; however, this rate can increase to up to 6% if patients are undergoing concurrent procedures, such as dilation of a stricture or removal of a foreign body. Most studies suggest a higher rate of perforation for rigid esophagoscopy compared with flexible procedures. In a study of 546 procedures by Tsao et al., a perforation rate of 2.6% was noted, all following rigid esophagoscopy. The authors suggest that patients for whom esophagoscopy was performed by junior residents may be most susceptible to injury and perforation. As such, close supervision is critical in academic training centers. Although esophageal perforation after esophagoscopy is rare, care needs to be taken to ensure meticulous technique

during the procedure; excessive force and misapplication of pressure or direction need to be recognized in advance and avoided.

Editorial Comment

Endoscopy of the aerodigestive tract is an important component in the evaluation of certain patients with problems in the head and neck. Full evaluation of the mucosal extent of tumors helps to guide decision making. Imaging evaluation is often inadequate in determining the mucosal extent because there is often effacement of the air space of the pyrifom sinuses.

Ruling out synchronous primary cancers and other lesions of the esophagus is also important when evaluating patients with cancer of the hypopharynx and cervical esophagus. Drs. Kadakia and Chai have given the essential details for the different methods of esophagoscopy. Flexible esophagoscopy is both safer and more effective than rigid esophagoscopy for this purpose. In addition, many patients with cancer of the hypopharynx or cervical esophagus require prolonged enteral access, and careful placement of the flexible esophagoscope to facilitate percutaneous endoscopic gastrostomy is required.

Hypopharyngoscopy represents a special challenge and is a hybrid procedure. Some specific things to keep in mind are that use of various laryngoscopes to displace the endotracheal tube anteriorly will help in visualizing the postcricoid area and esophageal inlet. These areas and the anterior, lateral, and medial walls and apex of the pyriform sinus are difficult to visualize with flexible scopes unless the larynx is displaced. Newer techniques used in the management of cancer of the hypopharynx, such as endoscopic and open partial laryngectomy, are available, and endoscopic assessment of exposure and tumor extent and accessibility using telescope and microscope helps in determining the feasibility for transoral laser surgery or transoral robotic surgery (TORS).

Telescopic visualization along with microlaryngoscopy for the better assessment of the mucosal extent of the cancer and documentation of the stage of the cancer for both early and advanced cancers is important for cancers in both surgical sites.

Laryngoscopes can also be used to facilitate exposure of the esophageal inlet for esophagoscopy when this access is difficult. In some cases the angle of approach or the cancer or even a cervical osteophyte will make access difficult. Videolaryngoscopy is often helpful to lift the tongue and provide this access. It is often helpful to have the surgeon place the laryngoscope and advance it while an assistant does the air insufflation, suction, and maneuvering. It is important to remove the air in the stomach on removing the scope, and the mucosa is best evaluated on the way out rather than on the way in.

For cancers of the hypopharynx and cervical esophagus, determination of the inferior extent of the cancer is important in determining resectability, particularly with reference to placement of vascularized tissue for circumferential reconstruction. For cancers that extend beyond the cervicothoracic inlet, consideration of total esophagectomy and gastric pull-up rather than free tissue transfer is advisable to avoid life-threatening leaks of saliva or gastric contents into the upper mediastinum.

Instrumentation has improved significantly over the past three decades, so when performed correctly, hypopharyngoscopy and esophagoscopy can be done very safely; however, in some cases, it is still better to avoid instrumenting the esophagus to avoid perforation. Unexpected pain and fever should be warnings of an unrecognized complication postoperatively. If there is any question of perforation after an esophagoscopy, the patient should be kept under careful observation until complications have been excluded or managed. In general, antibiotics and analgesics are not required for patients undergoing endoscopy including esophagoscopy. An exception is percutaneous endoscopic gastrostomy, when prophylactic antibiotics are indicated.

Christopher H. Rassekh

Access the review questions and additional sources list online at http://www.expertconsult.com



REFERENCES

1. Kelly HDB. President's address: Origins of oesophagology. Proc R Soc Med 1968;62:781–786.
2. Staffel JG, Pillsbury HC. The rigid esophagoscope: a new handle on an old problem. Otolaryngol Head Neck Surg 1991;105:483–486.
3. Boyd AD. Chevalier Jackson: The father of American bronchoesophagoscopy. Ann Thorac Surg 1994;57:502–505.
4. Bacon CK, Hendrix RA. Open tube versus flexible esophagoscopy in adult head and neck endoscopy. Ann Otol Rhinol Laryngol 1992;101:147–155.
5. Shaker R. Unsedated trans-nasal pharyngoesophagogastroduodenoscopy (T-EGD): Technique. Gastrointest Endosc 1994;40:346–348.
6. Dean R, Dua K, Massey B, et al. A comparative study of unsedated transnasal esophagogastroduodenoscopy and conventional EGD. Gastrointest Endosc 1996;44:422–424.
7. Beasley P. Anatomy of the pharynx and esophagus. In: Kerr AG, Gleeson M, editors. Scott-Brown's Otolaryngology. 6th ed. Oxford, UK: Butterworth-Heinemann; 1997.
8. Postma GN, Seybt MW, Rees CJ. Esophagology. In: Snow JB, Wackym PA, editors. Ballinger's Otolaryngology Head & Neck Surgery. 17th ed. Shelton, Conn: BC Decker Inc; 2009. p. 975–995.
9. Hollinshead WH. Anatomy for Surgeons: The Head and Neck. 3rd ed. vol. 1. Philadelphia: Harper & Row; 1982.
10. Lee KJ, editor. Essential Otolaryngology: Head and Neck Surgery. 4th ed. New York: Medical Examination; 1987.

REVIEW QUESTIONS

1. All of the following are true regarding esophagoscopy except:
   a. The operator should be careful not to push the scope aggressively against areas of resistance
   b. The operator should change the angle of the scope with the nondominant hand and guide the scope at the oral entry point with the dominant hand
   c. Flexible and rigid endoscopy both have advantages and disadvantages
   d. Esophagoscopy can be a versatile tool for therapeutic and diagnostic intervention

2. Which of the following is a potential complication of rigid esophagoscopy:
   a. Esophageal perforation
   b. Dental trauma
   c. Mucosal trauma
   d. All of the above

3. If esophageal perforation is suspected postoperatively, which of the following are important measures to take?
   a. Intravenous antibiotics
   b. NPO status
   c. Nasogastric tube
   d. All of the above

ADDITIONAL SOURCES

Gray H. Mediastinum. In: Standring S, editor. Gray's Anatomy: The Anatomical Basis of Clinical Practice. 40th ed. New York, NY: Churchill Livingstone Elsevier; 2008. p. 939–957. [chapter 35].

Howell RJ, Pate MB, Ishman SL, et al. Prospective multi-institutional transnasal esophagoscopy: Predictors of a change in management. Laryngoscope 2016;126(12):2667–2671.

Olsen AM. Chevalier Jackson lecture. Esophagology: an update. Ann Otol Rhinol Laryngol 1982;91(6 Pt 1):551–557.

Polat B, Karahatay S, Birkent H, Gerek M. The practicability of transnasal esophagoscopy and the evaluation of patient's perception: a prospective study. Clin Exp Otorhinolaryngol 2016;9(4):366–369.

Prinsley PR, Murrant NJ. Cervical esophageal perforation caused by diagnostic flexible esophagoscopy. J Otolaryngol 1989;18(6):314–326.

Tsao GJ, Damrose EJ. Complications of esophagoscopy in an academic training program. Otolaryngol Head Neck Surg 2010;142(4):500–504.

Vollweiler JF, Vaezi MF. The esophagus: anatomy, physiology, and diseases. In: Cummings CW, Flint PW, Harker LA, et al., editors. Otolaryngology Head and Neck Surgery. 4th ed. vol. 2. Philadelphia, PA: Mosby-Elsevier; 2005.

46 Dysfunction of the Upper Esophageal Sphincter

Bridget Hathaway, Ricardo L. Carrau

INTRODUCTION

The cricopharyngeus muscle is the major component of the upper esophageal sphincter (UES). The cricopharyngeus muscle is innervated by the pharyngeal plexus, which is composed of contributions from the vagus and glossopharyngeal nerves. Increasing evidence suggests that contributions from the recurrent laryngeal nerve (RLN) also innervate the cricopharyngeus muscle. The origin of the parasympathetic innervation is vagal, whereas sensory branches are derived from the glossopharyngeal nerve. Sympathetic fibers arise from the superior cervical ganglion and also join the pharyngeal plexus.

In its normal resting state, the cricopharyngeus muscle is in tonic contraction. When a swallow occurs, the cricopharyngeus relaxes during pharyngeal contraction (mediated by the vagus nerve), and anterior-superior movement of the larynx opens the UES to allow passage of the bolus into the esophagus; the bolus itself causes further distention of the UES. Dysphagia related to dysfunction of the UES results from (1) failure of cricopharyngeal relaxation, which can be due to lack of vagal innervation or loss of the normal viscoelastic properties of the muscle; (2) discoordination between cricopharyngeal relaxation and pharyngeal contraction; or (3) weakness of the suprahyoid musculature with poor elevation (anterosuperior movement) of the laryngeal complex.

Cricopharyngeal myotomy is used for alleviating cricopharyngeal dysfunction caused by lesions of the central and peripheral nervous systems, which affect laryngeal and pharyngeal muscle activity and coordination, as well as for the treatment of postsurgical dysphagia.

One of the most widely recognized manifestations of UES dysfunction is Zenker's diverticulum. Although the first description of a pharyngoesophageal diverticulum is attributed to Ludlow in 1769, this entity became known as Zenker's diverticulum after it was described in Zenker and Ziemssen's *Krankheiten des Oesophagus,* a landmark compilation of esophageal pathology published in 1877. Killian clarified the anatomic site of origin as the space between the inferior constrictor muscle and the cricopharyngeus muscle—hence its name Killian's triangle. Zenker's diverticulum is a pulsion diverticulum that forms in the muscular dehiscence of Killian's triangle as the UES fails to open with pharyngeal contraction, thus raising pressure in the pharynx (Fig. 46.1). Other areas of weakness have been identified and can lead to variations of the site of origin of the diverticulum (Killian-Jamieson and Lamier triangles). Failure of UES opening may be the result of failure of cricopharyngeal relaxation or weakness of laryngeal elevation.

The standard treatment of a Zenker's diverticulum includes a myotomy of the UES, which may be combined with resection of the diverticulum through a left-sided cervical incision; however, other techniques are also in common use. Dohlman and Mattson described an endoscopic technique for cricopharyngeal myotomy that has been modified with the introduction of bivalved endoscopes to provide better exposure of the party wall between the diverticulum and esophagus (containing the cricopharyngeus muscle) and the use of lasers, staplers, and harmonic scalpels for its transection. Advances in endoscopic instrumentation enabled Collard and associates to perform the first esophagodiverticulostomy with an endoscopic stapler in 1993. This procedure involves endoscopic division of the cricopharyngeus muscle with marsupialization of the diverticulum into the pharyngoesophagus. Modification of the stapler as described by Lang and colleagues allows the division to extend as close as possible to the inferior aspect of the diverticulum. Alternative endoscopic approaches use the CO_2 laser or the harmonic scalpel to divide the party wall between the esophagus and diverticulum.

KEY LEARNING POINTS

1. History of dysphagia and confirmation of upper esophageal dysfunction with imaging are essential in the diagnosis of dysfunction of the UES.
2. Presence of normal or nearly normal pharyngeal function will optimize swallowing outcomes following cricopharyngeal myotomy.
3. Transcervical and endoscopic approaches are valid treatments for Zenker's diverticulum and multiple factors should be considered in selecting the best approach for each patient.

PREOPERATIVE PERIOD

History

1. History of present illness
   a. Dysphagia to solids more than liquids
   b. Dietary restrictions related to dysphagia
   c. Regurgitation of undigested food
   d. Unintentional weight loss
   e. Recurrent pneumonia
   f. Gastroesophageal reflux symptoms and response to treatment
2. Past medical history and comorbid conditions
   a. Cerebrovascular accident
   b. Neurologic diseases (Parkinson's, amyotrophic lateral sclerosis [ALS]) or neuromuscular diseases (inclusion body myositis)
   c. History of head and neck surgery or radiation therapy to the neck

Physical Examination

1. Palpation of laryngeal elevation with swallowing
2. Flexible laryngoscopy
   a. Rule out other pathologies such as tumor or infection.
   b. Pooling of secretions in hypopharynx
3. Functional endoscopic examination of swallowing (FEES)
   a. Hypopharyngeal residue is suggestive of UES dysfunction.
   b. Evaluate for aspiration.
   c. Regurgitation (most commonly to the left piriform)

Imaging

1. Barium esophagram
   a. Prominence of the cricopharyngeus muscle on lateral view at the level of C5-C7 vertebral bodies
   b. Failure of relaxation of the cricopharyngeus muscle (Fig. 46.2)
   c. Presence of Zenker's diverticulum (Fig. 46.3)

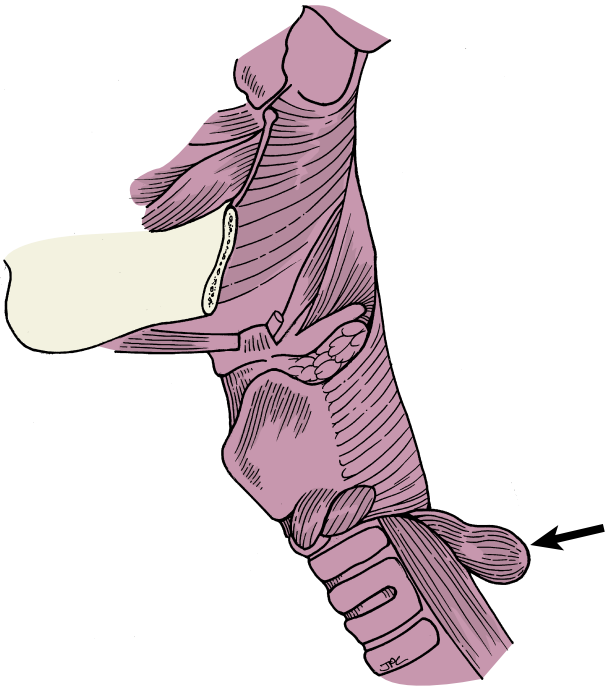

Fig. 46.1. Zenker's diverticulum posterior to the esophagus *(arrow).*

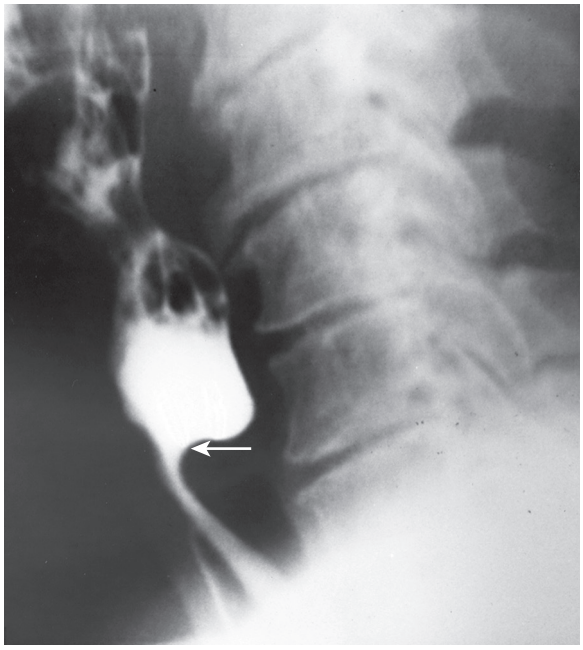

Fig. 46.2. Barium esophagogram (lateral view) demonstrating failure of relaxation of the cricopharyngeus muscle *(arrow).*

2. Modified barium swallow
   a. Identify and quantify laryngeal penetration and aspiration.
   b. Evaluate the coordination of swallow and laryngeal elevation.
3. High-resolution impedance manometry
   a. Allows for measurement of pharyngeal strength, UES relaxation, and intrabolus pressures
   b. During swallowing, normal pharyngeal contraction with elevated UES residual pressure is suggestive of UES dysfunction.

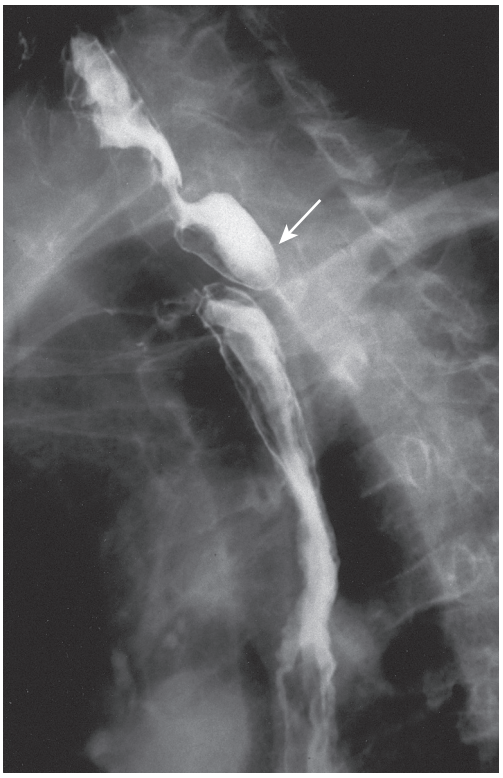

Fig. 46.3. Barium esophagogram demonstrating Zenker's diverticulum *(arrow).*

Indications

- Moderate to severe dysphagia symptoms with poor UES opening on Modified barium swallow MBS
  - Normal or nearly normal pharyngeal function, which is required for propulsion of the bolus
  - Adequate laryngeal elevation, which is required for opening of the UES
- Dysphagia causing significant weight loss
- Complications of aspiration (i.e., recurrent pneumonia)

Contraindications

- Medically unfit
- Diffuse pharyngeal motor abnormalities and poor anterosuperior laryngeal elevation
- Comorbid conditions such as ALS, Parkinson's disease, or cerebellar atrophy that would contribute to diffuse pharyngeal motor abnormalities
- Conditions that affect the opening of the lower esophageal sphincter LES (achalasia, stricture)
- Severe esophageal dismotility with antegrade regurgitation
- Uncontrolled gastroesophageal reflux disease GERD

Preoperative Preparation

- Discontinue antiplatelet drugs and herbal medicines.
- Optimize GERD control.

OPERATIVE PERIOD

Anesthesia

- General anesthesia is preferred.
- Local anesthesia can be used if the patient's condition does not permit general anesthesia (transcervical approach only).

Positioning

- Supine
- Shoulder roll facilitates exposure for transcervical approach

Perioperative Antibiotic Prophylaxis

- Antibiotics are administered during induction of anesthesia.
- Choices
  Clindamycin
  Ampicillin-sulbactam
  Cephalosporin and metronidazole

Monitoring

Routine anesthesia monitoring

Instruments and Equipment to Have Available

- Endoscopic approach for Zenker's diverticulum
  - Weerda diverticuloscope
  - Endo-GIA stapler
  - Endoscopic stitch or alligator forceps for retraction
  - Zero-degree and 30-degree endoscopes
- Transcervical approach
  - Rigid esophagoscope
  - Standard head and neck set
  - Bipolar cautery

Key Anatomic Landmarks

- Cricoid cartilage marks the level of the cricopharyngeus muscle
- Cricothyroid joint is the entry point of the RLN
- Cricopharyngeus muscle can be distinguished from inferior pharyngeal constrictor by the horizontal orientation of its fibers

Prerequisite Skills

- Rigid esophagoscopy
- Transcervical approach to the retropharyngeal space
- Closure of pharyngotomy

Operative Risks

- Injury to the teeth
- Contained salivary leak or salivary fistula
- Bleeding
- Mediastinitis

Surgical Technique

Cricopharyngeal Myotomy

- A nasogastric tube (NG) is placed.
- Transverse incision in a skinfold at the level of the cricoid cartilage
- Subplatysmal flaps are elevated inferiorly to the clavicle and superiorly above the thyroid notch.
- Sharp separation of the sternocleidomastoid (SCM) muscle from the strap muscles exposes the carotid sheath.
- The SCM and carotid sheath are separated from the strap muscles, thyroid gland, and laryngotracheal complex and retracted anterolaterally and rotated to the right to allow entry into the retropharyngeal-prevertebral space (Fig. 46.4).
- The middle thyroid vein and the omohyoid muscle may be divided to facilitate the exposure and decrease the need for retraction. A large double hook is placed in the posterior aspect of the midthyroid lamina, and the larynx, trachea, and thyroid gland are rolled medially. Care should be taken to avoid placing the retractor in the area of the cricothyroid joint in order to avoid injury of the RLN.
- The nasogastric tube is palpated through the entrance into the retropharyngeal space. The NG tube is engaged into the lateral aspect of the pharynx and grasped with Babcock clamps above and below the area of the cricopharyngeus, effectively isolating this muscle.
- This maneuver should be performed close to midline to avoid injury to the RLN. The cricoid cartilage will mark the level of the cricopharyngeal muscle; therefore, if the myotomy is performed at the level of the cricoid cartilage and extended above and below this level, it will be successful.
- Using a small hemostat, the oblique muscle fibers of the inferior constrictors are separated from the mucosa of the hypopharynx (Fig. 46.5). The muscle fibers are divided with

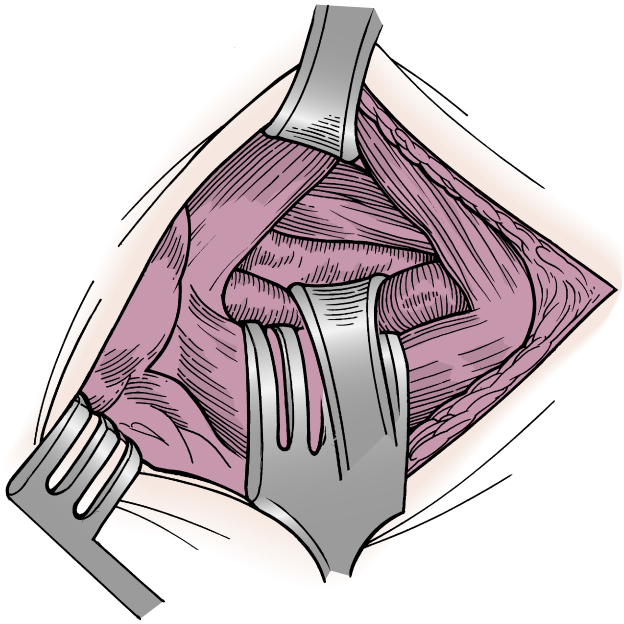

Fig. 46.4. The carotid sheath is retracted laterally to expose the prevertebral fascia.

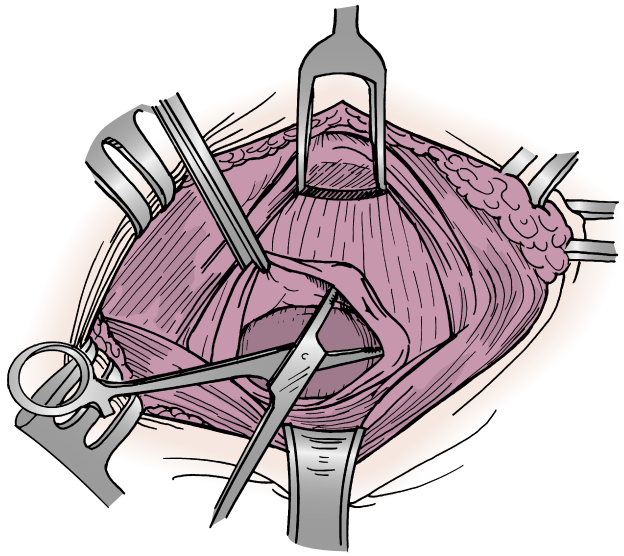

Fig. 46.5. Muscle fibers of the upper esophageal sphincter are separated from the hypopharyngeal mucosa in the midline with a hemostat.

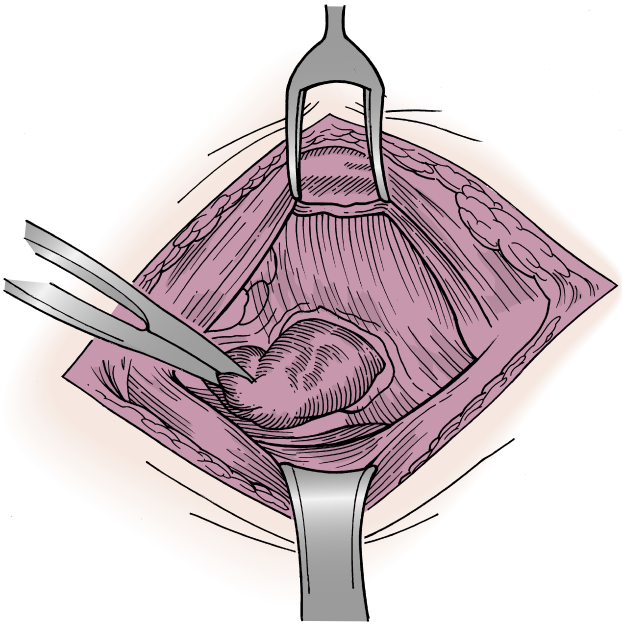

Fig. 46.6. The diverticulum is dissected from surrounding tissue.

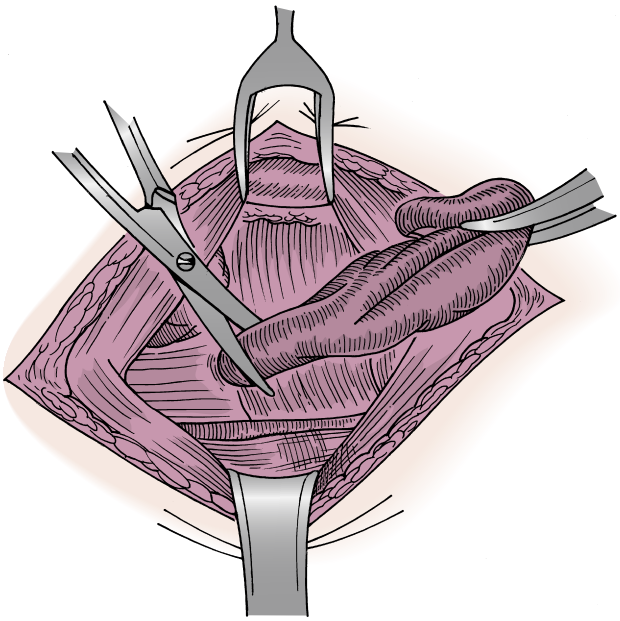

Fig. 46.7. Diverticulectomy is performed by excising the sac.

a bayonet-type, insulated bipolar electrocautery as the hemostat is advanced along the plane between the muscles and mucosa. Change from an oblique to a horizontal direction of the muscle fibers marks the change from the inferior constrictor to the cricopharyngeal muscle.
- Extension of the myotomy to include 1 to 2 cm of esophageal musculature will also ensure that the myotomy is complete. These steps are repeated until the entire height of the cricopharyngeus muscle is divided. The Babcock clamps and the NG tube are removed.
- The wound is then irrigated with normal saline solution and closed in layers.
- If the pharynx is entered inadvertently, the nasogastric tube is left in place and secured to the nose with a suture. Any opening into the pharynx is closed with absorbable suture in an interrupted fashion. The wound is then irrigated and closed in layers over a suction drain, which is inserted into the area of the prevertebral fascia between the operative site and the carotid sheath.

Excision of Zenker's Diverticulum

Transcervical Approach
- The transcervical approach is preferable for diverticula that are too small to accommodate the endoscopic stapler (<3 cm) or when endoscopic visualization is precluded by anatomic factors.
- Direct laryngoscopy is performed and the contents of the diverticulum aspirated. The mucosal surface is thoroughly examined to rule out squamous cell carcinoma, which occurs in a small percentage of patients with Zenker's diverticulum.
- Cricopharyngeal myotomy is accomplished as described in the previous section. For most patients a myotomy suffices to alleviate symptoms caused by Zenker's diverticulum, especially when the diverticulum is small. Large pouches, however, are excised to prevent retention of secretions or food and regurgitation on assuming a recumbent position.
- The diverticulum is dissected from the surrounding tissue as the myotomy is performed (Fig. 46.6). If a diverticulectomy is to be performed, the neck of the diverticulum may be treated in one of two ways. The classic technique is to grasp the tip of the sac with a clamp and excise the sac (Fig. 46.7). Excessive traction on the sac may lead to overresection of hypopharyngeal mucosa and result in a stricture. A 3-0 or 4-0 gastrointestinal suture is then used to close the mucosa. Alternatively, a stapler may be used to excise the sac and repair the pharyngeal mucosa.
- The muscles should not be closed over the mucosa.
- Diverticulopexy was developed to avoid the risks inherent in entering the pharynx. When a diverticulopexy is to be carried out, the fundus of the diverticulum is inverted and sewn to the prevertebral fascia.
- The wound is then irrigated and closed in layers over a suction drain, which is inserted into the area of the prevertebral fascia between the operative site and the carotid sheath.

Endoscopic Approach
- A bivalved endoscope is inserted with one blade into the cervical esophagus and the other into the diverticulum (Fig. 46.8). The endoscope is suspended.
- Visualization is achieved with a 0-degree rigid endoscope.
- The "bar" between the pouch and the esophagus, which consists of the cricopharyngeus muscle, is stabilized by grasping it with alligator forceps or by using a stitch placed with an endoscopic stitching device.
- The Endo-GIA stapler is then used to divide the party wall between the esophagus and diverticulum, with several rows of staples being deposited on each side in the process (Figs. 46.9 and 46.10). A modification of the Endo-GIA stapler as described by Lang and colleagues includes shortening the anvil so that it is as close as 1 mm to the metal clips. This allows the division of the party wall and marsupialization of the diverticulum to a level close to its fundus.

Common Errors in Technique

Incomplete transection of the muscle fibers comprising the UES can lead to persistent symptoms. If a pharyngeal closure is present, residual UES fibers can create a persistent high-pressure zone proximal to the UES, which can predispose to a pharyngeal leak in the postoperative period.

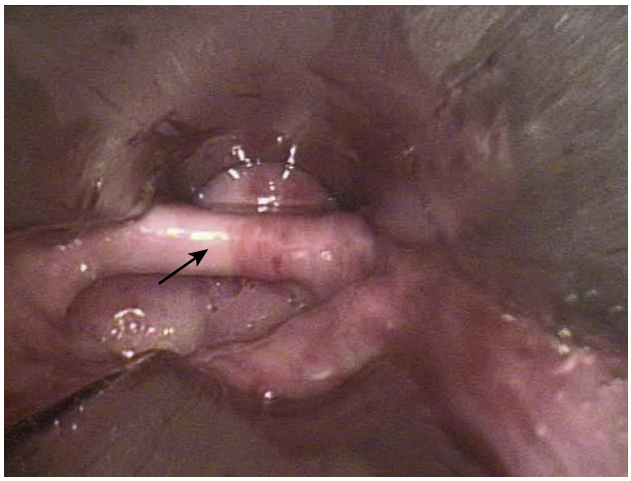

Fig. 46.8. Endoscopic view of the "bar" dividing the esophagus and pouch (the esophagus is anterior) *(arrow)*.

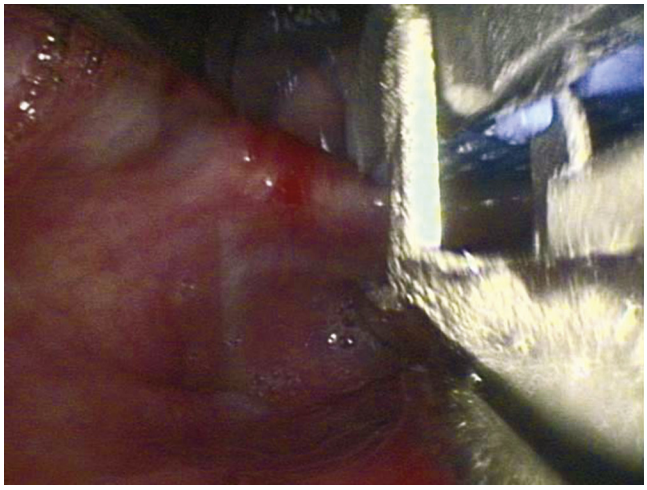

Fig. 46.9. The Endo-GIA stapler is positioned on the "bar" between the esophagus and pouch before stabilization with alligator forceps.

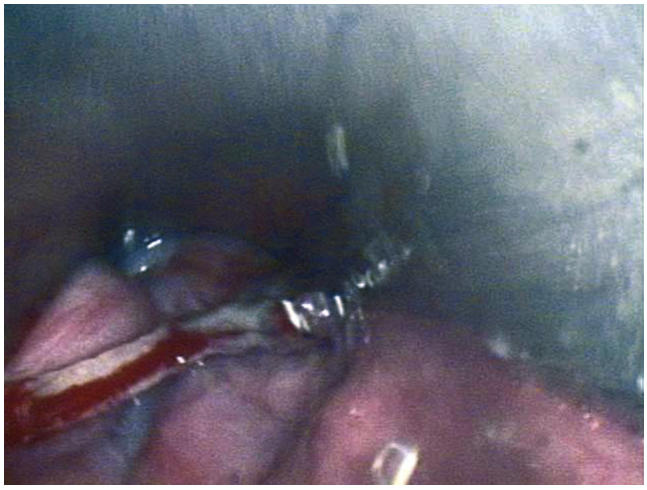

Fig. 46.10. The party wall between the esophagus and diverticulum has been divided and the resulting esophagostomy stapled in the process.

Postoperative Management

- Inadvertent entry into the pharynx is ruled out with a gastrografin esophagogram.
- For patients who have undergone primary cricopharyngeal myotomy without pharyngeal entry, a soft diet is started and advanced to solid as tolerated; the patient is usually discharged the day of surgery. If a stapler diverticulectomy has been performed, the patient may be kept in the hospital overnight, and the suction drain is removed on the first postoperative day. Diverticulectomy repaired with traditional suture requires a longer hospital stay with no oral intake (3 to 7 days).
- If the pharynx was entered, a nasogastric tube should be passed to decompress the stomach over the first 48 hours and then be used for tube feeding. On the fifth day, the tube may be withdrawn after confirming the lack of a leak by a gastrografin esophagogram. The patient is given a soft diet for 1 week and then advanced to more solid food as tolerated.
- If the patient complains of a change in voice, laryngoscopy should be performed to rule out vocal cord paralysis/paresis from injury to the RLN.

Complications

- Contained salivary leak and salivary fistula should be treated with surgical drainage.
- Mediastinitis
- Injury of the RLN

Alternative Management Plan

- Botulinum toxin A (BTX A) has been used as an alternative to surgical cricopharyngeal myotomy in the treatment of a select group of patients with UES dysfunction.
  - BTX A may be injected transcutaneously under electromyographic guidance in the office or endoscopically in the operating room.
  - Given the preliminary nature of the studies, BTX A should generally be reserved for patients who refuse surgery or are not surgical candidates or when the diagnosis, prognosis, and expected response to myotomy are in question.
  - BTX A improves only UES relaxation; thus patients with poor pharyngeal propulsion or weak elevation of the larynx, such as those with Parkinson's disease or ALS, are unlikely to benefit from BTX A injection.
- Dilation with balloons or bougies can also be employed in the treatment of UES dysfunction. While less invasive than surgical techniques, the results of dilation tend to be temporary.
- Observation is an option for any patient not amenable to surgical intervention.
- Enteral feeding access is an option for severe dysphagia, resulting in malnutrition and/or recurrent pneumonia.

DISCUSSION

Reports of outcomes after cricopharyngeal myotomy are limited to retrospective reviews. Prognosis is generally related to the underlying cause of dysphagia, as well as the severity of dysphagia. As mentioned previously, those with focal neurologic deficits or isolated UES dysfunction are likely to have better functional outcomes than those with central neurologic processes or underlying oropharyngeal dysphagia.

With respect to the treatment of Zenker's diverticulum, transcervical and endoscopic techniques are both acceptable, and it is prudent to select a technique with which the surgeon

is experienced that is best suited to the patient's needs. The endoscopic approach avoids potential RLN injury but has the potential complications of oral injury, dental injury, or laryngeal edema. Regardless of technique, complete myotomy is essential to minimize the persistence or recurrence of dysphagia.

Evidence-Based Medicine Question

Does the transcervical or endoscopic approach result in better outcomes in the treatment of Zenker's diverticulum?

Comparisons of endoscopic versus external approaches for the treatment of Zenker's diverticula have been retrospective. It is generally accepted that the endoscopic technique is associated with shorter operative time, length of hospital stay, and time to resume oral diet. A recent systematic review by Verdonck and Morton found a higher success rate but more complications associated with external approaches.[1] Based on this, they advocate an external approach for younger patients with few comorbidities, as well as for those patients whose anatomy precludes endoscopic exposure.

Editorial Comment

Disorders of upper esophageal function are frustrating to patients. The authors have focused on Zenker's diverticulum, which is the most common indication for operative management of muscular dysfunction in this area. As described, Zenker's results at least in part due to lack of relaxation of the cricopharyngeus muscle. Most upper esophageal dysfunction is caused by this failure of relaxation of the muscle.

Dr. Hathaway and Dr. Carrau have done an excellent review of the pathophysiology and management of Zenker's. Prior to the development of the GIA stapler technique, most patients were treated with the open approach, but the endoscopic approach (Dohlman procedure) was employed safely using electrocautery or laser. Complications from violation of the retropharyngeal space can occur if the procedure is performed improperly.[2] As discussed, an open approach is probably ideal for younger patients and for patients in whom identification of the cricopharyngeus endoscopically is difficult due to exposure. Patients with smaller diverticulae seem to be more challenging from the endoscopic approach as well.

Cricopharyngeal denervation is an important technique, and the authors have discussed the utility of botulinum toxin injection. In addition to management of patients with Zenker's, this technique can be used for patients with dysphagia or strained voice following total laryngectomy as an alternative to pharyngeal plexus neurectomy. The reader is encouraged to discover the literature in this realm as well.

Christopher H. Rassekh

Access the review questions and additional sources list online at http://www.expertconsult.com



REFERENCES

1. Verdonck J, Morton RP. Systematic review on treatment of Zenker's diverticulum. Eur Arch Otorhinolaryngol 2015;272:3095–3107.
2. Chang CW, Liou SS, Nettervill JL. Anatomic study of laser-assisted endoscopic cricopharyngeus myotomy. Ann Otol Rhinol Laryngol 2005;114:897–901.

REVIEW QUESTIONS

1. The best predictor of good functional outcome after criciopharyngeal myotomy is
   a. Age
   b. Preserved pharyngeal strength
   c. UES opening on MBS
   d. Preoperative diet

2. Which of the following is *not* a potential complication of endoscopic cricopharyngeal myotomy for Zenker's diverticulum?
   a. Pharyngeal leak
   b. Dental injury
   c. Mediastinitis
   d. RLN injury

3. Which of the following technical aspects is important in avoiding RLN injury during cricopharyngeal myotomy?
   a. Identification of inferior constrictor muscle fibers
   b. Division of cricopharyngeus muscle fibers posteriorly in the midline
   c. Retraction of the carotid sheath laterally
   d. Division of the omohyoid muscle

4. Which of the following factors can contribute to UES dysfunction?
   a. Vagus nerve injury
   b. Weakness of suprahyoid musculature
   c. Discoordination between pharyngeal contraction and cricopharyngeus muscle relaxation
   d. All of the above

ADDITIONAL SOURCES

Dohlman G, Mattison O. The endoscopic operation for hypopharyngeal diverticula. AMA Arch Otolarygol 1960;71. 744–572.

Hoffman HT, Fischer BA, VanDenmark D, et al. Botulinum neurotoxin injection after total laryngectomy. Head Neck 1997;19:92–97.

Singer MI, Blom ED, Hamaker RC. Pharyngeal plexus neurectomy for alaryngeal speech rehabilitation. Laryngoscope 1996;96:50–54.

Von Doersten PG, Byl FM. Endoscopic Zenker's Diverticulotomy (Dohlman procedure): forty cases reviewed. Otolaryngol Head Neck Surg 1997;116:209–221.

47 Penetrating Trauma to the Hypopharynx and Cervical Esophagus

Trevor Hackman

INTRODUCTION

Penetrating trauma to the hypopharynx and cervical esophagus is a potentially life-threatening injury, which may be the result of iatrogenic injury, accidental impalement, or assault. Multiple routine procedures and surgeries (intubation, nasogastric tube placement, rigid and flexible esophagoscopy with or without dilation/biopsy/foreign body removal, Zenker's diverticulectomy, cervical spine surgery, and transesophageal echocardiography) carry a risk of visceral perforation, which if not recognized can quickly lead to patient compromise. Patients involved in major motor vehicle accidents, especially when ejected from the car, are at high risk for impalement injuries. Finally, the victims of violent crimes (stabbings and gunshot wounds) also may suffer aerodigestive tract injuries. Typically, the patients with potential noniatrogenic penetrating traumas have multiple confounding injuries (spinal instability, fractures, cranial injuries, vascular injuries), which may delay recognition of the visceral injury.

As perforations can quickly lead to life-threatening danger space infections, including mediastinitis, a high index of suspicion is necessary. The most critical factor affecting patient outcome is the time between the injury and the initiation of treatment.[2] Rapid diagnosis and treatment are paramount to patient survival, as a delay in treatment of more than 24 hours significantly increases morbidity and mortality.[3]

Many iatrogenic perforations and penetrating gun shot wound (GSW) or stab wounds can be managed conservatively with broad-spectrum antibiotics against upper aerodigestive tract flora (e.g., ampicillin-sulbactam, clindamycin), nasogastric tube placement, and nothing by mouth status for 3 to 5 days.

Adequate nutrition is necessary for healing, and in cases where nasogastric tube placement is not feasible, laparoscopic gastrostomy tube placement can be performed.

KEY OPERATIVE LEARNING POINTS

1. High index of suspicion is necessary to identify patients with penetrating trauma to the hypopharynx and cervical esophagus, as the early symptoms may be subtle, and delayed recognition may be life-threatening.
2. The most common cause of penetrating trauma is iatrogenic, accidental visceral injury during a procedure.
3. The signs and symptoms of a perforation include neck pain, dysphagia, odynophagia, new onset fever, tachycardia, chest pain, subcutaneous emphysema, or pneumomediastinum and should raise suspicion for pharyngeal perforation.

PREOPERATIVE PERIOD

History

1. History of present illness
   a. Potential mechanisms of injury should be investigation
      1) Iatrogenic:
         a) Intraluminal instrumentation of the aerodigestive tract: Intubation, nasogastric tube placement, rigid and flexible esophagoscopy with or without dilation/biopsy/foreign body removal, Zenker's diverticulectomy, and transesophageal echocardiography
         b) External trauma—Cervical spine surgery, open Zenker's
      2) Traumatic; motor vehicle collision (MVC) ejection, gunshot, or stab wound
   b. The stability of a patient should be assessed.
      The ABCs of trauma (airway, breathing, circulation) should be assessed and addressed prior to further evaluation of a suspected perforation. In the cases of gunshot wounds and stabbings, the patient may also have life-threatening laryngeal and tracheal injuries, which may necessitate an immediate surgical airway.
   c. The patient's symptoms should be assessed.
      Neck pain, dysphagia, odynophagia, vocal pain, voice changes, and chest pain are all potential symptoms of a perforation, particularly after an at-risk procedure in the vicinity of the hypopharynx or esophagus.
   d. Nil per os (NPO) status
      Has the patient been eating? Is there pain with eating?
2. Past medical history
   a. Prior treatment
   b. Medical illness: ingestion of a foreign body
   c. Surgery: recent surgical procedure involving the neck, spine, or aerodigestive tract Zenker's diverticulectomy
   d. Family history
   e. Medications

Physical Examination

1. Vital signs
   As perforations can quickly lead to patient compromise, an assessment of vital signs and airway is critical. Fever, tachycardia, hypotension, tachypnea, and hypoxia can occur with perforation injuries. Airway symptoms, including dysphonia, hoarseness, and stridor, should alert the team to consider a surgical airway, such as a cricothyroidotomy or awake tracheostomy, depending upon the patient's stability.
2. Neck
   Examination of the neck may reveal fluctuance, bruising, evidence of recent surgical incision, or subcutaneous emphysema. Penetrating external trauma may also result in injury to the great vessels and airway.
3. Flexible fiberoptic laryngoscopy
   Confirms a safe and patent airway and may reveal mucosal abnormalities and bleeding if the trauma is high in the hypopharynx. Vocal fold mobility can be evaluated, as well as whether the patient is a candidate for intubation or requires an awake tracheostomy.

Imaging

1. Chest radiograph
   a. Chest radiograph is an expedient method to assess for subcutaneous emphysema, pneumomediastinum, pneumothorax, or tracheal shift.
2. Esophagogram
   a. Esophagogram is the most sensitive test for detecting perforation, ranging from 75% to 100%. Water-soluble contrast, such as meglumine diatrizoate (Gastrografin), is the preferred method for detecting perforations, as the extravasated contrast is quickly absorbed and cleared by the tissues, unlike barium. However, Gastrografin is extremely damaging to pulmonary tissues and may lead to life-threatening pneumonitis and pulmonary edema due to powerful osmotic shifts. Therefore it should be avoided in patients at risk for aspiration or complex laryngotracheal injury. A negative esophagogram does not definitively rule out a perforation, and thus when the index of suspicion is high, patients should still be managed accordingly to clinical findings.
3. Computed tomography (CT) spine/neck/chest
   a. When concomitant spine, vascular, or laryngotracheal injury is suspected in the stable patient, a CT is useful for evaluating soft tissue damage. In the case of suspected perforation, especially with a negative swallow study, a CT scan of the neck will often demonstrate free air in the soft tissues, as well as the extent of fluid collection/infection in the danger space and mediastinum, leading to prompt exploration and drainage. Pneumomediastinum, pneumothorax, and pleural infections can also be more clearly seen and prompt earlier intervention by a Thoracic Surgery (Fig. 47.1).
4. Angiography
   a. If zone 3 vascular injury is also suspected in the stable patient, angiography is useful for triaging management of the patient's problems.

Indications

1. Evidence of large perforation on esophagogram



Fig. 47.1. Axial computed tomography scan demonstrating free air in the deep planes of the neck, suggestive of an injury to the aerodigestive tract.

   A large pharyngeal defect is unlikely to heal spontaneously and will require direct repair or soft tissue flap coverage.
2. Chest radiograph demonstrating significant (or increasing) subcutaneous emphysema, pneumothorax, or tracheal shift
   In the case of expanding free air with airway shifting or pneumothorax, neck exploration with drain placement and likely chest tube insertion is necessary to prevent pulmonary compromise.
3. Progressive decline in patient stability despite conservative management
   Patients with progressive fevers and cardiopulmonary instability require surgical intervention, as they are likely developing mediastinal fluid collections and mediastinitis requiring drainage.

Contraindications

1. Patients who respond to conservative management
2. Major airway, vascular, and spine injuries require stabilization prior to investigation for visceral injury to the pharynx.

The patient should be stabilized first from an ABC standpoint and be covered with broad-spectrum antibiotics if perforation is suspected, prior to diagnostic tests (esophagogram) being performed.

Preoperative Preparation

1. Confirm cervical c-spine clearance.
2. Confirm plan for airway management—intubation versus tracheostomy.
3. Discontinue antiplatelet drugs if possible.
4. Monitor Hb/Hct and transfuse if necessary.

OPERATIVE PERIOD

Anesthesia

General: Surgery will require instrumentation of the pharynx and/or exploration with in the neck. To perform this safely, the airway must be secured and patient movement controlled.

Positioning

Supine: The patient is positioned the same as any neck exploration or endoscopy with the head of the bed turned toward the surgeon.

Perioperative Antibiotic Prophylaxis

Ampicillin-sulbactam (3 grams IV)
Piperacillin/tazobactam (3.375 grams IV)
Clindamycin with ciprofloxacin if allergic to penicillin

Monitoring

Recurrent laryngeal nerve (RLN)—In cases of patients with a intact and functioning larynx, for whom intubation is feasible, real-time recurrent laryngeal nerve monitor (while not shown in the literature) may be used to aid in laryngeal nerve identification and preservation during exploration of a contaminated neck wound.

Instruments and Equipment to Have Available

1. Basic rigid panendoscopy set

2. Basic neck dissection set: scalpel, scissors, retractors (Army/Navy, Deaver, Richardson), fine dissecting forceps (McCabe, Jake's), needle drivers, and suture
3. Nasogastric tube
4. Drains: Penrose drain, Jackson-Pratt drain
5. Methylene blue

Key Anatomic Landmarks

1. Laryngeal framework: The thyroid ala is a thin wedge-shaped cartilage, which houses the arytenoids and false and true vocal folds, and is positioned on top of the cricoid. The cricoid cartilage is the only complete cartilaginous ring of the airway. Anteriorly the cricothyroid membrane bridges the two structures and is the site for placement of an emergent airway (cricothyroidotomy).
2. Inferior pharyngeal constrictors: This muscle originates from the thyroid ala and cricoid cartilage in two separate bellies. Zenker's diverticulum develops between the two bellies of this muscle (thyropharyngeal and cricopharyngeal) in a small gap, known as Killian's triangle.
3. Recurrent laryngeal nerve: The recurrent laryngeal nerve courses from the thoracic inlet superiorly along the tracheoesophageal groove and enters the larynx at the posterior edge larynx between the thyroid ala and cricoid at the cricoarytenoid joint. The right recurrent laryngeal nerve has a more oblique course and in rare cases (retroesophageal subclavian artery) may be nonrecurrent.
4. Thyroid gland: A highly vascular horseshoe-shaped endocrine gland that bridges over the cricoid or upper trachea, overlies the esophagus, and occupies the bilateral central compartment (see Chapter 78).
5. Parathyroid glands: Small (3 to 5 mm) amber-colored endocrine glands deep to the thyroid lobe that control calcium absorption (see Chapter 84).

Prerequisite Skills

1. Upper aerodigestive tract endoscopy (see Chapters 18 and 45)
2. Neck dissection and exploration (see Chapters 64 and 75)

Operative Risks

1. Intraoperative injury to the recurrent laryngeal nerve
   If initial attention is paid to nerve identification using the laryngeal landmarks listed previously prior to management of the visceral injury, the risk is significantly reduced. In some settings, nerve monitoring may be beneficial. In cases of bilateral injury, tracheostomy may be necessary.
2. Parathyroid injury
   Leads to hypoparathyroidism and hypocalcemia. Preventable by performing meticulous dissection deep to the thyroid and identifying the glands, prior to addressing the perforation. In cases of recognized parathyroid injury, the glands may be minced and reimplanted into neck musculature. Intraoperative parathyroid hormone testing can be used to predict parathyroid function postoperatively, when injury is suspected.
3. Bleeding
   The common carotid artery, subclavian artery, thyrocervical trunk, jugular vein and superior thyroid vessels, and anterior jugular veins all course through this region and, depending on the location and trajectory of injury, may be involved. Meticulous dissection and high index of suspicion for preoperative trauma prevent injury to the major vessels.
4. Substernal extension
   In cases where the injury or neck infection extends substernally a Thoracic surgeon should be consulted for intraoperative management.

Surgical Technique: Direct Repair—Small and Early-Recognized Defects

Endoscopy: (see Chapters 18 and 45)

Prior to neck exploration, endoscopy/esophagoscopy may be helpful for assessment of the perforation and guided placement of a nasogastric tube. Care should be taken to avoid further expansion of the perforation. Insufflation flexible esophagoscopy is not recommended, as this will increase subcutaneous free air.

A horizontal neck crease at the level of the laryngeal framework is marked and injected with local anesthesia between the anterior sternocleidomastoid muscle edges (Fig. 47.2).

The crease chosen depends on the level of the injury; esophageal injuries are best exposed with midline incision over the trachea, whereas high hypopharyngeal injuries are best approached through incision over the thyroid ala.

- Subplatysmal flaps are elevated superiorly to the hyoid and inferiorly to the clavicle.
- Dissect the outer tunnel between the sternocleidomastoid muscle and strap muscles.
- Identify a carotid sheath and retract its contents laterally (Fig. 47.3).
- Identify and preserve the superior laryngeal nerve.
- Identify and preserve the recurrent laryngeal nerve.

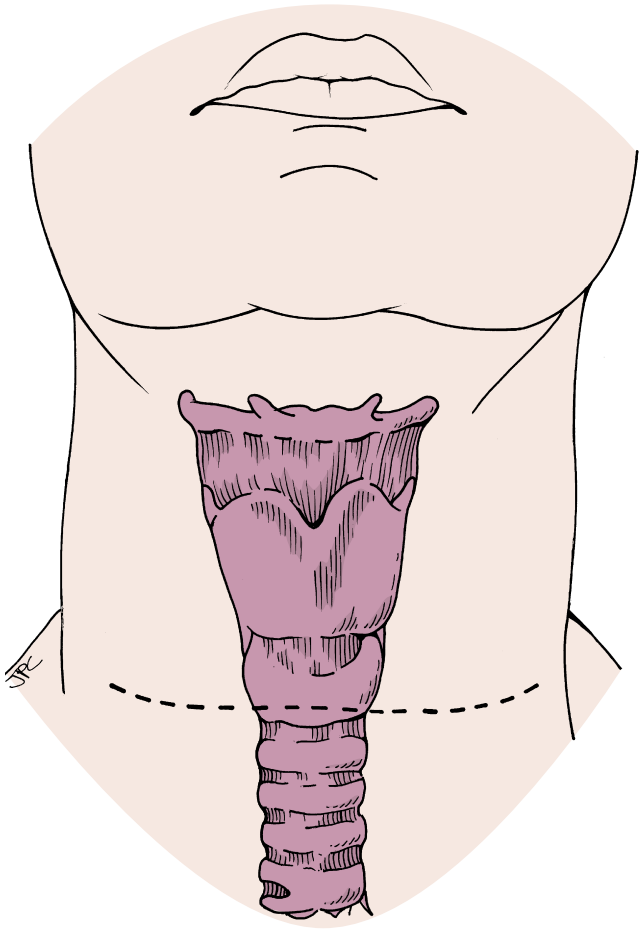

Fig. 47.2. A transverse cervical incision at the level of the inferior edge of the cricoid cartilage. This incision provides bilateral access to the pharyngoesophageal area. However, it can be adapted to a particular need according to the level of injury and laterality.

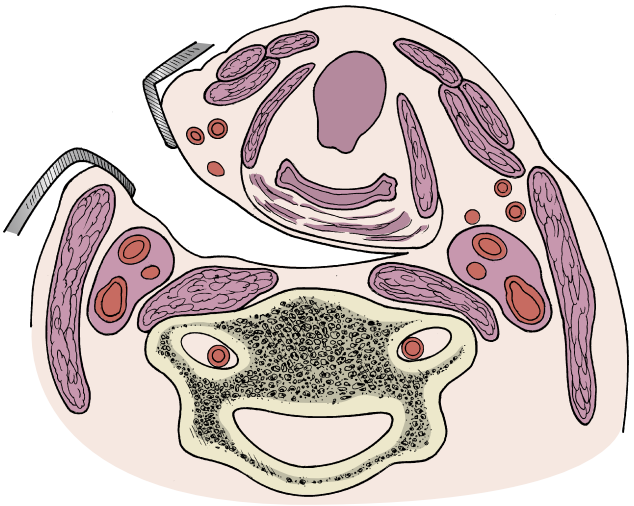

Fig. 47.3. Axial view of the surgical route to the pharyngoesophagus (retropharyngeal space). The retractor on the *left* is displacing the sternocleidomastoid muscle and the contents of the carotid sheath. The retractor on the *right* is rotating the larynx in an anteromedial direction.

- Blunt and sharp dissection are used to mobilize the laryngopharyngeal complex with the identified nerves off of the prevertebral fascia.
- Search for site of perforation—use of methylene blue-dyed saline irrigation of the oral cavity may aid in identification of the perforation.[4]
- The wound cavity is copiously irrigated with warm sterile saline.
- Perforation edges are freshened with a 15-blade scalpel and then closed in two layers: First an absorbable suture is used to invert and closed the mucosal injury; second the constrictor muscles or esophageal muscles are closed with interrupted suture.
- Blue dye irrigation of the oral cavity may be used to confirm watertight closure.
- The wound cavity is copiously irrigated with warm sterile saline.
- A suction drain is placed in the prevertebral space and extended into the chest as needed for pleural space contamination.
- For severe chest infection, mediastinitis, chest tube placement, and thoracotomy are often required.
- The neck is closed in multilayer fashion; platysmal closure, followed by skin closure

Surgical Technique: Direct Repair—Large or Delayed Defects

For large defects, or defects older than 24 hours, direct repair is not feasible or recommended. In these cases, local or regional flaps may be necessary, depending on the surrounding tissue quality. In severe cases, temporary esophagostomy may be necessary.

- Follow the previous steps until the freshening of perforation edges.
- Myofascial strap or sternocleidomastoid transposition flaps may be elevated and rotated over the defect to either buttress a closure or patch a defect (Fig. 47.4).[5,6]
- For more contaminated wounds and/or larger defects not amenable to local muscle flaps, a pectoralis major flap or free tissue transfer may be performed.[7]

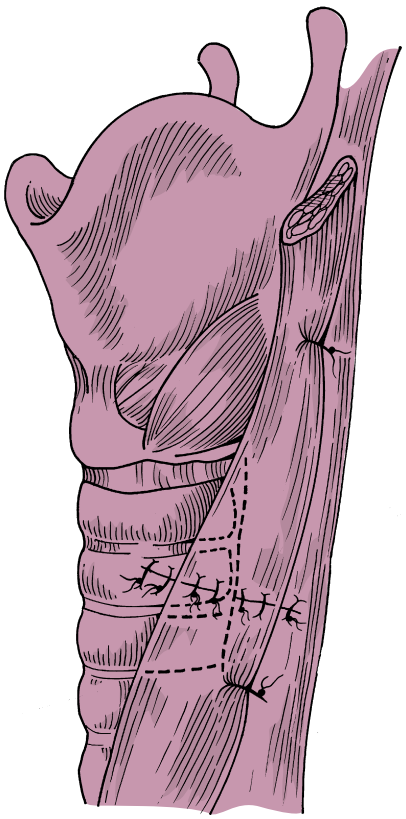

Fig. 47.4. Tracheoesophageal injury repaired primarily and reinforced with a strap muscle pedicle flap.

Surgical Technique: Diversion

In some cases (e.g., contaminated wounds, multiple sites of injury, complete esophageal transaction, or an unstable patient), a diverting esophagostomy is an efficient and safe method for salivary diversion, allowing time to stabilize the patient and develop a future surgical plan.

- Follow the previous steps until the perforation is identified.
- The cervical esophagus is mobilized inferiorly, and the injured segment is externalized and sewn to the cervical skin with Vicryl sutures as a controlled fistula (Fig. 47.5).

Surgical Technique: Special Circumstances

- In the case of concomitant tracheal injury, direct repair of the tracheal injury should be performed. The practitioner should have a low threshold for performing a tracheostomy below the level of tracheal injury to prevent further free air in the mediastinum.
- If the esophageal and tracheal injuries overlap, an interpositional local myofascial flap should be placed to prevent tracheoesophageal fistula.
- In the case of vascular injury, after repair of the vessel, salivary diversion should be planned away from the vessel, and one should consider local muscle flap coverage of the vessel repair.

Common Errors in Technique

1. Improper neck incision placement for the level of the defectFailure to properly localize the fistula may result

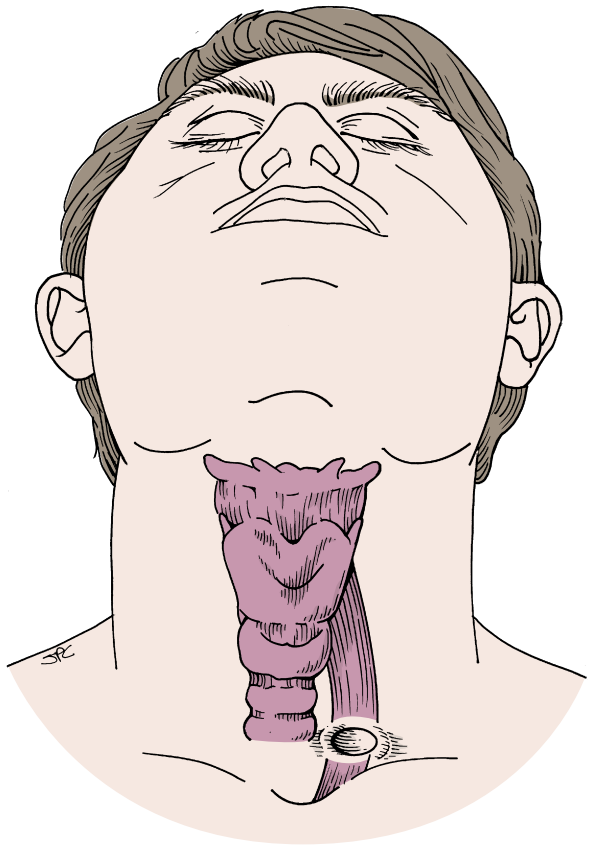

Fig. 47.5. Esophagostomy after completion.

in an incision that does not offer easy exposure and thus requires further lateral extension of the incision, or risk operative in a poor visual field, increasing the traction on tissues and risk of injuries.

2. Approaching prevertebral space too medially
   After lateralizing the carotid sheath, the next step is to elevate the laryngopharyngeal framework off of the spine. Care must be taken to start far laterally on the spine to avoid inadvertent injury to the pharynx or esophagus, which are often off the midline. Palpation of the nasogastric tube and blunt dissection in this area are helpful techniques.
3. Failure to freshen wound edges, invert the mucosa, or recognize compromised pharyngeal tissue, which may lead to delayed nonviable tissue in the suture line and hence delayed leaks
   The quality of the pharyngeal tissue and the closure technique (inverting the mucosal edges) are critical to success. If the exploration is delayed more than 24 hours and/or the tissue has discoloration (dusky quality), the wound edges should be freshened until healthy bleeding is seen, and secondary muscle patches should be utilized.
4. Attempts to force large wounds to closure primarily under tension
   The pharyngeal tissues, even when healthy, are not robust in strength and therefore cannot withstand tension.
5. Ischemic suture line
   Performing a running suture line (particularly locking fashion) with tension can lead to tissue ischemia and delayed leaks. The tissues and closure must be performed meticulously with gentle handling of the mucosa, adequate bites of tissue, and appropriately spaced sutures to avoid tissue ischemia.
6. Failure to adequately drain the space
   Prompt and adequate drainage of the neck and prevertebral space are the most important factors affecting patient prognosis. Failure to recognize mediastinal extension of the process and drainage of the collection can be devastating. Suction drains are preferable to a Penrose drain, as the drainage cavity often extends below the sternum, resulting in a nondependent drain position.

POSTOPERATIVE PERIOD

Postoperative Management

1. Check hematocrit.
2. Closely monitor patient on telemetry.
3. Monitor drain output, and maintain drain until negative esophagogram.
4. Daily chest radiograph to assess free air status
5. Antibiotics for at least 24 hours after surgery
6. Continued NPO status for at least 1 week after repair. Resumption of an oral diet only after a negative esophagogram. Consideration for gastrostomy tube placement in patients with complex defects requiring muscle flap repair, esophagostomy, or associated laryngotracheal repair
7. Strict antireflux precautions (head of bead >30 degrees, proton pump inhibitor), as the presence of a nasogastric tube will promote reflux due to stenting of the lower esophageal sphincter and acid reflux will severely inflame the surgical site raising the risk of tissue damage/necrosis

Complications

1. Persistent salivary leak
   Ensure adequate drainage of the space—CT scan of the chest can be used to confirm appropriate drain placement and identify loculated collections of fluid in the stable patient, if there is an index of suspicion. Robinul or scopolamine can be used to decrease secretions in the stable patient. Maintain adequate nutritional support to promote healing. In a clean wound, with good drainage and nutrition, the majority of salivary leaks should close spontaneously within 2 weeks.
2. Cellulitis/Abscess
   Due to delayed treatment, inadequate drainage, or narrow antibiotic coverage. Early wound washout and broad-spectrum antibiotics are critical.
3. Mediastinitis
   Due to delayed treatment, inadequate drainage, or narrow antibiotic coverage. A high index of suspicion for perforation and early management is critical to a patient's prognosis. Without prompt treatment, this condition is universally fatal.
4. Recurrent laryngeal or superior laryngeal nerve injury, which can affect voice, airway, and swallowing

DISCUSSION

Evidence-Based Medicine Question

Does the level of penetrating trauma to the pharyngoesophageal complex affect the success of conservative management?

A retrospective review of 70 patients revealed that the location of a pharyngoesophageal injury did impact the outcomes of patients, in particularly the successfulness of conservative management.[8] In this series of 70 patients (47 hypopharyngeal, 23 esophageal), no patient with a

penetration injury into the hypopharynx above the level of the arytenoid cartilages developed a complication, regardless of management (observation versus exploration). However, 22% of the patients with a hypopharyngeal injury below this level and 39% of patients with a cervical esophageal injury developed either a deep neck infection that required drainage or a postsurgical salivary fistula. They therefore concluded that injuries located in the upper portion of the hypopharynx can be routinely managed without surgical intervention. Neck exploration and adequate drainage of the deep neck spaces are, however, mandatory for all penetrating injuries into the cervical esophagus and most injuries into the lower portion of the hypopharynx.

Editorial Comment

Dr. Hackman has done an excellent job of reviewing the key points regarding the management of penetrating trauma to the hypopharynx and cervical esophagus caused by iatrogenic or accidental causes. As he has thoroughly described, the management involves not only meticulous surgical technique but also keen diagnostic evaluation for other associated injuries and associated medical and surgical treatments required. Some injuries are quite subtle, and as stated in the chapter, extremely careful observation for complications is required postoperatively. Because these injuries are relatively uncommon and present in numerous different clinical situations, a guide to the diagnostic evaluation and understanding of the indications for different aspects of surgical management are essential components of the operative strategy. It is important to expect the unexpected with these injuries.

Christopher H. Rassekh

Access the review questions online at http://www.expertconsult.com



REFERENCES

1. Rossetti G, Maffettone V, Napolitano V, et al. Esophageal perforation: which factors affect the prognosis? Chir Ital 2006;58:577–581.
2. Eroglu A, Can Kurkcuoglu I, Karaoglanoglu N, et al. Esophageal perforation: the importance of early diagnosis and primary repair. Dis Esophagus 2004;17:91–94.
3. Weigelt JA, Thal ER, Snyder WH, et al. Diagnosis of penetrating cervical esophageal injuries. Am J Surg 1987;54:619–622.
4. Taylor B, Patel AA, Okubadejo GO, et al. Detection of esophageal perforation using intraesophageal dye injection. J Spinal Disord Tech 2006;19:191–193.
5. Navarro R, Javahery R, Eismont F, et al. The role of the sternocleidomastoid flap for esophageal fistula repair in anterior cervical spine surgery. Spine 2005;30:E617–622.
6. Conley J, Gullane PJ. The sternocleidomastoid muscle flap. Head Neck Surg 1980;2:308–311.
7. Reid RR, Dutra J, Conley DB, et al. Improved repair of esophageal fistula complicating anterior spinal fusion: free omental flap compared with pectoralis major flap. J Neurosurg 2004;100:66–70.
8. Stanley Jr RB, Armstrong WB, Fetterman BL, et al. Management of external penetrating injuries into the hypopharyngeal-cervical esophageal funnel. J Trauma 1997;42(4):675–679.

REVIEW QUESTIONS

1. All of the following are essential in the management of a pharyngoesophageal perforation, except:
   a. Broad-spectrum antibiotics
   b. NPO status
   c. Steroid therapy
   d. Enteral access

2. Which of the following is an absolute indication to perform surgical management?
   a. Pharyngeal leak on esophagogram
   b. Subcutaneous emphysema
   c. Perforation during removal of an esophageal foreign body
   d. Mediastinal opacification on chest radiograph

3. What is the most common cause of penetrating trauma to the pharyngoesophagus?
   a. Gunshot wound
   b. Stabbing injury
   c. Motor vehicle trauma
   d. Spinal surgery

48 Partial Pharyngectomy

Rebecca E. Fraioli, Andrew Tassler

INTRODUCTION

The hypopharynx is the inferior-most portion of the pharynx, bounded by the oropharynx superiorly and the esophagus inferiorly. The hypopharynx is intimately related to the larynx, both anatomically and functionally. Anatomically, the hypopharynx extends from the base of the vallecula down to the apices of the piriform sinuses and the inferior border of the cricoid cartilage. For purposes of classification, the hypopharynx is divided into three subsites: the piriform sinuses, the posterior pharyngeal wall, and the postcricoid area. The mucosa of the hypopharynx is continuous with that of the larynx, and cancers that originate in one site frequently spread to the others. Functionally, the hypopharynx and larynx are responsible for coordinating the competing tasks of airway maintenance and deglutition.

Squamous cell carcinoma (SCCA) is the most common malignancy presenting in the hypopharynx and usually presents at an advanced stage. Alcohol and tobacco are strong risk factors, as with other cancers of the head and neck.

Due to the rich lymphatics of the pharynx, cervical metastases are common with hypopharyngeal primaries, and over two-thirds of patients present with stage III or IV cancer. Perhaps because of this, prognosis is often poor despite aggressive treatment—hypopharyngeal SCCA has the worst prognosis of SCCA at any subsite within the head and neck. The piriform sinus is the most common site for hypopharyngeal cancer.

Traditional treatment for hypopharyngeal SCCA included surgery, usually total laryngectomy with total or partial pharyngectomy, and was followed by postoperative external beam radiation therapy (XRT). However, following landmark studies using chemoradiation with surgical salvage for laryngeal[1] and hypopharyngeal[2] cancers, which showed equivalent survival in the surgical and nonsurgical arms, the use of primary surgical treatment of hypopharyngeal cancer has decreased.[3]

Both surgical and nonsurgical treatments for hypopharyngeal cancers carry significant functional morbidity. Gastrostomy tubes are often required during and after treatment, and swallowing and sometimes airway function following chemoradiotherapy may be permanently compromised, despite a surgically undisturbed larynx (Fig. 48.1).

Given the low cure rates and high rates of functional sequelae, alternatives to laryngectomy and nonsurgical organ preservation continue to be of interest and evolve. Such operations as transoral laser microsurgery (TLM),[4] transoral robotic surgery (TORS),[5] and extended partial laryngopharyngectomy procedures such as SCHLP (supracricoid hemilaryngopharyngectomy)[6] provide palliation and cure rates that rival other treatments and are being revisited for selected lesions.

KEY OPERATIVE LEARNING POINTS

Small cancers of the posterior wall of the pharynx may be resected transorally or through a suprahyoid pharyngotomy.

At least 2.5 to 3 cm of pharyngeal mucosa must remain in the transverse dimension after resection in order to close the pharyngeal mucosa primarily.

Cancer extension across the midline of the posterior hypopharyngeal wall or involving the postcricoid mucosa requires total laryngopharyngectomy with reconstruction.

Cancers extending to the esophagus cannot be excised and the wound closed primarily.

Failure to aggressively preserve uninvolved mucosa may preclude primary closure.

Wound closure under tension due to insufficient mucosa will predispose to wound breakdown, fistula formation, and postoperative dysphagia due to stricture formation.

Submucosal spread is common in hypopharyngeal cancers, and negative margins must be confirmed by frozen section.

Patients must understand that although every attempt may be made to perform partial laryngopharyngectomy, intraoperative findings or frozen section pathology may make this impossible. Therefore, patients should be consented for a possible total laryngopharyngectomy.

Patients with prior radiation or chemoradiation should have pharyngeal closure performed with a vascularized flap either integrated into the remaining pharyngeal mucosa or tubed in the case of total pharyngectomy defect. A pectoralis major flap can be used for closure of the anterior pharynx over remaining mucosa, but a complete pharyngeal defect with discontinuity is best reconstructed with free tissue transfer.

PREOPERATIVE PERIOD

History

History of Present Illness

Symptoms often occur late in the course of cancer of the hypopharynx.

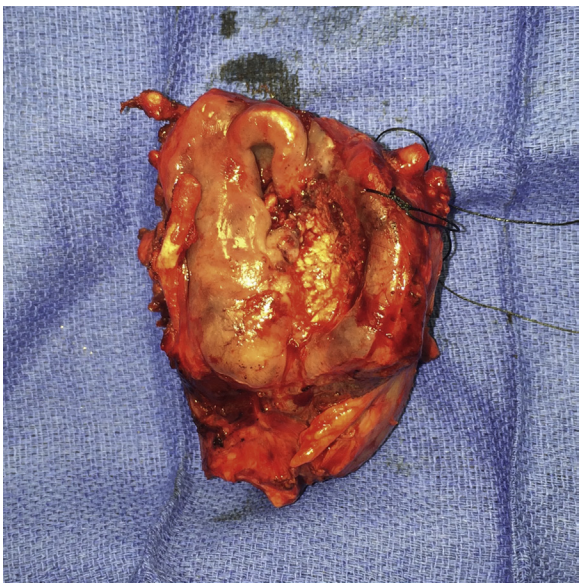

Fig. 48.1. A laryngopharyngectomy specimen removed for persistent disease following primary chemoradiation treatment. The epiglottis is misshapen and thickened from the chemoradiation. This photograph demonstrates why organ preservation therapy with chemoradiation does not always lead to preservation of a functional larynx.

Symptoms vary significantly, depending on the location of the cancer.
Sore throat, blood in the saliva, weight loss, dysphagia, and odynophagia may all be symptoms of cancer of the hypopharynx. Referred otalgia is another frequent symptom. Malnutrition may be a major problem when patients present with an advanced stage cancer.
Dysphagia is often a late symptom but can occur earlier in postcricoid carcinomas.
Sore throat and odynophagia may indicate perineural spread and advanced disease.
Globus and foreign body sensation in the throat can be indicators of a hypopharyngeal mass.
Hoarseness, difficulty breathing, and stridor generally indicate advanced cancer with hemilaryngeal fixation.

Past Medical History

Medical Illness

Pharyngectomy is an extensive operation with an often difficult postoperative course. Patients must be medically stable to survive the surgery and postoperative period.
Insulin-dependent diabetics are at increased risk for wound breakdown and fistula formation.
Patients must have adequate pulmonary reserve to be considered for a partial pharyngectomy or a partial laryngectomy.
Iron deficiency anemia, along with hypopharyngeal webs (Plummer-Vinson syndrome), may be associated with cancer of the hypopharynx, although the incidence of this syndrome appears to be decreasing with lower rates of iron deficiency anemia.
Gastroesophageal reflux is associated with esophageal cancer and may also be a major problem in cancer of the hypopharynx.

Surgical History

Prior thyroid or neck surgery may present surgical challenges and increase the risk of injury to the parathyroid glands.
A history of lung surgery or other pulmonary compromise may increase the consequences of aspiration and preclude partial laryngectomy.

Family History

Family history of cancer
History of adverse anesthesia reactions in family members

Social History

Tobacco and alcohol use are strong risk factors for the development of hypopharyngeal cancer.
Smoking also significantly impairs wound healing and is a risk factor for developing a fistula postoperatively.
Honest reporting of alcohol consumption is critical to provide adequate prophylaxis for postoperative withdrawal if alcohol dependence is present.

Medications

Anticoagulants and antiplatelet drugs should be discontinued if medically feasible.
Immunosuppressant medications may make the cancer more virulent.

Physical Examination

- A thorough examination of the oral cavity and oropharynx, including palpation of the tonsils and base of tongue, should be performed.
- Second primary cancers are not uncommon, even in patients with early-stage cancer.
- Trismus indicates involvement of the muscles of mastication.
- Fiberoptic examination of the pharynx and larynx is indicated to evaluate the extent of the cancer, assess for second primaries, and evaluate the mobility of the vocal folds.
- The Chevalier Jackson sign of saliva pooling in the piriform sinuses is also suggestive of hypopharyngeal carcinoma with distal obstruction.
- If partial laryngectomy is considered, pulmonary function must be evaluated, as patients undergoing these procedures must have excellent pulmonary reserve.
- Basic laboratory tests in the form of complete blood count (CBC) and metabolic profile are indicated. Liver function tests with measurement of serum albumin may also be useful to assess basic nutritional status.
- If open surgery is considered or the patient has a history of prior neck radiation or chemoradiation, thyroid function tests (thyroid stimulating hormone [TSH] and free T4) should be obtained.
- Examination under anesthesia with direct laryngoscopy, rigid esophagoscopy, and bronchoscopy must be performed prior to cancer resection.
- A biopsy should be obtained during the examination under anesthesia to provide a tissue diagnosis. Other benefits of endoscopy include evaluation of the size and extent of the cancer, palpation of the arytenoids to assess for fixation of the vocal folds, and identification of second primary cancers.

Imaging

- Barium swallow esophagram
  - Provides preoperative assessment of swallowing function, laryngeal penetration, and aspiration
  - May reveal extension of the cancer into the cervical esophagus
  - May demonstrate fixation of the cancer to the prevertebral fascia
- Computed tomography (CT) and/or magnetic resonance imaging (MRI)
  - Preoperative imaging is critical to assess the extent of the cancer and help plan the appropriate resection.
  - CT and MRI are both useful to assess the extent of the primary cancer.
  - MRI provides better assessment of the degree of invasion of the prevertebral musculature and may be preferable for cancers of the posterior pharyngeal wall.
  - CT is superior for assessment of invasion of the thyroid or cricoid cartilages.
  - Either CT or MRI should be performed with contrast whenever possible, as this better demonstrates the vasculature and areas of enhancement.
  - Given the high rate of cervical metastases at presentation, whichever imaging modality is chosen should include the neck. Cancer of the pharynx may involve the retropharyngeal nodes, which are usually not clinically apparent.
- Positron emission tomography (PET) CT
  - Indicated to identify synchronous second primaries as well as cervical lymph nodes and distant metastases
  - If PET/CT is not performed, a minimum of a chest CT should be performed.

Indications

- In properly selected patients, partial pharyngectomy with postoperative radiotherapy may be preferable to more extensive surgery or definitive chemoradiation therapy.
- A general stepwise paradigm for surgical excision of cancers of the hypopharynx is outlined in Table 48.1.

TABLE 48.1 Algorithm for Management of Hypopharyngeal Tumors

Extent of Surgery	Surgical Approaches	Indications	Reconstructive Options
Simple excision	• Transoral CO_2 laser excision or transoral robotic surgery	• Small tumors of posterior pharyngeal wall • Small tumors of medial or lateral wall of piriform sinus	• None; wounds heal by secondary intent
Partial pharyngectomy	• Lateral pharyngotomy • Suprahyoid pharyngectomy	• Small tumors of posterior pharyngeal wall • Carefully selected larger tumors of posterior pharyngeal wall	• Suture mucosal edges to prevertebral fascia • Skin graft
Partial pharyngectomy with partial laryngectomy	• Supraglottic hemilaryngopharyngectomy • Vertical hemilaryngopharyngectomy	Cancer limited to: • AE fold • Medial wall of piriform sinus • Anterior wall of piriform sinus	• Primary closure of pharyngeal mucosa bolstered by remaining thyroid cartilage perichondrium and infrahyoid musculature flap • Free flap reconstruction
Partial pharyngectomy with total laryngectomy	• Transcervical	Tumor involving piriform sinus with involvement of: • Larynx • Apex of piriform sinus • Lateral wall of hypopharynx	• Primary closure if ≥3 cm of pharyngeal mucosa remains
Total pharyngolaryngectomy	• Transcervical	• Postcricoid carcinoma • Large or pharyngeal wall • Piriform sinus carcinoma with extension across midline	• Total Pharyngolaryngectomy will always require either flap reconstruction, gastric pull-up, etc. Primary closure will never be possible in this scenario.

- Partial pharyngectomy—no laryngectomy:
  - Small T1/T2 cancers of the posterior pharyngeal wall without extension to the cervical esophagus may be treated by excision using a transcervical (lateral or suprahyoid) pharyngotomy or transoral resection (Fig. 48.2).
  - Larger cancers of the posterior wall of the hypopharynx can sometimes be completely excised via suprahyoid pharyngectomy and/or lateral pharyngotomy approaches and reconstructed with a free flap. However, excision of large amounts of posterior pharyngeal wall sensate mucosa will have negative effects on swallowing function, and this should be taken into account when planning surgery.
- Partial pharyngectomy with partial laryngectomy
  - Patients undergoing these procedures must have adequate pulmonary function to tolerate partial laryngectomy.
  - Vertical hemipharyngolaryngectomy
    - Mainly indicated for cancers of the medial piriform sinus without extension to the piriform apex
    - Involvement of the ipsilateral arytenoid is acceptable.
    - The excision can be extended to allow resection of cancer extending to the supraglottis and a portion of the lateral wall of the piriform sinus.
    - The most extreme extension of this procedure is a full supraglottic hemipharyngolaryngectomy, with resection of the epiglottis, vallecula/pre-epiglottic space, and a portion of the base of the tongue.
  - SCHLP
    - Extends the previous procedure by also excising the ipsilateral piriform sinus and supracricoid larynx
    - Patients are likely to have aspiration postoperatively, and only patients with excellent pulmonary reserve are candidates for this procedure.
    - The indications for this procedure were traditionally for early pyriform and arytenoid cancers, but it has been used in experienced hands for more advanced cancers.
- Partial pharyngectomy with total laryngectomy
  - The most common indication is piriform sinus carcinoma that extends medially to the larynx, inferiorly to the apex of the piriform sinus, or laterally to the lateral wall of the hypopharynx.
  - Partial pharyngectomy is indicated if 2.5 to 3 cm in horizontal dimension of posterior pharyngeal wall mucosa remains following excision of the cancer. In such cases, primary closure of the pharyngeal mucosa can result in a functional swallowing mechanism postoperatively.

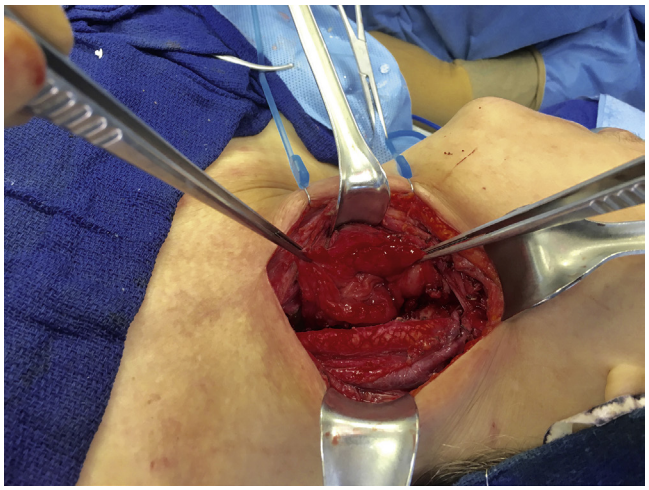

Fig. 48.2. Surgical photograph demonstrates the lateral transcervical approach to the hypopharynx.

- Total laryngopharyngectomy
  - In addition to the indications for total laryngectomy listed previously, common indications for total laryngopharyngectomy include piriform sinus carcinoma that extends across the midline and postcricoid cancer. The hypopharynx is shaped like a funnel, and while there may be sufficient pharyngeal mucosa in the superior hypopharynx to close a defect, the total area of pharyngeal mucosa in the postcricoid area is so limited that direct closure is not possible following cancer resection.
  - Total pharyngectomy is necessary when less than 2.5 cm of posterior pharyngeal wall mucosa remains horizontally following cancer resection; therefore, large cancers of the posterior hypopharyngeal wall are a common indication for this procedure.
- Neck dissection of at least levels II to IV should be performed in all patients. Metastatic cancer is found in 60% to 80% of patients with cancer of the hypopharynx, and 20% to 40% will have occult neck metastases to the cervical lymph node. Bilateral selective neck dissection (or radiation to the contralateral neck) is indicated for cancers of the medial wall of the piriform sinus, which tend to behave more like supraglottic carcinomas.[7]

Contraindications

- Contraindications to partial pharyngectomy without laryngectomy
  - Cancer involving the larynx
  - Location of the cancer in the piriform sinus or postcricoid area
  - Extension of posterior wall cancer to the lateral pharyngeal wall
  - Large cancer of the posterior pharyngeal wall, although acceptable in certain carefully selected patients, is generally contraindicated, as the loss of large amounts of sensate mucosa severely impairs swallowing function and places the patient at risk for aspiration.
- Contraindications to partial pharyngectomy with partial laryngectomy
  - Extension of the cancer to the apex or lateral wall of the piriform sinus
  - Large cancers of the posterior pharyngeal wall
  - Cardiopulmonary comorbidities with inability to tolerate postoperative aspiration require total laryngectomy.
- Contraindications to partial pharyngectomy with total laryngectomy
  - Insufficient pharyngeal mucosa to allow for a functional primary closure (Fig. 48.3)
  - Resection of the cancer at the following sites generally requires total pharyngectomy, due to insufficient mucosa remaining for primary closure:
    - Postcricoid carcinoma
    - Piriform sinus carcinoma with extension across the midline
    - Large cancer of the posterior pharyngeal wall
- Contraindications to total laryngopharyngectomy
  - Cancer spread to involve prevertebral fascia
  - Cancer involvement of carotid sheath
  - Involvement of the cervical esophagus by cancer will require esophagectomy in addition to total laryngopharyngectomy. Reconstruction is usually with gastric pull-up to minimize the risk of suture lines in the mediastinum with potential leak.



Fig. 48.3. Large carcinoma of the right pirifrom sinus. There was not sufficient uninvolved mucosa to allow for primary closure of the hypopharyngeal mucosa; therefore, primary closure was not possible and free tissue transfer was performed for pharyngeal reconstruction.

Preoperative Preparation

- Patients should be evaluated for their overall health and fitness for general anesthesia. Advanced age is not a contraindication in an otherwise healthy patient.
- If the patient is not undergoing a total laryngectomy, careful consideration of his or her pulmonary function and ability to tolerate aspiration is of critical importance.
- Preoperative evaluation by a speech language pathologist to evaluate preoperative swallowing function as well as motivation and ability to rehabilitate swallowing postoperatively is of significant value.
- If the cancer causes airway obstruction, preoperative discussion and planning for airway management with the anesthesiology team are mandatory.
- If free tissue transfer is to be considered, preoperative consultation by a microvascular surgeon should be obtained. Vascular imaging to assess the quality of vessels can be performed as indicated.
- Repeat endoscopy to ensure that the cancer has not grown or changed is important and is often done just prior to surgery.

OPERATIVE PERIOD

Anesthesia

- General anesthesia is required.
- Oral intubation is preferred unless significant airway obstruction is present, in which case initial tracheotomy may be the safest means of obtaining an airway. Some patients will have a pre-existing tracheostomy, and the tracheostomy tube can be removed and the patient intubated through the stoma.
- Continued communication with the anesthesiologist throughout the case is important for cranial nerve monitoring and regarding the use of vasopressors if microsurgical free flaps are planned.

Positioning

- The patient should be supine.
- Placement of a shoulder roll to extend the neck may help with exposure.
- Care should be taken to position the arms with adequate padding and protection.
- Sequential compression devices (SCD) should be placed on the lower extremities if possible. If a lower extremity is being used for reconstruction, a single SCD should be placed on the unprepped leg.
- The entire neck and lower face should be prepped, as access to the oral cavity may be helpful during an external approach to the laryngopharynx.
- The upper chest should be prepped into the field if there is a possibility that a regional flap such as a pectoralis major flap might be used.
- A thigh can be prepped for possible skin grafting.
- If a free flap reconstruction is possible, then the donor site should be prepped as well.

Perioperative Antibiotic Prophylaxis

- Partial pharyngectomy is a clean-contaminated procedure, and as such 24 hours of intravenous antibiotics covering oral flora is indicated.
- We prefer to use ampicillin/sulbactam. If the patient is allergic to penicillin, a combination of cefazolin and metronidazole can be used, as can clindamycin. If the patient has a pre-existing tracheostomy, it is often helpful to broaden the antibiotic coverage to include pseudomonas with an agent such as piperacillin/tazobactam.

- The first dose should be given prior to induction of anesthesia induction and redosed at the proper interval during the procedure.

Monitoring

- We prefer to limit the amount of paralytic agent given to facilitate monitoring of cranial nerves during the preliminary neck dissection.
- Nerves can be stimulated with either handheld nerve stimulators or electromyogram (EMG) based nerve monitoring and stimulation.

Instruments and Equipment to Have Available

- Head and neck surgical instrument set
- Head and neck endoscopy set
- Microvascular instruments and equipment if free flap reconstruction is planned

Key Anatomic Landmarks

- The hypoglossal nerve and lingual artery lie just adjacent to the greater cornu of the hyoid bone. Care must be taken when dissecting in this area to stay on the bone and avoid injury to these structures.
- The superior laryngeal nerve provides sensation that is important for the coordination of swallowing, and as such, effort should be made to preserve this nerve. However, if an extensive amount of sensate pharyngeal mucosa is resected, swallowing function will be severely compromised, even if the nerve is preserved.
- The recurrent laryngeal nerve is not routinely identified in partial pharyngectomy procedures, but postcricoid cancers may invade the nerve by direct extension into the tracheoesophageal groove.
- There is an area of weakness in the posterior pharyngeal wall in between the inferior constrictor muscle superiorly and the cricopharyngeus muscle inferiorly. This area is known as Killian's triangle, and this is a site where cancers of the posterior wall can spread to structures outside of the hypopharynx.

Prerequisite Skills

- Prior to attempting conservation laryngeal procedures, the surgeon should be adept at total laryngectomy.
- Free tissue transfer may be necessary for reconstruction. If the surgeon does not routinely perform free tissue transfer, a microvascular surgeon should be available.

Operative Risks

- Bleeding or hematoma
- Infection
- Permanent tracheostomy for airway compromise
- Swallowing dysfunction with the potential need for prolonged parenteral nutrition
- Potential for poor voice quality following partial laryngectomy
- Injury to the hypoglossal nerve
- Wound infection
- Pharyngocutaneous fistula

Surgical Technique

- Partial pharyngectomy—no laryngectomy
  - May be performed transorally, with endoscopy or robot, or transcervically via suprahyoid or transhyoid approaches
    - Transoral approaches
      - Typically performed for early (T1 or T2) cancers with limited or no laryngeal involvement. If significant laryngeal resection including the arytenoid is necessary, the functional outcome may be inferior to nonoperative treatment.
      - Perioperative tracheostomy should be strongly considered.
      - Preoperative endoscopy to assess the extent of the lesion and the endoscopic exposure is mandatory. This is particularly true in the salvage setting following prior radiation or chemoradiation.
      - Cancers with significant deep or lateral extension that will create communication with the lateral neck or retropharyngeal space are more appropriate for an open approach.
      - Endoscopic resection is commonly performed with either TLM technique, using either mounted or fiber-based CO_2 laser, or with TORS technique, which can use either monopolar cautery or fiber-based CO_2 laser.
    - Transcervical approaches
      - Transcervical pharyngotomy
        - Superiorly based apron flap incision
        - Tracheostomy
        - Subplatysmal flaps are elevated superiorly above the hyoid bone.
        - Neck dissection as indicated
        - Expose the posterior thyroid ala and divide the inferior constrictor attachments.
        - View the piriform sinus mucosa, and excise the cancer of the posterior or lateral wall under direct vision.
        - Frozen section margins are obtained.
        - Direct closure, skin graft, or flap reconstruction is performed.
      - Lateral transthyroid pharyngotomy
        - Steps through neck dissection given previously
        - Expose hyoid bone and thyroid cartilage
        - Thyroid perichondrium is incised superiorly and reflected inferiorly as an inferiorly based flap
        - Incisions are made through the lesser cornu of the hyoid bone and vertically through the posterior-lateral third of the thyroid cartilage.
        - The pharynx is entered through the vallecula, and incisions are made around the cancer under direct vision.
        - Frozen section margins are obtained.
        - Reconstruction with direct mucosal closure is reinforced by the perichondrial flap or by flap closure.
      - Transhyoid pharyngotomy
        - Steps through neck dissection given previously
        - Expose the hyoid bone.
        - Enter the vallecula above, though, or below the hyoid bone.
        - Retraction of the base of the tongue provides visualization of the posterior pharyngeal wall.
        - Cancers of the posterior wall can be excised under direct visualization; deep margin is the prevertebral fascia.
        - Frozen section margins are obtained.
        - Defect can be covered with a split-thickness skin graft or left to heal
        - Vallecular opening is closed primarily
        - Perichondrial flap provides a second layer of closure
- Partial pharyngectomy with partial laryngectomy
  - Horizontal partial pharyngolaryngectomy
    - Superiorly based apron flap incision
    - Tracheostomy

  - Subplatysmal flaps are raised.
  - Bilateral neck dissections
  - The hyoid bone is skeletonized superiorly, and the infrahyoid strap muscles are released from the hyoid bone.
  - The perichondrium is elevated off of the thyroid cartilage and left attached as an inferiorly based pedicle flap.
  - The thyroid cartilage is incised horizontally, halfway between the thyroid notch and the inferior border. The greater cornu is excised on the side of the cancer.
  - The vallecula is entered on the side ipsilateral to the cancer.
  - Grasp and retract the epiglottis, visualize the cancer, and excise the epiglottis and ipsilateral aryepiglottic fold, including the false vocal fold but not the true vocal fold.
  - The ipsilateral arytenoid can be included in the specimen if involved by cancer.
  - Excision can be extended to remove the mucosa of the medial, the anterior, and a portion of the lateral piriform sinus walls.
  - Frozen section margins are obtained.
  - If the arytenoid has been resected, the true vocal fold must be sutured back into the midline to the cricoid.
  - A cricopharyngeal myotomy should be considered.
  - Depending on the size of the resection, closure may be performed primarily or with regional flap or free tissue transfer.
- Vertical partial laryngopharyngectomy
  - Steps through neck dissection as noted previously
  - Expose the larynx from the hyoid bone down to the trachea.
  - Incise the thyroid perichondrium vertically from the thyroid notch down over the cricothyroid membrane to the cricoid cartilage.
  - Perichondrial flaps should be elevated laterally on both sides of the vertical incision. Often the strap muscles will still be attached, creating composite flaps.
  - Use a saw to cut through the thyroid cartilage, maintaining a 3-mm posterior strip.
  - Incise through the petiole of the epiglottis, thereby exposing the vocal cords.
  - Incise the cricothyroid membrane just superior to the cricoid cartilage to ensure that this area is free of tumors.
  - Cut through the vocal cord at the anterior commissure or 3 mm past the tumor if it crosses the midline.
  - Use hooks to open the larynx like a book.
  - Excise the remaining cancer under direct vision, and confirm the margins with the frozen section.
  - Cancers of the medial wall of the piriform sinus can be included in this resection.
  - Reconstruct the contralateral vocal cord by suturing it to the remaining cartilage or perichondrium.
  - If 3 cm or more of mucosa remains in the transverse direction, primary closure may be performed over a nasogastric tube. The remaining pharyngeal mucosa is sutured to the vallecula and remaining portion of the larynx.
  - Closure is reinforced by suturing the previously reflected thyroid cartilage mucoperichondrium and strap musculature.
- Partial pharyngectomy with total laryngectomy
  - Steps through neck dissection as noted previously
  - Incise the constrictor muscles along the posterior lamella of the thyroid cartilage on the side contralateral to the cancer.
  - Enter the larynx in the vallecula contralateral to the cancer, and dissect the piriform sinus mucosa free from the larynx on the side opposite the cancer.
  - Mucosal incisions should be made with the tumor under direct vision in order to maintain an adequate (1.5 to 2 cm) mucosal margin around the tumor while preserving as much mucosa as possible.
  - Dissect from the lateral edge of the epiglottis to the arytenoid.
  - Frozen section assessment of surgical margins must be obtained.
  - If 3 cm or more of mucosa remains in the transverse direction, primary closure may be performed.
- Total laryngopharyngectomy (see Chapter 17 for details)

Common Errors in Technique

- Attempts to perform primary closure of the pharyngeal defect when less than 2.5 cm of mucosa remains
- Failure to adequately visualize the cancer while making mucosal incisions may result in a total laryngectomy due to failure to preserve adequate mucosa.

POSTOPERATIVE PERIOD

Postoperative Management

- The pharyngeal reconstruction is performed over a nasogastric tube, which is used to provide enteral nutrition until oral feeding can sustain the patient's nutritional requirements.
- Oral feeding is generally initiated 10 days postoperatively.
- Speech pathology evaluation and possibly a formal swallowing study should be performed before initiating oral feeding in patients whose risk of aspiration is high.
- For patients undergoing partial laryngectomy, early and aggressive pulmonary toilet must be maintained due to the high likelihood of aspiration. In these patients, the tracheostomy tube can often be capped a week after the surgery, and early initiation of phonation is encouraged. The tracheostomy tube is not removed until oral feeding is established.
- Flexible nasolaryngoscopy may be performed to assess healing of the reconstructed laryngopharynx.

Complications

- Attempts at primary closure of the pharyngeal defect when insufficient mucosa remains following tumor excision place the suture line under excessive tension and predispose to wound fistula (pharyngocutaneous fistula).
- Closure of the pharyngeal defect with insufficient mucosa also predisposes to esophageal stricture, and esophageal dilation procedures and even placement of a surgical feeding tube may be necessary. Postoperative radiation therapy may also contribute to esophageal stricture and dysphagia.
- Postoperative aspiration is essentially guaranteed in patients undergoing partial laryngectomy, but it may also occur in patients where the entire larynx is preserved due to disruption of the swallowing mechanism and loss of sensate mucosa following pharyngectomy. Aspiration may lead to postoperative pneumonia and may be severe enough to necessitate permanent tracheostomy or secondary laryngectomy or laryngotracheal separation.
- Fever or back pain in the early postoperative period can be an indicator of retropharyngeal abscess.

Alternative Management Plan

Treatment with primary chemotherapy and radiation is a reasonable option for hypopharyngeal SCCA. Survival rates are comparable to surgery.

DISCUSSION

Evidence-Based Medicine Question

Has the trend toward chemoradiation therapy for organ preservation in hypopharyngeal cancer changed survival?

The landmark European Organization for Research and Treatment of Cancer (EORTC) study using chemoradiation for larynx preservation in hypopharyngeal cancer[2] began a paradigm shift in the treatment of hypopharyngeal cancer, with many patients who would formerly have been treated with primary surgery being treated with definitive chemoradiation therapy instead. Recent studies have suggested that in the case of laryngeal cancer, the shift to nonsurgical therapies may have reduced survival.[8] By contrast, in the case of hypopharyngeal cancer, a 2015 study of the SEER database by Newman and colleagues[8] showed an improvement in overall survival in the time period between 1990 and 2003, a time frame that corresponds to the shift in the treatment paradigm toward chemoradiation as definitive therapy.

There are several factors that may contribute to this increase in survival. First, the increase in overall survival in the study was mostly attributable to the increased survival in patients receiving radiation and no surgery. Therefore the study does not address the question of when primary surgery is indicated over primary chemoradiation therapy. Additionally, chemotherapy data were not available in this study, so the study does not directly address whether the addition of chemotherapy to treatment regimens could be responsible for the increased survival. However, temporal therapy trends suggest this as a possible explanation. It is also notable that studies in laryngeal and oropharyngeal carcinoma have demonstrated a survival benefit of chemoradiation therapy when compared with radiotherapy alone.[9]

Newman and colleagues also note that other changes have occurred during the studied time frame, including the adaptation of intensity modulated radiation therapy (IMRT), which in a study by Mok and colleagues[10] was shown to improve locoregional control in hypopharyngeal carcinoma when compared with conventional radiotherapy.

Another possible factor is the development of cetuximab, a monoclonal antibody to the epidermal growth factor receptor (EGFR), which was approved by the FDA in 2006 for use in advanced SCCAs of the head and neck. As a whole, cetuximab has fewer side effects and is better tolerated than platinum-based chemotherapies, and its availability may have increased the number of patients who are able to receive systemic therapy.[9]

There are many questions still to be answered regarding the treatment of hypopharyngeal carcinoma, especially regarding the relative roles of surgery and chemoradiation therapy, but data suggest that chemotherapy may play an important role.

Editorial Comment

This chapter by Dr. Fraoli and Dr. Tassler demonstrates the complexity of evaluating and managing cancer of the hypopharynx. The wide range of presenting symptoms and physical signs varies from minimal to profound. Many patients present only with neck metastasis or when the cancer is very advanced. The topic is covered very comprehensively but with an attempt to limit any redundancy with other related chapters on management of different aspects of cancer of the pharynx. However, as the authors have detailed, there is considerable overlap in the management of cancer of the hypopharynx, because cancers that arise in the hypopharynx commonly impact the larynx and oropharynx. Similarly, cancers of the oropharynx and larynx often are complicated when there is extension to the hypopharynx. Many of the surgical approaches for cancer of the hypopharynx are relevant in oropharyngeal and laryngeal cancer as well.

Partial pharyngectomy (sometimes referred to as "limited pharyngectomy") applies to both hypopharyngeal and oropharyngeal lesions. The management of cancer of the oropharynx is covered in detail elsewhere, but the armamentarium of surgical approaches includes transoral, transpharyngeal, and even combined laryngectomy/hypopharyngectomy operations. Technical nuances in these procedures are critically important when providing optimal oncologic and functional outcomes.

In order to be comprehensive, a surgeon must be familiar with all of these approaches. The authors have taken a very difficult and important topic and condensed it into a valuable reference, which is an excellent starting point. Readers are encouraged to look at the references to other chapters and refer back and forth to the chapters that overlap with this one to maximize the educational value and help master the critical elements in patient care.

Christopher H. Rassekh

Access the review questions and additional sources list online at http://www.expertconsult.com

REFERENCES

1. The Department of Veterans Affairs Laryngeal Cancer Study Group. Induction chemotherapy plus radiation compared with surgery plus radiation in patients with advanced laryngeal cancer. N Engl J Med 1991;324:1685–1690.
2. Lefebvre JL, Chevalier D, Luboinski B, et al. Larynx preservation in pyriform sinus cancer: preliminary results of a European Organization for Research and Treatment of Cancer phase III trial. EORTC Head and Neck Cancer Cooperative Group. J Natl Cancer Inst 1996;88:890–899.
3. Kuo P, Chen MM, Decker RH, et al. Hypopharyngeal cancer incidence, treatment, and survival: temporal trends in the United States. Laryngoscope 2014;124:2064–2069.
4. Martin A, Jäckel MC, Christiansen H, et al. Organ preserving transoral laser microsurgery for cancer of the hypopharynx. Laryngoscope 2008;118(3):398–402.
5. Park YM, Kim WS, De Virgilio A, et al. Transoral robotic surgery for hypopharyngeal squamous cell carcinoma: 3-year oncologic and functional analysis. Oral Oncol 2012;48(6):560–566.
6. Kania R, Hans S, Garcia D, et al. Supracricoid hemilaryngopharyngectomy in patients with invasive squamous cell carcinoma of the pyriform sinus. Part II: incidence and consequences of local recurrence. Ann Otol Rhinol Laryngol 2005;114(2):95–104.
7. Johnson JT, Bacon GW, Myers EN, et al. Medial vs. lateral wall pyriform sinus carcinoma: implications for management of regional lymphatics. Head Neck 1994;16:401–405.
8. Newman JR, Connolly TM, Illing EA, et al. Survival trends in hypopharyngeal cancer: a population-based review. Laryngoscope 2015;125:624–629.
9. Baxi SS, O'Neill C, Sherman EJ, et al. Trends in chemoradiation use in elderly patients with head and neck cancer: changing treatment patterns with cetuximab. Head Neck 2016;38:E165–E171.
10. Mok G, Gauthier I, Jiang H, et al. Outcomes of intensity-modulated radiotherapy versus conventional radiotherapy for hypopharyngeal cancer. Head Neck 2015;37:655–661.

REVIEW QUESTIONS

1. Regarding imaging for hypopharyngeal tumors, which of the following statements is *true?*
   a. Magnetic resonance imaging (MRI) is superior to computed tomography (CT) for assessment of the primary extent of the tumor.
   b. CT is superior to MRI for assessment of the primary extent of the tumor.
   c. MRI is superior to CT for assessment of prevertebral muscle invasion.
   d. CT is superior to MRI for assessment of prevertebral muscle invasion.

2. Which of the following is a contraindication to partial pharyngectomy?
   a. 1 cm cancer involving the medial wall of the piriform sinus
   b. 1 cm cancer involving the postcricoid area
   c. 1 cm cancer of the posterior pharyngeal wall
   d. 1 cm cancer of piriform sinus extending to ipsilateral arytenoid

3. Which of the following is a contraindication to partial laryngectomy in combination with partial or total pharyngectomy?
   a. Patient with severe chronic obstructive pulmonary disease (COPD)
   b. Patient with Plummer-Vinson syndrome
   c. Laryngeal involvement by cancer
   d. Cancer located on medial wall of piriform sinus

4. How much pharyngeal mucosa must remain following tumor resection in order to perform direct pharyngeal closure?
   a. 1 cm in horizontal dimension
   b. 1.5 cm in horizontal dimension
   c. 2.0 cm in horizontal dimension
   d. 2.5 cm in horizontal dimension

5. Which of the following is *not* a reasonable treatment option for cancer of the hypopharynx?
   a. Cisplatin and intensity modulated radiation therapy (IMRT)
   b. Cetuximab and IMRT
   c. Cisplatin and cetuximab
   d. Surgery and IMRT

ADDITIONAL SOURCES

Bradley PJ. Cancer of the hypopharynx. Oper Tech Otolaryngol 2005; 16:55–66.

Chevalier D, Watelet JB, Darras JA, et al. Supraglottic hemilaryngectopharyngectomy plus radiation for the treatment of early lateral margin and pyriform sinus carcinoma. Head Neck 1997;19:1–195.

Denis F, Garaud P, Bardet E, et al. Final results of the 94-01 French Head and Neck Oncology and Radiotherapy Group randomized trial comparing radiotherapy alone with concomitant radiochemotherapy in advanced-stage oropharynx carcinoma. J Clin Oncol 2004;22(1):69–76.

Edson MA, Garden AS, Takiar V, et al. Outcomes for hypopharyngeal carcinoma treated with organ-preservation therapy. Head Neck 2016;38:E2091–E2099.

Forastiere AA, Goepfert H, Maor M, et al. Concurrent chemotherapy and radiotherapy for organ preservation in advanced laryngeal cancer. N Engl J Med 2003;349:2091–2098.

Forastiere AA, Goepfert H, Maor M, et al. Concurrent chemotherapy and radiotherapy for organ preservation in advanced laryngeal cancer. J Clin Oncol 2013;31:845–852.

Herranz J, Martinez-Vidal J. The prevertebral fascia: an alternative approach for reconstruction of the posterior wall of the hypopharynx. Oper Tech Otolaryngol Head Neck Surg 1993;4(4):309–311.

Joo YH, Cho KJ, Park JO, et al. Role of larynx-preserving partial hypopharyngectomy with and without postoperative radiotherapy for squamous cell carcinoma of the hypopharynx. Oral Oncology 2012;48:168–172.

Julieron M, Kolb F, Schwaab G, et al. Surgical management of posterior pharyngeal wall carcinomas: functional and oncologic results. Head Neck 2001;23:80–86.

Kim MS, Joo YH, Cho KJ, et al. A classification system for the reconstruction of vertical hemipharyngolaryngectomy for hypopharyngeal squamous cell carcinoma. Arch Otolaryngol Head Neck Surg 2011;137(1):88–94.

Lydiatt WM, Kraus DH, Cordeiro PG, et al. Posterior pharyngeal carcinoma resection with larynx preservation and radial forearm free flap reconstruction: a preliminary report. Head Neck 1996;18:501–505.

Wang CC, Liu SA, Wu SH, et al. Transoral robotic surgery for early T classification hypopharyngeal cancer. Head Neck 2016;38(6):857–862.

Zelefsky MJ, Kraus DH, Pfister DG, et al. Combined chemotherapy and radiotherapy versus surgery and postoperative radiotherapy for advanced hypopharyngeal cancer. Head Neck 1996;18:405–411.

49 Reconstruction of Hypopharyngeal Defects

Jason I. Kass

INTRODUCTION

The hypopharynx is a complex anatomic region that begins at the level of the hyoid and terminates at the esophageal inlet. It is adjacent to, but distinct from, the larynx and is the functional conduit that carries food from the oropharynx to the esophagus. Three anatomic subsites are included: paired pyriform sinuses, posterior pharyngeal wall, and postcricoid pharynx (Fig. 49.1).

KEY OPERATIVE LEARNING POINTS

- There are many reconstructive options for creating a neopharynx, and decision making depends on the following four general criteria: (1) size of the defect (laryngectomy with partial pharyngectomy, total laryngopharyngectomy, and total laryngopharyngectomy with cervical esophagectomy), (2) surgeon's experience with regional and free tissue transfer, (3) available donor sites that will provide sufficient tissue to reconstruct the defect, and (4) donor site morbidity that may help to select among multiple tissue flaps.
- A pharyngeal leak is the primary complication that carries a risk of significant morbidity/mortality for the patient. A leak not only puts a free tissue reconstruction at risk but also leads to fistula, wound healing complications, and infection leading to possible carotid blowout. This will prolong the postoperative care and delay oral intake and rehabilitation of speech.
- Stricture resulting from an inadequate pharyngeal circumference will impact the quality of deglutition but will also predispose patients to developing a pharyngeal leak.

PREOPERATIVE PERIOD

In preparing for reconstruction of hypopharyngeal defects, it is critical to anticipate the size of the defect and the remaining adjacent healthy tissue. With small lesions that can be removed via a transoral approach no reconstruction may be necessary, and the tissue can be left to heal by secondary intention. Unfortunately, hypopharyngeal cancer usually presents late and requires not only resection of the hypopharynx but also the larynx. This is, in part, from their late presentation. In general, tumors of the hypopharynx, more than 95% of which are squamous cell carcinoma, carry very high overall mortality rates (65% of patients die within 5 years of presentation). These cancers are characterized by submucosal spread with invasion of surrounding structures that lack barriers for spread, metastases to the neck or distant metastases at presentation, and a higher rate of synchronous second primary cancers.

Understanding the variety of surgical approaches for tumor resection can be helpful when anticipating the size of the defect required for reconstruction (Table 49.1). They can generally be divided into approaches that spare the larynx and those that require a laryngectomy. Laryngeal sparing procedures include transoral endoscopic approaches to the hypopharynx, as well as open approaches that resect a portion of one or more hypopharyngeal subsites, but preserve the larynx. Examples include well-circumscribed cancers of the posterior pharyngeal wall or small cancers in the pyriform sinus that can be excised along with a portion of the aryepiglottic fold. Open approaches with partial resection of the larynx can carry higher morbidity, particularly if the patient has had prior radiation of the neck. Laryngeal-sparing open approaches include a midline pharyngotomy with or without mandibulotomy, lateral pharyngotomy, and partial resection of the larynx with partial pharyngectomy. More commonly, a laryngectomy is required for patients with advanced cancer at presentation or persistent cancer following chemoradiation. Achieving a negative margin may require partial pharyngectomy or total circumferential pharyngectomy (Fig. 49.2). When the cancer extends to the cervical esophagus, a cervical or total esophagectomy is required.

There are many options when evaluating the reconstruction of a hypopharyngeal defect, and many decisions are based on the surgeon's preference and experience. A defect-oriented approach can be helpful when deciding reconstructive options (Table 49.2). The simplest reconstruction is none at all—and this can be achieved with many defects following endoscopic resection because there is a lower risk for pharyngocutaneous fistula and the wound can be left to granulate. After an open

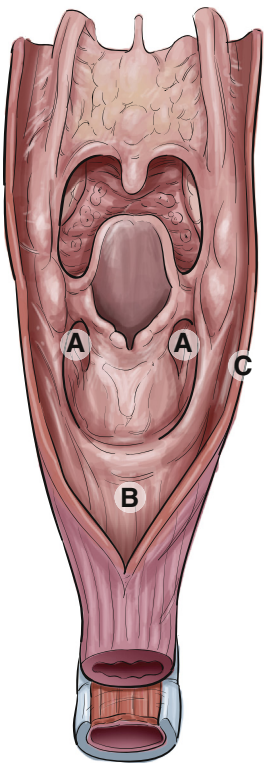

Fig. 49.1. Hypopharynx viewed posteriorly with the pharynx incised at the midline. The three subsites are identified. Paired pyriform sinuses *(A)*, postcricoid mucosa *(B)*, and posterior pharyngeal wall *(C)*.

TABLE 49.1 Surgical Approaches for Resection/Reconstruction of the Hypopharynx

- Laryngeal sparing:
  - Transoral resection subsite (either laser or robotic)*
  - Transhyoid midline pharyngotomy
  - Lateral pharyngotomy
  - Mandibulotomy with or without midline division of the tongue
  - Partial laryngeal surgery with hypopharyngectomy
- Laryngeal sacrifice:
  - Laryngectomy with partial pharyngectomy
  - Laryngectomy with total circumferential pharyngectomy
  - Laryngectomy with total circumferential pharyngectomy and cervical esophagectomy

*No reconstruction typically required—defect left to granulate.

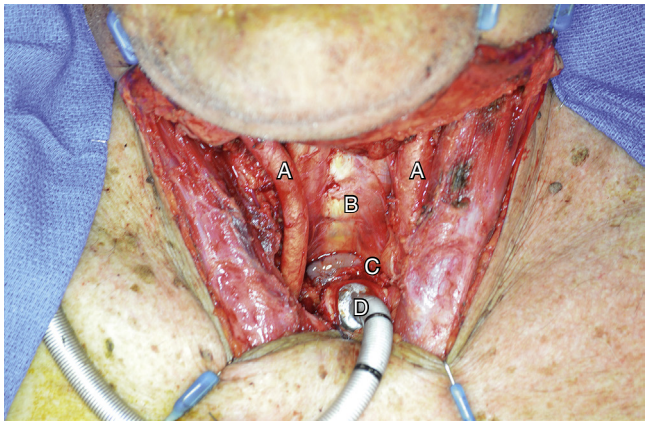

Fig. 49.2. Defect following total laryngopharyngectomy. Common carotid artery *(A)*, prevertebral fascia *(B)*, esophageal inlet *(C)*, and trachea with endotracheal tube in place *(D)*.

TABLE 49.2 Defect-Orientated Reconstructive Options of the Hypopharynx

- Hypopharyngeal defect following resection via endoscopic transoral approach
  - Healing via secondary intention with granulation and no reconstruction
- Partial laryngectomy with partial hypopharyngectomy (open approaches)
  - Primary closure with overlay local muscle flap (rare circumstance with no prior radiation and small defect)
  - Regional flaps
    - Pectoralis major myocutaneous flap
    - Deltopectoral fasciocutaneous flap
    - Island-deltopectoral fasciocutaneous flap
    - Supraclavicular fasciocutaneous flap
  - Free flaps
    - Radial forearm free flap
    - Anterolateral thigh flap
- Laryngectomy with partial pharyngectomy
  - Regional flaps
    - Pectoralis major myocutaneous flap
    - Deltopectoral fasciocutaneous flap
  - Free flaps
    - Radial forearm flap
    - Anterolateral thigh flap
- Laryngectomy with circumferential pharyngectomy
  - Regional flaps
    - Tubed pectoralis major myocutaneous flap
    - Tubed deltopectoral fasciocutaneous flap
  - Free flaps
    - Tubed radial forearm flap
    - Tubed anterolateral thigh flap
    - Jejunum free flap
    - Gastro-omental free flap
- Laryngectomy with total circumferential pharyngectomy and cervical esophagectomy
  - Gastric pull-up

approach is used to do a partial pharyngectomy, reconstruction is required. In the rare case of a small defect and no prior neck radiation, a primary closure with a local muscle flap (strap muscle or sternocleidomastoid muscle) can be used. More likely a cutaneous or fascial patch is required. A number of regional flaps can be elevated with a cutaneous skin paddle and rotated to close the pharyngectomy defect. The choices include the pectoralis major (PM) myocutaneous, deltopectoral (DP) fasciocutaneous, island deltopectoral (island-DP) fasciocutaneous, and supraclavicular (SC) flaps. Free tissue transfer is also an option and a thin pliable radial forearm (RFFF) or small anterolateral thigh free flap (ALT) can be used. With a total laryngopharyngectomy, the regional or free flap must be tubed to replace the entire pharynx. There are well-described series of reconstruction of the pharynx using tubed PM or DP flaps. In addition to the RFFF and ALT, the jejunum and gastro-omental free flaps are options. The jejunum is harvested as a tube so that there is one less suture line to leak. With each reconstructive option, there are limitations, and the problem with the jejunum is that it has an inferior voice outcome that sounds "wet" and food may be retained in the conduit, giving the patient significant halitosis. If the cervical esophagus is resected along with the larynx and pharynx, there are fewer options available for reconstruction. The gastric transposition (or "pull-up") is one way to recreate a pharyngeal conduit and requires collaboration with general surgeons.

For purposes of illustration, reconstruction of a total circumferential laryngopharyngectomy without cervical esophagectomy is described here using an ALT free flap. Other chapters describe the harvest of regional and free tissue transfer that can easily be translated to reconstruction of hypopharyngeal defects.

History

1. History of present illness
   a. Dysphagia—able to tolerate solids/liquids
   b. Mass in the neck
   c. Change in voice
   d. Hemoptysis/hematochezia
   e. Weight loss, nutritional status
   f. Fatigue
   g. Otalgia
   h. Functional status
2. Past medical history
   a. Prior head and neck treatment: any prior history of chemotherapy or neck radiation
   b. Comorbid medical illnesses—particularly pulmonary status if considering partial laryngeal surgery
   c. Surgical history: prior neck surgery? Prior surgery at potential donor sites (e.g. wrist, forearm, groin, or thigh)
   d. Family history: Disorders of bleeding/clotting are particularly important when considering free tissue transfer
3. Medications
   a. Antiplatelet drugs
   b. Herbal products
   c. Alcohol (consider risk of withdrawal)
   d. Allergies to antibiotics
4. Mental and social status

a. Coexisting or new situational depression
b. Ability to give consent
c. Social support structure

Physical Examination

1. Complete examination of the head and neck looking for synchronous second primary cancers and regional lymphadenopathy; incidental thyroid disease may be noted and inform which lobe of the thyroid to save or perform a total thyroidectomy at the time of the resection
2. Flexible fiberoptic examination—The cancer may not be visible so evaluate for effacement of the pyriform, visible blood or a friable mass, lack of vocal fold mobility, distortion of the larynx and pooling of saliva.
3. Potential donor sites for flaps
   a. Radial forearm free flap
      1) Evaluate for scars from prior surgery or injury.
      2) Perform an Allen test by occluding the radial and ulnar artery and asking the patient to squeeze a closed fist until the hand is pale. Release of the ulnar artery should result in brisk return of blood and normal color to the hand through the palmar arch. Delayed or no return indicates a radial dominant hand, which should not be used as a donor site.
   b. Anterolateral thigh free flap—Obesity may make the skin paddle too thick if making a tube; this is less of an issue if using it as a patch.
   c. Regional flaps—Evaluate for scars from prior surgery.
4. General health
   a. Nutrition
   b. Cardiovascular
   c. Respiratory
   d. Mental

Imaging

1. Chest radiograph
   a. Identify metastases.
   b. Synchronous lung cancer
   c. Pulmonary and cardiac status
2. Computed tomography (CT) of the neck with contrast
   a. Laryngeal erosion
   b. Esophageal involvement
   c. Metastasis to the neck
   d. Thyroid disease (consider ultrasound for characterization)
3. Magnetic resonance imaging (MRI)
   a. Not required in all cases
   b. Can be helpful to evaluate for preservation of adipose tissue planes
4. Chest CT
   a. Not required in all cases
   b. Can exclude pulmonary metastases
5. Positron emission tomography (PET)-CT
   a. Not required in all cases
   b. Excludes distant metastases; identifies second primary cancers
6. Modified barium swallow and cervical esophagram
   a. Functional status of the larynx
   b. Involvement of the mucosa of the esophagus
   c. Invasion of prevertebral fascia

Indications

1. Failure of nonoperative management with persistent cancer
2. In the setting of a nonfunctional larynx or advanced cancer it is reasonable to offer the patient a laryngectomy. In rare cases of limited cancer, partial resection of the hypopharynx with or without a partial laryngectomy can be considered.

Contraindications

1. Patient factors
   a. Medically unfit
   b. Unable to give informed consent
   c. Inadequate social support structure
2. Tumor factors
   a. Unable to obtain clear margins
   b. Invasion into the prevertebral fascia and spine
   c. Circumferential encasement of the carotid artery
3. Surgical factors
   a. Inadequate expertise available for reconstruction or postoperative complications

Preoperative Preparation

1. Optimize nutrition when possible with either nasogastric tube or gastric tube if the patient is not taking adequate nutrition by mouth.
2. Laboratory tests: preoperative prealbumin, albumin, thyroid stimulating hormone (TSH), white cell count, hematocrit, hemoglobin, and platelet count

OPERATIVE PERIOD

Anesthesia

1. Patients with cancer of the hypopharynx can usually be intubated without difficulty unless the cancer has eroded into the larynx, exerts mass effect, or extends superiorly to distort/obstruct the supraglottis.
2. At the time of reconstruction the patient should already have a tracheostomy in the case of laryngeal preservation approaches or via a tracheostoma following laryngectomy.

Positioning

1. Position the patient so that the ablative and reconstructive teams can work simultaneously to limit surgical time.
2. The patient is in the supine position with a shoulder roll for neck extension. This shoulder role may be removed following flap inset to facilitate the re-draping and closure of the skin of the neck.

Perioperative Antibiotic Prophylaxis

1. Clean-contaminated surgery with antibiotics during induction and continued for 24 hours
   a. First-generation cephalosporin + metronidazole
   b. Cefuroxime if allergic to penicillin
   c. Clindamycin alone provides inadequate antibiotic coverage in the setting of free tissue transfer.

Monitoring

1. Routine anesthesia monitoring
2. Arterial line for precision monitoring of blood pressure and access for intraoperative blood draws
3. During the resection, important cranial nerves, including CN X-XII, have typically been identified. Patient can be paralyzed at this point to allow the anesthesiologist greater control of blood pressure and respiratory status.

Instruments and Equipment to Have Available

1. Anterolateral thigh free tissue transfer
   a. Standard head and neck instrument set
   b. Harmonic scalpel can be helpful for dissecting through the vastus lateralis muscle
   c. Large Deaver retractor to aid with exposure when dissecting the proximal portion of the pedicle
   d. Microvascular instruments for vessel preparation and anastomosis
      1) Microvascular 9-0 nylon suture
      2) Microclips
      3) Heparin-injectable saline solution (1:200)
      4) Operating microscope or operating loupes
      5) Implantable Doppler (optional)
2. Montgomery salivary bypass tube (minimum 10- to 12-mm outer diameter) to assist with creation of the neopharynx

Key Anatomic Landmarks

1. PM, DP, and SC (see chapter on regional flaps)
2. Anterolateral thigh myocutaneous free tissue transfer
   a. A line drawn between the anterior superior iliac spine and lateral patella approximates the septum between rectus femoris and the vastus lateralis.
   b. Neurovascular anatomy
      1) The skin of the lateral thigh is typically supplied by two to three perforators from the descending branch of the lateral circumflex femoral artery (LCFA) and associated *venae comitantes.*
      2) The LCFA joins with the femoral artery (FA), and there are two *venae comitantes* that empty into the femoral vein.
      3) There is anatomic variation of the LCFA, and three types of cutaneous perforators have been described:
         a) Type I (70%): arise from the descending branch of the LCFA; 90% of them are musculocutaneous, and 10% are septocutaneous
         b) Type II (5% to 10%): arise from the transverse branch of the LCFA and travel a long distance though the vastus lateralis muscle
         c) Type III (1% to 5%): arise directly from the FA and are very small, take a long intramuscular course, and are usually too small for anastomosis
      4) The nerve to the vastus lateralis travels with the descending branch of the LCFA. This is a motor nerve, and when reconstructing the pharynx is not typically neurotized.

Prerequisite Skills

1. Pedicled flap harvest and inset—PM, DP, island-DP, and/or SC flaps
2. Free tissue transfer—ALT, RFFF, or alternative harvest sites that offer thin pliable tissue for inset (groin, lateral arm, jejunum, gastro-omental). For intra-abdominal donor sites, coordination with a general surgeon is essential.

Operative Risks

1. Related to duration of the procedure
   a. Intraoperative cardiac events
   b. Decubitus ulcers
2. Related to resection
   a. Aspiration—Ensure that there is no significant air leak and that the endotracheal tube is sufficiently inflated to protect the airway.
   b. Airway fire—Maintain oxygen saturation below 30% when using electrocautery near the airway. Maintain good communication with the anesthesia team regarding risks of a fire.

Surgical Technique

1. Anterolateral thigh free tissue harvest for a total laryngopharyngectomy defect (see Fig. 49.2)
   a. Choice of left or right thigh for flap harvest
      1) Avoid a side with prior surgery or injury at the donor site. Preoperative imaging is not required before harvest. If there are no scars or history of surgical intervention, then for the right-handed surgeon dissection toward the pedicle is easier from the right side. In cases of severe peripheral vascular disease, consider a different flap choice or angiography if there is no palpable popliteal pulse.
   b. Skin paddle design:
      1) Mark out a line drawn from the anterior superior iliac spine to the lateral patella.
      2) At the midpoint of this line, draw a circle with a 3-cm radius. Within this circle the vast majority of perforators can be found.
         a) Many surgeons use a Doppler to estimate the location of the perforators. A 5-0 Prolene suture can be used to mark the perforators.
      3) The skin paddle can be designed in either a spiral or horizontal configuration.
         a) Spiral configuration
            i) A long elliptical skin paddle is drawn with 8 cm at its largest width, centered at the midpoint of the circle. This can typically be closed primarily and evaluated by pinching the skin together.
         b) Horizontal configuration
            i) A trapezoid is drawn with an 8- to 14-cm width at one end for the base of tongue and 6 to 7 cm (the width of the cervical esophagus) at the other end. If the proximal portion of the neopharynx is longer than 8 cm, it may not be possible to close the donor site primarily.
         c) For pharyngeal reconstruction, a tube with a 3-cm distal radius is adequate for near-normal swallowing.
   c. Harvesting the flap
      1) The anterior incision is made through the skin, subcutaneous adipose tissue, and fascia down to the rectus muscle.
      2) The fascia and skin are gently retracted laterally to find the lateral edge of the rectus muscle and perforator vessels to the skin. The incision may need to be extended both superiorly and inferiorly to allow for identification of the perforator(s).
      3) Rarely there is an inadequate perforator (type III) to the lateral thigh (<5%) and either the other leg must be explored or a medial-thigh or free-style flap based on the medial system must be harvested.
      4) Two perforators from the descending branch of the LCFA are typically identified as either fasciocutaneous or musculocutaneous perforators.
      5) After the perforators are identified, mark their location by placing clips on the edges of the skin paddle fascia so they can be readily identified as the dissection proceeds.

6) Proximal separation of the rectus femoris from the vastus lateralis will allow for direct visualization of the main pedicle and palpation of the FA.
7) Careful proximal dissection from the distal perforator to the pedicle is important to ensure continuity of the perforator with the descending branch of the LCFA.
8) There are two *venae comitantes* that travel with the artery as well as the motor nerve to the vastus lateralis.
9) After the perforators have been traced to the pedicle, the proposed skin paddle is reexamined and shifted, if necessary, to ensure that they are included in the flap design. Care must be taken to correlate the site of the perforator with the location on the skin paddle. Mark this location on the skin so that the lateral incision will not injure the perforator.
10) The lateral incision of the skin paddle can now be made with confidence of the location of the perforator and continuity of the perforator with the pedicle.
11) The skin paddle should now be elevated, and the remainder of the dissection along the pedicle can be performed. It is helpful at this point to let the skin edges of the paddle bleed to ensure the viability of the flap.
12) A portion of the vastus muscle around the perforator and distal pedicle is typically harvested with the flap. This ensures that the vessels are protected. The harmonic scalpel can be helpful for efficient dissection through the muscle, particularly if the patient has not been paralyzed (i.e., if the ablative team prefers no paralysis during simultaneous harvest and neck dissection).
13) If the pedicle is under tension or twisted, it will go into spasm, and the edges of the flap will stop bleeding.

d. After the flap has been completely elevated, but still attached, check for adequate perfusion before clamping the pedicle and starting ischemic time period. The edges of the flap can be checked for bleeding, which should be bright red and flow readily. Abrading the skin edge with a sponge should initiate bleeding if the edges have been cauterized. If the flap bleeds slowly or is in question, then let it stay undisturbed for 10 minutes wrapped in a warm moist sponge and ensure that the pedicle is neither twisted nor under any tension. Temporarily secure the skin paddle to the leg in its anatomic position with a staple or a suture and let it warm up while ensuring that the recipient vessels are prepared in the neck.

2. Preparation of recipient vessels in the neck
   a. Arterial
      1) Any of the major branches of the external carotid (facial, lingual, and superior thyroid arteries) can be used. Alternatives that are preserved even in the setting of a previously operated field include the transverse cervical artery and internal mammary artery. The external carotid artery itself can also be used.
      2) The selected artery should be dissected free so that is it not tethered to the surrounding fascia. Small branches, particularly with the facial artery, should be clipped and divided.
      3) Minimal electrocautery (bipolar if necessary) should be used in proximity to the vessels. The vessels should be picked up only by their adventitia. Gentle handling of the vessels will minimize the chance of intimal injury and risk for thrombosis.
      4) After the artery has been dissected so that there is enough length to reach the free flap, a microvascular clamp is temporarily placed across the artery. The vessel should have brisk pulsatile flow with enough force to support the flap.
      5) Always have a second choice for an arterial input in case there are any problems with the artery after the ALT has been harvested and the ischemia window has started.
   b. Venous
      1) The external jugular vein and branches of the internal jugular vein are typically adequate to drain the flap. Transverse cervical and internal mammary veins can be used when the paired artery is dissected.
3. ALT inset
   a. Typically the majority of the flap is inset while ischemic to minimize edema of the flap.
   b. A tube is created by twisting the elliptical flap over a Montgomery pharyngeal stent (salivary bypass tube).
   c. This creates a spiral suture line that reduces the risk of postoperative stricture (Fig. 49.3).
   d. A distal portion of the skin paddle is de-epithelialized so that a monitoring portion can be incorporated externally (Figs. 49.4 and 49.5).
   e. Either a running Connell stitch or interrupted horizontal mattress sutures are used to close the pharynx
4. Revascularization of the flap
   a. Ask the anesthesiologist to maintain mean arterial pressure greater than 70.
   b. Under the microscope or with loupes using 9-0 suture, sew the artery. Evenly spaced interrupted sutures placed with care not to injure the intima will result in a successful anastomosis. Use heparinized saline to ensure complete visualization of proper placement of the sutures.
   c. Use a coupler for the venous anastomosis. If a coupler is not available or malfunctions, be prepared to sew the veins together. Irrigation of the vein with heparinized saline will keep the vein from collapsing and improve visualization of the edges of the vessel.
   d. After it is revascularized, use warm saline irrigation to warm up the flap.
   e. Perform a strip test on the vein to ensure adequate venous outflow.
   f. Palpate an arterial pulse on the flap pedicle.
   g. Turn the head in both directions to ensure the artery and vein do not become kinked.

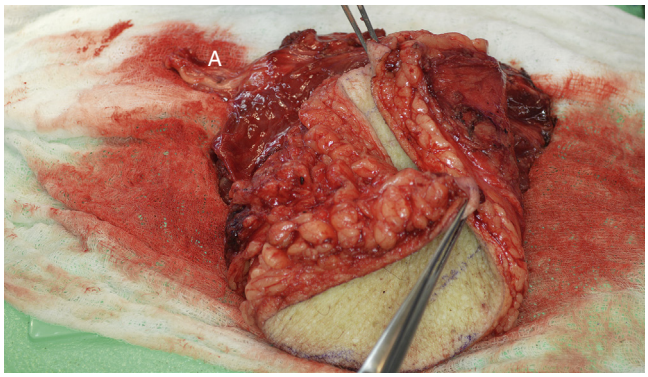

Fig. 49.3. Harvested anterolateral thigh free flap. The elliptical flap is brought together with a spiral suture line to create a neopharynx. The flap pedicle is lateral to the reconstruction for anastomosis with recipient neck vessels *(A)*.

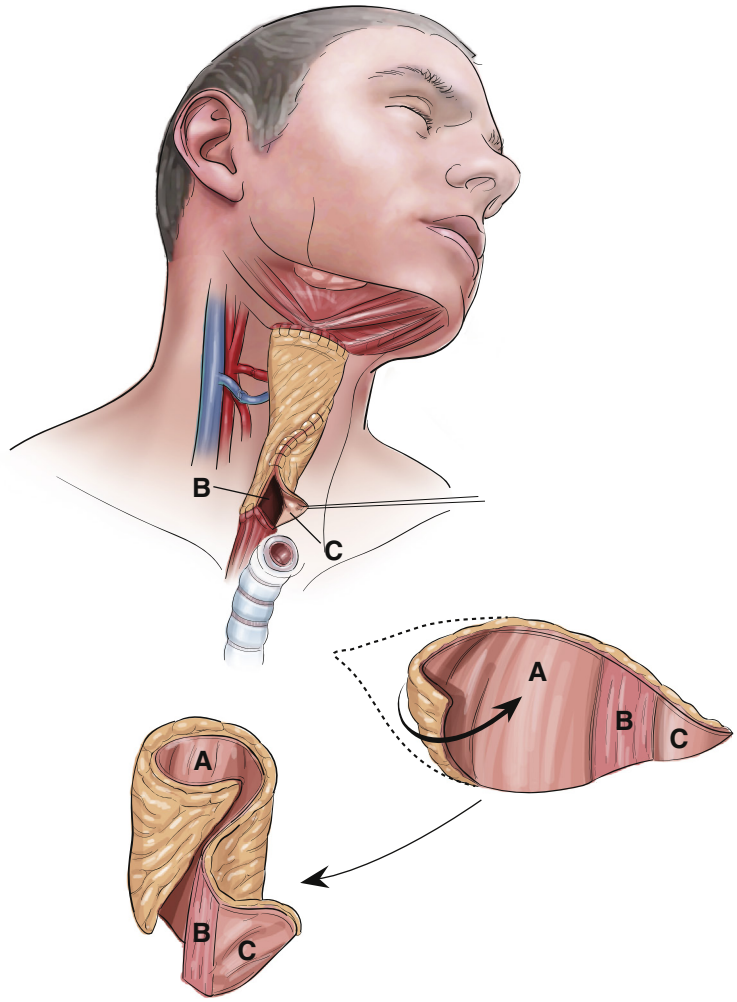

Fig. 49.4. A schematic detailing of one method of flap inset that allows for an external monitoring skin paddle. The skin paddle that will become the neopharynx *(A)*, de-epithelialized portion in the neck *(B)*, and triangular external monitor *(C)*.



Fig. 49.5. Final reconstruction of total laryngopharyngectomy with external skin paddle for monitoring. The flap shows bleeding with either pinprick or scratch. This monitor can be excised at a later time for better cosmesis.

h. Check the externalized portion of the skin paddle. Prick the flap with a 25-gauge needle and expect bright red bleeding after a slight delay.

5. PM inset
   a. The design and inset of the skin paddle are essentially the same as with the ALT; however, a monitoring skin paddle is not necessary.
   b. The flap should be elevated so that the distal edge of the skin paddle is not under tension, particularly when the patient turns his/her head.

Common Errors in Technique

1. General
   a. Creation of an inadequate tracheostoma—Half-mattress sutures should be used to bring the edges of the trachea to the skin (refer to chapter on total laryngectomy). Small distances should be between tracheal sutures, with wider distances on the skin flaps. This will stretch out and create a wide tracheostoma. The clavicular attachments of the sternocleidomastoid muscle can also impinge on the stoma. Partial medial division of these muscle fibers can allow for a larger stoma.
2. Reconstruction using regional pedicled flaps
   a. Tension on the proximal suture line—This usually occurs either as a result of poor planning of the skin paddle or inadequately releasing the pedicle so it can reach the most proximal inset on the contralateral side without tension.
      1) During flap design, accurately mark the pivot point for flap rotation. For the PM, the pivot point is where the thoracoacromial artery reaches the clavicle. At this point the flap will rotate over the clavicle. Use a large laparotomy towel and measure the distance from the most proximal inset point (on the contralateral

side) to the pivot point. To gain maximal rotation the lateral and medial muscle attachments must be released.

3. Reconstruction using ALT
   a. Internal rotation at the ankle can distort the position of the septum medially. This can result in a miscalculation of the medial incision for the skin paddle and result in injury to the perforators.

POSTOPERATIVE PERIOD

Postoperative Management

1. Reconstruction using regional pedicled flaps
   a. Antibiotics for 24 hours
   b. Monitor for hematoma—Distinguish between the normal appearance of the bulky pedicle overlying the clavicle.
   c. Early ambulation—postoperative day 1
2. Reconstruction using free tissue transfer
   a. Aspirin, subcutaneous heparin
   b. Flap monitoring—Methods and duration vary widely based on surgeon training and preference. Every four hours for the first two days, then every six hours for 1 day, and then twice daily until discharge works well.
      1) Clinical examination (color, capillary refill, skin turgor, bleed to pinprick with 25-gauge needle)
      2) Doppler signal
      3) Invasive methods (implantable Doppler around artery or vein)

Complications

1. Early
   a. Hypocalcemia—most common complication (45% in one series)
   b. Migration of the salivary bypass tube—if it is left in place during healing
   c. Fistula—a major cause of prolonged hospitalization, delayed oral intake, and delays in adjuvant therapy
      1) Recognize new or worsening tenderness, erythema, fever, wound breakdown, change in the drain output, or loss of stable suction drains.
      2) Confirm with bedside blue dye leak test, barium esophagram, or amylase in the drains.
      3) Establish a safe tract with a Penrose drain and then shift to local wound care, nutrition status, and general measures to help to close wounds.
      4) Ensure that the carotid artery is protected to prevent carotid blowout. A pharyngostome can be created to protect the carotid and divert saliva. This can then be closed at a later time.
   d. Flap failure
2. Late
   a. Permanent feeding tube
   b. Stricture
   c. Stomal stenosis
   d. Small bowel obstruction (those who have a laparotomy for reconstruction)

Alternative Management Plan

1. Primary nonoperative chemoradiotherapy for cancer of the hypopharynx
2. Alternative donor sites for regional and free tissue transfer (see Table 49.2)
3. Delayed reconstruction
   a. No reconstruction—oversew esophagus with planned salivary fistula
   b. Wookey flap—creating a neopharynx using the external cervical skin healed directly to the prevertebral fascia
      1) Two-step procedure with minimum 2- to 3-week delay between steps

DISCUSSION

Evidence-Based Medicine Question

What are the reported morbidity and mortality outcomes following reconstruction? How are the functional outcomes with regard to speaking and swallowing?

A number of retrospective series from individual institutions have looked at oncologic and functional outcomes after resection and reconstruction of the hypopharynx.[1] Here are the results of a representative series that reported on 136 patients treated over a 14-year period.[2]

Morbidity

Surgical and medical complications were 29% and 8%, respectively. Pharyngocutaneous fistula was the most common in this series. Of note, the rate of postoperative hypocalcemia, which had been previously found to be more common than fistula,[3] was not reported. Common complications included postoperative hemorrhage and cardiovascular events. Late complications reported in other series include stricture, stomal stenosis, permanent feeding tube, and small bowel obstruction (in patients who had a laparotomy for flap harvest).

Mortality

Perioperative mortality was 3% in this series. In general, the outcome was poor, with 5-year overall survival (OS) of 35% and disease-specific survival (DSS) of 49%. There was no difference in OS with respect to the size of the defect; however, disease free survival (DFS) was lower for partial pharyngectomy versus circumferential pharyngectomy. This suggests that the mucosa at risk may be greater than indicated by mucosal appearance and frozen section.

Speaking

Tracheoesophageal puncture (TEP) was performed in 38% (44% to 60% in other studies). Patients who were reconstructed with pedicled flaps were more likely to have a prosthesis placed. The authors note that those who had free flap reconstruction were more likely to have circumferential defects and were less amenable to voice prosthesis placement. Primary versus delayed TEP placement remains surgeon and institution dependent despite evidence that free flap reconstruction generally does not interfere with TEP placement and voicing. The jejunum free flap is associated with a "wet voice."

Swallowing

More than 80% of the patients in this series resumed full oral diet, and the remaining had a gastrostomy tube for partial or complete nutritional supplementation. There are no randomized studies evaluating the impact of type of reconstruction with swallowing. In this study the authors note that a bulky ALT may not be appropriate for reconstruction of a posterior pharyngeal defect with preservation of the larynx.

Editorial Comment

Hypopharyngeal defects may result from localized resections or from total laryngectomy with partial or total (circumferential) pharyngectomy. Optimal reconstruction of

complex hypopharyngeal defects requires special expertise and experience. Dr. Kass has divided the subject into laryngeal preservation and laryngeal sacrifice and provided the surgical armamentarium that is needed to reconstruct defects from relatively simple to extremely complex. As emphasized in the chapter, many hypopharyngeal defects require microvascular expertise. Historically, the jejunal free flap and radial forearm fasciocutaneous flaps were preferred for reconstruction of circumferential defects. The jejunal free flap had significant donor site morbidity and resulted in some problems with succus production and sometimes a very "wet" postlaryngectomy voice. The radial forearm free flap also has donor site morbidity, and stricture was sometimes a problem. Many surgeons now prefer the anterolateral thigh free flap. The larger volume of soft tissue makes it more versatile for insetting into defects that may involve not only the entire circumference of the hypopharynx but extension into the oropharynx, nasopharynx and cervical esophagus, and/or skin. In addition, the donor site morbidity is considerably less than either the jejunum or radial forearm. Although dilation of the pharyngoesophageal segment is sometimes required after ALT free flap reconstruction, stricture formation may be more manageable because of the volume of tissue in the flap.

Christopher H. Rassekh

Access the review questions and additional sources list online at
http://www.expertconsult.com

ACKNOWLEDGMENTS

I acknowledge Hyunjoo Park for the illustrations in this chapter.

REFERENCES

1. Welkoborsky H-J, Deichmüller C, Bauer L, et al. Reconstruction of large pharyngeal defects with microvascular free flaps and myocutaneous pedicled flaps. Curr Opin Otolaryngol Head Neck Surg 2013;21(4):318–327.
2. van der Putten L, Spasiano R, de Bree R, et al. Flap reconstruction of the hypopharynx: a defect orientated approach. Acta Otorhinolaryngol Ital 2012;32(5):288–296.
3. Clark JR, Gilbert R, Irish J, et al. Morbidity after flap reconstruction of hypopharyngeal defects. Laryngoscope 2006;116(2):173–181.

REVIEW QUESTIONS

1. What is the most common late postoperative complication following total laryngopharyngectomy?
   a. Salivary fistula
   b. Hypocalcemia
   c. Pharyngeal stricture
   d. Flap failure

2. When considering how to reconstruct the hypopharynx what factor is most important?
   a. Defect size
   b. Surgeon experience
   c. Prior surgery at potential donor sites
   d. All of the above

3. What is the most common arterial blood supply to the anterolateral thigh free flap?
   a. Septocutaneous and musculocutaneous perforators from the profunda femoris, a branch from the femoral artery
   b. Only septocutaneous perforators from the descending branch of the lateral circumflex femoral artery
   c. Septocutaneous and musculocutaneous perforators from the descending branch of the lateral circumflex femoral artery
   d. Only musculocutaneous perforators from the profunda femoris, a branch from the femoral artery

ADDITIONAL SOURCES

Blackwell KE. Anterolateral thigh free flap. In: Mark L. Urken, Mack L. Cheney, Keith E. Blackwell, Jeffrey R. Harris, Tessa A. Hadlock, Neal Futran, eds. Atlas of Regional and Free Flaps for Head and Neck Reconstruction: Flap Harvest and Insetting. Baltimore and Philadelphia: Lippincott Williams and Wilkins/Wolters Kluwer; 2012.

Goldstein DP, Clark J, Gullane PJ, et al. Carcinoma of the hypopharynx. In: Eric M. Genden, Mark A. Varvares, eds. Head and Neck Cancer: An Evidence-Based Team Approach. New York: Thieme; 2008.

50 Cancer of the Cervical Esophagus

Anastasios Maniakas, Apostolos Christopoulos

INTRODUCTION

Cancer of the cervical esophagus has long been known as one of the most difficult neoplasms to treat and cure surgically. It is relatively uncommon, representing less than 5% of all esophageal cancers, themselves representing 5% of all digestive system cancers.[1] In 2010 in the United States there were an estimated 16,640 new cases of esophageal carcinoma, with 14,500 deaths, thus explaining the paucity of data with cervical esophageal carcinoma.[1] Patients often present with advanced-stage cancer and several comorbidities. The aggressive clinical course of this disease is influenced by the high incidence of submucosal spread, ipsilateral or bilateral lymph node metastasis, and the high rate of a second primary cancer in the esophagus.[2] Involvement of the larynx and trachea is often encountered, as a distant metastasis. The surgical defects are often quite significant and most of the time circumferential, necessitating challenging reconstructive planning. A multidisciplinary team is therefore required for the proper management of patients with cancer of the cervical esophagus, including a head and neck surgeon, thoracic surgeon, reconstructive surgeon, medical oncologist, radiation oncologist, speech language pathologist, nutritionist, and physiotherapist. As such, the patients' treatment remains personalized and tailored to their needs, with the main goal being that of curing while attempting to allow for functional rehabilitation to maximize the patients' quality of life.

Squamous cell carcinoma is the most frequent histologic type of cancer found in the cervical esophagus. Primary adenocarcinoma of the cervical esophagus is rare and may arise from Barrett esophagus. Less common are tumors that arise from heterotopic gastric mucosa without evidence of Barrett disease. Benign lesions occur infrequently, the most common being pedunculated hyperplastic or fibrovascular polyps. Benign lesions are most often removed by endoscopic excision.

KEY OPERATIVE LEARNING POINTS

- Cancer of the cervical esophagus is a rare disease and may be a direct extension of a hypopharyngeal lesion.
- Early diagnosis is one of the most important factors for survival.
- Posttreatment quality of life, in association with functional outcomes, should be a key discussion point before choosing to move ahead with extensive surgery.
- Computed tomography (CT) is essential in the preoperative evaluation of a patient.
- Invasion of the prevertebral fascia must be ruled out before, or at the beginning of, any surgical intervention.
  - Any level of invasion is a strict contraindication to surgery.
- Encasement of the carotid artery is a strict contraindication to surgery.
- The presence of distal cervical esophageal or proximal thoracic esophageal cancer involvement is an indication for total esophagectomy.

PREOPERATIVE PERIOD

History

1. History of present illness
   a. Patients with cervical esophageal cancer often have vague and nonlocalizing symptoms, while also being known as long-term smokers and drinkers, thus requiring a thorough head and neck oncologic questionnaire, including the following signs and symptoms:
      1) Sore throat
      2) Hoarseness
      3) Gastroesophageal reflux
      4) Heartburn/chest pain
      5) Difficulty swallowing: dysphagia, odynophagia, aspiration, globus sensation
      6) Hemoptysis
      7) Weight loss; often associated with advanced disease
      8) Dyspnea
      9) Referred otalgia
      10) Mass in the neck
   b. A clear timeline of the signs and symptoms is important to collect because it often provides a preliminary idea of the evolution and progression of the cancer.
   c. More than one-third of patients with early-stage cancer will be asymptomatic at presentation.[3]
2. Past medical history and associated risk factors
   a. Medical illnesses
   b. Surgeries: oropharyngeal, laryngeal, or hypopharyngeal
   c. Previous head and neck radiation
   d. Family history of cancer
   e. Risk factors: tobacco (cigarette or pipe smoking), alcohol abuse, Plummer-Vinson syndrome, lower socioeconomic class, and lower educational levels. Heavy alcohol and tobacco abuse increases the risk of cancer of the head and neck.

Physical Examination

1. Appearance: Patients will often seem malnourished, dehydrated, and with poor oral hygiene.
2. The oral cavity and oropharynx should always be examined to avoid overlooking any asymptomatic second primary cancer or direct extension from a large cancer.
3. Mirror examination and flexible endoscopy
   a. Evaluation of the base of the tongue with proper protrusion of the tongue
   b. Vallecula
   c. Hypopharynx: requires a thorough evaluation reviewing bilateral vocal cord mobility, any extension into the pyriform sinuses (using a puffed cheek maneuver), postcricoid region, and/or the posterior pharyngeal wall. Pooling of secretions is often encountered as a result of distal obstruction by the cancer.
4. Palpation of the neck is performed to rule out regional metastasis. Paratracheal nodes are a common site of metastasis from cervical esophagus cancer.

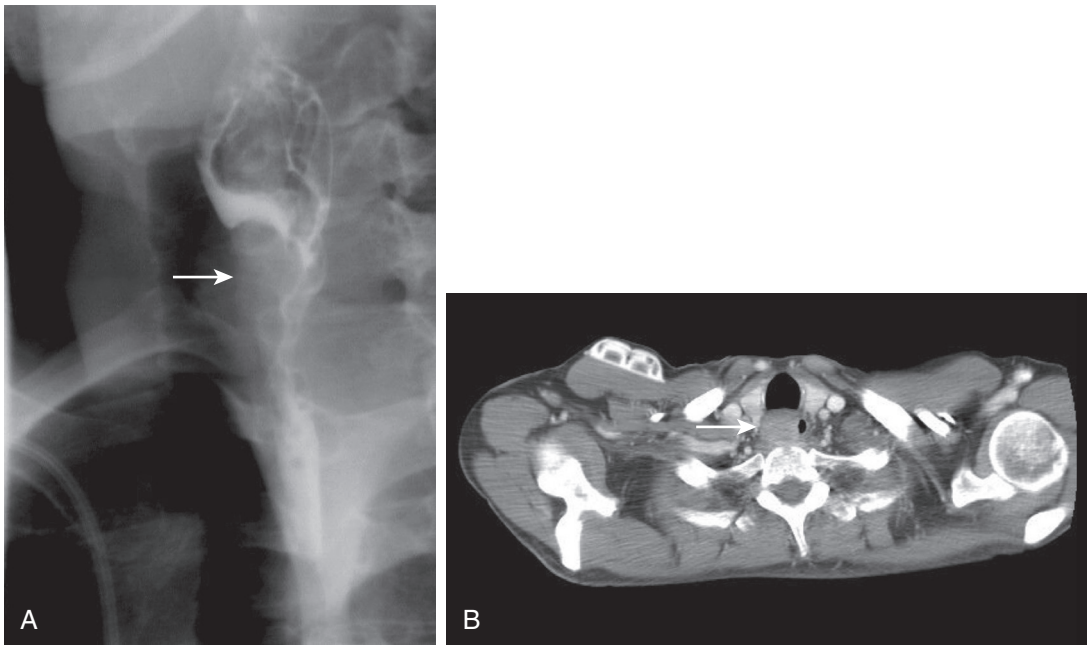

Fig. 50.1. A, Barium esophagogram demonstrating carcinoma of the cervical esophagus *(arrow)*. **B,** Computed tomography scan of same patient demonstrating the cancer with narrowing of the lumen of the cervical esophagus *(arrow)*.

Imaging

Imaging studies contribute to the diagnosis and staging while giving information about whether the cancer appears to be technically operable. Although flexible endoscopy provides a direct visualization of the mucosa, it is the imaging that will be most helpful in staging the cancer.

1. Esophagography (barium esophagogram)
   a. Used to determine the extent of mucosal involvement and to establish the presence of a second primary cancer in the more distal aspect of the esophagus (Fig. 50.1A)
   b. The most valuable aspect of this imaging modality is the evaluation of invasion of the posterior wall of the esophagus.
   c. Obliteration of the retropharyngeal and retroesophageal space or invasion of the prevertebral fascia can be estimated through dynamic fluoroscopic evaluation.
   d. In the presence of aspiration, it would be prudent to carry out a diatrizoate meglumine (Gastrografin) esophagogram rather than a barium esophagogram because less reaction occurs if the patient aspirates Gastrografin into the lungs than if barium is aspirated.
2. CT scan with intravenous contrast enhancement of the head, neck, and chest. All newly diagnosed cancers of the head and neck require at the least a CT of the chest before staging (see Fig. 50.1B).[4]
   a. Most widely used imaging technique for cancer of the cervical esophagus
   b. CT of the neck should be performed using maximum 3-mm slice thickness, whereas chest CT can be done with 5- to 7-mm slice thickness.
   c. Goal: accurately evaluate the location and size of the primary cancer and determine whether there is direct extension of tumor into the neck, especially posteriorly into the retropharyngeal and esophageal space, prevertebral fascia, or vertebral column (Fig. 50.2)
   d. Key points:
      1) An anteroposterior diameter of the cervical esophagus greater than 24 mm must be considered abnormal.
      2) The average thickness of the wall is 4.8 mm laterally and 3.8 mm posteriorly.
      3) Thickening of the esophageal wall and effacement of the adipose tissue plane are the two criteria with the best sensitivity.
      4) Presence of a circumferential mass surrounding the esophagus greater than 180 or 270 degrees has a reported sensitivity of 100%.
   e. Cancer of the cervical esophagus most often metastasizes to paratracheal, jugular chain, recurrent laryngeal nodes and superior mediastinal lymph nodes.
3. Magnetic resonance imaging (MRI) may provide greater soft tissue delineation and insight toward prevertebral fascia invasion; however, it does not provide additional staging information than does a CT scan. Some surgeons may prefer this modality to CT scan for initial staging.
4. Positron emission tomography (PET)-CT scan is an imaging tool that is now routinely used for staging cancer of the head and neck, as well as for evaluation of metastatic disease. It should be considered in the workup of cervical esophageal cancer, as well as in monitoring active response in treated patients. Having a trained radiologist or nuclear medicine specialist reviewing the PET-CT images is of utmost importance due to their complexity and the high rate of false-positive readings.
5. Ultrasonography (US) may be used to provide complementary information to the aforementioned imaging techniques via a transesophageal evaluation of the tissues. A US assessment of cervical lymph node metastasis can be made coupled with fine-needle aspiration biopsy to provide valuable information in the staging process.
6. Endobronchial US (EBUS) with fine-needle aspiration for more difficult to attain suspicious lymph nodes (paratracheal, subcarinal, paraesophageal) is often used in our center and allows for a more accurate staging of the disease.

Indications

1. The cancer is resectable with only regional metastases.
2. Patient fit for extensive surgical procedure with challenging and lengthy postoperative recovery period

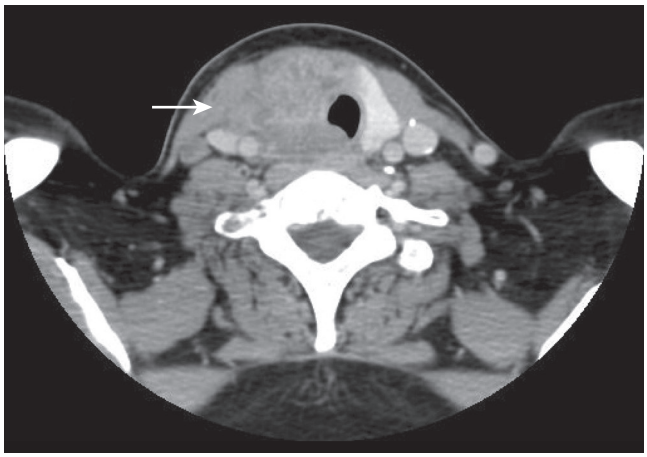

Fig. 50.2. Squamous cell carcinoma of the cervical esophagus with extensive invasion of surrounding structures in the neck *(arrow)*.

BOX 50.1 Staging of Cervical Esophageal Cancer

Tx: Unable to assess the primary tumor
T0: Unable to find the primary tumor
Tis (HGD): High-grade dysplasia (HGD) is abnormal cells that have not invaded deeper cell layers. This term has replaced the term carcinoma in situ for columnar mucosa in the gastrointestinal tract.
T1a: Tumor invades into the lamina propria or muscularis mucosa
T1b: Tumor invades the submucosa
T2: Tumor invades the muscularis propria
T3: Tumor invades the adventitia
T4a: Resectable tumor invading the pleura, pericardium, or diaphragm
T4b: Unresectable tumor that invades other structures, such as aorta, spine, trachea
Nx: Neck lymph nodes cannot be assessed.
N0: No evidence of any spread to nodes
N1: 1 or 2 cancerous nodes in the region
N2: 3 to 6 cancerous nodes in the region
N3: 7 or more cancerous nodes in the region
M0: No evidence of distant spread
M1: Evidence of spread outside of the head and neck (lungs, bone, brain)

Contraindications

1. Severe medical comorbidities rendering the patient unfit for surgery (poor nutritional status, medically unstable)
2. Encasement of the carotid artery visualized in the preoperative imaging is a definite contraindication to surgery. However, if the surgeon unexpectedly finds encasement of the carotid arteries intraoperatively, the extirpative part of the procedure should be completed with the understanding that it will be palliative rather than curative surgery.
3. Involvement of the prevertebral fascia or vertebral column. This should be assessed clinically at the beginning of surgery by using finger dissection of the hypopharynx and esophagus from the prevertebral fascia. If the cervical esophagus cannot be separated easily from the prevertebral fascia, cure is unlikely.
4. Distant metastases

Preoperative Preparation

1. Complete medical preoperative evaluation, including an electrocardiogram, complete blood count, liver function, and renal function tests is required. As previously mentioned, patients often present with severe comorbidities, such as advanced chronic obstructive pulmonary disease secondary to long-term cigarette smoking or cirrhosis of the liver due to chronic alcoholism. Preoperative evaluation by the internal medicine team is essential.
2. Before surgery, patients should be optimized accordingly:
   a. Patients with low hemoglobin should undergo transfusion.
   b. Nutritional status should be evaluated with a referral to a medical nutritionist, if deemed severe.
3. A diagnostic endoscopy and biopsy should be performed under general anesthesia, although some of these patients may also have upper airway obstruction or an unstable airway because of bilateral vocal cord paralysis, in which case the endoscopy should be preceded by a tracheostomy under local anesthesia. Tracheoscopy is also performed to evaluate the integrity of the tracheal wall.
4. Staging of the cancer should be performed after the physical examination, imaging, and biopsies are available. Staging for a cancer of the cervical esophagus does not resemble that of cancers of the hypopharynx and instead follows the latest National Comprehensive Cancer Network published clinical practice guidelines (Box 50.1).[5]
5. Percutaneous gastrostomy should be avoided preoperatively in the patient with severe dysphagia because this could jeopardize gastric transposition. Instead, a nasogastric feeding tube should be used if necessary. A percutaneous gastrostomy tube may be placed for nutritional replenishment before surgery but only after the reconstructive team has eliminated gastric transposition as an option.

OPERATIVE PERIOD

Anesthesia

All surgical procedures are conducted in the operating room under general anesthesia and endotracheal intubation.

Positioning

Patients are positioned in a dorsal decubitus (supine) manner, along with a shoulder roll and adequate headrest retraction to ensure maximal neck extension. The patient is then prepared and draped in such a way to have proper access to the head and neck, as well as the chest and abdomen for reconstruction purposes.

Perioperative Antibiotic Prophylaxis

A combination of a first-generation cephalosporin and metronidazole intravenously should be given preoperatively and for a minimum of 5 to 7 days postoperatively.

Monitoring

No special intraoperative monitoring is required.

Instruments and Equipment to Have Available

1. Standard neck dissection set
2. Tracheostomy set
3. Reconstruction set according to reconstruction team, including microvascular instrument set and sutures

Key Anatomic Landmarks

1. Refer to the chapter on neck dissection and laryngectomy landmarks.

2. The cricopharyngeus muscle represents the transition between the hypopharynx and cervical esophagus.
3. The retropharyngeal and retroesophageal spaces, along with the prevertebral fascia, are key sites that need to be evaluated and cleared of tumor invasion, as no surgical resection can ensure clear margins.
4. The cervical esophagus extends from the esophageal orifice, found at the lower border of the cricoid cartilage, to the sternal notch.
5. The carotid arteries must be cleared of any encasement by the cancer.

Prerequisite Skills

1. Surgery of the cervical esophagus should be performed by an oncologic surgeon with proper training in extensive neck procedures. The surgeon should be prepared for a complex resection that can include esophagectomy, laryngectomy, hypopharyngectomy, thyroidectomy, tracheal resection, and neck dissection including level 4 nodes.
2. Knowledge of meticulous margin assessment by the surgeon and his pathology team is of paramount importance.
3. A team well trained for all reconstructive options must be available for the surgery.

Operative Risks

1. Pneumothorax
2. Pneumomediastinum
3. Neck abscess
4. Fistula
5. Hemorrhage
6. Mediastinitis
7. Refer to neck dissection, thyroidectomy, and tracheostomy chapters for respective operative risks.

Surgical Technique

1. Total laryngopharyngoesophagectomy (LPE): Due to the typical presentation of advanced-stage disease, a laryngopharyngectomy is required to obtain proper surgical margins and avoid postoperative aspiration. Because the cancer often extends distally in the esophagus, a total esophagectomy is required. Ong and Lee were the first to describe this technique more than 50 years ago as a single-stage, three-phase operation involving cervical and abdominal incisions and a thoracotomy.[6] Thoracotomy was then replaced by a transhiatal esophageal mobilization and finally by the more recent thoracoscopic approach.
   a. *Apron flap elevation*
   b. *Evaluation of prevertebral fascia:* The sternocleidomastoid muscle is retracted laterally and the larynx medially. The carotid sheath is identified and retracted laterally. The prevertebral fascia is identified by blunt dissection. Finger palpation is then used to determine whether the cancer has infiltrated into the retropharyngeal or retroesophageal space or into the prevertebral fascia. If cancer is present in the retropharyngeal or retroesophageal space, the surgery should be terminated because it is impossible to get a clear margin of resection posteriorly when invasion of the prevertebral fascia is present. In such cases, a gastrostomy and possibly a tracheostomy should be carried out to provide a means of nutrition and maintenance of the airway. If the retropharyngeal space is clear, surgery should proceed.
   c. *Bilateral selective neck dissection:* If the patient has an N0 neck, levels II, III, IV, and VI are dissected. (For more information on Neck Dissection refer to *Chapters 64 and 66*.)
      1) Dissection of level VI is mandatory because multiple lymph nodes in the tracheoesophageal groove may be involved.
   d. *Tracheal resection:* The extent of tracheal resection is dictated by the imaging studies and tracheoscopy. If there is no involvement of the trachea, the usual transection of the trachea between the second and third tracheal rings is appropriate. However, if cancer has extended into the trachea, more of the distal trachea may need to be resected.
   e. *Laryngopharyngectomy: (For more information on laryngectomy refer to Chapter 16).* A transhyoid pharyngotomy is carried out (Fig. 50.3), and the retropharyngeal fascia is separated from the prevertebral fascia in the retropharyngeal space up into the level of the transhyoid incision. Scissors are used to cut through the posterior wall of the pharynx. After this is carried out, the specimen containing the larynx and pharynx attached to the cervical esophagus is then elevated by sharp and blunt dissection down as far as possible into the anterior mediastinum (Fig. 50.4). Ligation of the superior laryngeal arteries and veins is carried out during this procedure. The adjacent lymph nodes, including the retropharyngeal group, should be taken.
   f. *Thyroid and parathyroid glands:* Inspection of the thyroid gland will determine whether the thyroid gland should be left intact or be totally or partially removed. If the thyroid has been infiltrated by cancer, it must be removed along with the specimen (see Fig. 50.2). Parathyroid glands should be preserved and/or re-implanted if necessary. *(For more information on thyroidectomy and parathyroidectomy refer to Chapters 78 and 84, respectively.)*
   g. *Superior surgical margin:* Specimens should be taken from the superior margin of resection of the pharynx and sent to the pathology department for frozen section examination to make certain that the margins of resection are free of cancer. If not, the surgeon must take additional specimens until clear margins are obtained. The specimen remains attached until the stomach is mobilized.
   h. *Total esophagectomy:* The stomach is then mobilized in the abdomen. Blunt dissection in the mediastinum from the abdomen into the neck allows the specimen to be delivered and the stomach to be delivered into the neck by applying gentle traction to each (Fig. 50.5). The esophagus is separated from the stomach at the gastroesophageal junction, the lumen of the pharynx and esophagus is opened, and the edges of the specimen are checked microscopically for tumor clearance (Fig. 50.6).
   i. *Partial esophagectomy:* In certain cases in which limited proximal cervical esophageal cancer is encountered, a partial esophagectomy can be undertaken, ensuring a minimum of 2-cm margins, followed by reconstruction with tissue transposition or free tissue flap. Esophageal stay sutures should be placed because tissue retraction into the mediastinum can occur following partial cervical esophagectomy.
2. Reconstruction: In most patients undergoing an esophagectomy, reconstruction is performed using a gastric conduit with the ultimate goal to replicate the esophageal tract as close as possible. The options for reconstruction can be subdivided into pedicled enteric conduits, enteric free flaps, pedicled myocutaneous flaps, and myocutaneous free flaps, each demonstrating their own advantages and disadvantages.
   a. *Gastric transposition (pull-up):* This reconstruction technique following LPE for cancer of the cervical esophagus was popularized by Sir Donald Harrison.[7] It is a single-stage method of reconstruction and allows for rapid re-establishment of deglutition. A two-layer

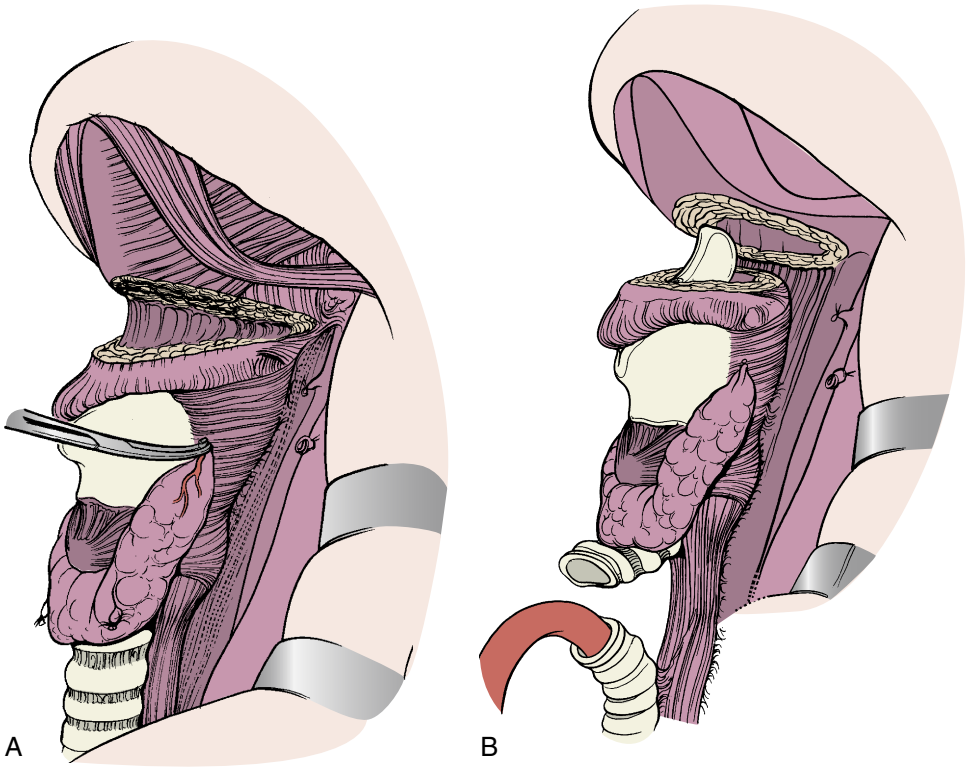

Fig. 50.3. A, Transhyoid pharyngotomy is carried out, and the pharyngeal lumen is explored. **B,** The incision is carried through the lateral and posterior pharyngeal wall to separate the pharynx from the base of the tongue. *(From Silver CE. Surgery for Cancer of the Larynx and Related Structures. New York: Churchill Livingstone; 1981, pp 198–199.)*



Fig. 50.4. The specimen is elevated off the prevertebral fascia by finger dissection as far inferior as the superior mediastinum, where it is pedicled on the cervical esophagus.

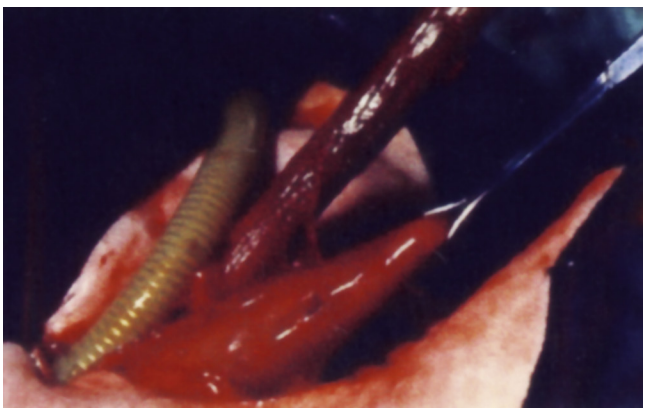

Fig. 50.5. Using gentle traction on the specimen and the stomach allows the specimen to be delivered and the stomach to be brought into the neck to complete the pharyngogastric anastomosis.

closure with nonabsorbable suture is carried out, anastomosing the stomach to the remaining walls of the hypopharynx and the base of the tongue (Fig. 50.7). Other authors have described the use of a single-layer technique with a 4-0 absorbable monofilament with the knots tied in the lumen.[8] Mucosal inversion is ensured using a modified Gambee technique. Several nonabsorbable sutures are then placed between the stomach and the left diaphragmatic crus to prevent herniation of the stomach back into the thorax. Overall, a gastric transposition offers a simple reconstructive solution with adequate length and robust blood supply. Postoperative chest radiography will show the stomach widening the mediastinal shadow (Fig. 50.8).

b. *Colonic interposition:* This procedure is usually reserved for the rare situation in which either a gastric transposition or a free tissue transfer is not possible. Preparation of the bowel with a pure liquid diet and oral intake of antibiotics directed at colonic flora is instituted 48 hours before surgery. The left colon is usually the preferred segment



Fig. 50.6. Laryngopharyngoesophagectomy specimen. It will be opened lengthwise to inspect the mucosa of the pharynx and esophagus and to be certain that tumor clearance is macroscopically adequate. Frozen sections will be carried out to confirm the adequacy of the margins.

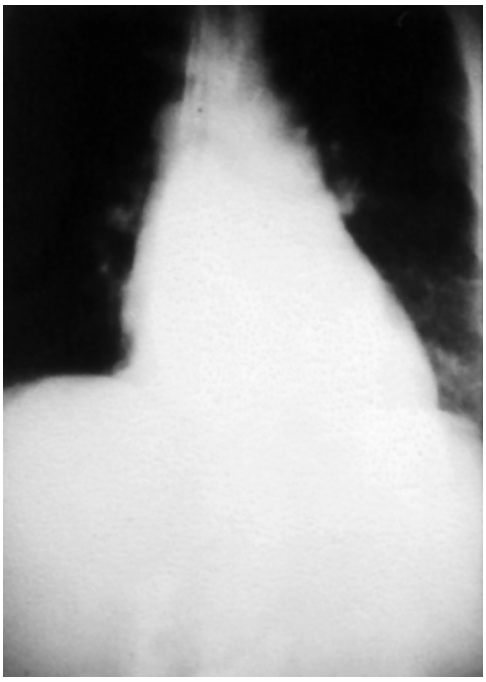

Fig. 50.8. Postoperative chest radiograph demonstrating the stomach widening the mediastinal shadow.

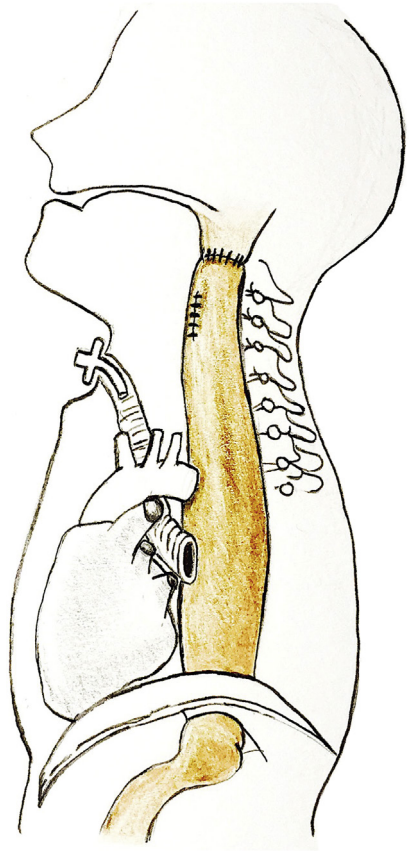

Fig. 50.7. Diagram of gastric transposition with pharyngogastric anastomosis (Drawn by Dr. Ilyes Berania, MD).

for esophageal replacement because it has a more stable blood supply, and its size is more closely associated to that of the esophagus, although all three segments can be used. Because it preserves its active peristalsis, it may offer a superior functional substitute to the esophagus compared with the more passive gastric transposition. Lastly, this reconstructive technique requires multiple anastomoses, thus increasing the risk of anastomotic leaks.

c. *Jejunal free flap:* This free tissue flap was the first use of a free tissue transfer in humans, reported by Seidenberg et al. in 1959.[9] It currently remains the abdominal organ used most frequently as a free tissue transfer for cervical esophageal reconstruction.[10] It is readily available and does not require a bowel preparation, and its diameter is an adequate replacement to the esophagus. Furthermore, its preserved peristalsis may help with the transport of the food bolus, and therefore care must be taken to insert the flap in an isoperistaltic orientation. We recommend having an exteriorized monitoring segment of jejunum based on the same pedicle that may be excised 5 to 7 days postoperatively. Finally, the jejunum has also shown strong tolerance to postoperative radiotherapy and will often allow for decreased rates of xerostomia due to its robust secretory surface.
d. *Gastro-omental free flap:* First reported in 1979 this free flap has the advantage of including a large omental apron that can be used to fill large dead spaces or cover the anastomosis and previously or potentially irradiated vessels. Mucus secretion is also found in this flap and aids in deglutition, although its composition is significantly more acidic, and mucosal ulceration of adjacent tissues is possible. Furthermore, unlike in the jejunal free flap, patients are left with a gastric staple line.
e. *Deltopectoral or pectoralis major myocutaneous flaps:* These myocutaneous flaps provide a large volume of well-vascularized tissue used to cover the newly reconstructed cervical esophagus and exposed major vessels after exenteration of the central compartment. Their pliable nature allows suturing of the trachea to the skin edge without tension and avoids intraluminal prolapse of

excess soft tissues, thus maintaining patency of the tracheostoma. However, they remain too bulky to create a tubularized conduit.

f. *Radial forearm free flap:* A group from Detroit described the successful use of a radial forearm free flap for reconstruction of an esophageal defect following resection of a localized squamous cell carcinoma of the cervical esophagus. This patient had previously undergone definitive chemoradiation (CRT) for a T4N2c of the base of the tongue and therefore was not eligible for CRT or an esophagectomy with a proximal anastomosis. This free flap may also be rolled into a tube in an effort to replace a short circumferential defect after a cervical esophageal excision. However, longer defects should be reconstructed with an alternative free flap.

g. *Anterolateral thigh free flap:* This free flap may be raised as a cutaneous, fasciocutaneous, or myocutaneous graft and provides a longer length than the radial forearm free flap. Yu described a novel technique performed in 10 patients for reconstruction of combined pharyngoesophageal, tracheal, and anterior neck defects with a single anterior thigh flap. The skin paddle was divided into two islands based on cutaneous perforators. One paddle was tubed and used for esophageal reconstruction and the other for repair of cutaneous defects. This technique provides good cosmetic and functional results with minimal morbidity and quick recovery.

3. Tracheoesophageal puncture can be completed postoperatively, as described in Chapter 83, to achieve phonation with a reasonable degree of success; a "tracheogastric" puncture in patients in whom reconstruction involves gastric transposition and "tracheojejunal" puncture in those in whom repair is accomplished with a jejunal interposition flap can be made. This procedure is simple and safe, and a puncture into the jejunum produces a rather "moist" voice but one that is understandable. Puncture through the posterior wall of the trachea into the transposed stomach also produces a suboptimal, although understandable, low-volume voice.
4. Occasionally, patients may present with small lesions where a limited resection of the cervical esophagus with preservation of the larynx and the function of the cricopharyngeus muscle and vocal cords may be possible. Interesting findings in laryngeal preservation surgery have been reported from a group in Japan, where 33 patients with cervical esophageal squamous cell carcinoma had a cervical esophagectomy followed by reconstruction with a jejunal free flap. Recurrence rates, complications rates, and overall survival were all comparable with the non–larynx-preserving group (25 patients), as well as with the current literature on cervical esophageal cancer surgery. Initial nodal status and the use of neoadjuvant therapy were comparable between the two study groups, although more than 50% of the larynx-preserving group had a T1 or T2 lesion, compared with the non–larynx-preserving group that had primarily T3 or T4 lesions. In another study by Mizobuchi et al., a Weerda laryngoscope was used to remove an early esophageal cancer in a single patient where the lesion was limited to the mucosa. Apart from mucosal resection, endoscopic therapy has evolved to include photodynamic therapy, argon plasma coagulation, multipolar electrocautery, laser therapy, cryotherapy, and radiofrequency ablation,[8] showing comparable long-term survival rates to surgical resection, although these therapies are only applicable to patients with mucosal lesions and for whom lymph node metastases are rare.

Common Errors in Technique

1. Failure to adequately assess the extent of the cancer preoperatively will often result in inadequate resection of the cancer.
2. Attempts to resect the cervical esophagus while maintaining an intact laryngotracheal tract are challenging and require a nearly perfect combination of tumor location, stage, surgical, and reconstructive skills.
3. Previous gastric surgery or placement of a gastrostomy tube to correct malnutrition may make gastric transposition impossible.

POSTOPERATIVE PERIOD

Postoperative Management

1. A chronic alcoholic who continues to drink heavily before surgery is at high risk for delirium tremens.
2. Antibiotic therapy, as discussed in the section "Perioperative Antibiotic Prophylaxis." Any fistula formation or anastomosis leak/breakdown requires continuous antibiotic therapy.
3. Strict nil per os for 24 to 48 hours followed by nasogastric or percutaneous gastrostomy feeding
4. Thyroid hormone replacement therapy for patients whose thyroid gland has been removed at the time of the surgery with the specimen
5. Calcium levels should be monitored closely followed by adequate replacement therapy.
6. Gastroesophageal reflux disease precautions should be taken, and every patient should receive proton pump inhibitors in the postoperative period.
7. Drain (cervical, thoracic, abdominal) management is often variable from one center or subspecialty to the next.
8. Such surgical procedures often lead to severe psychologic distress due to the mutilating aspect of the defect. Close follow-up with a psychologist or psychiatrist is highly recommended.
9. Adjuvant or neoadjuvant CRT should be considered in patients having undergone a total LPE.
10. An anastomotic leak with a gastric transposition should be aggressively treated because the acidity of gastric secretions may result in severe bleeding from neck vessels.

Complications

1. Nonspecific complications: pneumothorax, pneumonia, pleural effusion, fluid shifts, hemorrhage, pulmonary atelectasis, intrathoracic chyle leak, ischemia or necrosis of reconstruction tissue, peritonitis or gastrointestinal perforation (for gastric conduit reconstructions), tracheobronchial injury, wound dehiscence, hypocalcemia
2. Gastric pull-up
   a. Gravity will instill an important tension on the anastomosis and may increase rates of anastomosis leaks (10% to 37%), which can rapidly evolve to mediastinitis, sepsis, and death.
   b. Early satiety, postprandial discomfort, dysfunctional propulsion/dumping syndrome
3. Colonic interposition
   a. Short term: anastomotic leaks and strictures, as well as ischemia
   b. Long term: redundancy, leading to delayed emptying, stasis, and dysphagia
   c. Ulceration of the distal colonic interposition due to gastric reflux—can lead to stricture or perforation
4. All free flaps
   a. Stricture: treated by direct surgical revision, balloon dilatation, or placement of a stent
   b. Fistula formation: often treated by secondary intention. Chronic fistulas can be treated with a pedicled myocutaneous flap

5. Study specific outcomes
   a. Triboulet et al. reported a total mortality rate of 4.8% and an overall morbidity rate of 38.3% in a series of 209 patients, including 78 with cancer of the cervical esophagus. Reconstruction was carried out via gastric transposition, colonic transposition, or a jejunal free flap. Gastric transposition is the most frequent cause of respiratory complications. The survival rate without dysphagia is better in patients with gastric transposition than in those with jejunal grafts. The authors found no significant difference in survival between the techniques of reconstruction. However, better results were obtained with gastric transposition because of fewer postoperative complications, faster re-establishment of oral feeding, and better quality of life.
   b. Podrecca et al., in their review of 346 patients who underwent free flap reconstruction in the head and neck, found that poor preoperative condition, previous treatment, and requirement for a vein graft were significantly associated with an increased risk for flap failure and other morbidities. Fistula formation occurs in 7% to 37% of patients. Necrosis and fistula rates are higher in jejunal free flaps compared with gastric transposition. Murray et al. reported no fistula development in the 14 patients reconstructed with a combination of anterolateral thigh free flap and salivary bypass despite the fact that some had been treated previously. In one of their patients a stricture developed that was successfully treated by dilatation.

Alternative Management Plan

1. Treatment of cancer of the cervical esophagus has also been undertaken in certain centers by primary radiation therapy (RT), in an attempt to preserve laryngeal function. In a 224-patient retrospective study by Cao et al., 2-year local, regional, distant, and overall disease-free survival were comparable with primary surgical therapy. Further long-term (5-year) survival rates and quality of life reports are required to truly understand the advantages and potential complications of primary RT.
2. As advances in CRT continue to emerge, patients with advanced, unresectable cancer of the cervical esophagus are now being treated, with an increasing population reaching long-term status follow-ups. Studies are now showing that definitive CRT in advanced, unresectable cancers of the cervical esophagus show comparable 3- and 5-year overall survival rates to that of surgery. Gkika et al. treated 55 patients with cervical esophageal cancer with definitive CRT, and at 2 months 35 (64%) had a complete response, 28 biopsy-proven. Survival rates at 2, 3, 5, and 10 years were 35%, 29%, 25%, and 10%, respectively. All patients still alive at their last follow-up had normal swallowing and no or mild esophageal symptoms.

DISCUSSION

Evidence-Based Medicine Question

The management of unresectable cancer of the cervical esophagus remains a significant challenge. What role does primary CRT or RT alone play for unresectable cancer of the cervical esophagus, and what are the survival benefits?

- Refer to the section "Alternative Management Plan."

Editorial Comment

This chapter provides an important summary of the literature on cancer of the cervical esophagus. The prerequisite knowledge for management of this extremely difficult disease is contained in the other chapters in this section. In other words, it is important to understand all the principles of diagnosis and management of the entire hypopharynx, larynx, and upper esophagus to take on the challenge of cancer in this difficult location.

Comorbidity is the rule rather than the exception, and treatment failure is common due to the high incidence of regional failure. Although surgery may not be curative, it is often the only way to effectively palliate patients.

Reconstruction is covered not only here but also in other chapters, and the method of choice depends not only on tumor extent but also on coexisting conditions. The tolerance of visceral flaps, fasciocutaneous flaps, and the stomach to the high doses of radiation required to manage this cancer is an area of current and future investigation as improved methods of radiation delivery and new targeted drug therapies become available.

The authors have done an excellent job of adding important material from the recent literature to the chapter from the prior edition.

Christopher H. Rassekh

Access the review questions and additional sources list online at http://www.expertconsult.com

REFERENCES

1. Jemal A, Siegel R, Xu J, et al. Cancer statistics, 2010. CA Cancer J Clin 2010;60:277–300.
2. Lefebvre J, Chevalier D, Coche-Dequeant B. Cancer of the hypopharynx and cervical esophagus. In: Myers EN, Suen J, Myers J, Hanna E, editors. Cancer of the Head and Neck. Elsevier; 2003, London. p. 379–390.
3. Hoffman HT, Karnell LH, Shah JP, et al. Hypopharyngeal cancer patient care evaluation. Laryngoscope 1997;107:1005–1017.
4. Loh KS, Brown DH, Baker JT, et al. A rational approach to pulmonary screening in newly diagnosed head and neck cancer. Head Neck 2005;27:990–994.
5. Ajani JA, Barthel JS, Bentrem DJ, et al. Esophageal and esophagogastric junction cancers. J Natl Compr Canc Netw 2011;9:830–887.
6. Ong GB, Lee TC. Pharyngogastric anastomosis after oesophagopharyngectomy for carcinoma of the hypopharynx and cervical oesophagus. Br J Sur 1960;48:193–200.
7. Harrison DF, Thompson AE. Pharyngolaryngoesophagectomy with pharyngogastric anastomosis for cancer of the hypopharynx: review of 101 operations. Head Neck 1986;8:418–428.
8. Hagen JA, Grant K. Surgical treatment of cancer of the esophagus and esophagogastric junction. In: Yeo CJ, editor. Shackelford's Surgery of the Alimentary Tract. Elsevier Saunders; 2013, Philadelphia. p. 435.
9. Seidenberg B, Rosenak SS, Hurwitt ES, et al. Immediate reconstruction of the cervical esophagus by a revascularized isolated jejunal segment. Ann Surge 1959;149:162–171.
10. Chen HC, Tang YB. Microsurgical reconstruction of the esophagus. Semin Surg Oncol 2000;19:235–245.

REVIEW QUESTIONS

1. Which of the following is an absolute contraindication to a surgical intervention in cervical esophageal cancer?
   a. Unilateral cervical lymph node metastasis
   b. Bilateral cervical lymph node metastasis
   c. Prevertebral fascia invasion
   d. Thoracic esophageal disease

2. Which of the following is FALSE in cervical esophageal cancer?
   a. Imaging tools are highly sensitive in ruling out prevertebral fascia invasion.
   b. Ultrasound-guided fine-needle aspiration is a helpful tool in disease staging.
   c. A chest computed tomography (CT) or positron emission tomography-CT should be completed to evaluate distant metastasis.
   d. Endobronchial ultrasound may be used to evaluate intrathoracic lymph node metastasis.

ADDITIONAL SOURCES

Ali Mohammad FH, Go P, Ghanem T, et al. Long-term survival after local resection of cervical esophageal cancer. Ann Thorac Surg 2015;99:2202–2203.

Baudet J. Reconstruction of the pharyngeal wall by free transfer of greater omentum and stomach. Int J Microsurg 1979;1:53.

Cao CN, Luo JW, Gao L, et al. Primary radiotherapy compared with primary surgery in cervical esophageal cancer. JAMA Otolaryngol Head Neck Surg 2014;140:918–926.

Gkika E, Gauler T, Eberhardt W, et al. Long-term results of definitive radiochemotherapy in locally advanced cancers of the cervical esophagus. Dis Esophagus 2014;27(7):678–684.

Hihara J, Hamai Y, Emi M, et al. Role of definitive chemoradiotherapy using docetaxel and 5-fluorouracil in patients with unresectable locally advanced esophageal squamous cell carcinoma: a phase II study. Dis Esophagus 2016;29(8):1115–1120.

Miyata H, Yamasaki M, Takahashi T, et al. Larynx-preserving limited resection and free jejunal graft for carcinoma of the cervical esophagus. World J Surg 2013;37:551–557.

Mizobuchi S, Nakatani H, Akimori T, et al. Novel use of Weerda laryngoscope to remove early cervical esophageal cancer. Ann Thorac Surg 2005;79:e34–35.

Murray DJ, Gilbert RW, Vesely MJ, et al. Functional outcomes and donor site morbidity following circumferential pharyngoesophageal reconstruction using an anterolateral thigh flap and salivary bypass tube. Head Neck 2007;29:147–154.

Papachristou DN, Trichilis E, Fortner JG. Experimental use of free gastric flaps for the repair of pharyngoesophageal defects. Plast Reconstr Surg 1979;64:336–339.

Podrecca S, Salvatori P, Squadrelli Saraceno M, et al. Review of 346 patients with free-flap reconstruction following head and neck surgery for neoplasm. J Plast Reconstr Aesthet Surg 2006;59:122–129.

Triboulet JP, Mariette C, Chevalier D, et al. Surgical management of carcinoma of the hypopharynx and cervical esophagus: analysis of 209 cases. Arch Surg 2001;136:1164–1170.

Yu P. One-stage reconstruction of complex pharyngoesophageal, tracheal, and anterior neck defects. Plast Reconstr Surg 2005;116:949–956.

SECTION 9 Surgery of Obstructive Sleep Apnea

51 Office-Based Snoring Procedures

Amy Schell, Andrea Lewis

INTRODUCTION

"Primary snoring" can be described as a symptomatic, sleep-related, respiration-dependent acoustic phenomenon with an apnea-hypopnea index (AHI) of less than 5 and without complaints of daytime sleepiness.[1] Snoring is common; it is estimated that 35% to 45% of men and 15% to 28% of women snore regularly. Current evidence regarding the medical morbidity of snoring is inconclusive. Population-based studies have been contradictory regarding the effect of snoring on mortality, cardiovascular disease, metabolic syndrome, and stroke.[2] Like mild obstructive sleep apnea (OSA), treatment of snoring is still commonly considered elective and optional depending on the implications on the patient's sleep and that of his or her bed partner. Snoring is the most common presenting symptom in sleep-disordered breathing patients, and therefore otolaryngologists should be aware of the proper workup as well as procedures and therapies available to treat this condition.

Numerous medical therapies are available for snoring, including various over-the-counter (OTC) options. Several common OTC choices, such as lubricating oral spray, nasal dilator strips, and snoring pillows, were not shown to be individually beneficial in a randomized, blinded clinical trial. Oral appliances have been shown to significantly reduce snoring, theoretically by increasing the size of the pharyngeal airway in both the lateral and the anterior-posterior dimensions.[1,3] If oral appliances are used, follow-up is necessary to monitor the occlusion and dental health long term.[4] Like available OTC snoring aids, oral appliance therapy is also limited by the requirement of regularly nightly use of the device.

Snoring is caused by the vibration of soft tissues in the upper airway during respiration; these vibrations are exacerbated by sleep-related relaxation of upper airway dilator muscles. The source of vibration is typically the flutter of the soft palate but can theoretically be anywhere along the upper airway.[1] Surgeries addressing the patency of the nasal airway may help snorers who complain of nasal obstruction. The details of such procedures are discussed in detail elsewhere in this text. As a majority of snoring originates at the soft palate, the focus of the remainder of this chapter will be on awake, office-based palatal procedures. All of these procedures have the end goal of stiffening and/or reorienting the palate such that inhalation-induced vibration will be less likely to occur.

KEY OPERATIVE LEARNING POINTS

1. Snoring procedures must minimize morbidity and preserve function, especially as snoring is generally considered to be medically benign.
2. When choosing the appropriate snoring procedure, the patient's upper airway anatomy as well as social and financial concerns should be taken into consideration.
3. Long-term follow-up after any of these procedures is necessary in order to monitor for return of snoring symptoms or signs of progression to OSA.

PREPROCEDURE PERIOD

History

1. History of present illness
   a. Quality, quantity, and intensity of the snoring itself: A visual analog scale (VAS) can be helpful in quantifying the subjective intensity of snoring and can help assess the effect of treatment over time.
   b. Aggravating factors
      1) Position
      2) Medications
      3) Alcohol consumption
      4) Weight gain
   c. Presence of symptomatic nasal obstruction
   d. Sleep history: A full sleep history is warranted to assess for possible underlying and/or accompanying sleep disorders.
      1) Nocturnal apneas
      2) Daytime sleepiness
      3) Insomnia symptoms
      4) Morning headaches
      5) Restless sleep
      6) Nocturia
2. Past medical history
   a. Prior medical or surgical treatment for snoring or sleep-disordered breathing
   b. Medical illness: The patient must be healthy enough to tolerate an in-office procedure.
   c. Social history
      1) Nicotine use: Abstaining from nicotine may help maintain a regular overall sleep-wake cycle.
      2) Alcohol use: This can affect quality of sleep directly and can increase snoring by reducing upper airway muscle activity.
   d. Medications
      1) Sleep aids, benzodiazepines, and other sedating medications that impact central or peripheral control of breathing during sleep
      2) Anticoagulant drugs that may increase the risk of bleeding during the procedure
      3) Allergies to antibiotics

Physical Examination

1. Nasal cavity, including nasal endoscopy
   a. Septal deviation
   b. Turbinate hypertrophy
   c. Nasal polyposis
   d. Adenoid hypertrophy
2. Oral cavity
   a. Dentition, including width and depth of the dental arches
   b. Occlusion
3. Oropharynx
   a. Length of the soft palate
   b. Size of the uvula
   c. Hypertrophy of the tonsils
   d. Hypertrophy of the lateral oropharyngeal wall
4. Craniofacial morphology
   a. Retrognathia
   b. Maxillary retrusion
5. Overall body habitus, including body mass index (BMI): Weight reduction is often accompanied by a reduction in snoring and should be recommended for every overweight patient presenting with snoring.
6. Flexible laryngoscopy
   a. Sagittal configuration and length of the soft palate
   b. Size and compliance of the lateral oropharyngeal walls
   c. Size and position of the base of the tongue
   d. Shape and collapsibility of the epiglottis
   e. Muller's maneuver, an attempted inspiration with closed nose and mouth, may help identify problem areas with a tendency to obstruct.

Imaging/Testing

1. Sleep laboratory testing: A sleep study, either via home portable monitoring or in-lab polysomnography (PSG), is required to rule out the presence of OSA and other sleep disorders in those seeking treatment for snoring.
2. Drug-induced sedated endoscopy (DISE): DISE refers to flexible endoscopy performed on the sedated patient during spontaneous respiration. Sedation is typically achieved with propofol infusion. DISE may be considered if there is confusion regarding the anatomic source of snoring after clinical examination and flexible endoscopy. DISE may improve surgical success rates compared to clinical bedside examination in cases of snoring and OSA.
3. Allergy testing: In snoring patients with symptomatic nocturnal nasal obstruction and symptoms of allergic rhinitis, allergy testing may indicate a reversible cause. A trial of medical therapy for allergy may also be beneficial to determine the impact of the rhinitis and nasal resistance on the patient's snoring.
4. Lateral cephalometric radiograph: Imaging is not routinely indicated for primary snoring but may be helpful in cases of skeletal abnormalities.

Indications

1. Primary snoring in the setting of significant burden on the patient or bed partner

Contraindications

1. Patient factors
   a. Inability to tolerate awake, office-based intervention
   b. Allergy to local anesthetic
   c. For palatal procedures, pre-existing velopharyngeal insufficiency (VPI) or cleft palate
   d. Trismus or other oral anatomy (e.g., large torus palatinus) precluding adequate awake access to the soft palate
   e. Relative contraindication: Obesity is associated with lower success rates for snoring procedures; this should be discussed preoperatively.
2. Disease factors
   a. Underlying OSA: Procedures for primary snoring are not appropriate management in the setting of untreated moderate to severe OSA.
   b. Comorbid sleep disorders should also be addressed prior to procedures for primary snoring.

Preprocedure Preparation

Discontinue anticoagulant drugs if possible; however, the use of anticoagulants is not an absolute contraindication to these procedures.

PROCEDURES

Anterior Palatoplasty

When uvulopalatopharyngoplasty (UPPP) was first introduced and became widespread in the 1990s, the procedure involved relatively radical tissue resection that often resulted in common and bothersome adverse side effects. In the ensuing years, several less invasive, functional versions of the procedure were developed.[1] One of these UPPP descendants, the traditional cautery-assisted palatal stiffening operation (CAPSO), has been employed for snoring and involves the removal of a midline strip of palatal mucosa in the anterior-posterior direction. Though this procedure served to successfully stiffen the palate, the resulting scar was shown to narrow the distance between the tonsillar pillars laterally.

The modified CAPSO, or anterior palatoplasty, involves a horizontally oriented mucosal excision in the proximal soft palate. Resultant scarring and fibrosis not only stiffens the palate but also serves to pull the palate anteriorly and superiorly with healing (Fig. 51.1). This procedure seems to be especially suited for patients with obstruction at the genu of the soft palate.[5]

Anesthesia

- Local: If the patient requires only soft palate and uvula interventions, this procedure may be carried out under local anesthesia in the office setting.
- General: If a patient is noted to have large tonsils, a tonsillectomy may be simultaneously indicated. When tonsillectomy is required, the anterior palatoplasty may be carried out under general anesthesia at the time of tonsillectomy.

Positioning

- Seated: The patient should be sitting upright, at a level where the surgeon can comfortably visualize the oral cavity and oropharynx.
- Tongue depressor(s) are typically required to visualize the soft palate. The cooperative patient may assist with exposure by holding his or her own tongue depressor(s).

Perioperative Antibiotic Prophylaxis

- Anitbiotics are recommended prior to incision. Cefprozil 500 mg may be given orally 1 hour before procedure, or clindamycin may be used for patients who are penicillin-allergic.

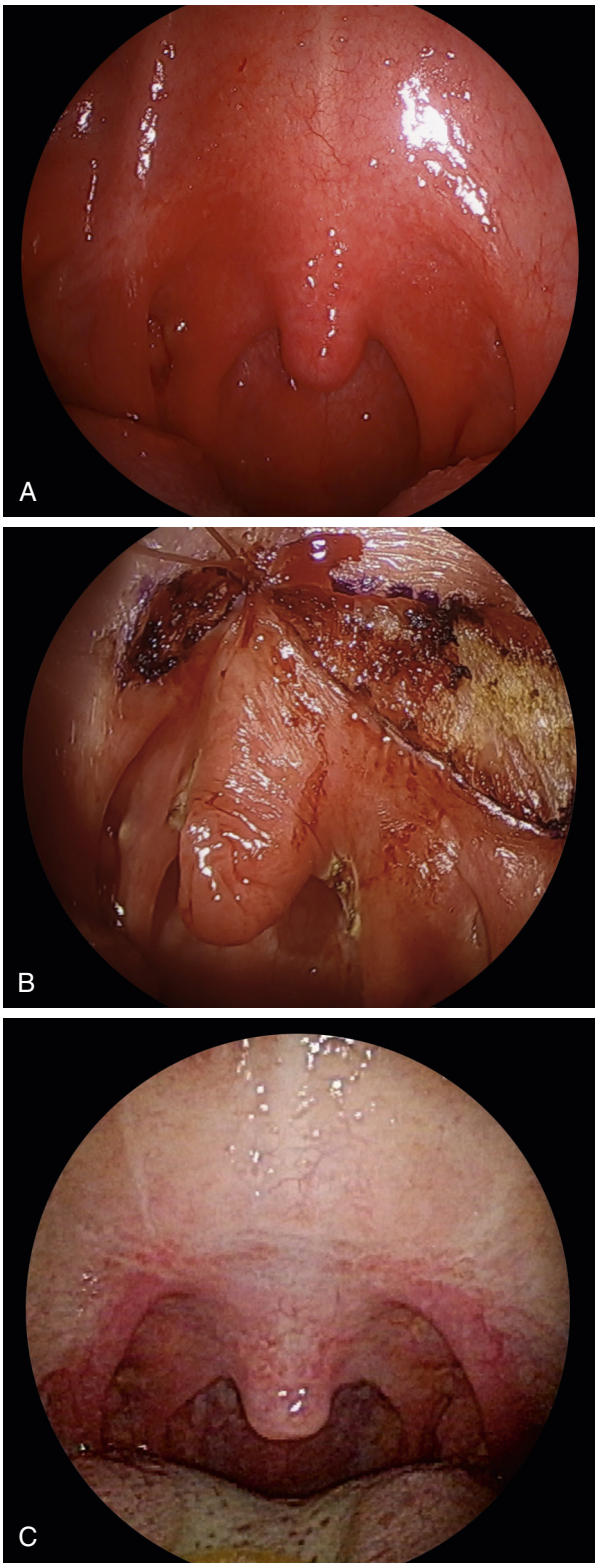

Fig. 51.1. A, Preoperative, **B,** intraoperative, and **C,** postoperative appearance of anterior palatoplasty.

Instruments and Equipment to Have Available

- Needle-tipped monopolar cautery on a setting of 10 to 15
- Suction for oral secretions, bleeding, and electrocautery fumes

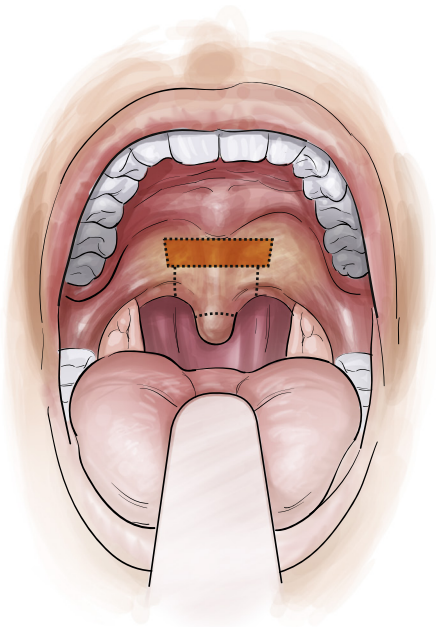

Fig. 51.2. Planned excision area for anterior palatoplasty.

Surgical Technique (Fig. 51.2, Video 51.1)

- Oral cavity prepped with chlorhexidine mouth rinse
- Apply benzocaine spray (or equivalent topical anesthetic) to the oropharynx
- Inject local anesthetic: Inject a total of 2 to 4 cc 1% lidocaine with 1:100,000 epinephrine (or equivalent) into the soft palate in three sites, midline and approximately 1.5 cm on either side of midline.
- Perform partial uvulectomy, if uvula elongated. The redundant mucosa may be grasped with forceps and truncated at the distal aspect of the musculus uvulae.
- Perform parauvular incisions, if necessary: If prominent palatal arch webbing is noted, full-thickness vertically oriented cuts may be made on either side of the uvula. This step may serve to widen the distance between the tonsillar pillars laterally.
- Remove a strip of mucosa: A horizontal strip of mucosa from the proximal soft palate, approximately 4 to 5 cm in length and 7 to 10 mm in width, is removed down to muscle.
- Suture the defect: Approximately 5 to 10 interrupted 4-0 Vicryl sutures are used to close the defect, effectively transposing the palate anteriorly and superiorly with closure.

Operative Risks and Common Errors in Technique

- Over-resection of the uvula: It is prudent to leave the muscular aspect of the uvula intact for maximum preservation of function.

Radiofrequency Ablation of the Soft Palate

Radiofrequency ablation (RFA) is a process that delivers thermal energy to submucosal soft tissues via a needle applicator, creating controlled, elliptical lesions and eventually inducing fibrosis and contracture. RFA gives the advantage of tissue volume reduction as well as stiffening. Thus this procedure may be particularly advantageous for the patient with a thick soft palate. Additionally, the safest area to treat is at or near the midline, where the palatal bulk is the greatest. A preprocedure lateral cephalogram can be used to measure the thickness of the soft palate in the midline when the

safety of the procedure is in question. Though the soft palate is the chief focus here, RFA has been applied at various levels of the upper airway, including the nasal turbinates and tongue base. RFA seems to be especially well tolerated from a discomfort standpoint; however, multiple sessions are typically required to achieve the desired levels of snoring reduction.

For information on anesthesia, positioning, and perioperative antibiotic prophylaxis, see section "Anterior Palatoplasty."

Instruments and Equipment to Have Available

- Commercially available handpiece: Two options include the Somnus temperature-controlled device (Somnus Medical Technologies, Sunnyvale, California) and the Coblation system with ReFlex Ultra 55 Plasma Wand (Smith & Nephew PLC, London, UK).
- Flexible laryngoscope

Surgical Technique (Fig. 51.3)

- Prepare oral cavity with chlorhexidine mouth rinse.
- Apply benzocaine spray (or equivalent topical anesthetic) to the oropharynx.
- Choose and mark treatment sites: A variety of soft palate RFA lesion patterns have been described, including one midline lesion, one midline lesion with two lateral lesions, and two paramedian lesions with two lateral lesions. Lesion pattern may be tailored to the patient's palatal size and thickness; one midline lesion with two lateral lesions seems to provide an acceptable balance between efficacy and morbidity in most patients. The first mark should be placed in the midline 1 cm below the border of the hard palate; the lateral lesions should each be placed approximately 1 cm away from the initial mark, just above the superior pole of the tonsil on either side. Adjacent radiofrequency applications should be placed a minimum of 8 mm apart to avoid lesion overlap and subsequent mucosal damage.
- Inject local anesthetic: Inject approximately 4 cc 1% lidocaine with 1:100,000 epinephrine (or equivalent) among the marked lesion sites. Generous local injection serves to increase interstitial volume and thus decrease the risk of tissue damage.
- Create lesions at marked treatment sites: In an anterior-posterior direction, insert the handpiece needle submucosally into the muscular tissue of the soft palate. The maximum depth of insertion should be 1 cm. The superior surface of the soft palate can be visualized with a flexible scope during lesion generation; any mucosal blanching during ablation indicates that the needle is too deep and should be withdrawn. There are two genres of ablation devices: those that use temperature-controlled RFA and those that employ plasma-mediated ablation (coblation). For the temperature-controlled devices, an energy level of 400 to 700 joules should be used for midline/paramedian lesions; 300 to 350 joules will suffice for lateral lesions, where the palate is typically thinner. The device should be kept at a maximum of 85°C. When using plasma-mediated ablation, 10 to 15 seconds of coblation at a power setting of 6 is appropriate for each lesion.[6]

Operative Risks

- Palatal anatomy should be evaluated critically prior to the procedure. The soft palate is thickest in the midline, and bulk drops off significantly more laterally. The risk of mucosal injury is higher in these lateral areas, especially in the patient whose palate is thin at baseline.

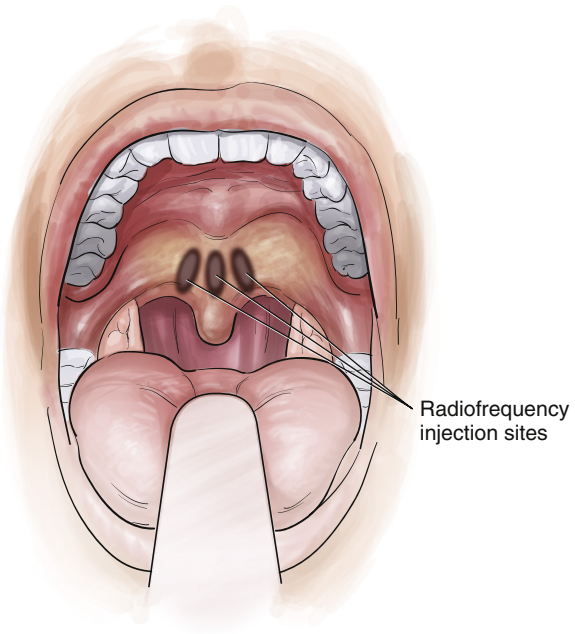

Fig. 51.3. Radiofrequency ablation sites.

Common Errors in Technique

- If RFA delivery sites are not adequately spaced, the surgeon runs the risk of lesion overlap. These areas of overlap may be at higher risk of mucosal injury.
- A lesion site too close to the base of the uvula may lead to uvular necrosis and sloughing.

Palatal (Pillar) Implants

This procedure, which was FDA approved for snoring in 2002, involves the insertion of cylindrical polyethylene terephthalate implants into the soft palate. The implants themselves as well as associated scarring serve to stiffen the soft palate.[7] Each implant is 18 mm in length by 2 mm in diameter. Three to five implants are commonly used.

There are some anatomic preprocedure considerations for patients undergoing palatal implantation. The patient's soft palate should be between 2 and 4 cm in length with a uvula less than 1.5 cm in length. If the palate and/or uvula is too long, palatoplasty and/or partial uvulectomy could be considered. If the soft palate is too short, this tissue may not be able to safely house the implant.[8] Palatal implants may be safely used after prior UPPP or other palatoplasty technique, as long as the patient has residual soft palate at least 2 cm in length and no evidence of nasopharyngeal stenosis.

For anesthesia, positioning, and perioperative antibiotic prophylaxis, see section "Anterior Palatoplasty."

Instruments and Equipment to Have Available

- Commercially available insertion device with implants (Pillar Palatal LLC, Texas)
- Flexible endoscope

Surgical Technique (Fig. 51.4)

- Oral cavity prepped with chlorhexidine mouth rinse
- Mark implant sites: Implants should be inserted just anterior to the hard-soft palate junction and should be placed within the muscular layer of the palate. The first implant

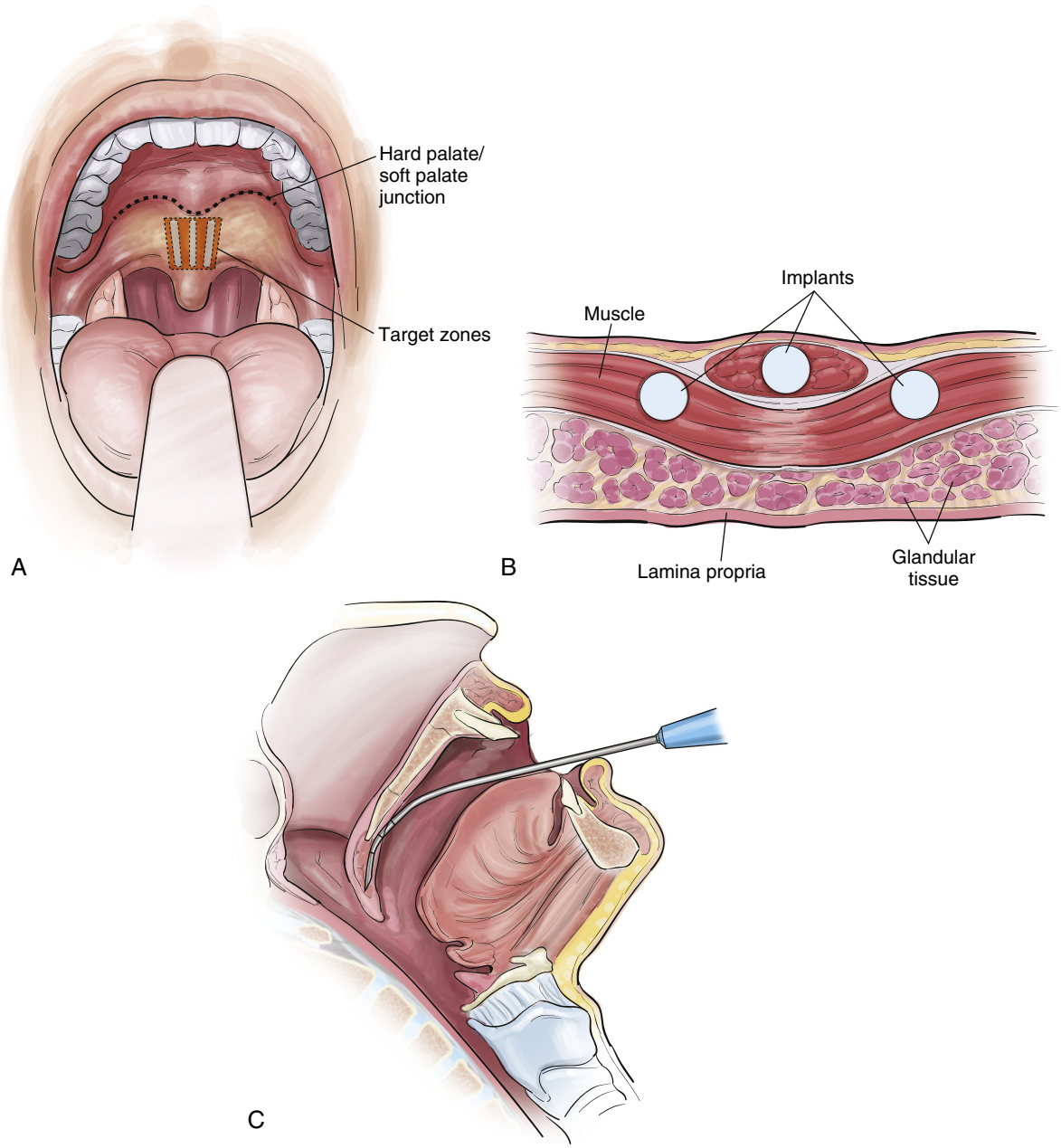

Fig. 51.4. A, Target zone for palatal implants. **B,** Implants within the muscular layer of the soft palate. **C,** Depth markings on the implant handpiece.

should be inserted at the midline. The other two should be inserted approximately 3 mm to the left and right of the initial implant, such that there is approximately 2 mm of space between each implant. More than three implants may be inserted at the discretion of the surgeon. This is mostly dependent on width of the soft palate.

- Inject local anesthetic: Inject approximately 0.5 cc 1% lidocaine with 1:100,000 epinephrine (or equivalent) into each insertion site.
- Insert implants: The handpiece has three markings. Introduce the applicator tip to the third marking in a curvilinear fashion, taking care not to bypass the soft palate. The author prefers to have an assistant look into the nasopharynx with a flexible endoscope at this time to make sure the applicator tip is not visible in the nasopharynx. Withdraw the applicator to the second mark and deploy the implant.
- Confirm placement with a flexible endoscope.

Operative Risks

- If placed in an incorrect trajectory, it is possible to come through the soft palate and enter the nasopharynx with the implant. The surgeon may avoid this by viewing the soft palate from above with a flexible laryngoscope.

Common Errors in Technique

- Prior to deploying the implant, it is also prudent to move the handpiece from side to side to ensure the implant is in the muscular layer.

Injection Snoreplasty

Injection snoreplasty involves the instillation of a sclerosing agent into the midline of the soft palate in order to induce

scarring and stiffening of the tissue. Though this procedure might not offer as much control as RFA or palatal implantation, it is very low cost, technically very simple, and does not require specialized equipment. Various sclerosants have been used in the literature, including a 50:50 mix of 2% lidocaine and 99% dehydrated ethanol, 1% to 3% sodium tetradecyl sulfate, and polidocanol.

For anesthesia, positioning, and perioperative antibiotic prophylaxis, see section "Anterior Palatoplasty."

Instruments and Equipment to Have Available

- Sclerosing agent, approximately 2 mL total
- Twenty-seven gauge needle and syringe for injection

Surgical Technique

- Prep oral cavity with chlorhexidine mouth rinse.
- Apply benzocaine spray (or equivalent topical anesthetic) to the oropharynx.
- Place 2% viscous lidocaine (or equivalent) on the end of a tongue depressor and hold against the central soft palate for 5 to 10 minutes.
- Inject sclerosant: Inject approximately 1.5 to 2 mL of the sclerosant into the soft palate approximately 1 cm above the proximal edge of the soft palate in a submucosal plane. Do not place in the uvula due to the risk of edema of the uvula.
- Watch for appropriate effects: When using sodium tetradecyl sulfate, a clear bulla of fluid is visible immediately after injection. Within about 2 minutes, the area takes on a purple, ecchymotic appearance.[9] If using ethanol, the palate will take on a blanched appearance in the area of injection. Either way, the resulting scar will evolve during the following weeks.
- Consider delayed, repeat injection: If the patient is not experiencing adequate snoring reduction, the surgeon may consider a repeat injection at a minimum of 6 weeks. If repeat injection is to be performed, sclerosant is typically placed just laterally to the initial site of scar; approximately 1 mL of sclerosant is injected on either side (Fig. 51.5).

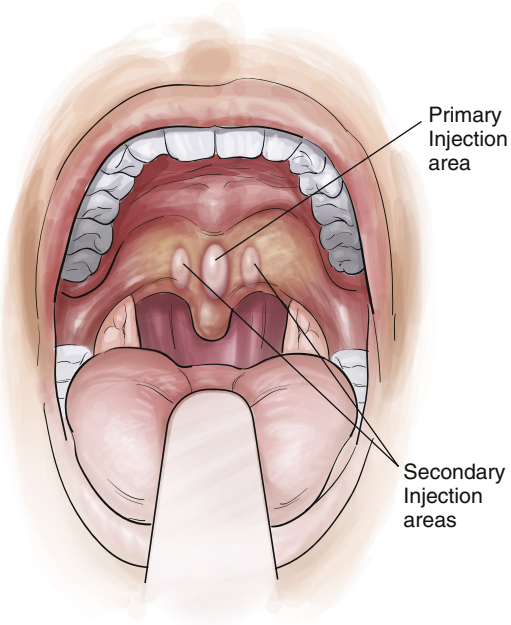

Fig. 51.5. Snoreplasty injection sites.

Operative Risks and Common Errors in Technique

- Similar to RFA, the thin palate is at a higher risk of mucosal breakdown and fistula when undergoing injection snoreplasty. A smaller volume of injection may need to be considered in this situation.

POSTPROCEDURE PERIOD

Postprocedure Management

- Observation: Patients should be observed for 20 to 30 minutes following these office-based upper airway procedures.
- Pain medication: Patients generally do well with 2 to 3 days of OTC analgesics. Anesthetic sprays and/or lozenges may be used as an adjunct. Some patients, including most who undergo anterior palatoplasty, will require narcotic medications.
- Antibiotics: 5 to 7 days of postoperative antibiotics should be prescribed following palatal implantation.
- Steroids: As scar and fibrosis are the desired outcomes for snoring procedures, postprocedure steroids are generally not recommended.
- Diet: Most patients can resume a normal diet postprocedure but may have less discomfort with a soft diet for 24 to 48 hours.

Complications

- Pain: Some discomfort should be expected with all of these procedures and will vary on a patient-to-patient basis. OTC pain medication should be adequate for most patients undergoing palatal implants, RFA, and injection snoreplasty. Of the previously noted procedures, anterior palatoplasty is generally associated with the greatest discomfort; these patients may require narcotics for several days.
- Edema: Mild to moderate soft palate and uvular edema can occur following any of these procedures. This is typically self-limited and does not require treatment, but the patient and surgeon should be aware of this potential complication and its impact on the airway.
- VPI: This is a theoretical risk (although very rare given the lack of excision of the velum) of most of these procedures, which serve to shift, shrink, and stiffen the palate.
- Mucosal blanching and erosion: These minor mucosal changes are commonly seen with RFA of the soft palate and are self-limited; rates have been quoted at 15% to 45%. The mucosal breakdown rate seen with injection snoreplasty is 12.5%.[9]
- Palatal fistula: Palatal fistulas are rarely seen following RFA, palatal implantation, and injection snoreplasty. All reported cases were noted to heal spontaneously, with or without antibiotics.[7] Those with thinner soft palates and/or risk factors for poor wound healing, including diabetes, vascular disease, and cigarette smoking, may be at higher risk and should be counseled as such.
- Palatal implant extrusion: Palatal implants have an extrusion rate of 9.3%.[7] Most of these extruded implants require removal in the office under local anesthesia.
- Infection: Infection is a rare but reported complication of palatal implantation.[7]

Alternative Management Plan

This chapter should serve as a menu of procedures and therapies from which to choose. If a patient fails with a certain procedure in the short or long term, one could always consider oral appliance therapy. As noted previously, these procedures can

often be performed in succession in the appropriate patient. For example, pillar implants may be used to stiffen the palate that has already undergone palatoplasty and/or uvulectomy. Lastly, it should be reiterated that snoring is currently considered medically benign. Thus observation alone is always an option.

DISCUSSION

Evidence-Based Medicine Question

What are the expected outcomes associated with snoring procedures?

In general, it seems that a majority of patients undergoing any of these procedures see some meaningful, short-term decrease in snoring. Both injection snoreplasty and RFA tend to require multiple treatments in order to achieve this benefit. Good, long-term data are relatively lacking; however, the long-term data available indicate that many patients experience a return of snoring symptoms. Additionally, patients with higher BMIs tend to have poorer outcomes.

1. Anterior palatoplasty:
- At about 2.5 years, all patients and sleep partners were noted to be satisfied with snoring results. VAS scores were significantly reduced from a mean of 8.4 preoperatively to 2.5 at 30 months.[5]
- Randomized, placebo controlled studies as well as longer-term studies are lacking.

2. RFA of the soft palate:
- Patients tend to note benefit in the short term.
  - A placebo-controlled trial showed significant reduction in snoring compared to placebo at approximately 2 months.
  - Also at about 2 months, most patients' (79% to 96%, depending on number of lesions) snoring is seen to decrease to levels no longer bothersome to their bed partner. Of note, most of these success stories required multiple treatments.
- Long-term results are variable.
  - A second placebo-controlled trial showed no significant difference in snoring outcomes at 1 year based on the subjective perception of patients' bed partners.[6]
  - Satisfaction rates seem to drop off in the long term. At 3 to 4 years postprocedure, only 25% of patients and bed partners were noted to be satisfied.
- BMI seems to be the main factor influencing treatment results; BMI over 30 is associated with poorer outcomes.[10]

3. Palatal implants:
- Snoring is significantly reduced in the short term compared to placebo.
  - A majority of patients experience at least 50% reduction in snoring VAS scores.
  - At 90 days, 75% of patients and 90% of bed partners recommend this procedure.
- Long-term results are variable; in one study, only 21.7% of patients recommend the procedure at 4 years.
- Responders tend to have lower BMIs and lower Mallampati scores.[8]
- In nonresponders with appropriately sized palates, the surgeon may consider an additional one to two implants, placed just laterally to the initial three.

4. Injection Snoreplasty:
- In the short term, 92% of patients report a significant decrease in snoring. Of note, about two-thirds of patients require more than one injection session, with about 15% requiring three or more to achieve these results.[9]
- Subjective success was noted to drop to 75% at a mean of 19 months; however, most patients (95%) stated that they would still recommend the procedure to others at that point.

Editorial Comment

Snoring most often results from palatal flutter and is a very common sleep-disordered breathing symptom that brings patients and bed partners into the otolaryngist's office. Since positive pressure therapy, custom mandibular repositioning appliances, and more involved surgical procedures are often not covered services in the absence of sleep apnea, minimally invasive procedures for the treatment of nonapneic snoring are potentially very applicable to the large population affected by nonapneic snoring. Palatal stiffening procedures may reduce snoring by reducing palatal flutter with low morbidity and risk. Combination therapy to manage all of the specific anatomic and pathophysiologic factors (e.g., positional therapy, lowering nasal resistance, weight loss) of each nonapneic snoring patient likely improves the outcome of the palatal procedures.

Ryan Soose

Access the review questions and additional sources list online at http://www.expertconsult.com

REFERENCES

1. Stuck BA, Abrams J, de la Chaux R, et al. Diagnosis and treatment of snoring in adults—S1 guideline of the German Society of Otorhinolaryngology, Head and Neck Surgery. Sleep Breath 2010;14:317–321.
2. Marshall NS, Wong K, Cullen S, et al. Snoring is not associated with all-cause mortality, incident cardiovascular disease, or stroke in the Busselton Health Study. Sleep 2012;35(9):1235–1240.
3. Marklund M, Carlberg B, Forsgren L, et al. Oral appliance therapy in patients with daytime sleepiness and snoring or mild to moderate sleep apnea: a randomized clinical trial. J Am Med Assoc Intern Med 2015;175(8):1278–1285.
4. Ramar K, Dort LC, Katz SG, et al. Clinical practice guideline for the treatment of obstructive sleep apnea and snoring with oral appliance therapy: an update for 2015. J Clin Sleep Med 2015;11(7):773–827.
5. Pang KP, Tan R, Puraviappan P, et al. Anterior palatoplasty for the treatment of OSA: three-year results. Otolaryngol Head Neck Surg 2009;141(2):253–356.
6. Holmlund T, Levring-Jaghagen E, Franklin KA, et al. Radiofrequency versus sham surgery of the soft palate on daytime sleepiness. Laryng 2014;124:2422–2426.
7. Choi JH, Kim SN, Cho JH. Efficacy of the pillar implant in the treatment of snoring and mild-to-moderate obstructive sleep apnea: a meta-analysis. Laryngoscope 2013;123(1):269–276.
8. Friedman M, Ramakrishnan V, Bliznikas D, et al. Patient selection and efficacy of pillar implant technique for treatment of snoring and obstructive sleep apnea/hypopnea syndrome. Otolaryngol Head Neck Surg 2006;134(2):187–196.
9. Brietzke SE, Mair EA. Injection snoreplasty: how to treat snoring without all the pain and expense. Otolaryngol Head Neck Surg 2001;124(5):504–510.
10. Back LJ, Hytonen MJ, Ronie RP, et al. Radiofrequency ablation treatment of soft palate for patients with snoring: a systematic review of effectiveness and adverse effects. Laryngoscope 2009;119(6):1241–1250.

REVIEW QUESTIONS

1. Approximately _____% of males and _____% of females are habitual snorers.
   a. 40 and 20
   b. 50 and 50
   c. 25 and 10
   d. 10 and 5

2. Procedures for snoring
   a. Are 100% effective
   b. Should follow a PSG to first rule out more significant OSA
   c. Are equal in effectiveness to OTC products
   d. Have shown no improvement in bed partner satisfaction

3. When considering palatal procedures for snoring
   a. Place pillar implants if palatal length less than 2 cm
   b. Injection snoreplasty works best if soft palate very thin
   c. Anterior palatoplasty can increase the anterior-posterior dimension of the velopharynx
   d. Pillar implants more effective if soft palate very long

ADDITIONAL SOURCES

Brietzke SE, Mair EA. Injection snoreplasty: extended follow-up and new objective data. Otolaryngol Head Neck Surg 2003;128(5):605–615.

Brietzke SE, Mair EA. Injection snoreplasty: investigation of alternative sclerotherapy agents. Otolaryngol Head Neck Surg 2004;130(1): 47–57.

Catalano P, Goh YH, Romanow J. Additional palatal implants for refractory snoring. Otolaryngol Head Neck Surg 2007;137(1):105–109.

Eichler C, Sommer JU, Stuck BA, et al. Does drug-induced sleep endoscopy change the treatment concept of patients with snoring and obstructive sleep apnea? Sleep Breath 2013;17:63–68.

Emery BE, Flexon PB. Radiofrequency volumetric tissue reduction of the soft palate: a new treatment for snoring. Laryng 2000;110(7):1092–1098.

Ferguson M, Smith TL, Zanation AM, et al. Radiofrequency tissue volume reduction: multilesion vs single-lesion for snoring. Arch Otolaryngol Head Neck Surg 2001;127(9):1113–1118.

Friedman M, Schalch P, Lin HC, et al. Palatal implants for the treatment of snoring and obstructive sleep apnea/hypopnea syndrome. Otolaryngol Head Neck Surg 2008;138:209–216.

Hultcrantz E, Harder L, Loord H, et al. Long-term effects of radiofrequency ablation of the soft palate on snoring. Eur Arch Otorhinolaryngol 2010;267:137–142.

Iseri M, Balcioglu O. Radiofrequency versus injection snoreplasty in simple snoring. Otolaryngol Head Neck Surg 2005;133(2):224–228.

Li AM, Au CT, Ho C, et al. Blood pressure is elevated in children with primary snoring. J Pediatr 2009;155(3):362–368.

Kezrian EJ, Powell NB, Riley RW, et al. Incidence of complications in radiofrequency treatment of the upper airway. Laryng 2005;115:1298–1304.

Main C, Liu Z, Welch K, et al. Surgical procedures and non-surgical devices for the management of non-apnoeic snoring: a systematic review of clinical effects and associated treatment costs. Health Technol Assess 2009;13(3):iii, xi-xiv, 1–208.

Mair EA, Day RH. Cautery-assisted palatal stiffening operation. Otolaryngol Head Neck Surg 2000;122(4):547–556.

Maurer JT, Sommer JU, Hein G, et al. Palatal implants in the treatment of obstructive sleep apnea: a randomized, placebo-controlled single-center trial. Eur Arch Otorhinolaryngol 2012;269:1851–1856.

Michaelson PG, Mair EA. Popular snore aids: do they work? Otolaryngol Head Neck Surg 2004;130(6):649–658.

Neruntaraat C. Long-term results of palatal implants for obstructive sleep apnea. Eur Arch Otorhinolaryngol 2011;268:1077–1080.

Pang KP, Terris DJ. Modified cautery-assisted palatal stiffening operation: new method for treating snoring and mild obstructive sleep apnea. Otolaryngol Head Neck Surg 2007;136(5):823–826.

Rich J, Raviv A, Raviv N, et al. An epidemiologic study of snoring and all-cause mortality. Otolaryngol Head Neck Surg 2011;145(2): 341–346.

Romanow JH, Catalano PJ, Initial US. pilot study: palatal implants for the treatment of snoring. Otolaryngol Head Neck Surg 2006;134(4):551–557.

Rotenberg BW, Luu K. Four-year outcomes of palatal implants for primary snoring treatment: a prospective longitudinal study. Laryng 2012;122:696–699.

Savage CR, Steward DL. Snoring: a critical analysis of current treatment modalities. Does anything really work? Curr Opin Otolaryngol Head Neck Surg 2007;15:177–179.

Stuck BA, Sauter A, Hormann K, et al. Radiofrequency surgery of the soft palate in the treatment of snoring: a placebo-controlled trial. Sleep 2005;28(7):847–850.

Troxel WM, Buysse DJ, Matthews KA, et al. Sleep symptoms predict the development of the metabolic syndrome. Sleep 2010;33(12): 1633–1640.

Virk JS, Kumar G, Al-Okati D, et al. Radiofrequency ablation in snoring surgery: local tissue effects and safety measures. Eur Arch Otorhinolaryngol 2014;271:3313–3318.

52 Drug-Induced Sedated Endoscopy

Raj C. Dedhia, David Kent

INTRODUCTION

Obstructive sleep apnea (OSA) is a state-dependent phenomenon in which the pharyngolarynx undergoes repetitive obstruction. For the otolaryngologist, the ability to phenotype the specific site(s), anatomic structures, and patterns involved in the upper airway obstruction appears crucial to successful outcomes.[1]

Upper airway evaluation in a sedated state was first published by Croft and Pringle in 1991.[2] Since that description, drug-induced sedated endoscopy (DISE) has demonstrated moderate-to-substantial inter-rater reliability and discriminant validity between snorers and non-snorers.[3-5] Patients undergoing DISE have been noted to have significantly more severe velopharyngeal and hypopharyngeal collapse than that observed during awake endoscopy with Müller maneuver.[6]

However, there are several important limitations, including a learning curve for the otolaryngologist and anesthesiologist to obtain the optimal plane of sedation, nonnatural sleep, variability in technique and staging systems, and the lack of quantitative measurements.

KEY OPERATIVE LEARNING POINTS

1. Proper technique and depth of sedation are critical to approximate natural sleep.
2. DISE provides an opportunity for dynamic assessment of the airway during a sleep-disordered breathing state and the effect of mandibular repositioning or other interventions.
3. The role of DISE is an adjunctive diagnostic tool to improve surgical decision making and outcomes, rather than a surgical roadmap in isolation.

PREOPERATIVE PERIOD

History

1. History of present illness
   a. Presence of common sleep disorders, such as insomnia and restless legs syndrome. Failure to treat these disorders will result in suboptimal outcomes.
   b. Subjective benefit from previous weight loss, positional therapy, oral appliance, or positive airway pressure (PAP) implicates OSA as driving force behind symptomatology.
   c. In-depth review of most recent diagnostic sleep study with attention to positional or stage-related differences. DISE is considered to largely resemble non-REM rapid eye movement sleep.
2. Past medical history
   a. Prior surgical otolaryngology treatment
   b. Comorbidities associated with OSA: diabetes, hypertension, stroke, myocardial infarction, arrhythmia, depression, obesity
   c. Difficulty with entrance or emergence from anesthesia

Physical Examination

1. Anterior rhinoscopy
   a. Septal deviation, turbinate hypertrophy, and nasal polyps: These structures can create proximal obstruction, thereby increasing negative pressure in the distal pharynx.
2. Facial skeleton evaluation
   a. Significant maxillary or mandibular constriction may require skeletal correction.
3. Neck exam
   a. Inferiorly positioned hyoid bone (greater than two fingerbreadths below mandibular plane) intimates an unfavorably elongated airway; treatment options must be tailored to this phenotype.

Imaging

- None—although DISE findings may be correlated with existing imaging results

Indications

Surgical evaluation for sleep apnea requires synthesis of patient's OSA symptoms, medical history, physical exam (including awake nasolaryngoscopy), sleep study results, patient preference, and patient expectations. If these elements are favorable for surgical treatment, the DISE can be performed as a planning tool either as a standalone procedure or immediately prior to surgical therapy in the operating room. Common indications include:

1. To plan a multilevel upper airway surgical plan in patients who have failed medical device therapy and present with concern for multilevel or multifactorial airway collapsibility
2. To evaluate the upper airway after prior failure of airway reconstructive surgery
3. To evaluate for anatomic candidacy for hypoglossal nerve stimulation therapy. At present, the Inspire hypoglossal nerve stimulator is the only surgical therapy that requires a priori DISE evaluation for candidacy determination. This requirement is related to indication guidelines from the US Food and Drug Administration.
4. At the time of staged or adjunctive nasal surgery, DISE to evaluate the rest of the upper airway anatomy should additional surgical considerations be needed in the future
5. In patients who achieve partial but incomplete results with oral appliance therapy, DISE with and without the oral appliance to evaluate for residual locations of collapse and additional medical or surgical treatment options to further augment the effectiveness of the oral appliance
6. In patients with persistent apnea-hypopnea index elevation or other evidence of airway obstruction despite CPAP (continuous positive airway pressure) use, DISE with and without the CPAP in place to investigate the reasons for CPAP failure, such as epiglottic collapse or iatrogenic airway obstruction due to the interface impact on the jaw and neck position
7. In the pediatric population, to evaluate for persistent OSA after adenotonsillectomy and other first-line therapy. DISE is often preferred to in-office awake laryngoscopy for both patient tolerability and visualization of dynamic collapsibility.

Contraindications

- History of drug allergy to sedating agent
- Pregnancy
- Significant nasal obstruction precluding endoscopic examination

Preoperative Preparation

- No food or drink after midnight because the patient is receiving general anesthesia

OPERATIVE PERIOD

Perioperative Medications

1. Fifteen minutes prior to the procedure, the patient is given 0.2 to 0.4 RCD mg intravenous glycopyrrolate (depending upon ideal body weight) to decrease oronasal secretions.
2. Topical oxymetazoline 0.05% and/or lidocaine 4% solution or 2% jelly are applied unilaterally to the more patent entry nostril.
3. No antibiotic prophylaxis is required.

Positioning

1. At the outset, supine position with one pillow under the head. Positioning changes over the course of the procedure (see "Surgical Technique" later).
2. Do not tuck the arms because this may lead to increased combativeness.
3. Place blow-by oxygen below chin for supplemental oxygen reservoir, if needed, without interfering with scope placement.

Anesthesia

1. Propofol
   a. Most commonly used agent with rapid sedation/emergence profile
   b. Continuous infusion started at 100 to 150 μg/kg/minutes and gradually titrated based on clinical parameters of sedation
   c. Boluses of 100 to 300 μg/kg optionally added as needed depending on surgeon judgment and patient sedation
2. Alternative agents include midazolam and dexmedetomidine.

Monitoring

1. Pulse oximetry
2. Blood pressure cuff
3. Five-lead EKG electrocardiogram monitoring
4. Bispectral index (BIS) monitoring is optional but may serve as a useful adjunct to determine proper depth of sedation. BIS range of 57 to 71 has been reported to correlate with the collapsibility and loss of genioglossus muscle activity seen in OSA.[7]

Instruments and Equipment to Have Available (Figs. 52.1 and 52.2)

1. Laryngoscope tower with audio and video recording capability
2. Flexible laryngoscope (3.5 mm or smaller)
3. Defog solution with sponge
4. Lubricating jelly applied on 4 × 4 gauze
5. Cotton-tipped applicators ×2 covered with 2% lidocaine jelly
6. Standard pillow



Fig. 52.1. Nasal medications, including oxymetazoline and lidocaine jelly with cotton-tipped applicators.



Fig. 52.2. Flexible laryngoscope with lubricating jelly and defog solution.

7. Foam doughnut
8. Body wedge
9. Anesthesia airway equipment (Ambu bag, laryngeal blades, endotracheal tubes)

Key Anatomic Landmarks

1. Velum
   a. Sagittal soft palate configuration (oblique vs. vertical)
   b. Position of and depth behind the maxilla
   c. Position of and depth behind the levator muscle sling or genu
   d. Soft palate length
   e. Degree of lateral velopharyngeal wall component
   f. Presence and degree of adenoid hypertrophy
   g. Pattern of collapse—concentric versus anterior-posterior
2. Oropharyngeal lateral walls
   a. Structure and position of the salpingopharyngeus, palatopharyngeus, palatoglossus, and palatine tonsils
   b. Degree of lateral oropharyngeal wall collapse
3. Tongue
   a. Upper tongue base versus lower/vallecular tongue base collapse
   b. Presence and degree of lingual tonsil hypertrophy
4. Larynx
   a. Epiglottis length, position, and pattern of collapse (anterior-posterior vs. lateral), if present
   b. Presence of other supraglottic collapse (aryepiglottic folds, arytenoids) or other laryngeal lesions



Fig. 52.3. DISE room setup with surgeon on patient *right*, screen for surgeon viewing on patient *left*, anesthesia at head of bed.

5. Jaw position and laxity
6. Nasal airway

Assessment

1. Multiple assessment tools have been proposed, but no single tool has been accepted as standard.
2. VOTE (velum, oropharyngeal lateral walls, tongue, epiglottis)[8]
   a. Most commonly used
3. NOHL (nose, oropharynx, hypopharynx, larynx)[9]
4. DISE index[10]

Prerequisite Skills

1. Flexible laryngoscopy

Operative Risks

1. Mucosal irritation and bleeding: These can be minimized by atraumatic technique and recommended preprocedure Afrin application.
2. Oversedation requiring assisted ventilation and causing central apnea

Surgical Technique

- Setup (Fig. 52.3; see also Figs. 52.1 and 52.2)
- In the procedure room, a single cotton-tipped applicator covered in 2% lidocaine jelly is placed along the floor of the entry nasal passage, approximately halfway back in the nasal cavity. A second cotton-tipped applicator covered in 2% lidocaine jelly is placed between the inferior and middle turbinate, at the same depth. The patient is to remain upright until the cotton-tipped applicators are removed.
  - NOTE: This technique minimizes unwanted anesthesia of the pharynx and contralateral nasal cavity, both of which may cause artificial worsening of OSA and false positives.
- After anesthesia is ready to deliver intravenous medication, the cotton-tipped applicators are removed and the patient is made supine with one pillow to simulate home environment. The room lights are dimmed. If BIS monitoring is used (optional), it should be placed over the forehead at this time.
- The laryngoscope lens is treated with defog solution, and the distal 3 to 5 cm of the shaft (not including the lens) are submerged in lubricating jelly.



Fig. 52.4. Right lateral decubitus positioning.

- Prior to nasal insertion, an image of the patient's wristband should be recorded to ensure correct labeling of patient and DISE exam. The laryngoscope is then inserted transnasally to the level of the proximal soft palate. Intravenous propofol bolus is administered by anesthesia.
  - NOTE: Placement of the laryngoscope prior to administration of sedating agent allows for visualization of the pharyngeal motion leading up to the obstruction ("crash"), as opposed to placing the telescope after obstruction has occurred (arriving "after the crash"). In addition, stimulation from the scope passage can interrupt the steady descent of increasing somnolence.
- The correct depth of sedation is clinically determined as the patient becomes unresponsive to verbal commands and experiences signs of obstructive periodic breathing. At this time, the patient's gown should be lowered to waist level to observe inspiratory effort, as well as paradoxical breathing. Throughout the exam, the scope should alternate between visualization of the palate and tongue base. After the patient has reached an obstructive steady state, notation should be made regarding the degree (percentage obstruction) and configuration of collapse (anterior-posterior, circumferential, lateral) at the soft palate, lateral walls, tongue base, and larynx.
- Evaluate mandibular laxity by viewing the patient's profile.
- Standard maneuvers
  - Ask assistant to place thumbs in mouth (mandibular gingivobuccal sulcus on either side of midline) with fingers outside mouth (below mandible) and protrude mandible 50% to 75% of maximal range, leaving 5 to 10 mm anterior open bite. Maximal range (millimeter) should be obtained in the office examination.
    - Observe both palate and tongue base for minimum of two respiratory cycles during maneuver until dominant collapse pattern is determined.
    - NOTE: Open bite simulates the interincisal gap generated by a standard oral appliance.
  - With use of room staff, roll patient on right side and use body wedge to maintain position (Fig. 52.4).
    - Observe both palate and tongue base for minimum of two respiratory cycles during maneuver until dominant collapse pattern is determined.

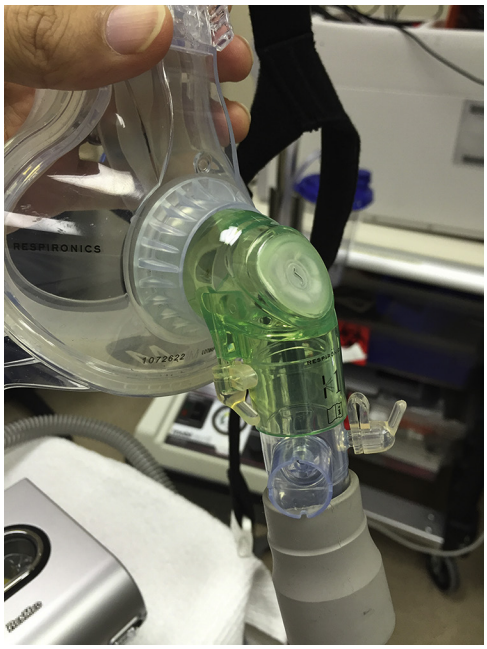

Fig. 52.5. Elbow bronchoscopy/laryngoscopy adapter between PAP mask and tubing.

  - The right side is preferred because the surgeon stands on the right side of patient.
- Exchange pillow for foam doughnut, placing the head in extension.
  - Observe both palate and tongue base for minimum of two respiratory cycles during maneuver, until dominant collapse pattern is determined.
  - This maneuver simulates the cervical pillow, which can be treatment for primary epiglottic obstruction.
- Optional maneuvers
  - If the patient uses an oral appliance, start sleep endoscopy with the oral appliance in place. Remove the appliance and compare airway collapse with and without oral appliance to determine efficacy.
    - Oral appliance may be difficult to seat without patient's aid; therefore it is recommend to start exam with oral appliance in place, and then remove it after patient is sedated.
  - If the patient uses PAP therapy with suboptimal objective or subjective results, ask the patient to bring the PAP machine. The use of a bronchoscopy elbow (Fig. 52.5) with full face mask allows for concurrent DISE with PAP therapy. This should allow for detection of residual obstruction with PAP therapy.
    - Similar to oral appliance, place mask with patient's cooperation while awake to ensure adequate seal. After the sedation steady state is achieved, the mask can be removed for baseline examination.

Common Errors in Technique

- Failure to achieve appropriate plane of anesthesia; oversedation can lead to excessive and even global upper airway collapse, overestimating the severity of patient's anatomic collapse
- Failure to prepare for difficult airway management scenarios
- Failure to perform maneuvers to simulate oral appliance or positional therapy

POSTOPERATIVE PERIOD

Postoperative Management

- Patients should be advised that they had a general anesthesia.
- They are not to drive or make major decisions following the procedure.
- As a result, the surgeon should *not* discuss future treatment plans with the patient on the day of the DISE.
- They may return to normal activity on post-procedure day 1.

Complications

- Minor bleeding from scope trauma
- Loss of airway
  - NOTE: This should be a *never* event. Airway management during the procedure is a joint effort between the otolaryngologist and anesthesia team. In the event of obstructive apneas resulting in significant desaturation, jaw thrust should be performed by the anesthesia provider, with endosopic visualization of the airway until reoxygenation is complete. In the event of prolonged central apnea, mask ventilation and, if required, endotracheal intubation should be performed.

Alternative Management Plan

- Forego DISE and rely on awake clinical examination to develop operative plan.
  - Again, only Inspire hypoglossal nerve stimulator requires a priori DISE evaluation for candidacy determination.

DISCUSSION

Evidence-Based Medicine Question

Does DISE resemble natural sleep?

Two studies have examined stage of sleep during DISE. One study used midazolam and demonstrated the electroencephalogram tracings similar to N1 and N2 sleep; the other study used propofol and illustrated largely N2 and N3 sleep.

Editorial Comment

Successful implementation of second-line therapy for OSA is critically dependent upon accurate determination of the anatomic and physiologic phenotype of each patient. Proper phenotyping of the muscular and skeletal anatomy of the upper airway allows for integration of the individual anatomy into a personalized medical, surgical, or multimodality treatment plan. DISE is simply one common, widespread, low-risk method available to facilitate this treatment planning. With proper technique and clinical application, DISE provides the sleep surgery specialist with key information on the anatomic structures, locations, and patterns of collapse under conditions that more closely resemble sleep rather than wakefulness. Further studies are needed to standardize technique and descriptive staging systems as well as to demonstrate whether DISE changes OSA outcomes.

Ryan Soose

Access the review questions and additional sources list online at http://www.expertconsult.com

REFERENCES

1. Sher AE, Schechtman KB, Piccirillo JF. The efficacy of surgical modifications of the upper airway in adults with obstructive sleep apnea syndrome. Sleep 1996;19(2):156–177.
2. Croft CB, Pringle M. Sleep nasendoscopy: a technique of assessment in snoring and obstructive sleep apnoea. Clin Otolaryngol Allied Sci 1991;16(5):504–509.
3. Kezirian EJ, White DP, Malhotra A, et al. Interrater reliability of drug-induced sleep endoscopy. Arch Otolaryngol Head Neck Surg 2010;136(4):393–397.
4. Berry S, Roblin G, Williams A, et al. Validity of sleep nasendoscopy in the investigation of sleep related breathing disorders. The Laryngoscope 2005;115(3):538–540.
5. Rodriguez-Bruno K, Goldberg AN, McCulloch CE, et al. Test-retest reliability of drug-induced sleep endoscopy. Otolaryngol Head Neck Surg 2009;140(5):646–651.
6. Cavaliere M, Russo F, Iemma M. Awake versus drug-induced sleep endoscopy: evaluation of airway obstruction in obstructive sleep apnea/hypopnoea syndrome. Laryngoscope 2013;123(9):2315–2318.
7. Lo YL, Ni YL, Wang TY, et al. Bispectral index in evaluating effects of sedation depth on drug-induced sleep endoscopy. J Clin Sleep Med 2015;11(9):1011–1020.
8. Kezirian EJ, Hohenhorst W, de Vries N. Drug-induced sleep endoscopy: the VOTE classification. Eur Arch Otorhinolaryngol 2011;268(8):1233–1236.
9. Vicini C, De Vito A, Benazzo M, et al. The nose oropharynx hypopharynx and larynx (NOHL) classification: a new system of diagnostic standardized examination for OSAHS patients. Eur Arch Otorhinolaryngol 2012;269(4):1297–1300.
10. Gillespie MB, Reddy RP, White DR, et al. A trial of drug-induced sleep endoscopy in the surgical management of sleep-disordered breathing. Laryngoscope 2013;123(1):277–282.

REVIEW QUESTIONS

1. If bispectral index (BIS) monitoring is used, what is the target level?
   a. 10 to 30
   b. 30 to 50
   c. 50 to 70
   d. 70 to 90

2. Which medication(s) should be given preoperatively?
   a. Glycopyrrolate
   b. Oxymetazoline and cetacaine spray
   c. Glycopyrrolate and oxymetazoline
   d. Glycopyrrolate, oxymetazoline, and Unasyn

3. To determine benefit of oral appliance, the mandible should be advanced what percentage of maximal range?
   a. 20%
   b. 40%
   c. 60%
   d. 100%

ADDITIONAL SOURCES

Carrasco Llatas M, Agostini Porras G, Cuesta Gonzalez MT, et al. Drug-induced sleep endoscopy: a two drug comparison and simultaneous polysomnography. Eur Arch Otorhinolaryngol 2014;271(1): 181–187.

Horner RL, Innes JA, Holden HB, et al. Afferent pathway(s) for pharyngeal dilator reflex to negative pressure in man: a study using upper airway anaesthesia. J Physiol 1991;436:31–44.

Rabelo FA, Braga A, Kupper DS, et al. Propofol-induced sleep: polysomnographic evaluation of patients with obstructive sleep apnea and controls. Otolaryngol Head Neck Surg 2010;142(2):218–224.

White DP, Cadieux RJ, Lombard RM, et al. The effects of nasal anesthesia on breathing during sleep. Am Rev Respir Dis 1985;132(5):972–975.

53 Uvulopalatopharyngoplasty and Related Modifications (Traditional Uvulopalatopharyngoplasty, Uvulopalatal Flap, Anterior Palatoplasty)

David Kent, Amy Schell

INTRODUCTION

Obstructive sleep apnea (OSA) is a dynamic collapse and obstruction of the upper airway occurring in sleep due to decreased upper airway neuromuscular activity. At least 13% of men and 6% of women aged 30 to 70 years in the United States have moderate-to-severe OSA (apnea-hypopnea index [AHI] ≥ 15/hour), and at least half of this population are likely to be intolerant of the first-line therapy, continuous positive airway pressure (CPAP).[1-3]

The traditional uvulopalatopharyngoplasty (UPPP) was developed by Fujita in 1981.[4] Despite numerous modifications, it remains the most commonly performed surgical intervention for snoring and OSA. Between 2000 and 2006 UPPP and its related modifications accounted for more than 80% of the surgeries performed for OSA in the United States.[5] UPPP has been demonstrated to significantly improve subjective OSA outcome measures and AHI in appropriately selected CPAP-intolerant patients.[6] Several UPPP modifications have been developed to target palatal anatomy variations and clinical scenarios, including the uvulopalatal flap (UPF) and anterior palatoplasty (AP).[7] More advanced palatal surgery modifications are discussed separately in Chapter 54.

KEY OPERATIVE LEARNING POINTS

- Careful patient selection and anatomic phenotyping are key to successful functional outcomes with UPPP, UPF, and AP.
- The patients most likely to benefit from a UPPP as primary therapy are those with a type I or II Friedman clinical stage.
- The UPF should be reserved for the patient with a thin and relatively atrophic soft palate.
- AP may be performed under local or general anesthesia.
- Transient velopharyngeal insufficiency is common and generally resolves spontaneously.
- Consider drug-induced sleep endoscopy (DISE) to help to guide surgical decision making.
- Many OSA patients benefit from a combination of surgical and medical therapies; upper airway surgery can improve CPAP treatment results and adherence.

PREOPERATIVE PERIOD

Patients with sleep-disordered breathing may present to the otolaryngologist with a wide variety of subjective and objective concerns, including: loud, disruptive snoring; daytime hypersomnolence; poor sleep quality; impaired quality of life; increased risk of motor vehicle accidents; and cardiovascular disease. As part of the initial evaluation, OSA patients undergo overnight diagnostic sleep testing either in the home via home sleep test (HST) or via in-lab polysomnography (PSG) to document OSA severity and to differentiate OSA from central sleep apnea, sleep-related hypoventilation, nonapneic snoring, or other sleep medicine pathology.

Patients diagnosed with moderate-to-severe OSA should undergo a trial of CPAP before surgical management in considered. A large body of evidence has shown that CPAP is highly effective in reducing OSA-associated morbidity and mortality. However, approximately 50% of patients are unable to adhere to long-term therapy. Each patient's experience with CPAP and the reasons for intolerance should be carefully reviewed for potential targeted intervention. Alternative positive pressure modalities may be helpful for patients having trouble tolerating CPAP. For others with complaints of nasal obstruction, nasal airway surgery may decrease the amount of positive airway pressure required, improving acceptance of CPAP.

Nonsurgical interventions for OSA include weight loss, behavioral modification, mandibular repositioning devices (MRDs) and other oral appliances, or positional therapy aids.[8] Positional therapy aids assist patients with maintaining lateral positioning during sleep and are most effective for patients with a clinically significant reduction in AHI in the lateral position. An MRD can be an effective alternative to CPAP in select patients and is an acceptable initial alternative to trial in patients with mild OSA. However, approximately half of patients will have persistent subjective symptoms or residual OSA during repeat testing. Patients should also be counseled that MRDs may eventually cause undesired occlusal changes.

The heterogeneous clinical presentations of snoring and OSA are further complicated by the large variety of pharyngeal collapse patterns. Comprehensive awake physical examination remains the most used tool in the diagnostic workup. Patients with significant skeletal abnormalities may be best served by maxillomandibular interventions. The patients most likely to benefit from a UPPP are those with a type I Friedman clinical stage (3 to 4+ tonsils, modified Mallampati score I or II) and a body mass index (BMI) less than 40.[9] Flexible nasopharyngoscopy should be used to visualize the base of the tongue and epiglottis. Because multilevel collapse is common and many patients do not have a clear site and pattern of pharyngeal obstruction during awake examination, DISE may provide a useful diagnostic tool to better characterize that anatomic location and pattern of obstruction and to better predict appropriate surgical therapy (see Chapter 52). CPAP-intolerant patients with multiple sites of upper airway obstruction may require combination medical and surgical therapy, multiple surgical procedures, or craniofacial modification.

UPPP is the most aggressive and excisional of the procedures described herein, followed by UPF and then AP. Although UPPP may benefit patients with more severe OSA, current evidence supports reserving UPF and AP for patients with mild-to-moderate OSA or nonapneic palatal snoring. UPF is most likely to be successful when used in patients with a thin, relatively atrophic soft palate with a significant vertical length. Folding the posterior, vertical component anteriorly alleviates airway obstruction. However, this

maneuver can create significant anterior soft palate bulk that is bothersome to the patient with a more robust soft palate. AP advances the entire soft palate structure anteriorly and is likely most effective in the patient with a shorter vertical palatal length. It can be performed under local anesthesia in appropriate patients.

All patients undergoing UPPP, UPF, or AP should be counseled that transient hypernasal speech or nasal regurgitation due to velopharyngeal insufficiency is not uncommon in the immediate postoperative period and almost always resolves spontaneously. Patients with significant OSA should also be counseled that postoperative sleep testing is recommended to assess for residual OSA, regardless of residual snoring symptoms. Those with significant residual OSA may find that surgery has improved their results and adherence with CPAP or MRD therapy.

History

1. History of present illness
   a. Nighttime symptoms
      1) Snoring (intensity, fluctuation with changes in weight/body position)
      2) Witnessed apneas
      3) Sleep maintenance insomnia or nocturia
   b. Daytime symptoms
      1) Sleepiness or fatigue
      2) Morning headaches
      3) Neurocognitive symptoms (e.g., memory loss, concentration difficulty, mood disturbance
   c. Nasal obstruction (daytime, nighttime, positional)
   d. Previous evaluation and diagnosis
      1) Prior diagnostic PSG or HST studies
      2) Prior CPAP titration studies
   e. Comorbid sleep disorders
      1) Other sleep-related breathing disorders (e.g., central sleep apnea, sleep-related hypoventilation due to pulmonary disease)
      2) Movement disorders (e.g., restless leg syndrome, periodic limb movement disorder)
      3) Circadian rhythm disorders
      4) Insomnias
      5) Parasomnias
   f. Prior treatment
      1) CPAP
      2) MRD
      3) Positional therapy
      4) Weight loss
2. Past medical history
   a. Hypertension, cardiovascular disease, stroke, functional status
   b. Endocrine disorders (e.g., diabetes, hypothyroidism)
   c. Prior head and neck surgery (for OSA or other indications)
   d. Prior head and neck radiation exposure
   e. History of cleft palate or velopharyngeal insufficiency
3. Family history of OSA
4. Medications
   a. Anticoagulants
   b. Alcohol
   c. Hypnotics
   d. Narcotics
   e. Allergies to antibiotics
5. Smoking history
6. Mental and social status
   a. Sleep-related quality of life
   b. Impact on bed partner
   c. Employment status (high-risk employment requiring optimal alertness)

Physical Examination

1. Body habitus, including BMI
2. Anterior rhinoscopy
   a. Septal deviation
   b. Turbinate hypertrophy
   c. Other sources of nasal airway obstruction (e.g., external/internal nasal valve compromise, nasal polyposis)
3. Facial skeleton evaluation
   a. Mandibular hypoplasia
   b. Maxillary deficiency
4. Neck evaluation
   a. Thyromental angle and hyoid position
   b. Neck circumference
5. Oral cavity and oropharyngeal evaluation
   a. Dentition
   b. Occlusion
   c. Palate width, thickness, and vertical length
   d. Modified Mallampati score
   e. Tonsil size, evidence of prior tonsillectomy or other upper airway surgery
   f. Lateral oropharyngeal wall (palatopharyngeus) component
6. Flexible nasopharyngoscopy (awake supine or DISE)
   a. Structural nasal airway obstruction
   b. Soft palate sagittal configuration (oblique vs. vertical) and length
   c. Tonsil and lateral oropharyngeal wall component
   d. Degree and pattern of collapse of the base of the tongue including lingual tonsillar hypertrophy
   e. Epiglottic collapse or other laryngeal pathology
   f. Impact of mandibular repositioning on retropalatal space

Imaging and Testing

1. Have prior PSG data available for review.
2. Consider DISE if the site(s) of obstruction are questionable.

Indications

1. OSA without significant central sleep apnea in the setting of CPAP intolerance
2. Upper airway resistance syndrome (significant sleep-disordered breathing symptoms and respiratory-related arousals on PSG in the absence of elevated AHI)
3. Selected cases of nonapneic snoring

Contraindications

1. Medically unstable
2. History of velopharyngeal insufficiency
3. History of cleft palate
4. History of pharyngeal malignancy or radiation therapy

Preoperative Preparation

1. Discontinue anticoagulant drugs if possible.
2. Other routine preparation for general anesthesia

OPERATIVE PERIOD

Anesthesia

- Nasotracheal intubation is not required.
- An oral RAE or armored endotracheal tube may help to reduce compression of the endotracheal tube by a McIvor mouth gag but is not required.

- The surgeon should always stand by during induction of anesthesia because OSA patients are frequently difficult to intubate.

Positioning

- Rotate the table either 90 or 180 degrees to allow the surgeon adequate working space at the head of the bed.
- The patient is placed in the supine position with a shoulder roll for neck extension.
- AP under local anesthesia may be completed with the patient sitting upright in the sniffing position.

Perioperative Antibiotic Prophylaxis

- Clean contaminated surgery
- Antibiotics are administered during induction of anesthesia and continued for 24 hours.
- Choices
  - Penicillin and β-lactamase (e.g., ampicillin/sulbactam)
  - Clindamycin
  - Amoxicillin-clavulanate
  - Cephalosporin and metronidazole

Monitoring

- Routine anesthesia monitoring
- Patient should remain paralyzed during surgery to facilitate mandibular relaxation and optimal oropharyngeal exposure

Instruments and Equipment to Have Available

- Monopolar and bipolar or suction electrocautery with protected tips
- Standard tonsillectomy set

Key Anatomic Landmarks

- Palate
  - Junction of the hard palate and soft palate
  - Genu of the soft palate (levator muscle sling)
  - Velum
  - Uvula
- Lateral pharyngeal wall
  - Palatine tonsils
  - Superior constrictor muscle
  - Palatoglossus and palatopharyngeus muscles

Prerequisite Skills

- Tonsillectomy

Surgical Technique

- UPPP
  - Remove the tonsils bilaterally, being careful not to violate the superior constrictor muscle and working to preserve the palatoglossus (anterior tonsillar pillar) and palatopharyngeus (posterior tonsillar pillar) muscles, as well as their overlying mucosa.
  - Adenoidectomy is not recommended to be simultaneously performed with traditional UPPP, due to increased risk for pharyngeal stenosis.
  - Local injection along the intended lines of dissection with 1% lidocaine with 1:100,000 epinephrine reduces intraoperative bleeding and immediate postoperative pain.
  - Begin dissection at the anterior tonsillar pillar and proceed superiorly in the sagittal plane to the intended coronal incision, approximately 8 to 10 mm anterior to the posterior edge of the soft palate.
    - Cold dissection and hemostasis using conservative bipolar electrocautery may reduce thermal injury and subsequent postoperative pain.
    - The coronal dissection line should be posterior to the natural genu of the soft palate to decrease the risk of velopharyngeal insufficiency.
  - A 90-degree angle between the coronal and sagittal incisions is favorable because a rounded transition may result in a purse-string contracture of the resulting scar (Fig. 53.1).
  - Complete the incisions through the palate, resecting the posterior section of the palate and the uvula.
  - Suture the anterior and posterior tonsillar pillars bilaterally to close the tonsillar fossa.
    - Vicryl or Monocryl sutures are favored for their durability due to the significant muscle forces generated during swallowing.
  - Approximate and suture the coronal incision mucosa in a similar fashion (Fig. 53.2).
- UPF
  - Remove the tonsils bilaterally, being careful not to violate the superior constrictor muscle and working to preserve the palatoglossus (anterior tonsillar pillar) and palatopharyngeus (posterior tonsillar pillar) muscles, as well as their overlying mucosa.
  - Gently fold the distal tip of the muscular uvula anteriorly to identify the anterior-most extent of oropharyngeal mucosa dissection; note the natural S-shaped curve of the posterior palatal edge as it courses across the oropharyngeal mucosa.
    - Applying excessive tension to the folded palate during incision planning increases the risk of postoperative wound dehiscence.
  - Generous injection in the intended areas of dissection with 1% lidocaine with 1:100,000 epinephrine reduces

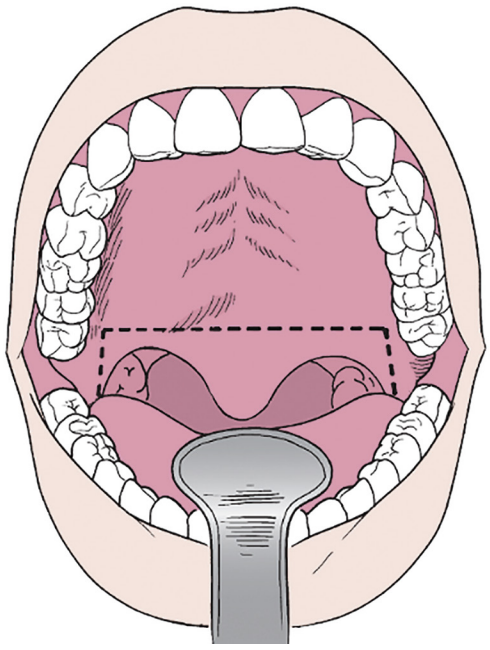

Fig. 53.1. Proposed incision line for traditional uvulopalatopharyngoplasty posterior to the soft palate genu.

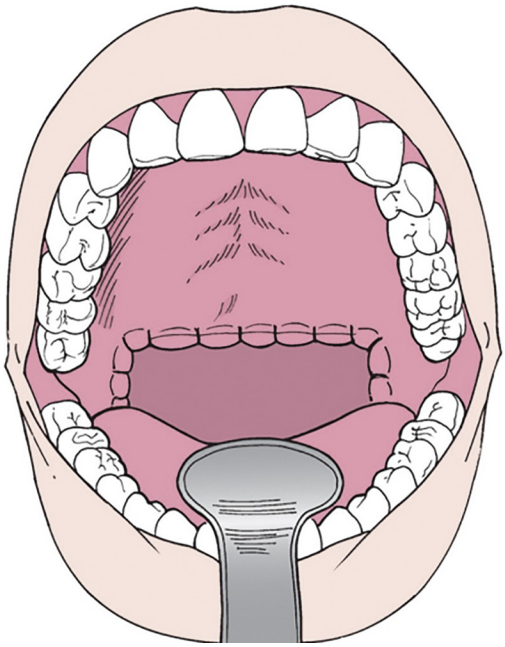

Fig. 53.2. Maintain a right angle between the coronal and sagittal closure to optimize lateral oropharyngeal dimension during wound healing.

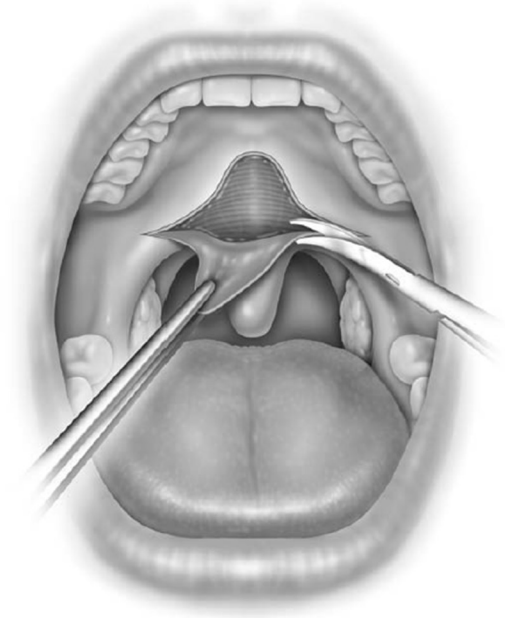

Fig. 53.3. Elevation of the uvulopalatal flap from the underlying palatal muscle. *(From Friedman M [ed]: Sleep Apnea and Snoring: Surgical and Non-Surgical Therapy, 1st ed. Philadelphia, PA: Elsevier; 2009, p 208 [Fig. 53.2].)*

intraoperative bleeding and immediate postoperative pain.
  - Allow several minutes for epinephrine to achieve maximal effect.
- Incise the oropharyngeal mucosa along the planned lines of incision from the anterior-most point of dissection to the posterior edge of the soft palate bilaterally.

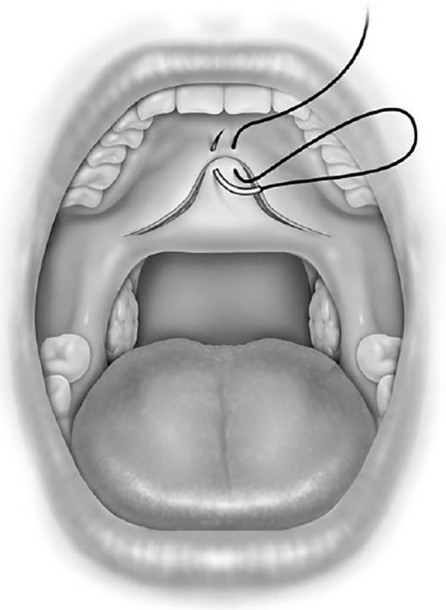

Fig. 53.4. Suturing of the uvulopalatal flap after folding the dorsal mucosa and flap anteriorly. *(From Friedman M [ed]: Sleep Apnea and Snoring: Surgical and Non-Surgical Therapy, 1st ed. Philadelphia, PA: Elsevier, 2009; p 209 [Fig. 53.3].)*

  - Cold dissection and hemostasis using conservative bipolar electrocautery help to minimize postoperative pain.
- Beginning at the anterior-most point of dissection, create a stellate-shaped mucosal defect by resecting the oropharyngeal mucosa from the underlying palatal musculature posteriorly until the posterior edge of the soft palate and the distal tip of the muscular uvula are exposed (Fig. 53.3).
  - Include redundant uvular mucosa distal to the musculus uvulae in the resection.
- Fold the distal tip of the uvula anteriorly and suture the nasopharyngeal mucosa of the uvular tip to the anterior-most point of dissection.
  - Vicryl or Monocryl sutures are favored for their durability due to the significant muscle forces generated during swallowing.
- Approximate and suture the remaining lines of dissection (Figs. 53.4 and 53.5).

- AP
  - Remove the tonsils bilaterally, being careful not to violate the superior constrictor muscle and working to preserve the palatoglossus (anterior tonsillar pillar) and palatopharyngeus (posterior tonsillar pillar) muscles, as well as their overlying mucosa.
    - Consider local anesthesia only if the patient has had a prior tonsillectomy or if the tonsils are very small (1+).
  - Generous injection of the intended dissection areas with 1% lidocaine with 1:100,000 epinephrine reduces procedural bleeding and pain.
    - Allow several minutes for epinephrine to achieve maximal effect.
  - A uvulectomy or partial uvulectomy may be performed, depending on the individual patient's anatomy.
    - Cold dissection and hemostasis using conservative bipolar electrocautery help to minimize postoperative pain.
  - If significant mucosal webbing between the posterior tonsillar pillars and the posterior pharyngeal wall is present,

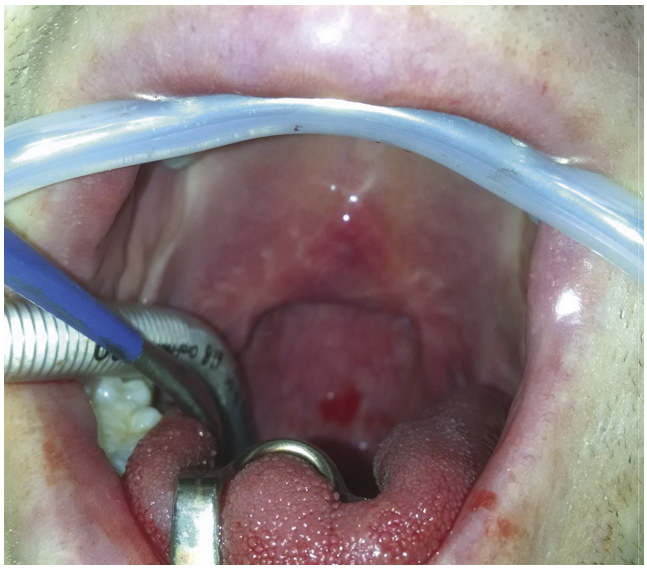

Fig. 53.5. Postoperative appearance of the uvulopalatal flap.

bilateral parauvular incisions in the sagittal plane may reduce tethering of the soft palate after advancement.
- Excise an approximately 1 × 4 cm^2 rectangle of mucosa from the soft palate immediately posterior to the insertion into the hard palate.
- After obtaining hemostasis, approximate and suture the anterior and posterior wound edges.
  - Vicryl or Monocryl sutures are favored for their durability due to the significant muscle forces generated during swallowing.

Common Errors in Technique

- UPPP
  - Rounding off the intersection of the coronal and sagittal palatal incisions may result in a purse-string contracture of the palatal scar and further aggravation of OSA.
  - Resection of soft palate tissue anterior to the natural palatal genu increases the risk of postoperative velopharyngeal insufficiency.
- UPF
  - Application in patients with robust palatal musculature may result in irritating palatal bulk postoperatively.
  - Excessive tension during wound closure increases the risk of wound dehiscence.
- AP
  - Failure to incise significant posterior tonsillar pillar webbing may reduce the effectiveness of palatal advancement.

POSTOPERATIVE PERIOD

- Antibiotics for 24 hours
- Patients with moderate-to-severe OSA undergoing upper airway surgery are often monitored overnight for airway observation and pulse oximetry.
- Patients using CPAP or MRD at the time of surgery maybe able to wear the medical device in the postoperative period to reduce perioperative respiratory risk.
- Diet
  - A soft diet for 10 to 14 days after surgery is recommended.
  - Monitor for adequate nutritional and fluid intake in the immediate postoperative period before hospital discharge.
- Monitor for adequate pain control using oral narcotic and acetaminophen medications before hospital discharge.
- Monitor viability of wound closure.

COMPLICATIONS

- Edema and airway obstruction
  - Monitor patients with moderate-to-severe OSA undergoing upper airway surgery in the immediate postoperative period.
- Narcotic respiratory suppression
  - Titrate narcotic therapy during inpatient observation to the minimal dose required for adequate pain control.
- Dehydration and poor nutritional intake
  - Monitor for adequate oral intake during inpatient observation and adequately control pain.
- UPF wound dehiscence
  - Débride UPF dehiscence to avoid further damage and airway obstruction.
- Velopharyngeal insufficiency/nasopharyngeal regurgitation
  - Typically self-limited but may benefit from speech or swallowing therapy in rare instances
- Nasopharyngeal stenosis
  - Rare but potentially debilitating complication of traditional UPPP. Best approach is *prevention* by avoiding concomitant adenoidectomy and by maximal mucosal preservation of the posterior pillars

DISCUSSION

Evidence-Based Medicine Question

Is UPPP effective (AHI <20 and decreased 50% from preoperatively) in isolation in patients with a Friedman clinical stage III examination?

A 2002 study of 134 patients undergoing UPPP found that Friedman clinical stage I patients had a surgical success rate of 80.6%, whereas stage II patients had a surgical success rate of 37.9% and stage III patients had a success rate of only 8.1%.[8]

Editorial Comment

UPPP has served as the cornerstone of surgical therapy for patients who fail medical treatment for OSA since the 1980s. UPPP and related modifications have substantial data on improving OSA symptoms and quality of life measures, as well as reducing the severity of the disease and associated health risks. A complete sleep medicine evaluation, thorough examination of the upper airway with proper patient selection and phenotyping, and meticulous surgical technique are all keys to successful implementation of UPPP. UPPP technique continues to evolve with increased focus on reconstruction (rather than excision) and modifications that can be tailored to the anatomy of each individual patient to further improve results and reduce morbidity.

Ryan Soose

Access the review questions online at http://www.expertconsult.com

REFERENCES

1. Young T, Finn L, Peppard PE, et al. Sleep disordered breathing and mortality: eighteen-year follow-up of the Wisconsin sleep cohort. Sleep 2008;31(8):1071–1078.
2. Rosen CL, Auckley D, Benca R, et al. A multisite randomized trial of portable sleep studies and positive airway pressure autotitration versus laboratory-based polysomnography for the diagnosis and treatment of obstructive sleep apnea: the HomePAP study. Sleep 2012;35(6):757–767.

3. Kushida CA, Nichols DA, Holmes TH, et al. Effects of continuous positive airway pressure on neurocognitive function in obstructive sleep apnea patients: the Apnea Positive Pressure Long-term Efficacy Study (APPLES). Sleep 2012;35(12):1593–1602.
4. Fujita S, Conway W, Zorick F, et al. Surgical correction of anatomic abnormalities in obstructive sleep apnea syndrome: uvulopalatopharyngoplasty. Otolaryngol Head Neck Surg 1981;89(6):923–934.
5. Kezirian EJ, Maselli J, Vittinghoff E, et al. Obstructive sleep apnea surgery practice patterns in the United States: 2000 to 2006. Otolaryngol Head Neck Surg 2010;143(3):441–447.
6. Browaldh N, Nerfeldt P, Lysdahl M, et al. SKUP3 randomised controlled trial: polysomnographic results after uvulopalatopharyngoplasty in selected patients with obstructive sleep apnoea. Thorax 2013;68(9):846–853.
7. Pang KP, Tan R, Puraviappan P, et al. Anterior palatoplasty for the treatment of OSA: three-year results. Otolaryngol Head Neck Surg 2009;141(2):253–256.
8. Marklund M, Verbraecken J, Randerath W. Non-CPAP therapies in obstructive sleep apnoea: mandibular advancement device therapy. Eur Respir J 2012;39(5):1241–1247.
9. Friedman M, Ibrahim H, Bass L. Clinical staging for sleep-disordered breathing. Otolaryngol Head Neck Surg 2002;127(1):13–21.

REVIEW QUESTIONS

1. What is a component of the traditional UPPP?
   a. Adenoidectomy
   b. Excision of the posterior tonsillar pillars bilaterally
   c. Avoiding suture closure of the anterior and posterior tonsillar pillars
   d. Join the coronal and sagittal incisions at a 90-degree angle

2. UPF is most appropriate for what anatomic findings?
   a. Thick, robust soft palate
   b. Modified Mallampati type IV
   c. A thin soft palate with little muscle bulk
   d. Short vertical soft palate length

3. Which patient is the best candidate for anterior palatoplasty?
   a. A 74-year-old male with AHI-7, modified Mallampati class II, loud snoring, associated daytime sleepiness, failure of medical therapy, and BMI of 26
   b. A 34-year-old female with AHI-29, CPAP intolerance, modified Mallampati class III, and BMI of 37
   c. A 62-year-old male with AHI-14, failure of medical device therapy, a low and anteriorly displaced hyoid, modified Mallampati class IV, and BMI of 23
   d. A 19-year-old female with AHI-21, central apnea index of 15, daytime sleepiness, idiopathic pulmonary hypertension, and BMI of 25

54 Advanced Palatal Surgery: Expansion Sphincter Pharyngoplasty & Transpalatal Advancement Pharyngoplasty

Raj C. Dedhia, Ryan Soose

INTRODUCTION

Obstructive sleep apnea (OSA) is a state-dependent phenomenon in which the pharyngolarynx undergoes repetitive collapse. Retropalatal obstruction is often the primary site of sleep-disordered breathing. Traditional uvulopalatopharyngoplasty (UPPP) as described by Fujita has important potential limitations, including nonphysiologic modification, residual proximal palatal obstruction, and risk of nasopharyngeal stenosis and velopharyngeal insufficiency. The two techniques discussed in this chapter, expansion sphincter pharyngoplasty (ESP) and transpalatal advancement (TPA), represent advanced palatal surgery modifications that use more reconstructive (rather than excisional) methods to improve effectiveness and reduce morbidity over traditional UPPP.[1]

ESP is the reverse of sphincter pharyngoplasty, which is used to address velopharyngeal incompetence. In ESP, the palatopharyngeus (posterior pillar) is transected inferiorly and the muscle pedicle is rotated anteriorly, superior, and laterally to enlarge the lateral velopharyngeal dimension. Although it bears similarity to UPPP in its effect on the distal palate, it avoids potential untoward consequences of UPPP, such as nasopharyngeal stenosis and globus sensation (at least in part by maximal mucosal and uvular preservation).

TPA is designed to address proximal palatal obstruction, especially for those patients with a vertically oriented soft palate and maxillary deficiency (Fig. 54.1). TPA removes a segment of hard palate and advances the soft palate anteriorly to increase the distance between the posterior nasal spine and posterior pharyngeal wall.

KEY OPERATIVE LEARNING POINTS

- Anatomic phenotyping with drug-induced sedation endoscopy (DISE) or other imaging or endoscopic techniques is essential for proper patient and procedure selection.
- ESP is ideally suited for a more obliquely or horizontally oriented soft palate with a large lateral oropharyngeal wall component and a circumferential pattern of collapse at the velum.
- TPA is ideally suited for a more vertically oriented soft palate with maxillary retrusion and anterior-posterior pattern of soft palate collapse at the genu and velum.
- Maximal mucosal preservation is key to preserving the largest potential velopharyngeal airway, as well as to maintaining the physiologic function of the palate and reducing morbidity.
- To minimize flap dehiscence in ESP, ensure that the suspension suture passed through the muscle belly contains fascia and that the anchor suture passed near the hamulus contains aponeurosis of the tensor tendon and/or buccopharyngeal raphe.
- To minimize risk of oronasal fistula in TPA, include hearty palatal aponeurosis in the suture around the bony keel segment.

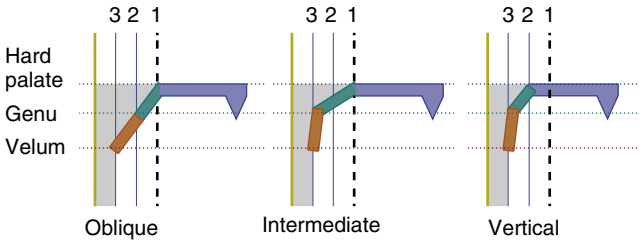

Fig. 54.1. Sagittal configuration of the soft palate. Key components include the posterior aspect of the hard palate, the insertion point of the levator veli palatini ("genu"), and velum. The size, shape, and position of these anatomic structures are integrated into palatal surgery decision making. *(Reproduced with permission from Woodson BT, Sitton M, Jacobowitz O: Expansion sphincter pharyngoplasty and palatal advancement pharyngoplasty: airway evaluation and surgical techniques. Oper Tech Otolaryngol 23:3-10, 2012.)*

PREOPERATIVE PERIOD

A comprehensive sleep medicine history is the critical first step before considering surgical therapy for any OSA patient. Approximately one-third of OSA patients have been reported to have another primary sleep disorder or sleep-modulating medical comorbidities, such as psychophysiologic insomnia, chronic pain, shift work sleep disorder, restless legs syndrome, or narcolepsy. Medications that negatively affect control of breathing (e.g., opiates or benzodiazepines), or alter sleep architecture or continuity directly (e.g., antidepressants), must also be taken in account in evaluating a patient's candidacy.

Because surgery is most commonly a second-line or alternative treatment strategy, it is also important to thoroughly evaluate and exhaust first-line medical therapy options. For patients who are unable to tolerate or achieve benefit with positive airway pressure (PAP) therapy, a detailed analysis of the PAP data download software and troubleshooting of specific PAP side effects remain important strategies prior to surgery. Many of the common mask-related, pressure-related, and psychosocial side effects of PAP can be overcome with therapy or equipment adjustments, behavioral modifications, positional therapy, or other conservative interventions. Furthermore, in patients with symptomatic nasal obstruction or chronic sinonasal disease, medical or surgical therapy of the nose can provide a pathway to improved adherence and results with PAP therapy (see Chapter 95; Chapter 97).

For patients who have exhausted PAP, oral appliance, positional therapy, and/or weight loss and require an effective option for disease reduction and symptomatic improvement, successful surgical therapy requires effective phenotyping of the patient's anatomy and sleep-disordered breathing pathophysiology. A standardized anatomic and physiologic staging system does not exist; however, physical examination, upper airway endoscopy, and imaging techniques are available to describe the upper airway anatomy and tailor a surgical treatment plan appropriately.

History

1. History of present illness
   a. Sleep-related symptoms and impact on quality of life, including snoring, witnessed apnea, gasping, choking, nocturnal awakenings, nocturia, morning headaches, daytime sleepiness, and cognitive dysfunction.
   b. Timing, duration, and onset of symptoms. Severe OSA that has already been present and untreated for many years may have implications on cardiovascular comorbidities. OSA symptom onset that coincides with specific events, such as a nasal injury, jaw surgery, weight gain, cerebrovascular event, or change in sleep position due to musculoskeletal problem, may have therapeutic implications.
   c. Presence of other sleep disorders, such as insomnia and restless legs syndrome, that may confound the assessment of OSA outcome measures. Successful management of the patient will often require treatment of both the OSA and other sleep pathology. A comprehensive sleep medicine history is essential.
   d. Prior OSA treatment history, both medical and surgical, including detailed information on side effects, treatment response, and adherence with PAP and other medical devices. Excellent PAP adherence in the setting of persistent daytime sleepiness, for example, is suggestive of other non-OSA etiology of sleepiness, and surgery may not be indicated.
2. Sleep laboratory testing
   a. Type of study: home sleep apnea test (HST) versus in-lab polysomnography (PSG)
   b. Sleep efficiency: Poor sleep efficiency may raise concern for unreliable sleep study results or the possibility of comorbid insomnia.
   c. Sleep architecture: Abnormal sleep architecture may be caused by OSA, as well as by medications (e.g., antidepressants, steroids) or other sleep pathology.
   d. Sleep continuity: An elevated arousal index or abnormal sleep continuity can also be caused by OSA or by chronic pain, medications, or other sleep or medical pathology.
   e. Respiratory analysis: snoring, apnea-hypopnea index (AHI), respiratory disturbance index (RDI), and oxygen saturations should be assessed to determine the severity of OSA. The presence of central sleep apnea, Cheyne-Stokes respiration, or other sleep-related hypoventilation or hypoxemia conditions (e.g., due to cardiopulmonary disease) should be ruled out because surgery may be contraindicated in many such conditions.
   f. Signs of other sleep pathology: PSG should evaluate for periodic limb movement disorder (PLMD), nocturnal seizure activity, rapid-eye movement (REM)-behavior disorder (RBD), or other nonrespiratory sleep disorders.
3. Past medical history
   a. Comorbidities associated with OSA (hypertension, diabetes, myocardial infarction, atrial fibrillation, cerebrovascular event, depression, gastroesophageal reflux disease, erectile dysfunction)
   b. Chronic back or neck pain, fibromyalgia, or other pain syndromes that may negatively impact sleep
   c. Cardiopulmonary disease (e.g., chronic obstructive pulmonary disease, valvular heart disease, or congestive heart failure) that may complicate control of breathing at night and introduce additional respiratory pathology beyond OSA
   d. History of dysphagia
   e. History of neuromuscular disease
4. Past surgical history
   a. Prior sinonasal surgery
   b. Prior pharyngeal or skeletal OSA surgery
   c. Prior bariatric surgery
5. Medications
   a. Anticoagulants
   b. Opiate pain medication, benzodiazepines, or other medications that can alter nocturnal control of breathing
   c. Selective serotonin reuptake inhibitors (SSRIs), tricyclic antidepressants (TCAs), lithium, or other neuropsychiatric medication that can independently alter sleep architecture and continuity
   d. Stimulant therapy (e.g., modafinil or methamphetamines), which may confound the assessment of daytime sleepiness
6. Family history
   a. Strong family history of OSA may provide insight in the anatomic/structural vulnerability.
7. Social history
   a. Occupation
      1) OSA in truck drivers, airline pilots, railroad engineers, and other occupations involving public safety risk has additional implications on treatment and report of outcomes.
      2) Shift workers may have residual sleep-related symptoms due to their circadian rhythm disturbance even after otherwise successful OSA treatment.
   b. Alcohol: Evening alcohol use has been correlated with increased obstructive respiratory events.
   c. Tobacco: Smoking has been shown to independently increase the risk of moderate-to-severe OSA, as well as increase sinonasal and pulmonary disease.
   d. Total sleep duration: Behaviorally induced insufficient sleep is one of the most common causes of daytime sleepiness and may confound the assessment of OSA treatment outcomes. Sleep deprivation has also been shown to exacerbate OSA.

Physical Examination

1. Anterior rhinoscopy
   a. Acquired nasal deformity, septal deviation, turbinate hypertrophy, rhinitis, nasal polyps, and nasal valve pathology may increase upper airway resistance and directly contribute to sleep-disordered breathing.
   b. Increased nasal resistance may also increase negative intraluminal pressure in the pharynx and increase the fraction of maladaptive mouth breathing, further contributing to OSA pathophysiology.
   c. Nasal surgery to lower nasal resistance should be considered either in conjunction with or prior to pharyngeal surgery in most cases.
2. Facial skeleton
   a. Significant maxillary or mandibular hypoplasia may require orthodontic or orthognathic surgical correction prior to consideration of pharyngeal surgery.
   b. Occlusion
      1) Angle classification
      2) Degree of overjet and overbite
3. Oral cavity
   a. Tongue ridging or scalloping suggests relative macroglossia for the available mandibular size.
   b. Quality and quantity of dentition have implications on the availability of adjunctive custom mandibular repositioning device (oral appliance) in the treatment plan.
   c. Height and width of the hard palate. A narrow high-arched soft palate may increase the difficulty of soft tissue work on the soft palate and may negatively affect treatment outcomes.
   d. The presence of large palatal tori may reduce operative exposure and make palatal surgery more technically challenging.

4. Oropharynx[2]
   a. Sagittal configuration of the soft palate (see Fig. 54.1)
      1) ESP is ideally suited for a more obliquely oriented soft palate with an open maxilla and open genu.
      2) TPA is ideally suited for a more vertically oriented soft palate with anteroposterior collapse pattern and maxillary retrusion.
   b. Soft palate length
   c. Modified Mallampati (MM) or Friedman Tongue Position (FTP). Low (stage I or II) MM or FTP scores have been associated with more favorable outcomes with isolated palate surgery.
   d. Tonsil size. Larger (3+ or 4+) tonsil sizes have been correlated with improved surgical outcomes.
   e. Lateral oropharyngeal wall component. The size and position of the posterior tonsillar pillars (palatopharyngeus muscles) have treatment implications. ESP specifically targets and repositions the lateral oropharyngeal wall collapse.
   f. Uvula size and configuration
5. Neck
   a. Neck circumference
   b. Hyoid bone position: A low or inferiorly positioned hyoid bone suggests a longer pharyngeal airway and greater risk of hypopharyngeal collapse that will likely require additional treatment beyond palatal or oropharyngeal surgery alone.
6. General health
   a. Blood pressure
   b. Cardiovascular
   c. Respiratory
   d. Mental
7. Drug-induced sleep endoscopy (DISE)[2]
   a. The length, width, and depth of the soft palate space are documented. Specifically, endoscopy assesses the position of the hard palate, the levator muscle sling (genu), the velum, and the lateral velopharyngeal walls.
   b. ESP is more conducive to the complete concentric pattern of collapse with an oblique soft palate and obstruction more distally at the velum due to large lateral velopharyngeal wall components (Fig. 54.2).
   c. TPA is more conducive to the anteroposterior pattern of collapse with maxillary constriction, more proximal obstruction at the genu, and a long vertical segment of soft palate.

Imaging

1. Chest radiography
   a. Preoperative screening
   b. Evaluate for cardiopulmonary disease
   c. Rule out immobility of the hemidiaphragm
2. Facial skeletal imaging may be indicated in select cases preoperatively particularly in cases of prior surgery of the mandible, suspected craniofacial abnormalities, or signs of maxillomandibular deficiency. Imaging studies may include:
   a. Lateral cephalometric radiograph
   b. Panorex
   c. Computed tomography (CT) three-dimensional imaging
3. Sinonasal imaging may be indicated in patients with suspected chronic sinonasal disease when simultaneous or staged nasal surgery is being considered with the palatal surgery.
4. Modified barium swallow study may be indicated prior to ESP or TPA in patients with baseline dysphagia or velopharyngeal insufficiency symptoms, particularly in those with swallowing problems after prior pharyngeal surgery.

Indications

1. OSA patients who are nonaccepting or intolerant or have inadequate adherence with PAP, oral appliance, weight loss, or other first-line medical device options with:
   a. Moderate-to-severe OSA (AHI >15), or
   b. Mild OSA (AHI 5 to 15) with medical comorbidities or excessive daytime sleepiness or other sleep-related symptoms impairing quality of life
2. Salvage therapy for OSA patients who have failed traditional UPPP or other prior upper airway surgery and have modifiable residual anatomic abnormalities
3. Anatomically, ESP is specifically indicated for patients with a more obliquely oriented soft palate with an open maxilla and genu but distal concentric palatal obstruction at the velum due to large lateral oropharyngeal wall component.
4. Anatomically, TPA is indicated for patients with a more vertically oriented soft palate with maxillary retrusion and an anteroposterior pattern of retropalatal obstruction at the genu and velum.

Relative Contraindications

1. Patient factors
   a. High perioperative risk
   b. Anticoagulation
   c. Poor nutritional status
   d. Pre-existing dysphagia or xerostomia
   e. Occupation dependent upon pharyngeal function (e.g., professional musician or vocalist)

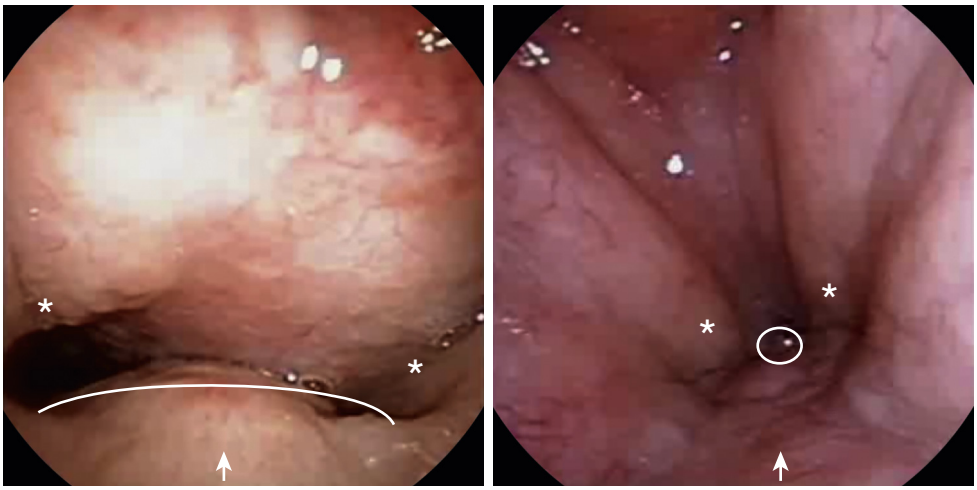

Fig. 54.2. Endoscopic view of the velopharyngeal space during sedated endoscopy. The palate on the left exhibits an anteroposterior pattern of collapse more common in vertical or intermediate soft palate configurations. TPA is more conducive to addressing this configuration, particularly when maxillary deficiency is present. However, ESP is more appropriate for the complete concentric pattern of collapse seen on the right image because the ESP procedure better addresses the large lateral pharyngeal wall component. Key—*White arrow:* soft palate; *white asterisk*: lateral velopharyngeal walls; *white line*: pattern of soft palate collapse.

2. Anatomic factors
   a. Cleft palate or prior cleft palate repair
   b. Poorly vascularized tissue due to radiation or scar tissue
   c. Large palatal tori

Preoperative Preparation

1. Anesthesiology consultation if there is a concern for difficult airway or intubation
2. Stop anticoagulation temporarily.
3. Request patient bring continuous positive airway pressure (CPAP) or oral appliance (if still available and in use) to the day of surgery in the event airway support is needed in the hospital setting

OPERATIVE PERIOD

Anesthesia

1. General anesthesia with oral intubation
2. Videolaryngoscope (i.e., Glidescope) and fiberoptic intubation equipment should be available if needed.

Positioning

- Rose position

Perioperative Antibiotic Prophylaxis

- Intravenous antibiotic dose preoperatively and continued for 24 hours postoperatively
- Antibiotic choice, such as ampicillin-sulbactam or clindamycin, should cover oropharyngeal pathogens, including anaerobes.

Monitoring

- Standard anesthesia and cardiopulmonary monitoring

Instruments and Equipment to Have Available

- ESP
  - Tonsillectomy set
  - Monopolar needle-tip cautery
  - We prefer Coblation (Smith and Nephew PLC, London, United Kingdom) instrumentation for the tonsillectomy portion and additional work related to the uvula and hemostasis during the pharyngoplasty.
  - Toothed forceps
  - Right angle clamp
  - Metzenbaum scissors
  - Haney needle driver
  - 2-0 polysorb suture or similar for muscle suspension
  - 4-0 chromic suture for mucosal closure
- TPA
  - Previous ESP instrumentation plus:
  - TPS drill with 4-mm pineapple burr
  - Woodson periosteal elevator
  - 0 Vicryl suture on UR-6 needle

Key Anatomic Landmarks

- ESP
  - Palatopharyngeus muscle in each posterior tonsillar pillar. The insertion point of the muscle into the soft palate serves as the fulcrum for the pedicled muscle flap.
  - Constrictor muscle in the lateral aspect of the tonsillar fossa (preserve constrictor to avoid unnecessary bleeding and reduce morbidity)
  - Pterygoid hamulus and buccopharyngeal raphe provide the target area to which the muscle flap is anchored
- TPA
  - For incision placement: greater palatine foramina, junction of hard and soft palate, maxillary tuberosity
  - Tendinolysis requires transection of the tensor tendon and fascial bands of the anterior belly of the levator palatine muscle.
  - The bony keel of the posterior nasal spine provides ligamentous attachments to the soft palate and should be preserved during the bony osteotomy.

Prerequisite Skills

- ESP: Tonsillectomy
- TPA: Skeletal surgery/drilling techniques

Operative Risks

- Bleeding

Surgical Technique

- ESP (Fig. 54.3)[3,4]

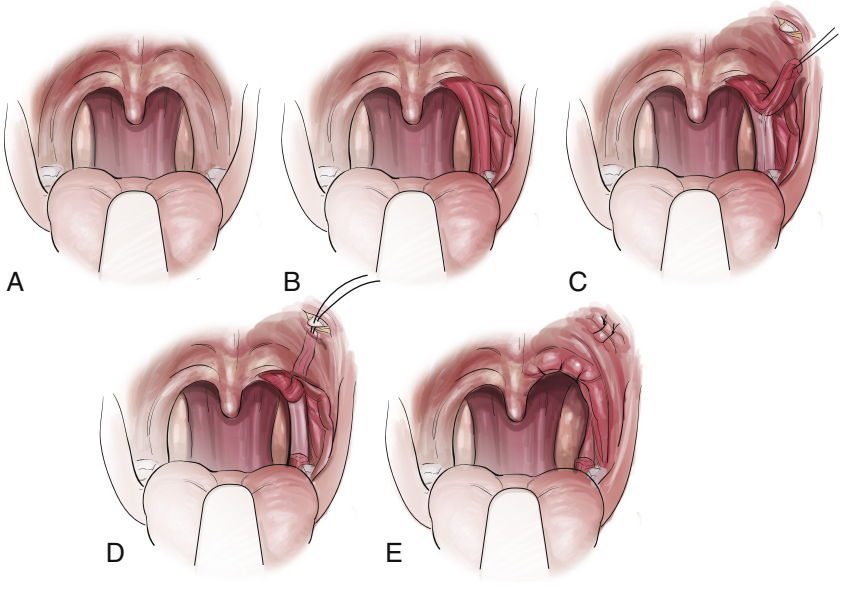

Fig. 54.3. Expansion sphincter pharyngoplasty technique. If tonsils are present, tonsillectomy is performed with maximal mucosal preservation followed by identification and dissection of the palatopharyngeus muscle, **A**, **B**. The palatopharyngeus muscle is rotated toward the hamulus as a pedicled muscle flap and pulled through a submucosal tunnel in the lateral soft palate, **C**, **D**. The muscle flap is anchored to the fibrous tissue adjacent to the soft palate, and additional palatoplasty along the velum may be tailored to the specific anatomy as needed, **E**. *(Reproduced with permission from Woodson BT, Sitton M, Jacobowitz O: Expansion sphincter pharyngoplasty and palatal advancement pharyngoplasty: airway evaluation and surgical techniques. Oper Tech Otolaryngol 23:3-10, 2012.)*

Downloaded for chemptnk chemptnk (chemptnk@gm
For personal use only. No other uses with

- Mirror examination of the nasopharynx is performed first to obtain a baseline retropalatal airway assessment to be used for comparison after completion of the pharyngoplasty.
- If an elongated or edematous uvula is present, we prefer to perform uvular resection or shortening first, before edema distorts the anatomy of the uvula. Most commonly the distal polypoid or edematous half of the uvula is transected sharply while preserving the uvular muscle and glandular function at the base.
- If palatine tonsils are present, bilateral tonsillectomy is performed. Care must be taken to preserve the mucosa overlying the posterior pillar.
- If palatine tonsils were previously removed, Colorado-tipped electrocautery on low setting should be used to incise the mucosa overlying the vertically oriented fibers of the palatopharyngeus muscle. At the lateral aspect of this muscle, the horizontally oriented fibers of the superior constrictor should be identified.
- A portion of the palatopharyngeus muscle is dissected from the surrounding mucosa medially and the constrictor muscle laterally with Metzenbaum scissors, being careful to keep the mucosa intact. A cuff of muscle may be left along the mucosal side and on the constrictor side to facilitate preserving these structures and to facilitate closure. A Mixter clamp or right angle forceps can be used to isolate the palatopharyngeus.
- The muscle is transected inferiorly with electrocautery adjacent to the base of the tongue with electrocautery and elevated as a pedicled muscle flap to the insertion point into the soft palate (fulcrum). Two 2-0 polysorb anchor sutures are placed in each muscle flap in a tendon stitch fashion.
- A separate stab incision is made in the lateral soft palate mucosa and submucosa just lateral to the pterygoid hamulus. The right angle clamp is used to dissect a tunnel (superficial to the palate musculature) from this stab incision into the superior pole of the tonsillar fossa.
- The palatopharyngeus pedicled muscle flap is then rotated anteriorly, superiorly, and laterally. The exact vector of the muscle flap may vary depending on each patient's palatal anatomy and width. Manual traction on the muscle flap should result in visible enlargement of the retropalatal space.
- The muscle flap and the attached sutures are brought through the tunnel in the superior pole and out through the stab incision. The 2-0 polysorb sutures are then anchored to the fibrous tissue of the lateral soft palate including the tensor aponeurosis and periosteum of the pterygoid hamulus.
- Mirror examination of the nasopharynx should demonstrate significant improvement in the retropalatal space and lateral oropharyngeal dimension.
- Additional 2-0 polysorb sutures are used to reapproximate the anterior and posterior tonsillar pillars on each side.
- 4-0 chromic mucosal sutures are used to close mucosal edges along the velum and uvula, as well as to close the lateral soft palate incisions and bury the 2-0 polysorb anchor sutures.

Transpalatal Advancement Pharyngoplasty (Figs. 54.4 and 54.5)[5]

- Maximal mouth opening and neck extension will optimize exposure.
- Bilateral greater palatine foramina should be infiltrated with 1% lidocaine with 1:100,000 epinephrine.
- NOTE: the greater palatine neurovascular bundle arises from the junction of alveolar, palatine, and maxillary bones.
- Fig. 54.4 highlights important landmarks for the incision. The trifurcation should be placed in the midline at the transition from the thinner, attached mucosa to thicker, unattached mucosa. The lateral limbs should be aimed toward the pterygoid hamulus. At all limb margins, several millimeters should be maintained from the alveolus to facilitate closure.
- The incision is made with Colorado-tipped electrocautery on low setting.
- The submucosal flaps should be elevated laterally and posteriorly using a Cottle elevator or equivalent. The posterior edge of the hard palate defines the posterior limit of flap elevation.
- For retraction of lateral flaps, dual Cottle elevators can now be placed in the greater palatine foramina.
- Hemostasis is achieved with bipolar cautery to minimize collateral damage.
- Using a pencil, a bony rectangle 10 mm in height should be marked out. The lateral extent varies but a wider window is preferred.
- The posterior nasal spine should be preserved (1 to 2 mm) to maintain the ligamentous attachments to the soft palate.
- A 4-mm pineapple burr (ovoid shape to minimize collateral damage) is used to thin the bony rectangle. As the bone becomes thin, a mastoid curette can be used to expose the nasal mucosa.

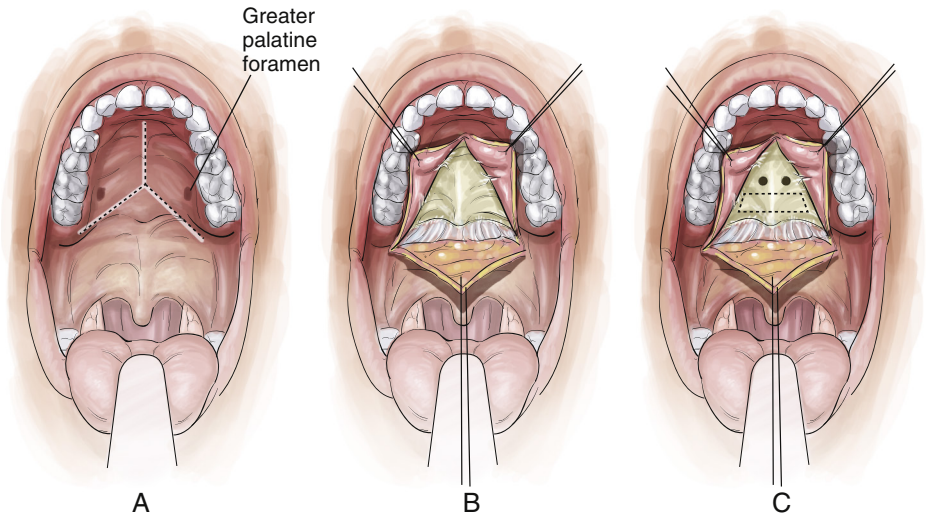

Fig. 54.4. Transpalatal advancement pharyngoplasty technique. After a propeller incision over the posterior aspect of the hard palate, flaps are elevated to fully expose the hard-soft palate junction, **A**, **B**. An osteotomy is marked for removal of approximately 8 to 10 mm of bone while preserving the posterior nasal spine ("keel") and its ligamentous attachments to the soft palate, **C**. *(Reproduced with permission from Woodson BT, Sitton M, Jacobowitz O: Expansion sphincter pharyngoplasty and palatal advancement pharyngoplasty: airway evaluation and surgical techniques. Oper Tech Otolaryngol 23:3-10, 2012.)*

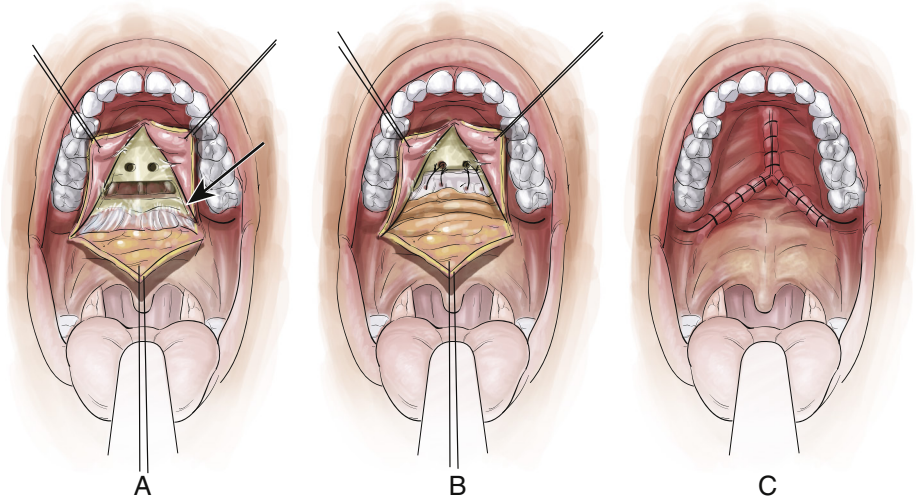

Fig. 54.5. Transpalatal advancement pharyngoplasty technique. After the osteotomy is complete, the soft palate is mobilized by releasing the tensor aponeurosis laterally, **A**, *(arrow)*. Soft palate advancement sutures are placed around the bony keel and through separate drill holes in the hard palate, and the mucosal incisions are subsequently closed without tension, **B**, **C**. *(Reproduced with permission from Woodson BT, Sitton M, Jacobowitz O: Expansion sphincter pharyngoplasty and palatal advancement pharyngoplasty: airway evaluation and surgical techniques. Oper Tech Otolaryngol 23:3-10, 2012.)*

- Heavy scissors should be used to separate nasal septum (superiorly) and maxillary alveolus (laterally).
- Two drill holes (each approximately 5 mm from the midline) using 1 mm TPS drill bit are created 5 mm proximal to osteotomized segment.
- If the nasal mucosa is violated using electrocautery, be careful not to inadvertently injure the adjacent inferior turbinates.
- As the nasopharynx is visualized, the palatine aponeurosis is identified as a condensed white band medial to the hamulus.
- After the aponeurosis is adequately incised with electrocautery, the eustachian tube orifices should be visualized.
- To validate adequate mobilization, anterior traction placed on the distal palatal segment should result in anterior displacement of the uvula.
- Vicryl sutures (0) on a UR-6 needle are passed (blunt end first) through the drill holes into the nasopharynx. Two sutures are placed in each drill hole. From each of the drill holes, a suture is placed medially around the center of the soft palate and another laterally to capture the palatal aponeurosis.
- After all four sutures are placed, the assistant approximates the posterior nasal spine to the new free edge of the hard palate with a blunt instrument while the surgeon ties the knot.
- Excess fibroadipose tissue is removed and mucosal flaps are closed with monofilament sutures.

Common Errors in Technique

- ESP
  - Tearing of the palatopharyngeus muscle flap
  - Perforation of the lateral oropharyngeal wall mucosa ("rent" or "buttonhole") during flap elevation
- TPA
  - Inadequate release of palatine tensor aponeurosis for distal palate mobility
  - Drill trauma to the nasal turbinate and subsequent epistaxis

POSTOPERATIVE PERIOD

Postoperative Management

- Discharge according to same-day surgery criteria regarding adequate oral intake, pain and nausea control, and cardiopulmonary monitoring.
- For patients with very severe OSA, significant obesity, medical comorbidities, high opioid pain medication requirement, or those not meeting acceptable outpatient discharge criteria, overnight hospital observation may be required for respiratory monitoring.
- Diet: soft, smooth, and slimy for approximately 2 weeks
- Activity: Avoid strenuous activity, frequent talking, heavy lifting, or bending over for approximately 2 weeks.
- Moisturization: Maintain adequate hydration throughout day and run humidifier at night.
- Medications
  - Opioid pain medication
  - Over-the-counter acetaminophen and/or nonsteroidal anti-inflammatory medication
  - Antibiotics for 24 hours
  - Steroid course in the first week
  - Sucralfate suspension swish and swallow for comfort and to promote remucosalization

COMPLICATIONS

- ESP
  - Bleeding
  - Velopharyngeal insufficiency
  - Dysphagia
- TPA
  - Bleeding
  - Velopharyngeal insufficiency
  - Dysphagia
  - Oronasal fistula should be initially treated with an oral splint. This hastens healing by reducing bacterial contamination, as well as facilitates speech and diet. If the fistula persists, suture closure in office or operative room can be undertaken.

ALTERNATIVE MANAGEMENT PLAN

At any stage of evaluation and management, patients should always be offered to continue or revisit PAP or other medical device therapy. In patients with persistent or residual OSA after advanced palatal surgery, adherence and success rates with PAP and oral appliance may be higher after surgical therapy to lower upper airway resistance.

DISCUSSION

Evidence-Based Medicine Question

Is expansion sphincter pharyngoplasty as effective as traditional uvulopalatopharyngoplasty in reducing the apnea-hypopnea index?

One randomized trial by Pang and Woodson showed that ESP was more effective than traditional UPPP as defined by 50% reduction in AHI and AHI less than 15. The ESP group had 78% success rate, whereas the UPPP group had 45% success rate ($P < .05$).[3]

Editorial Comment

Palatal surgery plays a key role in the management of patients with OSA who are intolerant or unable to achieve benefit with medical device therapy. However, traditional UPPP has several important limitations due to the excisional nature of the procedure and subsequent fibrosis. Research has demonstrated that postoperative improvement in airflow and OSA outcome measures is directly related to the increase in upper airway volume and cross-sectional area. ESP and TPA pharyngoplasty are examples of advanced modifications of palatal surgery that better reconstruct and enlarge the upper airway, which may reduce side effects and morbidity compared with traditional excisional techniques.

Ryan Soose


Access the review questions online at http://www.expertconsult.com

REFERENCES

1. Woodson BT, Sitton M, Jacobowitz O. Expansion sphincter pharyngoplasty and palatal advancement pharyngoplasty: airway evaluation and surgical techniques. Oper Tech Otolaryngol 2012;23:3–10.
2. Woodson BT. A method to describe the pharyngeal airway. Laryngoscope 2015;125:1233–1238.
3. Pang KP, Woodson BT. Expansion sphincter pharyngoplasty: a new technique for the treatment of obstructive sleep apnea. Otolaryngol Head Neck Surg 2007;137:110–114.
4. Pang KP, Pang EB, Win MT, et al. Expansion sphincter pharyngoplasty for the treatment of OSA: a systemic review and meta-analysis. Eur Arch Otorhinolaryngol 2016;273:2329–2333.
5. Woodson BT, Robinson S, Lim HJ. Transpalatal advancement pharyngoplasty outcomes compared with uvulopalatopharyngoplasty. Otolaryngol Head Neck Surg 2005;133:211–217.

REVIEW QUESTIONS

1. Which of the following palatal configurations is best suited for TPA?
   a. Oblique
   b. Intermediate
   c. Vertical
   d. Horizontal

2. The greater palatine foramen is located at the intersection of:
   a. Palatine, maxillary, and sphenoid bones
   b. Palatine, maxillary, and alveolar bones
   c. Maxillary, alveolar, and sphenoid bones
   d. Alveolar, sphenoid, and palatine bones

3. Initial management of oronasal fistula after TPA includes:
   a. Primary closure
   b. Secondary closure
   c. Local flap
   d. Dental splint

55 Volumetric Tongue-Base Reduction (Lingual Tonsillectomy, Coblation Midline Glossectomy, Trans Oral Robotic Surgery)

Don Keamy, Jr., Umamaheswar Duvvuri

INTRODUCTION

First-line surgical treatment of obstructive sleep apnea (OSA) in both pediatric and adult patients is adenotonsillectomy and has often been uvulopalatopharyngoplasty in adults. When initial medical or surgical treatment of OSA fails to successfully treat the condition, adjunct surgical treatment may be warranted. Lingual tonsillectomy and tongue-base reduction are two of these surgical techniques that can lead to improved outcomes in patients with OSA.[1,2]

In the pediatric population, adenotonsillectomy seems to be very successful initially. Months to years later, some of these initial successes present with recurrent symptoms. In these cases, lingual tonsillar hypertrophy may be the cause. In obese patients, the risk of lingual hypertrophy of the tonsil appears to be higher after adenotonsillectomy.

Lingual tonsillectomy alone can be very effective in relieving upper airway obstruction when the lingual tonsils are noted to be large and obstructive during drug-induced sleep endoscopy (DISE) or other methods of upper airway assessment. When lingual tonsils are small or absent, but there is still significant tongue-base collapse leading to upper airway obstruction, tongue-base reduction surgery may be beneficial (Fig. 55.1).

Various methods of video-assisted lingual tonsillectomy have been described. One such method is via suspension laryngoscopy with the use of the coblation device.[3] This has proven to be a reliable technique that can be performed without needing any assistants for retraction.

Both procedures aim to improve the retroglossal airway during sleep, which may improve OSA symptoms. Even if OSA is not resolved, these procedures can potentially improve compliance with continuous positive airway pressure (CPAP), leading to reduced pressure settings on CPAP devices.

KEY OPERATIVE LEARNING POINTS: ENDOSCOPIC LINGUAL TONSILLECTOMY

- Preoperative airway assessment with DISE is advocated for proper patient selection. Some centers employ CINE MRI when sleep endoscopy is not available.
- Lingual tonsillectomy is best considered in patients who have previously had adenotonsillectomy.
- While nasal intubation may aid in surgical ease, it is not necessary. The procedure can be performed with oral intubation to facilitate concurrent nasal surgery.
- The vallecula should be unobstructed and completely free of lingual tonsil tissue at the completion of the surgery.
- The lateral lingual tissue may be more superficially removed to reduce the risk of significant peri- or postoperative bleeding.
- This procedure can be performed in both pediatric and adult patients by using the appropriate pediatric and adult-sized laryngoscopes.

PREOPERATIVE PERIOD

A comprehensive medical history remains the cornerstone of the preoperative evaluation. Once it has been determined that a patient is intolerant or unable to achieve adequate benefit with standard medical treatments, surgical options should be considered. Physical examination, upper airway endoscopy, and imaging techniques should be used to describe the anatomy of the upper airway and tailor a comprehensive surgical treatment plan. The key to success with these techniques is patient selection, and significant time should be spent with the patient preoperatively to be certain that chances for success are optimized.

Patients considered for second-line surgical treatment should be evaluated for other medical conditions that could lead to sleep disorders. In pediatric patients, CPAP is often not tolerated and, when used long term, it may lead to craniofacial abnormalities. In this population, lingual tonsillectomy may be considered without a trial of CPAP. In adults, surgery would be considered for patients who fail or are intolerant of CPAP or other medical and dental treatments.

History

1. History of present illness
   a. Symptoms and impact on quality of life including snoring, apnea, gasping, choking, oropharyngeal pain, dysphagia, and cognitive dysfunction
   b. Timing, duration, and onset of symptoms. The severity and duration of symptoms should be carefully assessed. It is important to make the determination that removing hypertrophied lingual tonsils will alleviate the symptoms.
   c. Prior history of treatments, both medical and surgical, including detailed information on side effects and treatment response, should be gathered.
2. Past medical history
   a. Comorbidities associated with upper airway obstruction should be sought (hypertension, diabetes, myocardial infarction, atrial fibrillation, cerebrovascular event, depression, gastroesophageal reflux disease, erectile dysfunction).
   b. Chronic neck pain, trismus, and other conditions that may negatively impact exposure of the base of the tongue
   c. History of dysphagia
   d. History of neuromuscular disease
3. Past surgical history
   a. Prior surgery or injury to the tissues of the neck may be contraindications to tongue-base reduction surgery and need to be evaluated on an individual basis.
   b. Prior maxillofacial surgery that may lead to difficulty with exposure and/or injury to the teeth
4. Medications
   a. Anticoagulants
   b. Opiate pain medication, benzodiazepines, or other medications that can alter nocturnal control of breathing

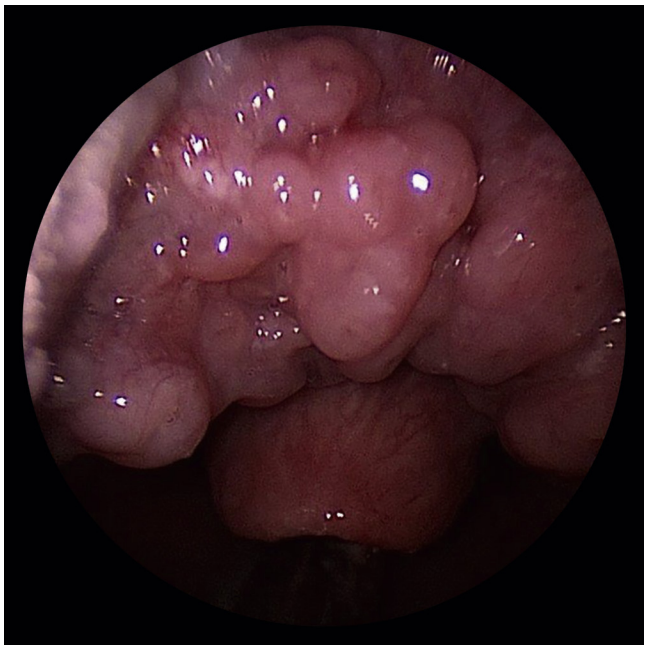

Fig. 55.1. Endoscopic view demonstrating hypertrophic lingual tonsil tissue.

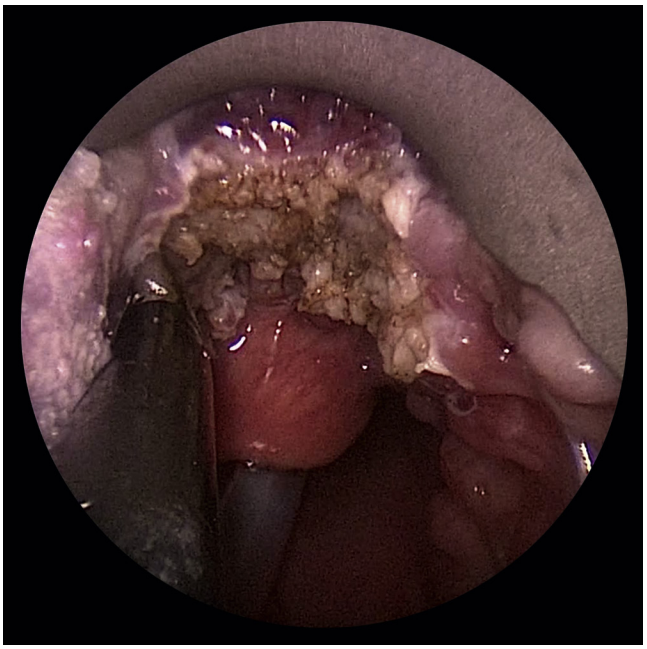

Fig. 55.2. Postoperative view of the tongue base after coblation lingual tonsillectomy.

5. Family history
   a. A strong family history of OSA may provide insight into the anatomic/structural vulnerability.
6. Social history
   a. Alcohol: Excessive alcohol use in adults can lead to postoperative withdrawal and complications.
   b. Tobacco: Smoking has been shown to independently increase the risk of pulmonary disease and hence anesthesia-associated complications. Also, in older patients with an extensive smoking and drinking history, the risk of malignancy in the oropharynx should also be considered.

Physical Examination

1. Evaluation of the facial skeleton
   a. Significant maxillary or mandibular hypoplasia may be associated with increased difficulty in exposure.
   b. Occlusion:
      1) Angle's classification
      2) Degree of overjet and overbite
2. Oral cavity
   a. Tongue ridging or scalloping suggests relative macroglossia for the available mandibular size.
   b. Quality and quantity of dentition have implications on the potential for injury to the teeth during the surgery.
   c. Height and width of the hard palate. A narrow high-arched soft palate may increase the difficulty of soft tissue work on the soft palate and may negatively affect treatment outcomes.
   d. The presence of large palatal tori may reduce operative exposure and make palatal surgery more technically challenging.
3. Oropharynx
   a. Tonsil size
   b. Crowded nature of the oropharynx
   c. Modified Mallampati (MM) or Friedman tongue position (FTP)
   d. Size and structure of the lateral oropharyngeal wall
4. Examination of the neck
   a. Neck circumference
   b. Hyoid bone position: A low or inferiorly positioned hyoid bone suggests a longer pharyngeal airway.
5. Cranial nerve examination with specific attention to the functional status of the hypoglossal nerve and glossopharyngeal nerves
6. General health
   a. Blood pressure
   b. Cardiovascular
   c. Respiratory
   d. Mental
7. Flexible fiberoptic laryngoscopy
   a. Awake
   b. DISE

Imaging

1. Chest radiograph
   a. Preoperative screening
   b. Evaluate for cardiopulmonary disease
   c. Rule out immobility of the hemidiaphragm
2. Computed tomographic imaging: may be indicated preoperatively to assess the extent of lingual tonsil hypertrophy and oropharyngeal crowding
3. Modified barium swallow study may be indicated prior to surgery for patients with baseline dysphagia, particularly in those with swallowing problems after prior pharyngeal surgery (Fig. 55.2).

Indications

1. Patients with enlarged lingual tonsils with symptoms of either hypertrophy of the lingual tonsil leading dysphagia/odynophagia or OSA
2. DISE is currently recommended to evaluate the anatomic location and pattern of pharyngeal collapse prior to proceeding with tongue-base reduction surgery. Particular attention is paid to the pattern of palatal collapse

and the degree of multilevel coupling between the tongue protrusion and enlargement of the retropalatal space.

Contraindications

1. Patient factors
   a. High perioperative risk due to comorbidities
   b. Patient taking anticoagulants
   c. Poor nutritional status
2. Anatomic factors
   a. Craniofacial abnormalities prevent access to the lingual tonsils or tongue base.

Preoperative Preparation

1. Anesthesiology consultation if there is a concern for difficult airway or intubation
2. Hold anticoagulation if possible
3. Request that the patient bring CPAP or an oral appliance (if still available and in use) to the day of surgery in the event that airway support is needed in the hospital setting.

OPERATIVE PERIOD

There are several techniques that can be used to perform tongue-base reduction surgery. The most commonly used are (1) coblator-based reduction performed through a laryngoscopy approach or (2) transoral robotic resection of the base of the tongue using either the Intuitive da Vinci or Medrobotics Flex system. We describe these methods in the subsequent sections.

Anesthesia

1. General anesthesia with nasal or oral intubation
2. Videolaryngoscope (i.e., GlideScope) and fiberoptic intubation equipment should be available if needed
3. Bronchoscopic equipment should be available for difficult intubations.
4. Perioperative dexamethasone administration should be requested.

Positioning

- Rose position unless patient has trisomy-21
- Neutral neck position for trisomy-21 patients

Perioperative Antibiotic Prophylaxis

- Not indicated

Monitoring

- Standard anesthesia and cardiopulmonary monitoring

Instruments and Equipment to Have Available (Lingual Tonsillectomy)

- Lindholm suspension set
- Coblation device with Procise Xact 70 wand
- Thirty-centimeter rigid endoscope with video tower
- Rigid laryngeal suction

Key Anatomic Landmarks

- Identify the circumvallate papillae.
- Palpate the hyoid bone.
- Visualize the epiglottis and the valleculae.

Surgical Technique

Lingual Tonsillectomy Using the Coblator

- The patient may be intubated nasally or orally. If no concurrent nasal or nasopharyngeal surgery is planned, a nasal intubation provides better exposure and increases the ease of surgery.
- The Lindholm suspension laryngoscope is inserted orally and suspended with a view of the lingual tonsils and epiglottis.
- A long 0-degree endoscope is inserted to further inspect the surgical field.
- The Procise Xact 70 coblation wand connected with setting of 7 coblate and 3 coagulate
- The wand and endoscope are both inserted through the Lindholm laryngoscope, and ablation of the lingual tonsils is performed.
- Care is taken not to injure the epiglottis. Lingual tonsil tissue should be pushed away from the epiglottis with the coblation wand prior to engaging the coblate peddle.
- Bleeding is controlled via the coagulation mode of the coblater.
- Coblation of the central lingual tonsils continues until the musculature of the tongue is reached and the vallecula is unobstructed.
- Lateral lingual tonsil tissue may also be ablated, but the risk of significant bleeding will be reduced if the lateral tissue is ablated more superficially.
- The Lindholm laryngoscope may need to be repositioned several times and further coblation performed to ensure adequate removal of lingual tonsillar tissue.
- We check for hemostasis and use gelatin foam with thrombin for hemostasis.
- Instrumentation is removed after adequate removal of lingual tonsillar tissue is obtained.

Lingual Tonsillectomy Using the da Vinci Robotic System

- The patient may be intubated nasally or orally. If no concurrent nasal or nasopharyngeal surgery is planned, a nasal intubation provides better exposure and increases the ease of surgery.
- A Dingman mouth gag using a flat blade is inserted orally and suspended with a view of the lingual tonsils and epiglottis.
- The surgical robotic system is placed into the mouth to further inspect the surgical field.
- The robotic instruments, a 5-mm Maryland and a 5-mm spatula cautery, are placed into the oral cavity.
- The dissection begins at the circumvallate papilla with a horizontal incision. The lingual tonsil tissue is bisected in the midline. The dissection then continues down to the level of the tongue musculature. Using cautery, the fasciculation of the muscles delineates the plane of dissection. The dissection is continued posteriorly to the level of the vallecula, and lymphoid tissue is removed from the vallecula as well.
- Care is taken not to injure the epiglottis. Lingual tonsil tissue should be pushed away from the epiglottis with the robotic instruments before the tissue planes are transected.
- Bleeding is controlled using the coagulation mode of the coblater.
- Instrumentation is removed after adequate removal of lingual tonsillar tissue is obtained.

Lingual Tonsillectomy Using the Medrobotics System

- The patient may be nasally or orally intubated. If no concurrent nasal or nasopharyngeal surgery is planned, a nasal intubation provides better exposure and increases the ease of surgery.

- A Dingman mouth gag using a flat blade is inserted orally and suspended with a view of the lingual tonsils and epiglottis.
- The Medrobotics Flex system is brought into the field.
- The Flex drive is placed in the mouth, and the surgical field is visualized.
- The instrument support system is placed and affixed to the surgical bed.
- The Maryland and cautery instruments are positioned into the patient's mouth.
- The Flex drive is manipulated and driven into the oral cavity to obtain appropriate visualization of the surgical field.
- Care is taken not to injure the epiglottis. Lingual tonsil tissue should be pushed away from the epiglottis prior to tissue dissection.
- Bleeding is controlled with coagulation using the cautery device or using a bipolar device operated by the bedside assistant.
- The dissection begins at the circumvallate papilla with a horizontal incision. The lingual tonsil tissue is bisected in the midline. The dissection then continues down to the level of the tongue musculature. Using cautery shows the fasciculation of the muscles, which delineates the plane of dissection. The dissection is continued down to the level of the vallecula, when tissue is removed.
- Lateral lingual tonsil tissue may also be ablated, but the risk of significant bleeding is reduced if the lateral tissue is more superficially ablated.
- Instrumentation is removed after adequate removal of lingual tonsillar tissue.

Common Errors in Technique

- Injury to the epiglottis, especially the tip, with the coblation wand
- Incomplete removal of the central lingual tonsil tissue

POSTOPERATIVE PERIOD

- Overnight postoperative observation in a monitored setting is appropriate given the potential for edema of the epiglottis and tongue postoperatively as well as possible bleeding.
- Postoperative steroids may help to reduce swelling.
- Diet: soft and smooth (mechanical soft) for approximately 2 weeks
- Activity: Avoid strenuous activity, frequent talking, heavy lifting, or bending over for approximately 2 weeks.
- Moisturization: Maintain adequate hydration throughout the day, and use the humidifier on a bedside table at night.
- Medications:
  - Opioid pain medication should be used with caution in pediatric patients.
  - Over-the-counter acetaminophen and/or nonsteroidal anti-inflammatory medication

Complications

- Bleeding can be encountered intraoperatively or postoperatively.
  - Intraoperative bleeding can be avoided through careful management of hemostasis, which is usually accomplished using a bipolar cautery. Postoperative bleeding occurs in 8% of patients. This can be ameliorated by performing vessel ligation, although this is usually performed in patients undergoing surgery for malignant processes.
- Airway edema and obstruction—airway edema occurs in a small subset of patients
  - This can, in certain cases, lead to obstructive symptoms and potentially result in airway compromise. This problem often occurs because of tongue swelling caused by traction injury. Such complications can be reduced or avoided if operative times are reduced and traction injury is avoided.
- Dysphagia—short term and long term
  - Short-term dysphagia is an expected side effect of tongue-base surgery. Long-term dysphagia is considered an undesired side effect/complication of this surgery.
  - Long-term dysphagia is often attributed to oropharyngeal stenosis, which occurs due to circumferential swelling. This can be avoided by not removing the palatine tonsils and lingual tonsils simultaneously.

Alternative Management Plan

At any stage of evaluation and management, patients should always be offered to continue or revisit CPAP or other medical device therapy. In patients with persistent or residual OSA after advanced palatal surgery, adherence and success rates with CPAP and oral appliance may be higher after surgical therapy to lower upper airway resistance.

DISCUSSION

Evidence-Based Medicine Question

Is lingual tonsillar hypertrophy common in obese patients?

One study by Guimaraes et al.[2] showed that 62% of obese children have measurable lingual tonsils on imaging.

Editorial Comment

For the treatment of obstructive sleep-disordered breathing, in both pediatric and adult patients, the retrolingual airway is of utmost importance. Traditionally, this portion of the upper airway has been difficult to assess and examine, and it has been challenging to expose and treat. Advanced diagnostic tools including sedated endoscopy and imaging have improved the clinician's ability to evaluate for tongue-base pathology. Furthermore, advances in microlaryngoscopy and endoscopy techniques, robotic surgery systems, and plasma wand technology have substantially improved the surgical exposure and the ability to safely and effectively treat retrolingual airway obstruction.

Ryan Soose

Access the review questions online at http://www.expertconsult.com



REFERENCES

1. Maturo SC, Mair EA. Coblation lingual tonsillectomy. Otolaryngol Head Neck Surg 2006;135(3):487–488.
2. Guimaraes CVI, Kalra M, Donnelly LF, et al. The frequency of lingual tonsil enlargement in obese children. AJR Am J Roentgenol 2008;190(4):973–975.
3. Rotenberg BI, Tan S. Endoscopic-assisted radiofrequency lingual tonsillectomy. Laryngoscope 2008;121(5):994–996.

REVIEW QUESTIONS

1. Lingual tonsillectomy is most appropriate
   a. As a primary treatment for obstructive sleep apnea (OSA)
   b. Only in pediatric or adult patients who have failed continuous positive airway pressure
   c. In pediatric patients who have previously had adenotonsillectomy and demonstrate obstructive lingual tonsils on DISE
   d. Whenever large lingual tonsils are found on fiberoptic laryngoscopy in patients with OSA

2. The most appropriate intubation technique for lingual tonsillectomy is
   a. Always nasotracheal intubation
   b. Always endotracheal intubation
   c. Decided by the anesthesiologist
   d. Either oral or nasotracheal depending on other planned nasal or nasopharyngeal procedures

3. The most feared complication of lingual tonsillectomy is
   a. Dysgeusia
   b. Hemorrhage
   c. Dysphagia
   d. Dysarthria

4. How long does dysphagia usually persist after lingual tonsillectomy?
   a. 1 day
   b. 1 month
   c. 2 weeks
   d. 2 months

56 Hypoglossal Nerve Stimulation Therapy

Ryan Soose, David Kent

INTRODUCTION

The prevalence of obstructive sleep apnea (OSA), its complex pathophysiology, and the suboptimal adherence rates with positive pressure therapy require alternative treatment strategies in many OSA patients. Hypoglossal nerve stimulation (HNS) represents a novel and unique therapeutic approach that combines a surgical implant procedure with a titratable medical device to provide multilevel upper airway improvement via neuromodulation of the hypoglossal nerve.[1] A recent multicenter prospective trial of HNS reported significant reduction in polysomnographic measures of disease severity and significant improvement in patient-reported quality of life measures that were maintained at 3 years follow-up, with overall low morbidity and good patient acceptance and adherence.[2-4] HNS therapy has established itself as a key component of the OSA treatment armamentarium, although further work is needed to advance the technology, determine the most appropriate patient phenotypes, refine the implant procedure, and optimize stimulation parameters and titration protocols.[5]

Traditional surgical procedures for sleep apnea exclusively target the anatomic structural vulnerability of the upper airway. There is increasing evidence that the neuromuscular control of breathing during sleep also plays a key role in the pathophysiology of sleep-disordered breathing for many OSA patients. A simplified version of the upper airway neuromuscular feedback loop has been described with afferents from the pharynx, through the superior laryngeal nerve, to the nucleus solitarius and efferents from the hypoglossal nerve motor nucleus to the genioglossus muscle. The genioglossus muscle is the primary upper airway dilator muscle and, in normal healthy subjects, responds to negative intraluminal pressure with a corresponding increase in genioglossus electromyographic (EMG) activity. This negative pressure reflex appears to be dysfunctional in many patients with OSA. Augmenting the efferent limb of the neuromuscular feedback loop by stimulating the hypoglossal nerve, or the genioglossus muscle directly, may provide a therapeutic mechanism for some OSA patients.

Two key factors play an important role in the potential success of the HNS therapy: (1) the ability of the therapy to provide *multilevel* upper airway improvement and (2) the ability to adjust and titrate the therapy. Imaging, fluoroscopy, and drug-induced sedated endoscopy (DISE) evaluation of HNS therapy responders demonstrated that HNS resulted in enlargement of the retropalatal space as well as the retrolingual portion of the airway.[6] Anterior displacement of the hyoid bone also occurred in the majority of participants. This multilevel improvement may be due to a number of factors but is primarily thought to occur from the mechanical coupling of the tongue and palate via the palatoglossal and palatopharyngeus muscles. During therapy titration, prior studies have shown a graded increase in airflow and airway measurements with increasing stimulation amplitudes. Unlike traditional sleep apnea surgery, HNS therapy can be titrated in the clinical or sleep laboratory setting to optimize both effectiveness and comfort across a longitudinal care model.

The role of anatomic phenotyping of the upper airway has been increasingly recognized as essential to successful patient selection and improved outcomes. For example, feasibility study data on the currently available HNS system suggest that outcomes are better in patients without a complete circumferential pattern of collapse at the soft palate during DISE. HNS differs from traditional OSA airway surgery in that the procedure does not alter the anatomy of the upper airway and is technically reversible. Unlike volumetric reduction of the base of the tongue or other surgeries of the pharynx, the HNS surgical procedure is completely external to the pharynx, thus substantially reducing postoperative discomfort and recovery time, and minimizing or even eliminating the traditional risks of hemorrhage, dysphagia, change in taste, or other untoward pharyngeal side effects of anatomy-altering procedures.

KEY OPERATIVE LEARNING POINTS

- Successful HNS therapy requires proper patient selection, anatomic phenotyping, meticulous procedure execution, and precise titration of stimulation parameters postoperatively.
- Intraoperative hypoglossal nerve monitoring is used to identify and selectively capture the distal tongue protrusor branches supplying the genioglossus muscle and to exclude lateral branches innervating the tongue retractor muscles.

PREOPERATIVE PERIOD

As discussed in Advanced Palatal Surgery, Chapter 54, a comprehensive sleep medicine history remains the cornerstone of preoperative evaluation. Once a patient is determined to be intolerant of or unable to achieve adequate benefits with standard medical treatments, surgical options may be considered. The optimal anatomic and physiologic phenotypes for HNS remain unclear and controversial. Physical examination, upper airway endoscopy, and imaging techniques are available to describe the upper airway anatomy and tailor a comprehensive and multilevel surgical treatment plan appropriately. The current US Food and Drug Administration (FDA)-approved HNS system has been studied in and approved for the treatment of *moderate-severe* OSA as second-line therapy after failure of positive pressure therapy. Several preoperative considerations are specific to HNS therapy and are also highlighted in the following list (**).

History

1. History of present illness
   a. Sleep-related symptoms and impact on quality of life, including snoring, witnessed apnea, gasping, choking, nocturnal awakenings, nocturia, morning headaches, daytime sleepiness, and cognitive dysfunction
   b. Timing, duration, and onset of symptoms. Previously untreated severe OSA may be further complicated by associated cardiovascular comorbidities. Specific events may coincide with OSA onset such as an injury to the nose, surgery of the mandible, weight gain, cerebrovascular events, and change in sleep position due to musculoskeletal problems. All may have therapeutic implications.

c. The presence of other sleep disorders such as insomnia and restless legs syndrome may confound the assessment of OSA outcome measures. Successful management of the patient will often require treatment of both the OSA and the additional comorbid sleep pathology. A comprehensive sleep medicine history is essential.
d. Prior OSA treatment history, both medical and surgical, including detailed information on side effects, treatment response, and adherence with PAP and other medical devices. Excellent positive airway pressure (PAP) adherence in the setting of persistent daytime sleepiness, for example, is suggestive of a non-OSA etiology of sleepiness, and surgery may not be indicated.

2. Sleep laboratory testing
   a. Type of study: Home sleep apnea test (HST) versus in-lab polysomnography (PSG)
   b. Sleep efficiency: Poor sleep efficiency may raise concern for unreliable sleep study results or the possibility of comorbid insomnia.
   c. Sleep architecture: Abnormal sleep architecture may be caused by OSA as well as by medications (e.g., antidepressants, steroids) or other sleep pathology.
   d. Sleep continuity: An elevated arousal index or abnormal sleep continuity can also be caused by OSA or by chronic pain, medications, or other sleep or medical pathology.
   e. Respiratory analysis: Snoring, apnea-hypopnea index (AHI), respiratory disturbance index (RDI), and oxygen saturation should be assessed to determine the severity of OSA. The presence of central sleep apnea, Cheyne–Stokes respiration, or other sleep-related hypoventilation/hypoxemia conditions (e.g., due to cardiopulmonary disease) should be ruled out, as surgery may be contraindicated in such conditions.
   f. Signs of other sleep pathology: PSG should evaluate for periodic limb movement disorder (PLMD), nocturnal seizure activity, REM-behavior disorder (RBD), or other nonrespiratory sleep disorders.
3. Past medical history
   a. **Medical conditions requiring the regular use of magnetic resonance imaging (MRI) such as multiple sclerosis or central nervous system neoplasm. MRI is contraindicated in patients with the current HNS implantable device.
   b. **History of allergy to metal or other synthetic materials
   c. Comorbidities associated with OSA (hypertension, diabetes, myocardial infarction, atrial fibrillation, cerebrovascular event, depression, gastroesophageal reflux disease, erectile dysfunction)
   d. Chronic back or neck pain, fibromyalgia, or other pain syndromes that may negatively impact sleep
   e. Cardiopulmonary disease (e.g., chronic obstructive pulmonary disease, valvular heart disease, or congestive heart failure) that may complicate control of breathing at night and introduce additional respiratory pathology beyond OSA
   f. History of dysphagia
   g. History of neuromuscular disease
4. Past surgical history
   a. **Prior surgery or injury to the tissues of the neck or upper chest (e.g., radiation of the head and neck, breast cancer surgery, pectoralis muscle flap, neck dissection) may be relative contraindications to HNS implant surgery and need to be evaluated on an individual basis.
   b. Prior sinonasal surgery
   c. Prior pharyngeal or skeletal OSA surgery
   d. Prior bariatric surgery
5. Medications
   a. Anticoagulants.
   b. Opiate pain medication, benzodiazepines, or other medications that can alter nocturnal control of breathing.
   c. Selective serotonin reuptake inhibitors (SSRIs), tricyclic antidepressants (TCAs), lithium, or other neuropsychiatric medication that can independently alter sleep architecture and continuity.
   d. Stimulant therapy (e.g., modafinil or methamphetamines) that may confound the assessment of daytime sleepiness.
6. Family history
   a. A strong family history of OSA may provide insight into the anatomic/structural vulnerability.
7. Social history
   a. Occupation
      i. **Occupations that include repeated mechanical trauma to the neck and chest (e.g., contact sports, martial arts) or the use of heavy firearms (e.g., hunting, law enforcement, military) may be relative contraindications to implantable HNS therapy due to possible damage to the device or patient discomfort. The pulse generator placement may be adjusted, however, to avoid contact with the stock of a rifle or shotgun.
      ii. OSA in truck drivers, airline pilots, railroad engineers, and other occupations involving public safety risk has additional implications on treatment and reporting of outcomes.
      iii. Shift workers may have residual sleep-related symptoms due to their circadian rhythm disturbance, even after otherwise successful OSA treatment.
   b. Alcohol: Evening alcohol use has been correlated with increased obstructive respiratory events.
   c. Tobacco: Smoking has been shown to independently increase the risk of moderate to severe OSA as well as increase sinonasal and pulmonary disease.
   d. Total sleep duration: Behaviorally induced insufficient sleep is one of the most common causes of daytime sleepiness and may confound the assessment of OSA treatment outcomes. Sleep deprivation has also been shown to exacerbate OSA.

Physical Examination

1. Anterior rhinoscopy
   a. Acquired nasal deformity, septal deviation, turbinate hypertrophy, rhinitis, nasal polyps, and other nasal valve pathology may increase upper airway resistance and directly contribute to sleep-disordered breathing.
   b. Increased nasal resistance may also increase negative intraluminal pressure in the pharynx and increase the fraction of maladaptive mouth breathing, further contributing to OSA pathophysiology.
   c. Nasal surgery designed to lower nasal resistance should be considered either in conjunction with or prior to pharyngeal surgery in most cases.
2. Facial skeleton
   a. Significant maxillary or mandibular hypoplasia may require orthodontic or orthognathic surgical correction prior to consideration of pharyngeal or HNS surgery.
   b. Occlusion:
      i. Angle's classification
      ii. Degree of overjet and overbite
3. Oral cavity
   a. Tongue ridging or scalloping suggests relative macroglossia in relation to the size of the mandible.

   b. Quality and quantity of dentition has implications on the availability of adjunctive custom mandibular repositioning devices (oral appliance) in the treatment plan.
   c. Height and width of the hard palate. A narrow high-arched soft palate may increase the difficulty of soft tissue work on the soft palate and may negatively affect treatment outcomes.
   d. The presence of large palatal tori may reduce operative exposure and make palatal surgery more technically challenging.
4. Oropharynx
   a. Sagittal configuration of the soft palate
   b. Length of the soft palate
   c. Modified Mallampati (MM) or Friedman Tongue Position (FTP)
   d. Size of the tonsils
   e. Size and structure of the lateral oropharyngeal wall
   f. Size and configuration of the uvula
5. Neck
   a. Circumference of the neck
   b. Position of the hyoid bone: A low or inferiorly positioned hyoid bone suggests a longer pharyngeal airway.
6. Chest
   a. To evaluate for chest wall deformity, scars, or other signs of prior surgery or trauma
7. Cranial nerves
   a. Examination with specific attention to the functional status of the hypoglossal nerves and the facial nerve
8. General health
   a. Blood pressure
   b. Cardiovascular
   c. Respiratory
   d. Mental
9. Flexible fiberoptic laryngoscopy
   a. Awake
   b. DISE

Imaging

1. Chest radiograph
   a. Preoperative screening
   b. Evaluate for cardiopulmonary disease.
   c. Rule out immobility of the hemidiaphragm.
2. Imaging of the facial skeleton may be indicated in select cases preoperatively, particularly in cases of prior mandibular surgery, suspected craniofacial abnormalities, or signs of maxillomandibular deficiency. Imaging studies may include:
   a. Lateral cephalometric radiograph
   b. Orthopantomogram
   c. Computed tomography (CT) three-dimensional imaging
3. Sinonasal imaging may be indicated in patients with suspected chronic sinonasal disease when simultaneous or staged nasal surgery is being considered with HNS surgery.
4. Modified barium swallow study may be indicated prior to expansion sphincter pharyngoplasty (ESP) or transpalatal advancement pharyngoplasty (TPA) in patients with baseline dysphagia or velopharyngeal insufficiency symptoms, particularly in those with swallowing problems after prior pharyngeal surgery.

Indications

1. Moderate to severe OSA patients who are not significantly obese and who are intolerant or have inadequate adherence with PAP therapy or other first-line medical device options
2. Drug-induced sedated endoscopy (DISE) is currently recommended to evaluate the anatomic location and pattern of pharyngeal collapse prior to proceeding with HNS therapy. Particular attention is paid to the pattern of palatal collapse and the degree of multilevel coupling between the protrusion of the tongue and enlargement of the retropalatal space. Early feasibility studies have demonstrated poorer results with a complete concentric pattern of palatal collapse but higher success rates with an anterior-posterior pattern of palatal collapse (Fig. 56.1).[6]
3. Patients who are willing to undergo implantation of a neurostimulation device should not have anticipated MRI requirements and should also have the ability and dexterity to operate a basic remote control.

Relative Contraindications

1. Patient factors
   a. High perioperative risk
   b. Anticoagulation
   c. Poor nutritional status
   d. Allergy to metal
   e. Occupation associated with repetitive trauma to the neck or chest

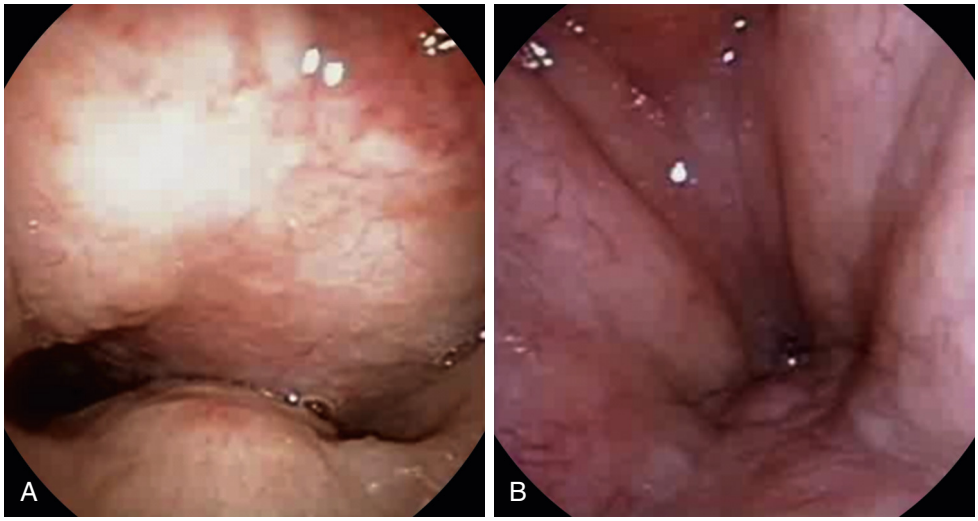

Fig. 56.1. Anterior-posterior versus circumferential velopharyngeal collapse during DISE. A primarily anterior-posterior pattern of velopharyngeal collapse **(A)** is favorable for hypoglossal nerve stimulation (HNS) therapy, while a circumferential pattern of collapse **(B)** is less likely to have a significant response to HNS therapy.

2. Anatomic factors
   a. Complete concentric pattern of palatal collapse on DISE
   b. Body mass index (BMI) greater than 32 kg/m^2

Preoperative Preparation

- Anesthesiology consultation if there is a concern regarding a difficult airway or intubation
- Hold or bridge anticoagulation.
- Have patient bring continuous positive airway pressure (CPAP) or oral appliance (if still available and in use) the day of surgery in case airway support is needed in the hospital.

OPERATIVE PERIOD

Only one HNS implantable device is FDA approved and commercially available in the United States at the time of publication. Although other systems may be available in the future, the operative portion of this chapter will focus on the procedure and technology components of the currently available system (Inspire Medical Systems, Minneapolis, Minnesota). The system consists of three implantable components: a pulse generator in a subcutaneous chest pocket, a stimulation cuff electrode on the distal portion of the hypoglossal nerve, and a pleural respiratory sensor in the intercostal space (Fig. 56.2).

Anesthesia

- General anesthesia with oral intubation
- Videolaryngoscope (i.e., GlideScope) and fiberoptic intubation equipment should be available if needed for a difficult intubation.
- Avoid long-acting muscle relaxant agents due to intraoperative nerve monitoring.

Positioning

- Supine position, head turned to the left, with exposure of the right side of the face, neck, and chest
- Shoulder roll for neck extension and right trunk roll for maximal exposure of the right side of the chest

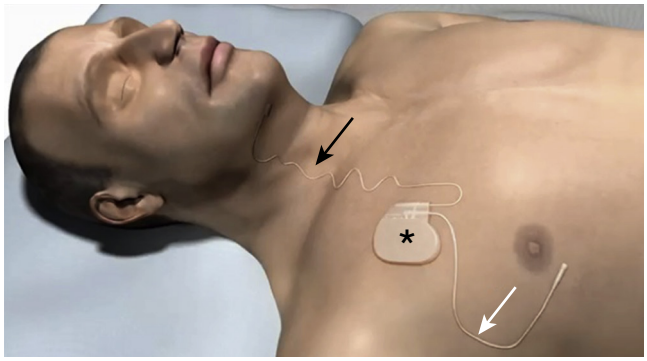

Fig. 56.2. Implantable upper airway stimulation hypoglossal nerve stimulation system. The hypoglossal nerve stimulation system consists of three implanted components: (1) an implantable pulse generator in a subcutaneous pocket in the upper chest *(asterisk)*, (2) a stimulation lead with a cuff electrode placed on the medial branch of the hypoglossal nerve in the submandibular space *(black arrow)*, and (3) a sensing lead to detect ventilatory effort placed in the intercostal space facing the pleura *(white arrow)*.

Perioperative Antibiotic Prophylaxis

- Standard intravenous antibiotics dose preoperatively

Monitoring

- Standard anesthesia and cardiopulmonary monitoring
- Intraoperative nerve monitoring with fine-wire electrodes in the genioglossus muscle and hyoglossus muscle

Instruments and Equipment to Have Available

- Intraoperative nerve monitoring system with bipolar stimulation probe
- Standard head and neck instrument set. Instrumentation and nerve dissection share similarities with parotidectomy.
- Monopolar and bipolar cautery
- Angled Debakey forceps and right angle clamp for placement of the cuff electrode on the nerve
- The three implantable HNS components: Stimulation cuff electrode, pulse generator, and pleural respiratory sensor
- Sterile telemetry unit and physician programmer for intraoperative device testing and programming

Key Anatomic Landmarks

- Cuff electrode placement
  - Junction of the digastric tendon and the antero inferior border of the submandibular gland
  - Free edge of the mylohyoid muscle
  - Breakpoint between the lateral hypoglossal nerve branches to the retractor muscles and the medial branches to the tongue protrusor muscles
  - Distal edge of the hyoglossus muscle
- Pulse generator placement
  - Pectoralis fascia
- Respiratory sensor placement
  - Fifth or sixth intercostal space
  - External intercostal muscle
  - Superior border of the lower rib (to avoid injury to the neurovascular bundle)

Prerequisite Skills

- Neck dissection
- Excision of the submandibular gland

Operative Risks

- Bleeding
- Nerve injury (cranial nerve XII or marginal branch of cranial nerve VII)
- Pneumothorax
- Poor cuff placement and suboptimal tongue movement
- Inadequate respiratory sensor waveform
- Device malfunction

Surgical Technique

- Surgical incision planning
  - The incision in the neck for the cuff electrode is similar to a standard submandibular gland incision but placed slightly more anteriorly to access the distal branches of the hypoglossal nerve. The incision is approximately 3 cm in length, between the mandibular body and hyoid, parallel to or within a natural skin crease (Fig. 56.3). The right side is most commonly used for implantation, unless there is a contraindication requiring use of the left side.

- The chest incision for the pulse generator is placed ipsilateral to the planned neck incision, approximately 4 cm below the clavicle and medial to the deltopectoral groove to avoid restriction of arm movement (Fig. 56.4).
- The respiratory sensing lead incision is placed ipsilateral to the planned chest incision, overlying the fifth or sixth rib space at approximately the intersection of the anterior axillary line and the nipple line.

- Preparation and draping
  - Fine-wire electrodes are placed in the genioglossus muscle and hyoglossus muscle on the planned side and connected to the nerve monitoring system.
  - Standard sterile preparation including iodine impregnated drape (Ioban)
  - View of the tongue is maintained through a clear sterile drape to allow for intraoperative assessment of tongue movement.
- Cuff electrode placement
  - An incision is made in the right upper neck and carried through the platysma, exposing the junction of the digastric tendon and the antero inferior border of the submandibular gland.
  - The gland is retracted postero superiorly and the free edge of the mylohyoid retracted antero superiorly to expose the floor of the submandibular triangle where the hypoglossal nerve is identified.
  - The ranine vein is clamped, divided, and ligated.
  - Anatomic landmarks and intraoperative nerve monitoring are used to selectively capture the distal tongue protrusor branches supplying the genioglossus muscle activity and to exclude branches innervating the tongue retractor muscles (Fig. 56.5).
  - The stimulation cuff electrode is placed around the distal protrusor branches and secured to the digastric tendon. If accessible, the C1 branch coursing along the inferior aspect of the hypoglossal nerve and innervating the geniohyoid muscle may also be included in the cuff.
- Pulse generator placement
  - A second incision is made in the right upper chest approximately 4 cm below the clavicle. The incision should be roughly centered over the right pectoralis muscle. Placing the pulse generator more laterally near the deltopectoral groove may cause it to interfere with shoulder movement.
  - A subcutaneous pocket overlying the pectoralis fascia is created for placement of the pulse generator.
- Respiratory sensor placement
  - A third incision is made in the right lateral chest at approximately the intersection of the anterior axillary line and the nipple line for placement of the pleural respiratory sensor.
  - Dissection is carried to the chest wall, staying inferior to the pectoralis muscle and anterior to the serratus muscle, until the external intercostal muscle of the exposed rib space is identified.

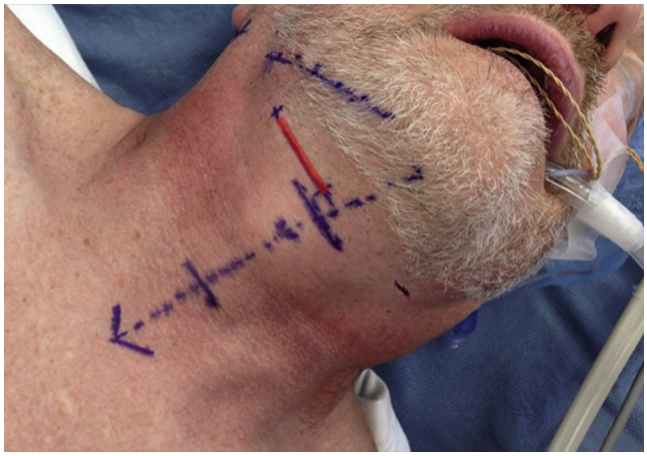

Fig. 56.3. Cuff electrode incision planning. The incision in the neck for the cuff electrode *(red line)* is placed in the submandibular triangle. It is placed more anteriorly and superiorly than a standard submandibular gland incision to ease access of the distal branches of the hypoglossal nerve. It is ideally placed in a natural skin crease for cosmesis.

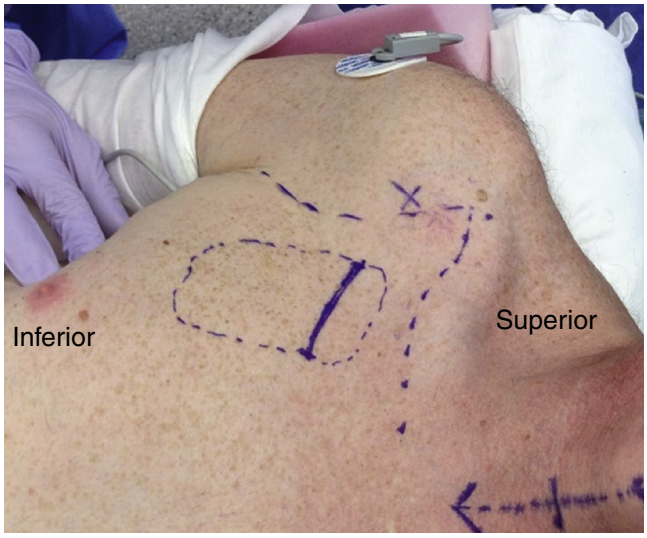

Fig. 56.4. Pulse generator incision planning. The chest incision for the pulse generator is placed on the ipsilateral side as the planned neck incision, approximately 4 cm below the clavicle and medial to the deltopectoral groove to avoid restriction of arm movement.

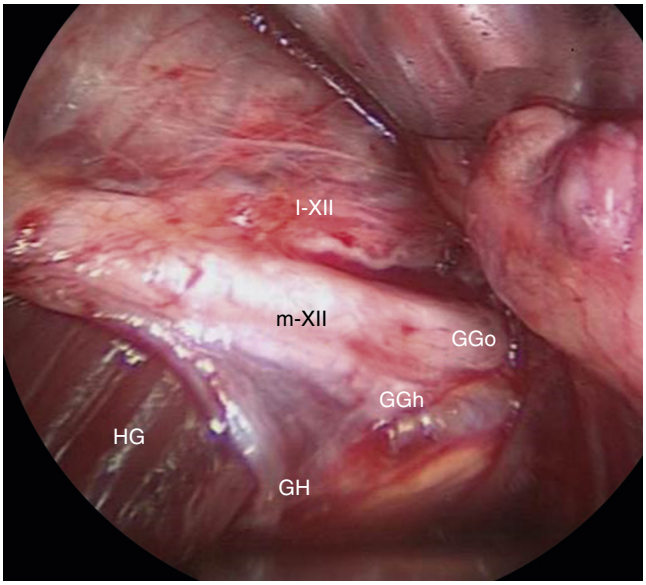

Fig. 56.5. Intraoperative neuroanatomy of the hypoglossal nerve. The tongue protrusor branches (m-XII, GGo, GGh, and GH) are selectively included in the cuff electrode, while the retractor branches (l-XII) are excluded, to maximize tongue protrusion during stimulation. *GGh,* Medial branch to the horizontal fibers of the genioglossus muscle; *GGo,* medial branch to the oblique fibers of the genioglossus muscle; *GH,* medial branch to the geniohyoid muscle; *HG,* hyoglossus muscle; *l-XII,* lateral hypoglossal nerve branches to the styloglossus and hyoglossus muscles; *m-XII,* medial hypoglossal nerve branches to the genioglossus and geniohyoid muscles.

- The sensor is inserted, facing the pleura, into a tunnel between the external and internal intercostal muscles in approximately the fifth or sixth intercostal space and secured to the chest wall.
- Completion
  - The sensing lead and stimulation lead are each tunneled into the subcutaneous pocket in the right upper chest and connected to the implantable pulse generator. The generator is then secured to the pectoralis fascia.
  - The sterile telemetry unit is brought into the field for device interrogation and programming. Electrical stimulation of the appropriate distal protrusor branches and an adequate respiratory sensing lead waveform are confirmed, followed by visual confirmation of adequate tongue protrusion. The three wounds are then irrigated and closed in a multilayer fashion with absorbable suture.
  - Steri-strips and pressure dressings are applied. Drains are not used.

Common Errors in Technique

- Placing the incision in the neck too far posteriorly, similar to a standard submandibular gland approach, may create a long tunnel and difficult access to the distal branches of the hypoglossal nerve.
- Incorrect placement of the cuff electrode. A common pitfall involves inclusion of a distal lateral retractor branch in the cuff. Intraoperative nerve monitoring and/or observation of tongue movement should identify suboptimal placement of the cuff. Repositioning of the cuff should be directed accordingly.
- Violating the external jugular vein during the tunneling process. Staying anterior to the external jugular vein may avoid troublesome intraoperative bleeding.

POSTOPERATIVE PERIOD

Postoperative Management

- Radiographs of the neck and chest are obtained in the recovery room prior to discharge to document baseline position of the components.
- Disposition: Unlike traditional anatomy-altering sleep surgery procedures, the majority of HNS patients can be safely discharged the same day given the lack of airway surgery, the minimal or lack of opioid pain medication use, and absence of significant obesity per the screening criteria.
- Diet: Regular
- Activity: Avoid strenuous activity or heavy lifting, particularly repetitive activity of the right arm, for the first 2 to 3 weeks.
- Medication: Over-the-counter acetaminophen and/or nonsteroidal anti-inflammatory medication
- Follow-up:
  - Postoperative check-up and wound examination 1 to 2 weeks after surgery
  - Device activation and programming in the outpatient office approximately 1 month after surgery
  - Postoperative sleep study to evaluate therapy effectiveness and to optimize stimulation settings approximately 2 months after surgery (1 month after activation and therapy initiation)
  - Standard long-term outpatient follow-up to monitor therapy adherence, to assess symptomatic improvement and subjective outcomes, and to check device

COMPLICATIONS

- Procedure-related
  - Bleeding
  - Infection, including possible need for device explants
  - Hematoma or seroma
  - Injury to the hypoglossal nerve and associated change in speech or swallowing
  - Injury to the marginal branch of the facial nerve and associated lower lip weakness
  - Pneumothorax
- Therapy-related
  - Abrasion of the tongue
  - Discomfort or sleep disturbance (insomnia) due to stimulation
  - Unfavorable tongue protrusion and inadequate therapy response

ALTERNATIVE MANAGEMENT PLAN

At any stage of OSA evaluation and management, patients should always be offered to continue or revisit PAP or other medical device therapy. Upper airway reconstructive surgery options may also be considered as an alternative to HNS therapy. Finally, combination therapy with more than one medical and/or surgical treatment may be required in some patients, particularly those with more severe disease.

DISCUSSION

Evidence-Based Medicine Question

What is the long-term safety and effectiveness of HNS therapy in patients who meet recommended clinical and anatomic screening characteristics?

Editorial Comment

The multicenter prospective Stimulation Therapy for Apnea Reduction (STAR) Trial demonstrated that approximately two-thirds of participants met responder status for objective measures of OSA and even more reported significant improvements in snoring, daytime alertness, and sleep-related quality of life. Furthermore, the results were maintained at 2- and 3-year follow-up periods. Subjective adherence rates were high while serious device- and procedure-related adverse events were very low, including no cases of permanent nerve injury.[3,4]

Ryan Soose

Access the review questions online at http://www.expertconsult.com



REFERENCES

1. Strollo Jr PJ, Soose RJ, Maurer JT, de Vries N, Cornelius J, Froymovich O, et al. Upper-airway stimulation for obstructive sleep apnea. N Engl J Med 2014;370:139–149.
2. Woodson BT, Gillespie MB, Soose RJ, Maurer JT, de Vries N, Steward DL, et al. Randomized controlled withdrawal study of upper airway stimulation on OSA: short- and long-term effect. Otolaryngol Head Neck Surg 2014;151:880–887.
3. Soose RJ, Woodson BT, Gillespie MB, Maurer JT, de Vries N, Steward DL, et al. Upper airway stimulation for obstructive sleep apnea: self-reported outcomes at 24 months. J Clin Sleep Med 2016;12:43–48.
4. Woodson BT, Soose RJ, Gillespie MB, Strohl KP, Maurer JT, de Vries N, et al. Three-year outcomes of cranial nerve stimulation for obstructive sleep apnea: the STAR trial. Otolaryngol Head Neck Surg 2016;154:181–188.
5. Dedhia RC, Strollo PJ, Soose RJ. Upper airway stimulation therapy: past, present, and future. Sleep 2015;38(6):899–906.
6. Vanderveken OM, Maurer JT, Hohenhorst W, Hamans E, Lin HS, Vroegop AV, et al. Evaluation of drug-induced sleep endoscopy as a patient selection tool for implanted upper airway stimulation for obstructive sleep apnea. J Clin Sleep Med 2013;9:433–438.

REVIEW QUESTIONS

1. Which of the following muscles is the primary upper airway dilator?
   a. Hyoglossus
   b. Genioglossus
   c. Styloglossus
   d. Geniohyoid
   e. Stylohyoid

2. Electrical stimulation of nerve branches to which of the following muscles will result in retraction of the tongue?
   a. Genioglossus
   b. Hyoglossus
   c. Styloglossus
   d. Both B and C
   e. A, B, and C

3. Based on the current available literature, which of the following clinical characteristics are contraindications to HNS therapy?
   a. BMI of 42 kg/m^2
   b. AHI of 62
   c. Anterior-posterior pattern of palatal collapse on DISE
   d. Patient age of 82
   e. Presence of a cardiac pacemaker

57 Hyoid Suspension

Andrea Lewis, Allison Ordemann

INTRODUCTION

It is estimated that adequate adherence to continuous positive airway pressure (CPAP) may vary from 28% to 80%.[1] For patients with moderate-to-severe obstructive sleep apnea (OSA) who fail CPAP, a variety of surgical procedures are available. To determine the surgical intervention most suitable, the airway is fully evaluated for level, pattern, and degree of airway collapse. In a prospective study of 108 patients, Kezirian et al. found hypopharyngeal collapse in 83% to 84% of subjects undergoing sleep endoscopy.[2] Treating the base of the tongue and epiglottis can be difficult, with a number of available procedures being invasive, thus requiring significant recovery time and the potential for complications.

Hyoid suspension (HS) is a relatively noninvasive technique with a low complication rate, often used to address anteroposterior (AP) collapse at the base of the tongue and epiglottic levels (Fig. 57.1). It can be performed as an isolated procedure or in combination with those addressing velopharyngeal, oropharyngeal, or nasal obstruction.

KEY OPERATIVE LEARNING POINTS

1. Operative procedures for OSA should minimize morbidity and preserve function. Leave the stylohyoid muscles attached to the hyoid bone. This is the key mechanism that advances the base of the tongue when the hyoid is suspended to the mandible.
2. When suspending the hyoid, make sure the patient's head is in normal pillow supine position. Adequate suspension should be obtained without overtightening to avoid suture breakage or complications.
3. The patient should be reevaluated with polysomnography (PSG) and long-term follow-up after HS is necessary, to evaluate for return of symptoms or signs of progression of OSA.

PREOPERATIVE PERIOD

History

1. History of present illness
   a. Sleep architecture: Assess hours of sleep per night, number of nighttime awakenings, and use of sleep medications.
   b. Sleep-related symptoms: Evaluate for the presence of snoring, witnessed apneas, restless sleep, sleep maintenance or onset insomnia, perspiration during sleep, nocturnal enuresis, nighttime seizures, narcolepsy, and restless leg symptoms.
   c. Daytime-related symptoms: Evaluate for the presence of excessive daytime sleepiness, morning headaches, and awakening feeling tired.
   d. Changes in weight should be quantified over a defined period of time.
   e. PSG: Has a PSG been obtained? If so, what are the results? When was the study done? Has there been any weight or health changes since the study? PSG should always be obtained prior to any surgical procedures.
   f. CPAP use: Has this been trialed yet? If so, is the patient able to tolerate it? If the patient is not able to tolerate it, why? Has any other medical therapy been tried?
2. Past medical history
   a. Medical comorbidities
      1) Hypertension (controlled?), cardiac arrhythmias (atrial fibrillation?), congestive heart failure, obesity hypoventilation syndrome, pulmonary hypertension, chronic obstructive pulmonary disease, neuromuscular/neurodegenerative disorder, additional sleep disorders
   b. Surgical history
      1) Tonsillectomy, adenoidectomy, septoplasty, turbinate reduction, rhinoplasty, bariatric surgery
   c. Family history
      1) Anesthesia-related complications
   d. Medications
      1) Antiplatelet drugs
      2) Herbal products
      3) Alcohol
   e. Social history
      1) Smoking status
      2) Caffeine intake per day
3. Epworth sleepiness scale

   A subjective patient self-assessment tool to determine sleepiness level with various activities. Comparison of preoperative and postoperative scores may assist in the evaluation of subjective outcome measures.

Physical Examination

1. Vital signs
   Resting pulse oximetry and body mass index (BMI) should be recorded.
2. Nose
   Evaluate for deviated septum, inferior turbinate hypertrophy, and nasal valve collapse.
3. Oral cavity and oropharynx
   Note size and presence or absence of tonsils, ability to visualize the uvula, soft palate, and hard palate for determination of Friedman tongue position. This can be instrumental in guiding surgical management.
4. Neck
   Measure the circumference of the neck. Note whether there is a large amount of subcutaneous adipose tissue or musculature, especially over the hyoid, because this may limit surgical success. Palpate laryngeal landmarks (i.e., hyoid bone and thyroid cartilage).
5. Flexible supine nasopharyngoscopy
   Flexible supine endoscopy is the most important preoperative portion of the examination. This can be done awake in the office and/or under sedation in the operating suite. We prefer drug-induced sedation endoscopy in the operating suite because it best mimics the sleep state. If performed in the office, addition of the Müller maneuver (inhalation with nasal and oral passages closed) can help to simulate an obstructive event. During endoscopy, the level (velopharyngeal, oropharyngeal, or hypopharyngeal), degree, and pattern of upper airway collapse is noted to determine the most suitable surgical intervention. Perform a jaw thrust maneuver to evaluate whether collapse improves. Note VOTE (velum, oropharynx, tongue base, epiglottis) classification.

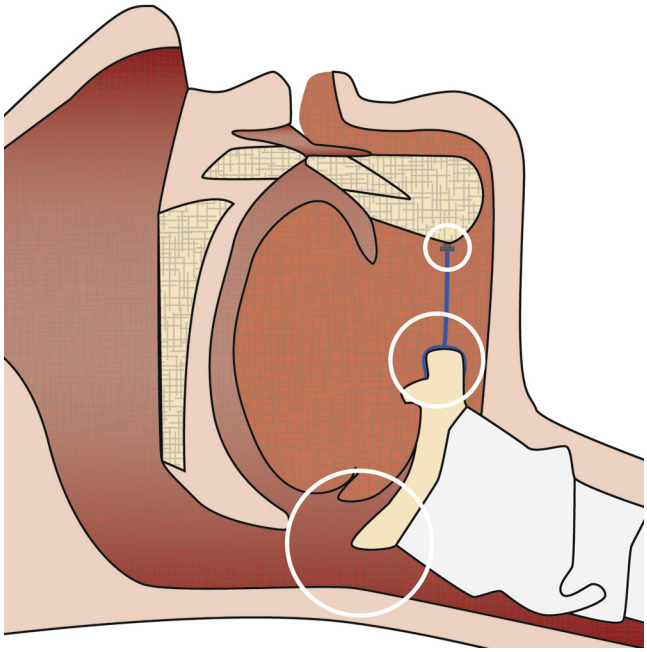

Fig. 57.1. Hyoid to mandible suspension showing favorable expansion of the hypopharyngeal space.

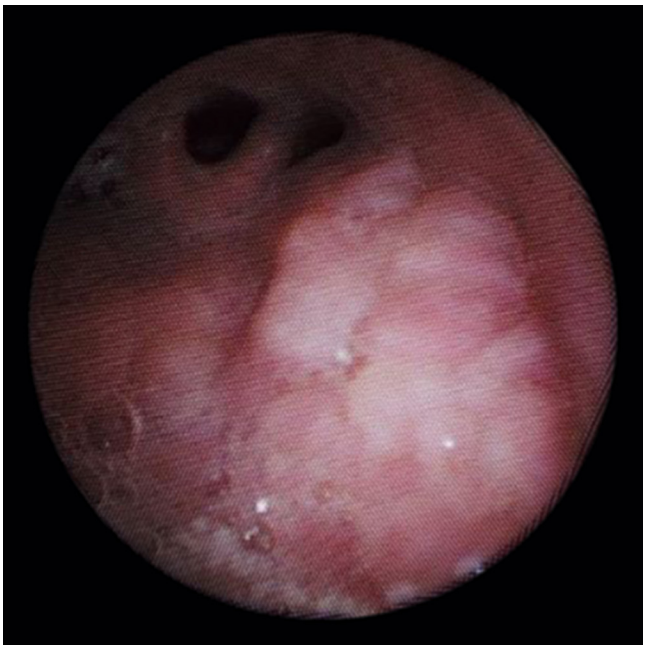

Fig. 57.2. Collapse of the base of the tongue and epiglottis.

Procedures

Polysomnography

Preoperative sleep testing with home portable monitoring or in-lab PSG is necessary for diagnosis of OSA. Medical necessity for treatment is often considered an apnea-hypopnea index (AHI) of greater than 15 or an AHI greater than 5 with sleep-related symptoms or comorbidities. Prior to surgical intervention, all patients should demonstrate inability to successfully use CPAP or other medical therapy options.

Imaging

No required imaging procedures, although lateral cephalometric radiograph may be considered for preoperative planning and documentation of hyoid position.

Indications

1. Patients with moderate-to-severe OSA (AHI of 15 or greater), who have failed adequate trial of CPAP or other medical therapy, with specific hypopharyngeal collapse at the base of tongue or epiglottis, as demonstrated on supine awake and/or sedated flexible endoscopy (Fig. 57.2)
2. Often used as a multilevel treatment of OSA in conjunction with other sleep surgical interventions aimed at addressing nasal, velopharyngeal, and/or oropharyngeal collapse

Contraindications

1. Medical comorbidities presenting increased risk for undergoing general anesthesia or upper airway procedures
2. Prior Sistrunk procedure

Preoperative Preparation

1. Preoperative anesthesia visit should be performed on all patients due to their history of OSA. Bloodwork, chest radiograph, electrocardiogram, and additional preoperative testing are dictated by the patient age, comorbidities and symptoms, and factors as with any procedure using general anesthesia.
2. Discontinue antiplatelet drugs.

OPERATIVE PERIOD

Anesthesia

General

Dependent on technique and surgeon preference, the type of anesthesia will vary. We prefer general anesthesia for patient comfort.

Awake sedation

Awake sedation may also be used as an alternative. One advantage is to allow for better postoperative evaluation of hypopharyngeal airway collapse with drug-induced supine sleep endoscopy. This should be used with caution in patients with severe OSA or those suspected to be difficult to intubate.

Local

Local anesthetic has been described as a viable technique for patients undergoing isolated HS to the thyroid cartilage.

Positioning

Supine

The head of the bed should be rotated 90 to 180 degrees away from the anesthesiologist. This will vary depending on surgeon preference and room setup. This is done to allow room for one or two assistants who are placed directly opposite the surgeon and/or at the patient's head.

Perioperative Antibiotic Prophylaxis

First-generation cephalosporin

Cefazolin is often used in the our institution because this provides adequate gram-negative and gram-positive coverage. The typical dose is 2 g given intravenously prior to incision.

Clindamycin
Clindamycin is used if the patient is allergic to penicillin. The typical dose is 600 mg given intravenously prior to incision.

Monitoring

Routine general anesthesia monitoring

Instruments and Equipment to Have Available

1. Standard soft tissue neck instrument set
   This should include knife handle, Senn retractors, Army-Navy retractors, Molt elevator #9, hemostat or other blunt dissecting instruments, Lahey or Allis clamp, toothed forceps, and needle driver.
2. Monopolar electrocautery: for division of subcutaneous tissues and musculature
3. Bipolar electrocautery: for control of bleeding around nerves. Can be used instead of monopolar electrocautery in the event of a pacemaker or defibrillator device.
4. For hyoid to mandible suspension, specific equipment will be needed. Two systems are currently available on the market.
   a. Encore (Siesta Medical, Los Gatos, CA) system
      1) A drill is necessary with this system.
   b. AIRvance (Medtronic, Dublin, Ireland) system

Key Anatomic Landmarks

1. Hyoid Bone: A horseshoe-shaped bone in the anterior midline of the neck situated between the base of the mandible and the thyroid cartilage that aids in tongue movement and elevation of the larynx anteriorly and superiorly in swallowing for airway protection. An inferiorly positioned hyoid is strongly associated with hypopharyngeal collapse.
2. Thyroid cartilage: A shield-shaped cartilage that protects the vocal cords and whose movement produces a change in vocal pitch. Its easily palpable superior thyroid notch marks midline, and it is attached to the hyoid via the thyrohyoid membrane.
3. Stylohyoid muscle: A slender muscle attaching at the junction of the lesser and greater cornu of the hyoid bone originating from the styloid process. It acts to elevate the hyoid bone during swallowing. This should be preserved to ensure proper advancement of the base of the tongue.
4. The inferior border of the mandible.

Prerequisite Skills

1. Familiarity with midline neck and floor of mouth anatomy to be able to correctly identify the hyoid bone and associated musculature
2. Efficiency in drug-induced sleep endoscopy and ability to discern the level, pattern, and severity of airway collapse

Operative Risks

1. Injury to the hypoglossal nerve
   If dissection around the hyoid is carried out too far laterally or superiorly, the hypoglossal nerve may be damaged. This can be avoided by staying in the midline, identifying the hyoid bone with blunt dissection, and carefully skeletonizing only the central portion of the hyoid bone.
2. Injury to the internal branch of the superior laryngeal nerve
   Limiting the dissection near the lesser cornu will minimize the risk of injury to the superior laryngeal nerve.

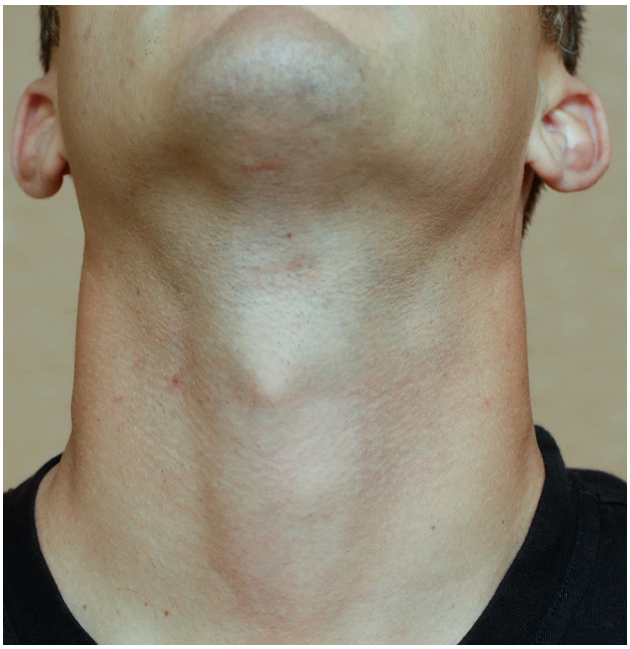

Fig. 57.3. Healed incisions.

3. Dental injury
   Placement of bone screws in the mandible is performed along the posterior lingual surface of the mandible at the level of the canines. If the screw is placed too far superiorly, injury to the tooth roots can occur. Screws are typically placed 1 cm superior from the inferior border of the mandible.
4. Bleeding
   Bleeding is managed in standard fashion with bipolar electrocautery and suture ligation.

Surgical Technique

Hyoid to Mandible Suspension

- Surgical incisions marked
  We use two incisions on the anterior neck (Fig. 57.3). The first is a 2-cm horizontal incision near the hyoid in a neck crease. The second is a 2-cm or smaller horizontal incision in the submental area posterior to the mentum.
  Some surgeons prefer one larger incision placed in the submental region above the hyoid. The author We prefer two incisions for better visualization throughout the surgery and flexibility to camouflage the incisions.
- Local anesthetic injection
  Lidocaine (1%) with epinephrine (1:100,000). A small amount is injected subcutaneously at planned incision sites. Avoid excessive amounts that may obscure laryngeal landmarks.
- Standard surgical preparation and draping
  Betadine solution, or chlorhexidine if the patient is allergic to iodine. The entire midline neck, including submental area, should be prepped. Four sterile towels should be placed, leaving the midline neck and chin visible.
- Skin incisions and dissection
  The skin is incised with a no. 15 blade at previously described incisions. Monopolar cautery is used to extend skin incisions through the subcutaneous adipose tissue and platysma layers. Next, the hyoid bone is identified through the inferior incision and inferior border of the mandible through the submental incision. Care is taken to stay right on the hyoid bone and limit dissection so that the muscles can remain attached.

- Skeletonization of the lingual surface of the inferior mandible approximately 1.0 cm lateral to the midline on either side
  Using monopolar cautery and a Molt elevator #9 through the submental incision, a small area of bone should be cleared of muscular and soft tissue attachments as described in preparation for insertion of bone screws. Avoid skeletonizing large areas.
- Insertion of bone screws into the mandible
  There are various products on the market currently to accomplish this. Depending on the system used, these steps will vary slightly. We have used both the handheld self-drilling AIRvance system and the Encore system, which requires predrilled 1.5-mm holes. In either system the bone screws are placed along the inferior lingual surface of the mandible in a region previously skeletonized. Screws should not be placed more than 1 cm superior from the inferior edge to avoid damage to the tooth roots. In the AIRvance system, two sutures are embedded within the bone screw and used in the next step.
- Placement of looping sutures around the hyoid bone
  A Lahey or Allis clamp should be placed around the hyoid bone to facilitate this step.
  In the Encore system the provided suture passer is passed from inferior to superior around the hyoid. The working suture is then loaded into the suture passer and brought around the hyoid bone as the passer is removed. The loops of the two suspension sutures are then placed through the loop of the working suture, which is then pulled so that the suspension sutures are around the hyoid bone. Girth hitches are created by pulling the tails of the suspension sutures through the loops and tightening (Fig. 57.4A and B).
  In the AIRvance system the looped sutures are embedded within the bone screws. A 1-inch McGowan needle is used to pass the sutures around the hyoid. On one side the suture is passed in an inferior to superior manner, whereas the contralateral side should be passed superior to inferior to allow opposing suture ends (Fig. 57.5A). Each suture should be passed twice around the hyoid. An additional suture can be used as a working suture and tightened to the suspension sutures to prevent having to pass each suture around the hyoid more than once.
- Tightening of sutures
  At this point, we prefer to use a flexible endoscope, which should be passed by an assistant for visualization of the hypopharynx to ensure that tightening the sutures to the airway will improve the airway space and does not retroflex the base of the tongue. Sutures should be tightened until adequate improvement in the anteroposterior dimension of the hypopharyngeal airway is achieved. Usually this requires approximately 1.5 cm of anterior superior pull with the patient's head in the neutral position.
  In the Encore system the tightened sutures are locked in place using a binary screw with a bone screw and a set screw. Subsequently the sutures are passed through the holes in the screw system. The set screws are then used to hold the sutures in place in position (see Fig. 57.4C). In the AIRvance system the tightened sutures are tied in a standard fashion with multiple surgeon's knots (see Fig. 57.5B).
- Hemostasis is obtained.
  In the event of any bleeding, which is rare, bipolar electrocautery should be used prior to wound closure.
- Irrigation of the wound with antibiotic solution
- Closure of the incision
  Closure can be performed to surgeon preference. We prefer to reapproximate the platysma and subcutaneous tissues with 4-0 Vicryl in an interrupted, buried fashion. The skin is closed with Dermabond. A drain is typically not used, although this has been described in the literature in an effort to prevent a seroma.
- Dressing
  A pressure dressing, such as the Jobst fascioplasty elastic dressing, is placed.

Common Errors in Technique

1. Overskeletonizing the hyoid bone: Release of the stylohyoid muscle will decrease the effectiveness of the surgery and may lead to aspiration postoperatively.
2. Difficulty placing bone screws: Check to ensure that the muscle attachments are completely removed from the mandible at the desired placement site to ensure proper seating of bone screws.
3. Incorrectly looping sutures: When using the AIRvance system, the surgeon must ensure that the contralateral sutures are looped in opposing directions around the hyoid to have the correct vector pull.
4. Suture tightening: The sutures must be tightened enough that the patient receives maximal benefit from an airway standpoint. However, tightening them too much may lead to aspiration or suture breakage, which may require further surgery.
5. Failure to create subplatysmal dissection tract between skin incisions: This may lead to unsightly suture lines under the skin.

POSTOPERATIVE PERIOD

Postoperative Management

1. Overnight observation: Patient is kept overnight in a monitored bed with pulse oximetry.
2. CPAP use restarted at current or decreased settings, if tolerated
3. Pain medication: Narcotic pain medication should be limited to avoid suppression of respiratory drive, but typically patients are discharged with liquid hydrocodone.
4. Postoperative steroids: Intravenous dexamethasone is given while in the hospital. Oral steroid course is often provided at discharge.
5. Postoperative antibiotics: 1 week of amoxicillin-clavulanate or comparable oral antibiotic

Complications

1. Dysphagia
   Temporary difficulty and discomfort with swallowing is expected. Patients should be counseled preoperatively about this expectation. This may last up to 4 weeks but usually resolves within the first 1 to 2 weeks.
2. Aspiration
   The internal branch of the superior laryngeal nerve supplies sensation to the supraglottic airway, and injury may lead to aspiration. Patients have also had aspiration develop after aggressive suspension, leading us to believe that the hyoid should not be too aggressively suspended. This is treated with partial release. Aspiration is usually transient.
3. Seroma and Hematoma
   A seroma should be drained with a large-gauge needle, and a compressive dressing should be placed. If a hematoma is occurring rapidly, the incision should be opened and the patient should be taken back to the operating suite to obtain hemostasis. Some surgeons leave in a drain for 1 to 2 days.
4. Cellulitis or breakdown of skin incision
   Treat conservatively with broad-spectrum antibiotics and local wound care.
5. Breakage of suspension material
   If this occurs, further surgical management will be needed. Alternative surgical interventions can be considered.

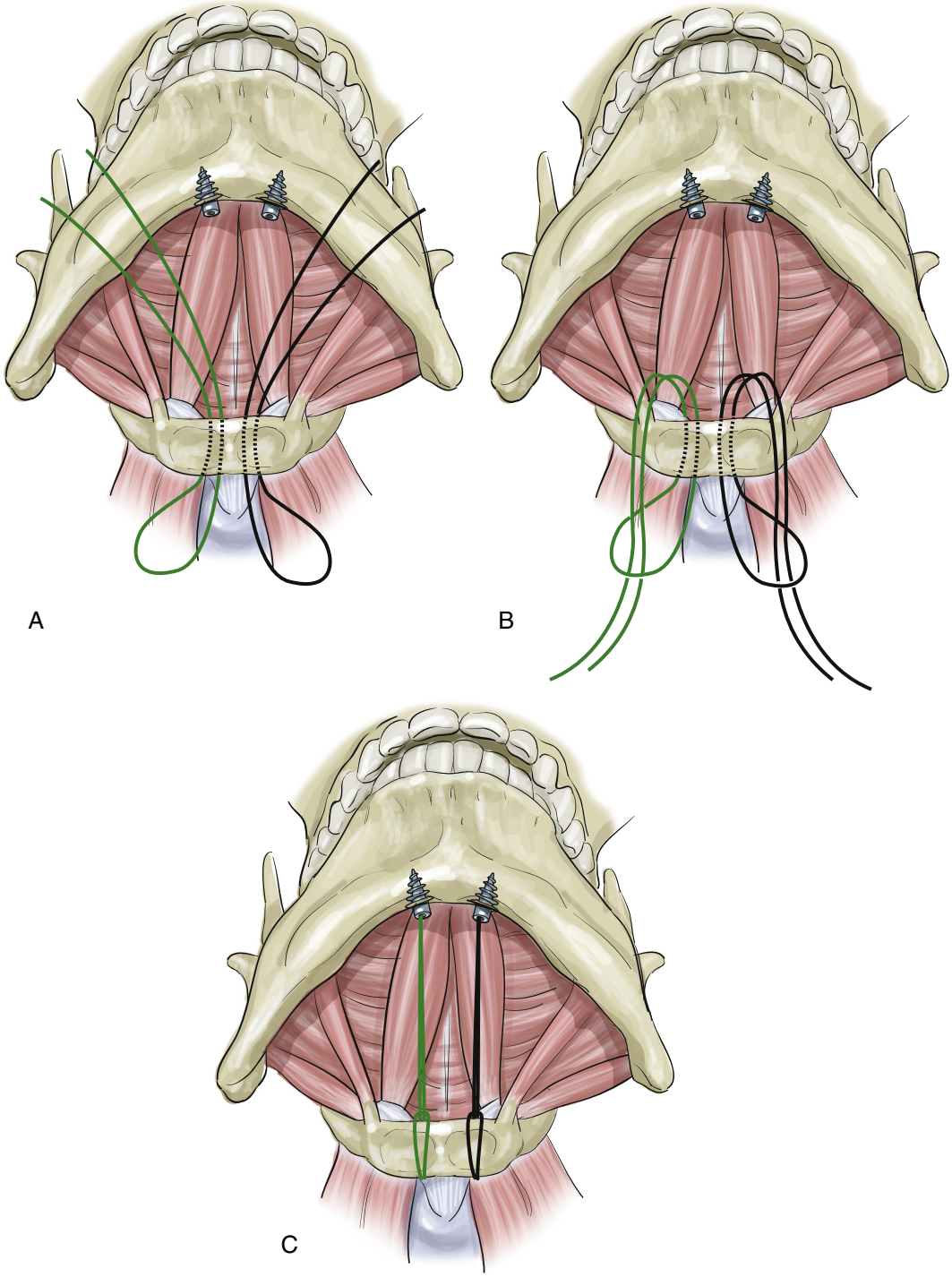

Fig. 57.4. Hyoid to mandible suspension technique using the Encore system. **A**, The loops of the suspension sutures are placed around the hyoid bone using the working suture. **B**, Girth hitches are created by pulling the tails of the suspension sutures through the loops and tightening. **C**, The sutures are passed through the holes in the screw system. The set screws are used to hold the sutures in place.

Alternative Management Plan

1. Other surgical interventions to address hypopharyngeal collapse: There are a variety of alternative surgical therapies to address base of tongue and hypopharyngeal collapse. These include tongue base reduction techniques (midline glossectomy, lingual tonsillectomy, radiofrequency ablation of the tongue), genioglossus advancement, maxillomandibular advancement, and hyoepiglottoplasty. These procedures are not suitable for every patient and should be carefully selected on an individualized basis.
2. Weight Loss: Many OSA patients are overweight. Weight loss can lead to improvement in AHI in a large percentage of these patients and should always be encouraged.
3. Continued CPAP use: If the patient is not a suitable operative candidate or does not wish to undergo invasive techniques, alternative CPAP masks should be trialed to improve compliance. Different masks include nasal pillows, nasal prongs, and nasal and oral masks.

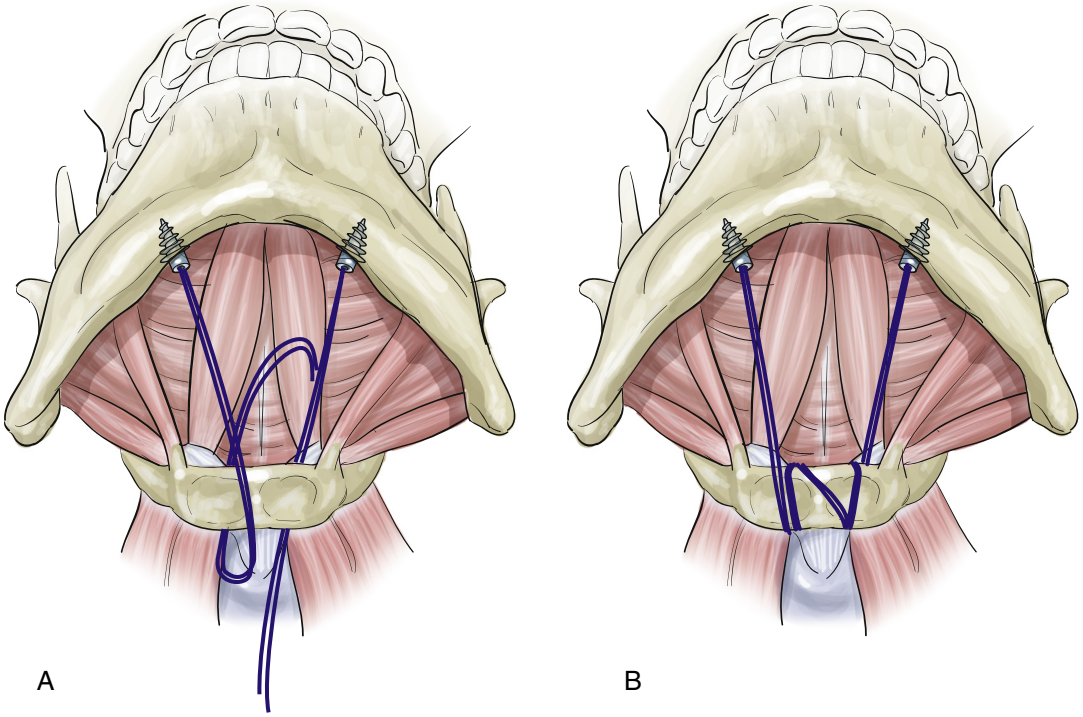

Fig. 57.5. Hyoid to mandible suspension technique using the AIRvance system. **A**, Suspension suture is passed inferior to superior on one side and superior to inferior on the contralateral side. Each suture is passed twice. **B**, The tightened sutures are tied to each other with multiple surgeon's knots.

DISCUSSION

Evidence-Based Medicine Question

What is the efficacy of hyoid to mandible suspension when used as part of a multilevel airway surgical approach? Is the efficacy better or worse than hyoid to thyroid suspension when used as part of a multilevel airway surgical approach? How does BMI affect surgical success?

HS can be performed as hyoid to mandible, as described previously, or hyoid to thyroid. Original description of the procedure was that of using a fascia lata sling suspending the hyoid from the mandible. This was modified to the hyoid to thyroid suspension to reduce the morbidity of the surgery.[2] With advances in technology, hyoid to mandible suspension has become much less invasive, requiring minimal dissection and short operative length.

There is little in the literature directly comparing the two variations of the procedure. Indeed, most of the literature on HS outcomes has been done on the hyoid to thyroid suspension modification. However, Gillespie et al. reported a surgical success rate (defined as a >50% reduction in AHI and AHI <20 postoperatively) in 70% of their patients undergoing hyoid to mandible suspension as part of a multilevel upper airway surgery.[3] An evidence-based medicine review on hypopharyngeal surgery in OSA by Kezirian and Goldberg showed that surgical success rates (defined the same way) ranged from 17% to 78% in patients undergoing hyoid to thyroid suspension as part of a multilevel upper airway surgery.[4] Bowden et al. performed the previously described study with the lowest success rate (17%). She compared her results to that of Neruntarat et al. (2003) and found her population to have a statistically significant larger BMI (average BMI of 34.1 vs. 29.4, respectively) and lower nadir oxygen saturation on preoperative sleep study (72.7% vs. 82.1%, respectively).[5]

Therefore the literature supports the relative success of hyoid to mandible suspension in comparison with that of hyoid to thyroid suspension, although this is debatable given the paucity of data. Some feel that this is due to the anterosuperior vector of pull on the hyoid with hyoid to mandible suspension, which allows for greater hypopharyngeal displacement than that of the anteroinferior vector of hyoid to thyroid suspension. Others still feel the hyoid to thyroid technique to be less invasive and feel that it adequately stabilizes the base of the tongue and epiglottis, preventing collapse during sleep. Some surgeons also feel that hyoid to thyroid may be more successful in male patients versus female patients, given the difference in anatomy.

Do additional procedures improve outcomes of HS or can it be used as a stand-alone procedure?

A MEDLINE review by Randerath et al. showed effectiveness of isolated HS for OSA to be 49.5% when averaging the success rates from three studies, assigning this a grade C recommendation level. Stronger recommendation level (grade B) was given to performing HS as part of a multilevel airway surgery (MLS), citing two level 2b studies finding a significant increase in effectiveness in those undergoing HS in MLS when compared with those not undergoing HS in MLS.[6]

Editorial Comment

The hyoid bone has key ligamentous and muscular attachments to the tongue and to the walls of the hypopharynx. HS provides a reconstructive method to enlarge and stabilize the hypopharyngeal portion of the upper airway with relatively low morbidity and risk. HS may further improve outcomes when combined with palatal surgery as part of a multilevel treatment plan. As with other surgical procedures for OSA, proper phenotyping of the upper airway and patient selection are critical to success. More research is needed to better understand the mechanism of action, most effective surgical technique, and selection of the most appropriate surgical candidates.

Ryan Soose

Access the review questions and additional sources list online at http://www.expertconsult.com

REFERENCES

1. Lin HC, Friedman M, Chang HW, et al. The efficacy of multilevel surgery of the upper airway in adults with obstructive sleep apnea/hypopnea syndrome. Laryngoscope 2008;118(5):902–908.
2. Kezirian EJ, White SP, Malhotra A, et al. Interrater reliability of drug-induced sleep endoscopy. Arch Otolaryngol Head Neck Surg 2010;136:393–397.
3. Gillespie MB, Ayers CM, Nguyen SA, et al. Outcomes of hyoid myotomy and suspension using a mandibular screw suspension system. Otolaryngol Head Neck Surg 2011;144(2):225–229.
4. Kezirian EJ, Goldberg AN. Hypopharyngeal surgery in obstructive sleep apnea: an evidence-based medicine review. Arch Otolaryngol Head Neck Surg 2006;132(2):206–213.
5. Bowden MT, Kezirian EJ, Utley D, et al. Outcomes of hyoid suspension for the treatment of obstructive sleep apnea. Arch Otolaryngol Head Neck Surg 2005;131(5):440–445.
6. Randerath WJ, Verbraecken J, Andreas S, et al. Non-CPAP therapies in obstructive sleep apnoea. Eur Respir J 2011;37(5):1000–1028.

REVIEW QUESTIONS

1. The most common complication following hyoid suspension:
   a. Dysphagia
   b. Seroma
   c. Tongue edema
   d. Aspiration

2. Muscle that inserts into the body of the hyoid at its junction with the greater cornu and should be left intact in hyoid suspension to prevent destabilization of the airway
   a. Omohyoid
   b. Digastric
   c. Genioglossus
   d. Stylohyoid

3. Limiting dissection of the hyoid to near the lesser cornu will:
   a. Prevent injury to the lingual nerve
   b. Lessen tongue edema
   c. Decrease the risk of postoperative aspiration
   d. Prevent injury to the external branch of the superior laryngeal nerve

ADDITIONAL SOURCES

Hörmann K, Baisch A. The hyoid suspension. Laryngoscope 2004;114(9):1677–1679.

Neruntarat C. Hyoid myotomy with suspension under local anesthesia for obstructive sleep apnea. Eur Arch Otorhinolaryngol 2003;260:286–290.

58 Genioglossus Advancement

Richard Bauer III, David W. Parker II

INTRODUCTION

The pathogenesis of obstructive sleep apnea (OSA) is complex and involves many anatomic and physiologic factors. The Fujita system for classifying the level of airway obstruction is often employed as a diagnostic tool. Level 1 indicates obstruction at the retropalatal/oropharyngeal level area. Level 2 indicates obstruction at the retropalatal/oropharyngeal and retroglossal/hypopharyngeal levels. Level 3 indicates obstruction at the retroglossal/hypopharyngeal area only. One of the major contributors to airway collapse in OSA is loss of muscular activity or tone to the pharyngeal dilators during sleep. The genioglossus muscle is one of the major pharyngeal dilators and the primary muscle allowing tongue protrusion. The muscle is attached to the genial tubercles located on the lingual aspect of the anterior mandible. Thus, its influence on obstruction at the retroglossal/hypopharyngeal level in OSA cannot be understated. For this reason, the genioglossus advancement (GA) procedure, with all of its variations and modifications, was developed.

The original GA procedure was described in a case report detailing a "high" sliding advancement genioplasty osteotomy, which was secured in place via wire osteosynthesis.[1] A limitation of this procedure is failure to capture the entire genial tubercle complex, resulting in suboptimal airway improvement. Riley et al.[6] then modified this procedure to incorporate the entire genioglossus muscle insertion at the genial tubercles using a mortised sliding advancement genioplasty, but the procedure led to higher risks of pathologic fracture of the mandible.[1] Subsequent modifications to reduce fracture risk included a rectangular bicortical osteotomy of the anterior mandible around the region of the genial tubercles, with subsequent advancement and 90-degree rotation of the attachments, followed by rigid fixation.[1] Lewis and colleagues later described a trephine osteotomy and rigid fixation system for advancing the genial tubercle/genioglossus muscles using the Stryker Leibinger genioglossus bone advancement technique (GBAT) system (Stryker Leibinger, Kalamazoo, Michigan).[1] There have been subsequent modifications and variations to this same theme during the past two decades. With many of these procedures, a simultaneous infrahyoid myotomy and hyoid suspension were often performed (see Chapter 37).

KEY OPERATIVE LEARNING POINTS

1. Patient selection is important to optimize GA surgical results. Patients with mild-moderate OSA and collapse in the retroglossal/hypopharyngeal region may be most likely to respond.
2. GA can be combined with other surgical treatments such as uvulopalatopharyngoplasty (UPPP), bilateral sagittal split advancement osteotomies of the mandible, and bimaxillary advancement osteotomies.
3. Advanced imaging using cone beam computed tomography (CBCT) technology combined with computer-assisted virtual surgical planning and custom three-dimensional (3D) printed marking and positioning guides can minimize operating time and improve the precision of with which the genial tubercles are captured and advanced.

PREOPERATIVE PERIOD

History

1. OSA history
   a. OSA diagnosis and severity
   b. Sleep-related symptoms
   c. Medical comorbidities (e.g., hypertension, heart disease)
   d. Prior OSA medical therapy (e.g., continuous positive airway pressure [CPAP], bilevel positive airway pressure [BIPAP], oral appliance)
   e. Prior OSA surgical therapy (e.g., UPPP)
   f. Comorbid sleep medicine disorders (e.g., insomnia)
2. Past medical history
3. Past surgical history
4. Family history
5. Social history, particularly alcohol and tobacco use
6. Medications, especially anticoagulants or herbal products

Physical Examination

1. *General*—A general examination of the patient is important to assess his or her overall health and development. It is also important to consider his or her body habitus or body mass index (BMI), as patients with high weights or BMI are less likely to benefit from a GA alone.
2. *Head and Neck*—It is important to carefully examine the patient's head and neck to look for any signs of skeletal hypoplasia that could be contributing to the patient's obstructive symptoms. Those individuals that could benefit most from GA often present with mandibular hypoplasia and/or microgenia. Mentalis strain and the competence of the lips are also important; often, skeletal Class II patients have lip incompetence and exhibit mentalis strain when trying to close their lips. Neck circumference and hyoid position are two other factors to consider, as larger, thicker necks are associated with higher risk of OSA, and a low-set hyoid may indicate the same.
3. *Nasal airway*—It is important to thoroughly examine the nasal cavity for any evidence of obstruction that could be resolved via nasal surgery alone or with a combination of nasal surgery and surgery, affecting another level of obstruction.
4. *Oral cavity and oropharynx*—This is a very important examination because it gives valuable information regarding the size of the tongue and its contributions to the patient's obstructive symptoms, the volume of soft tissue comprising the soft palate that may be amenable to UPPP, and the size of the tonsils, which may contribute to the symptoms. It is important to note that the presence or absence of periodontal disease could increase the risk of fracture if a GA is performed. The amount and health of the keratinized tissue located buccal to the mandibular incisors are important during the postoperative course, as the incision, closure, and any subsequent scarring are located adjacent to this area, and contractures may result in unaesthetic gingival recession around the mandibular incisors.

Imaging

1. *Panoramic Radiograph*—To visualize the periodontal tissues, dentition, height of the anterior mandible, mental foramina, inferior alveolar nerve canal, and temporomandibular joints
2. *Lateral Cephalometric Radiograph*—Evaluate the presence and severity of maxillary, mandibular, and genial hypoplasia, all of which can contribute to various levels of obstruction in the airway during sleep.
3. *CBCT Scan or Maxillofacial CT Scan*—Maxillofacial CT scans, and more recently CBCT scans, have been incorporated into the planning stages of various sleep surgeries, including GA. This is a proven technology that has been used for years and has been shown to have a high degree of accuracy.[2] CBCT scans are advantageous in that they provide useful data regarding the volumetric aspects of the airway. The technology also facilitates the ability to make precise measurements to aid in planning osteotomies, avoiding critical structures such as the mental foramina, and to locate crucial aspects of the patient's anatomy, such as the genial tubercles in this case. In addition, surgical models of the patient's anatomy can be printed and studied along with the fabrication of surgical stents and guides to assist with various osteotomies to be certain that critical structures are included or avoided and that the specific surgical goal that was planned is accomplished. Postoperatively, the patient can be scanned again, and volumetric data can be generated about the increase in airway size and capacity.

Indications

Mild-moderate OSA with failure or inadequate adherence with medical therapy:

1. Retrolingual or hypopharyngeal location of collapse
2. Fujita type 2 or 3
3. Microgenia or mandibular hypoplasia. GA for these patients may have both airway and aesthetic benefits.

Contraindications

1. Significant medical comorbidities prohibiting operative intervention
2. Severe obesity likely to decrease GA effectiveness and increase perioperative risk
3. Airway obstruction localized to Fujita Level 1
4. Severe OSA
5. Severe periodontal disease
6. Patients concerned about transient or permanent V3 paresthesia

Preoperative Preparation

1. Discontinue any antiplatelet and anticoagulant medications if possible.
2. Oxymetazoline nasal spray prior to the induction of nasal endotracheal anesthesia.
3. Consider perioperative course of high-dose steroids to minimize postsurgical edema of the floor of the mouth, tongue, and airway.

OPERATIVE PERIOD

Anesthesia

1. General anesthesia with local anesthesia
   a. The patient should be intubated for airway protection; ideally, the patient should have nasal intubation. In the event of a mandible fracture as a complication, the teeth would need to be wired together to set the occlusion before applying any rigid fixation plates.
   b. Local anesthesia with epinephrine is helpful for postoperative pain management (mental blocks) but is mainly for infiltration into the anterior mandibular buccal vestibule and floor of the mouth to minimize bleeding and facilitate visualization intraoperatively.

Positioning

1. Supine position with shoulder roll for partial neck extension

Perioperative Antibiotic Prophylaxis

1. Ampicillin/Sulbactam (Unasyn)
2. Clindamycin (Cleocin) for patients who are allergic to penicillin

Monitoring

1. Routine anesthesia monitoring

Instruments and Equipment to Have Available

1. #9 periosteal elevator
2. Frazier tip suction
3. Dingman bone clamp
4. Obwegeser retractors
5. Fine-tipped hemostats
6. Twenty-four-gauge wire; or maxillomandibular fixation screws and 26-gauge wire
7. Wire drivers
8. Wire cutters
9. Scalpel with #15 blade
10. Electrocautery with Colorado microdissection tip
11. Symphyseal retractor
12. Sagittal safe oscillating saw blade
13. Long reciprocating saw blade
14. Maxillofacial plating set with bicortical screws, fixation plates, and/or pre-bent genioplasty advancement plates
15. Compressive facial support dressing
16. Computer-assisted marking and positioning guides (if surgery virtually planned and designed)

Key Anatomic Landmarks

1. Mandibular buccal vestibule—For most solitary GA procedures, a standard intraoral approach is used via the anterior buccal vestibule, which has the advantage of a hidden, intraoral scar. The mandibular buccal vestibule is located between the mandibular incisors and the lower lip. It contains nonkeratinized stratified squamous mucosa.
2. Mentalis muscle—Located beneath the anterior buccal vestibular tissue of the mandible, it is the only elevator of the lower lip and chin. If this muscle is not repositioned properly during the closure, the chin will "droop," leading to a "witch's chin"–type deformity along with the sagging appearing of the lower lip, exposing more lower incisor. The mentalis originates from the mental prominence of the mandible and inserts into the soft tissues of the chin prominence. The most superior fibers are the shortest and pass almost horizontally into the chin, while the most inferior fibers are the longest and pass obliquely or vertically to the skin at the lower aspect of the chin. The origin of the mentalis muscle determines the depth of the labial vestibule. The mentalis muscle

is innervated by the marginal mandibular branch of the seventh cranial nerve (facial nerve).[3]

3. Mental neurovascular bundle—The major neurovascular structure that must be avoided during a GA procedure. The artery and vein that accompany the nerve are insignificant from a surgical standpoint. However, the mental nerve is a terminal branch of the mandibular division (V3) of the fifth cranial nerve (trigeminal nerve), and its function is to innervate the skin and mucosa of the lower lip, the facial gingiva of the mandibular incisors, and the skin of the chin. The mental nerve exits the mental foramen located near the apex of the first or second mandibular premolar teeth and usually then splits into three smaller branches that fan out into the region of innervation. The branching pattern can be variable, and some branches can be superficial within the oral mucosa.[3]
4. Genioglossus muscles/genial tubercles—The genioglossus muscles are one set of extrinsic muscles of the tongue. As such, they originate from the genial tubercles located on the lingual aspect of the mandible and then fan out vertically and horizontally within the body of the tongue. They are the main protrusors of the tongue. The muscles are innervated by the 12th cranial nerve (hypoglossal nerve). They receive their major blood supply from the lingual arteries bilaterally.[3] Silverstein et al., in their classic cadaveric study from 2000, detailed many relevant measurements regarding the nature of the genial tubercles and surrounding anatomy.[4] They showed that the average thickness of the mandible at the genial tubercle was approximately 13 mm at the midline inferior border 14.5 mm.[4] In addition, the average distance from the genial tubercles to the inferior border at midline was 14.5 mm, and the average distance from the apex of the mandibular incisor teeth to the genial tubercle was 11.8 mm.[4] The width of the genioglossus muscle attachments themselves was approximately 14 mm.[4]
5. Digastric muscles—The anterior digastrics are attached to the inferior border of the anterior mandible and the hyoid posteriorly. When advancing the inferior border segment during a GA, these muscles are placed under tension along with the genioglossus, which helps to pull the hyoid anteriorly and superiorly and helps to further open the airway.

Prerequisite Skills

1. Basic mandibular osteotomy skills
2. Familiarity with anatomy of the mandible and the floor of the mouth
3. Experience with internal rigid fixation

Operative Risks

1. Hemorrhage from the floor of mouth from the genioglossus muscles, the mylohyoid muscles, or the lingual or sublingual arteries. This often occurs when patients have remained on antiplatelet or anticoagulant medications or when the reciprocating saw tip is placed too deep into the floor of mouth.
2. Fracture of the mandible—If the inferior border osteotomy is placed too superior, leaving minimal to no mandibular basal bone and only mandibular alveolar bone to provide continuity
3. Damage to the mental nerves—Damage to the nerves can occur during the dissection of the mandible or during the osteotomy.
4. Avulsion of the genioglossus muscles from the genial tubercles—If the osteotomized segment containing the genial tubercles is placed under significant tension, the muscles can avulse from the tubercles.
5. Perforation of the lower lip or labiomental groove—This complication can occur if the surgeon is not careful during the intraoral dissection that is done to access the mandible.
6. Damage to the mandibular dentition—Damage to the teeth can occur during the osteotomy if the osteotomy is made too superior. The apices of the teeth can be cut off the roots, endangering the vitality of the teeth.

Surgical Technique

1. The patient is positioned, padded, prepped, and draped.
2. The anterior mandibular buccal vestibule is injected with 1% lidocaine with 1:100,000 epinephrine, with additional local anesthetic being injected into the anterior floor of the mouth to assist with hemostasis.
3. A moist throat pack is placed in the posterior oropharynx.
4. The jaws can then be wired shut with 26-gauge wire and temporary bone screws to provide stability to the mandible while performing the osteotomy.
   a. You may elect to use surgical marking and positioning guides, which are wired temporarily between the teeth once the dissection is complete. These guides were also screwed into the mandibular bone (Fig. 58.1). The guides, which had been printed with 3D printing technology, were based off of the data from the patient's preoperative CBCT scan and virtual surgical planning session. Their purpose was to allow us to include the genial tubercles with the osteotomized segment with a high degree of accuracy and then to advance the segment the intended, maximal amount (Figs. 58.2 and 58.3).
5. Two Obwegeser retractors or Army-Navy retractors are placed in each lateral mandibular vestibule to allow for visualization while the lower lip is retracted.
6. A needle tip Bovie cautery (settings 20/20) is then used to make an incision approximately 8 to 10 mm below the mucogingival junction on cut mode through the superficial mucosa from canine to canine. If the incision is made too high next to the attached gingiva, closure will be exceedingly difficult, and the surgeon risks dehiscence of the wound. If closure is done too inferior, the surgeon risks incising and scarring the lower lip musculature. Care is taken to locate and protect the three mental nerve branches using blunt dissection with a fine-tipped hemostat. The needle tip Bovie is then used on coag mode to incise through the mentalis muscle aiming toward the bone with one finger on the

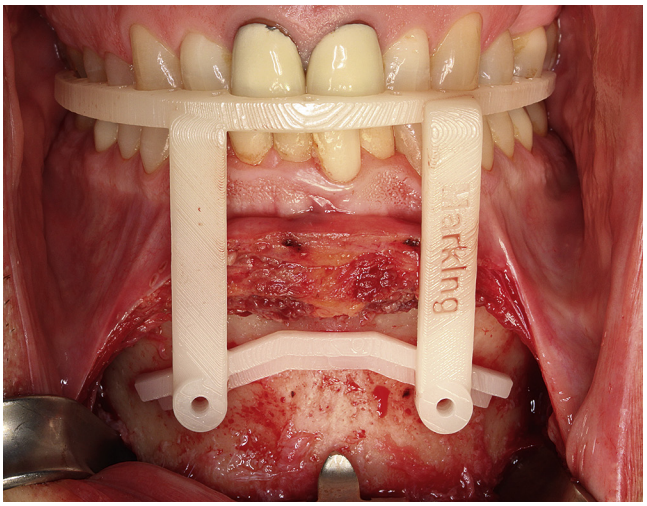

Fig. 58.1. Genioglossus marking guide.

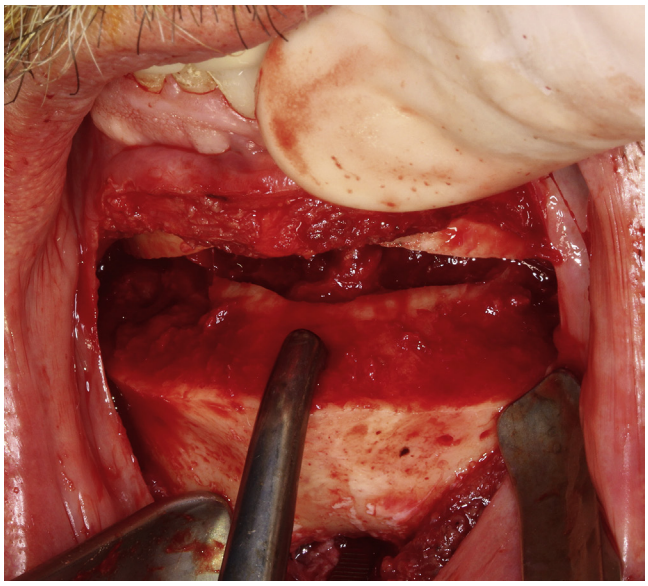

Fig. 58.2. Genial tubercle and attachments included with the free distal segment.

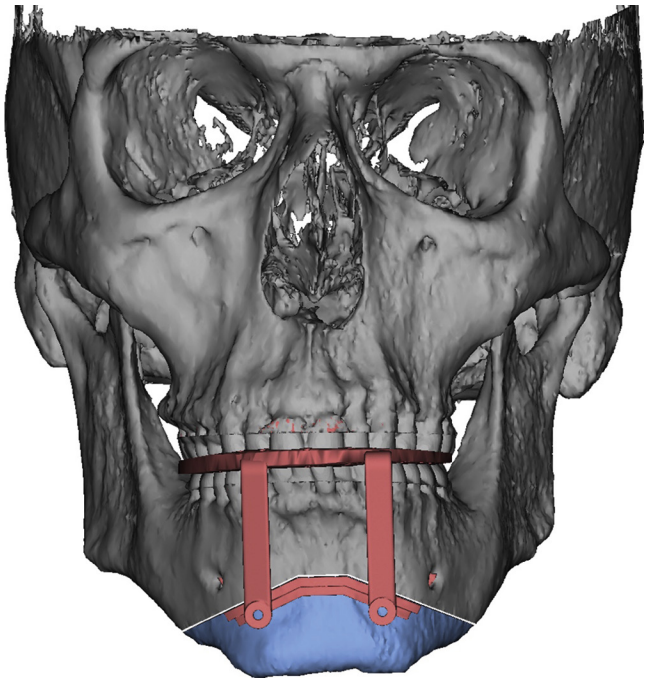

Fig. 58.3. Virtual planning for the genioglossus osteotomy.

underside of the lower lip to give tactile sensation of how close the surgeon is coming to the external lower lip while not perforating it.

7. Once the bone is reached, a #9 periosteal elevator is then used to gently reflect the mentalis muscle and periosteum both superiorly and inferiorly. The scalloped bone of the mandibular incisors is located to give reference of the teeth locations with care to not perforate the gingiva overlying the alveolar bone superiorly. Elevation of the tissue also continues inferiorly to expose the inferior border of the mandible. At this time, a symphyseal retractor can be placed to retract the tissues inferiorly. Dissection continues laterally with care to avoid the mental nerve and foramina. This is extended to the first molar region laterally to provide a "pocket" in which the reciprocating saw is placed.

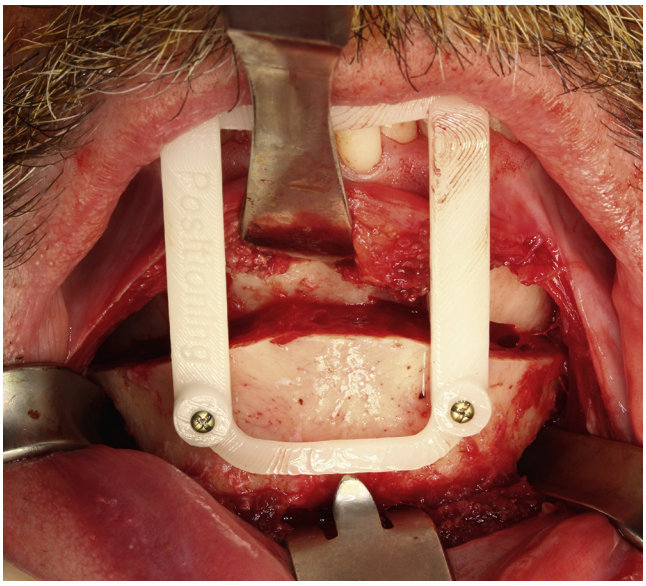

Fig. 58.4. Positioning guide for genioglossus advancement.

8. At this point, the "marking guide" was then placed between the teeth and allowed us to see the planned osteotomy outline that would include the genial tubercles and the genioglossus muscle.
9. The mandibular bone is then osteotomized with a sagittal safe oscillating saw blade enough to make marks in the outer cortex under copious sterile saline containing clindamycin (900 mg per 1 L saline).
10. The marking guide is removed from the teeth and then the osteotomy is then finished in a bicortical fashion with a standard short reciprocating saw blade under clindamycin irrigation. One side is done in a bicortical fashion with care exerted to not sink the tip too deep into the floor of mouth. The opposite side is then osteotomized to completion. The anterior, inferior border segment is then freed and mobilized with a Dingman bone clamp. Any bleeding areas should be investigated and controlled at this point.
11. Next, the positioning guide was then placed between the teeth and its inferior extension screwed into the mandible to give reference of the intended final position of the advanced segment (Fig. 58.4).
12. Due to significant muscular tension after advancing the segment, fixation in this patient was accomplished with three 2.0-mm bicortical screws and two prebent GA fixation plates (the surgeon should use his or her judgment on the type and amount of adequate fixation). Following this, the positioning guide was removed and the area irrigated with clindamycin saline solution.
13. As a final step, if the advanced segment creates a large "step" in the mandible and is likely to result in a cosmetic deformity, a surgeon can then use a MedPor chin implant, carved to fill the defect and allow for a smooth transition (Fig. 58.5).
14. Closure is then carried out first by suspending the mentalis muscle with a 3-0 or 4-0 Vicryl suture taking care not to *cheese wire* the sutures through the muscle with excessive tension. This is then followed by closure of the mucosal incision with a 3-0 chromic gut suture.
15. The jaws, if not already, are then unwired and any temporary bone screws removed. The throat pack is removed and the oropharynx suctioned. A "jaw bra" or facial support dressing is then placed on the patient, and the patient is extubated.

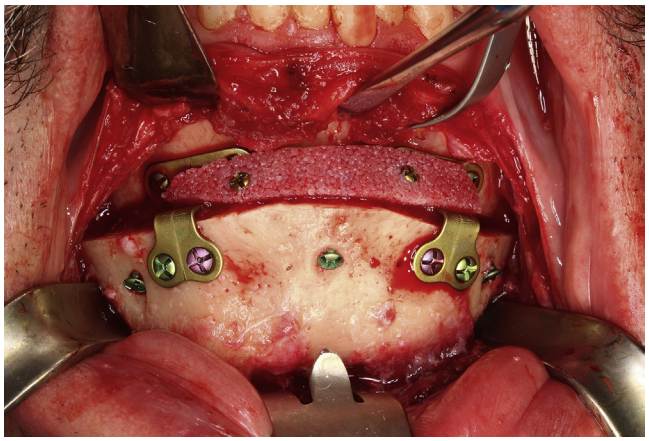

Fig. 58.5. Fixated genioglossus advancement with transitional Medpor graft.

Common Errors in Technique

1. Failure to properly position the incision. An incision too superior in the vestibule next to the attached gingiva will cause the closure to be exceedingly difficult and risk dehiscence. Incision too inferior or anterior into the lip can result in excessive scarring of the lower lip and a large amount of annoying tissue "drape" over the more superior site of the osteotomy.
2. Improper positioning of the osteotomy—This can result in damage to the tooth roots, mandibular fracture, or damage to the mental nerves (osteotomy positioned too high) or inability to capture the entire area of the genial tubercles/genioglossus muscle origin (osteotomy placed too low). In addition, beginning the osteotomy anterior to the second premolar/first molar area risks creating too much of a sudden transition and can result in "notching" of the mandible at the inferior border. This can be quite noticeable and unaesthetic in thinner individuals.
3. Allowing the tip of the reciprocating saws to be too deep into the soft tissues of the floor of the mouth while making the osteotomy. This can result in damage to the mylohyoid or genioglossus muscles and can also result in hemorrhage from multiple sources.
4. Exerting excessive force on the mandibular free segment containing the genial tubercles. This can result in avulsion of the genioglossus muscle.

POSTOPERATIVE PERIOD

Postoperative Management

1. Be certain that no active bleeding exists from the incision site or the floor of mouth.
2. Ensure airway patency. Special consideration should be given to a short course of high-dose steroids to minimize edema of the airway.
3. Patients often have a mild to moderate level of pain due to some temporary neuropraxic type injury to the mental nerves that have been retracted during surgery. Patients may be given intravenous acetaminophen initially, which can then be transitioned to liquid or pill form when taking PO. In addition, a low level of narcotics can be given to the patient postoperatively. Nonsteroidal anti-inflammatory drugs (NSAIDs), such as ketorolac, can be given on POD1, provided there is no active bleeding. Resumption of any home antiplatelet or anticoagulant medications should be determined based on the severity of the illness being treated by said medications and by the surgeon's own judgment.
4. Admit the patient to the intensive care unit for the first 24 hours for close monitoring. If the patient does very well postoperatively, he or she could potentially be discharged on POD1. Otherwise, he or she could be transferred to a monitored bed with continuous pulse oximetry on POD1 if doing well but not yet meeting other discharge criteria (i.e., continuing to have elevated postoperative pain and taking inadequate PO intake).
5. Patients are started on a clear liquid diet the night of surgery. The diet is then advanced to full liquids/blenderized on POD1. The patient is then advised to continue a blenderized, nonchew diet for the next 6 weeks to minimize the risk of late postoperative mandibular fracture. Along these same lines, the patient is prohibited from engaging in any heavy lifting, strenuous exercise, or contact sports that could predispose him or her to fracture.
6. The patient is often given a 24-hour course of prophylactic antibiotics.
7. The patient is advised to brush the teeth gently on POD1 and to avoid the incision. He or she is also given an oral chlorhexidine rinse to swish with twice per day for 7 days.
8. The patient should be seen in clinic for a follow-up appointment at 1 to 2 weeks postoperative. At that time, standard postoperative panoramic and lateral cephalometric radiographs are taken.

Complications

1. Hemorrhage from the floor of the mouth from the genioglossus muscles, the mylohyoid muscles, or the lingual or sublingual arteries—This often occurs when patients have remained on antiplatelet or anticoagulant medications or when the tip of the reciprocating saw is placed too deep into the floor of mouth. This complication usually presents during surgery but can emerge in the postoperative hours. It is advisable to avoid this by not allowing the saw blade to be inserted too deeply. If bleeding is noted, the surgeon should determine if it is from the muscle, which can be managed with local measures such as local anesthesia with epinephrine and Gelfoam, or arterial/venous, which would need to be managed by tying or clipping the vessel(s) in question.
2. Fracture of the mandible—If the inferior border osteotomy is placed too superior, leaving minimal to no mandibular basal bone and only mandibular alveolar bone to provide continuity. Should this happen intraoperatively, rigid fixation using fracture plates or possibly a reconstruction bar should be used to stabilize the segments. Although the patient technically could be left in maxillomandibular fixation, this is not ideal if the patient is undergoing the surgery to improve his or her already compromised airway.
3. Damage to the mental nerves—Damage to the nerves can occur during the dissection to the mandible or during the osteotomy. If this is recognized intraoperatively, the nerve endings should be freed up to remove any tension and sutured together under loupe or microscope magnification using a 7-0 or 8-0 Neurilon-type suture or equivalent.
4. Avulsion of the genioglossus muscles from the genial tubercles—If the osteotomized segment containing the genial tubercles is placed under significant tension, the muscles can be avulsed from the tubercles. Should this happen, the muscle would need to be reattached with a strong, slowly resorbing suture to the genial tubercles and the GA aborted while the patient heals.
5. Perforation of the lower lip or labiomental groove—This complication can occur if the surgeon is not careful during the intraoral dissection made to access the mandible. Should this happen, the surgeon should carefully close the laceration in layers.

6. Damage to the mandibular dentition—Damage to the teeth can occur during the osteotomy if the osteotomy is made too superior. The apices of the teeth can be cut off the roots, endangering the vitality of the teeth. Should this happen, the surgeon should be prepared to refer the patient to an endodontist for subsequent monitoring. The patient should be advised that the teeth may become necrotic and that the teeth may be lost.
7. Unaesthetic drooping or ptosis of the mentalis muscle (i.e., the "witch's chin" deformity). This results from failure to resuspend the mentalis muscle. This can be avoided by making sure to resuspend the muscle prior to closure and by having the patient wear some type of facial support/pressure dressing with light pressure on the chin, pushing it into the symphysis and being slightly superior. This should be worn continuously for 1 week, removing only for showers and eating if necessary. If the deformity occurred in the postoperative period, this requires a resuspension procedure, which can be difficult to correct secondarily.
8. Unaesthetic "notching" of the inferior border of the mandible. This can occur when the osteotomy is not started far enough posterior to gradualize the segment of bone. If this is noticed postoperatively by the patient, one solution would be to inject soft tissue fillers into the region of notching.
9. Infection of the hardware retaining the osteotomized segment. Management of this would include removal of the hardware and a possible redo of the operation. This can be prevented with careful incision design and soft tissue closure of the mandibular vestibule.
10. Avascular necrosis of the osteotomized segment. This is a dreaded, but fortunately, extremely rare consequence of this surgery. This should be avoided by using gentle manipulation of the osteotomized segment and minimizing the amount of muscle and periosteum "stripping" that is performed.
11. Nonunion of the osteotomized segment. Management would require a redo of the operation with new fixation.
12. Loss of fixation of the advanced segment. This must be managed by removing the previously placed rigid fixation and placing new fixation at the site.

Alternative Management Plan

1. Bilateral sagittal split osteotomies (BSSOs) with advancement and simultaneous GA
2. Bimaxillary advancement (LeFort I and BSSO) with or without GA
3. GA with simultaneous hyoid suspension
4. GA with other simultaneous sleep surgery procedures (i.e., tongue-base reduction, UPPP, tonsillectomy)
5. GA using a different, previously described osteotomy design such as the mortised GA or the Stryker Liebinger GBAT system (Stryker Leibinger, Kalamazoo, Michigan)

DISCUSSION

Evidence-Based Medicine Question

Is the sliding GA osteotomy done in conjunction with computer-aided planning and design as effective as other surgical techniques to advance the genioglossus muscle?

Historically, in the literature, GA has often been discussed in conjunction with surgical hyoid suspension. There has been very little evidence in the sleep medicine literature regarding isolated GA procedures. In addition, the GA is often combined in multiple studies with a simultaneous UPPP, which has been reported to result in a success rate of around 50% to 80%.[5] In discussing an isolated GA, it is important to reiterate that the anatomic basis of the surgery is the attachment of the genioglossus muscle to the genial tubercles of the anterior mandible. For the surgery to be a success, the patient must have an obstruction in the retrolingual/hypopharyngeal region, the entire genial tubercles and insertion of the genioglossus muscle must be captured in the advanced segment to maximize the outcome, and the patient cannot have severe sleep apnea or morbid obesity, as these would likely result in failure to improve the sleep apnea. We have presented a novel case in which the GA was combined with advanced imaging (CBCT), virtual surgical planning to locate the genial tubercles to ensure maximum muscle advancement, and custom 3D printed marking and positioning guides. Following C.E.'s surgery, his OSA symptoms resolved and he has shown remarkable improvement in quality of life and a reduction in his RDI scores. He no longer has daily headaches and feels rested in the morning from sleep.

Editorial Comment

GA is a long-standing tool in the surgical treatment armamentarium for the management of OSA that is refractory to medical therapy. Particularly when employed as part of a multilevel treatment plan, GA has decades of data to support its incremental effectiveness in improving OSA surgery outcomes in properly selected patients. Critical to the successful execution of the procedure, as well as to the minimization of potential risks, is the accurate isolation of the genial tubercle and capture of the entire genioglossus tendon. Advances in preoperative imaging and computer-assisted virtual surgical planning, in addition to surgeon experience, appear to be related to improved outcomes and reduced morbidity.

Ryan Soose

Access the review questions online at http://www.expertconsult.com



REFERENCES

1. Lee NR. Genioglossus muscle advancement techniques for obstructive sleep apnea. Oral Maxillofacial Surg Clin N Am 2002;14(3):377–84.
2. Yin SK, Yi HL, Lu WY, et al. Anatomic and spiral computed tomographic study of the genial tubercles for genioglossus advancement. Oto Head and Neck Surg 2007;136:632–7.
3. Ellis E, Zide M. Mandibular vestibular approach. In Surgical Approaches to the Facial Skeleton, 2nd ed. Philadelphia, Lippincott: Williams and Wilkins; c2006, chapter 8, p. 137–150.
4. Silverstein K, Costello BJ, Giannakpoulos H, Hendler B. Genioglossus muscle attachments: an anatomic analysis and the implications for genioglossus advancement. Oral Surg Oral Med Oral Pathol Oral Radiol Endod 2000;90:686–8.
5. Sher AE, Schechtman KB, Piccirillo JF. The efficacy of surgical modifications of the upper airway in adults with obstructive sleep apnea syndrome. Sleep 1996;19(2):156–77.
6. Riley RW, Powell NB, Guilleminault C. Obstructive sleep apnea syndrome: A surgical protocol for dynamic upper airway reconstruction. J Oral Maxillofac Surg 1993;51:742–747.

REVIEW QUESTIONS

1. The genioglossus muscles originate from what structure?
   a. Mandibular lingulae
   b. Sigmoid notch
   c. Coronoid processes
   d. Genial tubercles

2. The major blood supply to the genioglossus muscle is from what arteries?
   a. Masseteric
   b. Lingual
   c. Facial
   d. Superior thyroid

3. The major nerve at risk from the genioglossus advancement procedure is the
   a. Marginal mandibular branch of the facial nerve
   b. Cervical branch of the facial nerve
   c. Mental branch of the inferior alveolar nerve (trigeminal nerve)
   d. Great auricular nerve

59 Maxillomandibular Advancement for Obstructive Sleep Apnea

Richard Bauer III, Raj C. Dedhia

INTRODUCTION

The fundamental principle of maxillomandibular advancement (MMA) is to move the muscular attachments of the hard palate, tongue, and suprahyoid soft tissue in an anterior direction by advancement of the tooth-bearing segments of the maxilla and mandible.[1] This maneuver enlarges the bony vault, effectively improving retropalatal, lateral wall, and retroglossal airway collapse.

MMA has been used effectively for adults with obstructive sleep apnea (OSA) since the 1980s. During that period, Drs. Robert Riley and Nelson Powell modified orthognathic (i.e., for treatment of occlusion and cosmesis) techniques for telegnathic (i.e., for treatment of OSA) treatment.[2] Over the past 30 years, the data consistently demonstrate greater than 90% success rates, with success defined as postoperative apnea-hypopnea index (AHI) less than 20 and a 50% reduction in baseline AHI.[3,4]

Although this surgery represents a highly effective modality, its relative invasiveness and prolonged recovery often deter surgeons and patients alike from using MMA as a first-line surgical treatment. However, in otherwise healthy OSA patients with significant retrognathia or maxillary hypoplasia, this surgery can be first line because it provides orthognathic in addition to telegnathic benefits.

KEY OPERATIVE LEARNING POINTS

- Proper fabrication of intermediate and final occlusal splints is critical to achieving precise results.
- The Le Fort I maxillary osteostomy must be carried out above canine roots and parallel to occlusal plane.
- The bilateral sagittal split mandibular osteotomy should be placed at the posterior aspect of the second molar to allow for enough room for plate fixation, if needed.

PREOPERATIVE PERIOD

History

- A comprehensive sleep medicine history is the critical first step before considering surgical therapy for any OSA patient.
- Approximately one-third of OSA patients have been reported to have another primary sleep disorder or sleep-modulating medical comorbidities, such as psychophysiologic insomnia, chronic pain, shift work sleep disorder, restless legs syndrome, or narcolepsy. Medications that negatively affect control of breathing (e.g., opiates or benzodiazepines) or alter sleep architecture or continuity directly (e.g., antidepressants) must also be taken in account in evaluating a patient's candidacy.
- In addition to a sleep medicine history, documentation of a general medical history is paramount.
- Patients must be in good health overall because this surgery can result in significant blood loss and requires approximately 4 to 6 hours of general anesthesia.
- Patients must also be mentally well with a strong support network. The first 1 to 2 months of the recovery process are particularly challenging given difficulties with trismus and persistent perioral numbness. The perioral numbness can cause significant social impairment with unacceptable drooling and difficulty kissing.
- If patients have a history of anxiety or depression, we recommend that the patient see a mental health professional prior to surgery. Empiric medical treatment prior to surgery should be strongly considered.

Physical Examination

1. Nose
   a. Evaluate width of nasal base
      1) Patients should be informed of some degree of widening of nasal base with maxillary advancement.
   b. Acquired nasal deformity, septal deviation, turbinate hypertrophy, rhinitis, nasal polyps, and other nasal valve pathology may increase upper airway resistance and directly contribute to sleep-disordered breathing.
      1) If nasal obstruction requires treatment, it should be performed AFTER MMA because the healing from the maxillary advancement may disrupt septal alignment.
2. Facial skeleton evaluation
   a. Maxilla
      1) Evaluate transverse, vertical, and anteroposterior dimensions.
         a) Multipiece Le Fort osteotomy or a surgically assisted rapid palatal expansion (as a separate initial procedure) may be required to improve the transverse dimension.
         b) Maxillary impaction should be considered in cases of vertical maxillary excess.
   b. Mandible
      1) Evaluate width of mandibular vault and retrognathia.
         a) Retrognathia should be differentiated from micrognenia based on occlusal relationship and reference of the lower incisors and chin to the cranial base.
   c. Dentition
      1) Use of Angle occlusion at the first mandibular and maxillary molars and canines represents occlusal relationship and can assist in determining any skeletal malocclusion.
      2) Evaluate for open bite deformity or buccal/lingual crossbite.
      3) If correction of malocclusion is indicated, consider preoperative orthodontics.
      4) Evaluate the health of teeth based on enamel, periodontal status, and presence of extensive restorations. Crown and bridge work may alter plans for maxillomandibular fixation.
3. Soft tissue evaluation
   a. Transoral examination
      1) Evaluate the position of the tongue and soft palate.

b. Fiberoptic examination
   1) Retropalatal space
      a) Space from the posterior nasal spine to posterior pharyngeal wall will be increased with maxillary advancement.
      b) If previous uvulopalatopharyngoplasty (UPPP), assess for soft palate scarring or nasopharyngeal stenosis.
   2) Lateral wall collapse (Müller maneuver or under sedated endoscopy) as MMA provides tension to lateral walls to prevent collapse
   3) Retrolingual and hypopharyngeal space. Both tongue base and epiglottic obstruction can be treated with MMA.
   4) Lymphoid hyperplasia (e.g., palatine or lingual tonsil hypertrophy). Excessive intraluminal lymphoid tissue may need to be removed simultaneously or in a staged fashion with MMA.

Imaging

1. Photodocumentation
2. Plain films—primarily orthopantomogram and lateral cephalometric radiograph
3. Computed tomography (CT) or cone beam computed tomography (CBCT)

Computer-Assisted Planning and Splint Fabrication

1. Imaging allows improved understanding of deformities in multiple dimensions.
2. Virtual planning is developing into the standard for treatment of complex dental and facial reconstructions.
3. Virtual planning provides insight to anticipated anatomic relationships at osteotomies prior to surgery, allowing for efficient and detailed preoperative plans.
4. Laboratory time can be eliminated with accurate splints fabricated for intraoperative MMF. Splints can be fabricated to individual specifications (i.e., sandwich splints for multipiece double jaw surgery or addition of a palatal strap for maxillary widening).
5. Accurate and efficient interdental osteotomy guides can be fabricated from the patient data to prevent root damage.

Indications

1. Moderate to severe OSA with failure of medical device therapy
2. Mild to severe OSA with craniofacial anomaly

Contraindications

1. Central sleep apnea
2. Bisphosphonate medications use
3. Uncontrolled medical comorbidities
4. Recent history of maxillary or mandibular surgery with potential compromise of skeletal blood supply (e.g., transpalatal advancement pharyngoplasty)
5. Severe temporomandibular joint (TMJ) dysfunction

Preoperative Preparation

1. Thorough craniofacial evaluation with dental and occlusal records
2. Preparation of the patient for recovery and diet modifications
3. Prior to MMA, an orthopantomogram and lateral cephalometric radiographs are important to identify TMJ morphology, health of the dentition, and relationship of the maxilla and mandible to the cranial base.
   - We use three-dimensional (3D) planning for MMA. This uses a CBCT and third party surgical planning service. Additional data from the CBCT can be obtained, specifically airway analysis in three dimensions. It should be noted here that the CBCT data are obtained while the patient is upright and awake, and this may alter the depiction of the airway significantly in the sleep apnea patient (Fig. 59.1).
     The previous CBCT data show preoperative and postoperative overlays of the skeletal and airway changes.
   - The presurgical plan generated from the virtual planning session can be used to print intermediate and final occlusal splints and postsurgical models.

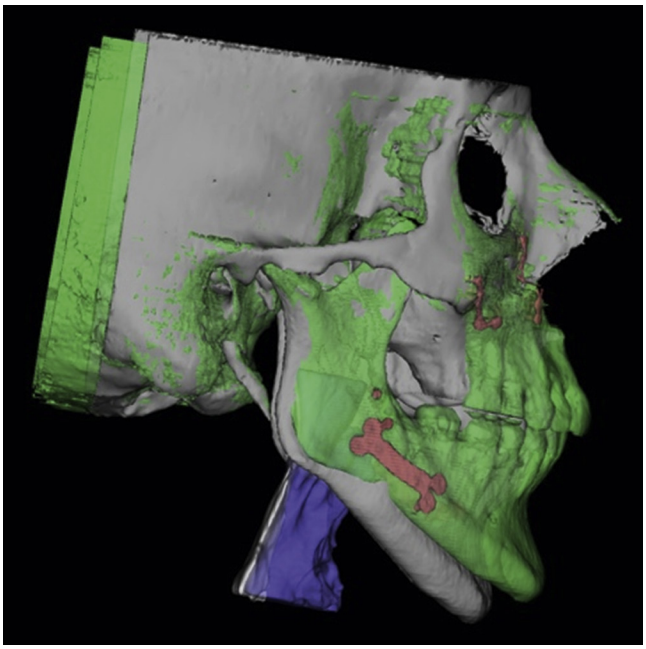

Fig. 59.1. The cone beam computed tomography data show preoperative and postoperative overlays of the skeletal and airway changes. Note the anterior and superior repositioning of the lower third of the face.

OPERATIVE PERIOD

Anesthesia

Anesthesia for MMA should be planned with the anesthesiologist in advance of the surgery. Nasal intubation is imperative, and a hypotensive anesthetic (provided this is appropriate based on the patient's medical history) facilitates a decrease in blood loss. Oxymetazoline nasal spray is used prior to the induction of nasal endotracheal anesthesia.

Positioning

The patient is placed in a supine position. We have found that morbidly obese patients with significant neck circumference and broad shoulders placed on a Mayfield head rest provide better working conditions for the operator and assisting surgeon.

Perioperative Antibiotic Prophylaxis

- Those not allergic to penicillin-based drugs—ampicillin/sulbactam (Unasyn)—this medication provides excellent coverage against most oral and sinus bacteria

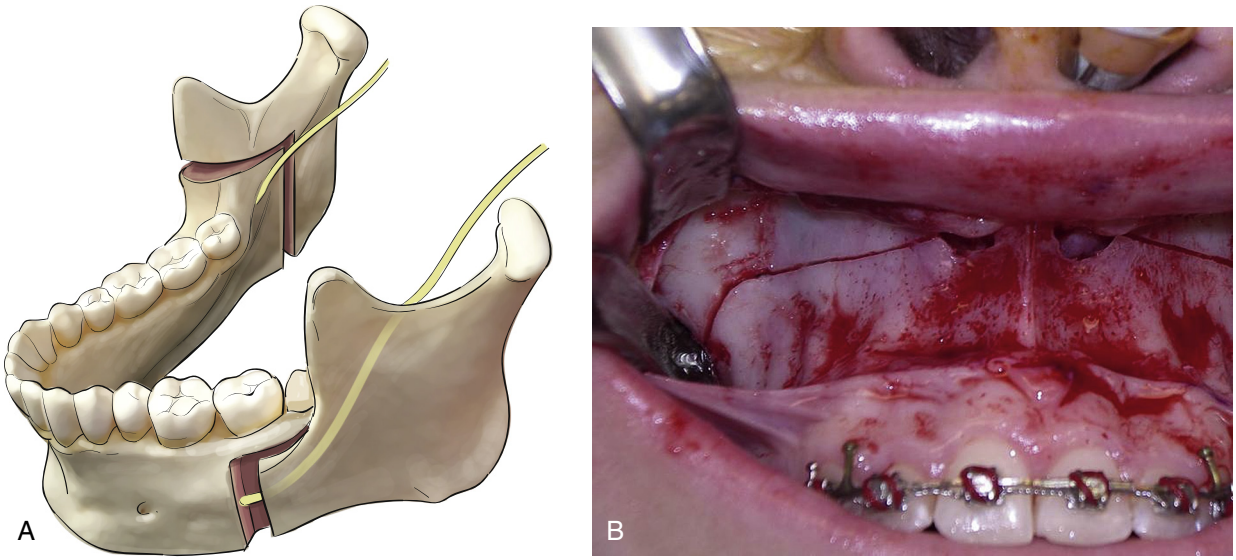

Fig. 59.2. A, Standard bilateral sagittal split osteotomy and **B,** Le Fort osteotomy.

- Allergies to penicillin-based drugs—clindamycin (Cleocin)—this medication provides good coverage against many oral bacteria

Monitoring

- Standard anesthesia and cardiopulmonary monitoring
- Foley catheter
- Consider placement of arterial line (real-time blood pressure monitoring).

Instruments and Equipment to Have Available

- Obwegeser retractors—small, medium, and large upturned (toe-out) and downturned (toe-in)
- Freer elevators—small and large curved
- Periosteal elevators
- Electrocautery with Colorado tip, spatula tip
- Osteotomes—single guarded, spatula, fiber handle, septal, and curved
- Rongeur forceps
- Tessier retromaxillary elevator
- 25-gauge wire for maxillomandibular fixation
- Reciprocating saw
- Drill with 1.2-mm cross-cut carbide, Lindemann, 702 and pineapple burrs
- Suture—4.0 Prolene suture, 3.0 Vicryl on SH needle, 3.0 chromic gut, 5.0 fast gut suture
- Erich arch bars, 25-g wire
- Heavy dental elastics

Key Anatomic Landmarks

- Le Fort I osteotomy must occur superior to the apex of bilateral canine roots.
- Lingula demarcates safe level to perform sagittal osteotomy as inferior alveolar nerve enters canal inferior to this structure.

Prerequisite Skills

- A strong understanding of rigid fixation and a command of orthognathic surgery are critical. The Le Fort I maxillary osteotomy and the bilateral sagittal split mandibular osteotomies are the foundation of this treatment.

Operative Risks

- Bleeding
- Loss of airway
- Malocclusion
- Fracture

Surgical Technique

The images above depict a Le Fort I maxillary osteotomy and standard bilateral sagittal split osteotomy (BSSO) of the mandible (Fig. 59.2).

Arch Bar Placement

- A throat pack is placed intraorally.
- 10mL of 0.5% Marcaine with 1:200,000 epinephrine is injected along the planned maxillary incision.
- Erich arch bars are secured to the upper and lower teeth with 25-g wire and Ivy loops.

Le Fort I Osteotomy

- Bovie electrocautery is used to make an incision from zygomatic buttress to zygomatic buttress, leaving a 10-mm cuff of unattached gingiva.
- The periosteum is elevated from the posterior maxilla to the piriform aperture.
- The nasal mucosa is elevated from the maxilla as far posterior as possible.
- The osteotomy is placed superior to the canine roots and parallel to the occlusal plane.
- A reciprocating saw is used to make the osteotomy from posterolateral maxilla to piriform aperture with a Freer elevator placed in the nasal cavity to protect the nasal mucosa.
- The process is repeated on the other side.
- A septal osteotome is used to separate the nasal septum from the underlying maxilla (below the maxillary crest) and a chisel for the medial maxillary buttress.
- A pterygoid osteotome is used to complete the pterygomaxillary separation.
- At this time, the maxilla is manually downfractured and should be freely mobile.

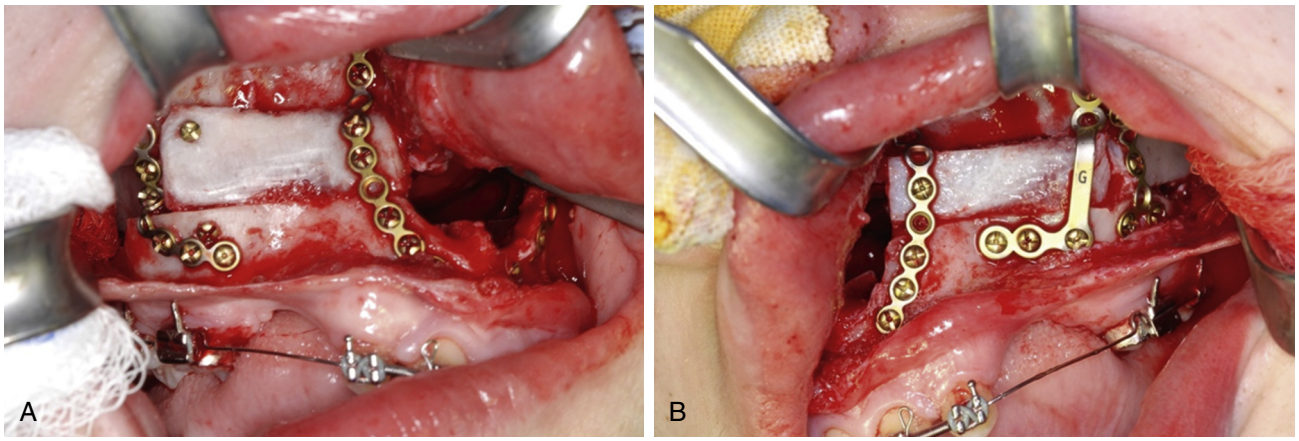

Fig. 59.3. Cadaveric iliac crest interpositional blocking grafts for long-term stability. **A,** Right Maxilla **B,** Left Maxilla.

- The bilateral palatine vessels are identified and ligated or cauterized.
- Bony interference is removed with rongeur forceps and a surgical bur.
- The intermediate splint is introduced until the proper fit is achieved and secured with 24-g wire.
- 1.7 or 2.0 midface plates × 2 are manipulated and placed on each medial maxillary buttress, followed by 2-L plates on the zygomatic buttress, secured with screws.
- Ensure that the midline is maintained.
- The field is irrigated, suctioned, and packed with Ray-tec sponges.

Bilateral Sagittal Split Osteotomy

- 10mL of 1% Lidocaine with 1:100,000 epinephrine is injected along the planned mandibular incisions.
- Bovie electrocatuery is used to make a incision down to right ramus of the mandible along oblique ridge.
- Elevate the periosteum on buccal cortex and use a notch retractor to lift the insertion of the temporalis on the coronoid.
- The lingula is identified on the lingual cortex, and a flap superior to this is elevated.
- A reciprocating saw or Lindemann bur is used to make a medial corticotomy followed by the vestibular osteotomy, with care taken superiorly to avoid damage to the nerve.
- These osteotomies are joined using the reciprocating saw or 702 bur.
- A mallet and osteotomes are used to carefully complete the osteotomy.
- The inferior alveolar nerve should be noted in the distal segment.
- A similar procedure should be carried out on the left side. All wounds are thoroughly irrigated.
- The patient is then placed in the final occlusion splint, secured with 24- or 26-g wire.
- Bicortical positioning screws or screws for plating can be placed via a transcutaneous trochar. True rigid fixation is imperative for large advancements typically encountered in surgery for sleep apnea.
- The MMF is removed, and occlusion is checked.
- All wounds should be irrigated. Hemostasis is obtained.

Closure

- For mandible, 3.0 chromic gut used to re-approximate periosteum and running, locking 3.0 chromic gut for mucosa
- For maxilla, 4.0 Vicryl to re-approximate muscle
- The mucosa is closed using 3.0 chromic gut in a running fashion.
- Oropharynx is thoroughly suctioned and throat pack removed.
- Trochar incisions are closed with 5.0 fast gut.
- A facial support (jaw bra) dressing is placed.
- The patient is returned to anesthesia.

COMMON ERRORS IN TECHNIQUE

Fixation for this procedure may vary depending on how large the movements are. Midface plates and screws are standard for the maxillary Le Fort fixation. Positional and/or lag screws are the minimum for the mandible; however, the authors feel that most mandibular advancements are large and that counterclockwise movements to enhance genioglossus advancements are common; therefore more rigid fixation with plates and screws are standard in our practice.

Complications

- Permanent paresthesia (12%)—risk minimized by careful identification and protection of the inferior alveolar nerve during sagittal split osteotomy
- Malocclusion—premature contact is common (44%) in the first 6 weeks, whereas long-term malocclusion is rare
- Hardware infection (1% to 33%)—the plates and screws can be safely removed 3 months after surgery, if necessary
- Nonunion/malunion (3%)—consider bone grafts for particularly large advancements to minimize risk for malunion (Fig. 59.3)

Evidence-Based Medicine Question

Does MMA provide a safe and stable long-term treatment option for moderate to severe sleep apnea?

- MMA is a clinically effective long-term treatment for patients with moderate to severe OSA because it predictably produces substantial and sustained reductions in AHI, blood pressure (BP), and subjective sleepiness, with concomitant significant improvements in quality of life (QOL).[5]
- Successful outcomes are routinely achieved with minimal short-term and long-term treatment-related adverse outcomes.

Editorial Comment

For decades Orthognathic surgery has been used successfully to manage OSA. Advances in preoperative imaging and virtual planning, as well as refinements in intraoperative technique, have led to further improvements in outcomes. The published high surgical success rates warrant consideration of this treatment modality in properly selected patients, particularly those

with severe refractory OSA or those with pre-existing skeletal deficiency. Nevertheless, the increased potential morbidity and risk compared with other OSA treatments also limit the generalizability and widespread use of skeletal advancement surgery in a large portion of the OSA population, particularly the milder end of the disease spectrum.

Ryan Soose

Access the review questions online at http://www.expertconsult.com

REFERENCES

1. Fonseca RJ, Marciani RD, Turvey TA. Oral and Maxillofacial Surgery. 2nd ed. vol. 3. St. Louis, Missouri: Saunders; 2009. p. 171.
2. Li KK, Riley RW, Powell NB, Guilleminault C. Maxillomandibular advancement for persistent obstructive sleep apnea after phase I surgery in patients without maxillomandibular deficiency. Laryngoscope 2000;110:1684–1688.
3. Zaghi S, Holty JE, Certal V, et al. Maxillomandibular advancement for treatment of obstructive sleep apnea: a meta-analysis. JAMA Otolaryngol Head Neck Surg 2016;142:58–66.
4. Giarda M, Brucoli M, Arcuri F, et al. Efficacy and safety of maxillomandibular advancement in treatment of obstructive sleep apnea syndrome. Acta Otorhinolarnygol Ital 2013;33(1):43–46.
5. Holty JE, Guilleminault C. Maxillomandibular advancement for the treatment of obstructive sleep apnea: a systematic review and meta-analysis. Sleep Med Rev 2010;14:287–297.

REVIEW QUESTIONS

1. All of the following are known side effects of maxillomandibular advancement (MMA), except
   a. Lower lip numbness
   b. Change in facial appearance
   c. Change in occlusion
   d. Trismus

2. Using polysomnogram criteria of reduction in baseline apnea-hypopnea index (AHI) by 50% and AHI less than 20, the success rate of MMA is approximately
   a. 50%
   b. 70%
   c. 90%
   d. 99%

3. To avoid damage to the inferior alveolar nerve during the bilateral sagittal split osteotomy, this bony landmark should be identified
   a. Antegonial notch
   b. Lingula
   c. Maxillary tuberosity
   d. Oblique ridge

60 Office-Based Procedures: Fine-Needle Aspiration Biopsy of a Mass in the Head and Neck

Jason I. Kass

INTRODUCTION

When evaluating a patient with a mass in the head and neck, the fine-needle aspiration biopsy (FNAB) plays a critical role in the initial workup. It can help establish a diagnosis, among a wide variety of pathology, including infectious, benign, and malignant lesions. Needle biopsy, first popularized in the 1920s by Dr. Hayes Martin at Memorial Sloan-Kettering Hospital, has been used for more than 100 years.[1] While he used large-bore needles under local anesthesia, it did not gain widespread acceptance in the United States until finer needles were available. Advances in cytology have made pathologists more comfortable in making a diagnosis, allowing head and neck surgeons to avoid unnecessary open biopsies.

FNAB is easily performed in the office, with high diagnostic accuracy, for both benign (95%) and malignant (87%) lesions. The technique can be used in a variety of sites in the head and neck, including the salivary glands, thyroid, and lymph node metastases. With a preoperative diagnosis, a definitive surgical plan prior to treatment can be established and discussed with the patient. FNAB is a minimally invasive technique, which allows for repeat sampling in the cases of a nondiagnostic specimen. It is safe, accurate, and cost-effective.

Fine-Needle Aspiration Biopsy for Thyroid Disease

Thyroid nodules, particularly in women, are a common finding. The American thyroid association (ATA) recommends a FNAB in all euthyroid and hypothyroid patients with suspicious lesions seen on a screening ultrasound (Table 60.1).[2] When evaluating thyroid lesions, the FNAB sample can be used for both histologic and molecular analysis. The specimens can also be stained and evaluated at the time of FNAB. This can provide both qualitative assessment of the specimen and often confirms the diagnosis. Thyroid cytopathology is typically reported using the Bethesda system (Table 60.2). Cytopathology in benign disease has an estimated risk of malignancy less than 3%, while those that are suspicious for malignancy vary between 60% and 75%. Cytopathology in cases of malignancy is 99% accurate. Not all thyroid cancers can be diagnosed by FNAB. Follicular adenomas are indistinguishable from carcinomas on needle biopsy. Therefore the report of a follicular neoplasm only carries a 15% to 30% risk of malignancy.

Fine-Needle Aspiration Biopsy for Salivary Gland Disease

Lesions of the parotid and submandibular glands can be readily accessible to sampling by FNAB. While not every mass needs to be biopsied, any patient who presents with pain, facial weakness, numbness, or a mass in the parotid gland should have an FNAB. FNAB can also support a decision not to operate, in patients with a normal clinical examination and benign cytopathologic diagnosis. For example, a Warthin tumor has an exceedingly low malignant potential and in many cases can be observed. FNAB has very high overall accuracy (90% to 95%) at distinguishing benign from malignant lesions; however, it is not reliable at determining the malignant subtype and tumor grade. In some low-grade malignancies, such as acinic cell carcinoma, it can be misinterpreted as benign or non-neoplastic. Low-grade lymphomas can be missed and erroneously reported as inflammation. Therefore a negative diagnosis must be viewed within the clinical context. If there are suspicious clinical or radiographic findings, either a repeat FNAB or excisional biopsy should be considered.

Fine-Needle Aspiration Biopsy for the Mass in the Neck

All palpable masses in the neck, in both adults and children, can be safely assessed with an FNAB.[3] Additionally, in most cases, ultrasound or computed tomography (CT) guidance can be used to localize and biopsy challenging or nonpalpable lesions. With lymphadenopathy, a specific diagnosis is obtained in 82% to 96% of cases. Cell blocks from the FNAB can be used for either immunohistochemistry or polymerase chain reaction (PCR)-based analysis. When a lymphoma is suspected, FNAB can rapidly establish a diagnosis and often avoid open neck biopsies.[4] Improvements in immunologic methods have allowed an FNAB specimen to be sufficient to establish the diagnosis of lymphoma with at least two needle passes.[5] In cases when an open biopsy is necessary to determine a gene rearrangement, reactive, inflammatory, and metastatic tumors are excluded, limiting the confirmatory diagnostic tests.

KEY OPERATIVE LEARNING POINTS

- Distinguishing benign from malignant cervical masses, rapid assessment, potential avoidance of surgical intervention, low complication rates, and cost-effectiveness have made FNAB diagnosis of masses in the head and neck the standard of care.
- FNAB for thyroid follicular lesions cannot differentiate benign from malignant neoplasms.
- A cystic mass in the lateral aspect of the neck, in an adult, with squamous cells should be considered malignant until proven otherwise. These masses are usually a cystic form of metastatic squamous cell carcinoma, usually from the base of the tongue or tonsil, and should not be mistaken for a branchial cleft cyst.

TABLE 60.1 Sonographic Patterns, Estimated Risk of Malignancy, and Fine-Needle Aspiration Guidance for Thyroid Nodules

Sonographic Pattern	US Features	Estimated Risk of Malignancy, %	FNA Size Cutoff (Largest Dimension)
High suspicion	Solid hypoechoic nodule or solid hypoechoic component of a partially cystic nodule with one or more of the following features: irregular margins (infiltrative, microlobulated), microcalcifications, taller than wide shape, rim calcifications with small extrusive soft tissue component, evidence of ETE	>70–90*	Recommend FNA at ≥1 cm
Intermediate suspicion	Hypoechoic solid nodule with smooth margins without microcalcifications, ETE, or taller than wide shape	10–20	Recommend FNA at ≥1 cm
Low suspicion	Isoechoic or hyperechoic solid nodule, or partially cystic nodule with eccentric solid areas, without microcalcification, irregular margin or ETE, or taller than wide shape	5–10	Recommend FNA at ≥1.5 cm
Very low suspicion	Spongiform or partially cystic nodules *without* any of the sonographic features described in low, intermediate, or high suspicion patterns	<3	Consider FNA at ≥2 cm Observation without FNA is also a reasonable option
Benign	Purely cystic nodules (no solid component)	<1	No biopsy†

ETE, Extrathyrodial extension.
US-guided FNA is recommended for cervical lymph nodes that are sonographically suspicious for thyroid cancer.
*The estimate is derived from high volume centers; the overall risk of malignancy may be lower, given the interobserver variability in sonography.
†Aspiration of the cyst may be considered for symptomatic or cosmetic drainage.
With permission from Haugen BR, Alexander EK, Bible KC, et al: 2015 American Thyroid Association management guidelines for adult patients with thyroid nodules and differentiated thyroid cancer: The American Thyroid Association guidelines task force on thyroid nodules and differentiated thyroid cancer. Thyroid 26(1):1–133, 2016, http://dx.doi.org/10.1089/thy.2015.0020.

TABLE 60.2 The Bethesda System for Reporting: Thyroid Cytopathology: Diagnostic Categories and Risk of Malignancy*

Diagnostic Category	Estimated/Predicted Risk of Malignancy by the Bethesda System (%)*	Actual Risk of Malignancy in Nodules Surgically Excised, % Median (Ranges)†
Nondiagnostic or unsatisfactory	1–4	20 (9–32)
Benign	0–3	2.5 (1–10)
Atypia of undetermined significance or follicular lesion of undetermined significance	5–15	14 (6–48)
Follicular neoplasm or suspicious for a follicular neoplasm	15–30	25 (14–34)
Suspicious for malignancy	60–75	70 (53–97)
Malignant	97–99	99 (94–100)

*As reported in The Bethesda System by Cibas ES, Ali SZ: The Bethesda System for reporting thyroid cytopathology. Am J Clin Pathol 132:658–665, 2009, http://dx.doi.org/10.1309/AJCPPHLWMI3JV4LA.
†Based on the meta-analysis of eight studies reported by Bongiovanni M, Spitale A, Faquin WC, et al: The Bethesda System for reporting thyroid cytopathology: A meta-analysis. Acta Cytol 56:333–339, 2012. The risk was calculated based on the portion of nodules in each diagnostic category that underwent surgical excision and likely is not representative of the entire population, particularly of nondiagnostic and benign diagnostic categories.
With permission from Haugen BR, Alexander EK, Bible KC, et al: 2015 American Thyroid Association management guidelines for adult patients with thyroid nodules and differentiated thyroid cancer: The American Thyroid Association guidelines task force on thyroid nodules and differentiated thyroid cancer. Thyroid 26(1):1–133, 2016, http://dx.doi.org/10.1089/thy.2015.0020.

PREOPERATIVE PERIOD

History

- History of present illness
  - Initial appearance of the mass in the head and neck
  - Change in size over time
  - Associated symptoms (pain, numbness, change in voice, facial weakness)
  - Presence of lymphadenopathy beyond the head and neck
- Past medical history
  - Radiation exposure
  - Previous attempts at biopsy
  - Previous treatment, particularly for cancer of the head and neck, or prior drainage of a cystic neck mass
- Family history
- Travel history
- Infectious history
- Medications
  - Anticoagulants

Physical Examination

- Palpable mass
- Mass characteristics (pain, fluctuance, overlying skin color changes)

Imaging

- None required for palpable masses
- Ultrasound-guided FNAB for nonpalpable masses and most thyroid nodules

Indications

- Masses in the neck (cystic and solid)
- Parotid lesions
- Thyroid nodules
- Palpable subcutaneous facial masses, including scalp

Contraindications

- There are no specific medical contraindications to the procedure.
  - A small hematoma may occur if the patient is on anticoagulants. Even vascular masses including carotid body tumors may be biopsied with a fine-gauge needle using manual external pressure to minimize bleeding. Surgeons may prefer not to perform these biopsies if the patient is also anticoagulated.

Preoperative Preparation

Informed consent should be obtained prior to performing an FNAB. Risks include a small amount of bleeding and/or bruise, infection, and a nondiagnostic specimen.

OPERATIVE PERIOD

Anesthesia

- Local anesthesia is optional, and most adult patients are able to tolerate the small gauge needle without discomfort.
- For increased comfort, I infiltrate the skin and subcutaneous tissue with 1% lidocaine with a 1:100,000 dilution of epinephrine.
- For children, sodium bicarbonate can also be included in a 1:10 dilution to buffer the lidocaine.
- Buffered lidocaine is nearly painless and very well tolerated.

Positioning

- Thyroid biopsy
  - Extend the neck with a pillow under the shoulders.
  - The individual performing the FNA may be more comfortable standing on the opposite side of the mass.
- Mass in the neck or parotid
  - Turn the head so that the mass is as superficial as possible.
  - For neck nodes, pushing from behind the sternocleidomastoid may make the mass more superficial (Fig. 60.1).

Perioperative Antibiotic Prophylaxis

- Antibiotics are not indicated. Cleaning the skin with an alcohol swab is sufficient.

Monitoring

- The procedure is performed with local injection with the patient awake, so monitoring is not required.

Instruments and Equipment to Have Available

- 20-mL syringe
- Syringe holder (optional)
- Glass slides with the patient's name written on the frosted end
- 1- to 1½-inch 21- to 25-gauge needles
- 95% alcohol or a spray fixative to fix the aspirate
- Alcohol swabs and gauze pad
- Balanced salt solution for rinsing the needle
- Small adhesive bandage (Fig. 60.2)

Key Anatomic Landmarks

- For nonultrasound guided FNAs, the mass should be palpable. While specific landmarks depend on the nearby structures, it is often helpful to identify the carotid artery and carotid bulb when performing an FNA on the lateral neck.

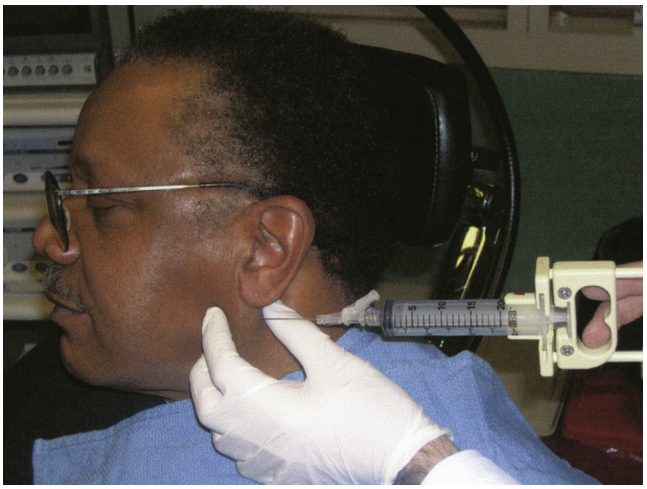

Fig. 60.1. The patient is positioned comfortably with a headrest. The surgeon may stand opposite the mass to secure it manually. The needle is introduced and multiple (15 to 20) short passes are made until material is observed within the needle hub. If excessive blood is noted, suction can be reduced or eliminated and passes continued through the mass.

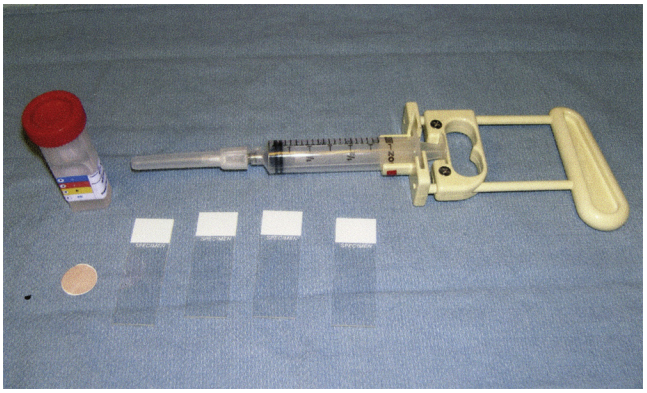

Fig. 60.2. Cytology slides, fixative, a 20-mL syringe with a holder, and a 22- to 25-gauge needle.

Prerequisite Skills

- No specific prerequisite skills are required; however, beginners have higher rates of nondiagnostic specimens.

Operative Risks

- The procedure is generally very safe. Risks include a small amount of bleeding and/or bruise, infection, and a nondiagnostic specimen. As with any in-office procedure, the surgeon should also be prepared to manage vasovagal syncope, should it occur.

Surgical Technique

- Aspiration technique
  - 20-cubic centimeter syringe with 1 mL of air placed in a syringe holder
  - Clean the area over the proposed puncture site with an alcohol swab.
  - If you are injecting local anesthesia, infiltrate the skin around the biopsy site with 1% lidocaine with a 1:100,000 dilution of epinephrine.

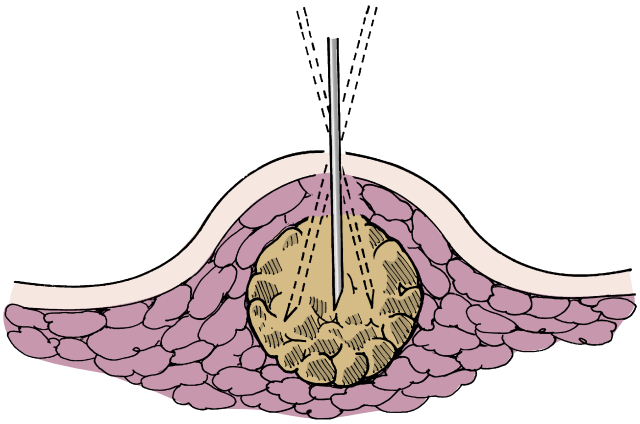

Fig. 60.3. The needle is moved in and out of the mass in short vibratory strokes for a distance of 2 to 3 mm.

- Localize the mass with the thumb and index finger of the nondominant hand and prevent it from moving. Stretching the skin also acts to decrease the pain.
- Place the needle inside the mass and pull back on the syringe, creating a vacuum.
- The needle is rapidly moved into and out of the mass in short distances, so as not to lose the vacuum. Care is taken not to move the direction of the needle, because it is more uncomfortable and can tear small blood vessels. This will make the specimen bloody and more difficult to interpret (Fig. 60.3).
- Watch the hub of the needle. Once material is seen in the hub, the vacuum on the syringe is released and the needle is withdrawn.
- This is repeated 3 to 4 times to ensure an adequate specimen is obtained.
- Gentle pressure is placed over the puncture site, and then an adhesive bandage can be placed.

- Nonaspiration technique
  - As noted previously, except the needle is place into the mass, and *no* vacuum pressure is applied. This can be useful for thyroid specimens or where negative pressure leads to a bloody specimen.
  - The nonaspiration technique can be performed with just the needle and no syringe attached.

Specimen Handling

- The content of the needle is pushed onto two glass slides, with the beveled edge of the needle touching the slide.
- The slides are then touched together to create a smear of the aspirated material on each slide.
- They are then quickly wet-fixed, using a 95% ethyl alcohol spray, held 8 to 10 inches from the slide.
- The needle should then be rinsed in a balanced salt solution (not normal saline). This specimen can be processed for microbiology or immunophenotyping by flow cytometry.
- It is preferable if the slides can be processed while the patient is present, to determine specimen adequacy. Obtain another pass if the slides are inadequate. One method for scoring specimens is provided in Box 60.1. Although it was originally designed for analysis of thyroid cytology at the University of Pittsburgh, it can be applied to other types of specimens.

Common Errors in Technique

- Exposure of cytology slides to air for prolonged periods before fixation leads to an air-drying artifact, which limits the quality of the specimen.

BOX 60.1 Thyroid Cytology Report of the Adequacy of Analysis

SATISFACTORY FOR INTERPRETATION

The specimen fulfills one of the diagnostic patterns listed.

LESS THAN OPTIMAL

The specimen is at least modestly cellular but does not fulfill all requirements for the diagnostic categories listed (nonspecific pattern).

UNSATISFACTORY

The specimen fails to show one of the patterns listed.

RECOMMENDED SEMIQUANTITATIVE GRADING OF ADEQUACY

Background Grade

0—Bloody background with little or no colloid

1—Bloody background with little or no colloid, and macrophages and/or inflammatory elements

2—Definite areas of sharply demarcated watery colloid with typical wrinkles/crackled features on at least one slide, with or without a bloody background, with or without macrophages and inflammatory elements

3—Abundant sharply demarcated watery colloid with typical wrinkles/crackled features on many slides, with or without macrophages and inflammatory elements, minimal or no blood

Cellularity Grade

0—Less than 8 to 10 cellular fragments (at least 10 cells) on two slides

1—≥8 to 10 cellular fragments (at least 10 cells) on two slides

2—Cellular fragments (at least 50 cells) on 50% of the slides reviewed

3—Cellular fragments (at least 50 cells) on 100% of the slides reviewed

Cellular Preservation Grade

0—All slides are poorly preserved and difficult to evaluate because of mechanical disaggregation, obscuration as a result of thick/bloody preparation, air drying, and so on.

1—Most slides are poorly preserved and difficult to evaluate because of mechanical disaggregation, obscuration as a result of thick/bloody preparation, air drying, and so on.

2—Most slides are well preserved and difficult to evaluate because of mechanical disaggregation, obscuration as a result of thick/bloody preparation, air drying, and so on.

3—All slides are well preserved without mechanical disaggregation; obscuration is due to thick/bloody preparation, air drying, and so on.

SEMIQUANTITATIVE ADEQUACY SCORE (ADD GRADE FROM EACH CATEGORY)

4 or less = *Inadequate*—Repeat FNA

5 = *Inferior*—Sensitivity of the study may be less than standard. Additional studies, including repeat fine-needle aspiration, should be considered.

6–7 = *Satisfactory*—Specimen quality supports an optimally sensitive study.

8–9 = *Superior*—Specimen quality supports an optimally sensitive study.

Courtesy Paul Ohori, MD.

- Using high suction (negative pressure) in the syringe will lead to bloody cytologic specimens that can be difficult for the cytopathologist to interpret.
- A single negative FNAB should not be overweighed in the context of other suspicious clinical data. Concern for malignancy should prompt further cytologic or histologic analysis of the neck mass.

POSTOPERATIVE PERIOD

Postoperative Management

- A small adhesive bandage is usually sufficient to cover the biopsy site. In patients who are anticoagulated, applying pressure for several minutes is helpful.

Complications

- The most common complication is a nondiagnostic specimen. Infection and hematoma can occur but are uncommon.

Alternative Management Plan

- If the mass is not clearly palpable or the surgeon isn't confident, he/she can sample the mass, and interventional radiology or ultrasonography can assist with a targeted biopsy.
- If the tissue architecture is important, or more tissue is required, a core needle biopsy can be performed.
- In the setting of two or more nondiagnostic FNAB, an open biopsy can be used to establish a diagnosis.

DISCUSSION

Evidence-Based Medicine Question

How successful are ultrasound-guided FNAB at obtaining an adequate specimen? Do immediate cytology and specialist radiologists improve the adequacy of FNAB?

These questions were recently addressed by a meta-analysis[6] and a retrospective review of 398 specimens obtained over a 6-month period.[7] Ganguly et al. found 78 studies that specifically stated their sample inadequacy rate for ultrasound-guided FNAB. Overall specimen inadequacy rate was 9.3%, with on-site cytopathologists having a lower rate of 6%. This literature suggests that the most accurate diagnoses are obtained when a pathologist is available to immediately review the slides and determine whether another pass should be performed.

The single-institution study by Sharma et al.[7] compared four different groups: (A) FNAB all performed by radiologists with cytology support, (B) FNAB all performed by all radiologists without cytology support, (C) FNAB performed by biopsy-subspecialized radiologists with cytology support, and (D) biopsy-subspecialist radiologists without cytology support. This group found that when cytology support was present, there was a significantly lower rate of inadequate specimens. When no cytologist was present, the radiologists with more training in performing FNAB obtained better specimens. Specimen inadequacy ranged from 10% (group C) to 44% (group B).

Taken together, the literature suggests that while there is a learning curve to achieve proficiency, there is also a ceiling to the success rate. A recent review of surgeon-performed ultrasound-guided FNAB of thyroid nodules at the University of Toronto[8] examined 423 consecutive cases from 2010 to 2015. They found dramatic increases with experience (from 70.8% to 94.3%) but at their best still had a 6% specimen inadequacy rate. Reasons for nondiagnostic specimens included an inadequate number of cells, absence of follicular cells, cystic lesion, and bloody specimen.

Editorial Comment

The chapter provides a comprehensive, evidence-based overview of FNAB for thyroid, salivary gland, and neck neoplasms. While FNAB provides a cost-effective, minimally invasive mechanism to establish a working diagnosis and plan further management, it must be remembered that FNAB findings need to be correlated with clinical findings. If FNAB results do not correlate with clinical findings or intuition for a malignant neoplastic process, this index of suspicion must be further investigated with additional FNAB, core biopsies, or an open biopsy. The authors have emphasized this as well. Like ultrasonography, FNAB is operator dependent, and this technique must be cultivated and practiced to get reliable results. Head and neck ultrasound is an important aspect of head/neck examination and complements in-office FNAB. Head/neck surgeons are incorporating head/neck ultrasonography into their practices, which along with an on-site cytopathologist provides a one-stop cost-effective and efficient diagnostic option for neck masses. Witt et al. demonstrated that surgeon-performed ultrasound-guided biopsy with an on-site cytopathologist improves adequacy and accuracy of FNAB results, as compared with surgeon-performed FNAB without surgeon-performed ultrasound guidance.[9]

Rohan R. Walvekar

Access the review questions online at http://www.expertconsult.com

REFERENCES

1. Martin H. Surgery of Head and Neck Tumors. New York: Harper & Row; 1957.
2. Haugen BR, Alexander EK, Bible KC, et al. 2015 American Thyroid Association management guidelines for adult patients with thyroid nodules and differentiated thyroid cancer: The American Thyroid Association guidelines task force on thyroid nodules and differentiated thyroid cancer. Thyroid 2016;26(1):1–133.
3. Anne S, Teot LA, Mandell DL. Fine needle aspiration biopsy: role in diagnosis of pediatric head and neck masses. Int J Pediatr Otorhinolaryngol 2008;72(10):1547–1553.
4. Swart GJ, Wright C, Brundyn K, et al. Fine needle aspiration biopsy and flow cytometry in the diagnosis of lymphoma. Transfus Apher Sci 2007;37(1):71–79.
5. Demurtas A, Accinelli G, Pacchioni D, et al. Utility of flow cytometry immunophenotyping in fine-needle aspirate cytologic diagnosis of non-Hodgkin lymphoma: a series of 252 cases and review of the literature. Appl Immunohistochem Mol Morphol 2010;18(4):311–322.
6. Ganguly A, Burnside G, Nixon P. A systematic review of ultrasound-guided FNA of lesions in the head and neck—focusing on operator, sample inadequacy and presence of on-spot cytology service. Br J Radiol 2014;87(1044):20130571.
7. Sharma SD, Kumar G, Horsburgh A, et al. Do immediate cytology and specialist radiologists improve the adequacy of ultrasound-guided fine-needle aspiration cytology? Otolaryngol Head Neck Surg 2015;152(2):292–296.
8. Fernandes VT, De Santis RJ, Enepekides DJ, et al. Surgeon-performed ultrasound guided fine-needle aspirate biopsy with report of learning curve; a consecutive case-series study. J Otolaryngol Head Neck Surg 2015;44:42.
9. Witt RL, Sukumar VR, Gerges F. Surgeon-performed ultrasound-guided FNAC with on-site cytopathology improves adequacy and accuracy. Laryngoscope 2015;125(7):1633–1636.

REVIEW QUESTIONS

1. Using the 2015 ATA guidelines, which thyroid nodule should undergo FNAB?
   a. A solid hypoechoic nodule with irregular margins and microcalcifications 0.8 cm in size
   b. A purely cystic nodule 5 cm in size
   c. A partially cystic, partially solid nodule 1.3 cm in size
   d. A hypoechoic solid nodule without microcalcifications 1.0 cm in size

2. Even in experienced hands, with ultrasound guidance and immediate cytology, what is an expected rate for nondiagnostic specimens?
   a. 10%
   b. 6%
   c. 1%
   d. 15%

3. A 50-year-old man presents with a 1-cm lesion of the left parotid with subtle weakness of the left midface. FNAB produces an adequate specimen that shows inflammatory cells and is reported as benign. What is your next step?
   a. Reassure the patient; however, follow up in 3 months for a repeat examination.
   b. Reassure the patient of the benign FNAB and follow up as needed.
   c. Repeat FNAB.
   d. Plan for superficial parotidectomy with left selective neck dissection.

61 Management of the Unknown Primary Cancer

Vikas Mehta, Umamaheswar Duvvuri

INTRODUCTION

Many patients with squamous cell carcinoma of the head and neck (SCCHN) present with metastasis to the cervical lymph nodes. Metastatic carcinoma in the neck without an identifiable primary cancer is defined as a squamous cell carcinoma of the head and neck of unknown primary origin (SCCHNUP). Patients with isolated supraclavicular metastatic carcinoma usually have a primary source from the skin or infraclavicular sites of origin (stomach, breast, lung, esophagus, and ovary) and are thus not the focus of this chapter. Retrospective studies suggest that SCCHNUP is a relatively rare disease, affecting between 1% and 3% of new cases of SSCHN.[1] However, as the incidence of human papillomavirus (HPV)–associated oropharyngeal cancer, which is known to metastasize to the lymph nodes with low-volume primary disease, continues to rise, SCCHNUP will likely increase in incidence as well. Since these patients provide a particularly challenging diagnostic problem to the head and neck surgeon, a systematic approach including a thorough physical examination, appropriate imaging, and surgical evaluation is necessary to identify the site of the primary cancer.

Patients who present with SCCHNUP can be treated with either surgery followed by adjuvant treatment or primary nonsurgical therapy. The identification of the primary cancer can help better define the targeted areas for radiation therapy and provide more accurate staging and prognostic information for these patients. A diagnostic regimen that includes transoral surgery (TOS) of the base of the tongue (BOT) has demonstrated a diagnostic ability of approximately 90% of the primary cancers that otherwise would go undetected by contemporary diagnostic tools.[2,3] This chapter delineates the evaluation and management of patients with squamous cell carcinoma metastatic to the neck from an unknown primary cancer and provides new insights into the application of transoral robotic technologies for the diagnosis and treatment of patients with SCCHN of unknown primary origin.

KEY OPERATIVE LEARNING POINTS

- Initial evaluation of a SCCHNUP patient should include a thorough history and physical examination, positron-emission tomography (PET) scan, molecular testing of the fine-needle aspiration biopsy (FNA) specimen, and examination under anesthesia (EUA) with palatine tonsillectomies.
- Transoral robotic surgery (TORS) of the BOT can be safely undertaken if these methods fail to identify the primary cancer and has shown a success rate in almost 90% in those cases.
- Care must be taken to remove all of the lingual tonsillar tissue, including the lymphoid areas within the glossotonsillar sulcus, since these occult tumors can be only a few millimeters in size.

PREOPERATIVE PERIOD

History

- The most common presenting symptom in Squaous cell carcinoma unknown primary (SCCUP) is a painless mass in the neck. Nearly 40% of patients come to medical attention with a single enlarged lymph node, which is most commonly located in level 2, suggesting an occult primary cancer location in the oropharynx.[4]
- Lymphadenopathy in level 3, without involvement of level 2, suggests a primary site in the supraglottic larynx or hypopharynx.[4]
- Patients with SCCHN are traditionally heavy tobacco and/or alcohol abusers. Recently, however, a larger number of patients who report never having been smokers, or who have stopped smoking in the distant past, and have a minimal history of alcohol intake are presenting with SCCHN. These patients often have a cancer that is related to the HPV, an etiologic factor contributing to the development of their cancer. Taking a thorough history on risk factor exposure that includes not only current alcohol and tobacco consumption but also questions regarding remote history of tobacco consumption or high-risk sexual behaviors is important, since these factors may also contribute to the diagnosis of an HPV-related malignancy.
- Female patients should be asked about their gynecological history, with a specific focus on abnormal Pap smears.
- It is also important to ascertain whether these patients have complaints of hoarseness, dysphagia, odynophagia, weight loss, or otalgia, all of which may point to the site of the primary cancer.
- A dermatologic history may also be relevant, and patients should be questioned about prior skin surgery or head and neck cutaneous squamous cell carcinoma.

Physical Examination

- A thorough examination of the head and neck is warranted in all patients who present with occult nodal metastasis.
- The physical examination should include palpation of the neck to determine whether the lymph nodes are fixed to the skin or underlying structures or if they are freely mobile. Palpation should also include examination of the thyroid and tracheal regions, as well as the nodal lymphatic basins of levels I through VI.
- Many cases of SCCHNUP are initially diagnosed by excision of a mass in the neck, which is ultimately confirmed to be SCCHN. In these cases, the physical examination can be challenging, since postsurgical scarring and induration can negatively impact palpation and examination of the residual cervical lymph nodes.
- An examination of the oral cavity and oropharynx should be performed, ideally with indirect mirror-laryngoscopy to examine the BOT and tonsillar fossae. Bimanual palpation of the BOT and tonsillar fossae is also required.
- The physical examination should also include a careful evaluation of the cutaneous structures of the head and neck, since previously treated primary malignancies of the skin can present with isolated metastatic SCC. Physical stigmata of prior skin resections, such as scars or white spots from liquid nitrogen–induced cryoablation, should also be documented.
- Once this portion of the physical examination is concluded, these patients should all be subjected to flexible fiberoptic nasopharyngolaryngoscopy. This provides a better view of

the BOT, tonsil fossae, glottis, hypopharynx, and supraglottic structures. It is important to evaluate vocal fold mobility and to look for areas of salivary pooling or submucosal masses in the postcricoid area. The nasopharynx should also be examined to exclude the possibility of an occult nasopharyngeal carcinoma.

Imaging

- Computed tomography (CT) and/or magnetic resonance imaging (MRI) with contrast is generally considered to be the first-line imaging for patients with SCCHNUP.
- If the CT and MRI do not identify the primary cancer, a PET with integrated CT (PET/CT) may be useful. If a PET/CT scan is performed, it should be done before panendoscopy, since the PET can potentially guide the surgeon, and the biopsies or surgical interventions may in fact induce FDG avidity on the PET/CT scan, thus resulting in a false positive. With addition of PET and fusion PET/CT images, a recent meta-analysis of patients with unknown primary cancer demonstrated an improved detection rate of 37.5% by adding PET/CT to the standard evaluation, with a sensitivity and specificity of 84% overall.[5]

Indications

Patients who present with a diagnosis of SCCHNUP are candidates for this procedure. The diagnosis of SCCHNUP should be established on the basis of pathologic evaluation of enlarged cervical lymph node(s).

Contraindications

There are no contraindications to surgery based on anatomic factors. However, patients who have significant medical comorbidities that may preclude the administration of general anesthesia may not be candidates for surgery. Those patients who have a demonstrable primary cancer that appears deeply invasive on preoperative imaging do not require robotic surgery to identify the primary cancer.

Preoperative Preparation

- Even with an extensive investigation and a thorough physical examination, a primary cancer may not be found. New diagnostic procedures can potentially aid in the identification of the primary cancer or at least suggest a subsite from which the primary cancer could have arisen.
- The majority of primary cancers that are identified among patients with SCCHNUP are located within the oropharynx.[6]
- Furthermore, recent studies suggest that a large percentage (up to 70%) of SCC of the oropharynx are HPV related, and only a small percentage of cancers from nonoropharyngeal sites in the head and neck are HPV related.[7] Therefore, detection of HPV within tissue biopsies from the lymph node strongly suggests the oropharynx as the primary source. Immunohistochemical analysis of p16 is a valuable biomarker and can identify those cancers that are associated with HPV infection. HPV in situ hybridization also provides confirmatory data that validate HPV etiology.
- Detection of HPV or Epstein-Barr virus (EBV) in the FNA from a metastatic lymph node may be useful and can provide prognostic information. EBV is also a sensitive marker for nasopharyngeal carcinoma, and positivity on lymph node aspirates for EBV strongly suggests a primary nasopharyngeal source. It should be noted that nasopharyngeal carcinoma typically metastasizes to the posterior neck (level 5), and isolated level 5 nodal metastases in a patient should raise the index of suspicion for an occult primary in the nasopharynx. However, despite the relatively high frequency of HPV and EBV positive cancers of the oropharynx and nasopharynx, respectively, a negative result does not necessary exclude the oropharynx or nasopharynx as the source of the primary cancer.
- Care must also be taken in relying solely on these biomarkers, as cutaneous malignancies have been shown to be p16 positive,[4] and nasopharyngeal cancers have demonstrated HPV positivity.[8]

OPERATIVE PERIOD

Patients in whom the unknown primary cancer remains occult despite having an extensive evaluation, including PET/CT scan, tonsillectomy, and directed biopsies of the nasopharynx/BOT, may benefit from a robotic BOT resection to identify the primary cancer. In prior series, the lingual tonsillectomy has demonstrated an approximately 90% success rate in finding the primary tumor when the standard methods have failed.[2,3] This method is especially useful when HPV positivity has been demonstrated in the metastatic node. The overall goal of the robotic BOT resection procedure is to use an en bloc resection approach under high magnification to remove all lingual tonsil tissue from the inferior portion of Waldeyer's ring as a method of identifying the primary cancer.

Anesthesia

General anesthesia. A small (6-0) regular endotracheal tube can be used intraorally with the tube taped to the contralateral side of the mouth from the mass in the neck. If robotic surgery is being considered after a prior EUA and directed biopsies, nasotracheal intubation can also be considered to further optimize surgical space for TORS but is not a requirement for TORS.

Positioning

- The table should be turned 180 degrees and the upper and lower teeth protected with a nasal splint that is bisected and molded to the teeth.
- A 2-0 silk suture is then placed in the midline of the tongue, which is a half mattress to allow for traction to be placed on the tongue.
- Both arms are then tucked for the patient (Fig. 61.1).

Perioperative Antibiotic Prophylaxis

- Clean contaminated surgery
- Antibiotics are administered during induction of anesthesia and continued for 24 hours.
- Choices
  - Clindamycin
  - Amoxicillin-clavulanate
  - Cephalosporin and metronidazole

Monitoring

- The surgeon and surgical team including anesthesia need to work together to monitor the patient during robotic surgery. For example, attention should be directed to ensure that robotic instrumentation is not clashing with mouth retractors or each other or causing trauma to the patient. In addition, care must be taken to avoid inadvertent extubation during the procedure from manipulation of the endotracheal tube by the surgeon or the assistant.

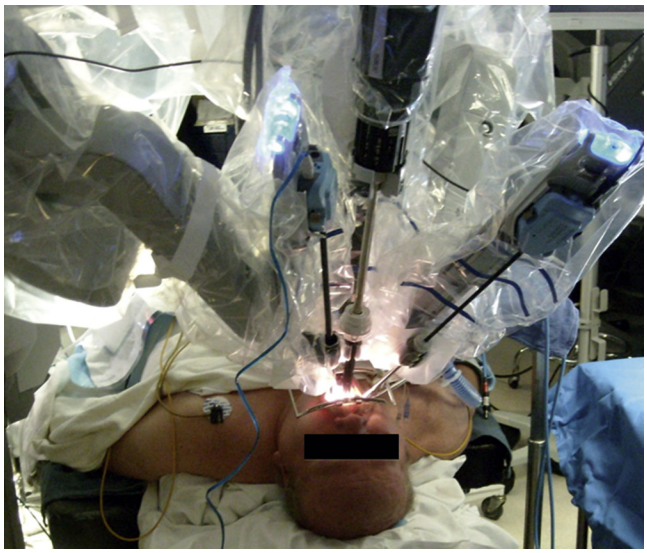

Fig. 61.1. Depiction of the placement of robotic instruments in the transoral robotic surgery approach for base of tongue resection. The patient's mouth is retracted using a Dingman retractor with a flat blade. The da Vinci robot is then docked with instruments in the patient's mouth.

- Particular attention is required to ensure that the height of the operating room table is not changed during the procedure. The robotic instruments are docked in the oral cavity in a fixed position. Relative movement of the patient to the instrument position (up-toward and down-away from the instruments in a sudden fashion) can cause inadvertent damage to the oral cavity or pharyngeal tissues.

Instruments and Equipment to Have Available

- Operating headlight
- Tooth guard
- Dingman, Crowe Davis, or Feyh-Kastenbauer (FK) retractor with various size flat tongue retractor blades
- da Vinci Robotic System (Intuitive Surgical)
- 5-mm spatula tip monopolar cautery
- 5-mm Maryland dissector
- 2-0 silk suture
- The patient's mouth is opened using a mouth gag with the flat retractor blade. It should be noted that the exposure obtained should demonstrate the circumvallate papillae and the lateral pharyngeal walls (Fig. 61.2). Once this exposure is obtained, the mouth gag is then suspended from a Mayo stand.

Key Anatomic Landmarks

- Circumvallate papillae
- Glossotonsillar sulcus and lingual artery
- Vallecula and epiglottis

Prerequisite Skills

- Experience with open head and neck surgery procedures
- Transoral robotic surgery training

Operative Risks

- There is a potential risk of injury to the lingual artery, which can result in significant bleeding. However, the robotic lingual tonsillectomy procedure does not resect a significant portion of intrinsic tongue musculature, and therefore the lingual artery is not at significant risk in many of these cases.
- There is, however, the possibility of experiencing some postoperative bleeding when the eschar that covers the surgical defect sloughs off. Most bleeding can be treated with observation or topical cautery if it occurs from a more anterior portion of the BOT.
- More active bleeding or bleeding from a deeper portion of the surgical wound may require control of the bleeding in the operating room. Neither author of this chapter has ever had to take a patient back to the operating room for surgical management of postoperative bleeding in a TORS SCCHNUP patient.
- Potential damage to the oral cavity from the mouth gag and/or robotic instruments

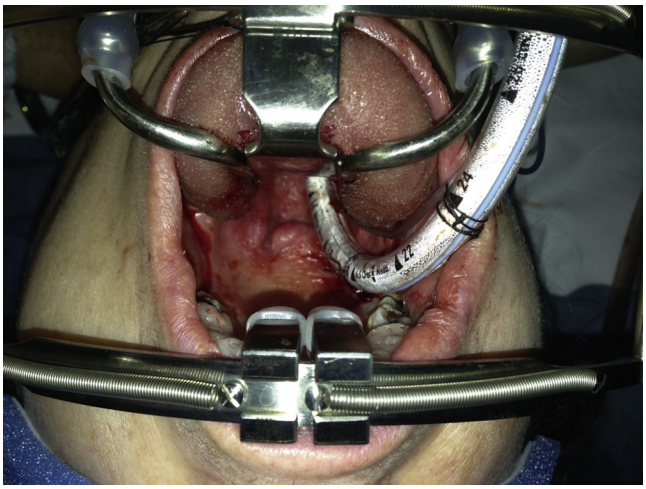

Fig. 61.2. The exposure of the oropharynx is obtained using a Dingman mouth retractor with a flat blade. The endotracheal tube is sutured to one side. The lateral pharyngeal walls and the circumvallate papillae are exposed.

Surgical Technique

- A direct laryngoscopy and examination should be performed under anesthesia to evaluate the oral cavity, oropharynx, larynx, and hypopharynx.
- If a nasopharyngeal cancer is suspected, a dedicated nasal examination with an endoscope and biopsies can be useful.
- An esophagoscopy should also be performed, along with laryngoscopy.
- Bimanual palpation of the mucosal surfaces of the BOT and tonsil while the patient is under anesthesia is essential to obtain a better examination of these areas, since the tumors often grow in an endophytic fashion within the tonsillar crypts.
- Directed biopsies to the areas of clinical suspicion of the BOT should be performed to try to identify the occult primary cancer.
- If an obvious cancer is not seen, a bilateral palatine tonsillectomy should be performed in patients with adequate lymphoid tonsil tissues as part of the initial evaluation. Approximately 10% of cancers of the tonsil will have contralateral cervical lymph node metastases, and thus a prophylactic bilateral palatine tonsillectomy for these patients is necessary.[9] In those patients in whom the radiographic imaging and initial operative endoscopy do not reveal the primary cancer, additional evaluation is warranted. Intraoperative consultation with the pathologist for the evaluation of palatine tonsils is generally of limited value, since

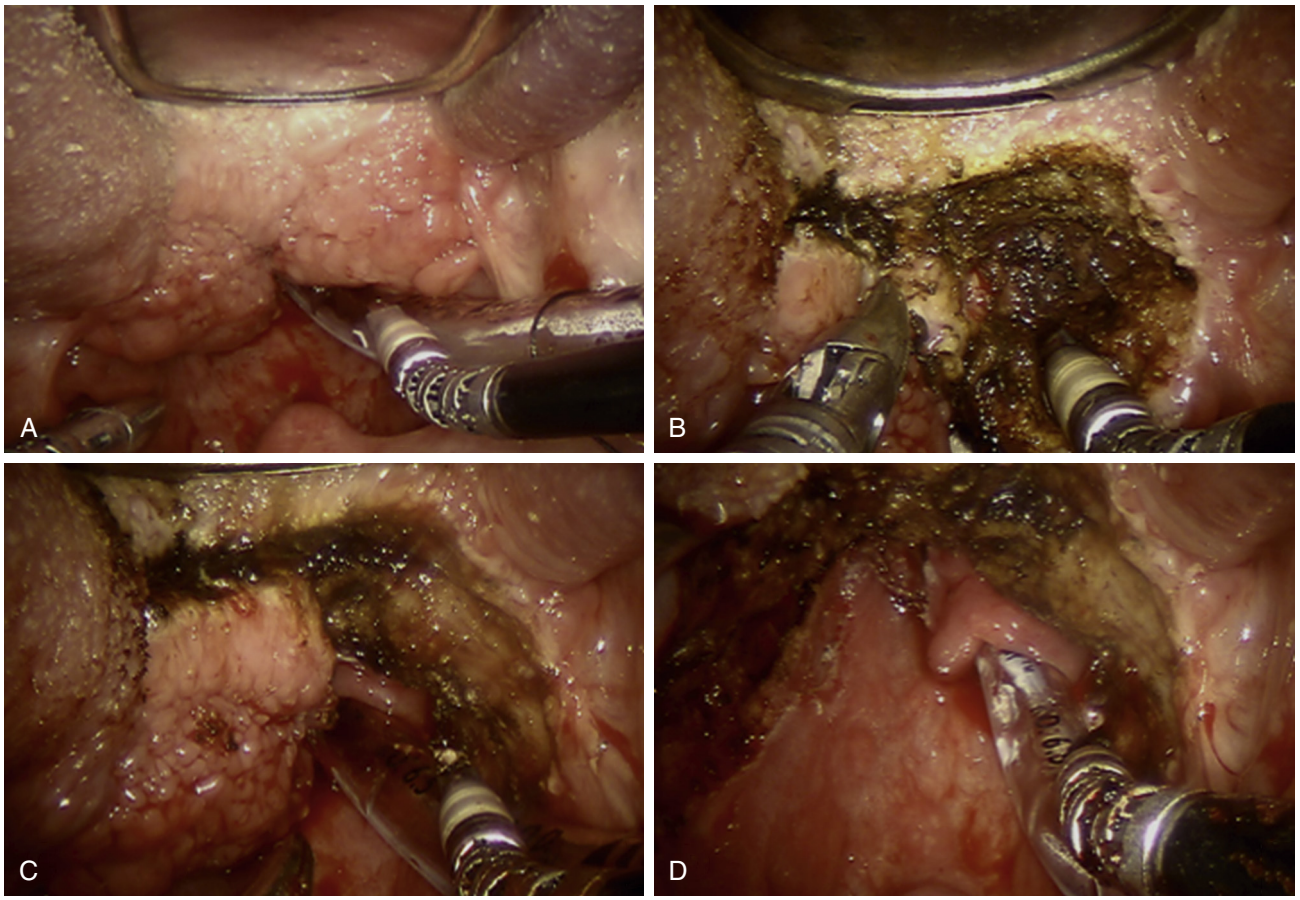

Fig. 61.3. A, The view of the lingual tonsils with the retractor in place. **B,** The initial incision is made along the circumvallate papillae from the left to right side. The lingual tonsil is then bisected in the midline, and a unilateral lingual tonsillectomy is performed. The dissection plane is to the level of the musculature of the base of the tongue (BOT). The dissection is then carried from midline to lateral, taking care to transect the glossotonsillar fold and remove any tonsil tissue that is present in the glossotonsillar sulcus. The dissection is then carried inferiorly to the level of the vallecula. **C,** The unilateral portion of the BOT is then removed. **D,** Once the dissection is completed on one side, a similar procedure is performed on the contralateral BOT. Here the bilateral lingual tonsils have been removed.

many cancers of unknown primary origin tend to be very small. We prefer therefore to send the palatine tonsils for permanent section evaluation.

- If these measures fail to find the primary source, the BOT should then be addressed, and a robotic assisted lingual tonsillectomy can be performed in these patients at the same sitting as the performance of the palatine tonsillectomies, especially if the neck metastases have been shown to be HPV positive.

Surgical Technique: Transoral Robotic Surgery

- After opening the mouth and exposing the BOT, the surgical robot is brought into the field. The arms of the surgical robot are then brought into position and introduced into the patient's mouth for the TORS approach. We use a 5-mm Maryland and a 5-mm cautery Bovie to perform the dissection.
- The initial incision is made along the circumvallate papillae from the left to right side.
- The lingual tonsil is then bisected in the midline, and a unilateral lingual tonsillectomy is performed (Fig. 61.3).
- The dissection plane is to the level of the musculature of the BOT. Since this is a diagnostic procedure as well as a resection of a relatively small cancer, the muscle of the BOT should not be violated or resected. By avoiding the muscle, inadvertent entry into the lingual artery and/or unnecessary morbidity can be avoided.
- The dissection is then carried from midline to lateral taking care to transect the glossotonsillar fold and remove any tonsil tissue that is present in the glossotonsillar sulcus. It should be noted that leaving lymphoid tissue at the area of the glossotonsillar sulcus could result in missed diagnosis, since many occult primary cancers can be quite small (on the order of a few millimeters in size).[2]
- The dissection is then carried inferiorly to the level of the vallecula. The area of the vallecula is easily identified by the appearance of minor salivary glands, which appears as small white lobular tissue, at the area of the vallecula. There are often small blood vessels in this area that supply the mucosa and can be easily controlled with electrocautery. Care must be taken not to transect the epiglottis or inadvertently injure the supraglottic structures (see Fig. 61.3).
- Once the dissection is completed on one side, a similar procedure is performed on the contralateral BOT.
- This specimen is then oriented on the back table with suture and ideally inked for orientation for the pathologist (Fig. 61.4). The tissue is then delivered to the pathologist for consultation and microscopic evaluation using frozen section technique.
- We prefer to start the dissection by performing ipsilateral resection of the BOT to the nodal metastasis in the initial setting. If the primary is grossly identified in the resection specimen, the contralateral half can occasionally be spared. However, it is known that cancer of the BOT can have bilateral metastasis.

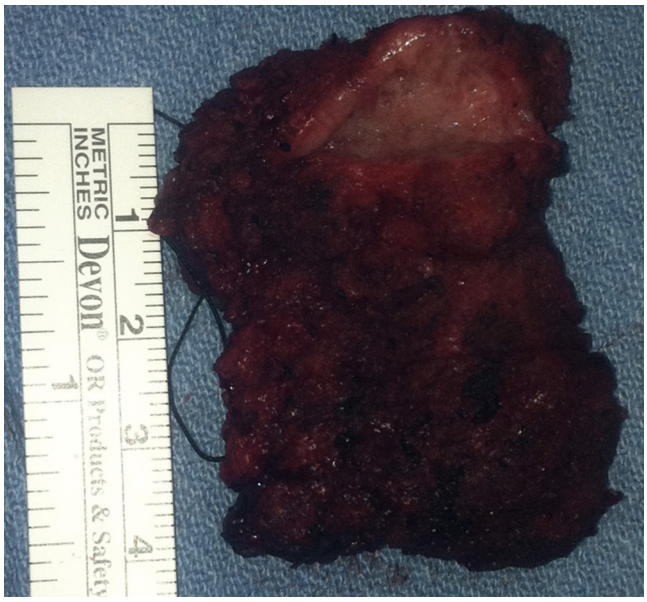

Fig. 61.4. A typical resection specimen is shown. The entire extent of the base of the tongue is resected from the left glossotonsillar sulcus to the right glossotonsillar sulcus and inferiorly to the valleculae.

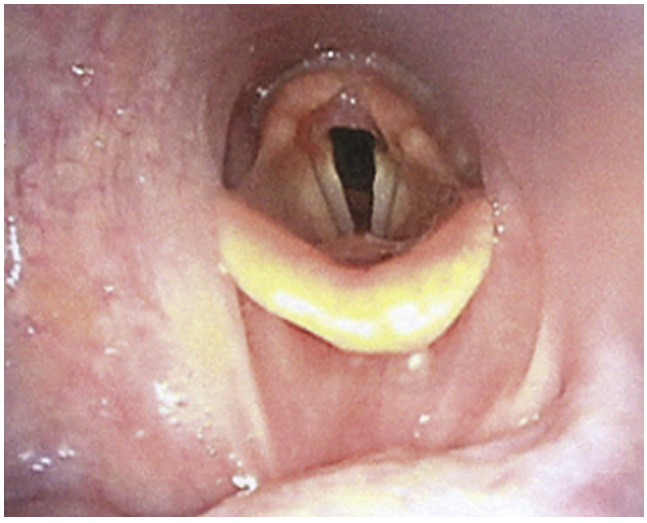

Fig. 61.5. The appearance of the tongue base 2 months after robotic assisted resection. This is the appearance prior to initiation of radiation therapy. The vallecula is preserved, and the tongue base is well healed.

We have documented an approximate 8% rate of nodal metastasis from an occult cancer of the BOT in the contralateral half. For this reason, we prefer to offer bilateral lingual tonsillectomy for patients with metastatic carcinoma from an unknown primary site.

- The wound is irrigated with cool saline and suctioned clear. A orogastric tube is passed down to the patient's stomach, and the stomach contents are evacuated. Floseal can be applied to the base of tongue to prevent oozing, but this is not required if no oozing is noted.

Common Errors in Technique

- As mentioned previously, a common mistake is not resecting all of the tonsillar tissue, especially within the glossotonsillar sulcus. These tumors can be only a few millimeters in size and thus require a complete lingual tonsillectomy.
- Care should be taken to avoid damaging the supraglottic structures.
- Avoid developing a plane that is too deep into the tongue that risks causing unnecessary bleeding, increases risk of postoperative hemorrhage by possibly damaging the lingual artery, and increases postoperative pain/dysphagia.

POSTOPERATIVE PERIOD

Postoperative Management

- Patients who have undergone TORS for an unknown primary cancer are extubated in the operating room or upon transfer to the postoperative recovery unit.
- The patients are then managed in the hospital overnight with intravenous pain medication as well as GI prophylaxis with proton pump inhibitors and an H2 blocker. We also treat patients with sucralfate to minimize exposure of the open wound at the BOT to gastric contents.
- The patients are fed a soft diet on the day of surgery. It should be noted that clear liquids are often the most difficult to swallow in the immediate postoperative period.
- Routine placement of a nasogastric feeding tube in these patients has not been necessary.
- Patients are then free to follow any diet they can tolerate as soon as they are able to have their pain under good control.
- Patients are usually discharged from the hospital on the first postoperative day.

Complications

- In general, the risks and type of complications observed with transoral robotic resection of the BOT for an unknown primary cancer are similar to those seen with other transoral approaches for resection of the BOT.
- There is a potential risk of injury to the lingual artery, which can result in significant bleeding. However, the robotic lingual tonsillectomy procedure does not resect a significant portion of intrinsic tongue musculature, and therefore the lingual artery is not at significant risk in many of these patients. There is, however, the possibility of experiencing some postoperative bleeding when the eschar that covers the surgical defect sloughs off. Most bleeding can be treated with observation or topical cautery if it occurs from a more anterior portion of the BOT. However, more active bleeding or bleeding from a deeper portion of the surgical wound may require control of the bleeding in the operating room.
- Neither author of this chapter has ever had to take a patient back to the operating room for surgical management of a postoperative hemorrhage in a TORS SCCHNUP patient.

Alternative Management Plan

The patient could be offered primary chemoradiation to both necks and Waldeyer's ring. This has been shown to be effective in controlling the disease but carries significant morbidity due to severe dysphagia and xerostomia.

DISCUSSION

Evidenced-Based Medicine Question

What are the oncologic, quality-of-life, and cost implications of performing the lingual tonsillectomy to identify the primary source?

Patients typically experience pain and dysphagia after robotic assisted surgery of the BOT. The pain lasts between 2 days through 3 weeks as the wound heals (Fig. 61.5). Most

patients do have dysphagia but are able to tolerate oral intake as early as postoperative days 1 to 2. Patients typically work with a speech pathologist with some basic swallowing exercises to facilitate early resumption of swallowing. The long-term risk of feeding tube dependence is highly correlated with the modality that is used to complete the definitive treatment of these patients. Those patients who undergo extensive chemoradiotherapy for the management of the disease tend to have a higher rate of feeding-tube dependence.[10]

Patients who have a small volume primary cancer can often be treated with surgery alone by definitively resecting the primary cancer with clear margins and performing an appropriate neck dissection. The neck dissection is typically postponed for 1 to 2 weeks after the primary TORS procedure to allow for final pathology reports to identify the presence of a close or positive margin, which can be addressed at the time of the neck dissection. As mentioned previously, the TOS lingual tonsillectomy has identified the primary site of tumor in approximately 90% of SCCHNUP patients that have failed the traditional evaluaion.[2,3] The average size of the cancer in our series was approximately 5 to 6 mm, and the vast majority of these lesions were HPV related.[2]

De-escalation protocols are currently being investigated for HPV-associated, low-risk oropharyngeal cancer. In those nonsmoking HPV+ patients with T1N1 or N2a disease without macroscopic extracapsular extension, resection of the BOT with negative margins and subsequent neck dissection are currently being investigated as sole therapy in different trials. In our anecdotal experience, patients treated in this fashion have excellent oncologic and functional results and return to work quickly without suffering from the long-term problems associated with chemoradiation. In those patients with adverse risk factors (HPV negative, tobacco abuse, N2b or higher, extracapsular spread), adjuvant treatment with radiation or chemoradiation is often necessary. However, the TORS lingual tonsillectomy affords the opportunity to obtain a definitive diagnosis and helps direct the radiation field to the primary site only, thereby avoiding radiation to the entire Waldeyer's ring. This has been shown to improve both functional and oncologic outcomes. The authors choose to perform a neck dissection based on the clinical nodal status and if there is a possibility of avoiding adjuvant chemotherapy.

The TORS BOT procedure is a safe and effective way of managing patients with SCCHN from an unknown primary, provided that the key surgical steps and oncologic principles are adhered to. The use of minimally invasive surgeries facilitates the identification of the unknown primary cancers, provides patients with prognostic information, and allows for patients to be stratified to clinical trial protocols. It is also possible to definitively resect the primary cancer and remove all active cancer from the neck, thus avoiding adjuvant therapy in select patients. The long-term sequelae of dysphagia may be reduced in those patients who can be treated with adjuvant dose of radiation after surgical therapy, especially if the primary site is identified.

Editorial Comment

Identification of the primary cancer site has important implications for prognosis, treatment planning, and salvage surgery. TORS provides an opportunity to identify small primary cancers in lingual tonsillar tissue that were only recognized if they were identified in random BOT biopsies performed during panendoscopy. While the advent of TORS creates an opportunity to optimize oncologic therapy and potentially reduce side effects by directing therapy to the primary cancer site and also opening the door for de-escalated treatments for HPV positive cancers, it must be remembered that chemoradiation protocols are also effective in treating HNSCCUP. The role of the head and neck surgeon in management of HNSCCUP is not only to assess patients for surgical options but also provide balanced evidence-based alternatives to the patient, especially as evidence and surgical experiences for management of the oropharynx are rapidly changing with increasing experience and technological advances.

Rohan R. Walvekar

Access the review questions and additional sources list online at http://www.expertconsult.com

REFERENCES

1. Strojan P, Ferlito A, Medina JE, et al. Contemporary management of lymph node metastases to the neck from an unknown primary: I. A review of diagnostic approaches. Head Neck 2013;35:123–132.
2. Mehta V, Johnson P, Tassler A, et al. A new paradigm for the diagnosis and management of unknown primary tumors of the head and neck: a role for transoral robotic surgery. Laryngoscope 2013;123:146–151.
3. Graboyes EM, Sinha P, Thorstad WL, et al. Management of human papillomavirus-related unknown primaries of the head and neck with a transoral surgical approach. Head Neck 2015;37:1603–1611.
4. Galloway TJ, Ridge JA. Management of squamous cancer metastatic to cervical nodes with an unknown primary site. J Clin Oncol 2015;33:3328–3337.
5. Kwee TC, Kwee RM. Combined FDG-PET/CT for the detection of unknown primary tumors: systematic review and meta-analysis. Eur Radiol 2009;19:731–744.
6. Keller LM, Galloway TJ, Holdbrook T, et al. p16 status, pathologic and clinical characteristics, biomolecular signature, and long-term outcomes in head and neck squamous cell carcinomas of unknown primary. Head Neck 2014;36:1677–1684.
7. Chaturvedi AK, Engels EA, Pfeiffer RM, et al. Human papillomavirus and rising oropharyngeal cancer incidence in the United States. J Clin Oncol 2011;29:4294–4301.
8. Maxwell JH, Kumar B, Feng FY, et al. HPV-positive/p16-positive/EBV-negative nasopharyngeal carcinoma in white North Americans. Head Neck 2010;32:562–567.
9. Koch WM, Bhatti N, Williams MF, et al. Oncologic rationale for bilateral tonsillectomy in head and neck squamous cell carcinoma of unknown primary source. Otolaryngol Head Neck Surg 2001;124:331–333.
10. Durmus K, Patwa HS, Gokozan HN, et al. Functional and quality-of-life outcomes of transoral robotic surgery for carcinoma of unknown primary. Laryngoscope 2014;124:2089–2095.

REVIEW QUESTIONS

1. p16 positivity within the lymph node fine-needle aspiration biopsy can also occur from a non-oropharyngeal primary site.
   a. True
   b. False

2. The transoral surgery base of the tongue resection has been shown to detect which percentage of tumors that have failed the traditional workup?
   a. 25%
   b. 50%
   c. 75%
   d. 90%

3. What are some advantages to identifying the primary tumor site?
   a. Improved oncologic outcomes
   b. Decreased long-term dysphagia
   c. Focused radiation
   d. All of the above

ADDITIONAL SOURCES

http://emedicine.medscape.com/article/848892.
http://www.uptodate.com/contents/head-and-neck-squamous-cell-carcinoma-of-unknown-primary.

62 Sentinel Lymph Node Biopsy

Mathew Geltzeiler, Robert L. Ferris

INTRODUCTION

Sentinel lymph node biopsy (SLNB) is primarily used in the head and neck for malignant melanoma and squamous cell carcinoma (SCC) of the oral cavity. The technique is employed to help the surgeon understand the pathologic status of a clinically N0 neck. Multiple prospective randomized trials for melanoma have failed to demonstrate a survival benefit for elective neck dissection in the N0 patient.[1-3] Similarly, no clear survival benefit exists for patients with SCC. Nevertheless, cervical metastasis remains the most important prognostic factor in patients with cancer of the head and neck. As the thickness of the primary cancer increases, so does the risk for cervical metastasis. Traditionally, patients with primary lesions felt to have a more than 20% risk of nodal metastasis would undergo an elective neck dissection. Lesions of lower risk could employ a "watchful waiting" approach. In this lower risk group, SLNB provides a minimally invasive technique to help surgeons better understand the status of the neck while sparing these patients the morbidity of an elective neck dissection. If the SLNB reveals lymph node metastasis, a selective neck dissection is subsequently performed clearing the neck levels at greatest risk for metastasis.[4]

The most important randomized control trial examining malignant melanoma was the 2006 Multicenter Selective Lymphadenectomy Trial (MSLT-1), which was updated again in 2014. MSLT-1 failed to establish a survival benefit for intermediate-risk patients stratified to observation versus SLNB with immediate lymphadenectomy for positive nodes.[2,3] This lack of survival benefit emphasizes the point that the purpose of the SLNB is to deliver prognostic information, provide regional control, and guide additional therapy. From this perspective, SLNB is extremely effective since the most important prognostic factor in survival from melanoma is the status of the sentinel node, and SLNB has a negative predictive value of 96%.[5]

Similar to melanoma, neck dissection for oral cavity SCC (OCSCCa) has no proven survival benefit. SLNB is useful when the indication to perform elective neck dissection is unclear. The largest study concerning this group is the American College of Surgeons Oncology Group (ACOSOG) study from 2010 which also revealed a negative predictive value of 94% to 96% for T1 to T2 lesions after examining 106 SLNBs.[6] Of note, lesions less than 6 mm were excluded.

The use of SLNB is also being examined in other cutaneous malignancies (i.e., SCC and Merkel cell carcinoma) in addition to other sites in the upper aerodigestive tract (i.e., nasopharynx, oropharynx, and larynx). At this point, the evidence supporting these techniques is still being collected. Similarly, SLNB is being used to determine whether a cancer approaching the midline has unilateral or bilateral drainage pathways to help inform the extent of the neck dissection. Some investigators are also studying SLNB's utility in predicting lymphatic drainage in patients with recurrent cancer. These are areas of active research. We will therefore focus on primary malignant melanoma and oral cavity SCC for the remainder of the chapter.

KEY OPERATIVE LEARNING POINTS

1. SLNB should only be offered to patients who have a clinically N0 neck with malignant melanoma of the head and neck stage 1b or greater.
2. SLNB can also be used for patients who have OCSCCa with T1 to T2 lesions who are clinically N0.
3. SLNB provides prognostic information and determines the need for additional neck dissection and potentially adjuvant therapy.
4. SLNB has approximately 96% negative predictive value in both melanoma and oral cavity SCC.
5. Patients who undergo subsequent neck dissection for a positive SLNB have no benefit in overall survival but benefit from reduced regional recurrence.
6. Sentinel lymph nodes are removed until the remaining count on the gamma probe has reduced 90% from the original value.
7. Thinner sectioning of the sentinel lymph node (SLN) and immunohistochemical testing for cancer markers differentiate this technique from routine lymph node evaluation. Immunohistochemistry (IHC) for S-100 and melan-A (MART-1) are used for melanoma and cytokeratin used for SCCa.
8. Patients should be counseled on the possible need to undergo two operations.
9. Optimal injection requires a comfortable patient, especially for oral cavity lesions.
10. Avoid injection of local anesthetic in the immediate vicinity of the tumor.
11. Accurate injection of radiocolloid into the dermal lymphatics is crucial.
12. Avoid "shine through" artifact by properly injecting the primary tumor, resecting the primary tumor first, and creating adequate exposure to direct the gamma probe at the lymph nodes but away from the primary site.

PREOPERATIVE PERIOD

History

1. All patients with cancer of the head and neck should undergo a complete history and physical examination.
2. Patients with malignant melanoma will typically describe a cutaneous lesion that is changing in size, shape, or color. The lesion can also be pruritic, while at later stages it may bleed and become painful. A history of sun exposure, sunburns, prior skin biopsies, prior skin cancers, occupation, and family history also should be sought.
3. Patients with OCSCCa will typically report a lesion in the mouth that has persisted or is slowly growing over time. The lesion can become painful and cause bleeding. A history of dysarthria, dysphagia, odynophagia, ill-fitting dentures, and weight loss should be sought. Importantly, tobacco (smoking and chewing) and alcohol use should be discussed.

Physical Examination

1. Primary malignant melanoma should be evaluated for the "ABCDE" checklist. Lesions of concern are **a**symmetric, have **b**order irregularity, **c**olor variation, and a **d**iameter of greater than 6 mm, and be **e**volving over time.

2. Patients with malignant melanoma require a full body cutaneous examination searching for second primary lesions. Great care must be taken when examining the patient's scalp as hair can make identifying additional lesions difficult.
3. The pinna should be carefully examined along with palpation of the parotid gland and neck.
4. Evaluation of facial nerve function is important for primary cancers at risk of draining to the parotid lymph node basin.
5. For OCSCCa, complete evaluation of the upper aerodigestive tract mucosa is imperative, including flexible fiberoptic laryngoscopy, as many patients will be at risk for second primary lesions given the high incidence of smoking and alcohol use in this patient population.
6. Palpation of the primary lesion can give a sense of the depth of the cancer. For a lesion of the tongue, one should assess mobility. Additionally, attention should be paid to the function of the mental, lingual, and hypoglossal nerves.
7. Oral opening should also be assessed, as trismus is not only indicative of invasion into the pterygoid muscles but also makes performing injection of the radiotracer into the primary difficult.
8. All patients should have their neck palpated to search for cervical lymph node metastasis.

Imaging

1. Patients with malignant melanoma and SCC of the head and neck will undergo a computed tomography (CT) scan of the neck with contrast to evaluate for cervical lymph node metastasis. The CT scan will also give information on the degree of invasion for larger primary cancers.
2. The metastatic evaluation for malignant melanoma and SCC is dictated by the stage of the primary tumor. Patients who are candidates for SLNB are clinically N0. Stage 1 patients do not require any chest imaging. Stage 2 and 3 patients should undergo optional chest imaging.
3. Chest radiograph is preferred for melanoma, and chest CT scan should be considered with OCSCCa patients with a prior history of smoking. Lastly, patients who have stage 3 melanoma can get an optional lactate dehydrogenase level.
4. Lymphoscintigraphy during the SLNB procedure will be discussed below.

Indications

1. For malignant melanoma, SLNB has proven to be the most sensitive and specific tool for identification of occult cervical metastasis with a negative predictive value of approximately 96%.[5]
2. SLNB is currently recommended for all patients with melanoma with a primary tumor that is >1 mm thick and a clinically N0 neck.
3. The National Comprehensive Cancer Network (NCCN) additionally recommends offering SLNB to stage 1b patients (≤1 mm thick with ulceration or mitotic rate ≥1 per mm^2).[7]
4. The NCCN notes that one can consider a SLNB in T1a patients (tumor <1 mm without ulceration and low mitotic rate) with other negative prognostic factors like young age, angiolymphatic invasion, or deep positive margins.[7]
5. For OCSCCa, the indications are slightly less clear. Traditionally, most cancers of the oral cavity would warrant an elective neck dissection. Patients with only superficially invasive lesions might have their neck observed.
6. The ideal lesion for SLNB is a T1 to T2 with intermediate thickness (2–4 mm). Cancers with invasion into deeper structures are better served with elective neck dissection.

Contraindications

1. SLNB is only offered to patients who are clinically N0. Therefore, the presence of clinically positive lymphadenopathy is an absolute contraindication to the procedure.
2. OCSCCa with advanced-stage primary cancer (T3 to T4 lesions) carries a high enough risk of occult lymph node metastasis that elective neck dissection is more appropriate than SLNB. Additionally, the patient should have adequate oral opening, and the cancer should be in a location that is easily accessible for injection of the radiotracer.

Preoperative Preparation

1. Clinical staging should be completed, and indications for the procedure must be validated prior to the surgery.
2. Preoperative check must be made to ensure that the required instrumentation is available prior to surgery, especially ensuring coordination with the nuclear medicine team.

OPERATIVE PERIOD

Anesthesia

1. SLNB can be performed under monitored anesthesia care (MAC) or general anesthesia.
2. Patients with OCSCCa are better served with general anesthesia, as resection of the primary is easier with the patient intubated.

Perioperative Antibiotic Prophylaxis

1. Antibiotic protocols vary by institution. SLNB is a clean procedure; therefore antibiotic prophylaxis is not required. At our institution, skin flora is routinely covered with Cefazolin.

Positioning

1. The patient is positioned supine with a horizontally oriented shoulder roll.

Monitoring

1. The surgeon can consider the use of facial nerve monitoring for lesions in the parotid gland. We do not routinely use facial nerve monitoring when performing SLNB.

Instruments and Equipment to Have Available

1. Handheld gamma probe
2. Technetium 99 (^{99}T)
3. Methylene blue

Key Anatomic Landmarks

1. Understanding the natural flow of lymph throughout the head and neck is critical for planning surgical interventions.[8] The location of the primary cancer dictates the cervical nodal basins at greatest risk for metastasis. While these relationships are not directly involved with performing an SLNB, they do help surgeons predict the location of the sentinel node and inform the extent of the therapeutic neck dissection, if necessary.
2. The surgeon can draw an imaginary coronal plane through the external auditory canal. For primary cancers of the facial skin, ear, and scalp, lesions arising anterior to this plane typically drain through the parotid lymph nodes then down to jugular lymphatic chain.

3. More inferiorly and anteriorly located lesions (i.e., the chin) can drain through the facial and submandibular lymph nodes, avoiding the parotid.
4. Lesions posterior to this coronal plan will drain to the postauricular, occipital, and posterior triangle lymphatics.
5. Surgeons should be comfortable performing the resection and reconstruction of cutaneous lesions in anatomically high-risk areas (i.e., near the lips and eyelids).
6. For OCSCCa, the lymphatics at greatest risk are the facial, submental, and submandibular lymph nodes, which then drain to the jugular chain.
7. Understanding the surgical anatomy of the parotid and neck is critical to avoiding morbidity when performing SLNB. Approximately 25% to 30% of head and neck melanomas drain through the parotid bed.[9]
8. When sentinel lymph nodes are detected in the parotid, the surgeon can safely remove the nodes without performing a superficial parotidectomy because these nodes typically lie within the superficial lobe of the gland.[10] However, the surgeon should always be aware of the proximity of the facial nerve and be prepared to perform a superficial parotidectomy if necessary.
9. Facial nerve monitoring can be considered as an adjunct tool in this setting.
10. For sentinel nodes that are present in the neck, great care must be taken to preserve the spinal accessory nerve as well as the other critical neurovascular structures typically saved in a selective neck dissection.

Prerequisite Skills

1. Surgeons should be experienced in performing the resection and reconstruction of cutaneous lesions in anatomically high-risk areas (i.e., near the lips and eyelids).
2. Surgeons should be experienced in performing superficial parotidectomy with preservation of the facial nerve, if required.
3. Surgeons should be experienced in performing the selective neck dissection if the sentinel node is found to be positive.

Operative Risks

1. SLNB is a safe procedure with a complication rate of less than 1%.
2. Injury to the facial nerve and spinal accessory nerve are both potential risks of the procedure depending on the location of the sentinel node.
3. Morbidity from the resection of the primary tumor is also an important consideration. As mentioned previously, the surgeon should feel comfortable with resection and reconstruction of the primary tumor site.

Surgical Technique

1. Effective collaboration with nuclear medicine physicians is essential in performing effective SLNB.
2. Prior to the operating room, the patient is brought to the nuclear medicine suite, and the primary tumor site is injected with radiotracer.
3. Lymphoscintigraphy is subsequently performed, and the first node to which the tracer flows is defined as the sentinel lymph node. This site is marked on the patient's skin.
4. Lymphoscintigraphy can also be fused with a CT scan for increased spatial localization.
5. The injection typically takes place the morning of the procedure but can also be done the night prior. The ideal time delay is not defined, but we prefer to perform the operation within 4 hours of the injection.

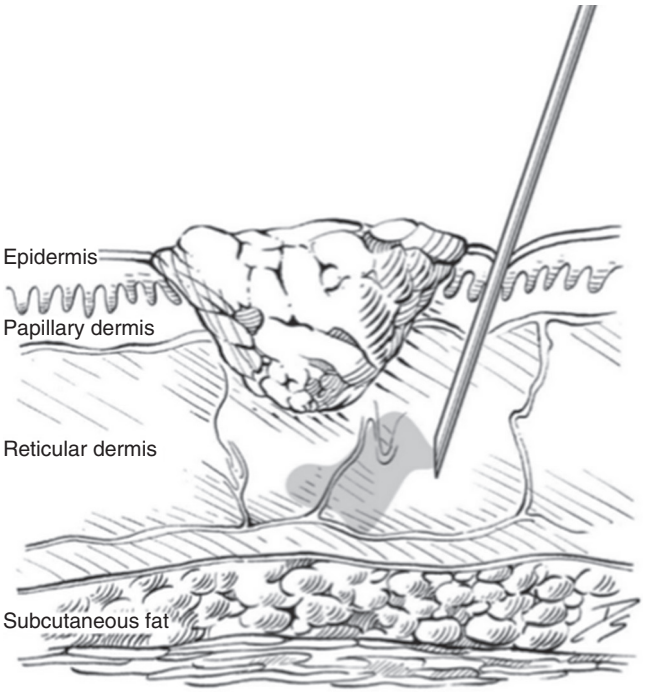

Fig. 62.1. Proper depth and location for injection of radiocolloid (^{99}T) and methylene blue. *(Taken with permission from Cohen J and Clayman G, Atlas of Head & Neck Surgery, Elsevier; Phila, PA 2011.)*

6. ^{99}T is the only available radiocolloid in the United States, but others can be obtained in Europe. ^{99}T is available in filtered and unfiltered forms. The unfiltered form is preferred, as it does not flow downstream as quickly. While this decreases the likelihood of finding multiple sentinel nodes, it does result in increased "shine through" artifact, which is when residual tracer at the primary site interferes with readings around the nodal basin. "Shine through" artifact is a more pronounced concern with oral cavity lesions than melanoma.
7. The operating room staff is exposed to a minimal amount of radiation during these cases. The dose is sufficiently low to not require any special precautions; however, team members, especially those who may be pregnant, should be notified.
8. Injection of the radiotracer is performed at the primary site in an awake patient. The use of anesthesia with endoscopic guidance is only required for pharyngeal, laryngeal, and sinonasal tumors, which are still under investigation.
9. A narrow needle (25 g) is used to inject 4 to 5 mL of ^{99}T with a circumferential or four-quadrant technique into the underlying dermis for melanoma (Fig. 62.1).
10. Oral cavity cancers should be injected along their leading mucosal edge and within the cancer itself (Fig. 62.2).
11. It is important in either case not to inject into the subcutaneous or submucosal spaces as these do not accurately map the sentinel node and can lead to excessive "shine through" artifact.
12. The patient can be given mild sedation or regional anesthesia for oral cavity cancers, but one should avoid directly injecting the area of the tumor with epinephrine containing local anesthetic as this may affect the lymphatic drainage.
13. If the primary cancer has already been resected, the remaining scar can be injected with good results shown in melanoma.

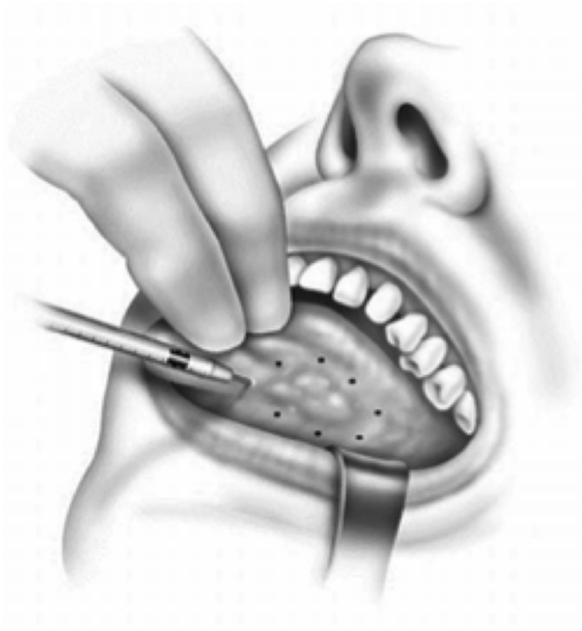

Fig. 62.2. An example of proper injection technique of radiocolloid for a cancer of the oral cavity. *(Taken with permission (permission yet to be requested) from Myers and Ferris, Master Technique in Otolaryngology—Head and Neck Surgery, vol 1. Thyroid, Parathyroid, Salivary Glands, Paranasal Sinuses and Nasopharynx, Wolters Kluwer Health-Lippincott Williams & Wilkins; Phila, PA 2014.)*

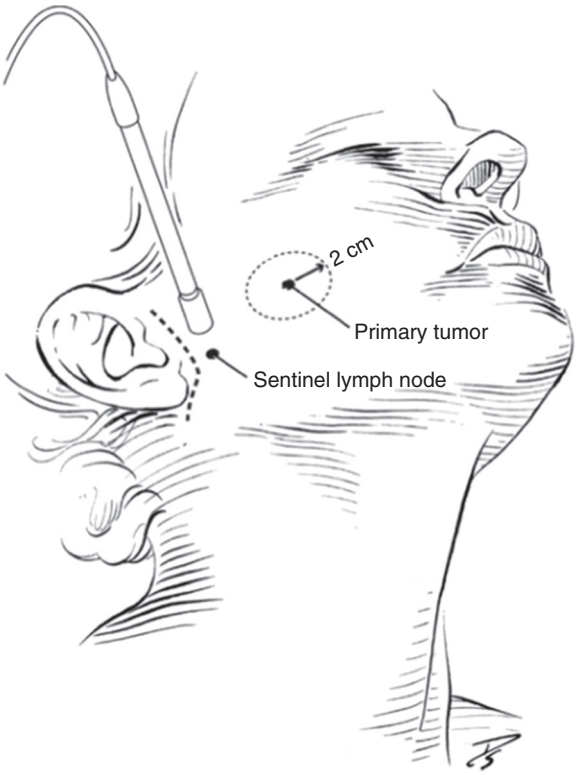

Fig. 62.3. An example of a primary cancer site with planned incision for sentinel lymph biopsy. *(Taken with permission (permission yet to be requested) from Cohen J and Clayman G, Atlas of Head & Neck Surgery, Elsevier; 2011.)*

14. The sentinel node is then mapped with lymphoscintigraphy plus or minus CT scan as previously described.
15. The patient is then taken to the operating room and positioned with the head of the bed rotated 90 degrees away from the operative side. A horizontally oriented shoulder roll is placed, and the sentinel node position is confirmed with the gamma probe.
16. Excision of the primary site should include adequate margins based upon the depth of the cancer for melanoma and T-stage for OCSCCa.
17. The incision for the SLNB should be planned with consideration of the subsequent neck dissection, if required (Fig. 62.3).
18. Methylene blue is then injected in a similar manner to the ^{99}T as already described. Typically 0.2 to 0.5 mL is injected into the dermal lymphatics, which produces a characteristic bluish infiltrate. The purpose of the methylene blue is to color the sentinel node and make intraoperative identification easier.
19. Methylene blue is preferred to isosulfan blue due to the approximately 1% incidence of anaphylaxis with isosulfan.
20. The patient is then prepped and draped.
21. The primary cancer is excised first. Performing this step first gives the methylene additional time to flow to the sentinel node and removes residual ^{99}T at the primary site to help with confounding "shine through." Oral cavity cancers can be sent for frozen section determination of margin status. This step is usually skipped in melanoma.
22. The sentinel lymph node dissection is then performed. Exposure to the site will vary depending on the location of the node. As mentioned earlier, sentinel nodes located within the parotid gland can be removed safely without performing a formal superficial parotidectomy.
23. The gamma probe sensor is directional in nature, so adequate exposure should allow for placement of the probe directed at the sentinel node, yet away from the primary site. The methylene blue can help visually identify the sentinel node and can also illuminate small lymphatics, which can be followed to the sentinel node.
24. Once the sentinel lymph node is identified, a 10-second count on the gamma probe is performed and recorded (Fig. 62.4A). The node is then removed, and the count is repeated on the specimen node itself. Lastly, a count is performed within the remaining lymphatic bed (Fig. 62.4B).
25. If a single sentinel node is removed, there should be no more than 10% residual activity within the nodal bed. Any more than 10% means that the node removed was not the only sentinel node or the patient has multiple sentinel nodes. In either case, additional nodes should be removed until a 90% reduction from the original maximum count is reached.
26. It is not uncommon to have multiple sentinel lymph nodes present in cancers in the head and neck. If the surgeon is unable to reduce the residual activity to 10%, judgment must be used to determine when to stop. We typically do not remove more than 4 sentinel nodes.
27. The wound is then closed in layers.
28. After removal, the specimen is sent to pathology and specifically labeled as "sentinel lymph nodes." Proper labeling is important, as the pathology team will perform finer sectioning of the nodes than typically performed with a standard neck dissection. Serial sectioning, usually 150 to 200 μm, is utilized with hematoxylin and eosin (H&E) staining in addition to IHC for S-100 and MART-1 for melanoma.
29. Frozen section is not used in melanoma.
30. With OCSCCa, frozen section of the node can be useful because the selective neck dissection can be performed immediately. However, the sensitivity of frozen section for SCC is only 60%.[6]

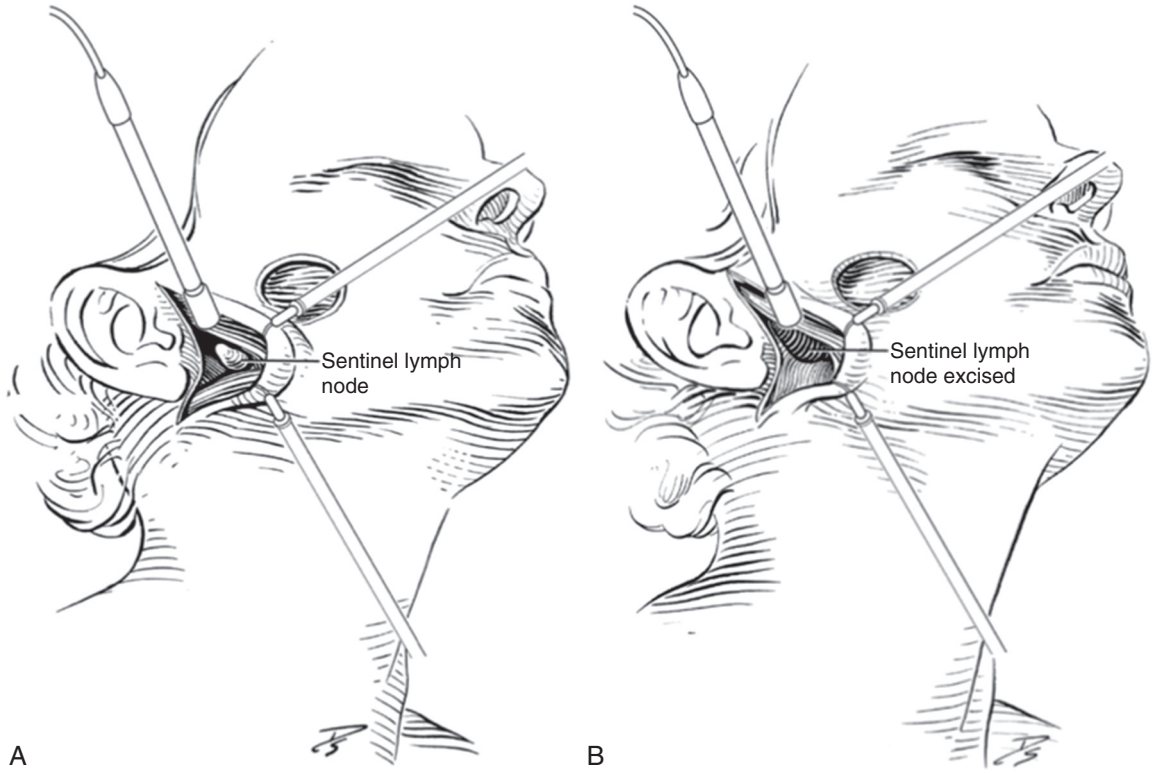

Fig. 62.4. A, Identification of sentinel lymph node with gamma probe and, **B,** measurement of residual activity after sentinel lymph node removal. *(Taken with permission (permission yet to be requested) from Cohen J and Clayman G, Atlas of Head & Neck Surgery, Elsevier; Phila, PA 2011.)*

Common Errors in Technique

1. Injection of the ^{99}T and methylene blue should be into the subdermal plexus, which is the location of the lymphatics, and not deeper in the subcutaneous tissue. Oral cavity cancers should be injected along their leading mucosal edge and within the cancer itself.
2. "Shine through" artifact is when radiation from the primary injection is inadvertently detected by pointing the gamma probe toward the primary when searching for a sentinel node in the neck. This problem is most commonly encountered when looking for level 1 A sentinel nodes for a primary cancer of the floor of mouth. "Shine through" artifact can be minimized by properly injecting the primary cancer, resecting the primary cancer first and creating adequate exposure to direct the gamma probe at the lymph nodes but away from the primary site.
3. No more than four sentinel lymph nodes need to be removed even if a 90% reduction of background activity has not been achieved.

POSTOPERATIVE PERIOD

Postoperative Management

1. Routine postoperative care can be performed as similar to excisional lymph node biopsy.
2. Drains typically are not required unless a neck dissection is performed.

Complications

1. Complications for SLNB are rare.
2. As noted previously, there is less than 1% incidence of injury to the facial and spinal accessory nerves.

Alternative Management Plan

1. For malignant melanoma, the SLNB has become the standard of care, and indications for SLNB are covered in the *Indications* section above. For lower risk patients, the neck can be observed. For higher risk patients, an elective neck dissection can be performed.
2. For OCSCCa, the ideal cancer for SLNB is a T1 to T2 with intermediate thickness (2–4 mm mm). A small superficially invasive cancer can be managed with resection alone with no neck dissection as long as the patient is clinically N0. T2 and larger cancers all require management of the neck with either an SLNB or neck dissection. Given that OCSCCa is typically managed surgically, elective neck radiation is generally not indicated.

DISCUSSION

Evidence-Based Medicine Question

Does performing SLNB improve overall survival for patients with malignant melanoma and SCC of the oral cavity?

There is no clear survival benefit that has been established for performing SLNB for malignant melanoma or OCSCCa. Additionally, no survival benefit exists when performing a neck dissection in an elective or therapeutic manner in either of the disease processes. The purpose of the SLNB is to provide prognostic information and help to guide additional therapy and reduce regional recurrence.

Editorial Comment

SLNB addresses a decision-making process with respect to elective neck dissection in early stage melanoma and OCSCCa. Although evidence does not point to improvement in overall survival, as we have mentioned, SLNB provides valuable

prognostic information that can guide further treatment and reduce regional recurrences, both of which bring value to overall patient care. A recent article in NEJM by DCruz AK et al. (2015) reports improved overall and disease-free survival in patients undergoing elective versus therapeutic neck dissection for early-stage (T1 to T2) oral cancer. Future research will further elaborate when we, as head and neck surgeons, must be aggressive surgically in the management of the neck and also develop criteria for avoiding neck dissections and avoiding unnecessary morbidity to the patient.

Rohan R. Walvekar



Access the review questions and additional source list online at http://www.expertconsult.com

REFERENCES

1. Coit D. Sentinel lymph node biopsy for melanoma: a plea to let the data speak. Ann Surg Oncol 2014;21(11):3359–3361. Available at http://www.ncbi.nlm.nih.gov/pubmed/25059791.
2. Morton DL, Thompson JF, Cochran AJ, et al. Sentinel-node biopsy or nodal observation in melanoma. N Engl J Med 2006;355(13):1307–1317. Available at http://www.nejm.org/doi/abs/10.1056/NEJMp1415160.
3. Morton DL, Thompson JF, Cochran AJ, et al. Final trial report of sentinel-node biopsy versus nodal observation in melanoma. N Engl J Med 2014;370(7):599–609. Available at http://www.nejm.org/doi/abs/10.1056/NEJMoa1310460.
4. Geltzeiler M, Monroe M, Givi B, et al. Regional control of head and neck melanoma with selective neck dissection. JAMA Otolaryngol Head Neck Surg 2014;140(11):1014–1018. Available at http://www.ncbi.nlm.nih.gov/pubmed/25275362.
5. Patel SG, Coit DG, Shaha AR, et al. Sentinel lymph node biopsy for cutaneous head and neck melanomas. Arch Otolaryngol Head Neck Surg 2002;128(3):285–291. Available at http://www.ncbi.nlm.nih.gov/pubmed/11886345.
6. Civantos FJ, Zitsch RP, Schuller DE, et al. Sentinel lymph node biopsy accurately stages the regional lymph nodes for T1–T2 oral squamous cell carcinomas: results of a prospective multi-institutional trial. J Clin Oncol 2010;28(8):1395–1400. Available at http://jco.ascopubs.org/cgi/doi/10.1200/JCO.2008.20.8777.
7. National Comprehensive Cancer Network: NCCN Clinical Practice Guidelines in Oncology: Melanoma. Accessed November 8, 2015. Available at http://www.nccn.org/professionals/physician_gls/pdf/melanoma_blocks.pdf.
8. O'Brien CJ, Petersen-Schaefer K, Ruark D, et al. Radical, modified, and selective neck dissection for cutaneous malignant melanoma. Head Neck 1995;17(3):232–241. Available at http://www.ncbi.nlm.nih.gov/pubmed/7782208 .
9. Schmalbach CE, Nussenbaum B, Rees RS, et al. Reliability of sentinel lymph node mapping with biopsy for head and neck cutaneous melanoma. Arch Otolaryngol Head Neck Surg 2003;129(1):61–65. Available at http://www.ncbi.nlm.nih.gov/pubmed/12525196.
10. Wagner JD, Park H-M, Coleman JJ, et al. Cervical sentinel lymph node biopsy for melanomas of the head and neck and upper thorax. Arch Otolaryngol Neck Surg 2000;126(3):313. Available at http://archotol.jamanetwork.com/article.aspx?doi=10.1001/archotol.126.3.313.

REVIEW QUESTIONS

1. Which of the following patients would be a candidate for a sentinel lymph node biopsy (SLNB)?
   a. 1.6-mm thick melanoma with a single palpable cervical lymph node
   b. 0.5-mm thick melanoma with negative surgical margins
   c. 1.1-mm thick melanoma without angiolymphatic invasion
   d. T3N0 oral cavity squamous cell carcinoma (SCC) with trismus

2. Before removal of the first sentinel lymph node, the activity in the field is 6400. After removal of the node, what level of residual activity would signify the end of the procedure?
   a. 500
   b. 700
   c. 1000
   d. 3200

3. A patient is scheduled for an SLNB at noon. When should the primary cancer be injected with Technetium 99 (^{99}T)?
   a. Within 3 days of the procedure
   b. At 8 a.m. that morning
   c. Immediately prior to going into the OR
   d. Just prior to resection of the primary tumor

4. A patient is scheduled for an SLNB at noon. When should the primary tumor be injected with methylene blue?
   a. Within 3 days of the procedure
   b. At 8 a.m. that morning
   c. Immediately prior to going to the OR
   d. Just prior to resection of the primary tumor

5. The proper site of injection of the radiocolloid for malignant melanoma is
   a. Within the epidermis
   b. Within the dermis
   c. Within the subcutaneous fat
   d. Into the primary lesion itself

ADDITIONAL SOURCE

DCruz AK, Vaish R, Kapre N, et al. Elective versus therapeutic neck dissection in node-negative oral cancer. New Eng J Med 2015;373(6):521–529.

63 Superselective Neck Dissection

Brian J. Boyce, David M. Cognetti

INTRODUCTION

The nodal status of the neck remains one of the most important prognostic factors for overall survival in patients with cancer of the head and neck. The lymphatic drainage of the neck is organized into anatomic compartments (Fig. 63.1). The type of neck dissection depends on the nodal levels removed and the extent of nonlymphatic structures preserved (Table 63.1). Over the past century, the surgical approach to regional nodal metastases has continued to evolve in an effort to lessen morbidity while preserving locoregional control and survival rates. The radical neck dissection for a clinically positive neck was described by Crile more than 100 years ago and included removal of the sternocleidomastoid (SCM) muscle, spinal accessory nerve (SAN), internal jugular vein (IJV), submandibular gland, and sensory rootlets, in addition to the lymphatic bearing fibroadipose tissue. In the 1950s Suarez found success using an approach that preserved at least one of the nonlymphatic tissue-bearing structures that would come to be known as the modified radical neck dissection, which would be popular throughout the 1950s and 1960s. In both of these procedures, the lymph node levels I–V were removed, but the postoperative morbidity was decreased with the modified radical neck dissection. In the 1960s and 1970s, Ballantyne advocated for the removal of only the nodal compartments at highest risk while leaving some nodal stations undissected and preserving all nonlymphatic structures. This type of dissection would be known as the selective neck dissection and has many variations, including the supraomohyoid and the lateral neck dissection. The concept of selective neck dissections was further popularized by the work of Lindberg and then by Shah, which showed that regional spread occurs in an orderly and predictable fashion. Many studies have shown that selective neck dissection has decreased the morbidity with surgical treatment of the neck, while preserving oncologic safety in both the N0 and N+ neck.

Recently there has been an interest in more precisely targeting nodal levels at risk and further minimizing potential complications by using the superselective neck dissection (SSND). This technique is defined by dissection of only one or two contiguous nodal stations and preservation of all nonlymphatic bearing tissue. In this chapter we will discuss the indications, technique, and rationale for SSND.

KEY OPERATIVE LEARNING POINTS

- SSND is the removal of one or two contiguous neck levels while preserving all nonlymphatic structures.
- SSND is appropriate for N0 necks by examination and imaging, salvage neck dissections with a single concerning node, and indeterminate lateral nodes in papillary thyroid cancer (PTC).
- SSND performed for oral cavity primaries and N0 neck should include levels I and II.
- SSND performed for laryngeal primaries and N0 neck should include levels II and III.
- The goal of SSND is to minimize morbidity while maintaining regional control and survival rates.

PREOPERATIVE PERIOD

History

- All patients with cancer of the head and neck should have a complete basic history regarding the mass in the neck, including onset, duration, location, pain, severity, and progression.
- All patients should be questioned about dyspnea, dysphagia, weight loss (how much over specific time period), hemoptysis, dysphonia, and otalgia.
- All patients should be asked about previous cancer of the head and neck. If yes, how were they treated? Surgery? Radiation? Chemotherapy? Combination of modalities?
- A full social history should be included regarding their occupation use of tobacco and alcohol, illicit drugs, and exposure to carcinogens or radiation.
- The patient should have a good social support system and be motivated to proceed with SSND. Reliability is an important factor as well, since close surveillance and follow-up are warranted.
- All patients should have a detailed family history performed with an emphasis on malignancies of the head and neck/thyroid.

Past Medical History

- The history regarding bleeding and coagulation disorders must include a history of bleeding or bruising easily. Ask about a family history of bleeding easily or a history of hemophilia or von Willebrand's disease.
- Ask if there is a history of reactions to general anesthesia or malignant hyperthermia.
- Ask about a history of previous neck surgery (cervical spine fusion, thyroid surgery, previous neck dissection or open biopsies, carotid endarterectomy).
- Review the list of medications.
  - Any anticoagulants other than aspirin should be held in the perioperative period.
  - All herbal and over the counter (OTC) vitamins should be held perioperatively.
- Ask all patients about risk factors for poor wound healing (chronic steroid use, hypothyroidism, connective tissue disorders).

Physical Examination

- Overall appearance of the patient: Cachectic? Dehydrated? Well-nourished?
- Primary site: Note the location of the primary cancer and whether it extends to areas that include bilateral lymphatic drainage (midline lesions such as the base of the tongue, floor of the mouth, or supraglottis). It is important to estimate the thickness of the cancer, since this has been shown to correlate with occult cervical metastases.
  - In patients who have been previously treated for the cancer, evaluate for complete response, and biopsy any suspicious areas (leukoplakia, erythema, or ulcerations).
- Evaluate all mucosal surfaces of the oral cavity, oropharynx, larynx, and hypopharynx to rule out synchronous lesions.

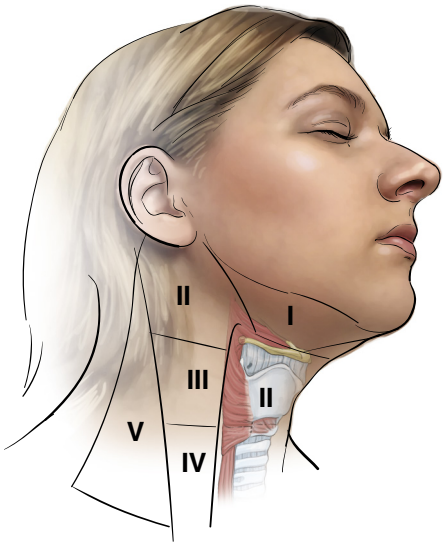

Fig. 63.1. Nodal compartments in the neck.

TABLE 63.1 Classic Definitions of Neck Dissections

Radical neck dissection	Removal of nodal compartments I–V, IJV, SCM, and CN XI
Extended radical neck dissection	Removal of nodal compartments I–V, IJV, SCM, CNXI, and a nonlymphatic structure (nerve, vessel, muscle, skin, etc.)
Modified radical neck dissection	Removal of nodal compartments I–V and preservation of at one of the following: IJV, SCM, or CN XI
Selective neck dissection	Removal of lymphatic bearing tissue only, leaving at least 1 nodal compartment undissected
Superselective neck dissection	Removal of one or two contiguous nodal compartments and preserving all nonlymphatic tissue

IJV, Internal jugular vein; *SCM,* sternocleidomastoid.

- Perform laryngoscopy to search for any mucosal lesions and vocal fold mobility.
- Neck: Palpate for any appreciable lymphadenopathy and note the level. Is the mass freely mobile or adherent to the skin or underlying structures?
  - Evaluate mobility, including flexion and extension. Look for scars or evidence of previous surgery.
  - In patients who have previously undergone radiotherapy to the neck, note the pliability and firmness of the tissue.
- It is important to note baseline function, especially in patients who have been previously treated.
  - Shoulder mobility, normal protrusion of the tongue, facial nerve movement, and vocal fold mobility

Imaging

- With an overall 30% rate of occult lymph node metastases in squamous cell carcinoma (SCCa) of the head and neck, physical examination of the neck should be augmented with imaging.
- The best imaging modality to detect nodal disease not appreciated on physical examination is controversial. While the sensitivity, specificity, and predictive values vary depending on the institution, we suggest that any of the modalities listed here are excellent options either in the pretreatment or posttreatment setting.
  - Ultrasound
  - Computed tomography (CT) scan with contrast
  - Magnetic resonance imaging (MRI) with gadolinium
  - Positron emission tomography - Computed tomography (PET-CT)

Indications

- There are currently two clinical situations where SSND is considered:
  - Patients whose primary cancer is in the larynx or oral cavity and an N0 neck by examination and imaging
  - Patients who have been previously treated with either surgery or radiotherapy and have a persistent neck mass
- Another proposed indication is an SSND for pathologically indeterminate lateral neck nodes but clinically suspicious for patients with malignancy. These are typically patients who have nodes that are suspicious on ultrasound or CT, but the fine-needle biopsy was indeterminate or unable to be performed due to the location of the lymph node.

Contraindications

- Poor surgical candidate based on the patient's medical status or comorbidities
- Patients with distant metastatic cancer
- In patients undergoing primary treatment, known cervical lymph node metastases are a contraindication to SSND. These patients will have a high risk of having nodal metastasis extending beyond one or two levels.
- Any evidence of extracapsular extension that would require sacrifice of nonlymphatic tissue

Preoperative Preparation

- All imaging should be reviewed prior to surgery. Any previous biopsies or pathology slides should be reviewed in house. We recommend a second review at the end of the case but before closing to ensure that no other suspicious areas were missed initially.

OPERATIVE PERIOD

Anesthesia

- General endotracheal anesthesia with the endotracheal tube taped to the side opposite the neck dissection
- Paralysis should be avoided so that the surgeon can stimulate nerves once identified and be alerted by movement if dissecting near a nerve.

Positioning

- Supine with a shoulder roll or inflatable pillow for cervical extension. Exercise caution in patients with fusions or overextension in elderly patients.
- We prefer that the table be turned 180 degrees away to allow freedom of movement around the patient's head and neck.

Preoperative Antibiotic

- The use of preoperative antibiotics in clean cases such as neck dissections is controversial. It is also important to note that many patients with cancer of the head and neck have

risk factors for surgical site infections (age, poor nutrition, diabetes mellitus, tobacco and alcohol use, recent hospitalization, and previous treatment with radiation and chemotherapy).
- The World Health Organization advocates preoperative antibiotic prophylaxis in all cases.
- The American Society of Health System Pharmacists recommends against the routine use of antibiotics in clean cases without mucosal contamination.
- We routinely use a single dose of Ancef (cefazolin) before incision and discontinue it in the postoperative period, given the risk factors listed previously in patients with cancer of the head and neck and the low risk of a single preoperative antibiotic dose. Clindamycin is an alternative choice in patients with an allergy to beta-lactam antibiotics.

Monitoring

- Nerve monitoring is not used routinely. A handheld probe is used to confirm identification and function of nerves. The use of continuous neuromonitoring is controversial, but typically monitored nerves include the spinal accessory and marginal mandibular branch of the facial nerve. There is some predictive value of postoperative function to neuromonitoring CN XI based on amplitude and latency changes. However, these nerves should be at low risk during an SSND.

Instruments and Equipment to Have Available

- Standard neck dissection set
- Handheld nerve stimulator
- Many surgeons use energy devices to seal and cut vessels using ultrasonic or bipolar energy.

Key Anatomic Landmarks

- Platysma: This is the first muscle that is visualized after performing the initial incision on the neck. It is divided, and sub-platysmal flaps are elevated superiorly and inferiorly.
- External jugular vein (EJV): Located inferior to the great auricular nerve as it courses over the superior third of the SCM. EJV can have several communications to the facial, deep facial, and retromandibular veins.
- Great auricular nerve: Located just above the EJV and is the sensory nerve to the earlobe, and the skin around the inferior aspect of the auricle
- Marginal mandibular nerve: Branch of the facial nerve that innervates the depressor anguli oris, depressor labii inferiorus, and mentalis. It can be routinely identified coursing over the facial vessels at the mandibular notch or 1 cm anterior and 1 cm inferior to the angle of the mandible.
- The fibroadipose tissue containing lymphatic structures and nodes is located between the fascia of the SCM laterally, carotid sheath medially, and deep layer of the deep cervical fascia.
- Posterior belly of the digastric muscle: This separates level IB from IIA. It is safe to dissect on the inferior border of this muscle. The facial vein runs superficial to the digastric, so care must be taken not to damage this structure as it crosses. The spinal accessory and hypoglossal nerves run deep to the digastrics and should be safe while dissecting on the superficial surface of the muscle.
- Omohyoid: Strap muscle that originates from the scapula and inserts on the hyoid bone and depresses the larynx, and it defines the border of level III and IV. Dissecting on the superficial surface of this muscle protects the contents of the carotid sheath.
- Hyoid bone: Horseshoe-shaped structure in the upper neck that divides level II and III. Consists of the body, lesser cornu, and greater cornu.
- Hypoglossal nerve: Innervates the muscles of the tongue except for the palatoglossus. It can be found immediately anterior to the IJV in level IIA or inferior to the posterior belly of the digastric coursing under the ranine veins.
- SAN: Motor nerve to the SCM and trapezius muscles. It has a variable relationship to the IJV and can course over (96%), under (3%), or through (1%) the IJV. It can be found high in level IIA as it crosses the IJV, at its insertion in the SCM around the tendon, about 1 cm above Erb's point or about two finger breadths above the lateral clavicle as it enters the trapezius. It divides level IIA from IIB.

Prerequisite Skills

- Experience with radical neck dissection, modified radical neck dissection, and selective neck dissection techniques

Operative Risks

- The risks of this procedure are similar to those in any neck dissection. The risks should be minimized due to the limited dissection area, but thorough anatomic knowledge of the neck is essential.
  - Poor wound healing (especially radiated patients), hematoma, infection, scarring, shoulder dysfunction, chyle leak, marginal mandibular nerve weakness, damage to major vessels including stroke, voice problems and swallowing difficulty, phrenic nerve damage resulting in paralyzed diaphragm, numbness, and Horner's syndrome

Surgical Techniques

- This description provides a technique that can be applied to all levels of the neck that are indicated for SSND.
- For lesions that have bilateral lymphatic drainage (supraglottis, floor of the mouth), bilateral SSND should be performed.
- An incision should be planned in an existing transverse skin crease if possible. We recommend injection into the skin crease with 1% lidocaine and 1:100,000 parts epinephrine prior to incision. Given the limited dissection area, a smaller incision can be made.
- The incision is carried down through the subcutaneous tissue until the platysma is identified. It should be divided and subplatysmal flaps elevated circumferentially. Care should be exercised to elevate these flaps immediately deep to the platysma to avoid damaging superficial structures such as the marginal mandibular nerve superiorly over the mandible. This is especially true in thinner patients who have little fibroadipose tissue present.
- Identify and preserve the EJV and great auricular nerve when elevating subplatysmal flaps.
- For oral cavity primary SSCa, dissection of level I is necessary. The first maneuver should be to identify the marginal mandibular nerve. It can be found in a 1 × 1-cm area at the mandibular notch or approximately 1 cm and anterior and inferior to the angle of the mandible. The nerve must be dissected free and swept superiorly over the mandible to protect it during further dissection.
  - Dissection then proceeds along the inferior aspect of the mandible to displace the submandibular gland and fibroadipose contents inferiorly. The facial artery and vein must be controlled and ligated at this step.

  - Dissect inferiorly along the anterior and posterior belly of the digastric. The facial vein must again be identified and controlled along the posterior belly of the digastric.
  - Begin by reflecting the fibroadipose tissue laterally off the mylohyoid. Here the nerve to the mylohyoid and submental vessels are encountered and can be ligated. The submental vessels can retract and cause bothersome bleeding, so pre-emptive control is important. Once the mylohyoid is free, retract it medially using an Army-Navy retractor.
  - The loose areolar tissue around the submandibular gland can be pushed away with blunt dissection until the specimen is pedicled on the submandibular ganglion and submandibular duct. The facial artery can be ligated as it emerges from behind the posterior belly of the digastric.
  - The submandibular ganglion is divided to preserve the lingual nerve, and the duct is ligated as close to the floor of mouth as possible, which mobilizes the specimen.
  - Level IA can be quickly dissected off of the mylohyoid centrally between the two anterior bellies of the digastric.
- Dissect along the anterior border of the SCM while reflecting the muscle laterally and fibroadipose contents medially. The SAN should be identified and preserved as it enters the SCM. Care should be exercised in avoiding the branch of the SAN to the trapezius, as this branch can leave CN XI before it enters the SCM (Fig. 63.2). The SAN should be traced in a superomedial direction until it intersects the IJV under the posterior belly of the digastric. Retraction of the posterior belly superiorly aids in this dissection. We do not routinely advocate the dissection of level IIB in N0 necks, given the low incidence of isolated disease in the absence of level IIA metastases. This also reduces potential injury to CN XI and postoperative morbidity.
- Once the posterior edge of the SCM is reached, change the angle of dissection and begin moving in a medial direction.
- Identify the cervical sensory rootlets and elevate the fibroadipose tissue off of these nerves, keeping them intact. Do not dissect deep to the omohyoid muscle into level IV in salvage neck dissections for oral cavity/laryngeal primaries with N0 necks. This minimizes the risk of damage to the transverse cervical vessels, thoracic duct, and phrenic nerve. When dissecting level IV for indeterminate lateral lymphadenopathy in PTC, dissection should proceed over the deep cervical fascia to protect the phrenic nerve. The transverse cervical artery and vein will be visualized as well, and small branches off them to the nodal packet should be controlled. When dissecting medially in level IV, the fibroadipose contents should be clamped and ligated to prevent a chyle leak.
- As the specimen is dissected medially the carotid sheath is encountered. It is important to recognize this landmark and not to continue dissection behind the carotid artery, which puts the sympathetic chain at risk.
- We use a 15-blade scalpel to dissect the contents off of the IJV, carotid artery, and vagus nerve. Care should be taken in controlling small vessels off the IJV, which can result in significant bleeding if cut. Attempts to preserve the ansa cervicalis are encouraged but not mandatory. The jugular vein should be nearly circumferentially free after this portion of the dissection.
- Medial to the IJV dissection proceeds over the descendens hypoglossi to remove the remainder of level III to the sternohyoid. In level IIA, the hypoglossal nerve should be identified, and the fibroadipose contents superficial to it should be removed (Fig. 63.3).
- A drain is placed after a Valsalva is performed and hemostasis is achieved.
- A layered closure of the platysma and skin is performed

Common Errors in Technique

- Not choosing the correct patient for this procedure
- Not recognizing suspicious lymph node metastases on imaging
- Not removing involved lymph nodes in a salvage neck dissection
- If concerning nodes or lymphatic tissue are encountered, the SSND should be abandoned, and a traditional selective neck dissection should be performed with the levels based off of the primary site location.

POSTOPERATIVE PERIOD

Postoperative Management

- Clear liquids initially progressing to a regular diet as tolerated is recommended.
- Postoperative antibiotics are not indicated.



Fig. 63.2. Right superselective neck dissection with complete isolation of the spinal accessory nerve and no fibroadipose tissue remaining lateral to the internal jugular vein.

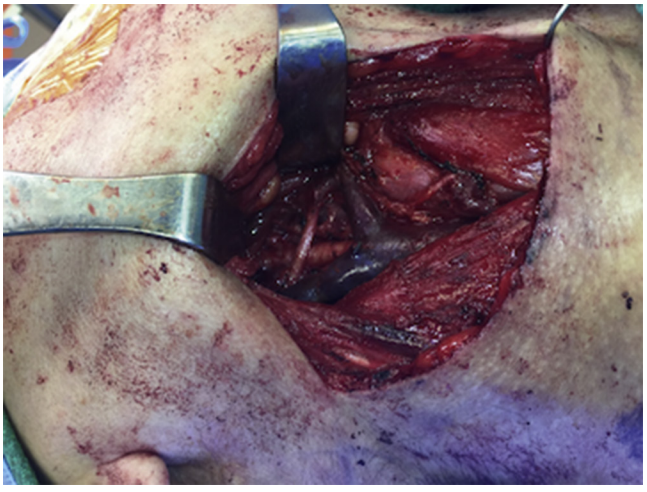

Fig. 63.3. Example of superselective neck dissection completely clearing the level IIA and III nodal groups. The hypoglossal nerve is seen coursing over the external carotid artery without any remaining fibroadipose tissue left in this area.

- Given the limited area of dissection, a surgical drain is typically not needed, but this is at the surgeon's discretion.
- May discharge the patient from the hospital the same day. If a drain is placed, it can usually be removed the following morning.

Complications

- Complications typical of any neck dissection: infection, poor healing, hematoma, seroma, numbness, nerve/vessel injury but theoretically minimized due to the limited extent of neck dissection

Alternative Management Plan

- May require radical or modified radical neck dissection depending on intraoperative findings

DISCUSSION

Evidence-Based Medicine Question

What is the evidence for performing an SSND for patients with an N0 neck, salvage setting, and indeterminate lateral nodes in papillary thyroid carcinoma (PTC)?

The rationale for performing an SSND in these two situations is based off of research evaluating nodal levels at the highest risk for metastases from these primary sites. This concept is based off the idea that nodal metastases follow an orderly and predictable pattern based on the primary site. In the oral cavity, the work by Woolgar describes the pattern of nodal metastases as an "inverted cone" with the majority of metastatic nodes present in levels I and II.[1] She reported a gradual reduction in the volume and extent of lymph node metastases at progressively higher nodal compartments but does note a 10% risk of skip metastases from cancer of the tongue to level IV. This is an important point to consider, because they would not be removed in an SSND of levels I and II. Another study evaluated skip metastases in primary cancer of the oral tongue and showed a 3.8% and 1.9% risk of isolated nodal disease in levels III and IV, respectively. In laryngeal carcinoma, the majority of nodal disease will be present in levels II and III. This was demonstrated in a large study of 402 patients that revealed that levels II and III were the first compartments involved in every patient.[2] They also demonstrated occult isolated metastases occurred to level IV in only 3% of cases. Other studies have confirmed this finding as well.

Another indication for SSND is in patients who have been treated with primary nonoperative management and have persistent, suspicious adenopathy in one nodal compartment. In a study that included 240 patients who underwent salvage neck dissection after chemoradiotherapy, SSND was performed in 8% of patients.[3] The regional control rate was significantly superior for SSND when compared with patients that underwent Radical neck dissection (RND) or Modified radical neck dissection (MRND), but there was no significant difference in survival between the groups. In another study that included two institutions, 35 SSNDs were performed in the salvage setting, and there were no regional recurrences over a median follow-up of 33 months.[4]

Lastly, there is controversy regarding the optimal way in which to treat suspicious lymph nodes in the lateral neck of patients with PTC. These are nodes that are concerning on imaging but are in difficult locations and cannot undergo FNA. According to the ATA guidelines, lateral neck dissection should be performed in cases of pathologically confirmed metastatic carcinoma. Performing an SSND of levels III and IV is an option and can be performed through the existing thyroidectomy incision. This prevents overtreating with a lateral neck dissection for nodes that might be negative and also prevents potentially having to perform a second surgery for nodes that were initially positive. In a study of 35 patients, SSND was performed for indeterminate nodes, and 38% had metastatic cancer in the pathologic specimen.[5] The oncologic outcomes of the SSND patients were compared with patients with known lateral neck disease who underwent formal lateral neck dissection. The patients who had SSND had significantly better recurrence-free survival than the patients with known N1b neck metastasis who had a lateral neck dissection.

In an effort to reduce the morbidity of surgical treatment of the neck, neck dissections have been progressively more targeted. In the SSND, we remove only the nodal compartments with the highest probability of harboring disease but risk missing disease in adjacent compartments. When limiting our dissection, we must weigh the potential advantages of the SSND against the risks of an SSND. When performed by a proficient surgeon, the SSND has a minimal postoperative morbidity. More studies and randomized controlled trials are needed to show the benefit of SSND while preserving oncologic safety.

Editorial Comment

SSND is a sophisticated option for management of neck metastasis with select indications. Pros and cons must be weighed carefully, and the surgeons must look beyond clinical indications for the procedure and also consider patient factors such as patient reliability and social support that may impact timely follow-up and consequently identification of recurrent cancer. The authors provide a comprehensive overview of the technique and a balanced perspective of how SSND fits into the paradigm for management of neck metastasis.

Rohan R. Walvekar

Access the review questions and additional sources list online at http://www.expertconsult.com



REFERENCES

1. Woolgar JA. The topography of cervical lymph node metastases revisited: the histological findings in 526 sides of neck dissection from 439 previously untreated patients. Int J Oral Maxillofac Surg 2007;36(3):219–225.
2. Redaelli de Zinis LO, Nicolai P, Tomenzoli D, et al. The distribution of lymph node metastases in supraglottic squamous cell carcinoma: therapeutic implications. Head Neck 2002;24(10):913–920.
3. Robbins KT, Doweck I, Samant S, et al. Effectiveness of superselective and selective neck dissection for advanced nodal metastases after chemoradiation. Arch Otolaryngol Head Neck Surg 2005;131(11):965–969.
4. Robbins KT, Dhiwakar M, Vieira F, et al. Efficacy of super-selective neck dissection following chemoradiation for advanced head and neck cancer. Oral Oncol 2012;48(11):1185–1189.
5. Kim H, Jin YJ, Cha W, et al. Feasibility of super-selective neck dissection for indeterminate lateral neck nodes in papillary thyroid carcinoma. Head Neck 2014;36(4):487–491.

REVIEW QUESTIONS

1. What is not a current indication for SSND?
   a. T2N0 oral tongue SCCa
   b. T1N0 supraglottic SCCa
   c. T1N1 floor of mouth SCCa
   d. Residual adenopathy in level II after CRT

2. What is an example of a SSND?
   a. Removal of levels II, III, and IJV
   b. Removal of levels III and IV
   c. Removal of levels I, II, and III
   d. Removal of levels II and IV

3. All of the following are potential benefits of SSND, except
   a. Less operative time
   b. Improved survival
   c. Less postoperative morbidity
   d. Smaller incisions

4. If you encounter a clinically suspicious node with ECS during SSND, what should you do?
   a. Continue with SSND.
   b. Close and offer radiation to the patient.
   c. Remove the single node and close the incision.
   d. Adjust to MRND to include the tissue involved in the ECS.

ADDITIONAL SOURCES

Balasubramanian D, Thankappan K, Battoo AJ, et al. Isolated skip nodal metastasis is rare in T1 and T2 oral tongue squamous cell carcinoma. Otolaryngol Head Neck Surg 2012;147(2):275–277.

Barroso Ribeiro R, Ribeiro Breda E. Fernandes Monteiro E: prognostic significance of nodal metastasis in advanced tumors of the larynx and hypopharynx. Acta Otorrinolaringol Esp 2012;63(4):292–298.

Brazilian Head and Neck Cancer Study Group. End results of a prospective trial on elective lateral neck dissection vs type III modified radical neck dissection in the management of supraglottic and transglottic carcinomas. Head Neck 1999;21:694–702.

Clayman GL, Frank DK. Selective neck dissection of anatomically appropriate levels is as efficacious as modified radical neck dissection for elective treatment of the clinically negative neck in patients with squamous cell carcinoma of the upper respiratory and digestive tracts. Arch Otolaryngol Head Neck 1998;124:348–352.

Crile G. Excision of cancer of the head and neck. With special reference to the plan of dissection based on 132 patients. JAMA 1906;47:1780–1786.

Crile GW. On the surgical treatment of cancer of the head and neck. With a summary of one hundred and twenty-one operations performed upon one hundred and five patients. Trans South Surg Gynecol Assoc 1905;18:108–127.

Ferlito A, Robbins KT, Shah JP, et al. Proposal for a rational classification of neck dissections. Head Neck 2011;33(3):445–450.

Ferlito A, Silver CE, Rinaldo A. Selective neck dissection (IIA, III): a rational replacement for complete functional neck dissection in patients with N0 supraglottic and glottic squamous carcinoma. Laryngoscope 2008;118(4):676–679.

Givi B, Andersen PE. Rationale for modifying neck dissection. J Surg Oncol 2008;97(8):674–682.

Haugen BR, Alexander EK, Bible KC, et al. 2015 American Thyroid Association Management Guidelines for adult patients with thyroid nodules and differentiated thyroid cancer. Thyroid 2016;26(1):1–133.

Hinsley ML, Hartig GK. Anatomic relationship between the spinal accessory nerve and internal jugular vein in the upper neck. Otolaryngol Head Neck Surg 2010;143(2):239–241.

Kim H, Jin YJ, Cha W, et al. Feasibility of super-selective neck dissection for indeterminate lateral neck nodes in papillary thyroid carcinoma. Head Neck 2014;36(4):487–491.

Layland MK, Sessions DG, Lenox J. The influence of lymph node metastasis in the treatment of squamous cell carcinoma of the oral cavity, oropharynx, larynx, and hypopharynx: N0 versus N+. Laryngoscope 2005;115(4):629–639.

Lindberg R. Distribution of cervical lymph node metastases from squamous cell carcinoma of the upper respiratory and digestive tracts. Cancer 1972;29(6):1446–1449.

Moe K, Wolf GT, Fisher SG, et al. Regional metastases in patients with advanced laryngeal cancer. Department of Veterans Affairs Laryngeal Cancer Study Group. Arch Otolaryngol Head Neck Surg 1996;122(6):644–648.

Pagedar NA, Gilbert RW. Selective neck dissection: a review of the evidence. Oral Oncol 2009;45(4-5):416–420.

Redaelli de Zinis LO, Nicolai P, Tomenzoli D, et al. The distribution of lymph node metastases in supraglottic squamous cell carcinoma: therapeutic implications. Head Neck 2002;24(10):913–920.

Robbins KT, Dhiwakar M, Vieira F, et al. Efficacy of super-selective neck dissection following chemoradiation for advanced head and neck cancer. Oral Oncol 2012;48(11):1185–1189.

Robbins KT, Doweck I, Samant S, et al. Effectiveness of superselective and selective neck dissection for advanced nodal metastases after chemoradiation. Arch Otolaryngol Head Neck Surg 2005;131(11):965–969.

Shah JP. Patterns of cervical lymph node metastasis from squamous carcinomas of the upper aerodigestive tract. Am J Surg 1990;160(4):405–409.

Suárez O. The problem of metastasis lymphatic cancer of the larynx and hypopharynx. Rev Otorrinolaringol 1963;23:83–99.

Woolgar JA. The topography of cervical lymph node metastases revisited: the histological findings in 526 sides of neck dissection from 439 previously untreated patients. Int J Oral Maxillofac Surg 2007;36(3):219–225.

64 Selective Neck Dissection

Karen Pitman

INTRODUCTION

Selective neck dissection (SND) is distinguished by the preservation of lymph node groups and nonlymphatic structures that are removed during radical neck dissection. SND is a generic term that applies to a group of procedures named according to the levels of the neck in which the lymph nodes are removed. SNDs evolved as surgeons developed an understanding of the predictable lymphatic drainage patterns in head and neck cancer and sought opportunities to optimize the patient's postoperative function. The primary indication for SND is management of the clinically negative neck when the risk of occult metastases is greater than 15% to 20% and the primary tumor is treated surgically. Selective procedures are used for elective treatment of the neck in primary cancers of mucosal sites of the head and neck, malignancies of the thyroid, salivary glands, and skin.[1]

Guidelines for naming neck dissections were developed by a committee with representatives from the American Head and Neck Society and the American Academy of Otolaryngology–Head and Neck Surgery.[2] The committee also recommended the use of levels and sublevels designated by Roman numerals I–VII to describe the location of lymph nodes in the neck. The naming convention is accepted by surgeons worldwide and facilitates communication and reporting of results. This system names the procedure according to the levels/sublevels that are removed.[3]

The most common SNDs are:

1. SND I–III, known as supraomohyoid neck dissection, SND I–IV, or extended supraomohyoid, typically used for treatment of oral cavity cancer
2. SND II–IV or lateral neck dissection for squamous cell carcinoma (SCC) of the oropharynx, hypopharynx, and larynx
3. SND II–V or posterolateral neck dissection for cutaneous malignancies posterior to the coronal planes through the external auditory canal (EAC) (e.g., posterior pinna and scalp). The suboccipital and retroauricular lymph node groups are included in the dissection.
4. SND VI or central compartment neck dissection, for thyroid cancer and cancers of the glottis and subglottis, piriform sinus, cervical esophagus, and trachea.

KEY OPERATIVE LEARNING POINTS

- Occult or micrometastases are not detectable on physical examination or radiographic imaging.
- SNDs are used for pathologic staging of the clinically negative neck.
- Pathologic findings guide decision making for adjuvant therapy.
- Learn both clinical and radiographic borders for the levels of the neck.
- Understand the lymphatic drainage patterns and lymph node groups at risk for occult metastasis according to site and stage of the primary cancer.
- Be familiar with the surgical anatomy of the neck.
- SNDs are also used for N1 and limited N2 cancers.[4,5]

PREOPERATIVE PERIOD

History

- Complete patient history with attention to symptoms of the primary cancer
- No specific symptoms for occult lymph nodes

Physical Examination

- Complete examination of the head and neck to assess the extent of primary cancer
- Accuracy of neck examination is dependent on patient habitus.
- Assess location and mobility of palpable neck nodes.
- Rule out synchronous second primary cancer.

Imaging

- CT or MRI of the neck and primary cancer within 30 to 60 days prior to surgery to assess local extent of primary tumor and the status of cervical lymph nodes
- Radiographic criteria for suspicious lymph nodes: size, shape, irregular enhancement, groups of lymph nodes
- Imaging not sensitive or specific enough to detect lymph node metastasis less than 1 cm
- Ultrasound-guided fine-needle aspiration biopsy of suspicious lymph nodes if results will impact the treatment plan

Indications for Selective Neck Dissection

- Clinically N0 neck and risk of occult metastases greater than 15% to 20%
- Transcervical approach to the primary cancer
- Access the neck for vascular anastomosis/free flap reconstruction
- Clinically N1 neck with metastases in the first echelon level[4,5]
- Low-volume clinical N2 neck without fixation of surrounding soft tissue invasion[4,5]
- Limited neck metastasis following radiation or chemoradiation
- Indications for specific levels by primary site:
  - Ia: Cancer of the lower lip, anterior tongue, and anterior mandibular alveolar ridge
  - Ib: Oral cavity, anterior nasal cavity, skin of the midface, and submandibular gland
    IIa/IIb: Oral cavity, nasal cavity, nasopharynx, oropharynx, hypopharynx, and larynx. Level IIb has a very low (<5%) incidence of occult adenopathy and is usually not dissected in elective neck dissection. Removal of IIb is included when SND is performed for clinically positive neck metastasis.[6-9]
  - III: Oral cavity, nasopharynx, oropharynx, hypopharynx, and larynx[6,7]
  - IV: Larynx, hypopharynx, thyroid, and cervical esophagus
  - V: Nasopharynx, oropharynx, skin of the posterior scalp and neck
  - VI: Thyroid, glottis/subglottis, hypopharynx, and cervical esophagus

Contraindications

- Poor surgical candidate
- Nonsurgical treatment of primary cancer
- Unresectable primary cancer
- Fixed cervical lymph adenopathy
- Distant metastases

Preoperative Preparation

- Appropriate assessment of surgical risk from medical standpoint
- Plan for reconstruction of primary site defect if applicable.

OPERATIVE PERIOD

Anesthesia

- General endotracheal anesthesia
- Avoid muscle paralysis to assist with identification of important nerves. Once at-risk nerves are identified, the patient can be paralyzed at the surgeon's discretion.
- Communicate during the case when anticipated significant blood loss and any change in the patient's condition is encountered.
- Presurgical discussion with anesthesia team about duration of procedure, anticipated blood loss, nerve monitoring, and other intraoperative concerns

Positioning

- Turn table 90 to 180 degrees to facilitate surgeon and assistant's access to the head and neck, especially with bilateral neck dissections.
- Patient position—Supine with head turned away from side of surgery
- Shoulder roll—Moderate shoulder roll for neck extension; avoid hyperextension to prevent postoperative neck pain

Perioperative Antibiotic Prophylaxis

- Guided by surgical approach to the primary cancer
- Not required for isolated neck dissection

Monitoring

- Not routinely used for isolated neck dissection

Instruments and Equipment to Have Available

- Standard neck dissection set
- Vascular suture for inadvertent internal jugular venotomy or other bleeding
- Nerve hooks and/or loops
- Headlight and loupes
- Bipolar, monopolar, and harmonic scalpel

Key Anatomic Landmarks

- External during surgical marking
  - Osseous: Lower border and angle of mandible, mastoid tip, clavicle, and hyoid bone
  - Non-osseous: sternocleidomastoid (SCM) muscle, external jugular vein, and carotid sheath
- Superficial and deep layers of the deep cervical fascia—SND removes the lymphoareolar tissue between these two layers
- Erb's point—Landmark for location of spinal accessory nerve at posterior border of SCM
- Cervical plexus—Motor and sensory branches
- Phrenic nerve
- SCM, anterior and posterior belly of digastric, sternohyoid, and omohyoid muscles
- Level I—Facial artery and vein, marginal mandibular nerve, lingual and hypoglossal nerves
- Spinal accessory nerve
- Carotid artery, jugular vein, vagus nerve
- Thoracic duct—Location, tributaries, and course
- Cervical sympathetic trunk—Ascending preganglionic sympathetic fibers; deep and medial to the carotid artery with multiple ganglia. Injury results in ipsilateral Horner's syndrome.

Surgical Landmarks for the *Levels of the Neck*

- Ia: Submental lymph nodes—Triangle overlying the anterior belly of digastric muscles, from the mandible to the hyoid
- Ib: Submandibular lymph nodes—Triangle bounded by mandible, anterior belly of digastric muscle and stylohyoid muscle, along with the posterior belly of the digastric muscle; includes the submandibular gland, the preglandular, prevascular, retrovascular, retroglandular, intracapsular, and deep submandibular lymph node groups
- IIa/IIb: Upper jugular lymph nodes—Area from the skull base to the hyoid bone, bounded anteriorly by the lateral border stylohyoid muscle; extends to the posterior border of the sternocleidomastoid muscle. A vertical plane formed by CN XI divides IIa from IIb.[9]
- III: Middle jugular lymph nodes—Inferior border of the hyoid bone to inferior border of cricoid cartilage, bounded anteriorly by the lateral border sternohyoid muscle; extends to the posterior border of the sternocleidomastoid muscle
- IV: Lower jugular lymph nodes—Lower border of the cricoid cartilage to the clavicle. Anterior extent is the lateral border of sternohyoid muscle; extends to the posterior border of sternocleidomastoid muscle
- Va/Vb: Posterior triangle lymph nodes—Superior border is intersection of sternocleidomastoid trapezius muscles, triangle formed by anterior border of trapezius, clavicle inferiorly, and posterior border of SCM. A horizontal plane extending from the inferior border of the cricoid cartilage divides level Va cranially from Vb caudally. Level Va includes the spinal accessory lymph node group, and Vb are the supraclavicular and transverse cervical lymph nodes.
- VI: Central compartment lymph nodes, including the prelaryngeal, pretracheal, and paratracheal lymph nodes. Surgical boundaries are the hyoid bone superiorly and medial border of carotid sheath bilaterally to the suprasternal notch inferiorly.
- Other lymph node groups: Groups of nodes located outside these levels are named by anatomic location:
  - Superior mediastinum: Suprasternal notch to innominate arteries, lateral boundary-carotid sheath, includes the anterosuperior mediastinum, and tracheoesophageal grooves
  - Retropharyngeal
  - Periparotid
  - Postauricular lymph nodes—on and behind the mastoid process
  - Occipital lymph nodes

Prerequisite Skills

- Basic surgical skills
- Familiar with the anatomy of the neck

Operative Risks

- Shoulder dysfunction, shoulder pain, capsulitis
- Chyle leak
- Infection
- Edema of the neck and face
- Sialocele
- Wound healing problems/flap necrosis in post radiation neck
- Hematoma
- Hypocalcemia for bilateral central compartment
- Nerve damage
- Vocal cord paralysis
- Skin and ear numbness
- Dysphagia
- Marginal mandibular nerve weakness/paralysis
- Dysarthria, tongue weakness, tongue numbness
- Horner's syndrome
- Paralysis of the diaphragm

Surgical Technique

- Neck dissections are defined by the levels that are removed, and the surgical steps for each level are described individually here. The sequence of events for every neck dissection will be different, depending on surgeon preference, the location of palpable lymph nodes, and the plan for excision of the primary cancer. General principles for all neck dissections are to define the superficial borders of the dissection and work from the superficial to deep structures to ensure adequate exposure of critical structures.
- Planning the incision—Depends on levels being removed and surgeon's preference. A transverse incision placed in a skin crease or standard utility incision affords good exposure for most SNDs.
- Incise the skin along the entire length of the planned incision. Identify the platysma prior to incising it, as the posterior border provides a reliable landmark for the external jugular vein and great auricular nerve.
- Incise platysma and elevate subplatysmal flaps. Keep the plane of dissection just deep to the platysma; this is an avascular plane that facilitates preservation of the external jugular vein, great auricular nerve, and the superficial layer of the deep cervical fascia (e.g., the fascia overlying the SCM). In areas where the platysma is dehiscent, flap elevation is continued in a subcutaneous plane of the dissection that is best defined by the surgeon.
- The extent of flap elevation depends on the levels of the neck that will be removed.
  - Level I: Inferior border of the mandible. Staying in the avascular plane just deep to the platysma will minimize the risk of injury to the marginal mandibular nerve.
  - Level II: Posterior belly of the digastric muscle
  - Level III: Inferior belly of omohyoid muscle
  - Level IV: Clavicle
  - Level V: Anterior edge of the trapezius muscle and clavicle
  - Level VI: Sternal notch, anterior border of SCM, hyoid bone
- Expose the most superficial boundaries of the neck dissection according to levels removed:
  - Level Ia—Lateral border of contralateral anterior belly digastric, mentum, and hyoid
  - Level Ib—Lower border of mandible, anterior and posterior digastric, facial artery and vein at their junction with the lower border of the mandible
  - Levels II–III—Posterior belly of digastric, lateral border of sternohyoid, and SCM from behind the angle of the mandible to the posterior omohyoid muscle
  - Levels II–IV—Posterior belly of the digastric, lateral border of sternohyoid, SCM from behind the angle of the mandible to the clavicle, and the clavicle anterior to the insertion of SCM
  - Level V—Mastoid tip, anterior border of trapezius, clavicle, and posterior border SCM

Level I Dissection

- Level Ia—Submental triangle: Dissect the fibrofatty tissue overlying the anterior bellies of the digastric muscles, from the mentum to the hyoid bone; includes lymphatic tissue between and deep to the anterior digastrics
- Complete dissection of level Ib includes the investing fascia of the submandibular gland and requires identification, dissection, and protection of the marginal mandibular nerve (Fig. 64.1).[10] The course of the nerve in relation to the inferior border of the mandible is variable, and identification is facilitated by opening the investing fascia in the vicinity of the angle of the mandible, where it exits the tail of the parotid. Once the nerve is skeletonized and placed above the inferior border of the mandible, the fascia of the gland is separated from the inferior border of the mandible, and the facial artery and vein are ligated. Level I contents are retracted inferiorly and posteriorly while dissecting the lymphatic tissue from the anterior belly of the digastric and mylohyoid to expose the lateral border of the mylohyoid. After ligating the blood supply to the mylohyoid, an angled retractor is used to retract the lateral border anteriorly to expose the lingual and hypoglossal nerves, submandibular ganglion, and duct and cross the hyoglossus muscle. The ganglion and the duct are ligated and transected while visualizing the lingual nerve and, once accomplished, will allow inferior retraction of the specimen and improved exposure of the hypoglossal nerve inferior and deep to the submandibular duct. Both the lingual and hypoglossal nerves are identified prior to ligating the submandibular duct as anteriorly as possible to ensure removal of the accessory gland tissue along the duct.

Level II–III and II–IV Dissection

- Elevate the investing fascia of the SCM along the entire anterior border preserving the great auricular nerve. Ligating the external jugular vein is not required but may be performed to improve exposure to level IIb. If the external jugular vein is ligated, consideration is given to reconstruction needs, and it should be ligated high along the anterior border of the SCM so sufficient length remains for anastomosis. As the fascia is developed, retract the SCM posteriorly to clear fascia off the deep surface of the muscle (Fig. 64.2).
- Identify CN XI as it enters the SCM. Avoid vigorous traction or trauma to the nerve. The transverse process of the atlas is a palpable landmark for the lateral border of the jugular in proximity of XI if anatomy obscures immediate visual identification.
- Skeletonize the inferior border of the posterior belly of the digastric muscle and retract superiorly to expose CN XI as it crosses the jugular vein.
- Expose the lateral border of the jugular vein at the superior extent of the dissection, which will be defined by whether IIb is included in the dissection. For IIa, the superior extent of dissection is inferior to the intersection with CN XI. If level IIb is included in the dissection, retract the posterior belly of the digastric/stylohyoid muscle complex superiorly and the SCM posteriorly with angled retractors. Then skeletonize CN XI from the lateral border of IJ to its entrance into the SCM (Fig. 64.3). Expose the lateral border of the jugular vein, and gently retract XI inferiorly to fully expose level IIb.

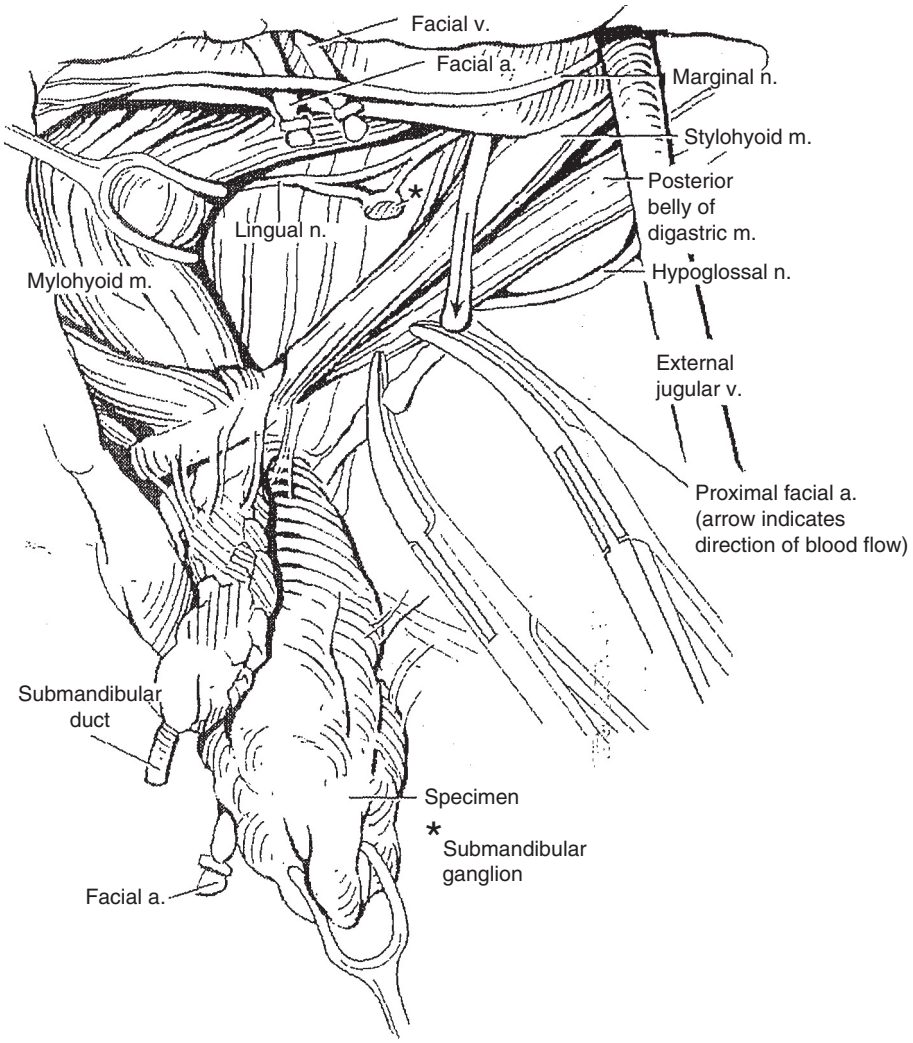

Fig. 64.1. Level Ib lymph node dissection. *(From Cohen JI, Clayman GL: Atlas of Head and Neck Surgery. 2012 [9781416033684, Fig. 19.6], Elsevier, with permission).*

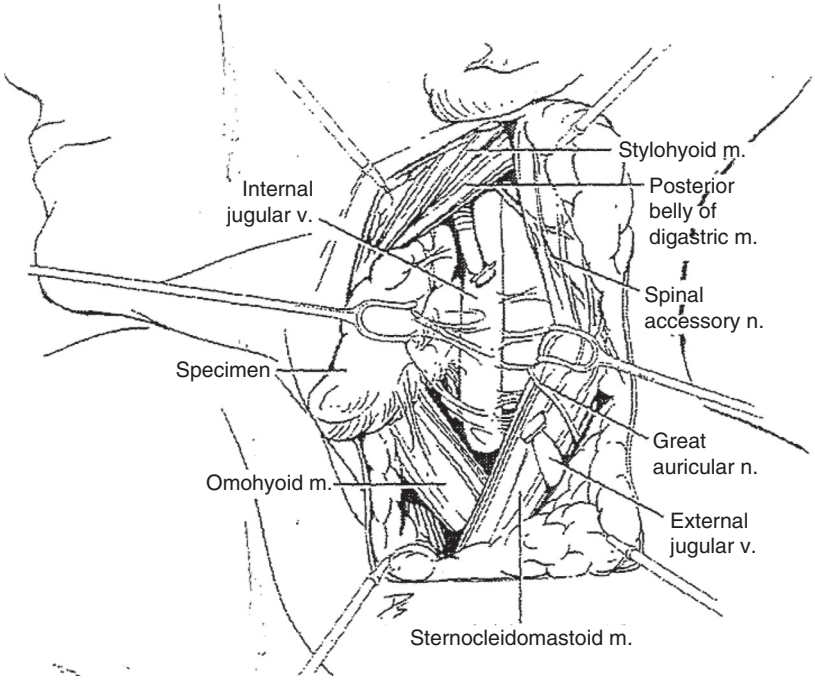

Fig. 64.2. Level II and III lymph node dissection. *(From Cohen JI, Clayman GL: Atlas of Head and Neck Surgery. 2012 [9781416033684, Fig. 19.7], Elsevier, with permission).*

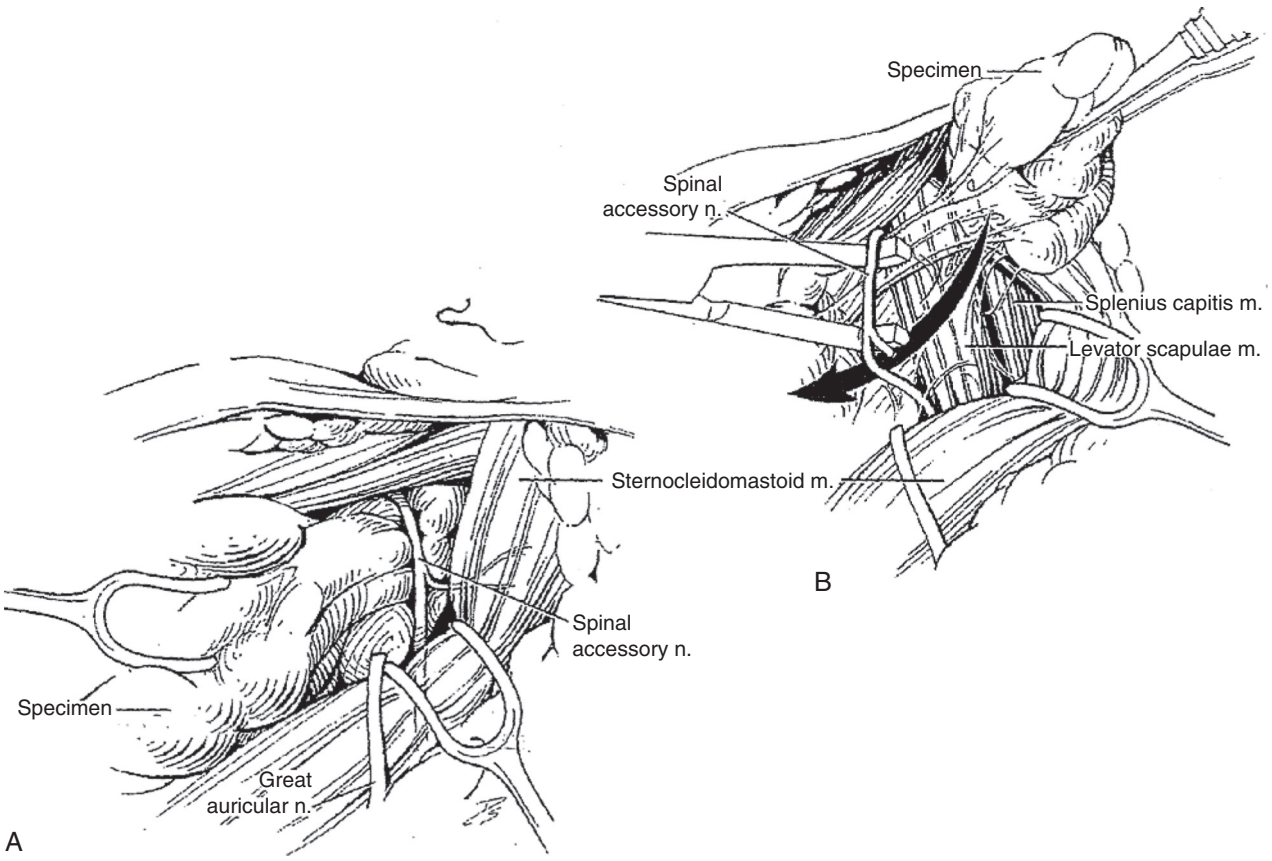

Fig. 64.3. Level IIb lymph node dissection. **A,** Level IIb as identified. **B,** Fibroadipose tissue in Level IIb dissected free of spinal accessory nerve and the muscular floor. *(From Cohen JI, Clayman GL: Atlas of Head and Neck Surgery. 2012 [9781416033684, Fig. 19.8], Elsevier, with permission).*

Bovie cautery can be used to clear the fibroadipose tissue from the muscular floor in the superolateral corner of IIb but as the dissection nears CN XI and the jugular vein changes to a dissector and bipolar cautery or Ligasure are used instead. Sweep IIb contents under CN XI and continue in continuity with level IIa.

- The posterior border of the SCM and cutaneous branches of the cervical plexus are the lateral extent of II–IV dissection. While retracting the SCM posteriorly, define the floor of the neck by incising the fibroadipose tissue deep to the SCM to expose the muscular floor while the assistant provides countertraction of the specimen anteriorly using a surgical sponge. This will expose the deep cervical fascia overlying the scalene and levator scapulae muscles.
- Division of the posterior omohyoid muscle facilitates complete exposure of level III and removal of the jugulo-omohyoid lymph node. This LN group should be removed in both level III and IV dissections (Fig. 64.4).
- The deep cervical fascia is left intact on the deep muscles of the neck. This protects the phrenic nerve and brachial plexus. The cervical rootlets are also preserved in SNP. The plane of dissection continues anteriorly in the plane superficial to the deep layer of cervical fascia from the posterior border of the SCM to the carotid sheath. The transverse cervical artery and vein are superficial to the fascia and can be preserved.
- Prior to dissection of the carotid sheath, identify the inferior most extent of the level III/IV dissection. To prevent inadvertent torsion of the internal jugular vein (IJV) here, identify the lateral border of the IJV, and open the carotid sheath by using a dissector to expose the lateral border of the IJV. Then clamp and tie the lymphatic tissue lateral to this point for about 2 to 3 cm toward the SCM. Since this is the location of the thoracic duct and its tributaries, the use of Bovie cautery alone for this maneuver is avoided.
- The superior and inferior borders of the carotid sheath dissection are clearly defined by exposing them; the neck contents are retracted anteriorly by the assistant to provide a broad plane of dissection along the entire length of the internal jugular vein. The carotid sheath is incised sharply, while the assistant provides anterior retraction, and the surgeon holds countertraction, both adjusting position as the internal jugular vein is exposed by the surgeon. Tributaries to the IJV are ligated as they are encountered. Traction and countertraction, and a sharp #10 blade, ensure complete clearance of the jugular chain lymph nodes of levels II, III, and IV.
- After dissection of the jugular vein the contents are freed from the lateral border of the sternohyoid muscle. If the omohyoid muscle was divided, the superior belly is in the specimen and is separated from the hyoid completing removal of the specimen.

Level V Dissection

- Expose boundaries of dissection: posterior edge of SCM, clavicle, and anterior border of the trapezius muscle.
- The spinal accessory nerve is identified at the posterior border of the SCM and skeletonized as it traverses the posterior triangle to its point of entry into the trapezius muscle. CN XI is distinguished from other nerves traveling parallel deep to the anterior border of the trapezius muscle for 1 to 2 cm before inserting into the muscle. CN XI is protected as level V is dissected from the posterior scalene and levator scapulae muscle, leaving fascia on the muscles (Fig. 64.5).

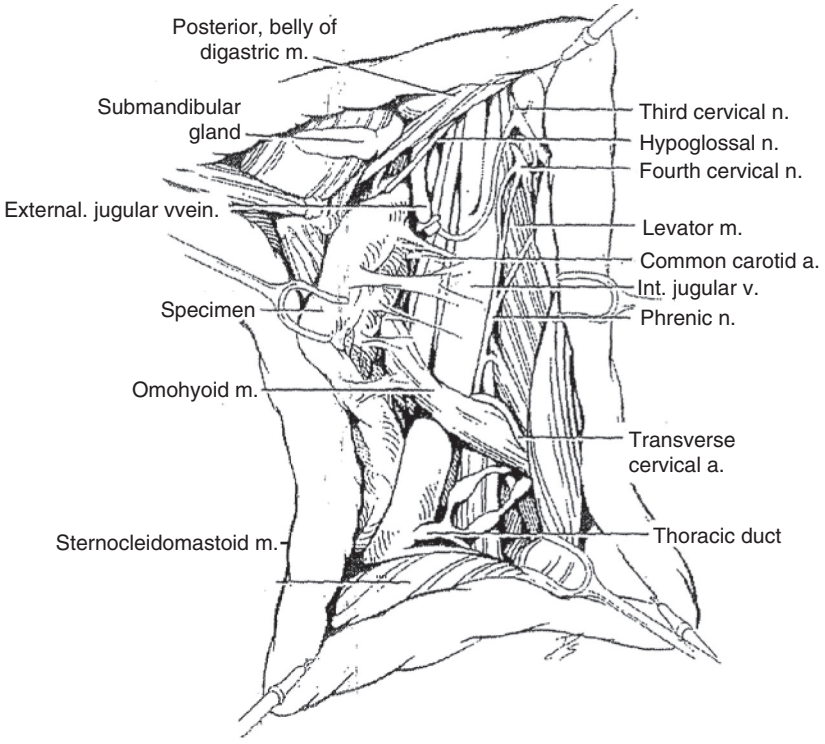

Fig. 64.4. Level IIa, III, and IV dissection. *(From Cohen JI, Clayman GL: Atlas of Head and Neck Surgery. 2012 [9781416033684, Fig. 20.6A], Elsevier, with permission.)*

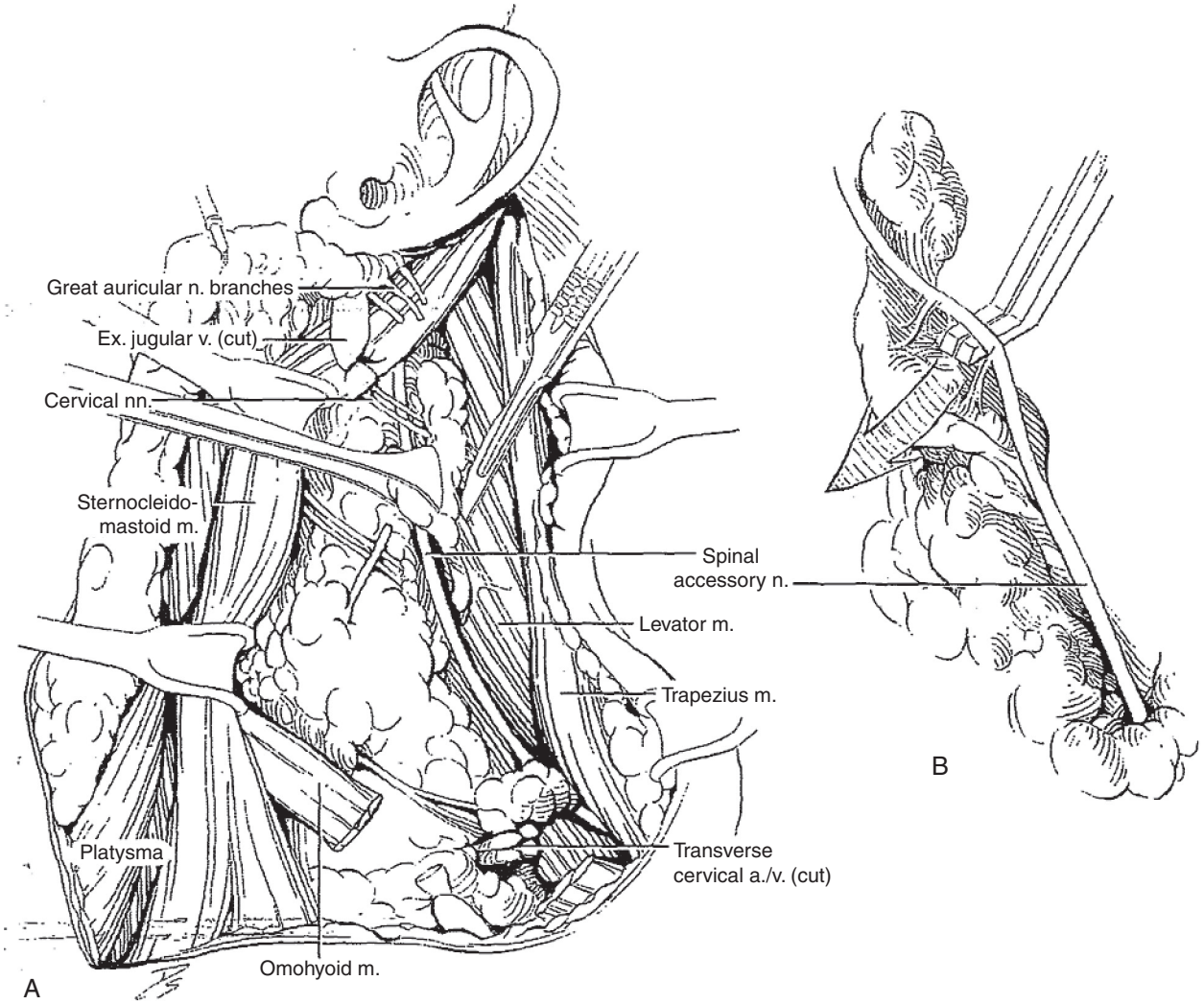

Fig. 64.5. Transposition of spinal accessory nerve. **A,** Spinal accessory nerve is identified. **B,** Spinal accessory nerve is skelatonized and the contents of Level 5 are brought deep to the nerve for further dissection. *(From Cohen JI, Clayman GL: Atlas of Head and Neck Surgery. 2012 [9781416033684, Fig. 21.5], Elsevier, with permission).*

- Contents of level V are dissected off the splenius capitus, levator scapulae, and scalene muscles, leaving a deep layer of the deep cervical fascia intact to protect the brachial plexus.
- If included with level II–IV, the contents of level V are brought deep to the SCM and removed with the jugular chain lymphatics.

Level VI Dissection

- Identify the boundaries of dissection: carotid sheath laterally, cricoid superiorly, trachea medially, innominate artery inferior.
- Identify and preserve the recurrent laryngeal nerves (RLNs) and parathyroid glands. Frozen section analysis and autotransplantation can be used to distinguish the parathyroid glands from the lymph nodes.
- Skeletonize the RLN through the central compartment and remove lymphatic tissue deep to the RLN.

Steps Once Dissection Is Complete

- The specimen is divided into respective levels, labeled accordingly and sent to pathology.
- The surgical bed is inspected for bleeding and leakage of chyle. A Valsalva maneuver performed by the anesthetist assists with identification of both. Identify and ligate lymphatic ducts if there is evidence of a chyle leak. Repeat inspection after ligation to ensure the leak has been repaired.
- Closed suction drains placed carefully to ensure drainage of the most dependent aspect of surgical bed. Drains connected to wall suction during skin closure to prevent blood clotting in the drain tubing and rendering the drain nonfunctional.
- Layered closure starting with the several interrupted dissolvable sutures placed in the platysma. Subcutaneous layer reapproximated with interrupted dissolvable sutures at close interval. Drain tubing changed from wall to bulb suction now ensures closure is airtight prior to skin closure.
- Skin closed with running nylon, Prolene suture, or surgical skin staples

Common Errors in Technique

- Maintain the deep layer of the deep cervical fascia intact on the floor of the neck dissection to protect the brachial plexus and phrenic nerve.
  Preservation of the cervical plexus nerves minimizes shoulder dysfunction and numbness of the skin.
- If microvascular reconstruction is planned, preservation of the external jugular vein and transverse cervical vessels will be available as anastomotic options and, when possible, maintain a generous pedicle when ligating branches of the external carotid artery and internal jugular vein.
- Torsion of the jugular vein during carotid sheath dissection prevents adequate visualization of the vein walls and inadvertent entry. This is prevented by exposing the lateral border of the jugular vein at the superior and inferior extent of the dissection prior to performing carotid sheath dissection.
- CN XI enters the trapezius muscle on its under surface about 1 cm from the free edge, distinguishing it from branches of the cervical plexus traveling through the posterior triangle.
- The thoracic duct and right lymphatic duct are in predictable locations, and when the dissection involves these structures, carefully inspect for chyle leak at the completion of the procedure. This is accomplished by having the anesthetist perform a Valsalva maneuver and/or applying firm, constant pressure to the abdomen while inspecting the area. If chyle is identified, every effort must be made to stop the leak. A variety of techniques can be used, including clips, clamp, suture ligation, and interposition of local muscle flaps or using the Ligasure or Harmonic scalpel to seal the lymphatic vessels to ensure that the leak is completely stopped and then reinforcing the area with fibrin glue.

POSTOPERATIVE PERIOD

Postoperative Management

- Wound care—antibiotic ointment to incision
- Measure and record drain output.
- Shoulder physical therapy starting POD 1 or 2

Complications

- See operative risks.

Alternative Management Plan

- Radiation or observation for poor surgical candidates

DISCUSSION

Evidence-Based Medicine Question

Is an SND as effective as comprehensive neck dissection for pathologic staging of the clinically negative neck?

Beginning in the middle of the 20th century, surgeons began to modify the classical radical neck dissection when performing elective neck dissection. The evolution toward procedures that remove only lymph node groups that were at risk for occult metastasis based on the location of the primary tumor (e.g., selective procedures) was guided by clinical studies that demonstrated cervical lymph node metastasis occurs in predictable drainage pathways. A key motivation for the development of selective procedures was better functional and cosmetic outcomes relative to comprehensive procedures. Since their initial adoption, multiple studies have shown acceptable regional recurrence rates following selective procedures, as shown in the review of Barzan et al. 2015.

Editorial Comment

Based upon his milestone paper in 1906, Dr. George Crile's name is indelibly linked with the radical neck dissection. The operation, as he described it, called for the removal of both lymphatic and non-lymphatic structures in the neck which contained cancer from various sites in the head and neck metastatic to the cervical lymph nodes. This procedure, despite its negative impact on form and function, remains the "standard of care" for metastatic cancer in the neck. However, if one reads Crile's paper analytically, it appears that less than one half of the more than 100 patients described had undergone a true radical neck dissection so that Dr. Crile was removing metastatic lymph nodes at various levels in the neck while preserving non-lymphatic structures and thereby describing both the RND and SND in this important paper.

In the 1960's, Professor Gavilan and Suarez described the "functional neck dissection" in which the lymph nodes could be removed while preserving the non-lymphatic structures thereby preserving form and function. Professor Ettore Bocca, in 1991, published his landmark paper describing the results using bilateral SND's in 1000 patients in the management of cancer of the supraglottic larynx which resulted in a decreased rate of recurrence in the neck while preserving cosmesis and function.

Dr. Jatin Shah and colleagues published a paper, in 1991, which was a review of the records of more than 1000 patients who has undergone RND in the Memorial Hospital and correlated the levels in the neck when metastatic lymph nodes were present with the site of the primary cancer. This important

work made the selection of the proper type of SND more precise since it demonstrated that cervical lymph node metastasis have predictable drainage pathways.

As part of the movement towards surgical minimalism the SND was embraced because of its preservation of form and function. While obviously these important issues they only matter if the control of cancer in the neck is comparable to the more comprehensive procedure. Publications from our Department, including Dr. Pitman's important work "Effectiveness of Selective Neck Dissection for Management of the Clinically Negative Neck" as well as others cited in the references, including Myers and Gastman and Hosal, Carrau, Johnson et al has demonstrated that the versatile operation results in cancer control rates comparable to the new comprehensive operation and may be employed in the management of the NO or the N+ neck.

Eugene N. Myers



Access the review questions and additional source list online at http://www.expertconsult.com

REFERENCES

1. Myers EN, Gastman BR. Neck dissection: an operation in evolution: Hayes Martin Lecture. Arch Otolaryngol Head Neck Surg 2003;129:14–25.
2. Ferlito A, Robbins KT, Shah JP, et al. Proposal for rationale classification of neck dissections. Head Neck 2011;33:445–450.
3. Robbins KT, Clayman G, Levine PA, et al. Neck dissection classification update: revisions proposed by the American Head and Neck Society and the American Academy of Otolaryngology-Head and Neck Surgery. Arch Otolaryngol Head Neck Surg 2002; 128:751–758.
4. Andersen PE, Warren F, Spiro J, et al. Results of selective neck dissection in management of the node-positive neck. Arch Otolaryngol Head Neck Surg 2002;128:1180–1184.
5. Hosal AS, Carrau RL, Johnson JT, et al. Selective neck dissection in the management of the clinically node-negative neck. Laryngoscope 2000;110(12):2037–2040.
6. Woolgar JA. Histological distribution of cervical lymph node metastases from intraoral/oropharyngeal squamous cell carcinomas. Br J Oral Maxillofac Surg 1999;37:175–180.
7. Woolgar JA. Detailed topography of cervical lymph-node metastases from oral squamous cell carcinoma. Int J Oral Maxillofac Surg 1997;26:3–9.
8. Cappiello J, Piazza C, Giudice M, et al. Shoulder disability after different selective neck dissections (levels II-IV versus levels II-V): a comparative study. Laryngoscope 2005;115(2):259–263.
9. Lea J, Bachar G, Sawka AM, et al. Metastases to level IIb in squamous cell carcinoma of the oral cavity: a systematic review and meta-analysis. Head Neck 2010;32(2):184–190.
10. Dinardo LJ. Lymphatics of the submandibular space: an anatomic, clinical, and pathologic study with applications to floor-of-mouth carcinoma. Laryngoscope 1998;108(2):206–214.

REVIEW QUESTIONS

1. Indications for selective neck dissection include
   a. T2 N0 oral tongue cancer
   b. T2 N0 tonsil cancer
   c. T2 N1 oral tongue cancer
   d. All

2. Selective neck dissection for cutaneous malignancy of the posterior scalp includes the occipital lymph nodes.
   a. True
   b. False

3. Shoulder dysfunction is observed in 15% of individuals following SND II-IV.
   a. True
   b. False

ADDITIONAL SOURCE

Barzan L, Talamani R, Franchin G, et al. Effectiveness of selective neck dissection in head and neck cancer. Laryngoscope 2015;125:1849–1855.

65 Modified Radical Neck Dissection

Steven Parnes, Anna Butrymowicz

INTRODUCTION

In the early 1900s, George Crile recognized that cancer of the head and neck was primarily a locoregional disease and felt that patients could be cured if the cancer was completely excised. The cervical lymph nodes were recognized as the initial area of spread and so the best chance for cure was excision of the primary cancer sites in concert with the ipsilateral cervical soft tissue.[1] He described and popularized radical neck dissections for the treatment of regionally metastatic head and neck cancer. Crile's radical neck dissection remained the standard of care for cervical metastases for almost 70 years.

Modifications of the traditional radical neck dissection came after 1963, when Suarez demonstrated that the nonlymphatic structures (sternocleidomastoid muscle and internal jugular vein) were anatomically separated by fascia from the lymph nodes. Oncologic outcomes were found to be similar to radical neck dissections, and the functional and aesthetic outcomes of patients were clearly superior.[2-4] In addition, particularly with the advent of radiation therapy, preservation of the sternocleidomastoid muscle was found to protect the carotid artery from subsequent damage and potential blowout.[5]

Several classification schemes for a neck dissection were introduced, and in an effort to present a common language the Committee for Head and Neck Surgery and Oncology of the American Academy of Otolaryngology–Head and Neck Surgery introduced the most widely accepted classification system in 1991. A modified radical neck dissection was defined as "the excision of all lymph nodes routinely removed by the radical neck dissection, with preservation of one or more nonlymphatic structures."[6]

KEY OPERATIVE LEARNING POINTS

- Modified radical neck dissection is strictly defined as the removal of lymph nodes from levels 1 to 5 while preserving one or more of the nonlymphatic structures (sternocleidomastoid muscle, spinal accessory nerve, internal jugular vein).
- Decisions to perform a modified radical neck dissection are often made intraoperatively, when those nonlymphatic structures are found to be involved with cancer.
- Preservation of the spinal accessory nerve maintains normal shoulder function.
- Neck dissections can be done safely when the surgeon has thorough knowledge of the anatomy.
- Soft tissue in level 4 should be clamped and ligated to prevent chyle leaks.
- Manipulation of the carotid artery can cause excessive stimulation of the carotid body reflex, resulting in bradycardia and hypotension. This can be resolved with injection of lidocaine directly into the carotid sinus.
- When approaching the carotid sheath, it is important to keep the plane of dissection over the jugular vein to prevent inadvertent damage to the sympathetic trunk, vagus nerve, or carotid artery.

PREOPERATIVE PERIOD

History

- History of present illness
  - Presentation at diagnosis
  - Location of the primary cancer: The primary site will dictate which nodal levels are at risk for metastases and therefore will determine the extent of surgery. For example, cancer of the floor of the mouth rarely metastasizes to level V, and so if these nodes are not clinically or radiographically involved, level V nodes can be preserved, thereby obviating the need for a radical neck dissection.
  - Symptoms related to the site of the primary
  - Restriction in range of motion of the neck
  - Shortness of breath: can be secondary to the primary lesion or medical comorbidities secondary to tobacco use; however, involvement of the phrenic nerve is possible. A chest radiograph will help to determine the integrity of the phrenic nerve.
  - Numbness of the anterior tongue
  - Dysgeusia
  - Dysphagia
  - Voice changes
  - Weight loss: The patient's nutritional status should be optimized before undergoing any surgical procedure because this will affect his or her wound healing. If a patient has had significant weight loss secondary to dysphagia or odynophagia, it may be beneficial to place a feeding tube and improve the patient's nutritional status before intervention to prevent postoperative complications.
  - Any neoadjuvant or definitive treatment
- Past medical/surgical history
  - Medical illness: cardiovascular disease, stroke, carotid insufficiency
  - Neck surgery: carotid endarterectomy, anterior approach to the cervical spine
  - Family history of cancer
  - Medications
    - Antiplatelet drugs
    - Vitamins/herbal products: i.e., vitamin E, Ginkgo biloba
    - Opiates: Postoperative pain control in chronic pain patients is very different from opiate-naive patients. Consultation should be sought in those particularly complex cases (e.g., patients on suboxone or methadone).
- Social history
  - Opiate abuse
  - Drug rehabilitation programs
  - Smoking
  - Occupation
  - Alcohol intake: Extent of alcohol intake is important in anticipating a patient's postoperative needs and the risk for delirium tremens.
- Informed consent

Physical Examination

- Thorough examination of the head and neck with documentation of nodal levels involved as well as relevant

surgical findings that may affect surgical decision making such as fixation to overlying structures (e.g., skin) or underlying structures (e.g., deep muscles of the neck)
- Fiberoptic nasopharyngoscopy
- Auscultation of the carotid for bruits
- Neurologic examination
  - Invasion of major nerves
    - Facial nerve: Observe symmetry with facial movement, with focus on the inferior division.
    - Lingual nerve: difficult to examine, nerve injury often elicited through history
    - Vagus nerve: ipsilateral vocal cord paresis and palate asymmetry
    - Hypoglossal nerve: deviation of the tongue toward the injured side
    - Spinal accessory nerve: winged scapula, sternocleidomastoid and atrophy of the trapezius
    - Sympathetic trunk: ipsilateral Horner syndrome
    - Phrenic nerve: History and imaging will help to determine phrenic nerve involvement.
    - Brachial plexus: motor-sensory dysfunction in the ipsilateral arm

Imaging

- Chest radiograph
  - Metastases
  - Synchronous primary cancer in the lung
  - Pulmonary and cardiac status
- Computed tomography (CT) (Fig. 65.1)
  - Adequate for radiographic staging when imaging of the chest is added
  - May help to anticipate involvement of nonlymphatic structures
- Positron emission tomography (PET)-CT: In a multicenter prospective trial assessing the CT versus PET/CT for initial staging, PET/CT upstaged and changed management in almost 14% of patients.[7] Studies like this have prompted the National Comprehensive Cancer Network to include recommendations for PET/CT in stage 3 or 4 cancer in the majority of subsites in the head and neck.[8]
  - Assesses local involvement
  - Identifies distant metastases
  - Second primary cancers
- Magnetic resonance imaging (MRI)
  - Not required in many cases
  - Helps to identify the presence of perineural invasion and the extent of the cancer
- Angiography
  - Balloon occlusion testing helps anticipate the risk of stroke in patients with carotid involvement who may require carotid resection.

Indications

Modified radical neck dissection is indicated when the spinal accessory nerve, internal jugular vein, or sternocleidomastoid muscle can be preserved without affecting oncologic outcomes and when a selective neck dissection would not adequately remove the volume of cancer in the neck. The decision to proceed with a modified radical neck dissection is often made intraoperatively, when the sternocleidomastoid muscle, spinal accessory nerve, or internal jugular vein are found to be involved with cancer.

For a neck dissection to be classified as a modified radical neck dissection, all lymph node levels must be dissected. Level 5 nodes are infrequently involved with noncutaneous head and neck squamous cell carcinoma. As demonstrated by Lindberg in 1972 and in many subsequent publications, nasopharyngeal primaries frequently metastasize to level 5 nodes; however, other head and neck sites rarely involve this level.[9,10] Therefore, without palpable or radiographic evidence of metastases to level 5, dissections of level 5 is not indicated, with the exception of nasopharyngeal and some oropharyngeal primaries.

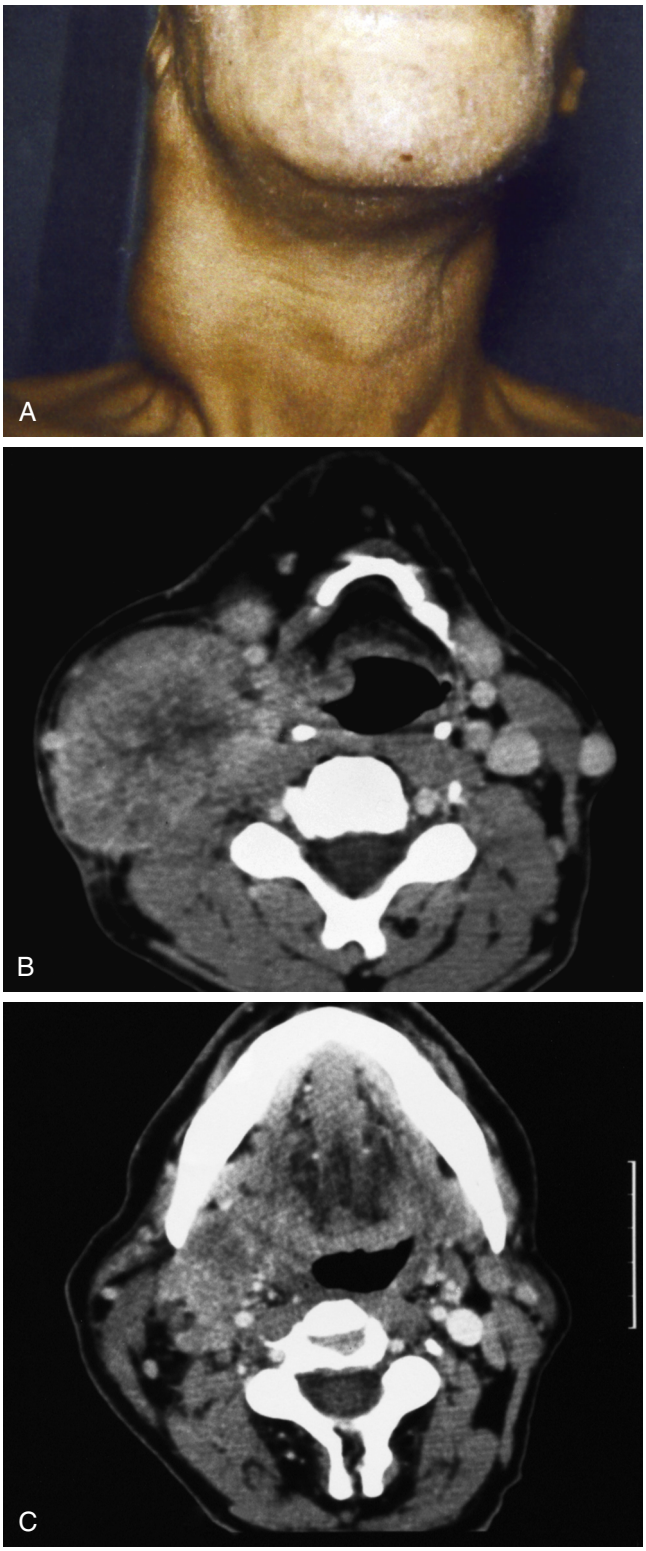

Fig. 65.1. A, Photograph and **B** and **C** axial computed tomography (CT) scans of the neck of a patient with massive cervical lymphadenopathy. The CT scans demonstrate encasement of the left carotid artery and suggest tumor invasion of the sternocleidomastoid muscle and the deep cervical muscles.

Contraindications

- N0 neck (see Selective Neck Dissection Chapter)
- Extensive metastasis
  - Encasement of the carotid artery
  - Invasion of the deep muscles of the neck
  - Invasion of the skull base
- Distant metastases
- Comorbidities that prevent safe administration of general anesthesia

Preoperative Preparation

- Chlorhexidine wash: Despite the Centers for Disease Control and Prevention (CDC) recommending chlorhexidine washes preoperatively to decrease the bacterial load on the skin, there has been little to no evidence that it decreases the rate of soft tissue infections in head and neck surgery. For patients with a history of methicillin-resistant *Staphylococcus aureus* infections, a preoperative chlorhexidine wash may be of benefit.

OPERATIVE PERIOD

Anesthesia

- General anesthesia
- Avoid paralysis: The anesthesia team should be aware of the need to monitor stimulation of particular muscles during the surgery; therefore paralysis should be avoided.
- Intubation: Technique varies depending on the site of the primary. Regardless, the otolaryngologist should be involved during the intubation to guide the anesthesiologist through the altered anatomy and to provide a surgical airway if necessary.

Positioning

- Supine, head extended with adequate shoulder support and turned to the nonoperative side to provide adequate exposure of the surgical site
- Table turned 90 degrees; 180 degrees if bilateral procedure is planned
- Shoulder roll or inflatable surgical pillow (e.g., surgical thyroid pillow) can be used for shoulder support and to provide neck extension.

Perioperative Antibiotic Prophylaxis

- There is no clear evidence that prophylactic perioperative antibiotics decrease the incidence of surgical site infections in clean neck dissections, although Carrau et al. did show a trend for a higher incidence of infections in untreated patients.

Monitoring

- Facial nerve monitor can be used to help with identification of the marginal mandibular nerve during dissection of level 1.

Instruments and Equipment to Have Available

- Head and neck set
- Bipolar and monopolar cautery
- 2.0 and 3.0 silk reel

Key Anatomic Landmarks

- External landmarks:
  - Angle of the jaw
  - Mastoid tip
  - Midline of the neck
  - Anterior and posterior borders of the sternocleidomastoid muscle
  - Clavicle
- Levels of the neck (Fig. 65.2):
  - Level Ia: submental triangle
    - Boundaries: anterior belly of the digastric muscles and the hyoid bone
  - Level Ib: submandibular triangle
    - Boundaries: body of the mandible and the anterior and posterior belly of the digastric muscle
  - Level II: upper jugular nodes
    - Anterior boundary: border of the stylohyoid muscle
    - Posterior: posterior border of the sternocleidomastoid muscle
    - Superior: skull base
    - Inferior: Level of the hyoid bone
    - Further divided into level IIa and IIb by the spinal accessory nerve
  - Level III: middle jugular nodes
    - Anterior boundary: lateral border of the sternohyoid muscle
    - Posterior: posterior border of the sternocleidomastoid muscle
    - Superior: hyoid bone
    - Inferior: omohyoid muscle or cricoid cartilage
  - Level IV: lower jugular nodes
    - Anterior boundary: lateral border of the sternohyoid muscle
    - Posterior: posterior border of the sternocleidomastoid muscle
    - Superior: omohyoid/cricoid
    - Inferior: clavicle
  - Level V: posterior triangle
    - Anterior boundary: posterior border of the sternocleidomastoid muscle
    - Posterior: anterior border of the trapezius muscle

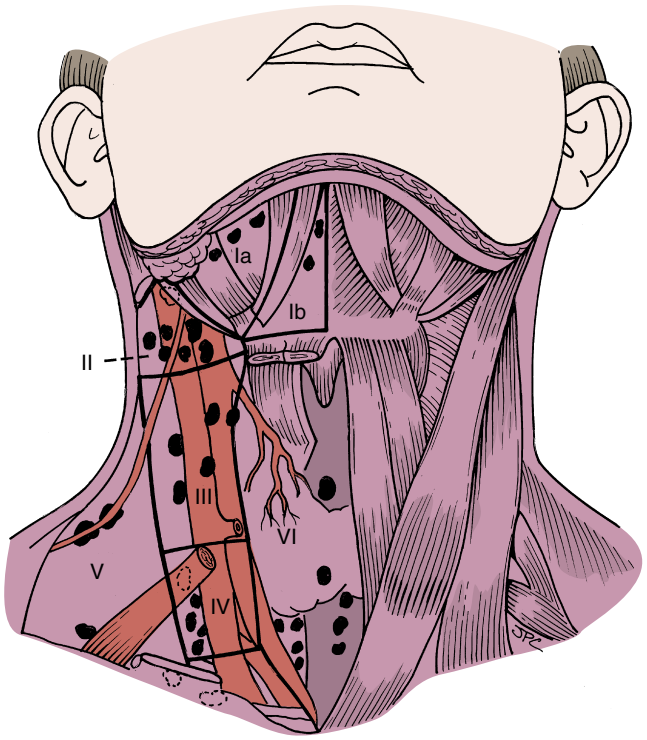

Fig. 65.2. Levels of neck nodes. Selective neck dissections are labeled according to the levels of nodes removed.



Fig. 65.3. A patient with paralysis of the right trapezius and a dropped shoulder, resulting from 11th nerve sacrifice.

- Inferior: clavicle
- Further divided into level Va and Vb by a horizontal extension at the level of the cricoid cartilage

Prerequisite Skills

- Soft tissue surgery
- Neurovascular dissection
- Radical neck dissection (see Chapter 66 on Radical Neck Dissection)

Operative Risks

- Stroke and/or death
- Scarring of skin
- Bleeding, infection, edema
- Neck asymmetry (Fig. 65.3)
- Shoulder weakness and pain (Fig. 65.3)
- Tongue weakness with resultant swallowing or articulation difficulties
- Voice and swallowing dysfunction from vagal injuries
- Weakness of lower lip and/or face
- Horner syndrome
- Chyle leak
- Risk of significant facial or cerebral edema, particularly in bilateral internal jugular vein injury/sacrifice
- Necrosis of the skin flap
- Possible need for further intervention
- Salivary fistula: of concern when the neck dissection is combined with oral or pharyngeal procedures or if a part of the parotid is included in the neck dissection

Surgical Technique

- Prep: 10% povidone iodine; prep should include rectangular area anteriorly just past the midline of neck, posteriorly beyond the posterior border of the sternocleidomastoid muscle, inferiorly below the level of the clavicle, superiorly just above the mandible to include the mastoid tip
- Incision: The Lahey (hockey stick) incision is marked from the mastoid tip down diagonally tracking just posterior to the anterior border of the sternocleidomastoid muscle. At the level of the cricoid or cricothyroid membrane, the incision continues vertically toward the midline. Care is taken to make this incision in a pre-existing neck crease to help to conceal the scar.
- Skin flap elevation: The superior skin flap should be grasped with sharp Senn retractors or Lahey tumor forceps to tent the skin edge up perpendicular to the plane of dissection. With Bovie electrocautery, the skin flap is elevated in a subplatysmal plane leaving the cervical plexus and external jugular vein down. If the mass closely abuts the platysma muscle, a cuff of healthy muscle should be taken with the mass. Involvement of the skin requires removal of the involved segments. As the flap is elevated toward the mandible, it is essential to identify and preserve the marginal mandibular branch of the facial nerve. Although its course is highly variable, a number of landmarks can help to identify the marginal branch during this point in the dissection. Dissection should transition from sharp to dull to allow proper identification. The antegonial notch and the pulse of the facial artery can be palpated along the inferior border of the mandible. Careful dissection in the soft tissue overlying the facial artery and vein will allow safe identification of the marginal mandibular nerve. After being identified, the soft tissue overlying the nerve should be carefully dissected anteriorly and posteriorly. As the facial vein, inferior to the nerve, is ligated, the soft tissue can be deflected superiorly to the skin flap, protecting the marginal nerve from inadvertent injury. The maneuver will also allow for dissection of the perifacial lymph nodes. The skin flap should then be elevated to the anterior border of the trapezius muscle and inferiorly to the clavicle and sternal notch. The spinal accessory nerve emerges from behind the sternocleidomastoid muscle in a relatively superficial plane, and because the platysma muscle does not continue beyond the sternocleidomastoid muscle, the spinal accessory nerve is vulnerable to injury. The nerve can be identified in relation to Erb's point, which can be identified by following the greater auricular nerve to the posterior border of the sternocleidomastoid muscle. The spinal accessory nerve can be found approximately 1 cm above this point.
- Level 1 dissection: First, identify the contralateral anterior belly of the digastric muscle. Incise the fascia over its medial surface and dissect the submental adipose tissue pad in a lateral direction over the ipsilateral anterior belly of the digastric and the mylohyoid muscle. The mylohyoid muscle is then retracted anteriorly while the submandibular gland is retracted inferiorly. The specimen can be swept inferiorly with a sponge, exposing the lingual nerve and the submandibular ganglion. The attachment of the lingual nerve at the ganglion is then clamped, ligated, and tied. This will in turn expose Wharton's duct, which should also be clamped, ligated, and tied as distally as possible. The facial artery is again ligated at the posterior aspect of the gland, and the dissection continues laterally over the posterior belly of the digastric muscle. The level 1 lymph nodes are now pedicled on the level 2 nodal basin.
- Superior ligation of nonlymphatic structures: Continue dissection along the posterior belly of the digastric muscle until the sternocleidomastoid muscle is identified. The spinal accessory nerve can be identified as it continues deep to the muscle and over the internal jugular vein (Fig. 65.4). The soft tissue overlying the nerve should be bluntly dissected posteriorly, under the sternocleidomastoid to the anterior border of the trapezius muscle. The medial aspect of the sternocleidomastoid muscle should be dissected away from

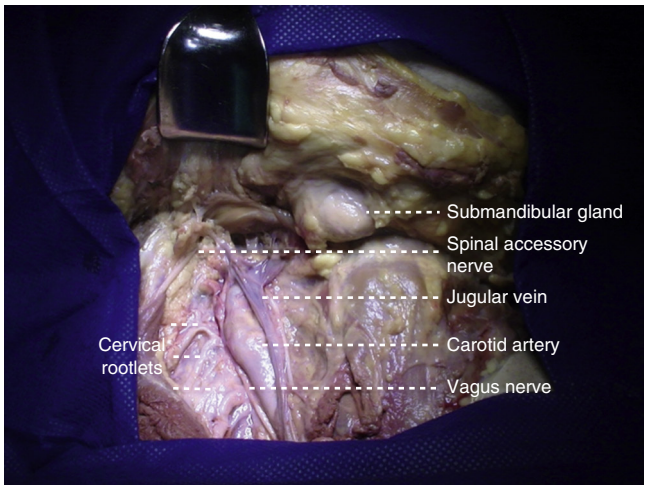

Fig. 65.4. Cadaveric specimen after right-sided dissection of levels 1 to 4 with preservation of the submandibular gland, jugular vein, and spinal accessory nerve.

the underlying soft tissue superior to the spinal accessory nerve toward the mastoid tip. If the internal jugular vein is to be included in the specimen, the posterior belly of the digastric muscle is retracted superiorly, and the internal jugular vein is dissected free of the surrounding soft tissue, clamped, ligated twice with a 2.0 silk tie and then suture ligated. At this point, the spinal accessory nerve can be divided or retracted, depending on the preoperative plan. If the muscle is being excised, it should be dissected off of the mastoid tip and reflected inferiorly.

- Level 2 and 5 dissection superior to the cranial nerve XI: If the spinal accessory nerve is preserved, it can be carefully retracted inferiorly with a nerve hook. Level 2 nodes can be retracted inferiorly while the Bovie electrocautery aids in deep dissection down to the fascia of the splenius capitus and levator scapulae muscles. The dissection is continued at this depth posteriorly, to the anterior border of the trapezius muscle, slowly retracting the specimen inferiorly. After the plane of dissection has reached the level of the spinal accessory nerve, the specimen can be draped under the nerve. Alternatively, if the spinal accessory nerve is being removed, the nerve can be clamped and ligated at the level of the posterior belly of the digastric muscle.
- Completing lymphadenectomy: The dissection is then carried anteriorly away from the anterior border of the trapezius muscle. The omohyoid muscle should be ligated at the border of the trapezius muscle and should be dissected along with the main specimen. It is helpful to leave the fascia on the deep muscles to protect the neural supply to the levator scapulae muscle, as well as the roots of cervical plexus. As the dissection is continued medially, beyond the posterior border of the sternocleidomastoid muscle, care must be taken to stay superficial to the level of the cervical rootlets keeping the transverse cervical artery, phrenic nerve, and brachial plexus deep to the plane of dissection (Fig. 65.5). The soft tissue between the level of the omohyoid and clavicle (level 4) should be bluntly dissected, clamped, and ligated to prevent inadvertent damage to the lymphatic vessels, which could lead to a chyle leak. If the surgical plan includes removal of the sternocleidomastoid muscle, it can be transected off the clavicle and the sternal head, one fingerbreadth above the bone. The jugular vein should be identified and protected prior to transection of the muscle. At this point, the anesthesiologist should be asked to provide positive pressure to aid in identification of a chyle leak.

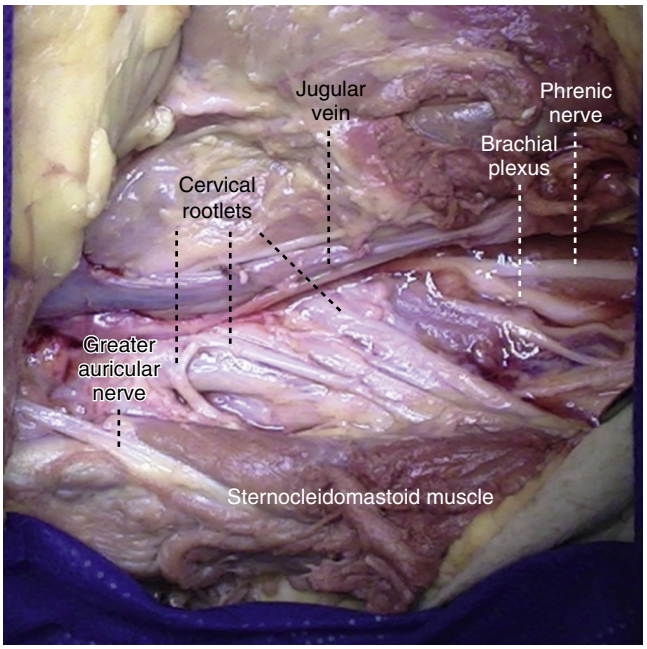

Fig. 65.5. Cadaveric specimen after right-sided dissection of levels 1 to 4 with preservation of the jugular vein with identification of the phrenic nerve and brachial plexus.

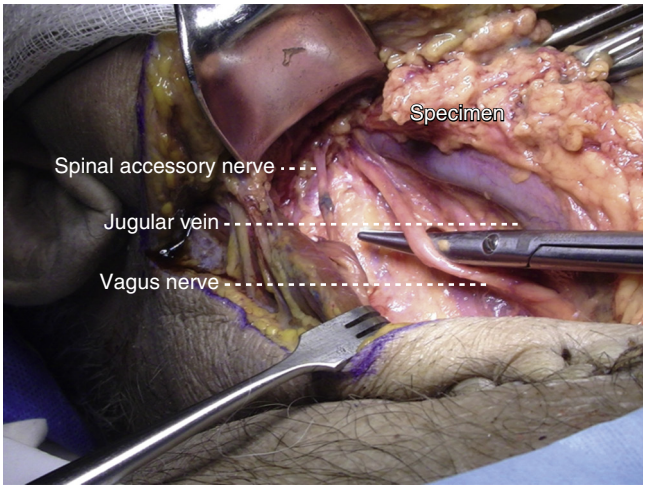

Fig. 65.6. Cadaveric specimen after right-sided dissection of levels 1 to 4 demonstrating the relationship of the jugular vein to the spinal accessory nerve and the vagus nerve.

- With continued dissection, the carotid sheath is approached posteriorly. The jugular vein should be skeletonized, carefully, 2 cm above the clavicle, clamped, and ligated, as described previously (if resection of the vein is planned). Otherwise, the fascia of the carotid sheath should be carefully dissected, anteriorly, over the jugular vein (Fig. 65.6). Small tributaries should be carefully divided with silk ties or bipolar cautery, depending on their size. Dissection continues superiorly as the ansa cervicalis and ansa hypoglossi are elevated away from the sheath and divided.
- If significant and sustained bradycardia or hypotension result during dissection around the carotid artery, it may be necessary to inject the carotid bulb with plain lidocaine. The specimen should now only be attached to the area overlying the hyoid bone, which can be dissected with ease.

Once the specimen is removed from the underlying healthy soft tissue, hemostasis should be confirmed. Finally, copious irrigation with warm saline is followed by insertion of #10 Jackson Pratt drains, to drain the surgical defect. The platysma is re-approximated with 4.0 chromic sutures, and the skin is closed with surgical staples.

Common Errors in Technique

- Failure to both tie and suture ligate the internal jugular vein stump may result in slipping of the silk tie off the vascular stump.
- If the marginal mandibular nerve is not identified during the elevation of the skin flap, it can be easily injured during subsequent dissection.

POSTOPERATIVE PERIOD

Postoperative Management

- Drain management: Drains are maintained on bulb suction, and the output is strictly monitored. After the output had decreased to 20 mL or less in an 8-hour period, the drain is removed. The quality of the drain output is monitored to ensure that there is no chyle-like fluid.
- Monitor for delirium tremens:
  - Onset 48 to 72 hours
  - Leads to increased morbidity and mortality
  - Increases length of hospital stay
- Dressing: After the Jackson Pratt drain is removed, a circumferential pressure dressing is placed and maintained for 24 hours. Circumferential dressings are avoided when a free flap is used to reconstruct the primary resection site to prevent strangulation of the vascular anastomosis.
- Staples are removed 10 to 14 days postoperatively.
- Shoulder rehabilitation is recommended.

Complications

- Chyle fistula
  - Intraoperative diagnosis: Chyle fistulas can result from inadvertent damage to chyle vessels located in the inferior aspect of the neck (level 4). Most of the time, the thoracic duct is present in the left neck but can be found on the right approximately 5% of the time. These fragile lymphatic channels are difficult to visualize and so the soft tissue dissected in level 4 should be tied to prevent a chyle leaks. If a leak is suspected intraoperatively, increase in intrathoracic pressure by the anesthesiologist can help to identify the location of the stream of clear fluid. If a lymphatic channel is identified, these vessels are so fragile that manipulating the vessel in an attempt to tie it off frequently results in more damage. And so, the soft tissue surrounding the location of the leak should be clamped or plicated and tied with a 3.0 or 4.0 silk tie. If the source is not identified, figure-of-eight sutures can be placed in the general area of the leak with good effect. Fibrin glue and/or muscle flaps have been helpful in obtaining an effective seal in these situations.
  - Postoperative diagnosis
    - A collection of milky fluid in the neck drain after the patient is fed
    - Fluid can be sent for identification of chylomicrons if the diagnosis is in question.
    - A patient's fluid and electrolyte balance must be closely monitored and maintained, especially in high volume leaks.
  - Conservative management
    - Pressure dressing
    - Medium chain fatty acid diet is frequently effective in resolving low output leaks.
    - Octreotide: a hormone that acts in a number of endocrine and paracrine pathways to reduce chyle production and has been found to be a useful adjunct in the treatment of low output leaks
    - Negative pressure wound management
      - Should be avoided if great vessels are exposed to wound vacuum
    - Total parenteral nutrition: should be considered in leaks that persist beyond 5 days or for leaks >1 L/day
  - Surgical management
    - Indications: failure of conservative measures, uncontrolled electrolyte imbalance, persistent high output fistula
    - Lymphatic duct embolization
    - Therapeutic lymphography
    - Thoracic duct ligation
    - Locoregional flaps
    - Microsurgical lymphatic-venous anastomosis
- Hematoma
  - Prevention: thorough hemostasis, blood pressure control
  - Treatment
    - Small, nonexpanding hematomas can be aspirated.
    - Expanding hematomas should be explored emergently.
- Salivary fistula: increased risk if neck dissection is completed in concert with resection of oral or pharyngeal primary
- Stroke
  - Increased risk of perioperative stroke after neck dissection (with preservation of carotid) associated with comorbidities: stroke, diabetes, hypertension
  - Incidence of stroke similar to that after thoracic surgery or colectomy
- Infection
  - Rare in isolated neck dissections
  - Risk increases with opening of the upper aerodigestive tract mucosa
- Deep vein thrombosis (DVT)
  - Cancer patients are twice as likely to develop venous thromboembolus compared with the general postoperative population.
  - Most common cause of death in postoperative period in cancer patients.
  - Prevention with early ambulation, chemoprophylaxis, and compression stockings
  - Anticoagulant prophylaxis decreases the risk of DVT but increases bleeding complications.

Alternative Management Plan

- Selective neck dissection (see Chapter 64)
- Concomitant chemoradiation for select patients
- Palliative treatment

DISCUSSION

Evidence-Based Medicine Question

Does carotid artery encasement preclude patients from undergoing a safe and effective surgical treatment of cervical metastases?

Traditionally, because of the morbidity of carotid resection and poor overall prognosis, patients with carotid artery involvement were not considered surgical candidates. However, with the evolution of vascular reconstruction techniques

and preoperative testing to identify those at risk for stroke, carotid artery resection is no longer an uncommon procedure. Kennedy recognized that patients with carotid artery involvement had a dismal prognosis and often died of local disease as opposed to distant metastases. He questioned whether resection of the carotid would result in improved survival. Since then, a number of studies have shown that carotid resection can be completed safely, frequently with saphenous vein or synthetic grafting, and with improved survival compared with untreated patients.

Editorial Comment

Modified radical neck dissection has become an increasingly uncommon operation due to evidence supporting selective and superselective dissection of nodal basins. However, it continues to be an important component of head and neck cancer surgery for indications already discussed in this chapter. Carotid artery sacrifice, although feasible, must be considered after careful consideration of pros and cons with the patient and his or her family due to the likelihood of significant complications associated with carotid artery sacrifice. The case for carotid artery sacrifice becomes stronger when the carotid artery involvement is the only reason why the patient is otherwise unresectable. If complete resection cannot be obtained, carotid artery sacrifice becomes less justifiable.

Rohan R. Walvekar


Access the review questions and additional sources list online at http://www.expertconsult.com

REFERENCES

1. Crile G. Excision of cancer of the head and neck with special reference to the plan of dissection based on one hundred and thirty-two operations. JAMA 1906;22:1780–1786.
2. Zwetyenga N, Fricain JC, Demeaux H, et al. Effectiveness of modified radical neck dissection and postoperative radiotherapy. Rev Stomatol Chir Maxillofac 2010;111(2):59–62.
3. Ferlito A, Gavilan J, Buckley JG, et al. Functional neck dissection: fact and fiction. Head Neck 2001;23:804–808.
4. Jesse RH, Ballantyne AJ, Larson D. Radical or modified neck dissection: a therapeutic dilemma. Am J Surg 1978;136(4):516–519.
5. Chen YJ1, Wang CP, Wang CC, et al. Carotid blowout in patients with head and neck cancer: associated factors and treatment outcomes. Head Neck 2015;37(2):265–272.
6. Deschler DG, Moore MG, Smith RV, editors. Quick reference guide to TNM staging of head and neck cancer and neck dissection classification. 4th ed. Alexandria, VA: American Academy of Otolaryngology–Head and Neck Surgery Foundation; 2014.
7. Lonneux M, Hamoir M, Reychler H, et al. Positron emission tomography with [18F]fluorodeoxyglucose improves staging and patient management in patients with head and neck squamous cell carcinoma: a multicenter prospective study. J Clin Oncol 2010;28:1190–1195.
8. National Comprehensive Cancer Network. NCCN clinical practice guidelines in oncology™ 2014. Head and neck cancers v 2014;2. http://www.nccn.org/professionals/physician_gls/f_guidelines.asp#headand-neck.
9. Lindberg R. Distribution of cervical lymph node metastases from squamous cell carcinoma of the upper respiratory and digestive tracts. Cancer 1972;29(6):1446–1449.
10. Subramanian S, Chiesa F, Lyubaev V, et al. The evolution of surgery in the management of neck metastases. Acta Otorhinolaryngologica Italica 2006;26(6):309–316.

REVIEW QUESTIONS

1. The borders of a modified radical neck dissection include all, except
   a. Clavicle
   b. Anterior border of the trapezius muscle
   c. Stylohyoid muscle
   d. Posterior border of the sternocleidomastoid muscle
   e. Mandible

2. The following situations are contraindications to modified radical neck dissection, except
   a. Carotid artery encasement
   b. Invasion of the deep neck muscles
   c. Invasion of the spinal accessory nerve
   d. Skull base involvement

3. A patient presents with miosis, ptosis, and anhydrosis after neck dissection. This presentation is secondary to damage to the
   a. Vagus nerve
   b. Sympathetic trunk
   c. Spinal accessory nerve
   d. Ansa cervicalis
   e. Phrenic nerve

ADDITIONAL SOURCES

Carrau RL, Byzakis J, Wagner RL, et al. Role of prophylactic antibiotics in uncontaminated neck dissections. Arch Otolaryngol Head Neck Surg 1991;117(2):194–195.

Clayburgh DR, Stott W, Cordiero T, et al. Prospective study of venous thromboembolism in patients with head and neck cancer after surgery. JAMA Otolaryngol Head Neck Surg 2013;139(11):1143–1150.

de Gier HH, Balm AJ, Bruning PF, et al. Systematic approach to the treatment of chylous leakage after neck dissection. Head Neck 1996;18(4):347–351.

Janfaza P, Nadol JB, Galla RJ, et al. Surgical Anatomy of the Head and Neck. Cambridge, MA: Harvard University Press; 2011.

Kennedy JT, Krause CJ, Loevy S. The importance of tumor attachment to the carotid artery. Arch Otolaryngol 1977;103(2):70–73.

MacNeil SD, Liu K, Garg AX, et al. A population-based study of 30-day incidence of ischemic stroke following neck dissection. Medicine (Baltimore) 2015;94(33):e1106.

Mangram AJ, Horan TC, Pearson ML, et al. Guideline for prevention of surgical site infection, 1999. Hospital Infection Control Practices Advisory Committee. Infect Control Hosp Epidemiol 1999;20(4):250–278.

McCready RA, Miller SK, Hamaker RC, et al. What is the role of carotid arterial resection in the management of advanced cervical cancer? J Vasc Surg 1989;10(3):274–280.

Muhm M, Grasl MCh, Burian M, et al. Carotid resection and reconstruction for locally advanced head and neck tumors. Acta Otolaryngol 2002;122(5):561–564.

Orgill DP, Bayer LR. Update on negative-pressure wound therapy. Plast Reconstr Surg 2011;127(suppl. 1):105S–115S.

Penel N, Lefebvre D, Fournier C, et al. Risk factors for wound infection in head and neck cancer surgery: a prospective study. Head Neck 2001;23(6):447–455.

Ramos W, Faintuch J. Nutritional management of thoracic duct fistulas: a comparative study of parenteral versus enteral nutrition. J Parenter Enteral Nutr 1986;10:519–521.

Reilly MK, Perry MO, Netterville JL, et al. Carotid artery replacement in conjunction with resection of squamous cell carcinoma of the neck: preliminary results. J Vasc Surg 1992;15(2):324–329. discussion 330.

Shuman AG, Shuman EK, Hauff SJ, et al. Preoperative topical antimicrobial decolonization in head and neck surgery. Laryngoscope 2012;122(11):2454–2460.

Wright JG, Nicholson R, Schuller DE, et al. Resection of the internal carotid artery and replacement with greater saphenous vein: a safe procedure for en bloc cancer resections with carotid involvement. J Vasc Surg 1996;23(5):775–780.

66 Radical Neck Dissection

Stephen Hernandez, Rohan R. Walvekar, Daniel W. Nuss

INTRODUCTION

The cervical lymphatics remain an important area of consideration in the evaluation of advanced cancer of the head and neck. Metastasis to cervical nodes carries negative prognostic implications, and therefore management of the neck is a critical topic of discussion. Although operative management of the neck has become more selective over time,[1] radical neck dissection (RND) still plays an important role in the management of advanced stage neck metastasis.

KEY OPERATIVE LEARNING POINTS

1. RND includes removal of the cervical lymphatics in levels I through V *in addition to* nonlymphatic structures including the sternocleidomastoid muscle (SCM), internal jugular vein (IJV), and spinal accessory nerve (cranial nerve [CN] XI) (Fig. 66.1).
2. The brachial plexus and phrenic nerves are important structures in the floor of the neck to identify and preserve.
3. It is important to clearly identify and delineate the IJV before ligating it to prevent injury to the vagus nerve (CN X) in the carotid sheath.
4. It is important to secure the inferior vascular stump of the IJV with double ligation, one of which must be a suture-ligature to prevent slippage of these surgical ties. This method is also important for ligation of the superior stump of the IJV at the skull base.
5. Identification of lymphatic vessels and control of an intraoperative lymphatic duct injury are important: right lymphatic duct in the right neck and thoracic duct in the left neck, respectively.
6. Dissection must stay superficial to the deep cervical fascia in order to prevent injury to the phrenic nerve.

PREOPERATIVE PERIOD

History

1. History of presenting illness: Patients will often present with a sizable mass in the neck. Important questions include:
   a. *Duration and rate of growth of the mass?* Rapidly growing masses or a sudden increase in the size of the neck mass may indicate an aggressive cancer that requires expedited management.
   b. *Are there any other associated factors?* Patients may also complain of dysphagia, dysphonia, otalgia, epistaxis, hemoptysis, rapid weight loss, or other symptoms that may help in identifying the site of the primary cancer.
2. Past medical history
   a. The medical history should seek to identify significant medical comorbidities that may influence or, in some cases, preclude operative management.
   b. Recognition of comorbid disease helps to identify patients who will require close observation or specialized intervention during the perioperative course. For example, those with history of deep venous thromboembolism or atrial fibrillation will require a coordinated effort to ensure appropriate perioperative management of their coagulation status.
3. Past surgical history
   a. It is important to consider whether there has been any prior operative management including fine-needle aspiration (FNA), open biopsy, or previous neck dissection. Such prior interventions may influence incision planning and the extent of resection.
   b. Any previous operative and/or pathology reports should be reviewed. When possible, discussion with the previous operating surgeon can be of tremendous value in reoperative situations.
   c. Prior history of radiation is important. Surgical incision planning to avoid three-point closures over the carotid system and carotid coverage with vascularized tissue may be considerations in radiated patients due to the high incidence of wound infection and breakdown, increasing the risk of carotid blowout.
4. Social history
   a. Alcohol and tobacco are known to be risk factors for cancer of the head and neck; addiction history (including use of illicit drugs) also helps in preparation for postoperative management. For example, chronic alcohol abuse requires very close observation and frequently involves medical management for prevention of delirium tremens and other associated sequelae of alcohol withdrawal syndrome.

Physical Examination

1. A complete examination of the head and neck including the cranial nerves and flexible fiberoptic laryngoscopy is critical in evaluating the primary cancer, residual disease, or recurrence.
2. A general examination of the patient may reveal signs of temporal wasting (indicating malnutrition), previous surgical incisions, or post-radiation skin changes.
3. All patients considered for RND should have clinically apparent lymph node metastasis. There is no indication for RND in the N0 neck. Questions to consider during examination of a neck mass should include:
   a. *Is the mass in the neck mobile?* If the mass appears firm, ill-defined, and partially fixed to underlying structures, RND is likely indicated. If the mass is well defined and mobile, the patient may be a candidate for a modified radical neck dissection (MRND) instead.
   b. *Where is the mass in the neck located*? Large, fixed, and matted nodes high in level II or low in level V may portend the need for RND, as these tend to be overlapping locations for the critical nonlymphatic structures (SCM, IJV, CN XI).
   c. *Is there involvement of the overlying dermis or skin*? If the skin is inseparable from the underlying neck mass, this may be a sign that an extended neck dissection with resection of the skin is warranted. This is important when considering design of the incision, as the resulting defect will likely require consideration of different reconstructive options.

4. Examination of the cranial nerves: Examination of the cranial nerves, particularly the lower cranial nerves (VII and IX to XII), will give an indication of the extent of the cancer, help to anticipate postoperative morbidity, and allow estimation of prognosis; the latter may impact the treatment plan.

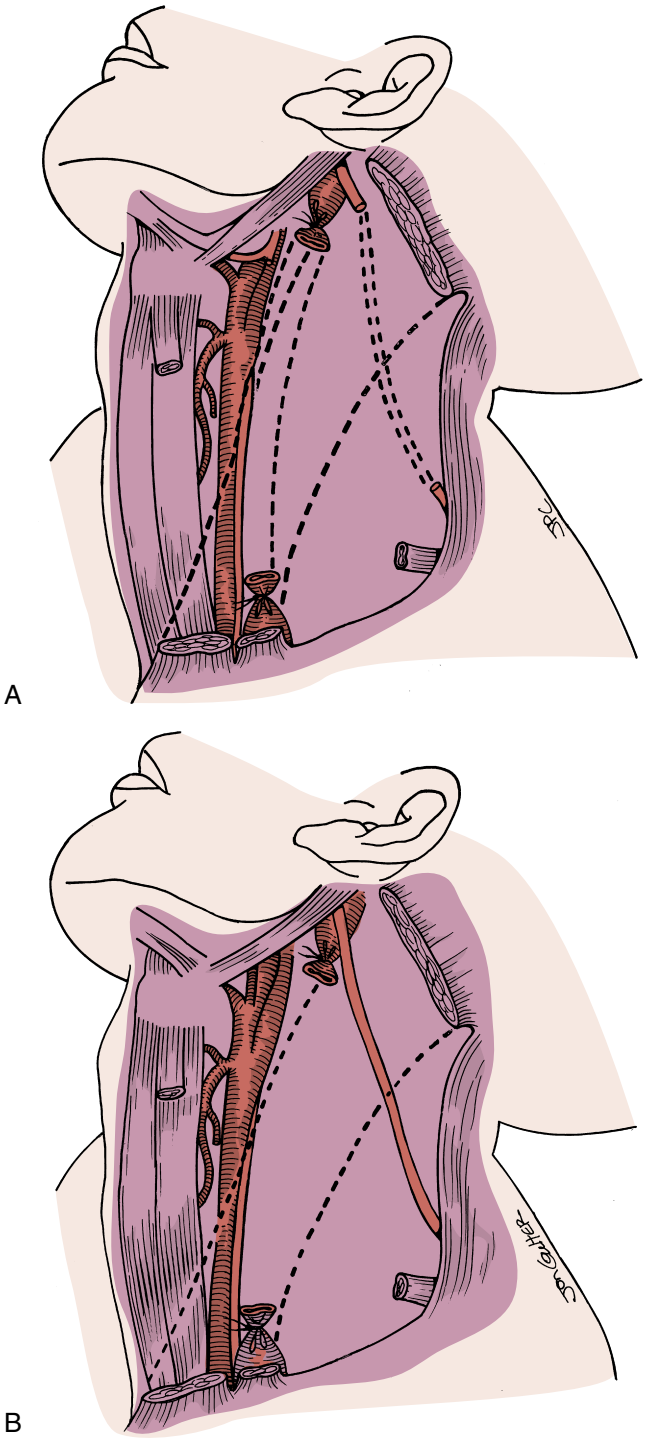

Fig. 66.1. Radical neck dissection—the sternocleidomastoid muscle, the internal jugular vein, and the 11th nerve have all been resected with the specimen; dotted lines reveal outlines of the resected structures.

Imaging

1. Contrasted computed tomography (CT) scan of the neck with and without contrast (1 mm sections)
   a. A contrasted CT scan is complementary to the physical examination and allows preoperative assessment of lymph node metastasis, levels involved, and critical information regarding proximity/involvement of major vessels, skin, and deep muscles of the neck.
   b. In these situations of advanced cancer of the head and neck, CT imaging may assist in determining the resectability of the cancer. Invasion of the prevertebral/paraspinal musculature or encasement of the carotid artery may guide the surgeon away from operative management.
2. Positron emission tomography (PET)-CT
   a. Those patients being considered for RND have advanced stage cancer. A preoperative PET-CT assists in ruling out distant metastases, as the latter would preclude operative management of the neck, unless planned only for palliation.
3. CT angiography or formal angiography
   a. Some patients who have bulky lymph node metastasis will be found to have involvement of the carotid artery. In select patients, evaluation of the carotid artery with angiography and balloon occlusion testing may assist in the preoperative evaluation if extended RND with carotid resection is being considered (see Discussion).

Indications

1. MRND and selective neck dissections (SNDs) have been validated to show similar oncologic outcomes to RND but with much less morbidity.[2] As such, the RND is not as frequently performed as it has been in the past.
2. RND is still indicated when there is bulky lymph node metastasis involving the SCM, IJV, and CN XI. These are often found in close proximity high up in level II (Fig. 66.2) or lower in the posterior triangle of the neck.
3. Rather than attempting dissection of these structures away from the cancer, it is more oncologically sound to include these nonlymphatic structures in the specimen, generally speaking.

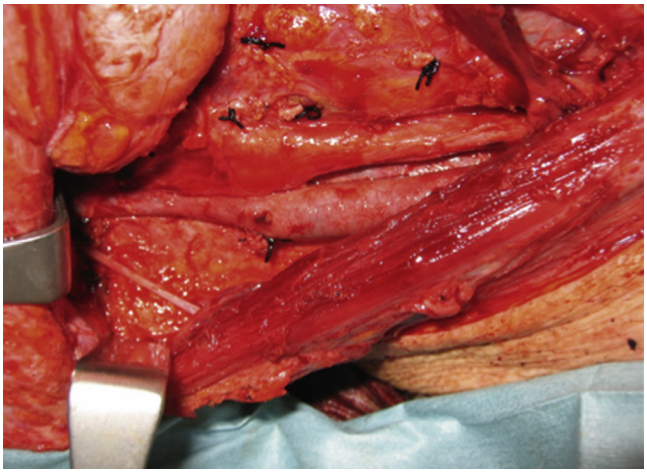

Fig. 66.2. Operative photo of right neck contents, demonstrating close association of the sternocleidomastoid muscle, internal jugular vein, and spinal accessory nerve in level II.

Contraindications

1. Invasion of the prevertebral or paraspinal musculature
2. Involvement of the brachial plexus
3. Complete encasement of the carotid artery is a relative contraindication.
   a. Studies have shown that carotid artery resection and grafting are feasible and can be considered, provided adequate collateral cerebral circulation can be gauged with preoperative balloon occlusion studies.[3]
4. Involvement of the cranial base
5. Inability to completely control the primary cancer
6. Distant metastasis

Preoperative Preparation

1. Medical comorbidities should be appropriately addressed prior to consideration for surgery. Those patients with significant cardiopulmonary issues should be evaluated by the anesthesiologist and undergo a comprehensive medical evaluation for clearance.
2. Patients may also be severely malnourished, and when possible, the nutritional status should be optimized prior to surgery.
3. Informed consent and patient understanding are critical. Specifically, patients should comprehend the morbidity of facial lymphedema as well as shoulder dysfunction and associated pain (Fig. 66.3), which may require intensive postoperative physical therapy.

OPERATIVE PERIOD

Anesthesia

1. General anesthesia
2. Paralytic agents are generally avoided so that motor nerves can be stimulated and monitored.
   a. The marginal mandibular nerve should be identified and protected after elevating the subplatysmal skin flaps. Avoiding paralysis can help with identification, allowing use of the handheld nerve stimulator. Identification of CN XI can also be facilitated, especially in the posterior triangle of the neck.



Fig. 66.3. A patient with "shoulder syndrome" resulting from 11th nerve sacrifice.

Positioning

1. The operating table is turned 180 degrees from anesthesia.
   a. This facilitates adequate positioning for retraction by assistants around the head of the table.
   b. This position also moves the anesthesia circuit to the foot-end of the patient, permitting adequate working space for the surgeons around the head and neck region.
2. A shoulder roll is placed to allow for appropriate neck extension.
3. The arms are tucked, and the chest should be included in the prep field in the event that a pectoralis major flap is required.

Perioperative Antibiotic Prophylaxis

1. A first-generation cephalosporin is generally used for RND.
2. If RND is being performed in conjunction with resection of the primary cancer in which mucosal spaces will be exposed, the perioperative antibiotic regimen may change accordingly.

Monitoring

1. An arterial line is generally placed while positioning the patient. In addition, for prolonged cases, central venous access may be required.
2. Nerve monitoring systems are not routinely used. However, as noted, paralytic agents are avoided and the handheld nerve stimulator can be used if needed.

Instruments and Equipment to Have Available

1. A basic head and neck set
2. Monopolar and bipolar electrocautery
3. Harmonic focus (Ethicon)
4. A handheld nerve stimulator
5. Vessel loops

Key Anatomic Landmarks

1. The marginal mandibular nerve
   a. This should be identified and dissected free to be retracted with the elevated subplatysmal flap along with the posterior facial vein and facial artery, protecting the nerve from injury (Hayes-Martin maneuver) (Fig. 66.4).
2. The posterior belly of the digastric muscle
   a. Many critical structures are deep to the digastric muscle, so it can be an important landmark, especially in a field with distorted anatomy.
   b. Dissection of the posterior belly may sometimes facilitate identification of the hypoglossal nerve.
   c. A safe dissection can be created over the posterior belly of the digastric ("digastric tunnel"). The only structure to identify and ligate is the retromandibular vein while dissecting over the posterior belly of the digastric muscle.
3. CN XI
   a. Should be identified in "unwrapping" the SCM, although this may be difficult if RND is being done for bulky metastasis high in level II

4. The lateral process of C2
   a. This is a consistent and palpable landmark for identifying the junction of the spinal accessory nerve where it crosses the IJV just below the skull base. The superior end of the IJV lies just anterior to the lateral process of C2.
5. The omohyoid muscle
   a. The contents of the carotid sheath can be found just deep to the omohyoid muscle lower in the neck. (This is similar to the relationship of the digastric muscle to the sheath in the upper neck.)
6. The phrenic nerve
   a. This should always be identified, lying on the superficial aspect of the anterior scalene muscle. It is an important landmark, especially when bringing the specimen anteriorly. Keeping the nerve in view and staying superficial to the deep cervical fascia will prevent injury to the nerve.

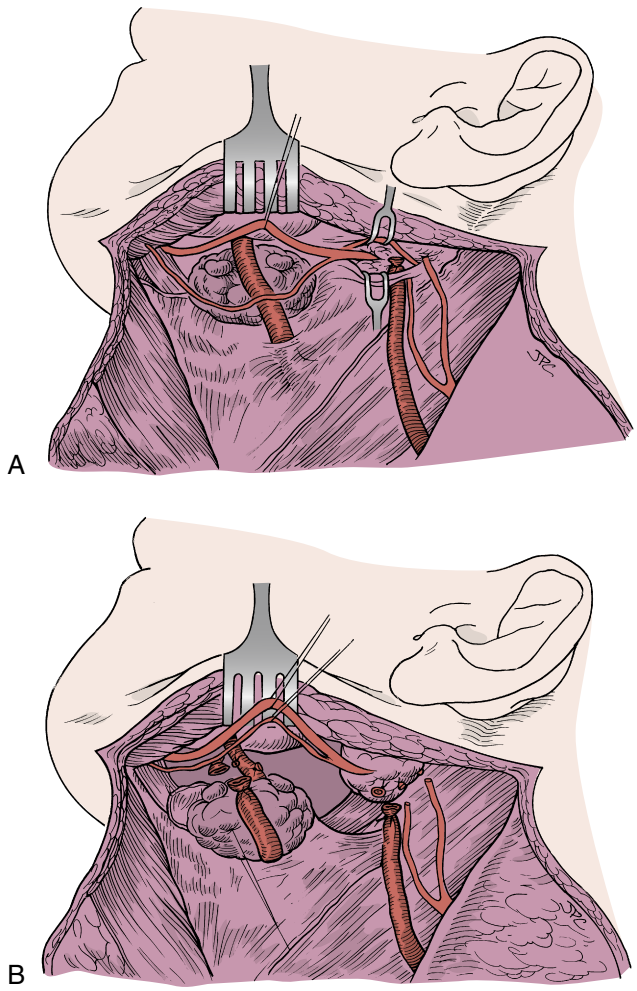

Fig. 66.4. Dissection of the marginal mandibular nerve from the submandibular gland posteriorly in order to preserve the nerve. **A,** Marginal mandibular nerve, emerging from the tail of the parotid gland, passes across the inferior border of the submandibular gland. **B,** Marginal mandibular nerve dissected free of the submandibular gland and elevated along with subplatysmal skin flap. Facial artery and vein have been ligated and divided. Note that all branches of the great auricular nerve have been divided in this illustration. In practice, the posterior branch can usually be preserved.

Prerequisite Skills

1. Techniques from previous chapters discussing selective neck dissection and modified radical neck dissection also apply here.
2. Open head and neck surgery skills

Operative Risks

1. Infection
2. Injury to the marginal mandibular nerve
3. CN XI injury
4. Injury to the phrenic nerve
5. Injury to the brachial plexus
6. Carotid artery rupture
7. Injury to the vagus nerve
8. Chylous fistula
9. Air embolism
10. Hemorrhage

Surgical Technique

1. Surface landmarks should be identified and marked out.
   a. We delineate and mark out the mastoid tip, the angle of the mandible, suprasternal notch, and the cricoid cartilage.
2. Incision is planned. We use an extended "hockey stick" incision or half-apron incision for unilateral neck dissection, designed from the mastoid tip and extending to a skin crease in the lower neck (Fig. 66.5).
   a. If bilateral neck dissections are planned, the incision carries over to the opposite mastoid tip (an "apron" incision).
3. Subplatysmal flaps are elevated to define the boundaries of the neck dissection.
   a. Superior boundary: inferior border of the mandible that extends to a line joining the angle of the mandible to the mastoid tip
   b. Anterior boundary: superior belly of the omohyoid and anterior belly of the digastric muscle
   c. Inferior boundary: suprasternal notch and clavicle
   d. Posterior boundary: anterior border of the trapezius
      1) Initially, the great auricular nerve and external jugular vein are identified and protected unless involved by cancer, in which case they may be sacrificed.
4. The marginal mandibular nerve should then be identified (Fig. 66.4).



Fig. 66.5. Operative photo of "hockey stick" incision used for unilateral radical or elective neck dissection.

a. Its course can be quite variable, but generally blunt dissection starts about 1 cm below the antegonial notch near the point where it exits the parotid gland. Identification can be assisted with the use of magnifying loupes and the handheld nerve stimulator.
b. Once located, it should be dissected anteriorly and posteriorly, freeing it from the submandibular fascia to allow for retraction with the superior subplatysmal flap that was elevated.
c. Multiple branches may be identified, and they should all be preserved if possible.
d. The Hayes-Martin maneuver involves identifying the facial artery and vein below the course of the marginal mandibular nerve, ligating these vessels and reflecting them superiorly with the subplatysmal flaps, in effect, preserving the marginal mandibular nerve.

5. Level 1 neck dissection
a. With the marginal mandibular nerve safely elevated, the fascia deep to it is incised and the anterior belly of the digastric muscle is identified. The submental adipose tissue and nodes are grasped and dissection is carried inferiorly along the anterior belly of the digastric muscle.
b. As the dissection continues, the mylohyoid muscle will come into view. The mylohyoid muscle is dissected and the free edge exposed posteriorly, then retracted with an Army-Navy retractor. Care must be taken to identify and cauterize the submental branches of the facial vessels. The edge of the mylohyoid muscle is delineated in its entirety and then retracted anteriorly. The submandibular gland is retracted posteriorly and inferiorly. This maneuver helps to identify the lingual nerve, the submandibular ganglion, and the submandibular duct (Fig. 66.6).
c. The submandibular duct and submandibular ganglion are then clamped and ligated, bringing the contents of submandibular triangle (level Ib) along with the specimen.
d. The facial artery and vein are ligated at the level of the posterior belly of the digastric and the submandibular gland with level 1b contents delivered.

6. Dissection is then continued over the digastric tunnel. The retromandibular vein is ligated, and this dissection often involves resecting the lower-most portion of the tail of the parotid gland. In this maneuver, the marginal branch of CN VII is again protected. The gland is suture ligated with a silk tie to promote fibrosis and prevent salivary leak and sialocele formation.

7. Level II dissection
a. The digastric muscle is retracted superiorly and CN XI is identified and traced to its point of entry into the SCM (assuming it is not encased in tumor at this level).
b. The superior aspect of the IJV is isolated.
c. The hypoglossal nerve is identified and preserved. Attention is then directed to the inferior border of the neck dissection.

8. Dividing the inferior attachments of the SCM (Fig. 66.7)
a. The sternal and clavicular heads of the SCM are divided approximately 1 cm above the clavicle.
b. The proximal end of the muscle is then retracted superiorly, and the omohyoid muscle can be seen. This is an important landmark, as it is just anterior to the contents of the carotid sheath.
c. The omohyoid is divided and traced toward the midline, marking the anterior limit of the neck dissection.

9. Level IV dissection
a. Blunt dissection in level IV should be performed until the phrenic nerve and brachial plexus are identified. The phrenic nerve is located on the anterior surface of the anterior scalene muscle. The brachial plexus is located between the anterior and middle scalene muscles.
b. With the phrenic nerve in view, the surgeon can then clamp and ligate the contents of the supraclavicular adipose tissue pad, retracting it superiorly as part of the specimen.
c. Care must be taken to clamp and ligate the contents of level IV to avoid damage to the thoracic duct on the left and right lymphatic duct on the right side of the neck.
d. The lower end of the IJV is identified and secured. It is dissected free from the common carotid artery and clearly defined from the vagus nerve.

10. Level V exposure
a. The dissection is continued posterior-lateral to the SCM, releasing the contents of the supraclavicular fossa, defining the transverse cervical vessels and brachial plexus. Working from the critical structures identified in level IV, the dissection is carried posteriorly until the anterior border of the trapezius muscle is identified.

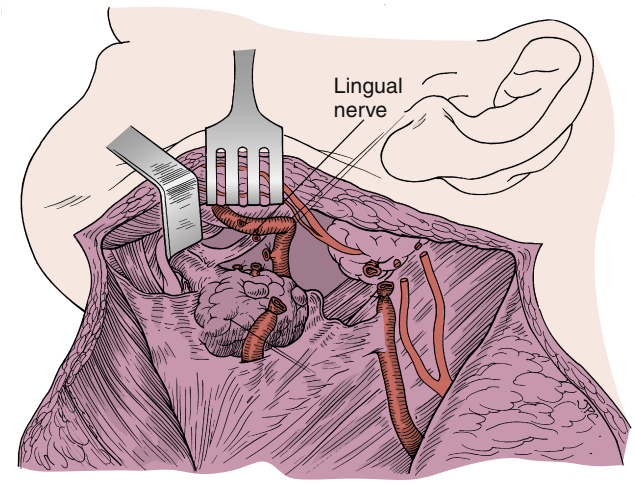

Fig. 66.6. Retraction of the mylohyoid muscle to expose the lingual nerve, submandibular ganglion, and Wharton's duct.

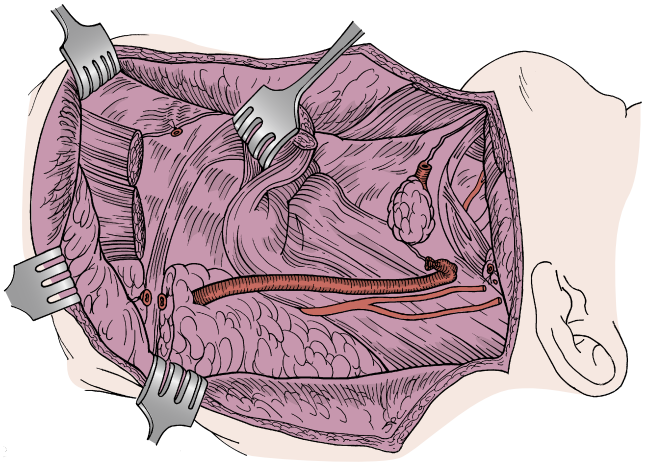

Fig. 66.7. Dividing the clavicular head of the sternocleidomastoid muscle and supraclavicular tissue lateral to the omohyoid muscle. The brachial plexus, carotid sheath, and phrenic nerve are protected by their deep position to this muscle.

b. The anterior border is dissected superiorly toward the skull base.
c. The spinal accessory nerve is usually encountered in level V. It is sacrificed here and brought anteriorly with the specimen.

11. Dividing the superior attachments of the SCM
    a. The SCM is then divided just inferior to the mastoid tip, and the dissection carries down to the fascia overlying the deep musculature of the neck.
    b. The SCM is now free both superiorly and inferiorly. With the anterior border of the trapezius delineated, the dissection (of fibroadipose and lymph-node bearing soft tissues) now carries anteriorly, taking care to leave some fascia on the deep neck musculature, thus sparing as much as possible of the cervical plexus.
    c. The dissection continues, and the nerves of the cervical plexus are divided from the specimen high in the neck. The phrenic nerve should always be kept in view during this stage to avoid inadvertent injury (Fig. 66.8).
12. Dividing the IJV
    a. As the specimen is reflected anteriorly, the carotid sheath will be encountered.
    b. The isolated IJV is now ligated and included within the specimen. This is first done inferiorly in level IV. The IJV should be clearly delineated, and the vagus nerve should also be identified to avoid iatrogenic injury.
    c. The IJV is then doubly clamped and suture ligated. With the critical anatomic structures under direct visualization, the lymphatic pedicle can now be clamped and ligated, freeing the inferior portion of the specimen.
    d. Dissection is now brought superiorly along the carotid sheath. The posterior belly of the digastric muscle is retracted superiorly and the IJV isolated in level II. The spinal accessory nerve is sacrificed here, and the IJV is then again doubly clamped and suture ligated. Branches of the IJV including the common facial, lingual, and superior thyroid, which are variable in size and location, must also be ligated at this step.
        1) In difficult cases with large cancers, the lateral process of C2 is a consistent palpable landmark for identification of the IJV and the accessory nerve at its junction with the IJV.
13. Bringing the specimen anteriorly to the midline
    a. Now free superiorly and inferiorly, the specimen is connected to the previous level I dissection and brought to the midline with the lateral border of the strap muscles being the anterior limit. The specimen is removed.

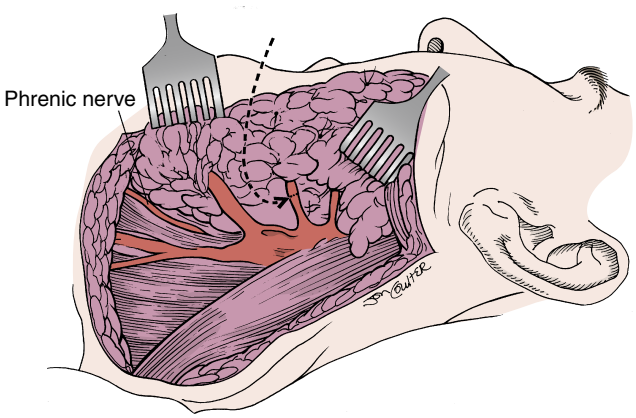

Fig. 66.8. Exposure of the cervical nerves (shown here in red) as they leave the cervical plexus. Care must be taken to avoid stripping the cervical plexus off the deep muscles.

14. The neck is then copiously irrigated and the Valsalva maneuver is performed to check for hemostasis and/or any evidence of chyle leak.
15. After hemostasis is achieved, suction drains are placed in the wound. The platysma is re-approximated, and the skin incision is closed with staples.

Common Errors in Technique

1. Inadequate identification of the marginal mandibular nerve
2. Failure to isolate and control the IJV or its branches
3. Failure to adequately ligate the lymphatic pedicle
4. Failure to identify the phrenic nerve and brachial plexus

POSTOPERATIVE PERIOD

Postoperative Management

1. Patients should be admitted to a monitored unit following RND.
2. Perioperative antibiotics should continue for 24 to 48 hours.
3. Drains are maintained on suction with accurate recordings.
4. Physical therapy should be initiated early in the postoperative period to address shoulder dysfunction and minimize pain.

Complications

1. Infection
    a. Perioperative antibiotics reduce the risk of infection and should be continued for 24 to 48 hours postoperatively. There is a greater risk of infection when the upper aerodigestive tract is involved in the surgical field.
    b. Postoperative wound infections may manifest as erythema, edema, or purulent drainage from the suction drains.
    c. Broad-spectrum antibiotics should be initiated and cultures sent. Antibiotics can be narrowed down following isolation and appropriate sensitivities.
    d. If there is no improvement with medical management, the neck may require exploration and drainage of an abscess in the operating room.
2. Hematoma
    a. Most commonly occurs due to inadequate hemostasis intraoperatively
    b. Hematomas should be managed in the operating room with re-exploration, irrigation, and identification of the underlying bleeding vessel. Often, no definite vessel is found, but it is still important to evacuate an expanding hematoma and replace the drains, as they may now be clotted off and are no longer useful.
3. Marginal mandibular nerve injury
    a. An injury to the marginal branch may not be noticed until the postoperative period. Some of the asymmetry may be related to a neuropraxic injury from retraction or even weakness from the plastysmal contribution to the lower lip.
    b. Most patients have no issues with oral competency, and it can be managed expectantly in the immediate postoperative period.
4. Phrenic nerve injury
    a. It is important to always keep the phrenic nerve in view during the dissection.
    b. Unilateral phrenic nerve injury is tolerated by most patients, but for some patients with underlying pulmonary disease it can be problematic.

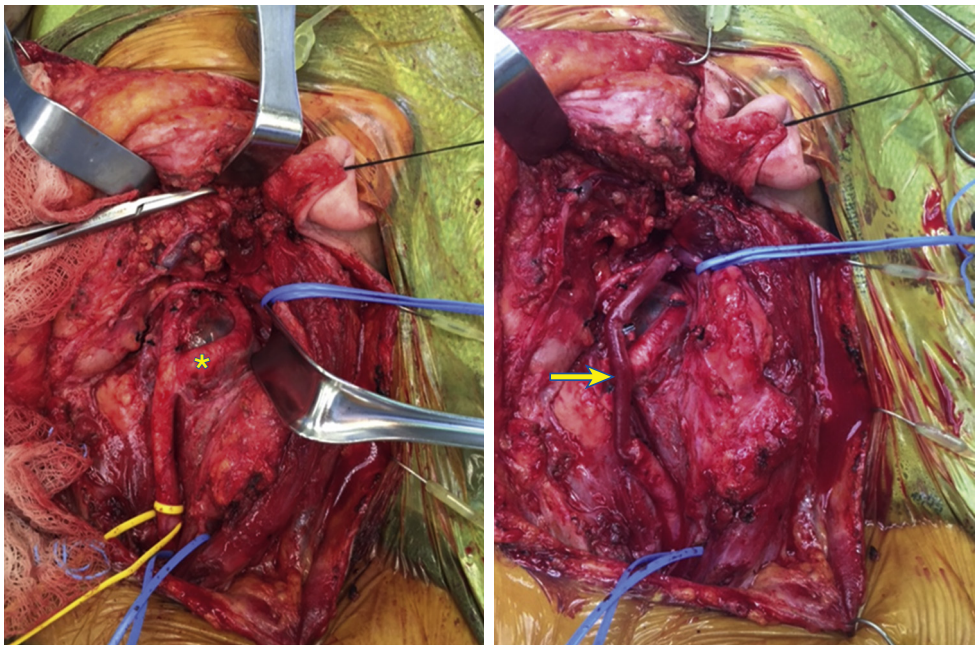

Fig. 66.9. Extended neck dissection with sacrifice of the common and internal carotid artery with saphenous vein interposition grafting. *Left:* Star shows the internal carotid artery involved with cancer just distal to the bifurcation. *Right:* Arrow demonstrates the saphenous vein interposition graft from the common to the internal carotid artery.

5. Brachial plexus injury
   a. Injury to the brachial plexus can be avoided by careful dissection and identification in level IV.
   b. The physical therapy team should be involved early if there are findings of brachial plexopathy.
6. Chylous fistula
   a. The lymphatic pedicle is clamped and ligated during the RND. Most chyle leaks are recognized intraoperatively; however, there can still be problems that manifest during the postoperative course.
   b. Low output fistulas can be managed conservatively with a medium chain triglyceride diet, pressure dressing, and medical management.
   c. For higher output fistulas or those that are not responding to conservative management, surgical re-exploration may be required.

Alternative Management Plan

1. MRND
   a. There may be some instances where RND is anticipated, but operative findings may determine that RND is not required.
   b. During the initial portions of the procedure, there should be an attempt to determine the status of the SCM and spinal accessory nerve.
   c. Occasionally, one or more of the nonlymphatic structures can be preserved, significantly reducing morbidity without necessarily compromising outcome (Fig. 66.8).
2. Extended neck dissection
   a. With these advanced cancers of the head and neck, there may be an occasion where other structures should be included in the specimen for oncologic reasons.
   b. This may include other nodal groups (e.g., paratracheal, suboccipital, or mediastinal nodes) or other nonlymphatic structures such as overlying skin, muscle (digastric muscle, levator scapulae muscle), or cranial nerves (hypoglossal nerve, vagus nerve). This is classified as an extended neck dissection.
3. Nonoperative management
   a. A clinical and radiographic preoperative evaluation should be completed to determine resectability of the primary cancer and regional lymph node metastasis. With rare exceptions, RND should not be performed in those instances where there is involvement of the cranial base, the deep neck musculature/prevertebral fascia, encasement of the carotid artery, or evidence of distant metastasis.
   b. Additionally, there may be some patients who cannot tolerate the surgery or perhaps do not want to proceed with surgery. It is important to provide specific and detailed informed consent while respecting the patient's wishes.

DISCUSSION

Evidence-Based Medicine Question

Is there a role for surgical management of the neck with advanced stage cancer when there is radiographic evidence of carotid artery involvement?

Historically, involvement of the carotid artery has been a contraindication to surgical management of cervical lymph node metastasis. With initial complications and stroke rates greater than 50%, the morbidity and mortality of such intervention did not outweigh any potential benefits. With the advent of advanced imaging and new testing, there have been recent attempts to identify those patients who may tolerate carotid resection or ligation.[4] Angiography and temporary balloon-occlusion testing have now become standard in the evaluation of those patients who are being considered for extended RND with resection and reconstruction of the common or internal carotid artery. Freeman et al. reviewed a series of 58 patients who underwent either ligation or carotid resection with saphenous vein interposition grafting (Fig. 66.9).[5] Cerebrovascular accident (CVA) was found to occur in 20% of patients; however, disease-specific and disease-free median survival were found to be only 12 months. Furthermore, 24%

of patients were found to ultimately have distant metastases. There are other retrospective studies to suggest an impact on survival in those patients with involvement of the carotid artery.[6] However, the data remain limited with regard to this topic, and it is still a difficult avenue of discussion with patients and their caregivers. The current standard is to perform preoperative balloon-occlusion testing to assess for patient tolerance and acceptable collateral cerebral perfusion. For those patients with reasonable collateral flow, surgery may be offered with the patient having reasonable expectations and understanding the risk of CVA and potential mortality even in the presence of a normal balloon occlusion test.

Editorial Comment

Metastasis to the cervical lymph nodes is a documented indicator of poor prognosis for patients with head and neck cancer. The appropriate management of the neck is vital to outcomes, quality of life, and palliation. Although RND has lost favor in the recent years due to increasing evidence of oncologic safety and viability of more functional forms of neck dissection, it still has an important place in the management of advanced neck disease and surgical palliation. The changing paradigm from primarily surgical management of head and neck cancer to nonsurgical approaches has brought on its own set of challenges, that is, operating in radiated fields with a high incidence of complications and equally important wound breakdown and infection that may lead to life-threatening complications such as carotid artery rupture. Head and neck surgeons have to be cognizant of these challenges and be prepared to reconstruct the neck when indicated. A thorough knowledge of rotational flaps such as the pectoralis major myocutaneous flap or levator flaps can be instrumental in providing robust and efficient options for carotid artery cover. RND is the foundation of all forms of neck dissection; every practicing head and neck surgeon must be competent in performing this procedure.

Rohan R. Walvekar

Access the review questions online at http://www.expertconsult.com

REFERENCES

1. Shah JP. Patterns of cervical lymph node metastasis from squamous carcinomas of the upper aerodigestive tract. Am J Surg 1990;160:405–409.
2. Davidson J, Khan Y, Gibert R, et al. Is selective neck dissection sufficient treatment for the N0/Np+ neck? J Otolaryngol 1997;26:229–231.
3. Chung EJ, Kwon KH, Yoon DY, et al. Clinical outcome analysis of 47 patients with advanced head and neck cancer with preoperative suspicion of carotid artery invasion. Head Neck 2016;38(suppl 1): E287–E292.
4. De Vries EJ, Sekhar LN, Hortan JA, et al. A new method to predict safe resection of the internal carotid artery. Laryngoscope 1990;100:85–88.
5. Freeman SB, Hamaker RC, Borrowdale RB, et al. Management of neck metastasis with carotid artery involvement. Laryngoscope 2004;114:20–24.
6. Manzoor NF, Russel JO, Bricker A, et al. Impact of surgical resection on survival in patients with advanced head and neck cancer involving the carotid artery. JAMA Otolaryngol Head Neck Surg 2013;139:1219–1225.

REVIEW QUESTIONS

1. A radical neck dissection (RND) involves removal of the sternocleidomastoid muscle (SCM), internal jugular vein (IJV), and cranial nerve (CN) XI along with which nodal levels?
   a. Levels II to IV
   b. Levels II to V
   c. Levels I to V
   d. Levels I to IV

2. Which of the following is not a contraindication to RND?
   a. Skull base involvement
   b. Skin involvement
   c. Distant metastasis
   d. Brachial plexus involvement

3. Which structure is at risk if not appropriately identified before ligating the lymphatic pedicle?
   a. The phrenic nerve
   b. The cervical plexus
   c. The internal carotid artery
   d. The vagus nerve

67 Central Compartment Neck Dissection

Cherine H. Kim, Alfred Simental Jr.

INTRODUCTION

The central compartment contains the first nodal basin for cancer originating in the thyroid and parathyroid and can be involved in cancers of the laryngotracheal complex. This space encompasses the prelaryngeal, pretracheal, and paratracheal lymph nodes, also known as the level VI lymph nodes, although superior mediastinal nodes and retro-esophageal nodes are often included and represent level VII. In cases of squamous cell cancer involving the central compartment viscera or parathyroid carcinoma, comprehensive central compartment lymph node dissection is routinely employed, often in combination with ipsilateral thyroidectomy. However, the central compartment lymph nodes are most commonly affected by the regional spread of thyroid cancers. Well-differentiated thyroid cancer (WDTC) will prove to have metastases in the central compartment in 20% to 50% of cases.[1] In these cases, central compartment neck dissection is unquestionably indicated, given the strong relationship between loco-regional control and treatment of clinically positive central compartment disease. Subclinical micrometastases have been shown to be present in up to 90% of cases of thyroid cancer,[1] presumably with less defined clinical significance when compared with macrometastases. There has been no survival benefit associated with prophylactic treatment of the central neck, with equivocal data on local control.[2] Patients with known metastasis in the central compartment are more likely to experience recurrence than their counterparts. Prophylactic central compartment dissection with total thyroidectomy has shown increased rates of postoperative hypocalcemia when compared with total thyroidectomy alone. However, the use of prophylactic central compartment neck dissection results in improved local control and decreases the potential risk of morbidity of reoperative surgery. Additionally, the pathologic assessment of the central compartment lymph nodes may help in risk stratification for additional adjuvant treatment such as radioactive iodine (RAI).

The literature fails to offer definitive evidence advocating prophylactic treatment of the central compartment in the management of well-differentiated thyroid cancer (WDTC). The role of prophylactic central compartment neck dissection remains controversial, largely due to the lack of a large randomized prospective trial—the feasibility of which is questionable given the prohibitively large sample size it would require.[3] Ultimately, comprehensive preoperative evaluation and appropriate risk assessment and anatomic knowledge are imperative for successful surgical treatment of the central neck. The presence of medullary thyroid carcinoma, with or without evidence of nodal involvement, is an indication for dissection of the lymph nodes in the central compartment.[4]

KEY OPERATIVE LEARNING POINTS

1. Central compartment dissection is often a reoperative surgery and may require a different surgical strategy (lateral to medial).
2. Identification and continued observation of the recurrent laryngeal nerve (RLN) is the best way to avoid injury to the nerve.
3. Identify and lateralize the superior parathyroid glands with their blood supply.
4. A low threshold for auto-transplantation of inferior parathyroid glands after pathologic verification
5. Complications are more common with paratracheal dissection, especially hypocalcemia, vocal fold paralysis, and injury to the esophagus.

PREOPERATIVE PERIOD

History

1. History of present illness
   a. Determine if this is primary or secondary disease. Central compartment dissection is often employed in the case of a loco-regional recurrence of thyroid cancer.
      1) Obtain operative and pathology reports from previous surgeries.
   b. Evaluate for pre-existing morbidity.
      1) chronic obstructive pulmonary disease (COPD) or cardiovascular disease
      2) History of gastric bypass or gastrointestinal absorption abnormality
         a) May require calcium challenge if parathyroid hormone (PTH) is elevated to ensure gastric absorption
   c. Invasive symptoms: hemoptysis, skin fixation, or voice changes from vocal cord paralysis
      1) Fiberoptic laryngoscopy
      2) Advanced imaging
2. Risk factors for severe morbidity
   a. Pre-existing vocal fold paralysis
      1) Contralateral deficit may result in tracheostomy
   b. History of previous neck surgery or radiation
   c. Hemoptysis or cough
      1) May signify invasive component
      2) Require cross-sectional imaging
3. Past medical history
   a. Well-differentiated thyroid cancer (WDTC)
   b. Medullary thyroid carcinoma, multiple endocrine neoplasia (MEN)

Physical Examination

1. Complete examination of the head and neck
   a. Palpate thyroid bed and paratracheal regions.
      1) Note location of masses with, relation to swallowing, fixation to skin, or underlying structures.
   b. Palpate lateral neck for lymphadenopathy.
   c. Listen for hoarseness, stridor.
   d. Determine location of native anatomy.
      1) Low-lying larynx/cricoid
2. Direct or indirect laryngoscopy
   a. Essential in detecting vocal cord paralysis
   b. The voice may be normal despite a paralyzed vocal cord.

Diagnostic Studies

Laboratory Studies

1. Thyroid stimulating hormone (TSH)
   a. Verify that the patient is euthyroid.
2. Thyroglobulin (Tg)/thyroglobulin antibody (Tg Ab)

   a. Determine relative burden of disease, especially in reoperative cases.
3. Calcitonin
   a. Patient with a family history of medullary thyroid carcinoma or MEN-2, or biopsy shows medullary thyroid carcinoma
4. Parathyroid hormone

Imaging

1. High-resolution ultrasound (US)
   a. Microcalcifications are associated with markedly increased risk of malignancy, while cystic and spongiform appearance may be associated with benign lesions.
   b. Low-cost, no radiation, and reliable when performed by experienced clinicians
   c. Low sensitivity of detecting lymphadenopathy in the central neck due to shadowing effect of the thyroid gland
2. Computed tomography (CT) and magnetic resonance imaging (MRI)
   a. Helpful for:
      1) Substernal extension
      2) Cervical and mediastinal lymphadenopathy
      3) Invasion of surrounding structures such as trachea and esophagus
      4) Metastasis to distant sites
   b. High sensitivity and specificity in detecting cervical lymphadenopathy, and less operator dependence, offers visualization of adjacent structures
   c. Expensive, radiation exposure, and use of iodinated contrast may preclude the use of RAI for 1 to 3 months
3. Radionuclide scanning
   a. Useful for rising Tg with negative imaging
4. positron emission topography (PET) imaging
   a. Useful for RAI negative, Tg positive patients

Fine-Needle Aspiration

1. Essential for reoperative surgery
   a. Minimally invasive, safe, and cost-effective
   b. Sensitivity 65% to 98%, specificity 72% to 100%
   c. US guidance increases accuracy and success of fine needle aspiration (FNA).
2. Suspicious cervical lymph nodes or masses should undergo FNA.
3. When multiple nodules are present, the largest and/or most sonographically suspicious should be biopsied preferentially.
   a. Multiple nodules may need to be biopsied to increase diagnostic yield.
   b. Biopsies should direct surgical planning.

Molecular Biomarkers

1. Newer studies introduced to increase accuracy of FNA and better characterize the risk of malignancy, especially in indeterminate cytology, Atypia of Undetermined Significance (AUS), and Follicular Lesion of Undetermined Significance (FLUS). These markers may:
   a. Reduce unnecessary surgery for benign lesions
   b. Reduce completion thyroidectomy by guiding initial use of total thyroidectomy
   c. Provide prognostic information such as:
2. BRAF, RAS, TIMP1, RET/PTC, Pax8-PPARγ, galectin-3, cytokeratin, microRNA, gene sequencing
3. Uncertain evidence regarding efficacy and utility

Indications

1. Differentiated thyroid cancer
   a. Initial surgery
      1) BRAF positive disease
      2) Gross extrathyroidal extension
      3) Presence of suspicious paratracheal lymph node (LN)
         a) Microcalcifications
      4) Initial presentation of well-differentiated thyroid carcinoma (WDTC) with lateral neck metastasis
   b. Contralateral thyroid nodule or distant metastasis
   c. Multinodular goiter with radiation exposure to the head and neck
   d. First-degree family members with thyroid cancer
2. Medullary thyroid carcinoma
   a. May require concomitant lateral neck dissection
3. Parathyroid cancer
   a. Ipsilateral thyroid lobectomy

Contraindications

Relative Contraindication

1. Uncontrolled medical disease
2. Pregnancy
   a. May elect to postpone until postpartum
   b. If substantial growth, surgery may be performed in second trimester to reduce risk of miscarriage.
3. Significant distant metastasis unresponsive to suppression
4. Contralateral vocal fold paralysis

Absolute Contraindications

1. Unresectable mediastinal disease
2. Intracranial metastasis

Preoperative Preparation

1. Screen for comorbidities.
2. Document vocal cord movement with indirect laryngoscopy prior to surgery.
3. Ensure euthyroid state.
4. Accurately map disease and surgical plan.

OPERATIVE PERIOD

Anesthesia

1. General anesthesia with endotracheal intubation

Positioning

1. Supine
   a. Shoulder roll to extend neck slightly and elevate laryngeal framework
   b. Head placed in a donut to prevent rotation
2. The bed can be shifted away or rotated 180 degrees from anesthesia to provide more surgical space.
3. The back and head may be elevated 10 to 30 degrees to reduce venous congestion.
4. Prepare neck and upper chest with povidone-iodine or chlorhexidine (entire chest if sternotomy anticipated).
5. Arms tucked at the side with padding of elbows and heels
6. Protect face and eyes.

Perioperative Antibiotic Prophylaxis

1. Perioperative antibiotics are not necessary in clean thyroid surgery.
   a. A single preincision intravenous dosing of antibiotic is administered.
      1) Cefazolin or clindamycin

Monitoring

1. Intraoperative laryngeal nerve monitoring (IONM) may be used.
   a. Endotracheal tube with surface electrodes placed at the level of the vocal cords
   b. Likely greater utility in reoperative setting than primary setting
   c. Increased cost and setup time
   d. Useful adjunct for identification of recurrent nerve, which may result in decreased operative time and surgeon comfort

Instruments and Equipment to Have Available

1. Basic head and neck set
2. Monopolar and bipolar cautery
   a. Consider advanced energy such as ultrasonic technology if a thyroidectomy is planned.
   b. Surgical clips should be available in room (unopened).
3. Mahorner, Lone Star, or Weitlander self-retaining retractors may be helpful if an assistant is not available.
4. Kittner/peanut sponges are helpful for blunt dissection, retracting, and protecting nerves or parathyroid tissue from the heat of electrocautery or ultrasonic technology.
5. Babcock forceps are helpful in grasping and retracting thyroid tissue.
6. McCabe dissector
   a. Has curved, precise, nonlocking tips
   b. Excellent for identifying and dissecting out the nerves

Key Anatomic Landmarks

1. Trachea/cervical spine
2. Vasculature[5]
   a. Arterial
      1) Superior thyroid artery: first branch of the external carotid artery (branch of the common carotid in 16%)
      2) Inferior thyroid artery: branch of the thyro-cervical trunk
      3) Thyroidea ima artery (in thyrothymic adipose tissue)
         a) Branch of the innominate, subclavian, or right common carotid, internal thoracic arteries, or aortic arch
         b) Supplies thyroid isthmus inferiorly
         c) Present in 2% to 12% of cases
      4) Carotid artery system
         a) Lateral border of central compartment
      5) Innominate artery
         a) Inferior extent of dissection
         b) Right common carotid artery may branch early
   b. Venous
      1) Innominate vein inferiorly
      2) Internal jugular system
         a) Lateral border
   c. Lymphatics: prelaryngeal, pretracheal, paratracheal, parapharyngeal, deep cervical, and supraclavicular nodes
3. RLN[5]
   a. Descends within the vagus nerve
      1) Left: wraps around the aortic arch below the ligamentum arteriosum and returns to the neck in the trachea-esophageal groove
      2) Right: branches from the vagus higher than the left and wraps around the subclavian artery before ascending along the tracheoesophageal groove more laterally than the left
      3) Courses beneath the inferior pharyngeal constrictor muscle and passes posterior to the cricothyroid joint
      4) Enters the larynx above the first tracheal ring, below the cricoid cartilage
   b. Landmarks
      1) Simon's triangle: bound by common carotid artery laterally, esophagus medially, and inferior thyroid artery superiorly
      2) Variably associated with the inferior thyroid artery
         a) Found behind or between branches of the artery in 80%
         b) The relationship between the RLN and the inferior thyroid artery is different on the left and right in about 50% of cases.
      3) Usually in the vicinity of the inferior parathyroid gland
      4) Majority found within 3 mm of Berry's ligament, often laterally, and sometimes passing through the ligament
      5) May pass through the capsule of the thyroid gland
      6) Deep to the tubercle of Zuckerkandl in 98% of patients
      7) Non-RLNs can be found in up to 0.7% of patients.
         a) Primarily on the right (associated with aberrant subclavian artery), except in cases of situs inversus (dextrocardia)
         b) May arise at the level of the thyroid cartilage or superior pole of thyroid and course directly into the larynx
      8) May divide at various levels, and 40% to 65% bifurcate or trifurcate—more than 5 mm below the cricoid cartilage
4. Superior laryngeal nerve (SLN)
   a. Arises from the nodose (inferior) ganglion of the vagus nerve about 4 cm above the carotid bifurcation, near the jugular foramen
      1) Descends lateral to the pharynx and posteromedial to the carotid sheath
      2) Splits into internal and external branches about 2 cm above the superior pole of the thyroid, with the former penetrating through the postero-inferior thyrohyoid membrane
   b. Function
      1) Internal branch: sensation and secretomotor function to the supraglottis, epiglottis, base of the tongue, piriform sinus, and upper esophageal sphincter
      2) External branch: cricothyroid and inferior constrictor muscles
   c. SLN external branch landmarks
      1) Sternothyrolaryngeal triangle (Joll's triangle): bound by the midline medially, superior thyroid pole laterally, and attachments of the strap muscles superiorly
      2) Deep to the superior thyroid artery 82% to 86% of the time and penetrates the inferior constrictor muscle at variable levels
      3) Can be found below, and up to 1 cm above, the level of the upper pole of the thyroid in 37% of patients
5. Parathyroid glands
   a. Superior parathyroids
      1) Fourth branchial arch structure
      2) Superior or inferior thyroid vessels
      3) Frequently above cricoid cartilage
   b. Inferior parathyroids
      1) Third branchial arch structure
      2) Variable location
         a) Frequently below cricoid cartilage

Prerequisite Skills

1. Intimate knowledge of the use of surgical instruments and meticulous soft tissue/neural dissection

Operative Risks

1. RLN injury
   a. Preferential visual identification of the RLN before the thyroid or lymph nodes are dissected off the trachea and esophagus
2. SLN injury
   a. Carefully dissect out the superior pole to ensure the SLN is not coursing within the vascular pedicle before ligation.
   b. Avoid thermal injury or excessive dissection of cricothyroid and constrictor muscles.
3. Parathyroid injury or devascularization
   a. Lateralize parathyroids with their blood supply when medializing the thyroid gland.
   b. Reimplant normal, frozen biopsy confirmed parathyroids.
4. Intraoperative hemorrhage
   a. Anterior jugular veins: Carefully undermine subplatysmal skin flaps and ligate large vessels.
   b. Carotid artery: Use a blunt instrument when dissecting in this region, especially the superior pole, and be aware of depth of dissection at all times.
   c. Thyroid gland and surface vessels: Use blunt dissection close to the thyroid capsule and meticulously seal or ligate the vasculature.
5. Tracheoesophageal injury
   a. Most commonly occurs at Berry's ligament or subcricoid trachea
   b. Primary repair is usually satisfactory.

Surgical Technique

1. Marking
   a. Mark a 5-to 6-cm horizontal incision line between the cricoid cartilage and suprasternal notch.
      1) Usually 2 to 3 cm above the sternal notch
   b. Use an existing neck crease or line of relaxed skin tension that could be lengthened if lateral neck dissection is ever needed.
   c. Mark the incision higher in younger patients because the scar will migrate lower over time and a scar below the clavicle is unsightly.
   d. If sternotomy is possible, the incision should be at the clavicles or lower.
2. Local anesthesia
   a. Inject 0.25% bupivicaine with 1:200,000 epinephrine 1 to 2 cm above and below the incision line to reduce distortion and maximize hemostasis in the incision.
3. Incision
   a. Use a #15 blade to incise the dermis to the platysma.
   b. Incise through the platysma to the subcutaneous tissue with electrocautery to the investing fascia.
   c. Avoid injuring the communicating anterior jugular veins.
4. Elevate skin flaps
   a. Using skin rakes for tension, subplatysmal flaps are elevated with blunt dissection and electrocautery in the plane just above the investing fascia and anterior jugular veins up to the thyroid notch and down to the sternal notch.
   b. Ligate large vessels with 2-0 silk ties.
   c. Protect the skin with occlusive material such as Steri-Strips (preferred by the senior author; Fig. 67.1).
      1) Suture in place with locking 2-0 silk running sutures.
      2) Protects the skin from heat or instrument injury
   d. Place a self-retaining retractor in the wound if an assistant is not available.



Fig. 67.1. Occlusive skin dressing for protection. Steri-Strips with 2-0 silk.

5. Split and elevate the strap muscles.
   a. Identify the median raphe of the strap muscles.
   b. Divide the straps in the midline up to the thyroid notch and down to the sternal notch with electrocautery.
   c. Elevate the strap muscles off of the thyroid (if present) and trachea.
      1) Elevate bluntly with a Freer elevator, peanut sponge, or with electrocautery.
      2) The strap muscles should be sacrificed with a healthy margin if there is any infiltration of the muscles by the tumor.
      3) Electrocautery, surgical clips, or ties may also be used to augment ligation of the superior pedicle.
6. Mobilize the thyroid/trachea medially.
7. Identify and skeletonize the carotid artery.
   a. In reoperative surgery, this may be done before dissection of the trachea.
   b. If the strap muscles are adherent to the thyroid or trachea
      1) Identify the carotid artery by dissecting lateral to the strap muscles.
      2) The strap muscles can be horizontally transected to gain access to the paratracheal compartment and facilitate dissection.
8. Identify the recurrent laryngeal nerve.
   a. Rotate the thyroid gland and trachea medially.
   b. Using the McCabe dissector, dissect near the cricothyroid joint and the tracheoesophageal groove to identify the RLN.
      1) Do not close the clamp when the tips are buried in tissue.
      2) Once the RLN is identified, dissecting parallel and directly on the nerve sheath prevents damaging the nerve and its branches.

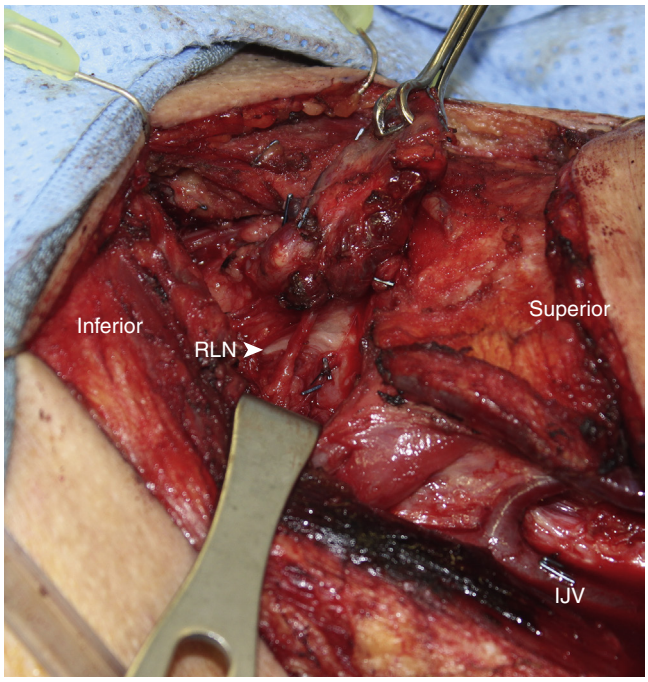

Fig. 67.2. Paratracheal packet being retracted medially away from recurrent nerve. *RLN,* Recurrent laryngeal nerve, *IJV,* internal jugular vein.

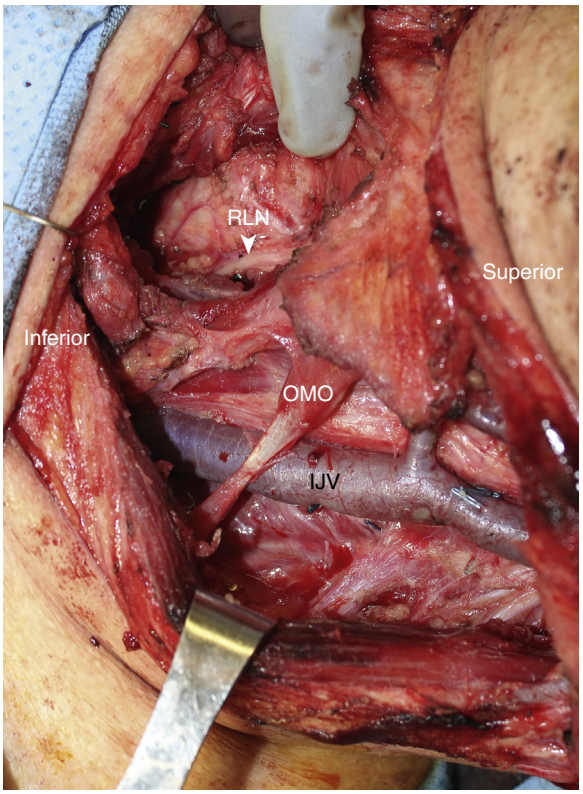

Fig. 67.3. Paratracheal dissection in combination with lateral neck dissection with preserved parathyroid gland medial to the recurrent nerve. *RLN,* Recurrent laryngeal nerve, *IJV,* internal jugular vein, *OMO,* omohyoid.

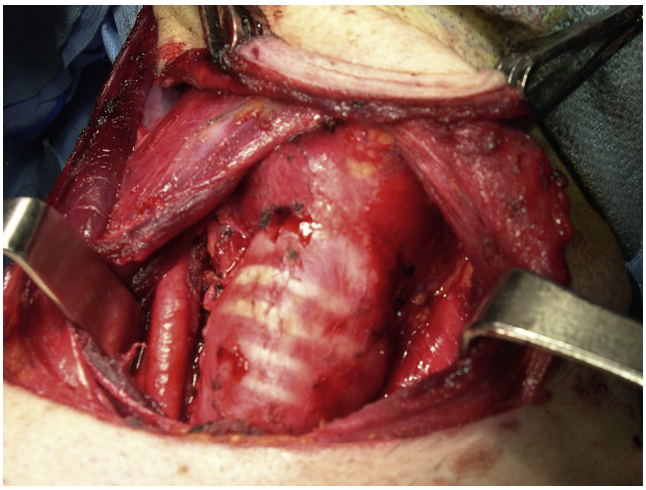

Fig. 67.4. Bilateral paratracheal dissection with carotid to carotid exposure and preservation of superior parathyroid tissue.

3) Trace the RLN from the paratracheal region up to the cricothyroid muscle, being careful not to damage either the anterior or posterior branch.
   a) In reoperative surgery, starting lateral near the carotid will facilitate a safe and focused dissection.
4) Grasp the paratracheal tissue with a Babcock clamp (Fig. 67.2).
   a) Pull the packet superior and medial away from the nerve.
   b) All fibroadipose tissue and lymph nodes overlying the trachea and medial to the carotid artery should be removed.

c. Carefully dissect and lateralize the parathyroid glands with their blood supply (Fig. 67.3).
   1) The parathyroid glands usually receive their blood supply from the inferior thyroid arteries, but the superior parathyroids may derive their arterial supply from the superior thyroid artery.
   2) Inferior glands may need to be autotransplanted after frozen section verification.
   3) Glands superior to the cricoid cartilage can often be preserved.

9. Achieve hemostasis (Fig. 67.4).
   a. Irrigate the wound thoroughly; evaluate bleeding during Valsalva by anesthesia. Bipolar cautery used for hemostasis.
   b. Hemostatic agents such as Surgicel may contribute.
   c. A drain may be used at the surgeon's discretion.
10. Wound closure
   a. The strap muscles are approximated with absorbable sutures (3-0 Vicryl).
      1) Leave a space inferiorly to allow drainage of potential hematomas.
   b. Approximate the platysma layer carefully.
   c. Close the skin with absorbable subcuticular sutures (4-0 Monocryl).
   d. Dress the skin with an adhesive such as Mastisol and apply Steri-Strips.

Common Errors in Technique

1. Failure to preserve or recognize devascularized parathyroid glands
2. Failure to identify the RLN, and preserve both branches
3. Leaving tissue in the superior mediastinum overlying the trachea
4. Inadequate hemostasis throughout surgery puts nerves and parathyroids at risk.
5. Overstretching and burning the skin edges with hot instruments

POSTOPERATIVE PERIOD

Postoperative Management

1. Check serum PTH after 1 hour in the recovery unit for total or completion thyroidectomy.
   a. Overnight observation if PTH is less than 15 pg/mL
   b. Serum calcium may take more than 12 hours to stabilize with a change in PTH.
2. Pain medications: ibuprofen or acetaminophen with narcotics for breakthrough
3. Wound care
   a. Neck incision to be kept dry for 48 hours, after which it may be wet
   b. Examine patient in 1 week and replace Steri-Strips to prevent scar formation.
   c. Surgical drains
4. Thyroid replacement medication is needed if total thyroidectomy is performed.
   a. Thyroid hormone withdrawal for RAI treatment
   b. May start liothyronine and stop 2 weeks prior to RAI
5. RAI therapy will depend upon the pathology of the tumor and presence of metastasis.

Complications

1. Hematoma
   a. Usually detected within 2 hours of surgery
      1) Dyspnea
      2) Dysphagia
      3) Expanding mass in the neck
   b. Assure patency of drains.
   c. Immediately open incision and evacuate blood clots to prevent airway compromise.
   d. Take the patient back to the operating room to explore the wound and achieve hemostasis.
2. RLN injury
   a. Hoarseness and a weak voice with vocal cord in the paramedian position
   b. May have aspiration
   c. Intraoperative transection may require immediate reanastomosis, which may provide tone and decrease vocal cord atrophy.
   d. Consider early vocal cord medialization for known transection.
   e. Bilateral RLN injury will result in airway distress and stridor after extubation and may necessitate reintubation and tracheostomy.
3. SLN injury
   a. Results in difficulty projecting voice or poor pitch control in high frequencies
   b. Voice therapy may be helpful.
4. Hypoparathyroidism
   a. Risk with total or completion thyroidectomy or patients previously operated for hyperparathyroidism
   b. Treat severe symptoms with intravenous (IV) calcium gluconate.
   c. Cardiac monitoring if severe hypocalcemia
   d. May need oral calcium carbonate and vitamin D supplementation temporarily or for life
5. Tracheoesophageal injury
   a. Subcutaneous air or increased drainage
   b. Usually heralded by wound infection
   c. Often self-limited
   d. Surgical exploration for persistent or massive output

Alternative Management Plan

1. Radioiodine therapy
2. External beam radiation
3. Chemotherapy (tyrosine kinase inhibitors)

DISCUSSION

Evidence-Based Medicine Question

In what setting may prophylactic central compartment neck dissection warrant a stronger consideration?

A meta-analysis carried out in 2013 of 11 studies capturing 2318 patients with papillary thyroid carcinoma demonstrated recurrence rates of 7.9% in those who received total thyroidectomy alone, versus 4.7% in those who underwent total thyroidectomy with prophylactic central compartment neck dissection; however, this result did not reach statistical significance. However, the study points out the recurrence rate of 3.8% in five single cohort studies performed by high-volume thyroid cancer surgeons. On the basis of calculated risk reduction, the number of patients needed to treat to achieve a lower recurrence rate is 31. In addition, the relationship of surgeon volume and patient outcomes has been examined over the years, with studies demonstrating that high-volume surgeons have the lowest complication rates. A stronger consideration may be given to prophylactic central compartment neck dissections, particularly when performed by high-volume thyroid surgeons.

Editorial Comment

Central compartment dissection is an operation that requires skill and patience. A meticulous central compartment dissection is not only important for disease control and oncologic completeness but also permits maximum preservation of RLN and parathyroid gland function. The dissection must be an anatomic one, with limits of the dissection defined by the anatomic landmarks earlier described in the chapter. Due to the complex anatomy, critical structures, and impact of surgical expertise and experience on complications and surgical outcomes, central compartment dissection should be performed by high volume endocrine and head neck surgeons, rather than the occasional thyroid surgeon.

Rohan R. Walvekar

Access the review questions and additional sources list online at http://www.expertconsult.com



REFERENCES

1. Haugen BR, Alexander EK, Bible KC, et al. 2015 American Thyroid Association management guidelines for adult patients with thyroid nodules and differentiated thyroid cancer. Thyroid 2016;26:1–133.
2. Wang TS, Cheung K, Farrokhyar F, et al. A meta-analysis of the effect of prophylactic central compartment neck dissection on locoregional recurrence rates in patients with papillary thyroid cancer. Ann Surg Oncol 2013;20:3477–3483.
3. Carling T, Carty SE, Ciarleglio MM, et al. American Thyroid Association design and feasibility of a prospective randomized controlled trial of prophylactic central lymph node dissection for papillary thyroid carcinoma. Thyroid 2012;22:237–244.
4. Wells SA, Asa SL, Dralle H, et al. Revised American Thyroid Association guidelines for the management of medullary thyroid carcinoma. Thyroid 2015;25(6):567–610.
5. Fancy T, Gallagher D, Hornig JD. Surgical anatomy of the thyroid and parathyroid glands. Otolaryngol Clin North Am 2010;43(2):221–227.

REVIEW QUESTIONS

1. Each of the following is a strategy to avoid complications in central compartment neck dissection, except:
   a. Skeletonize the superior pole of the thyroid prior to ligation
   b. Trace the RLN from the paratracheal region up to the cricothyroid muscle
   c. Immediately autotransplant devascularized parathyroid glands
   d. Medialize the parathyroid glands with their blood supply

2. According to the American Thyroid Association guidelines, which of the following is not an indication for a central compartment neck dissection?
   a. A 1-cm follicular thyroid carcinoma with clinically involved central nodes
   b. A 5-mm medullary thyroid carcinoma with clinically negative nodes
   c. A 2-cm papillary thyroid carcinoma with clinically negative nodes
   d. A 1-cm follicular thyroid carcinoma extending beyond the thyroid capsule with clinically negative nodes

3. Which of the following is not a benefit of a prophylactic central compartment neck dissection?
   a. Improvement of long-term survival in WDTCs
   b. Obtaining accurate pathologic staging to direct postoperative RAI therapy
   c. Reducing recurrence in high-risk primary tumors
   d. Avoiding morbidity of reoperation in the central compartment

ADDITIONAL SOURCES

Kandil E, Noureldine SI, Abbas A, et al. The impact of surgical volume on patient outcomes following thyroid surgery. Surgery 2013;154(6):1346–1352.

Schulte KM, Talat N, Miell J, et al. Lymph node involvement and surgical approach in parathyroid cancer. World J Surg 2010;34: 2611–2620.

Wei CH, Harari A. Parathyroid carcinoma: update and guidelines for management 2012;13:11–23.

68 Retropharyngeal Neck Dissection

Vikas Mehta

INTRODUCTION

The retropharyngeal lymph nodes (RPLNs) are a small chain of lymph nodes located in the retropharyngeal space (RP) where they are divided into the medial and lateral groups. The boundaries of the RP are the carotid sheath laterally, skull base superiorly, prevertebral fascia posteriorly, and the pharynx anteriorly, and inferiorly, the RP is in continuity with the posterior mediastinum. The medial group of nodes are usually ill-defined and often absent in adults, thus not having a significant role in RPLN metastases. The lateral RPLN, which lies superior to the sympathetic ganglion at the level of C1, can harbor metastases from a variety of cancers; oropharyngeal cancer being the most common. There may be one to three nodes that are often difficult to identify in the absence of metastatic involvement. Typically, the lateral RPLNs are usually smaller than 4 to 4.5 mm in the greatest diameter of their shortest axis, where 6 to 10 mm has been described as the pathologic threshold for RPLNs.

Rouviere, in 1938, first mapped lymphatic drainage of the oropharynx and characterized the spread of oropharyngeal carcinomas to the RP.[1] RPLN positivity in all oropharyngeal squamous cell carcinomas (OPSCC) has been found to be 10% to 27%, using a variety of imaging modalities.[2–5] Additionally, RPLN involvement in OPSCC is an important prognostic factor and has been shown that there is an increased risk for regional recurrence (45% vs. 10%) and reduced rates of disease-specific survival (38% vs. 58%).[6] RPLN metastases are more common from the soft palate and posterior pharynx, but they can occur from any subsite within the oropharynx. Due to the incidence of metastases, the RPLNs are routinely targeted during radiation therapy for OPSCC. Currently, when the lateral lymphatics of the neck are dissected in a conventional selective neck dissection, the RPLNs are not routinely dissected. With increasing use of transoral surgery (TOS) as a primary treatment modality for OPSCC, dissection of the RPLN during cervical lymphadenectomy becomes more important, especially in cases where no adjuvant treatment is recommended.

KEY OPERATIVE LEARNING POINTS

- Approach can be transcervical or transoral
  - Transcervical approach preferred if a concurrent neck dissection is being performed
- Avoid injury to the sympathetic chain that is located lateral to the RPLN and can often be mistaken for lymphadenopathy
- A positive positron emission tomography (PET)/computed tomography (CT) of the RPLN has an excellent PPV and suggests that the RPLN needs to be addressed when primary or recurrent squamous cell carcinomas (SCC) are present.

PREOPERATIVE PERIOD

The keys to deciding when to perform the surgery in the primary setting are: (1) to ascertain the risk of RPLN metastases based on the oropharyngeal cancer subsite and nodal cancer burden and (2) decide whether primary surgical treatment will be employed. If preoperative imaging suggests metastasis in the RPLN and a neck dissection is being performed, the RPLN can be safely dissected in this situation. If the RPLN is negative on PET/CT and another imaging modality (CT or magnetic resonance imaging [MRI]), then the RPLN can either be ignored or treated electively with radiation therapy, depending on the TNM staging and subsite (Fig. 68.1).[7] In the setting of lymph node metastasis persistence or recurrence after chemoradiation, PET/CT has demonstrated adequate accuracy at predicting RPLN disease and can be used to guide whether the RPLNs need to be addressed during a salvage-neck dissection. As with all head and neck cancers, I advocate for presenting the patient to a multidisciplinary tumor board and considering various factors, for example, the patient's comorbidities, preferences, and social situation prior to proceeding with primary treatment.

The RPLN can be approached by using either a transcervical or transoral technique. I suggest a transcervical approach in the primary setting when performed in conjunction with an elective neck dissection. The technique for the transcervical approach, as outlined below, has been demonstrated to be a safe and reliable method of RPLN sampling during primary surgical management. For therapeutic removal of a metastatic RPLN, both the transcervical and transoral techniques can be used. If a concurrent neck dissection is being performed, I prefer using the transcervical approach to avoid violating the pharynx and creating a potential salivary fistula. If, however, the RPLN is the only node being removed (i.e., in the case of a previously dissected neck with only a RPLN positive node or a solitary papillary thyroid cancer metastasis), then a transoral approach can be considered to avoid an external incision based on the familiarity of the surgeon with the anatomy and techniques.

If primary surgical therapy is being considered for the oropharyngeal cancer, informed consent must include the usual potential morbidity associated with the primary resection of the cancer and the selective neck dissection. In addition to these risks, the RPLN dissection through a transcervical approach increases the risk of a salivary fistula due to the close proximity to the pharynx. Also, the dissection of the RPLN can include potential damage to cranial nerve (CN) IX and the sympathetic chain, which can increase the risk of aspiration and result in Horner's syndrome, respectively. If the transoral approach is performed in isolation, there is minimal risk of a salivary fistula but the incidences of postoperative aspiration, Horner's syndrome, and damage to major vessels are likely increased due to the limited exposure and technical difficulties associated with this approach.[8]

History

1. History of present illness
   a. Risk factors: smoking, alcohol, Human papillomavirus (HPV) infection
   b. Weight loss, nutritional status
   c. New onset of pain in the pharynx or otalgia
   d. Dysphagia/odynophagia
   e. Neurologic deficits
   f. Voice changes
   g. Presence of masses or lesions in the throat or neck

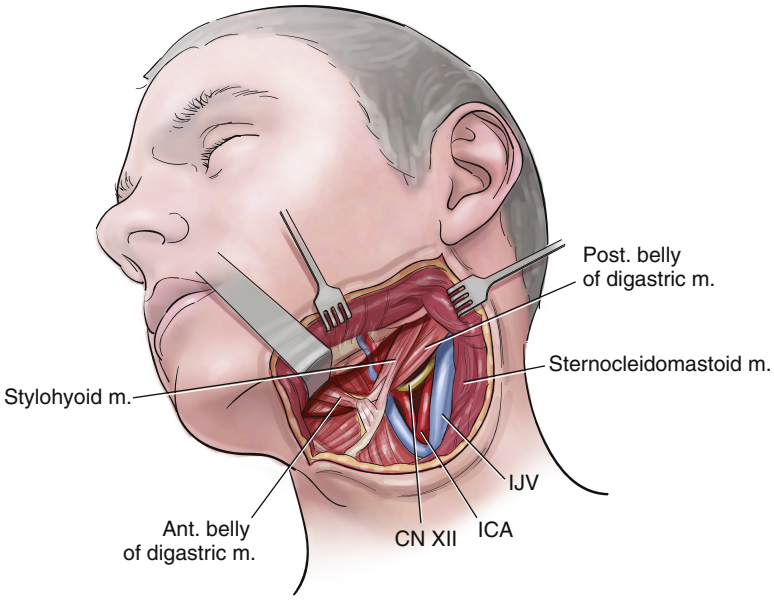

Fig. 68.1. Depiction of the transcervical approach to the retropharyngeal lymph nodes following a selective neck dissection. *ICA*, Internal carotid artery. *IJV*, Internal Jugular Vein.

2. Past medical history
   a. Previous squamous cell carcinomas or thyroid cancer
   b. Previous radiation to the head and neck
   c. Previous surgery or trauma to the neck or pharynx
3. Prior treatment of oropharynx or neck
   a. Previous (chemo)radiation for oral/oropharyngeal cancer
   b. Prior surgery for metastatic thyroid cancer
4. Medical illness
   a. Cardiopulmonary disease
   b. Alcoholism, risk of perioperative alcohol withdrawal syndrome and substance abuse
   c. Sexual history for risk of HPV exposure
5. Medications
   a. Anticoagulants
   b. Allergies to antibiotics
6. Mental and social status
   a. Ability to give informed consent

Physical Examination

1. Oropharyngeal cancer
   a. Determine primary site and tumor extent (if present)
      1) Tonsil
         a) Extension to soft palate, base of tongue (BOT), and posterior oropharynx
         b) Invasion of the mandible
      2) Palate
         a) Extension into the mucosa on the nasal side
         b) Involvement of the hard palate or other oropharyngeal structures
      3) Posterior oropharynx
         a) Extension into nasopharynx
         b) Direct extension to the RPLN space
      4) BOT
         a) Extension to contralateral BOT
         b) Involvement of other oropharyngeal structures or mandible
      5) Invasion of major nerves
         a) Lingual nerve (loss of sensation of anterior tongue and floor of mouth)
         b) Inferior alveolar nerve (loss of sensory function of mental nerve)
         c) Hypoglossal nerve (deviation of tongue)
         d) Glossopharyngeal nerve (lack of palate sensation, may be difficult to assess)
2. Assessment of nodal extension
   a. Oropharyngeal examination and palpation (if tolerated)
3. Cervical lymph node metastasis
   a. Palpate the neck for the presence of cervical metastases.
   b. Examine the neck for previous surgery and scars that may affect surgical planning.
4. Examine the oral cavity, pharynx, and larynx for synchronous primaries.
5. Thyroid
   a. If there is a history of thyroid cancer and the RPLN appears to be a thyroid metastasis
6. Fiberoptic laryngoscopy
   a. Particular attention to superior and inferior extent of primary cancer and RPLN
7. General health
   a. Nutrition
   b. Cardiovascular
   c. Respiratory
   d. Mental

Imaging

1. Chest radiograph
   a. Metastases
   b. Synchronous lung cancer
   c. Pulmonary and cardiac status
2. CT scan of the neck with contrast
   a. Important to assess the relationship of the node(s) with the prevertebral fascia and carotid artery
   b. Assess the extent of the primary cancer.
3. PET/CT
   a. Data suggest it is an extremely sensitive modality to assessing for recurrent disease and RPLN metastasis.
   b. Provides information regarding distant metastasis
4. Thyroid scan
   a. Required only if thyroid metastasis suspected
   b. Can provide information regarding adjuvant treatment with I131, in addition to information on other metastatic sites

Indications

- Salvage following previous (chemo)radiation with PET/CT demonstrating persistent cancer
- Presence of a metastatic node from a primary cancer in the thyroid
- Primary surgical treatment of an oropharyngeal cancer with advanced lymph node metastasis (N2b or higher)

Contraindications

1. Patient factors
   a. Medically unfit
   b. Poor nutritional status
   c. Inability to give informed consent
   d. Severe trismus
2. Tumor factors
   a. Early stage oropharyngeal SCC in the primary surgical setting
   b. Distant metastases
   c. Negative PET/CT scan for RPLN disease
   d. Unresectable cancer with gross fixation to the prevertebral musculature
3. Surgical factors
   a. Inadequate expertise with resection via a transcervical approach

Preoperative Preparation

1. Evaluations by
   a. Oncologic Surgeon
   b. Radiation and Medical Oncologist
   c. Speech and swallowing therapist
   d. Anesthesiology
   e. Tumor board presentation
2. Postoperative care planning
3. Discontinue antiplatelet drugs if possible.

OPERATIVE PERIOD

Anesthesia

- Ask the anesthetist to insert an oral endotracheal tube.
- The anesthetic machine is positioned at 90 degrees from the patient's head if performing a transcervical approach and at 180 degrees if a transoral approach is to be attempted.
- One dose of steroids should be given intravenously. I prefer to use Decadron 8 to 12 mg depending on the patient's size/weight.

Positioning

- The surgery is performed with the patient in a supine position with the neck extended.
- The lower face and neck are prepared and appropriately draped if performing a transcervical approach.

Perioperative Antibiotic Prophylaxis

- Clean-contaminated surgery
- Antibiotics are administered during induction of anesthesia and continued for 24 hours if a transoral approach will be used. No antibiotics are needed for a transcervical approach unless there is a violation of the pharynx during neck surgery.
- Choices
  - Clindamycin
  - Amoxicillin-clavulanate
  - Cephalosporin and metronidazole

Monitoring

- Routine anesthesia monitoring
- Patient should not be paralyzed to facilitate preserving the spinal accessory and marginal mandibular nerves.

Instruments and Equipment to Have Available

- Monopolar and bipolar electrocautery
- Resection and neck dissection sets
  - Standard instruments used for head and neck cancer surgery
- Transoral robotic approach
  - Mouth-retractor (FK, Crow-Davis, or Dingman)
  - The 5-mm Monopolar spatula electrocautery and 5-mm Maryland dissector
  - Thirty- and 0-degree endoscopes available
  - Robotic surgery platform (daVinci system, Intuitive Surgical; Flex robotic system, Medrobotics)

Key Anatomic Landmarks

- Neck dissection: See neck dissection.
- Retropharyngeal node dissection
  - Transcervical
    - Posterior belly of the digastric Chapters 64 and 65
    - Stylohyoid muscle
    - Hypoglossal nerve
    - Common carotid and the internal and external carotid arteries (Fig. 68.2)
    - Pharynx
    - Glossopharyngeal nerve
    - Sympathetic trunk
  - Transoral
    - Tonsil anterior and lateral to the incision
    - Sympathetic trunk may overlie or be lateral and can resemble lymphadenopathy
    - Internal carotid artery (ICA) lateral to the RPLN space
    - Prevertebral fascia (posterior limit of dissection)
    - Level of hyoid (not seen but identifies inferior limit of dissection)

Prerequisite Skills

- Neck dissection: selective levels 1 to 5; modified; and radical
- Radical tonsillectomy
- Resection of the base of the tongue
- Transoral robotic surgery

Surgical Technique

- Intraoperative evaluation after the patient has been intubated
  - Panendoscopy to exclude synchronous cancers in upper aerodigestive tract
  - Reassess extent of primary cancer, especially posterior and lateral extents.
  - Re-evaluate the neck for cervical lymph nose metastases.
- Surgical approach (transcervical)
  - Perform after the standard neck dissection is completed
  - Identify and retract superiorly the posterior belly of the digastric muscle, the stylohyoid muscle, and the hypoglossal nerve (see Fig. 68.2). The muscles can be divided to provide additional exposure if necessary.
  - Dissect within the carotid sheath between the ICA and the pharynx, which are retracted laterally and medially, respectively.

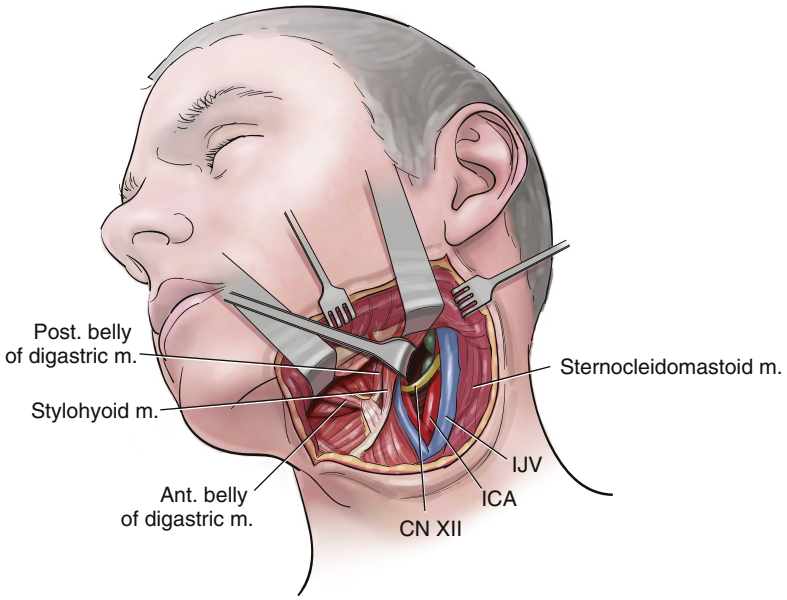

Fig. 68.2. After retraction of the hypoglossal nerve and posterior belly of the digastric, blunt and sharp dissection medial to the internal carotid artery will identify the retropharyngeal lymph node. *ICA*, Internal carotid artery. *IJV,* Internal Jugular Vein.

- Incise the alar fascia medial the ICA, and dissect the node with scissors and bipolar cautery.
- The sympathetic trunk can be identified lateral to the RPLN and should be preserved. Monopolar cautery should be avoided in this area to prevent injury to this structure.
- Visualize and palpate for residual lymph nodes. Send the packet of lymph nodes for frozen section to be certain that at least one RPLN has been obtained.

- Surgical approach (transoral)
  - In OPSCC cases, the RP can be entered directly through the primary site defect.
  - Identify the ICA and dissect medial to it using blunt dissection.
  - The superior and inferior mucosa can be retracted to get around the entire node.
  - Blunt dissection should be used as much as possible to avoid injury to the sympathetic chain, which lies in close proximity and can resemble the RPLN.
  - The prevertebral fascia serves as the posterior limit of dissection.
  - In cases of metastatic modes with no primary site, the assistant at the head retracts the tonsillar fossa laterally exposing the posterior pharyngeal wall.
  - A vertical mucosal incision is made just medial to the posterior tonsillar pillar directly overlying the RPLN.
  - Dissection is performed using the same technique as described above.
- Closure
  - The neck is irrigated and then closed over suction drains.
  - The oropharyngeal wound is left to heal by secondary intention or can be approximated by interrupted sutures if easily accessible and can be closed without excess tension.

Common Errors in Technique

- Creating an inadvertent pharyngotomy during the transcervical technique by not properly identifying the pharynx
- Failing to identify the sympathetic trunk and causing injury

POSTOPERATIVE PERIOD

- Antibiotics: when drain is in place or if pharyngeal/cervical communication encountered
- Remove suction drains when less than 50 mL drainage/24 hours
- Feeding
  - Oral feeding with liquids that can be advanced to soft diet (if transoral approach used)
  - Speech and swallowing therapist assists the patient with swallowing if needed
- Postoperative (chemo)radiation generally commenced within 6 weeks of surgery if indicated

Complications

- Hematoma
  - A hematoma in the neck usually occurs within the first 24 hours after an operation. If the hematoma is rapidly expanding, the incision may need to be opened at the bedside to avoid airway compromise.
  - The patient should be returned to the operating room as soon as possible to avoid airway-related complications.
  - Since the dissection is intimately involved with the carotid arteries, injury to these structures should be ruled out first given the potential serious complications of damage to the internal carotid.
- Oral hemorrhage
  - A small amount of blood in the sputum is common after a transoral approach.
  - The patient may present with oral hemorrhage up to 2 weeks postoperatively or longer.
  - The first priority in severe hemorrhage is to secure the airway.
  - After securing the airway, the pharynx can be packed with gauze to tamponade the bleeding.
  - If an injury to the carotid arterial system is suspected, interventional radiology should be consulted for an emergent angiogram with intervention.
  - If the external carotid system is the source of bleeding, ligation through a surgical transcervical approach should only be taken as a last resort, since it has the potential to create a salivary fistula and/or create a situation in which collateral flow contributes to further bleeding and there is difficulty accessing the area via angiography due to the ligated vessel.
- Alcohol withdrawal syndrome
  - Onset on day 2 to 3

- Additional morbidity and mortality and prolongs hospitalization
- May require deep sedation and ventilation
- Involve internist or intensivist in care

- Dysphagia and aspiration
  - Uncommon after an isolated injury to CN IX
  - Assess with a modified barium swallow and/or functional endoscopic evaluation swallow (FEES).
- Horner's syndrome
  - This can result from inadvertent injury to the sympathetic chain, which can be mistaken for a lymph node.
  - The patient presents with the triad of miosis, ptosis, and anhidrosis.
- Salivary leak
  - A salivary leak may occur in both the transcervical and transoral approaches.
  - Transcervical—inadvertent injury to the pharynx during dissection. Sutures should be placed to attempt a primary repair. In an irradiated patient, Use a local muscle flap (i.e., the digastric muscle) to further bolster the repair.
  - Transoral—Since the neck is not usually compromised in these cases, a leak is rarely encountered and may be more common in radiated patients due to the delayed secondary healing.

Alternative Management Plan

In the primary setting, patients can be managed with nonsurgical therapy alone. In the recurrent setting, surgical resection remains the only option for cure. The patient can be offered re-irradiation (if already performed) and/or chemotherapy as palliative measures.

DISCUSSION

Evidence-Based Medicine Question

What are the common risk factors for RPLN metastasis in patients with OPSCC?

The overall rate of RPLN positivity in oropharyngeal cancer has been reported as ranging from 14.5% to 36%.[5,7,8,9,10] Advanced cancers of the soft palate and posterior pharyngeal wall have a higher incidence of RPLN metastasis than the BOT and tonsil subsites. With the increasing incidence of HPV positive oropharyngeal cancer, the latter two subsites (tonsil and BOT) become increasingly more common. In a study by Moore et al.,[7] the authors performed elective RPLN dissection in 72 OPSCC patients undergoing primary surgical management with Transoral Robotic Surgery (TORS) and selective neck dissection. They found the RPLN to be positive in 14.5% of the patients with all the positive nodes in patients with tonsil cancer only and either cT3/4, cN2b/N2c/N3, or with positive imaging preoperatively. There were no positive RPLNs in patients with BOT primary SCCA. Therefore, the authors advocate addressing the RPLN electively, with surgery or radiation, in patients with either positive imaging (CT or PET/CT) or those with more advanced cancer of the tonsil, soft palate, and posterior pharynx. Additionally, the authors found that while the negative predictive value of PET/CT and CT was quite good (92.6% and 91.7%, respectively), imaging failed to detect micrometastases in 37.5% of patients, thus suggesting that a negative scan in advanced disease patients should be interpreted with caution.

Editorial Comment

Cancers of the oropharynx are managed with nonsurgical approaches in most institutions. HPV status has introduced the possibility of de-intensified therapy and consideration of surgery as a primary modality for management of cancers of the oropharynx. Additionally, TORS has created the opportunity to manage primary cancers of the oropharynx and retropharyngeal nodes with surgery. As RPLN surgery becomes more commonplace consideration must be given because both transoral and transcervical dissection of the RPLN can lead to significant dysphagia due to disruption of the pharyngeal plexus. Surgical or nonsurgical management of the RPLNs must be carefully considered with emphasis on obtaining the best functional and oncologic outcomes while staying within the parameters of evidence-based protocols.

Rohan R. Walvekar

Access the review questions and additional source list online at http://www.expertconsult.com



REFERENCES

1. Rouviere H. Anatomy of the Human Lymphatic System: a Compendium. Ann Arbor, MI: MJ Edwards; 1938.
2. Bussels B, Hermans R, Reijnders A, et al. Retropharyngeal nodes in squamous cell carcinoma of oropharynx: incidence, localization, and implications for target volume. Int J Radiat Oncol Biol Phys 2006;65:733–738.
3. Chu HR, Kim JH, Yoon DY, et al. Additional diagnostic value of (18)F-FDG PET-CT in detecting retropharyngeal nodal metastases. Otolaryngol Head Neck Surg 2009;141:633–638.
4. Gunn GB, Debnam JM, Fuller CD, et al. The impact of radiographic retropharyngeal adenopathy in oropharyngeal cancer. Cancer 2013;119:3162–3169.
5. Shimizu K, Inoue H, Saitoh M, et al. Distribution and impact of lymph node metastases in oropharyngeal cancer. Acta Otolaryngol 2006;126:872–877.
6. Dirix P, Nuyts S, Bussels B, et al. Prognostic influence of retropharyngeal lymph node metastasis in squamous cell carcinoma of the oropharynx. Int J Radiat Oncol Biol Phys 2006;65:739–744.
7. Moore EJ, Ebrahimi A, Price DL, et al. Retropharyngeal lymph node dissection in oropharyngeal cancer treated with transoral robotic surgery. Laryngoscope 2013;123:1676–1681.
8. Givi B, Troob SH, Stott W, et al. Transoral robotic retropharyngeal node dissection. Head Neck 2016;38(Suppl. 1):E1688–694.
9. Chung EJ, Oh JI, Choi KY, et al. Pattern of cervical lymph node metastasis in tonsil cancer: predictive factor analysis of contralateral and retropharyngeal lymph node metastasis. Oral Oncol 2011;47:758–762.
10. Hasegawa Y, Matsuura H. Retropharyngeal node dissection in cancer of the oropharynx and hypopharynx. Head Neck 1994;16:173–180.

REVIEW QUESTIONS

1. Which of the following structures is NOT in close proximity to the retropharyngeal lymph node (RPLN)?
   a. Sympathetic chain
   b. Internal carotid artery
   c. Glossopharyngeal nerve
   d. Accessory nerve

2. Which cancer is most at risk for having a RPLN metastasis?
   a. T1N1 base of tongue (BOT) squamous cell carcinoma (SCC)
   b. T3N2b tonsil SCC
   c. T1N1 tonsil SCC
   d. T3N2a BOT SCC

3. Which of the following structures is commonly encountered and can be sacrificed when approaching the RPLN transcervically?
   a. Hypoglossal nerve
   b. Mandible
   c. Sympathetic chain
   d. Stylohyoid muscle

ADDITIONAL SOURCE

Vasan NR, Medina JE. Retropharyngeal node dissection. Oper Tech Otolaryngol 2004;15:180–183.

69 Management of Tumors in the Prestyloid Parapharyngeal Space

Jessica H. Maxwell, Jonas T. Johnson

INTRODUCTION

The management of a patient with a tumor of the parapharyngeal space (PPS) is a challenging task. The complex nature of the anatomy of the PPS and the diversity of its contents gives rise to a wide variety of tumors. This presents an opportunity for technically challenging surgery. Current imaging modalities, including computed tomography (CT) and magnetic resonance imaging (MRI), have characterized the intricate anatomy of the PPS.[1] Once these imaging techniques became readily available, surgical techniques were subsequently devised to remove the tumors identified within the PPS.

The PPS has historically been subdivided into the prestyloid and poststyloid compartments (Figs. 69.1 and 69.2).[1] The two compartments are divided by the fascia of the tensor veli palatini as it extends from the styloid process to its insertion on the lateral pterygoid plate. The prestyloid compartment lies deep to the masticator space, with the deep lobe of the parotid extending into its lateral aspect. The prestyloid PPS contains the deep lobe of the parotid gland, adipose tissue, small blood vessels, lymphatics, and minor nerves. The poststyloid compartment, also termed the carotid space, encompasses the carotid sheath and is traversed by cranial nerves IX, X, and XII. The cervical sympathetic chain lies posterior to the carotid artery.[1] This information is invaluable in developing a differential diagnosis and plan of management for these tumors. The remainder of this chapter focuses on the management of tumors found within the prestyloid PPS.

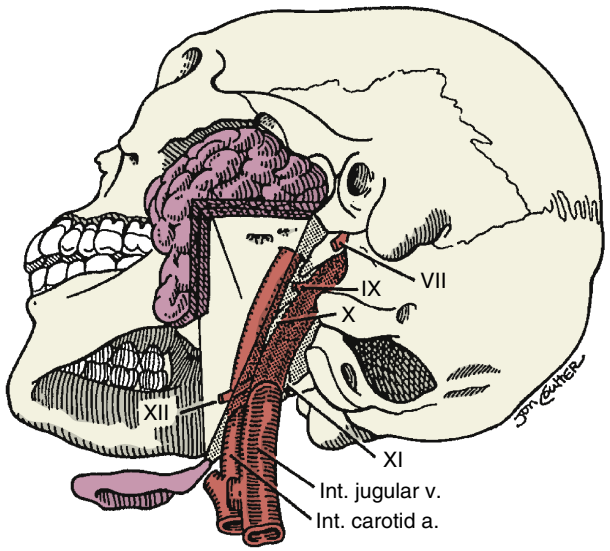

Fig. 69.1. Diagram of parapharyngeal space. *(Reprinted with permission from Carrau RL, Myers EN, Johnson JT: Management of tumors arising in the parapharyngeal space. Laryngoscope 100:583-589, 1990.)*

KEY OPERATIVE LEARNING POINTS

1. The PPS is described as being an inverted triangle extending from the skull base to its apex at the hyoid bone (see Fig. 69.1).
2. The vast majority of tumors within the prestyloid PPS are of salivary gland origin, most commonly pleomorphic adenomas.[2-4]
3. The prestyloid PPS is ideally approached using the transcervical submandibular operative technique.

PREOPERATIVE PERIOD

History

1. History of present illness: The signs and symptoms associated with tumors that arise in the PPS are numerous and depend on both the location within the PPS as well as the histologic type.
   a. Location
      1) The most common presentation is an asymptomatic mass in the lateral wall of the oropharynx with or without a mass in the parotid or neck (Figs. 69.3 and 69.4).[2,3]
      2) Large tumors in the prestyloid PPS may present with otalgia, aural fullness, or temporomandibular joint tenderness likely related to the mass effect of the tumor on surrounding structures.[2]
      3) Tumor expansion may interfere with swallowing, breathing, or the proper fit of dentures.
   b. Histology
      1) Benign tumors often present as a submucosal asymptomatic mass in the oropharynx.
      2) Malignant tumors are more often associated with the presence of pain or neuropathy or, less frequently, facial nerve weakness.
2. Past medical and surgical history
   a. A prior history of parotid tumors or cancer should be elicited from the patient.
   b. Has the patient had parotid surgery in the past or a history of radiation?
   c. Is there a history of autoimmune disease, skin cancer, or lymphoma?

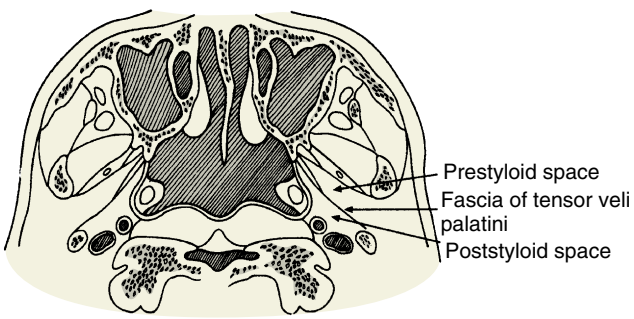

Fig. 69.2. The fascia of the tensor veli palatini muscle divides the parapharyngeal space into a prestyloid and a poststyloid compartment.

3. Family history
   a. In patients suspected of having paragangliomas within the poststyloid compartment, a family history of paragangliomas should be sought.
4. Medications
   a. Antiplatelet and anticoagulation medications, including herbal products, should be elicited prior to surgery.

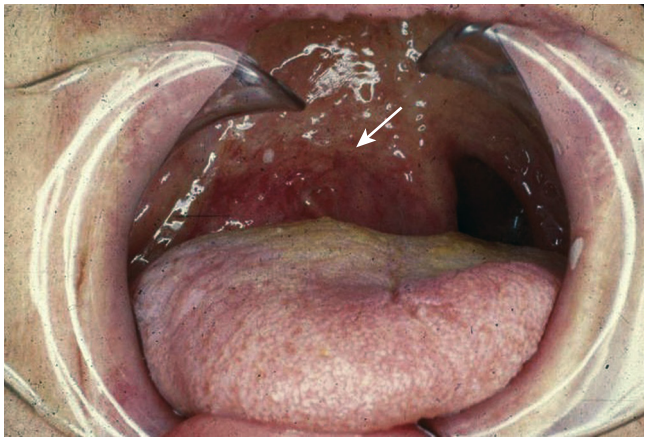

Fig. 69.3. Typical appearance of a tumor of the parapharyngeal space displacing tonsil and uvula medially *(arrow)*.

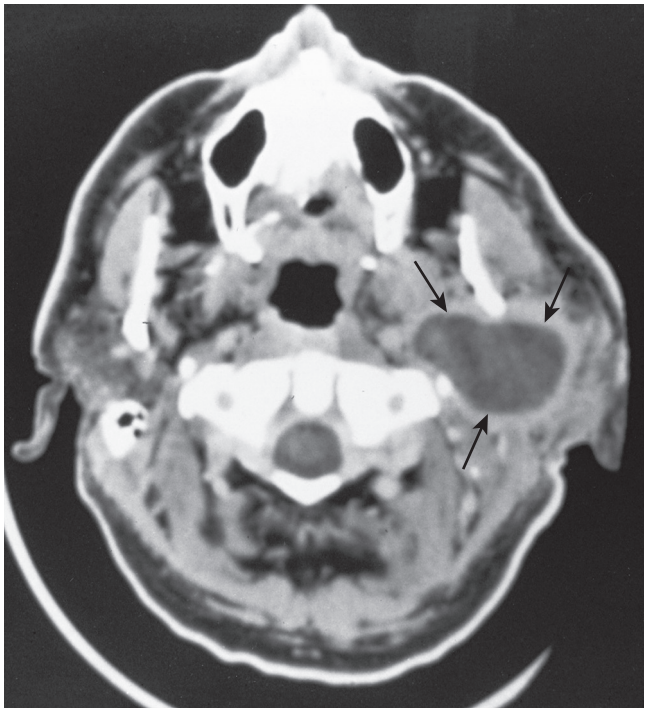

Fig. 69.4. Axial computed tomography scan of a pleomorphic adenoma originating in the deep lobe of the parotid gland with extension through the stylomandibular tunnel into the prestyloid parapharyngeal space *(arrows)*.

5. Social history
   a. A tobacco and alcohol history should be obtained.

Physical Examination

1. Oral cavity/oropharynx
   a. The PPS is bounded laterally by the mandible, superiorly by the skull base, and medially by the buccopharyngeal fascia and the constrictor muscles of the pharynx. Because two sides of the PPS are bone, tumors arising in the PPS expand along the path of least resistance toward the soft tissue of the pharyngeal wall, displacing the wall and the tonsil to present as a submucosal and often asymptomatic mass in the pharynx.
   b. Direct palpation of the tumor both intraorally and extraorally is essential.
   c. Deviation of the uvula away from the affected side is occasionally seen with large tumors.
2. Cranial nerve examination
   a. Cranial nerve VII neuropathy may indicate facial nerve involvement of a tumor arising from the deep lobe of the parotid gland.
   b. Other cranial nerve neuropathies suggest poststyloid involvement of a PPS lesion.
3. Neck
   a. Large prestyloid PPS tumors may present with fullness in the neck and/or parotid region.
   b. Palpable cervical lymphadenopathy may represent metastatic disease.
4. Flexible fiberoptic laryngoscopy
   a. This is a critical aspect of the head and neck examination in a new patient with a lesion of the PPS. Often a submucosal lateral pharyngeal mass is visualized on flexible laryngoscopy. Vocal cord movement should also be evaluated for cranial nerve X involvement of a poststyloid PPS lesion.

Imaging

All patients suspected of having a tumor in the PPS should undergo imaging studies. Both contrast-enhanced CT and gadolinium-enhanced MRI provide excellent detail for evaluating lesions of the PPS.[1,5] The distinction between tumors of the prestyloid and poststyloid space is determined radiographically based on a clear understanding of the anatomy in this region.

CT scan with contrast is often used due to its excellent anatomic detail, ease of use, and accessibility and can be done in patients with contraindications to MRI (Table 69.1). However, when possible, many radiologists advocate the use of gadolinium-enhanced MRI with T1- and T2-weighted images for optimal characterization of tumors in the PPS.[1,5] Furthermore, MRI is the optimal technique when there is suspicion of intracranial extension or nerve involvement.

Prior to evaluating imaging characteristics of a lesion, it is critical to identify that the lesion originates in the PPS and is not an extension of a lesion from an adjacent space.[1] Visualizing a margin of adipose tissue separating the lesion from the bordering space is paramount to not only confirming that a lesion

TABLE 69.1 Correlation of Imaging Studies and Operative Findings in Tumors of the Parapharyngeal Space

Computed Tomography Scan
• Accurately defined position of the tumor relative to the styloid in 96% (43/45) of the cases • Correct identification of the origin of salivary gland tumors (parotid vs. nonparotid) in 88% (14/16) of the cases • Assessment of the tumor vascularity correlated with the angiographic findings (28/28) as well as with the surgical findings (45/45)

From the Department of Otolaryngology, University of Pittsburgh.

originated in the PPS but also formulating the differential diagnosis. Tumors that arise de novo in the PPS independent of the parotid gland have an adipose tissue plane separating it from the deep lobe of the parotid gland (Fig. 69.5). Conversely a deep lobe parotid mass located within the prestyloid PPS will show obliteration of the adipose tissue plane at the posterolateral margin of the PPS.[1,5] This is a very important point in the differential diagnosis, because tumors that are independent of the parotid gland may be removed through a cervical approach, whereas tumors arising in the deep lobe of the parotid gland with extension into the PPS must be approached through a parotid-submandibular approach in order to avoid injury to the facial nerve.

Indications

Patients with prestyloid PPS tumors should be offered surgical treatment if they are healthy enough to undergo a general anesthesia. Even patients with pleomorphic adenomas of the prestyloid PPS benefit from surgery, given the risk of malignant transformation if these tumors are merely observed.

Relative Contraindications

1. Medical comorbidities with increased risk for general anesthesia
2. Significant cervical stenosis or fusion preventing neck rotation and extension
3. Vascular tumors with variable vascular supply
   a. These are more likely to present in the poststyloid PPS.

Preoperative Preparation

1. Review imaging studies to confirm tumor location in the prestyloid PPS.

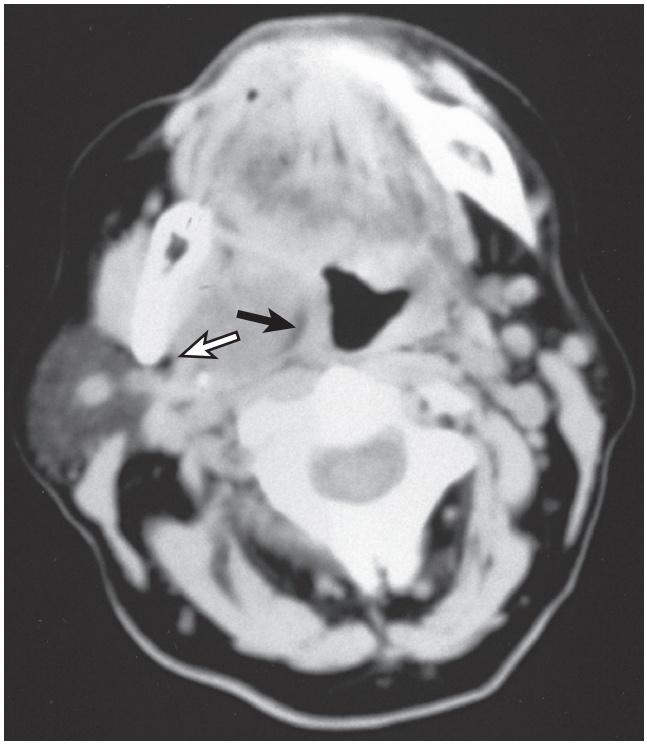

Fig. 69.5. Computed tomography scan demonstrating a pleomorphic adenoma arising de novo in the prestyloid parapharyngeal space. The tumor displaces adipose tissue medially *(closed arrow).* An adipose tissue plane separates the tumor from the parotid gland *(open arrow).*

2. Consider fine-needle aspiration (FNA) to obtain preoperative diagnosis.
   a. The role of FNA in the evaluation of patients presenting with a PPS mass is controversial.[6,7] Some clinicians advocate its use for unusual cases, given that nonneoplastic processes, such as branchial cleft cysts and inflammatory masses, may occasionally present in the PPS.[7] Given the difficult location of the PPS, CT-guided FNA is typically employed via a transfacial approach.[7]
3. Discontinue antiplatelet medications, if possible, and optimize the patient's medical status prior to surgery.

OPERATIVE PERIOD

Anesthesia

General anesthesia: Given the deep location of the prestyloid PPS and the amount of dissection necessary to expose this area, general anesthesia with oral intubation is recommended.

Positioning

The patient is placed in the supine position with the neck extended and rotated away from the surgeon. A shoulder roll is helpful to achieve maximum extension.

Perioperative Antibiotic Prophylaxis

- First-generation cephalosporin
- Second-generation cephalosporin
- Clindamycin, if the patient is allergic to penicillin

Monitoring

Facial nerve monitoring may be used depending on surgeon preference. If the PPS tumor originates from the deep lobe of the parotid gland, the trunk of the facial nerve may be in close proximity to the tumor. In these instances, facial nerve monitoring is often employed. A handheld nerve stimulator may also be used. The surgical team must communicate to the anesthesia team at the start of the case that muscle relaxants should be avoided.

Instruments and Equipment to Have Available

1. A standard head and neck set
2. Depending on surgeon preference, 0- and 30-degree endoscopes may be useful for visualizing the deepest (superior) extent of the tumor.
3. Large hemoclips and vascular instruments should be available in the event that large vessel injury occurs during the dissection.

Key Anatomic Landmarks

1. Stylomandibular ligament: Transecting this ligament improves exposure provided by the transcervical approach.[8] The styloid musculature and posterior belly of the digastric may also be removed if necessary to further enhance exposure.
2. Main trunk of the facial nerve: For prestyloid PPS tumors originating in the deep lobe of the parotid, identification and careful preservation of the facial nerve are paramount.

Prerequisite Skills

1. Parotidectomy
2. Neck dissection



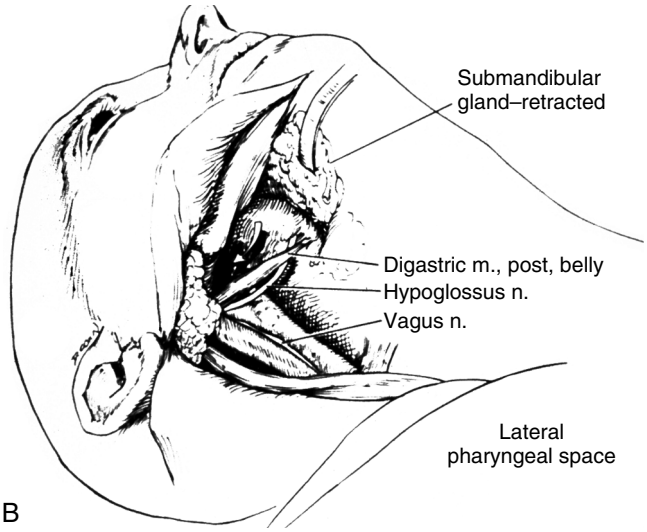

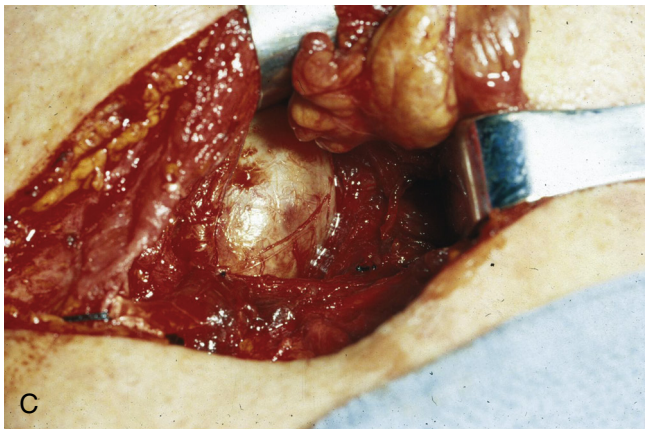

Fig. 69.6. A, Computed tomography scan demonstrating tumor of parapharyngeal space. **B,** Diagram of transcervical approach to prestyloid parapharyngeal space. Submandibular gland retracted anteriorly. **C,** Tumor seen in prestyloid parapharyngeal space. (**B,** *Reprinted with permission from Rabuzzi DD, Johnson JT: Diagnosis and Management of Deep Neck Infections. Washington, American Academy of Otolaryngology–Head and Neck Surgery Foundation, 1976.)*

Operative Risks

1. Facial nerve injury
   a. If transection occurs inadvertently, the two transected ends should be identified and reapproximated if there is minimal loss of nerve tissue. If there is a segment of nerve missing or nonviable, then a nerve graft can be used, often from the greater auricular nerve.
   b. With thermal injury, the extent of nerve damage is often difficult to determine, and clinical outcomes may vary. Typically, the operation should be completed and the patient should be placed on peri- and postoperative IV steroids with supportive postoperative care as needed.
2. Injury to cranial nerves or cervical sympathetic chain
   a. Although uncommon, these injuries tend to occur with large tumors or malignancies. During the transcervical approach, careful dissection along the great vessels and a thorough knowledge of anatomic landmarks are critical to avoiding nerve injury.

Surgical Technique

1. Transcervical submandibular approach (Fig. 69.6)
   a. The skin incision is made in the major transverse skin crease in the neck and carried down through subcutaneous tissue and platysma muscle.
   b. The marginal mandibular branch of the facial nerve must be identified and preserved.
   c. Identification of the anterior border of the sternocleidomastoid muscle facilitates identification of the posterior belly of the digastric muscle.
   d. The submandibular gland is then dissected free of the surrounding tissues and retracted anteriorly.
   e. The facial artery is clamped, transected, and doubly ligated with silk suture.
   f. Improve exposure if necessary.
      1) Transection of the posterior belly of the digastric
      2) Consider dividing the stylomandibular ligament.
      3) Anterior dislocation of the mandible may be necessary for large tumors of the PPS.

g. Using sharp and blunt dissection, the tumor is dissected free from the surrounding tissues, taking care to preserve the main trunk of the facial nerve.
h. To prevent recurrence, every effort should be made not to disrupt the capsule of the tumor.
i. Hemostasis is obtained, and the wound irrigated.
j. A suction drain is placed to collapse the dead space, and the wound is closed in a layered fashion.

2. Other surgical approaches
   a. Parotid-submandibular approach (Fig. 69.7)
      1) Ideal for patients with deep lobe parotid tumors
      2) Modified-Blair incision with transcervical extension
      3) Identify the main trunk of the facial nerve via a standard superficial parotidectomy approach; then proceed as described previously via the transcervical approach.
   b. Transoral
      1) Historic approach
      2) No longer recommended as a stand-alone approach due to inadequate exposure and risk of tumor seeding into the pharynx. See Chapter 33 on the transoral robotic approach to tumors to understand selection criteria and indications for a transoral approach.
   c. Transmandibular
   d. Transparotid
   e. Infratemporal fossa

Common Errors in Technique

1. Poor exposure
2. Violation of the tumor capsule
3. Inadequate identification of the facial nerve

POSTOPERATIVE PERIOD

Postoperative Management

1. Monitor drain output.
   a. Remove drain when output is less than 20 cc per shift.
2. Pain management
3. Swallowing evaluation as needed
4. Resumption of anticoagulants/antiplatelet medications

Complications

1. Facial nerve injury
   a. If the PPS tumor originates from the deep lobe of the parotid gland, then it is possible to injure the facial nerve, either from inaccurate dissection or traction on the nerve. Patients who have weakness or paresis from traction on the facial nerve in whom the nerve is anatomically intact should expect a return of function within 3 months.[9]
   b. Proper eye care is essential for patients with facial nerve injury. In the immediate postoperative period, a moisture chamber is used. Patients who are expected to have a prolonged recovery phase benefit from insertion of a gold weight into the upper eyelid.
2. First bite syndrome
   a. This is characterized by a cramping pain in the parotid region after the first bite of each meal. The pain lasts a few seconds, improves with each bite, and is extinguished over the next several bites. Symptoms are at their worst with the first bite of food in the meal.[10]
   b. Treatment options are limited with no well-documented medical treatment available. Some clinicians advocate the use of Botox injections into the affected parotid gland to reduce the severity of symptoms. Surgical treatment requires transmeatal excision of Jacobson's plexus on the promontory of the middle ear.
3. Sialocele
   a. Exposure of raw parotid tissue or transection of the parotid duct can lead to the accumulation of saliva in the wound. Treatment often begins conservatively with a pressure dressing. If the sialocele grows or fails to resolve, needle aspiration is indicated. Botox injections are useful in reducing the production of saliva into the wound bed. Finally, surgical exploration in the operating room should be considered in refractory cases.
4. Hemorrhage
   a. Avoidance of anticoagulants preoperatively and careful dissection help prevent this potentially life-threatening complication.

Alternative Management Plan

1. Radiation therapy
   a. Reserved for unresectable disease and/or patients who are medically inoperable
   b. Often delivered as intensity modulated radiation therapy (IMRT) to target tumor cells while sparing adjacent critical tissues and structures
2. Chemotherapy
   a. Platinum-based agents are occasionally used in conjunction with radiation therapy in patients with good performance status and unresectable disease.

DISCUSSION

Evidence-Based Medicine Question

What are the indications for adjuvant radiotherapy in patients with prestyloid PPS tumors?

Although surgery is the mainstay in treatment of prestyloid PPS tumors, adjuvant radiotherapy is recommended at times to improve outcomes. Patients with malignant major salivary gland tumors with high-risk features benefit from adjuvant radiotherapy. High-risk features include advanced stage, high-grade tumor, positive surgical margins, and recurrent tumors. Data from the Surveillance, Epidemiology, and End Results (SEER) database have demonstrated improved locoregional recurrence rates and improved overall survival in such patients who were treated with adjuvant radiotherapy as opposed to surgery alone.

Editorial Comment

PPS tumor surgery is challenging due to the proximity of critical structures and limited access. The success is not gauged only by complete tumor removal but also by avoidance of tumor spillage, which can have significant repercussions. Multifocal recurrence in the PPS of commonly occurring pathology such as pleomorphic adenomas can be devastating for the patient and difficult to treat. Similarly, cranial neuropathy can also cause significant morbidity to the patient affecting speech, swallowing, and facial nerve function. PPS tumor surgery should be systematic and meticulous. Critical cranial nerves pathways (VII, IX, X, XI, and XII) must be identified to allow preservation and maximum mobilization for tumor delivery. Similarly, efforts must be taken to provide wide access by taking steps such as dividing the stylomandibular ligament, facilitating adequate distraction of the mandible. In rare instances, a mandibulotomy may also be necessary to provide wide exposure to avoid tumor spillage. Critical vasculature (carotid and jugular systems) must be identified and proximal control obtained before tumor dissection can begin. With the advent of newer technology, transoral surgery with or without endoscopic or robotic guidance has become a possibility; these

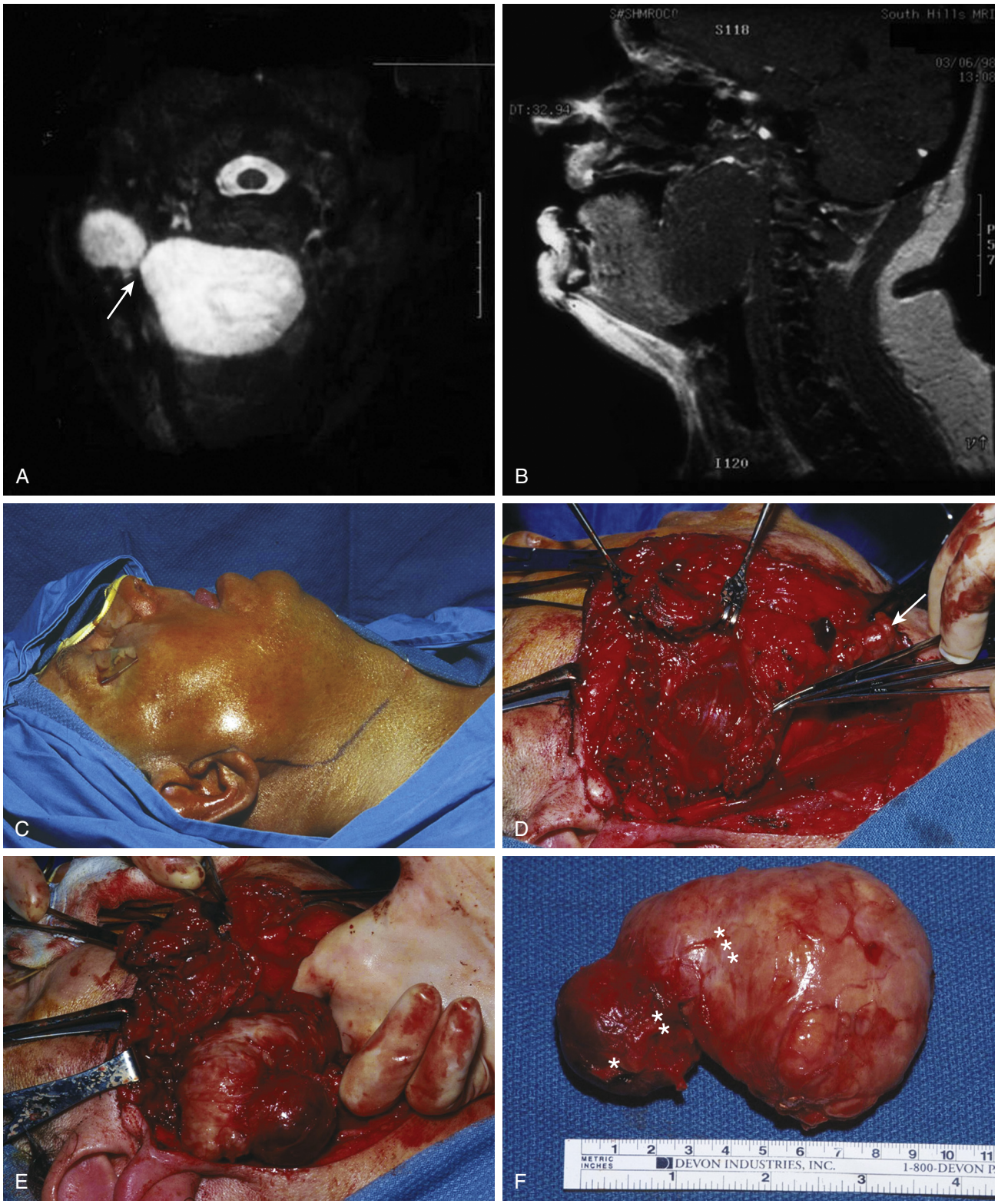

Fig. 69.7. A, Axial magnetic resonance (MR) scan revealing a tumor originating in the deep lobe of the parotid gland with massive extension into the parapharyngeal space. The dark line *(arrow)* reflects the impression of the stylomandibular ligament. **B,** Sagittal MR scan demonstrating almost complete obstruction of airway. **C,** Large parotid mass noted. The parotid submandibular incision is outlined. **D,** Facial nerve dissected free from the deep lobe of parotid gland. Submandibular gland retracted anteriorly *(arrow).* **E,** Blunt dissection through the submandibular space into the parapharyngeal space releases the tumor. **F,** Specimen revealing tumor originating in deep lobe of parotid gland (single left asterix), impression of stylomandibular ligament (double asterix) and parapharyngeal component of the tumor (triple right asterix).

sophisticated approaches must be performed by highly experienced surgeons using careful case selection.

Jessica H. Maxwell

Access the review questions and additional sources list online at http://www.expertconsult.com

REFERENCES

1. Gupta A, Chazen JL, Phillips D. Imaging evaluation of the parapharyngeal space. Otolaryngol Clin North Am 2012;45(6):1223–1232.
2. Hughes KV, Olsen KD, McCaffrey TV. Parapharyngeal space neoplasms. Head Neck 1995;17:124–130.
3. Myers EN, Johnson JT, Curtin HD. Tumors of the parapharyngeal space. In: Myers EN, Suen JY, Myers JN, Hanna EY, editors. Cancer of the Head and Neck. 4th ed Philadelphia: WB Saunders; 2003. p. 511–530.
4. Mendelsohn AH, Bhuta S, Calceterra TC, et al. Parapharyngeal space pleomorphic adenoma: a 30-year review. Laryngoscope 2009;119:2170–2174.
5. Liu XW, Wang L, Li H, et al. A modified method for locating parapharyngeal space neoplasms on magnetic resonance images: implications for differential diagnosis. Clin J Cancer 2014;33(10):511–520.
6. Oliai BR, Sheth S, Burroughs FH, et al. "Parapharyngeal space" tumors: a cytopathological study of 24 cases on fine-needle aspiration. Diagn Cytopathol 2005;32(1):11–15.
7. Ohmann EL, Branstetter BF, Johnson JT. The utility of fine needle aspiration to identify unusual pathology in a parapharyngeal mass. Am J Otolaryngol 2011;32(1):82–84.
8. Orabi AA, Riad MA, O'Regan MB. Stylomandibular tenotomy in the transcervical removal of large benign parapharyngeal tumours. Br J Oral Maxillofac Surg 2002;40:313–316.
9. Cohen SM, Buckey BB, Netterville JL. Surgical management of parapharyngeal masses. Head Neck 2005;27:669–675.
10. Chiu AG, Cohen JI, Burningham AR, et al. First bite syndrome: a complication of surgery involving the parapharyngeal space. Head Neck 2002;24:996–999.

REVIEW QUESTIONS

1. Name the anatomic landmark separating the prestyloid from the poststyloid compartment.
   a. Stylomandibular ligament
   b. Tensor veli palatini
   c. Styloid process
   d. Lateral pterygoid muscle
   e. Medial pterygoid muscle

2. The most common tumor of the prestyloid PPS has the following histology:
   a. Zellballen pattern of cells
   b. Double layer epithelium with cysts and papillary projections
   c. Epithelial nests with myoepithelial and stromal components
   d. Cords of uniform cells with thin fibrous stroma
   e. Spindle cells with eosinophilic cytoplasm and cigar-shaped nuclei

3. A deep lobe parotid tumor within the prestyloid PPS displaces the PPS adipose tissue in which direction?
   a. Anteromedial
   b. Posterolateral
   c. Superior
   d. Posterior
   e. Posteroinferior

ADDITIONAL SOURCES

Mahmood U, Koshy M, Goloubeva O, et al. Adjuvant radiation therapy for high-grade and/or locally advanced major salivary gland tumors. Arch Otolaryngol Head Neck Surg 2011;137(10):1025–1030.

Oh YS, Russell MS, Eisele DW. Salivary gland neoplasms. In: Johnson JT, Rosen CA, editors. Bailey's Head and Neck Surgery Otolaryngology. 5th ed Philadelphia: Lippincott Williams & Wilkins; 2014. p. 1760–1787.

70 Transoral Approach to the Parapharyngeal Space

Christopher H. Rassekh, Kyle Hatten

INTRODUCTION

The management of patients with tumors of the parapharyngeal space (PPS) is a challenge for head and neck surgeons. The diverse anatomic structures in the PPS give rise to many different tumors, and the relationship of such lesions to critical neurovascular contents provides a technical challenge during surgery. Various operative techniques have been described to safely approach this deep neck space. However, while considering that 80% of PPS tumors are benign,[1] the correct approach to minimize surgical morbidity while successfully treating the patient should be chosen. Of the many approaches to the PPS, the transoral approach has been an ideal technique for carefully selected tumors and minimizes complications experienced with other surgical alternatives.

KEY OPERATIVE LEARNING POINTS

- The transoral approach to the PPS should be reserved for benign prestyloid tumors.
- Fine-needle aspiration should be performed preoperatively to rule out malignancy.
- Cross-sectional imaging should identify that the carotid artery is displaced posterolaterally.
- The transoral robotic approach can provide improvement in optics of the surgical procedure and allow for a surgical assistant at the bedside to facilitate dissection.
- Blunt dissection, meticulous hemostasis, and careful attention to closure of the pharyngeal incision are critical in avoiding complications.

PREOPERATIVE PERIOD

History

- Most patients are asymptomatic, with tumors incidentally found during unrelated imaging.
- When symptomatic, patients commonly present with awareness of an intraoral mass or a mass in the neck.
- Facial pain or cranial neuropathies are usually associated with malignant lesions, which are not amenable to transoral removal.

Physical Examination

- Oral cavity/oropharyngeal exam ination: The most common finding is a mass displacing the tonsil/soft palate or both, medially. In addition, the mouth opening should be adequate for transoral surgical exposure.
- Examination of the neck may demonstrate a palpable mass. However, only 28% of patients present with both an intraoral and external neck mass.[2]
- Additional findings may include paralysis of the vocal cord and/or palate, middle ear fluid on the side of the lesion, Horner's syndrome, and pulsations over the mass in the neck.

Imaging

- Cross-sectional imaging with contrast-enhanced computed tomography (CT) or magnetic resonance imaging (MRI) is used to determine the relationship of neoplasms to vasculature structures. In addition, imaging provides information on the location of the tumor in the prestyloid versus poststyloid space.
- Imaging can provide information on the vascularity of the mass.
- Transoral fine-needle aspiration (FNA) of palpable and visible lesions is usually well tolerated by patients in the office setting. However, inadequate stabilization of PPS masses as well as limits of intraoral angles may require a CT-guided FNA through the skin, rather than making a "blind" pass toward a mass with large caliber vasculature structures adjacent to the lesion.

Indications

- Benign cysts/neoplasms isolated to the prestyloid PPS
  - Salivary gland neoplasms; most commonly pleomorphic adenomas
  - Trigeminal nerve branch schwannomas
  - Lipomas

Contraindications

- Malignant tumors
- Poststyloid PPS masses
- Patients with significant trismus
- Vascular tumors such as paragangliomas due to proximity to the carotid artery
- Tumors involving the skull base
- Tumors with significant extension to the deep lobe of the parotid or the stylomandibular tunnel

OPERATIVE PERIOD

Anesthesia

General endotracheal intubation with the tube in the side of the nose opposite the mass

Positioning

- Supine
- Robotic-assisted cases should have the bed positioned flat and with the operating table as low as possible to maximize the access of mechanical arms in the operative field. A constant communication is important with the anesthesia team to ensure that the bed position is not moved during surgery without adjusting the position of the robotic arms, since the robot with its arms docked in the oral cavity is fixed in position relative to the bed and the patient.

Perioperative Antibiotic Prophylaxis

Preoperative antibiotics may be given within 60 minutes of the mucosal incision to provide coverage for oral flora.

Monitoring

Monitoring by the Anesthesia Team

The patient should be paralyzed to improve mouth opening.

Instrument and Equipment to Have Available

- Modified (for transoral robotic surgery [TORS]) Crowe-Davis mouth gag (Fig. 70.1)
- A da Vinci surgical system robot is not required but improves surgical optics and allows for "4 handed" surgery, rather than a single bedside surgeon.
- 0-degree endoscope placed at center robotic arm. Thirty-degree endoscope is useful in select cases to visualize the superior aspect of the PPS.
- Monopolar cautery with spatula tip placed in robotic arm ipsilateral to PPS lesion
- 5-mm endowrist Maryland dissector can be used in a contralateral robotic arm
- Two Yankauer suctions are used bedside by the assistant to provide retraction and evacuate blood and smoke.
- Bipolar cautery should be available for precise cautery while dissecting in close proximity to neurovascular structures.

Key Anatomic Landmarks

- Surgical view should have exposure of anterior tonsillar pillar and have oral tongue displaced to the contralateral side of the lesion.
- Pterygomandibular raphe should be identified and be the lateral border of surgical dissection.

Prerequisite Skills

- Prior extensive experience with da Vinci surgical system
- Comprehension of anatomic boundaries and contents of PPS
- Experience with open, transcervical approaches to the PPS

Operative Risks

- Injury to lip, gums/teeth during placement of the mouth gag
- Injury to the lingual nerve
- Major hemorrhage
- Dehiscence of mucosal incision
- Infection of surgical site

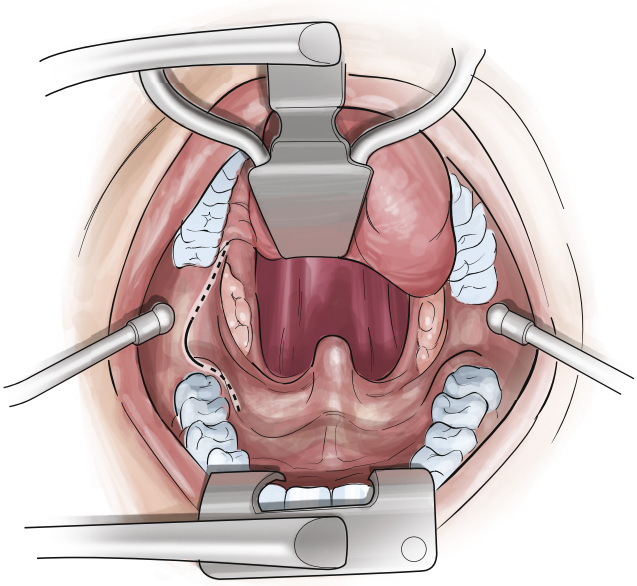

Fig. 70.1. Crowe-Davis mouth gag provides exposure of the surgical field. The tongue is lateralized to improve surgical access.

Surgical Technique

- Approach
  - Exposure of the surgical field is attained with a Crowe-Davis mouth gag, with attention to displacing the oral tongue away from side of the planned surgical incision.
  - The mucosal incision is made in a curvilinear fashion over the soft palate, making sure to stay superficial and not violate the tumor capsule. Care is taken to avoid injury to the lingual nerve and to preserve adequate mucosa for closure.
  - Blunt dissection to approach the pterygomandibular raphe and lateralizing the fascia while maintaining the pharyngeal constrictor musculature medially
  - The exposure of the tumor is aimed toward allowing circumferential access to the border of the lesion. Superior medial pterygoid muscule fibers are dissected and transected as needed to gain exposure superiorly and laterally (Fig. 70.2).
  - The stylohyoid musculature *does not* need to be divided, as the lesion lies in the prestyloid PPS.
- Tumor dissection
  - The spatula tip cautery can then be used as a blunt dissector to sweep away the soft tissue from the tumor. Meanwhile, the bedside assistant can retract with suctions to provide exposure.

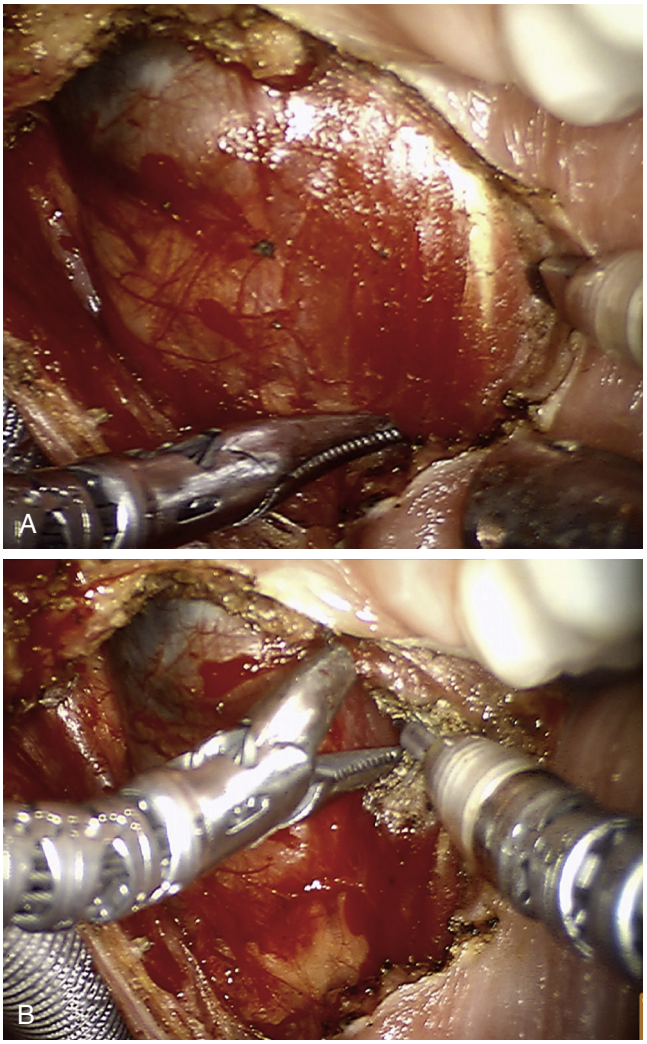

Fig. 70.2. Medial pterygoid musculature is isolated and released to gain access to the parapharyngeal space.

- It is helpful to have the assistant use one suction for retraction and the other to evacuate fluid and smoke.
- The Crowe-Davis mouth gag can be removed to allow for finger dissection at the bedside by the surgeon to feel for fascial attachments. In addition, palpation allows for assessment of the internal carotid artery pulsations to identify the anatomic relationship to the artery (Fig. 70.3).
- If the tumor's superior attachment is not visualized, a 30-degree scope can be used to facilitate exposure and further dissection.
- A hybrid approach is occasionally required when blunt dissection is performed by both the surgeon at the console and the bedside surgeon. The robotic arms can be used for retraction to expose the surgical field, while the bedside assistant performs blunt dissection. Very limited sharp dissection may be cautiously performed and only under direct visualization.

- Closure
  - Following delivery of the tumor, careful inspection of the tumor capsule should be performed to ensure it has not been ruptured.

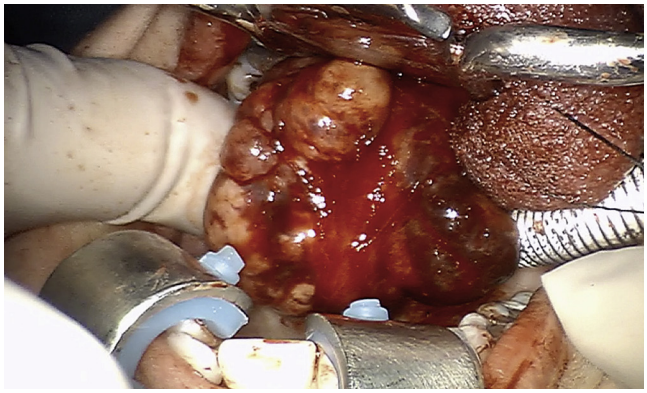

Fig. 70.3. Finger dissection performed by the bedside surgeon helps facilitate delivery of the mass. Digital palpation also allows for localization of the internal carotid artery in the parapharyngeal space.

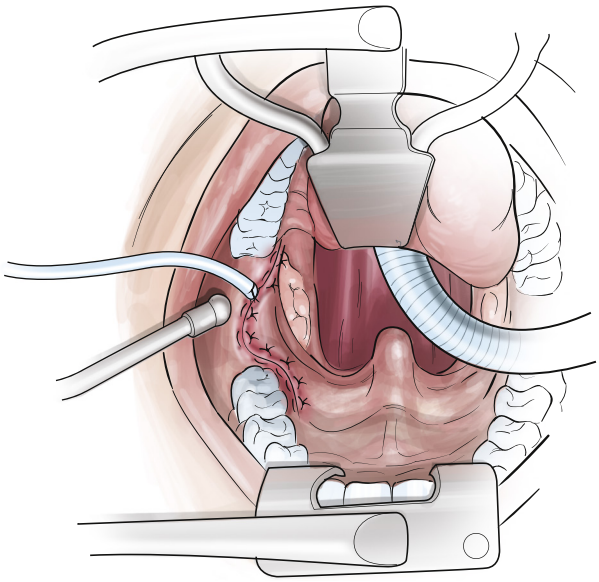

Fig. 70.4. Soft palate mucosa is closed with horizontal mattress suture. Penrose drain is placed within the suture line.

  - Irrigation is performed with water followed by normal saline.
  - Horizontal mattress 3-0 Vicryl sutures are placed through mucosa and musculature to complete a muscle flap/pharyngoplasty closure. A single ¼″ Penrose drain is placed in the midportion of the incision to allow for drainage of any fluid that may accumulate (Fig. 70.4).
  - The drain can be secured with tape on the external skin and removed the following day.
  - Jaw Bra may be used to apply pressure to the PPS.
  - Extubation is performed at the completion of the procedure.

Common Errors in Technique

- Failure to release the medial pterygoid musculature limits the ability to deliver the tumor from PPS.
- Traumatic blunt dissection resulting in rupture of the tumor capsule
- Inadequate closure around the Penrose drain, resulting in wound dehiscence
- Insufficient hemostasis

POSTOPERATIVE PERIOD

Postoperative Management

- The drain is removed on the first postoperative day.
- Diet should be limited to liquids until the mucosa is healed. A soft diet should be maintained for approximately 2 weeks.

Complications

- Immediate
  - Edema of the tongue or hematoma requiring delayed extubation
  - Lingual nerve injury while extending the mucosal incision along the floor of the mouth
  - Major nerve or vascular injury, which has not occurred in our series
- Delayed
  - Dehiscence of pharyngoplasty closure may occur and is commonly seen when drain placement leaves a large pharyngeal defect. Management of such a complication with limited oral intake allows for healing by secondary intention. This complication has been largely avoided by using horizontal mattress sutures with careful attention to detail and the dietary regimen noted previously.
  - First bite syndrome that was experienced in a patient who had a resection of a Schwannoma

Alternative Management Plan

- Transcervical, transparotid, or transmandibular or combination approach to PPS. These alternative surgical techniques should be discussed with all patients.
  - In addition, patients should be consented preoperatively for possible transcervical approach, if the surgeon identifies that the patient has inadequate transoral exposure or he/she is concerned with rupture of tumor capsule.
- Observation of benign prestyloid PPS tumors

DISCUSSION

Evidence-Based Medicine Question

Is there evidence to suggest that the robotic approach has advantages over the open technique?

PPS tumors: TORS versus open approaches

The transoral approach to PPS tumors was described in 1920 as an effective technique for surgical removal; however, piecemeal removal was often required due to anatomic constraints of surgical dissection.[3] Open approaches increased in popularity with the improvement of safety measures during surgery. The transcervical approach became the most widely accepted and described technique. This surgical dissection requires a cervical lymphadenectomy of level II and frequently requires removal of the styloid process and its associated musculature. The access provided by the transcervical approach allows excellent exposure to the neurovascular structures located in the poststyloid PPS, "carotid space," including the internal carotid artery, internal jugular vein, lower cranial nerves, and the sympathetic chain.

In recent years, advances in surgical techniques of the transoral approach were introduced with the da Vinci Surgery System. O'Malley et al. described the first series of patients with benign prestyloid PPS tumors removed using TORS and demonstrated high local control and low complication rates.[4] TORS provided improved visual optics and the ability to use a surgical bedside assistant to enhance exposure and surgical feasibility. The surgical technique was reserved for select patients, including those with benign tumors confirmed on needle aspiration and lesions confined to the prestyloid PPS. TORS approach to the PPS did not result in any of the most commonly described complications reported with open approaches, including first bite syndrome (12%) and facial nerve weakness (4%).[5] In addition, transoral approaches avoid the need for a skin incision and consequently a visible scar.

Critics of the transoral approach express reservations about the risk of tumor rupture that may lead to recurrence. However, reserving this surgical technique for tumors in the prestyloid PPS obviates the risk of traumatic rupture by the styloid process, as this anatomic structure is posterior to the surgical dissection. In addition, we believe the robot offers improvement with visualization and tremor stabilization that enhances the safety profile of the transoral approach. Also, the primary surgeon is removed from the surgical field during TORS to allow an assistant to actively participate in the dissection at the bedside.

The TORS approach to the PPS has most frequently been performed for resection of pleomorphic adenomas arising in minor salivary glands, which are separate from the deep lobe of the parotid gland. Regardless of the surgical technique chosen by the surgeon, transcervical or transoral, the dissection will require blunt dissection. The major advantage in the transoral approach is the avoidance of an external scar, decreased risk of facial nerve injury, and lower incidence of first bite syndrome. However, the transoral approach requires careful surgical technique to avoid injury to the lingual nerve and pharyngeal wound dehiscence. Also, the transoral approach requires long-term follow-up to ensure the tumor rupture and recurrence are not more common.

Transoral approach chosen in appropriately selected patients in very experienced hands offers an approach that minimizes specific aspects of surgical morbidity while still providing excellent tumor removal.

Editorial Comment

The important aspect of TORS or other transoral approaches to PPS tumors is case selection, ensuring that the oral cavity permits adequate surgical exposure and access. One of the key components of PPS tumor surgery is digital palpation and blunt dissection (often blunt finger dissection). While the robot provides excellent visualization, dexterity, and access and permits assistant participation, it does not currently have true haptic feedback. Consequently, hybrid techniques that involve maximizing the benefits of the robotic technology coupled with open surgery concepts (i.e., blunt dissection and finger palpation of the tumor at the bedside) are critical to safe outcomes in these cases. In agreement with the author, transoral approaches (robotic or nonrobotic) must be considered only by expert surgeons with an extensive experience with open techniques and knowledge of transoral and PPS anatomy.

Rohan R. Walveker

Access the review questions and additional sources list online at http://www.expertconsult.com

REFERENCES

1. Carrau RL, Myers EN, Johnson JT. Management of tumors arising in the parapharyngeal space. Laryngoscope 1990;100(6):583–589.
2. Hughes KV, Olsen KD, McCaffrey TV. Parapharyngeal space neoplasms. Head Neck 1995;17(2):124–130.
3. New GB. Mixed tumors of the throat, mouth and face. J Am Med Assoc 1920;75(11):732–736.
4. O'Malley BW, Quon H, Leonhardt FD, et al. Transoral robotic surgery for parapharyngeal space tumors. ORL J Otorhinolaryngol Relat Spec 2010;72(6):332–336.
5. Cohen SM, Burkey BB, Netterville JL. Surgical management of parapharyngeal space masses. Head Neck 2005;27(8):669–675.

REVIEW QUESTIONS

1. Transoral approach to the parapharyngeal space (PPS) requires release of which muscle to gain better exposure?
   a. Superior pharyngeal constrictor muscles
   b. Styloglossus
   c. Medial pterygoid
   d. Stylohyoid

2. What is a contraindication to the transoral approach to PPS?
   a. Displacement of internal carotid artery posteriorly
   b. Trigeminal nerve schwannoma
   c. Elongated styloid process
   d. Vascular tumors

3. What is the most common complication of the transoral approach to PPS?
   a. First bite syndrome
   b. Marginal mandibular nerve weakness
   c. Dehiscence of pharyngeal mucosa closure
   d. Stroke

ADDITIONAL SOURCES

Linkov G, Morris LG, Shah JP, et al. First bite syndrome: incidence, risk factors, treatment, and outcomes. Laryngoscope 2012;122:1773–1778.

Kawashima Y, Sumi T, Sugimoto T, et al. First-bite syndrome: a review of 29 patients with parapharyngeal space tumor. Auris Nasus Larynx 2008;35:109–113.

Goodwin Jr. WJ, Chandler JR. Transoral excision of lateral parapharyngeal space tumors presenting intraorally. Laryngoscope 1988;98:266–269.

Rassekh CH, Weinstein GS, Loevner LA, O'Malley BW. Transoral robotic surgery for prestyloid parapharyngeal space masses. Op Tech Otolaryngol 24:99–105.

71 Posterolateral Neck Dissection

Natalie L. Silver, Jeffrey N. Myers

INTRODUCTION

The posterolateral neck dissection is an operation that is typically used in the management of cutaneous cancers of the posterior scalp, auricle, or upper neck. It is done either electively, to stage the clinically node-negative neck, or therapeutically, to treat the node-positive neck. In contemporary practice, this operation is most often used to treat a clinically node-negative neck that has been found to have microscopically positive nodal disease in one or more of the regional nodal basins. The posterolateral neck dissection is an extended neck dissection that is often combined with a comprehensive or selective neck dissection. A description of this operation was first published in 1962. More recently, however, in 1980, Drs. Goepfert, Jesse, and Ballantyne of the M.D. Anderson Cancer Center wrote a definitive description of this procedure and their results with it.[1,2] Typically this operation involves the removal of the lymph nodes in the postauricular, suboccipital, spinal accessory, and jugular lymph node basins (Fig. 71.1). In experienced hands, this operation provides excellent oncologic, functional, and cosmetic results.

KEY OPERATIVE LEARNING POINTS

1. The spinal accessory nerve must be identified on the anterior and posterior border of the sternocleidomastoid muscle (SCM) and traced in its entirety to prevent inadvertent injury to this structure.
2. During the procedure, fibroadipose node-bearing tissue is removed from the inferolateral portion of the neck where the trapezius and clavicle meet. Extreme caution must be exercised in this region to avoid injury to inferolateral branches of the brachial plexus and the terminal aspect of the spinal accessory nerve.

PREOPERATIVE PERIOD

History

1. Personal history of skin cancer: The majority of patients undergoing posterolateral neck dissection have skin cancer as the primary indication for the procedure (Fig.71.2); therefore, a history of prior skin cancers is useful in treatment planning. This includes histologic type, location, and previous treatment (history of surgery or radiation treatment for skin cancer).
2. History of sun exposure
3. Family history of skin cancer
4. Occupational history: This operation, when performed without complication, can lead to decreased shoulder function for up to 18 months following surgery. Typically this is manifested by a decreased range of motion and strength on shoulder abduction, which, with intervention by a trained physical therapist, can be improved greatly with anticipated return to baseline.

Physical Examination

1. Skin
   a. Visual evaluation and palpation of the extent of the primary tumor
      1) Include examination of the skin of the head and neck, especially the scalp, and auricle.
2. Neck
   a. Inspect and palpate the postauricular, suboccipital, spinal accessory, and jugular nodal basins.
      1) Note the number and size of each involved node and use as part of the clinical staging.
      2) Assess the extent of nodal burden and involvement of regional structures.
3. Nerve function: Evaluate and document preoperative function of the spinal accessory nerve and brachial plexus, because these nerves will be at risk for injury during the dissection.

Imaging

1. Axial computed tomography (CT) scan with contrast
   a. Define the location and extent of the primary cancer.
   b. Assess regional lymph node metastases.
2. Magnetic resonance imaging (MRI) or positron emission tomography (PET)/CT
   a. Systemic imaging may be indicated based on the histology and clinical stage of the disease.
      1) For patients with melanoma or Merkel cell carcinoma with thick primary tumors or extensive lymph node metastasis, a PET/CT and brain MRI or brain MRI with CT scan of the head and neck, chest, and abdomen should be ordered for a complete metastatic evaluation.

FINE-NEEDLE ASPIRATION BIOPSY

1. Fine-needle aspiration (FNA) is indicated for patients found to have palpable lymph node metastasis if the results will change the management of the patient's problem.
   a. If the presence of histologically confirmed lymph node metastasis is part of the inclusion criteria for a protocol of neoadjuvant systemic therapy, and FNA should be obtained
2. Use to confirm or rule out the presence of regional lymph node metastasis to facilitate treatment planning in cases where the finding of lymph node metastasis is indeterminate by cross-sectional imaging criteria.

Indications

1. The treatment of occult and clinically node-positive metastasis to the neck from a cutaneous malignancy involving the skin of the posterior scalp, auricle, and upper neck
2. The treatment of microscopically positive disease in the lymphatic basin after sentinel lymph node biopsy for cutaneous malignancy

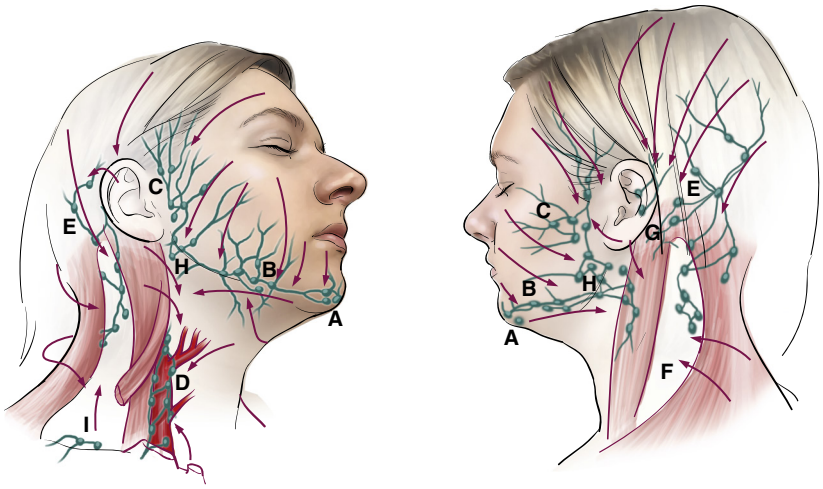

Fig. 71.1. Nodal drainage patterns of the head and neck. *A*, submental. *B*, submandibular. *C*, pre-auricular. *D*, deep cervical/jugular chain. *E*, occipital. *F*, posterior cervical chain. *G*, posterior auricular. *H*, parotid. *I*, supraclavicular.



Fig. 71.2. Given the location, this scalp melanoma may require posterolateral neck dissection for gross disease or positive sentinel lymph node biopsy.

Contraindications

1. Disseminated metastases: This operation is contraindicated in patients for whom the procedure would provide neither prolonged survival nor significant palliation.
2. Patients with extensive lymph node metastasis: Those with involvement of the deep muscles of the neck, vertebrae, or carotid artery are advised to consider systemic therapy options that could help to decrease the risk of distant metastatic cancer and potentially make the locoregional disease burden more manageable by resection.
3. Medical comorbidities with increased risk for general anesthesia: Patients deemed to be medically at high risk for general anesthesia who have microscopic lymph node metastasis can be often be managed successfully with radiation therapy alone.

OPERATIVE PERIOD

Anesthesia

General

- Place the endotracheal tube and secure it at the oral commissure contralateral to the side of the neck that is being dissected.
- Use a paralytic agent throughout the procedure. This prevents excess stimulation of motor nerves by electrical dissection. Even in the presence of paralyzing agents, these motor nerves are readily identified by reliable anatomic landmarks and the stimulation provided by electrical dissection.

Positioning

Supine

- Place the patient in the supine position with the ipsilateral upper extremity tucked at the patient's side and the operating table turned at a 90-degree angle such that the side of the dissection is facing out.
- Place a roll under the patient's shoulders to extend the neck and turn the head toward the anesthesiologist.
- When bilateral posterolateral neck dissection is performed, consider placing the patient in the prone position. This occurred in only 3 of 55 patients reported in a large series, making this a rare position for this operation.

Perioperative Antibiotic Prophylaxis

First-generation cephalosporin

Monitoring

None necessary

Instruments and Equipment to Have Available

1. Major head and neck soft tissue set
2. Bipolar electrocautery
3. Two half-inch Penrose drains to be used for retraction

Key Anatomic Landmarks

1. Erb's point (punctum nervosum): Located on the posterior border of the SCM midway between its attachments to the mastoid process, sternum, and clavicle. Cutaneous branches of the cervical plexus (C5 and C6 roots) emerge at Erb's point from behind the posterior border of the SCM. The four cutaneous nerves of the cervical plexus are the lesser occipital nerve, great auricular nerve, transverse cervical nerve, and supraclavicular nerve. The spinal accessory nerve exits the SCM muscle approximately 1 cm superior to Erb's point.

2. The spinal accessory nerve: After exiting the skull base, it most often passes anteriorly to the jugular vein and enters, and innervates, the SCM and exits the SCM at the posterior margin of the muscle. It then courses inferolaterally through the posterior triangle and passes under the trapezius muscle that it innervates.
3. Trapezius muscle: The upper fibers of the trapezius originate from the spinous processes of C1 to C7, the external occipital protuberance, the medial third of the superior nuchal line of the occipital bone, and the ligamentum nuchae. Inferiorly the fibers travel downward and laterally and insert into the posterior border of the lateral third of the clavicle.

Prerequisite Skills

- Neck dissection levels 1 through 5
- Selective neck dissection
- Radical neck dissection
- Posterolateral neck anatomy

Operative Risks

1. Nerve injury: Significant risk to the accessory nerve. Other nerves are at risk, including the brachial plexus and phrenic nerve.
2. Possible disinsertion of the SCM muscle from the mastoid during dissection
3. Chylous fistula
4. Superficial loss of the most distal (superior) aspects of the skin flap

Surgical Technique

- Draping:
  - Neck, shoulder, and upper chest are sterilely prepped.
  - Using towels, square off the operative field, including exposure of the posterior neck to the nuchal line, the clavicle, the anterior neck to the midline, and the superior aspect of the auricle.
  - The ear or scalp should be included in the operative field based on the location of the primary.
- Incision
  - The incision is designed to provide optimal visual access to facilitate the removal of all the nodal groups to be dissected while preserving vital structures and cosmesis.
  - The location of the primary tumor and incisions used for prior procedures such as a lymph node biopsy may dictate the design of the incision.
  - I prefer an S-shaped incision in which a horizontal limb is oriented along the occiput from the midline to the postauricular region, where it then descends vertically just anterior to the anterior border of the trapezius to a lower cervical skin crease, which the incision should follow horizontally anterior to the anterior border of the SCM (Fig.71.3).
- Elevation of the flap
  - Make the incision with a scalpel or cautery.
  - The superior flap is elevated to the pinna anteriorly, the superior aspect of the auricle superiorly, and the midline medially.
  - The posteroinferior flap is elevated to the midline in the superior half of the neck and the anterior border of the trapezius muscle in the inferior half of the neck all the way to the clavicle.
  - The anterior flap is elevated to the anterior border of the omohyoid muscle.



Fig. 71.3. "S" type incision used for posterolateral neck dissection.

  - Care should be taken to elevate a very thin flap in a subcutaneous plane, leaving the majority of the subcutaneous adipose tissue on the specimen, since the lymph nodes can be found within the subcutaneous adipose tissue in this portion of the neck.
  - Secure flaps with skin hooks.
- Identification of the spinal accessory nerve
  - Incise the superficial layer of the deep cervical fascia from the mastoid tip to the clavicle along the anterior aspect of the SCM.
  - Elevate the fascia on both the medial and lateral aspects of the muscle. This fascia and the external jugular lymph nodes should be entirely removed, as they are important components of the specimen in cutaneous malignancies of the scalp, ear, and/or face.
  - Identify the spinal accessory nerve while dissecting along the anterior aspect of the SCM.
  - Skeletonize the accessory nerve throughout its entire course, from deep to the posterior belly of digastric muscle to its entry into the SCM. Dissection on the lateral aspect of the muscle from anterior to posterior will bring one to the underdeep surface of the SCM, where the spinal accessory nerve can be seen exiting the muscle (Figs.71.4 and 71.5).
  - Follow the nerve to the trapezius muscle and skeletonize the nerve throughout its course in the operative field to ensure its preservation.
- Nodal dissection
  - Dissect the fibroadipose lymph node bearing tissue of the postauricular and suboccipital regions off the underlying bone and muscle in a posteroinferior direction. Prior delineation of the SCM helps to prevent detachment of the SCM insertion from the mastoid/occipital skull during the dissection of these posterosuperior nodes.
  - The suboccipital lymph nodes lie along the course of the occipital artery; divide branches of this artery in order to remove this group of lymph nodes.
  - Wrap two half-inch Penrose drains around the superior and inferior aspects of the SCM, exert traction anteriorly, and secure to the drapes to provide exposure of the posterior aspect of the neck.
  - Identify the internal jugular vein (IJV) just above the clavicle and delineate the posterior aspect of the vein.
  - Divide the fibroadipose tissue overlying the deep layer of deep cervical fascia from the IJV to the trapezius just above the clavicle.
  - Gently spread with gauze sponges and elevate the tissue off the deep layer of deep cervical fascia to expose the phrenic nerve and brachial plexus. Take care to avoid injury to these nerves and prevent avulsion of the transverse cervical vessels or thoracic duct.

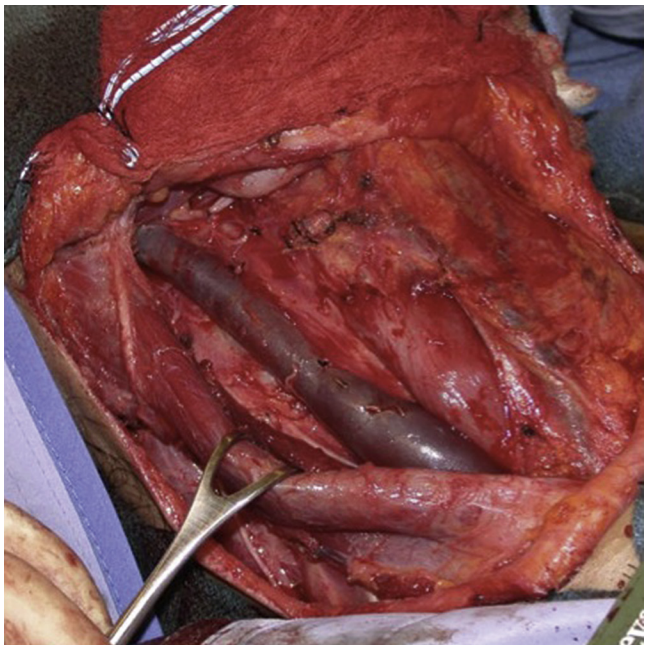

Fig. 71.4. The anatomy of a completed posterolateral neck dissection is illustrated. Levels II through V have been removed.

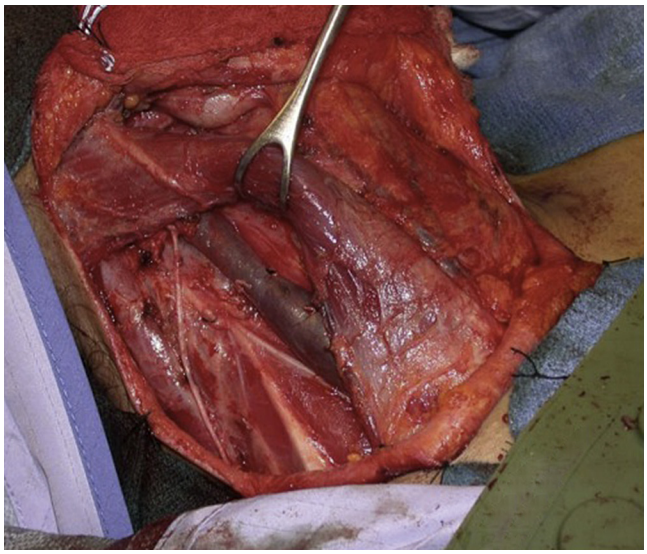

Fig. 71.5. Here the accessory nerve is seen exiting the sternocleidomastoid muscle.

- Remove fibroadipose from the inferolateral portion of the neck where the trapezius and clavicle meet. Use extreme caution in this region to avoid injury to inferolateral branches of the brachial plexus and the terminal aspect of the spinal accessory nerve. Clamp and oversew this tissue with 2-0 silk sutures.
- Extend the dissection from lateral to medial, elevating the nodal tissue off the trapezius to the midline in the upper half of the neck and the anterior border of the trapezius in the lower neck.
  - Some authors advocate resection of the superior aspect of the trapezius from C1 to C4 in order to remove nodes deep to this muscle.[3]
  - Divide the sensory rootlets of the cervical plexus as the dissection transitions anterior to the trapezius and the rootlets and the node-bearing specimen are elevated off of the levator scapulae and splenius capitis muscles.
  - Advance the specimen superomedially, and divide the sensory rootlets of the cervical plexus distally in order to preserve their contributions to the phrenic nerve.
  - Exert traction on the Penrose drains posteriorly and secure them to provide optimal exposure of the carotid sheath structures and anterior aspect of the neck.
  - Dissect the neck specimen onto and off the carotid sheath contents.
  - Identify and preserve the hypoglossal nerve throughout its course.
  - Dissect the specimen up to the lateral aspect of the omohyoid muscle and release the Penrose drains.
  - Provide hemostasis to the wound with bipolar cautery.
  - Irrigate the wound with sterile saline solution and inspect it again for signs of bleeding.
- Wound closure and drain placement
  - Place two 7-mm Blake (Ethicon) flat suction drains in the depth of the wound through a separate stab incision and secure them with a suture of 2-0 nylon or 2-0 silk.
  - Avoid placing the drain in the lower neck posterior to the jugular vein, as this can contribute to development of a chylous fistula.
  - Close the wound in layers with 3-0 Vicryl suture for the subcutaneous and platysmal layers and skin staples or 5-0 nylon suture to approximate the skin edges.[4]
- Specimens
  - Divide the neck dissection specimen into levels 2, 3, 4, and 5 and the postauricular and suboccipital regions and send for permanent section analysis.

Common Errors in Technique

1. Elevating thick superior and posterior skin flaps: The flaps should be elevated in the subcutaneous plane. This is important because the occipital and preauricular lymph nodes can be located within the subcutaneous adipose tissue in this portion of the neck.
2. Failure to gain adequate exposure of both the anterior and posterior neck during the dissection
3. Incompletely visualizing and dissecting the neural structures at risk, such as the spinal accessory nerve and brachial plexus: It is necessary to identify and preserve the spinal accessory nerve in the posterior triangle of the neck.

Postoperative Management

1. Overnight admission for observation: Monitor for hematoma. Inspect drain output for chylous fluid.
2. Consult with physical therapists for shoulder rehabilitation.

Complications

1. Chyle leak, bleeding, neural injury: Complications of the posterolateral neck dissection include all of the complications associated with the more standard selective/comprehensive neck dissection.
2. Injury to the spinal accessory nerve: Owing to the extensive inferoposterior and inferior dissections, the risk of injury to the spinal accessory nerve and/or brachial plexus is greater than in more standard neck dissections. Surgical misadventures involving these neural structures can best be avoided by careful dissection of these nerves under direct visualization.

Alternative Management Plan

Indications for posterolateral neck dissection include management of lymph node metastasis from primary cancers that are traditionally not radiosensitive. Radiation therapy and chemotherapy may be considered as a palliative approach.

DISCUSSION

Evidence-Based Medicine Question

How effective is posterolateral neck dissection in achieving local control for patients with skin cancer? How effective is postoperative adjuvant radiation?

A case series review of 55 patients treated over a 10-year period from 1982 through 1991 with a minimum of 3 years of follow-up at M.D. Anderson Cancer Center included 35 patients with melanoma, 10 with squamous cell carcinoma, and 10 with other histologic types. In this series, disease was controlled at the site of the primary tumor in 89% of patients (94% of patients with melanoma) and regional disease was controlled in 93% of patients (89% of patients with melanoma).[5]

Additional studies of regional metastatic melanoma of the head and neck region treated at M.D. Anderson Cancer Center show that the addition of postoperative adjuvant radiation therapy can enhance locoregional control. Ballo and et al. reported their experience in administering five 6-Gy fractions of external beam radiation twice weekly in the postoperative setting to 160 patients with melanoma of the head and neck region, 148 (93%) of whom had node-positive disease. Patients in this group had undergone simple lymph node excision (35), selective neck dissection (90), or a radical or modified radical neck dissection (35). The actuarial local, regional, and locoregional control rates in this population at 10 years were 94%, 94%, and 91%, respectively.[6]

Editorial Comment

Posterolateral neck dissection is indicated for skin cancers of the upper neck, posterior scalp, and auricle. Primary resection of these cancers can be quite complex, involving resection of the temporal bone, lateral skull base, temporomandibular joint, and/or mandible. The need for facial nerve sacrifice adds further complexity, consequently posing unique reconstructive challenges. Planning of the surgery and incision for posterolateral neck dissection should take into account the extent of the primary resection, type of reconstruction planned (e.g., cervicofacial rotation flap), and adequate surgical access to lymph node metastasis.

Rohan R. Walvekar

Access the review questions and additional sources list online at http://www.expertconsult.com



REFERENCES

1. Rochlin DB. Posterolateral neck dissection for malignant neoplasms. Surg Gynecol Obstet 1962;115:369–373.
2. Goepfert H, Jesse RH, Ballantyne AJ. Posterolateral neck dissection. Arch Otolaryngol 1980;106(10):618–620.
3. Plukker JT, Vermey A, Roodenburg JL, et al. Posterolateral neck dissection: technique and results. Br J Surg 1993;80(9):1127–1129.
4. Klein JD, Myers JN, Kupferman ME. Posterolateral neck dissection: preoperative considerations and intraoperative technique. Oper Tech Otolarynogl 2013;24:24–29.
5. Diaz Jr EM, Austin JR, Burke LI, et al. The posterolateral neck dissection. Technique and results. Arch Otolaryngol Head Neck Surg 1996;122(5):477–480.
6. Ballo MT, Bonnen MD, Garden AS, et al. Adjuvant irradiation for cervical lymph node metastases from melanoma. Cancer 2003;97(7):1789–1796.

REVIEW QUESTIONS

1. Landmarks associated with Erb's point include all of the following, except
   a. The SCM
   b. The spinal accessory nerve
   c. The great auricular nerve
   d. The trapezius muscle

2. Potential complications specific to the posterolateral neck dissection include all of the following, except
   a. Chyle leak
   b. Anesthesia of skin over the clavicle
   c. Shoulder weakness
   d. Weakness of the marginal mandibular branch of the facial nerve

3. All of the following nodal basins should be removed with a posterolateral neck dissection, except the
   a. Postauricular basin
   b. Suboccipital basin
   c. Preauricular basin
   d. Jugular basin

ADDITIONAL SOURCES

Klein JD, Myers JN, Kupferman ME. Posterolateral neck dissection: preoperative considerations and intraoperative technique. Oper Tech Otolarynogl 2013;24:24–29.

Medina JE. Posterolateral neck dissection. Oper Tech Otolaryngol Head Neck Surg 2004;15:176–179.

72 Excision of Neural Tumors of the Parapharyngeal Space

Johan Fagan

INTRODUCTION

To safely resect neural tumors of the parapharyngeal space (PPS) and to counsel patients about potential consequences and complications of surgery requires that the surgeon has a detailed knowledge of the surgical anatomy of the PPS, requests appropriate radiological studies from which the likely pathology can be predicted (80% benign), and understands the possibilities and limitations of the various surgical approaches.

Neural tumors in the PPS include solitary schwannomas, neurofibromas, and malignant nerve sheath tumors. There are at least three major types of neurofibromas: neurofibromatosis-1 (NF1), neurofibromatosis-2 (NF2), and schwannomatosis. They all represent genetic abnormalities. With schwannomas, the nerve fibers of the parent nerve may be draped over the tumor, making it possible to preserve the nerve, although transient postoperative paresis is common. However, in most cases the schwannoma is inseparable from the nerve and the nerve must be sacrificed. Neurofibromas are not encapsulated, and because the nerve fibers are part of the tumor, the nerve cannot be preserved. Malignancy occurs in about 10% of patients with NF1 and may be signified by invasion of adjacent tissue, or metastases.

The PPS has prestyloid and poststyloid compartments. It is important to distinguish preoperatively between a prestyloid and a poststyloid mass, as this affects the differential diagnosis and may determine the surgical approach. Poststyloid neural tumors arise from cranial nerves IX–XII or from the sympathetic nerves. Prestyloid tumors are likely to originate from branches of the mandibular division of cranial nerve V. However, the nerve of origin may not be apparent even at surgery if a tumor has originated from minor, unnamed nerves. Vagal and carotid paragangliomas also arise in the poststyloid PPS and may be difficult to differentiate from a schwannoma on computed tomography (CT) and magnetic resonance imaging (MRI), as flow voids that are typical of a paraganglioma may not be apparent in a small paraganglioma, and schwannomas may also appear vascular. Carotid angiography may be helpful in such situations to draw a distinction. Salivary gland tumors and metastases (e.g., from papillary thyroid carcinoma) should also to be considered in the differential diagnosis.

The PPS extends as an inverted pyramid from the skull base superiorly, to the hyoid bone inferiorly. Fig. 72.1 presents an axial view of the prestyloid (yellow) and poststyloid (pink) components of the PPS separated by the styloid process, *tensor veli palatini* muscle, and its fascia (brown). The poststyloid space contains the internal carotid artery and the internal jugular vein, as well as the lower cranial nerves IX–XII, and the sympathetic trunk. It is confined medially by the pharyngobasilar fascia and the superior constrictor muscle of the pharynx.[1]

Prestyloid tumors may present with bulging of the lateral wall of the oropharynx, which displaces the tonsil medially (Fig. 72.2). The prestyloid PPS is bordered anterolaterally by the medial pterygoid muscle, and posterolaterally by the deep lobe of the parotid gland (see Fig. 72.1). It contains mainly adipose tissue. Radiologically, prestyloid tumors typically displace the adipose tissue of the PPS anteromedially (Fig. 72.3).

Poststyloid masses typically present as a mass extending into the superior lateral neck or the oro- or nasopharynx, dysfunction of cranial nerves IX–XII, or Horner's syndrome. The poststyloid PPS is limited medially by the pharyngobasilar fascia and the superior pharyngeal constrictor. It contains the internal carotid artery and the internal jugular vein, as well as the lower cranial nerves IX–XII, and the sympathetic trunk (see Fig. 72.1). Radiologically, poststyloid tumors typically displace the adipose tissue of the PPS anterolaterally (see Fig. 72.3, Fig. 72.4).

KEY OPERATIVE LEARNING POINTS

Selecting the appropriate surgical approach is very important in achieving adequate access and in minimizing morbidity. In order to plan the correct surgical approach and before embarking on surgery, the surgeon needs the following information:

- *Is the mass pre- or poststyloid?* This is determined clinically and radiologically with CT/MRI. This information permits the surgeon to narrow down the differential diagnosis, to plan the best approach, and to counsel patients preoperatively about possible sequelae.
- *Is the mass benign or malignant?* This may influence the surgical approach, and even affect the decision whether or not to do surgery. It is generally determined by Fine needle aspiration cytology (FNAC) done transcervically or transorally. The surgeon should not be concerned about puncturing the internal carotid artery with a small-caliber needle, as bleeding can be controlled with digital pressure.
- *Is the mass a paraganglioma?* This is important, as paragangliomas may rarely be hormonally active and may require preoperative embolization. When it is difficult to distinguish a paraganglioma from a schwannoma on CT or MRI, proceed to a diagnostic angiogram.
- *What are the anatomical relations of the internal and external carotid arteries to the mass?* Particularly with a poststyloid mass, knowledge of the position of the arteries in relation to the mass is important in planning and doing the surgery (see Fig. 72.4).
- *What is the cerebral cross-over blood flow like should the internal carotid artery have to be sacrificed?* Should this be a concern, it can be determined by angiography ± balloon occlusion testing.

PREOPERATIVE PERIOD

- *What neurological deficits may be caused by surgical excision?* Causing permanent cranial nerve deficits, a cerebrovascular accident, or first bite syndrome can be devastating for the surgeon and patient alike, and may significantly impact on a patient's quality of life.
- *Does the patient have NF1, NF2 or schwannomatosis?*
- *Does the patient require surgery, radiation, or watchful waiting?* Not all benign neural tumors require surgical excision, as

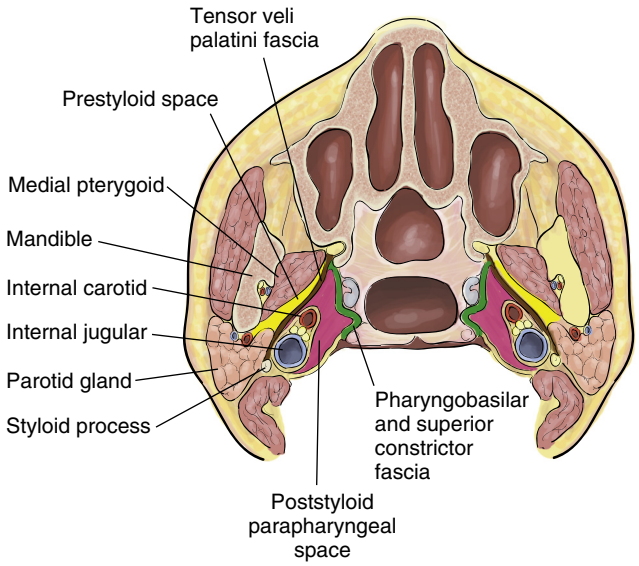

Fig. 72.1. Schematic axial view of prestyloid *(yellow)* and poststyloid *(pink)* parapharyngeal spaces, the pharyngobasilar fascia and superior constrictor *(green)*, and tensor veli palatini and its fascia *(brown)*. *(With permission from Access to parapharyngeal space. In Fagan JJ [ed]:* The Open Access Atlas of Otolaryngology Head and Neck Operative Surgery. *Available at https://vula.uct.ac.za/access/content/group/ba5fb1bd-be95-48e5-81be-586fbaeba29d/Access%20to%20parapharyngeal%20space.pdf.)*



Fig. 72.2. Prestyloid parapharyngeal space mass displacing the palate. *(With permission from Access to parapharyngeal space. In Fagan JJ [ed]:* The Open Access Atlas of Otolaryngology Head and Neck Operative Surgery. *Available at https://vula.uct.ac.za/access/content/group/ba5fb1bd-be95-48e5-81be-586fbaeba29d/Access%20to%20parapharyngeal%20space.pdf.)*

they are often slow growing, and growth may be arrested by radiation. Therefore careful consideration should be given to nonsurgical treatment options, especially in older patients.

History

1. History of present illness
   a. Growth rate
   b. Pain (suggests malignancy or schwannoma)
   c. Neurological deficits of V, IX, X, XI, XII, sympathetic
   d. Pointers to paraganglioma (hypertension, headaches, palpitations, tachycardia, and anxiety)
   e. Pointers to NF, as discussed under physical examination
2. Past medical history
   a. Previous malignancy (metastasis)
   b. Cerebrovascular accidents or ischemia (risk of cerebro vascular accident (CVA) at surgery)
   c. NF
3. Family history
   a. NF
   b. Paragangliomas
4. Medical illness
   a. Fitness to deal with aspiration and dysphagia if neurological complications occur
   b. Fitness for surgery

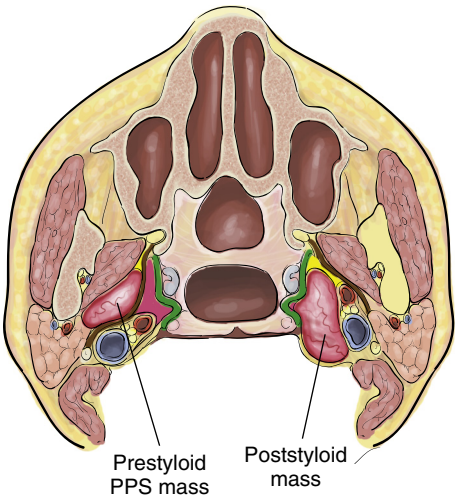

Fig. 72.3. Directions of displacement of adipose tissue as seen on computed tomography or magnetic resonance imaging with prestyloid parapharyngeal space mass (R) and poststyloid mass (L).

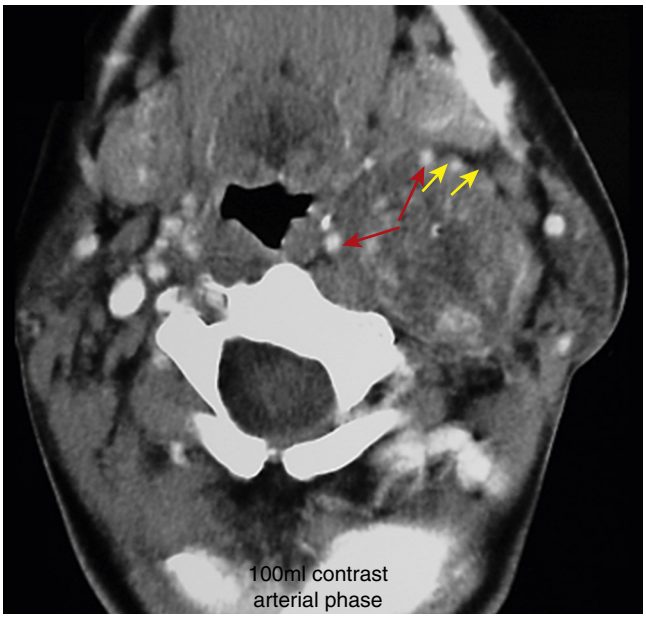

Fig. 72.4. Computed tomography scan of poststyloid vagal schwannoma, demonstrating direction of displacement of adipose tissue *(yellow arrows)* and medial displacement of the carotid vessels *(red arrows)*.

5. Medications
   a. Anticoagulants
6. Mental and social status
   a. Ability to overcome challenges related to speech and swallowing
   b. Ability to give informed consent
   c. Social support
   d. Employment and hobbies may be affected by speech or swallowing impairment.

Physical Examination

1. Primary PPS mass
   a. Confined to the neck? May be resectable by simple transcervical approach
   b. Extends above angle of mandible? May need to include transparotid approach
   c. Does the tumor distort the oropharynx?
2. Neurofibromatoses?
   a. NF1: Café-au-lait spots, axillary and inguinal freckling, subcutaneous or cutaneous neurofibromas, plexiform neurofibroma, Lisch nodules, benign and malignant nervous system neurofibromas, sphenoid dysplasia, long bone abnormalities, scoliosis, pseudoarthroses
   b. NF2: Vestibular schwannomas, meningioma, schwannoma, glioma, neurofibroma, posterior subcapsular lenticular opacities
   c. Schwannomatosis: Multiple schwannomas
3. Neurological deficits?
   a. Cranial nerves V3, IX, X, XI, XII
   b. Horner's syndrome
4. Neck
   a. Palpate the neck for cervical metastases.
   b. Examine the neck for the presence of a mass or signs of previous surgery and scars that may affect surgical planning.
5. General health
   a. Nutrition
   b. Cardiovascular
   c. Respiratory
   d. Mental

Laboratory Testing

1. Twenty-four-hour urine and serum metanephrines if a paraganglioma is part of the differential diagnosis to rule out the presence of a secreting paraganglioma or pheochromocytoma

Imaging

1. Chest radiograph
   a. Metastases
   b. Pulmonary and cardiac status
2. Swallowing evaluation by a speech language pathologist, if the patient is aspirating
3. CT scan of head and neck (with contrast)
   a. All cases
   b. Size of tumor
   c. Superior extent of tumor
   d. Relationship to internal and external carotid arteries
   e. Multiple tumors
4. MRI
   a. To compliment CT scan findings
   b. Multiple tumors
5. Carotid angiogram
   a. To exclude a paraganglioma
   b. To determine course of carotid vessels if uncertain on CT or MRI
   c. To check cross-flow if concern about risk to carotid artery during surgery

Indications

- Not all patients require surgery
- Diagnostic if concerned about malignancy
- Mass effect or potential for future mass effect

Contraindications

1. Patient factors
   a. Medically unfit
   b. Inability to give informed consent
   c. Inability to overcome challenges related to deficits in speech and swallowing
   d. Inadequate social support
2. Tumor factors
   a. Malignant tumor: Unresectable and/or distant metastases
   b. Benign tumor: Unresectable
   c. Potential morbidity unacceptable to patient
3. Surgical factors
   a. Inadequate expertise

Preoperative Preparation

1. Evaluations by
   a. Head and neck surgeon
   b. Anesthesiology
   c. Speech language pathologist
2. Discontinue antiplatelet drugs if possible

OPERATIVE PERIOD

Anesthesia

- Nasal endotracheal tube if transparotid approach is used, as orotracheal tube may reduce access
- Avoid muscle relaxants so that cranial nerves (V3, VII, X, XI, XII) can be monitored.

Positioning

- Supine with neck extended
- Face and neck sterilized and appropriately draped

Perioperative Antibiotic Prophylaxis

- No antibiotics required unless the pharynx will be entered
- Should antibiotics be required, use
  - Clindamycin
  - Amoxicillin and clavulanate
  - Cephalosporin and metronidazole

Monitoring

- Routine anesthesia monitoring
- Patient should not be paralyzed to facilitate preserving V3, VII, X, XI, XII nerves.
- Facial nerve monitor may be used with transparotid approach.

Instruments and Equipment to Have Available

- Monopolar electrocautery
- Long bipolar electrocautery (to reach skull base)
- Standard head and neck set
- Oscillating saw, drill, and mandibular plating set if mandibulotomy planned
- Facial nerve monitor (optional)

Key Anatomic Landmarks (Depends Upon the Approach)

- Transcervical approach
  - Facial vein
  - Inferior border of submandibular gland
  - Posterior belly of digastric muscle
  - XIIn, where it descends anterior to internal jugular vein and crosses the carotid artery
  - Carotid arteries: Common, internal, and external
  - Xn
  - XIn
  - Superior laryngeal nerve
  - Transverse process of C1 (internal jugular vein and XIn immediately anterior)
  - Styloid process (VIIn crosses lateral to it; internal carotid passes medial to it)
- Transparotid approach (see Chapters 92 and 93)
- Transcervical-submandibular
  - Marginal mandibular nerve
  - Facial artery and vein
  - Digastric and stylohyoid muscles
  - Hyoid bone

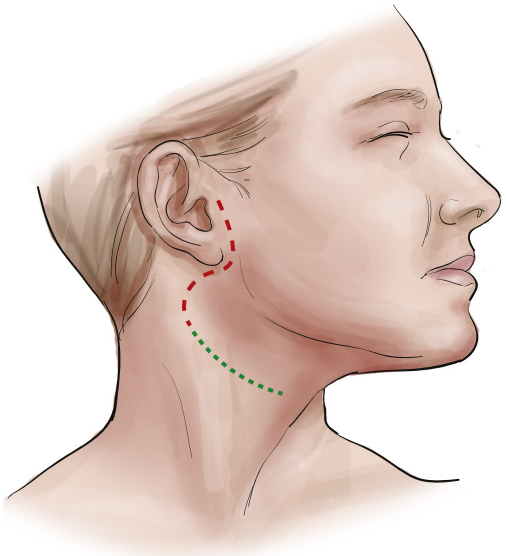

Fig. 72.5. Skin incisions: *Green* for transcervical ± submandibular approach; add *red* incision for transparotid approach.

- XIIn
- Medial pterygoid muscle

Prerequisite Skills

- Neck dissections
- Total parotidectomy
- Carotid artery repair/graft (selected cases)

Operative Risks

- Lower cranial nerve injuries VII, IX, X, XI, XII
- Horner's syndrome
- Injury to carotid arteries with cerebrovascular events
- Internal jugular vein injury

Surgical Technique

- Good surgical access is essential to expose and preserve important nerves and vessels, to achieve an adequate resection, and to control bleeding.
- Open the neck as indicated in Fig. 72.5.
- Fig. 72.6 illustrates the surgical approaches to the PPS.

Prestyloid Surgical Approaches

Masses in the prestyloid space are mostly benign, well defined, surrounded by adipose tissue, and unlike tumors of the poststyloid space, are generally not tethered to structures such as major nerves and vessels. These tumors can therefore generally be removed by careful blunt dissection along the tumor capsule. The tumors are situated anywhere between the hyoid bone and the skull base, but generally do not extend above the level of the hard palate or pterygoid plates, and are situated on the medial aspect of the medial pterygoid muscle. They are readily accessed via a transcervical submandibular approach. Only rarely is a transoral approach ± mandibulotomy required. A large tumor may require a combined transcervical and transparotid approach.

Transcervical Submandibular Approach to Prestyloid Tumors

- Make a horizontal skin crease incision at the level of the hyoid bone.
- Identify the submandibular salivary gland (SSG) and digastric muscle.
- Ligate and divide the anterior facial vein.
- Incise the capsule of the SSG.

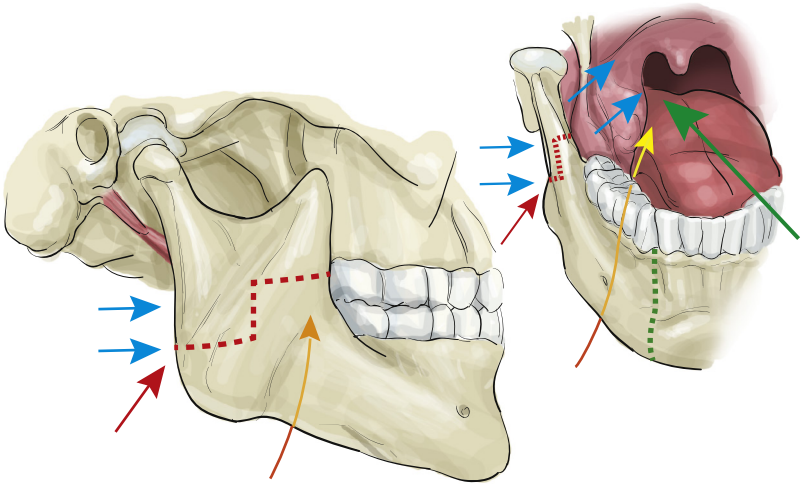

Fig. 72.6. Approaches to parapharyngeal space: transoral ± mandibulotomy *(green)*; transcervical submandibular *(yellow)*, transparotid *(blue)*, and transcervical ± mandibulotomy *(red)*.

- Mobilize the SSG in a subcapsular plane so as to protect the marginal mandibular nerve.
- Identify the facial artery posteroinferiorly to the gland where it emerges from behind the posterior belly of the digastric muscle (Fig. 72.7).
- Ligate and divide the facial artery where it emerges from behind the posterior belly of digastrics.
- Mobilize the SSG with finger dissection in a posterior-to-anterior direction, leaving the thin fascial layer over the ranine veins and the hypoglossal nerve intact (Fig. 72.8).
- Additional mobility of the SSG may be achieved (if required) by dividing the facial artery and anterior facial vein above the SSG.
- By retracting the posterior belly of digastric posteriorly, the mandible superiorly, and the SSG anteriorly, the surgeon can pass a finger/instrument directly into the prestyloid PPS and mobilize and remove the tumor.

Transoral Approach to Prestyloid Tumors

This approach is essentially the same as an extended tonsillectomy, and may include a midline or paramedian mandibulotomy for additional access. A disadvantage is that the neck is not opened and the vessels not exposed in the event of injury to the major vessels requiring proximal vascular control.

Combined Transcervical Submandibular and Transparotid Approaches to Prestyloid Tumors

Even large prestyloid tumors may be resected via a combination of transparotid and transcervical approaches. Transecting the posterior belly of the digastric muscle, the stylohyoid muscle and the sphenomandibular ligament further improve access.

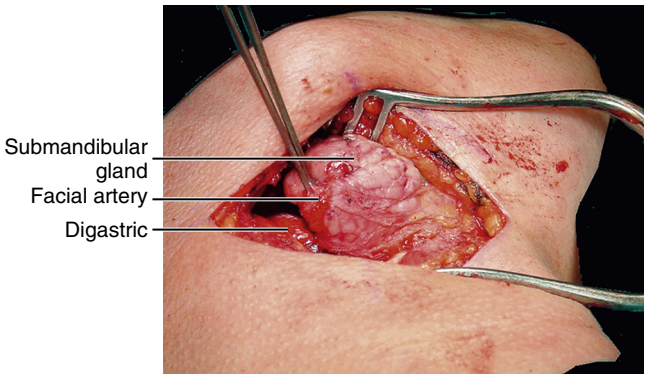

Fig. 72.7. Exposure of left submandibular gland, digastric muscle, and facial artery.

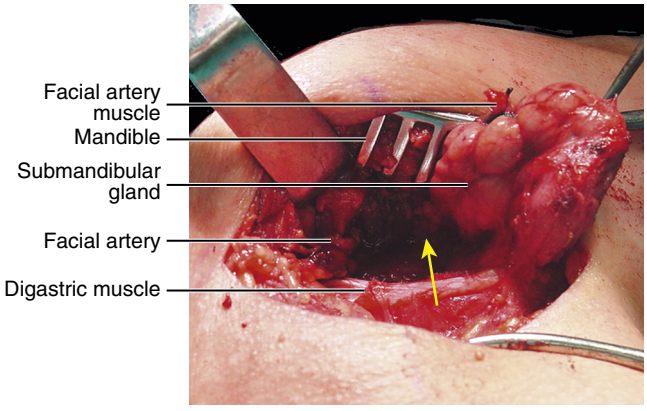

Fig. 72.8. Displacement of submandibular gland for transcervical submandibular access to prestyloid parapharyngeal space.

Poststyloid Parapharyngeal Space Surgical Approaches

The principal challenges relating to removal of a poststyloid mass are avoiding injury to the internal carotid artery, internal jugular vein, and the lower cranial and sympathetic nerves. Access is restricted by the vertical ramus of the mandible, the parotid gland, the facial nerve, and the styloid process with its muscular and ligamentous attachments. Resection requires good exposure of the mass and the major vessels and nerves via transcervical and/or transparotid approaches. Rarely a mandibulotomy of the vertical ramus is required for additional exposure. Patients should be cautioned about the sequelae of vascular and lower cranial nerve injury, as well injury to the sympathetic trunk causing Horner's and First Bite Syndromes.

Transcervical Approach to Poststyloid Parapharyngeal Space

The transcervical approach is suitable for neural tumors, extending up to about the level of the styloid process (Fig. 72.9). The upper neck is exposed via a transverse incision in a skin crease, the X, XI, and XII nerves are identified, as are the carotid bifurcation and the internal jugular vein. The mass is then mobilized by blunt dissection and then removed. The posterior belly of the digastric muscle may either be retracted superiorly, or divided to provide additional access deep to the parotid gland.

Transparotid Approach to Poststyloid Parapharyngeal Space

A transparotid approach is required for masses situated in proximity to the skull base (Figs. 72.10 to 72.12).

- Elevate the superficial lobe of the parotid gland off the facial nerve.
- Free the nerve from the deep lobe using blunt dissection.
- Resect the deep lobe of the parotid gland.
- This exposes the styloid process.
- Immediately medial to the styloid are the contents of the poststyloid PPS.
- Access can be further improved by excising the styloid process with a bone nibbler, and retracting the mandible anteriorly (taking care to avoid excessive tension on the facial nerve) and inferiorly by dividing the posterior belly of the digastric and stylohyoid muscles.

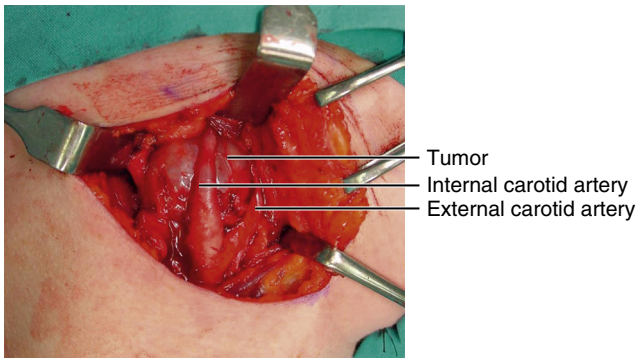

Fig. 72.9. Resection of poststyloid schwannoma via transcervical approach.

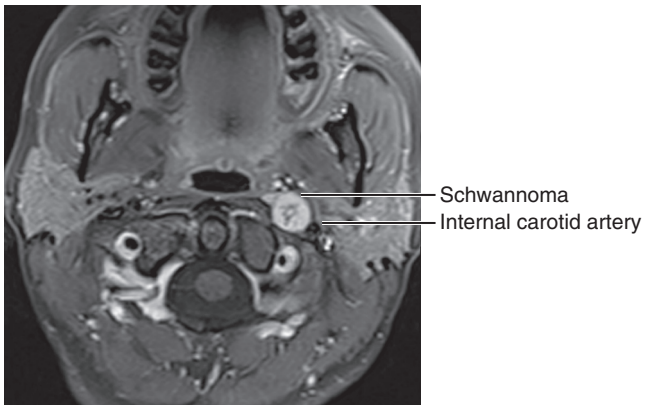

Fig. 72.10. Schwannoma of poststyloid parapharyngeal space located medial to internal carotid artery.

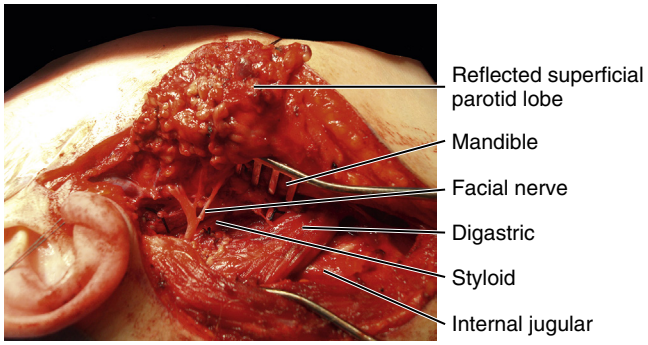

Fig. 72.11. Transparotid access to poststyloid parapharyngeal space in Fig. 72.10.

Closure

- Insert a suction drain to prevent a hematoma that could obstruct the airway.

Common Errors in Technique

- Selecting the wrong surgical approach
- Not inserting a suction drain

POSTOPERATIVE PERIOD

Postoperative Management

- Remove suction drains when less than 50 mL drainage/24 hours.
- Check that patient swallows without aspirating before introducing oral feeds.
- Speech language pathologist assists the patient if dysphagia and aspiration ensues.

COMPLICATIONS

- Hematoma: Return to the operating room as soon as possible and evacuate the hematoma, control the bleeding, and if necessary, perform a tracheostomy.
- Injury to one or more cranial nerves
  - Dysphagia and aspiration
  - Facial nerve paresis
- Cerebrovascular accident
- Sympathetic trunk injury
  - First bite syndrome
  - Horner's syndrome

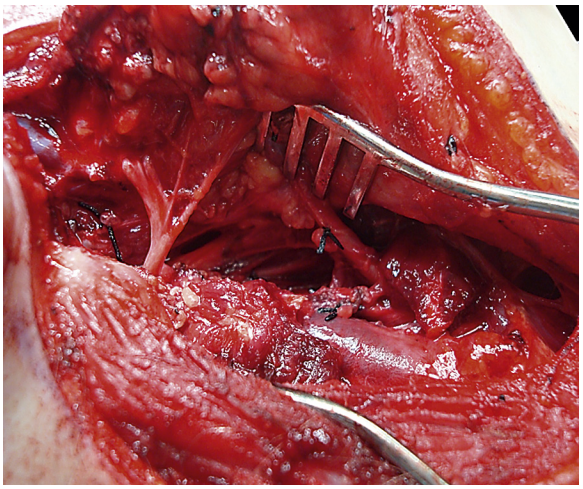

Fig. 72.12. Additional access to poststyloid parapharyngeal space by transection of digastric muscle.

TABLE 72.1 Complications Following Resection of Tumors of the Parapharyngeal Space

	Temporary (%)	Permanent (%)
Vascular injury	13	—
Cerebrovascular accident	4	4
Respiratory infection	4	—
Unplanned tracheotomy	4	—
Xn	9	4
Xln	4	4
Xlln	26	9
Marginal mandibular nerve	30	—

With permission from Carrau RL, Myers EN, Johnson JT: Management of tumors arising in the parapharyngeal space. Laryngoscope *1990; 100(6):583-539.*

ALTERNATIVE MANAGEMENT PLAN

Always discuss nonsurgical options with patients, such as watchful waiting and radiation therapy.

DISCUSSION

Evidence-Based Medicine Question: What Is the Complication Rate of Surgery for Tumors in the Parapharyngeal Space?

Table 72.1 presents a summary of complications following resection of tumors of the PPS as reported by Carrau et al.[2] It does not include first bite syndrome, which can vary from mild to quite debilitating and is a result of injury to the sympathetic nerve supply to the parotid gland.[3] It manifests as cramping or spasm in the parotid area when taking the first bite of food, and diminishes with the following few bites. Linkov et al.[3] reported that it occurred in 22% of patients undergoing PPS dissection, 38% when only the deep lobe of the parotid gland was resected, and 49% when the sympathetic chain had been sacrificed; all of these variables were significant independent predictors of first bite syndrome. Although symptoms generally improve over time, few experience complete resolution of symptoms.[3]

Editorial Comment

This is a well-rounded description of approaches to the PPS; success is dependent on adequate preoperative planning, evaluation, and intraoperative surgical exposure with good proximal control of major blood vessels (internal jugular vein (IJV) and common carotid artery (CCA)) and also identification and isolation of major cranial nerves (XII, XI, X, and IX). When using the transcervical approach, exposure can be improved by dividing the stylohyoid ligament, which is felt like a cord deep to the posterior belly of the digastric muscle. This allows adequate retraction of the mandible and provides necessary exposure for removal without spillage.

Rohan R. Walvekar


Access the review questions online at http://www.expertconsult.com

REFERENCES

1. Access to parapharyngeal space. In Fagan JJ (ed): The Open Access Atlas of Otolaryngology Head and Neck Operative Surgery. Available at https://vula.uct.ac.za/access/content/group/ba5fb1bd-be95-48e5-81be-586fbaeba29d/Access%20to%20parapharyngeal%20space.pdf.
2. Carrau RL, Myers EN, Johnson JT. Management of tumors arising in the parapharyngeal space. Laryngoscope 1990;100(6):583–589.
3. Linkov G, Morris LG, Shah JP, et al. First bite syndrome: incidence, risk factors, treatment, and outcomes. Laryngoscope 2012;122(8):1773–1778.

REVIEW QUESTIONS

1. Tumors in the poststyloid space are generally accessed via
   a. Cervical approach
   b. Cervical-submandibular approach
   c. Transoral approach
   d. Transparotid-cervical approach

2. Routine preoperative evaluation generally includes
   a. Open biopsy
   b. Trucut biopsy
   c. FNAC
   d. CT scan
   e. Positron Emission tomography (PET-CT)

3. Nerves at risk at surgery for poststyloid tumors include
   a. V2n
   b. V3n
   c. Sympathetic trunk
   d. Xn
   e. VIIIn

73 Excision of Carotid Body Tumors

Eugene N. Myers, Jason I. Kass

INTRODUCTION

Most of the tumors that originate in the poststyloid parapharyngeal space (PPS) are tumors of neural origin. Most of these are paragangliomas (PGLs), the most common of which is the carotid body tumor (CBT). It is usually possible to tell preoperatively, by imaging studies, whether these tumors are in fact CBT, glomus vagale tumors, or schwannomas. The computed tomography (CT) scan with contrast is very helpful in the differential diagnosis. The CBT is located at the bifurcation of the carotid artery, whereas the glomus vagale tumor, because of its site of origin from the vagus nerve, arises posterior to the carotid artery.

The Shamblin classification of CBT and its relationship to the carotid artery (Fig. 73.1) has proved to be very useful in the assessment of CBT.[1] The Shamblin I and Shamblin II types of tumors are amenable to surgery by dissecting the tumor off of the carotid artery using the subadventitial technique. However, the Shamblin III tumors in which the carotid artery is encased by tumor, cannot be removed safely by this technique. Not only is the artery encased in the tumor but the tumor may actually invade into the muscularis of the artery and cannot be dissected free. Further dissection then creates an opening in the wall of the carotid artery with resultant hemorrhage. Patients with Shamblin III tumors should undergo a complete resection of the artery by a vascular surgeon with reconstruction using either a vein graft or a synthetic graft (Fig. 73.2).

Although most CBTs are the result of sporadic mutations, there is a subset of PGLs that are inherited. They are referred to as the familial form (PGL1). These PGLs are multiple and usually involve the carotid body so that there may be unilateral CBT or bilateral CBT with additional PGLs arising from unnamed arteries in the vicinity. Tumors in the familial PGL group, in addition to being multiple, are also more likely to be malignant and more likely to have an associated pheochromocytoma.

The familial form of PGL has an autosomal dominant inheritance pattern. Baysal et al. reported in *Science* the analysis of families carrying the *PGL1* gene, which revealed mutations in the succinate dehydrogenase (SDHD), a mitochondrial complex 11 gene in hereditary PGL, on chromosome 11q23.[2] In this paternal inheritance pattern, the father may pass the gene along to the son, who has a 50% chance of having a PGL, who may pass it along to successive males. However, it may also pass to the female, who may develop a tumor but cannot pass the gene to her offspring because of genetic imprinting. The families of patients who have PGL1 should undergo genetic testing. For patients who are found not to have the gene, this is reassuring, and no further testing is required. Patients who test positive should undergo magnetic resonance imaging (MRI) screening. If the MRI discloses a tumor, this should be removed. If the MRI is negative, it should be repeated annually so that if a tumor develops it may be identified at an early stage and may be removed safely.

KEY OPERATIVE LEARNING POINTS

- Modern imaging techniques permit the surgeon to formulate a plan of management without a preoperative biopsy.
- Attempting to remove a Shamblin III type of CBT using a subadventitial approach will eventuate in massive bleeding due to invasion of the wall of the artery by tumor.
- Failure to evaluate for abnormal catecholamines in patients with PGL may result in intraoperative hypertensive crisis in the presence of a secreting PGL or pheochromocytoma.
- Failure to preserve the lower cranial nerves during the excision of a CBT will result in hoarseness and aspiration in the postoperative period.

PREOPERATIVE PERIOD

History

1. History of present illness
   a. Presence of a mass in the lateral neck
   b. Labile or difficult to control hypertension
   c. Sudden flushing
   d. Palpitations
   e. Changes in voice
   f. Dysphagia
   g. Weakness of the tongue
   h. Tinnitus (may be present on the side of the tumor from the high-flow state)
2. Past medical history
   a. Prior neck surgery
   b. Comorbid medical illnesses (particularly hypertension that requires multiple medications for control)
   c. Pheochromocytoma
   d. Carotid atherosclerotic disease
   e. Transient ischemic attacks (TIAs)
3. Family history
   a. Familial PGLs
   b. Disorders of bleeding/clotting
4. Medications
   a. Antiplatelet drugs
   b. Herbal products
   c. Allergies to antibiotics

Physical Examination

1. Complete examination of the head and neck evaluating for a neck mass, which may be either unilateral or bilateral. Evaluation of cranial nerves with particular attention to involvement of the vagus or hypoglossal nerves. Assessment of any scars in the neck from prior surgery
2. Flexible fiberoptic examination
   a. Evaluation of both superior and recurrent laryngeal nerve function especially vocal fold mobility

Imaging

1. CT scan with contrast—Provides excellent resolution and the CBT will enhance intensely with contrast. The tumor will splay the internal and external carotid arteries ("Lyre sign"). The CT scan may also reveal other PGLs.
2. MR angiography
   a. T1 imaging will show an isointense or hypointense lesion when compared with muscle. Larger lesions will have a "salt and pepper" appearance representing small regions of slow blood flow (salt) and flow voids

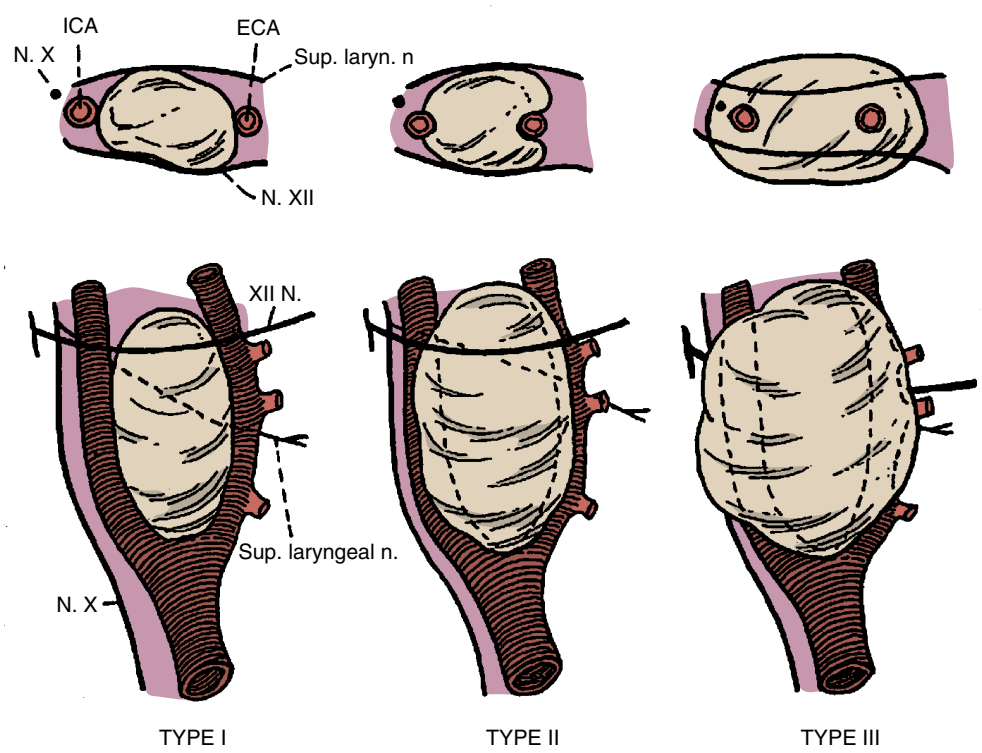

Fig. 73.1. Carotid body paragangliomas. Shamblin classification scheme: type I—small and easy to dissect, type II—medium and more intimately attached to the carotid artery, and type III—large with transmural invasion of the wall of the carotid artery requiring resection and grafting. *(With permission from Shamblin WR, ReMine WH, Sheps SG, et al: Carotid body tumors. Am J Surg 122:733-739, 1971.)*

(pepper). The lesion will have intense enhancement with gadolinium contrast (Fig. 73.3).

b. T2 imaging—CBT will be hyperintense to muscle, and there will also be a speckled appearance with flow voids.

3. Transfemoral angiography—Remains the gold standard for true identification and assessment of tumor vascularity (Fig. 73.4). The senior author (ENM) has had at least one case of misdiagnosis based on history, physical examination, and a vascular blush seen on MR scanning. What was thought to be a CBT was surprisingly identified intraoperatively as an aneurysm of the internal carotid artery (Fig. 73.5).
4. Octreotide or metaiodobenzylguanidine (MIBG) scintigraphy—A sensitive but not specific test for phenochromocytoma. A variety of neuroendocrine tumors including other PGLs (glomus tumors) will enhance, as will non-neuroendocrine tumors (lymphoma, Merkel cell carcinoma). This test can be helpful when evaluating the patient for multiple lesions.

Indications

1. Small tumors that have recently been discovered should be removed, as should tumors demonstrating growth, whether accelerated or steady, with or without involvement of the lower cranial nerves. Patients who are in the Shamblin I or II classification may have this tumor removed safely.
2. Patients demonstrating neuropathy, such as vocal cord paralysis or paralysis of the tongue, should also have the tumor removed. These tumors are usually Shamblin type III and require resection and replacement of the carotid artery.
3. Secreting CBT

Contraindications

Patients who are elderly, have severe comorbidities, refuse surgery, or fail a balloon occlusion test should be considered for observation, including yearly CT scans or radiation therapy.

Preoperative Preparation

1. All patients who have the preoperative diagnosis suggestive of PGL should have examination of a 24-hour urine specimen for catecholamines (vanillylmandelic acid) before surgery. If an abnormality is identified, then an MRI of the abdomen should be performed to try to identify a pheochromocytoma. Pheochromocytomas should be removed before removing the PGL to avoid a potentially fatal intraoperative hypertensive crisis.
2. If the abnormal catecholamines are present but no pheochromocytoma is identified, it must be assumed that an unusual catecholamine-secreting PGL is present. The anesthesiologist should be consulted in advance and a program for the management of a potential hypertensive crisis planned.
3. Preoperative embolization is not required in most cases because the tumors that do not encase the carotid artery can be dissected off of the muscularis of the carotid artery using dissection in the subadventitial plane. We believe that the preoperative embolization may induce an intense inflammatory response that may lead to obliteration of the subadventitial plane, making dissection of the tumor dangerous.
4. Discussion with a vascular surgeon is recommended in all cases. If there is an injury to the internal carotid artery during resection, vessel repair with a patch or graft should be performed. It is essential to schedule these cases on days when a vascular surgeon can be available.

OPERATIVE PERIOD

Anesthesia

Surgery is performed under general anesthesia. In most cases the CBT does not secrete catacholamines, and no special



Fig. 73.2. A, Patient with a mass in the neck, which has increased in size over a 10-year period. **B,** Magnetic resonance imaging demonstrates a large carotid body tumor with numerous flow voids. **C,** Lateral view of mass extending to prevertebral fascia.

perioperative management is required. In rare cases of catecholamine-secreting tumors, patients are typically pretreated with α- and β-receptor blockers for several weeks to prevent intraoperative hypertensive crisis, as well as circulatory collapse following tumor excision.

Positioning

The patient is placed in the supine position with a shoulder roll for neck extension.

Perioperative Antibiotic Prophylaxis

Excision of CBTs is a clean procedure and antibiotic prophylaxis is not indicated.

Monitoring

Routine anesthesia monitoring is used, generally without paralysis. An arterial line may be placed for precision monitoring of blood pressure.

Instruments and Equipment to Have Available

1. Standard head and neck instrument set
2. Vessel loops to help identify and isolate neural and vascular structure

Key Anatomic Landmarks

1. The superior border of the thyroid cartilage is the most reliable landmark for the level of the carotid bifurcation.
2. The internal carotid artery ascends in the neck lateral and posterior to the external carotid and does not have any branches prior to entering the skull base. The external branch of the carotid artery is more medial and has eight branches. The superior thyroid, ascending pharyngeal, lingual, facial, and occipital arteries are the first five branches most likely encountered during resection.

Prerequisite Skills

The surgeon should be comfortable with routine identification and isolation of the carotid artery and nearby neurovascular

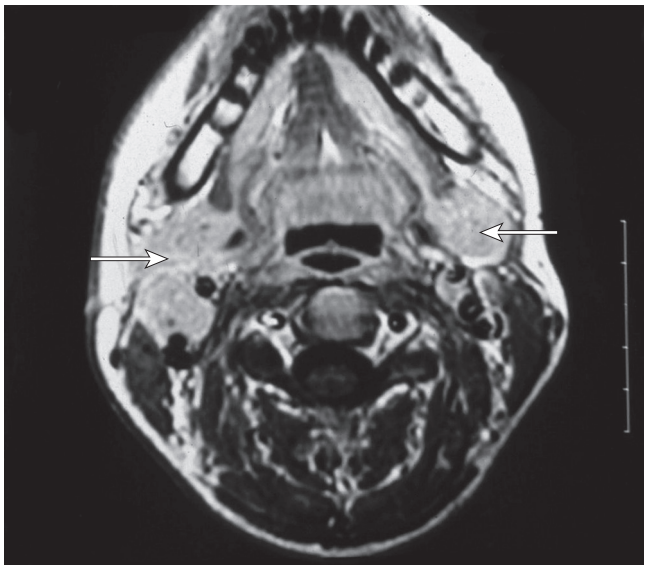

Fig. 73.3. Magnetic resonance angiogram of a 21-year-old woman with bilateral carotid body tumors *(arrows)*.



Fig. 73.5. Magnetic resonance angiogram of a mass in the neck mistakenly diagnosed as a carotid body tumor. Transfemoral angiography revealed an aneurysm of the internal carotid artery.

structures. Experience with excision of Shamblin type I tumors is recommended before excising larger and more complex tumors.

Operative Risks

1. Bleeding and inadvertent injury to neurovascular structures while managing bleeding are the two key operative risks for the procedure.
2. With careful identification and protection of the hypoglossal, vagus, and superior laryngeal nerves prior to resection of the tumor, risk of neural injury is low.
3. Obtaining proximal and distal control of the carotid artery with vessel loops limits the risk of catastrophic blood loss.



Fig. 73.4. Angiogram of the same patient demonstrates a carotid body tumor.

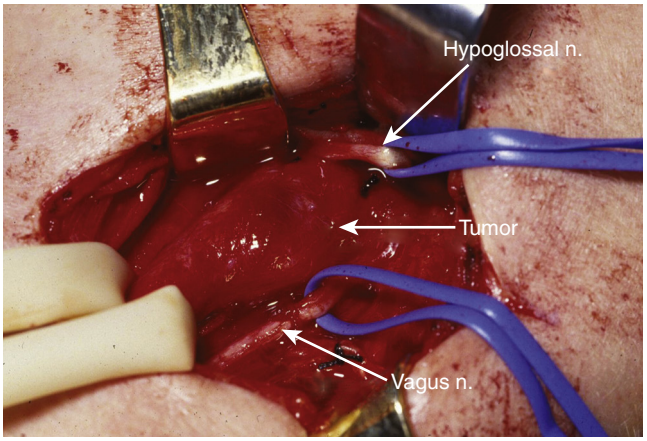

Fig. 73.6. The operative field, including tumor. The carotid artery and cranial nerves XI and XII have been identified; vessel loops are placed for safety.

Surgical Technique

CBTs are approached through a cervical incision. The incision is placed in a natural skinfold in the neck at the level of the superior border of the thyroid cartilage and carried through subcutaneous tissue and the platysma muscle. Subplatysmal skin flaps are elevated and the sternocleidomastoid muscle is identified and retracted. There is no need to dissect the submandibular triangle in this approach.

After the sternocleidomastoid muscle has been retracted, the carotid sheath will be identified. The jugular vein is then identified and dissected free of the carotid artery. The vagus and hypoglossal nerves are also skeletonized (Fig. 73.6). Arterial loops are placed around these structures for the purpose of identification and retraction. The common carotid artery is then identified and skeletonized, and a Penrose drain is placed around the artery. There is usually a large venous plexus that tracks inferiorly, approximately halfway down from the carotid bifurcation to the clavicle. At the point where the carotid artery

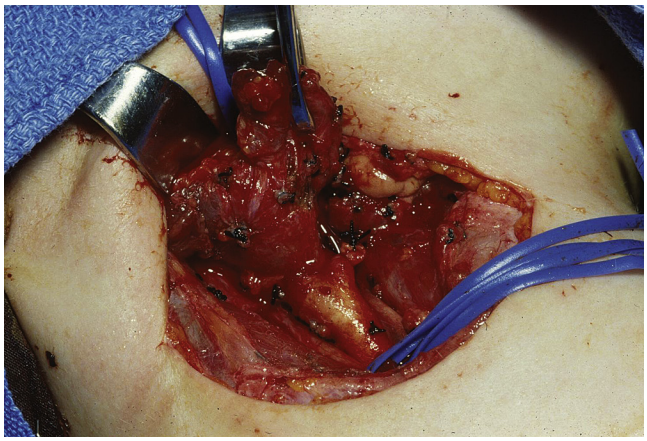

Fig. 73.7. Dissection is carried along the carotid artery in a subadventitial plane up to the bifurcation of the artery. The external carotid artery is then ligated.

is clear of this plexus, subadventitial dissection is begun. The dissection is carried superiorly until the bifurcation of the artery is encountered. At this time, dissection is carried superiorly along the external carotid artery approximately 1 to 2 cm above the bifurcation. The artery is then clamped, transected, and ligated with silk tie and a suture ligature (Fig. 73.7). The larger CBTs usually extend deep and may extend down to the prevertebral fascia (see Fig. 73.2), and, if the external carotid artery is not ligated, it is very difficult to gain entry for dissection in this deep plane. Using the same plane of dissection, the tumor is then dissected off the internal carotid artery and removed. Identification and retraction of the neural structures and the jugular vein usually result in a very clean, safe, uncomplicated, and relatively bloodless removal of the tumor.

Common Errors in Technique

The potential for injury to the carotid artery is minimized by preoperative evaluation to rule out the possibility of encasement of the carotid artery and invasion of the artery by the tumor. Even very precise dissection in the subadventitial plane is dangerous and should not be attempted in this setting. Failure to properly identify and preserve the vagus and hypoglossal nerves will result in functional deficits.

POSTOPERATIVE PERIOD

Postoperative Management

Patients may complain of pain in the area of the parotid gland and jaw that lasts a few seconds and is most painful with the first meal of the day. This "first bite" syndrome may occur when the carotid sheath is violated and sympathetic deinnervation to the parotid region occurs. Many find the pain tolerable; however, botulinum toxin type A injection to the parotid can be used successfully in patients who have significant discomfort.

In special circumstance of bilateral CBT excision, patients are at risk for baroreceptor failure. With the loss of parasympathetic input, they are at risk for hypertensive crisis when the sympathetic system is triggered. These patients must be referred for blood pressure management and have been given anxiolytics to blunt a sympathetic drive.

The vast majority of CBTs are benign lesions that do not require long-term follow-up. Rarely, malignant degeneration of a CBT is identified. The benign and malignant forms have the same histologic pattern. The diagnosis of malignancy is based upon finding CBT in the cervical lymph nodes, invasion of adjacent structures, or distant metastases. These tumors should be discussed in a multidisciplinary fashion with radiation and medical oncologists, and the patients should be followed long-term for recurrent disease.

Complications

Inadvertent injury to the hypoglossal in itself is not severe; however, whenever possible a neurorrhaphy should be performed. Inadvertent transection of the vagus nerve will require evaluation and management of a paralyzed vocal fold. Although medialization is an option at the time of surgery, it is also reasonable to assess the voice quality and risk for aspiration in the immediate postoperative period. Immediate thyroplasty is discussed in detail in Chapter 6. The position of the paralyzed vocal fold may vary, and, if immobilized in the paramedian position, it may not require medialization. Patients will have substantial dysphagia and risk of aspiration if both the hypoglossal and the vagus nerve are injured.

Alternative Management Plan

Definitive radiation is an acceptable option for patients who are not good candidates for surgical resection or who demonstrate growth of CBT on CT scan or become symptomatic due to tumor-related effects, such as cranial nerve deficits or hypertension.

DISCUSSION

Evidence-Based Medicine Question

What is the role for preoperative embolization on CBT surgery?

The use of preoperative embolization and its effect on blood loss, operative time, and complication rate is controversial and has not been prospectively studied. In a recent review of current guidelines regarding evaluation and management of PGLs, Moore et al. do not offer criteria for when to consider preoperative embolization.[3] Litle et al. considered this question and found no benefit for tumors smaller than 5 cm.[4]

Jackson et al. recently summarized the available literature.[5] There is limited evidence to determine whether preoperative embolization has an effect on operative blood loss, operative time, or complications (including permanent cranial nerve injury). Of 2418 studies available in the literature, only 22 studies provided qualitative data and 8 provided quantitative data, which could be included in a meta-analysis. None of these studies were prospective or used patient randomization. Nonetheless, when studying blood loss, data could be extracted for 295 tumors and demonstrated significantly less estimated blood loss by more than 50%. In addition, 174 tumors were analyzed for operative time, and the authors found that the tumors excised following embolization required nearly half the time. Although there are a number of limitations to this meta-analysis, the potential effect is large. This question would best be addressed in a randomized prospective study.

Editorial Comment

Radiologists using the CT scanner introduced in the early 1980s were the ones who defined the PPS. Hugh Curtin and Peter Som were leaders in providing head and neck surgeons with invaluable information, which was a tremendous help in devising a plan of management for tumors arising in the PPS. These radiologists correlated the CT scans with surgical findings, which allowed the surgeon to predict the types of tumors in the PPS. They divided the PPS into pre and post styloid and

observed that most tumors arising in the post-styloid space were of neural origin, and most were PGLs.

This observation led to a safer way of managing the PPS tumors. The Shamblin classification of CBT, published prior to the use of CT scanners has been of great value in predicting whether a CBT could be removed safely with low morbidity.

In addition to improvements in imaging and surgical techniques, research into the molecular genetics of PGLs has been of great help in the management of patients with PGLs and their families. Bora Baysal in the Department of Human Genetics, in collaboration with members of the Department of Otolaryngology at the University of Pittsburgh, identified the relationship of the SDHD gene (an oxygen sensing gene) in the development of PGLs. Multiple PGLs in the head and neck are common in patients with SDHD mutations. Hereditary PGLs are mostly caused by mutations of the SDHD gene. These observations have allowed us to establish a website that offered screening for the presence of the SDHD gene in family members of patients who have been diagnosed with an SDHD type of PGL. This has resulted in early detection and successful removal of otherwise undetected PGLs with a low morbidity.

Eugene N. Myers



Access the review questions and additional sources list online at http://www.expertconsult.com

REFERENCES

1. Shamblin WR, ReMine WH, Sheps SG, Harrison EG. Carotid body tumor (chemodectoma). Clincopathologic analysis of ninety cases. Am J Surg 1971;122(6):732–739.
2. Baysal BE, Ferrell RE, Willett-Brozick JE, et al. Mutations in *SDHD*, a mitochondrial complex II gene in hereditary paraganglioma. Science 2000;287:848–851.
3. Moore MG, Netterville JL, Mendenhall WM, Isaacson B, Nussenbaum B. Head and neck paragangliomas: an update on evaluation and management. Otolaryngol Head Neck Surg 2016;154(4):597–605.
4. Litle VR, Reilly LM, Ramos TK. Preoperative embolization of carotid body tumors: when is it appropriate? Ann Vasc Surg 1996;10(5):464–468.
5. Jackson RS, Myhill JA, Padhya TA, McCaffrey JC, McCaffrey TV, Mhaskar RS. The effects of preoperative embolization on carotid body paraganglioma surgery: a systematic review and meta-analysis. Otolaryngol Head Neck Surg 2015;153(6):943–950.

REVIEW QUESTIONS

1. What distinguishes a Shamblin type II from a Shamblin type III carotid body tumor?
   a. Size alone
   b. Size and attachment to the carotid artery
   c. Attachment to the carotid artery
   d. Associated cranial neuropathy

2. In the familial form of CBT, what is the dominant type of genetic inheritance?
   a. Autosomal recessive
   b. Autosomal dominant
   c. X-linked
   d. Mitochondrial

3. What is the most reliable anatomic landmark for the carotid bifurcation?
   a. Hyoid bone
   b. Thyroid notch
   c. Superior border of the thyroid cartilage
   d. Angle of the mandible

4. What is the laboratory test used to determine if the CBT is secreting adrenaline?
   a. Blood norepinephrine and epinephrine levels
   b. Urine epinephrine level
   c. Urine norepinephrine/epinephrine ratio
   d. Urine vanillylmadelic acid level

ADDITIONAL SOURCES

Chiu AG, Cohen JI, Burningham AR, et al. First bite syndrome: a complication of surgery involving the parapharyngeal space. Head Neck 2002;24:996–999.

Cohen SM, Buckey BB, Netterville JL. Surgical management of parapharyngeal masses. Head Neck 2005;27:669–675.

Netterville JL, Jackson CG, Civantos F. Thyroplasty in the functional rehabilitation of neurotologic skull base surgery patients. Am J Otol 1993;14:460–464.

Song AY, Myers EN, Gupta N. A case of mistaken identity: intraoperative discovery of an extracranial internal carotid artery aneurysm. Ann Vasc Surg 2005;19:896–899.

74 Endoscopic and Robotic Applications to Neck Surgery

Brian J. Boyce, David M. Cognetti

INTRODUCTION

Traditional approaches for surgery of the neck involve a relatively long incision that is usually through a transverse skin crease. The length of the incision varies and depends on the procedure to be performed, but it must be of sufficient length to provide adequate exposure and removal of the desired tissue. For neck dissections, several eponymous incisions have been described such as the Crile, MacFee, and Kocher incisions. While safety and exposure are the first priorities when planning a surgical incision, providing optimal cosmesis is also an important factor for many patients.

Many recent technological advances have allowed for smaller incisions from remote locations. In the 1950s, Harold Hopkins invented the rod lens endoscope that provides superior illumination, image resolution, and magnification for minimal access surgery. The Hopkins rod lens endoscope remains the instrument of choice today for endoscopic surgeons and is frequently paired with a high-definition camera system. Robotic surgical platforms are another technology that has been used in minimal and remote access surgery. Robotic surgery allows for enhanced visualization using a three-dimensional high-definition endoscopic camera system, wristed instrumentation, and tremor reducing technology. Typically, the surgeon sits at a console that controls the robotic instrumentation, and a bedside cart contains the robotic arms and endoscope.

The initial application in head and neck surgery for minimally invasive surgery, both endoscopic and robotic, was in parathyroid and thyroid surgery.[1-4] As surgeons became more comfortable with direct incision endoscopic techniques, the approaches expanded to include rhytidectomy and retroauricular incisions and applications expanded to include excision of the submandibular glands and neck dissections.[5] The details of thyroid and parathyroid endoscopic and robotic surgery, including transaxillary approaches, are covered in another chapter.

The first description of endoscopic excision of the submandibular gland in humans was described by Guyot, when he determined the feasibility in human cadavers.[6] While there was a 17% complication rate with damage to the facial artery and lingual nerve, both of these injuries occurred on the first cadaver dissection and were attributed to lack of training. There were no complications in many of the remaining dissections. A study was also performed on 12 patients using an incision in the midline at the hyoid bone, which did not have any complications or need to convert to an open procedure.[7] Multiple other studies have shown the efficacy of endoscopic excision of the submandibular gland without the need for gas insufflation.[8,9] Some studies have used CO_2 insufflation to maintain the working space, but complications from the insufflation including massive subcutaneous emphysema, arrhythmia, pneumothorax, hybercarbia, and death have been reported.

Robotic approach to the submandibular gland through a retroauricular incision has also been described.[10] As a natural extension of the robotic work with thyroid cancer, there has been an interest in performing central and lateral neck dissections through the same remote and minimally invasive incisions. These have been described through retroauricular incisions and transaxillary incisions. In 2012, the first study on cadavers focusing solely on lateral neck dissection was published demonstrating feasibility. The robot was then used successfully for lateral neck dissections in patients with upper aerodigestive tract malignancies with both N0 and N+ neck disease. Lastly, endoscopic and robotic approaches to benign tumors of the neck, especially second branchial cleft cysts, have been reported with good success. This chapter will focus on the rationale and technical aspects of endoscopic and robotic neck surgery.

KEY OPERATIVE LEARNING POINTS

- The primary advantages of endoscopic and robotic neck surgery are a less conspicuous and more aesthetically pleasing scar.
- The current applications for these approaches include submandibular gland excision, lateral neck dissection in early stage malignancies, and excision of the branchial cleft cysts.
- Endoscopic and robotic approaches to the neck are comparable in efficacy and safety to standard approaches but offer improved cosmesis.
- Endoscopic and robotic approaches require more operative time, but increased experience reduces the operative time.

PREOPERATIVE PERIOD

History

- Benign tumors of the neck: onset, location, previous infections, previous treatments (incision and drainage), changes in size, and date of the last infection
- Sialadenitis: onset, duration, number of previous infections, most recent infection, pain with eating, hydration status, previous treatments
- Malignancy: onset, location, pain, otalgia, dyspnea, dysphagia, weight loss, any previous biopsies or imaging
- Past medical history
  - Medical history: previous treatment for cancer of the head and neck, carotid artery disease/TIA, bruising or bleeding easily, hypertrophic scarring or keloids, connective tissue disorders
  - Surgical history: previous surgery of the head or neck (e.g., excisional biopsy, spine surgery, carotid endarterectomy)
  - Social history: tobacco, alcohol, or use of illicit drugs
  - Family history: bleeding disorders (von Willebrand's disease, hemophilia), history of adverse reactions to anesthesia
  - Medications:
    - List any anticoagulants and have a perioperative plan for managing them. This should be made in conjunction with the prescribing physician.
    - Stop all herbal supplements and over-the-counter vitamins one week prior to surgery.

Physical Examination

- Head
  - Examine for any previous scars along the hairline indicating a previous cosmetic procedure, especially previous facelift.
- Oral cavity and oropharynx
  - Assess the primary site for any patient with malignancy.
  - Palpate the floor of the mouth for any submandibular calculi.
- Salivary glands
  - Palpate the parotid and submandibular glands and note any swelling, firmness, or tenderness.
  - Massage the glands and evaluate for salivary flow from Stensen's and Wharton's ducts. Note the presence or absence of saliva and consistency (purulent, turbid, normal).
- Neck
  - Note the patient's habitus/obesity and neck girth.
  - Examine neck for scars indicating previous surgery.
  - Palpate the neck for any lymphadenopathy.
  - Examine for neck mobility.
- Neurologic examination
  - Shoulder mobility and function of CN XI (ability to raise the arm above the shoulder)
  - Tongue mobility and sensation
  - Assessment of facial nerve function
- Laryngoscopy
  - Evaluate the hypopharynx and larynx in patients with known cancer of the head and neck.

Imaging

- The best modality depends on the type of pathology and the surge on preferences.
- Ultrasound
  - Good initial choice to assess submandibular glands or suspected branchial cleft cysts in younger patients to avoid radiation exposure
  - Able to evaluate tissue characteristics with good resolution and real-time Doppler
  - Also good for evaluating the neck for metastases to the cervical lymph nodes and can be combined with fine-needle aspiration (FNA) biopsy
  - The biggest disadvantage is that the image acquisition is operator dependent.
- Computed tomography (CT) scan with contrast
  - Advantages include lower relative cost and excellent anatomic detail.
  - Best for evaluation of sialolithiasis and osseous detail
- Magnetic resonance imaging (MRI) with gadolinium
  - Best anatomic detail for soft tissues
  - Limited by its increased cost, susceptibility to motion artifact, and poor osseous detail

Indications

- Submandibular gland excision
  - Sialolithiasis
  - Chronic sialadenitis
  - Benign tumors of the salivary gland
- Selective neck dissection
  - Early stage primary (T1 or T2) where no microvascular reconstruction is needed
  - Early stage salivary gland malignancies (T1 or T2)
  - N0 (or N1 in select patients) neck stage
- Branchial cleft cysts or other benign masses of the neck

Contraindications

- Previous neck surgery
- Metastases to the cervical lymph nodes with evidence of extracapsular extension on imaging
- History of radiation to the neck. Some authors have performed robotic neck dissections in patients with a history of radiation to the neck, but given the longer operative times, we do not recommend it.
- Recurrent cancers of the head and neck
- Primary tumors that require microvascular reconstruction
- Significant inflammation or high degree of adhesions surrounding the submandibular gland
- Coagulopathies

Preoperative Preparation

- Review all imaging studies prior to making the incision.
- Discuss surgical options in detail with the patient including the likelihood of possible conversion to a more conventional open technique.
- Perform a system check and instrument check prior to the incision, especially when considering distant access approaches.

OPERATIVE PERIOD

Anesthesia

- General anesthetic
- No paralytics

Positioning

- Supine
- Head turned to the contralateral side
- Neck slightly extended with shoulder roll
- For transaxillary approaches, the ipsilateral arm should be raised by 70 to 90 degrees, and no shoulder roll should be used.

Preoperative Antibiotic Prophylaxis

- None, since it is considered a clean surgery

Monitoring

- None
- Continuous nerve monitoring is not routinely used for neck dissections, submandibular gland (SMG) excisions, or excisions of branchial cleft cyst/benign neck mass.
- A hand held stimulator is helpful to confirm function of the nerves once they have been identified using standard landmarks and knowledge of anatomy.

Instruments and Equipment to Have Available

- Endoscopic
  - Four-millimeter rigid Hopkins-rod endoscope
    - Both 0- and 30-degree scopes
  - Long Debakey forceps
  - Harmonic scalpel (optional)
  - Endoscopic clip appliers
- Robotic
  - daVinci robotic surgical platform
  - Five-millimeter Maryland dissector
  - Eight-millimeter Prograsp forceps

- Five-millimeter Harmonic scalpel
- Endoscopic clip appliers
- Lighted breast retractors
- Chung retractor set with suspension table
- Long vascular Debakey forceps

Key Anatomic Landmarks

- Advanced knowledge of neck anatomy is the foundation for safe and effective surgery. This is especially true for robotic and endoscopic approaches to the neck. Since these techniques approach from remote locations and unusual angles, the surgeon can easily become disoriented. It is important to know the anatomic relationships and dissection planes, so the operation can be performed effectively and safely without increased complications.
- See the neck dissection chapters (see Chapters 63, 64, 65, and 66) for detailed descriptions of the landmarks below that will provide a road map for endoscopic and robotic neck surgery.
  - Platysma
  - Sternocleidomastoid muscle (SCM)
  - Great auricular nerve
  - External jugular vein
  - Cervical rootlets
  - Carotid artery
  - Vagus nerve
  - Internal jugular vein
  - Marginal mandibular nerve
  - Facial artery and vein
  - Lingual nerve
  - Hypoglossal nerve
  - Spinal accessory nerve

Prerequisite Skills

- Experience with conventional neck dissections
- Experience with conventional excision of the submandibular gland
- Robotic surgery training and experience
- Familiarity with endoscopic and laparoscopic equipment can be advantageous

Operative Risks

- Neural
  - Marginal mandibular nerve weakness
  - Spinal accessory nerve damage/shoulder syndrome
  - Horner's syndrome from injury to the sympathetic chain
  - Tongue weakness or dysesthesia from injury to the hypoglossal nerve or lingual nerve
  - Numbness
- Vascular
  - Intraoperative bleeding
  - Postoperative bleeding/hematoma
  - Stroke
- Seroma
- Sialocele
- Chyle leak
- Infection
- Poor wound healing/scarring

Surgical Techniques

- Direct endoscopic excision of the submandibular gland
  - Methods using CO_2 insufflation and a gasless technique have been described. A gasless technique is preferred as it avoids potential life-threatening complications of CO_2 insufflation such as pneumothorax, subcutaneous crepitus, hypercarbia, and arrhythmias.
  - A 20- to 25-mm incision is made in a well-hidden transverse skin crease at the inferior border of the SMG. Some authors make their incision in the submental crease in the midline in an effort to better hide the scar, but this makes visualization of the lingual nerve and SMG duct deep to the mylohyoid more challenging.
  - Inject the planned incision with 1% lidocaine with 1:100,000 parts epinephrine.
  - Sharply incise through the skin and subcutaneous tissue. Divide the platysma and elevate subplatysmal flaps. Retractors are used to maintain the working space.
  - An assistant surgeon inserts either the 0-degree or 30-degree endoscope into the surgical bed to provide visualization.
  - Use either bipolar cautery or sharply incise the fascia of the SMG.
  - Bluntly dissect the fascia off the lateral surface of the gland. Staying in this plane will protect the marginal mandibular nerve as it is swept superiorly in the fascia.
  - As the superior surface of the gland is encountered, ligate the distal facial artery and vein. It is safer to ligate the entire distal facial artery instead of trying to preserve it and ligate only the branches to the SMG.
  - At the inferior border, bluntly dissect the gland away from the digastric muscle. As dissection is carried along the posterior belly of the digastric, identify and ligate the proximal facial artery with double hemoclips.
  - Dissect anteriorly to release the gland off the mylohyoid. Beware of the submental vessels that will need to be controlled.
  - Retracting the gland inferiorly and the mylohyoid anteriorly, the lingual nerve, submandibular ganglion, and submandibular duct can be visualized under magnification.
  - Ligate the submandibular ganglion and duct. If removing the gland for sialolithiasis, ensure that the calculus is included in the duct before ligation.
  - Remove the gland.
  - Irrigate the wound and ensure hemostasis.
  - Sometimes the skin edges can be traumatized due to the amount of retraction needed and can be freshened to provide optimal wound healing and cosmesis.
  - Place a drain (suction or Penrose) as needed.
  - Close the wound in layers.
- Robotic retroauricular approach
  - This approach can be used for resection of the SMG, neck dissections, and excisions of the branchial cleft cyst. There are three steps to the surgery: elevation of the flap, bedside direct visualization, and robotic visualization.
  - Flap elevation
    - A retroauricular incision is made from the post-auricular crease and curves inferiorly into the hairline by 5 to 10 mm to hide the scar (Fig. 74.1).
    - Dissection proceeds anteriorly in a subplatysmal plane. The great auricular nerve and external jugular vein are identified and preserved. Continue dissection to the midline anteriorly, clavicle inferiorly, and inferior mandible as the upper limit. Using a lighted breast retractor can aid in visualization.
  - Bedside direct visualization
    - Under direct visualization, the marginal mandibular nerve is identified at the mandibular notch and swept above the mandible for protection.



Fig. 74.1. Outline of rhytidectomy and retroauricular incision.

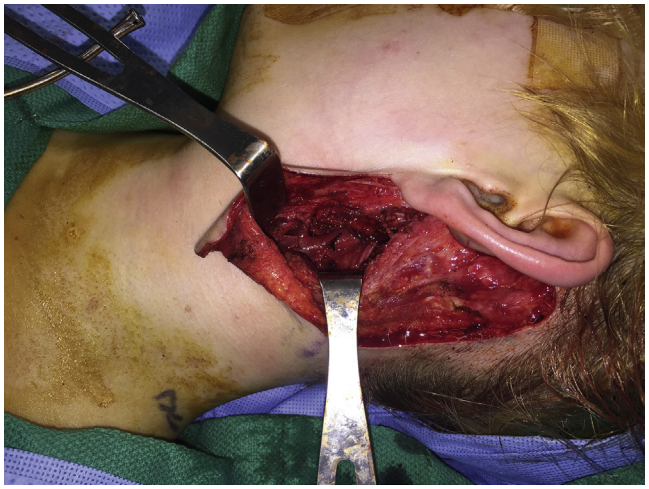

Fig. 74.2. Example of the exposure gained through a retroauricular incision for removal of a branchial cleft cyst that has been excised.

- Begin dissecting along the anterior border of the SCM, and identify CN XI.
- If you are excising a branchial cleft cyst, at this time dissect along the cyst wall circumferentially. If a tract is identified toward the pharynx, ligate it with 2-0 silk suture. The majority of branchial cleft cysts can be excised without robotic assistance (Fig. 74.2).
- For neck dissection, trace CN XI in a retrograde fashion until it crosses the IJV. The position of CN XI relative to the IJV is variable, but it typically crosses superficial to the IJV (detailed in Neck Dissection Chapters 63, 64, 65, and 66).
- Dissect level IIB off the trapezius muscle, and sweep it under CNXI.
- In level IIA and III, dissect through the fibroadipose tissue to identify the cervical rootlets. Dissect the fibroadipose tissue anteriorly over the deep cervical fascia and cervical rootlets.
- The level II and III contents lateral to the IJV are then dissected off the carotid sheath.
- If dissection of level V is required, this is also performed under direct visualization. Identify CN XI at the posterior border of the SCM approximately 1 cm above Erb's point. Trace CN XI in an anterograde fashion through level V. Dissect onto the floor of level V preserving the transverse cervical vessels and brachial plexus. Reflect the fibroadipose tissue medially around the cervical rootlets if possible until they are completely excised. If the supraclavicular nerves require sacrifice distally, make sure the proximal transection on the cervical rootlets preserves the contributions to the phrenic nerve.

- Robotic
  - At this point the robot is docked and the Maryland dissector is used in one operating arm and the Harmonic shears are used in the other.
  - For excision of the submandibular gland, begin at the posterior digastric and ligate the proximal facial artery with hemoclips. Next, retract the submandibular gland inferiorly and ligate the facial artery and vein distally at the inferior border of the mandible. The marginal mandibular nerve should be protected at this time since it has already been identified and swept over the mandible.
    - Bluntly dissect the fascia off the gland anteriorly and onto the mylohyoid.
    - Retract the gland inferiorly and identify the lingual nerve, submandibular ganglion, and submandibular duct.
    - Ligate the ganglion and the duct using the Harmonic shears, and remove the gland.
  - If proceeding with a neck dissection, release all the fibroadipose contents containing the perifacial nodes inferiorly off the inferior aspect of the mandible to the anterior belly of the digastric.
  - Sweep the anterior IB content posteriorly off the mylohyoid identifying and controlling the submental vessels with the Harmonic scalpel.
  - Identify the lingual nerve, submandibular ganglion, and SMG duct. Ligate the duct and ganglion with the Harmonic shears, which will free the level IB contents.
  - Using monopolar cautery, dissect level IA from between the anterior bellies of the digastric and off the mylohyoid muscle.
  - For dissection of level IV, proceed by incising the fibroadipose tissue and identifying the transverse cervical vessels and cervical rootlets. Sweep the contents medially over the phrenic nerve. When dissecting medially along the carotid sheath, use the Harmonic scalpel and hemoclips to divide the tissue inferiorly to prevent a chyle leak. Dissect the contents off the carotid sheath to free it completely.
  - Obtain hemostasis after irrigation.
  - Place a suction drain that exits in the hairline.
  - Close the incision in a layered fashion (Fig. 74.3).
- Robotic transaxillary neck dissection
  - This approach is typically used for metastatic cancer to the nodes in the lateral neck in papillary thyroid cancer, so levels IIA, III, IV, and VB are the commonly dissected levels.
  - Position the patient facing the contralateral side. The arm is abducted at least 70 to 90 degrees to provide an adequate corridor for the robot (Fig. 74.4).
  - Make a 10-cm incision along the anterior axillary crease. Dissect in a suprafascial plane above the pectoralis major muscle to the sternal notch and clavicle.



Fig. 74.3. Example of an inconspicuous healed retroauricular incision at 3 months postoperative.



Fig. 74.4. Positioning for the robotic transaxillary approach for thyroidectomy or neck dissection. Incision is planned on the anterior axillary crease.

- Once over the clavicle, dissect in a subplatysmal plane to the midline and superiorly to the submandibular gland. CN XI is identified in level V and traced retrograde to the SCM. The external jugular vein is ligated as it crosses the posterior border of the SCM. Identify and preserve the great auricular nerve.
- Dissect deep to the SCM, and divide the clavicular head of the SCM.
- Insert the Chung retractor under the SCM and place it in suspension (Fig. 74.5).
- The docking of the robot is the next step in the procedure, and it should be performed conscientiously. If the necessary time and attention to detail are not allowed to ensure proper placement of the robotic arms, it will cause collisions and more time spent adjusting the robot later.



Fig. 74.5. Placement of the Chung retractor under the SCM through the transaxillary incision.

- Place the 30-degree camera facing down in the center of the axillary incision. The ProGrasp forcep should be placed just to the right of the camera but at the superior-most portion of the working space. The Maryland dissector is placed as far to the left of the camera as possible and the Harmonic shears are as far to the right of the camera as possible.
- Divide the omohyoid at the level of the thyroid cartilage.
- The ProGrasp forcep is used to grasp the IJV and pull it superomedially.
- Dissection begins in level III and IV as the plane is developed between the IJV and fibroadipose tissue laterally. Once this plane is developed, the fibroadipose tissue can be dissected off the carotid sheath in a medial to lateral fashion. In level IV on the right side, it might be necessary to switch the Maryland dissector to the right hand and the Harmonic to the left in order to reach in lower level IV under the clavicle. Take care not to damage the thoracic duct, phrenic nerve, and transverse cervical vessels.
- Continue dissection into level VB over the deep cervical fascia and brachial plexus. Divide the omohyoid near the scapula origin. CN XI should already have been exposed in the initial step of the surgery to create a working corridor.
- In order to access level IIA, the Chung retractor will have to be re-inserted more cranially.
- The Maryland is used to pull the fibroadipose contents inferior and lateral, and it is released from the submandibular gland. Dissection proceeds over the carotid sheath medially and cervical rootlets laterally.
- The entire specimen can be removed en bloc.
- Irrigate the surgical bed and obtain hemostasis.
- Place a suction drain.
- Close the incision in a layered fashion.

- Direct incision endoscopic branchial cleft cyst excision
  - Identify a transverse skin crease over the cyst.
  - A two-centimeter incision is placed over the cyst regardless of the size of the cyst.
  - Incise the skin and platysma.
  - Elevate subplatysmal flaps.
  - Dissect along the anterior border of the SCM around the cyst.
  - A 25 G needle is inserted into the cyst to partially decompress it. A hemostat clamp is placed over the puncture site to prevent further leakage and to assist with manipulation of the cyst.

- Dissect along the cyst wall circumferentially under endoscopic magnification.
- If a tract to the pharynx is encountered, be sure that it is ligated before complete excision of the cyst.
- Obtain hemostasis after irrigation.
- A drain is not typically needed.
- Close the skin in a layered fashion.

Common Errors in Technique

- Not converting to open approach if significant bleeding or if significant inflammation/adhesions are encountered

POSTOPERATIVE PERIOD

Postoperative Management

- Regular diet
- Pain control regimen
- Drains may be removed once output is less than 30 to 50 cc/day

Complications

- See neck dissection and submandibular gland excision chapters.
- It is important to mention that with transaxillary approaches, there is a possibility of brachial plexus neuropathy due to the arm positioning as well as due to surgical dissection in the neck.

Alternative Management Plan

- Conventional open neck surgery

DISCUSSION

Evidence-Based Medicine Question

Are robotic lateral neck dissections as effective and safe as traditional approaches to the neck?

While there have not been any randomized controlled studies that address this question, several manuscripts have retrospectively compared the two approaches. A study by Kang et al. compared the results of 56 patients who had a robotic neck dissection with 109 patients who had a conventional neck dissection for papillary thyroid cancer. There was no significant difference in the total number of lymph nodes retrieved or in the rates of complications. Another study compared the two approaches retrospectively in patients with oral cavity cancer. This again demonstrated no difference in the complication rate or number of lymph nodes removed. Neither group had any evidence of regional recurrence, but the follow-up time was limited to 6 months. Lastly, a North American–based group reported on their experience with robotic lateral neck dissection in patients with head and neck mucosal malignancies. This study did not find any significant differences in lymph nodes removed or compilations. In all the studies listed above, the robotic approach was associated with significantly longer operative times than the traditional approach.

Editorial Comment

Distant access surgery provides an option for surgical access for patients seeking a more cosmetic option for a visible scar on the neck. While distant access neck surgery (endoscopic and robotic) have been proven to be safe, these procedures are longer and require expertise available in few centers. In addition, certain complications are introduced to the conventional procedure that are unique to distant access surgery, such as conversions to open approaches, brachial plexus neuropathy due to arm position for transaxillary surgery and hypercarbia, and subcutaneous emphysema associated with insufflation techniques. The surgical anatomy and approach for these procedures can be challenging for even experienced head and neck surgeons. Consequently, although feasible, distant access surgery must be offered at centers where expertise in these procedures is available; moreover, case selection must performed carefully, taking into consideration patient factors (cosmesis, patients anatomy, BMI, comorbidities), surgical factors (surgeon experience and comfort level with surgical anatomy), and institutional factors (availability of equipment and trained staff).

Rohan R. Walvekar

Access the review questions and additional sources list online at http://www.expertconsult.com

REFERENCES

1. Gagner M. Endoscopic subtotal parathyroidectomy in patients with primary hyperparathyroidism. Br J Surg 1996;83:875.
2. Miccoli P, Elisei R, Materazzi G, et al. Minimally invasive video-assisted thyroidectomy for papillary carcinoma: a prospective study of its completeness. Surgery 2002;132:1070–1073.
3. Lee J, Kang SW, Jung JJ, et al. Multicenter study of robotic thyroidectomy: short-term postoperative outcomes and surgeon ergonomic considerations. Ann Surg Oncol 2011;18:2538–2547.
4. Kuppersmith RB, Holsinger FC. Robotic thyroid surgery: an initial experience with North American patients. Laryngoscope 2011;121:521–526.
5. Byeon HK, Holsinger FC, Tufano RP, et al. Robotic total thyroidectomy with modified radical neck dissection via unilateral retroauricular approach. Ann Surg Oncol 2014;21(12):3872–3875.
6. Guyot L, Duroure F, Richard O, et al. Submandibular gland endoscopic resection: a cadaveric study. Int J Oral Maxillofac Surg 2005;34(4):407–410.
7. Chen MK, Su CC, Tsai YL, et al. Minimally invasive endoscopic resection of the submandibular gland: a new approach. Head Neck 2006;28(11):1014–1017.
8. Baek CH, Jeong HS. Endoscope-assisted submandibular sialadenectomy: a new minimally invasive approach to the submandibular gland. Am J Otolaryngol 2006;27(5):306–309.
9. Parente Arias PL, Fernández Fernández MM, Varela Vázquez P, et al. Minimally invasive video-assisted submandibular sialadenectomy: surgical technique and results from two institutions. Surg Endosc 2015;30(8):3314–3320.
10. Terris DJ, Haus BM, Gourin CG, et al. Endo-robotic resection of the submandibular gland in a cadaver model. Head Neck 2005;27(11):946–951.

REVIEW QUESTIONS

1. What is the primary benefit of robotic and endoscopic approaches to the neck?
   a. Fewer complications because of the magnified field
   b. Shorter hospital stay
   c. Improved cosmesis and less conspicuous scar
   d. Improved postoperative pain scores

2. Which of the following is a contraindication to robotic and endoscopic neck surgery?
   a. BMI >30
   b. N1 nodal disease
   c. Lymph node with ECS
   d. Allergy to latex

3. All of the following are drawbacks to robotic neck surgery, except
   a. Increased rate of complications
   b. Longer operative times
   c. Increased cost

ADDITIONAL SOURCES

Byeon HK, Holsinger FC, Kim DH, et al. Feasibility of robot-assisted neck dissection followed by transoral robotic surgery. Br J Oral Maxillofac Surg 2015;53(1):68–73.

Byeon HK, Holsinger FC, Tufano RP, et al. Robot-assisted level II-IV neck dissection through a modified facelift incision: initial North American experience. Int J Med Robot 2014;10(4):391–396.

Kang SW, Chung WY. Transaxillary single-incision robotic neck dissection for metastatic thyroid cancer. Gland Surg 2015;4(5):388–396.

Kang SW, Lee SH, Park JH, et al. A comparative study of the surgical outcomes of robotic and conventional open modified radical neck dissection for papillary thyroid carcinoma with lateral neck node metastasis. Surg Endosc 2012;26(11):3251–3257.

Kim CH, Koh YW, Kim D, et al. Robotic-assisted neck dissection in submandibular gland cancer: preliminary report. J Oral Maxillofac Surg 2013;71(8):1450–1457.

Lee HS1, Kim WS, Hong HJ, et al. Robot-assisted supraomohyoid neck dissection via a modified face-lift or retroauricular approach in early-stage cN0 squamous cell carcinoma of the oral cavity: a comparative study with conventional technique. Ann Surg Oncol 2012;19(12):3871–3878.

Shin YS, Hong HJ, Koh YW, et al. Gasless transaxillary robot-assisted neck dissection: a preclinical feasibility study in four cadavers. Yonsei Med J 2012;53(1):193–197.

Teng SE, Paul BC, Brumm JD, et al. Endoscope-assisted approach to excision of branchial cleft cysts. Laryngoscope 2016;126(6):1339–1342.

75 Management of Traumatic Soft Tissue and Vascular Injuries to the Neck

Richard A. Goldman, David M. Cognetti

INTRODUCTION

Patients with evidence of vascular or soft tissue trauma must be approached in a similar fashion as all trauma patients. Primary and secondary surveys initially screen for any imminently life-threatening injuries and guide the acute workup. Occasionally, that survey reveals a vascular injury to the neck requiring immediate surgical exploration, but in most cases, soft tissue injuries are addressed following initial evaluation and stabilization.

Fractures of the facial skeleton, injury of the orbit, pharyngoesophageal perforation, and laryngotracheal trauma must be considered and incorporated into the comprehensive approach to the trauma patient, but the details of the specific management of these injuries are addressed elsewhere in this textbook. Here we focus on the repair of mucosal and cutaneous injury, as well as the evaluation and management of vascular trauma.

KEY OPERATIVE LEARNING POINTS

1. A comprehensive knowledge of head and neck anatomy is essential in order to approach the wide variety of traumatic injuries.
2. Soft tissue repair requires meticulous attention to anatomic reapproximation with wound eversion and tension-free closure.
3. Management of vascular trauma should follow a systematic approach and appropriate application of diagnostic and therapeutic interventions.
4. The management of certain vascular and soft tissue injuries may require experience and techniques beyond the scope of practice of many head and neck surgeons, and consultation with additional specialists may be required.

PREOPERATIVE PERIOD

History

1. History of present illness
   a. Mechanism of injury: This is the single most important piece of historical information and will guide further history taking, physical examination, and workup.
      1) Determining the type of trauma allows an estimation of forces involved and potential severity of the injury.
         a) Types of blunt trauma: motor vehicle accident, fall, or assault
         b) Types of penetrating trauma: impalement, stab wound, projectile trauma, or gunshot wounds. The type of firearm and projectile should be investigated when possible to estimate the energy transmitted with the injury. A high-power rifle wound, for instance, will cause a greater degree of injury out of the immediate path of the projectile due to concussion and cavitation. Such injuries can be missed on initial evaluation and can result in delayed soft tissue necrosis.
   b. Timing of the injury: Prolonged delay will increase the risk of infection following primary closure.
   c. Additional historical considerations
      1) Memory of event/loss of consciousness
      2) High-volume or pulsatile bleeding prior to presentation
      3) Restrained or unrestrained, airbag deployment, and the use of a helmet
   d. Symptoms that may suggest additional injuries
      1) Dyspnea
      2) Dysphonia
      3) Nasal obstruction
      4) Changes in vision
      5) Malocclusion
      6) Epistaxis/rhinorrhea
2. Past medical history
   a. Medical illness
      1) Disease states that may affect wound healing or infection risk (e.g., diabetes, immunocompromised states)
   b. Prior surgery and anesthesia
   c. Family history: bleeding disorders
   d. Medications
      1) Anticoagulants
   e. Allergies
      1) Antibiotics
      2) Local anesthetics

Physical Examination

1. Primary and secondary trauma surveys
2. "Hard signs" of penetrating trauma
3. Neurologic examination
4. Signs of skull base injury
5. Types of soft tissue trauma
   a. Lacerations
      1) Simple, stellate, flap
   b. Abrasions
   c. Avulsions
   d. Burns
   e. Bite wounds—human/animal
   f. Gunshot and stab wounds
6. Specific anatomic evaluations
   a. Facial skeleton, projection, occlusion
   b. Facial nerve function
   c. Globe, pupillary response, orbit, eyelid, and lacrimal apparatus
   d. Lip, oral cavity, and pharynx
   e. Scalp
   f. Nasal deformity, septal hematoma
   g. Ear

Imaging

None

For simple soft tissue trauma with no evidence of more serious injury and low suspicion based on mechanism of injury, no imaging is required.

Computed Tomography

Computed tomography (CT) imaging is the mainstay of the trauma evaluation. In addition to the standard trauma head and cervical spine CT, noncontrast maxillofacial scans should be considered in patients with evidence of significant soft tissue injury (facial edema and ecchymosis) to evaluate for underlying trauma to the facial skeleton or skull base. A CT scan of the neck with contrast may help to evaluate injury to the upper aerodigestive tract. These studies may also identify orbital hematoma and injuries to the globe.

Computed Tomography Angiography

CT angiography (CTA) should be considered when initial studies have demonstrated evidence of skull base fractures extending close to the carotid canal. It has also become the dominant imaging modality in the evaluation of penetrating trauma of the neck.

Magnetic Resonance Imaging

While magnetic resonance imaging (MRI) may have some value in delayed evaluation of traumatic vascular and soft tissue injuries of the head and neck, its role is limited in the acute and preoperative setting.

Angiography

Four-vessel digital subtraction angiography is the generally accepted modality used in the evaluation of suspected vascular injury to the neck. Traditionally, it was a key part of the classical algorithms for management of penetrating trauma based on anatomic zones of injury. While somewhat controversial, its role in that respect has decreased in favor of more selective use. Over time, endovascular techniques have improved, and angiography as a diagnostic study can be combined with a variety of therapeutic interventions, including embolization and stenting, instead of open surgical exploration.

Duplex Ultrasonography

This modality may be used in the evaluation of the carotid arteries, but subtle signs of injury may be missed, and there is a high degree of interoperator variability.

Indications

1. Indications for immediate surgical exploration after penetrating trauma; "Hard signs"[1]
   a. Shock
   b. Pulsatile bleeding
   c. Expanding hematoma
   d. Unilateral pulse deficit
   e. Signs of stroke/cerebral ischemia
   f. Bruit or thrill
   g. Stridor, hoarseness
   h. Extensive subcutaneous air or wound bubbling
2. Indications for additional evaluation and possible exploration; "Soft signs"
   a. History of heavy or pulsatile bleeding
   b. Presence of clot
   c. Findings on angiography or CTA
3. Lacerations: P - capitalize to be consistentrimary closure usually indicated
4. Burns: Operative débridement may be required acutely.
5. Avulsions and abrasions: initial management usually limited to wound care
6. Penetrating trauma: Usually left open but partial closure of large wounds may be considered.

Contraindications

1. Other immediately life-threatening injury
2. Hemodynamic instability
3. Contaminated wounds open greater than 24 hours and penetrating wounds

Relative contraindication: Primary closure can be considered, but infection risk is increased. Antibiotics and drains may be appropriate.

Preoperative Preparation

1. Airway: Evaluate and secure when appropriate.
2. Control of hemorrhage: Active bleeding should be controlled in the trauma bay or emergency department.
   a. For suspected injury to the carotid artery, an assistant may need to maintain manual pressure to prevent exsanguination while proceeding emergently to the operating room. A balance must be struck between adequate pressure to control hemorrhage and the need to maintain cerebral perfusion.
   b. Hemorrhage from other soft tissue trauma should be controlled with pressure and dressings. Nasal packing can be used judiciously but with caution if there is concern for skull base injury. If the airway has been controlled, oral and pharyngeal bleeding can generally be controlled with packing. Scalp wounds can result in clinically significant blood loss. Hemostasis can be achieved with pressure dressing or temporary closure with staples or suture until definitive repair is performed.
3. Trauma resuscitation
4. Laboratory evaluation
   a. Hemoglobin/hematocrit
   b. Type and screen
   c. Toxicology

OPERATIVE PERIOD

Anesthesia

General Anesthesia

Emergent exploration of the neck requires a definitive airway and general anesthesia. Transnasal intubation might improve access to the high carotid by allowing increased subluxation and anterior displacement of the mandible. Transnasal intubation should not be performed if there is suspicion for skull base injury.

General anesthesia is also preferable for extensive soft tissue injuries, which will require extensive débridement and a lengthy repair. Long-acting paralytics should be avoided if nerve dissection and stimulation are required, as in facial nerve exploration and repair.

Sedation

Intravenous sedation may be an option if general anesthesia is contraindicated or if inadequate resources are available in a timely manner, since it can be administered outside of the operating room and without an anesthesiologist. The patient, however, must be continuously monitored, and a separate physician should be dedicated to that role. Sedation is often a good option in the pediatric population when general anesthesia is not required, but cooperation is inadequate to permit local anesthesia alone.

Local Anesthesia

The majority of minor soft tissue trauma can be repaired using local anesthesia alone. Knowledge of sensory neuroanatomy

and regional blocks can be extremely useful. These techniques allow excellent anesthesia with a lower total dose of anesthetic, and they avoid further distortion of the anatomy by local infiltration. Even if some local infiltration is needed or desired for hemostasis, blocking the area first will significantly improve patient comfort. Some of the simplest and most useful blocks include the inferior alveolar, mental, infraorbital, supraorbital, and supratrochlear.

Positioning

Positioning will vary depending on the specific procedure performed. For exploration of the neck, the patient is positioned supine with some degree of extension of the head and neck. The patient's arms should be secured at the sides so that access to the chest is maintained. The chest should also be prepared and included in the surgical field in the event that vascular access requires removal of the clavicle or a median sternotomy. Turning the bed 90 or 180 degrees may be helpful.

For soft tissue repairs, the patient should be positioned and prepped to afford access to all injuries including the scalp. For facial wounds, both sides of the face should remain in the field to evaluate symmetry. In awake and sedated procedures, semi-recumbent positioning will improve the patient's comfort and help him or her to maintain his or her airway.

Perioperative Antibiotic Prophylaxis

Operative primary closure of open wounds of the head and neck could be considered clean-contaminated or infected surgery, and, therefore, prophylactic antibiotic therapy would be indicated, according to clinical practice guidelines for surgery.[2] The use of antibiotics for simple wound repair, however, has been investigated with multiple clinical trials and a definite benefit has not been demonstrated.

Prophylactic antibiotics are, therefore, reserved for extensive injury or contamination and bite wounds, where a benefit has been demonstrated.[3]

First line: cefazolin + metronidazole, cefuroxime + metronidazole, or ampicillin-sulbactam
Second line: clindamycin

For bite wounds:

Prophylactic antibiotics for 3 to 5 days are indicated for repaired human or animal bite wounds to the head and face.

First-line treatment: amoxicillin-clavulanate
Second line:

- Moxifloxacin
- Doxycycline
- Cefuroxime + clindamycin or metronidazole
- Trimethoprim-sulfamethoxazole + metronidazole or clindamycin

Tetanus toxoid should also be administered if not previously received within 10 years or if unknown.

Monitoring

Routine general or sedation anesthesia monitoring.
EMG: Multichannel electromyography is essential in patients undergoing facial nerve exploration and repair.
EMG/EEG: Electromyography and electroencephalography can be used to evaluate for cerebral ischemia during routine carotid surgery but are not typically available in emergency surgery.
Pressure transduction: Backflow pressure of the distal carotid stump after clamping can be used to assess cerebral perfusion. Pressures below 50 mmHg indicate inadequate collateral flow and necessitate shunting.[4]

Instruments and Equipment to Have Available

Available equipment should be appropriate for the intended procedure and any contingency. This may include:

1. Basic plastic and eyelid instruments, hooks, and retractors
2. Intraoral retractors (Obwegeser, Minnesota, Weider [sweetheart])
3. Monopolar and fine bipolar cautery
4. EMG/nerve stimulation and monitoring system
5. Microsurgical instrumentation for nerve repair or revascularization
6. Vascular instruments and clamps
7. Specialty vascular supplies (shunts, balloon catheters)

Prerequisite Skills

1. Soft tissue handling and basic reconstructive technique
2. Oculoplastic experience in the management of major eyelid and lacrimal apparatus injuries
3. Microsurgical skill for neurorrhaphy and revascularization of amputated tissue segments
4. Neck dissection skills and management of the great vessels of the neck
5. Vascular techniques for carotid repair and revascularization

Operative Risks

1. Orbital injury
2. Facial nerve injury
3. Salivary duct obstruction
4. Lacrimal/canalicular obstruction
5. Skin ischemia
6. Massive hemorrhage/death
7. Stroke

Surgical Techniques

Wound Preparation

Irrigation

- Open wounds should be copiously irrigated with saline. For large and heavily soiled wounds, pulsatile irrigation systems can help to efficiently cleanse the wound. Dried blood, clots, and foreign material should be removed, and the wounds should be carefully inspected to fully appreciate all injuries. When included in the field, the eye should be protected with a scleral shield or tarsorrhaphy.

Débridement

- Foreign material that is not rinsed from the wound should be removed mechanically. Most large pieces of debris can be removed with agitation with a sponge or forceps. Implanted projectiles and glass may need to be gently dissected from the wounds. Small imbedded foreign bodies that are retained will result in tattooing so attempts should be made to remove them with mechanical débridement or dermabrasion. This can be done carefully with a scalpel in a scraping rather than cutting motion.
- Devitalized tissue should be sharply excised. Severely contused wound edges can be débrided to facilitate closure between healthier tissues. Rough and irregular wound edges can also be débrided to facilitate simple linear or curvilinear re-approximation.

Re-approximation and Adjacent Tissue Rearrangement

Low tension closure: Deeper layers should be closed such that the epidermis can be aligned and closed without tension.

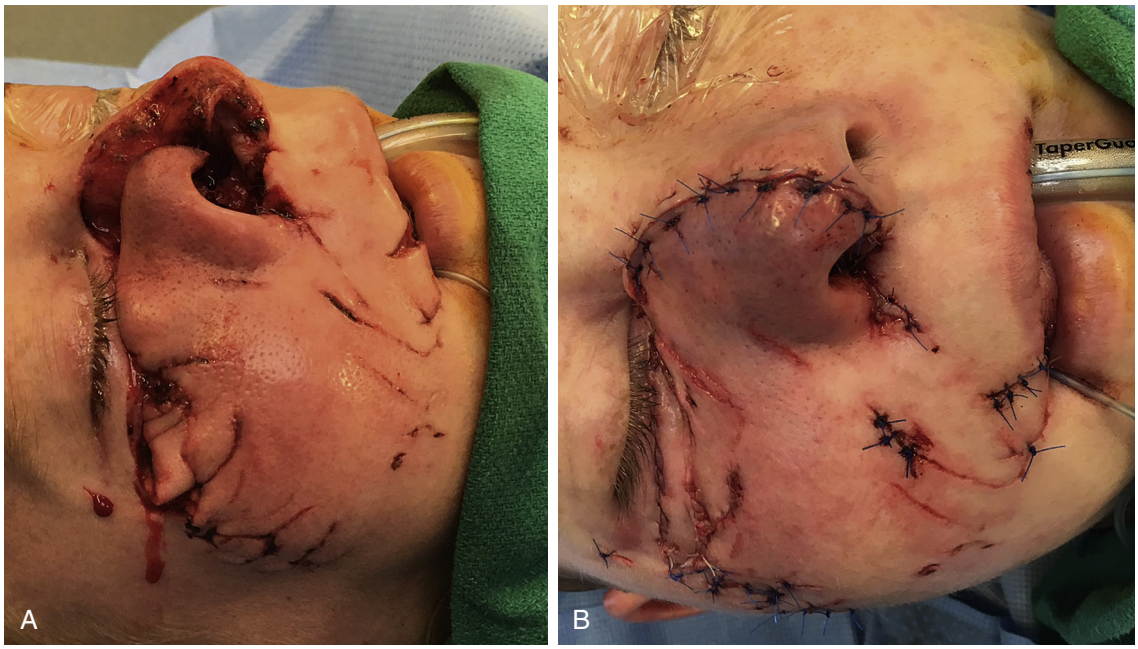

Fig. 75.1. A, Multiple lacerations from a dog bite. **B,** Nasal injury repaired in layers and mattress sutures used to provide adequate eversion.

Some degree of undermining and local flap advancement can help to reduce tension, but careful placement of the sutures is probably most important. It is critical to close the deeper fascia (platysma, superficial musculoaponeurotic system, galea) whenever possible to provide strength and take tension off of the superficial tissues. If it is not possible or that layer is intact, deep dermal sutures should be used instead. We typically use 3-0 and 4-0 braided synthetic absorbable suture (Vicryl, Ethicon, Inc., Somerville, New Jersey). In the galea, 2-0 suture may be more appropriate, and 5-0 may be better in the thinner nasal and periorbital tissue.

Eversion: In the deep layers, precise suture placement set back from the leading wound edge will result in eversion when the tie is made. It also thereby removes all tension from more superficial layers. If eversion from the deeper closure is inadequate, vertical or horizontal mattress sutures should be employed (Fig. 75.1). These techniques provide reliable eversion and remove tension from the healing edge.

Skin closure: A variety of techniques and materials are available, and the specific choice of material will depend on a variety of factors including preference. Fine nylon or fast-absorbing gut suture is frequently used on the face. While some might advocate for a permanent nylon suture, removal within 5 days is required, or the result is certainly worse than with a rapidly dissolving gut suture. Alternatives include tissue adhesives such as Dermabond (Ethicon, Inc., Somerville, New Jersey) or taping. Staples are a good option for the scalp and are easier to remove.

Alignment and soft tissue handling: Meticulous technique will improve the ultimate aesthetic outcome. Accurate placement of the sutures is critical to realign skin edges. The tissue depth of the course of the needle and suture should be symmetric on each side of the wound edge. Further tissue trauma can be minimized with the use of skin hooks and fine-toothed forceps. The skin should be manipulated by grasping the deeper tissues instead of the epidermis wherever possible. Closure may proceed in a running or interrupted fashion. A corner stitch or Gillies stitch may be helpful with acute angles and trifurcations. A combination of the above techniques is routinely used for complex lacerations (Fig. 75.2).

Lip and Intraoral Wounds

A large percentage of intraoral wounds will not require closure and can be left open to heal by second invention. Larger and deeper injuries, however, should be addressed. These include lacerations through the full thickness of the lip or vestibule from skin to mucosa, as well as tongue and oropharyngeal lacerations, which extend through the underlying musculature.

Tongue and soft palate musculature should be re-approximated. Mucosal or musculo-mucosal sutures can then be used to loosely re-approximate the superficial wound, but wide spacing should be maintained and watertight closure should be avoided.

Full-thickness lip and vestibule injuries should be repaired following the same principles as above. The deeper muscle (orbicularis, buccinator) is closed, followed by plastic repair of the skin. The key maneuver is the deep suture, which reestablishes continuity of the orbicularis muscle. The skin and vermillion border should be roughly realigned with some eversion or redundancy. It is worthwhile to cut and revise this suture if the initial attempt is imperfect. Excessive local anesthetic infiltration should be avoided, as it will distort tissue and hamper precise realignment. The white roll and vermillion border must be precisely realigned when closing the skin and vermillion. The mucosal closure should be relatively loose.

Nose and Auricle

The principles of layered closure and precise realignment apply. In this case the cartilaginous framework provides the deep strength layer.

In the nose, a mucosal closure should be achieved whenever possible. If any pedicle is maintained, an avulsed auricular or nasal segment generally should be reattached. The nonviable portions can be débrided in a delayed fashion if required at all. In the event of complete amputation, delayed reconstruction or use of a prosthetic is often the best option. Microvascular replantation has been described for facial segments. Ear cartilage can also be de-epithelialized

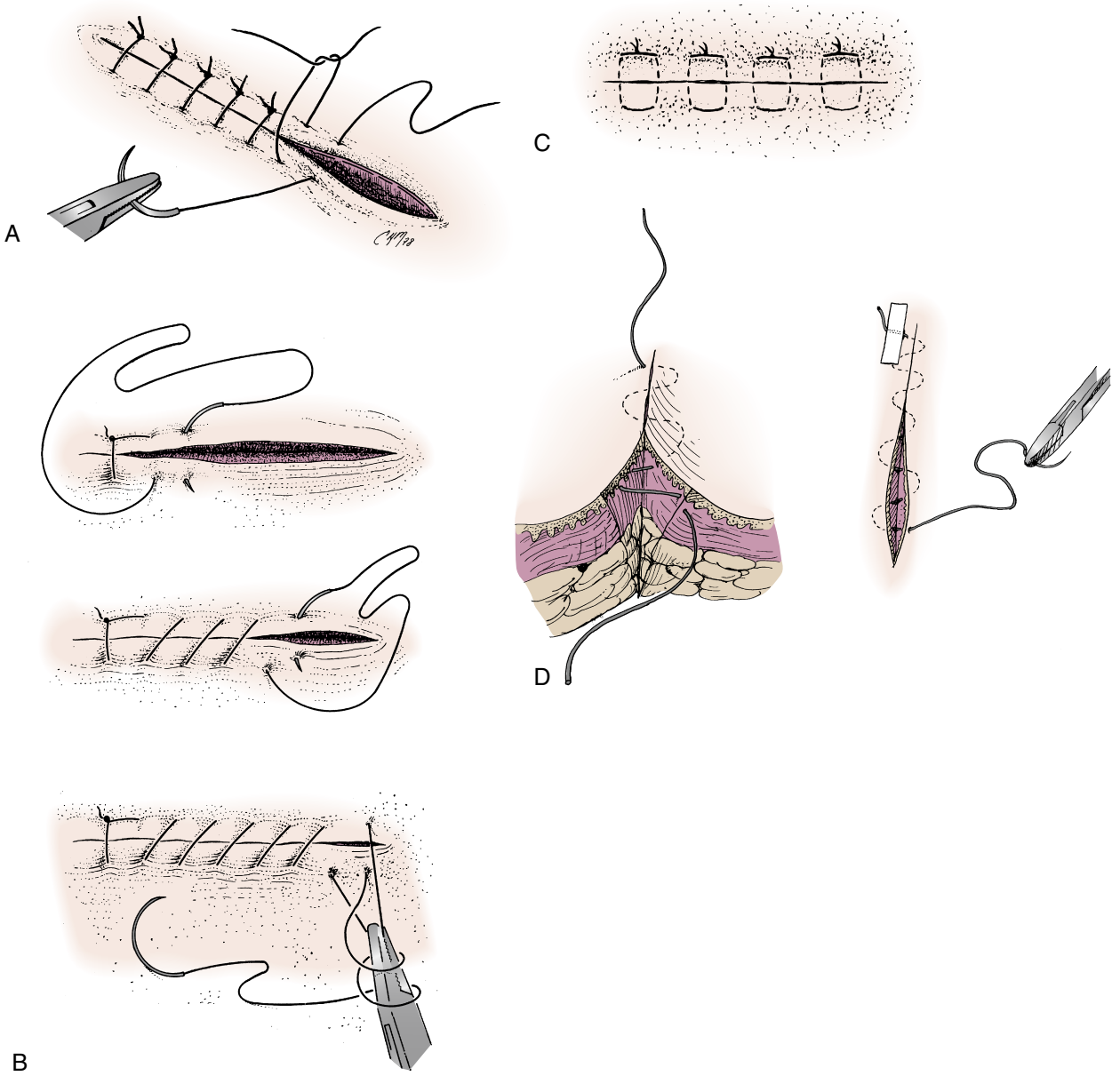

Fig. 75.2. A, Simple interrupted sutures should be placed evenly and far enough away from the laceration edge that eversion of the skin edge is achieved. **B,** A simple continuous suture may be used for lacerations that are easily approximated. **C,** Horizontal mattress sutures are rarely used on skin but may be used for wounds that require extra strength, such as avulsions or gunshot wounds, and are expected to require revision. The surgeon must remember to avoid tying the sutures too tight or the blood supply to the margins of the laceration will be constricted. **D,** Running subcuticular sutures may be used in wounds that are well approximated and cleanly lacerated. A very aesthetic closure can be achieved if the wound edges are everted appropriately. *(Redrawn from Laskin DM (ed). Oral and Maxillofacial Surgery, vol 1. St Louis: CV Mosby; 1980, pp 277-280.)*

and used as a free graft. Primary reconstruction with that cartilage, a temporoparietal fascia flap, and skin grafting could be considered. In delayed reconstruction the cartilage is buried under the dermis for preservation. Cosmetic results from cartilage grafting, however, are frequently inferior to prosthetics or reconstruction using a porous polyethylene implant.

Due to the multiple sensory nerve contributions, peripheral blockade can be challenging, and additional local infiltration is often required.

Auricular hematoma: These are typically the result of blunt trauma and should be drained acutely to prevent cauliflower ear deformity. Incision and drainage is superior to aspiration to ensure that the consolidated clot is evacuated. A bolster and or bolstering sutures should be used to prevent re-accumulation. We prefer to mold petroleum gauze into the scaphoid fossa and secure it with a mattress suture through the full thickness of the auricle.

Scalp

Large scalp wounds that result in a large scalp flap can be quite impressive on examination and can result in significant bleeding, but repair is generally straightforward. A large sub-galeal space may be opened and should be carefully cleansed (Fig. 75.3A).



Fig. 75.3. A, Complex injuries of the face, scalp, and periorbital from motor vehicle crash. **B,** Scalp flap replaced and closed over a suction drain.

Advancement to cover any avulsed area can be challenging. The scalp is very inelastic, and any rearrangement requires wide undermining. Parallel incisions in the galea made perpendicular to the line of advancement can improve the stretch of a scalp flap. Care must be taken to avoid any vessels in the skin flap just superficial to the fascia.

Undermining should not extend beyond the temporal line anteriorly in order to avoid the frontal branch of the facial nerve.

Suction drains may be considered for large potential spaces and contaminated wounds. Infection and hematoma risk is low, but the morbidity of a drain is also quite low (see Fig. 75.3B).

Periorbital Injuries

While most eyelid lacerations may be approached with confidence by the facial surgeon, a comprehensive discussion of oculoplastic techniques is beyond the scope of this chapter. Here we provide a basic overview of the approach to periorbital trauma.

Similar to other facial units, periorbital tissues must be repaired with meticulous attention to the approximation of the native anatomy in layers. In the eyelid this includes the tarsal plate, orbicularis muscle, lid margin, and eyelash line. The deeper layers may be closed with 6-0 Vicryl and the skin with 6-0 nylon or fast-absorbing gut. The conjunctiva can frequently be left open or closed partially with a few 6-0 fast-absorbing gut sutures with a buried knot. The canthi must be resuspended, if disrupted. Suture tails at the margins should be left long and then held down by adjacent knots to avoid corneal abrasion (see Fig. 75.3B).

Special attention must be given to inspection of the lacrimal apparatus. If a laceration extends near or through the puncta, then the canaliculi should be examined with probing and potentially stented for a prolonged period.

In the event of significant loss of tissue, the lid can be reconstructed with primary closure or with small advancement flaps for defects up to 50% of the upper or lower lid (e.g., Tenzel flap). Larger defects will require more extensive reconstruction.

For the above more complex injuries, oculoplastic expertise should be sought when possible.

Salivary Duct Injury

Significant injury to Stensen duct and Wharton's duct fortunately is uncommon. Failure to identify and manage such an injury may result in obstruction, sialocele, sialadenitis, or salivary fistula.

Exploration using lacrimal probes or sialendoscopy along with massage of the gland may help to identify a ductal injury.

Ducts may be repaired with diversion and sialodochoplasty or reanastomosis over a stent. A large angiocatheter may be used in this capacity and sutured in place for a matter of weeks. Alternatively, the proximal duct may be ligated. In this case, botulinum toxin injection of the gland may help to decrease obstructive symptoms.

Facial Nerve Injury

Injury to the facial nerve should be suspected based on the type and location of trauma and confirmed by physical examination. Detection of a nerve injury may be difficult in patients with decreased mental status who cannot attempt voluntary movements on examination. While older patients may demonstrate a loss of facial tone immediately following a nerve injury, younger patients may demonstrate near normal tone in the acute setting despite a totally severed nerve.

Wounds should be explored within three days of injury while the severed distal nerve branches can still be stimulated. Even if the repair is not done at that point, the distal segments can be confirmed with stimulation and then marked with clips or suture for future reconstruction.

Depending on the location of the injury, wounds can be explored locally (Fig. 75.4A and B) or with a parotidectomy approach. Injuries medial to the lateral canthus typically do not warrant exploration and repair. Due to distal branching

and decussating fibers, innervation tends to be redundant, especially in the midface. The small size of the distal branches also makes neurorrhaphy challenging.

Nerve repair can be done primarily (see Fig. 75.4C) or with interposition nerve grafts, most commonly using the great auricular or sural nerve. An additional option is the use of conduit grafts in which the nerve segments are held in opposition by suturing to and within a conduit, such as a small sleeve from a vein graft or a commercially available conduit graft. The use of loupe or microscope magnification is beneficial.

Parotidectomy, soft tissue dissection, and use of grafts will facilitate a tension-free repair, which is the key to success.

Neck Exploration for Penetrating Trauma

Incision: endarterectomy-type incision along the anterior sternocleidomastoid or a transverse incision as in neck dissection

- The transverse incision requires additional elevation of subplatysmal flaps but offers excellent exposure to structures in the neck beyond the carotid sheath.

Carotid sheath exposure: Dissection continues deep to the sternocleidomastoid muscle.

- The internal jugular vein is identified first. The omohyoid may be divided or retracted to improve exposure. The internal jugular vein should be mobilized with blunt



Fig. 75.4. A, Deep preauricular laceration with upper paralysis of the face. **B,** Wound explored demonstrating transection of the main trunk of the facial nerve. **C,** End-to-end repair of the nerve conducted under binocular microscopy. Cut ends are held in tension-free opposition with 9-0 nylon suture through the epineurium. Fibrin glue can also be used in addition to or instead of suture.

dissection, and circumferential control should be obtained above and below any site of injury.
- The internal jugular vein is a low-pressure but high-volume vessel, and massive hemorrhage can occur with injury, including iatrogenic injury during exploration. The clot should be left in place until distal and proximal control is achieved. Active hemorrhage can be arrested with relatively light pressure while control is established. Vessel loops or a variety of vascular clamps can be used.
- A laceration of the veins can be repaired primarily, or larger defects can be patched with vein graft. The vessel may also be ligated with relatively low morbidity.
- The carotid artery may be approached anteriorly or posteriorly to the jugular vein. The anterior approach requires division of the common facial vein and any other anterior branches but affords better exposure to the external carotid system and the hypoglossal nerve.

The course of the common and internal carotid arteries is then dissected.
- Vagus and hypoglossal nerves are identified and preserved
- The posterior belly of the digastric muscle can be divided to improve superior exposure.
- The mandible should be subluxed and retracted anteriorly.
- The descending ansa cerivcalis can be divided and even used to help retract the hypoglossal nerve superiorly.
- The external carotid artery will course medially and anteriorly to the internal. It can be ligated and divided when necessary, but multiple branches should be seen prior to ligation to ensure appropriate identification. The external system can also be used to bypass a damaged internal carotid segment, so it should only be divided if necessary.

Management of carotid artery trauma[4]
- Ligation for impending exsanguination or if neurologic injury has already occurred
- Ligation or occlusion of inaccessible injury, use of balloon catheter to occlude the distal segment at the skull base
- Revascularization preferable
- Distal and proximal control with vessel loops: distal clamp first to avoid embolus
- Cerebral perfusion assessment and shunting when possible
- Suture or patch repair
- Resection with end-to-end anastomosis
- Interposition graft with reversed saphenous or superficial femoral vein
- External carotid transposition

The techniques required to revascularize a damaged carotid artery are beyond the scope of practice for most head and neck surgeons. Emergent consultation and assistance from a vascular surgeon or neurosurgeon are always indicated.

Common Errors in Technique

1. Inadequate débridement and undermining
2. Lack of wound edge eversion
3. High tension closure or anastomosis
4. Tight closure of intraoral wounds or penetrating trauma
5. Inadequate exposure and vessel control

POSTOPERATIVE PERIOD

Postoperative Management

1. Neurologic monitoring and intensive care management for suspected vascular injuries
2. Continued trauma resuscitation
3. Wound cleansing with dilute peroxide or soap and water at 48 hours
4. Petroleum-based ointment (avoid neomycin-containing preparations)
5. Sun protection
6. Remove sutures from facial wounds within 5 days.
7. Massage scar after initial healing.

Complications

1. Infection
   Exploration and drainage
2. Seroma, hematoma
   Aspiration versus drainage, pressure dressing
3. Corneal abrasion
   Ophthalmologic consultation, ophthalmic ointment
4. Skin flap ischemia and necrosis
   Delayed débridement when necessary
5. Sialocele, salivary fistula, or duct obstruction
   Aspiration, pressure dressing, anticholinergics, Botox
6. Unfavorable scar: hypertrophic or prominent
   Steroid injection, dermabrasion, other resurfacing techniques, and scar revision
7. Cranial nerve injuries (VII, IX, X, XI, XII)
8. Hemorrhage
9. Stroke
10. Death

Alternative Management Plan

1. Wound care with delayed closure and/or reconstruction
2. Angiography with endovascular management of carotid and vertebral injuries

DISCUSSION

Evidence-Based Medicine Question

What is the benefit of immediate surgical exploration of penetrating zone 2 injuries in stable patients?

Traditionally, the approach to penetrating trauma to the neck was based on anatomic zones of injury (Table 75.1). The proposed algorithms developed in the 1970s recommended immediate surgical exploration for the more accessible zone 2 injuries. The less accessible zone 1 and 3 injuries were assessed with angiography and endoscopy. The most apparent shortcoming of this system is the unreliability of external wounds to predict internal injuries. An additional problem was the very high rate of negative findings on immediate exploration, resulting in significant morbidity.

In a 2013 review, Shiroff and colleagues proposed a "no zone" approach based on available evidence, whereby patients with hard signs are managed with immediate surgery, and stable patients without concerning findings on physical examination are evaluated with CTA initially.[1] Findings on imaging then direct subsequent management with surgery, diagnostic or therapeutic angiography, and observation (Fig. 75.5). Physical examination alone has been shown to be sensitive for identifying vascular injuries, which require repair. Observation following initial examination requires intensive monitoring and serial examinations. It - break up sentence for clarification may miss tracheal and pharyngoesophageal injuries.

TABLE 75.1 Zones of the Neck

Zone 1	Clavicle/sternal notch to cricoid cartilage
Zone 2	Cricoid cartilage to angle of mandible
Zone 3	Angle of mandible to skull base

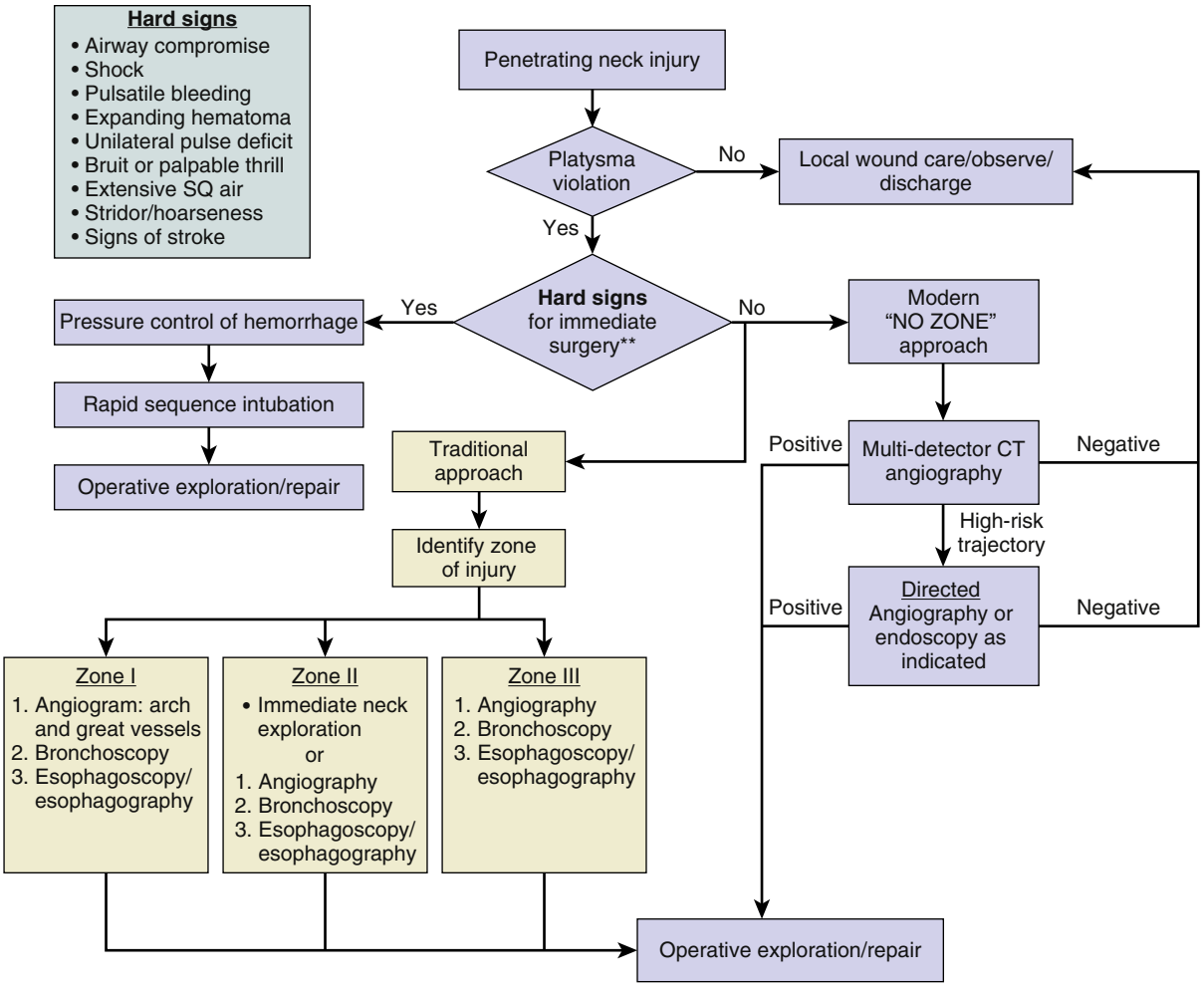

Fig. 75.5. Algorithm for the modern management of penetrating neck. *(From Shiroff AM, Gale SC, Martin, ND, et al. Penetrating neck trauma: a review of management strategies and discussion of the 'No Zone' approach. Am Surg 79(1):23-29. 2013.)*

CTA provides additional triage capability and has been found to be highly sensitive for the detection of vascular injury. Given advances in imaging technology in the modern era and the available evidence, a transition to the above approach from the older and more invasive zone-based approaches should be considered in the evaluation and management of penetrating neck trauma.

Editorial Comment

Traumatic injuries to the soft tissues and vascular structures in the neck need a protocol-based intervention to maintain effective and efficient interventions in what tend to be high-stress situations. Involvement of additional expertise such as vascular surgery, intensive care team, or reconstructive surgery at appropriate times is key to successful outcomes in terms of function, cosmesis, and long-term sequelae.

Rohan R. Walvekar

Access the review questions and additional sources list online at http://www.expertconsult.com

REFERENCES

1. Shiroff AM, Gale SC, Martin ND, et al. Penetrating neck trauma: a review of management strategies and discussion of the 'No Zone' approach. Am Surg 2013;79(1):23–29.
2. Bratzler DW, Dellinger EP, Olsen KM, et al. Clinical practice guidelines for antimicrobial prophylaxis in surgery. Am J Health Syst Pharm 2013;70(3):195–283.
3. Stevens DL, Bisno AL, Chambers HF, et al. Practice guidelines for the diagnosis and management of skin and soft tissue infections. Clin Infect Dis 2014;59(2):147–159.
4. Wahlberg E, Olofsson P, Goldstone J. Vascular injuries to the neck. In: Wahlberg E, Olofsson P, Goldstone J, editors. Emergency Vascular Surgery: A Practical Guide. Berlin, Heidelberg: Springer; 2007. pp. 3–14.

REVIEW QUESTIONS

1. Which of the following is NOT recommended as monotherapy for prophylaxis after bite wound?
   a. Moxifloxacin
   b. Amoxicillin-clavulanate
   c. Doxycycline
   d. Clindamycin

2. Benefits of computed tomography angiography (CTA) in the assessment of penetrating trauma compared to angiography include all of the following, except
   a. Rapid availability and widespread accessibility
   b. Lower rates of negative exploration following positive findings
   c. Less effect of movement or metallic foreign body artifacts
   d. Lower morbidity/less invasive

3. Suspected facial nerve transection should be explored within
   a. 24 hours
   b. 3 days
   c. 7 days
   d. 2 weeks

ADDITIONAL SOURCES

Dutton J. Atlas of Oculoplastic Surgery. Philadelphia: Lippincott Williams and Wilkins; 2013.
Zide BM, Swift R. How to block and tackle the face. Plast Reconstr Surg 1998;101(3):840–851.

76 Deep Neck Abscesses

Lisa Galati

INTRODUCTION

The potential for a seemingly benign entity like an infected tooth, tonsil, or skin lesion to cause life-threatening illness is due to the complex relationship between the spaces of the neck. Deep neck infection (DNI) may result from any of the above and can extend into the mediastinum and beyond when these spaces are involved. Aggressive bacterial species, inadequate host defenses, and access to medical care all contribute to the development of deep neck infections and make management difficult. Understanding the relationship of the potential spaces of the neck to each other, as well as the most common pathogens, is key to successful treatment of this problem.

KEY OPERATIVE LEARNING POINTS

- Knowledge of the anatomy and relationships between the deep neck spaces is necessary to adequately drain the neck during incision and drainage (I&D).
- Failure to drain pockets of infection will prolong recovery or lead to complications.
- Deep neck abscesses are often fulminating and can lead to rapid changes in status by causing airway obstruction, vascular compromise, or sepsis and need to be treated in an urgent manner.
- Tracheostomy is often required for safe airway management.

PREOPERATIVE PERIOD

Patients with DNI typically have localized pain and swelling, fever, and an elevated white blood cell counts. All patients undergo a computed tomography (CT) scan to assess the extent of disease, unless airway compromise dictates otherwise. If an aspirate is available for Gram stain analysis, this is helpful in identifying pathogens before empiric antibiotics are administered. Otherwise, intravenous antibiotics should be administered and chosen on the presumed site of origin. Oropharyngeal abscess requires coverage of beta-lactamase producing streptococcal and staphylococcal organisms; oral infections require coverage of anaerobic bacteria. Use of antibiotics with coverage of anaerobes and beta-lactamase–producing microbes provides good broad-spectrum coverage for most cases.

History

1. History of present illness
   a. Duration of symptoms
   b. Odynophagia or dysphagia
   c. Dental history—periodontal disease, fractured teeth, periapical abscess, carious teeth
   d. Preceding upper respiratory tract infection or trauma
2. Past medical history
   a. Diabetes mellitus
   b. Other forms of immunocompromised states—HIV, iatrogenic (chemotherapy)
3. Medications
   a. Antibiotics
   b. Anticoagulants

Physical Examination

1. Airway
   a. Flexible fiberoptic laryngoscopy to assess for patency
   b. Presence of swelling of the posterior pharyngeal wall
2. Neck
   a. Extent and location of edema
   b. Presence of fluctuance, tenderness, erythema
3. Oral cavity
   a. Gingival swelling and erythema, purulent discharge near carious teeth
   b. Edema of the floor of the mouth with retrodisplacement of the tongue
4. Oropharynx
   a. Bulging of the soft palate/tonsil
   b. Trismus

Imaging

CT
1. Preferred for rapid procurement of images (over MRI)
2. Contraindicated if the airway is unstable
3. Recommend use of contrast
4. Standard 3-mm cuts

Indications

- Abscess with airway compromise
- Sepsis
- Smaller abscess with lack of response to IV antibiotics
- Lack of resolution that will require revision surgery

Contraindications

- Hemodynamic instability

Preoperative preparation

1. Evaluate imaging to determine the extent of the abscess
2. Culture–If the patient is stable, obtain an aspirate at the bedside to initiate Gram stain and culture studies.
3. Antibiotics–Empiric administration of intravenous antibiotics that provide aerobic and anaerobic coverage
4. Manage any airway compromise

OPERATIVE PERIOD

Anesthesia

- Management of impending airway collapse in the patient with a deep neck abscess takes precedence over all other considerations.
- Tracheotomy is achieved with the patient awake with the anesthesiologist prepared to administer general anesthesia once the airway is secured.
- Sedation is contraindicated as it may lead to further collapse of the airway.

Positioning

- The patient is placed in the supine position with a shoulder roll used to gently extend the neck.

Perioperative Antibiotic Prophylaxis

- Antibiotics that provide coverage of aerobes and anaerobes are administered intravenously perioperatively.

Monitoring

- Paralytic agents should not be used in order to avoid injury to the cranial nerves.

Instruments and Equipment to Have Available

- Head and neck instrument set

Key Anatomic Landmarks

Management of deep neck space infections mandates a thorough understanding of the anatomy of deep neck spaces, etiology of the abscess, and knowledge of the pathogens involved.

Anatomy

Anatomic structures and fascial layers delineate the spaces of the neck. Fascial layers envelope muscles, bone, and viscera in the neck and are coalescent in some areas, dehiscent in others. Where multiple layers come together, it is very unlikely that infection will spread beyond as in the inferior limit of the retropharyngeal space. In regions where the fascia is thin, deep neck abscesses are able to spread to neighboring spaces if left untreated.

There are two layers of cervical fascia: superficial and deep. The superficial layer lies superficial to the platysma and extends from the upper chest to the zygoma. DNI only involves the spaces formed by the three layers of deep cervical fascia—superficial, middle, and deep—which create a potential "highway" from the neck, allowing infection to spread as far as the sacral spine.

The superficial layer of deep cervical fascia encircles the neck like a drum. It lies on the submandibular gland (and the marginal mandibular division of the facial nerve runs within it) and sternocleidomastoid (SCM), omohyoid, and trapezius muscles. The superior or "investing" fascia attaches inferiorly to the sternum, clavicle, and first rib, superiorly to the mandible, mastoid, and occipital bone. The lateral portion of the carotid sheath and the stylomandibular ligament are formed by this layer. The submandibular and sublingual spaces lie deep to this fascial layer, which is bordered by the digastric muscle inferiorly, mandible laterally, hyoglossus muscle medially, and sublingual gland superiorly. The masticator space is bounded medially and laterally by the superficial layer as it splits above the jaw and extends up to the skull base and zygomatic arch.

Infections of the sublingual space are most often odontogenic, with the first molar being the usual source. The patient presents with edema of the floor of the mouth, dysarthria, pain, and fever. Transoral drainage is helpful, but dental consultation is paramount in avoiding recurrent infection. If the swelling is due to a periapical abscess, the latter must be drained. Infection of the second molar leads to swelling of the submandibular space, as this tooth lies posterior to the insertion of the mylohyoid muscle (Fig. 76.1). An abscess of the submandibular space should be drained via a transcutaneous route. Ludwig's angina is an infection of both spaces that often manifests as significant retro-displacement of the tongue, edema of the floor of the mouth, and impending airway collapse (Fig. 76.2). Management often requires awake tracheostomy because intubation is not feasible due to the edema and the position of the tongue. Incision and drainage is done through an incision in the neck and often yields a thin, watery discharge. Wounds are drained and left open; both surgical drains and the tracheostomy are removed once the edema has subsided and the infection has resolved.

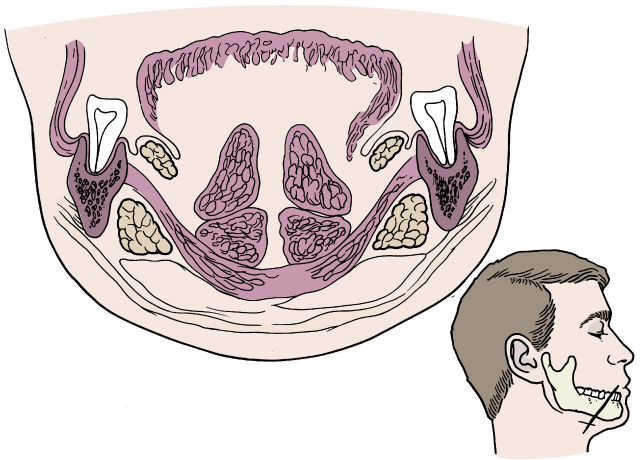

Fig. 76.1. The mylohyoid sling divides the submental space into two relatively independent sites. The plane of this schematic is depicted in the *inset.*

The middle layer of the deep cervical fascia, also known as the visceral layer, contributes to the carotid sheath (which is formed by all three layers). The middle layer envelops the thyroid, esophagus, constrictor muscles, and trachea. The superior portion of the middle layer, the buccopharyngeal fascia, envelops the constrictors and buccinator muscle. As it courses behind the pharynx, it forms the anterior boundary of the retropharyngeal space. A midline raphe attaches to the alar layer component of the deep layer of the deep cervical fascia, which is responsible for the hallmark finding of a unilateral retropharyngeal abscess, which differentiates it from an abscess in either the danger or prevertebral space (Fig. 76.3). However, the converse is not true—a midline abscess does not necessarily exclude a retropharyngeal location. The midline raphe is often breached, resulting in a midline, retropharyngeal abscess. The retropharyngeal space extends to the thoracic spine (T1 to T6), and infection may descend into the mediastinum, a potentially fatal complication.

Retropharyngeal abscesses usually result from sinonasal or nasopharyngeal infection (adenoiditis). Odynophagia, meningismus, and a muffled quality of the voice are common findings. Although a radiograph of the lateral neck is an easy way to assess the retropharynx, all patients require CT imaging prior to definitive treatment. On lateral radiographs of the neck, the retropharyngeal soft tissues near C2 should be about 4 mm in thickness—over 7 mm is considered pathologic. At the level of C6, the retropharyngeal depth is thicker—up to 14 mm for children and 22 mm in adults are considered normal.

The deep layer of the deep cervical fascia consists of alar and prevertebral layers, which define the danger and prevertebral spaces. The posterior boundary of the retropharyngeal space is formed by the alar layer. Posterior to the alar layer lies the "danger zone" of the neck, as infections here can spread as for inferior as the abdomen, where the fascia terminates. The prevertebral space lies deep to the fascia of the same name and extends from skull base to sacrum. Infections in this area are most often caused by infections of the spine (either iatrogenic or, less commonly, tuberculous), but fulminant infections from neighboring spaces can also affect the prevertebral space.



Fig. 76.2. The classic appearance of a patient with Ludwig's angina. Note **A,** upward displacement of the tongue and the erythema, and **B,** edema of the submental skin.

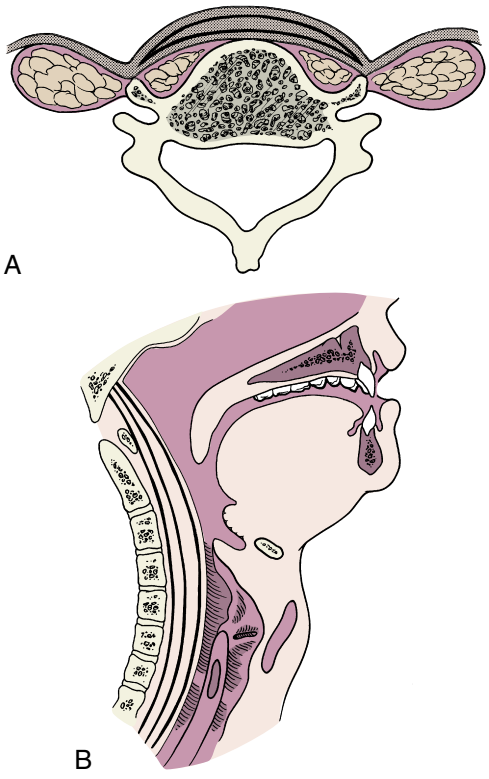

Fig. 76.3. A, Axial schematic of the relationship of the potential space anterior to the vertebral bodies. The alar fascia separates the prevertebral space from the retropharyngeal space. **B,** Sagittal drawing depicting the relationship between the retropharyngeal and prevertebral spaces.

The parapharyngeal space is important because of its central location and proximity to other deep neck spaces. The middle layer of deep cervical fascia forms its medial border as it envelops the superior constrictor. Posteriorly, the prevertebral fascia and two other spaces border it. Laterally, it abuts the masticator space and, inferiorly, the submandibular. The inverted pyramidal space extends from the skull base to the hyoid bone and is most often involved due to tonsillitis, but given its central location, abscesses here can extend into any of these other spaces. Peritonsillar abscess starts out confined by the constrictor muscle and fascia but if untreated can gain access to the parapharyngeal space. Patients present with trismus, drooling, and swelling in the neck. Parapharyngeal space abscesses require external drainage, as transoral I&D is inadequate to drain the inferior extent.

Pathogenesis

- The most common source of DNI is the teeth.
- Infections of the upper aerodigestive tract, illicit intravenous drug use, and surgical complications are responsible for some cases.
- The cause is never identified in approximately 50% of cases.
- Delay in treatment, immunocompromised status, and antibiotic resistance also play a role in the transformation of a common infection into a life-threatening illness.

Pathogens

- Anaerobic bacteria are causative in odontogenic infection.
- In pediatric patients aerobic infection is most common.[1]
- The most common aerobes are *Streptococcus pyogenes* and *Staphylococcus aureus.*
- Anaerobes are more common in adults and non-diabetics.
- *Prevotella*, proprionobacter, and *Peptostreptococcus* are the most common anaerobes in deep neck infection. *Fusobacterium*, *Porphyromonas*, and *Bacteroides* are other common anaerobes involved in DNI stemming from an oral source.
- Polymicrobial culture results (both aerobes and anaerobes) occur in 30% to 40% of cases.

Increasing drug resistance and difficulty in obtaining accurate anaerobic cultures contribute to the prevalence of these potentially life-threatening infections. Anaerobic cultures must be carefully collected, transported, and cultivated

without exposure to air to properly identify flora. Beta-lactamase-producing bacteria (BLPB) render beta-lactam antibiotics ineffective and can shield non-BLPB from these drugs as well.[2] Both aerobes (*S. aureus, Haemophilus influenzae, Moraxella catarrhalis*) and anaerobes (prevotella and porphyromonas) are capable of producing beta-lactamase.

Prerequisite Skills

- Experience with neck dissection and surgery of the parapharyngeal and retropharyngeal spaces
- Experience with tracheostomy

Operative Risks

- Recurrent/persistent deep neck infection
- Cranial nerve injury
- Vascular injury

Surgical Technique: Incision and Drainage

- Perform through an external incision, which is planned, based on the location of the abscess.
- Ludwig's angina is drained through a submental incision.
- Parapharyngeal space abscess is best approached through an incision at the level of the hyoid, which allows access to the posterior belly of the digastric. The muscle is retracted superiorly, and blunt dissection here allows access to the parapharyngeal space and drainage of the abscess (Fig. 76.4).
- Retropharyngeal abscess drainage should be planned at a level appropriate to reach loculations and the abscess cavity. The surgeon must consider that abscesses in this space may extend into the mediastinum, and an incision at one or two fingerbreadths above the clavicle may be very advantageous. This is often helpful in cases in which thyroiditis also exists. Third or fourth branchial cleft cyst abscess is associated with thyroiditis and can extend down into the mediastinum. Management includes thyroid lobectomy and tracing the tract up to its origin in the piriform sinus. Dissection deep and medial to the carotid sheath provides access to the retropharyngeal space.
- Abscesses involving multiple spaces may require several separate "stair-stepped" incisions (horizontal to each other) for drainage of all loculations. Occasionally, bilateral incisions are required for adequate drainage.

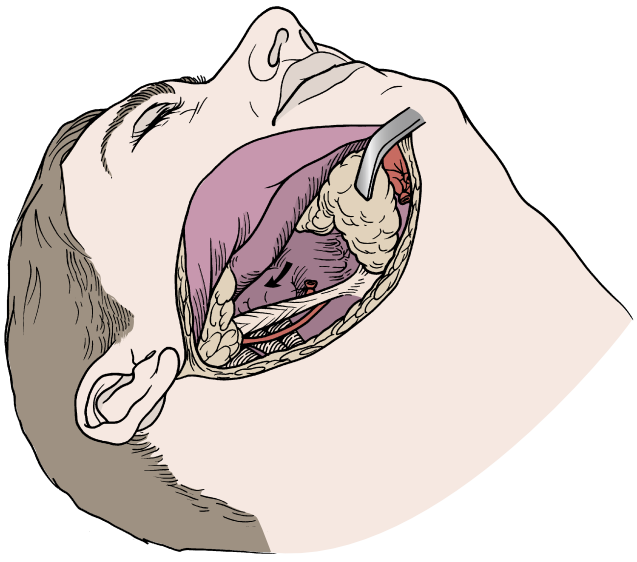

Fig. 76.4. Surgical approach to the parapharyngeal space.

- Once purulent exudate is encountered, specimens are gathered for Gram stain and aerobic, anaerobic, and fungal cultures.
- Using the CT scan as a "map" to identify all loculations is helpful, but gentle palpation within the abscess cavity may also uncover areas of infection.
- After the wound has been thoroughly examined, it should be irrigated with copious amounts of sterile saline until no further turbidity is noted. Large (half-inch) Penrose drains are inserted into each incision and sutured to the skin to prevent dislodgement. An absorbent dressing is applied to help contain discharge and to prevent maceration of the surrounding skin.

Common Errors in Technique

- Failure to adequately drain all abscess loculations
- Injury to cranial nerves

POSTOPERATIVE PERIOD

Postoperative Management

Monitoring.

- Intensive care unit placement for
  a. Ventilatory requirements
  b. Hemodynamic instability due to sepsis
  c. Adequate pain control and sedation

Wound Care.

- Multiple dressing changes each day until the discharge decreases
- Frequent checks on microbiology reports are crucial to determine if antibiotic coverage needs to be altered.
- Penrose drains are maintained until drainage decreases and then are slowly backed out of the wound.
- Wounds are allowed to close by secondary intention.
- Repeat lavage is indicated for wounds that produce copious amounts of purulent discharge.
- In cases of necrotizing fasciitis (NF), revision surgery may be required if the patient's condition does not improve and further necrotic tissue is identified.

Complications and Other Considerations

- Persistent signs of infection—elevated WBC, fever, sepsis, and abnormal CT
- In odontogenic cases the offending tooth/teeth must be extracted.
- Consider reoperation if scans indicate an abscess.
- Infectious diseases consult to adjust antibiotic coverage.
- Minimally invasive trends continue to develop, but abscesses that are multiloculated, occur in the critically ill, threaten airway patency, or have failed conservative management *must* be drained through an external incision.
- Dysphagia may result from dissection of the retro- or parapharyngeal space or edema of the airway. It is particularly important to assess this in geriatric patients due to the high incidence of pre-existing dysphagia in this population. Management of dysphagia requires speech pathology consultation and nutritional support via a nasogastric tube or percutaneous endoscopic gastrostomy tube

Lemierre Syndrome

Lemierre syndrome is a life-threatening complication of deep neck infection. Thrombosis of the internal jugular vein and

bacterial emboli are the hallmarks of this disease (Fig. 76.5). Spiking fevers ("picket fence"), dyspnea, and an oropharyngeal or dental source are common. The most common pathogen is fusobacterium, a gram-negative anaerobe (*Fusobacterium necrophorum* is most common), but bacteroides, prevotella, and peptostreptococcus may also be identified. Hemagglutinin produced by these microbes leads to platelet aggregation and thrombus formation. Prior to the antibiotic era, such cases would most likely end in death, and the only treatment available was ligation of the vein. Currently, ligation of the vein is not routinely indicated. Anticoagulation is frequently used in this disease although consistent evidence for this strategy is lacking (see Fig. 76.5A and B).

Necrotizing Fasciitis (NF)

Perhaps the most dreaded of all neck infections, NF is a fulminant infection involving the superficial fascial layers. In the head and neck, odontogenic sources are also most common, but simple skin disruption from minor trauma (insect bites have been reported as the seminal event in some cases) may be enough to introduce the virulent streptococcus and bacteroides most often implicated in this disease.[3] Infection leads to liquefaction of subcutaneous tissues, venous thrombosis,[4] and endarteritis obliterans. Risks include lack of immunocompetency (diabetes being most common), alcoholism, obesity, advanced age, or peripheral vascular disease. Presenting signs may mimic deep neck abscess, but presence of subcutaneous air, skin anesthesia, and duskiness should raise concerns for NF.

Surgical management includes drainage of the thin, gray, foul-smelling fluid that is typical in NF and débridement of necrotic tissue. This often involves removal of significant amounts of soft tissue, as exposure of healthy bleeding tissue is the goal of an adequate operation. Wounds are never closed at the time of débridement. Reconstruction is performed after signs of infection have resolved. The use of hyperbaric oxygen has been shown to improve healing in some studies but is not a standard recommendation.[4] Mortality rates of 23% have been reported and increase to more than 40% if the process extends into the mediastinum.

Longus Colli Tendinitis

This unusual condition is seen at our institution several times each year. Described in 1964 by Hartley, retropharyngeal calcific tendinitis is an acute inflammation of calcium crystal deposits in the longus colli tendon as it inserts into the muscle. Therefore, these calcifications are always seen at the level of C1, occasionally C2, and the surrounding edema can mimic a phlegmon, leading to erroneous consultation for retropharyngeal abscess or, worse, unnecessary surgery.

Calcific tendinitis is characterized by severe neck pain and stiffness as well as odynophagia. Physical findings include erythema and edema of the posterior nasopharyngeal wall. Fever and elevated WBC are not part of the presentation, but elevated sedimentation rate and C-reactive protein may be. CT is the recommended imaging, revealing calcifications and retropharyngeal edema that may extend to the lower cervical vertebral level. The calcifications are pathognomonic, but it is important to remember that lack of reactive lymphadenopathy also differentiates this from an infectious process. Nonsteroidal anti-inflammatory drugs are the treatment of choice,[5] although steroids may also be used, and complete resolution is expected in 1 to 2 weeks (Fig. 76.6A and B).

Vascular Rupture

Hemodynamic instability is most often due to sepsis, but in some cases of deep neck infection, it may be a sign of vascular rupture. Patients with neck ecchymosis, rapid swelling, and hypotension may have suffered a catastrophic injury to the carotid due to exotoxins produce by virulent bacteria. If during the I&D of the abscess, the surgeon encounters a blood clot in proximity to the artery, intraoperative vascular consultation should be obtained immediately.

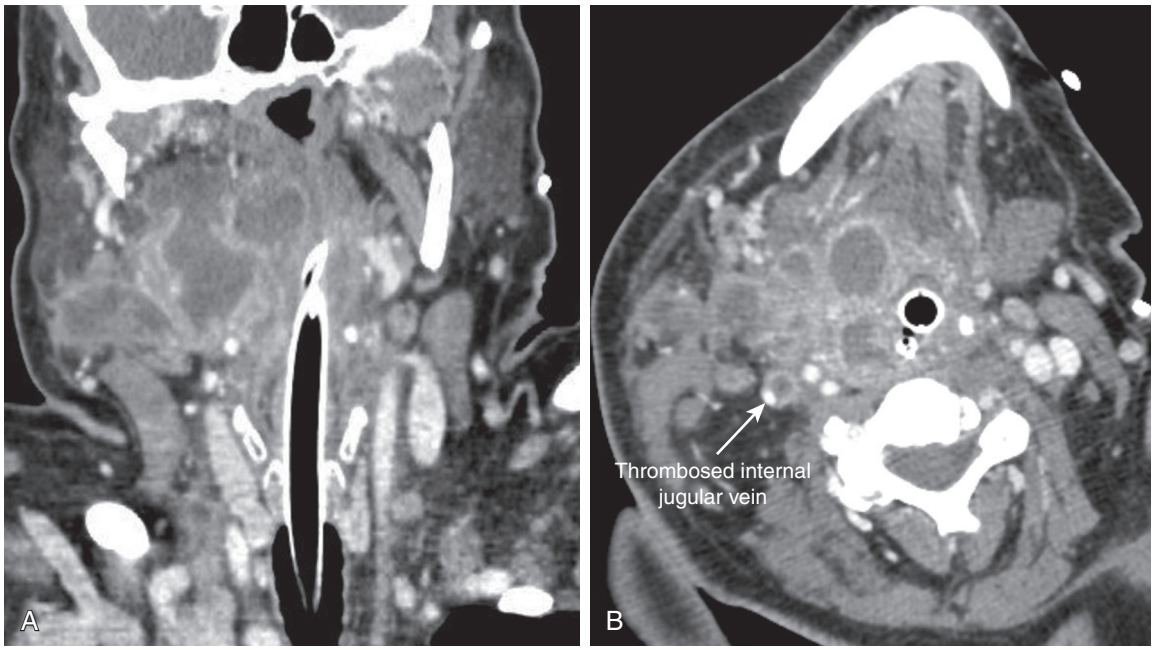

Fig. 76.5. A, Computed tomography (CT) scan from a 62-year-old diabetic woman who presented with thrombosis of the internal jugular vein (IJV) that resulted from an untreated peritonsillar abscess. She was also noted to have multiple fractured carious teeth. **B,** CT scan demonstrating large multiloculated right parapharyngeal space abscess. Image on right shows classic "O" sign of IJV thrombosis *(arrow).* Cultures grew strep anginosus. The patient was successfully treated with intravenous antibiotic therapy and incision and drainage and did not require tracheostomy.

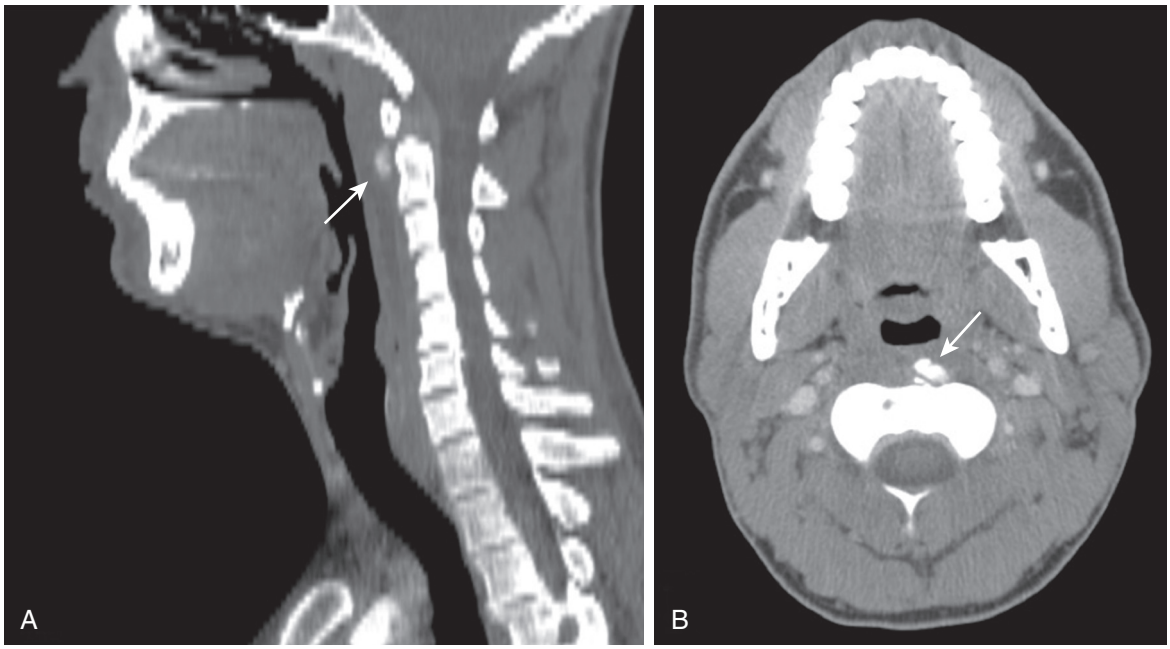

Fig. 76.6. A, A reconstructed lateral neck CT scout film of a patient with longus colli tendinitis. The retropharyngeal soft tissue is thickened at C1 to C2 and measures 8 mm (*arrow*). **B,** The hallmark calcifications near C1 (*arrow*). Note the hypodensity as well; this inflammatory change is sometimes misinterpreted as a phlegmon or abscess.

Alternative Management Plan

A recent report[6] of ultrasound-guided aspiration has shown good results in selected cases of deep neck abscess. Patients with well-defined, unilocular abscesses are candidates for this approach. No recurrences were noted, and hospital stays were shorter. It is unclear if this technique is an option for immunocompromised patients (diabetics).

Transoral drainage of retropharyngeal abscess is indicated for pediatric patients or small abscesses limited to this space. It should not be used for infections that extend out laterally to the parapharyngeal space or if revision surgery is necessary for persistent infection.

DISCUSSION

Evidence-Based Medicine Question

How are outcomes affected by conservative management and delay of surgery in deep neck abscesses?

Conservative management of deep neck abscess with intravenous antibiotics, with or without needle aspiration, is used more often in the pediatric population. In a recent study by Cramer et al.,[7] adult patients had significantly higher risk of morbidity and mortality if surgery was delayed (11.5% day 0, 17.3% day 1 to 2; $P = .02$). The risk increased 2.4-fold if surgery occurred after day 2. The authors found that delay of surgery did not affect the risk of morbidity and mortality in pediatric patients. Despite this, there appears to be a subset of pediatric patients who require immediate surgical intervention. Lawrence and Batemen[8] describe the controversies involved in treating deep neck abscess in the pediatric age group and concluded that airway compromise, complications (Lemierre syndrome, cranial nerve palsy, septicemia), abscess >2.2 cm, age <4, and ICU admission are reasonable criteria for surgery.

Editorial Comment

Clinical evaluation, appropriate imaging, and active aggressive management are vital to successful outcomes for DNI. Usually the origins of the DNI are evident from clinical and radiologic examination. However, efforts must be made to identify the source of infection, and this must be treated synchronously or in an elective fashion. Although the majority of deep neck abscesses are due to infectious sources such dental or oropharyngeal infections, the possibility of a malignant fistula must be considered, especially in patients who have a prior history of head and neck cancer.

Rohan R. Walvekar

Access the review questions and additional source list online at http://www.expertconsult.com

REFERENCES

1. Celakovsky P, Kalfert D, Smatanova K, et al. Bacteriology of deep neck infections: analysis of 634 patients. Aust Dent J 2015; 60(2):212–215.
2. Brook I. Anaerobic bacteria in upper respiratory tract and head and neck infections: microbiology and treatment. Anaerobe 2012;18:214–220.
3. Levya P, Herrero M, Eslava J, et al. Cervical necrotizing fasciitis and diabetic ketoacidosis: literature review and case report. Int J Oral Maxfac Surg 2013;42:1592–1595.
4. Flanagn C, Daramola O, Maisel R. Surgical debridement and adjunctive hyperbaric oxygen in cervical necrotizing fasciitis. Otolaryngol Head Neck Surg 2009;140:730–734.
5. Gabra N, Belair M, Ayad T. Retropharyngeal calcific tendinitis mimicking a retropharyngeal phlegmon. Case Rep Otolaryngol 2013;912628:1–4. 2013.
6. Biron V, Kurien G, Dziegielewski P, et al. Surgical vs ultrasound-guided drainage of deep neck space abscesses: a randomized controlled trial: surgical vs ultrasound drainage. J Otolaryngol Head Neck Surg 2013;42:18–23.
7. Cramer J, Purkey M, Smith S, et al. The impact of delayed surgical drainage of deep neck abscesses in adult and pediatric populations. Laryngoscope 2016;126:1753–1760.
8. Lawrence R, Batemen N. Controversies in the management of deep neck space infection in children: an evidence-based review. Clin Otolaryngol 2017;42(1):156–163. http://dx.doi.org/10.1111/coa.12692. Jun11.

REVIEW QUESTIONS

1. Which of the following is true?
   a. Most deep neck abscesses that occur in adults are caused by mixed aerobes and anaerobes.
   b. Upper respiratory tract infection is the most common cause of DNI.
   c. Pediatric DNIs are most often anaerobic.
   d. Streptococcal species are responsible for most abscesses of dental origin.

2. The boundaries of the masticator space include all of the following, except
   a. The mandible
   b. Buccinator, masseter, and orbicularis muscles
   c. Deep layer of the deep cervical fascia
   d. Zygomatic arch

3. A patient presents to the ER with 2 days of increasing pain in the neck and stiffness. Which of the following is indicative of an abscess?
   a. Elevated sedimentation rate
   b. Elevated WBC and erythematous swelling of the submandibular triangle
   c. CT showing phlegmon of retropharyngeal space and calcifications near C1
   d. History of URI

ADDITIONAL SOURCE

Johnson JT, Yu VL. Infectious Diseases of the Ears, Nose and Throat. Philadelphia, W.B.: Saunders Company; 1997.

77 Anterior Transcervical Approach to the Cervical Spine

Carl H. Snyderman

INTRODUCTION

The otolaryngologist is often involved in surgery to provide access to the cervical spine. This is usually for the treatment of cervical spondylosis by the orthopedic or neurologic surgeon. Rarely the head and neck surgeon will be involved in the treatment of pathology involving the spine, such as infection or primary and metastatic neoplasms. Potential benefits for the primary surgeon of the participation of the otolaryngologist include increased efficiency, decreased risk of injury to the vagus nerve or esophagus, decreased medicolegal risk, and follow-up care of voice and swallowing problems.

Familiarity with these approaches is also important for the treatment of conditions that do not involve the spine, such as deep neck infections, retropharyngeal lymph node metastases, and cricopharyngeal achalasia with Zenker's diverticulum. Surgical approaches to the cervical spine can be categorized as anterior cervical, lateral cervical, transoral, and transnasal approaches. This chapter will focus on anterior transcervical approaches to the cervical spine. Transoral and transnasal approaches to the upper cervical spine are included in Chapter 123.

KEY OPERATIVE LEARNING POINTS

- C1 and C2 are at or above the level of the body of the mandible. C3 and C4 are at the level of the hyoid bone and the superior aspect of the thyroid cartilage. C5 and C6 are at the level of the posterior cricoid cartilage. C7 is at the lower limit of the neck and may be below the level of the clavicle in some patients.
- The anterior cervical spine is approached medial to the carotid sheath and lateral to the strap muscles.
- The superior laryngeal nerve courses across the neck deep to the carotid artery at the level of the thyrohyoid membrane and is in close association with the superior thyroid artery.
- The recurrent laryngeal nerve is situated in the tracheoesophageal groove superficial to the plane of the prevertebral fascia and enters the larynx at the cricothyroid joint.
- Injury to the recurrent laryngeal nerve can be avoided by maintaining a plane of dissection deep to the nerve.
- In revision surgeries, the carotid artery is medially displaced due to scar contracture and at greater risk of injury.
- Lateral to the vertebral bodies, the vertebral artery courses within the vertebral canal of the lateral processes.
- The lateral retropharyngeal lymph nodes (nodes of Rouviere) are situated just medial to the internal carotid artery at the level of the transverse process of the first cervical vertebra (atlas).[1]

PREOPERATIVE PERIOD

History

1. History of present illness
   - Pain
     Patients may have pain in the neck or shoulders from nerve root compression from cervical spondylosis; it may radiate to the upper extremities. Pain may also be exacerbated by movement of the neck.
   - Neurologic dysfunction
     Patients may have sensory and motor loss from spinal cord compression. Patients should be questioned about sensory loss or weakness of the extremities (decreased grip strength, difficulty ambulating).
   - Hoarseness
     Patients who have had prior cervical surgery should be questioned about hoarseness following prior surgery. Hoarseness may signal vocal cord paresis from injury to the recurrent laryngeal nerve. Decreased vocal range with coughing due to aspiration may be associated with injury to the superior laryngeal nerve.
   - Dysphagia
     Dysphagia is often multifactorial. Large osteophytes can cause compression of the esophagus with dysphagia for solids. Dysphagia with regurgitation of undigested food is suggestive of a Zenker's diverticulum.
2. Past medical history
   - Prior cervical spine surgery
     In patients with a prior history of cervical spine surgery, it is important to inquire about the indications for the previous surgery, the operated spine levels, postoperative complications, and the duration of postoperative symptoms. Prolonged hoarseness after surgery may indicate injury to the recurrent laryngeal nerve.
   - Other neck surgery or trauma to the cervical spine
     Other operations in the cervical region such as thyroidectomy should be noted.

Physical Examination

- Inflammation
  Inflammatory conditions such as osteomyelitis or retropharyngeal abscess can result in erythema and edema of the soft tissues. Rarely, crepitus from subcutaneous air is palpable if there is communication with the pharynx or esophagus.
- Range of motion
  Cervical osteophytes may limit the range of motion of the neck (flexion, extension, rotation). Patients with Forestier's disease or diffuse idiopathic skeletal hyperostosis (DISH) often have limited flexion/extension due to extensive calcification of the anterior longitudinal ligaments.[2]
- Mass in the neck
  A mass in the neck may be inflammatory or neoplastic. A large Zenker's diverticulum is rarely palpable. A large thyroid goiter may interfere with a low cervical approach.
- Evidence of prior surgery
  The side and level of prior surgical approaches to the cervical spine should be noted, since this may have an impact on the surgical approach. If a new level is targeted, it may not be possible to use the same incision.
- Upper airway
  The upper airway should be examined by endoscopy to assess the safety of the airway for intubation. Large osteophytes posterior to the pharyngeal mucosa may limit access to the airway.
- Neurologic function
  The function of the larynx should be assessed by laryngoscopy. If there is paresis of a vocal cord, this should be clearly documented.



Fig. 77.1. Sagittal plane computed tomography scan demonstrates position of cervical hardware as well as relationships of laryngeal landmarks to cervical spine levels. In this patient, there is compression of the esophagus by the hardware.

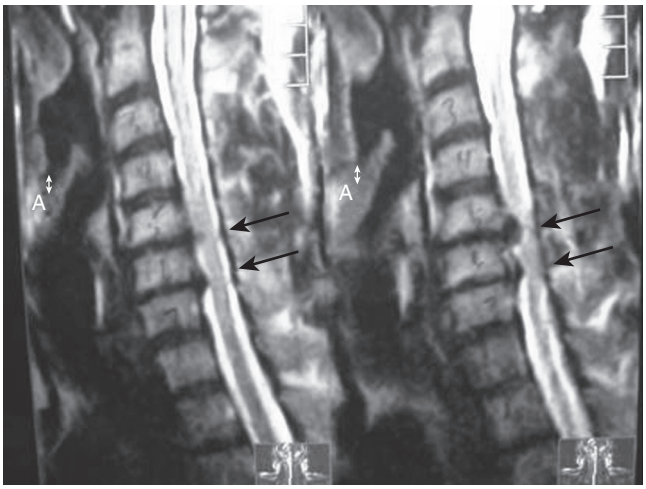

Fig. 77.2. Preoperative magnetic resonance image (sagittal plane) demonstrating the relationships of the cervical vertebrae to palpable laryngeal landmarks, as well as significant spinal cord compression at the C5-C6 and C6-C7 levels due to cervical spondylosis *(arrows)* (A = anterior).

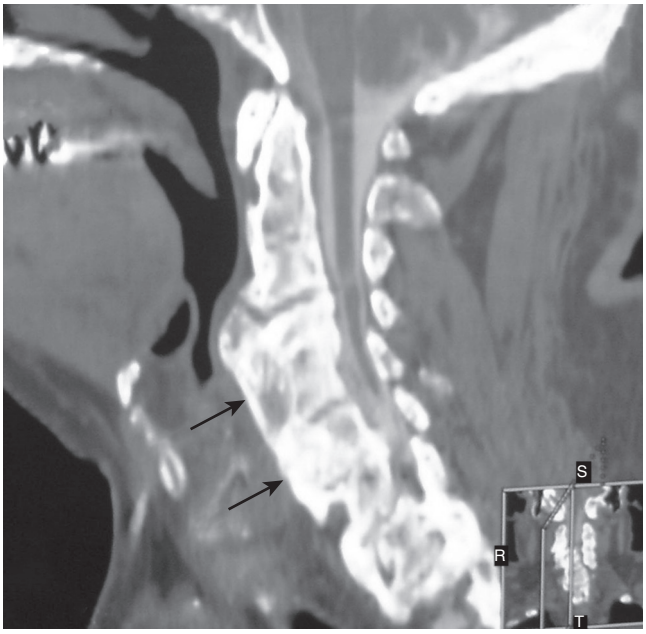

Fig. 77.3. Forestier's disease, or diffuse idiopathic skeletal hyperostosis, is characterized by extensive calcification of the anterior longitudinal ligaments *(arrows).*

Imaging

- Lateral plane radiograph
  Anterior-posterior and lateral spine radiographs provide basic details of bone anatomy and are good for visualization of spinal hardware. The optimal placement of the skin incision can be determined based on the relationship of the cervical spine level to the bony/cartilaginous landmarks of the hyoid bone and thyroid cartilage.
- Esophagram
  If there is suspected perforation of the esophagus, an esophagram is obtained using a water-soluble contrast agent. An esophagram or modified barium swallow is also helpful in assessing the severity and contribution of osteophytes to dysphagia.
- Computed tomography (CT)
  A CT scan with contrast should be considered in patients with associated symptoms or physical findings suggestive of a neoplasm or osteomyelitis. A sagittal view provides optimal viewing of cervical hardware: cervical spine levels, displaced hardware, compression of esophagus (Fig. 77.1).
- Magnetic resonance imaging (MRI)
  MRI is superior for delineating the level of cord compression from a herniated disc (Fig. 77.2).

Indications

1. Cervical spondylosis
   The most common indication for an anterior approach to the cervical spine is cervical spondylosis (Fig. 77.2). Revision surgery is sometimes necessary when there is infection or displacement of plating hardware. Bulky hardware may also contribute to postoperative dysphagia and may be removed electively to improve swallowing function. Large osteophytes occur most commonly at the C4-C6 levels in approximately 12% to 30% of the elderly and may be associated with symptomatic dysphagia and aspiration. It can be difficult to demonstrate that the patient's symptoms are due to the osteophyte, however, since dysphagia is frequently multifactorial in these patients. Patients with Forestier's disease or DISH can develop extensive calcification of the anterior longitudinal ligaments with resultant dysphagia (Fig. 77.3).[2] The calcifications usually span multiple levels.
2. Cervical osteomyelitis
   Rarely infection of the vertebral bodies (osteomyelitis from adjacent infection or hematogenous seeding of the vertebral body; e.g., tuberculosis) may require surgery.

3. Neoplastic involvement of cervical spine
   Malignancies metastatic to the vertebral bodies are usually treated with palliative radiation but may also require surgery for stabilization of the cervical spine.
4. Retropharyngeal abscess
   Infection of deep neck spaces may result in a retropharyngeal abscess. This may result from a suppurative upper respiratory infection with involvement of the retropharyngeal lymph nodes, esophageal perforation, or a foreign body.
5. Zenker's diverticulum
   Although most cricopharyngeal myotomies for Zenker's diverticulum are now performed endoscopically, an anterior cervical approach to the cervical spine provides the necessary exposure of the cricopharyngeus and inferior pharyngeal constrictor muscle for performance of a myotomy or excision of diverticulum with a myotomy, especially in patients who are not candidates for an endoscopic approach.
6. Esophageal perforation
   An esophageal perforation may result from intraluminal trauma (e.g., passage of a tube or esophagoscope), erosion by spinal hardware, or iatrogenic injury from neck surgery. A transcervical approach provides drainage of air/fluid to prevent infection and allows primary surgical repair.
7. Retropharyngeal lymphadenectomy
   Neoplasms of the soft palate, pharynx, thyroid, and skull base may metastasize to retropharyngeal lymph nodes. Although the survival is poor in patients with squamous cell carcinoma metastatic to the retropharyngeal lymph nodes, retropharyngeal lymphadenectomy may be beneficial in selected patients with other types of neoplasms (esthesioneuroblastoma, thyroid cancer).

Contraindications

1. Active neck infection
   Untreated neck infection is a contraindication to cervical spine surgery with instrumentation, unless the patient requires surgical treatment of osteomyelitis. Staging of surgery may be necessary with surgical drainage of infection and medical therapy prior to spine surgery.
2. Major medical comorbidities
   If a patient is not a candidate for general anesthesia, limited surgery for biopsy or drainage of an abscess can be performed with minimal sedation and local anesthesia.

Preoperative Preparation

- Informed consent
  Informed consent includes a discussion of potential risks and expected sequelae of surgery. For anterior approaches, the greatest concern is postoperative hoarseness or aspiration due to injury to the superior or recurrent laryngeal nerves. Some degree of dysphagia is expected postoperatively and can persist for months in a minority of patients.[3] The risk of infection or significant bleeding is negligible. Perforation of the esophagus or hypopharynx is a remote possibility, but the risk is increased when displaced hardware or a large osteophyte is being removed.
- Neck incision
  The laterality of the incision is generally not important. Arguments can be made for either side, depending on the level of exposure, handedness of the surgeon, risk of retraction injury of the recurrent laryngeal nerve, deviation of the esophagus, and prior surgery. Most right-handed surgeons find a right-sided approach to be easier for instrumentation of upper cervical levels and a left-sided approach for instrumentation of lower cervical levels.

  Using the same side as a previous incision is preferred if the same cervical spine level is targeted, especially if spinal hardware needs to be removed. If there is paresis of a vocal cord or preoperative examination of the larynx was not performed, it is safer to operate on the same side to avoid possible paresis of the contralateral vocal cord.

  Assessment of the anatomic relationship of vertebral bodies to cartilaginous and bony landmarks is assessed with a lateral radiograph of the cervical spine or on CT or MRI (sagittal view; Figs. 77.1 and 77.2). The level of upper cervical vertebrae is judged based on their relationship to the hyoid bone. The level of midcervical vertebrae is best judged based on their relationship to the posterior cricoid cartilage and thyroid cartilage. Since cartilaginous landmarks are not well visualized on MRI, the epiglottis is a useful landmark. The anterior ring of the cricoid cartilage is a readily identifiable landmark for localizing the lower cervical vertebrae.
- Neurophysiology
  Neurophysiologic monitoring of spinal cord function is performed intraoperatively when there is preoperative compression of the spinal cord or when surgery on the spinal cord is performed. If there is severe preoperative compression, a baseline study is performed after induction of anesthesia and prior to positioning. After positioning, the patient is reassessed to confirm that neurologic function has not worsened. Continuous monitoring is performed throughout surgery.
- Navigation
  Intraoperative image guidance with a navigational system is helpful for pathology of the upper cervical spine and cranial base but is impractical for lower levels. When a navigational system is used, a CT angiogram will provide good visualization of bony anatomy, as well as the course of the vertebral artery.

OPERATIVE PERIOD

Anesthesia

- General

Positioning

- Supine
  Extension of the neck should be performed cautiously inpatients with cervical spine pathology. In patients with spinal compression, this should be done with neurophysiologic monitoring. The shoulder may be retracted with tape to avoid interference with a lateral neck radiograph (Fig. 77.4).

Perioperative Antibiotic Prophylaxis

- First-generation cephalosporin. A single dose of antibiotic given IV is sufficient for a clean case. If there is active infection, a therapeutic course of antibiotics may be necessary.
- Clindamycin if the patient is allergic to penicillin

Monitoring

- None. However, in reoperative cases, recurrent laryngeal nerve monitoring could be considered.

Instruments and Equipment to Have Available

- Neck dissection set
- Monopolar and bipolar electrocautery



Fig. 77.4. Positioning of the patient for an anterior cervical approach. The neck is extended and the shoulder is retracted inferiorly with tape to avoid obstruction of a lateral cervical radiograph. The skin incision is marked.

- Right angle Mixter forceps
- Meyerding retractors
- Self-retaining spinal retractors

Key Anatomic Landmarks

- Sternocleidomastoid and omohyoid muscles
  - The surgical approach is between the sternocleidomastoid and strap muscles (sternohyoid, sternothyroid, thyrohyoid, and omohyoid muscles). Inferiorly, the surgical window narrows between the sternocleidomastoid and omohyoid muscles.
  - The thyroid lobe is deep to the strap muscles.
- Carotid sheath
  - The carotid sheath contains the carotid artery, internal jugular vein, and vagus nerve. The vagus nerve is lateral to the vascular structures.
- Prevertebral fascia and longus colli muscles
  - The prevertebral fascia covers the longus colli muscles. In the midline, there is separation of the muscles.
- Recurrent laryngeal nerve
  - The recurrent laryngeal nerve runs vertically in the tracheal-esophageal groove and enters the larynx at the level of the cricothyroid joint.
- Superior laryngeal nerve
  - The superior laryngeal nerve is closely associated with the superior thyroid artery and crosses the surgical field obliquely (deep to the carotid artery) to enter the larynx at the thyrohyoid membrane.

Prerequisite Skills

- Neck dissection
- Repair of esophagus

Operative Risks

- Vascular injury
  The risk of vascular injury is greater in revision cases where there is scar tissue and medial displacement of the carotid artery.
- Injury to the esophagus
  The esophagus may be injured during the exposure or from excessive retraction.
- Injury to the recurrent laryngeal nerve



Fig. 77.5. Skin incisions for approaching, upper cervical spine (C3-5) and, lower cervical spine (C5-7).

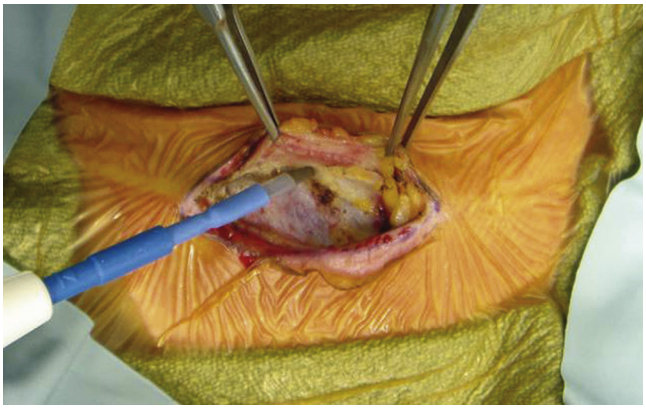

Fig. 77.6. Subplatysmal flaps are elevated.

The recurrent laryngeal nerve may be injured directly (transection, crush injury, thermal injury) or from retraction.[4,5]

- Superior laryngeal nerve injury
  The superior laryngeal nerve is at greatest risk of injury with high cervical approaches.

Surgical Technique

- The level of the incision is dependent on the desired level of exposure (vertebral level; Fig. 77.5). A transverse incision is planned in a natural skin crease in the mid- to upper neck for C2-C4 and the mid- to lower neck for C5-C7. The incision extends from the paramedian position (1 cm lateral to the midline) to the anterior border of the sternocleidomastoid muscle. The proposed skin incision is infiltrated with 10 cc of 0.5% xylocaine with epinephrine (1:200,000) and marked. After prepping, adhesive drapes are used to avoid the placement of metal instruments around the surgical field. These may interfere with intraoperative imaging (lateral radiograph or fluoroscopy) to confirm the cervical spine level.
- Subplatysmal flaps are elevated (Fig. 77.6), and dissection continues medial to the sternocleidomastoid muscle and lateral to the strap muscles (Fig. 77.7). The internal jugular vein is identified, and dissection continues medially (Fig. 77.8). Motor branches of the ansa cervicalis to the strap muscles are preserved when possible. In a patient with a muscular neck, transection of the omohyoid muscle is sometimes necessary to provide adequate exposure of lower cervical levels. The carotid sheath is identified,

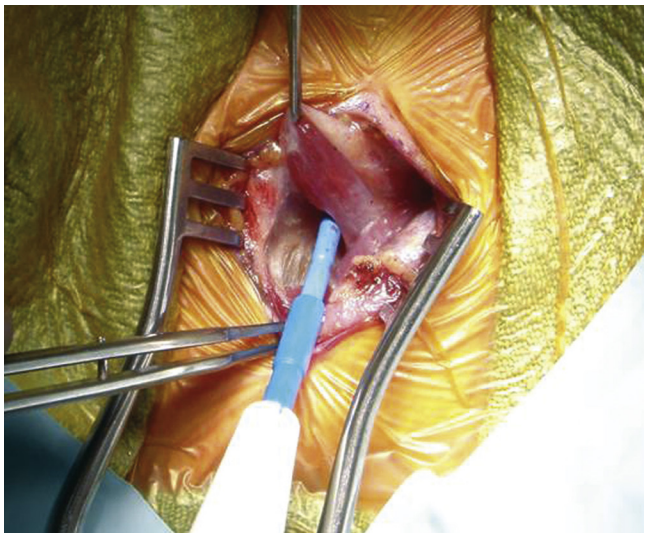

Fig. 77.7. Dissection is performed between the sternocleidomastoid and omohyoid (forceps) muscles (right neck).

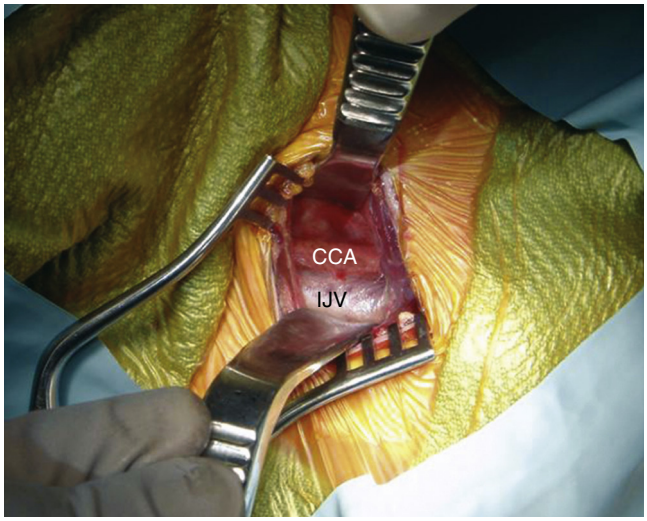

Fig. 77.8. The internal jugular vein *(IJV)* and common carotid artery *(CCA)* are exposed and retracted laterally (right neck).

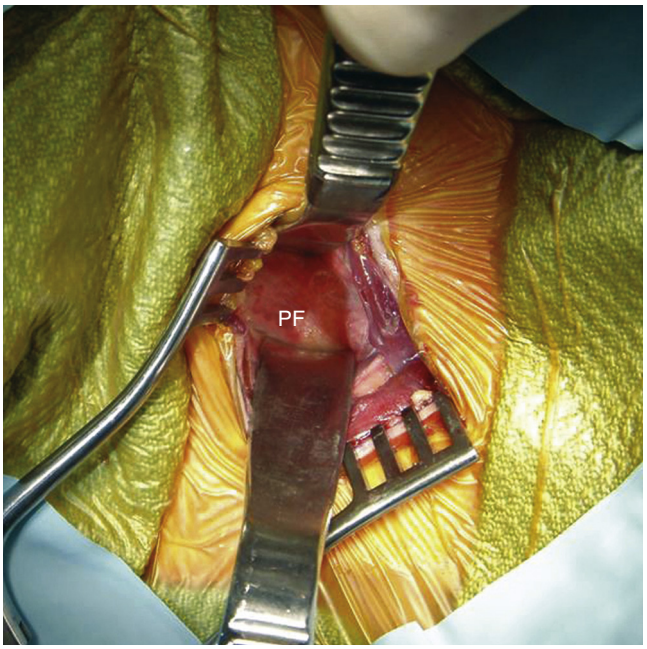

Fig. 77.9. The retropharyngeal space is bluntly dissected, and the larynx and esophagus are retracted medially to expose the prevertebral fascia *(PF)* (right neck).

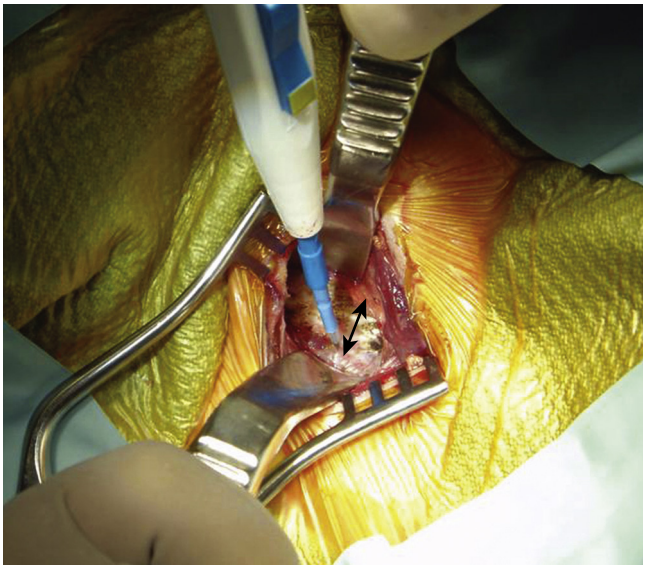

Fig. 77.10. The prevertebral fascia is incised in the midline and the longus colli muscles *(arrows)* are elevated from the vertebral bodies (right neck).

and blunt finger dissection medial to the carotid artery is usually sufficient to create a tunnel between the carotid sheath and the esophagus to expose the prevertebral fascia (Fig. 77.9).

- The length of the exposure is extended superiorly and inferiorly with appreciation of the course of the laryngeal nerves. With a superior exposure, careful dissection is performed along the medial aspect of the carotid sheath. The superior laryngeal nerve crosses from lateral to medial deep to the carotid artery and is closely associated with the superior thyroid artery. Once the nerve is identified, dissection of the retropharyngeal space can be performed deep to the nerve with gentle superior retraction. It is rarely necessary to identify the recurrent laryngeal nerve. A plane of dissection is maintained deep to the nerve and esophagus to avoid injury.
- The larynx and esophagus are retracted medially, and the prevertebral fascia is incised in the midline with electrocautery (Fig. 77.10). The edges of the longus colli muscles are elevated from the underlying vertebral bodies at the desired levels. Venous bleeders from the surface of the bone are controlled with electrocautery. Excessive lateral dissection should be avoided due to potential risk to the vertebral arteries. The cervical spine level is confirmed radiographically by placing a spinal needle with a 1-cm "stair-step" bend at the tip in the intervertebral space and obtaining a lateral radiograph (Fig. 77.11). Self-retaining or fixed retractors are then placed (Fig. 77.12). Further decompression and fusion are performed by the spine surgeon.
- Access to the retropharyngeal space for other disease processes is performed in the same way. Although the retropharyngeal lymph nodes may be approached anterior or posterior to the carotid sheath, an anterior approach is recommended, since there is less retraction of the carotid artery, less risk of

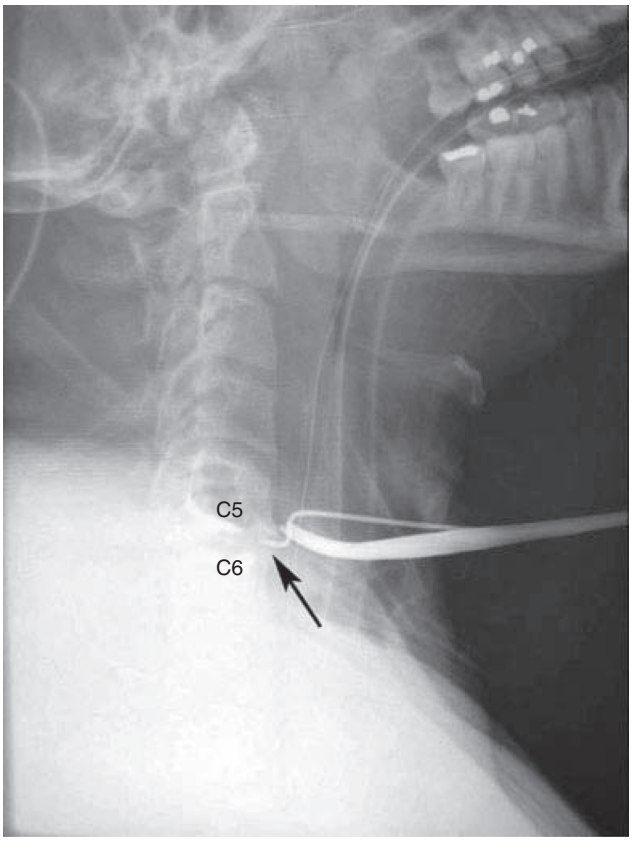

Fig. 77.11. A spinal needle with the tip bent in stair-step fashion is inserted into a disc space to mark the cervical spine level. A lateral cervical radiograph demonstrates the spinal needle *(arrow)* in the C5-C6 disc space.



Fig. 77.12. Self-retaining retractors are placed between the longus colli muscles.

injury to the sympathetic chain, and greater exposure. The sternocleidomastoid muscle and carotid sheath are retracted laterally, and the digastric muscle and hypoglossal nerve are retracted superiorly. Transection of the descendens hypoglossi nerve may be necessary to mobilize the hypoglossal nerve. The superior laryngeal nerve is identified, and a window is created between these nerves. The retropharyngeal lymph nodes are anterior to the superior sympathetic ganglion at the level of the transverse process of the atlas.[1]

- The wound is irrigated with saline, and a suction drain is placed between the muscles and medial to the carotid sheath. The platysma and skin layers are closed separately.

Common Errors in Technique

- Placement of skin incision
  Improper placement of skin incisions can create problems for the surgeon. An incision that is too far superior runs the risk of injury to the marginal mandibular branch of the facial nerve. An incision that is made too far inferior is obstructed by the sternal head of the sternocleidomastoid muscle. If the dissection is too medial, the strap muscles and the thyroid gland will interfere with the approach. Occasionally, an enlarged thyroid lobe is encountered and needs to be mobilized along its lateral margin. If the dissection is too far laterally, there is the potential of dissection lateral to the carotid artery with risk of injury to the vagus nerve and sympathetic chain (Horner's syndrome).
- Plane of dissection
  If the laryngeal retractor is not placed deep enough to protect the esophagus, an esophageal perforation may result. Failure to maintain a plane of dissection on the surface of the prevertebral fascia may injure the recurrent laryngeal nerve in the tracheoesophageal groove.

POSTOPERATIVE PERIOD

Postoperative Management

- The neck drain is removed in 1 to 2 days. If output remains high or the contents are cloudy, the patient should be evaluated with an esophagram to identify an esophageal leak.
- Postoperative care focuses on the function of the lower cranial nerves. Transient hoarseness may be due to edema of the vocal cord. Hoarseness that persists for more than a week should be evaluated further with examination of the larynx to evaluate vocal cord function. A significant percentage of recurrent laryngeal nerve injuries following cervical spine surgery go unrecognized. The patient should also be queried about aspiration. If a complete paralysis is observed, options include observation, vocal cord injection if symptoms are significant, and laryngeal EMG to evaluate the degree of injury.
- Transient dysphagia is to be expected, and most patients can accommodate a mechanical soft diet until it resolves. The incidence of postoperative dysphagia is 50% at 1 month, 32% at 2 months, 18% at 6 months, and 13% at 12 months.[3] Mechanisms of injury include laryngeal nerve injury, pharyngeal plexus injury, scarring of the pharynx, and obstruction by hardware. Persistent dysphagia should be evaluated with an esophagram. A follow-up radiograph will usually be obtained by the spine surgeon to assess adequate placement and retention of the spinal hardware.
- The following billing codes may be used for an anterior cervical approach to the cervical spine: 22554-62: *"spinal arthrodesis or fusion . . . incision is made through the neck, avoiding the esophagus, trachea, and thyroid . . . separate the intervertebral muscles,"* and 22585-62: *"each additional interspace treated in conjunction with the code for the primary procedure."*

Complications

- It is possible to dissect lateral to the carotid sheath. If it is not detected, excessive medial displacement of the carotid artery by the retractors may result in carotid injury or ischemia.

There is a greater risk of this mistake in revision cases when postoperative scarring results in medial displacement of the carotid artery. Direct injury to the vagus nerve can also occur.

- If the dissection is too superficial, there is a risk of injury to the esophagus and recurrent laryngeal nerve.
- Vocal cord paralysis secondary to injury of the recurrent laryngeal nerve may occur from direct nerve injury (transection, thermal injury from electrocautery), excessive and prolonged retraction, and overinflation of the endotracheal tube cuff.[4,5] Animal models and clinical studies have demonstrated that there is a sharp increase in endotracheal tube cuff pressures when retractors are placed. The recurrent laryngeal nerve is susceptible to ischemic injury where it enters the larynx at the cricothyroid articulation. The risk of neuropraxia can be reduced by readjusting the cuff pressure after retractors are placed. The anesthetist is asked to deflate the cuff and reinflate with the minimum amount of air necessary to achieve a seal. This is usually 1 to 2 cc less air.
- Vertebral artery
  The vertebral arteries are deep to the transverse processes of the cervical vertebrae. Excessive lateral dissection with electrocautery can injure the artery, where it is exposed in the transverse foramen.
- Dysphagia
  Postoperative dysphagia is common and results from tissue edema, compression from hardware, and rigidity of the spine.[3]
- Hoarseness
  Hoarseness may result from intubation trauma, surgical injury to the recurrent laryngeal nerve, or compressive neuropraxia from the endotracheal tube cuff.
- Horner's syndrome
  Dissection lateral to the carotid sheath can cause Horner's syndrome.

Alternative Management Plan

- A cricopharyngeal myotomy for Zenker's diverticulum is preferentially performed using an endoscopic/microscopic transoral approach, unless the patient's anatomy is unfavorable.
- An esophageal perforation without neck abscess can be managed conservatively with a nasogastric feeding tube. Healing occurs by secondary intention.

DISCUSSION

Evidence-Based Medicine Question

What are risk factors for dysphonia following anterior cervical spine surgery?

Dysphonia is a common postoperative complaint following cervical spine surgery. Most of the time, it is transient with full recovery. Injury to the superior or recurrent laryngeal nerves can result in chronic dysphonia.

In a review of 815 consecutive patients undergoing anterior cervical spine surgery, 3.9% developed postoperative dysphonia. All cases were performed using a team approach with a neurosurgeon and head and neck surgeon. Fiberoptic laryngoscopy demonstrated that only nine (1.1%) of these patients had ipsilateral vocal fold palsy. Of these nine patients, only one (0.1%) was found to have permanent vocal fold paralysis at 1-year follow-up. In contrast, a review of published studies reveals that the incidence of recurrent laryngeal nerve injury (both temporary and permanent paralysis) was 3.3% (100/3072).[5]

There is a low incidence of postoperative dysphonia when cervical spine exposure is provided by a head and neck surgeon. Factors associated with voice change and vocal cord motion impairment included kyphosis, revision surgery, and level C6-C7 surgery. Kyphosis was the only independent factor correlating with voice change. Team surgery appears to reduce laryngeal complications and optimize the management of temporary or permanent postoperative dysphonia.

Editorial Comment

Transcervical approaches to the cervical spine provide an opportunity for multidisciplinary management of patients with cervical spine disease. The otolaryngologist can make valuable contributions to the surgical plan by providing access to the cervical spine, especially in patients who have multilevel disease or scar tissue from previous neck surgery, due to their knowledge and comfort level with the anatomy of the neck, specifically the course of the recurrent and superior laryngeal nerves. In addition, oversight by an otolaryngologist is helpful from the perspective of postoperative management of complications such as recurrent nerve injury, causing hoarseness or dysphagia that require swallow evaluation and therapy.

Rohan R. Walvekar

Access the review questions and additional sources list online at http://www.expertconsult.com

REFERENCES

1. Ozlugedik S, Ibrahim Acar H, Apaydin N, et al. Retropharyngeal space and lymph nodes: an anatomical guide for surgical dissection. Acta Otolaryngol 2005;125:1111–1115.
2. Sarzi-Puttini P, Atzeni F. New developments in our understanding of DISH (diffuse idiopathic skeletal hyperostosis). Curr Opin Rheumatol 2004;16:287–292.
3. Bazaz R, Lee MJ, Yoo JU. Incidence of dysphagia after anterior cervical spine surgery, a prospective study. Spine 2002;27:2453–2458.
4. Jung A, Schramm J, Lehnerdt K, et al. Recurrent laryngeal nerve palsy during anterior cervical spine surgery: a prospective study. J Neurosurg Spine 2005;2:123–127.
5. Razfar A, Sadr-Hosseini SM, Rosen CA, et al. Prevention and management of dysphonia during anterior cervical spine surgery. Laryngoscope 2012;122(10):2179–2183.

REVIEW QUESTIONS

1. Indications for an anterior transcervical approach to the spine include all of the following, except
   a. Laryngocele
   b. Cervical spondylosis with nerve compression
   c. Retropharyngeal abscess
   d. Zenker's diverticulum with dysphagia

2. Injury to the recurrent laryngeal nerve can be avoided by
   a. Preserving the omohyoid muscle
   b. Maintaining a plane of dissection deep to the esophagus
   c. Preserving the superior thyroid artery
   d. Maintaining constant endotracheal tube cuff pressure throughout the procedure

3. Risks of an anterior transcervical approach to the spine include all of the following, except
   a. Vocal cord paralysis
   b. Injury to the vertebral artery
   c. Chyle leak
   d. Horner's syndrome

ADDITIONAL SOURCES

Joaquim AF, Murar J, Savage JW, et al. Dysphagia after anterior cervical spine surgery: a systematic review of potential preventative measures. Spine J 2014;14(9):2246–2260.

Tetreault L, Ibrahim A, Côté P, et al. A systematic review of clinical and surgical predictors of complications following surgery for degenerative cervical myelopathy. J Neurosurg Spine 2016;24(1):77–99.

SECTION 11 Thyroid and Parathyroid

78 Open Thyroidectomy

Yuan F. Liu, Alfred Simental, Jr.

INTRODUCTION

Although thyroid disease has been recognized for centuries, consistently accepted techniques of thyroid surgery date back approximately 100 years. With a combined mortality of 40% from hemorrhage and sepsis, thyroidectomy was banned by the French Academy of Medicine in 1850. However, with the advent of antiseptic technique, vascular ligation, and precise capsular dissection, Theodor Kocher reduced the perioperative mortality rate to less than 1% in 900 cases for benign goiter in 1895. He was awarded the Nobel Prize in Medicine in 1909 for his contributions to thyroid surgery. Crile, Lahey, and the Mayo brothers founded their internationally famous private clinics largely based on their ability to perform thyroid surgery safely.

Thyroid nodules are found by palpation in 4% to 7% of subjects and by imaging in 30% to 67% of the population. While nonmalignant thyroid abnormalities are quite common, 5% to 20% of nodules may contain malignancy on excision. Studies suggest that 33% of subjects have thyroid cancer on autopsy, and that approximately 50% of the population may have microscopic thyroid cancer.

Carcinoma of the thyroid accounts for approximately 3.8% of cancers in the United States, with an estimated 62,450 new cases in 2015 and 75% occurring in women. It is currently the fifth leading new cancer diagnosis in women and is projected to overtake colorectal cancer as the fourth leading cancer diagnosis overall in the United States by 2030. Although the incidence of thyroid cancer has risen in recent years, perhaps due to the increased use of ultrasound, its mortality rate has remained stable with a 5-year survival of approximately 98%, accounting for 0.3% of all cancer deaths in 2015.

KEY OPERATIVE LEARNING POINTS

1. Identification and continued observation of the recurrent laryngeal nerve is the best way to avoid injury to the nerve.
2. Skeletonize the superior pedicle and ligate close to the thyroid gland to avoid injury to the superior laryngeal nerve and parathyroids.
3. Identify and lateralize the parathyroid glands with their blood supply.
4. Careful placement of the incision and protection of skin edges promote optimal cosmetic results.

PREOPERATIVE PERIOD

History

1. History of present illness[1]
    a. Evaluate for onset, duration, change in size, growth rate, and pain.
        1) Asymptomatic nodules are often found on imaging.
        2) Rapid growth of a new or previously stable nodule is concerning for malignancy.
        3) Pain is not commonly associated with thyroid cancer and may represent thyroiditis or hemorrhage into a benign nodule.
    b. Compressive symptoms: Shortness of breath and dyspnea (especially with lying flat), persistent dysphagia
    c. Invasive symptoms: Hemoptysis, fixation of the overlying skin, or hoarseness from paralysis of the vocal cord
    d. Hyper or hypothyroid symptoms: Palpitations, weight change, fatigue, anxiety, sleep disturbance, or menstrual changes
2. Risk factors for thyroid cancer
    a. Age
        1) Less than 20: ~20% risk of malignancy in a solitary nodule
        2) 20 to 40: 5% to 10% risk of malignancy in a solitary nodule
        3) Peak in women 45 to 50, men 65 to 70
    b. Gender: There is a triple prevalence in women, but thyroid nodules in men are more likely to be malignant.
    c. Two or more first-degree relatives with a history of thyroid cancer
    d. Exposure to low dose radiation to the neck
3. Past medical history
    a. Hashimoto's thyroiditis
        1) Nodules are 30% more likely to contain papillary thyroid cancer.
        2) Increased risk of lymphoma
    b. Consider multiple endocrine neoplasia type 2 (MEN-2) and medullary thyroid carcinoma in patients with pheochromocytoma, hyperparathyroidism, marfanoid habitus, and/or mucosal neurofibromas.
    c. Gardner syndrome (polyposis coli) and Cowden disease are associated with thyroid cancer.

Physical Examination

1. Complete examination of the head and neck.
    a. Palpate thyroid for enlargement and nodules.
        1) Note size, shape, firmness, movement with swallowing, fixation to skin, or underlying structures.
    b. Palpate neck for lymphadenopathy.
    c. Listen for hoarseness, stridor.
2. Direct or indirect laryngoscopy
    a. This is essential in detecting vocal cord paralysis.
    b. The voice may be normal despite a paralyzed vocal cord.

Laboratory Studies

1. Thyroid stimulating hormone (TSH)[1]
   a. Initial study of choice to rule out hypo or hyperthyroidism
2. Thyroglobulin (Tg)[1]
   a. Cannot reliably differentiate between benign and malignant thyroid disease
3. Calcitonin
   a. Usually not recommended unless patient has a family history of medullary thyroid carcinoma or MEN-2, or biopsy shows medullary thyroid carcinoma

Imaging

1. Ultrasound (US)[1]
   a. Thyroid US with attention to central compartment should be performed in all patients with a thyroid nodule, even when found on computed tomography (CT).
   b. Provides details on size, consistency, other nodules, and associated cervical lymphadenopathy
   c. Useful for serial monitoring of nodules and lymph nodes
   d. Findings associated with malignancy include
      1) Complex nodules
      2) Irregular margins
      3) Increased nodular vascularity
   e. Microcalcifications are associated with markedly increased risk of malignancy, while cystic and spongiform appearance may be associated with benign lesions.
2. CT and magnetic resonance imaging (MRI)
   a. Generally not needed
   b. Can be helpful for
      1) Substernal extension
      2) Cervical and mediastinal lymphadenopathy
      3) Invasion of surrounding structures such as trachea and esophagus
      4) Metastasis to distant body sites
   c. Use of iodinated contrast may preclude the use of radioactive iodine (RAI) for 1 to 3 months.
3. Radionuclide scanning
   a. Usually performed with ^{123}I or technetium 99m (^{99m}Tc) sestamibi
   b. Incidence of malignancy is 4% in "hot" nodules and 10% to 15% in "cold" nodules.
   c. Not routinely performed unless TSH level indicates hyperthyroidism
      1) If hyperfunctioning nodule, no cytologic evaluation necessary and consideration for ablative radioiodine
      2) If hypofunctioning, may indicate malignancy
      3) Most cancers are isometabolic

Fine Needle Aspiration

1. Best initial diagnostic test
   a. Minimally invasive, safe, and cost effective
   b. Sensitivity 65% to 98%; specificity 72% to 100%
   c. US guidance increases accuracy and success of fine needle aspiration (FNA)
2. Suspicious cervical lymph nodes should undergo FNA in addition to that of thyroid nodules.
3. When multiple nodules are present, the largest and/or most sonographically suspicious should preferentially be biopsied.
   a. Multiple nodules may need to be biopsied to increase diagnostic yield.
4. Bethesda classification of thyroid cytopathology[2]
   a. I: Nondiagnostic, 1% to 4% risk of malignancy
   b. II: Benign, 0% to 3% risk.
   c. III: Atypia of undetermined significance (AUS) or follicular lesion of undetermined significance (FLUS), 5% to 15% risk.
      1) This is a gray zone where repeat FNA, observation with serial US, and surgery are all potential options.
   d. IV: Follicular neoplasm, 15% to 30% risk
   e. V: Suspicious for malignancy, 60% to 75% risk
   f. VI: Malignant, 97% to 99% risk

Molecular Biomarkers

1. Newer studies introduced to increase accuracy of FNA and better characterize the risk of malignancy, especially in indeterminate cytology, AUS, and FLUS lesions.[3] These markers may
   a. Reduce unnecessary surgery for benign lesions
   b. Reduce completion thyroidectomy by guiding initial use of total thyroidectomy
   c. Provide prognostic information
2. Examples: BRAF, RAS, TIMP1, RET/PTC, Pax8-PPARγ, galectin-3, cytokeratin, microRNA, gene sequencing
3. Uncertain evidence regarding efficacy and utility

Indications

Total Thyroidectomy

1. Differentiated thyroid carcinoma if one or more of the following:[1]
   a. Tumor greater than 4 cm
      1) Between 1 and 4 cm: Option of lobectomy or total thyroidectomy
   b. Gross extrathyroidal extension
   c. Contralateral thyroid nodule or cervical/distant metastasis
   d. Multinodular goiter with radiation exposure to head and neck
   e. First degree family members with thyroid cancer
2. Medullary thyroid carcinoma
3. Anaplastic thyroid carcinoma, depending on resectability
4. Bilateral indeterminate nodules
5. Multinodular goiter causing compressive symptoms
6. Medically refractory Grave's disease or hyperthyroidism

Thyroid Lobectomy

1. Papillary or follicular thyroid carcinoma if all of the following:[1]
   a. Less than 4 cm
   b. Low-risk pathology
   c. Unifocal/solitary thyroid nodule
   d. Intrathyroidal
   e. No prior head and neck radiation
   f. No cervical metastasis
2. Isolated, indeterminate nodule (AUS, follicular neoplasm, or suspicious for carcinoma)
   a. Patient may elect for total thyroidectomy to avoid completion thyroidectomy
3. Benign nodule greater than 3 to 4 cm
4. Nodule causing compressive symptoms

Contraindications

1. Uncontrolled, severe hyperthyroidism (relative contraindication)
   a. Risk of intraoperative thyroid storm

2. Pregnancy (relative)
   a. May elect to postpone until postpartum
   b. If substantial growth, surgery may be performed in second trimester to reduce risk of miscarriage.
3. Prohibitive comorbid medical conditions

Preoperative Preparation

1. Screen for comorbidities.
2. Document vocal cord movement with indirect laryngoscopy prior to surgery.
3. Assure euthyroid state.

OPERATIVE PERIOD

Anesthesia

1. Administer general endotracheal anesthesia.
2. Local anesthesia with sedation may be considered with significant comorbidities such as poor cardiac function, or in pregnant patients.

Positioning

1. Supine
   a. Shoulder roll to slightly extend neck and elevate thyroid
   b. Head placed in a donut to prevent rotation
2. The bed can be shifted away from anesthesia to provide more surgical space.
3. The back may be elevated 10 to 30° to reduce venous congestion.
4. Prepare neck and upper chest with povidone-iodine or chlorhexidine (entire chest if sternotomy anticipated for a substernal goiter).
5. Arms tucked at the side with padding of elbows and heels.

Perioperative Antibiotic Prophylaxis

1. Perioperative antibiotics are not necessary in clean thyroid surgery.
   a. A single preincision intravenous dose of broad-spectrum antibiotic such as second-generation cephalosporin or clindamycin antibiotic is acceptable.

Monitoring

1. Intraoperative laryngeal nerve monitoring (IONM) may be used.[4]
   a. Endotracheal tube with surface electrodes placed at level of vocal cords
   b. Becoming increasingly popular but efficacy is controversial
   c. No difference in rate of vocal cord palsy between visual identification and IONM
   d. Increased cost and setup time
   e. Not a substitute for gold standard of visual identification and careful dissection
   f. Useful adjunct for identification of the recurrent nerve, which may result in decreased operative time and increased surgeon comfort

Instruments and Equipment

1. Basic head and neck set
2. Ultrasonic scalpel (preferred by the senior author for its hemostatic ability and speed) and bipolar cautery
3. Mahorner, Lone Star, or Weitslander self-retaining retractors may be helpful if an assistant is not available.
4. Kittner/peanut sponges for blunt dissection, retracting and protecting nerves or parathyroid tissue from the heat of electrocautery or ultrasonic technology
5. Babcock forceps are helpful in grasping and retracting thyroid tissue.
6. McCabe dissector
   a. Has curved, precise, nonlocking tips
   b. Excellent for identifying and dissection of nerves
7. Surgical clips

Key Anatomic Landmarks

1. Embryology
   a. Thyroid gland arises from the first and second pharyngeal pouches at the foramen cecum.
   b. It descends along the thyroglossal duct, anterior to the hyoid bone, to its final position overlying the second to fourth tracheal rings.
2. Thyroid gland[5]
   a. Lateral lobes: 4 to 5 cm tall, 1 to 2 cm wide, 2 to 4 cm thick
   b. Isthmus: 12 to 15 mm wide, absent in 5% to 10%
   c. Pyramidal lobe: Remnant of the thyroglossal duct, found as a superior extension of the isthmus in 40% to 50%
   d. Tubercle of Zukerkandl: Remnant of the lateral thyroid processes (ultimobranchial bodies), found as posterolateral projection (sometimes bifid) of each lobe in 63% to 78%
   e. Lies within the middle layer of the deep cervical fascia (pretracheal fascia)
   f. Attached by ligaments that are extensions of a thin but tightly adherent capsule, which extends as septa into the thyroid parenchyma, dividing it into lobules.
      1) Superomedial: Anterior suspensory ligament to thyroid and cricoid cartilages
      2) Posteromedial: Posterior suspensory ligament (Berry's ligament) to first and second tracheal rings and cricoid cartilage
3. Vasculature
   a. Arterial
      1) Superior thyroid artery: First branch of the external carotid artery (branch of the common carotid in 16%)
      2) Inferior thyroid artery: Branch of the thyrocervical trunk
      3) Thyroidea ima artery (in thyrothymic adipose tissue)
         a) Branch of the innominate, subclavian, or right common carotid, internal thoracic arteries, or aortic arch
         b) Supplies thyroid isthmus inferiorly
         c) Present in 2% to 12%
   b. Venous
      1) Superior thyroid veins: Run alongside the superior thyroid arteries and join with the internal jugular veins
      2) Middle thyroid veins: Join the internal jugular veins
      3) Inferior thyroid veins: Frequent anastomoses before joining the innominate veins
   c. Lymphatics: Prelaryngeal, pretracheal, paratracheal, parapharyngeal, deep cervical, and supraclavicular nodes
4. Recurrent laryngeal nerve (RLN)
   a. Emanates from the vagus nerve as it courses inferiorly, anterior to the aortic arch
      1) Left: Wraps around the aortic arch below the ligamentum arteriosum, and returns to the neck in the trachea-esophageal groove
      2) Right: Branches from the vagus higher than the left and wraps around the subclavian artery before ascending along the tracheoesophageal groove more laterally than the left

3) Courses beneath the inferior pharyngeal constrictor muscle and passes posterior to the cricothyroid joint
4) Enters larynx above the first tracheal ring, below cricoid cartilage

b. Function
1) External branch: All intrinsic muscles of the larynx (except the cricothyroid muscle)
2) Internal branch: Sensation to the laryngeal mucosa of the glottis and subglottis

c. Landmarks
1) Simon's triangle: Bound by common carotid artery laterally, esophagus medially, and inferior thyroid artery superiorly
2) Variably associated with the inferior thyroid artery
a) Found behind or between branches of the artery in 80%
b) Relationship between the RLN and the inferior thyroid artery different on the left and right in about 50% of cases
3) Usually in the vicinity of the inferior parathyroid gland
4) Majority found within 3 mm of Berry's ligament, often laterally, and sometimes passing through the ligament
5) May pass through the capsule of the thyroid gland
6) Deep to the tubercle of Zukerkandl in 98% of patients
7) Nonrecurrent laryngeal nerves can be found in up to 0.7% of patients.
a) Primarily on the right (associated with aberrant subclavian), except in cases of situs inversus (dextrocardia)
b) May arise at the level of the thyroid cartilage or superior pole of thyroid and course directly into the larynx
8) May divide at various levels, and 40% to 65% bifurcate or trifurcate more than 5 mm below the cricoid cartilage

5. Superior laryngeal nerve (SLN)
a. Arises from the nodose (inferior) ganglion of the vagus nerve about 4 cm above the carotid bifurcation, near the jugular foramen
1) Descends lateral to the pharynx and posteromedial to the carotid sheath
2) Divides into internal and external branches about 2 cm above the superior pole of the thyroid, with the former penetrating through the posteroinferior thyrohyoid membrane

b. Function
1) Internal branch: Sensation and secretomotor function to the supraglottis, epiglottis, base of tongue, piriform sinus, and upper esophageal sphincter
2) External branch: Cricothyroid and inferior constrictor muscles. Tensor of vocal cords

c. SLN external branch landmarks
1) Sternothyrolaryngeal triangle (Joll's triangle): Bound by the midline medially, superior thyroid pole laterally, and attachments of the strap muscles superiorly
2) The nerve is deep to the superior thyroid artery 82% to 86% of the time and penetrates the inferior constrictor muscle at variable levels.
3) Can be found below and up to 1 cm above the level of the upper pole of the thyroid in 37% of patients

Prerequisite Skills

1. Intricate knowledge of surgical instrument use and meticulous soft tissue/neural dissection

Operative Risks

1. Injury to the recurrent laryngeal nerve
a. Preferential visual identification of the RLN before the thyroid is dissected off of the trachea
2. Injury to the superior laryngeal nerve
a. Carefully dissect out the superior pole to ensure that the SLN is not hidden within the vascular pedicle before ligation.
3. Injury to or devascularization of the parathyroid gland
a. Lateralize parathyroids with their blood supply when medializing the thyroid gland
b. Re-implant normal, frozen biopsy confirmed parathyroids.
4. Intraoperative hemorrhage
a. Anterior jugular veins: Carefully undermine subplatysmal skin flaps and ligate large vessels.
b. Carotid artery: Use a blunt instrument when dissecting in this region, especially superior pole, and be aware of depth of dissection at all times.
c. Thyroid gland and surface vessels: Use blunt dissection close to the thyroid capsule and meticulously seal or ligate vasculature.

Surgical Technique

Thyroid Lobectomy

1. Marking
a. Mark a 3 to 5 cm horizontal incision line between the cricoid cartilage and suprasternal notch.
1) Usually 2 to 3 cm above the sternal notch
b. Use an existing neck crease or line of relaxed skin tension.
c. Mark the incision higher in younger patients, because the scar will migrate lower over time and a scar below the clavicle is often unsightly.
2. Local anesthesia
a. Inject 0.25% bupivicaine with 1:200,000 epinephrine 1 to 2 cm above and below the incision line to reduce distortion, since the arterial supply is coming from below.
3. Incision
a. Use a #15 blade to incise the dermis to the platysma.
b. Incise through the platysma to the subcutaneous tissue with electrocautery to the investing fascia.
c. Avoid injuring the communicating anterior jugular veins.
4. Elevate the skin flaps.
a. Using skin rakes for tension, subplatysmal flaps are elevated with blunt dissection and electrocautery in the plane just above the investing fascia and anterior jugular veins up to the thyroid notch and down to the sternal notch.
b. Ligate large vessels with 2 to 0 silk ties.
c. Protect the skin with occlusive material such as Steri-Strips (preferred by the senior author; Fig. 78.1).
1) Suture in place with locking 2 to 0 silk running stitches
2) Protects the skin from heat or instrument injury
d. Place a self-retaining retractor if an assistant is not available.
5. Divide and elevate the strap muscles.
a. Identify the median raphe of the strap muscles.
b. Divide the strap muscles in the midline up to the thyroid notch and down to the sternal notch with electrocautery.
c. Elevate the strap muscles off of the thyroid.
1) Elevate bluntly with a Freer elevator, peanut sponge, or with electrocautery.



Fig. 78.1. The skin edges are protected with running, locking silk sutures after raising subplastysmal flaps.

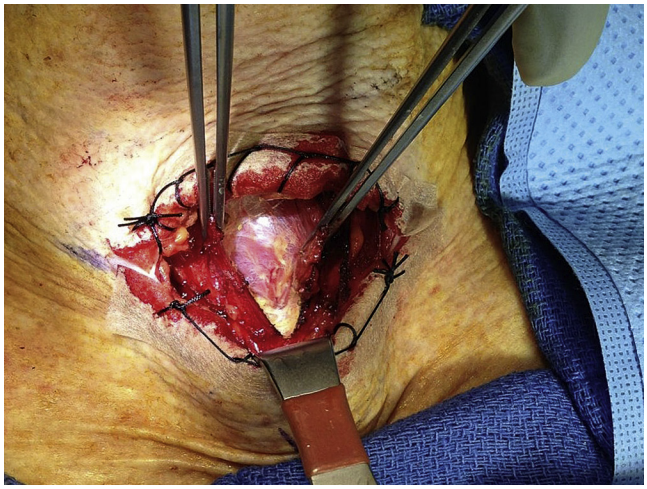

Fig. 78.2. The strap muscles are divided at the median raphe with electrocautery.

2) The strap muscles should be sacrificed with a healthy margin if there is any tumor infiltration of the muscles.

6. Ligate the superior vascular bundle.
   a. Using an Army-Navy retractor, retract the strap muscles superolaterally to expose the superior pole.
   b. The sternothyroid and or thyrohyoid muscles may have to be divided to provide better exposure of the superior pole in large goiters.
   c. Once the superior vascular bundle has been identified, skeletonize the vessels circumferentially using a right-angle clamp.
   d. Make sure the external branch of the SLN is not within the pedicle.
   e. Use the ultrasonic device to ligate the superior vascular pedicle (Fig. 78.2).
      1) Ligating the superior pole close to the thyroid helps decrease the risk of SLN injury
      2) Cauterize the pedicle at two to three areas before transecting the pedicle to ensure hemostasis.

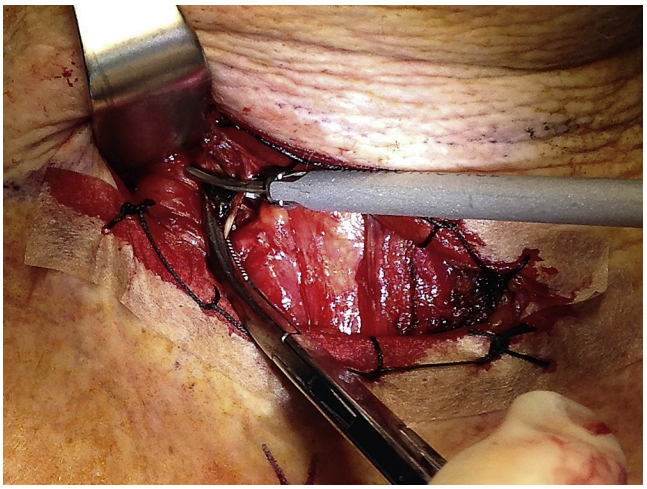

Fig. 78.3. The superior vascular pedicle is ligated with an ultrasonic scalpel close to the superior pole of the thyroid.

      3) The proximal stump will retract back into the neck, and bleeding from the stump can be difficult to control.
      4) Electrocautery, surgical clips or ties may also be used to augment superior pedicle ligation.
7. Mobilize the thyroid medially.
   a. Dissect the thyroid carefully inferiorly and medially using a peanut sponge.
   b. The thyroid can be retracted with Babcock clamps for relatively atraumatic grasping.
   c. The middle thyroid veins are encountered and ligated with the ultrasound scalpel.
8. Identify the RLN.
   a. Rotate the thyroid gland medially.
   b. Using the McCabe dissector, dissect near the cricothyroid joint and the tracheoesophageal groove to identify the RLN.
      1) Do not close the clamp when the tips are buried in tissue.
      2) Once the RLN is identified, dissecting parallel and directly on the nerve sheath prevents damaging the nerve and its branches (Fig. 78.3).
      3) Trace the RLN from the paratracheal region up to the cricothyroid muscle, being careful not to damage either the anterior or posterior branch.
   c. Once the RLN has been identified, transect Berry's ligament with the ultrasonic device.
      1) Take care to protect the RLN by retracting it gently with a peanut sponge to avoid heat from the ultrasonic blades and heated fluids generated from cautery.
      2) Sometimes a small cuff of thyroid tissue may have to be left behind to prevent injury to the RLN.
   d. Carefully dissect and lateralize the parathyroid glands with their blood supply when dissecting the thyroid capsule.
      1) The parathyroids usually receive their blood supply from the inferior thyroid arteries, but the superior parathyroids may derive their arterial supply from the superior thyroid artery.
      2) Auto-transplant any parathyroid glands that have been devascularized immediately.
         a) Send a biopsy for frozen pathology to confirm normal parathyroid tissue.
      3) Finely mince the parathyroid gland before re-implantation.

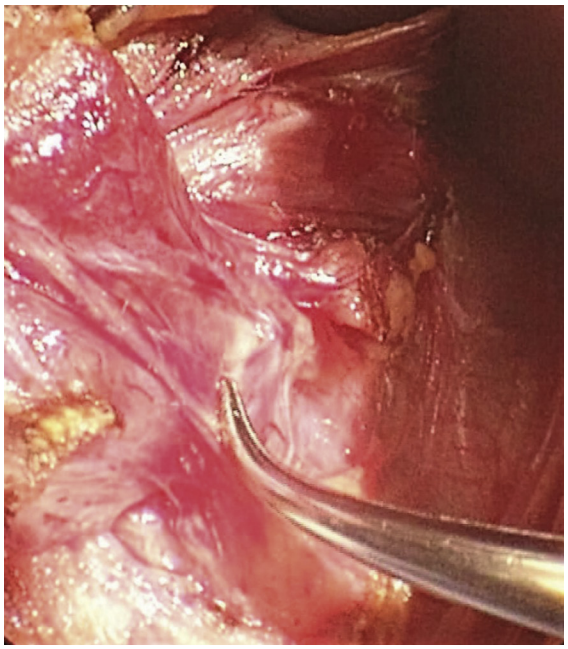

Fig. 78.4. The recurrent laryngeal nerve is found and dissected along its pathway immediately on top of the nerve with a McCabe dissector.

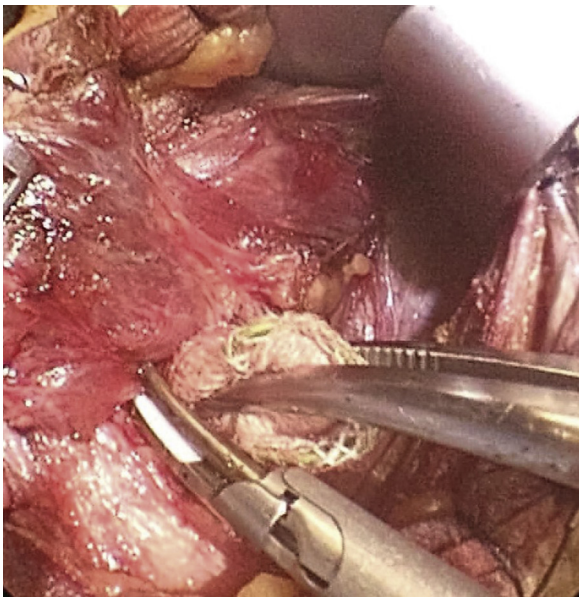

Fig. 78.5. The thyroid lobe is dissected off the trachea with an ultrasonic scalpel, while the recurrent laryngeal nerve is protected with a peanut sponge.

        4) Implant in muscle pockets of the ipsilateral strap or sternocleidomastoid muscle.
    e. Do not suction near the RLN or on the parathyroid glands.
9. Deliver the thyroid lobe and ligate the inferior pole.
    a. Once the RLN and the inferior parathyroid gland have been safely identified, ligate the inferior vascular pedicle while the thyroid is mobilized medially.
        1) Make sure to identify early branching of the RLN near the inferior pedicle before ligating the pedicle.
        2) Ligate the inferior pedicle close to the thyroid to avoid devascularizing the inferior parathyroid.
    b. Using the ultrasonic device, dissect the thyroid off of the trachea along the pretracheal fascia.
        1) Keep the active blade of the ultrasonic device away from the trachea.
        2) Protect the recurrent nerve with a moistened peanut (Fig. 78.4).
    c. Transect the thyroid at the junction of the isthmus and the contralateral lobe.
    d. Remove the pyramidal lobe if present, up to the thyroid notch.
10. Achieve hemostasis
    a. Irrigate the wound thoroughly, and evaluate bleeding during Valsalva by anesthesia with bipolar cautery hemostasis.
    b. Hemostatic agents such as Surgicel may contribute.
    c. A drain is not typically used.
11. Wound closure
    a. The strap muscles are approximated with absorbable sutures (3-0 vicryl).
        1) Leave a space inferiorly to allow drainage of potential hematomas.
    b. Approximate the platysma layer carefully.
    c. Close the skin with absorbable subcuticular stitches (4-0 monocryl).
    d. Dress the skin with an adhesive such as Mastisol and apply Steri-Strips.

Total Thyroidectomy

1. The contralateral side is removed in the same manner as the previously described lobectomy.
2. It is especially important to prevent excessive manipulation of the parathyroid glands to prevent temporary calcium imbalance after total thyroidectomy.
3. Carefully inspect and palpate the thyroid bed and surrounding areas for irregular lymph nodes, possible residual thyroid tissue, or other suspicious lesions, and send to the pathology department.
4. If cartilage invasion is present, shave resection may suffice but is not preferred.
    a. Shave resection is defined as removal of all macroscopic disease without formal resection of the full thickness of the adherent trachea or larynx.
    b. There is no survival benefit with extensive resection versus shave resection; however, the recurrence rate is decreased with en bloc resection.
5. Management of the neck in differentiated thyroid cancer
    a. Remove central compartment (level VI) nodes if there were suspicious nodes on preoperative imaging or intraoperative exploration.
    b. Perform a selective or modified radical neck dissection for metastatic lateral neck lymph nodes after biopsy proven metastasis is identified.
    c. Elective neck dissection is not indicated.
    d. Do not "berry pick" individual nodes.

Common Errors in Technique

1. Failure to skeletonize the superior pole before ligation, risking injury to the superior laryngeal nerve
2. Failure to identify the RLN, its pathway, and both branches (Fig. 78.5)
3. Not dissecting directly on top of the RLN when following its course

4. Transecting vasculature to the parathyroid glands
5. Inadequate hemostasis throughout surgery puts nerves and parathyroids at risk.
6. Overstretching and burning the skin edges with hot instruments

POSTOPERATIVE PERIOD

Postoperative Management

1. Check serum parathyroid hormone (PTH) after 1 hour in the recovery unit for total or completion thyroidectomy.
   a. Implement overnight observation if PTH is less than 15 pg/mL.
   b. Serum calcium may take more than 12 hours to stabilize with a change in PTH.
2. Pain medications: Ibuprofen or acetaminophen with narcotics for breakthrough
3. Wound care
   a. Neck incision may be wet after 48 hours.
   b. Examine the patient in 1 week and replace Steri-Strips to prevent scar formation.
4. Thyroid replacement medication is necessary if total thyroidectomy is performed.
   a. Thyroid hormone withdrawal for RAI treatment
   b. May start liothyronine and stop 2 weeks prior to RAI
5. RAI therapy will be dependent on the pathology of the tumor and presence of metastasis.

Complications

1. Hematoma
   a. Usually detected within 2 hours of surgery
      1) Dyspnea
      2) Dysphagia
      3) Expanding mass
   b. Immediately open incision and suction out blood and clots to prevent airway obstruction and prevent the patient's death.
   c. Take the patient back to the operating room to explore the wound and achieve hemostasis.
2. RLN injury
   a. Hoarseness and a weak voice with the vocal cord in the paramedian position
   b. The patient may aspirate.
   c. Intraoperative transection may require immediate reanastomosis, which may provide tone and decrease vocal cord atrophy.
   d. Consider early vocal cord medialization for known transection.
   e. Bilateral RLN injury will result in airway distress and stridor after extubation, and may necessitate re-intubation and tracheostomy (Fig. 78.6).
3. SLN injury
   a. Results in difficulty projecting voice or poor pitch control in high frequencies
   b. Voice therapy may be helpful.
4. Hypoparathyroidism
   a. Risk with total or completion thyroidectomy or patients previously operated for hyperparathyroidism
   b. The patient may need oral calcium carbonate and vitamin D supplementation temporarily or for life.
   c. Treat severe symptoms with IV calcium gluconate.
   d. Implement cardiac monitoring in cases of severe hypocalcemia.

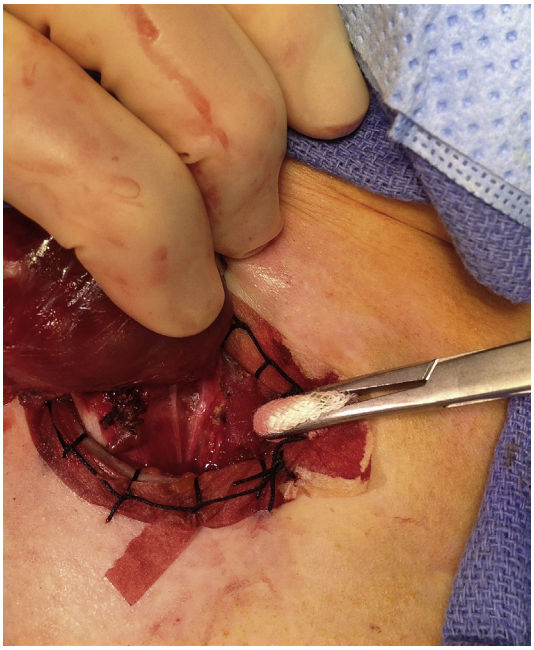

Fig. 78.6. Following the recurrent laryngeal nerve pathway led to identification of two branches, both of which must be traced and protected before dissecting the thyroid off the trachea.

Alternative Management Plan

1. Endoscopic or robotic thyroid surgery
2. Low risk nodules may be observed with serial US exams every 6 to 12 months
3. Chemotherapy and/or radiation for anaplastic thyroid cancer

DISCUSSION

Evidence-Based Medicine Question: What is the role of prophylactic central neck dissection (CND) in thyroidectomy?

A meta-analysis in 2010 of 1264 patients comparing thyroidectomy versus thyroidectomy with CND showed no difference in central or lateral neck recurrence, and a retrospective study of 266 patients in 2009 showed no advantage in disease-free survival in patients undergoing prophylactic N0 CND. A meta-analysis in 2009 of 1132 patients showed an increased risk of temporary hypocalcemia in those undergoing CND, but not of temporary or permanent vocal cord paralysis. Another large retrospective study found increased temporary and permanent hypoparathyroidism in those undergoing CND. At this time, prophylactic CND is likely not indicated and may cause significantly increased morbidity, except possibly in T3 or T4 disease or if there are involved lateral neck nodes.

Editorial Comment

Thyroidectomy has evolved over the last 150 years to become a safe and reproducible treatment for many thyroid problems. While complications are still a risk, these can be minimized by adherence to standardized principles of hemostasis, preservation of the parathyroids, and identification of the recurrent laryngeal nerves. Most patients can expect to safely undergo outpatient surgery with minimal cosmetic sequelae.

Alfred Simental, Jr.

Access the review questions and additional sources list online at http://www.expertconsult.com

REFERENCES

1. Haugen BR, Alexander EK, Bible KC, et al. 2015 American Thyroid Association Management Guidelines for Adult Patients with Thyroid Nodules and Differentiated Thyroid Cancer: The American Thyroid Association Guidelines Task Force on Thyroid Nodules and Differentiated Thyroid Cancer. Thyroid 2016;26(1):1–133.
2. Cibas ES, Ali SZ. The Bethesda system for reporting thyroid cytopathology. Am J Clin Pathol 2009;132(5):658–665.
3. Ferris RL, Baloch ZW, Bernet V, et al. American Thyroid Association Statement on Surgical Application of Molecular Profiling for Thyroid Nodules: current impact on perioperative decision-making. Thyroid 2015;25(7):760–768.
4. Fancy T, Gallagher D, Hornig JD. Surgical anatomy of the thyroid and parathyroid glands. Otolaryngol Clin North Am 2010;43(2):221–227.
5. Higgins TS, Gupta R, Ketcham AS, et al. Recurrent laryngeal nerve monitoring versus identification alone on post-thyroidectomy true vocal fold palsy: a meta-analysis. Laryngoscope 2011;121(5):1009–1017.

REVIEW QUESTIONS

1. Landmarks for the RLN include all of the following except
   a. The inferior thyroid artery
   b. Berry's ligament
   c. The tubercle of Zukerkandl
   d. The superior parathyroid gland

2. Which of the following is not a direct complication of thyroid surgery?
   a. Tracheocutaneous fistula
   b. Hypercalcemia
   c. Carotid artery injury
   d. SLN damage

3. Which of the following is not an indication for total thyroidectomy?
   a. A 2 cm benign thyroid nodule found during pregnancy
   b. A 3 cm isolated papillary thyroid carcinoma
   c. A 1.7 cm thyroid nodule containing malignancy in a 60-year-old female
   d. A 0.5 cm thyroid nodule containing medullary thyroid carcinoma

ADDITIONAL SOURCES

Kloos RT, Eng C, Evans DB, et al. Medullary thyroid cancer: management guidelines of the American Thyroid Association. Thyroid 2009;19(6):565–612.

Nixon IJ, Ganly I, Patel SG, et al. Observation of clinically negative central compartment lymph nodes in papillary thyroid carcinoma. Surgery 2013;154(6):1166–1173.

Stack BC, Ferris RL, Goldenberg D, et al. American Thyroid Association consensus review and statement regarding the anatomy, terminology, and rationale for lateral neck dissection in differentiated thyroid cancer. Thyroid 2012;22(5):501–508.

79 Minimally Invasive Video-Assisted Thyroidectomy

Robert L. Ferris, Meghan T. Turner

INTRODUCTION

Thyroid nodules are a common clinical problem, diagnosed by palpation on clinical examination in approximately 5% of women and 1% of men in Western society. Their presence requires evaluation to exclude thyroid cancer, the incidence of which is 15% in at-risk groups. In recent decades, the incidence of thyroid cancer has nearly tripled from 4.9 per 100,000 in 1975 to 14.3 per 100,000 in 2009. Today, it is currently the 10th most common cancer among men and women in the United States, according to the Centers for Disease Control. The National Cancer Institute's surveillance, epidemiology, and end results (SEER) Program estimates that there will be 62,450 new cases of thyroid cancer in 2015, accounting for 3.8% of all new cancer diagnoses but only 0.3% of all cancer deaths.[1] The increased incidence is partially attributed to the increasing use of high-resolution ultrasound in the evaluation of benign thyroid disease and solitary thyroid nodules as well as the discovery of "incidentalomas" on high-resolution computed tomography (CT), magnetic resonance imaging (MRI), and positron emission tomography (PET) scans performed for other indications.[1] In recent years, increasingly strict guidelines have been created to prevent overtreatment. There has also been a trend toward development of less invasive techniques in order to prevent morbidity in young patients with benign and low-risk papillary thyroid cancer (PTC).

In the 1990s, surgeons in Japan and Italy pioneered the development of endoscopic surgery for both benign and malignant thyroid pathology. This was driven by patient demand for either a smaller cervical scar or no scar, instead of the 8-cm incision originally described by Kocher.[2] Since the first minimally invasive approach, various techniques have been described in the literature (Table 79.1).

The technique now known as minimally invasive video-assisted thyroidectomy (MIVAT), which has demonstrated widely reproducible results, will be the focus of this chapter. First and best described by Miccoli[2] in 1999 for the treatment of benign thyroid disease, this technique has been expanded to include solitary nodules, low-to-intermediate risk malignancy, and central compartment neck metastases. Groups in the United States have tested its efficacy and safety, while expanding indications to include previous, relative contraindications such as patients with high body-mass index, thyroiditis, prior neck surgery, larger nodules, goiters, and completion lobectomies.[3-5]

KEY OPERATIVE LEARNING POINTS

- Careful patient selection is necessary for safe and expedient MIVAT surgery. Ideal candidates for MIVAT have nodules less than 3.5 cm and a thyroid gland volume less than 25 mL.
- Subplatysmal flaps are unnecessary and create dead space for seroma formation.
- Two assistants are needed: one to hold the retractors and expose the superior pole and tracheoesophageal groove and another to hold the endoscope during dissection of the superior pole, parathyroid glands, and the recurrent laryngeal nerve.
- Use of the harmonic scalpel for superior and inferior pole vessels can significantly reduce operative times.
- Conversion to open thyroidectomy (OT) should be performed for posterior nodules that prevent visualization of the recurrent laryngeal nerve (RLN), large glands that cannot be delivered through the incision, or excessive bleeding that prevents safe identification of the RLN.

PREOPERATIVE PERIOD

Ideal candidates for MIVAT include patients with asymptomatic solitary nodules or patients with low-to-intermediate risk well-differentiated thyroid cancer and account for about 10% of all patients referred for thyroidectomy.[6] Careful patient selection is necessary in the preoperative evaluation for MIVAT, especially for the novice surgeon. Clinical evaluation of any patient with a mass in the thyroid gland begins with a careful history and physical examination. The history, physical examination, and workup should help the surgeon exclude patients with the absolute and relative contraindications to this surgical technique, according to the surgeon skill set.

History

- History of present illness
  - Presentation: How and when was the thyroid nodule discovered?
  - Has it been biopsied under ultrasound?
  - Does the patient have any symptoms of hyper- or hypothyroidism?
  - Does the patient have hoarseness, dyspnea, dysphagia, or aspiration?
  - Has the patient noticed any masses in his or her neck?
  - Has the patient noticed progressively enlarging nodules?
- Past medical history
  - Has the patient been diagnosed with hyper- or hypothyroidism?
  - Does he or she have other autoimmune disease, such as Grave's disease or acute Hashimoto's thyroiditis?
  - Has the patient had prior radiation of the head and neck?
  - Has the patient been exposed to ionizing radiation?
  - Does the patient have a history of previous cardiac stent, deep vein thrombosis, or pulmonary embolization requiring anticoagulation or antiplatelet therapy?
  - Is the patient pregnant?

TABLE 79.1 Minimally Invasive and Endoscopic Thyroidectomy Techniques

Minimally invasive—mini-incision
Video-assisted transcervical endoscopic
Completely closed endoscopic
Transcervical approach
Axillary approach
Anterior chest approach
Breast approach

- Past surgical history
  - Has the patient had any previous thyroid surgery or parathyroid surgery?
  - Has the patient had other prior neck surgery?
- Family history
  - Is there a family history of thyroid cancer or cancer-related syndrome?
  - Is there a family history of thyroid disease?
  - Is there a presence of familial bleeding disorders?
  - Is there a family history of hyperthermia or acetylcholinesterase deficiency with any previous anesthesia?
- Medications
  - Is the patient taking thyroid hormone replacements?
  - Is the patient on antiplatelet therapy or anticoagulation?

Physical Examination

- Voice
  - Assess the quality of voice; is it coarse or breathy?
- Breathing
  - Does the patient have stridor?
- Thyroid gland
  - Assess the size of the nodule and its mobility on swallowing.
  - Assess the mobility of the overlying tissues.
- Neck
  - Palpate deeply to detect any cervical lymphadenopathy that would suggest metastatic disease, as this would be a contraindication to MIVAT and would require OT with neck dissection.
  - Examine the neck in extension in order to detect any substernal extension that might require OT.
- Flexible laryngoscopy
  - Preoperative paresis or paralysis suggests invasive cancer that should be treated with open techniques.
  - Identification of contralateral paralysis is also crucial in patients who are to undergo completion lobectomy.

Imaging

- Ultrasound and ultrasound-guided fine-needle aspiration biopsy (US-FNAB)
- Ultrasound can detect additional suspicious nodules (solid or hypoechoic nodules with irregular margins, microcalcifications, and/or taller than wide shape, as well as evidence of soft tissue invasion or extrathyroidal extension), hypervascularity associated with thyroiditis, large thyroid volume, or substernal extension that may contraindicate MIVAT.[7]
- Ultrasonography of the neck to evaluate lateral lymph nodes for cervical metastases is indicated for all patients being considered for MIVAT. Those patients with lateral metastases should have OT and selective neck dissection.[2,8]
- CT/MRI neck
  - Patients are often referred for evaluation of a thyroid nodule after incidental discovery on other imaging. For those cases where CT or MRI leads to detection of the nodule, no further imaging of the neck is necessary to look for metastatic cancer.
- PET/CT
  - The incidence of focally, fluorodeoxyglucose-avid (FDG-avid) thyroid nodules on PET-CT performed for other means is 1% to 2%. Because there is a 35% risk of cancer in such cases, hemi-thyroidectomy is indicated for pathologic tissue analysis.[7]

Indications

The main indications for MIVAT in the literature include benign lesions, indeterminate nodules, and low-risk papillary thyroid carcinoma.[3-5,8]

- Small thyroid nodules (25 to 30 mm in diameter)
- Thyroid gland volume (about 20 cm^3)
- No evidence of acute thyroiditis
- Specific groups
  - Children
    - Thyroid masses in children are most commonly well-differentiated papillary thyroid carcinoma (WDPTC) and medullary thyroid carcinoma (MTC).
    - Fine-needle aspiration biopsy (FNAB)–proven, WDPTC is an indication for MIVAT.
    - FNAB-proven MTC is a relative contraindication, as the patient requires total thyroidectomy with central compartment and possible lateral neck dissections. Prophylactic treatment of pediatric patients with familial disease and positive RET (rearranged during transfection) proto-oncogene testing, who display no evidence of thyroid nodules or neck metastases on exam or imaging, can be treated by MIVAT alone in experienced hands.[8] An advantage of MIVAT in these two patient populations is the significant reduction in postoperative pain, as compared with standard thyroidectomy.
  - Patients with a history of exposure to ionizing radiation
    - Patient's with occupational or environmental radiation exposures are considered to be in the high-risk category and are more likely to have multifocal cancer requiring total thyroidectomy. A third of abnormalities in the thyroid gland in patients with a history of radiotherapy will be malignant.[7] These patients are perfect candidates for MIVAT.
    - Patients with a history of therapeutic head and neck radiation should undergo OT, as the radiation creates scarring, radiation changes and an adverse surgical field with increased risk for bleeding.
  - Geriatric patients
    - This group can undergo MIVAT safely with low morbidity, as with younger patients. However, MIVAT has been shown to require longer anesthesia times as compared with conventional techniques in inexperienced hands.[6,9] Therefore only experienced surgeons, with comparable operative times to conventional open approaches, should offer MIVAT for patients in the geriatric age group.[6]

Contraindications

As centers have become more facile with MIVAT, the indications have expanded and the contraindications have been revised. For example, many groups have proven that larger nodules, nodules in patients with Hashimoto's thyroiditis, Grave's disease, prior neck surgery (as in completion thyroidectomy), and central compartment lymph node metastases requiring central neck dissection are no longer contraindications, but should still remain relative contraindications in less than experienced hands.[3,4,8]

- Absolute contraindications include thyroid disease requiring OT.
  - Large multinodular goiters
  - Substernal thyroid nodules or goiters
  - Revision thyroidectomy
  - Prior ipsilateral neck surgery or external beam radiation to the neck

- Biopsy proven MTC
- Presence of lateral lymph node metastases

- Relative contraindications include conditions that would make minimally invasive approaches more difficult and therefore increase morbidity.
  - Active thyroiditis
  - Grave's disease
  - Adverse anatomic aspects (short neck in the obese patient)
  - Nodules greater than 4 cm
  - Completion thyroidectomy
  - Central compartment metastases

Preoperative Preparation

- Thyroid function tests
  - Preoperative thyroid-stimulating hormone (TSH) levels with reflexive triiodothyronine (T_3) and thyroxine (T_4) testing to ensure the euthyroid state and avoid thyroid storm.
  - Subnormal TSH levels require a radioactive iodine scan to diagnose a possible benign hyperfunctioning adenoma that can be medically treated.
- Serum thyroglobulin
  - Thyroglobulin levels are not routinely indicated in the preoperative workup of nodules and low-risk cancer, as they can be elevated in many types of thyroid disease.
- Antibodies
  - Antithyroglobulin antibody, antithyroid peroxidase antibody, and thyroid stimulating immunoglobulin can rule in or rule out thyroiditis, which is a relative contraindication to MIVAT. This may be particularly helpful to the novice surgeon and discourage his or her use of MIVAT, due to the higher likelihood of intraoperative bleeding and less favorable conditions for identification and preservation of the RLNs and parathyroid glands.
- FNAB
  - FNAB should be performed on thyroid nodules greater than 1 cm and suspicious cervical lymph nodes and sent for cytologic analysis according to the Bethesda Guidelines for Cytologic Evaluation and Reporting.[7]
  - FNAB may diagnose atypia, a follicular lesion, or a Hürthle cell lesion, in which case one might perform a minimally invasive thyroid lobectomy for diagnosis and risk stratification.
- Molecular testing
  - Testing for various mutations known to be associated with a high-risk of malignancy has been performed on FNAB specimens, allowing surgeons to be more selective about performing diagnostic lobectomy for Bethesda III and IV lesions using minimally invasive techniques.

OPERATIVE PERIOD

Anesthesia

- MIVAT is usually performed with the patient under general anesthesia. MIVAT has been described under local anesthesia, employing bilateral cervical plexus blocks.[2]
- Careful preoperative planning with the anesthesia team is required. Only short-acting paralytic agents should be administered if the surgeon intends to use intraoperative nerve monitoring (IONM).
- For those cases where IONM is being employed, intubation should be carried out with the GlideScope or followed by direct laryngoscopy so that the surgeon can observe proper placement of the endotracheal electrodes in the larynx.

Positioning

- The patient is placed in supine position and centered on the table.
- Arms should be tucked at the patient sides, with care to protect the ulnar nerves.
- The head is positioned at the very top of the table and stabilized with a donut cushion.
- A shoulder roll facilitates exposure of the gland in patients with a short neck, but it is sometimes not necessary.
- Excessive neck extension should be avoided.
- Ventilation tubing extensions are required so that the table may be moved away from the anesthesia team and allow for the positioning of the endoscopic video tower and slave monitor at the patient's head, where the surgeon and endoscopist can easily see them (Fig. 79.1).

Perioperative Antibiotic Prophylaxis

- Thyroidectomy is considered "clean head and neck surgery." Thus perioperative antibiotics are not required.
- Administration of one dose prior to surgery for coverage of skin flora is acceptable. The most common choice is a

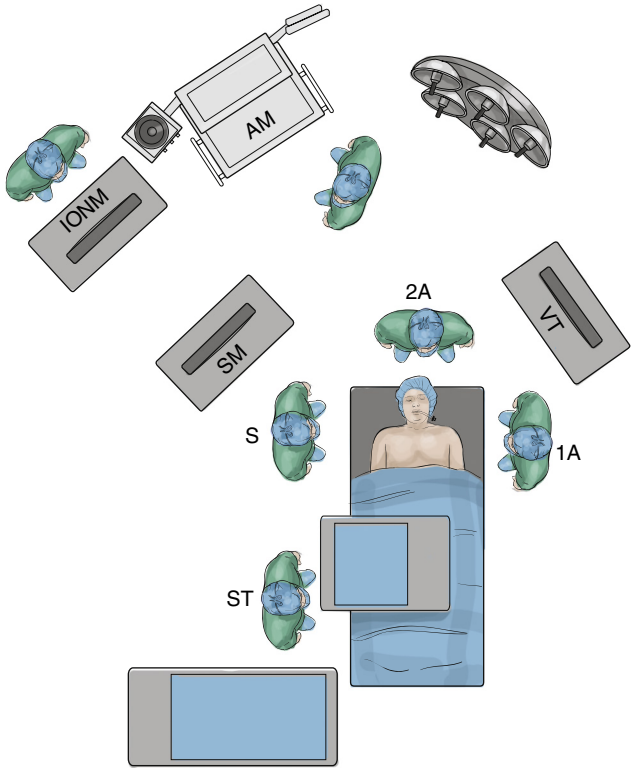

Fig. 79.1. Operating room setup plays an important role in minimally invasive video-assisted thyroidectomy. The surgical team needs adequate room for the surgeon, two assistants, a video tower, and a slave monitor. This requires adequate distance from the anesthesia monitor and team, with the use of ventilation tube extensions. It also involves positioning of nerve monitoring equipment. *AM,* Anesthesia machine; *IONM,* intraoperative nerve monitoring system; *SM,* slave monitor; *ST,* surgical tech; *S,* surgeon; *VT,* videotower; *1A,* first assistant/endoscopist; *2A,* second assistant.

first-generation cephalosporin or clindamycin, for those with penicillin allergy that may have cross-sensitivity to cephalosporins.

Monitoring

- Intraoperative nerve monitoring (IONM) of the RLN is routinely used by many groups.[3-5,8]
- Endotracheal tube electrodes are placed in contact with the mid vocal folds bilaterally under direct vision by the surgeon.
- The nerve is stimulated when identified to confirm identification and integrity.
- It is then stimulated after lobectomy.

Detectable responses after direct stimulation of the RLN confirm that the nerve is intact and functional after lobectomy. Loss of response after lobectomy may indicate injury or neuropraxia in an intact nerve and may direct immediate management, allowing the surgeon to abort a total thyroidectomy in favor of completion thyroidectomy when nerve function returns.

Instruments and Equipment to Have Available

- Standard neck dissection/thyroid set
- Endoscopic video tower and slave monitor
- 5-mm 30-degree endoscope
- Endosurgery harmonic scalpel
- Bipolar forceps and cautery
- Intraoperative nerve monitoring system and nerve stimulator

Key Anatomic Landmarks

- Same as for conventional OT. See Chapter 102.

Prerequisite Skills

- Same as for conventional OT. See Chapter 102.
  - Some groups have described the need for conversion to OT in those cases where unexpected bleeding is encountered, in cases of substernal goiter, or when the RLN cannot be identified prior to removal of the lobe.
  - A recent systematic review of randomized controlled trials looking at MIVAT versus OT found the conversion rate to be 3.4%.[9] This number varies with the experience of the surgeon, the selection criteria, and the difficulty of the case being attempted.
- Central compartment neck dissection (CND)
  - Suspicious central compartment nodes appreciated by the surgeon at the time of surgery or thyroid cancers with high risk of central neck metastases (such as follicular variant) may require elective central neck dissection. Several groups have shown that this can be safely performed with MIVAT.[3,4,8]

Surgical Technique

Minimally Invasive Video-Assisted Thyroidectomy

- The incision is designed in a line of relaxed skin tension (Fig. 79.2). The best time to plan the incision is in the preoperative area while the patient is in the upright, sitting position with the neck in neutral position.[5] In a patient who has a long, slender neck, the incision must be placed somewhat more superior to be able to achieve adequate exposure. The incision should ideally be 2 to 3 cm.[3]
- Surgeons performing total thyroidectomy should begin the operation on the side of the biopsy-proven cancer or suspicious nodule to ensure removal of the suspected malignancy should the case need to be aborted after lobectomy. The surgeon should then switch sides for removal of the contralateral lobe.

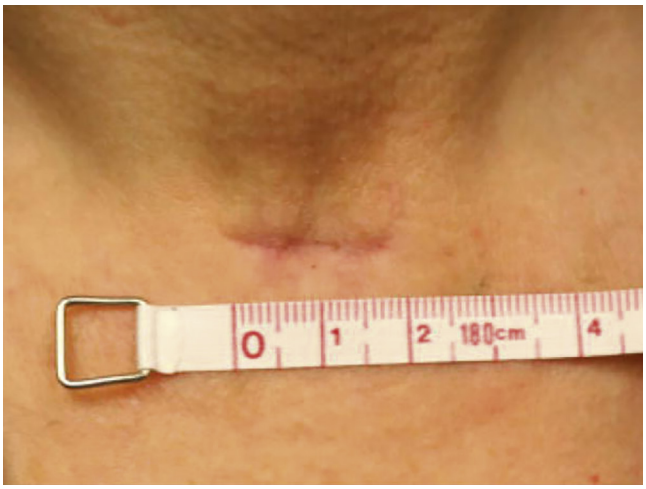

Fig. 79.2. Postoperative incision site following minimally invasive video-assisted thyroidectomy procedure. The incision has reverted to the 2.0-cm initial length approximately 1 month after minimally invasive video-assisted thyroidectomy. *(From Lai ST, Walvekar RR, Ferris RL: Minimally invasive video-assisted thyroidectomy: Expanded indication and oncologic completeness. Head Neck 30(11):1403-1407, 2008.)*

- The incision may be made with a cutting instrument, whether a cold knife, electrocautery, or a Shaw scalpel. The incision is carried down through the platysma muscle, avoiding injury to the anterior jugular veins.
- Subplatysmal flaps are intentionally avoided during MIVAT, as this does not increase exposure and increases the risk of seroma.
- The median raphe of the strap muscles is then opened widely, from approximately 2 to 3 cm above the cricoid and inferiorly below the gland.
- The thyroid gland is then mobilized from the strap muscles and carotid sheath with meticulous blunt dissection and careful hemostasis, using retractors (Army-Navy, Terris retractors, or Micolli retractors) and Kitner sponges on a Kelley clamp.
- The superior pole is then isolated with retraction inferiorly and blunt dissection. A Babcock clamp helps with this maneuver.
- The 30-degree endoscope is introduced into the wound, visualizing the superior pole. The external branch of the superior laryngeal nerve (SLN) can be identified with endoscopy and preserved with gentle upward retraction and by ligating the superior pole vessels as they enter the superior pole (Fig. 79.3).
- The harmonic scalpel is used to ligate vessels at 12 o'clock, 10 o'clock, and 2 o'clock positions, ensuring safe and expeditious control of the blood supply of the thyroid gland.[10]
- The thyroid gland is then delivered through the wound and retracted medially using blunt Sen retractors.
- The endoscope is kept in the operative field and aids in identification and preservation of the parathyroid glands in their adipose tissue pads near the tubercle of Zuckerkandl and the inferior thyroid artery (see Fig. 79.3). Once the adipose tissue pads are dropped laterally, the RLN is identified and preserved.
- Once the nerve is exposed, wet sponges and Kitners should be used for hemostasis to prevent retraction injury and trauma to the nerve.
- The branches of the inferior thyroid artery should be identified and ligated as they enter the gland just medial to the

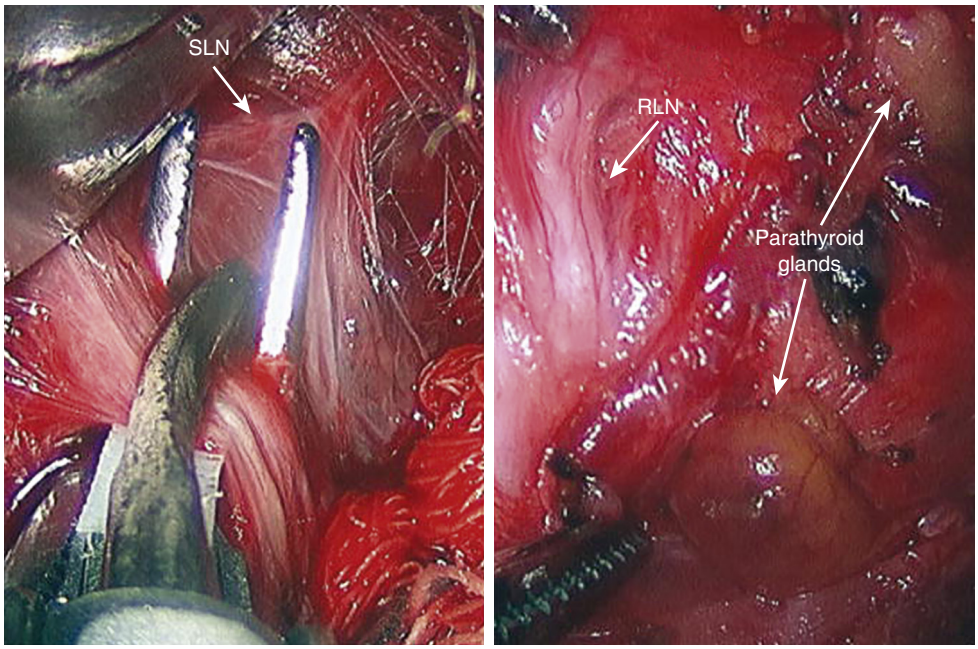

Fig. 79.3. Improved visualization of critical anatomic structures. Minimally invasive video-assisted thyroidectomy permits excellent intraoperative visualization of the superior laryngeal nerve *(SLN; left panel)*, as well as the recurrent laryngeal nerve (RLN) and parathyroid glands *(right panel)*. *(From Lai ST, Walvekar RR, Ferris RL: Minimally invasive video-assisted thyroidectomy: Expanded indication and oncologic completeness. Head Neck 30(11):1403-1407, 2008.)*

parathyroid glands, either with bipolar cautery or clips. Great care is taken to identify and visualize the course of the RLN prior to ligation. Small bleeding vessels around the nerve should be controlled using patience, pressure, and precise bipolar cautery, so as not to injure the nerve.

- The RLN should be dissected until it enters the larynx and is freed from the thyroid lobe. Berry's ligament can then be exposed and transected. This is first done sharply with tenotomy scissors in order to prevent thermal injury to the RLN. Then monopolar cautery can be used to dissect the lobe and isthmus from the trachea.
- The isthmus can either be divided with the harmonic scalpel or left intact while the surgeon proceeds with mobilization of the contralateral lobe in cases of total thyroidectomy via MIVAT.
- The specimen is appropriately marked and sent to pathology. All bleeding points are controlled, and the wound is irrigated. Surgicel is placed within the wound.
- Gelfoam is placed in the tracheoesophageal groove to protect the parathyroid glands and RLN during closure.
- The strap muscles are then loosely approximated in the midline with 3-0 Vicryl suture. The platysma is also reapproximated with 3-0 Vicryl suture. The dermis is then reapproximated using undyed 4-0 Vicryl, and the skin is closed with a 4-0 monofilament suture in running subcuticular fashion. Finally, adhesive and Steri-Strips are applied to the skin.

Common Errors in Technique

- An unsightly scar may result from a poorly designed incision that is not in a relaxed skin tension line or those that lie too low over the clavicles.
- Raising subplatysmal flaps creates more dead space, puts patients at risk for postoperative seroma, and may require postoperative drain placement.
- Failure to identify the RLNs may lead to inadvertent transection.
- Failure to identify and preserve the parathyroid glands on at least one side may result in hypoparathyroidism and hypocalcemia.
- Failure to maintain a bloodless field can result in difficult visualization and possible injury to the RLNs and parathyroid glands.

POSTOPERATIVE PERIOD

Postoperative Management

- Postoperative care is best undertaken by nurses experienced with thyroidectomy patients, because of the potential for airway complications and postoperative hypocalcemia.
- Patients who have undergone a lobectomy are regularly discharged the same day after a short period of observation.
- Patients who are undergoing completion lobectomy or total thyroidectomy may need to stay for calcium monitoring. Serial serum calcium levels are used to help guide postoperative calcium supplementation. Most patients are discharged by postoperative day 1 when calcium levels stabilize and require some level of calcium and vitamin D supplementation. Patients with symptomatic hypocalcemia are supplemented with additional doses. Those that resolve with immediate oral calcium are managed expectantly. Those that do not are asked to come to the ER for measurement of serum calcium levels and are treated accordingly.
- Hypothyroidism after total thyroidectomy is managed with hormone replacement. Levothyroxine sodium or liothyronine may be initiated in the immediate postoperative period, depending on the pathology report.
- ^{131}I scanning can be used postoperatively to determine the completeness of the surgical procedure and to detect residual or metastatic cancer. Small foci of residual cancer or occult distant metastasis can be adequately treated with therapeutic doses of radioactive iodine. Patients with thyroid carcinoma treated by MIVAT can be expected to have similar radioactive iodine scanning results as those treated by OT.[3] Postoperative thyroglobulin levels are also similar among patients with well-differentiated thyroid cancer (WDTC) treated by MIVAT and conventional OT and can thus still be used for surveillance in patients with WDTC who have elevated serum thyroglobulin preoperatively.[3]

COMPLICATIONS

- Prominent or hypertrophic scarring
  - A low incision, planned when the patient is in the extended position, may come to rest over the clavicles. This may produce a stretched or prominent scar that can be disguised only by clothing or jewelry.

- Hematoma
  - This complication is rare after both OT and MIVAT. A recent meta-analysis of randomized controlled trials comparing outcomes following OT and MIVAT found no difference in the rate of postoperative hematoma between groups. Similarly, the rate of postoperative hematoma was not increased in any of, and was not seen in any of the large tertiary care cancer centers looking at expanded indications for MIVAT.[3-5,9]
  - I Hematoma is generally detected in the first few hours after surgery and presents as a mass in the anterior neck, sometimes with overlying ecchymosis, bleeding from the incision, and loss of palpable landmarks (including cricoid and sternal notch). As it expands, the patient may develop hoarseness or stridor and finally experience respiratory distress.
  - Circumferential neck dressings are forbidden, as they prevent nurses and physicians from recognizing potential cervical hematoma. A constricting dressing in the presence of an expanding hematoma places the patient on a "death trajectory" from compression of the airway.
  - Hematoma s occur because of insufficient hemostasis at the time of surgery. All patients should be observed in the post-anesthesia care unit (PACU) for several hours prior to discharge in order to allow for prompt return to the operating room if a hematoma develops.
- Nerve injury
  - The external branch of the SLNs and the RLNs is vulnerable to injury during MIVAT.
  - In a systematic review of randomized controlled trials comparing MIVAT and OT, there were no reported injuries to the external branch of the SLN in those undergoing MIVAT, while 2% of patients incurred this injury following OT.[9]
  - Current rates of temporary and permanent injury to the RLN reported in the literature are comparable to that reported after OT. Transient injury rates range from 4.8% to 17%, being higher in studies in which routine postoperative laryngoscopy was performed in the PACU.[3,4] Permanent injury rates, defined as recurrent nerve dysfunction lasting longer than 6 months, are reportedly low, ranging from 0% to 1.9% in single institution studies[3-5] and 0.3% in a systematic review.[9] Unilateral recurrent nerve paralysis is often asymptomatic in the immediate postoperative period and not often symptomatic until postoperative day 2 or 3. Patients suspected of injury to the nerve should have indirect laryngoscopy performed either in the PACU or at the first postoperative visit to confirm the presence of vocal cord paresis/paralysis.[5] To date, no case of bilateral cord paralysis following MIVAT has been reported.
- Hypoparathyroidism
  - The rate of this complication is not reported to be significantly different between groups following MIVAT or OT, reported as 4.1% and 3.7%, respectively.[9] If thyroid lobectomy has been carried out, no further testing is done in the postoperative period unless the patient has previously undergone thyroid surgery. We implement oral calcium and vitamin D supplementation on all patients undergoing a total or completion thyroidectomy. Serum magnesium is drawn and repleted as necessary, since it is a cofactor for the functional parathyroid hormone (PTH). Serum calcium levels are measured repeatedly on the first and second postoperative days in order to prescribe tailored supplementation based on serum calcium levels.

Alternative Management Plan

- Operative
  - Conversion to OT for hemorrhage or inability to identify the RLN
- Postoperative care
  - Patients undergoing total thyroidectomy may be observed as described with serial calcium levels.
  - Alternatively, patients may be discharged with a planned, postoperative calcium taper without measurement of calcium levels, unless the patient develops symptoms of hypocalcemia that are not treated with additional oral calcium.
  - Postoperative PTH levels can also be drawn after surgery to guide postoperative calcium management. PTH levels less than 10 pg/dL may predict transient hypocalcemia, require overnight observation, and the addition of calcitriol to the postoperative calcium regimen.
- Observation with serial imaging for medically fragile patients
- Radioactive Iodine therapy, external beam radiation or tyrosine kinase inhibitors for unresectable thyroid cancer

DISCUSSION

Evidence-Based Medicine Question

What is the role of elective central CND in MIVAT?

For patients undergoing MIVAT, management of the neck is limited to central CND. Originally central neck metastases were a contraindication to MIVAT but now are merely a relative contraindication. Several groups have proven the safety and efficacy of CND through the MIVAT technique.[3,4,8] Despite the fact that in multivariate analyses cervical lymph node metastasis has no prognostic importance in dealing with papillary carcinoma of the thyroid, we are recognizing neck recurrence more frequently with modern imaging. The question then becomes, "How necessary is central neck dissection?" More recent philosophy suggests that paratracheal (level VI) lymph node dissection should be carried out at the time of thyroidectomy. However, in some reports, CND resulted in higher rates of transient and permanent postoperative hypocalcemia. More data should be collected about the safety and efficacy of CND via MIVAT.

Editorial Comment

Advances in imaging and laboratory testing result in increasing numbers of patients requiring thyroid surgery for low-risk cancer. Fortunately, advances in hemostasis, anesthesia, and medical optics have provided the opportunity for less invasive surgical techniques in thyroid surgery. MIVAT appears to offer equal efficacy in treating low-risk cancer, while simultaneously decreasing postoperative pain, bleeding, and surgical scarring, and continuing to maintain minimal complications. Minimally invasive surgery has been widely sought by patients in general, and MIVAT has provided thyroid surgeons and patients an alternative to standard thyroidectomy. MIVAT appears to be easily learned and adopted by surgeons with prior experience in thyroid surgery.

Alfred Simental, Jr.

Access the review questions and additional sources list online at http://www.expertconsult.com

REFERENCES

1. National Institute of Health. National Cancer Institute. Surveillance, Epidemiology and End Results Program. Fact Sheet: Thyroid Cancer. Available at http://seer.cancer.gov/statfacts/html/thyro.html.
2. Miccoli P, Berti P, Conte M, et al. Minimally invasive thyroid surgery for thyroid small nodules: preliminary report. J Endocrinol Invest 1999;22:849–851.

3. Lai ST, Walvekar RR, Ferris RL. Minimally invasive video-assisted thyroidectomy: expanded indication and oncologic completeness. Head Neck 2008;30(11):1403–1407.
4. Kim AJ, Liu JC, Ganly I, et al. Minimally invasive video-assisted thyroidectomy 2.0: expanded indications in a tertiary care cancer center. Head Neck 2011;33(11):1557–1560.
5. Duke WS, White JR, Waller JL, et al. Six-year experience with endoscopic thyroidectomy: outcomes and safety profile. Ann Otol Rhinol Laryngol 2015;124(11):915–920.
6. Capponi MG, Belloti C, Lotti M, et al. Minimally invasive video-assisted thyroidectomy: ascending the learning curve. J Minim Access Surg 2015;11(2):119–122.
7. Haugen BR, Alexander BK, Bible KC, et al. 2015 American Thyroid Association Management Guidelines for Adult Patients for Thyroid Nodules and Differentiated Thyroid Cancer. Thyroid 2016;26:1–133. http://dx.doi.org/10.1089/thy.2015.0020.
8. Minuto MN, Berti P, Miccoli M, et al. Minimally invasive video-assisted thyroidectomy: an analysis of results and a revision of indications. Surg Endosc 2012;25:818–822.
9. Pisanu A, Podda M, Reccia I, et al. Systematic review with meta-analysis of prospective randomized trials comparing minimally invasive video-assisted thyroidectomy (MIVAT) and conventional thyroidectomy (CT). Langenbecks Arch Surg 2013;398:1057–1068.
10. Shemen L. Thyroidectomy using the harmonic scalpel: analysis of 105 consecutive cases. Otolaryngol Head Neck Surg 2002; 127:284–288.

REVIEW QUESTIONS

1. Which is not an absolute contraindication to MIVAT?
   a. Substernal goiter
   b. Thyroidectomy needed for focally avid thyroid nodule on PET-CT, performed for a laryngeal cancer treated with chemoradiotherapy
   c. Hashimoto's thyroiditis
   d. Revision lobectomy needed for substernal goiter

2. Which is an absolute contraindication for MIVAT?
   a. Medullary thyroid cancer with lateral cervical metastases
   b. RET-positive patient without thyroid nodules or abnormal lymph nodes needing only prophylactic thyroidectomy
   c. Thyroiditis
   d. Completion thyroidectomy

3. Which is the best candidate for MIVAT?
   a. A 30-year-old woman with Grave's disease, large goiter, and a suspicious thyroid nodule
   b. A 5-year-old patient with a family history of MTC, positive RET testing, and negative serologic studies, who needs only prophylactic thyroidectomy
   c. A patient with a 5-cm PTC
   d. A patient with prior high-dose neck radiation and a 2-cm nodule with suspicious features on ultrasound

4. What is the rate of conversion to OT for properly selected patients?
   a. 20%
   b. 10%
   c. 3% to 4%
   d. <1%

5. True or False: MIVAT and conventional OT provide similar results in terms of removal of thyroid tissue based on radioactive iodine scanning.
   a. True
   b. False

ADDITIONAL SOURCES

Nelson KL, Hinson AM, Lawson BR, et al. Postoperative calcium management in same-day discharge thyroid and parathyroid surgery. Otolaryngol Head Neck Surg 2016;154(5):854–860.

Singer MC, Bhakta D, Seybt MW, et al. Calcium management after thyroidectomy: a simple and cost-effective method. Otolaryngol Head Neck Surg 2015;146(3):362–365.

80 Robotic-Assisted Thyroidectomy

Chwee M. Lim, Umamahaeswar Duvvuri

INTRODUCTION

Open thyroidectomy incorporated a midline skin crease was first popularized by Kocher in 1906; since that time it has remained the standard surgical technique for thyroidectomy.[1] This approach provides the most direct route to the thyroid bed and offers complete visualization of the surgical field. Therefore it results in excellent, predictable, and reproducible clinical outcomes with consistent preservation of the parathyroid glands and recurrent laryngeal nerves (RLN).

Gaining access to the thyroid bed from a remote site was made possible with the recent development of the da Vinci robotic system (Intuitive Surgical Inc., Sunnyvale, California). There are two approaches to the thyroid bed during robotic thyroidectomy. The first approach accesses the thyroid bed from the lateral direction by entering the bed between the anterior border of the sternocleidomastoid muscle and the sternothyroid muscle. This is accomplished either by way of the transaxillary (TA) or retroauricular (RA) approach. The former method was described first by Chung et al. and has been widely adopted as a single-incision gasless approach to the thyroid bed from the axilla.[2] The RA, or modified facelift technique, was first described by Terris et al. and has become a popular remote access to the neck for robotic-assisted approaches.[3] Byeon et al. recently demonstrated an acceptable cosmetic outcome with a good safety profile in their series of 87 patients undergoing RA thyroidectomy.[4]

The second surgical access to the thyroid bed begins in the midline using the bilateral axillobreast (BABA) technique.[5] This approach offers the surgeon the same midline approach as open thyroidectomy. The main benefit of remote access thyroidectomy is that it leaves no scar on the neck, which is obviously important to some patients. The robotic system also provides the surgeon with a magnified, three-dimensional view of the surgical field which enhances the ability to preserve the RLN, external branch of the superior laryngeal nerve (EBSLN), and the parathyroid glands. In this chapter, we describe the robotic thyroidectomy performed via the lateral approach from either the TA or RA incision.

KEY OPERATING LEARNING POINTS

1. It is essential to gain exposure and create a wide working space before proceeding to the console to perform robotic thyroidectomy.
2. Make sure that the robotic working arms are docked between 30 and 45 degrees to the camera arm so as to increase the maneuverability of both working instruments.
3. Identify the omohyoid muscle first before proceeding to mobilize the thyroid gland; this is important in preventing inadvertent injury to the internal jugular vein (IJV).
4. Owing to the lack of haptic feedback to the console surgeon, proper identification of the trachea and cervical esophagus is crucial in avoiding accidental injury to these structures.
5. It is important to ensure a near bloodless field when the RLN is dissected at Berry's ligament to prevent inadvertent injury to the nerve and postoperative hematoma.
6. Monitoring of the RLN is helpful to confirm both anatomic and functional preservation of the nerve during surgery and upon completion of the thyroidectomy.

PREOPERATIVE PERIOD

History

1. Previous thyroidectomy or other neck surgery
2. Thyroid status (e.g., hypothyroid or thyrotoxic)
3. History of neck or shoulder problems
4. History of keloid or hypertrophied scar

Physical Examination

1. Body mass index (BMI)
2. Size of thyroid nodule, unilateral or bilateral nodules
3. Range of motion of cervical spine and shoulder
4. Direct laryngoscopy before surgery to evaluate vocal cord function

Imaging

Thyroid Ultrasound

Because of the operator-dependent nature of this modality, thyroid ultrasound is best performed by a physician specializing in thyroid imaging. The overall size of the gland, number of thyroid nodules, and any features raising suspicion of malignancy (e.g., taller than wide, hypoechoic nodule, peripheral vascularization, microcalcifications, irregular margins) should be documented. The presence of enlarged and suspicious lymph nodes in the central compartment should also be noted.

Fine-Needle Aspiration Biopsy

Fine-needle aspiration biopsy (FNAB) is helpful for categorizing nodules according to risk of malignancy. At both our institutions, the Bestheda classification system is adopted. Additionally, we perform molecular markers (using a panel of common mutation markers) to help further risk-stratify nodules categorized as indeterminate (e.g., follicular lesion of undetermined significance (FLUS), follicular neoplasm, suspicious for malignancy). Using this panel of markers, preoperative counseling for upfront total thyroidectomy, rather than a diagnostic thyroid lobectomy, can be achieved in order to avoid completion thyroidectomy as a second-stage procedure.[6]

Thyroid Scan

This is seldom performed unless there is clinical suspicion of a hyperfunctioning solitary thyroid nodule that could account for a thyrotoxic state. In this instance, the scan will demonstrate a solitary "hot" thyroid nodule, and surgery to remove this nodule would be indicated to restore a euthyroid state.

Indications for Robotic Thyroidectomy

1. Thyroid nodule smaller than 5 cm
2. BMI less than 35
3. No prior neck surgery
4. Small T1–T2 thyroid cancer (well-differentiated variant papillary thyroid cancer or follicular cancer)

TABLE 80.1 Differences Between the Transaxillary and Retroauricular Approaches

	Retroauricular Approach	Transaxillary Approach
Elevation of the cervical flap	Shorter distance to thyroid bed	Longer distance to thyroid bed
Identification of the superior thyroid pedicle/EBSNL	Excellent	Good
Identification of the recurrent laryngeal nerve	Excellent	Excellent
Concurrent central compartment neck dissection	Excellent	Good
Brachial nerve neuropathy	No	Rare (2%)
Maximum number of deployable operating robotic arms in the da Vinci Si system	Two	Three

EBSNL, External branch of the superior laryngeal nerve.

Contraindications

1. Graves disease
2. Substernal extension of the gland
3. Locally advanced thyroid cancer with invasion of the RLN/tracheoesophageal complex/strap muscles
4. Known central compartment or lateral cervical lymph node metastasis
5. Medullary thyroid cancer

Relative Contraindications

1. Thyroid pathologies that require primary total thyroidectomy (e.g., multinodular goiter with sizable nodules on both thyroid lobes, thyroid cancer)
2. Suspicion for central compartment lymph node metastasis in patients with thyroid cancer

Preoperative Preparation

The choice of the surgical approach should be discussed preoperatively with the patient. We have no specific preference in the choice of surgical access, although an RA approach is associated with a shorter dissection distance to the thyroid bed, and this access is also more intuitive for head and neck surgeons. Nevertheless, in the TA approach, up to three operating robotic arms may be deployed, which can facilitate the retraction of tissue by the third operating arm. This third arm may be inserted directly from the TA incision or via another 5- to 8-mm periareolar incision. However, in our experience with the RA approach, the deployment of the third operating arm through this incision often makes it collide with the working arms, since operating arms of the da Vinci Si system are bulky. A comparison of these two approaches is summarized in Table 80.1.

OPERATIVE PERIOD

Anesthesia

The patient is placed in the supine position, and an orotracheal tube (a laryngeal monitoring tube) is inserted for intraoperative monitoring of the RLN. The orotracheal tube is placed to the side opposite the site of thyroidectomy, and the airway circuit is brought down toward the patient's feet.

Position

In the TA approach, the upper arm is extended with the elbow flexed and internally rotated so as to expose the entire axilla without undue tension on the brachial plexus (Fig. 80.1). It is critical to make sure that the bony pressure points of the upper limb are adequately protected with soft cotton padding so as to prevent skin necrosis. Because of the remote risk of traction brachial plexopathy with prolonged shoulder extension, some surgeons have adopted additional intraoperative monitoring for both the radial and ulnar nerves. However, we have not found this to be necessary as the key to prevention lies in avoiding undue tension on the brachial plexus with the modified position of the upper limb. In the RA approach, both arms are tucked alongside the body in neutral position, and the head is turned away from the site of operation. We do not use a shoulder roll for neck extension in either of these approaches.



Fig. 80.1. Modified arm position for transaxillary thyroidectomy (arm is flexed at the elbow to avoid undue tension on the axilla).

Perioperative Antibiotic Prophylaxis

A thorough cleaning of the surgical field with Betadine iodine is adequate, and no perioperative antibiotic is necessary.

Instruments and Equipment to Have Available

At both our institutions, robotic thyroidectomy is performed using the da Vinci Si robotic system. We use the 10-mm 30-degree camera, which is positioned downward in order to visualize the entire surgical field. The two robotic working arms are the harmonic shears (8 mm) and the Maryland grasper (5 mm). An atraumatic Prograsp (8 mm) may be used instead of the Maryland grasper.

The assistant surgeon is stationed at the patient's side and assists the console surgeon in the following ways:

1. Providing countertraction during dissection
2. Retraction of the sternocleidomastoid muscle (in the RA approach)
3. Hemostasis using a fine long-tip bipolar cautery
4. Suctioning of the smoke fumes during surgery
5. Ensuring that the working arms are functioning at an optimal position without collision

The equipment that is essential to perform these functions is as follows:

1. Long-tip monopolar and bipolar cauteries
2. Lighted retractor system during flap elevation
3. Headlight
4. "Chung" retractor system
5. Rolled cotton pledgets
6. Yankauer suction

Key Anatomic Landmarks

1. Omohyoid muscle
2. Trachea
3. Cricothyroid muscle
4. Inferior thyroid artery (ITA)

Prerequisite Skills

Before embarking on robotic thyroidectomy, the surgeon must have sufficient experience in performing open thyroidectomy. A prior experience in endoscopic surgery was not identified as a significant requirement among fellowship-trained surgeons embarking on robotic thyroidectomy.[7] The console surgeon should be familiar with the setup and functions of the da Vinci robot. This can be accomplished through either structured credentialing courses (offered by Intuitive Surgical Inc.) or through a comprehensive head and neck fellowship program including a large volume of robotic surgery. Additionally, both dry and wet laboratory training are helpful in shortening the learning curves involved. In the dry laboratory, computer-simulated programs mimicking several surgical situations can increase the surgeon's skills in accomplishing the tasks required by robotic surgery. Similarly, wet laboratory cadaveric training with hands-on operative experience is invaluable in enhancing the learning experience. We recommend that the beginning surgeon perform the first five cases under supervised proctorship by an experienced surgeon in order to gain confidence with this new technique.

Operative Risks

In addition to the specific risks to the RLN and EBSLN, robotic thyroidectomy carries with it several potentially serious complications that are not usually encountered in standard open thyroidectomy. Perforation of the trachea and vascular injuries have been reported, which may be related to the lack of haptic feedback afforded to the console surgeon.[8] However, a good understanding of the surgical anatomy and keeping the surgical field bloodless will help to minimize these complications. In the TA approach, excessive and prolonged traction on the shoulder may result in brachial plexopathy. With our modified positioning of the upper limb, we have not encountered this complication. Injuries to vascular structures such as the carotid artery or IJV may occur during dissection, especially if the dissection is performed in a rough manner. In the event of an injury to the carotid artery, direct external pressure to the carotid artery should be applied while the surgeon opens the neck in the conventional manner to expose the carotid sheath. As for injury to the IJV, bleeding from minor lacerations may be stopped with bipolar cautery or hemostatic surgical clips. In the instance of a major injury to the IJV, this vein may have to be sacrificed in order to gain complete hemostasis.

In patients who develop delayed postoperative hemorrhage or hematoma, securing hemostasis under general anesthesia is performed through the same remote access incision and without using the da Vinci robot. In this situation, a 10-mm endoscope (both 0 and 30 degrees) will help the surgeon to stop the bleeding points with either bipolar cautery or harmonic shears.

Surgical Technique

The surgical techniques of robotic thyroidectomy can be divided into the following categories.

Creating the Working Space

The creation of an adequate working space over the thyroid bed is critical to gain unrestricted maneuverability of the robotic instruments. This part of the operation is performed under direct vision using a long-tip monopolar cautery and a headlight for adequate illumination of the surgical field. A lighted retractor system is progressively deployed once the skin flap has been raised approximately 5 cm from the incision. A Yaukeur suction is used to aspirate the smoke and provide countertraction during the dissection. The typical length of the skin flap raised for the TA and RA approaches is between 12 to 14 cm and 10 to 12 cm from the incision, respectively.

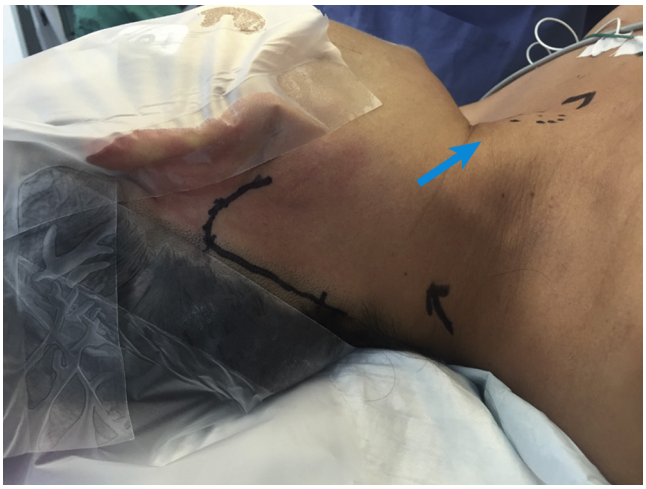

Fig. 80.2. Planned incision of retroauricular approach to the thyroid (arrow).

In the TA approach, a 4- to 5-cm incision is placed 5 to 8 mm posterior to the anterior axillary fold in order to conceal the scar posterior to the skin fold. A skin flap is elevated over the pectoralis major muscle until the clavicle is encountered. Beyond this point, the skin flap is elevated in a subplatsymal fashion. The skin flap is elevated over the clavicular and sternal attachments of the sternocleidomastoid muscle until the level of the thyroid cartilage and just beyond the midline of the neck. Care must be taken to identify the omohyoid muscle and avoid getting deep to this muscle, since the carotid sheath and the IJV lie deep and medial to this plane.

In the RA approach, a 4- to 5-cm incision is placed approximately 5 to 8 mm posterior to the hairline in order to conceal the incision (Fig. 80.2). The flap is raised in the direction of the suprasternal notch, and this plane is also approximately the axis where the retractor blade will be positioned to retract the flap. First, the line of incision is infiltrated with xylocaine with adrenaline (1:80,000). A subplatysmal skin flap is elevated over the sternocleidomastoid muscle, taking care to preserve the greater auricular nerve and external jugular vein. The skin flap is elevated medially over the strap muscles beyond the midline raphe and as far superior as the clavicle at the inferior limit. The flap is elevated over the tail of the parotid and up to the ramus of the mandible. Care must be exercised to avoid injuring the marginal mandibular nerve.

Docking the da Vinci Si Robot

Once the working space has been created, the sternohyoid muscle is elevated off the thyroid bed, and the Chung retractor is inserted under the muscle to maintain exposure of the thyroid bed throughout the dissection. The Chung retractor is then secured and fixed onto the operating table. Upon retraction of the skin flap, it is important to note that the vertical height from the base of the incision to the skin flap upon suspension should be more than 5 cm (Fig. 80.3). This aspect is crucial so that an adequate working space is established before the robotic arms are brought into the field.

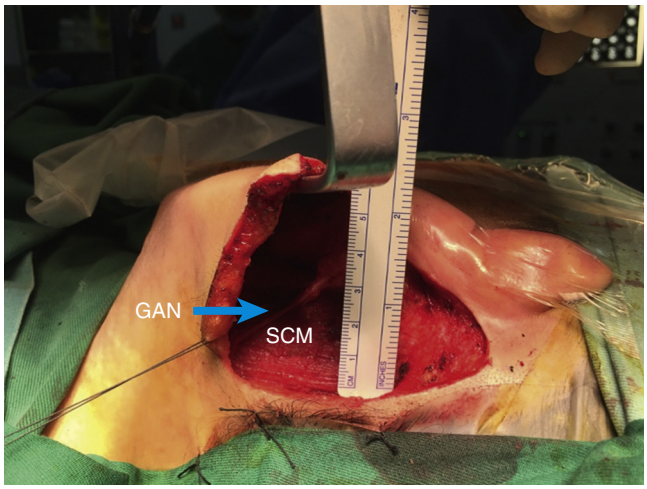

Fig. 80.3. Adequate working space must be ensured in the retroauricular approach to thyroid (height of elevation should be more than 5 cm) (arrow). *GAN*, great auricular nerve; *SCM*, sternocleidomastoid muscle.

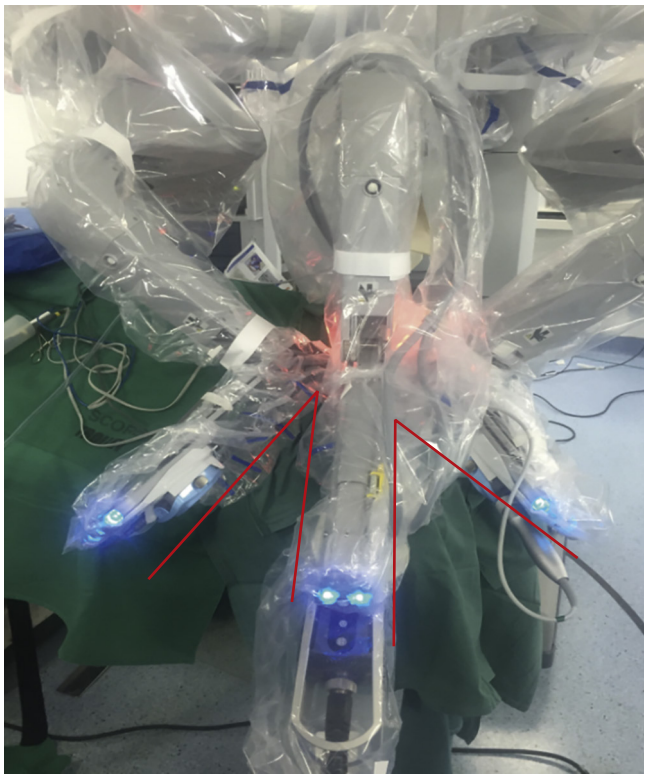

Fig. 80.4. Docking of da Vinci robotic arms in retroauricular approach.

The da Vinci robot is then brought into the surgical field opposite the site of operation. The robot is brought in at a 30- to 45-degree angle to the surgical table, approximately at the level of the patient's shoulder. The robot is subsequently docked, and the three working arms are brought into the working space. The camera port (10 mm) is docked in the midline, with the two working arms positioned at an angle of 30 to 45 degrees to the axis of the camera arm (isosceles triangle configuration) (Fig. 80.4). The rationale for placing these two working arms in this configuration is to minimize collision of these arms during dissection.

Our preference is to use the 8-mm harmonic shears and 8-mm atraumatic Prograsp forceps as our working instruments



Fig. 80.5. Exposure of the left thyroid bed from the retroauricular approach.

for robotic thyroidectomy. Some surgeons may opt for the 5-mm Maryland grasper, since it is narrower and hence may minimize the working space necessary to maneuver the instrument. However, we believe that the tip of the 5-mm Maryland grasper is too sharp and can cause inadvertent trauma to the thyroid tissue during tissue handling. This may result in unnecessary bleeding during the dissection, which can obscure the surgical field. Once the robot is docked, the entire thyroid bed should be visualized before the surgery is performed (Fig. 80.5).

Ligation of the Superior Thyroid Artery

In both the RA and TA approach, the thyroidectomy begins by mobilizing the superior pole of the thyroid gland. The sternothyroid muscle may be transected for better exposure and visualization of the superior pole of the gland. A lateral and medial plane are delineated around the superior pole, and the superior thyroid artery (STA) is isolated and ligated using the harmonic shears. We do not routinely identify the EBSLN, but we avoid injury to this nerve by ligating the STA close to the thyroid gland. With the magnified view of the superior pole, our experience is that the EBSLN can often be visualized and preserved during ligation of the STA. Next, the cricothyroid muscle is identified, since this landmark is helpful in demarcating the level where the RLN enters the larynx.

Preservation of Parathyroid Glands

With both the RA and TA approaches, we reach the thyroid gland from lateral to medial. The thyroid gland is mobilized and reflected medially toward the trachea. The middle thyroid vein is often encountered and is ligated using the harmonic shears. The superior parathyroid gland is identified superiorly and freed from the thyroid gland again using the harmonic shears. Next, attention is focused on the inferior pole of the thyroid gland. The ITA is often encountered and ligated as distal as possible to preserve the vascular supply to the parathyroid glands. The ITA is not a useful landmark for identifying the RLN, since their relationship is inconsistent. In a similar fashion, the inferior parathyroid gland is identified and freed from the thyroid with its vascular pedicle intact. Use

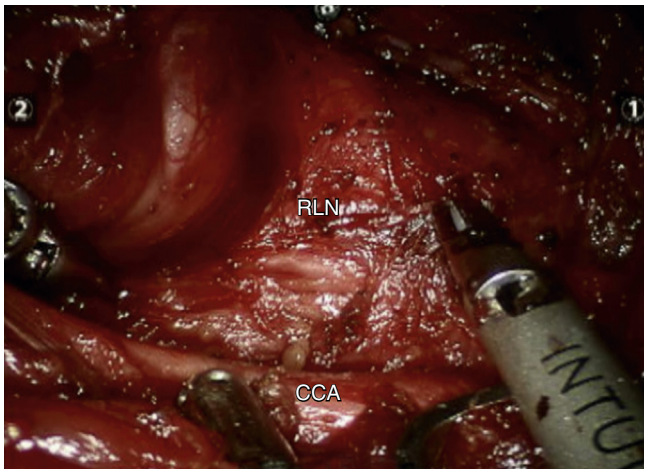

Fig. 80.6. Right thyroid bed after robotic thyroidectomy demonstrating the recurrent laryngeal nerve *(RLN)* and common carotid artery *(CCA)*.

of the robotic system allows the surgeon to have a magnified view of the operative field and aids in identifying and preserving these structures.

Identification of the Recurrent Laryngeal Nerve and Freeing the Thyroid Gland From Berry's Ligament

The trachea is next identified and exposed. This orients the console surgeon with regard to the medial limit of the dissection. With the thyroid gland reflected medially by the Maryland grasper, the RLN is identified in the tracheoesophageal groove. Care must be taken to avoid inadvertent injury to the esophagus in this area. We generally prefer to identify the RLN close to the cricothyroid joint, since this is the most consistent location of the nerve that is not influenced by anatomic variantion or by pathologies of the thyroid gland. Once the RLN has been identified, the nerve is traced toward Berry's ligament. At this point meticulous dissection of the nerve is required, since there are usually small vessels overlying the nerve near Berry's ligament. These vessels must be individually identified and ligated using the harmonic shears. We like to place a wet rolled cotton pledget over the RLN at this point to protect it from thermal injury from the harmonic shears. The cotton pledget can also be used to bluntly dissect the nerve at the cricothyroid area. If the nerve is closely adherent to the cricothyroid area, a fine-tip bipolar cautery may be applied to divide Berry's ligament. Once Berry's ligament has been divided, the thyroid lobe is mobilized off of the trachea. The thyroid isthmus is divided and the thyroid lobe removed. The thyroid bed is irrigated with warm saline, and the RLN is stimulated at 0.5 to 1 mA to confirm preservation of its function. The view of the thyroid bed following robotic thyroidectomy is illustrated in Fig. 80.6. The wound is closed over a drain, and the drain is brought out at the edge of the incision.

Common Errors in Technique

1. Inadequate countertraction when elevating the skin flap may result in perforation of the flap.
2. Getting deep to the plane of the omohyoid muscle prematurely risks possible injury to the IJV or one of its branches.
3. Dividing a large piece of tissue at the superior pole of the thyroid gland. The individual superior thyroid vessel should be skeletonized before ligating it with the harmonic shears. This is important, since the vessel may not be completely exposed during ligation if additional soft tissue is still attached to the vessel. Additionally, a low-lying EBSLN (Cernea type 2b) may be at risk if an indiscriminate ligation of the STA is performed.
4. Dividing Berry's ligament without completely mobilizing the entire thyroid lobe

POSTOPERATIVE PERIOD

Postoperative Management

1. Surgical drainage is charted, and the drain is removed when the drainage is less than 20 mL over a 24-hour period.
2. Compression dressing is not necessary to compress the skin flap in the immediate postoperative period. Some degree of edema of the flap is expected and will subside within 1 to 2 weeks in most instances.

Complications

1. Wound infection
2. Hematoma formation
3. RLN injury
4. Temporary numbness over the anterior chest wall (TA approach) and around the ear (RA approach)

Alternative Management Plan

Open thyroidectomy should always be discussed with patients undergoing robotic thyroidectomy. The chance of conversion to an open approach is exceedingly low with proper patient selection. In rare instances when vascular injuries are encountered (e.g., of the IJV or carotid artery), an open approach may be required to secure hemostasis in an expedient manner.

DISCUSSION

Evidence-Based Medicine Question

Numerous studies have reported robotic thyroidectomy to be a safe and feasible alternative to open thyroidectomy.[4,5,8,9] As with all new surgical techniques, a learning curve is involved in achieving good clinical outcomes. A thorough understanding of the surgical anatomy and prior experience in open thyroidectomy will invariably shorten the learning curve in robotic thyroidectomy.

Because there are no randomized clinical trials comparing open thyroidectomy to robotic thyroidectomy, most evidence for robotic thyroidectomy is limited to large case series in high-volume centers. A meta-analysis conducted by Lang et al. concluded that robotic thyroidectomy was associated with an increased risk of temporary RLN palsy,[10] although there was no significant difference in permanent morbidity or complications. However, in a subsequent meta-analysis by Son et al., there were no significant differences in terms of either temporary or permanent RLN injuries or hypocalcemia. One of the reasons for this difference is that Son et al. excluded cohort studies of less than 40 patients in their analysis, and this observation suggests that surgical experience is relevant in the initial learning curve toward achieving good clinical outcomes in robotic thyroidectomy. Additionally, when robotic thyroidectomy was performed on patients with thyroid cancer, the mean postoperative thyroglobulin assays did not differ significantly among patients receiving either open thyroidectomy or robotic thyroidectomy.

It is therefore premature at this juncture to draw conclusions about the long-term oncologic outcomes among patients

receiving robotic thyroidectomy for thyroid cancer. Certainly, with proper patient selection and familiarity with the da Vinci robotic system, robotic thyroidectomy may be adopted as a means of treating patients with thyroid disease.

Editorial Comment

Over the past 150 years, thyroid surgery has developed into a relatively safe and reliable procedure for the treatment of various thyroid diseases. The current techniques are readily taught in a reproducible manner with a low incidence of complications, even for the occasional practitioner. The evolution of thyroid surgery to progressively less invasive strategies has been aided by advances in visual, hemostatic, and anesthetic techniques. Robotic thyroidectomy certainly represents the current pinnacle of technological advances in thyroid surgery. However, contrary to other techniques, robotic surgery requires special surgical expertise and experience with robot technology. This unfortunately is not easily taught or readily available to all surgeons and must be approached with relative caution when recommending this potentially beneficial technique to appropriately selected patients.

Alfred Simental, Jr.



Access the review questions and additional sources list online at http://www.expertconsult.com

REFERENCES

1. Rogers-Stevane J, Kauffman Jr GL. A historical perspective on surgery of the thyroid and parathyroid glands. Otolaryngol Clin North Am 2008;41(6):1059–1067. vii.
2. Holsinger FC, Chung WY. Robotic thyroidectomy. Otolaryngol Clin North Am 2014;47(3):373–378.
3. Singer MC, Terris DJ. Robotic facelift thyroidectomy. Otolaryngol Clin North Am 2014;47(3):425–431.
4. Byeon HK, Kim da H, Chang JW, et al. Comprehensive application of robotic retroauricular thyroidectomy: the evolution of robotic thyroidectomy. Laryngoscope 2016;126(8):1952–1957.
5. Lee KE, Kim E, Koo do H, et al. Robotic thyroidectomy by bilateral axillo-breast approach: review of 1,026 cases and surgical completeness. Surg Endosc 2013;27(8):2955–2962.
6. Nikiforov YE, Ohori NP, Hodak SP, et al. Impact of mutational testing on the diagnosis and management of patients with cytologically indeterminate thyroid nodules: a prospective analysis of 1056 FNA samples. J Clin Endocrinol Metab 2011;96(11):3390–3397.
7. Park JH, Lee J, Hakim NA, et al. Robotic thyroidectomy learning curve for beginning surgeons with little or no experience of endoscopic surgery. Head Neck 2015;37(12):1705–1711.
8. Ban EJ, Yoo JY, Kim WW, et al. Surgical complications after robotic thyroidectomy for thyroid carcinoma: a single center experience with 3,000 patients. Surg Endosc 2014;28(9):2555–2563.
9. Yi O, Yoon JH, Lee YM, et al. Technical and oncologic safety of robotic thyroid surgery. Ann Surg Oncol 2013;20(6):1927–1933.
10. Lang BH, Wong CK, Tsang JS, et al. A systematic review and meta-analysis evaluating completeness and outcomes of robotic thyroidectomy. Laryngoscope 2015;125(2):509–518.

REVIEW QUESTIONS

1. Which of the following is the most likely benefit to patients receiving robotic thyroidectomy?
   a. Better visualization of the recurrent laryngeal nerve
   b. Better visualization of the parathyroid glands
   c. Improved cosmetic outcome by avoidance of a scar on the neck
   d. Enhanced wrist maneuverability of the robotic arms
   e. Reduced risk of postoperative bleeding

2. Which is the most important step in robotic thyroidectomy?
   a. Docking of the robotic arms at an "isosceles" angle to the camera arm so as to minimize collision of the working arms
   b. Complete exposure of the thyroid bed before docking the robot
   c. Monitoring of the recurrent laryngeal nerve to minimize injury
   d. Using a 30-degree camera scope rather than a zero-degree camera scope for better visualization
   e. Using the 8-mm fenestrated bipolar Cadiere forceps rather than the 8-mm fenestrated Maryland bipolar for hemostasis

3. Which of the following is the best candidate for robotic thyroidectomy?
   a. A 70-year-old male with a 6-cm benign solitary right thyroid cyst
   b. A 34-year-old female with Graves disease and, on ultrasound, a diffusely enlarged thyroid gland with no discrete nodules
   c. A 55-year-old man with a 4.5-cm right thyroid nodule and FNA cytology showing papillary thyroid cancer
   d. A 60-year-old female with a history of keloid scar and ultrasound showing multiple thyroid nodules in both lobes (largest measuring 4 cm)
   e. A 27-year-old female with a 3-cm solitary thyroid nodule and FNA cytology showing a follicular lesion of undetermined significance

ADDITIONAL SOURCES

Berber E, Bernet V, Fahey 3rd TJ, et al. American Thyroid Association Statement on Remote-Access Thyroid Surgery. Thyroid 2016;26(3):331–337.

Son SK, Kim JH, Bae JS, et al. Surgical safety and oncologic effectiveness in robotic versus conventional open thyroidectomy in thyroid cancer: a systematic review and meta-analysis. Ann Surg Oncol 2015;22(9):3022–3032.

81 Massive and Substernal Goiter

Miriam N. Lango

INTRODUCTION

Prior to the 20th century, thyroid surgery was associated with a high operative mortality rate. The meticulous surgical technique advanced by Kocher in the late 1890s transformed thyroidectomy into a safe operative procedure associated with a 1% mortality rate. Although generally safe and effective, surgery for massive and substernal goiter remains subject to potentially significant surgical complications.

Approximately 5% of the population in the United States is estimated to have benign enlargement of nodules within the thyroid gland, known as a goiter. Iodine deficiency has been associated with the development of goiter, but this cause of goiter is now uncommon in the developed world. The vast majority of goiters are not associated with abnormal thyroid hormone function, and most are asymptomatic. However, massive enlargement can occur in which the gland extends around the pharynx or extends below the level of the thoracic inlet into the chest. In 1939 Crile described substernal goiters as those extending to the aortic arch. Recently In 2008, Huins et al. described, a three-tiered system derived from a large meta-analysis which classified substernal goiters in relation to the aortic arch, pericardium, and atrium.[1]

Massive and substernal goiters are often technically demanding procedures, due to the gland's vascularity and its proximity to the larynx, trachea, and the recurrent laryngeal nerves controlling vocal cord movement. In addition, the exposure needed to identify and preserve important structures is hampered when the goiter extends below the level of the thoracic inlet into the enclosed space of the chest. Nevertheless, even large goiters can usually be delivered out of the chest through an incision low in the neck using technical maneuvers.[2] However, extension inferior to the aortic arch more often necessitates additional exposure.[1]

Substernal goiters may come to clinical attention as a visible mass or as a result of goiter-related symptoms: a compressive pressure–type sensation, shortness of breath on lying down, and problems swallowing. Indeed, substernal goiters are more often symptomatic than massive goiters limited to the neck. Substernal goiters may not be visible on inspection because most of the gland is in the mediastinum (Figs. 81.1 to 81.3). Patients develop symptoms due to cumulative growth within the confines of the thoracic inlet and chest cavity, compressing or displacing the trachea, esophagus, and mediastinal blood vessels. Enlargement is typically slow and progressive over many years. Sudden, rapid enlargement of a long-standing goiter suggests the development of cancer but could also be due to abrupt bleeding into the gland.

Surgery for goiter is the definitive treatment for massive or substernal goiter but is associated with a number of potential complications. The surgery is highly effective in ameliorating goiter-related symptoms, but diligent surgical execution is needed to optimize favorable outcomes. Strategies to limit intraoperative bleeding, enhance exposure, and facilitate atraumatic surgical dissection will diminish intraoperative complications.

KEY OPERATIVE LEARNING POINTS

1. Assess the level of patient-reported symptoms, prior to surgery. Consider using a thyroid-specific tool, such as the short version of the thyroid-related patient-reported outcome (ThyPRO) tool[3] prior to surgery; this tool may also be administered several months after surgery. Rapid enlargement associated with pain and dysphagia suggests the development of an aggressive malignancy.
2. Preoperative evaluation[4] should include serum thyroid-stimulating hormone (TSH) and imaging. Both an ultrasound and a computer tomography (CT) scan should be obtained. The CT scan with intravenous contrast will determine the substernal extent of the goiter and its relationship with large blood vessels and identify posterior mediastinal extension associated with displacement of the recurrent laryngeal nerve. The appearance may also suggest the presence of an infiltrative malignancy that could alter the treatment plan.
3. Continuous laryngeal nerve monitoring that tests the functional integrity of the recurrent laryngeal nerve by means of continuous intraoperative vagal nerve stimulation is particularly useful in the management of large substernal goiters. During these cases the recurrent laryngeal nerve may not be readily identified because it is hidden behind a large obstructing goiter and subject to traction injury. Evidence for the use of continuous laryngeal nerve monitoring is mounting, but this technology does not yet represent standard of care.[5]
4. Instrumentation used for minimally invasive thyroid surgery is useful in substernal goiter surgery, which usually requires dissection in narrow spaces with limited exposure; having the proper instrumentation may obviate the need for manubrium or sternal osteotomies, which may be required in revision cases or those involving substernal thyroid cancer (Fig. 81.4).

PREOPERATIVE PERIOD

History

1. History of present illness
   a. History of anterior neck mass
      1) Duration of mass, interval enlargement
   b. Patient symptoms
      1) Direct compression of the trachea or esophagus by a substernal goiter can cause dysphagia to solids, positional dyspnea, and dysphonia. Positional dyspnea and orthopnea are frequently associated with substernal goiter with tracheal compression on cross-sectional imaging.
   c. History of snoring, daytime somnolence, sleep apnea
   d. Factors predisposing to thyroid cancer, such as history of neck radiation, or family history of thyroid cancer



Fig. 81.1. A large substernal goiter is not necessarily associated with an obvious abnormality in the neck visible by inspection alone.

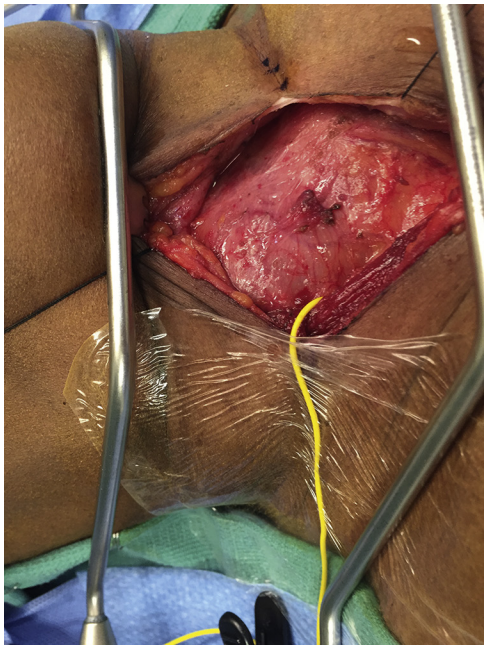

Fig. 81.2. The cervical incision must be large enough to accommodate delivery of the gland. A continuous laryngeal nerve monitor stimulates *(yellow wire)* the ipsilateral vagus nerve, monitoring the functional integrity of the recurrent laryngeal nerve during the procedure.

2. Past medical history
   a. A complete past medical and surgical history must be obtained from the patient. Prior imaging and biopsies should be reviewed. A history of hypertension and prior neck surgery should be noted.

Physical Examination

1. Respiratory distress? Stridor? Hoarseness?
2. Venous congestion of neck/facial venous collaterals
3. Neck
   a. Size and location of the goiter
      1) Consistency: Is the mass firm or hard?
      2) Is it tethered to the overlying skin; is the skin indurated?
      3) Does it extend to the clavicle?



Fig. 81.3. The massive substernal component was delivered prior to definitive identification of the recurrent laryngeal nerve. In the absence of amplitude or latency changes, safe delivery without traction injury was accomplished.

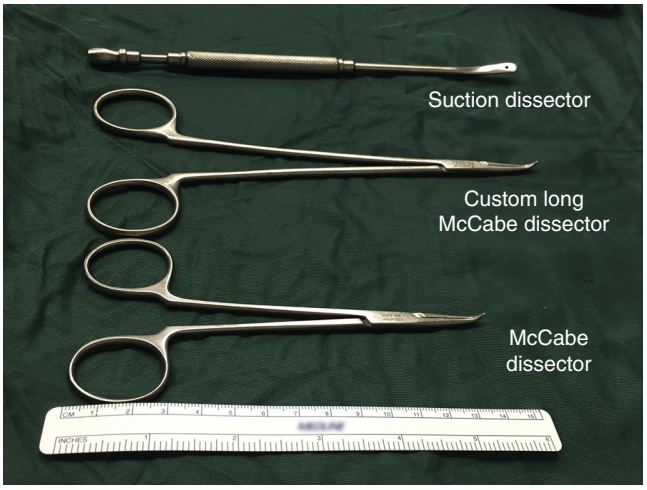

Fig. 81.4. Specialized equipment can be helpful. A custom, long McCabe is superior to the classic McCabe dissector, a Schnidt, or a right-angle clamp in reaching into deep narrow spaces. A suction dissector may be used like a Kittner sponge but is less abrasive.

      4) Does it move with swallowing? Is the inferior extent palpable with swallowing?
      5) Is the trachea palpable, and is it deviated?
      6) World health organization (WHO) classification (Table 81.1): Patients with goiters visible on casual inspection may have few goiter-related symptoms. Substernal goiters associated with patient symptoms may not necessarily be appreciated on clinical examination alone (see Fig. 81.1).
   b. Palpable cervical lymphadenopathy and neck levels involved
4. Larynx: Examination of the larynx should also assess the pharynx for compression, as well as vocal cord mobility.

TABLE 81.1 World Health Organization Classification of Goiter

Grade 0	Impalpable/invisible
Grade 1a	Palpable but invisible even in full extension
Grade 1b	Palpable in neutral position/visible in extension
Grade 2	Visible no palpation required to make diagnosis
Grade 3	Visible at a distance

WHO, World Health Organization.

TABLE 81.2 Classification and Approach for Retrosternal Goiters

Grade	Anatomic Location	Approach
1	Above aortic arch/above T4 vertebra	Cervical
2	Aortic arch to pericardium	Manubriotomy
3	Below right atrium	Full sternotomy

Reproduced with permission Huins CT, Georgalas C, Mehrzad H, et al.: A new classification system for retrosternal goitre based on a systematic review of its complications and management. Int J Surg 6(1):71-76, 2008.

5. Pemberton maneuver: The maneuver is performed by having the patient raise both arms against the face for several minutes to see if the patient develops reversible facial flushing or cyanosis, sometimes associated with shortness of breath or stridor. A positive Pemberton sign indicates superior vena cava syndrome causing diminished venous outflow from and venous congestion of the head and neck due to goiter-related compression of the vessels in the mediastinum. Patients may also have enlargement of venous collaterals in the chest and neck.

Imaging

Ultrasound of the neck

Prior to thyroidectomy, patients should undergo a formal ultrasound of the neck and thyroid gland to assess the risk of malignancy in the goiter. In the presence of abnormal adenopathy or invasive features, a fine-needle aspiration biopsy may be warranted.

CT of the neck/chest

A CT scan of the neck and chest is recommended if substernal extension is suspected.[6] Evaluation of the caudal extent of the goiter will facilitate surgical planning and enable added thoracic exposure should it prove to be necessary.[1]

Caudal growth of a goiter in the visceral space initially involves extension into the pretracheal space into the anterior mediastinum or retroesophageal extension into the posterior mediastinum. Significantly, posterior mediastinum extension is rare in the absence of concomitant anterior mediastinum involvement.[7] Goiter extension into the posterior mediastinum suggests anterior displacement of the recurrent laryngeal nerve. A meta-analysis linked extension to specific structures with the need for additional procedures (Table 81.2). Goiter extension above the fourth vertebrae or above the level of the aortic arch can usually be managed transcervically. Posterior mediastinum extension of the goiter necessitates a thoracotomy for exposure and extirpation.

The degree of tracheal compression, described as the percentage reduction in tracheal diameter, should be noted. Any assessment of substernal goiter should include a description of the degree of tracheal compression is described as the greatest percentage reduction in tracheal diameter. Compression greater than 35% is considered prognostic, with near-universal relief of preoperative positional dyspnea.[4]

Indications

1. Substernal goiter

Historically, the presence of a substernal goiter has been considered a sufficient indication for surgery. However, specific preoperative factors predict greater improvements in patient symptoms. Improvement or resolution of positional dyspnea varies with the degree of preoperative tracheal compression. Greater than 35% narrowing of the tracheal lumen has been associated with resolution of positional dyspnea in 57% to 95% of patients; lesser narrowing is less reliably associated with improvement in positional dyspnea postoperatively.[4] Thyroid gland weight greater than 100 g or thyroid lobe greater than 75 g has also been associated with an improvement in patient symptoms,[4] but this information is not available prior to surgery. Older adult or infirm patients with lesser narrowing may be observed for progression, whereas younger or more symptomatic patients may be offered surgery promptly.

Contraindications

1. Patient refusal of consent
2. Unresectable aggressive or anaplastic thyroid carcinoma
3. Major medical comorbidities

Preoperative Preparation

1. TSH
2. Anesthesia and medical consultations
3. Recurrent laryngeal nerve monitoring
4. Thyroid-specific instrumentation (see Fig. 81.4)
5. Type and screen
6. Vessel sealing devices (optional)

OPERATIVE PERIOD

Anesthesia

General anesthesia

Positioning

Supine with neck extension

Perioperative Antibiotic Prophylaxis

First-generation cephalosporin or alternative for those allergic

Monitoring

Laryngeal nerve monitoring

The role of laryngeal nerve monitoring in thyroid surgery remains an active area of investigation. Moreover, laryngeal nerve monitoring may be done intermittently or in real time, using vagal nerve stimulation during the thyroidectomy. A study suggested intermittent laryngeal nerve monitoring results in higher rates of laryngeal nerve palsies.[8] Such monitoring might be particularly valuable in cases in which the recurrent laryngeal nerve is obscured by a large obstructing goiter and subject to traction injury. Electromyographic signals suggesting no changes in the amplitude or latency of recurrent laryngeal nerve signals during surgical maneuvers to deliver a large substernal goiter provide real-time feedback regarding the function of the recurrent laryngeal nerve.

Instruments and Equipment to Have Available

1. Standard thyroidectomy set
2. Extra long McCabe dissector (see Fig. 81.4)
3. Suction dissector (see Fig. 81.4)

Thyroid sets developed for minimally invasive thyroid surgery are also useful for substernal goiter surgery. Some of these are commercially available. In general, longer instruments are needed than those needed for standard thyroidectomy. Standard McCabe dissectors are relatively short (14 cm); longer versions of this instrument can be custom ordered at a reasonable cost and are extremely useful in these complex procedures (see Fig. 81.4). The tip of the right angle clamp common on many surgical trays may not fit in the tight space between the thyroid goiter and the thoracic inlet. The tip of a McCabe dissector is shorter, and the angle of the tip is wider, making it more suited to dissection in this region. The use of a suction dissector developed for endoscopic sinus surgery is less traumatic for blunt dissection during thyroid surgery than the use of Kittner[9] (see Fig. 81.4). The suction dissector is used to expose planes around the goiter, making tunnels into the mediastinum, whereas the long McCabe ("the Longo") facilitates dissection of vessels between the tunnels. Endoscopic visualization is not usually needed, but a good headlight is mandatory.

Key Anatomic Landmarks

Anatomic landmarks for the recurrent laryngeal nerve:

- The recurrent laryngeal nerve may be found in the triangle marked by the carotid artery laterally, the trachea, and the lower pole of the thyroid gland (Fig. 81.5).[10]
- The recurrent laryngeal nerve crosses the inferior thyroid artery to enter the larynx posterior to the inferior thyroid artery.
- Goiters extending into the posterior mediastinum enlarge caudally posterior to the inferior thyroid artery along or behind the esophagus, displacing the recurrent laryngeal nerve in an anterior direction (see Fig. 81.5).
- The vast majority of goiters involving the posterior mediastinum also involve the anterior mediastinum.[7]

Prerequisite Skills

1. Mastery of nonsubsternal thyroid surgery. Substernal goiter surgery is complex, and outcomes after surgery are better when surgery is performed by experienced, high-volume thyroid surgeons.

Operative Risks

1. Airway compromise during intubation
2. Intraoperative hemorrhage
3. Recurrent laryngeal nerve injury
4. Hypoparathyroidism and hypocalcemia
5. Tracheal or esophageal injury

Surgical Technique

After a systematic workup, the patient is brought to the operating room.

Intubation

Communication between the otolaryngologist and the anesthesiologist is a prerequisite for safe airway management in a patient with an obstructive lesion. Most patients with large goiters can be safely intubated. Tracheal deviation does not hamper passage of an endotracheal tube, although intubation over a flexible fiberoptic bronchoscope can help to guide advancement and placement of the endotracheal tube with severe deviation. With substantial tracheal compression, a smaller-caliber endotracheal tube may be necessary. An awake or emergency tracheotomy is rarely necessary. Nevertheless, it is prudent for the surgeon to be present during induction of anesthesia.



Fig. 81.5. Left hemineck. The rln enters the larynx posterior to the inferior thyroid artery. Most goiters extend into the anterior, rather than posterior mediastinum. Goiters extending into the posterior mediastinum expand caudally along the esophagus, posterior and deep to the inferior thyroid artery. *cc*, Common carotid; *ct*, cricothyroid muscle; *icm*, inferior constrictor muscle; *ita*, inferior thyroid artery; *rln*, recurrent laryngeal nerve; *t*, trachea. *(Reproduced with permission Asgharpour E, Maranillo E, Sanudo J, et al.: Recurrent laryngeal nerve landmarks revisited. Head Neck 34[9]:1240-1246, 2012.)*

Thoracic consultation

The vast majority of substernal goiters may be removed transcervically, without need for additional exposure afforded by osteotomy of the manubrium or sternum. Nevertheless, adhesions from prior surgery or locally invasive thyroid cancer or ectopic thyroid tissue may require added exposure. Patients with a history of sternotomy for cardiac surgery should never undergo repeat sternotomy without the ability for cardiopulmonary bypass, because atrial injury becomes a factor. A large meta-analysis has also linked the need for thoracic exposure based on caudal extent of the goiter (see Table 81.1).[1] Extension of the goiter to the pericardium suggests the need for a manubriotomy, whereas extension to the atrium suggests the need for a sternotomy, often involving the first two or three rib insertions (Fig. 81.6).

Surgical technique

The skin incision is made, and skin flaps are raised. The strap muscles are separated in the midline (see Figs. 81.1 and 81.2). In cases of massive extension the strap muscles may be sectioned and reapproximated with mattress suturing at the conclusion of the case. Typically, the superior pole is dissected out first. The superior vascular pedicle is ligated. Retropharyngeal extension of the goiter may be encountered but is less common than substernal extension. Extracapsular dissection will limit bleeding during this part of the procedure.

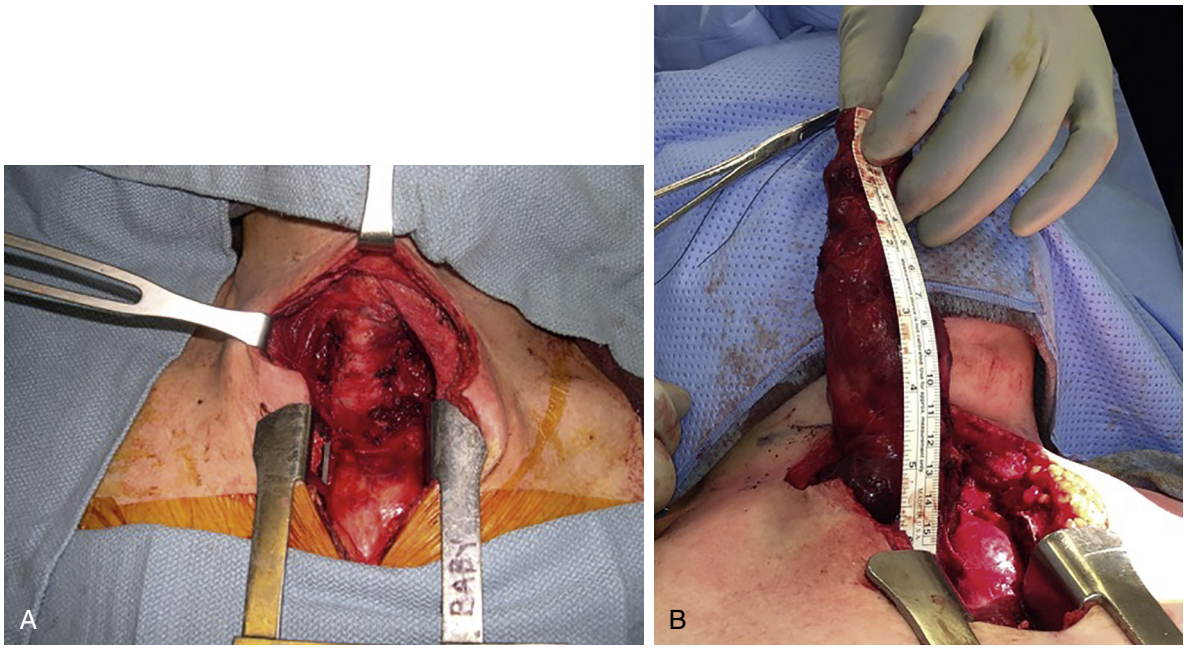

Fig. 81.6. A and **B,** Increased exposure afforded by median sternotomy, allowing increased access to the region surrounding the great vessels, enabling safe complete resection.

The recurrent laryngeal nerve is usually in its normal anatomic position, even in cases involving large substernal goiters. After the goiter is mobilized off the pharynx and larynx, the recurrent laryngeal nerve may potentially be identified if the larynx is relatively high in the neck, just lateral to Berry's ligament, which is sectioned prior to mobilization of the substernal component. However, if the larynx is relatively low relative to the thoracic inlet, it will be difficult to identify the recurrent laryngeal nerve prior to delivering the substernal component into the neck. Dissection of the substernal component can be challenging due to limited exposure afforded by the thoracic inlet. This is particularly the case if there has been prior surgery and the goiter is scarred to the tissues around the thoracic inlet. Instruments used for minimally invasive thyroid surgery can be very useful.

Palpation into the chest with finger dissection assists with delivery of the substernal component into the neck. If the gland cannot be mobilized and delivered, thoracic surgery consultation for added exposure is mandatory. Thus the substernal component of the gland is often delivered into the neck without dissecting the recurrent laryngeal nerve prior to this maneuver. Moreover, mobilization of the gland out of the chest is frequently associated with substantial bleeding. This may be minimized by ligating the inferior thyroid pedicle. However, in the presence of a large substernal goiter, the inferior thyroid pedicle may not be well visualized prior to delivering the gland out of the neck. Upon delivering the gland out of the chest, hemostasis must be undertaken with care. Application of manual pressure to the bleeding surface of the thyroid and other areas is followed by meticulous hemostasis. Many nerve injuries occur during the process of obtaining hemostasis.

In the vast majority of cases the recurrent laryngeal nerve remains posterior to the thyroid gland; in cases with goiter extension into the posterior mediastinum, the recurrent laryngeal nerve is displaced in an anterior direction. In these cases, finger dissection and mobilization will be associated with a severe traction injury to the nerve. A high index of suspicion will prevent this complication. After hemostasis is achieved, the strap muscles are reapproximated which the neck is closed in layers. A drain may be used and hastens resolution of postoperative edema in the neck.

Common Errors in Technique

1. Improper equipment
2. Intraoperative bleeding
3. Incomplete removal of the goiter
4. Inadvertent entry into the airway or esophagus
5. Failure to identify or protect the recurrent laryngeal nerve

POSTOPERATIVE PERIOD

Postoperative Management

1. Assessment of the adequacy of the airway—evaluate for shortness of breath and stridor
2. Assessment of vocal cord mobility by means of laryngoscopy
3. Thyroid hormone supplementation—necessary for total thyroidectomy
4. Postoperative calcium—rule out postoperative hypoparathyroidism
5. Pain medication as needed

Complications

Intraoperative Complications

1. Hemorrhage
2. Recurrent laryngeal nerve injury
3. Airway entry

Because goiters are engorged with enlarged blood vessels, intraoperative bleeding is not uncommon. Early ligation of the superior and inferior thyroid pedicles will diminish blood loss. Intraglandular dissection should be avoided. Hemorrhage from the posterior aspect of the thyroid bed following

delivery of the substernal component is managed by pressure or packing and careful identification and ligation of the bleeding sites. A preoperative type and screen is mandatory; transfusion is used when necessary. Injury to the recurrent laryngeal nerve usually results from excessive traction on the nerve during mobilization. The use of continuous laryngeal nerve monitoring identifies this type of injury and enables the surgeon to modify the approach. However, nerve monitoring cannot prevent inadvertent transection or thermal-related injury. If a loss of signal is encountered, deferring management of the contralateral lobe should be considered. Entry into the airway or esophagus is rare but should be repaired if feasible. A Penrose or suction drain may help to prevent the accumulation of subcutaneous air.

Postoperative Complications

1. Hemorrhage
2. Hoarseness/voice change
3. Hypoparathyroidism
4. Stridor
5. Wound infection

Suspected hemorrhage after surgery should be managed with surgical exploration and evacuation of the hematoma. If hemorrhage is associated with rapid enlargement of a hematoma and dyspnea, the wound should be opened at the bedside to relieve pressure on the airway. Formal exploration may be undertaken in the operating room after the patient is safely intubated. Hoarseness may be related to the endotracheal tube or nerve injury. Vocal cord mobility should be evaluated with laryngoscopy. Calcium may be repleted with or without vitamin D. The management is similar to hypoparathyroidism following total thyroidectomy.

Patients undergoing surgery should be extubated in the operating room when possible. Stridor may be related to vocal cord paralysis or alternatively tracheomalacia. Reintubation may be needed, but an assessment of vocal cord mobility should be undertaken, if possible. Wound infection after thyroidectomy is rare and usually represents a small unrecognized tracheal or esophageal perforation. This can be managed with antibiotics and placement of a drain into the wound; often a Penrose drain will suffice.

Alternative Management Plan

1. Thyroid hormone administration
2. Radioiodine treatment
3. Surveillance or supportive care

DISCUSSION

Evidence-Based Medicine Question

How effective is thyroidectomy in relieving goiter-related symptoms?

Thyroidectomy is effective in relieving positional dyspnea in 82% of patients with goiter and 88% of patients with substernal goiter. Heavier glands predict greater response to surgery, although such measurements cannot be made prior to surgery. Substernal thyroidectomy has been associated with resolution of pulmonary hypertension and heart failure. Dysphagia associated with compression of the esophagus or pharynx is also caused by other processes. Resolution of dysphagia less reliably follows after thyroidectomy. Patient-reported outcomes have detected improvements in swallowing-related symptoms 1 year after surgery, but recurrent laryngeal nerve injury negates any benefit from surgery on outcome.[4]

Editorial Comment

Fortunately most patients with massive or substernal goiter are asymptomatic, which allows them to attain their size without treatment. Substernal goiters are frequently found as an incidental finding on routine imaging for another problem, such as metastatic workup or motor vehicle accident. Some patients may have significant compression of the trachea, esophagus, or great vessels. The majority of symptomatic patients can expect relief of symptoms after surgical removal of the goiter.

Alfred Simental, Jr.

Access the review questions online at http://www.expertconsult.com

REFERENCES

1. Huins CT, Georgalas C, Mehrzad H, et al. A new classification system for retrosternal goitre based on a systematic review of its complications and management. Int J Surg 2008;6(1):71–76.
2. Cho HT, Cohen JP, Som ML. Management of substernal and intrathoracic goiters. Otolaryngol Head Neck Surg 1986;94(3):282–287.
3. Watt T, Bjorner JB, Groenvold M, et al. Development of a short version of the thyroid-related patient-reported outcome ThyPRO. Thyroid 2015;25(10):1069–1079.
4. Chen AY, Bernet VJ, Carty SE, et al. American Thyroid Association statement on optimal surgical management of goiter. Thyroid 2014;24(2):181–189.
5. Deniwar A, Kandil E, Randolph G. Electrophysiological neural monitoring of the laryngeal nerves in thyroid surgery: review of the current literature. Gland Surg 2015;4(5):368–375.
6. Chen X, Xu H, Ni Y, et al. Complete excision of a giant thyroid goiter in the posterior mediastinum. J Cardiothorac Surg 2013;8:207.
7. Chin SC, Rice H, Som PM. Spread of goiters outside the thyroid bed: a review of 190 cases and an analysis of the incidence of the various extensions. Arch Otolaryngol Head Neck Surg 2003;129(11):1198–1202.
8. Schneider R, Sekulla C, Machens A, et al. Postoperative vocal fold palsy in patients undergoing thyroid surgery with continuous or intermittent nerve monitoring. Br J Surg 2015;102(11):1380–1387.
9. Terris DJ, Gourin CG, Chin E. Minimally invasive thyroidectomy: basic and advanced techniques. Laryngoscope 2006;116(3):350–356.
10. Asgharpour E, Maranillo E, Sanudo J, et al. Recurrent laryngeal nerve landmarks revisited. Head Neck 2012;34(9):1240–1246.

REVIEW QUESTIONS

1. Preoperative surgical evaluation of a patient suspected of having a substernal goiter includes all of the following *except*:
   a. TSH
   b. Chest radiograph
   c. CT scan of the chest
   d. Thyroid ultrasound
   e. Laryngoscopy

2. Potential immediate complications of a total substernal thyroidectomy include all of the following except:
   a. Postoperative hemorrhage
   b. Vocal cord paralysis
   c. Hypoparathyroidism
   d. Wound infection
   e. Hypothyroidism

3. Contraindications for substernal thyroidectomy include all of the following except:
   a. Medically inoperable patient
   b. Refusal of consent
   c. Unresectable anaplastic thyroid carcinoma
   d. Presence of unilateral vocal cord paralysis
   e. Uncontrolled hyperthyroidism

4. Of the following preoperative factors, which is least associated with an improvement of symptoms after thyroidectomy?
   a. Preoperative tracheal compression
   b. Preoperative positional dyspnea
   c. Preoperative dysphagia
   d. Resected gland weight greater than 100 g
   e. Resected lobe weight greater than 75 g

82 Invasive Thyroid Cancer

Daniel Kwon, Steve Lee

INTRODUCTION

Thyroid cancer is a curable disease with increasing incidence and treatment strategies. This corresponds with the widespread use of screening modalities and improved health care availability. With more cases being detected in early stages, the incidence of invasive thyroid cancer is relatively low, ranging from 5% to 25%.[1,2] Despite the low incidence, invasive thyroid cancer has significant prognostic implications, with nearly half of deaths from thyroid cancer being attributable to local disease, typically due to airway obstruction and bleeding.[3] Extrathyroidal extension (ETE) in well-differentiated thyroid cancer is a surrogate indicator for loss of normal cellular architecture and poor prognosis. However, in contrast to invasive anaplastic thyroid cancer, tumors of papillary or follicular histology with ETE often retain a favorable prognosis and can successfully be managed surgically.[4,5] Invasive thyroid cancer is a challenging surgical problem that requires complete preoperative evaluation, comprehensive surgical planning, and often a multispecialty surgical team to manage the wide range of surgeries that are required for complete tumor extirpation while minimizing morbidity.

KEY LEARNING POINTS

1. Patients with a high risk of invasive thyroid cancer should be identified and have cross-sectional imaging preoperatively.
2. ETE into muscle or other connective tissue may be adequately treated with wide local excision.
3. The recurrent laryngeal nerve (RLN) should be resected if invaded and preoperative assessment revealed ipsilateral paralysis. Conversely, efforts should be made to spare the nerve if preoperatively it was determined to be functional.
4. Shave resection may be acceptable for limited invasion into the larynx, trachea, and esophagus but with increased rates of local recurrence.
5. Transmural invasion into the viscera of the neck typically requires more aggressive margin-negative resection.

PREOPERATIVE PERIOD

History

1. History of present illness
   a. Evaluate onset, growth, and pain.
      1) Rapidly growing tumors may represent a more aggressive histology and behavior.
      2) Pain or stiffness in the neck may be a feature of invasion.
      3) If a diagnosis of malignancy has not yet been confirmed, index of suspicion must be high for goiters with an aggressive clinical history.
   b. Is there a history of voice changes?
      1) Complaints of voice changes are often the earliest symptom of invasion and should alert the surgeon to evaluate further for laryngotracheal or nerve invasion.
      2) Voice change is not very sensitive for detecting vocal fold paralysis.
   c. Does the patient have complaints of dysphagia, dyspnea, cough, or hemoptysis?
      1) May represent intraluminal invasion of neck viscera
      2) However, may also be secondary to compression as in benign goiters
      3) Absence of symptoms does not make invasion less likely, because the majority of invasive thyroid cancers are asymptomatic.
   d. Is there a history of previous thyroid cancer?
      1) Recurrent cancer in the original thyroid bed has a high risk of invasion
2. Risk Factors
   a. Age
      1) There is a higher incidence of ETE in older patients with thyroid cancer.
   b. Size of the mass
      1) Primary cancer >4 cm have increased incidence of invasion
   c. Histology
      1) Papillary thyroid carcinoma is the most common histologic type.
      2) ETE is often associated with subtypes such as insular, tall cell, and trabecular carcinomas.
      3) Anaplastic or poorly differentiated cancers are nearly uniformly invasive but have a different decision-making tree due to their poor prognosis
3. Past medical history
   a. History of previously treated thyroid cancer
      1) Central neck recurrence after thyroidectomy is often invasive due to anatomic proximity, as well as disruption of natural tissue planes.

Physical Examination

1. Complete examination of the head and neck
   a. Examine the thyroid for fixation to underlying structures and overlying skin and assess movement with swallowing.
   b. Palpate the neck to evaluate for lymph node metastases.
   c. Assessment of cranial nerves
2. Laryngeal function should be routinely assessed.
   a. Voice assessment is required in all patients being seen for thyroid cancer.
   b. Best practice includes visualization of the larynx because laryngeal paralysis often does not produce noticeable voice changes.
      1) Mirror laryngoscopy or flexible laryngoscopy should be used to document vocal fold mobility.
   c. Preoperative ipsilateral vocal fold paralysis is highly predictive of invasive thyroid cancer, and these patients should receive advanced cross-sectional imaging.

Diagnostic Studies

1. Fine-needle aspiration (FNA)
   a. FNA is an important initial diagnostic tool for workup in the evaluation of thyroid tumors.
   b. Regional metastases and recurrent masses should be biopsy-proven prior to surgical treatment.
2. Laboratory studies
   a. Of limited clinical value in evaluating the extent of invasive thyroid cancer
   b. Rising thyroglobulin or thyroglobulin antibodies may indicate recurrent or metastatic disease.

3. Imaging
   a. Ultrasound
      1) Performed routinely for all thyroid cancer evaluations
      2) May identify invasion into surrounding structures, although studies have shown a wide range of sensitivity and specificity
      3) Operator dependent
      4) May be useful for surgical planning if performed by the operating surgeon
   b. Computed tomography (CT) and magnetic resonance imaging (MRI)
      1) Should be done for all patients suspected of invasive thyroid cancer
      2) CT and MRI have similar rates of sensitivity and specificity in detecting extent of tumor and invasion.
      3) CT is rapid, widely available, and easily read by most surgeons.
      4) Use of iodinated contrast may interfere with postoperative radioactive iodine (RAI) treatment for up to 6 to 8 weeks and should be used judiciously.
   c. Positron emission tomography (PET)
      1) May identify metastatic or recurrent disease in radioiodine negative tumors
      2) Evaluation of distant extent of disease (Fig. 82.1) may alter treatment decisions at the primary site.

Indications

1. Surgical resection remains the hallmark of treatment for thyroid cancer, invasive or otherwise.
2. Optimal resection should result in negative margins with wide resection of tumor and involved structures
   a. Structures with low morbidity on resection such as strap muscles
   b. Preoperative nerve infiltration causing dysfunction
   c. Transmural invasion of larynx, trachea, or esophagus
3. Shave resection may provide similar survival with decreased morbidity.
   a. Partial-thickness invasion into larynx, trachea, or esophagus
   b. Nerve encasement with normal preoperative function

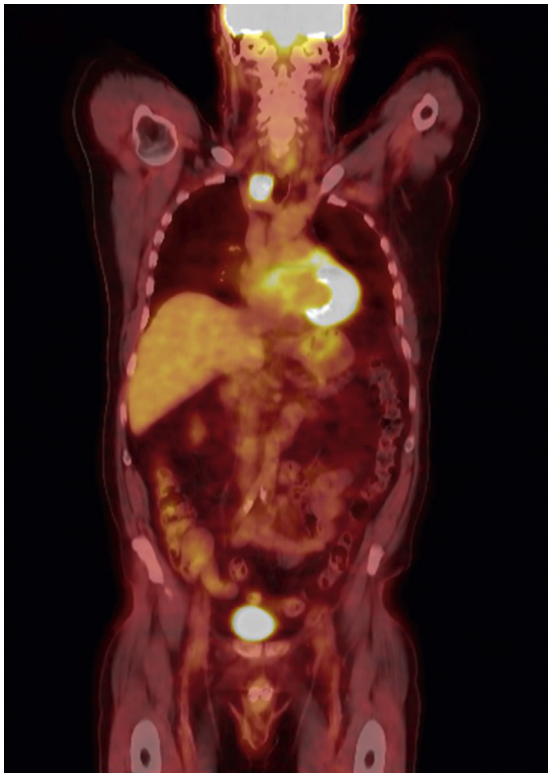

Fig. 82.1. PET evaluation of primary and distant sites, showing hypermetabolic activity in the right thyroid.

Contraindications

1. Morbidity or surgical sequelae of resection unacceptable to patient
2. Major organ resection should be avoided, if possible, in the case of incidental finding of invasion if patient has not been counseled preoperatively.
3. Limiting morbidity and surgical risk in widely metastatic or unresectable, poorly differentiated thyroid carcinoma

Preoperative Preparation

1. Discussion/informed consent with patient regarding treatment goals and extent of resection
   a. Many studies fail to demonstrate survival difference between aggressive and conservative surgery.
   b. Local control rates vary and conservative surgery may require repeated surgery and eventual salvage.
2. The surgeon should be prepared for the wide range of surgical resections and reconstructions that may be required.
   a. When transmural invasion is suspected, reconstructive options should be available, including microvascular surgery and thoracic surgery support.

OPERATIVE PERIOD

Anesthesia

1. Surgery for invasive thyroid cancer generally requires general anesthesia with endotracheal intubation.
2. Thyroid cancer with limited extension could theoretically be done with sedation and local anesthesia, but this is not typical.
3. Esophageal temperature probe or nasogastric tube (NGT) placement is helpful to easily identify the esophagus intraoperatively, as well as use for stenting and feeding in the case of esophagectomy or pharyngectomy.

Positioning

1. Neck should be placed in slight extension with shoulder roll
2. Reverse Trendelenburg or elevated head of bed to promote venous drainage away from the neck

Perioperative Antibiotic Prophylaxis

1. Major head and neck surgery warrants a preincisional antibiotic dose, typically a first-generation cephalosporin for gram-positive coverage.
2. If upper aerodigestive tract breach is expected, coverage for anaerobic bacteria should be added with metronidazole or clindamycin.

Monitoring

1. Intraoperative laryngeal nerve monitoring may be used.
   a. Utility and benefit in routine thyroidectomy are controversial.

b. May provide information regarding functional status of the nerve intraoperatively in the case of surgery of invasive disease and may help to guide extent of surgery and treatment of the contralateral side
c. Should not substitute direct identification and preservation by the surgeon

Instruments and Equipment

1. Basic open neck surgery instruments
   a. Thyroid or neck dissection sets
   b. Fine-tipped dissectors or McCabe dissection for nerve dissection
2. Vascular instruments should be available or open if vascular involvement is suspected.



Fig. 82.2. CT imaging demonstrating laryngeal invasion into the left paraglottic space from around the lateral edge thyroid cartilage.

Key Anatomic Landmarks

1. RLN
   a. The right RLN course is often more tangential due to its course around the subclavian artery when compared with the left side.
   b. The RLN enters the larynx just deep to the inferior laryngeal constrictor, behind the cricoarytenoid joint, where it is closely associated with branches of inferior thyroid artery.
   c. RLN invasion is most common at its entry into the larynx due to its relative fixed position.
   d. The expected position of the RLN may be distorted in cases of thyroid malignancy.
2. Larynx
   a. Invasion occurs through direct extension through the thyroid and cricoid cartilage or via the paraglottic space around the lateral edge of the thyroid cartilage (Fig. 82.2).
   b. Extension into the hypopharynx may occur through the piriform sinus, which is closely associated with the lateral edge of the thyroid cartilage.
3. Trachea
   a. Invasion occurs from direct extension from the thyroid or paratracheal lymph node metastases.
   b. Adherence and superficial invasion into the peritracheal fascia and perichondrium occur first.
   c. Transmural invasion typically occurs between the cartilaginous rings with feeding vessels that traverse the soft tissue.
      1) Often has submucosal spread before intraluminal extension (Fig. 82.3)
4. Esophagus
   a. Invasion may be due to direct extension or paratracheal lymph node metastases.
   b. The esophagus is generally resistant to invasion and invasion typically involves outer muscular layers without intraluminal invasion.

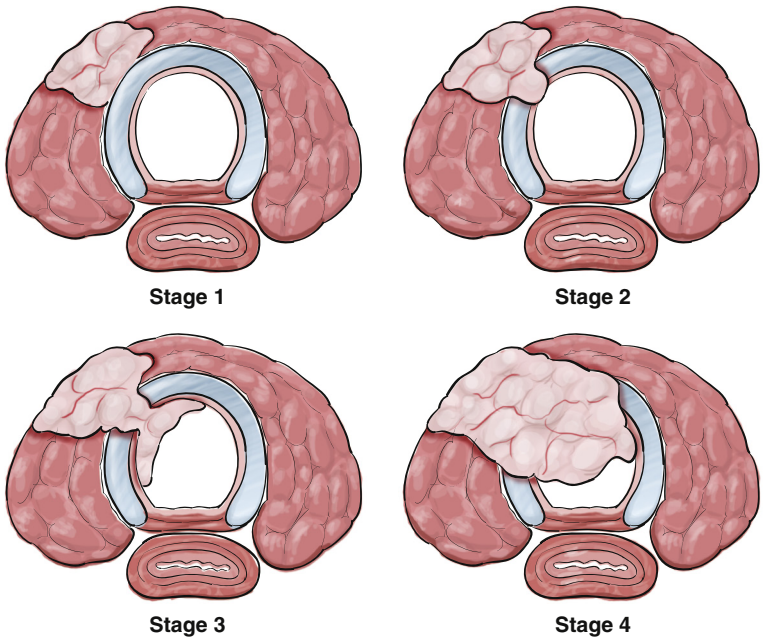

Fig. 82.3. Grading of tracheal invasion from thyroid cancer.

5. Vascular structures
   a. Internal jugular vein IJV is most commonly involved from metastatic lymph node spread rather than primary tumor and should be suspected in bulky lateral lymphadenopathy (Fig. 82.4)
   b. When carotid artery involvement is suspected, evaluation of circle of Willis must be done with angiography

Prerequisite Skills

1. Intimate knowledge of deep neck anatomy and open neck surgical technique
2. Thyroidectomy (see Chapter 78)
3. Neck dissection (see Chapters 64–67)
4. Partial and total laryngectomy (see Chapters 12, 13, 16, 17)
5. Sleeve resection of trachea (see Chapter 22)
6. Pharyngectomy (see Chapter 40)
7. The surgeon should have personal expertise or readily available assistance from surgeons specializing in thoracic surgery, vascular surgery, or microvascular reconstruction if extensive invasion is suspected of confirmed.

Operative Risks

1. Vocal cord paralysis
   a. If the nerve is functional preoperatively, all efforts should be made to dissect and preserve the RLN.
2. Airway obstruction
3. Pharyngeal or esophageal fistula
4. Dysphagia
5. Hypocalcemia
6. Vascular injury

Surgical Technique

1. Surgical approach
   a. Anterior horizontal incision in line of relaxed skin tension if possible
   b. Incision should be extended as needed to incorporate large cancers or allow for lateral neck dissection
      1) McFee incision
      2) Hockey stick or apron incision
   c. Strap muscles may be transversely transected for exposure and should be reapproximated with sutures if uninvolved with tumor on closure.
   d. Median sternotomy may be necessary for substernal extension or for tracheal resection (Fig. 82.5).
      1) Unlike benign thyroid goiters with a substernal component, malignancies with ETE often do not mobilize and require wide exposure.
2. Muscle and skin invasion
   a. Invasion into overlying strap muscles is the most common manifestation of ETE and is often found incidentally.
   b. Bluntly dissect strap muscle off thyroid capsule with Freer, Kittner sponge, or dissecting forceps until invasion is identified.
   c. Simple wide resection with a cuff of normal muscle is adequate.
3. Nerve invasion
   a. The RLN should always be identified and dissected.
      1) Avoid unnecessary devascularization, tension, or pressure on RLN during surgery.
      2) Preoperative paresis or paralysis may be due to compression.
   b. Tumor may be shaved from the RLN if laryngeal function was normal preoperatively
   c. RLN should be resected with tumor specimen en bloc if there is documented preoperative paralysis with confirmed invasion.
   d. RLN should immediately be repaired if sacrificed.
      1) Primary end-to-end neurorrhaphy
         a) For small segments with tension-free approximation
         b) Microscopic magnification should be used.
         c) Nerve ends should be carefully cleaned and prepared.
         d) 9-0 nonabsorbable sutures through epineural sheath to coapt nerve fascicles
      2) Interposition graft
         a) If tension-free approximation not possible
         b) Similar neurorraphy technique
         c) Ansa cervicalis, great auricular nerve, sural nerve are all good potential donor sites
      3) Cross-grafting
         a) Motor branch of ansa cervicalis may be anastamosed to distal RLN stump if proximal stump is unavailable

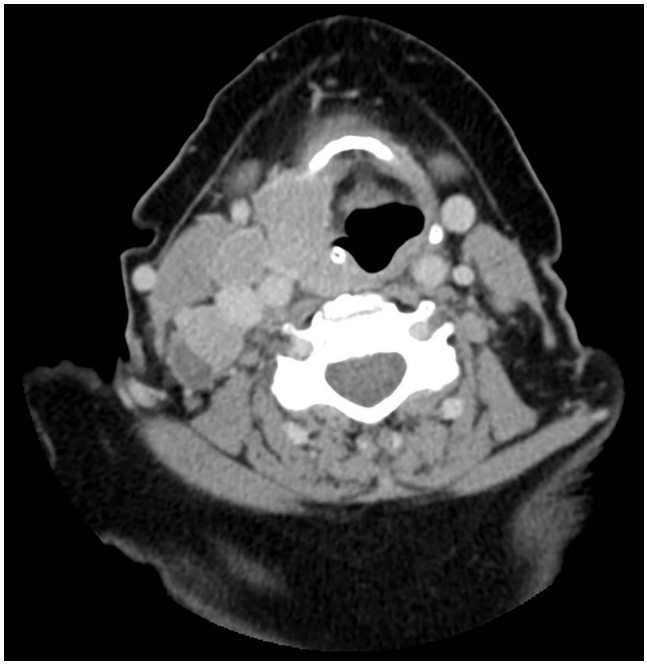

Fig. 82.4. Bulky metastatic cancer in the right lateral neck involving sternocleidomastoid muscle with obliteration of right neck vasculature.

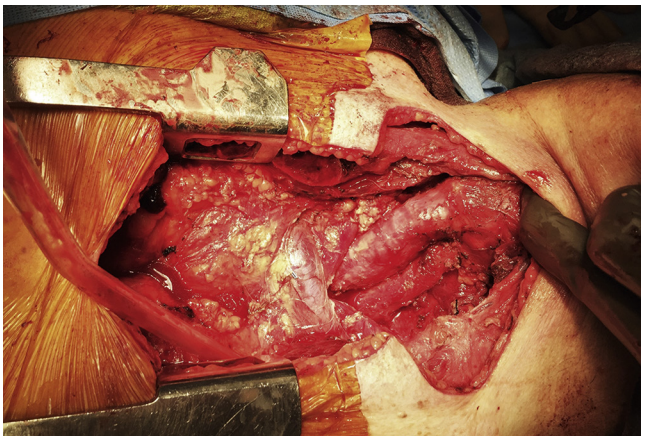

Fig. 82.5. Total thyroidectomy requiring medial sternotomy.

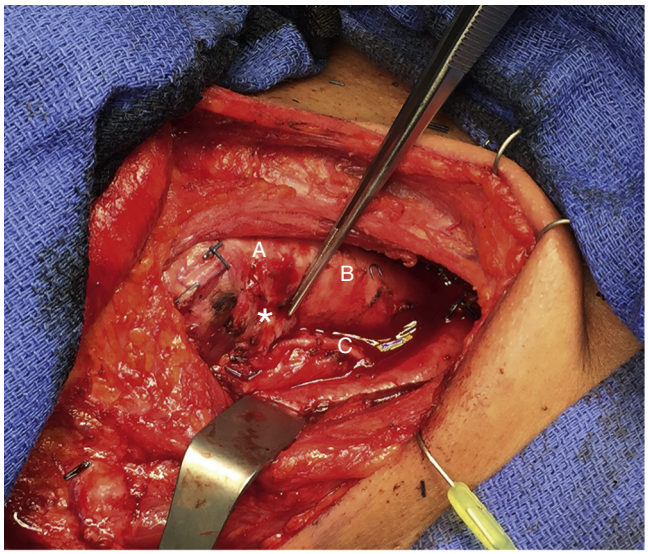

Fig. 82.6. Right thyroid gland (retracted laterally in clamps) with invasion *(asterisk)* and adherence to laryngotracheal complex. **A**, Cricoid, **B,** trachea, **C,** recurrent laryngeal nerve.

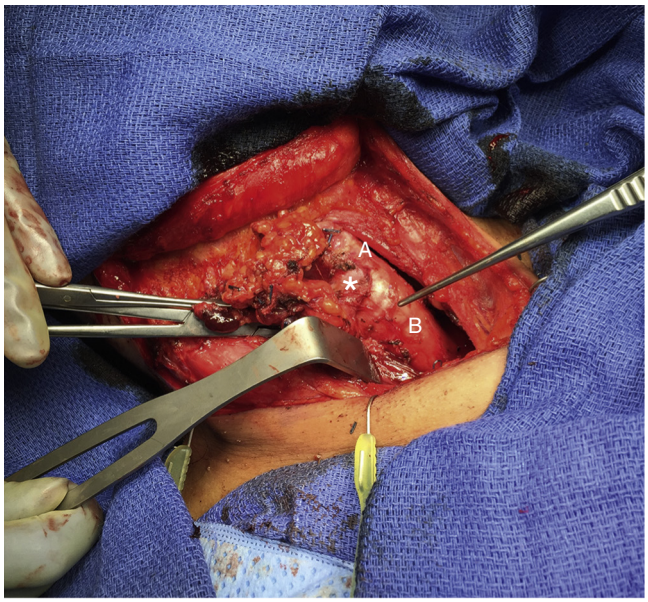

Fig. 82.7. Shave excision *(asterisk)* of thyroid cancer with right-sided laryngeal invasion. **A,** Cricoid, **B,** trachea.

e. Adjunctive laryngeal rehabilitation may be done immediately or at a later time, as necessary.
   1) Vocal cord injection
   2) Medialization thyroplasty
   3) Arytenoid adduction
   4) Neuromuscular pedicle

4. Laryngeal invasion
   a. Direct laryngoscopy rather than simple mirror examination should be done when laryngeal invasion is suspected preoperatively.
   b. Resection of macroscopic tumor off of the thyroid cartilage, cricoid, and cricothyroid membrane (shave resection) may be considered in superficially invasive or adherent tumors (Figs. 82.6 and 82.7).
      1) Impossible to assess true disease extension
      2) Invasive tumors are more likely poorly differentiated and may be less responsive to RAI.
      3) Shave resections have been associated with poorer prognosis and need for repeat surgery.
   c. Negative margin resection may require laryngectomy.
      1) Vertical partial laryngectomy (see Chapter 13)
         a) May be extended as needed if able to preserve one cricoarytenoid unit
         b) Tracheostomy required
         c) Reconstruction may be done with cartilage grafting and strap muscle flap.
      2) Cricoid resection
         a) Up to one-third of cricoid ring
            i) Cartilage reconstruction to prevent airway stenosis
         b) Resection margins involving greater than one-third of cricoid or extension below cricoid cartilage require total laryngectomy.
      2) Total laryngectomy (see Chapter 16)
         a) Indicated for extensive laryngeal involvement or when partial laryngectomy is impractical
         b) May be combined with tracheal resection

5. Tracheal invasion
   a. Bronchoscopy
      1) Should be done prior to resection when tracheal invasion is seen on imaging
      2) Intraluminal findings are a late finding of tracheal invasion, and normal mucosal examinations on bronchoscopy do not rule out involvement of the trachea
   b. Shave excision
      1) Sharply separate tumor from the airway leaving the mucosa of the airway intact.
      2) Typically does not need reconstruction
      3) May be used as in the larynx for ETE adherence or superficial invasion
      4) Impossible to assess extent of true disease
      5) Higher rates of recurrence and need for additional surgery
   c. Tracheal resection
      1) Circumferential tracheal resection
         a) Involved tracheal rings are completely excised en bloc with the cancer.
            i) Up to seven to eight tracheal rings may be resected safely.
         b) Blunt mobilization of the trachea done anteriorly with limited lateral dissection to preserve lateral blood supply
         c) Inferior mobilization carried down to carina
         d) Larynx may be released from the hyoid superiorly
         e) Neck flexion may aid in releasing tension.
         f) Tension-free anastomosis of the trachea should be done with monofilament sutures.
         g) Extraluminal knots should be used to reduce risk of stenosis.
         h) Circumferential resection preferred due to propensity of intraluminal invasion to spread circumferentially along tracheal ring
      2) Window tracheal resection
         a) Only involved anterior tracheal excised with tumor with various options for repair
            i) Resulting defect may be patched with pedicled or free tissue transfer, often sternocleidomastoid muscle
            ii) Sliding tracheoplasty involves wedge resection of lateral portion of window to allow for tension-free primary closure

iii) Window may be stomatized for tracheostomy and staged closure
b) Risks underestimating lateral spread of intraluminal invasion
c) May have less morbidity than circumferential excision

6. Esophageal and pharyngeal invasion
   a. Esophagoscopy
      1) May be done before or at time of surgery to assess the lumen
      2) Low yield due to low rate of intraluminal extension
   b. Resection of muscular layer
      1) Simple wide excision of muscularis layer of esophagus with tumor
      2) Bougie, NGT, or esophageal temperature probe may aid in identifying esophagus and avoiding mucosal defect
      3) Reconstruction is typically not required.
   c. Full-thickness resection
      1) Wide, full-thickness excision of involved intraluminal disease
      2) Small defects in the pharynx or cervical esophagus may be closed primarily in a multilayered fashion.
      3) Larger defects may require a supporting myofascial flap or myocutaneous flap.
      4) Involvement of thoracic esophagus or large circumferential defects may require a gastric pull-up.
7. Vascular invasion
   a. Preoperative CT or MRI angiography should be completed with formal angiography to access cerebral collateral flow if resection of carotid artery is planned.
   b. IJV
      1) Vessel should be dissected, isolated, and controlled distal and proximal to site of invasion
      2) Perform wide resection en bloc with the cancer.
         a) For extensive involvement, sacrifice of IJV should be done.
         b) For focal invasion, noncircumferential resection may be done.
            i) May be repaired primarily for small defects
            ii) Patch angioplasty with autologous vein graft or synthetic material
      3) Suture ligation should be done meticulously to avoid uncontrollable bleeding, especially in the skull base.
      4) Unilateral involvement with patent contralateral IJV requires no reconstruction.
      5) If bilateral sacrifice is necessary or if contralateral IJV flow is absent, one or both veins should be repaired with an autologous vein graft.
         a) Saphenous or femoral vein may be used
         b) Staged resection of IJV may be done to allow for development of collateral flow
   c. Carotid artery
      1) Distal and proximal control of the carotid artery should be done with atraumatic vessel loops.
      2) In most cases, tumor is able to be dissected or peeled from carotid while maintaining the integrity of the vessel
      3) Sacrifice of common or internal carotid should only be done in the following circumstances
         a) Invasion is circumferential (Fig. 82.8) or no dissection plane possible
         b) Cancer = involving the carotid artery is the only barrier to achieving complete resection of disease
         c) Preoperative imaging and counseling have been done with the patient with acceptable risk of neurovascular injury with temporary disruption of cerebral blood flow

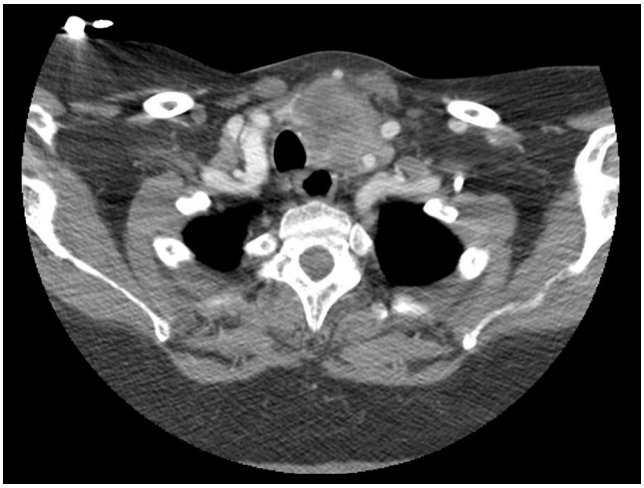

Fig. 82.8. Left thyroid cancer demonstrating encasement of the left common carotid artery on CT.

      4) Limited proximal common carotid resection may maintain cerebral perfusion through external carotid artery backflow
         a) Carotid resection and common carotid artery to Internal carotid artery bypass is often done with polytetrafluoroethylene material or autologous grafts.
      5) If aerodigestive tract resection or communication is involved in the same operation, meticulous protection and separation are essential to avoid carotid blowout.
         a) Local versus regional muscle flaps may be sutured to the prevertebral fascia to separate lateral neck from central visceral compartment

Common Errors

1. Inadequate preoperative index of suspicion and evaluation of the patient
   a. Invasion discovered intraoperatively and surgeon unprepared for necessary surgery
   b. Incorrect surgical planning
   c. Patient counseling incomplete
2. Incomplete evaluation of extent of invasion in the trachea and larynx
3. Failure to have appropriate subspecialty surgical support available

POSTOPERATIVE PERIOD

Postoperative Management

1. Intensive care unit level of care for airway monitoring and ventilation management in cases of major laryngeal, tracheal, and vascular resection and reconstruction
2. Surgical drains for any extensive resection, entry into viscera, or neck dissection
3. Monitoring for hypocalcemia
   a. Serum parathyroid hormone (PTH) should be drawn postoperative if available; alternatively serial serum calcium levels may be monitored.
   b. Calcium supplementation for low PTH <20 pg/mL or downtrending calcium levels
4. Hypothyroidism
   a. Thyroid hormone replacement is necessary in all patients receiving total thyroidectomy.
   b. Thyroid hormone withdrawal or liothyronine may be used in anticipation of RAI.
   c. thyroid-stimulating hormone should be suppressed.

5. Adjuvant treatment
   a. RAI therapy (I-131)
      1) Indicated for iodine avid cases of gross ETE, known residual disease, metastatic disease
      2) An important adjunct treatment if shave resection was used
      3) Maybe have limited efficacy in poorly differentiated histology
   b. External beam radiation
      1) May be considered for:
         a) High-grade histology (unlikely to uptake iodine)
         b) Unresectable gross disease
         c) Cases with extensive invasion
      2) Associated with improved locoregional control
   c. Chemotherapeutic agents
      1) Tyrosine kinase inhibitors have been shown to slow or halt progression of disease in iodine-refractory thyroid cancers
      2) A variety of antineoplastic agents have been described or are being studied with some promise.

Complications

1. Fluid Collection
   a. Hematoma
   b. Seroma
   c. Infection/abscess
      1) Usually indicates leak from luminal structure (trachea, esophagus, pharynx)
   d. Wound-healing issues
2. RLN injury
   a. May be temporary or partial due to dissection or complete in the case of sacrifice
   b. Priority of rehabilitation should be airway first, then swallowing, and lastly phonation
   c. If bilateral paralysis or paresis is present, tracheostomy may be necessary
3. Hypoparathyroidism
   a. Common when total thyroidectomy is done with extensive paratracheal or lateral neck dissection
   b. Monitor postoperative serum PTH and calcium.
   c. A patient with a laryngectomy will not be able to verbalize symptoms.
4. Anastomotic leak
   a. Can be evidenced by signs of neck infection
      1) Increased pain
      2) Erythema and edema of skin
      3) Neck swelling
      4) Suture line dehiscence and discharge
   b. Surgical drain fluid may change in quality.
      1) Can be tested for amylase if diagnosis is equivocal
   c. Can usually be managed conservatively with surgical drain, antibiotics, or packing
   d. Feeding tube should be placed if the leak is from pharynx or esophagus
   e. Breakdown of airway anastomosis can be life threatening
5. Airway stenosis
   a. Typically occurs at the site of anastomosis
   b. Antacid medications, antibiotics, and steroids may be used immediately postoperatively to help to avoid inflammation and scarring.
   c. Serial laryngoscopy and bronchoscopy should be done to monitor healing.
   d. Endoscopic balloon dilations are effective in treating and preventing stenosis.
6. Carotid blowout
   a. May be the result of repair breakdown, infection, or recurrent disease
   b. High index of suspicion when patient presents with heralding "sentinel bleed"
   c. If the diagnosis is made before a catastrophic bleed, treatment includes:
      1) Emergent surgical sacrifice
      2) Endovascular stenting or embolization

Alternative Management Plan

1. Unresectable disease or unsuitable patients may elect to have palliative external beam radiation therapy (EBRT) with or without chemotherapy.
2. Tyrosine kinase inhibitors

DISCUSSION

Evidence-Based Question

What should the extent of surgery be for invasive well-differentiated thyroid carcinoma involving the laryngotracheal complex?

Several series have been published supporting the use of shave resection, citing similar survival rates.[6-8] Proponents of shave resection argue that for short segments of superficial tracheal invasion, shave resection may completely excise the disease and the morbidity of circumferential or window resection is unwarranted given the lack of survival difference. However, the evidence currently available is derived from relatively small series with no prospective randomized trials. It is difficult to interpret these series due to inherent heterogeneity in terms of patient selection, histology, stage, iodine avidity, the use of adjuvant treatment, and number of reoperations for local recurrence. Shave excision precludes assessment of the depth of invasion, which is an important prognostic factor for survival.[2,9,10] Okazi et al. reported a series of 21 cases receiving circumferential tracheal resection for invasive thyroid cancer with pathology revealing extension deep to the peritracheal fascia in 19 cases. Not surprisingly, studies have shown high rates of local recurrence in patients receiving shave excision.[8,10] These patients often require additional adjuvant treatment, reoperation, and often eventual salvage laryngotracheal resection. In general, a central goal of treatment in thyroid cancer is local control in the central compartment. The risks and morbidity of more complete margin-negative resections versus shave resections involving the larynx and trachea must be weighed. Considerations should include the overall status of disease, patient preference, surgeon experience, and treatment goals.

Editorial Comment

The diagnosis of thyroid cancer continues to rise to an estimated 62,000 cases in the United States in 2016. Fortunately invasive thyroid cancer remains relatively uncommon but is responsible for considerable morbidity. Historically, tracheal or esophageal invasion was felt to represent unresectable cancer, and gross tumor was often left behind. With the participation of head and neck oncologic surgeons, thyroid cancer can be treated with aggressive surgical techniques typically reserved for other head and neck cancers, such as laryngeal squamous cell carcinoma. Although considered morbid, treatments such as tracheal resection, esophagectomy, and laryngectomy can confer excellent survival and disease-free control.

Alfred Simental, Jr.

Access the review questions and additional sources list online at http://www.expertconsult.com

REFERENCES

1. Hay ID, Thompson GB, Grant CS, et al. Papillary thyroid carcinoma managed at the Mayo Clinic during six decades (1940–1999): temporal trends in initial therapy and long-term outcome in 2444 consecutively treated patients. World J Surg 2002;26:879–885.
2. Djalilian M, Beahrs O, Devine K, et al. Intraluminal involvement of the larynx and trachea by thyroid cancer. Am J Surg 1974;128:500–504.
3. McCaffrey JC. Aerodigestive tract invasion by well-differentiated thyroid carcinoma: diagnosis, management, prognosis, and biology. Laryngoscope 2006;116:1–11.
4. Urken ML. Prognosis and management of invasive well-differentiated thyroid cancer. Otolaryngol Clin N Am 2010;43:301–332.
5. Ortiz S, Rodriguez JM, Soria T, et al. Extrathyroid spread in papillary carcinoma of the thyroid: clinicopathological and prognostic study. Otolaryngol Head Neck Surg 2001;124:261–265.
6. McCaffrey TV, Bergstralh EJ, Hay ID. Locally invasive papillary thyroid carcinoma: 1940–1990. Head Neck 1994;16:165–172.
7. Tsukahara K, Sugitani I, Kawabata K. Surgical management of tracheal shaving for papillary thyroid carcinoma with tracheal invasion. Acta Otolaryngology 2009;129(12):1498–1502.
8. McCarty T, Kuhn J, Williams W, et al. Surgical management of thyroid cancer invading the airway. Ann Surg Oncol 1997;4:403–408.
9. Shin DH, Mark EJ, Suen HC, et al. Pathologic staging of papillary carcinoma of the thyroid with airway invasion based on the anatomic manner of extension to the trachea: a clinicopathologic study based on 22 patients who underwent thyroidectomy and airway resection. Hum Pathol 1993;24:866–870.
10. Park CS, Suh KW, Min JS. Cartilage-shaving procedure for the control of tracheal cartilage invasion by thyroid carcinoma. Head Neck 1993;15:289–291.

REVIEW QUESTIONS

1. What is the best imaging modality to evaluate extent and location of tumor invasion into surrounding structures?
   a. Ultrasound
   b. CT
   c. MRI
   d. PET

2. What is the recommended management of an RLN adherent to papillary thyroid cancer in a patient with normal preoperative voice and laryngeal function?
   a. En bloc resection of the nerve with end-to-end anastomosis
   b. En bloc resection of the nerve with interposition nerve graft
   c. Attempts at nerve preservation with sharp dissection of tumor off the nerve
   d. En bloc resection of the nerve with ansa to RLN cross-graft

3. What surgical option allows the best chance of local control in tracheal invasion?
   a. Window resection
   b. Shave resection followed by EBRT
   c. Shave resection followed by RAI
   d. Circumferential tracheal resection

ADDITIONAL SOURCES

Honings J, Stephen AE, Marres HA, Gaissert HA. The management of thyroid carcinoma invading the larynx or trachea. Laryngoscope 2010;120:682–689.

Ozaki O, Sugino K, Mimura T, Ito K. Surgery for patients with thyroid carcinoma invading the trachea: circumferential sleeve resection followed by end-to-end anastomosis. Surgery 1995;117:268–271.

Randolph GW, Kamani D. The importance of preoperative laryngoscopy in patients undergoing thyroidectomy: voice, vocal cord function, and the preoperative detection of invasive thyroid malignancy. Surgery 2006;139:357–362.

Rocha AS, Soares P, Fonseca E, et al. E-cadherin loss rather than beta-catenin alterations is a common feature of poorly differentiated thyroid carcinomas. Histopathology 2003;42:580–587.

Shindo ML, Caruana SM, Kandil E, et al. Management of invasive well-differentiated thyroid cancer: an American Head and Neck Society Consensus Statement. Head and Neck 2014;36(10):1379–1390.

83 Intraoperative Parathyroid Hormone Monitoring

Jeffrey Steitz, Jeffrey Bumpous

INTRODUCTION

Parathyroid hormone (PTH) is secreted from the parathyroid glands and is primarily responsible for calcium homeostasis. The mechanism by which this occurs is through renal tubular reabsorption, bone resorption, and formation of calcitriol from calcidiol in the renal tubular cells. The hormone is synthesized as an inactive polypeptide chain, which is then cleaved at the N-terminal in the parathyroid glands to an active form. The half-life of the hormone ranges from 2 to 4 minutes, making it useful for serologic analysis by rapid immunoassay following excision of an abnormally functioning gland.

Primary hyperparathyroidism is a disorder of the parathyroid glands in which excess PTH is secreted. This most commonly results from a single parathyroid adenoma (80% to 85%) or less frequently from four-gland hyperplasia (10% to 15%) or double adenoma (4% to 6%). Rarely, primary hyperparathyroidism can be caused by parathyroid carcinoma (0.1% to 1%).[1] Historically, primary hyperparathyroidism has been treated with a four-gland exploration with removal of abnormal-appearing parathyroid tissue and biopsy verification of normal parathyroid tissue in the case of adenoma versus three and a half gland excision in cases of hyperplasia. However, bilateral neck exploration has a higher incidence of temporary and permanent hypocalcemia, which may lead to longer hospital stays and increased morbidity from symptomatic hypocalcemia. With the advent of improved imaging techniques and radioguided parathyroidectomy, minimally invasive techniques have decreased the morbidity associated with this condition and led to overall better outcomes.

Preoperative imaging with a sestamibi scan has excellent sensitivity in the case of a single parathyroid adenoma. However, in patients who have underlying four-gland hyperplasia or double adenoma, sensitivity decreases significantly to 30% to 44%. This decreased sensitivity may lead to treatment failure and subject patients to an additional surgery. Intraoperative PTH monitoring is a valuable adjunct in the approach to minimally invasive parathyroidectomy. It allows for the rapid detection of PTH prior to and following excision of abnormal-appearing parathyroid tissue. This decreases the need for bilateral neck exploration as well as the overall risk of postoperative hypocalcemia, hematoma, and recurrent laryngeal nerve injury; it also shortens the operative time. Intraoperative PTH monitoring is a rapid assay performed at three intervals throughout the surgery: before incision and at 10 and 15 minutes after excision. If the PTH level drops at least 50% from the highest preincision or preexcision levels, the procedure can safely be concluded without further neck exploration (Table 83.1).[2,3]

In addition to providing immediate feedback during parathyroid surgery, intraoperative PTH monitoring has been used to predict the likelihood of hypocalcemia following total thyroidectomy. Hypocalcemia is the most frequent complication following total thyroidectomy, with a reported incidence of 20% to 50%. Debilitating and permanent hypocalcemia, though less common, can still occur in close to 2% of patients. Historically patients are admitted to the hospital following total thyroidectomy for the monitoring of hypocalcemia, since symptoms can occur within 24 to 48 hours and can be life threatening. Research in the use of PTH levels following total thyroidectomy is ongoing and a consensus on the timing of blood draw and appropriate levels for discharge has not been clearly elucidated. In general, PTH assay results drawn within 6 hours after total thyroidectomy have been found to be the most reliable. Cutoff values for PTH that accurately predict hypocalcemia unfortunately do not exist. Studies have shown that patients who went on to develop hypocalcemia had 70% to 80% declines in PTH as opposed to 20% to 30% declines in patients who remained normocalcemic.[4,5]

KEY OPERATIVE LEARNING POINTS

1. Intraoperative PTH monitoring is a valuable adjunct in minimally invasive parathyroidectomy, especially in the setting of negative preoperative imaging studies.
2. A blood sample can be easily and rapidly collected from the internal jugular vein, peripheral vein, or an arterial line.
3. PTH should be sampled at three separate points: before incision and at 10 and 15 minutes following excision. A greater than 50% decrease in the highest PTH value following excision correlates with complete removal of abnormal parathyroid tissue.

PREOPERATIVE PERIOD

History

1. History of present illness
   a. See Chapter 108 (Parathyroidectomy for Primary Hyperparathyroidism and Non-Localizing Hyperparathyroidism)
2. Past medical history
   a. Medical illness
      1) Bone pain or history of pathologic fracture
      2) History of renal calculi or other renal disorder
      3) Underlying psychologic illness or depression
      4) Generalized weakness, abdominal pain, muscle spasm
   b. Surgery
      1) Previous thyroid or parathyroid surgery
      2) Any other neck surgery
   c. Family history
      1) History of familial hypercalcemia should raise concern for multiple endocrine neoplasia (MEN) syndrome or familial hypocalciuric hypercalcemia
   d. Medications
      1) Calcium supplements
      2) Lithium: may cause hypercalcemia
      3) Antiplatelet drugs
      4) Herbal products
      5) Alcohol

TABLE 83.1 Intraoperative Parathyroid Hormone Assay and Expected Values After Assay Performed

Intraoperative Parathyroid Hormone Assay Performed	Expected Value
Preincision	Varies depending on level of patient hyperparathyroidism
10 minutes postexcision	In successful surgery, a decrease of greater than 50% or at least a trend downward in preincision PTH levels is seen
15 minutes postexcision	With successful surgery, a decrease of greater than 50% in preincision PTH levels is seen

PTH, Parathyroid hormone.

Physical Examination

1. See Chapter 108 (Parathyroidectomy for Primary Hyperparathyroidism and Non-Localizing Hyperparathyroidism).

Imaging

No imaging is required.
Ultrasound
Thyroid ultrasound can be useful for the localization of parathyroid adenoma; however, its utility is limited, especially in the setting of thyroid nodule or multinodular goiter.
Technetium-99 Sestamibi Scan
The sestamibi scan has consistently been shown to be a highly sensitive study in single parathyroid adenoma. However, in the setting of parathyroid hyperplasia or double adenoma the sensitivity significantly decreases to 30% to 44%.
Single photon emission computed tomography (SPECT)
Dual-energy X-ray absorptiometry (DEXA) Scan
The DEXA scan is a useful adjunct in patients with primary hyperparathyroidism who are at high risk for operative intervention. Its utility lies in the diagnosis of osteoporosis or osteopenia, conditions that can lead to a pathologic fracture. In patients without any underlying bone abnormality, some high-risk patients with subclinical hyperparathyroidism can be safely observed.

Indications

1. Intraoperative PTH assessment in parathyroid adenoma, double adenoma, or hyperplasia
2. Postoperative prediction of hypocalcemia following total thyroidectomy. This can be useful in otherwise low-risk patients to determine the likelihood of symptomatic hypocalcemia in the perioperative period.

Contraindications

1. Significant medical comorbidities with elevated perioperative risk
   Patients with significant comorbidities that preclude operative intervention can be monitored for complications associated with hyperparathyroidism, including but not limited to arrhythmias, renal disease, and pathologic fracture.

Preoperative Preparation

1. Assessment of preoperative PTH levels
2. Assessment of preoperative calcium levels
3. Discontinuation of antiplatelet drugs if possible

OPERATIVE PERIOD

Anesthesia

General: Although this procedure can be done with awake sedation, general anesthesia is preferred for patient comfort and protection of the airway if there is active bleeding.
Monitored anesthesia care (MAC)
Local anesthesia

Positioning

Supine. In addition to supine positioning, proper neck extension and shoulder-roll placement are especially important in dissection of the lower neck.
Prone
Lateral recumbent

Perioperative Antibiotic Prophylaxis

First-generation cephalosporin: We prefer cefazolin 1 mg if the patient weighs less than 75 kg or 2 mg if the patient weighs more than that.
Second-generation cephalosporin: Clindamycin if the patient is allergic to penicillin

Monitoring

None
Recurrent laryngeal nerve monitor: Can be a useful adjunct in the identification and preservation of the recurrent laryngeal nerve, especially in revision surgery

Instruments and Equipment to Have Available

1. Basic head and neck surgery set
2. Nerve integrity monitor (NIM) endotracheal tube if monitoring of the recurrent laryngeal nerve is planned
3. In drawing blood for intraoperative PTH assessment, we authors use a 10-mL syringe with an 18-gauge needle placed into the internal jugular vein.

Key Anatomic Landmarks

1. See Chapter 108 (Parathyroidectomy for Primary Hyperparathyroidism and Non-Localizing Hyperparathyroidism) for anatomic landmarks useful in parathyroidectomy.
2. The internal jugular vein lies within the carotid sheath lateral to the thyroid gland.

Prerequisite Skills

1. Parathyroidectomy or total parathyroidectomy; see Chapter 108 (Parathyroidectomy for Primary Hyperparathyroidism and Non-Localizing Hyperparathyroidism).

Operative Risks

1. Intraoperative hemorrhage from the internal jugular vein
2. Venous thrombosis/thrombophlebitis
3. Damage to the recurrent laryngeal nerve
4. Devascularization of normal parathyroid tissue

Surgical Technique

- See Chapters 108 and 102 regarding surgical management in parathyroidectomy and total thyroidectomy.

In performing thyroid and parathyroid surgery, the surgeon should be comfortable in managing the vascular pedicles of the glands. Dissection laterally from the thyroid gland leads to the structures of the carotid sheath. In preparation for venipuncture, the internal jugular vein should be dissected bluntly from the carotid sheath with the assistance of a bipolar cautery. Alternatively a peripheral or arterial line can be used for assays.

- PTH assays should be performed at four intervals:
  - Preincision: from a peripheral source
  - At 10 minutes postexcision: from the internal jugular vein or peripherally
  - At 15 minutes postexcision: from the internal jugular vein or peripherally
- Should the PTH level drop to greater than 50% of the highest preincision value, the procedure can safely be concluded. Should the PTH drop less than 50%, four-gland exploration may need to be performed to rule out double adenoma or four-gland hyperplasia. See Chapter 108 for discussion of four-gland exploration.
- Hemostasis from internal jugular vein venipuncture

Bleeding from the internal jugular vein at the venipuncture site can easily be controlled with digital pressure for 3 to 5 minutes. Alternatively, thrombin-soaked Gelfoam can also be applied. Rarely, suture repair or ligation may have to be performed.

Common Errors in Technique

1. Laceration of the internal jugular vein during venipuncture
2. Failure to recognize underlying renal disease

PTH is a rapidly metabolized hormone with a half-life of 2 to 4 minutes in a normal person. Underlying renal disease can be common in patients with hyperparathyroidism and may prolong the half-life of PTH.

POSTOPERATIVE PERIOD

Postoperative Management

1. Routine postoperative care for patients undergoing parathyroidectomy or thyroidectomy (see Chapters 102 to 106 and 108 to 110)
2. In patients who undergo PTH assay following total thyroidectomy, should the PTH level drop significantly, the patient should be monitored in the hospital for hypocalcemia. In contrast, low-risk patients without a significant decrease in PTH may be discharged on a case-by-case basis.
3. After parathyroidectomy, should the PTH fail to drop more than 50% and four-gland exploration is performed, monitoring for hypocalcemia as an inpatient will be required.

Complications

1. Hemorrhage from the venipuncture site in the internal jugular vein

   This can occur if the venipuncture needle lacerates the internal jugular vein, leading to a larger rent in the vessel. If pressure does not control the hemorrhage, primary repair can be performed with a 5-0 or smaller vascular prolene suture. Rarely, if the laceration in the vein becomes enlarged by attempts at control and is unsalvageable, the internal jugular vein can be sacrificed. This can be done with 2-0 silk ties or medium hemoclips.
2. For complications related to parathyroidectomy and thyroidectomy, see Chapters 102 to 106 and 108 to 110.

Alternative Management Plan

1. Minimally invasive radioguided parathyroidectomy

   Use of radiolabeled tracer in parathyroid surgery detected by the gamma probe is another useful adjunct in minimally invasive surgical approaches to the parathyroid gland. This does not exclude intraoperative PTH assay and can be used in conjunction with it.
2. Four-gland exploration

   Historically four-gland exploration was the standard for primary hyperparathyroidism. There is unfortunately an increased risk of complications and the need for repeat surgery in the event of four-gland hyperplasia.

DISCUSSION

Evidence-Based Medicine Question

Why perform intraoperative assays at 10 and 15 minutes postexcision?

Once the intraoperative PTH assay was developed and validated, several criteria were developed to determine the most sensitive and accurate times for assay. The accepted criterion is known as the Miami criterion and has a sensitivity and overall accuracy of 97%. Additionally the positive predictive value is 99% and negative predictive value 88%. The criterion itself is an equal to or greater than a 50% decrease from the highest preexcision PTH value at 10 minutes. When several criteria were compared, the Miami criterion showed significantly fewer false-negative results (2.6% vs. 6% to 24%), making it the most accepted method. PTH assays done at longer time intervals (>15 minutes) have been shown to increase operating time as well as the likelihood of false-negative results.

Editorial Comment

The PTH assay has greatly influenced modern parathyroid surgery, resulting in shorter operative times and greater surgical success. Outpatient thyroid surgery has also used rapid PTH assays to predict potential hypocalcemia in postoperative patients.

Alfred Simental, Jr.

Access the review questions and additional sources list online at http://www.expertconsult.com

REFERENCES

1. Ruda JM, Hollenbeak CS, Stack BC. A systematic review of the diagnosis and treatment of primary hyperparathyroidism from 1995-2003. Otolaryngol Head Neck Surg 2005;132(3):359–372.
2. Ozimek A, Gallwas J, Stocker U, et al. Validity and limits of intraoperative parathyroid hormone monitoring during minimally invasive parathyroidectomy: a 10-year experience. Surg Endosc 2010;24:3156–3160.
3. Fraker DL, Harsono H, Lewis R. Minimally invasive parathyroidectomy: benefits and requirements of localization, diagnosis and intraoperative PTH monitoring: long-term results. World J Surg 2009;33:2256–2265.
4. Lee DR, Hinson AM, Siegel ER, et al. Comparison of intraoperative versus postoperative parathyroid hormone levels to predict hypocalcemia earlier after total thyroidectomy. Otolaryngol Head Neck Surg 2015;153(3):343–349.
5. Grodski S, Serpel J. Evidence for the role of perioperative PTH measurement after total thyroidectomy as a predictor of hypocalcemia. World J Surg 2008;32:1367–1373.

REVIEW QUESTIONS

1. A PTH assay should be performed at all of the following times during minimally invasive parathyroidectomy EXCEPT
   a. Preincision
   b. 10 minutes postexcision
   c. 2 hours postexcision
   d. 15 minutes postexcision

2. Postexcision levels of PTH should drop by what percentage to be considered safe to conclude the operation?
   a. ≥10%
   b. ≥30%
   c. ≥75%
   d. ≥50%

3. Following total thyroidectomy, a PTH level drawn within what time frame can be useful to determine likelihood of postoperative hypocalcemia?
   a. At 6 hours
   b. At 10 minutes
   c. At 4 hours
   d. At 24 hours

ADDITIONAL SOURCES

Carneiro DM, Solorzano CC, Nader MC, et al. Comparison of intraoperative iPTH assay (QPTH) criteria guiding parathyroidectomy: which criterion is the most accurate? Surgery 2003;134(6):973–979.

Irvin 3rd GL, Dembrow VD, Prudhomme DL. Operative monitoring of parathyroid gland hyperfunction. Am J Surg 1991;162(4):299–302.

84 Parathyroidectomy for Primary Hyperparathyroidism and Nonlocalizing Hyperparathyroidism

Joshua S. Park, Alfred Simental, Jr.

INTRODUCTION

The parathyroid glands are usually found adjacent to the thyroid gland and produce parathyroid hormone (PTH), which increases serum calcium levels by enhancing bone resorption, increasing calcium reabsorption in the distal tubules of the kidneys, and converting calcidiol to the active calcitriol form of vitamin D, which stimulates intestinal calcium absorption. About 85% of the population have two superior (4th pouch) and two inferior (3rd pouch) parathyroid glands, embryologically originating from the dorsal portion of the respective pharyngeal pouches. Supernumerary (more than four) parathyroid glands may occur in up to 15% of the population, and 1% to 3% of parathyroid glands are ectopic.[1]

Primary hyperparathyroidism (PHPT) affects up to 0.5% of the US population and is 4 times more common in females. When sporadic, PHPT is most commonly associated with parathyroid adenoma (80% to 90% of cases) (Fig. 84.1), glandular hyperplasia (6% to 15%) (Fig. 84.2), double adenomas (2% to 5%), and carcinoma (<5%).[1] Familial conditions such as multiple endocrine neoplasia (MEN) type 1, MEN type 2A, and familial isolated hyperparathyroidism are also associated with PHPT. Radiation exposure and genetic defects in cyclin D1 (PRAD) oncogene, MEN1, and Cyclin dependent kinase inhibitory B (CDKN1B) have been identified as risk factors for the development of adenomas and hyperplasia, but there are many yet unknown factors that cause PHPT. Parathyroidectomy is the only curative treatment for patients with PHPT.

KEY OPERATIVE LEARNING POINTS

- Superior parathyroid glands are most commonly located on the posterolateral aspect of the upper two-thirds of the thyroid lobes. Their location can be estimated 1 cm above and below the intersection between the recurrent laryngeal nerve (RLN) and the inferior thyroid artery.
- Inferior parathyroid glands are most commonly found in the thyrothymic tract at the level of the inferior aspect of the thyroid lobes.
- The RLN is almost always anterior to the superior parathyroid glands and usually posterior to the inferior parathyroid glands.
- Focused approaches to parathyroidectomy are made possible by preoperative localization of the hyperfunctioning parathyroid gland and intraoperative PTH monitoring.

PREOPERATIVE PERIOD

History

1. History of present illness
   a. Most patients with PHPT are asymptomatic, but many have nonspecific symptoms such as fatigue, weakness of the proximal extremities, diffuse bone pain, anorexia, and constipation.
   b. Symptoms of hypercalcemia
      1) Urinary system: Polydipsia, polyuria, nephrolithiasis
      2) Skeletal system: Osteopenia, osteoporosis, or osteitis fibrosa cystic, which presents with bone pain, pathologic fractures, and/or "brown tumors"
      3) Gastrointestinal system: Peptic ulcer disease (PUD), pancreatitis, cholelithiasis
      4) Cardiovascular system: Hypertension, arrhythmias, embolic events
      5) Neurologic system: Depression, anxiety, cognitive dysfunction, psychosis
   c. Symptoms of coexistent thyroid disease
      1) Compressive symptoms such as dysphagia, hoarseness, cervical pressure, globus sensation
2. Past medical history
   a. Previous treatment of PHPT
   b. History of radiation therapy to the neck
   c. Medical illnesses, to determine candidacy for surgery
   d. Past surgical history, especially operations on the neck
3. Family history: Thyroid or parathyroid disease, familial isolated hyperparathyroidism, MEN type 1 or 2A, or familial hypocalciuric hypercalcemia
4. Medications
   a. Anticoagulants and antiplatelet medications
   b. Lithium or thiazide diuretics
      1) May cause mild hypercalcemia and hyperparathyroidism, so discontinue for at least 1 month before confirming PHPT.
   c. Allergies to antibiotics

Physical Examination

1. Neck
   a. Examination findings are nonspecific
   b. Assess for thyroid nodules and cervical adenopathy.
   c. A palpable mass in the neck in the patient with hypercalcemia may indicate parathyroid carcinoma.
2. Laryngoscopy
   a. Assess preoperative RLN function.
   b. Essential prior to reoperation

Laboratory

1. Most cases of PHPT are diagnosed following an incidental finding of elevated serum calcium.
2. Calcium, total vitamin D, and PTH should be measured together.
3. Measure 24-hour urine calcium excretion in order to distinguish PHPT from familial hypocalciuric hypercalcemia.
4. Other laboratory abnormalities in PHPT include hypophosphatemia and mild hyperchloremic acidosis secondary to renal involvement.
5. Use creatinine and blood urea nitrogen (BUN) to rule out renal insufficiency.
6. Patients who have had gastric bypass surgery should have calcium challenge to assure absorptive ability.

Imaging

1. Preoperative imaging/localization results in
   a. Increased operative success
   b. Decreased surgical risk/extent of dissection
   c. Decreased operative time

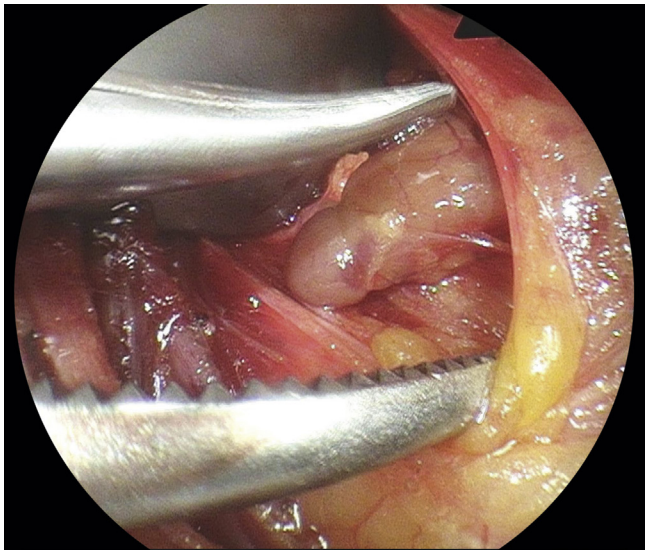

Fig. 84.1. Parathyroid adenoma.

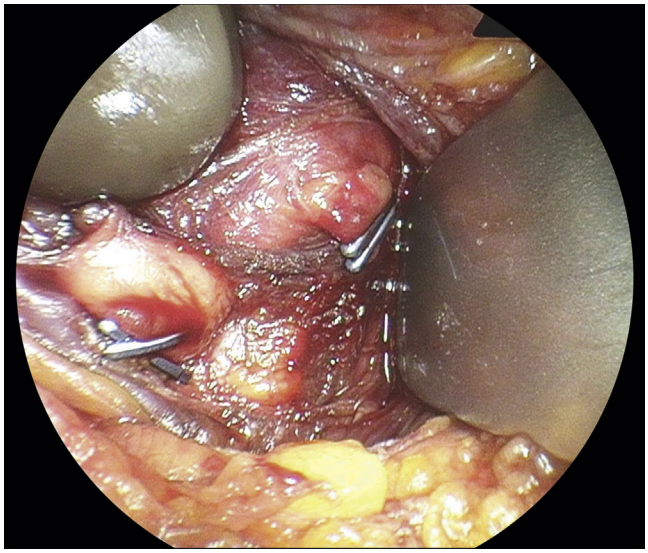

Fig. 84.2. Parathyroid hyperplasia. Surgical clips have been placed on the parathyroid glands.

2. Imaging is particularly important prior to reoperation.
3. Imaging guides the operative approach.
4. Imaging has no role in the diagnosis of PHPT.
5. Imaging options:
   a. Ultrasound
      1) Parathyroid adenomas have a homogeneous hypoechoic appearance on ultrasound.[1]
      2) Ultrasound has emerged as the preferred initial preoperative localization method for many surgeons and endocrinologists.
      3) Ultrasound can screen for concomitant thyroid lesions that require surgical intervention, though the sensitivity of ultrasound is diminished in those with concurrent thyroid disease.
      4) As in other applications, the major limitation of sonography is that accuracy is operator-dependent.
   b. Technetium-99m sestamibi scintigraphy (Fig. 84.3)
      1) Sestamibi scintigraphy has been the traditional standard for preoperative localization.

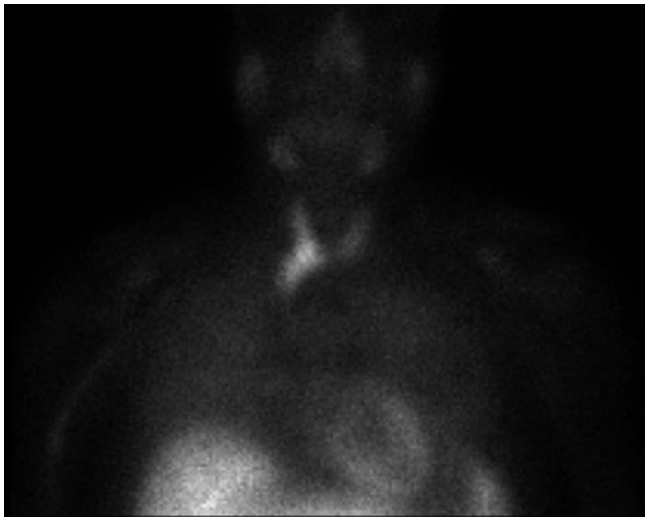

Fig. 84.3. Sestamibi scintigraphy. This scan shows increased activity on the right. In the presence of hypercalcemia, this finding suggests a parathyroid adenoma.

      2) Planar images[2] are captured after the injection of the radiotracer technetium-99m-methoxyisobutylisonitrile (MIBI), which is taken up preferentially by the mitochondria of the cells of the hyperfunctioning parathyroid gland(s).
6. Patients with familial hyperparathyroidism, MEN type 1, and MEN type 2A only need ultrasound to screen for coexistent thyroid disease because they will undergo four-gland exploration.

Invasive Localization

1. Invasive localization techniques may be employed if previous imaging is nonlocalizing or conflicting.
2. Selective venous sampling and arteriography effectively localize pathologic parathyroid glands.
   a. Associated with risks such as hematoma of the groin, possible embolic events, and contrast-induced anaphylaxis or acute kidney injury
3. Fine-needle aspiration of a parathyroid mass under ultrasound guidance can confirm location by measuring PTH in aspirate.

INDICATIONS

1. Symptomatic PHPT, including parathyroid crisis
2. Familial PHPT
3. Suspicion for parathyroid cancer
4. Presence of thyroid disease that can be surgically treated at the same time as PHPT
5. Asymptomatic PHPT patients in whom at least one of the following is true[3]:
   a. Age less than 50 years
   b. Serum calcium greater than 1 mg/dL above the upper limit of normal
   c. Bone mineral density T score less than −2.5
   d. Vertebral fracture
   e. Creatinine clearance less than 60 mL/minute or reduced more than 30% for age
   f. Twenty-four-hour urine calcium greater than 400 mg/dL
   g. Nephrolithiasis or nephrocalcinosis on imaging

CONTRAINDICATIONS

1. Contralateral RLN injury
2. Symptomatic cervical disc disease
3. Other comorbidities that preclude surgery

PREOPERATIVE PREPARATION

1. Discontinue antiplatelet and anticoagulation medications
2. An important factor for surgically curing PHPT and minimizing morbidity is correctly determining the extent of the surgery that should be performed
   a. Minimally invasive parathyroidectomy (MIP), which generally consists of successful preoperative localization, cervical block anesthesia, a smaller incision, and intraoperative PTH monitoring, results in complication and cure rates equal to or better than traditional bilateral neck exploration (BNE)[4] and may reduce costs.
      1) The success rate of parathyroidectomy for PHPT, via either MIP or traditional BNE, approaches 95% to 97% in experienced, high volume surgical centers.
   b. Video-assisted (endoscopic) parathyroidectomy is a minimally invasive technique that has excellent safety and outcomes.
      1) It is performed under local or general anesthesia with intraoperative PTH monitoring in patients with positive preoperative localization of a single adenoma.
      2) Video augmentation with 30-degree endoscopes provides optimal illumination and magnification.
      3) Potential benefits include improved cosmesis and reduced postoperative cervical discomfort.
   c. Bilateral cervical exploration remains the first-line option for certain subsets of the PHPT population:
      1) Patients with nonlocalizing, equivocal, or contradicting preoperative imaging
      2) Suspected multiglandular disease; most hereditary forms of PHPT cause multiglandular disease:
         a) MEN type 1
            i) Subtotal parathyroidectomy, which consists of the removal of three and a half glands, or total parathyroidectomy with autotransplantation
            ii) Thymectomy is also performed, since the thymus is the most common site of supernumerary parathyroid glands, which are common in MEN type 1.
            iii) It is important to diagnose MEN preoperatively because undiagnosed patients may undergo MIP instead of BNE, likely resulting in operative failure.
         b) MEN type 2A
            i) Usually BNE with resection of enlarged glands, but some prefer subtotal or total parathyroidectomy
         c) Familial isolated hyperparathyroidism
            i) Subtotal or total parathyroidectomy and thymectomy
         d) Familial neonatal hyperparathyroidism
            i) Treat urgently with total parathyroidectomy and thymectomy.
      3) Failure of intraoperative PTH to normalize after unilateral exploration
      4) Concurrent indication for thyroidectomy
   d. Despite the high success rate of parathyroidectomy, the surgeon's experience and expertise are invaluable in parathyroid surgery.
      1) When a minimally invasive procedure is chosen as the initial approach, the surgeon must know when and how to convert the procedure to a BNE.
         a) The most common reasons for conversion are incorrect preoperative localization, failure of normalization of intraoperative PTH, and intraoperative evidence of multiglandular disease.

OPERATIVE PERIOD

Anesthesia

- Parathyroid surgery is generally performed under general endotracheal anesthesia.
- MIP, in cases involving a well-localized single adenoma in patients without a history of neck surgery, may be completed using a superficial cervical plexus block with conscious intravenous sedation.
  - Similar cure and complication rates while reducing postoperative pain and nausea
  - Significant risk for conversion to general anesthesia, most commonly due to intraoperative discovery of concurrent thyroid pathology or multiglandular parathyroid disease

Positioning

- Position the patient in the supine position, and tilt the head of bed to 30 degrees in reverse Trendelenburg to enhance venous drainage from the head and neck.
- Augment slight neck extension by placing a small roll under the scapulae.

Perioperative Antibiotic Prophylaxis

- Perioperative antibiotics are not required in clean neck surgeries such as parathyroidectomy and can be limited to a single preincision dose.

Monitoring

- Routine anesthesia monitoring
- Generally no neural intraoperative monitoring is necessary, but may be used depending on surgeon preference.

Instruments and Equipment to Have Available

- Basic head and neck set
- Ultrasonic scalpel for thyroidectomy
- Monopolar and bipolar cautery
- Kittner/peanut sponges for blunt dissection, retraction, and protection of nerves from thermal energy
- Babcock forceps are helpful in grasping and retracting thyroid tissue.
- McCabe dissector
  - Its curved, precise, nonlocking tips are excellent for identification and dissection of nerves.
- Surgical clips should be available.
- Mahorner, Lone Star, or Weitlaner self-retaining retractors may be helpful if an assistant is not available.

Key Anatomic Landmarks

- RLN
  - The right RLN originates from the vagus nerve at the level of the subclavian artery and transversely travels toward the trachea, entering the tracheoesophageal groove before eventually entering the larynx near the first tracheal ring.
  - The left RLN originates from the vagus nerve at the level of the aortic arch and travels more directly cranially toward the tracheoesophageal groove to enter the larynx.

PREREQUISITE SKILLS

- Intricate knowledge of surgical instrument use and meticulous soft tissue/neural dissection
- Experience with thyroid surgery

OPERATIVE RISKS

- Injury to the RLN
  - The nerve does not always need to be identified and traced but should be visualized and consciously protected if exploration involves the paraesophageal and retroesophageal spaces.
  - RLN monitoring via electromyography may aid in nerve localization but has not altered the incidence of postoperative vocal fold paresis.
- Incidental excision of normal parathyroid gland tissue
  - Verify parathyroid tissue by frozen section and then mince the tissue into 1 mm pieces and autotransplant into sternocleidomastoid or strap muscles.

SURGICAL TECHNIQUE

- Draw preoperative PTH level.
  - Collect blood samples from peripheral venous or arterial access because central venous samples may result in falsely elevated PTH levels if drawn ipsilateral to an adenomatous gland.
- After injecting local anesthetic, make a Kocher skin incision between the cricoid and suprasternal notch, ideally in a relaxed skin crease.
  - In BNE, place a 3- to 5-cm incision in the midline.
  - In MIP, the incision can be smaller and lateralized to the suspected side.
- Raise subplatysmal flaps transversely.
- Divide the median raphe longitudinally to reveal and split the strap muscles in the midline, retracting laterally from the thyroid gland, which is retracted medially.
  - Thyroid vein ligation aids mobilization of the thyroid lobe.
- Rotate the thyroid medially in order to visualize the entire posterior aspect of the gland and identify parathyroids on the posterior capsular surface.
- Continue dissection in order to visualize the carotid artery, paratracheal region, and retrothyroid space.
- Identify RLN and trace it inferiorly to the carotid artery and superiorly to the cricothyroid muscle.
- Search for parathyroid glands (Video 84.1).
  - Utilize visualization and palpation to detect the glands.
    - Normal parathyroid glands are about the size of a grain of rice or lentil and weigh 30 to 50 mg.
    - Do not remove normal parathyroid glands, even if an enlarged parathyroid is not found.
    - Regardless of pathology, parathyroid glands can vary in color.
      - Normal parathyroid glands are usually light brown compared to adipose tissue, which is yellow.
      - A white, firm parathyroid gland should raise suspicion for carcinoma.
    - Non malignant parathyroid glands have greater mobility than thyroid nodules and perithyroidal lymph nodes.
  - In MIP, attempt to find the enlarged gland that was identified on preoperative imaging.
  - In BNE, surgeon preference determines the order in which the search is conducted, but it should be systematic and consistent.
- Locating superior parathyroid glands
  - Embryologically, the superior parathyroid glands arise from the fourth branchial pouch and migrate caudally with the thyroid lobe.
  - Most commonly found on the posterolateral surface of the upper two-thirds of the thyroid lobe, in proximity to the cricothyroid junction
    - This position is approximated about 1 cm above and below the intersection of the RLN and the inferior thyroid artery
  - Less common locations include the piriform sinus, tracheoesophageal groove, and the paraesophageal/retroesophageal spaces (Fig. 84.4)
- Locating inferior parathyroid glands
  - The inferior glands are derived from the dorsal wing of the third branchial pouch and have greater variability in location due to the longer path of embryologic descent, which is paired to the thymus.
  - Most commonly found in the anterior mediastinal compartment, often associated with the thymus or the inferior portion of the thyroid lobe
  - Missing inferior glands should be sought near the thymus and superior mediastinum (see Fig. 84.4).
- Adjunctive intraoperative techniques can help localize an occult gland
  - Radio-guided probe: Technetium-99m–labeled sestamibi is injected 2 hours prior to surgery to allow concentration into the hyperfunctioning gland; a handheld gamma probe is used to guide incision placement, depending on greatest radioactivity, and to survey the postexcisional surgical site for remnant parathyroid tissue.

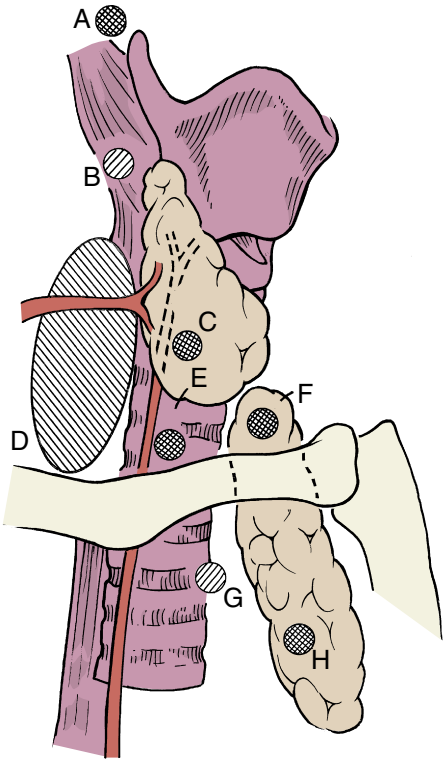

Fig. 84.4. Ectopic locations of the superior (B, partially descended; D, tracheoesophageal groove; G, mediastinal) and inferior (A, undescended; C, intrathyroid; E, mediastinal outlet; F, intrathymic; H, anterior mediastinal) parathyroid glands.

    - Limited by its inability to exclude multiglandular disease, and the fact that thyroid nodules may take up the technetium-99m and cause false positive results
  - Methylene blue: Intravenous injection can augment visual localization
    - Typically reserved for reoperative cases, in large part due to the risk of neurotoxicity
  - Jugular vein sampling of PTH levels may help lateralize the hyperfunctioning gland.
- Once an enlarged parathyroid gland is identified, dissect it circumferentially from surrounding structures before sealing the vessels (Video 84.2).
  - Parathyroid adenoma and hyperplasia are shown in Figs. 84.1 and 84.2, respectively.
- Excise the parathyroid gland and send for frozen section analysis in order to confirm that it was indeed parathyroid tissue that was removed.
- Deciding whether to discontinue exploration should only occur after identification of at least one abnormal and one normal gland or use of PTH.
- Intraoperative PTH monitoring may also guide the decision to conclude surgery.
  - The short half-life of PTH (3 to 5 minutes) allows for rapid assay techniques that can be completed within 20 minutes.
  - Intraoperative PTH monitoring allows for less extensive surgeries,[4] reduces costs, and results in excellent outcomes, even for reoperative parathyroidectomy and surgery performed for patients with nonlocalizing scans.
  - The Loma Linda University protocol requires the measurement of four intraoperative PTH levels: preincision, and 10-, 15-, and 20-minute postexcision levels.
    - A PTH decrease of greater than 50% compared to the preincision level within 10 minutes after gland excision suggests the patient is cured.
    - The 15- and 20-minute levels should continue to significantly drop, as leveling off in the slope of decline is worrisome for persistent disease.
  - The incision may be closed while awaiting the results of the PTH assay, but the patient should remain under anesthesia until satisfactory levels are reached.
  - An unchanged PTH level likely signifies the failure to remove abnormal parathyroid tissue.
  - PTH levels do not need to be drawn after the removal of each parathyroid gland if BNE had been planned.
- If further surgical dissection is warranted based on PTH testing, then explore the ipsilateral side to find the other parathyroid gland on that side.
  - Enlargement of this second gland is further evidence of multiglandular disease.
    - In this case, explore all four glands and perform subtotal parathyroidectomy.
    - Surgical clips should be placed to aid in localization of parathyroid glands left in situ, especially in cases of suspected hyperplasia (see Fig. 84.2).
- Over 95% of adenomatous parathyroid glands are removed transcervically, but a median sternotomy may be necessary if a mediastinal enlarged gland is inaccessible through the neck.
- Conclude the procedure by reapproximating the strap muscles and platysma with interrupted absorbable sutures, and close the skin with a running subcuticular absorbable suture or adhesive Steri-Strips.

Common Errors in Technique

- Poor hemostasis resulting in staining of the surgical field
  - The plane between the strap muscles and thyroid capsule is particularly vascular.
    - Use careful blunt dissection during exploration.
- Insufficient visualization of common parathyroid gland locations.
  - Enhance medial retraction of the thyroid lobes by ligating the middle thyroid veins.
  - Open the fascial sheath (pretracheal fascia) to access the paraesophageal and retroesophageal spaces.
- Devascularization or removal of normal parathyroid glands.
  - These should be identified intraoperatively and the glands autotransplanted.

POSTOPERATIVE PERIOD

Postoperative Management

1. Mild analgesics are generally adequate following parathyroid surgery.
2. The first postoperative visit, which should occur within 2 weeks of surgery, includes laboratory tests such as calcium, PTH, and vitamin D.
   a. TSH may be checked as well, since parathyroidectomy is a risk factor for thyroid dysfunction.
3. PTH and calcium should be measured again 6 months after surgery to confirm a cure.
4. Bone mineral density should be measured about 18 months after surgery.

Complications

1. Operative failure
   a. The goal of parathyroid surgery is to induce eucalcemia that lasts at least 6 months after the operation.
   b. Persistent or recurrent hyperparathyroidism is the most common complication, occurring in up to 5%.
   c. Given the increased difficulty and complication rates associated with re-exploration of the neck, extensive preoperative evaluation is appropriate.
      1) The PHPT diagnosis should first be confirmed via serum testing, ruling out other causes of hypercalcemia.
      2) Reoperative parathyroid surgery is associated with a higher rate of supernumerary and ectopic glands.
         a) Optimally, two preoperative imaging techniques should be utilized to congruently localize the hyperfunctioning gland.
         b) MRI and 4-D CT are useful for localizing ectopic glands and identifying mediastinal disease if previous imaging studies are nonlocalizing.
         c) Invasive venous sampling and arteriography, which are employed more commonly in these patients compared to those without prior cervical surgery, are effective secondary options.
      3) Assess RLN function with laryngoscopy.
   d. Reoperative surgery
      1) Even in reoperation, the most common cause of hyperparathyroidism is a single adenoma, so a focused approach may be appropriate with positive localization.
      2) The incision can be placed medially, which offers a direct approach, or laterally, which helps avoid the previous surgical field.
      3) The search for abnormal glands is carried out in a fashion opposite to first-time operations.
         a) Dissection should start laterally and work medially in an attempt to avoid scarred regions.
   e. Reoperation results in similar success rates as initial procedures when performed by experienced surgeons.
2. Cervical hematoma
   a. Evacuation of a cervical hematoma is required in less than 1% of all parathyroidectomy patients.

3. Hypocalcemia
   a. Presents with paresthesias and numbness but can progress to life-threatening tetany, seizures, and arrhythmias.
   b. Treatment involves oral calcium and calcitriol; intravenous calcium may be administered if the patient remains symptomatic despite oral supplementation.
4. RLN injury
   a. If suspected, assess vocal folds with direct laryngoscopy.
   b. Bilateral RLN injury presents with difficulty breathing and stridor shortly after extubation.
      1) If immediate reintubation is unsuccessful, emergent tracheostomy should be performed.
   c. Unilateral RLN injury can usually be managed with speech therapy and medialization of the vocal fold.
5. Wound infection
   a. Remove sutures and perform incision and drainage.
   b. Provide a short course of systemic antibiotics.
6. Thyroid dysfunction
   a. Occurs due to manipulation of the thyroid gland during surgery
   b. Presents with hyperthyroidism in the immediate postoperative phase, but hypothyroidism may result long term

ALTERNATIVE MANAGEMENT PLAN

- Parathyroidectomy is the only cure for PHPT, but there are alternative options for poor surgical candidates.
  - Bisphosphonates may be used to protect bone mineral density.
  - Calcimimetics such as cinacalcet can help decrease PTH secretion, thereby decreasing serum calcium.
  - Angiographic ablation, ethanol ablation, and laser ablation may result in transient or durable reduction in serum calcium.
  - Aggressive hydration may help decrease serum calcium but will not prevent osteoporosis.
- Nonsurgical patients with PHPT should be regularly monitored for serum calcium, bone mineral density, and renal function.[3]

DISCUSSION

Evidence-Based Medicine Question: What Is the Best Method for Preoperative Localization?

Sestamibi scintigraphy (see Fig. 84.3) has been the traditional method for preoperative parathyroid imaging. Sensitivity for correct lateralization of the hyperfunctioning gland with this modality varies widely, but most report rates above 70%. Unfortunately, this leaves a significant cohort with nonlocalizing scans, even when the etiology is a single adenoma. When performed by experienced surgeons, ultrasound may be more sensitive than planar sestamibi,[5] even in the presence of multiglandular disease. Therefore, some believe that sonography is more convenient, less invasive, and results in health care savings compared to scintigraphy. However, sonography is limited by operator dependence, and patient factors such as gland size, body mass index, and serum calcium can further impact its accuracy.[5] Sonography and planar sestamibi scintigraphy are less reliable in those with multiglandular disease, smaller parathyroid adenomas, and coexisting thyroid pathology. A combination of these two relatively inexpensive, minimally invasive techniques likely results in the best outcomes, since concurrence between ultrasound and planar sestamibi results indicates excellent accuracy.

Sestamibi single-photon emission computed tomography (SPECT) produces three-dimensional images that enhance the detection of multiglandular disease and ectopic parathyroid glands, but may miss multiglandular disease in a significant number of cases. Sestamibi SPECT combined with CT provides excellent localization, but is expensive and requires significant radiation exposure.[2] Four-dimensional CT with intravenous contrast has the ability to accurately localize the abnormal gland to the correct quadrant. Magnetic resonance imaging (MRI) is another option that is most appropriate if ultrasound and sestamibi scintigraphy do not provide definitive localization. Abnormal parathyroid glands usually appear hypointense on T1 and hyperintense on T2.

Editorial Comment

Parathyroidectomy remains the only definitive treatment for PHPT and with proper experience and planning is expected to yield a high success rate with a low complication rate. A robust knowledge of thyroid and parathyroid embryology and anatomy will aid the surgeon. Fortunately, advances in imaging and intraoperative serology have aided the surgeon in improving success and decreasing operative time.

Joshua S. Park and Alfred Simental, Jr.

Access the review questions and additional sources list online at http://www.expertconsult.com



REFERENCES

1. Lee L, Steward DL. Techniques for parathyroid localization with ultrasound. Otolaryngol Clin North Am 2010;43(6):1229–1239.
2. Mandal R, Muthukrishnan A, Ferris RL, et al. Accuracy of early-phase versus dual-phase single-photon emission computed tomography/computed tomography in the localization of parathyroid disease. Laryngoscope 2015;125(6):1496–1501.
3. Bilezikian JP, Brandi ML, Eastell R, et al. Guidelines for the management of asymptomatic primary hyperparathyroidism: summary statement from the Fourth International Workshop. J Clin Endocrinol Metab 2014;99(10):3561–3569.
4. Schneider DF, Mazeh H, Sippel RS, et al. Is minimally invasive parathyroidectomy associated with greater recurrence compared to bilateral exploration? Analysis of more than 1,000 cases. Surgery 2012;152(6):1008–1115.
5. Berber E, Parikh RT, Ballem N, et al. Factors contributing to negative parathyroid localization: an analysis of 1000 patients. Surgery 2008;144(1):74–79.

REVIEW QUESTIONS

1. Which of the following is the best method for diagnosis of PHPT?
   a. Confirm elevated calcium on single occasion and subsequently measure PTH
   b. Confirm elevated calcium, vitamin D, and PTH
   c. Confirm simultaneously elevated calcium and PTH on two separate occasions and determine elevated 24-hour urine calcium excretion
   d. Confirm elevated calcium on two separate occasions, measure PTH, and determine location of parathyroid adenoma by sonography
   e. Confirm elevated calcium and abnormal sestamibi scintigraphy

2. In which of the following scenarios is preoperative localization of the abnormal parathyroid gland(s) most useful?
   a. Patient with confirmed MEN type 1
   b. Elderly asymptomatic patient with normal bone mineral density but elevated serum calcium
   c. Patient with elevated calcium and PTH and low 24-hour urine calcium
   d. Patient who has undergone previous parathyroidectomy but has persistent hyperparathyroidism
   e. Patient with PHPT and concurrent Hashimoto's thyroiditis

3. Which of the following is *false* with regard to intraoperative identification of parathyroid glands?
   a. Parathyroid glands can vary widely in color
   b. Parathyroid glands normally weigh 30 to 50 mg
   c. Superior parathyroid glands are most commonly found on the posterolateral surface of the upper two-thirds of the thyroid lobes
   d. Inferior parathyroid glands can be associated with the thymus
   e. The RLN is usually posterior to the superior parathyroid glands

4. Which of the following is *false* regarding intraoperative PTH monitoring?
   a. The short half-life of PTH makes this technique possible
   b. MIP should be performed with intraoperative PTH monitoring regardless of preoperative localization
   c. Minimal change in PTH 20 minutes after excision of a parathyroid gland indicates hyperplasia
   d. A PTH decrease of greater than 50% compared to the highest pre-excision level within 10 minutes suggests that the correct gland was removed and that surgery can conclude
   e. Intraoperative PTH monitoring has been shown to reduce costs

5. A 55-year-old male patient diagnosed with PHPT undergoes unilateral neck exploration and excision of one parathyroid gland. However, he presents 2 months later with persistently elevated serum calcium and worsening bone pain, fatigue, and memory problems. Which of the following is *least* appropriate?
   a. Lab tests to confirm diagnosis of PHPT
   b. Laryngoscopy
   c. Attempt to localize the abnormal parathyroid gland(s) with both sonography and sestamibi scintigraphy
   d. Offer arteriography if imaging techniques are nonlocalizing
   e. Plan for BNE and total parathyroidectomy regardless of imaging in order to avoid a potential third neck surgery

ADDITIONAL SOURCES

Akerstrom G, Malmaeus J, Bergstrom R. Surgical anatomy of human parathyroid glands. Surgery 1984;95(1):14–21. (This article uses 503 autopsy cases in order to discuss the number and anatomic distribution of the parathyroid glands).

Mohebati A, Shaha AR. Anatomy of thyroid and parathyroid glands and neurovascular relations. Clin Anat 2012;25(1):19–31. (This article reviews the anatomy and embryology of the parathyroid glands and important surrounding structures).

Steward DL, Danielson GP, Afman CE, et al. Parathyroid adenoma localization: surgeon-performed ultrasound versus sestamibi. Laryngoscope 2006;116(8):1380–1384. (This study compared surgeon-performed ultrasound with sestamibi scintigraphy with repect to adenoma localization to the correct quadrant. They found that ultrasound was significantly more sensitive. Combining the methods results in slightly improved sensitivity than ultrasound alone).

Suh YJ, Choi JY, Kim SJ, et al. Comparison of 4D CT, ultrasonography, and 99mTc sestamibi SPECT/CT in localizing single-gland primary hyperparathyroidism. J Otolaryngol Head Neck Surg 2015;152(3):438–443. (This study found that 4D CT is more accurate than ultrasound or SPECT/CT in localizing the hyperfunctioning parathyroid gland. Greater parathyroid hormone level, gland diameter, and gland volume were factors that improved localization with 4D CT).

85 Parathyroidectomy for Secondary Hyperparathyroidism

Pedro Andrade Filho

INTRODUCTION

Secondary hyperparathyroidism (SHPT) is a consequence of the decreased concentration of ionized calcium in the blood, which may have many causes. SHPT is characterized by increased compensatory parathyroid hormone (PTH) secretion due to the malabsorption of intestinal calcium mainly caused by chronic renal disease. For this reason, SHPT is often referred to as renal SHPT, but it may be due to other chronic conditions that result in low serum calcium. Increased parathyroid function is stimulated by calcium deficiency (presenting with normocalcemia or hypocalcemia); thus the parathyroid gland has no functional autonomy. Other causes of SHPT include long-term lithium therapy, osteomalacia, rickets, malabsorption diseases, severe Crohn disease, celiac disease, and vitamin D deficiency. Gastric bypass or weight reduction (bariatric) surgery may also result in SHPT. Renal SHPT is initially treated medically, although parathyroidectomy (PTX) remains an efficient and definitive treatment option for this condition, since it may bridge the time until kidney transplantation can be performed.

In theory, if the feedback mechanism involving the level of blood calcium and PTH is interrupted, it could result in regression of the parathyroid glands. For patients with chronic kidney disease–mineral and bone disorder (CKD-MBD), the feedback mechanism is interrupted by successful renal transplantation. The hypertrophic gland transformation occurs over years of progressive kidney disease. The sustained hypersecretion of PTH is associated with an increase in the size of the parathyroid gland, leading to diffuse parathyroid hyperplasia. Subsequently, some cells inside the parathyroid gland can proliferate in a monoclonal growth pattern, which results in an advanced type of nodular hyperplasia.[1] During the process of parathyroid hyperplasia, both calcium-sensing receptors (CaSRs) and vitamin D receptors (VDRs) are progressively downregulated.[2] As a result, the parathyroid glands with nodular hyperplasia become increasingly unresponsive to active treatment with vitamin D.

Whether a regression of parathyroid hyperplasia can occur after medical treatment with calcitriol or vitamin D3 remains uncertain. Also, regression of parathyroid hyperplasia has been reported in rare cases of spontaneous infarction of the glands.[3] Also, enhanced apoptosis of parathyroid cells has been observed in diffuse hyperplasia following kidney transplantation, which suggests the possibility of the long-term regression of an individual gland.[4]

The use of a new generation of vitamin D analogues and calcimimetics as well as changes in diet and modified dialysis techniques has led to a reduction in fractures and PTX for renal SHPT in patients with CKD-MBD. However, the required medications can be expensive, and the cost of 9 months of calcimimetic treatment may exceed that of surgical therapy.[5]

The elevation of PTH takes time; when it reaches values higher than 495 pg/mL, there is a 25% increased risk of mortality.[6] The response to vitamin D is reduced by 50% at PTH levels above 750 pg/mL.[7] Therefore early surgery can potentially offer an improved quality of life and possibly a higher long-term rate of survival.[5-7]

KEY OPERATIVE LEARNING POINTS

1. The surgical strategy should focus on a correct balance between the extent of parathyroid resection with prevention of recurrence while also minimizing permanent hypoparathyroidism.
2. The common surgical procedures are subtotal parathyroidectomy (SPTX) and total parathyroidectomy (TPTX). SPTX and TPTX can be coupled with parathyroid autotransplantation (AT) and bilateral cervical thymectomy (BCT) (Table 85.1). The surgeon's preference and transplantation status influence the type of operation performed.
3. BCT is considered an essential part of any effort to remove supernumerary glands or ectopic parathyroid nests, thus reducing persistent and recurrent SHPT.
4. Proper timing of the decision for surgery is essential in order to avoid a procedure done too early in the development of renal SHPT, which would prove unnecessary, or one that is done too late, which would pose increasing risks and complications due to the patient's worsening comorbidities. Therefore integrated, multidisciplinary care is vital to detect the best surgical timing as well as careful postoperative care to control for metabolic alterations.
5. A comprehensive approach to the treatment and prevention of progressive renal SHPT is crucial, starting with early monitoring for biomarkers (PTH, Ca, and phosphorus), dietary modifications, mode of renal replacement therapy, and drug therapy.

PREOPERATIVE PERIOD

History

1. History of present illness
   a. Many patients with renal SHPT may be asymptomatic but may present with nonspecific symptoms, such as bone or joint pain, cutaneous itching, and fatigue. However, abnormalities may be already detectable by laboratory or radiographic studies. Patients may present with elevated serum phosphate levels, reduced vitamin D production, and low or normal serum calcium levels; as a result, PTH levels would be markedly elevated.
   b. What serologic parameters indicate changes in renal SHPT, and is it possible to avoid progressive PTH elevation?

At the beginning of CKD stage III (estimated glomerular filtration rate [GFR] <60 mL/min), PTH levels start to increase. According to the recommendations of the kidney disease outcomes quality initiative (KDOQI), PTH should be kept between 150 and 300 pg/mL to avoid the complete suppression of osteoclasts and prevent adynamic bone disease[8] (Table 85.2). Current therapeutic strategies include the modification of calcium and phosphorus balance by restricting the intake of dietary calcium and phosphorus and their removal during hemodialysis as well as the administration of phosphate binders, vitamin D receptor activators (calcitriol and newer vitamin D analogues), and a calcimimetic. When PTH levels cannot

TABLE 85.1 Acceptable Surgical Procedures for Secondary Hyperparathyroidism and Outcomes

Procedure	Recurrence/Persistence (%)	Hypoparathyroidism (%)	Reference/Type Study/Level of Evidence
SPTX with or without BCT	20	0	Rothmund et al. (1991)/RCT/1b
SPTX with or without BCT and with AT	4.8	2.4	Gasparri et al. (2001)/CRS/3
SPTX with or without BCT and without AT	0	0	Schnierder (2012)/CRS/3

AT, Autotransplantation; *BCT*, bilateral cervical thymectomy; *SPTX*, subtotal parathyroidectomy.

TABLE 85.2 Target Ranges for Monitoring of Secondary Hyperparathyroidism

Stage of CKD	GFR	Corrected Calcium (mg/dL)	Phosphorus (mg/dL)	iPTH (pg/mL)	Monitoring of iPTH	Monitoring of Calcium and Phosphorus
3	30–60	Normal limits	2.7–4.6	35–70	1 year	1 year
4	15–29	Normal limits	2.7–4.6	70–110	3 months	3 months
5	<15	8.4–9.5	3.5–5.5	150–300	3 months	1 month

CKD, Chronic kidney disease; *GFR*, glomerular filtration rate; *iPTH*, intact parathyroid hormone.

be maintained within the target ranges, the surgical option should be considered so as to avoid the progression of ectopic calcification.

c. Why do PTH levels continue to increase despite dietary restriction and the administration of phosphate binders, calcimimetics, and vitamin D analogues?

As the process of low-level secretion of extracellular Ca-stimulating PTH continues, the parathyroid glands are gradually transformed from normal glands into glands manifesting diffuse hyperplasia, then nodular hyperplasia, and finally multiple adenomas. The glandular growth/hyperplasia is hyperactive, irregular, asymmetrical, and asynchronous; this process is related to the time on dialysis until the parathyroid gland finally becomes autonomous. At that point there is no longer any response to medical treatment. This is an important part of disease progression, because even after kidney transplantation the hypersecretion of PTH and hypercalcemia can persist. This condition, called tertiary hyperparathyroidism, can jeopardize the transplant surgery and long-term viability of the transplanted kidney.

Although PTH levels can be suppressed by continuous treatment with phosphate binders, vitamin D analogues, and/or calcimimetics, a progressive reduction in the expression of CaSRs and VDRs can occur. This can ultimately result in resistance to medical management, at which point PTX might be required.

d. Which patients may benefit from PTX?

Surgical intervention should be considered in symptomatic patients who present with bone or muscle pain, muscle weakness, irritability, pruritus, bone loss, the exacerbation of anemia due to resistance to erythropoietin, or worsening cardiomyopathy. There are patients who develop resistance or intolerance to medical therapy; they too should be considered candidates for surgical intervention.

Patients may present with painful pink or purple firm nodules or plaques surrounded by livedo reticularis that progress to deep painful ulcers covered with black eschar; such patients must be screened for surgery immediately. Sepsis from infections in skin ulcers can cause up to 80% mortality.

This condition is known as calciphylaxis, which may be bilateral and symmetrical, affecting the thighs, abdomen, and buttocks. It occurs in only 4% of patients undergoing surgery.[9] Where it appears that vascular calcification is driven by PTH, calcimimetic (as cinacalcet) is the preferred treatment for the control of PTH levels, as demonstrated by the evaluation of cinacalcet hydrochloride therapy to lower cardiovascular events (EVOLVE) trial.[10] PTX is a surgical option for controlling elevated PTH levels and has been effective in isolated cases. In patients with calciphylaxis who have received urgent surgical treatment with TPTX, median survival was significantly prolonged. However, the risks associated with surgery, especially in medically complicated patients, make this a second-line treatment following failed medical management. Calciphilaxis is more commonly observed in women, patients with diabetes mellitus, obesity, hypoalbuminemia, and/or liver cirrhosis as well as in patients taking warfarin and those with a systemic inflammation or malignant disease.

e. What PTH level indicates the need for surgical intervention?

Intact PTH levels should be higher than 500 pg/mL and refractory to medical treatment.

2. Past Medical History
   a. Most of these patients have significant worsening of the CKD; therefore the following questions must be addressed:
      1) Is this patient on dialysis? If so, how long has this been the case?
      2) What is the patient's general state of health?
      3) Has the patient had any previous hospitalizations related to SHPT?
   b. Medical illness

The following must be investigated as they may influence surgery: anemia, heart disease, hypertension, diabetes mellitus, hyperlipidemia, previous thrombosis, gastrointestinal malabsorption, and voice changes.

   c. Surgery
      1) Evaluation of any previous neck surgery or thyroid/parathyroid surgery is mandatory. Postoperative complications are higher and success rates lower if there was previous cervical exploration.
   d. Family history
      1) There are some studies showing that the loss of heterozygosity (LOH) in 3q was detected more frequently in uremic parathyroid hyperplasia in comparison with LOH in 11q13 and 1q in parathyroid adenomas and LOH in 1q and 6q in familial hyperparathyroidism. It has been reported that LOH in 11q13 and the X-chromosome is present in uremic parathyroid hyperplasia.

e. Medications
   1) The use of anticoagulants or antiplatelet medication should be discontinued several days prior to surgery to reduce complications from bleeding.
   2) Prolonged diuretic (especially thiazides) or lithium use is a cause of SHPT, which can lead to hyperplasia or persistent hypercalcemia.

Physical Examination

1. Head and Neck
   a. Inspection of the neck and thyroid gland to evaluate
      1) Symmetry, size, firmness, fixation, and associated lymph nodes as well as evidence of previous neck surgery
   b. Laryngoscopic evaluation

Vocal fold function should be assessed, especially in repeat surgery or in the case of associated thyroid masses.

Laboratory

1. Patients may present with elevated serum phosphate, reduced vitamin D, and low or normal serum calcium levels and, as a result, elevated PTH levels.
2. The KDOQI of the National Kidney Foundation recommends the following target levels for renal SHPT patients who are on dialysis:
   a. Serum calcium level between 8.4 and 9.5 mg/dL
   b. Serum phosphate level of 3.5 to 5.5 mg/dL
   c. Intact PTH (iPTH) of 150 to 300 pg/mL
3. Although there are no specific indications for PTX listed in the KDOQI guidelines, PTX is considered in severe renal SHPT refractory to medical treatment. PTX effectively and quickly lowers calcium, PTH, and phosphorus levels and also helps to prevent cardiovascular complications and ectopic calcifications. Postoperative bone biopsy has shown suppression of bone resorption and initiation of bone formation. Up to 32% of patients with prolonged renal failure require PTX despite expensive medical treatment.[5]

Imaging

1. Preoperative routine evaluation includes the following:
   a. Ultrasonography (US) of the neck
      1) To localize the parathyroid as well as to evaluate any concomitant thyroid disease or nodules that may point to the presence of an intrathyroidal parathyroid gland (Fig. 85.1)
   b. Technetium-99m (^{99m}Tc) sestamibi scintigraphy with or without single-photon emission computed tomography (SPECT)
      2) This is usually not ordered but may be helpful in identifying ectopic glands and facilitating surgical planning. The combination of US and 99mTc sestamibi scintigraphy can provide more accurate results. Because hyperplasia is the predominant physiologic mechanism, the presence of ectopic glands creates surgical challenges more frequently (4 times higher) as compared with primary hyperparathyroidism.
   c. Four-dimensional contrast-enhanced CT (4D CT)
      3) Used mainly in preparation for reoperation to provide precise anatomic information regarding orthotopic or ectopic glands, multiglandular disease, and coexisting pathology such as thyroid nodules or lymph nodes. Disadvantages include cost and radiation exposure.

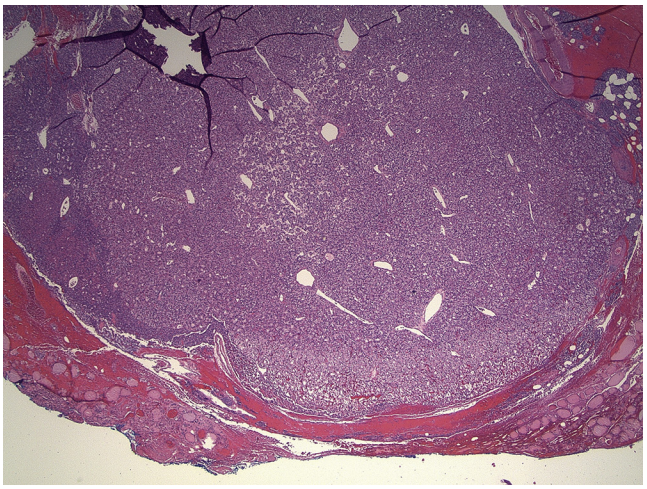

Fig. 85.1. Photomicrograph showing an intrathyroid parathyroid gland.

   d. Magnetic resonance imaging (MRI)
      4) This is helpful in the visualization of mediastinal hyperplastic parathyroid glands. Abnormal glands, identified on adipose tissue–saturated T2-weighted (hyperintense) imaging, can be distinguished from the surrounding mediastinal adipose tissue using this modality, and gadolinium may help to enhance the abnormal glands. MRI is not as helpful in visualizing cervical glands.
   e. C-methionine positron emission tomography and computed tomography (PET CT) or 18 fluorodeoxyglucose (FDG) PET CT—or even selective venous catheterization with PTH assessment—appear to be reserved for special indications such as reoperation.

Indications

1. Severe renal SHPT
   a. Hyperphosphatemia refractory to medical management with PTH levels exceeding 800 pg/mL or extraosseous calcifications with PTH greater than 500 pg/mL as well as severe radiologically or histologically proven osteopathy
2. Calciphylaxis
3. Intractable pruritus
4. Symptomatic patients or patient's preference
5. Nodular hyperplastic parathyroid

Contraindications

1. High-risk medical comorbidities
2. Pre-existing recurrent nerve paralysis
3. Previous neck surgery or explorations constitute a relative contraindication; surgery in this setting should be performed only by experts in parathyroid surgery.

Preoperative Preparation

1. Dialysis patients should undergo dialysis 12 to 24 hours or at the latest 36 hours prior to surgery so as to minimize the administration of heparin.
2. Cardiologic evaluation is desirable because renal SHPT patients (around 80%) frequently have coexisting hypertension, diabetes, and cardiac disease.
3. Electrolyte abnormalities should be corrected as much as possible. Be aware of hypocalcemia, hyperphosphatemia (main cause of pruritus), hypermagnesemia, and hyperkalemia.

The consequences of hypermagnesemia include hypoventilation, central nervous system (CNS) depression, hypotension, and shock. Hyperkalemia is an important electrolyte disorder to consider in contemplating general anesthesia and the potential use of muscle relaxants, which may increase serum calcium and result in various cardiac arrhythmias. Electrocardiography (ECG) in hyperkalemic patients can show a high T wave, extended P-R interval, and widened QRS complex. Elective surgery is ideally performed with a potassium value below 5.5 mEq/L.

4. Anticoagulant medications should be discontinued if possible.
5. All tissue removed at previous surgeries should be acquired and reviewed by in-house experts.

OPERATIVE PERIOD

Anesthesia

1. General anesthesia is preferred owing to the need for bilateral exploration, tracheal manipulation, and potentially longer surgical times.
2. PTX can be performed under local anesthesia in selected high-risk patients to minimize the risk of general anesthesia.

Positioning

1. Supine with a small shoulder roll, slightly extending the neck
2. The arms should be tucked in at the patient's side with the elbows padded to protect the ulnar nerve.

Perioperative Antibiotic Prophylaxis

1. Antibiotics are not mandatory in clean surgical cases. A single perioperative dose of a broad-spectrum antibiotic may be considered.

Monitoring

1. Intraoperative PTH monitoring is advocated for routine use during PTX in order to ensure adequate resection goals with final PTH levels less than 300.
2. Intraoperative nerve monitoring (IONM) of the recurrent laryngeal nerve with special endotracheal tubes that have electromyographic (EMG) capability may be helpful in reoperations.

Required Instruments and Equipment

1. Standard thyroid set
2. Bipolar/monopolar cautery
3. McCabe surgical dissecting clamp
4. Endotracheal tubes with EMG capability may be recommended in reoperations and at the discretion of the surgeon.
5. Intraoperative PTH monitoring: PTH half-life is approximately 2 to 5 minutes and 10 minutes of removing all hyperactive parathyroid tissue; the PTH levels should then fall by more than half. By testing PTH levels before removing the hyperactive parathyroid glands (usually before starting the surgery and before tying off the blood supply to the gland) and then again after removal of the abnormal gland, the surgeon can determine the presence of additional hyperfunctioning glands. Although there are different criteria for a successful operation, most surgeons look for at least a 50% drop in PTH levels to consider the patient cured. PTH is tested following the removal of the glands after 10, 15, and 20 minutes. Ideally the 20-minute, postexcision PTH level should be below 300. It can take anywhere from 10 to 40 minutes to get the results from each PTH testing. The patient usually remains in the operating room during this time.

Key Anatomic Landmarks

1. Laryngotracheal complex: The recurrent laryngeal nerve enters the larynx between the cricoid cartilage and the first tracheal ring. Any dissection below the cricoid cartilage requires expert knowledge of the anatomy of the recurrent laryngeal nerve to avoid injury.
2. Recurrent laryngeal nerve: The superior glands usually lie posterior to the plane of the nerve while the inferior glands lie anterior to the nerve in most cases.
3. Thyroid gland: Most parathyroid glands lie directly posterior to or around the capsule of the thyroid gland; identification and mobilization of the gland are required in four-gland explorations.
4. Inferior thyroid artery: Parathyroid glands are often located near the junction of the inferior thyroid artery and the recurrent laryngeal nerve. The proper identification of the artery prevents inadvertent nerve injury.
5. Carotid arteries: These constitute the lateral boundaries of dissection.

Prerequisite Skills

1. Proficiency in thyroid surgery
2. Knowledge of thyroid and parathyroid embryology

Operative Risks

1. Injury to the recurrent laryngeal nerve
   a. Temporary hoarseness occurs in less than 5% of cases and typically resolves within a few weeks. However, hoarseness may take up to 6 months to fully recover when the parathyroid gland is juxtaposed or posterior to the nerve. In less than 1% of cases, the nerve may be permanently injured.
2. "Hungry-bone syndrome" is defined as severe hypocalcemia requiring a prolonged postoperative hospital or readmission and can occur in some 28% of patients after PTX, developing within the first 18 postoperative hours.
3. Parathyromatosis is a condition of persistent HPT caused by diffuse functional ectopic parathyroid tissue, which is often spilled at the time of parathyroid gland removal.
4. Hematomas may occur, usually within the first 4 hours of surgery, although bleeding can happen up to a week later, especially in patients with a bleeding disorder or those who are taking anticoagulants. This occurs in less than 1% of cases and usually requires surgical evacuation to prevent serious compressive sequelae.
5. Infections are extremely rare and should raise the concern of incidental injury to the trachea or esophagus. Generally opening the wound and placing a Penrose drain should suffice as initial management.
6. Inadequate parathyroid resection and persistence of the disease

Surgical Technique

1. After intubation, blood should be drawn for baseline testing of PTH levels before removing the hyperactive parathyroid glands; this is best achieved before starting the operation and with minimal manipulation of the neck.

2. The skin is marked for thyroid surgery, followed by infiltration of the skin with local anesthesia (epinephrine). A 3- to 4-cm Kocher incision is placed into a line of relaxed skin tension approximately 2 fingerbreadths above the suprasternal notch. Dissection continues through the platysma muscle and the subplatysmal flaps are elevated. All four glands should be exposed for surgical decision. The location of the superior parathyroid gland is sought on the posterior and lateral aspects of the thyroid gland. The middle thyroid veins are ligated and the gland is rotated. The superior gland should be located near the superior pole of the thyroid, often deep to the plane of the recurrent laryngeal nerve and superior to the intersection of the recurrent laryngeal nerve and the inferior thyroid artery. Blunt dissection of the fibroareolar tissue to expose the thyroid gland using a Kittner or peanut dissector with a Freer elevator is recommended. Diligent hemostasis is mandatory. It is preferable to identify the recurrent laryngeal nerve before any gland is removed. If additional exposure is needed, the superior thyroid artery can be ligated as it enters the superior aspect of the thyroid; the thyroid gland can then be further rotated anteromedially. The inferior parathyroid is usually medial and anterior to the recurrent laryngeal nerve, often overlying the trachea or tracheoesophageal groove in the region of the intersection of the recurrent laryngeal nerve and the inferior thyroid artery. Dissection along the nerve down the tracheoesophageal groove and along the esophagus toward the mediastinum may be required to find the abnormal gland. The search for the inferior gland should include the thyrothymic adipose tissue and the superior aspect of the thymus. The use of BCT may also be required. After visualizing all four glands, the surgeon will choose one of the following approaches:
   a. TPTX without AT
   b. TPTX with AT
   c. PTX

The optimal surgical treatment of SHPT has not been clearly defined but may be influenced by the likelihood of subsequent renal transplantation. SPTX involved the resection of 3½ parathyroid glands with a remnant left in situ (between 50 and 70 mg of the gland) (Figs. 85.2 and 85.3). TPTX is the resection of all four parathyroid glands (Fig. 85.4) and is often accompanied by AT of a portion of a normal-appearing gland, usually into the forearm or in the neck, but can also include cryopreservation and delayed AT. The technique of parathyroid AT includes mincing (Fig. 85.5), thin-sectioning, and homogenization into a paste form. A frozen-section biopsy specimen is obtained to confirm that it is parathyroid tissue before reimplantation is performed with the residual gland (usually a remnant of 50 mg). The reimplantation can use neck musculature such as the sternocleidomastoid muscle (SCM) or involve the forearm in the brachioradialis muscle. Small pockets are created in the muscle (Fig.85.6), followed by insertion of the minced gland and closure and marking with a surgical clip or permanent suture. Cervical thymectomy may be required, especially because ectopic or supernumerary glands can be found in up to 37% of the cases. The tissue overlying the trachea just inferior to the thyroid down to the innominate artery/aortic arch inferiorly, the trachea posteriorly, and the bilateral carotid artery medially should be removed. The appropriate surgical approach will vary from patient to patient and will fall into one of these acceptable surgical treatments.

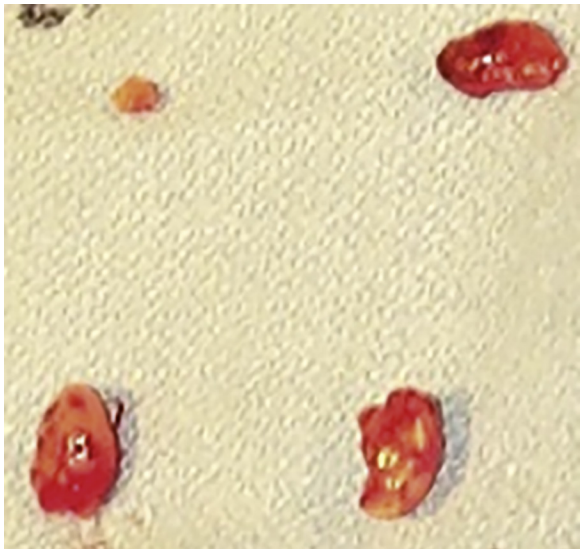

Fig. 85.2. Subtotal parathyroidectomy (removal of 3½ glands).

Common Errors in Technique

1. Excessive bleeding
   a. A blood-free field is mandatory. If blood is present it will stain the lymph nodes and adipose tissue located in the paratracheal space, making it more difficult to identify the parathyroid tissue.
   b. Bleeding also increases the risk of inadvertent injury to the recurrent nerve or esophagus.
2. Excessive parathyroid gland remnant. In SPTX, the remnant piece of parathyroid may necessitate reoperation for recurrent disease, which is associated with a higher rate of complications. For this reason, the remnant parathyroid gland is marked with a surgical clip (for later identification) and should be left away from the RLN and preferably anterior to the RLN. Approximately 50 to 70 mg should be preserved in order to avoid damage to the blood supply. Devascularized glands rapidly become dusky and should be removed and reimplanted after frozen section confirms the presence of parathyroid tissue.
3. In TPTX with AT, the parathyroid can be implanted in the forearm to alleviate the risks of reoperative neck surgery. Reimplantation will not prevent immediate postoperative hypocalcemia. Autotransplantation to a forearm location may be technically challenging in patients with one or more pre-existing arteriovenous fistulas or grafts in the upper extremities.
4. Poor cosmesis
   a. Incisions should be carefully placed into lines of relaxed skin tension for camouflage.
   b. Subcuticular closure is preferred to prevent track marking.
   c. The strap muscle and platysma should be approximated to prevent adhesion of the trachea to the underlying skin.

POSTOPERATIVE PERIOD

Postoperative Management

1. Pain control
   a. Usually small doses of narcotics can be given for 1 to 2 days.
   b. Patients should quickly be transitioned to a nonnarcotic pain medication such as naproxen sodium or acetaminophen.
2. Postoperative dialysis

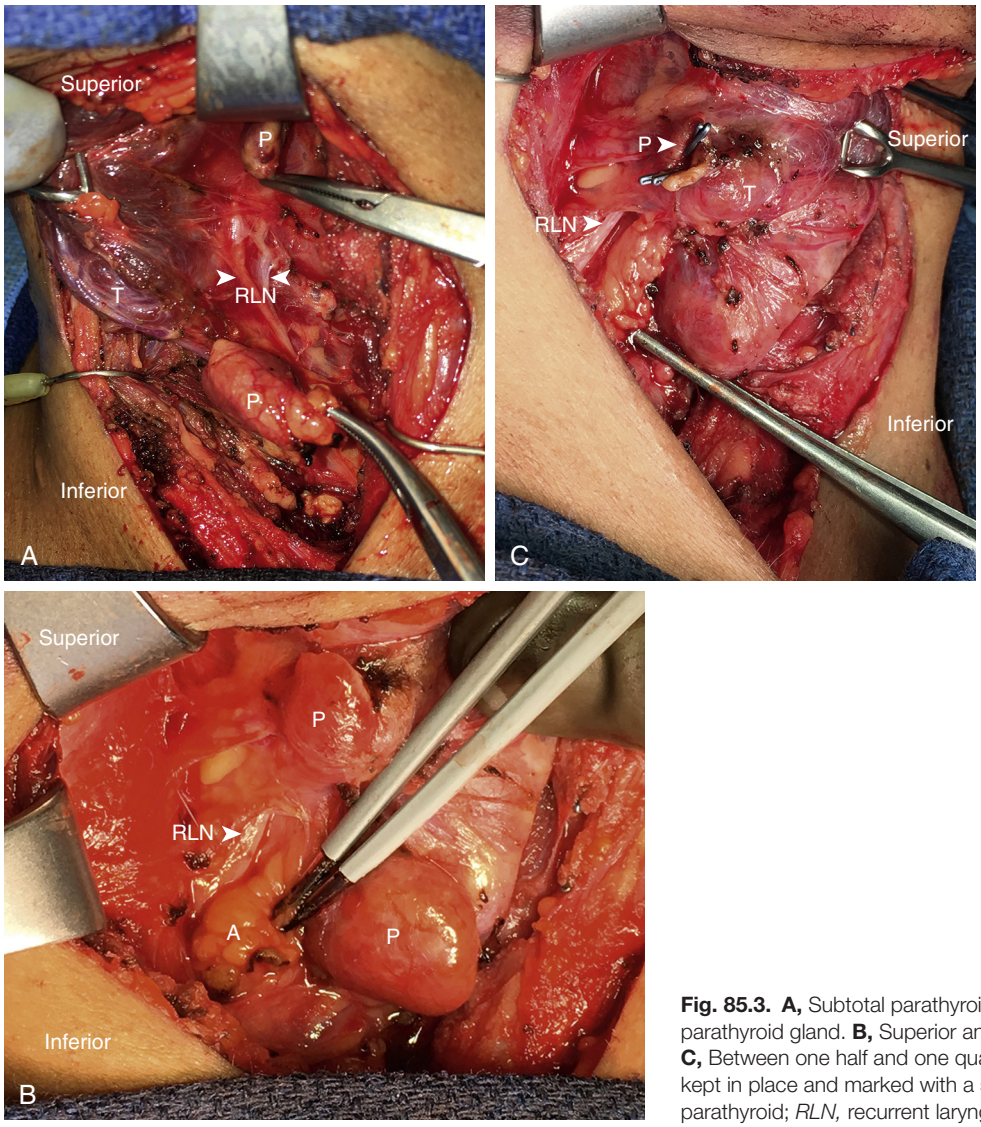

Fig. 85.3. A, Subtotal parathyroidectomy; Superior and inferior left parathyroid gland. **B,** Superior and inferior right parathyroid gland. **C,** Between one half and one quarter of the right superior gland was kept in place and marked with a surgical clip. *A,* Adipose Tissue; *P,* parathyroid; *RLN,* recurrent laryngeal nerve; *T,* thyroid gland.

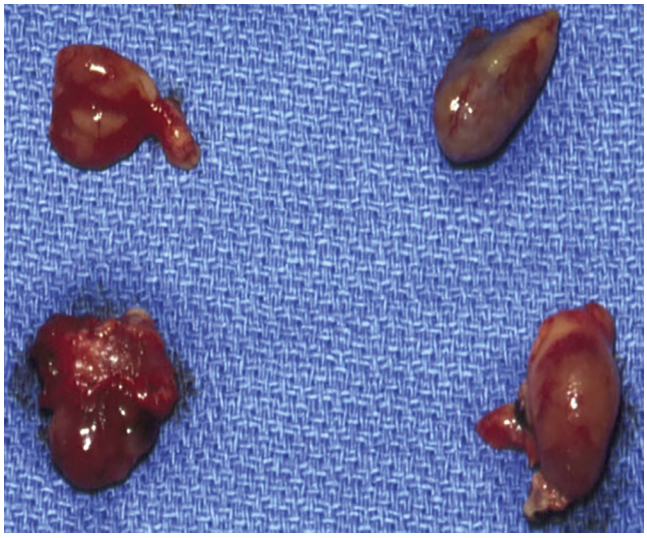

Fig. 85.4. Total parathyroidectomy (four-gland excision).

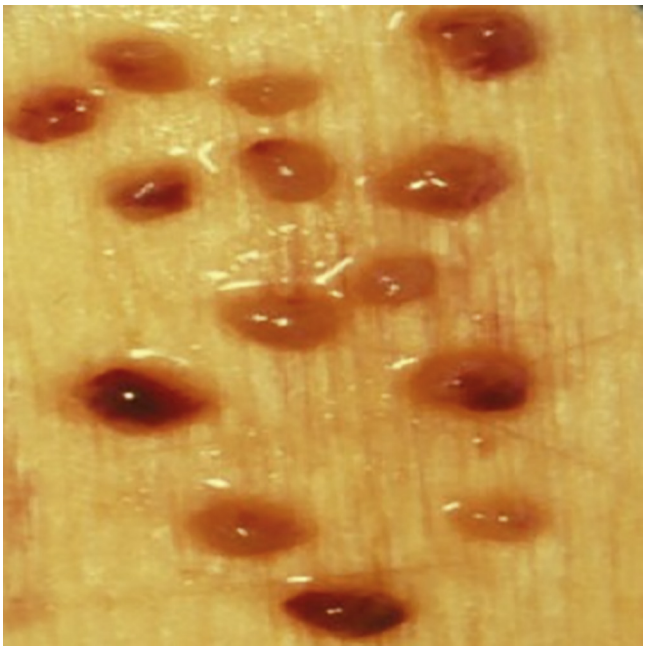

Fig. 85.5. Remnant of gland minced into pieces smaller than 1 mm^3 using scalpel or scissors and ready for transplantation into striated muscle.

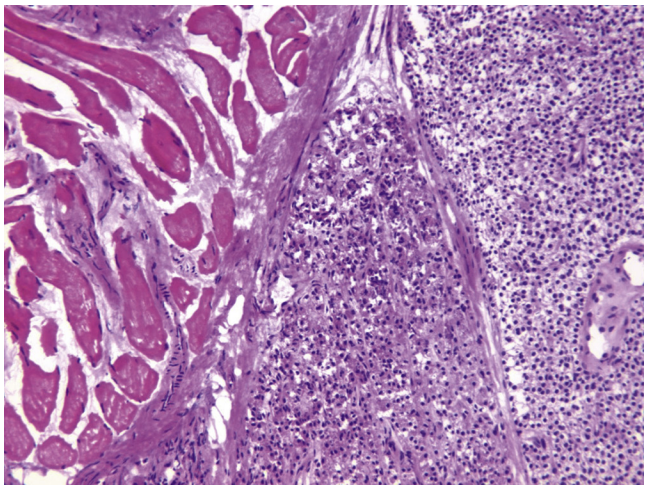

Fig. 85.6. Parathyroid tissue transplanted into the striated muscle tissue.

3. Calcium replacement
   a. SHPT patients are best managed by a minimum of overnight observation and should be started on empiric oral calcium and vitamin D supplementation. Hungry-bone syndrome is a risk for hypocalcemia despite persistently elevated PTH.
   b. Calcium should be checked every 12 hours after total PTX. In the first 72 hours, patients may need intravenous (IV) calcium in addition to high doses of oral calcium and calcitriol, which will be decreased during the subsequent weeks.

Complications

1. Hypocalcemia is the most common postoperative complication following PTX in renal SHPT. Up to 85% of the patients will experience hypocalcemia. Prophylactic calcium and calcitriol can be started before or after surgery. The National Kidney Foundation recommends the following postoperative treatment of hypocalcemia:

The blood level of ionized calcium should be measured every 12 hours for the first 48 to 72 hours after surgery and then twice daily until the patient is stable. If the blood levels of ionized or corrected total calcium fall below normal (<0.9 mmol/L or <3.6 mg/dL corresponding to corrected total calcium of 7.2 mg/dL), a calcium gluconate infusion should be initiated at a rate of 1 to 2 mg elemental calcium per kilogram body weight per hour and adjusted to maintain an ionized calcium in the normal range (1.15 to 1.36 mmol/L or 4.6 to 5.4 mg/dL). The calcium infusion should be gradually reduced when the level of ionized calcium attains the normal range and remains stable. When oral intake is possible, the patient should receive calcium carbonate 1 to 2 g 3 times a day as well as calcitriol of up to 2 μg/day, and these therapies should be adjusted as necessary to maintain the level of ionized calcium in the normal range.

2. Hyperparathyroidism after PTX. Postoperative PTHs should ideally be less than 300 pg/dL. Persistent or recurrent hyperparathyroidism occurs in 2% to 30% of cases even in the hands of experienced surgeons after either SPTX or TPTX plus AT. Persistence should be rare and recurrence is lower after TPTX without transplantation. SPTX has a higher chance for hyperparathyroidism than TPTX plus transplantation.
3. Recurrent laryngeal nerve injuries are extremely rare, occurring in less than 1% of cases, and most of these injuries are transient neuropraxias.
4. Hematomas, wound infection, dehiscence, and death are also extremely rare.

Alternative Management Plan

1. Arteriographic embolization and percutaneous ethanol ablation resulting in transitory hypoparathyroidism has been described in the past; however, this is not commonly recommended.
2. Aggressive vitamin D and calcium replacement to inhibit PTH secretion
3. Administration of cinacalcet (Sensipar) can be used in refractory cases or medically fragile patients who cannot undergo surgery.

DISCUSSION

Evidence-Based Medicine Question

Is there any marker that predicts the success of PTX?

Intraoperative PTH monitoring has been considered the gold standard for intraoperative monitoring and is necessary during function-controlled PTX. This type of monitoring predicts the cure and is very helpful in persistent or recurrent disease. The benefits extend beyond the economic savings resulting from limited exploration and reduced operating times. Surgery is considered successful when PTH levels drop to a level less than 300 pg/mL in cases of STPX at the end of the procedure.

Editorial Comment

Surgery for SHPT has become more common with improvements in dialysis and cardiac care in patients with renal failure. Surgery should be tailored according to transplantation status and requires more experience than that called for by typical parathyroid surgery. In contrast to patients with primary hyperparathyroidism, surgery for SHPT should not routinely be performed as an outpatient procedure, as the risk of significant hypocalcemia is a valid concern.

Alfred Simental, Jr.

Access the review questions and additional sources list online at http://www.expertconsult.com

REFERENCES

1. Cozzolino M, Butti A, Chiarelli G, et al. New insights in the pathogenesis of secondary hyperparathyroidism. G Ital Nefrol 2005;22(4):329–336.
2. Lewin E, Olgaard K. Parathyroidectomy vs calcimimetics for treatment of persistent hyperparathyroidism after kidney transplantation. Nephrol Dial Transplant 2006;21(7):1766–1769.
3. Komaba H, Takeda Y, Abe T, et al. Spontaneous remission of severe hyperparathyroidism with normalization of the reversed whole PTH/intact PTH ratio in a haemodialysis patient. Nephrol Dial Transplant 2008;23:1760–1762.
4. Taniguchi M, Tokumoto M, Matuo D, et al. Persistent hyperparathyroidism in renal allograft recipients: vitamin D receptor, calcium-sensing receptor, and apoptosis. Kidney Int 2006;70:363–370.
5. Schneider R, Kolios G, Koch BM, et al. An economic comparison of surgical and medical therapy in patients with secondary hyperparathyroidism—the German perspective. Surgery 2010;148:1091–1099.
6. Ganesh SK, Stak AG, Levin NW, et al. Association of serum phosphorus and calcium × phosphorus product, and parathyroid hormone with cardiac mortality risk in chronic hemodialysis patients. J Am Soc Nephrol 2001;13:2131–2138.

7. Rodriguez M, Caravaca F, Fernandez E, et al. Parathyroid function as a determinant of the response to calcitriol treatment in the hemodialysis patient. Kidney Int 1999;13(1):306–317.
8. National Kidney Foundation. K/DOQI clinical practice guidelines: bone metabolism and disease in chronic kidney disease. Am J Kidney 2003;42:S1–201.
9. Angelis M, Wong L, Myers S, et al. Calciphylaxis in patients on hemodialysis: a prevalence study. Surgery 1997;122:1083.
10. Floege J, Kubo Y, Floege A, et al. The effect of cinacalcet on calcific uremic arteriolopathy events in patients receiving hemodialysis: the EVOLVE trial. Clin J Am Soc Nephrol 2015;10(5):800–807.

REVIEW QUESTIONS

1. The following are acceptable surgical options for renal SHPT except
   a. 3½ PTX
   b. TPTX
   c. TPTX + autotransplantation
   d. Cervical thymectomy alone

2. What is the most preventable cause of postoperative death in PTX?
   a. Cardiac complication
   b. Acute hypocalcemia
   c. Infection
   d. Hyperkalemia

3. Which is the predominant parathyroid pathology seen in patients with secondary hyperparathyroidism?
   a. Carcinoma
   b. Hyperplasia
   c. Adenoma
   d. Apoplexy

4. If your surgical decision is SPTX, which gland should be left in situ?
   a. Closer to the recurrent laryngeal nerve
   b. Deep in the carotid sheath
   c. Retropharyngeal
   d. Any easily retrievable parathyroid gland (more anterior plane)

ADDITIONAL SOURCES

Aly A, Douglas M. Embryonic parathyroid rests occur commonly and have implications in the management of secondary hyperparathyroidism. ANZ J Surg 2003;73:284–288.

Falchetti A, Bale AE, Amorosi A, et al. Progression of uremic hyperparathyroidism involves allelic loss on chromosome 11. J Clin Endocrinol Metab 1993;76:139–144.

Farnebo F, Farnebo LO, Nordenstrom J, et al. Allelic loss on chromosome 11 is uncommon in parathyroid glands of patients with hypercalcaemic secondary hyperparathyroidism. Eur J Surg 1997;163:331–337.

Fukagawa M, Nakanishi S. Role of parathyroid intervention in the management of secondary hyperparathyroidism. Nephrol Dial Transpl 2003;18(Suppl. 3):23–26.

Gasparri G, Camandona M, Abbona GC, et al. Secondary and tertiary hyperparathyroidism: causes of recurrent disease after 446 parathyroidectomies. Ann Surg 2001;233(1):65.

Girotto JA, Harmon JW, Ratner LE, et al. Parathyroidectomy promotes wound healing and prolongs survival in patients with calciphylaxis from secondary hyperparathyroidism. Surgery 2001;130:645–651.

Goldfarb M, Gondek SS, Lim SM, et al. Postoperative hungry bone syndrome in patients with secondary hyperparathyroidism of renal origin. World J Surg 2012;36(6):1314–1319.

Kane WJ, Petty PM, Sterioff S, et al. The uremic gangrene syndrome: improved healing in spontaneously forming wounds following subtotal parathyroidectomy. Plast Reconstr Surg 1996;98(4):671–678.

Rothmund M, Wagner PK, Schark C. Subtotal parathyroidectomy versus total parathyroidectomy and autotransplantation in secondary hyperparathyroidism: a randomized trial. World J Surg 1991;15(6):745–750.

Schneider R1, Slater EP, Karakas E, Bartsch DK, et al. Initial parathyroid surgery in 606 patients with renal hyperparathyroidism. World J Surg 2012;36(2):318–326.

Tominaga Y1, Kohara S, Namii Y, et al. Clonal analysis of nodular parathyroid hyperplasia in renal hyperparathyroidism. World J Surg 1996;20(7):744–50. discussion 750–752.

Vulpio C, Bossola M, De Gaetano A, et al. Usefulness of the combination of ultrasonography and 99mTc-sestamibi scintigraphy in the preoperative evaluation of uremic secondary hyperparathyroidism. Head Neck 2010;32(9):1226–1235.

86 Reoperative Parathyroidectomy

Christopher Azbell, Jeffrey Bumpous

INTRODUCTION

Parathyroidectomy for primary hyperparathyroidism has a success rate of 90% to 95% among experienced surgeons. However, management of persistent hyperparathyroidism following surgery can be challenging. Careful preoperative analysis of factors that lead to the failure of the initial surgery must be performed prior to reoperative parathyroidectomy. After confirmation of the diagnosis of persistent hyperparathyroidism, all prior operative reports, pathology reports, and imaging studies should be reviewed in detail. Planning for reoperation should include obtaining new imaging, when indicated, and formulating a methodical operative plan. Surgery can be complicated by tissue fibrosis, edema, inflammation, and loss of surgical landmarks.[1] Reoperative parathyroidectomy is still associated with lower success rates and increased postoperative hypocalcemia and recurrent laryngeal nerve injury.[2-4]

KEY OPERATIVE LEARNING POINTS

1. Careful confirmation of the diagnosis of primary hyperparathyroidism is essential before planning the operation.
2. Localizing imaging, including a parathyroid nuclear scan with single photon emission comptuted tomograph (SPECT), and when negative, four-dimensional (4D) computed tomography (CT) and/or selective venous angiography and parathyroid hormone (PTH) sampling, are important potential adjuncts to preoperative identification of single gland disease in the reoperative scenario.
3. A detailed discussion with the patient regarding the risks of reoperative surgery is necessary.

PREOPERATIVE PERIOD

History

1. History of present illness
   a. Signs or symptoms of hypercalcemia
      1) Nephrolithiasis
      2) Severe osteoporosis
      3) Pancreatitis
      4) Abdominal pain
      5) Extremity (bone and muscle) pain
      6) Depression, anxiety, fatigue
   b. How are symptoms now different from symptoms prior to the initial surgery?
2. Prior surgical treatment
   a. Surgical approach (unilateral vs. bilateral)
   b. Specimens removed (assessment of size, weight and number of glands removed or biopsied, thyroid removal). This helps to avoid unnecessary exploration in regions devoid of parathyroid tissue.
   c. Complications encountered: The presence of preexisting vocal fold paralysis would greatly influence the random exploration of the paratracheal region on the ipsilateral side of the functioning vocal fold to prevent tracheostomy.
3. Past medical history
   a. Obtain preoperative and postoperative calcium and PTH levels. The diagnosis of primary hyperparathyroidism should be independently reconfirmed.
   b. Obtain detailed operative and pathology reports from all prior surgeries.
   c. Personal history
      1) Endocrinopathies, including thyroid disorders or carcinoma, pheochromocytoma
      2) Renal disease (increased chance that subtotal parathyroidectomy is necessary for cure)
      3) Hypothalamus-pituitary axis disease
   d. Family history of endocrinopathies (multiple endocrine neoplasia syndromes, familial hyperparathyroidism)
   e. Medications
      1) Exogenous calcium/vitamin D supplementation
      2) Anticoagulants
      3) Diuretics (especially thiazides)
      4) Use of lithium
      5) Allergies

Physical Examination

1. Neck
   a. Palpation of any midline or lateral neck masses (unlikely, but if present raise the concern of coexistent thyroid pathology or parathyroid carcinoma)
   b. Palpation of thyroid
   c. Examination of prior surgical incision
2. Flexible laryngoscopy
   a. Assess recurrent laryngeal nerve function (fiberoptic laryngoscopy is preferable)

Imaging

1. Ultrasound of the neck: identifies concomitant thyroid disease and potentially abnormal parathyroid glands
2. Parathyroid uptake scan [technetium 99 metastable (Tc99m) Sestamibi SPECT preferred]: greater than 80% success in localizing side of overactive parathyroid
3. Dexa bone density scan: Patients with severe osteoporosis, especially with pathologic fractures, must strongly be considered for reoperation, even if persistently nonlocalizing.
4. Possible 4D CT scan of neck and chest in patients that are not localizing by ultrasound or nuclear medicine scans
5. Selective venous angiography and PTH sampling

Indications

1. Persistent symptomatic hypercalcemia within 6 months following prior parathyroidectomy
2. Recurrent primary hyperparathyroidism greater than 6 months following parathyroidectomy
3. Recurrent parathyroid carcinoma
4. Parathyromatosis (seeding from prior surgery/spillage)
5. Bone mineral density greater than 2 standard deviations below gender- and age-matched group (z score <–2.0)
6. Recurrent nephrolithiasis

Contraindications

1. Asymptomatic disease with borderline hyperparathyroidism
2. Recurrent laryngeal nerve injury contralateral to parathyroid adenomas (relative)
3. Significant medical comorbidities increasing risk of anesthesia
4. Cause other than hyperparathyroidism for hypercalcemia is confirmed
5. Diagnostic uncertainty (should be resolved prior to repeat surgery)

Preoperative Preparation

1. Detailed explanation of risks and benefits to reoperation
2. Obtain baseline PTH.
3. Review imaging and have relevant imaging available.

OPERATIVE PERIOD

Anesthesia

General
Awake sedation
Local

Positioning

Supine: The patient is positioned with a shoulder roll to extend the neck and better expose the anterior midline cervical structures.
Prone
Lateral recumbent

Perioperative Antibiotic Prophylaxis:

First-generation cephalosporin (Kefzol)
Second-generation cephalosporin
Clindamycin if allergic to penicillin

Monitoring

None
Neural integrity monitor (NIM) electromyogram (EMG) endotracheal tube—optional on physician preference and experience

Instruments and Equipment to Have Available

1. Major head and neck set
2. Bipolar cautery: necessary for careful dissection in previously dissected tissues
3. Pass probe for confirmation of recurrent laryngeal nerve identification (If NIM is used)
4. Intraoperative PTH assay
5. Relevant imaging

Key Anatomic Landmarks

1. Recurrent laryngeal nerve: The nerve ascends in the tracheoesophageal groove bilaterally, entering the larynx at the inferior border of the inferior pharyngeal constrictor. It is typically located more laterally in the left neck.
2. External branch of superior laryngeal nerve: This branch supplies the cricothyroid muscle. It descends along the inferior constrictor muscle within 1 cm of the superior pole of thyroid. In approximately 20% of cases, the nerve may be closely adherent to the superior pole.
3. Superior parathyroid glands: Derived from the fourth branchial pouch, they are found along the posterolateral aspect of the superior thyroid pole, deep (posterior) to the plane of the recurrent laryngeal nerve.
4. Inferior parathyroid glands: The inferior parathyroids, like the thymus, are derived from the third branchial pouch. They are more variable in position because of their longer descent but are typically found along the posterolateral aspect of the inferior thyroid pole, superficial (anterior) to the plane of the recurrent laryngeal nerve (i.e., anterior superior mediastinum in the thymic remnant).

Prerequisite Skills

1. Localization and preservation of recurrent laryngeal nerve
2. Experience in thyroid and parathyroid surgery

Operative Risks

1. Paralysis or paresis of recurrent laryngeal nerve
2. Postoperative hypocalcemia
3. Intraoperative hemorrhage from innominate artery
4. Esophageal perforation

Surgical Technique

1. Skin incision
2. Raising supraplatysmal flaps
   a. Exposure superiorly to level of thyroid notch
   b. Exposure inferiorly below level of inferior thyroid pole
   c. Placement of retractors
3. Medial approach
   a. Divide midline raphe of strap muscles.
   b. Gentle lateral retraction of ipsilateral strap muscles
   c. Divide fascia from thyroid capsule using bipolar cautery.
4. Lateral approach (especially in localizable disease by imaging in which the patient has had prior midline approach. The senior author prefers the lateral approach for unilaterally localizable disease.)
   a. Define lateral border of strap muscles.
   b. Retract strap muscles contralaterally, exposing ipsilateral thyroid lobe.
   c. Divide fascia from thyroid capsule using meticulous bipolar cautery dissection.
5. Localization of parathyroid glands
   a. Careful identification of recurrent laryngeal nerve
   b. Use of gamma probe to identify parathyroid adenoma (useful adjunct in re-exploration if the offending gland is localizable on Tc99m Sestamibi imaging)[5]
   c. Search regions where unrecognized parathyroid glands are usually found.
   d. Ensure adequate exposure of paratracheal region, including identification of carotid artery laterally and thyroid/trachea medially, followed by medialization of thyroid gland and exposure of the posterior surface where parathyroid glands are often found (Fig. 86.1).
6. Reimplantation of glands where vascularity is questionable, functional glands have previously been explanted, intraoperative PTH is low (<10 pg/dL)

Common Errors in Technique

1. Inadequate preoperative localization
2. Failure to identify recurrent laryngeal nerve
3. Insufficient four gland exploration
4. Incorrect diagnosis of primary hyperparathyroidism (i.e., familial hypocalciuric hypercalcemia, a calcium-sensing receptor [CaSr] genetic abnormality). In cases of hypercalcemia

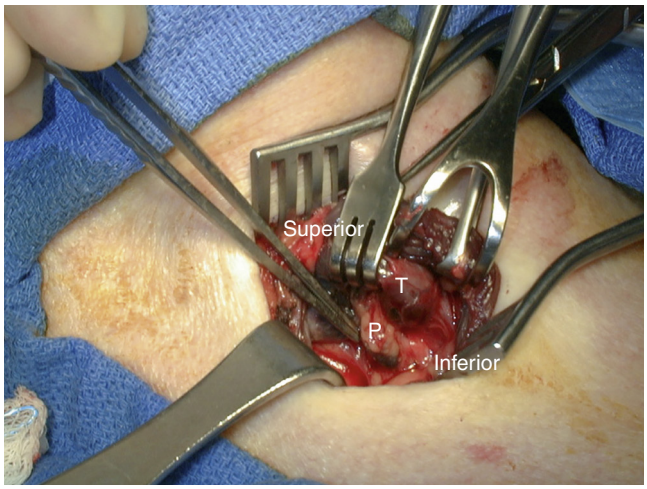

Fig. 86.1. Reoperative inferior parathyroid. Parathyroid located in paratracheal groove after adequate mobilization and medial retraction of thyroid gland. Right lateral approach for reoperative parathyroidectomy using methylene blue as an intraoperative adjunct and demonstrating a right superior parathyroid adenoma and a normal inferior gland. *P,* Parathyroid; *T,* thyroid.

and normal PTH, consideration of other causes of hypercalcemia must be entertained; 24-hour urine calcium may be helpful in this instance. Furthermore, in cases of mildly elevated PTH and normal total calcium, ionized calcium levels should be obtained and if elevated are indicative of primary hyperparathyroidism.

5. Failure to preserve adequate volume of functional parathyroid tissue or consider reimplantation of a portion of a gland into a well-vascularized recipient bed

POSTOPERATIVE PERIOD

Postoperative Management

1. Obtain ionized calcium and parathyroid hormone levels postoperatively.
2. Discharge patient on day of surgery for limited unilateral surgeries.
3. Twenty-three–hour observation overnight for more extensive four gland explorations
4. Pain management
5. Careful patient and family education regarding the symptoms of hypocalcemia (leg cramps, perioral hyperesthesia/tingling) and the need for serious attention to those symptoms
6. Assess and manage vitamin D deficiency as a factor that may prolong hypocalcemia and "bone hunger."

Complications

1. Injury to recurrent laryngeal nerve. Unilateral injury can be observed initially, with expected improvement in several months. Bilateral injury may require a tracheostomy.
2. Postoperative hypocalcemia. Calcium supplementation with calcium gluconate and vitamin D. Rare use of exogenous parathyroid hormone in refractory cases (costly and requires parenteral administration)
3. Hemorrhage. Postoperative hemorrhage requires surgical exploration, with identification and ligation of the bleeding vessels.
4. Persistent hyperparathyroidism (normocalcemia and persistently elevated PTH in particular represents a challenging scenario, which can represent secondary hyperparathyroidism, metabolic bone disease with or without vitamin D deficiency, or persistent primary hyperparathyroidism. If the ionized calcium is elevated in the presence of elevated PTH, persistent primary hyperparathyroidism is much more likely.)

Alternative Management Plan

1. Observation and serial calcium and PTH levels
2. Calcimimetic agents (cinacalcet) in patients that are symptomatic and otherwise not surgical candidates

DISCUSSION

Evidence-Based Medicine Question

What are the most important imaging modalities when preparing for reoperative parathyroid surgery?

Answer

It is clear that reoperative surgery represents a challenge due to the increased risk of ectopic gland location, likelihood of multiple gland disease, and the presence of postsurgical scarring from the initial surgical exploration. Nuclear medicine examination with Sestamibi scanning is paramount in identifying metabolically active parathyroid tissue. This allows for the identification of ectopic parathyroid tissue in more than 80% of cases. High-resolution imaging with CT or magnetic resonance imaging has also shown a high degree of sensitivity in detecting abnormally enlarged paratracheal, paraesophageal, and superior mediastinal masses that may represent overactive parathyroid tissue.

Editorial Comment

Parathyroid surgery for primary hyperparathyroidism has a high success rate on initial surgery, but reoperative surgery faces special challenges that may include abnormal patient anatomy, scarring from previous surgery, and concomitant thyroid pathology. Detailed review of previous reports and operative attempts, as well as repeat attempts at localization, is essential in maximizing success. When possible, reoperative surgery should be performed by experienced parathyroid surgeons in the presence of intraoperative parathyroid hormone monitoring.

Alfred Simental, Jr.

Access the review questions and additional sources list online at http://www.expertconsult.com

REFERENCES

1. Terzioglu T, Senyurek YG, Tunca F, et al. Excision efficiency of radioguided occult lesion localization in reoperative thyroid and parathyroid surgery. Thyroid 2010;20(11):1271–1278.
2. Yen TW, Wang TS, Doffek KM, et al. Reoperative parathyroidectomy: an algorithm for imaging and monitoring of intraoperative parathyroid hormone levels that results in a successful focused approach. Surgery 2008;144(4):611–619.
3. Richards ML, Thompson GB, Farley DR, et al. Reoperative parathyroidectomy in 228 patients during the era of minimal access surgery and intraoperative parathyroid hormone monitoring. Am J Surg 2008;196(6):937–942.
4. Karakas E, Muller HH, Schlosshauer T, et al. Reoperations for primary hyperparathyroidism - improvement of outcome over two decades. Langenbecks Arch Surg 2013;398(1):99–106.
5. Morris LF, Lee S, Warneke CL, et al. Fewer adverse events after reoperative parathyroidectomy associated with initial minimally invasive parathyroidectomy. Am J Surg 2014;208(5):850–855.

REVIEW QUESTIONS

1. Which of the following is NOT a symptom of persistent hypercalcemia?
   a. Pancreatitis
   b. Perioral numbness
   c. Abdominal pain
   d. Fatigue

2. The external branch of the superior laryngeal nerve innervates which muscle?
   a. Lateral cricoarytenoid
   b. Posterior cricoarytenoid
   c. Vocalis
   d. Cricothyroid

3. Which of the following is a relative contraindication to repeat parathyroidectomy?
   a. Symptomatic hypercalcemia 1 year after a previous parathyroid adenoma excision
   b. Retroesophageal mass with increased uptake seen on SPECT/CT
   c. Elevated serum calcium and decreased urinary calcium in a patient with a family history of similar finding
   d. A new parathyroid mass in a patient with a history of parathyroid carcinoma

4. The inferior parathyroid glands are derived from which embryonic structure?
   a. Third branchial pouch
   b. Fourth branchial pouch
   c. Fifth branchial pouch
   d. Ventral diverticulum of the tongue

ADDITIONAL SOURCES

Akerstrom G, Stalberg P, Hessman O. Remedial Parathyroid Surgery. Surgery of the Thyroid and Parathyroid Glands. 2012 (Chapter 38).
Another review of approaches for reoperative parathyroidectomy.

Marti JL, Randolph GW. Management of Refractory Disease. Parathyroid Surgery: Fundamental and Advanced Concepts, 2013 (Chapter 20).
Gives a review of the workup and strategies for reoperation on parathyroid disease.

SECTION 12 Salivary Glands

87 Office-Based Procedures

Trevor Hackman

INTRODUCTION

The breadth of office-based procedures continues to expand within the field of otolaryngology. Office-based procedures allow for prompt, low-cost diagnosis and management of many otolaryngological conditions. Fine needle aspiration (FNA) is a well-established procedure, which provides prompt and accurate diagnosis of neck pathology, including saliva gland and thyroid masses. The application of ultrasound guidance improves accuracy as well as diagnostic yield. In addition, the application of technologic advances and adaptive surgical techniques has improved patient outcomes and expanded the breadth of procedures possible in clinical settings, avoiding the risks and costs of general anesthesia for otherwise minor procedures. Sialendoscopy is a procedure well suited for the transition to the clinic setting for management of salivary gland pathology. The indications for and performance of ultrasound-guided FNA and in-office salivary gland procedures are reviewed in this chapter, including operative setup, procedural details, and complications.

KEY OPERATIVE LEARNING POINTS

1. FNA is a highly accurate procedure for classifying the histology of cervical masses (salivary, thyroid, adenopathy).
2. Ultrasonography enhances the accuracy of the physical examination and FNA.
3. In-office salivary gland procedures, including sialendoscopy, provide excellent minimally invasive gland-sparing therapy without the need for general anesthesia.

PREOPERATIVE PERIOD

History

1. History of present illness
   a. Duration of the mass in the neck may impact the decision to pursue further evaluation
      1) A persistent or slowly progressive mass in the neck lasting for more than 3 weeks should be screened for malignancy.
   b. Does the patient have any associated symptoms or high-risk behavior?
      1) Does the patient display fevers, chills, malaise, weight loss, otalgia, odynophagia, dysphagia, hoarseness, or hemoptysis? Does the patient have a history of smoking/alcohol use or hazardous exposure?
   c. How long has the patient experienced problems with the saliva gland?
      1) Acuity of symptoms relates to gland health—ongoing periodic swelling (reversible damage) versus persistent enlargement (end-stage fibrosis).
   d. How many glands are affected?
      1) Multiple gland involvement is likely inflammatory/autoimmune (radioactive iodine induced sialadenitis or Sjogren's syndrome). Solitary gland symptoms are more suggestive of focal obstruction (sialolithiasis or stricture).
   e. What symptoms is the patient experiencing?
      1) Obstructive symptoms—Swelling of the gland, pain, salty discharge, prandial association
      2) Inflammatory symptoms—Dry eyes, dry mouth, multigland involvement, history of radioactive iodine, chronic swelling
   f. Is there a prandial relationship to these symptoms?
      1) Sialadenitis is exacerbated by the salivary stimulus of a meal. Pain with mastication and swelling that persists for more than a few hours, or occurs upon arousal from sleep, is more indicative of temporomandibular joint disorders.
2. Past medical history
   a. Prior treatment: Antibiotic therapy, sialogouges, steroid therapy
   b. Medical illness: Renal calculi; Sjogren's syndrome, diabetes mellitus, severe dehydration
   c. Surgery: Parathyroidectomy, renal lithotripsy
   d. Family history: Autoimmune diseases
   e. Medications
      1) Antihypertensive medications
      2) Antiplatelet medications

Physical Examination

1. Neck
   Examination of the neck may reveal a fixed or a mobile mass.
2. Oral cavity
   Examination of the oral cavity may reveal turbid discharge from the salivary ducts, palpable submucosal masses consistent with calculi, or oral cavity lesions. If calculi are palpated, the location and the size of the calculi should be noted.
3. Salivary glands
   Examination may reveal a swollen or firm salivary gland, draining sinus, and nodularity to the skin (seen with Sjogren's syndrome).
4. Pharynx/larynx
   Examination may reveal a primary malignant lesion within the oropharynx, hypopharynx, or larynx responsible for the mass in the neck.

Imaging

Ultrasonography (Fig. 87.1) of the salivary glands may reveal salivary gland masses, calculi, abnormal architecture of the

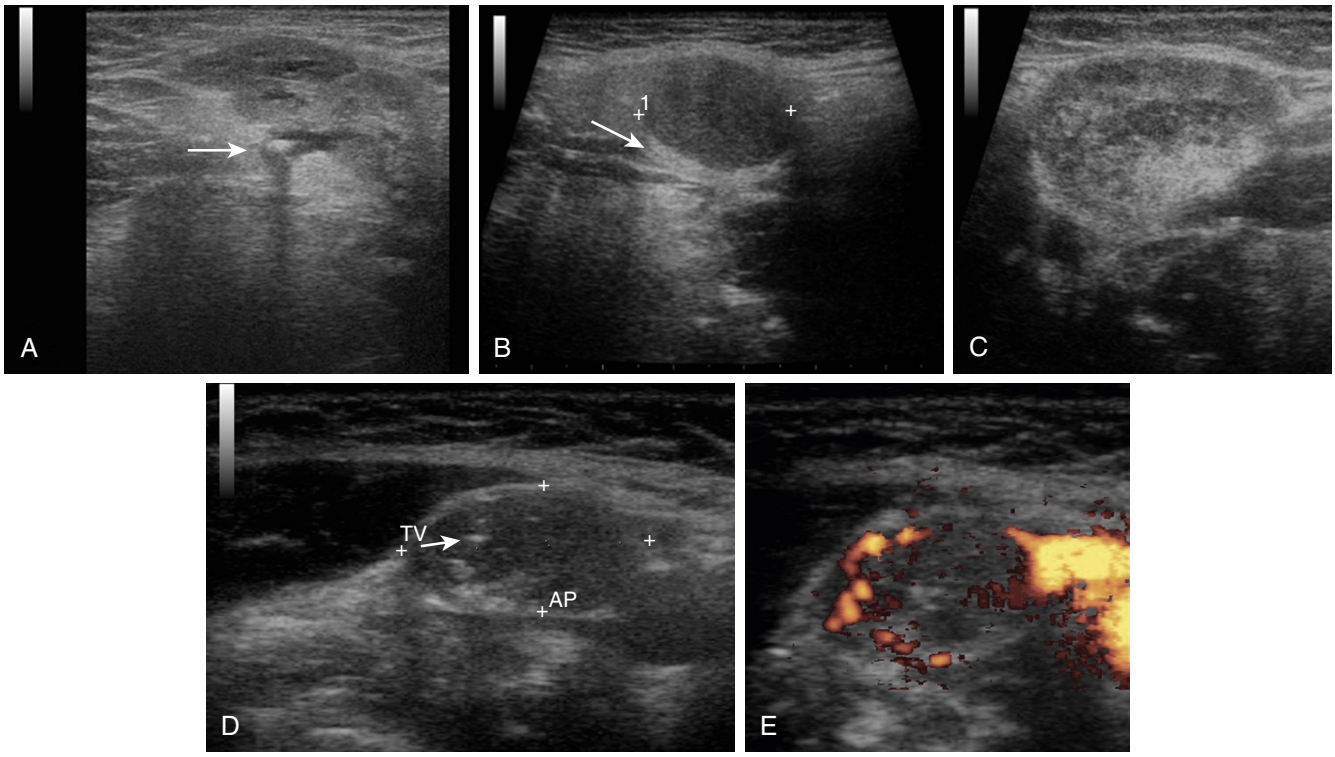

Fig. 87.1. Ultrasound Images. A, Submandibular stone—hyperechoic signal *(arrow)* with shadow artifact. **B,** Pleomorphic adenoma—hypoechoic mass with posterior enhancement *(arrow)*. **C,** Cystic degeneration from Sjogren's syndrome. **D,** Necrotic adenopathy with loss of hilum and microcalcification. **E,** Pripheral vascularity seen in malignant adenopathy. *TV,* transverse; *AP,* anterior/posterior.

gland, cyst formation (seen in Sjogren's syndrome, HIV, atypical infections), ductal dilation (seen with salivary stricture or sialolithiasis), honeycomb appearing parenchyma (seen with lymphoma and Sjogren's syndrome). In the neck, ultrasound can visualize vital neck anatomy (thyroid, lymph nodes, and vessels), characterize palpable mass in the neck, or visualize nonpalpable malignant adenopathy. Using characteristic imaging criteria, thyroid and neck masses can be radiographically triaged for biopsy (see Chapter 78 and Chapter 64).

1. Computed tomography (CT)
   CT scan may reveal salivary calculi, markedly dilated ducts, saliva gland masses, and a mass in the neck and thyroid. When performed with contrast, the CT scan may reveal primary aerodigestive tract lesions and malignant adenopathy (>1 cm, round, necrosis), reveal pharyngeal space lesions (deep lobe parotid tumors), and help classify vascular lesions.
2. CT angiography
   Useful when the clinician suspects a vascular tumor (carotid body) or anticipates trauma to the carotid artery
3. Magnetic resonance imaging
   Useful when the clinician suspects soft tissue masses (superficial or deep lobe parotid lesions), vascular lesions (glomus tumors, paragangliomas), or neural tumors (schwannomas, neurofibromas)
4. Angiography
   May be required for evaluation of carotid body tumors and preoperative embolization. If carotid artery injury or sacrifice is anticipated, angiography may be used to direct therapy (embolization/stenting) or assess for circle of Willis communication (balloon occlusion).

Indications

1. Mass in the neck, thyroid, or saliva glands refractory to conservative therapy
   Ultrasound and FNA allow for imaging characterization and pathologic assessment of the lesion. The ultrasound enhances accuracy of the biopsy and may help distinguish malignant from benign lesions. FNA directs future management/treatment. Even when lymphoma is suspected, FNA provides an initial diagnostic assessment of the concerning adenopathy, which will prevent the clinician from inadvertently performing an excisional or incisional biopsy of metastatic adenopathy and contaminating the neck. With enough passes,[1-2] lymphoma may be identified by FNA alone and confirmed with flow cytometry, obviating the need for a surgical procedure and expediting patient care. With the exception of Hodgkin's lymphoma, which may show a polymorphous lymphoid population on cytology, lymphoma will often reveal a monoclonal population on cytology, confirming the clinical diagnosis of lymphoma. In some cases, patients may still require incisional or excisional biopsy to further categorize the type of lymphoma, but following this algorithm, at least other malignancies have been excluded prior to violating the neck.
2. Recurrent acute and chronic sialadenitis
   Sialendoscopy with or without sialolithotomy effectively relieves salivary gland obstruction related to high viscosity salivary debris, sialolithiasis, or salivary stricture. Patients with chronic progressive salivary dysfunction from autoimmune disease (Sjogren's syndrome) and radioactive iodine therapy for thyroid cancer also respond symptomatically to sialendoscopy. Ultrasonography is also useful in localizing nonpalpable salivary calculi, directing incisions in the floor

of the mouth for salivary calculi, and managing complex salivary strictures (visualization of balloon dilator position, transfacial access to dilated proximal parotid duct for Seldinger technique anterograde dilation). Typically calculi less than 3 mm are amenable to endoscopic retrieval. Larger calculi greater than or equal to 4 mm often require the addition of a cutdown and ductotomy or fragmentation of the calculi.

3. Transcutaneous injections and vocal fold motion
   In addition to the imaging and biopsy guidance afforded by ultrasonography, the ultrasound can also be effective for targeting Botox injections into the salivary glands for sialorrhea or into the muscles of mastication for refractory temporomandibular joint pain with associated muscle hypertrophy (temporalis and masseter). Ultrasound may also be used to map difficult laryngeal anatomy and direct injections into the subglottis (steroid for subglottic stenosis) and vocal folds for augmentation, and direct Botox for spasmotic dysphonia. In many patients, vocal fold and/or arytenoid motion may be seen through the cricothyroid or thyrohyoid membranes.

Contraindications

1. Patients with strong vasovagal reactions
   Patients who report vigorous vasovagal reactions are not suitable for in-office minor procedures. FNA may be possible, but patients require preprocedural counseling, and the clinician should be prepared to handle an episode.
2. Antiplatelet therapy or bleeding disorders
   Patients with bleeding disorders are best managed in an operating room setting. Those on antiplatelet therapy should discontinue therapy prior to elective procedures. FNA may still be performed safely in these patients, as the bore of the needle is narrow in caliber. Patients should be prepared for likely bruising at the biopsy site.

Preoperative Preparation

1. External surfaces should be cleansed with alcohol prior to the procedure.
2. Discontinue antiplatelet drugs if possible prior to invasive salivary procedures.
3. In the case of FNA, slides should be prepared and labeled and containers ready.
4. When performing intraoral procedures, a suction should be made available.

OPERATIVE PERIOD

Anesthesia

1. Local: Although these procedures can be performed in the operating room, the administration of local anesthesia is sufficient for FNA and most salivary procedures in the vast majority of patients. From a practical standpoint, these procedures are performed in the office, and therefore avoidance of sedation expedites patient throughput, decreases the need for additional patient monitoring, and allows patients to transport themselves to and from clinic. Injectable 1% lidocaine with 1:100,000 epinephrine into the skin site overlying the FNA improves patient comfort with the FNA, particularly when multiple passes are planned. For sialendoscopy, an intraductal irrigation with a 2% lidocaine solution is sufficient anesthesia for diagnostic endoscopies and sialolith wire basket retrievals. The clinician should be careful to limit the volume and pressure of the irrigation, as high-pressure irrigation will result in cell/duct damage, diffusion of local anesthetic into the soft tissues, and patient discomfort. It is recommended to limit the volume of lidocaine irrigation to less than 5 cc. If further irrigation is required, due to length of the procedure, the clinician should then transition to sterile saline.
2. Awake sedation: This may improve patient tolerance with FNA in select cases, but requires the physician obtain sedation privileges and that the clinic setting is appropriately outfitted for sedation. One of the challenges with sedation can be the depth of sedation: too little and the patient will move, deleteriously affecting efficacy of the procedure; too much and the respiratory drive and airway protection may be suppressed. Therefore, sedation is not recommended for sialendoscopy but may be a feasible route for select cases of FNA, such as the otherwise healthy adult or child whose anxiety over needles prevents a purely local anesthetic approach.
3. General: Reserved for pediatric patients and those with developmental delays who are unable to cooperate and remain still for an FNA, for patients with large parotid calculi requiring transfacial cutdown procedures, and those unable/unwilling to undergo salivary procedures under local anesthesia.

Positioning

1. Chair: The patient is positioned ideally in an adjustable procedure chair. For FNA procedures, the clinician may elect to stand and have the patient sitting upright, or sit and position the patient supine. In cases where the patient becomes vasovagal, the clinician should have the ability to place the patient in a supine or slightly Trendelenburg position. For salivary procedures, the patient is ideally positioned in the upright sitting position to allow for optimal patient control of secretions and ergonomic positioning for the physician, particularly while performing endoscopy and viewing the monitor.
2. Prone
3. Lateral recumbent

Perioperative Antibiotic Prophylaxis

1. None: Not required unless the patient has a prosthetic implant (heart valve) and sialolithotomy is planned
2. Second-generation cephalosporin
3. Clindamycin

Monitoring

1. None

Instruments and Equipment to Have Available

1. FNA
   a. Ultrasound
   b. Fine-bore needles (23 to 25 gauge), 1 to 1.5 inch length
   c. 10-mL Luer-lock syringes
   d. Glass slides
   e. 95% alcohol or a spray fixative
   f. Alcohol swabs
   g. 1% lidocaine with 1:100, 000 epinephrine, or alternative local anesthesia
   h. IV extension tubing (optional). The tubing is ideal for ultrasound-guided suction aspiration technique, as the operator holds the needle at the hub and therefore has markedly improved dexterity. (Fig. 87.2)
   i. Balanced salt solution (optional) for rinsing the needle

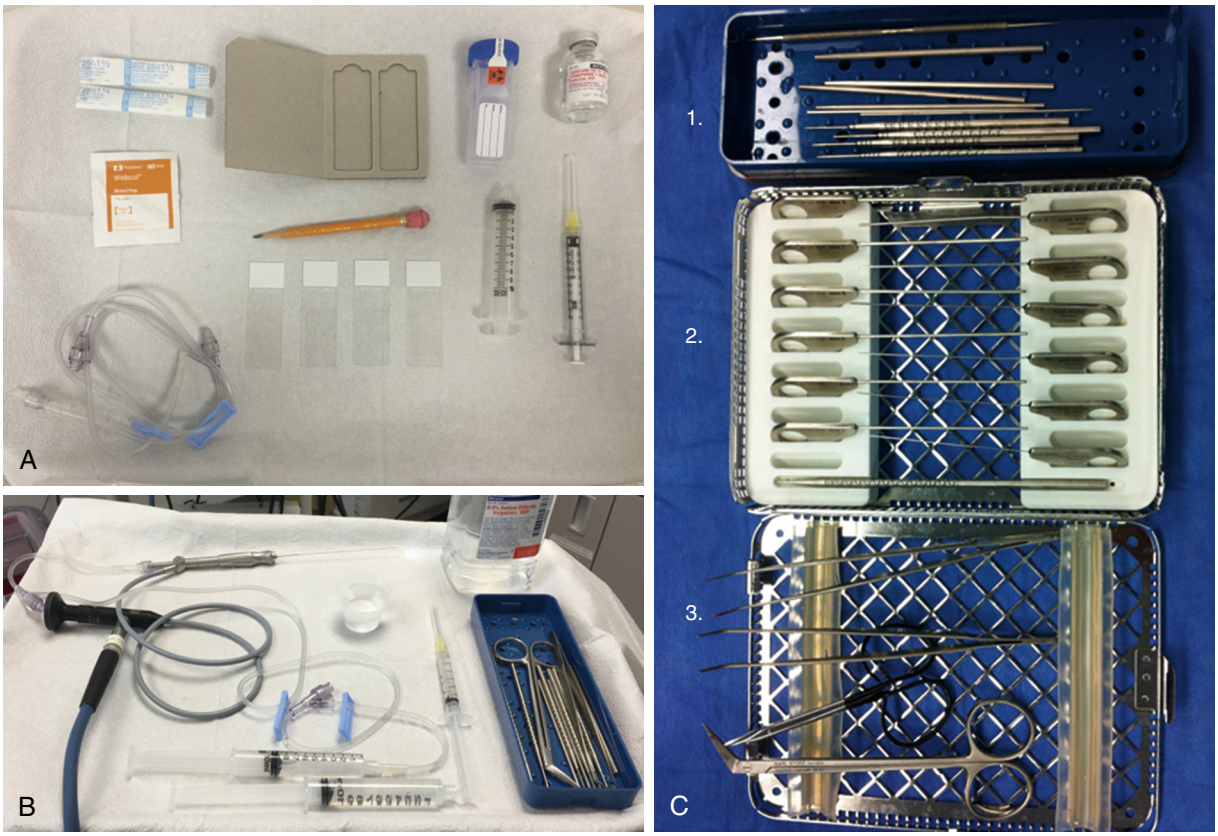

Fig. 87.2. Procedural Equipment. A, Equipment for a standard ultrasound guided fine needle aspiration. **B,** Basic equipment for in office sialendoscopy. **C,** Accessory sialendoscopy equipment—*1*. Conical and tapered dilators; *2*. Lacrimal probes; *3*. Forceps and sharp scissors.

2. Sialendoscopy.
   a. Salivary dilators/probes
      1) Conical dilators, Marchal dilators, tapered dilators, Bougie dilators
   b. Sialendoscopes: Diagnostic (0.8 mm) and interventional scopes (0.4 mm working channel; 0.6 mm working channel)
   c. Sterile normal saline
   d. 2% lidocaine solution
   e. IV extension tubing
   f. Light cord; HD video camera attachment and video tower
   g. Yankauer suction and tubing
   h. Injectable local anesthesia (noted previously)
3. Sialolithotomy
   a. Items listed under sialendoscopy
   b. 0.4 mm and 0.6 mm wire baskets
   c. Endoscopic graspers
   d. 11 or 15 blade scalpel
   e. Fine-toothed forceps
   f. Salivary stents

Key Anatomic Landmarks

1. Wharton's duct papilla: Located in the anterior floor of the mouth bilaterally, just lateral to the frenulum, the papilla is a raised area of mucosa, which contains the punctal orifice of the submandibular duct.
2. Stensen's duct papilla: Located within the buccal mucosa bilaterally and adjacent to the premolars, the papilla is a raised area of mucosa, which contains the punctal orifice of the parotid duct.
3. Submandibular hilum: The posterior edge of the mylohyoid muscle seen on ultrasonography separates the submandibular duct into a hilar component and a distal ductal region. Calculi posterior and inferior to the posterior edge of the mylohyoid muscle are considered hilar calculi and may be more difficult to palpate and extract.
4. Ramus of the mandible: The anterior and posterior edges of the ramus of the mandible can be seen on ultrasonography. Location of a calculus relative to the mandible will often dictate the ease and approach for sialolithotomy.[1]

Prerequisite Skills

1. Diagnostic ultrasonography
2. Sialendoscopy

Operative Risks

1. Bleeding due to fine needle trauma to a superficial vessel (self-limited): Using color flow Doppler prior to performing an aspiration, the practitioner can plan a biopsy route to avoid vasculature.
2. Duct perforation: The parotid and submandibular ducts are pliable membranous structure. Sialendoscopy involves rigid endoscopy under a hydrostatic irrigation. Vigorous blind instrumentation can lead to duct perforation and fluid extravasation. Patient real-time feedback with respect to examination comfort is an advantage of awake sialendoscopy. In addition, use of a guide wire for Seldinger advancement of the scope may also reduce trauma in the patient with a stricture. Given the narrow nature of the

parotid duct, its thicker wall, and its tortuous course over the ramus of the mandible, the parotid duct is more prone to injury.
3. Duct avulsion: This is primarily an issue when a practitioner attempts to extract a calculus, which exceeds the lumen size, with wire basket retrieval using excessive force. If a calculus is snared but the calculus does not withdraw with mild tension, the practitioner should be prepared to perform a direct duct cutdown and removal.
4. Hyperinflation of the gland: Overzealous irrigation during endoscopy, particularly in long cases, can lead to significant gland swelling and discomfort, as well as disruption of the basement membrane of the acini. Low-volume irrigation is recommended. If local anesthesia is used in the irrigation during the endoscopy, the volume of local anesthetic should be limited to prevent extravasation of the local anesthetic resulting in facial weakness or intravascular absorption resulting in vasovagal reactions or tachycardia.

Surgical Technique

Ultrasound-Guided Fine Needle Aspiration

Prior to discussing ultrasound guidance for needle aspiration, a review of proper ultrasound technique is required. The linear transducer is a flat, narrow-based probe that produces the highest quality images when applied to a flat surface. The quality of the image depends on the transmission and collection of sound waves, —hence a gel buffer between the probe and skin is required to maximize sonic transmission. As the neck is a highly contoured region, the utility of ultrasound depends on probe manipulation in an orientation that maximizes complete flat contact. Proper handling of the probe, with the operators' fingers and thumb gently and comfortably grasping the base of the probe above the transducing portion, allows for maximal control for fine motor manipulation, rotation, angulation, and steadying of the probe during biopsy.

Procedure Preparation

1. Prep the skin with alcohol.
2. Percutaneous injection of local anesthesia under ultrasound guidance
   a. Typically 0.5 to 1 mL of 1% lidocaine with 1:100,000 epinephrine loaded on a 1-mL syringe with a 27-gauge needle will suffice.
3. Map lesion with ultrasound probe lined with gel.
   a. As opposed to the traditional FNA, when performing ultrasound guided-FNA, the site of skin puncture does not typically directly overlie the mass. Instead, the probe overlies the mass and the needle is introduced into the skin tangential to either the long axis (longitudinal technique) or short axis (transverse technique) of the probe. The degree of angulation of the needle with respect to the skin and probe is dependent on the depth of the wound, and with experience, this angulation can be better predicted.

Longitudinal Technique

1. Probe and needle orientation
   For novice practitioners, the longitudinal technique is preferred, as the full shaft of needle can be visualized during correct placement. In this technique, the probe is centered over the mass with the orientation notch to the patient's right, and local anesthesia is applied to the skin adjacent to the end of the probe with the notch. This ensures that the direction of the needle on screen will mirror that of the needle in the clinician's hand. This provides the clinician an opportunity to assess the trajectory necessary for the biopsy. (Fig. 87.3A and B)
2. Needle placement
   It is my practice to handle the needle directly, and either perform capillary (suction free technique) action or use a suction aspiration technique where an IV extension tubing is used to connect the needle to a syringe operated by an assistant. The needle is advanced initially through the skin in line with midline longitudinal axis of the probe under ultrasound guidance toward the lesion, adjusting the trajectory as needed. To maximize visualization of the tip, the needle should be placed with the bore facing directly toward the face of the probe.
3. Biopsy technique
   Once in the mass, the suction is applied, or the finger released off of the hub, in the capillary technique, and brisk stokes are made with the needle under guidance through the mass. The length of the stroke is dependent on the space of the lesion. The ability to vary needle stroke length and improve tissue acquisition with each individual mass is another benefit afforded by ultrasound guidance. Aspiration is discontinued once material enters the needle hub; the improved diagnostic yield afforded by ultrasound guidance allows clinicians to limit the sample to one to two passes.

Transverse Technique

The transverse technique is more technically challenging but is also more versatile than the longitudinal technique (see Fig. 87.3C and D). The transverse technique minimizes the distance between the skin and the lesion, mirroring more the trajectory of the traditional unguided technique. The relative disadvantage of this technique is the limited visualization of the needle, as the needle is traveling through the tissue in a plane perpendicular to the probe and therefore will appear only as a dot on the two-dimensional screen

1. Probe and needle orientation
   During this technique, the probe is typically held in standard cross-sectional fashion, and the skin is anesthetized superior to the probe in the midsagittal plane of the probe. The degree of angulation of the needle with respect to the skin and the probe is dependent on the depth of the lesion. Deep lesions require a more vertical needle orientation with respect to the skin.
2. Needle placement
   In this technique, the needle is introduced into the skin and advanced with a gentle vibratory motion while the operator keenly observes the area of motion on the screen until a bright "dot" appears. Attention during this portion of the exam is important, as the needle image will never appear bigger than a dot, regardless of which portion of the needle is in view. If there is concern of the needle being "passed point," either the needle can be slowly withdrawn until the dot disappears or the probe can been manipulated along a plane parallel to the needle trajectory. Once in the specimen, aspiration can begin as noted previously.
3. Technical tips
   Adjusting (lowering) the dynamic range on the control panel will help to enhance the appearance of the needle during biopsy. The activation of color flow during the biopsy allows the operator to visualize vessels but simultaneously reduces the visualization of the needle. It is recommended therefore to map the pathway on color flow Doppler first and then perform the needle biopsy on the standard B-mode.

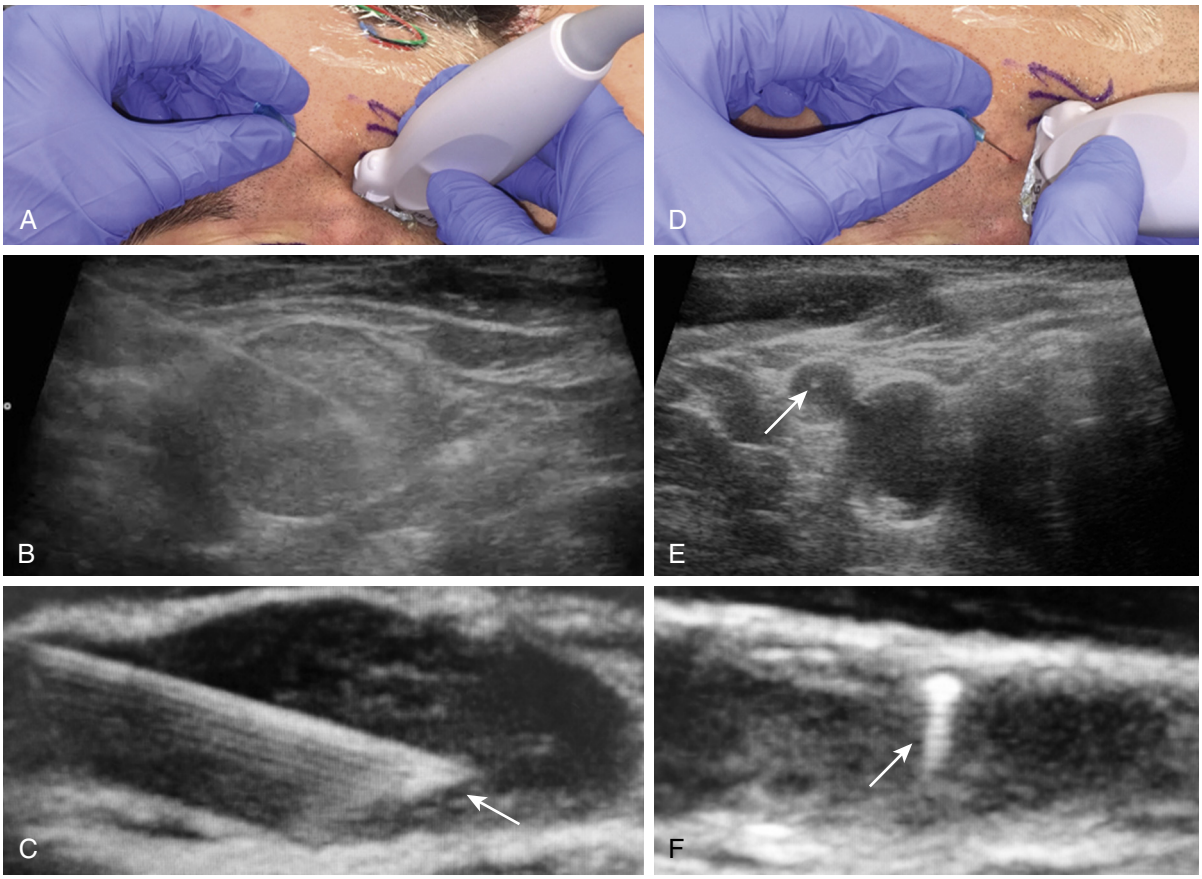

Fig. 87.3. Ultrasound fine needle aspiration techniques. A, Proper hand, probe, and needle position for longitudinal technique. **B,** Ultrasound image of longitudinal technique into hypoechoic parotid mass. **C,** Magnified view of longitudinal technique displaying the classic reverberation artifact of the shaft and tip *(arrow)*. **D,** Proper hand, probe, and needle position for transverse technique. **E,** Ultrasound image of transverse technique with needle tip in the mass *(arrow)*. **F,** Magnified ultrasound view of needle tip with reverberation artifact on transverse technique *(arrow)*.

Office-Based Sialendoscopy/Sialolithotomy

Office-based salivary procedures are well tolerated in appropriately selected patients.[2] These are two-person procedures, and thus a capable assistant is required. Patients with large (>4 mm) parotid calculi will likely require a transfacial approach and hence should be excluded from an office setting. However, submandibular calculi may be removed in an office setting, provided they are either palpable and/or less than 3 mm.[2,3] Endoscopic retrieval is well tolerated, and direct floor of mouth incisions for megalith calculi (>7 mm) are very feasible in the appropriately selected patient. As a rule, the submandibular duct is more challenging to access for dilation and endoscopy but easier to navigate than the parotid duct, due to the variances in the size of the duct, the thickness of the wall, and surrounding anatomic barriers (ramus of the mandible).[2,3]

Procedure Preparation (Fig. 87.4)

The patient is placed in the upright position with suction available. The scope is white balanced and irrigation connected. Scope selection is dependent on the goal of the procedure. Diagnostic exams are best performed with the 0.8-mm sialendoscope. Stone removal requires a 0.6-mm or 0.4-mm (preferable size for parotid duct procedures) working channel scope. The default setup in the office is to have the tower behind the patient's left shoulder with the practitioner standing alongside the patient's right and facing the patient with the chair height position ergonomically adjusted for the practitioner. Dilators and probes, along with topical and injectable anesthesia, are laid out. Prior to insertion, it is essential the practitioner have the scope oriented to the display screen. Unlike sinus endoscopy, the camera attachment is separate from the handheld portion of the scope. Therefore, the camera attachment must be stably oriented before the procedure. Such orientation will assure the practitioner of a 0-degree view when the scope is held with the irrigation port in the upright position.

Sialendoscopy

Stensen's Duct

The patient maintains mouth opening while the practitioner gently grasps the cheek at the oral commissure. The other hand gently massages the gland from the tail to the duct orifice while observing for salivary outflow. The duct orifice is identified and then gently dilated serially with lacrimal probes or tapered dilators. This step often is painless, however, if the patient reports discomfort; injectable anesthesia can be placed around the papilla. Next, the sialendoscope is introduced and a topical lidocaine infusion is used while the practitioner advances the scope under direct visualization to the hilum. The parotid duct may take a tortuous course, and manipulating the patient's degree of mouth opening may help navigate the scope over the ramus of the mandible. After the initial 5 mL

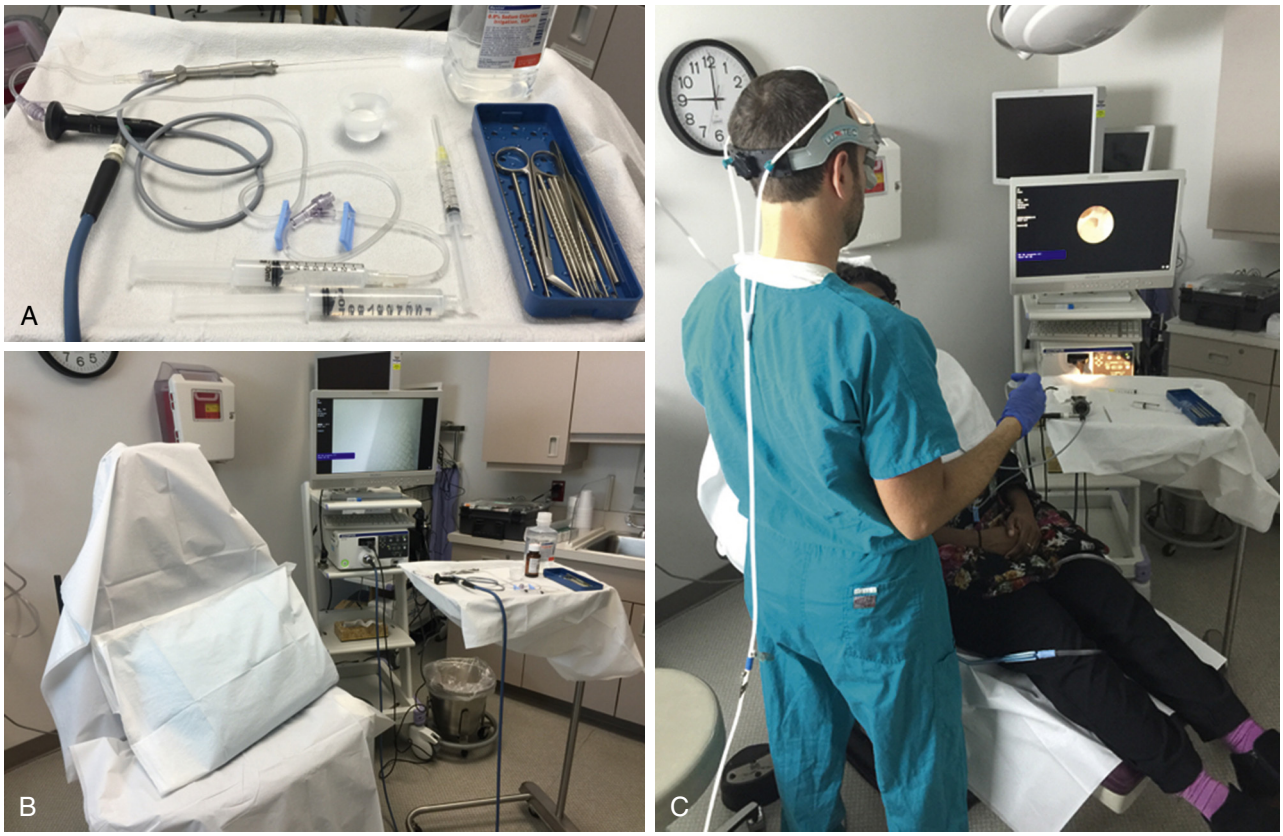

Fig. 87.4. Sialendoscopy Office Procedure. A, Mayo stand set-up with scope, tubing, dilators, saline, and local injectable anesthesia. **B,** Room set-up for procedure. **C,** Practitioner and patient in ergonomic position for procedure.

of 2% lidocaine infusion with pressure titrated to patient comfort, a normal saline infusion is used. Debris is flushed from the system. Debris may indicate a calculus or inflammation of the duct. If a calculus is seen, the 0.4-mm working channel scope is then introduced. In cases where the duct is narrow/tight, a guide wire may be used to navigate the duct in Seldinger fashion and lower the risk of duct trauma/perforation. Small calculi may then be extracted via deployment of a 0.4-mm wire basket through the working channel of the scope. The basket is opened beyond the calculus and slowly withdrawn until the calculus is captured. The calculus and scope are removed together. If the calculus will not deliver from the orifice, a small controlled incision is made to widen the papilla. The scope is reinserted to check for further calculi.

In the case of salivary stricture, the ultrasound may be used with the scope to visualize the stricture and duct trajectory. In these cases, the proximal duct is often dilated and readily visible on ultrasound, as is the metal scope. Imaged-guided dilation may be performed with the scope or balloon catheters and then a stent placed for 2 to 3 weeks.

Wharton's Duct

The patient maintains mouth opening and lift of the tongue to expose the papilla. Mild submandibular pressure allows the surgeon to visualize flow out of the papilla. Citric acid powder may also be helpful. Next, serial dilation is performed with the various probes and dilators mentioned previously. When the patient reports discomfort local anesthesia 1% lidocaine with 1:100, 000 epinephrine may be injected with a 27- to 30-gauge needle, 0.1 to 0.3 mL, with care to place the injection site away from the expected natural orifice. The use of injection may also help with a "floppy" papilla, increasing the tissue turgor and allowing visualization of the orifice for dilation. The papilla should *not* be grasped with forceps during this step, as this results in trauma, bleeding, and potential scarring, as well as causing orifice confusion. If the orifice cannot be found, the practitioner can inject the floor of mouth proximal to the papilla with 0.5 mL of local anesthesia and perform a small cutdown and ductotomy (described later) to permit duct access and sialendoscopy.[4] Once access has been obtained, endoscopy proceeds as described previously. In cases of removal of a calculus, the larger 0.6-mm working channel scope is frequently used, as the duct is larger in caliber and has a greater capacitance.

Sialoithotomy

In cases of palpable submandibular stone more than 4 mm, endoscopic retrieval is not feasible. While laser lithotripsy has been described, its efficacy is poor and the time and safety implications with this technique obviate its use in the clinic setting. In the properly selected patient, floor of mouth cutdown may be performed at any portion of the duct, from the papilla to the hilum of the gland.

The patient maintains mouth opening while the practitioner displaces the tongue medially. In cases of posterior/hilar stones, the patient or assistant delivers superior submandibular gland pressure to displace the stone toward the floor of the mouth. Local anesthesia of 2 to 4 mL is injected into the floor of the mouth. After 5 minutes, a 3- to 4-cm incision is made in the mucosa overlying the palpable stone. Dissection is continued in the submucosa with sharp scissors. Care is taken to first identify and lateralize the lingual nerve. The stone is palpated in the duct and typically visible after identifying the nerve.

A controlled linear longitudinal incision is made on the duct over the calculus, large enough to remove the calculus. The ultrasound may be useful for localizing and sizing the calculus prior to or during the procedure. After release of the calculus and secretions, the sialendoscope is then introduced through the ductotomy to evaluate the proximal system and ensure there is no further pathology. For anterior calculi, it is recommended to place a suture proximal to the calculus to prohibit retropulsion of the stone to the hilum prior to floor of mouth incision or consider endoscopic basket entrapment prior to performing the cutdown.

In the case of posterior incisions, no duct repair is necessary, and the incision is left to heal by secondary intention as the rate of stricture is low. In addition, there is often up to 1 cm of soft tissue separation between the duct and mucosa. If significant trauma to the duct occurs, as in the case of an adherent calculus, stent placement may be performed from the natural orifice. Within the anterior floor of mouth, the duct is smaller and within millimeters of the mucosal surface, and therefore a formal sialodochoplasty is performed. 5-0 to 7-0 interrupted chromic sutures (three to five sites) are used to approximate the duct to the mucosa. If there is concern for duct lumen trauma, a stent may be placed as well.

Common Errors in Technique

Ultrasound-Guided-Fine Needle Aspiration

1. Delayed visual acquisition of needle in longitudinal technique
   A common error is to place the needle into the deep tissue and then search for the shaft. Often the angle and level of the needle are off target, and the practitioner will struggle to change the trajectory of the needle. Manipulation of the needle trajectory after the shaft is within the tissue is challenging, as often the thin bore shaft of the needle will bend under the pressure of the surrounding tissue. The practitioner should identify the tissue displacement created by the needle pressure at the skin level and then trace the needle shaft fully to the target in the longitudinal technique.
2. Using a large-bore needle—greater than 23 gauge
   This leads to increased blood in the specimen, decreasing the diagnostic yield.
3. Pass point placement of needle in transverse technique
   The tip and the shaft of the needle will look identical in this technique, so careful observation of the screen is needed to avoid a needle passed point error. Slow advancement of the needle and gentle toggling of the probe in a cranial-caudal direction ensures proper placement.
4. Overaggressive aspiration
   Too much blood in the specimen will lower the diagnostic yield. Careful observation of the vascular flow on ultrasound and the needle hub during biopsy prevents excessive blood in the specimen.
5. Leaving excess gel on the neck at the puncture site
   Ultrasound gel will distort the cytology smear and create an artifact if it incidentally enters the needle hub during aspiration.

Sialendoscopy/Sialolithtomy

1. Grasping the papilla with forceps or injection near the papilla
   This can result in bleeding or trauma leading to delayed scarring, or distortion of the anatomy leading to false passage during dilation.
2. Improper camera orientation
   This significantly hinders driving the scope and performing endoscopy.
3. Advancing the scope against resistance and/or without view of the lumen
   This may lead to perforation of the duct and soft tissue trauma, which results in aborting the case.
4. Overaggressive irrigation
   This leads to patient discomfort and gland swelling. If performed with local anesthesia, the patient may develop transient facial weakness, headache, or vasovagal symptoms due to extravasation of to the soft tissue and vasculature.
5. Withdrawing the calculus in a wire basket against resistance
   If the calculus fails to slide forward for extraction, excessive force may lead to duct avulsion. In the case of a trapped basket, a cutdown technique is needed to complete stone removal.
6. Excessive torque on the endoscope
   The scopes are rigid, but *very* fragile. The scopes will fracture very easily if bent while trying to navigate around a corner on the screen. This is a particular risk in parotid sialendoscopy when trying to maneuver around the mandible.

POSTOPERATIVE PERIOD

Ultrasound-Guided Fine Needle Aspiration

Postoperative Management

1. Assess for bleeding at the skin level.
2. Assure the patient is not lightheaded after completion of the biopsy and in a seated position.
3. If symptomatic, the patient's vital signs should be checked.

Complications

1. Hematoma
   Given the fine-gauge needles used, if a hematoma occurs, it is small and self-limiting and will respond to direct pressure.
2. Nondiagnostic yield
   If a nondiagnostic sample occurs, repeat sampling versus and open biopsy may be performed.

Alternative Management Plan

1. Core needle biopsy
   When lymphoma is suspected, more tissue may be necessary and a core needle may be performed. However, a prior fine needle aspirate result suspicious for lymphoma should direct whether this is necessary.
2. Incisional biopsy
   When lymphoma is suspected, more tissue may be necessary and an incisional biopsy may be performed. However, a prior fine needle aspirate result suspicious for lymphoma should direct whether this is necessary.

Sialendoscopy/Sialolithotomy

Postoperative Management

1. Patients undergoing posterior floor of mouth cutdown require 3 to 5 days of a narcotic analgesic.
2. All patients are instructed to maintain hydration and massage their glands at least twice per day.
3. If stents are placed, the patient returns 2 to 3 weeks later for removal.

Complications

1. Perforation of the duct
   This occurs from overaggressive blind advancement of the scope—typically in the parotid system. If this occurs, the procedure is immediately terminated.
2. Trapped basket: Basket containing a stone that cannot be removed
   A cutdown procedure is needed to remove the basket and the calculus.
3. Punctal trauma and false passage
   This occurs with grasping the papilla and may lead to stricture. It can be avoided with the no touch gentle technique described previously.
4. Failure to reach or removed calculus
   Patient may require an operating room attempt at removal versus excision of the gland.
5. Trauma to the duct
   If severe, this may lead to stricture and recurrent obstructive sialadenitis; stent placement may mitigate risk of stricture.
6. Vasovagal reaction
   This may be due to patient factors or overinfusion of lidocaine solution. The case should be aborted and patient recuperated.
7. Bleeding
   This is rarely an issue and usually responsive to bipolar cautery. It is seen in posterior floor of mouth cutdown procedures, typically with deep dissection.

Alternative Management Plan

1. Operating room procedure
   Patients may not tolerate the procedure from a pain or vasovagal reaction standpoint. In these situations, an operating room attempt may be successful.
2. Excision of the gland
   If the patient is refractory to endoscopic therapy or the stone cannot be removed, gland excision is an effective treatment option.

DISCUSSION

Evidence-Based Medicine Question: Does Ultrasound Guidance Improve Specimen Adequacy in a Cost-Effective Manner?

Khalid et al. in 2008 performed a cost-effective analysis of ultrasound-guided FNA and traditional FNA. Ultrasound guidance improved specimen adequacy 95% versus 80% at an additional cost of $289 per correct diagnosis.[5]

Editorial Comment

The practitioner faced with patients with salivary problems has many fine tools available for office-based diagnosis and treatment. Increasingly, ultrasound has become an extension of the physical exam of head and neck patients. Salivary endoscopy is increasingly finding its way into the office as well, for the diagnosis and treatment of certain obstructive salivary pathologies.

Barry Schaitkin

Evidence-Based Medicine Question: Is Sialendoscopy Effective in the Management of Salivary Pathology?

A meta-analysis revealed weighted pooled success rates of 86% (endoscopy alone) and 93% (endoscopy with combined procedure) for patients undergoing sialendoscopy for obstructive disease.[6]

Access the review questions online at http://www.expertconsult.com

REFERENCES

1. Kiringoda R, Eisele DW, Chang JL. A comparison of parotid imaging characteristics and sialendoscopic findings in obstructive salivary disorders. Laryngoscope 2014;124(12):2696–701.
2. Marchal F, Becker M, Dulguerov P, et al. Interventional sialendoscopy. Laryngoscope 2015;125(11):2427–9.
3. Rahmati R, Gillespie MB, Eisele DW. Is sialendoscopy an effective treatment for obstructive salivary gland disease? Laryngoscope 2013;123(8):1828–9.
4. Chang JL, Eisele DW. Limited distal sialodochotomy to facilitate sialendoscopy of the submandibular duct. Laryngoscope 2013;123:1163–7.
5. Khalid AN, Quraishi SA, Hollenbeak CS, et al. Fine-needle aspiration biopsy versus ultrasound-guided fine-needle aspiration biopsy: cost-effectiveness as a frontline diagnostic modality for solitary thyroid nodules. Head Neck 2008;30(8):1035–9.
6. Strychowsky JE, Sommer DD, Gupta MK, et al. Sialendoscopy for the management of obstructive salivary gland disease: a systematic review and meta-analysis. Achiv Otolaryngol Head Neck Surg 2012;138(6):541–7.

REVIEW QUESTIONS

1. Ultrasound guided FNA can reliably diagnose the following lesions *except*
   a. Squamous cell carcinoma
   b. Lymphoma
   c. Schwannoma
   d. Thyroid cancer

2. All of the following factors affect specimen adequacy *except*
   a. Ultrasound gel
   b. Needle gauge
   c. Suction aspiration
   d. Use of local anesthesia

3. Which of the following remarks about technique is accurate?
   a. Capillary action is preferable for a vascular thyroid nodule
   b. Longitudinal technique is preferred for a deep lobe thyroid nodule
   c. Transverse technique involves tracking the needle throughout its course
   d. Needle track adjustments are easier once the needle is within the deep tissues

4. All of the following are true with regard to salivary stone management *except*
   a. Parotid stones greater than 4 mm should be addressed in the operative room
   b. Follow-up endoscopy is necessary after stone removal
   c. All cutdown procedures require a sialodochoplasty
   d. Impacted calculi have a higher rate of delayed stricture

5. Which of the following techniques should be avoided?
   a. Placing a suture around the duct proximal to the stone
   b. Injection of the papilla with local anesthesia
   c. Floor of mouth incisions for stones greater than 7 mm
   d. Grasping the papilla during dilation

6. All of the following increase the risk of gland/duct trauma *except*
   a. Use of ultrasound for image guidance
   b. Overaggressive irrigation
   c. Advancement of the scope against resistance without a clear lumen
   d. Wire basket removal against resistance

7. Which of the following statements is true?
   a. Sialendoscopes are easily fractured with minimally force/bend
   b. Duct perforation necessitates immediate case abortion
   c. Submandibular stone size does not determine candidacy for an office-based procedure
   d. All of the above

88 Salivary Endoscopy

Barry Schaitkin, Rohan R. Walvekar

INTRODUCTION

Salivary endoscopy is a minimally invasive technique for the treatment of a variety of inflammatory salivary gland pathologies. The procedure has been in practice globally since the early 1990s. The small high-resolution telescopes are in their fifth generation of development and now incorporate rinsing and instrumentation capabilities. The technique is useful for removing calculi and treating stenosis, as well as for inflammatory conditions such as Sjögren's syndrome, recurrent juvenile parotitis, and for the secondary effects of radioactive iodine on the major salivary glands.

Patients most commonly present with meal-time obstructive symptoms of swelling of the gland and discomfort with provocation. The inflammatory processes can have more constant symptoms not associated with meals.

KEY OPERATIVE LEARNING POINTS

- The dilation of the papilla of the submandibular gland (SMG) and parotid gland is the initial rate-limiting step and requires delicate handling of the tissue.
- The SMG duct is difficult to access via the papilla but very easy to navigate with the salivary endoscope.
- Although the papilla of the parotid is relatively easy to dilate, the challenge is where the duct curves around the masseter muscle. Straightening the duct helps to facilitate this part of the endoscopy.
- The scopes range in size from the diagnostic scope (0.8 mm) to therapeutic scopes (1.1 to 1.6 mm).

PREOPERATIVE PERIOD

History

- History of present illness
  - Duration of symptoms
  - Age at onset
  - Provocation with meals
  - Previous history of calculi
  - Dry eye and/or dry mouth
- Past medical history
  - History of radioactive iodine
  - Previous surgery of the salivary gland
  - Medical illness
  - Family history
  - Medications:
    - Anticoagulants

Physical Examination

- Palpation of all major salivary glands
- Intraoral examination including examination under the operating microscope
  - Notation of size and location of the papilla particularly of SMG
  - Observation of quality and quantity of expressible saliva
  - Palpation for calculi along Wharton's duct
  - Palpation for calculi at or near the papilla of Stensen's duct
  - Evaluation of potential surgical challenges to the procedure
    - Teeth
    - Tori
    - Piercings

Imaging

- Ultrasound (US) is the primary imaging modality outside of the United States and is becoming more popular in the United States. US is able to detect calculi as small as 2 mm and is very good at demonstrating ductal dilation associated with any form of obstruction. It is also a dynamic study and can be done with concurrent salivary stimulation with food. It is also possible to do the study with intraoral palpation to further delineate calculi. The most difficult area to image is the anterior aspect of Wharton's duct.
- Computerized tomography (CT) without contrast is very good at identifying calculi larger than 1 mm. It is not useful for most cases of stenosis unless the duct is dramatically dilated. Contrast should be used in cases where a neoplasm remains in the differential diagnosis.
- Sialography
  - Conventional sialography is invasive and very operator and interpreter dependent, but it can be useful in some difficult to understand cases of obstruction.
  - MRI sialography is available in a few centers. No contrast is required because the saliva is used as contrast. It is expensive and has all the limitations of normal MRI. It requires extra back table work and programming to acquire the images.

Indications

- Obstruction of the salivary glands by history and imaging compatible with calculi or stenosis
- Inflammatory conditions significant enough to warrant operative intervention due to frequency and severity
- Symptoms related to administration of I^{131}

Contraindications

- Salivary endoscopy during an acute infection is a relative contraindication with the possibility of worsening the infection or perforating the duct.
- Medical comorbidities should not be a contraindication because most of these procedures can be done using local anesthesia alone or with awake sedation.

Preoperative Preparation

- Preoperative antibiotics if necessary to control an acute process

OPERATIVE PERIOD

Anesthesia

- General: Although this procedure can be done using local anesthesia or with awake sedation, general anesthesia is

often preferred for patient comfort. For some hybrid procedures and bilateral cases, nasal intubation may provide better exposure in the oral cavity.
- Awake sedation is possible.
- Local anesthesia, including office salivary endoscopy, is possible in some situations.

Positioning

- Supine: The patient is positioned the same as any endoscopic sinus procedure with the head turned slightly toward the surgeon.

Perioperative Antibiotic Prophylaxis

Not all surgeons use perioperative or postoperative antibiotics for a routine type of procedure. However, if there has been recent infection or for a combined approach with some degree of opening through the mucosa combined with an endoscopy, antibiotics are recommended.

- If combined approach through a face lift incision is used to address parotid pathology, then a first-generation cephalosporin is used.
- Clindamycin if the patient is allergic to penicillin
- Patients having transoral hybrid procedures receive amoxicillin/clavulanic acid.

Monitoring

- For combined approaches to the parotid gland and Stensen's duct, some surgeons use facial nerve monitoring. There is no evidence that it improves outcomes, and we do not use such monitoring.

Instruments and Equipment to Have Available

- Camera and light source tower for endoscopy
- Basic salivary endoscopy set with mouth props, dilators of multiple types, and delicate scissors and forceps
- Retractors including sweetheart, malleable, and self-retraining
- 20-cc syringe with saline
- Irrigations with intravenous (IV) connecting tubing
- Multiple salivary endoscopes of different dimensions (1.1, 1.3, and 1.6 mm) for different pathologies
- Disposable instruments including stone baskets, balloons, dilators, and stents
- Kenalog
- Local anesthesia if the case is not under general; local without epinephrine can be used as the irrigation fluid instead of saline to stent the duct open to perform the procedure

Key Anatomic Landmarks

- Internally the SMG papilla is located posterior to the anterior incisors, although its exact location is variable and should be noted in the office while stimulating the patient's salivary glands with food.
- The parotid papilla is adjacent to the second molar in the buccal mucosa.
- Stensen's duct is in close proximity to the buccal branch of the facial nerve.
- Calculi in the hilum of the SMG are close to the lingual nerve, which frequently has to be moved laterally for hybrid approaches to an SMG calculus.

Prerequisite Skills

- Endoscopic skills
- Basic open head and neck surgery skills
- Patience

Operative Risks

- Failure to retrieve the calculus or eliminate the pathologic process
- Perforation of the duct by penetrating the duct with the scope
- Avulsion of the duct by pulling too hard on an impacted calculus
- Blocked basket requiring an open procedure to retrieve the basket stuck on a salivary calculus
- Stenosis of the duct from instrumentation, laser thermal injury, or combined approach incisions
- Airway obstruction from irrigation
- Cranial nerve injury to the lingual or buccal branch of the facial nerve during hybrid procedures
- Bleeding from an injured vessel. No risk of these during purely endoscopic procedures
- Failure of the procedure and the need for excision of the salivary gland

Surgical Technique

- Salivary endoscopy

Submandibular Gland

- Patients are selected for local, monitored anesthesia care, or general anesthesia based on patient factors, pathology, and comorbidities.
- Visualize the papilla with magnification.
- Saliva milked from the gland is a useful landmark but is of limited quantity and must be used sparingly.
- Do not use toothed forceps or instruments that can create a dimple in the mucosa simulating an orifice.
- Atraumatic dilation technique with rigid dilation progressively or with Seldinger technique (Video 88.1)
- Choose scope size based on expected pathology and instruments that fit through each port.
- Check scope for optics, focus, and white balance, and determine the direction of up while holding the scope in your hand outside the patient so that you will know this direction during the endoscopy.
- Irrigate both ports of the scope with saline to avoid air bubbles.
- Insert the scope without force.
- Use appropriate stone (calculus) baskets for size (more wires for smaller calculi and fewer for larger stones) (Video 88.2).
- Stones larger than 4 mm in their smallest dimension that are not near the papilla will need either hybrid procedures or fractionation before retrieval.
- Floating calculi are usually retrievable.
- Most calculi require papillotomy for extraction (Video 88.3).

Parotid Gland

- Identify the papilla near the second molar. These are usually easier to locate than the submandibular papilla.
- Dilation using metal dilators
- Scope set up as previously described
- Realize that Stensen's duct is smaller

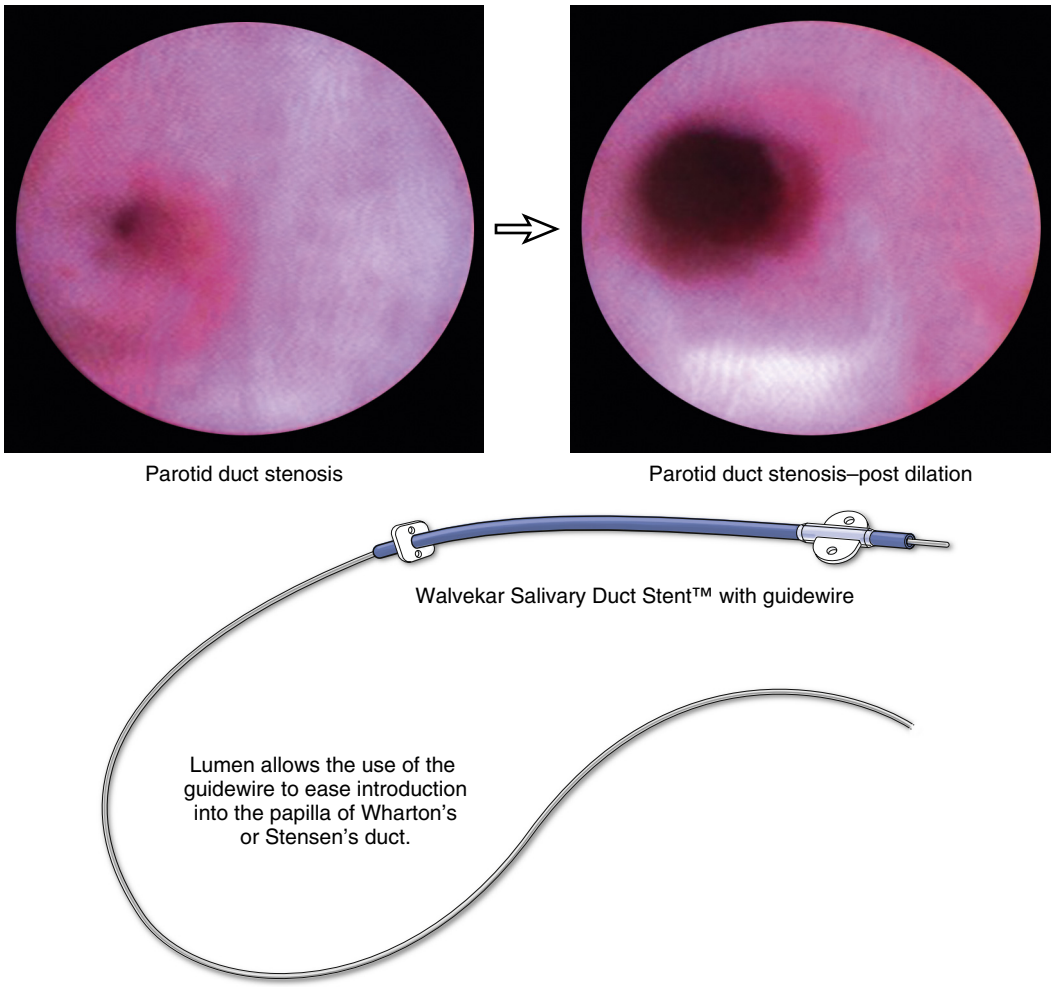

Fig. 88.1. Dilation of parotid stenosis before and post stenting. (Hood Laboratory, Pembroke, MA.)

- Be aware that attempted endoscopic removal of calculus in the ductal system proximal to the masseter muscle has a low success rate.[1]
- Calculi larger than 3 mm that are not floating may need fragmentation or hybrid approaches.
  - Most stenosis tends to occur in the parotid ductal system.
  - Stenosis cases may be single diaphragmatic ideal cases or more difficult multilevel or severe cases.
  - A stenotic duct can be dilated by a balloon or scopes in sheaths (Fig. 88.1).

HYBRID APPROACHES

- SMG (Video 88.4)
  - Distal calculi at the papilla can be extracted as an office procedure.
  - Medium calculi in the midduct or hilum can be treated with transoral sialolithotomy or fragmented and extracted with salivary scopes.
  - Large calculi in the midduct or hilum can be removed by transoral sialolithotomy, with care taken to see and protect the lingual nerve.[2,3]
  - Postextraction endoscopy confirms no residual fragments. Fragments left behind will lead to recurrence/persistence of disease.
  - Repair of the duct is not necessary.
  - Mucosa is loosely closed over the sialolithotomy.
- Transfacial (Video 88.5)
  - Mini-face lift incision used with typical parotid exposure and protection of the greater auricular nerve
  - Calculus should either be:
    - Seen and marked with methylene blue by US
    - Easily palpable
    - Highlighted by parotid salivary scope left in place
    - Ideally trapped in a stone basket so that it can be manipulated within the duct to facilitate extraction
  - An anteriorly based U-shaped superficial muscular aponeurotic system (SMAS) flap is elevated over the calculus.
  - The buccal branch of the facial nerve if visualized is dissected free of the calculus entry site.
  - Scalpel sialolithotomy is enlarged with middle ear scissors as much as necessary to retrieve the calculus.
  - Watertight closure of the parotid duct is necessary and is checked by placing water at low pressure via the scope and observing the closure.
  - SMAS flap provides second layer closure.
  - Vein grafts for stenosis not amenable to dilation have been described.[3]
- Transbuccal (Video 88.6)
  - A curvilinear incision is placed anterior to the papilla of the parotid duct.
  - The incision is developed through the buccinator muscle to expose Stensen's duct in the buccal space.

- A variety of interventions are then possible after this access has been obtained.
  - Parotid duct stenosis or calculi distal to the anterior border of the masseter muscle can be treated by performing a sialodochotomy and calculus release in the buccal space or alternatively dilating the parotid duct stenosis under direct visualization. After the stenosis is dilated or the calculus is removed, the duct can be visualized by endoscopy via the natural ostium to go past the area of pathology into the more proximal duct, followed by placement of a guidewire and stent. Usually, if the duct has been incised, it is repaired at this time over the stent. Botox injection of the parotid parenchyma should be a consideration to prevent sialoceles.
  - The midbuccal space sialodochotomy also provides access to perform endoscopy through it and visualize and treat pathology in the parotid hilum.
  - For more distal stenosis, the curvilinear incision can be completed to create a circumferential incision around the duct opening in the buccal mucosa. The duct is dissected from the buccal space to retract it into the oral cavity (i.e., duct stretching). The distal duct can then be excised (usually 1 to 2 cm) and the remnant proximal duct sutured to the buccal mucosa to complete the sialodochoplasty.

Common Errors in Technique

- Inability to dilate the papilla
- Making punctures with injection needles, dilators, or guidewires that look like the papilla opening
- Not staying central in the lumen and so no real view
- Pushing without visualization and perforating the duct
- Continuing to irrigate after perforating the duct
- Basketing a fixed calculus and having the basket trapped—"trapped basket syndrome"
- Breaking the salivary endoscope by excessive force or bending it over the teeth
- Too much irrigation, consequently overinflating the gland or causing ductal injury and extravasation of irrigation into the floor of the mouth or buccal space, causing swelling of the floor of the mouth or cheek, respectively

POSTOPERATIVE PERIOD

Postoperative Management

- These procedures are done in the clinic under local anesthesia or in the operating room, and then the patient is discharged.
- Antibiotics are given for patients with evidence of infection during endoscopy.

Complications

- Perforation of the duct is usually managed with antibiotics, occasionally by stenting the duct.
- Infection can occur because of postoperative edema of the duct and papilla.
- Blocked baskets occur when the calculus is not floating and the calculus can be grasped but not released.
- Duct avulsion comes from pulling too hard on a stone basket combination. This requires removal of the gland in most cases.
- Vascular and neural complications are rare; lingual nerve paresis with combined approach techniques for submandibular calculi
- Scopes are fragile; be gentle so as not to break them.

Alternative Management Plan

The alternatives to gland-preserving approaches that involve salivary endoscopy and hybrid approaches are either observation or excision of the gland. Patients in whom salivary endoscopy has not been helpful in mitigating symptoms should consider excision of the gland. In patients with parotid sialadenitis, Botox injection with US guidance may temporize symptoms and can offer an alternative in some patients who do not wish to undergo parotidectomy with a risk of facial nerve paresis and disfigurement that may be associated with the procedure.

DISCUSSION

Evidence-Based Medicine Question

After removal of hilar submandibular calculi by salivary endoscopy, what percentage of patients have stable or increased salivary flow as judged by scintigraphy?[4]

In general, large SMG calculi and hilar calculi are often looked upon as situations in which gland preservation is not feasible. The premise of salivary endoscopy was the ability of the procedure to permit return of flow and afford gland preservation. The authors denote that up to 66% of glands demonstrate stable or increased salivary flow as judged by scintigraphy after removal of submandibular hilar stones. The study provides objective evidence that validates endoscopic gland-preserving techniques. Salivary flow is not the only indicator of successful intervention. The patients must be evaluated for symptom relief (i.e., relief of obstructive symptoms), pain, and recurrent stenosis or calculi formation. The latter are often responsible for salvage gland excision after successful endoscopic intervention.

Editorial Comment

Inflammatory disease of the salivary gland traditionally involved removal of the gland. Minimally invasive approaches can now be used for obstructive calculi and stenosis, as well as inflammatory conditions such as juvenile recurrent parotitis, radioactive iodine–induced sialadenitis, and Sjögren's syndrome. There is a learning curve, and the technique requires gentleness and patience. With the addition of hybrid techniques, gland retrieval can be used to rescue a small percentage of cases of inflammatory and obstructive diseases of the salivary glands.

Barry Schaitkin

Access the review questions online at http://www.expertconsult.com

REFERENCES

1. Kiringoda R, Eisele DW, Chang JL. A comparison of parotid imaging characteristics and sialendoscopic findings in obstructive salivary disorders. Laryngoscope 2014;124(12):2696–2701.
2. Walvekar RR, Bomeli SR, Carrau RL, et al. Combined approach technique for the management of large salivary stones. Laryngoscope 2009;119(6):1125–1129.
3. Marchal F. A combined endoscopic and external approach for extraction of large stones with preservation of parotid and submandibular glands. Laryngoscope 2007;117(2):373–377.
4. Makdissi J, Escudier MP, Brown JE, et al. Glandular function after intraoral removal of salivary calculi from the hilum of the submandibular gland. Br J Oral Maxillofac Surg 2004;42(6):538–541.

REVIEW QUESTIONS

1. Calculi may need to have hybrid approaches or fragmentation of calculi if they are
   a. In the submandibular duct and smaller than 3 mm
   b. In the parotid duct and smaller than 2 mm
   c. In the parotid duct and larger than 4 mm
   d. At the papilla

2. A blocked basket occurs when
   a. A calculus is irregular and does not fit well into the basket
   b. Dilating a stenosis that is tight
   c. A calculus that is not floating is grasped and the basket cannot be released
   d. A calculus is particularly dense

3. Stenosis is most commonly
   a. Found in the submandibular duct
   b. Found in Stensen's duct
   c. Found in Bartholin's duct
   d. Found in Wharton's duct

89 Surgical Management of Ranula

Rohan R. Walvekar, Rachel Barry

INTRODUCTION

A ranula is an extravasation mucocele that arises in the floor of mouth secondary to trauma to the sublingual gland or obstruction of the salivary ducts. The term ranula is derived from the Latin word *rana*, meaning frog, which describes the bluish floor of mouth swelling that resembles a frog's underbelly. These lesions are classified into two types: oral or simple ranulas and cervical or "plunging" ranulas. Oral cavity ranulas present only in the floor of mouth and are located above the mylohyoid sling, while the plunging ranula presents as swelling in the neck and arises from herniation of the ranula through or around the mylohyoid muscle (Figs. 89.1 and 89.2). Plunging ranulas are pseudocysts, meaning that the wall of the ranula is lined with granulation or connective tissue and lacks an epithelial lining.[1]

While surgical therapy is the recommended treatment modality for both oral and plunging ranulas, the preferred approach has evolved over the years. Various methods have been described, including marsupialization and excision of the ranula with or without excision of the sublingual gland for oral ranulas. Others have described a transcervical approach and excision of the submandibular gland in the management of a plunging ranula. More recent literature supports the excision of the sublingual gland with transoral drainage of the plunging component as the modality with the fewest complications and recurrences.[2]

KEY OPERATIVE LEARNING POINTS

1. A comprehensive knowledge of anatomy of the sublingual gland is essential to avoid injury to the lingual nerve and Wharton's duct.
2. Surgical management of plunging ranulas has shifted from combined approaches with excision of transcervical ranula, and sometimes excision of the submandibular gland, to intraoral excision of the sublingual gland with evacuation of the ranula.
3. Complete excision of the sublingual gland is associated with the fewest recurrences of ranulas.

PREOPERATIVE PERIOD

History

1. History of present illness
   a. Painless swelling of the floor of the mouth
   b. History of recurring lesions with formation of cysts with resolution being pathognomonic of a ranula.
   c. Larger lesions can lead to difficulty with speech, swallowing, and breathing.
   d. Mass effect can cause impairment of submandibular salivary flow, leading to swelling and pain in the gland after eating.
   e. Plunging ranulas present with an enlarging, painless mass in the neck, with or without accompanying swelling of the floor of the mouth.
2. Past medical history
   a. Trauma to the floor of the mouth or neck
   b. History of surgical procedures to the floor of the mouth or salivary glands
3. Family history
   a. Bleeding disorders
4. Medical illness
   a. Medical comorbidities that may impact eligibility for or viability of surgical intervention
5. Medications
   a. History of anticoagulant therapy or the use of herbal products

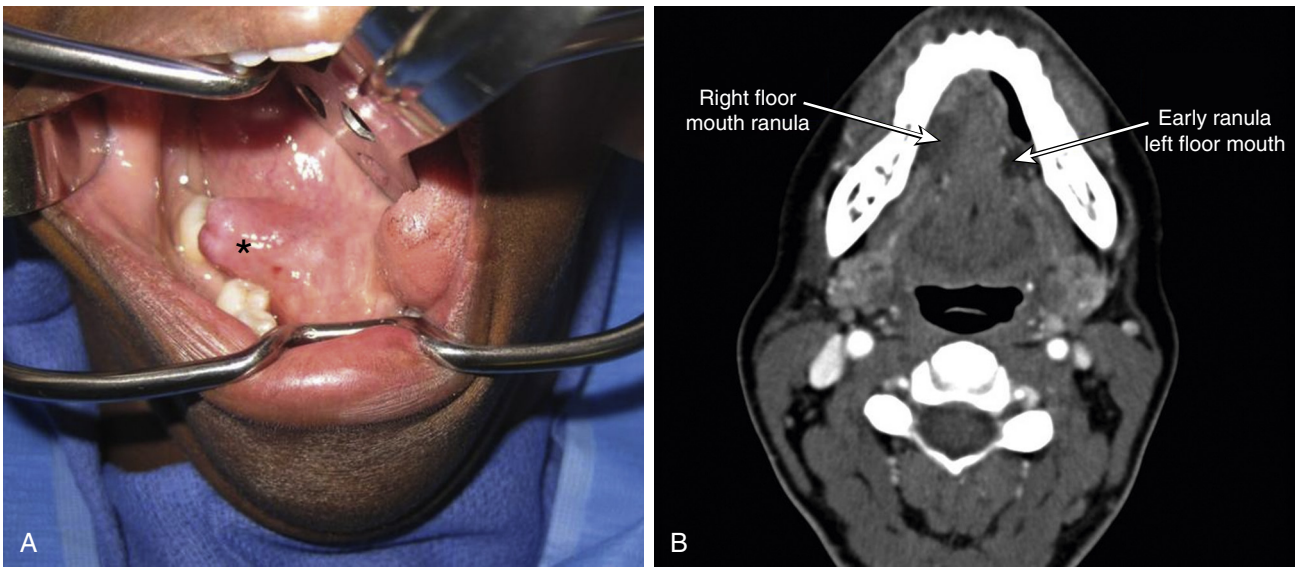

Fig. 89.1. A, Bilateral floor of mouth ranula; the *asterix* showing a prominent floor of mouth ranula. **B,** Computed tomography scan (axial view) showing bilateral floor mouth ranulas.

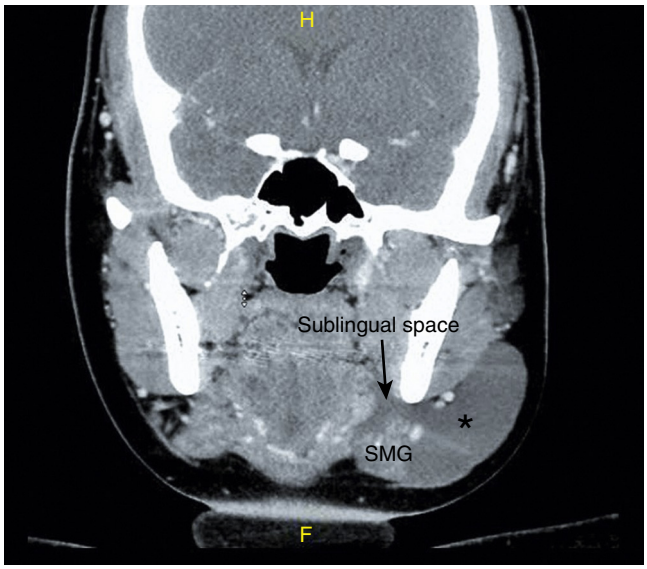

Fig. 89.2. Computed tomography scan (coronal view) showing ranula involving sublingual space and expanding beyond the mylohyoid sling into the upper neck spaces. The arrow points to the sublingual space. SMG indicates the location of the submandibular gland being displaced by the plunging component of the ranula (indicated by asterix).

6. Allergies
   a. Antibiotics
   b. Local anesthetics

Physical Examination

1. Oral cavity
   a. Unilateral bluish mass beneath the mucosa of the anterior floor of the mouth
   b. If large, the lesion may cross the midline.
   c. Bimanual palpation of the floor of the mouth must be performed to rule out coincidental salivary calculi. In the case of a plunging ranula, external pressure on the neck mass often makes the corresponding sublingual fossa prominent.
   d. An effort must be made to identify and check the function of the submandibular duct. Location of the papilla of the submandibular duct must be recorded. These steps facilitate cannulation of the submandibular duct if placement of a stent is considered and also facilitates early decision making to perform a marsupialization of the submandibular duct if the submandibular papilla is stenotic.
   e. Patency of all four salivary ducts must be examined and documented
2. Neck
   a. Fluctuant, nontender, unilateral mass in the submandibular region
   b. Giant ranulas can extend to also involve parapharyngeal space or to the level of the clavicles.
   c. Can have neck mass without oral cavity component

Imaging

1. Computerized tomography (CT) scan of neck with contrast and without contrast, 1 mm cuts[3]
   a. Essential in cases of plunging ranula to determine cervical extent and relationships prior to operative management
   b. Appears as a nonenhancing, homogeneous, unilocular lesion in the sublingual space with extension to the submandibular and sometimes the parapharyngeal spaces in plunging ranulas (see Fig. 89.2)
   c. Sublingual gland or space may be replaced by radiolucent material suggestive of extravasated saliva, typical of ranula formation. The submandibular gland is often displaced or surrounded by the radiolucency making it difficult at times to decipher if the gland is the origin of the pathology or is being affected as a consequence of it.
2. Magnetic resonance imaging (MRI)[3]
   a. Not required, can complement or replace CT scan
   b. Hyperintense cystic lesion on T2-weighted images, low to intermediate intensity on T1-weighted images
3. Ultrasonography[4]
   a. Ultrasound has also been shown to successfully evaluate cystic lesions in the submandibular space, as well as evaluate areas of dehiscence in the mylohyoid muscle.
   b. Ultrasound can be a valuable tool intraoperatively as well as to ensure complete drainage of the plunging component of the ranula.
4. Laboratory tests
   a. Serum amylase: The diagnosis of a ranula is a clinical and radiological diagnosis; however, in cases where there is a question regarding the origin of the cyst, a raised serum amylase level in cyst aspirate can confirm salivary origin.

Indications

1. Ranulas causing airway obstruction or compromise require immediate treatment with either incision and drainage or excision.
2. Recurrent ranula with infection
3. Partial obstruction of Wharton's duct with obstructive sialadenitis
4. Interference with speech and articulation
5. Asymptomatic patients who want to avoid progression to the above
6. Cosmesis

Contraindications

1. Patient with medical comorbidities precluding administration of general anesthesia
2. Active infection is considered a relative contraindication.

Preoperative Preparation

1. Evaluation by
   a. Head and neck surgeon
   b. Anesthesiology
      1) A coordinated effort is important to plan the management of the airway for large obstructing ranulas that may distort the anatomy or make for a difficult airway.
      2) If there is a concern, an awake fiberoptic oral or nasal intubation is preferred. Use of video laryngoscopes are also advocated for better visualization.
2. Discontinue antiplatelet drugs if possible 5 to 7 day prior to surgery.
3. Preoperative imaging

OPERATIVE PERIOD

Anesthesia

- General anesthesia
  - Oral or nasal intubation
  - Muscle relaxation is recommended for better intraoral access.

- Local anesthesia can be considered for localized floor of mouth ranula in adults where simple marsupialization is being considered.

Positioning

- Supine
- Intraoral and extraoral betadine prep may be considered. We do not routinely prep the oral cavity.
- Mouth opening is facilitated by the use of dental props or mouth retractors.

Perioperative Antibiotic Prophylaxis

- Perioperative administration of antibiotics to cover oral flora is recommended; usually clindamycin.

Monitoring

- Routine anesthesia monitoring; nerve monitoring is not indicated in these procedures

Instruments and Equipment to Have Available

- Head and neck set
- Monopolar and bipolar electrocautery
- Intraoral retractors
  - Disposable plastic cheek retractors
  - Jennings retractors, Minnesota retractors, Dental props
- Salivary duct dilators and stent for cannulation of Wharton's duct
  - Marchal or Schaitkin Dilator Systems (Karl Storz, Germany)
  - Disposable dilator systems (Cook Medical, Bloomington, IN, USA)
  - Salivary duct stents
  - Salivary endoscopy set along with salivary endoscopes to perform a diagnostic or interventional sialendoscopy, if indicated or considered by surgeon (Karl Storz, Germany)

Key Anatomic Landmarks

- A comprehensive knowledge of the sublingual gland and the surrounding anatomy is essential in the successful treatment of ranulas. The sublingual gland is the smallest of the three major salivary glands and lies in the sublingual space. This potential space is bounded anterolaterally by the medial surface of the mandible, medially by genioglossus muscle, and posteriorly by the submandibular gland. The inferior boundary is the mylohyoid muscle, and the superior boundary is the mucosa of the floor of the mouth. Wharton's duct and the lingual nerve lie medial to the gland. The submandibular duct passes adjacent to the sublingual gland and, in its distal 10 to 15 mm, lies just deep to the mucosa of the floor of the mouth. In this position, the duct is liable to be injured during resection of the sublingual gland. Consequently, some surgeons routinely stent the submandibular duct prior to excision of the sublingual gland in an effort to protect it from injury. The lingual nerve must also be identified as its terminal branches pass beneath the sublingual gland and course below the submandibular duct to innervate the tongue.
- There are no posterior fascial limitations, allowing spread of ranulas into the submandibular and parapharyngeal spaces. In contrast to the parotid and submandibular glands, the sublingual gland lacks a surrounding capsule. Drainage of the gland into the floor of the mouth occurs through 8 to 20 small ducts of Rivinus. These ducts can also join together to form one major sublingual duct called the duct of Bartholin, which joins Wharton's duct.[5]

Prerequisite Skills

- Experience with salivary gland and salivary duct surgery

Operative Risks

- Risks of general anesthesia
- Bleeding
- Infection
- Recurrence of the lesion
- Injury to the lingual nerve: sensory loss to anterior two-thirds of the tongue, tongue numbness, or metallic taste in the mouth
- Submandibular duct injury/papillary stenosis: obstructive sialadenitis or salivary leakage subsequently requiring excision of the submandibular gland if not resolved
- Need for additional procedures

Surgical Techniques

- There are varying surgical procedures described to manage ranula. The most common ones include excision of the floor of the mouth cyst and marsupialization of the cyst to the floor of the mouth. This chapter will focus on the comprehensive technique that is associated with the lowest recurrence rate, that is, excision of the sublingual gland with excision or drainage of the floor of the mouth ranula or drainage of the plunging component of the ranula.
- General anesthesia with oral or nasal intubation is induced. Bite block and oral retractors are placed for adequate intraoral exposure.
- The submandibular papilla is identified and sequentially dilated. After appropriate dilation, the duct is cannulated with a salivary duct stent to assist with identification and preservation during the procedure. If the opening of the submandibular duct is abnormal and the duct cannot be cannulated easily, this step can be deferred. If expertise and instrumentation are available, a diagnostic endoscopy of the submandibular duct to ensure that there is no coincidental submandibular duct pathology is reasonable and will also allow identification of the duct for cannulation or repair.
- A monopolar electrocautery with a fine tip is used to make an incision along the floor of the mouth lateral to the submandibular duct. In cases where the cyst is prominent, an elliptical excision of the mucosa of the floor of the mouth can be made to include the adherent portion of the cyst wall (Fig. 89.3).
- Dissection is carried in the plane between the sublingual gland and the submandibular duct, with the inferior limit being the mylohyoid and posterior limit being the submandibular gland.
- The lateral portion of the gland is dissected away from the surrounding tissue.
- Adequate hemostasis is key to prevent incomplete excision of the gland or damage to the lingual nerve and Wharton's duct. The submandibular duct runs in an anterior-superior direction from the submandibular gland to its papilla on the floor of mouth, and it makes contact with the medial surface of the sublingual gland.
- The lingual nerve is identified in association with the posterior portion of the sublingual gland, running lateral to medial and deep to the submandibular duct.
- In cases with a plunging component, the cervical pseudocyst can be drained transorally with probing through the mylohyoid muscle or bimanual palpation. Since the plunging ranula is a pseudocyst, merely draining the cyst will allow for the resolution of the cyst as long as the source of the saliva is removed, that is, the sublingual gland.

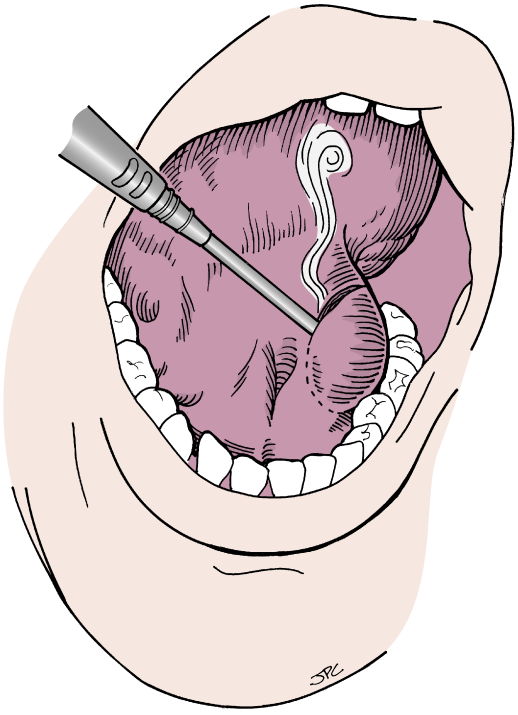

Fig. 89.3. The incision is outlined on the floor of the mouth. The entire sublingual gland must be excised with the cyst.

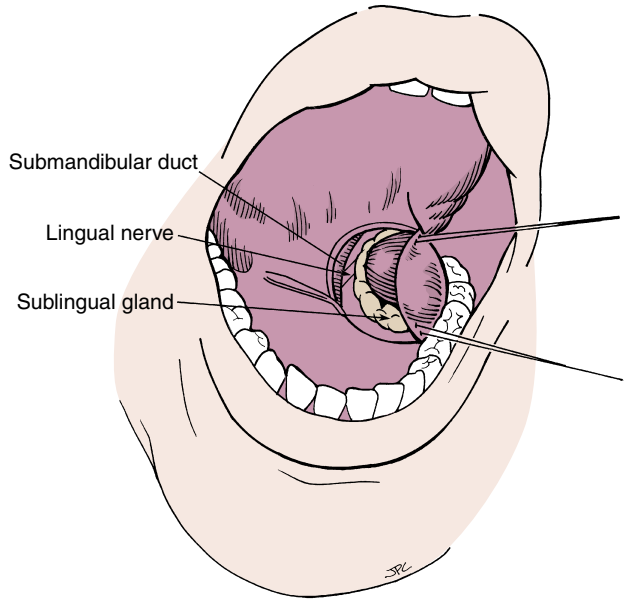

Fig. 89.4. If the submandibular duct has been interrupted, it should be marsupialized by suturing the edges of the duct mucosa to the edges of the floor mouth mucosa or the wound, whichever is possible without adding excessive tension to the sutures. However, suturing the duct to the floor mouth mucosa is preferred.

- If the submandibular duct is damaged or interrupted, the posterior remnant of the duct is opened and marsupialized into the wound using absorbable sutures (Fig. 89.4).
- If the submandibular duct is intact, the incision in the floor of the mouth is then closed loosely with interrupted absorbable suture to allow drainage of any postoperative bleeding. The stent in the submandibular duct can be removed at the conclusion of the procedure. If there is a concern regarding the integrity of the submandibular duct, a diagnostic salivary duct endoscopy can be performed after removing the stent.

Common Errors in Technique

1. Failure to use imaging studies may lead to underestimating a plunging ranula.
2. Failure to remove the sublingual gland increases the recurrence rate.
3. Transcervical approaches may increase morbidity with little added benefit.
4. Failure to identify Wharton's duct and the lingual nerve will result in injury to these structures.

POSTOPERATIVE PERIOD

Postoperative Management

- Half-strength hydrogen peroxide or chlorhexidine rinse 15 mL tid, after meals, to keep the suture line clean
- In general, postoperative antibiotics are not necessary. However, if a salivary stent is left in place to manage a damaged submandibular duct, a course of postoperative antibiotics for 10 to 14 days is recommended. The stent is usually left in place for 10 to 14 days and can be removed as an in-office procedure.
- In our institution, this procedure is scheduled as a same-day surgery procedure. However, overnight observation may be required if there is significant edema of the floor of the mouth with concern for airway compromise; in our experience this is a very rare occurrence.

Complications

- Recurrence
  - Rare with complete removal of the sublingual gland
  - Subsequent excisions significantly more difficult due to scarring in the floor of the mouth
- Hypoesthesia of the tongue
- Bleeding/hematoma
  - Hematoma requires evaluation and control of bleeding to avoid swelling of the floor of the mouth and potential airway compromise
- Postoperative infection
  - Incision and drainage, culture, antibiotics
- Injury to Wharton's duct
  - Marsupialization of the duct if identified intraoperatively
  - Sialocele or salivary fistula: aspiration and anticholinergics. If persistent, diagnostic salivary endoscopy and stent and/or Botox injection with ultrasound guidance. In recalcitrant cases, submandibular gland excision
  - Stricture or stenosis: sialendoscopy with dilation and stent placement, duct marsupialization, or excision of the submandibular gland

Alternative Management Plan

- Marsupialization can be performed under local anesthesia in patients unable to undergo general anesthesia; this is, however, associated with higher recurrence rates.[2]
- Sclerotherapy with intracystic injection of OK-432 has been described as an alternative to surgery.[6]
- A case series reported three cases of simple ranula treated with injection of Botox into the ranula and sublingual gland. The proposed mechanism is denervation of parasympathetic nerve endings responsible for saliva production.[7]

- Low-dose radiation has also been described in the treatment of a case of a recurrent plunging ranula that failed initial surgical treatment.[8]

DISCUSSION

Evidence-Based Medicine Question

Oral and plunging ranulas: What is the most effective treatment?[2]

The surgical treatment of ranulas, particularly plunging ranulas, has been controversial and has evolved over the years. Described approaches for oral ranulas include incision and drainage, marsupialization, excision, and sublingual gland excision. Others have described a transcervical excision and submandibular gland excision in the management of a plunging ranula.

More recent literature, however, has shown that even in the case of a plunging ranula, a transcervical approach to remove the ranula and submandibular gland is unwarranted and may place the marginal mandibular and hypoglossal nerves at unnecessary risk. A literature review performed by Patel et al. reported 864 patients who underwent various methods of treatment for oral and plunging ranulas, including incision and drainage, marsupialization, sclerotherapy, ranula excision, sublingual gland excision, submandibular gland excision, and transcervical ranula excision. They found that the treatment modality yielding the lowest recurrence and complication rates for both oral and plunging ranulas is removal of the ipsilateral sublingual gland with evacuation of the ranula. In cases of plunging ranula, complete removal of the pseudocyst wall is unnecessary. Transcervical excision may be required in cases where intraoral drainage was unsuccessful or if drain placement is desired.[1]

Novel surgical and nonsurgical treatment modalities for ranula continue to be introduced. Lai et al. published a three-person case series and literature review describing carbon dioxide laser ablation for intraoral ranula. The laser in these cases was used to unroof the ranula and vaporize the walls and base of the lesion, all while maintaining excellent hemostasis and visualization. There were no documented recurrences or complications in this group.[9] Robot-assisted transoral management of ranula (oral and plunging) has also been described with favorable results.[10]

Editorial Comment

Ranulas can be very symptomatic due to recurrent infection, large size, or compressive effects. However, in most cases, they tend to be asymptomatic. Surgery must be tailored to the severity of the problem. Patients with a small asymptomatic ranula can be observed or benefit from minimally invasive intervention (aspiration, marsupialization), while patients with recurrent, symptomatic, or plunging ranula must be managed aggressively by excision of the sublingual gland. In relative terms, one could consider complications associated with ranula surgery (injury to the lingual nerve and submandibular duct) as minor since they are not life threatening. However, it must be remembered that these complications can cause significant morbidity and disturbances in quality of life for patients and should be carefully considered in surgical consent and decision making.

Rohan R. Walvekar

Access the review questions and additional sources list online at http://www.expertconsult.com



REFERENCES

1. Lesperance MM. When do ranulas require a cervical approach? Laryngoscope 2013;123:1826–1827.
2. Patel MR, Deal AM, Shockley WW. Oral and plunging ranulas: what is the most effective treatment? Laryngoscope 2009;119:1501–1509.
3. Kalra V, Mirza K, Malhotra A. Plunging ranula. Radiology Case 2011;5:18–24.
4. Jain P, Jain R, Morton RP, et al. Plunging ranulas: high-resolution ultrasound for diagnosis and surgical management. Eur Radiol 2010;20:1442–1449.
5. Johnson JT, Rosen CA, Bailey BJ. General otolaryngology, Bailey's Head and Neck Surgery. 5th ed. Philadelphia: Wolters Kluwer; 2014.
6. Roh JL. Primary treatment of ranula with intracystic injection of OK-432. Laryngoscope 2006;116:169–172.
7. Chow TL, Chan SW, Lam SH. Ranula successfully treated by botulinum toxin type A: report of 3 cases. J Oral Maxillofac Surg 2008;105:41–42.
8. Shimm DS, Berk FK, Tilsner TJ, et al. Low-dose radiation therapy for benign salivary disorders. Am J Clin Oncol 1992;15:76–78.
9. Lai JB, Poon CY. Treatment of ranula using carbon dioxide laser-case series report. Int J Oral Maxillofac Surg 2009;38:1107–1111.
10. Walvekar RR, Peters G, Hardy E, et al. Robotic-assisted transoral removal of bilateral floor of mouth ranulas. World J Surg Oncol 2011;9:1–4.

REVIEW QUESTIONS

1. What CT finding is considered pathognomonic for plunging ranula?
   a. Lyre sign
   b. Thumb sign
   c. Tail sign
   d. Frog sign
   e. Halo sign

2. Which is associated with the highest rate of recurrence of ranula?
   a. Marsupialization
   b. Aspiration
   c. Sclerotherapy
   d. Sublingual gland excision only
   e. Ranula excision only

3. Which is not a complication of transoral ranula surgery?
   a. Lingual nerve injury
   b. Hypoglossal nerve injury
   c. Recurrence
   d. Submandibular duct injury
   e. Hematoma

ADDITIONAL SOURCES

Bailey BJ, Johnson JT. 4th ed. Head & Neck Surgery—Otolaryngology, vol. 1. Philadelphia: Lippincott Williams & Wilkins; 2006.
Myers EN, Ferris RL. Salivary Gland Disorders. Philadelphia: Springer; 2007.

90 Mass in the Buccal Space

Phillip Huyett, Eugene N. Myers

INTRODUCTION

A mass appearing within the substance of the cheek is unusual and suggests a tumor of the buccal space or the accessory lobe of the parotid gland. The buccal space, first described by Kostrubala in 1945, is a potential space between the buccinator muscle and the more superficial muscles of facial expression (Fig. 90.1).[1] There are a number of reports of buccal space masses, and many surgical approaches have been suggested in the literature.[1-9] Lesions in the buccal space are readily apparent because they are easily palpated just beneath the buccal mucosa or the skin of the cheek.

Most neoplasms in the buccal space are tumors of minor salivary gland origin. Benign tumors are most often pleomorphic adenoma, monomorphic adenoma, or Warthin tumor. Malignant tumors in the buccal space include adenocarcinoma; adenoid cystic, mucoepidermoid, acinic cell, anaplastic, and small cell carcinoma; carcinoma ex pleomorphic adenoma; polymorphous low-grade adenocarcinoma; and metastasis from other sites. Other less common primary tumors include fibroma, fibrosarcoma, lipoma, lymphoma, melanoma, nerve sheath tumor, and hemangioma. For tumors other than lipoma, biopsy is necessary because no clinical or radiographic criteria are reliable in establishing a histologic diagnosis.

KEY OPERATIVE LEARNING POINTS

- Evaluate the patient with fine-needle aspiration biopsy and imaging before surgery to enhance planning for the surgical procedure and patient counseling.
- Evaluate the patient's needs regarding cosmetic appearance. The modified parotid incision leaves an unobtrusive but visible scar, so for a female patient, a rhytidectomy approach may be a better option, whereas the incision in a male patient is usually hidden in the beard line and is acceptable.
- Undermining in the plane between the subcutaneous tissue and the superficial musculoaponeurotic system (SMAS) protects the facial nerve.
- Identify the buccal and zygomatic branches of the facial nerve and dissect them off the mass.
- Retract the branches of the nerve away from the mass so that it may be excised without injury to the nerve.
- Closing the SMAS either primarily or with a flap will prevent an unsightly depression in the face.

PREOPERATIVE PERIOD

History

History of Present Illness

- The typical history encountered in patients with a mass in the buccal space is that of a slowly growing, painless mass in the cheek (Fig. 90.2).
- If the mass is more deeply seated, it tends to lie more medial and the patient may be able to feel the intraoral mass with the tongue (Fig. 90.3).
- When the mass is located in the oral cavity, patients are often seen initially by their dentist or an oral maxillofacial surgeon.
- Constitutional symptoms suggest infection, an inflammatory condition, or lymphoid neoplasm.

Past Medical History

- History of previous salivary gland or other neoplasms
- Recent dental work or cervicofacial infections
- Recent injection of facial fillers for cosmetic purposes
- Serious comorbidities
- Social History
  - Use of alcohol and tobacco
- Medications
  - Many medications may increase the likelihood of sialolithiasis.
  - Use of anticoagulants

Physical Examination

- A complete examination of the head and neck is warranted, as with all masses in the head and neck.
- Particular attention should be given to examination of the skin for primary cutaneous malignancies and palpation for cervical metastases.

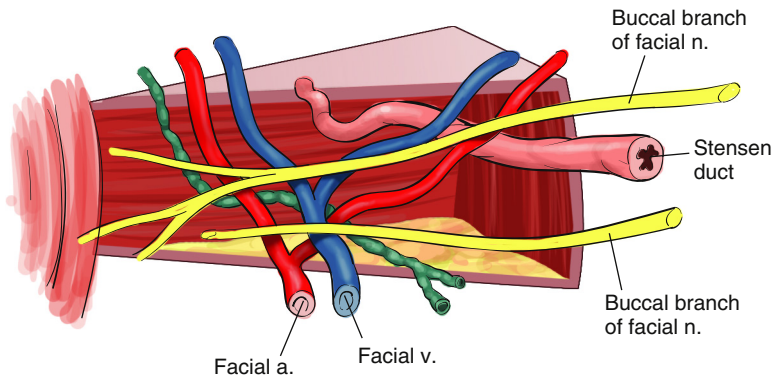

Fig. 90.1. The left buccal space and its contents.

- Inspection and bimanual examination usually reveals a mobile mass within the substance of the cheek that can be seen in the oral cavity (see Fig. 90.3).
- Although facial nerve deficits are uncommon given the rich distal cross-innervation, attention to the facial nerve function is mandatory.
- Basic determination of the patency of Stensen duct can be achieved by visualizing the duct orifice while milking or massaging the parotid gland from posterior to anterior.



Fig. 90.2. Preoperative frontal view illustrating a mass in the cheek.

Imaging/Diagnostics

- Kurabayashi et al. evaluated the computed tomography (CT) features of masses in the buccal space in 53 patients (33 benign tumors, 11 malignancies, 9 non-neoplastic lesions) and concluded that CT was useful in demonstrating the presence and location of masses in the buccal space.[7] CT can sometimes assist in the differential diagnosis but the value of CT in differentiating benign from malignant lesions in the buccal space is limited.
- Tumors of the buccal space were found adjacent to the outer surface of the buccinator muscle in contrast to epidermoid cysts and tumors of the accessory lobe of the parotid gland, which were completely separate from it.
- Tumors of the accessory lobe of the parotid gland, epidermoid cysts, lipomas, and lymphoma could be differentiated from other lesions.
- Hemangiomas were characterized by multiple masses and the presence of phleboliths.
- Kurabayashi et al. also studied 30 patients with benign and malignant lesions in the buccal space with magnetic resonance imaging (MRI).[6] MRI was useful in demonstrating the extent of lesions in the buccal space, but similar to CT its diagnostic value in predicting malignancy was very limited (Fig. 90.4). This was especially true for malignant tumors of minor salivary gland origin, which were typically seen as well-defined masses without infiltration into surrounding structures on MRI.
- Ultrasound may be helpful in characterizing the lesion (size, echogenicity, flow, calcifications) or in assisting fine-needle aspiration biopsy.
- Fine-needle aspiration biopsy is most helpful in determining the need for surgery rather than providing a definitive diagnosis.
- Definitive diagnosis of a mass in the buccal space is made by excision of the mass and histopathologic evaluation.
- Incisional biopsy is never appropriate, as the risks of facial nerve injury and tumor spillage are increased and postbiopsy changes may make the definitive surgery more complex.
- The differential diagnosis of a mass in the buccal space includes lesions originating from each of the tissue components in the space. Table 90.1 lists the lesions that have been found in the buccal space.

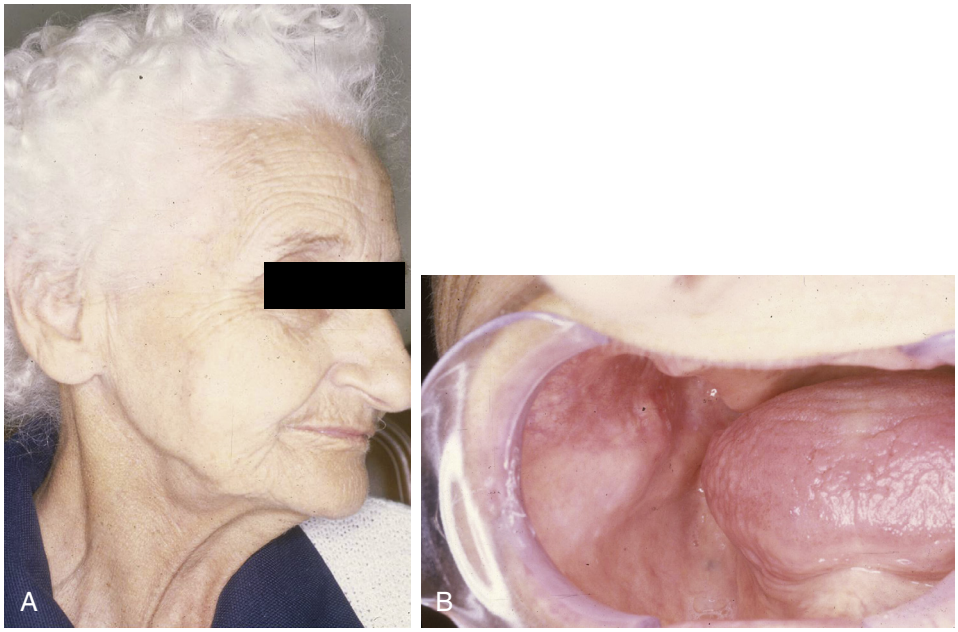

Fig. 90.3. (**A**) External view of a right buccal space mass. (**B**) Internal view. Note the intraoral bulge produced by the mass.

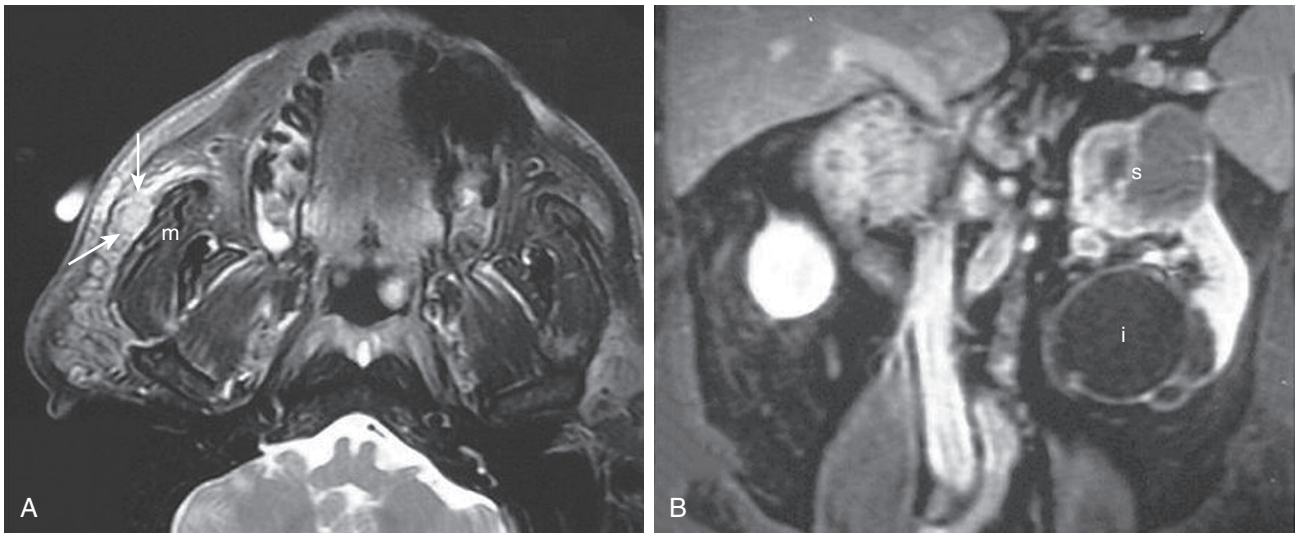

Fig. 90.4. (**A**) T2-weighted axial MRI through the parotid gland demonstrating a round 10-mm mass *(arrows)* overlying the masseter muscle *(m)*. The mass has a signal intensity slightly higher than the adjacent gland but not high enough to be definitive for pleomorphic adenoma. It proved to be renal cell carcinoma metastatic to the accessory lobe. (**B**) Sagittal post-contrast-enhanced spoiled-gradient MRI of the abdomen with T1 weighting shows two distinct masses in the left kidney. The superior mass *(s)* has cystic and solid components. The inferior mass *(i)* is predominantly cystic and has extensive septations. This renal cell carcinoma was the primary tumor.

TABLE 90.1 Reported Lesions in the Buccal Space

Connective
Angioleiomyoma
Extraskeletal mesenchymal chondrosarcoma
Fibroma, fibrosarcoma, solitary fibrous tumor
Fibromatosis
Lipoma, liposarcoma
Nodular fasciitis
Rhabdomyosarcoma
Spindle cell lipoma

Glandular
Accessory parotid or aberrant salivary gland tumors
Acinic cell carcinoma
Adenoid cystic carcinoma[6]
Carcinoma ex pleomorphic adenoma
Chronic sialadenitis
Minor salivary gland calculus
Mucoepidermoid carcinoma (low and high grades)
Oncocytoma
Papillary cystadenoma lymphomatosum
Parotid duct tumor or calculus
Pleomorphic adenoma
Polymorphous low-grade adenocarcinoma
Sebaceous adenoma
Tuberculous granuloma and adenoid cystic carcinoma manifested as a single buccal space mass

Inflammatory
Abscess formation
Aspergilloma
Sarcoidosis

Lymphatic
Benign reactive lymph node
Calcified lymph node
Lymphangioma
Lymphoma
Lymphosarcoma
Metastasis to lymph node

Muscular
Masseteric hypertrophy
Myositis ossificans

Neural
Neurofibroma
Neuroma

Other
Facial fillers and injectables
Lymphoepithelial cyst
Metastatic carcinoma (skin, sinus, renal cell, lung, buccal mucosa)
Migrated molar

Vascular
False aneurysm
Hemangioendothelioma
Hemangioma
Hemangiopericytoma
Hyalinized thrombus

Indications

- Excisional biopsy is indicated in patients whose preoperative examination suggests a neoplastic condition.
- Undesired cosmetic appearance of the mass

Contraindications

- Patients who are not healthy enough to tolerate or benefit from excision of the mass

Preoperative Preparation

- Several surgical approaches to the buccal space have been described.
- The approach used most commonly is a direct transmucosal intraoral incision with dissection and removal of the mass. This approach is appealing, because the bulging of the mass into the intraoral area lends itself to easy excision and eliminates a skin incision with its inevitable scar (see Fig. 90.3).

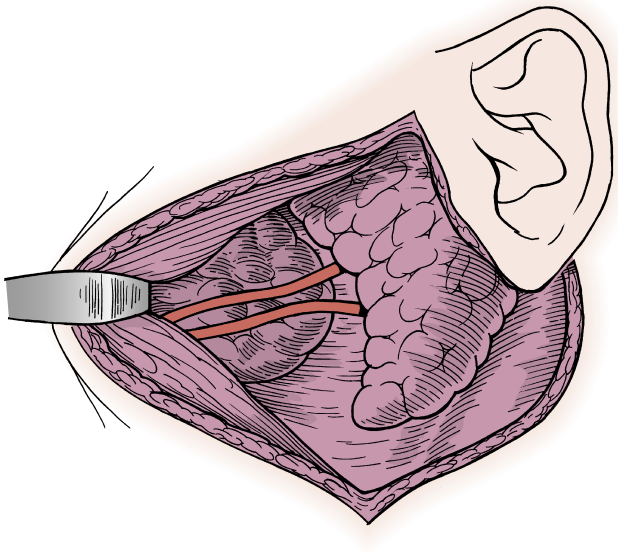

Fig. 90.5. Surgical exposure of a mass in the buccal space demonstrating the branches of the facial nerve adherent to the lateral aspect of the mass.

- Despite this apparent advantage, the intraoral approach may not provide adequate exposure. While removing these masses through the external approach, we have observed that the buccal branches of the facial nerve are always closely associated with or actually incorporated into the capsule on the *lateral* aspect of the mass, which cannot be well visualized through the intraoral approach (Fig. 90.5). Stensen duct is also closely associated with these tumors. Without proper exposure, these vital structures are at risk for injury, which could produce facial paralysis and sialocele.
- The direct transcutaneous approach is appealing because of the advantage of requiring less time and dissection and no need to raise skin flaps, thereby avoiding the possibility of flap necrosis. We do not recommend this approach because of the highly visible scar and the risk to branches of the facial nerve and Stensen duct. This approach also makes it difficult to use local tissue to fill in the depressed area left after removal of the mass.
- An extended parotid-submandibular incision (Fig. 90.6) for removal of a mass in the buccal space is used in our department because it provides excellent exposure and minimizes the risk of complications such as injury to Stensen duct or the facial nerve during excision of these tumors.[4,5] This technique also provides an excellent cosmetic result.
- The rhytidectomy approach that Madorsky and Allison described can be used for removal of a mass in the buccal space and offers a superior cosmetic result.[8]

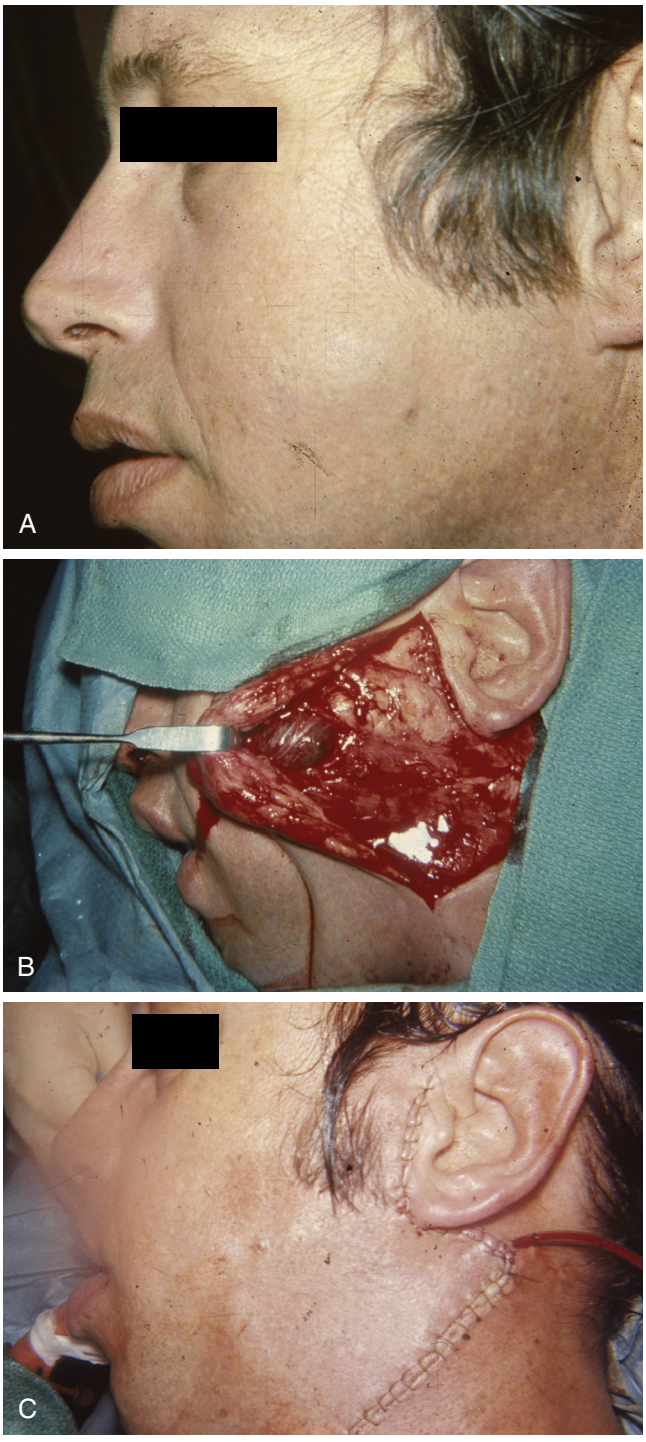

Fig. 90.6. (**A**) Lateral view of a mass in the buccal space. (**B**) Surgical exposure of the mass. (**C**) Surgical closure over suction drains.

OPERATIVE PERIOD

Anesthesia

- General anesthesia
- Oral intubation with the endotracheal tube secured to the contralateral side
- FiO_2 less than 30% if electrocautery is to be used in order to avoid an airway fire

Positioning

- For rhytidectomy and extended parotid-submandibular approach, a shoulder roll with the head rotated contralaterally will facilitate better exposure.
- The hemi-face should be prepped and draped in the field for observation of facial nerve stimulation.

Perioperative Antibiotic Prophylaxis

- Not required with external approaches

Monitoring

- No routine monitoring is required, and facial nerve monitoring is optional.

Instruments and Equipment

- Standard head and neck set
- Handheld nerve stimulator, vessel loops

Key Anatomic Landmarks

- Understanding the three-dimensional anatomy of the buccal space is necessary for proper management.[4,5]
- Medial wall: Buccinator muscle and its overlying fascia, which extends from the mandibular body inferiorly to the maxilla superiorly, orbicularis oris anteriorly, and pterygomandibular raphe posteriorly (see Fig. 90.1)
- Lateral wall: Muscles of facial expression (risorius, zygomaticus major, and levator labii superioris) and their fascia. More superficial to these muscles lie the superficial fascia and skin.
- Anterior border: The orbicularis oris muscle
- Posterior border: Anterior border of the masseter muscle and parotid gland
- Superior and inferior limits: Fascial attachments of the muscles of facial expression to the zygomatic arch and mandibular periosteum
- Anatomic structures found in the buccal space include Stensen duct, the facial artery and vein, lymphatic channels, minor salivary glands, accessory parotid lobules, and most laterally, the buccal branches of the facial nerve (see Figs. 90.1 and 90.5). These nerve branches enter the medial surface of the muscles of facial expression, except the buccinator, which is innervated from its lateral aspect.
- The majority of the buccal space is filled with adipose tissue, referred to as the buccal fat pad, and lymph nodes.
- The accessory lobe of the parotid gland is an island of salivary gland tissue found anterior to and separate from the main parotid gland. It is present in approximately 21% to 56% of the population.
- The accessory lobe is generally 0.5 to 2.5 cm in size and is separated from the main parotid gland by an average of 6 mm. This is in contradistinction to the anterior facial process of the parotid gland, which is an anterior extension of the main gland.
- The accessory lobe of the parotid gland is usually located along Stensen duct, and the lobe drains through one or more ducts into Stensen duct. This position makes it intimately related to the buccal and zygomatic branches of the facial nerve.
- Neoplasms of the accessory lobe of the parotid gland are more often malignant than the parotid gland proper (50%) and are predominantly of salivary gland origin with few case reports of metastatic cancers to this area. One to seven percent of all parotid neoplasms arise within the accessory lobe of the parotid gland, depending on inclusion criteria.

Prerequisite Skills

- Parotidectomy (Chapter 115) and rhytidectomy techniques (Chapter 168)

Operative Risks

- Patients are counseled that the buccal branch of the facial nerve will be dissected and elevated off the tumor and is therefore vulnerable to intraoperative injury and postoperative weakness as a result of dissection and stretching of the nerve. Permanent facial nerve paralysis is possible but unlikely.
- Other risks include facial paresthesias, injury to the parotid duct, undesirable scars, hematoma, and infection.

Surgical Technique

Extended Parotid-Submandibular Incision

- The incision is a modification of the standard parotidectomy incision (see Fig. 90.6). Extension of the preauricular incision somewhat superiorly and extension of the cervical incision into a submandibular space skin crease allows for wide undermining of the flap, which is necessary to gain exposure anterior to the parotid gland for visualization of the mass.
- It is not necessary to carry out a formal parotidectomy or to identify the facial nerve at the stylomastoid foramen, because the mass is anterior to the anterior border of the parotid gland and therefore only the buccal branches of the nerve are anatomically associated with these masses.
- The skin flap is elevated anterior to the anterior border of the parotid gland where the mass will be encountered. Further elevation of the flap provides exposure of the entire mass. The SMAS is divided over the mass.
- Care must be taken when undermining the superior aspect of the flap because the zygomatic branch of the upper division of the facial nerve is superficial in this area and the branch could be injured with resultant facial nerve paralysis.
- The buccal branches of the facial nerve and Stenson duct are easily identified, usually during blunt dissection of the mass, and confirmed using a facial nerve stimulator (Figs. 90.5 and 90.6).
- Dissection of the branches of the nerves somewhat anterior and posterior to the mass itself will allow undermining and mobilization of the nerve. A small nerve retractor is then used to retract the branches of the nerve away from the mass. Once dissected, the nerves may be marked with arterial loops.
- The mass itself is then removed by sharp and blunt dissection. After the mass is removed, the nerves are returned to their normal anatomic position.
- Removal of the mass leaves a noticeable defect in the facial contour that is eliminated by approximating the SMAS.
- Hemostasis is obtained, the wound is irrigated, and a Hemovac drain is inserted under the skin flap and brought out through a separate stab wound posterior to the incision.
- The skin incision is closed with subcutaneous 4-0 Vicryl or equivalent and then a running closure with 5-0 or 6-0 fast-absorbing plain gut suture.
- Steri-Strips and a pressure dressing are applied.

Rhytidectomy Approach

- In 1976, Mitz and Peyronie described the rhytidectomy approach and how this technique allows reconstruction of the contour defect associated with tumor extirpation by SMAS interposition.[9] They used this technique in five patients: two tumors of the accessory lobe of the parotid gland, one cyst in the parotid gland, one case of nodular fasciitis of the anterior masseter muscle, and one lymphoma.
- The incision begins at the temple and continues in a preauricular crease and then post-tragal. The incision is carried inferior to the earlobe, up to the level of the posterior auricular muscle posteriorly, and posteriorly into the hairline.
- The skin is undermined anterior to the mass, mobilized, and retracted away from the mass. The mass is then excised as described earlier.
- After removal of the mass, the SMAS is closed directly to give sufficient support to the cheek to avoid deformity.
- Rotation of a flap of SMAS has been recommended for defects that are too large for direct closure or advancement closure. This technique distributes the volume defect over a wider area and converts the depression to a gradual transition that is less noticeable.

- Madorsky and Allison relied on their extensive experience with the rhytidectomy approach in managing 126 patients who had a tumor of the parotid gland and adjacent structures.[8] They described the relationship of the SMAS as being superficial to the facial nerve. If too much tension is placed by direct SMAS closure, the SMAS is mobilized by dissecting the facial nerve branches underlying it and advancing it for closure.
- Closure and wound care are implemented as described previously.

Common Errors in Technique

- Failure to select the proper incision based on the patient's perceived needs can leave undesired visible scars.
- Failure to identify and preserve the important structures contained in the buccal space, especially the facial nerve and Stensen duct, can lead to complications.
- Failure to close the SMAS properly will result in an unsightly depression in the cheek.

POSTOPERATIVE PERIOD

Postoperative Management

- The patient is allowed to recover from anesthesia and is admitted overnight if a drain is left in place.
- Within 24 hours, the drainage has usually stopped, the pressure dressing and drain are removed, and the patient is discharged.

Complications

- Complications are minimized with the extended parotidectomy-submandibular and rhytidectomy approaches because of the superior exposure.
- The need to identify the branches of the facial nerve is the fundamental advantage over the transcutaneous approach.
- The general principles of surgery are never better demonstrated than in this procedure, which includes (1) adequate exposure, (2) potential to extend the surgery if necessary, (3) complete excision of the mass, and (4) an acceptable cosmetic result.

Alternative Management Plan

- Antibiotics and observation for infectious processes
- Observation if the patient declines surgery

Editorial Comment

The experience of caring for a patient who had a mass previously removed through an incision in the buccal mucosa during which an injury to the facial nerve was sustained and a sialocele developed in the buccal space because of inadvertent injury to Stensens duct provided the incentive to design the extended parotid-submandibular incision.

The outcomes of using this technique are invariably positive. Using these techniques that provide excellent exposure enables complete removal of the mass. Complications are rare and the prognosis is good since most of these masses are benign.

Eugene N. Myers

Access the review questions and additional sources list online at http://www.expertconsult.com



REFERENCES

1. Kostrubala JG. Potential anatomical spaces in the face. Am J Surg 1945;68:28–37.
2. Maguire CP, Horton CE, Pickrell KL. Tumors of the cheek; observations on etiology, differential diagnosis, and methods of surgical approach. Am Med Assoc Arch Surg 1955;71(6):869–906.
3. Weaver DF. Tumors of the cheek. Arch Otolaryngol 1964;79:229–238.
4. Gallia L, Rood SR, Myers EN. Management of buccal space masses. Otolaryngol Head Neck Surg 1981;89(2):221–225.
5. Rodgers GK, Myers EN. Surgical management of the mass in the buccal space. Laryngoscope 1988;98(7):749–753.
6. Kurabayashi T, Ida M, Tetsumura A, et al. MR imaging of benign and malignant lesions in the buccal space. Dentomaxillofac Radiol 2002;31(6):344–349.
7. Kurabayashi T, Ida M, Yoshino N, et al. Computed tomography in the diagnosis of buccal space masses. Dentomaxillofac Radiol 1997;26(6):347–353.
8. Madorsky SJ, Allison GR. Management of buccal space tumors by rhytidectomy approach with superficial musculoaponeurotic system reconstruction. Am J Otolaryngol 1999;20(1):51–55.
9. Mitz V, Peyronie M. The superficial musculo-aponeurotic system (SMAS) in the parotid and cheek area. Plast Reconstr Surg 1976;58(1):80–88.

REVIEW QUESTIONS

1. What is the medial border of the buccal space?
   a. Facial artery
   b. Pterygomandibular raphe
   c. Stensen duct
   d. Buccinator muscle
   e. Zygomaticus major muscle

2. What is the most common mass in the buccal space?
   a. Neurofibroma
   b. Neoplasm of the minor salivary gland
   c. Neoplasm of the accessory lobe of parotid
   d. Aspergilloma
   e. Minor salivary gland calculus

3. Which of the following is *not* a complication related to excision of a mass in the buccal space mass?
   a. Hematoma
   b. Sialocele
   c. Facial nerve injury
   d. Gustatory sweating
   e. Depression in the cheek

ADDITIONAL SOURCES

Allan JH, Finch LD, Chippendale I. Sialolithiasis of the minor salivary glands. Oral Surg Oral Med Oral Pathol 1969;27(6):780–785.

Barnard JD. Primary clinical manifestation of bronchial carcinoma as a buccal metastasis. Br Dent J 1975;138(5):174–176.

Calhoun NR. Lipoma of the buccal space. Report of a case. Oral Surg Oral Med Oral Pathol 1963;16:246–249.

Crean SJ, Bryant C, Bennett J, et al. Four cases of polymorphous low-grade adenocarcinoma. Int J Oral Maxillofac Surg 1996;25(1):40–44.

Ewbank RL, Mitchell DF. Hyalinized thrombi of the cheek: report of case. J Oral Surg Anesth Hosp Dent Serv 1964;22:456–459.

Frommer J. The human accessory parotid gland: its incidence, nature, and significance. Oral Surg Oral Med Oral Pathol 1977;43(5):671–676.

Gupta SR, Saran RK, Sharma P, et al. A rare case of extraskeletal mesenchymal chondrosarcoma with dedifferentiation arising from the buccal space in a young male. J Maxillofac Oral Surg 2015;14(Suppl 1):293–299.

Inaba T, Adachi M, Yagisita H. A case of angioleiomyoma in the buccal space. Odontology 2015;103(1):109–111.

Johnson FE, Spiro RH. Tumors arising in accessory parotid tissue. Am J Surg 1979;138(4):576–578.

Kim HC, Han MH, Moon MH, et al. CT and MR imaging of the buccal space: normal anatomy and abnormalities. Kor J Radiol 2005;6(1):22–30.

Klotz DA, Coniglio JU. Prudent management of the mid-cheek mass: revisiting the accessory parotid gland tumor. Laryngoscope 2000;110(10 Pt 1):1627–1632.

Kwong MD, Bert RJ. Neuroradiology case of the day. Polymorphous low-grade adenocarcinoma of a minor salivary gland in the right buccal space. Am J Roentgenol 1999;173(3) 805:8–9.

Landa LE, Kathju S, Nepomuceno-Perez MC, et al. Tuberculous granuloma and adenoid cystic carcinoma presenting as a single buccal space mass. J Craniofac Surg 2002;13(4):533–537.

Merchant NE. Cavernous haemangioma of the cheek. Dent Pract Dent Rec 1972;22(11):436.

Ohba S, Nakatani Y, Kakehashi H, et al. The migration pathway of an extracted maxillary third molar into the buccal fat pad. Odontology 2014;102(2):339–342.

Ozolek JA, Bastacky SI, Myers EN, et al. Immunophenotypic comparison of salivary gland oncocytoma and metastatic renal cell carcinoma. Laryngoscope 2005;115(6):1097–1100.

Perzik SL, White IL. Surgical management of preauricular tumors of the accessory parotid apparatus. Am J Surg 1966;112(4):498–503.

Pinto PX, Coleman N. Regional metastasis in polymorphous low grade adenocarcinoma. Report of a case. Int J Oral Maxillofac Surg 1997;26(6):447–449.

Polayes IM, Rankow RM. Cysts, masses, and tumors of the accessory parotid gland. Plast Reconstr Surg 1979;64(1):17–23.

Rodriguez V, Bardwil JM, Bodey GP. Primary aspergilloma cured with amphotericin B. South Med J 1971;64(4):396–398.

Slater LJ, Edwards RC, Faircloth Jr WJ, et al. Lymphoepithelial lesion of accessory parotid presenting as a buccal space mass. J Oral Maxillofac Surg 1992;50(10):1131–1135.

Smith JF. Nodular fasciitis of the buccal pad. Arch Otolaryngol 1967;86(2):217–218.

Tate RJ. Unusual facial abscess. Report of a case. Br Dent J 1971;131(11):504.

Toh H, Kodama J, Fukuda J, et al. Incidence and histology of human accessory parotid glands. Anat Rec 1993;236(3):586–590.

Tomizawa M, Nakajima T, Fukushima M. False aneurysm of the cheek: report of two cases. J Oral Surg 1979;37(7):515–518.

Trester PH, Markovitch E, Zambito RF, et al. Myositis ossificans, circumscripta and progressiva, with surgical correction of the masseter muscle: report of two cases. J Oral Surg 1969;27(3):201–205.

Yamada H, Hamada Y, Fujihara H, et al. Solitary fibrous tumor of the buccal space resected in combination with coronoidectomy. Oral Surg, Oral Med, Oral Pathol Oral Radiol 2012;114(1):e9–e14.

91 Excision of the Submandibular Gland

Rebecca E. Fraioli

INTRODUCTION

The submandibular gland is one of three paired major salivary glands that drains into the oral cavity. It is midway in size and location between the largest, the parotid gland, and the smallest, the sublingual gland. Histologically, it consists of both serous and mucinous acini, which collectively drain into an excretory duct that carries the secreted saliva into the oral cavity.

The gland is located within the submandibular triangle, superior and lateral to the hyoid bone and digastric sling, and inferior to the mandible. Its excretory duct, known as Wharton's duct, passes deep to the mylohyoid muscle, paralleling the course of the lingual nerve. The duct and nerve lie immediately adjacent to the sublingual gland, just deep to the mucosa of the floor of the mouth. The duct opens through the sublingual papilla adjacent to the lingual frenulum (Fig. 91.1). The narrowest point in the duct is at its orifice; therefore calculi that form in the gland may become impacted at the orifice and be visible or palpable in the floor of the mouth. Eighty percent of all salivary calculi are found in the Wharton's duct. This is likely due to both the horizontal path of and the higher concentration of mucin in the Wharton's duct. Impacted calculi that obstruct salivary outflow will result in enlargement of the gland, stasis of secretions, and ultimately inflammation of the gland (sialadenitis).

With age, the submandibular glands tend to become ptotic and assume a more inferior position, often even prolapsing lateral to the greater cornu of the hyoid bone. In this ptotic position, the gland may be mistaken for a neoplastic mass and lead to referral for further evaluation.

KEY OPERATIVE LEARNING POINTS

- The marginal mandibular branch of the facial nerve lies within the operative field and must be either identified or avoided, depending on the situation.
- It is important to recognize that when a shoulder roll is placed and the patient's head is rotated to the contralateral side, the marginal mandibular nerve is found more inferiorly and may lie directly over the gland.
- When excision of the gland is being performed for benign disease, identification of the nerve may not be necessary. In such cases the nerve may be protected by ligation and elevation of the facial vein (Hayes-Martin maneuver; Fig. 91.2).
- When the gland is removed for malignancy or in conjunction with a neck dissection, the marginal mandibular nerve must be identified to allow the removal of the prevascular and postvascular nodes. Identification of the nerve will help to avoid injury of the nerve posterior to the gland, where the nerve may often be located a significant distance inferior to the level of the mandible.
- In cases in which there is extensive inflammation and scar tissue, a handheld nerve stimulator may be useful to help to locate and preserve the marginal mandibular nerve.
- The proximal stump of the facial artery should be doubleligated and the wound examined for bleeding vessels before closure.
- Care must be taken in patients who have had significant infection and scarring to ensure identification of the lingual nerve before sectioning Wharton's duct.
- Care should be taken after the gland is freed posteriorly to visualize the hypoglossal nerve as it courses deep to the vessels, parallel to the submandibular duct. If inflammation hinders identification of the nerve, it is advisable to find the nerve inferior to the posterior belly of the digastric muscle and follow it in a posterior-to-anterior direction through the submandibular triangle to avoid injury.

PREOPERATIVE PERIOD

History

- History of present illness
  - Patients with sialadenitis often present with unilateral erythema, edema, and pain in the submental region that worsens with eating. Patients may also report foul-tasting (purulent) saliva, particularly when pressure is applied to the affected gland.

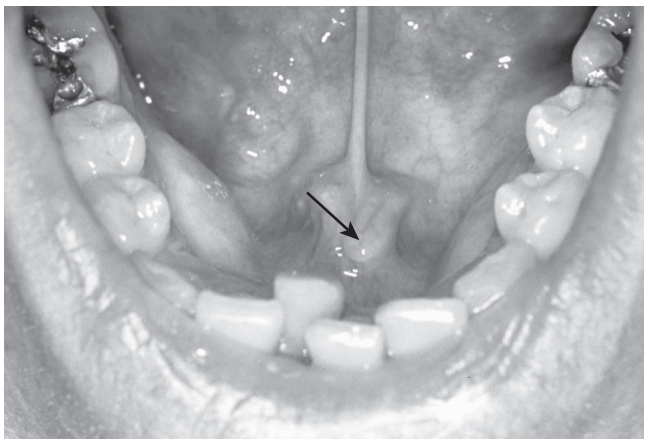

Fig. 91.1. The opening of the Wharton's duct *(arrow)* adjacent to the frenulum of the tongue.

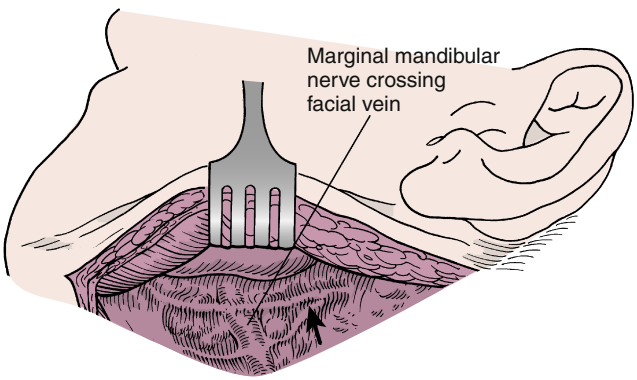

Fig. 91.2. Exposure of the submandibular gland by elevating the platysmal muscle with the skin flap. Note the position of the marginal mandibular nerve *(arrow)*.

- Patients may present with a mass in the submandibular area.
- Neoplasms of the submandibular gland are not common and are more likely to be benign than malignant, but the finding of a mass in the submandibular gland merits further investigation to rule out malignancy.
- Signs or symptoms of nerve invasion, such as weakness of the tongue or lower lip or numbness of the tongue, suggest malignancy.
- Patients presenting for excision of the submandibular gland for chronic sialorrhea must be evaluated for duration and severity of the drooling, as well as for the underlying cause of the sialorrhea and its likelihood of improvement.

- Past medical history
  - Medical history
    - Collagen vascular disease such as Sjögren's syndrome (or its symptoms)
    - Prior radiation to the neck or treatment with I^{131} increases the risk of sialadenitis and of salivary neoplasm.
  - Surgical history
    - Prior attempts at drainage, biopsy, or surgical removal of salivary calculi
    - History of other neck surgery
  - Social history
    - Occupational exposure to silica dust or nitrosamines is linked to an increased risk of cancer of the salivary glands.
    - Use of tobacco and alcohol
- Medications
  - Antiplatelet drugs and anticoagulants
  - Use of supplements that may predispose to bleeding

Physical Examination

- Complete examination of the head and neck should be performed. Lymphadenopathy in the neck must trigger a full evaluation for suspected malignancy. Approximately one-quarter of cancers of the submandibular gland will have regional neck metastases.[1]
- Visual examination and palpation of the floor of mouth may reveal a calculus in the distal Wharton's duct.
- Bimanual palpation of the submandibular gland allows for evaluation of the size of the gland, presence of a discrete mass or calculus, tenderness of the gland to palpation, and degree of fixation of the gland to surrounding structures.
- The quality of the expressed saliva on each side should be evaluated and compared. Cloudy or purulent saliva suggests sialadenitis. The absence of salivary flow in the presence of an enlarged gland suggests obstruction of the outflow tract.
- A careful neurologic examination of the head and neck must be performed. Weakness of the tongue ipsilateral to the involved gland may be a sign of tumor or perineural invasion along the hypoglossal nerve. Likewise, numbness of the ipsilateral tongue may represent involvement of the lingual nerve. Facial weakness involving the ipsilateral lower lip is worrisome for malignant invasion of the marginal mandibular branch of the facial nerve.

Imaging/Diagnostics

- Ultrasound is useful for visualization of salivary calculi and for localization of a mass within the submandibular gland for fine-needle aspiration (FNA). Ultrasound can also show a dilated ductal system in cases of chronic sialadenitis.
- Computed tomography (CT) is most sensitive for identifying a calcified salivary duct calculus and should be ordered for patients presenting with acute or recurrent swelling of the gland with postprandial pain.
- Contrast is not indicated for sialolithiasis but should be used if neoplasm or severe infection with abscess is in the differential diagnosis.
- CT with intravenous (IV) contrast is the most useful modality in a known or suspected malignancy if there is suspicion of bone involvement or destruction.
- Magnetic resonance imaging (MRI) with IV gadolinium contrast is the imaging modality of choice for a suspected neoplasm of the submandibular gland. MRI is able to clearly delineate the neoplasm from the surrounding gland and can demonstrate invasion into nearby structures. In addition, MRI is the best modality for identifying evidence of perineural spread of tumor, which is especially important if adenoid cystic carcinoma is suspected.
- Sialography may reveal narrowing of the duct from scarring with secondary ductal ectasia within the hilum and the gland itself. However, sialography is contraindicated in an acutely infected gland, and MRI sialography has now essentially replaced this procedure.
- FNA is an important element in the diagnostic evaluation for suspected neoplasms of the salivary gland. However, a negative FNA is not definitive, and excision of the gland should still be performed for definitive diagnosis.

Indications

- Neoplasm or suspected neoplasm is an indication for excision of the submandibular gland. If FNA is nondiagnostic and the mass is confined to the gland, excision of the gland can be performed for diagnosis. For a known malignancy, more extensive excision including lymph node dissection is indicated.
- Sialolithiasis with subsequent duct obstruction and sialadenitis was formerly a common indication for excision of the submandibular gland. With the advent of sialoendoscopy, excision of the gland for this indication is now rare.
- In patients with dilated ectatic ducts and chronic infection, excision of the gland may still be necessary for chronic sialadenitis.
- Chronic sialorrhea in patients with neuromuscular swallowing disorders may be treated with submandibular gland excision. In such cases, this procedure is performed bilaterally and in combination with ligation of Stensen's duct.

Contraindications

- Excision of the submandibular gland should be avoided in cases of acute infection due to loss of tissue planes and subsequent difficulty in identifying key structures. In fulminant cases in which abscess and elevation of the floor of mouth occur, incision and drainage, possibly even requiring tracheotomy, may be necessary; however, definitive gland excision can often be delayed until the acute inflammation has passed.
- Although not a contraindication, obstruction of the duct due to calculus, chronic sialadenitis, prior radiation, or Sjögren's syndrome can sometimes be managed with sialoendoscopy. Minimally invasive procedures should be considered prior to proceeding with excision of the gland.

Preoperative Preparation

- FNA results and imaging should be reviewed preoperatively in patients with a mass in the submandibular gland.
- Anticoagulant/antiplatelet medications should be discontinued if possible.

- Several approaches to excision of the submandibular gland have been described, and the choice of approach should be made before surgery.
- The lateral transcervical approach is the traditional approach to excision of the submandibular gland and remains the most commonly used approach despite the description of newer approaches in recent years.[2]
- The intraoral approach is designed to avoid visible scarring from the cervical incision and injury to the marginal mandibular nerve, which is the most frequently injured nerve in the traditional transcervical approach. Branches of the facial nerve are not at risk with the intraoral approach and are not identified during this dissection.[3,4]
- Pitfalls of the intraoral approach stem from significant retraction of the floor of the mouth, including the lingual nerve and mylohyoid muscle. In one study, temporary injury to the lingual nerve was observed in 81% of patients, and 68% reported a temporary decrease in tongue mobility that resolved within 2 weeks of surgery and was attributed to edema of the floor of the mouth rather than injury to the hypoglossal nerve.[3]

OPERATIVE PERIOD

Anesthesia

- General anesthesia is preferred; however, excision of the submandibular gland may be performed under local anesthesia in patients who are poor candidates for general anesthesia as long as the gland does not have findings suspicious for malignancy.[5]
- Paralysis should be avoided to aid in identification of the marginal mandibular and hypoglossal nerves, especially in cases with suspected malignancy or a history of recurrent infection.

Positioning

- For the transcervical approach, placement of a shoulder roll is used to extend the neck and provide better exposure of the submandibular triangle. The patient is then positioned with the head elevated slightly and rotated toward the opposite side.
- Orotracheal intubation is performed for the transcervical approach, and the tube is taped to the side contralateral to the surgical site.
- Nasotracheal intubation is necessary for the intraoral approach.

Perioperative Antibiotic Prophylaxis

- Antibiotic prophylaxis is not required when using the transcervical approach because this is a clean procedure according to the Centers for Disease Control and Prevention (CDC) surgical site infection guidelines.
- Transoral excision is a clean-contaminated procedure, and a 24-hour course of prophylactic antibiotics covering oral flora is recommended.

Monitoring

- Nerve monitoring is not routinely performed during excision of the submandibular gland.
- Handheld nerve monitoring without the use of IV paralytics may be useful in cases of suspected malignancy or severe chronic infection where surgical planes may be lost.

Instruments and Equipment to Have Available

- Head and neck surgical set
- Bipolar electrocautery
- Handheld nerve monitor

Key Anatomic Landmarks

- The facial vein will be identified on the lateral surface of the submandibular gland. Ligation and elevation of this vein will help to preserve the marginal mandibular nerve (Hayes-Martin maneuver) (see Fig. 91.2) in cases in which the adjacent prevascular and postvascular nodes do not require dissection.
- The anterior belly of the digastric muscle should be identified and reflected posteriorly to expose the mylohyoid muscle.
- The mylohyoid muscle is an important landmark in that the lingual nerve and Wharton's duct, as well as the sublingual gland and the anterior portion of the submandibular gland, lie immediately deep to it.
- The posterior belly of the digastric muscle may be used to help identify the hypoglossal nerve in cases in which inflammation makes identification of the nerve difficult. The hypoglossal nerve may be found inferior to the posterior belly of the digastric muscle and then can be followed in a posterior-to-anterior direction through the submandibular triangle.

Prerequisite Skills

General surgical skills and an intimate knowledge of the anatomy of the head and neck

Operative Risks

- Injury to the marginal mandibular nerve
- Injury to the hypoglossal nerve
- Injury to the lingual nerve
- Retained calculus with possible obstruction and infection
- Hemorrhage from the facial artery with possible hematoma and elevation of the floor of mouth
- Wound infection
- Fistula formation
- Unsightly scar
- Xerostomia

Surgical Technique

Transcervical Approach

- The incision is made at the inferior margin of the submandibular gland in a natural skin crease, usually slightly above the level of the hyoid bone.
- Localization of a smaller submandibular gland can be simplified by placing a gloved finger in the mouth and depressing the floor of the mouth on the affected side.
- The incision is carried through skin, subcutaneous tissue, and platysma muscle. Once through the platysma muscle, the nerve is at risk, and dissection should first be directed toward the inferior portion of the submandibular gland.
- After exposure of the submandibular gland, the fascia overlying the gland is incised and the superior flap of fascia is elevated from the lateral surface of the gland. As this is performed, the facial vein is encountered. Ligation and elevation of this vein will help preserve the marginal mandibular nerve (see Fig. 91.2).
- If the gland is excised as a part of a neck dissection or if the gland is being excised for possible malignancy, the nerve must be dissected free of the underlying vein and adjacent prevascular and postvascular nodes (Fig. 91.3), which should be removed.
- When the superior aspect of the gland has been encountered, blunt dissection is used to free it from the surrounding soft tissue. The marginal mandibular nerve will be preserved if dissection is maintained directly on the gland and deep to the fascia.

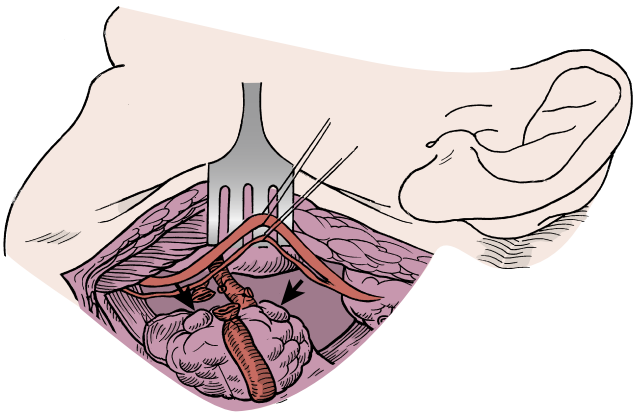

Fig. 91.3. Elevation of the marginal mandibular nerve can be done by dividing the facial vein low on the gland and elevating the nerve along with the vein. Note the prevascular and postvascular lymph nodes *(arrows)*.

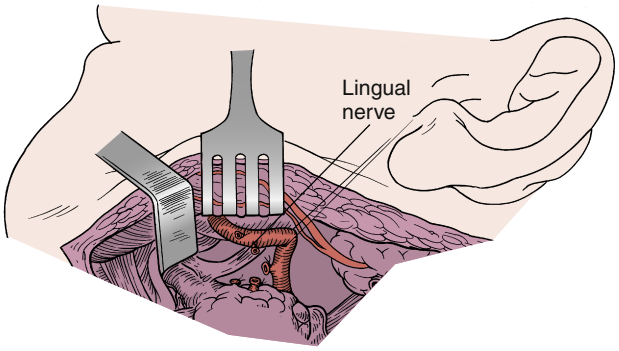

Fig. 91.4. The posterior edge of the mylohyoid muscle is exposed and then retracted anteriorly to expose the Wharton's duct and the lingual nerve.

- If the gland has been chronically inflamed and is adherent to surrounding soft tissue, it is often necessary to identify the nerve. Magnification and a handheld facial nerve monitor may be helpful.
- After the entire flap has been elevated off the lateral aspect of the gland, the anterior portion of the gland is freed from soft tissue at the level of the anterior belly of the digastric muscle. This is best done by incising the fascia over the anterior belly of the digastric muscle and reflecting it posteriorly.
- As this reflection occurs, the mylohyoid muscle is encountered. The muscle can be identified by the direction of its fibers extending from posterosuperior to anteroinferior (at a significantly different angle from that of the anterior belly of the digastric muscle).
- The dissection is carried posterior to the edge of the mylohyoid muscle. The mylohyoid muscle is occasionally difficult to identify, especially with chronically infected glands adherent to the muscle. This muscle may also be dehiscent in areas and lead to difficulty identifying its posterior aspect.
- Several perforating vessels, as well as its motor nerve, enter the mylohyoid muscle. The vessels are usually sacrificed to free the overlying portion of the submandibular gland.
- A small right-angled retractor can be used to retract the muscle anteriorly off of the deep portion of the gland (Fig. 91.4).
- The anterior portion of the gland, the duct with the closely adherent sublingual gland, and the lingual nerve will be encountered immediately deep to the mylohyoid muscle. The lingual nerve can be seen superiorly as a broad band extending from deep to the mandible posteriorly and looping close to the anterior portion of the gland, where it gives rise to nerve roots extending into the submandibular ganglion.
- The lingual nerve ascends superiorly as it extends anteriorly to innervate the anterior aspect of the tongue and floor of the mouth. This nerve must be carefully dissected free and the rootlets incised.
- Every effort should be made to identify and preserve the lingual nerve because injury will result in loss of sensation of the lateral aspect of the oral tongue.
- After the nerve has been identified and the rootlets incised, the duct can usually be identified in the fascia superficial to the floor of the submandibular triangle. A large vein generally accompanies the duct and should be ligated separately.
- The hypoglossal nerve can then be identified extending along the floor of the triangle, where it emerges from deep to the posterior belly of the digastric muscle. Care must be taken to avoid injury to the hypoglossal nerve. Injury is unusual unless previous inflammation has made it difficult to identify the plane deep to the gland.
- After the hypoglossal nerve has been identified, the duct can be divided (Fig. 91.5). Care must be taken to include dissection of the duct up to the mucosa of the floor of the mouth; otherwise, calculi can be retained in the duct and result in postoperative chronic inflammatory disease of the duct remnant. Bimanual palpation at this stage often helps prevent retained calculi in the duct.
- A salivary scope can be placed into the duct through the neck in a retrograde fashion if there is concern regarding retained calculi.
- When the anterior portion of the gland has been freed from the lingual nerve and submandibular duct, the remainder of the gland is easily detached from the underlying fascial planes over the floor of the submandibular triangle. The gland can then be retracted inferiorly with countertraction placed on the soft tissue superior to the gland, and the superior aspect of the gland is dissected free from the soft tissue just inferior to the mandible.
- Care must be taken to avoid injury to the marginal mandibular nerve where it courses just lateral and superior to the gland. Injury is avoided by either identifying the nerve or by maintaining dissection within a plane immediately adjacent to the substance of the gland. The latter technique may be difficult in a severely inflamed gland.
- As the gland is reflected inferiorly, the facial artery can be seen indenting the posterosuperior surface of the gland. It is usually divided as it leaves the gland superiorly and then again as it enters the gland, although it can be preserved in noninflamed cases by dissecting the artery free of the gland and individually identifying, dividing, and ligating the feeding vessels extending into the substance of the gland.
- When the gland has been freed from the artery, the gland is removed.
- The submandibular triangle should be examined for vessels that require ligation. Particular care should be taken to examine the anterior portion of the triangle deep to the mylohyoid muscle.
- The wound is irrigated, a suction drain is inserted, and the wound is closed. The platysma muscle, subcutaneous layer, and skin should each be closed separately.

Intraoral Approach

- Following nasotracheal intubation, lidocaine with epinephrine (1:100,000) is injected into the mucosa for hemostasis.

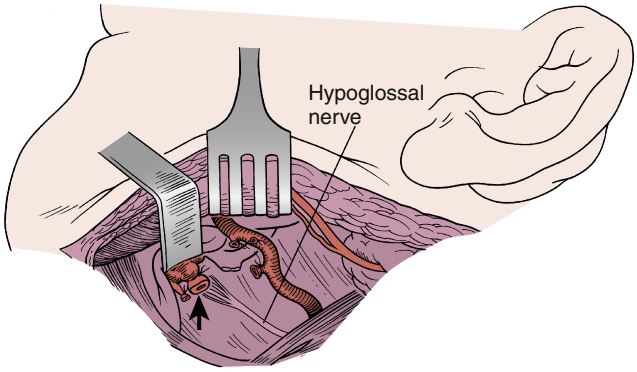

Fig. 91.5. The branches of the lingual nerve passing to the submandibular ganglion are divided to free the nerve from the specimen. The Wharton's duct is divided *(arrow)*, and the specimen is removed. Care must be taken to ensure that there are no calculi distal in the duct, or postoperative infection in the duct remnant may result.

- A probe is inserted into Wharton's papilla, and an intraoral incision is made through the mucosa of the floor of the mouth from the duct orifice posteriorly to the lingual aspect of the retromolar region.[3]
- Dissection and removal of the sublingual gland will facilitate exposure of the duct.
- Careful dissection along the course of the Wharton's duct will reveal its close relationship to the lingual nerve. Retraction of the tongue and floor of the mouth, including the lingual nerve, allows visualization of the mylohyoid muscle.[3]
- Anterior retraction of the posterior margin of the mylohyoid muscle allows visualization of the superficial portion of the submandibular gland. Blunt dissection is used to free the submandibular gland from surrounding structures.
- Transcervical pressure on the gland will elevate the gland in the floor of mouth and aid in visualization.
- The facial artery and vein and their branches are identified and may be either avoided or ligated.
- The gland is then carefully removed, and hemostasis is achieved. A drain may be inserted through the incision site, and the mucosa is re-approximated with absorbable suture.

Endoscopic Approach

There are case reports of endoscopic excision of the submandibular gland via either a transoral or small neck or hairline incision. Techniques are endoscopically assisted but otherwise are similar to those described above.

Robotic Approach

- The robotic approach, although not yet commonly performed, shows promise in reducing operative times over straight endoscopic techniques.[6]
- A retroauricular incision can be used[7,8] or else three small incisions (14, 10, and 10 mm) are made in the neck to allow trocar placement.[6] In the latter case, the gland is removed through the 14-mm incision.
- If trocars rather than the retroauricular approach are used, a surgical pocket is created with inflation of a hernia balloon.[6]
- The gland is approached in the subplatysmal plane, and dissection proceeds from inferior to superior in the subcapsular plane to avoid injury to the marginal mandibular nerve.
- The Wharton's duct and facial artery and vein are ligated with surgical clips.

COMMON ERRORS IN TECHNIQUE

- Failure to protect the marginal mandibular nerve
- Failure to address calculi in the hilum or distally at the time of gland resection for calculi
- Failure to achieve adequate homeostasis before closure

POSTOPERATIVE PERIOD

Postoperative Management

- Postoperative management is minimal and includes elevation of the head of the bed and removal of the drain after drain output decreases.
- Excessive persistent drainage will require re-exploration because uncontrolled hematoma in this area may result in airway difficulty secondary to displacement of the tongue musculature.
- Patients undergoing excision of the submandibular gland are customarily observed for 24 hours postoperatively, primarily to avoid the risk of airway compromise due to unanticipated postoperative edema.

Complications

- The marginal mandibular nerve can be injured and result in paralysis of the lower lip, especially in patients with chronic inflammation of the gland where the anatomic planes of dissection are obliterated by inflammation and scarring.
- Failure to dissect Wharton's duct all the way to the mucosa of the floor of the mouth during excision of the submandibular gland can result in retained calculi with infection later on.
- Postoperative hemorrhage can lead to significant airway obstruction as a result of edema of the tongue musculature.
- The lingual nerve can be injured by injudicious sectioning of the duct without first identifying and freeing the nerve where it lies directly superior to the duct.
- The hypoglossal nerve may be adherent to the medial aspect of the gland and inadvertently resected or transected.

Alternative Management Plan

- Sialoendoscopy has changed the paradigm for patients with calculus, obstruction, and chronic sialadenitis, and the excision of the gland can often be avoided in such patients.[9]
- Excision of the gland is necessary for the diagnosis and treatment of a mass in the submandibular gland. Patients refusing surgery should, at a minimum, be followed as an outpatient.

DISCUSSION

Evidence-Based Medicine Question

How do rates of marginal mandibular nerve injury with the newer approaches to submandibular gland excision compare with rates with the traditional transcervical approach?

The intraoral approach to submandibular gland excision accesses the submandibular gland from its deep surface, thereby avoiding the marginal mandibular nerve. Although authors have been successful in avoiding marginal nerve injury, overall neurologic injury may be higher with this approach, with one study showing 81% of patients developing transient partial anesthesia of the tongue and 68% developing mild temporary limitation of movement of the tongue, although this was attributed more to edema than to nerve injury.[3] A subsequent study by Weber et al. found no changes in mobility of

the tongue and a lower (43%) incidence of temporary alteration in sensation of the tongue sensation.[4] However, the study by Weber and colleagues consisted of only seven patients, and it is not clear that these results can be generalized to a wider population.

The submental approach has been studied by Roh[10] in a prospective randomized fashion, with no increased incidence of injury to the facial nerve found with the submental approach. Roh has also studied the retroauricular approach and had no instances of marginal nerve injury with this approach, although he had two such incidents in the same study while using the traditional transcervical approach.[7] Endoscopic and robotic approaches are being developed that may be able to further improve visualization and limit neurologic trauma.

A limitation of all of the above studies is small sample size. It is important to recognize that even with the traditional transcervical approach reports of transient injury to the marginal mandibular nerve have varied significantly, from 7.7% to 36%.[2] The indication for gland excision (e.g., benign disease vs. malignant disease versus inflammatory disease) may, to some degree, explain this variability. However, given this wide variability, we must be cautious in extrapolating the findings of the current small studies to a wider population of surgeons and patients. Nevertheless, the findings of these early studies are promising, and alternative approaches to submandibular gland excision are reasonable to consider in the properly selected patient.

Editorial Comment

Inflammatory disease of the submandibular gland is increasingly managed with minimally invasive techniques. This is better for the patient and allows the surgeon to avoid open surgery in an inflamed or infected difficult surgical field. Open procedures are still indicated for nonendoscopic candidates, for surgical failures, and for neoplasms. The chapter highlights the important anatomy and suggests techniques for avoiding the neurologic complications that are functionally very important.

Barry Schaitkin

Access the review questions and additional sources list online at http://www.expertconsult.com



REFERENCES

1. Sunwoo JB, Lewis JS, Tomeh C, et al. Malignant neoplasms of the salivary glands. In: Flint PW, Haughey BH, et al., editors. Cummings Otolaryngology—Head and Neck Surgery. 6th ed. Elsevier, Philadelphia; 2015. p. 1258–1280.
2. Beahm DD, Peleaz L, Nuss DW, et al. Surgical approaches to the submandibular gland: a review of the literature. Int J Surg 2009;7:503–509.
3. Hong KH, Kim YK. Intraoral removal of the submandibular gland: a new surgical approach. Otolaryngol Head Neck Surg 2000;122:798–802.
4. Weber RS, Wax MK, Kim JH. Transoral excision of the submandibular gland. Otolaryngol Head Neck Surg 2007;137:343–345.
5. Chow TL, Choi CY, Lam SH. Submandibular sialoadenectomy with local anesthesia in the era of minimally invasive surgery. Otolaryngol Head Neck Surg 2008;138:752–755.
6. Terris DJ, Haus BM, Gourin CG, Lilagan PE. Endo-robotic resection of the submandibular gland in a cadaver model. Head Neck 2005;27:946–951.
7. Roh JL. Removal of the submandibular gland by a retroauricular approach. Arch Otolaryngol Head Neck Surg 2006;132:783–787.
8. Byeon HK, Koh YW. The new era of robotic neck surgery: the universal application of the retro-auricular approach. J Surg Oncol 2015;112:707–716.
9. Kopec T, Wierzbicka M, Szyfter W, et al. Algorithm changes in treatment of submandibular gland sialolithiasis. Eur Arch Otorhinolaryngol 2013;270:2089–2093.
10. Roh JL. Removal of the submandibular gland by a submental approach: a prospective, randomized, controlled study. Oral Oncol 2008;44:295–300.

REVIEW QUESTIONS

1. What is the most commonly injured nerve in the transcervical approach?
   a. Lingual nerve
   b. Hypoglossal nerve
   c. Marginal mandibular branch of the facial nerve
   d. Alveolar nerve

2. What is the least commonly injured nerve in the transoral approach?
   a. Lingual nerve
   b. Hypoglossal nerve
   c. Marginal mandibular branch of the facial nerve
   d. Alveolar nerve

3. Injury to the lingual nerve causes which of the following deficits?
   a. Numbness to ipsilateral anterior ⅔ of tongue
   b. Numbness to ipsilateral posterior ⅓ of tongue
   c. Weakness of the ipsilateral tongue
   d. Weakness of the contralateral tongue

4. Injury to the hypoglossal nerve causes which of the following deficits?
   a. Numbness to ipsilateral anterior ⅔ of tongue
   b. Numbness to ipsilateral posterior ⅓ of tongue
   c. Weakness of the ipsilateral tongue
   d. Weakness of the contralateral tongue

5. The lingual nerve is identified deep to the:
   a. Facial vein
   b. Facial artery
   c. Anterior belly of digastric muscle
   d. Posterior belly of digastric muscle
   e. Mylohyoid muscle

ADDITIONAL SOURCES

Hong KH, Yang YS. Intraoral approach for the treatment of submandibular salivary gland mixed tumors. Oral Oncol 2008;44:491–495.

Hong KH, Yang YS. Surgical results of the intraoral removal of the submandibular gland. Otolaryngol Head Neck Surg 2008;139:530–534.

Koh YW, Choi EC. Robotic approaches to the neck. Otolaryngol Clin N Am 2014;47:433–454.

Smith AD, Elahi MM, Kawamoto Jr HK, et al. Excision of the submandibular gland by an intraoral approach. Plast Reconstr Surg 2000;105:2092–2095.

Smith WP, Markus AF, Peters WJN. Submandibular gland surgery: an audit of clinical findings, pathology, and postoperative morbidity. Ann R Coll Surg Engl 1993;75:164–167.

Springborg LK, Moller MN. Submandibular gland excision: long-term clinical outcome in 139 patients operated in a single institution. Eur Arch Otorhinolaryngol 2013;270:1441–1446.

Stern Y, Feinmesser R, Collins M, et al. Bilateral submandibular gland excision with parotid duct ligation for treatment of sialorrhea in children: long-term results. Arch Otolaryngol Head Neck Surg 2002;128:801–803.

92 Superficial Parotidectomy

Lisa Galati

INTRODUCTION

Tumor resection is the most common indication for superficial parotidectomy. Approximately 85% of parotid neoplasms are benign. Malignant tumors vary greatly in behavior, from the indolent (acinic cell carcinoma) to the highly lethal (carcinosarcoma). A recent surveillance epidemiology and end results (SEER) data base review of more than 22,000 cases showed that mucoepidermoid carcinoma continues to be the most common salivary gland malignancy (31%).[1] Some high-grade malignancies may be managed with superficial parotidectomy but require neck dissection as well. Metastatic lymphadenopathy from primary skin malignancies is also a common indication for parotidectomy. Lymphoma poses a particular challenge to the parotid surgeon—accurate diagnosis may be available only after open biopsy. Therefore it is important to keep lymphoma in the differential to avoid extirpative surgery for this medically-managed disease. Chronic parotitis is a less common indication for superficial parotidectomy and is recommended for patients who are refractory to medical management or minimally invasive techniques.

KEY OPERATIVE LEARNING POINTS

- Superficial parotidectomy allows resection of either part or all of the gland lateral to the facial nerve.
- The facial nerve has arbitrarily been set as the divider of the parotid, actually a single structure, into superficial (lateral) and deep lobes.
- Systematic dissection—dividing the parotidomasseteric fascia; identifying the "pointer" of the cartilaginous external auditory meatus, mastoid tip, and tympanomastoid suture line; and delicate handling of the tissues to avoid undue bleeding—allows for consistent identification of the main trunk of the facial nerve at the outset of this procedure.

PREOPERATIVE PERIOD

History of Present Illness

- Pain, gradual onset of facial paralysis, rapid growth, and fixation are suggestive of a malignant tumor.[2]
- A history of radiation exposure increases the risk of mucoepidermoid carcinoma; a prior history of lymphoma or Sjögren disease should place lymphoma higher in the differential diagnoses.
- A history of skin cancer or nonhealing skin lesions
- Family history is not usually contributory, but there are case reports of familial parotid malignancies in the literature.[3]
- Social history of smoking in a patient with a cystic parotid mass makes a Warthin tumor a likely possibility.
- A long history of a parotid mass may pose a higher risk of malignancy. Malignant degeneration occurs in 5% to 10% of pleomorphic adenomas; although the risks are not well defined, a long-term history or recurrence of pleomorphic adenomas may point to an increased prevalence of carcinoma ex pleomorphic adenoma.
- History of previous parotid surgery.
- Medications—use of nonsteroidal anti-inflammatory drugs (NSAIDs) and/or vitamin/herbal supplements or aspirin may contribute to prolonged bleeding and should be stopped 1 week prior to surgery.

Physical Examination

- A mobile mass is suggestive of a benign tumor. Fixation is worrisome but may occur in benign tumors that extend through the stylomandibular tunnel into the prestyloid parapharyngeal space or that are inflamed.
- Cervical lymphadenopathy is concerning for malignancy but occasionally may result from an inflammatory process.
- Paralysis of one or more branches of the facial nerve is a hallmark of malignancy.
- There may be evidence of previous surgery in the parotid area.

Imaging

- Computed tomography (CT) or magnetic resonance imaging (MRI) with contrast is indicated to evaluate the anatomy, tumor extension and characteristics, presence of lymphadenopathy, and sialoliths.
- MRI is particularly useful in the evaluation of parotid neoplasms.
  - Lesions with irregular borders, infiltration into soft tissue, and low signal intensity on T2-weighted images should raise suspicion of malignancy.
  - Recent studies have demonstrated the usefulness of MRI in identifying malignant tumors because they enhance earlier and have less "washout" at longer relaxation times.[4]
  - Pleomorphic adenomas may be heterogeneous and have sharp scalloped borders.
  - Warthin tumors are cystic and have high signal intensity on T2 imaging.
- Positron emission tomography (PET) is indicated for staging a known malignancy.
- Ultrasound is useful for identifying enlarged intraparotid lymph nodes. If normal architecture is preserved, surgery may be avoided.

Indications

- Neoplasms of the superficial lobe
- Chronic parotitis refractory to medical management

Contraindications

- Patient is a poor surgical candidate owing to medical history
- Involvement of the deep lobe
- Malignant tumor extending into the parapharyngeal space, mandible, skin, or ear canal or the presence of distant metastases

Preoperative Preparation

Biopsy

- Fine-needle biopsy (FNA) is indicated in the case of any suspicious tumor.
- The false-positive rate of FNA is about 10%.
- Frozen section analysis has lower false-positive results (5%)[5] and is used to confirm the diagnosis and evaluate margins.
- FNA results are useful in managing salivary gland tumors in patients who are elderly and/or have significant medical contraindications to surgery.
- Open biopsy should be used with caution owing to risk to the nerve or seeding of tumor. However, with a large mass in the tail of the parotid extending beyond 1 cm posterior to the ascending ramus, a small incision can be made parallel to the ramus, 1 cm posterior to it, to obtain tissue for flow cytometry and pathology. This technique is very useful in elderly patients with lymphoma and can be performed in the office.

OPERATIVE PERIOD

Anesthesia

- General anesthesia
- Avoidance of long-acting paralytic agents

Positioning

- The entire side of the face and ear is prepped and draped into the field after the neck is gently extended.

Perioperative Antibiotic Prophylaxis

- Prophylactic use of antibiotics in patients undergoing parotidectomy for tumor removal is not indicated.[6]
- Suction drains are not an indication for antibiotics.
- Antibiotics are indicated in surgeries performed for chronic parotitis.

Monitoring

- Facial nerve monitoring is not considered the standard of care but is often used, especially in revision cases or chronic parotitis.

Instruments and Equipment to Have Available

- Head and neck set
- Facial plastics set
- Blunt-tipped dissecting scissors
- Right-angle retractors

Key Anatomic Landmarks

- Cartilaginous "pointer" external auditory meatus
- Mastoid tip
- Posterior belly of the digastric muscle

Prerequisite skills

- Nerve dissection

Operative Risks

- Numbness of the ear and/or skin of the face and neck
- Gustatory sweating (Frey syndrome); drainage from the wound and sialocele formation
- Facial nerve injury
  a. The risk of injury to the facial nerve and its significance must be discussed with all patients.
  b. Patients who have malignant tumors must be informed of the plan regarding nerve sacrifice and reconstruction.

Surgical Technique

Incision

- The modified Blair incision is most commonly used (Fig. 92.1A). For tumors at or above the level of the lobule, the incision need not extend onto the neck.
- The skin is elevated off of the SMAS. If it is not involved by tumor, the superficial musculoaponeurotic system (SMAS) may be elevated as a flap for later use to fill the defect.

Identification of the Facial Nerve

- The superior aspect of the sternocleidomastoid muscle is skeletonized.
- The greater auricular nerve is divided in most cases.
- Dissection is carried along the cartilaginous external auditory meatus, the pointer is identified, and the parotid gland is retracted anteriorly. *From here it is helpful to continue dissection in a plane parallel to the floor*; a more perpendicular course will lead to the styloid, deep to the facial nerve (see Fig. 92.1B).
- The parotidomasseteric fascia is incised. This exposes parotid tissue and allows access to the plane in which the nerve courses.
- Palpation of the tympanomastoid suture line, which is located between the pointer and mastoid tip, helps to identify the spot at which the nerve will enter the gland parenchyma (large tumors may displace the main trunk in a more vertical direction, paralleling the course of the sternocleidomastoid (SCM)). Staying over the suture line and carefully dividing small pieces of fascia and parotid are very reliable methods of exposing the facial nerve (see Fig. 92.1B and C).
- Identification of the digastric muscle is also helpful, as the stylomastoid foramen lies just medial to its attachment to the mastoid (see Fig. 92.1D).
- Retrograde dissection of the marginal mandibular nerve is a seldom used but reliable technique used to identify the main trunk of the nerve when the standard approach is not possible.

Parotid Dissection

- Once the nerve has been identified, dissection continues along the main trunk and branches.
- The parotid lateral to the visible portion of the nerve is divided.
- Overstimulation of the nerve is to be avoided. Overuse of the facial nerve stimulator can cause praxis of the nerve, as can improper dissecting technique. The tissues over the nerve should be spread apart in a plane parallel to the nerve fibers; any angulation away from this plane may cause undue trauma to the nerve.
- Superficial parotidectomy is the current standard procedure for parotitis[7]; removal of the entire superficial lobe with or without duct ligation produces cure rates approaching 100%.[8]
- Endoscope-assisted accessory parotid lobe excision aids in safe facial nerve dissection without the large or facial incisions that would be necessary to reach this anterior position.[9]

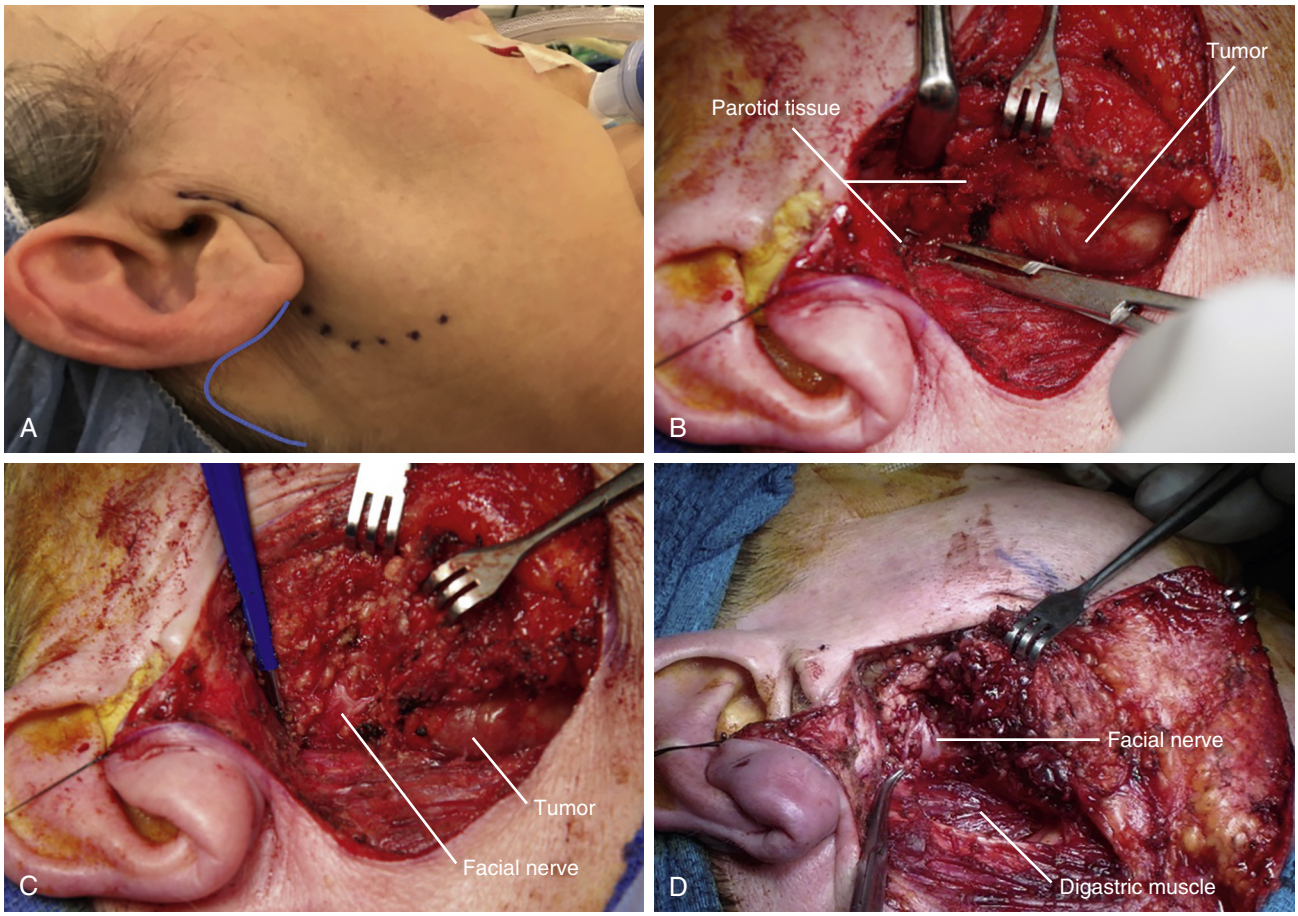

Fig. 92.1. **A**, The classic modified Blair incision is marked in the preauricular crease at the level of the meatus, behind the lobule and down into a neck crease. The solid line depicts the "face lift" modification, to hide the posterior limb near the hairline. **B,** The McCabe dissector allows dissection of the delicate tissues lateral to the facial nerve. Here the dissection is carried out near the tympanomastoid suture line in a plane moving toward the parotid, not down toward the bony ear canal. The nerve lies deep to this tissue. **C**, The facial nerve is exposed and dissection continues along its branches until reaching soft tissue anterior to the mass. **D**, The digastric muscle inserts onto the mastoid process and lies lateral to the nerve as it exits the stylomastoid foramen.

- Extracapsular dissection descended from the technique of intracapsular enucleation, which was performed up to the 1960s. It was intended to decrease injuries to the facial nerve but resulted in recurrence rates of over 40% due to incomplete resection of the capsule.
- Use of a microscope is required during division of salivary tissue around the tumor capsule; minimal amounts of normal salivary gland are removed and the facial nerve is not dissected.[10]

Margins

- Benign parotid neoplasms require excision of a fairly small cuff of normal gland.
- However, the deep portion of the dissection of the facial nerve often yields no margin of tissue other than the tumor capsule itself. Careful dissection of the tumor away from the nerve is necessary to avoid injury to the facial nerve and complete excision of the capsule. Once the tumor has been dissected off the facial nerve beyond the anterior limit of the lesion, the parotid is divided and the specimen is removed.
- In cases of malignancy, particularly low-grade tumors, the extent of parotidectomy may be similar to that involved in the resection of benign tumors.
- After superficial parotidectomy for a tumor with negative margins that is found to be malignant on final pathology, reoperation is not required.

Hemostasis

- Suture ligation of small vessels or bipolar cautery is used to avoid injury to the nerve.
- A harmonic scalpel appropriate for head and neck procedures was introduced in 2008. It coagulates and divides tissue and has been shown to significantly decrease operative time.

Closure

- The main trunk of the facial nerve is stimulated prior to closing to evaluate its integrity.
- Insertion of a suction drain is useful after the wound is irrigated.
- Defects resulting in obvious contour hollowing can be repaired by
  1. Approximating the SMAS to the SCM or creating a small rotation flap by dividing some of the superior fibers of the SCM and suturing them anteriorly. Care must be exercised to avoid injury to the spinal accessory nerve.

2. Use of allogenic dermal grafts. These have been reported to be safe, but this avascular foreign body has also been found to promote infection and salivary fistula.
3. Insertion of adipose tissue grafts, which are limited by reabsorption and a separate donor site

- Subcutaneous layer approximated with interrupted 3-0 absorbable suture, skin edges with either 6-0 absorbable suture or histacryl glue
- Steri-Strips are applied, followed by a sterile parotid dressing.

Common Errors in Technique

- Excessive traction on the facial nerve during dissection
- Difficulty identifying the facial nerve
- Traumatic dissection of the facial nerve or its branches

Postoperative Management

Facial Nerve Function

- If function is weak but the nerve was found to be intact intraoperatively, a full recovery of function is expected.
- Steroids are not indicated as they do not improve outcome.
- Reoperation is indicated only if the nerve was not identified during the dissection. In this case attempts to find and repair the nerve should be made.

Drains and Dressing

- Drains are left to bulb suction to avoid inadvertent stress to the nerve.
- The drain is removed if total output is less than 20 mL in 24 hours. After that point, the drain is removed if there is less than 5 mL of drainage over the next 8 hours.
- The harmonic scalpel does not decrease the amount of postoperative drainage.
- The dressing is left on for 24 hours after discharge.
- Exertional activities are restricted for 2 weeks and driving is restricted for 1 week.

Complications

Hematoma

- Sudden facial swelling or rapid filling of the drain should be treated by exploration of the wound in the operating room.
- Evacuation of the hematoma is important in order to avoid wound infection and necrosis of the flap.

Frey Syndrome

- Occurs in up to 60% of parotidectomy patients but only about 10% consider it to have a negative impact on quality of life
- Antiperspirant application or botulinum toxin injections are temporary management options.
- Long-term control involves placement of vascularized tissue between the parotid bed and the skin.
- Intraoperatively, a flap can be created by lifting the SMAS off of the gland, leaving it pedicled anteriorly, and then placing in the defect before closure.
- Revision surgery for Frey syndrome should be carefully considered because of the increased risk of facial nerve injury due to scarring.

Injury to the Facial Nerve

- Mild neuropraxia resolves in 4 to 6 weeks.
- More severe traction injuries resulting in axonal death will take much longer to recover (6 months); imperfect recovery leads to permanent weakness and synkinesis.
- Transected nerve fibers should be repaired if possible.
- Nerve ends should be examined and freshened by excising a small amount of nerve to create a blunt edge.
- Epineurium is reapproximated using 8- or 9-0 monofilament suture; a neural tube can be placed to support the repaired nerve.
- If a nerve graft is required, the greater auricular is readily available.
- When the nerve is repaired in a second stage, the sural nerve or medial branchial cutaneous nerve is a good graft choice.
- If the nerve was normal preoperatively and a microscopic repair is performed immediately, the best result possible is a House-Brackmann grade III. Recovery takes about 6 to 12 months.

Infection

- Occurs in less than 5% of cases

Sialocele Formation and Seroma

- A very uncommon (approximately 5%) but persistent complication of superficial parotidectomy
- Use of allogenic dermal grafts or Surgicel and anterior location of the tumor have been implicated as risk factors.
- Ballotable swelling noted at the postoperative check should be aspirated in the office. The skin is prepped to avoid the introduction of bacteria, and a large-bore (16–20 French) needle is used to aspirate the collection. Pressure dressings at this point confer little advantage. Repeat aspiration may be necessary, especially in cases of seroma formation.
- We instituted the use of Botox after extrapolating from early reports its use for Frey syndrome and have had success with this nonoperative approach.
- Expectant management is also reasonable, and most of these conditions resolve without treatment in 4 to 6 weeks.

Flap Necrosis and Hypertrophic Scars

- Flap necrosis is avoidable if the skin is elevated with the subcutaneous adipose tissue.
- Smoking increases the risk of flap necrosis.
- Keloid formation may be seen early in the postoperative period and is best treated when first noted. Injection of triamcinolone directly into the scar is effective. Local anesthesia with lidocaine prior to injection or mixed with triamcinolone is important, as hypertrophic scar injection is often painful.

Recurrent Tumor or Infection

- Occurs in 2% of cases
- Is often multifocal
- Incomplete capsule removal and, less commonly, tumor spillage are causative.
- If capsule rupture occurs, the wound is irrigated with copious amounts of saline and carefully inspected to remove all tumor fragments.
- Imaging and FNA are required.
- The goal of revision surgery is resection of all tumor deposits, which may not be possible without sacrificing a portion of facial nerve.
- Radiation is used in cases of widespread recurrence or multiple surgeries.

Alternative Management Plan

If surgery for a benign tumor is contraindicated owing to the patient's medical condition, the tumor may be observed; evaluation for radiation therapy may be considered in patients with malignant parotid neoplasms.

DISCUSSION

Evidence-Based Medicine Question

What factors influence decisions to sacrifice the facial nerve during superficial parotidectomy for malignant neoplasms?

A decision to resect the nerve is most easily made if preoperative paralysis is present. The decision is much more difficult if nerve function is normal. Given its low sensitivity (52%) in the case of suspicious and malignant lesions, FNA should not be used to determine the fate of a normally functioning facial nerve. Most reports support the concept that all efforts should be made to preserve the nerve. The exceptions—*of which the patient should be informed*—are encasement of the nerve by tumor, frozen section evidence of infiltration, or incomplete resection of gross tumor. Microscopically positive margins at the level of the nerve have been successfully eradicated with radiation therapy.

Editorial Comment

The concept of surgical excision of a parotid tumor is attributed to Bertrandi in 1802. The initial application of this surgery caused serious disfigurement and disability. John C. Warren was the first surgeon to resect a parotid tumor under ether anesthesia (Massachusetts General Hospital, 1846).

Codreanu, a Romanian surgeon, did the first total parotidectomy with facial nerve dissection in 1892. McWharten in 1917 described the surgical anatomy of the parotid gland as a bilobed structure, the interspace allowing for passage of the facial nerve.

W. E. Sistrunk of the Mayo Clinic wrote in 1921 that "surgery is the only means of curing a parotid tumor" and described a technique in which the facial nerve was identified and preserved. With the use of this technique only, permanent facial paralysis resulted in one of six patients. In 1934, Jones developed a surgical-anatomic technique for dissection and advocated isolation of the main trunk of the facial nerve with dissection carried forward so that that there would be less risk of injury to the peripheral branches of the facial nerve.

It was not until 1975 that the surgeons from the Mayo Clinic reported their results, comparing two series of cases that included 1360 primary parotid tumors. Local resection was used in the first 15-year period (1940–1954). In the second series (1955–1969) a superficial or total parotidectomy with identification and preservation of the facial nerve was carried out. The latter technique became the standard of care owing to the decreased incidence of both recurrence and facial nerve injury.

Parotidectomy is the quintessential head and neck operation requiring a mastery of the anatomy, traction and countertraction, use of surgical planes, meticulous hemostasis, and microneurosurgical techniques. Careful preoperative planning with imaging and, where appropriate, histology allow for the best surgical planning. In the event of nerve injury, the most skilled person should repair the nerve to allow for the best possible recovery.

Eugene N. Myers

Access the review questions and additional sources list online at http://www.expertconsult.com

REFERENCES

1. Xiao C, Zhan K, White-Gilbertson S, et al. Predictors of nodal metastasis in parotid malignancies. Otolaryngol Head Neck Surg 2015;154(1):121–130.
2. Britt C, Stein A, Patel P, et al. Incidental parotid neoplasms: pathology and prevalence. Otolaryngol Head Neck Surg 2015; 153(4):566–568.
3. Depowski P, Setzen G, Chui A, et al. Familial occurence of acinic cell carcinoma of the parotid gland. Arch Pathol Lab Med 1999;123(11):1118–1120.
4. Lam P, Kuribayashi A, Imaizumi A, et al. Differentiating benign and malignant salivary gland tumors: diagnostic criteria and the accuracy of dynamic contrast-enhanced MRI with high temporal resolution. Br J Radiol 2015;88(1049):1–11.
5. Zbaren P, Guelat D, Loosli H, et al. Parotid tumors: fine-needle aspiration and/or frozen section. Otol Head Neck Surg 2008; 139(6):811–815.
6. Johnson J, Myers E, Thearle P, et al. Antimicrobial prophylaxis for contaminated head and neck surgery. Laryngoscope 2015;125:275–280.
7. Nouraei S, Ismail Y, McLean N, et al. Surgical treatment of chronic parotid sialadenitis. J Laryngol Otol 2007;121:880–884.
8. Sharma R. Superficial parotidectomy for chronic parotid sialadenitis. Int J Oral Maxillofac Surg 2013;42:129–132.
9. Zhang D, Wang Y, Liang Q, et al. Endoscopic-assisted resection of benign tumors of the accessory parotid gland. J Oral Maxillofac Surg 2015;73(8):1499–1504.
10. Cristofaro M, Allegra E, Giudice A, et al. Pleomorphic adenoma of the parotid: extracapsular dissection compared with superficial parotidectomy—a 10 year retrospective cohort study. Sci World J 2014;564053:2014.

REVIEW QUESTIONS

1. Which structure lies medial to the facial nerve?
   a. Cartilaginous ear canal
   b. Mastoid tip
   c. Styloid process
   d. Posterior belly digastric

2. Which finding is most worrisome for a malignant parotid neoplasm?
   a. Fixation
   b. Pain
   c. Size greater than 4 cm
   d. Weakness of the temporal branch of the facial nerve

3. FNA indicates pleomorphic adenoma preoperatively. The patient undergoes successful superficial parotidectomy without complication but final pathology is carcinoma ex pleomorphic adenoma with close but negative margins. Which is NOT an appropriate course of action?
   a. Do revision surgery with resection of the normally functioning facial nerve.
   b. Perform a metastatic workup.
   c. Recommend close observation after multidisciplinary conference and review of all pathology and imaging results indicate no other disease.
   d. Perform neck dissection after abnormal PET scan and indeterminate lymph node FNA results.

ADDITIONAL SOURCES

Barbera R, Castillo F, D'Oleo C, et al. Superficial musculoaponeurotic system flap in partial parotidectomy and clinical and subclinical Frey's syndrome. Cosmeses and quality of life. Head Neck 2014;36(1):130–136.

Chen A, Garcia J, Bucci M, et al. The role of postoperative radiation therapy in carcinoma ex pleomorphic adenoma of the parotid. Int J Radiat Oncol Biol Phys 2007;67:138–143.

Cracchiolo J, Shaha A. Parotidectomy for parotid cancer. Otolaryngol Clin N Am 2016;49:415–424.

Lee Y, Park G, Lee J, et al. Prevalence and risk factors of sialocele formation after partial superficial parotidectomy: a multi-institutional analysis of 357 consecutive patients. Head Neck 2016;10:1–4.

Muhanna N, Peleg U, Schwartz Y, et al. Harmonic scalpel assisted superficial parotidectomy. Ann Otol Rhinol Laryngol 2014;123(9):636–640.

Vargas H, Galati L, Parnes S. A pilot study evaluating the treatment of postparotidectomy sialoceles with botulinum toxin. Arch Otolaryngol Head Neck Surg 2000;126(3):421–424.

93 Deep Lobe Parotidectomy

Andrew Tassler, Seungwon Kim

INTRODUCTION

The most common indication for surgery of the parotid gland is the presence of a mass or tumor. The majority of distinct parotid masses are neoplasms with benign tumors predominating. Pleomorphic adenoma (mixed tumor) and Warthin tumor (papillary cystadenoma lymphomatosum) account for the majority of benign lesions with adenomas and oncocytomas being encountered regularly.

Malignant tumors of the parotid gland represent a heterogeneous group of different pathologies with varying clinicopathologic characteristics.[1] Mucoepidermoid carcinoma is the most common malignancy found in the parotid gland with adenoid cystic carcinoma being encountered nearly as often. Other malignant tumors include acinic cell carcinoma, adenocarcinoma, salivary duct carcinoma, primary squamous cell carcinoma of the parotid gland, and carcinoma ex-pleomorphic adenoma. Nodal metastasis to intraparotid lymph nodes from skin cancers of the face and scalp are also seen with reasonable frequency; more rare are metastases from malignancies originating outside the head and neck with spread to the parotid.

Lymphoma can also present in the parotid gland and is more commonly seen in patients with chronic inflammatory disease of the parotid(s) such as Sjogren's syndrome.[2] The majority of parotid lymph nodes lie within the superficial lobe of the gland and thus are somewhat less germane to a discussion of deep lobe parotid lesions and surgery. However, in the management of a malignant tumor originating within the deep lobe, metastasis can occur that requires removal of the superficial gland as a means of lymphadenectomy.

Although it is decreasing in frequency, parotidectomy is also sometimes undertaken for chronic parotiditis. In instances of parotidectomy for chronic parotitis, the goal of the surgery is typically removal of all remaining parotid tissue, including the glandular tissue of the deep lobe. Other causes of swelling and possible masses of the parotid include congenital lesions such as first branchial cleft cysts and inflammatory conditions such as Sjogren's syndrome and sarcoidosis.

Any condition that can affect the superficial lobe of the parotid may affect the deep lobe as well, and despite modern imaging techniques and examination characteristics, the discovery of the relationship of a mass to the facial nerve often cannot be made until the time of surgery. Parotidectomy is a procedure that has standardized steps and a variable component that must be personalized at each operation while considering the pathology, location of the lesion, and patient-specific factors.

KEY OPERATIVE LEARNING POINTS

- Deep lobe parotidectomy is a procedure with both standardized steps and variable portions that should be tailored to the patient and his or her pathology.
- Preoperative imaging (computed tomography [CT] or magnetic resonance imaging [MRI]) is recommended for all suspected deep lobe parotid lesions, as it can provide useful information regarding the tumor and its relationship to critical structures.
- Facial nerve dissection and mobilization are likely to be necessary unless the tumor is purely parapharyngeal.
- Preoperative tissue sampling is recommended, as deep lobe malignancy often requires additional exposure with a mandibulotomy.
- The surgeon should have a low threshold for removal or division of structures such as the great auricular nerve, posterior belly of digastric muscle, or stylomandibular ligament to improve access and exposure.

PATIENT SELECTION/PREOPERATIVE PERIOD

Masses originating in the deep lobe of the parotid are typically either discovered by the presence of the mass on examination or found incidentally on cross-sectional imaging such as CT or MRI. Most benign tumors will present with minimal symptomatology related to the lesion except for the presence of the mass itself and possibly some mild discomfort. Significant or worsening pain, trismus, immobility of the lesion, skin change overlying the mass, and facial nerve weakness are all clinical signs that should raise the suspicion for malignancy. Given their anatomic location, however, benign tumors that arise in the deep lobe of the parotid may have decreased mobility on physical examination as compared to a mass in the superficial lobe or may not be readily palpable at all.

Palpable masses can be evaluated in similar fashion to a superficial parotid mass and are often first investigated with fine-needle aspiration (FNA) biopsy. Masses that are found incidentally are often not readily palpable, and FNA of the mass often needs to be done with image guidance such as ultrasound or CT. The necessity of obtaining FNA biopsy of parotid lesions prior to surgery is debatable and goes beyond the scope of this chapter focused on surgical planning and technique. We feel that the complication rate of FNA is so low and the potential information gathered from the FNA is often quite accurate in terms of differentiating between benign and malignant lesions that we favor performing this preoperatively whenever feasible. The information obtained from FNA can often allow more informed preoperative discussion with the patient and may also allow observation of likely benign lesions such as Warthin tumors in patients who are poor operative candidates.[3]

FNA of suspected deep lobe parotid masses can be more difficult than for superficial lesions and may require image guidance. Given the anatomic location of a deep lobe parotid tumor, however, information regarding potential malignancy may be of even greater value. Complete discussion regarding possible need for mandibulotomy, nerve manipulation or even nerve resection allows for informed consent prior to removal of a deep lobe mass worrisome for malignancy. Similar to with a superficial parotid tumor, we recommend wiating for either frozen section or final pathologic confirmation of parotid malignancy prior to resecting vital structures such as the facial nerve.

PREOPERATIVE PERIOD

1. History of present illness
   a. Presence of the mass—how discovered, how long present, growth
   b. Associated symptoms—pain, trismus, facial twitching, facial paralysis, or weakness

   c. Other head and neck symptoms—dysphagia, otalgia, aural fullness, decreased hearing, epistaxis, visual change, and voice change
   d. Constitutional/general symptoms—weight loss, fevers, chills, night sweats, and malaise
2. Past head and neck specific history
   a. Prior salivary gland surgery or infection
   b. Prior tobacco exposure (Warthin tumor)
   c. Prior head and neck cancer, prior radiation treatment including radioactive iodine
   d. Prior skin cancer of the head and neck region, primarily squamous cell carcinoma or melanoma
3. General medical history
   a. Comorbid conditions including autoimmune issues and sarcoidosis
   b. Cardiovascular health—prior pacemarker of automated implantable cardioverter defibrillator (AICD) - able to have MRI
   c. Medications/allergies—anticoagulants

Physical Examination

1. General appearance
   a. Obvious parotid/neck mass or asymmetry
   b. Facial weakness
   c. Voice change, that is, muffled
   d. Secretion management, airway obstruction
2. Complete examination of the head and neck with attention to areas noted below
3. Skin
   a. Worrisome or suspicious lesions of the facial skin or scalp—infiltration, ulceration, erythema, asymmetry, and melanotic lesions
4. Otologic
   a. Worrisome skin lesions of auricle or ear canal
   b. Middle ear effusion, possible parapharyngeal extension
5. Oral cavity/oropharynx
   a. Trismus
   b. Dentition/height of mandible if mandibulotomy possible
   c. Pharyngeal asymmetry, soft palate, tonsillar fossa, and lateral pharyngeal wall
6. Salivary glands/neck
   a. Palpable mass
   b. Size, mobility, and tenderness/firmness
   c. Borders of mass if palpable, apparent depth of extension, and relationship to angle of mandible
   d. Facial nerve function, upper and lower divisions, and weakness/twitching/paralysis
   e. Cervical adenopathy

Imaging

Cross-sectional imaging is recommended for tumors with possible deep lobe location. Imaging of a parotid mass provides information regarding both the possible location (superficial or deep lobe) and nature of the pathology (benign or malignant). Imaging landmarks that offer clues to the location of the facial nerve include the styloid and mastoid processes, the posterior belly of the digastric muscle, and the retromandibular vein. The vein is typically a superior extension of the external jugular vein (or occasionally the common facial vein) and can be identified by following the vein in an inferior to superior fashion in the axial plane. In a normal anatomic situation, the facial nerve and its branches will lie just superficial to the vein within the substance of the parotid gland; thus, the relationship of a parotid mass to the vein can be used to infer the relationship between the nerve and a mass. Given this, a deep lobe tumor will often displace the retromandibular vein laterally and superficially.

1. MRI with contrast
   a. Superior assessment of tumor, soft tissues, and possible perineural invasion
2. CT with contrast
   a. Best assessment of bone anatomy, mandible, mastoid, and styloid processes
3. Positron emission tomography (PET)/CT
   a. Fluorodeoxyglucose (FDG) avidity of salivary gland tumors can be unreliable. Positron emission tomography (PET)/CT is rarely needed but can be considered in cases of possible high-grade malignancy or other known malignancy where a parotid lesion may represent a metastasis or to be aware of lung metastasis as part of preoperative evaluation.

Indications

1. The treatment for parotid neoplasms is surgical excision.
2. The treatment of inflammatory conditions of the parotid is first management of the underlying inflammatory condition, but surgery may eventually be indicated for refractory cases.
3. Subtotal resection or biopsy of parotid lesions may be indicated if the likely diagnosis is a condition that is typically not treated surgically such as lymphoma or sarcoidosis.

Contraindications

1. Medical comorbidities that place the patient at high risk for general anesthesia particularly if imaging and FNA suggests a benign tumor

PREOPERATIVE PREPARATION

1. For tumors where the relationship to the facial nerve is not obvious from preoperative workup, surgical planning is similar to that for superficial parotidectomy.
2. Prepare for extended exposure/resection if necessary.

Operative Period

1. The procedure is almost universally performed under general anesthesia.
2. Long-term paralytic agents should be avoided.
3. Use of Electromyography (EMG) nerve monitoring in primary surgery is somewhat controversial and has not been shown to decrease the incidence of facial nerve weakness or injury.
4. The use of active monitoring in revision cases is more common and often aids in the identification of nerve branches in a previously operated field.

Monitoring

- Routine anesthesia monitoring
- Patient should not be given long-term paralytic to facilitate identification and preservation of the facial nerve and its branches

Instruments and Equipment to Have Available

- Monopolar and bipolar cautery; ultrasonic tissue device if desired
- Nerve stimulator
- Topical epinephrine on pledgets
- Standard for head and neck surgery set
  - Consider McCabe type dissector for fine nerve dissection.
- Saw and maxillofacial plating system if mandibulotomy considered
- Loupes or operating microscopes can be helpful.

Key Anatomic Landmarks

1. The parotid gland is located anterior and inferior to the ear lobule on either side of the face and is the largest of the major salivary glands in the body.
2. The superficial layer of the deep cervical fascia splits around the parotid gland and invests it in a fascial layer that anteriorly becomes continuous with the superficial musculoaponeurotic system (SMAS).
3. Posterior and inferior margins are the anterior border of the superior aspect of the sternocleidomastoid muscle.
4. The deep surface of the gland contacts multiple anatomic landmarks.
   a. The mastoid process of the temporal bone
   b. The external auditory canal
   c. The ascending ramus of the mandible and more inferiorly
   d. The posterior belly of the digastric and stylohyoid muscles
5. The facial nerve runs through the parotid gland with the majority of the glandular tissue (70% to 80%) lying superficial to the nerve.
6. The nerve exits the skull through the stylomastoid foramen and typically gives off small branches to the postauricular muscles and the posterior belly of the digastric prior to the more significant division into upper (temporofacial) and lower (cervicofacial) divisions at the pes anserinus.
7. The glandular tissue of the parotid gland is referred to as having both superficial and deep lobes, but there is no distinct anatomic, fascial, or compartmental delineation between the two lobes. Rather, the distinction between the two refers to relationship of the glandular tissue to the facial nerve and its branches.
8. The deep lobe of the parotid has three anatomic areas.
   a. The largest portion occupies the space deep to the facial nerve and between the mastoid process posterolaterally and the ramus of the mandible anteromedially. Tumors arising from this tissue typically displace the facial nerve and its branches in a lateral or superficial direction.
   b. Small portions of deep lobe parotid tissue also exist anteriorly between the distal facial nerve branches and the masseter muscle with deep lobe tumors in this location often clinically appearing more superficial than their true anatomic position.
   c. There is also a small amount of parotid tissue in the posterior inferior aspect of the deep lobe where the gland is connected to the parapharyngeal space via the stylomandibular tunnel. Tumors in this location may extend medially via the tunnel into the prestyloid parapharyngeal space.

Prerequisite Skills

- Superficial parotidectomy
- Parapharyngeal space surgery
- Neck dissection

Operative Risks

1. Facial weakness—more common following the often significant manipulation required for deep-lobe tumors
2. Hematoma—most hematomas can be monitored expectantly, but operative intervention is required for expanding hematoma with airway compromise
3. Seroma/sialocele—seromas and salivary leaks will almost universally resolve with either conservative management, serial aspiration, or a combination of the two
4. First bite syndrome—can be seen after dissection into the parapharyngeal space or with mobilization of the deep lobe of the parotid gland[4]

Surgical Technique

1. The patient should be prepped in a sterile fashion such that the entire face is visible for observation.
2. The entire ipsilateral neck should be prepped as well and if a wider exposure such as mandibulotomy is felt to be possible then the exposure should extend anteriorly across the midline.
3. A modified Blair type incision is typically designed, which begins anterior and superior to the tragal cartilage and extends inferiorly around the ear lobe.
4. Incisions
   a. For lesions located more posteriorly or superiorly, the inferior limb of the incision can be extended posteriorly from the ear lobe in a postauricular location.
   b. For more anteriorly located lesions and for the majority of most possible deep lobe masses the inferior aspect of the incision anteriorly into a transverse cervical component in a natural skin crease
   c. Small hash marks can be made perpendicular to the incision to aid in approximation of the skin at the conclusion of the case.
5. An anterior skin flap over the parotid fascia is developed.
6. The anterior border of the sternocleidomastoid muscle is then identified and fascial attachments are divided.
7. The great auricular nerve
   a. Typically the nerve divides into an anterior and posterior branch.
   b. The nerve and its branches can be preserved as felt to be feasible without compromising exposure.
   c. If the nerve is divided
      1) Divide the nerve in a sharp fashion using the cold knife technique.
      2) Bury the proximal end in the muscle to prevent formation of a potentially painful neuroma postoperatively.
   d. The external jugular vein typically lies approximately 1 cm anterior to the great auricular nerve and can often be preserved (but should be ligated if felt to be limiting exposure anteriorly).
8. With lateral retraction of the sternocleidomastoid muscle the posterior belly of the digastric muscle is then identified.
9. The pre-tragal tissues and the avascular plane between the parotid and tragal cartilage are developed and opened to the level of the pointer.
10. Bipolar electrocautery is used to divide the tail of the parotid using the tragal pointer and digastric levels as references.
11. Anatomic references for the facial nerve
    a. The tragal "pointer"
    b. The tympanomastoid suture line
    c. The posterior belly of the digastric muscle
12. For tumors felt to be in the deep lobe and in the region of the stylomastoid foramen itself the surgeon must be aware of the possibility of a laterally/superficially displaced main trunk of the facial nerve.
13. Hemostasis near the facial nerve
    a. Pressure
    b. Topical hemostatic agents (i.e., epinephrine)
    c. Well-placed surgical clips
    d. Judicious bipolar cautery
14. Facial nerve dissection
    a. Proceed along the facial nerve to expose the necessary branches for safe removal of the tumor or tissue in question.
    b. The branches in proximity to the tumor will often need to be fully dissected and released from the underlying

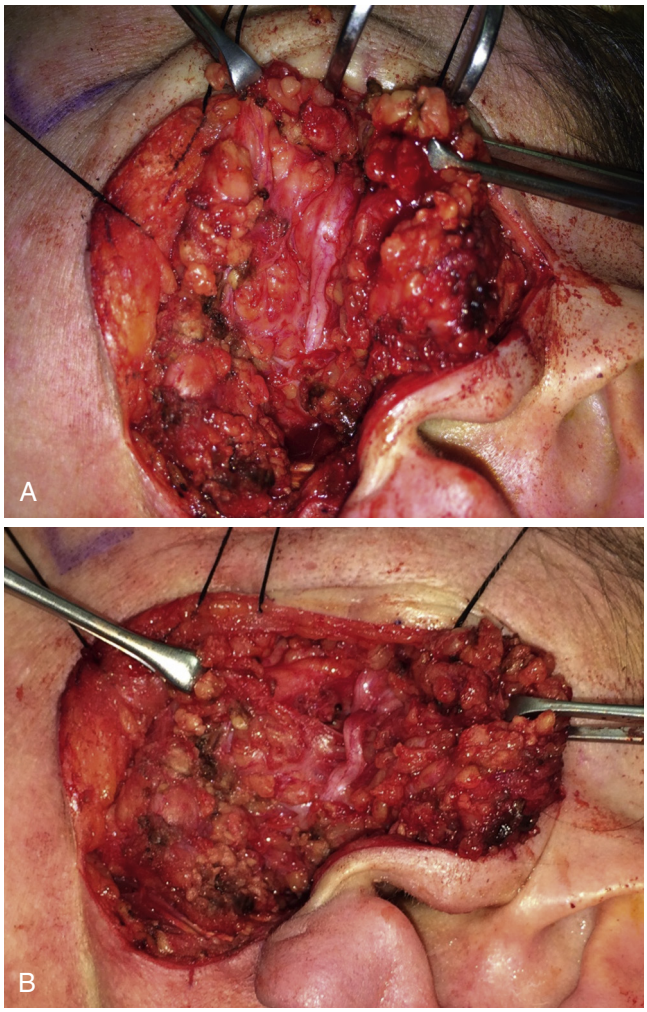

Fig. 93.1. Small left parotid tumor found incidentally on brain imaging. **A,** The tumor was found to be just deep to a main branch of the upper division of the facial nerve. **B,** The nerve was dissected free from the underlying tumor, and the tumor was removed. Pathology revealed a basal cell adenoma.

tissues to allow mobilization of the tumor (Fig. 93.1). Normal parotid tissue overlying the nerve branches can be divided with bipolar cautery, ultrasonic device, or even cold knife technique (Fig. 93.2).

c. The use of monopolar cautery to divide tissues over facial nerve branches is discouraged as this can transmit unwanted current to the nerve.

d. The superficial lobe tissue can often be released in a posterior to anterior fashion while remaining pedicled anteriorly.

15. Closure

If the mobilized superficial lobe has been preserved it can then be replaced providing an excellent cosmetic A suction drain is placed along the posterior digastric to avoid contact with the facial nerve and its branches.

Surgical Technique for Deep Lobe Tumor With Parapharyngeal Extension

As mentioned in the surgical anatomy section, tumors that arise from the posterior and inferior aspects of the deep lobe are positioned to extend medially into the parapharyngeal space and create so-called "dumbbell" tumors with the narrow portion being created by the limited space of the stylomandibular tunnel (Fig. 93.3—MRI of large dumbbell pleomorphic adenoma). While a purely parapharyngeal space tumor is most commonly approached via a transcervical approach without need for a transparotid component of the dissection, tumors involving both the deep lobe of the parotid and the parapharyngeal space usually require both parotid and cervical exposure and dissection.

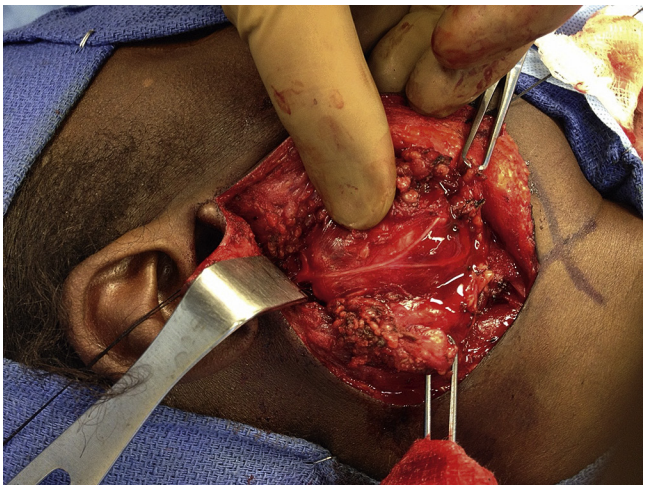

Fig. 93.2. Large pleomorphic adenoma found to be located in the deep lobe of the right parotid gland at the time of surgery. The main trunk of the facial nerve is just deep to the arm of the retractor with the tumor located deep to the lower division of the facial nerve. Note the superiorly and inferiorly based portions of the superficial lobe that are reapproximated after the procedure.

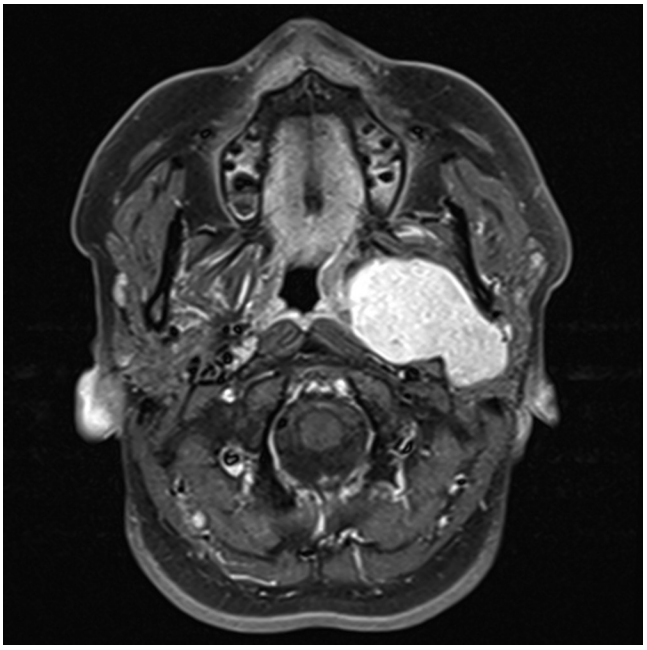

Fig. 93.3. Magnetic resonance image (contrast enhanced, axial T1 fat suppression) of dumbbell-shaped tumor of the deep parotid gland with parapharyngeal extension.

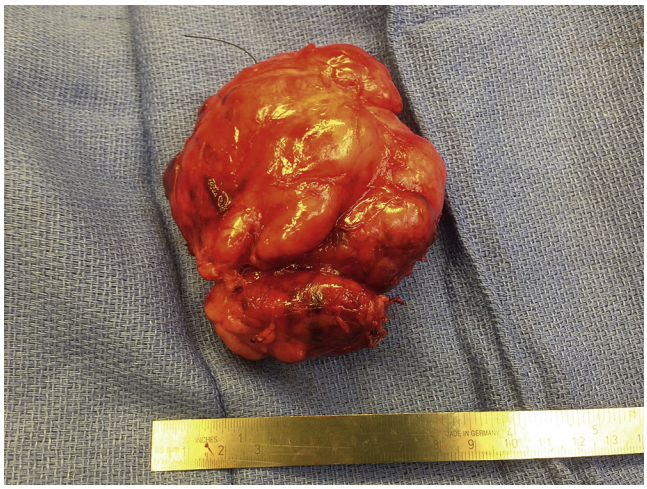

Fig. 93.4. Large epithelial/myoepithelial carcinoma of the deep lobe parotid and parapharyngeal space. The larger portion of the tumor (superior aspect of picture) was located in the parapharyngeal space with the imprint of the stylomandibular ligament showing the demarcation between the deep lobe and parapharyngeal components.

1. Similar initial approach to deep lobe tumor without parapharyngeal extension as above
2. Design incision with more anterior/cervical extension
3. Once the main trunk of the facial nerve is identified, palpation or visual inspection can often identify the deep lobe component of the tumor, and this should be gently freed as previously described.
4. The parapharyngeal component is then approached transcervically—skeletonize the posterior belly of the digastric muscle.
5. The submandibular gland can be left in situ or lateral vasculature (facial artery and vein) divided to allow medial displacement.
6. Inferior retraction on digastric reveals deep parotid and parapharyngeal space.
7. Maneuvers that aid in mobilization of the medial portion of the tumor
   a. Division of the posterior belly of the digastric muscle
      1) If division of the digastric is performed, this should be done at the medial ligamentous portion if reapproximation is to be considered as the divided muscle fibers will not be able to be approximated.
   b. Division of the stylomandibular ligament
   c. Application of medial to lateral pressure from the oropharynx (Fig. 93.4—deep lobe tumor with imprint of the stylomandibular ligament)

Malignant Tumors of the Deep Lobe

A complete review of the varying malignant salivary pathologies is beyond the scope of this chapter. A malignant tumor of the deep lobe parotid is managed in similar fashion to one of the superficial lobe; however, the anatomic location in the deep lobe often places the tumor in even closer proximity to the facial nerve and makes it more difficult to obtain a significant margin of normal surrounding tissue.

We routinely use frozen section of a resected tumor that can reliably differentiate between high-grade malignancy and tumors that are either benign or represent low-grade malignancy. If intraoperative findings are suggestive of a malignant tumor and facial nerve involvement is found, pathologic confirmation of malignancy is strongly suggested prior to nerve resection even if this requires waiting for final pathology. Even with confirmation of malignancy in patients with an intact functioning facial nerve preoperatively, every effort should be made to try to preserve continuity of the facial nerve.

Postoperative radiation therapy is indicated for parotid malignancy with high-grade features, positive margins, high T stage, and nodal involvement. Even with negative margin resection, pathologies such as adenoid cystic carcinoma benefit from postoperative radiation in achieving improved local control given their propensity for perineural invasion and local recurrence.

Common Errors in Technique

1. Poor patient selection in terms of adequacy of preoperative evaluation of pathologic extent on imaging and metastatic workup
2. Operating in the face of malignancy with perineural spread on multiple nerves not preoperatively assessed or not surgically resected
3. Failure to have clinical experience with a sufficient volume of surgical cases to comfortably approach deep lobe tumors
4. Resecting a facial nerve that could be preserved

POSTOPERATIVE PERIOD

Postoperative Care

The wound and the drain are monitored overnight, and the drain is typically removed on the first postoperative day unless the output is unexpectedly high (>100 cc total or >50 cc for the prior nursing shift).

Patients use topical antibiotic ointment such as bacitracin over the sutures for the first 3 to 5 days. Some patients will have an inflammatory reaction to common topical antibiotic ointments, and this should be considered if patients develop erythema of the surgical site postoperatively.

In a healthy, nonradiated patient, sutures can typically be removed approximately 1 week postoperatively. Patients are encouraged to massage the surgical site and the incision starting at 2 weeks postoperatively to soften the area and more rapidly disperse edema and lessen scar formation.

Outcomes, Prognosis

Long-term outcomes are related to the pathology being addressed surgically. For benign tumors of the deep lobe, complete excision is curative. Multiple case series regarding the excision of parotid pleomorphic adenomas demonstrate the long-term control of this tumor with close but negative margins. For malignant tumors of the deep lobe, outcome and prognosis are closely related to the specific pathology, grade of the tumor, and margin status.

Evidence-Based Medicine Question

Does greater auricular nerve preservation improve sensation?

Periauricular numbness is a common, sometimes the most common, complaint after parotidectomy. In studies that investigate the preservation of the posterior branch of the nerve, short-term improvement of sensation was better in the preservation group. In addition, there is long-term improvement in sensation, but the deficit is always greater than the normal unoperated side, and long-term quality of life data do not support preservation.

Editorial Comment

Deep lobe parotid tumors are decidedly uncommon related to superficial pathologies. Similar to many operations, complications are related to clinical volume. Deep lobe tumors should be managed, as discussed in this chapter, by high-volume salivary gland surgeons. When this is performed, even difficult but appropriate inflammatory and malignant lesions can be safely managed.

Stella E. Lee



Access the review questions and additional sources list online at http://www.expertconsult.com

REFERENCES

1. Lewis AG, Tong T, Maghami E. Diagnosis and management of malignant salivary gland tumors of the parotid gland. Otolaryngol Clin North Am 2016;49(2):343–380.
2. Shum JW, Emmerling M, Lubek JE, et al. Parotid lymphoma: a review of clinical presentation and management. Oral Surg Oral Med Oral Pathol Oral Radiol 2014;118(1):e1–5.
3. Liu CC, Jethwa AR, Khariwala SS, et al. Sensitivity, specificity, and posttest probability of parotid fine-needle aspiration: a systematic review and meta-analysis. Otolaryngol Head Neck Surg 2016;154(1):9–23.
4. Linkov G, Morris LG, Shah JP, et al. First bite syndrome: incidence, risk factors, treatment, and outcomes. Laryngoscope 2012;122(8):1773–1778.

REVIEW QUESTIONS

1. Deep lobe parotid tumors do which of the following?
   a. Usually present as a facial paralysis
   b. Usually turn out to be malignant
   c. Frequently are discovered incidentally on imaging for other indications
   d. Are never palpable

2. Surgery on the deep lobe tumor can sometimes be enabled by all of the following, except
   a. Division of the digastric muscle
   b. Division of the stylomandibular ligament
   c. Medial to lateral pressure applied intraorally
   d. Mastoidectomy

ADDITIONAL SOURCES

Grammatica A, Perotti P, Mancini F, et al. Great auricular nerve preservation in parotid gland surgery: long-term outcomes. Laryngoscope 2015;125:1107–1112.

Guntinas-Lichius O, Klussmann JP, Wittekindt C. Parotidectomy for benign parotid disease at a university teaching hospital: outcome of 963 operations. Laryngoscope 2006;116(4):535–540.

94 Office-Based Diagnosis of Sinonasal Disorders

*Berrylin J. Ferguson**

INTRODUCTION

Nasal endoscopy is integral to the physical examination of patients with sinonasal symptoms seeking management from the otolaryngologist. With proper local decongestion and anesthesia, it is possible to obtain excellent visualization of the nasal mucosal lining, middle meatus, inferior meatus, sphenoethmoid recess, olfactory cleft, turbinates, septum, and nasopharynx with minimal discomfort to the patient.

Anesthesia is accomplished with a variety of techniques, including atomizers using disposable nasal tips with the topical anesthetics 4% lidocaine or 2% tetracaine. Frequently a topical decongestant, such as oxymetazoline 0.05%, is added. These agents may also be used on cotton pledgets that are placed in the nose for 5 to 10 minutes until decongestion and anesthesia are achieved.

The examination is facilitated if there is access to small-caliber endoscopes, such as the 2.9-mm rigid Hopkins telescope (Fig. 94.1). A 30-degree endoscope is typically most useful for office-based diagnosis of sinonasal disease. For patients who have had sinus surgery, a 70-degree endoscope can be helpful to visualize the frontal and maxillary sinuses. A video camera and high-definition monitors are a critical part of visualizing the examination. Video documentation with archiving can be helpful in monitoring the patient's progress over time.

The following discussions (and accompanying videos) highlight some of the common disorders encountered in endoscopic diagnosis of the nose and sinuses.

KEY OPERATIVE LEARNING POINTS

1. Nasal endoscopy should be performed in a standardized manner and include examination of the nasal mucosal lining, middle meatus, inferior meatus, sphenoethmoid recess, olfactory cleft, turbinates, septum, and nasopharynx.
2. Failure to inspect the nasopharynx will lead to inability to diagnose common disorders that mimic sinusitis (i.e., Thornwaldt cysts, hypertrophic adenoid tissue or tumors).
3. In addition to anatomic description, the diagnostic examination evaluates the presence of mucopurulent drainage, presence of polyps, masses, and characteristics of the sinonasal mucosal lining.
4. Vasculitic diseases should be considered if the mucosa is abraded or bleeding (i.e., granulomatosis with polyangiitis [GPA], formerly known as Wegener granulomatosis), as well as cocaine or intranasal opioid abuse.
5. Sarcoidosis can present with cobblestone appearance of the mucosa with inflammation and edema refractory to decongestion.
6. If the mucus is tenacious and appears to contain eosinophil by-products, send it for fungal cultures and stains to evaluate for possible allergic fungal sinusitis.
7. Endoscopically obtained cultures can help to direct antibiotic therapy.

History

1. History of present illness
   a. Determine symptoms that are most troublesome to the patient in order to best direct therapeutic recommendations.
   b. Patients with suspected chronic rhinosinusitis (CRS) should be questioned regarding symptoms of nasal obstruction, discolored drainage, facial pain/pressure, and loss of the sense of smell.
      1) Antibiotic and steroid treatment
      2) Imaging, if available
      3) Allergic rhinitis symptoms and, if positive, history of allergy testing and treatment
      4) Past surgical procedures, specifically endoscopic sinus surgery (ESS)
2. Past medical history
3. Social history
   a. Patients with allergic rhinitis should be asked about environmental exposures at work and home
   b. Occupation
   c. Tobacco history
4. Family history
   a. Allergic rhinitis
   b. Asthma
   c. Nasal polyposis or cystic fibrosis

Physical Examination

1. Proper topical decongestion and anesthetic should be administered before nasal endoscopy.
2. A 30-degree Hopkins endoscope can be used to visualize all key landmarks in patients who have not had ESS. A 70-degree endoscope is helpful to visualize the frontal sinus osteum and the maxillary sinus in patients who have had ESS.
   a. First pass along the middle meatus with the endoscope angled at the 4-o'clock position. The light source can then be angled superiorly to visualize the olfactory cleft.
   b. Second pass visualizing the inferior meatus with the endoscope angled at 6-o'clock position and then toward the nasopharynx, passing the scope medial to the inferior turbinate. The light source can then be angled superiorly to visualize the sphenoethmoid recess superiorly.
3. Examination of the cranial nerves can help to evaluate patients suspected of a sinonasal malignancy or a granulomatous process.

*deceased



Fig. 94.1. A 2.9-mm 30-degree Hopkins telescope can be useful in performing a complete nasal endoscopy with minimal discomfort to the patient, especially in patients who have not had sinus surgery.

Imaging

Maxillofacial computed tomography (CT) scan is indicated in patients suspected of having the following:

1. CRS
2. Nasal polyposis
3. Unilateral sinusitis
4. Concern for malignancy
5. Cerebrospinal fluid (CSF) rhinorrhea and associated skull base defect

Indications

Diagnostic nasal endoscopy is indicated in patients suspected of the following:

1. Symptoms suggestive of CRS with or without polyposis
2. Acute bacterial rhinosinusitis
3. Unilateral symptoms
4. Concern for malignancy

Contraindications

1. Patients unable to tolerate rigid endoscopy; rare if adequate topical decongestion and anesthetic is used
2. Patients with hereditary hemorrhagic telangiectasia (HHT) require caution when performing endoscopy and if actively bleeding or with packing in place; endoscopy and control of epistaxis is best done in the operating room.

Preoperative Preparation

1. Topical anesthesia and decongestion should be administered before endoscopy (see section on Anesthesia).
2. Patients should be positioned appropriately for endoscopy (see section on Positioning).
3. Maxillofacial CT scan should be performed for patients with CRS, nasal polyposis, unilateral disease, CSF rhinorrhea/skull base defect, or any patient with concern for malignancy.
4. It is helpful to turn off the overhead lights for optimal visualization of the monitor during the procedure.

Anesthesia

1. Topical anesthesia can be accomplished with 4% lidocaine either via atomization into the nasal cavities or on pledgets.
2. Use of 2% tetracaine can be helpful in patients who require in-office procedure, débridement, or inadequate anesthesia with topical lidocaine.
3. Oxymetazoline is commonly added to the topical anesthetic to provide concomitant mucosal decongestion.

Positioning

Seated and reclined if possible with the patient head turned facing the physician. The patient, the screen, and the physician should be coaxial.

Perioperative Antibiotic Prophylaxis

None necessary

Monitoring

None necessary

Instruments and Equipment to Have Available

1. Hopkins telescopes: 0-, 30-, 70-degree endoscopes. The 30-degree endoscope is the most popular scope, and, if available, a 2.9-mm scope allows for improved visualization of the sphenoethmoid recess and nasopharynx with minimal discomfort to the patient.
2. Flexible endoscope for patients who cannot tolerate rigid endoscopy or when the floor or anterior wall of the maxillary sinus cannot be fully examined with a rigid endoscope.
3. Topical decongestant and anesthetic. We prefer 4% lidocaine with oxymetazoline either on pledgets or via an atomizer. For patients who require débridement, biopsy, or in-office procedures, 2% tetracaine is preferred. The window of toxicity with tetracaine should be considered, with the use of doses not to exceed 100 mg.[1]

KEY ANATOMIC LANDMARKS

1. Middle meatus
2. Sphenoethmoid recess
3. Nasopharynx
4. Inferior meatus
5. For patients who have had functional ESS (FESS), visualization of all sinus cavities should be performed.

Prerequisite Skills

1. Appropriate use of the rigid nasal endoscope to visualize key anatomic landmarks
2. Flexible laryngoscopy

Operative Risks

1. Epistaxis
2. Vasovagal episode

Surgical Technique

Allergic Rhinitis (Video 94.1)

1. After administration of topical decongestion and anesthetic, a 30-degree endoscope is used to examine the patient's nasal cavities.

2. The middle meatus is examined bilaterally to demonstrate the absence of polyps or mucopurulence. The nasopharynx appears clear.
3. Polypoid middle turbinates can be an indication of allergic rhinitis.
4. History should direct whether patients should undergo allergy testing. In this example, a 33-year-old male presented with bilateral nasal congestion with seasonal exacerbation in the spring and summer. Skin testing was positive for dust mite, cat, dog, Bermuda grass, Timothy grass, oak tree, and maple tree.
5. Typically in allergic rhinitis, turbinates have a pale edematous appearance. Erythematous mucosa suggests other etiologies, such as exposure to tobacco smoke, irritants, rhinitis medicamentosa, or food allergy.

Rhinitis Medicamentosa (Video 94.2)

1. This patient had been using oxymetazoline 2 or 3 times a day for several months.
2. Note the upregulation of seromucinous glands characterized as "cobblestoning" along the septum and the inferior turbinate.
3. The mucosa is typically erythematous and friable. Septal perforations can also be seen in patients with chronic use of a topical decongestant spray.

Acute Bacterial Rhinosinusitis With Endoscopically Directed Middle Meatal Culture (Video 94.3)

1. Patients presenting with mucopurulent drainage benefit from having an endoscopically directed culture obtained to facilitate decision making for antibiotic therapy.
2. Maxillary sinus taps (MSTs) have largely fallen out of favor as a preferred method for obtaining culture data.
3. A Calgi swab is bent at a 30-degree angle at the tip and followed to the middle meatus with a 30-degree endoscope. A 0-degree endoscope can be used if visualization is adequate.
4. The culture swab is inserted carefully so as not to contaminate it with bacteria from the nasal vestibule.
5. Typically, aerobic cultures only are necessary. For suspected odontogenic infections, anaerobic cultures are indicated.

Maxillary Sinus Tap in Acute Bacterial Sinusitis (Video 94.4)

1. This procedure is rarely needed due to endoscopic approaches that can be performed in the operating room or with balloon dilation techniques in the office for patients who cannot tolerate general anesthesia. Unilateral maxillary sinusitis should also raise the concern for an odontogenic source or obstructive mass. Imaging should be conducted prior to instrumentation of the sinus. In this case of acute bacterial sinusitis, the nasal cavity is first anesthetized for an MST.
2. A cotton pledget with 4% Xylocaine and a few drops of epinephrine 1:1000 is placed into the nasal cavity.
3. After a few minutes, when the mucosa is partially decongested and anesthetized, this pledget is removed and a second pledget is placed under the inferior turbinate into the inferior meatus.
4. An ear curette is useful in positioning the pledget under the inferior turbinate. After this pledget has been in place for approximately 5 to 10 minutes, it is removed and 0.5 to 1 mL of 1% Xylocaine with 1:100,000 epinephrine is injected into the mucosa of the inferior meatus using a 1.5-inch long 25-gauge needle. This is usually painless after the topical anesthetic has been in place for 5 to 10 minutes.
5. Anesthetizing the inferior turbinate allows one to painlessly medialize the inferior turbinate, if needed, in the placement of either a 16- to 18-gauge spinal needle or a commercial antral tap trocar.
6. The antral tap trocar or needle is introduced through the thin bone in the lateral inferior meatus into the maxillary sinus. The bone is usually thin and easiest to penetrate in the superior lateral aspects of the inferior meatus.
7. Occasionally, very thick bone or nasal anatomy precludes inferior meatal antral tap. After the needle or trocar is introduced through the bone into the sinus, the trocar is removed and the purulent exudate is aspirated from the maxillary sinus with a syringe.
8. The aspirated specimen obtained is sent for Gram stain and aerobic and anaerobic cultures. Depending on the circumstances, such as in an immunocompromised patient or fungal sinusitis, fungal cultures should be obtained.
9. After the culture specimen is obtained, the sinus can be irrigated. If the sinus tap is free of secretions, then a small amount of sterile saline is introduced into the maxillary sinus and re-aspirated.
10. To irrigate the sinus, the patient is given a basin and asked to lean forward while the sinus is gently irrigated with 10 to 50 mL of sterile saline. If the procedure is uncomfortable to the patient, it should be stopped because sometimes the outflow tract of the sinus is obstructed with edema, preventing fluid egress.
11. MST and irrigation can be not only diagnostic but also therapeutic. At the end of the irrigation, air is usually introduced into the sinus cavity. Topical antibiotics can also be introduced, if desired.

Chronic Bacterial Sinusitis With Biofilm (Video 94.5)

1. Occasionally, patients' sinus infections are refractory to both surgical and medical intervention.
2. The biofilm is readily apparent in this patient by rigid endoscopy with a 30-degree endoscope.
3. Patients with stenotic sinuses or purulence along the floor or anterior aspect of the sinus may require flexible fiberoptic examination for visualization and diagnosis.
4. Cultures of the purulent exudate can be obtained, and irrigation can be performed.
5. A 3-mm curved suction facilitates aspiration and irrigation of the sinus.

Complete Internal and External Nasal Valve Collapse With Inspiration (Video 94.6)

1. This patient demonstrates collapse of the nasal valve with inspiration, due to lack of support from the lower lateral cartilages.
2. Surgery of the septum and the inferior turbinates would not successfully resolve this situation.
3. The condition was treated with cartilage battens added to the lower lateral cartilages to strengthen them to prevent closure with inspiration.
4. The more rapidly a patient inspires, the more vigorous the closure of the nasal valve. This is due to the Bernoulli effect of a vacuum produced by increased velocity of the inspired air.
5. Patients who complain of nasal obstruction and in whom no site of obstruction is detected on physical examination with the nasal speculum should be evaluated for nasal valve collapse.

Anterior Epistaxis (Video 94.7)

1. Epistaxis commonly occurs from the anterior nasal septum, often called Little area or Kiesselbach plexus.
2. In such a patient, the nasal cavity should be decongested and anesthetized with topical tetracaine 2% and oxymetazoline.
3. If the nose is actively bleeding, the source should be identified if possible and selectively cauterized with silver nitrate.
4. Opposing areas of the septum should not be cauterized, due to the risk of septal perforation.
5. Telangiectasias can also be a source of significant bleeding, often only visible as a 1- to 3-mm domelike lesion.
6. If gently touched with the silver nitrate stick, brisk bleeding will often then occur, identifying this as the source of epistaxis. Usually this is successfully treated with cauterization.

Septal Perforation With Placement of Nasal Septal Button (Video 94.8)

1. Symptomatic perforation bleeding and crusting can often be controlled with the placement of a Silastic septal button.
2. Septal buttons are commercially available through several manufacturers and are available in different sizes.
3. The septal perforation should first be measured, and then the button should be fashioned to fit the defect. Most perforations are not perfectly round but oval shaped, and therefore care should be taken to trim the button to the appropriate shape.
4. The nasal cavity is first anesthetized, and then, using the endoscope or a headlight for visualization, the button is introduced into the nose on one side.
5. The flange is extracted through the contralateral side, and then the button is positioned to optimally span the perforation.
6. Placement of a water-soluble antibiotic ointment to the nasal cavity daily may delay the formation of a bacterial biofilm.
7. However, crusting along the button may require removal. At this point the perforation may be sufficiently mucosalized, so there is no further bleeding or crusting.

Atrophic Rhinitis (Video 94.9)

1. Atrophic rhinitis is commonly caused by *Klebsiella ozaenae*, but other bacteria may be responsible.
2. *Citrobacter koseri* was cultured from this 80-year-old Cambodian woman with a 1-year history of a foul smell from her nose.
3. The nasal cavities can be débrided using Tobey forceps and using a 0- or 30-degree endoscope.
4. After extensive débridement of her nasal cavity, initiation of topical antibiotics directed toward the pathogen (gentamicin 80 mg per 500 mL of saline with 20-mL irrigations twice a day), and after several months of an oral fluoroquinolone, the patient's foul-smelling crusting resolved.

Eosinophilic Mucin Rhinosinusitis (Video 94.10)

1. Patients with refractory CRS with polyposis often present with eosinophilic mucin, as shown in this video.
2. This patient's evaluation via culture and pathology did not exhibit a bacterial or fungal etiology. Note the tenacity of the mucous secretions, which often show copious eosinophils and Charcot-Leyden crystals on pathology.
3. If the mucin is filling the sinus, local irrigation can help with removal of the tenacious secretions.
4. The mucin should be sent for histopathologic evaluation for the presence of fungi. Hyphae present in eosinophilic mucin in conjunction with elevated immunoglobulin E (IgE) to the cultured fungus are diagnostic of allergic fungal rhinosinusitis.
5. An attempt should be made to remove all eosinophilic mucin, if possible, to help to remove the source of inflammation and allow for effective topical therapy.

Chronic Rhinosinusitis With Polyposis and In-Office Polypectomy (Videos 94.11)

1. Patients with CRS have symptoms at least 12 weeks or longer of nasal obstruction, discolored drainage, facial pain/pressure, and diminished sense of smell.
2. Nasal endoscopy helps to confirm the diagnosis by determining whether the patient has polyps in the nasal cavity or the middle meatus or purulent mucous/edema in the middle meatus or anterior ethmoid area. Radiographic imaging showing inflammation can also confirm the diagnosis of CRS when endoscopy is normal and patients present with the symptoms described.
3. This patient's endoscopy (see Video 94.11) demonstrates polyps completely filling the nasal cavities. Unilateral polyps are concerning for tumor or possible encephalocele.
4. Polyps can be debulked in the office for appropriately selected patients who have nasal obstruction, are not appropriate candidates for general anesthesia, or who do not wish to undergo sinus surgery. Appropriate preparation as followed for FESS is applicable, including discontinuation of anticoagulation and pretreatment and posttreatment with oral steroids.

Sarcoidosis

1. A disorder of exclusion and of unclear etiology but assumed to be a reaction to a variety of antigens that induce noncaseating granulomas in the nose, skin, and lungs particularly but also other organ systems
2. This patient presented with cutaneous manifestations, as well as significant nasal crusting and inflammation as shown in this video.
3. *Staphylococcus aureus* is commonly cultured from these patients, and, with appropriate immunomodulatory therapy, topical steroids, and culture-directed antibiotics, patients can have improvement in their symptoms, as shown in the second endoscopic examination.
4. Sarcoidosis may be localized to the nose and have a remitting or active course. Systemic involvement without adequate diagnosis and treatment can be fatal.
5. On endoscopic examination of the nasal cavity, sarcoidosis should be suspected when the septal mucosa appears cobblestoned, reflecting very small collections of lymphocytes and submucosal granulomas. Crusting and mucopurulent secretions can also be seen.
6. Biopsy of the affected nasal lining can facilitate the diagnosis.

Granulomatosis With Polyangiitis, Formerly Referred to as Wegener Granulomatosis

1. A systemic disorder that is a form of vasculitis characterized by both granulomas and polyangiitis and if untreated has a high mortality rate secondary to pulmonary and renal damage
2. Patients often present with serous otitis media, as demonstrated in this video, as well as significant nasal inflammation

with a friable lining and mucopurulent exudate present on nasal endoscopy.
3. After being appropriately treated with immunomodulator therapy, topical steroids, and culture-directed antibiotics, the patient can have reasonable control of disease, as shown in the subsequent nasal endoscopies.
4. The course is often one of remission and relapse. Early relapse can be suspected by return of nasal bleeding and excoriations, as well as evaluation of anti-neutrophil cytoplasmic antibody serology.
5. Biopsy of the affected nasal lining can facilitate the diagnosis.

Inverted Papilloma

1. The most common benign tumor of the nasal cavity, inverted papilloma, should be suspected with unilateral polypoid lesions and unilateral sinusitis.
2. Biopsy can be performed in the office, but a maxillofacial CT scan should be performed to rule out skull base dehiscence or other pathology.
3. The site of suspected inverted papilloma is first injected with 1% lidocaine with epinephrine 1:100,000, and the cup biopsy forceps are used to obtain the biopsy.
4. Localized bleeding can be controlled with oxymetazoline on pledgets.

Cicatricial Pemphigoid

1. In this patient with cicatricial pemphigoid, complete restenosis of the right side of her nose is seen and well over 50% restenosis of the left side despite several prior surgical procedures.
2. The left side of her nose is kept patent only with the insertion of a stent, which is only removed for cleaning and then is reinserted.

Common Errors in Technique

1. Inadequate decongestion and anesthesia leading to incomplete endoscopic examination
2. Improper positioning
3. Instrumentation and endoscope should move in tandem, and typically the instrument should be below the endoscope to allow for proper visualization.

Postoperative Management

1. Patients who undergo procedures in the office are advised to avoid nose blowing or strenuous activity.
2. Appropriate use of topical analgesics should eliminate the need for opioid medications.

Complications

1. Epistaxis can occur in patients with inadvertent abrasions to the mucosa during nasal endoscopy or in-office procedures.
2. Vasovagal episodes

Alternative Management Plan

1. Flexible endoscopy may be necessary in patients who cannot tolerate rigid endoscopy.
2. Management in the operating room for patients who require extensive débridement, extensive polypectomy, biopsy, control of epistaxis, or other procedures that would be difficult to accomplish in the office due to patient discomfort and equipment needs

DISCUSSION

A large number of disorders can present with sinonasal manifestations, and therefore a careful history and a comprehensive physical examination, often including nasal endoscopy, are necessary. Patients often describe such symptoms as nasal congestion, facial pressure, and postnasal drainage that are quite common but may not correlate with objective findings.[2]

Nasal endoscopy is an important skill in the armamentarium of the otolaryngologist to accurately diagnose and treat patients with sinonasal disorders. Diagnostic nasal endoscopy can be facilitated by using adequate decongestion and topical anesthetic. We prefer to use 4% lidocaine with oxymetazoline on cotton pledgets and 2% tetracaine as an alternative to lidocaine in patients who require procedures including débridement post FESS.

A 2.9-mm endoscope is useful in patients who have not had prior surgery in order to obtain a comprehensive examination with minimal discomfort to the patient. Typically, a 30-degree endoscope is most useful for diagnostic nasal endoscopy and angled telescopes, such as the 45- and 70-degree endoscopes, to examine the maxillary and frontal sinuses in patients who have had prior surgery.

The most common procedures performed in-office include biopsies, control of epistaxis, endoscopically directed cultures, and, in appropriately selected patients, polypectomy, placement of septal buttons, and inferior turbinate reduction. With appropriate decongestion and topical anesthesia, these procedures can be successfully performed. However, patient selection is key in determining their tolerance for an in-office procedure, and expectations should be fully discussed with the patient. Balloon dilation has recently emerged as an in-office procedure, but indications and patient selection need further clarification (see Chapter 10).

Maxillofacial CT scan is also a useful adjunct in patients in which CRS or recurrent acute rhinosinusitis is suspected but nasal endoscopy is negative. Patients with suspected tumors or unilateral disease also merit undergoing maxillofacial CT.[2] Odontogenic sinusitis is commonly missed, and careful attention to the dentition on imaging is important in making an accurate diagnosis.

Office-based diagnosis of sinonasal disorders is facilitated by a comprehensive history in conjunction with a complete physical examination, often including diagnostic nasal endoscopy. Validated symptom surveys can be a useful tool to assess and follow patients over time, as well as determine outcome from interventions. Often patients with sinonasal symptoms present with a disorder that impacts their quality of life, and as a result it is paramount to tailor interventions that are balanced with the severity of patient symptomatology, as well as provide a thoughtful dialogue on the role of medical management in chronic conditions.

Evidence-Based Medicine Question

Is MST comparable to endoscopically directed cultures to obtain an accurate result to diagnose and treat rhinosinusitis?

Endoscopically directed middle meatal (EDDM) culture has shown to be highly sensitive and accurate. A meta-analysis comparing MST to EDDM culture showed that EDMM had a sensitivity of 80.9%, specificity of 90.5%, positive predictive value of 82.6%, a negative predictive value of 89.4%, and an overall accuracy of 87.0%.[3] The authors concluded that EDMM may be a more sensitive culture method for diagnosis of pathogenic bacteria in acute bacterial rhinosinusitis and therefore preferred over MST.

Editorial Comment

This chapter provides an updated approach to in-office diagnosis of patients presenting with sinonasal symptoms, the etiologies of which can range from common allergic rhinitis to rare but critical to diagnose disorders, such as sarcoidosis and GPA. BJ Ferguson was a thought leader in the field of rhinology and contributed important insights and practical guidance in the management of patients with these chronic disorders. She passed away during the writing of this chapter, and an attempt was made to best capture her insights in the completion of this work. Most important is the tailored management approach to patients and continuation of the conversation with patients regarding sinonasal disorders, which are often chronic and require thoughtful ongoing medical management.

Stella E. Lee


Access the review questions and additional sources list online at http://www.expertconsult.com

REFERENCES

1. Saif AM, Farboud A, Delfosse E, et al. Assessing the safety and efficacy of drugs used in preparing the nose for diagnostic and therapeutic procedures: a systematic review. Clin Otolaryngol 2016;41(5):546–563.
2. Orlandi RR, Kingdom TT, Hwang PH, et al. International consensus statement on allergy and rhinology: rhinosinusitis. Int Forum Allergy Rhinol 2016;6(Suppl. 1):S22–09.
3. Benninger MS, Payne SC, Ferguson BJ, et al. Endoscopically directed middle meatal cultures versus maxillary sinus taps in acute bacterial maxillary rhinosinusitis: a meta-analysis. Otolaryngol Head Neck Surg 2006;134(1):3–9.

REVIEW QUESTIONS

1. A 42-year-old woman presents with uveitis, cough, and chronic nasal obstruction with crusting. Endoscopic evaluation reveals a cobblestone appearance and thickening of the nasal mucosal lining. What is the most likely diagnosis?
   a. Granulomatosis with polyangiitis
   b. Allergic fungal rhinosinusitis
   c. Sarcoidosis
   d. Allergic rhinitis

2. Patients with allergic rhinitis have characteristic findings of which of the following on endoscopy?
   a. Mucopurulence
   b. Polypoid middle turbinate
   c. Erythematous friable lining
   d. Telangiectasias

3. A 33-year-old man with cough, frequent epistaxis, and friable lining on endoscopy with enlarged blood vessels should be suspected of having which of the following disorders?
   a. Allergic fungal rhinosinusitis
   b. Nasal polyposis
   c. Granulomatosis with polyangiitis
   d. Cicatricial pemphigoid

4. Frequent and long-term use of oxymetazoline may lead to which of the following endoscopic findings?
   a. Nasal polyposis
   b. Erythematous nasal mucosal lining with inflammation
   c. Pale boggy inferior turbinates
   d. Telangiectasias

5. Allergic fungal rhinosinusitis is usually associated with which of the following endoscopic findings?
   a. Thin, watery drainage
   b. Tenacious thick eosinophilic mucin
   c. Telangiectasias
   d. Cobblestoning of the septum

ADDITIONAL SOURCES

Rosenfeld RM, Piccirillo JF, Chandrasekhar SS, et al. Clinical practice guideline (update): adult sinusitis. Otolaryngol Head Neck Surg 2015;152(Suppl. 2):S1–39.

Seidman MD, Gurgel RK, Lin SY, et al. Clinical practice guideline: allergic rhinitis. Otolaryngol Head Neck Surg 2015;152(Suppl. 1):S1–43.

95 Septoplasty—Classic and Endoscopic

Grant S. Gillman, Stella E. Lee

INTRODUCTION

The most common structural cause of persistent nasal obstruction unresponsive to nasal decongestants or medical therapy is a deformity of the nasal septum.

Septal deformities may be cartilaginous, bony, or both, with tilts to the septum, curves, spurs, twists, angulations, telescoping segments, or any combination thereof. A septal deviation can be observed within a nasal framework that is straight externally, crooked, twisted, or collapsed and with compromise at the internal nasal valve, the external nasal valve, both, or neither. One must realize, therefore, that there is no single operation that will remedy all septal deviations and that some may in fact require application of more complex functional rhinoplasty techniques. In all cases, astute evaluation and flexibility in technique are the essential foundation for improved outcomes.

In this chapter we endeavor to provide guidance for the more basic or routine deformities and correction via classic (endonasal) and endoscopic approaches. The techniques of endoscopic septoplasty can be useful in addition to classical endonasal techniques, especially in patients who also require concomitant endoscopic sinus surgery. Endoscopic septoplasty can provide excellent visualization of the anatomy and can be successfully incorporated into the existing armamentarium of the endoscopic sinus surgeon. This chapter also provides recommendations on how to identify deformities that warrant more advanced surgical intervention to minimize failure and maximize success rates.

KEY OPERATIVE LEARNING POINTS

1. Elevation of the mucosal flaps in the correct plane is crucial for performing the procedure with the classical endonasal or endoscopic technique.
2. Careful dissection through grooves and around angles or spurs will minimize the risk of mucosal tears and possible septal perforation. To whatever extent is possible, mucosal tears should be repaired when quilting the septal flaps at the end of the procedure.
3. Preoperatively and intraoperatively, attention should be focused specifically at the common sites of failure: curvatures within the dorsal septal strut and caudal septal deviations. Deviations within these areas can be subtle but nonetheless have a significant impact on airflow secondary to high resistance in these areas (the internal and external nasal valves).
4. With the endoscopic approach:
   a. Once the flap is elevated appropriately, it is helpful to keep an instrument or scope in the plane of dissection to facilitate visualization and limit manipulation of the flap.
   b. The axilla of the middle turbinate should be visualized bilaterally once the deviation has been corrected to allow for appropriate access, especially if frontal sinus surgery is necessary.

PREOPERATIVE PERIOD

History

1. History of present illness
   a. Most troublesome symptoms: This helps in direct counseling and expectations of what surgery can and cannot achieve.
   b. Duration of obstruction
   c. Laterality, if any: Most often, symptoms will be worse on one side, but S-shaped septal deflections can compromise both sides of the nasal airway.
   d. Specific symptoms: Nasal obstruction, hyposmia, epistaxis, facial pressure/pain, nasal discharge/postnasal drip
   e. Use of any topical medications (e.g., nasal steroid sprays) and response
   f. Trial and effect of nasal dilating strips
   g. History of environmental allergy
2. Past medical history
   a. Prior nasal surgery, cosmetic or functional, increases the index of suspicion for loss of volume or support of upper or lower lateral cartilages and implies greater scarring between previously elevated mucosal flaps and therefore higher risk of mucosal tears.
   b. Prior nasal trauma: Depending on physical findings, prior trauma may require application of functional septorhinoplasty techniques for optimal correction of the nasal airway.
   c. Medical illnesses
   d. Medications:
      1) Antiplatelet drugs
      2) Herbal products
      3) Alcohol
      4) Smoking cigarettes

Physical Examination

1. Observation: Breathing at rest and with moderately forceful inspiration to assess stability of nasal sidewall for static or dynamic collapse
2. Anterior rhinoscopy to enable description of the septal deflection (tilt, curves, angulation, spurs, grooves, location). This should include critical evaluation of the position of the caudal septum and patency/obstruction of the angle of the internal valve.
3. Palpation of caudal septum to clarify position, orientation with respect to dorsal strut, strength, and angulation if any
4. Nasal endoscopy to evaluate for other sources of obstruction (e.g., sinonasal mass, polyposis, adenoid hypertrophy) and document pre-existing septal perforation if present. An endoscopic evaluation involves three "passes" of the endoscope:
   a. Along the floor of the nose to inspect the inferior turbinate, inferior meatus, nasolacrimal duct, and nasopharynx (fossa of Rosenmuller and Eustachian tube orifice)
   b. Toward the middle turbinate, examining the middle meatus, ethmoid bulla, uncinate and lateral nasal wall, sphenoethmoidal recess, superior turbinate, and sphenoid os
   c. Superiorly toward the olfactory cleft (often with a 30-degree endoscope)

Overall, the physical examination should enable the surgeon to describe the cartilaginous and bony septal deformity in detail, with particular note made of deviations of the dorsal or caudal septum, obstruction impacting the internal or external nasal valve, and/or instability of the nasal sidewall.

Upon completion of the physical examination, the surgeon should be able to recognize the more complex septal deformity

for which "routine" septoplasty might prove to be inadequate. This is an essential part of minimizing failure or revision rates. Circumstances that present a higher risk for surgical failure, for which a more involved operation (functional septorhinoplasty) might be more appropriate, are more readily identifiable at the completion of the examination by routinely asking the following questions:

- Is there a nasal valve problem?
- Is there a dorsal septal deviation?
- Is there a caudal septal deviation?
- Are there complex deformities in regions that provide critical support to the nasal dorsum or tip that cannot be treated with conventional excisional techniques and require reconstruction or reimplantation of cartilage?

Imaging

Imaging is not routinely required in the evaluation of the deviated septum unless one is concerned about alternative sources of nasal obstruction or evaluating for concomitant sinus disease, in which case a dedicated maxillofacial computed tomography (CT) scan would be warranted.

Indications

1. Symptomatic nasal airway obstruction with a deviated nasal septum
2. Access to paranasal sinuses for endoscopic sinus surgery
3. Sphenoid sinus/pituitary access
4. Management of epistaxis posterior to a septal deflection

Contraindications

1. Unfit for general anesthesia (medical comorbidities)
2. Uncorrectable coagulopathy or use of anticoagulants that cannot be held through the perioperative period

Preoperative Preparation

1. Discontinue antiplatelet drugs.
2. Coagulation profile if there is a history of excessive bleeding
3. Medical clearance if necessary
4. Preoperative counseling regarding the procedure, risks, and complications

OPERATIVE PERIOD

Anesthesia

Although septoplasty can be done with good topical and local anesthesia, general anesthesia maximizes patient comfort and optimizes airway protection, which is particularly important in the setting of anticipated intraoperative bleeding. An oral RAE tube is preferred for intubation because the preformed contour allows it to rest tension-free in the midline.

Positioning

Supine
With the endoscopic approach:

1. The surgeon, the patient, and the screens from which the surgeon is operating (image guidance and endoscopic view) should be in a common axis for optimal visualization and instrumentation.
2. The head of the bed is elevated to 20 to 30 degrees to assist with venous congestion and tilted 15 degrees to the surgeon's side.

Perioperative Antibiotic Prophylaxis

First-generation cephalosporin
Clindamycin or gentamicin if the patient is allergic to penicillin

Monitoring

Hemodynamic monitoring (anesthesiology). Although exceptions may be made due to cardiovascular status and medical history, maintaining a heart rate at 60 beats/minute and mean arterial pressure of 60 mm Hg is felt to be safe and effective at reducing bleeding.

Instruments and Equipment to Have Available

1. Basic septorhinoplasty set
2. Tower, camera, and 0- and 30-degree telescopes (endoscopic technique)

Key Anatomic Landmarks

1. Submucoperichondrial plane when elevating flap
2. Bony-cartilaginous junction
3. Perpendicular plate of the ethmoid bone, vomer, and maxillary crest
4. Internal nasal valve, external nasal valve (nasal vestibule)

Prerequisite Skills

1. Familiarity and comfort with septal anatomy
2. Functional septorhinoplasty experience for more complex septal reconstruction
3. Basic endoscopic skills

Operative Risks

1. Disarticulation of quadrangular cartilage from the perpendicular plate of the ethmoid bone (separation carried too far anteriorly) with loss of dorsal height (supratip depression)
2. Mucosal tears
3. Loss of dorsal/tip support (overly aggressive resection of cartilaginous struts)

Surgical Technique: Classic Septoplasty

1. Anterior rhinoscopy: Following the induction of general anesthesia, the nose should be reexamined (rhinoscopy) and the caudal septum palpated (to establish strength, position, and shape) to confirm prior clinical findings.
2. Injection: Inject the septum bilaterally with 1% lidocaine with 1:100,000 epinephrine (typically 5 to 10 mL), then decongest the nose with oxymetazoline-soaked pledgets. The cottonoids are left in place for 10 to 15 minutes to maximize vasoconstriction.
3. Incision: Once the table is turned and the patient is draped, a small speculum is used to expose the caudal end of the septum and a hemitransfixion incision is made along the free caudal edge using a number 15 blade (Fig. 95.1). Typically a left-sided access incision is preferred, although this can vary with surgical preference. If the caudal septum is extremely deviated into the right nares and therefore relatively inaccessible from the left, then a right-sided hemitransfixion is used. The incision is carried through the perichondrium to expose the ice-blue color of the septal cartilage.
4. Flap elevation: Submucoperichondrial and submucoperiosteal flaps are elevated bilaterally using Woodson and Cottle elevators (Fig. 95.2). The dissection pocket is visualized directly with the benefit of a smaller speculum

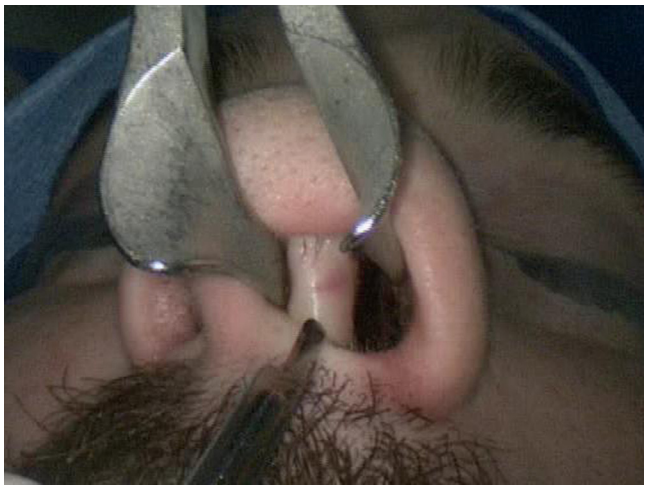

Fig. 95.1. Site of a left hemitransfixion incision along the caudal edge of the septum.

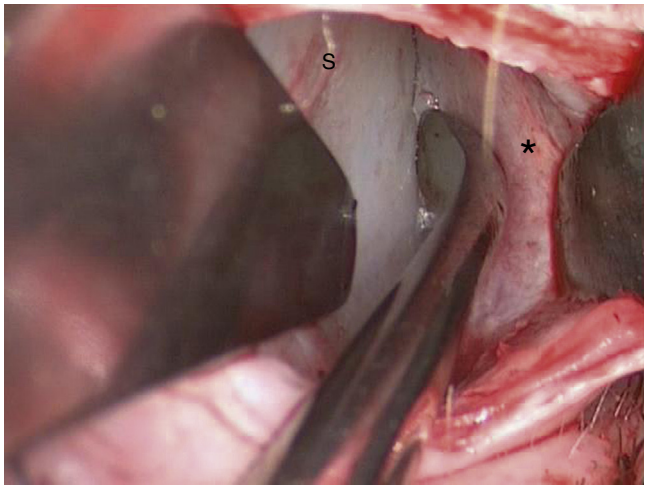

Fig. 95.2. Speculum in place showing elevation of the left submucoperichondrial flap. Septal cartilage *(S)* is seen to the left of the Woodson elevator and the mucosal flap *(asterisk)* to the right.

lower in the nose, transitioning to a medium-length Killian speculum further back in the nose. The flap elevation is begun using a Woodson elevator and transitions to a Cottle elevator when working farther posterior in the nose where it is easier to see over the flatter profile of the Cottle elevator. In the proper plane, the dissection is fairly quick and relatively bloodless. Bilateral flap elevation is felt to be advantageous for several reasons: optimizing exposure, maximizing release of deforming mucosal tension, and enhancing surgical access for more complicated correction or reconstruction of complex septal deformities. Flap elevation must be done cautiously to minimize the risk of inadvertent mucosal tears.

5. Reassess: At this point, another intraoperative assessment of the septum is carried out to get a better sense of the nature of the septal deformity and which deforming forces must be overcome to correct the septal alignment.
6. Correcting the septum: Working sequentially from the posterior nasal airway toward the caudal septum is preferred. Because alterations or manipulation of the caudal septum is potentially more disruptive to tip support, it is better to address those last and reconstruct that area as needed without the need to do more work farther back in the nose, which might destabilize a reconstructed caudal septum at that point.
7. Intraoperative checklist: In every case, the same system is consistently applied to analyze the nasal airway as the surgery proceeds. Having a system in place will focus attention in a deliberate way and reduce the chance of leaving a persistent deflection unattended or overlooked. Specifically, as the surgery proceeds from back to front, the author evaluates the following:
   a. Is the nasal airway open at the back (typically bony septal deviations)?
   b. Is the nose open anteriorly (dorsally) through the nasal valve? If the root of the middle turbinate can be easily visualized without having to pass a speculum too far into the nasal cavity or without opening the nasal speculum too forcibly, then one can be reassured that airflow will move easily through the internal nasal valve. This is a common site of failure, and even modest deviations in the valve region should be addressed.
   c. Is the nose open along the floor (typically spurs of maxillary crest or displacements of quadrangular cartilage over crest)?
   d. Is the caudal septum straight and maintaining a tension-free position in the midline?
8. Separate the quadrangular cartilage from the bony septum: Applying steady pressure with the Cottle elevator, the quadrangular cartilage will separate from the bony septum (perpendicular plate of the ethmoid) posteriorly. The separation is carried to within 1 to 1.5 cm of the nasal dorsum (Fig. 95.3). Care is exercised not to completely disarticulate the two.
9. Removal of the deflected perpendicular plate of ethmoid and vomer: If the bone is at all off-center, the rigid nature of the bone will overpower the softer more pliable nature of the attached cartilage, tethering it into a sustained nonmidline position. Bone removal must therefore be as complete as deemed necessary rather than overly conservative. Whenever possible, superior cuts in the bone should be made sharply to avoid the very rare complication of fracturing the cribriform plate and creating a cerebrospinal fluid fistula. Using double-action scissors, cuts are made high (dorsally) and low (over the maxillary crest), and the intervening deflected segment is removed using a double-action rongeur (see Fig. 95.3). Reassessment of the nasal airway bilaterally follows.
10. Cartilage removal: If there is a persistent deviation of the quadrangular cartilage, incisions are made and cartilage removal proceeds as necessary. Under direct vision and using a number 15 blade, one incision is made in the cartilage paralleling the nasal dorsum and another incision is made paralleling the caudal septal edge/columella, outlining the segment of cartilage to be removed. Remove as little cartilage as is needed to improve the nasal airway. At a minimum, cartilage removal should preserve at least a 1-cm dorsal septal strut and a 1-cm caudal septal strut. This is critical to maintain adequate support to the nasal tip and dorsum to minimize the risk of postoperative settling of the supratip dorsum (saddle deformity). If a determination is made preoperatively that a clinically significant curvature or angulation exists within the dorsal 1 cm of the quadrangular cartilage, then the surgeon should consider correcting the nasal airway through an external functional septorhinoplasty approach or referring this patient to a surgeon who is capable of such. An external rhinoplasty approach gives the surgeon maximal exposure to correct, divide, excise, and/or reconstruct the dorsal septal strut as needed. Removed cartilage segments that are reasonably straight (but were off the midline and hence excised) can be replaced between the septal flaps for added septal support prior to quilting the mucosal flaps. In such cases the returned segment should be positioned above the caudal strut and behind the dorsal strut to minimize inadvertent obstruction that might arise from an overlap.

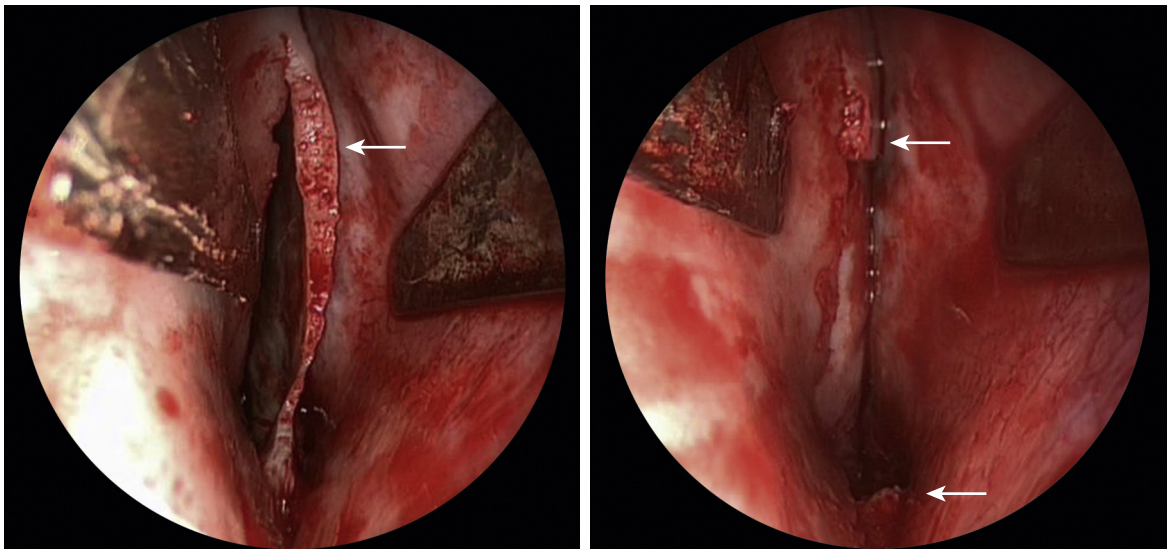

Fig. 95.3. Left image: separation of quadrangular cartilage (being displaced to the left of the speculum) from the perpendicular plate of ethmoid bone (edge indicated by *arrow*). Right image: high and low bone cuts *(arrows)* with removal of intervening bony segment.

11. Removal of inferior bony septal spurs (maxillary crest): The surgeon must decide whether a spur or localized deviation of the maxillary crest is of a magnitude that might contribute to airway compromise. Smaller deviations toward the floor of the nose are often asymptomatic, unlike smaller deviations dorsally toward the internal nasal valve. Larger spurs, spurs that contact the inferior turbinate, or crest deviations that create a secondary deviation of the overlying quadrangular cartilage should be removed. Bilateral elevation of the mucoperiosteum over the lateral aspect of the crest can be tedious and must be done carefully because the mucosa tends to be thinner and more adherent to the bone as compared to cartilage. The deviated crest can then be removed with a double-action rongeur or a 4- to 6-mm chisel or osteotome.
12. Correction of caudal septal deformities: Severe angulation or rotation of the caudal strut off the midline sagittal plane should be readily identifiable at the preoperative consultation. Routine palpation of the caudal septum provides valuable insight over and above anterior rhinoscopy and will distinguish those deformities that would not be correctable with "traditional" excisional surgery or submucous resection. An external functional septorhinoplasty approach should be considered for more extreme caudal septal deformities to minimize the likelihood of surgical failure, patient dissatisfaction, and the need for more difficult revision surgery in the future. The caudal septum that is tilted or displaced off the anterior nasal spine or gently bowed or curved is very amenable to an endonasal correction. Likewise, if there is a mild to moderate angulation (as opposed to curvature) in the midportion of the caudal septum, where the caudal edge of the septum is still directed inferiorly and the apex of the fracture is directed laterally, this can be addressed endonasally. On the other hand, if the fracture/angulation extends along an anteroposterior vector through the junction of the caudal and dorsal septum, the caudal septal segment may be completely rotated off the axis of the dorsal septum. In this circumstance the caudal edge of the septum will not be directed inferiorly but will be oriented laterally toward the nasal sidewall and inferior turbinate instead. This type of caudal septal deviation can always be identified preoperatively with a thoughtful and thorough examination. A more radical caudal septal deviation such as this may require complete transection (explanting) of the caudal septum from the dorsal septum with reorientation and restabilization of the native segment or replacement of that segment with a separate free cartilage replacement graft and then restabilization. This can be done endonasally (but it is very challenging and requires significant experience to execute) or through an external rhinoplasty approach. Such cases can jeopardize dorsal and tip support and as such are best attended to by surgeons experienced in reconstructive nasal airway surgery and comfortable with external approach reconstructive rhinoplasty. This will not be covered in this chapter. Caudal septal deformities are better appreciated and more readily corrected with the benefit of bilateral mucosal flap elevation. For the caudal septum that is merely tilted off the anterior nasal spine or gently bowed to one side, conservatively removing a small wedge of cartilage over the anterior nasal spine and thus shortening the posterior end of the caudal strut—nominally and conservatively—will enable movement to a midline position over the anterior nasal spine (Figs. 95.4 and 95.5). This resection is typically no more than 2 to 3 mm. The goal is to allow the caudal strut to sit tension-free right over (in contact with) the anterior nasal spine but not to hang well above it. This reduces the chance of posterior settling of the supratip dorsum and a visible dorsal depression. If the reduction is inadequate, however, the tilt or curve may persist, or the patient may complain that there is movement and "clicking" in that region as the posterior septal edge contacts or moves across the spine. For the caudal septum that is angulated (as one might see with a prior fracture), removing a small wedge above the anterior nasal spine and crest as described previously does nothing to remove the angulation and will therefore prove to be inadequate. In such cases the surgeon must transect the caudal strut along a cephalocaudal vector, through the apex of the fracture line. The caudal septum thus becomes two segments, one anterior (contiguous with the dorsal strut) and one posterior (attached at the nasal spine). The excess length will allow the two segments to be overlapped and suture secured to one another to strengthen the caudal strut. Typically one will have to try the two overlap options (posterior segment to the left of anterior segment and vice

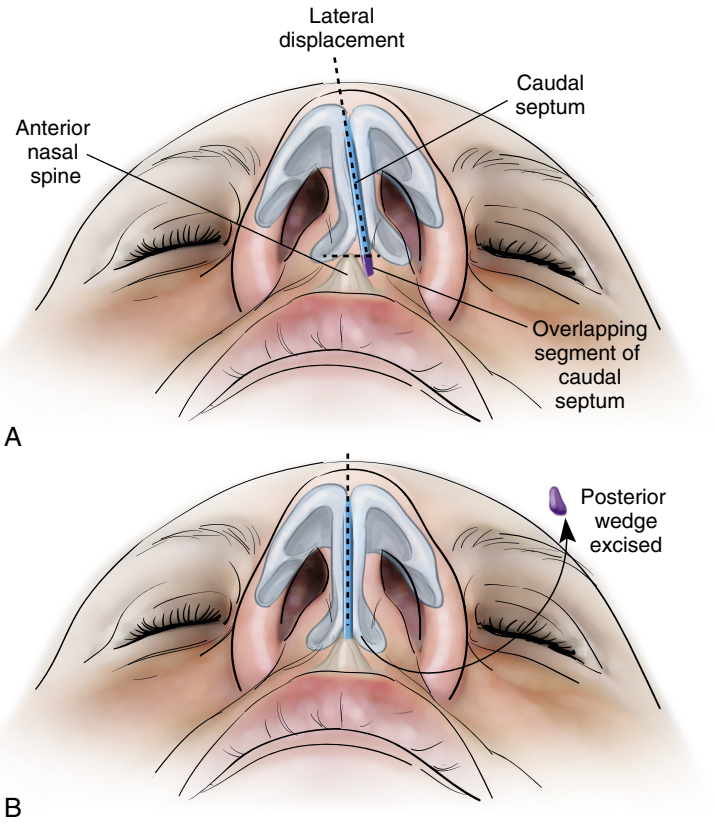

Fig. 95.4. When the caudal septum is tilted/displaced over the anterior nasal spine (A), excising a small wedge of cartilage—incrementally and conservatively—will allow the caudal strut to move into a midline position immediately atop the nasal spine (B). *(Adapted with permission from Kennedy DW, Myers EN(eds): Master Techniques in Otolaryngology Head and Neck Surgery: Rhinology. 1st ed. Wolters Kluwer; 2016.)*

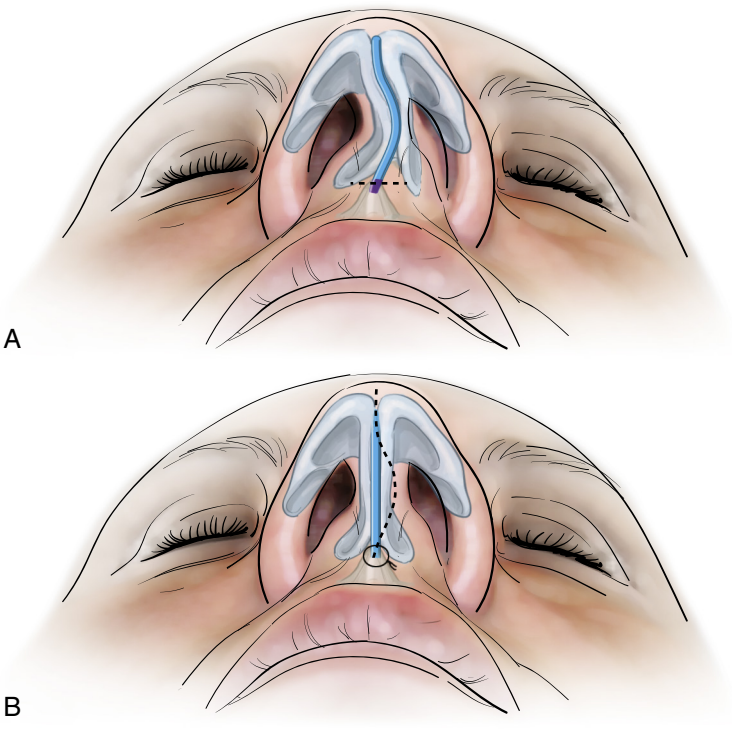

Fig. 95.5. Conservatively shortening the gently curved or bowed caudal septum above the anterior nasal spine (A) will allow the bowed segment to release, straighten, and assume a midline position (B). *(Adapted with permission from Kennedy DW, Myers EN(eds): Master Techniques in Otolaryngology Head and Neck Surgery: Rhinology. 1st ed. Wolters Kluwer; 2016.)*

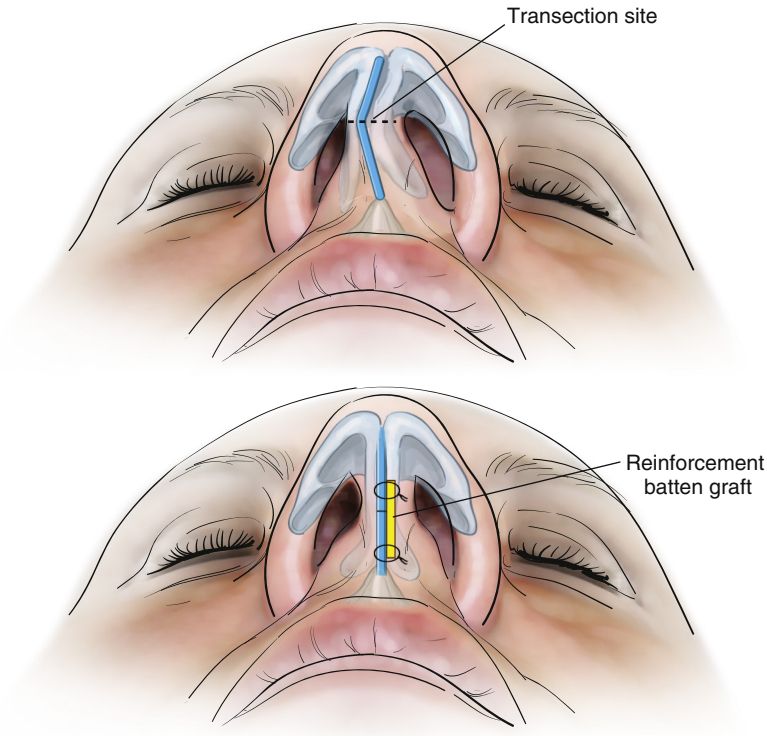

Fig. 95.6. The angulated caudal septum is divided through the apex of the angulation (A). The anterior and posterior segments can then be overlapped and suture-secured to one another. Alternatively, the overlap can be excised and the two segments aligned end to end and stabilized with a sutured-in-place batten (reinforcement) graft (B). *(Adapted with permission from Kennedy DW, Myers EN(eds): Master Techniques in Otolaryngology Head and Neck Surgery: Rhinology. 1st ed. Wolters Kluwer; 2016.)*

versa) to establish which arrangement is most favorable to airway patency. An alternative to overlapping is to excise the excess cartilage so that the two segments rest end to end. That junction is stabilized by using harvested septal cartilage to fashion a reinforcement batten graft, which is then sutured in place on one side or the other to bridge the two segments (Fig. 95.6).

13. Septal flaps: The septal flaps from either side are quilted to one another with a running through-and-through 4-0 plain gut suture. The hemitransfixion incision is closed with simple interrupted 5-0 plain gut, through-and-through 4-0 plain gut septocolumellar sutures, or a combination thereof.
14. Placement of Doyle splints: Doyle splints are placed on either side of the septum and stabilized with a through-and-through 3-0 Prolene suture.

Surgical Technique: Endoscopic Septoplasty

1. Once the submucoperichondrial plane is elevated anteriorly to create a pocket large enough to allow for introduction of the endoscope (approximately 2 to 3 cm; see Fig. 5.1), the dissection at this point transitions to the endoscopic technique (Fig. 95.7).
2. A Cottle elevator is used to elevate the flaps bilaterally (Fig. 95.8). If the caudal septum is not affected by the septal deformity (e.g., superior deviation of the perpendicular plate of the ethmoid limiting the view for a frontal sinus dissection or a posterior bony spur), the flap is only raised caudally on one side, and the cartilaginous septum is traversed to the opposite side more posteriorly without disruption of the mucoperichondrial attachments of the caudal septum.
3. The location of the traversing incision is measured with an intranasal view from the nasal columella to the site just anterior to the deviation using the Cottle elevator.

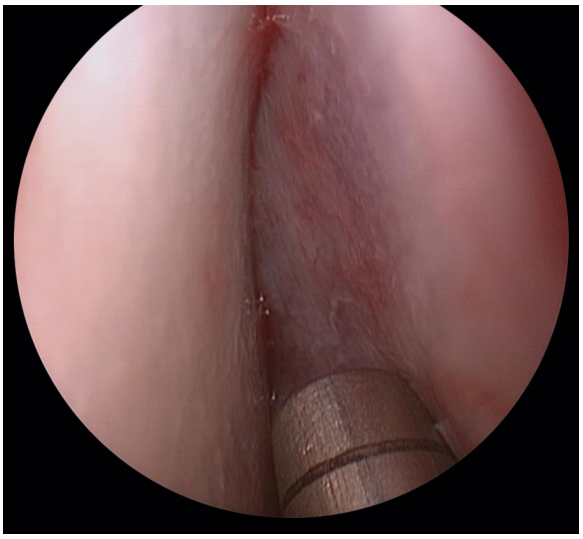

Fig. 95.7. The endoscopic views are demonstrated with a 0-degree Hopkins telescope. (Mucosal flap to the *right* of suction, quadrangular cartilage to the *left*.)

4. The deviated portion of the cartilaginous septum is removed with a Ballenger swivel knife or through-cutting straight Blakesley forceps taking care to preserve the cartilaginous strut.
5. Deviation of the bony septum is removed by creating a cut superiorly with double-action scissors. The double-action scissors should be introduced into the flap with the jaws oriented in a vertical fashion to prevent injury laterally to the middle turbinates.

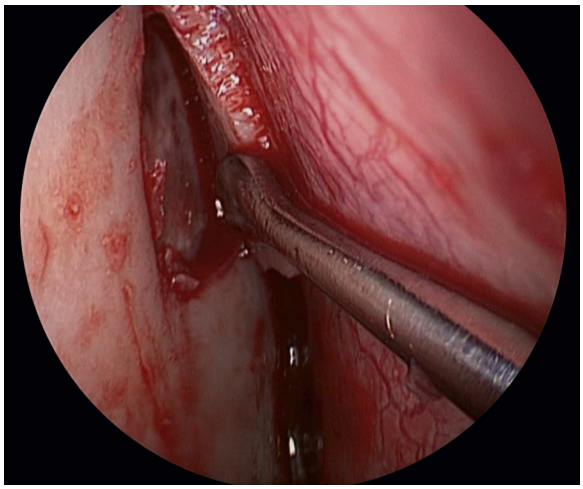

Fig. 95.8. Flap elevation bilaterally is performed with a Cottle elevator.

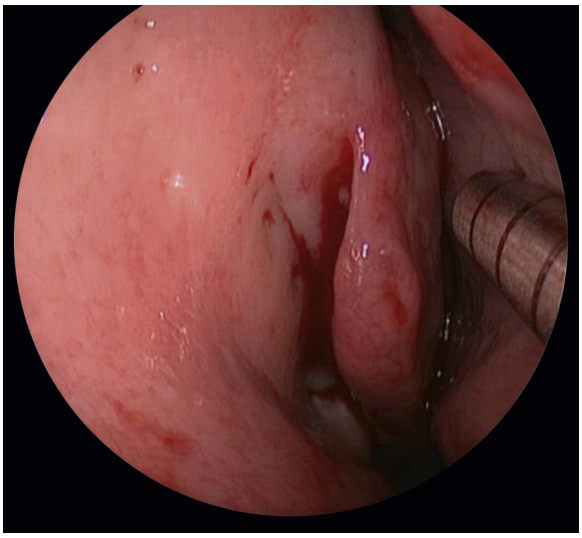

Fig. 95.9. The axilla of the middle turbinate can now be visualized, which allows for access to the paranasal sinuses, especially to the frontal sinus.

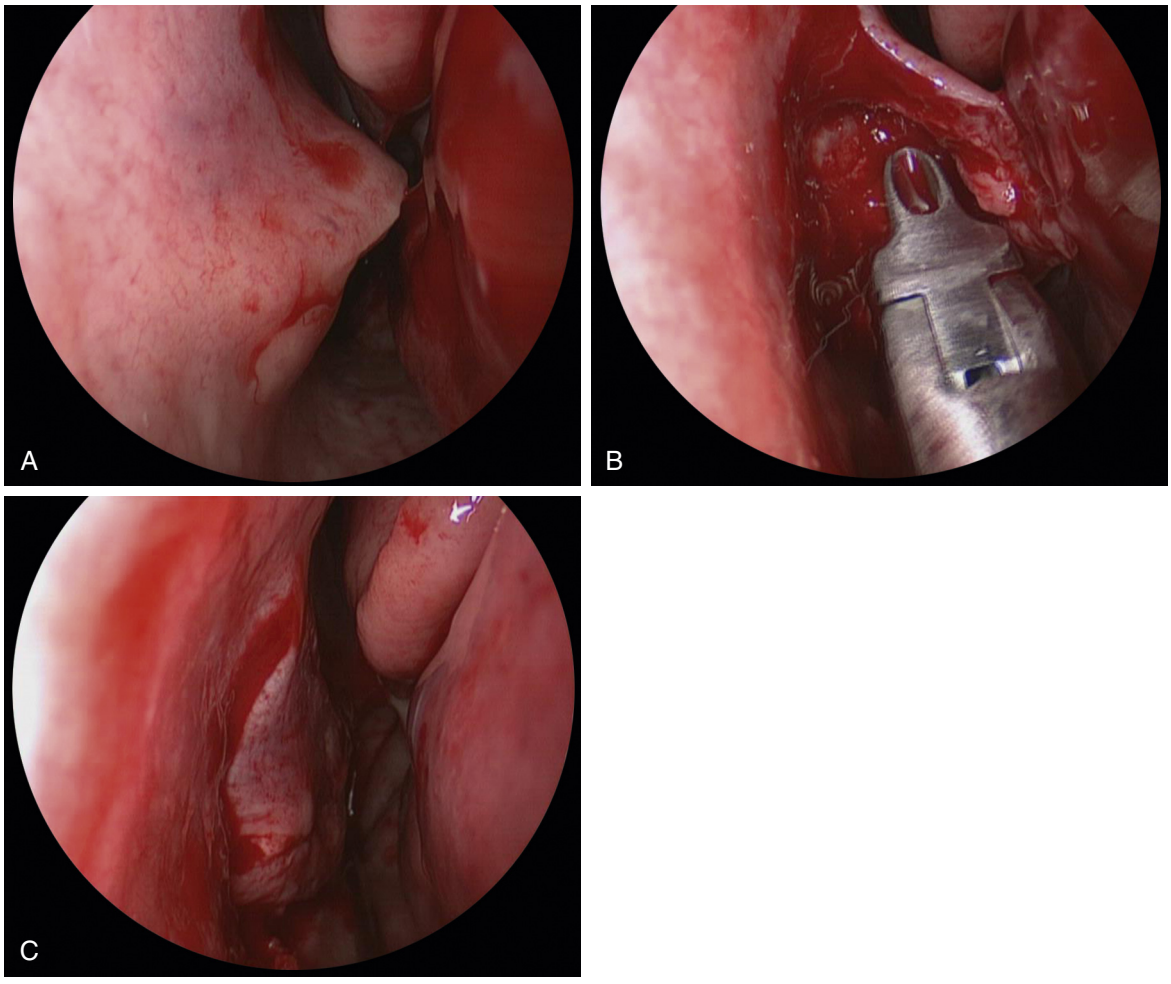

Fig. 95.10. **A** to **C,** Localized flaps can be raised to remove obstructive bony spurs, obviating the need for large flap elevation.

6. Once the deviated portion of the septum is removed appropriately, the axilla of the middle turbinates should be visible bilaterally (Fig. 95.9). This is important should the patient require a frontal sinus surgery.
7. Isolated septal spurs can be removed by elevating a C-shaped flap anterior to the spur in appropriate cases and removal of the spur with through-cutting Blakesley or Gruenwald forceps while preserving the overlying mucosa (Fig. 95.10A to C).

8. The anterior hemitransfixion incision is closed with a series of interrupted 5-0 fast-absorbing suture, and the septal flaps are reapproximated with a quilting 4-0 plain gut suture.
9. The middle turbinates can also be included in the quilting suture by pexy to the septum to prevent lateralization.
10. Doyle splints are then placed into the nose bilaterally and secured anteriorly with 3-0 Prolene. The endoscope is used to ensure that the splints do not cause lateralization of the middle turbinate. The most superior/posterior portion of the splint can be trimmed to ensure that the splint does not disrupt the pexy suture.

Common Errors in Technique

1. Improper elevation of the mucosal flap
2. Failure to achieve complete exposure of the septal deviation
3. Inadequate resection of the bony deviation leading to persistent septal deviation
4. Inattention to septal shift dorsally or caudally leading to persistent septal obstruction at the internal or external valve, respectively

POSTOPERATIVE PERIOD

Postoperative Management

1. Patients are typically discharged the day of surgery.
2. Antibiotic coverage for *Staphylococcus aureus* is used while splints are in place.
3. Patients are instructed to irrigate the intranasal splints with a high-volume (8 oz) saline solution 3 to 4 times daily. After each rinse, the nasal vestibule is cleaned of any loose/clotted blood with a cotton swab soaked in hydrogen peroxide, following which an over-the-counter antibiotic ointment is applied inside the nares to moisturize the nose. This regimen helps keep the splints clear, thus maximizing comfort and enabling the patient to breathe through the splints.
4. The intranasal splints are removed at 5 to 7 days postoperatively.

Complications

1. Excess postoperative bleeding: Bleeding may respond to a topical vasoconstrictor spray (e.g., oxymetazoline) or gentle packing over the splints with absorbable woven hemostatic mesh (e.g., Surgicel). Continued bleeding will require splint removal and cauterization if the focal site is identifiable or exploration in the operating room.
2. Sinusitis: Should the patient develop sinusitis, culture-directed antibiotics are preferable. If not available, amoxicillin-clavulanate is recommended per current guidelines or, in penicillin-allergic patients, doxycycline.
3. Septal perforation: This is generally preventable with meticulous elevation of intact mucosal flaps and repair of any incidental mucosal tear.
4. Septal hematoma: Suture quilting the septal flaps from one side to the other eliminates the surgical dead space and minimizes the chance of septal hematoma. If intraoperative bleeding or oozing between septal flaps is felt to be excessive, a small venting stab incision should be made in the septal mucosa posteriorly if there are no inadvertent mucosal tears. Should a hematoma develop, as suggested by increasing pain, nasal congestion, and visible bilateral distention or swelling of the septum, aspiration with an 18-gauge needle is reasonable in an effort to evacuate the hematoma. If drainage is incomplete or limited, early surgical exploration and drainage are essential. An unrecognized hematoma can lead to pressure ischemia, loss of the remaining septal cartilage, and a saddle nose deformity.
5. Toxic shock syndrome: This has been reported in patients with and without nasal packing following nasal septoplasty and is thought to be due to colonization of the nasal packing by *S. aureus,* which produces exotoxin. There does not appear to be an absolutely certain way to prevent this complication. If a patient reports early fever, serious diarrhea, or ischemia of the limbs, evaluation for toxic shock syndrome should be done immediately. The packing should be removed and cultured, antistaphylococcal antibiotics should be administered, and careful observation and intervention should be done as needed. Nasal packing post septoplasty is rarely necessary, however, with the availability of silastic splints.
6. Cerebrospinal fluid (CSF) leak: This situation is very uncommon and is likely attributable to avulsion of the perpendicular plate of the ethmoid and its attachment to the cribriform plate. This can be avoided by not avulsing any bone or cartilage unless a superior cut has already been made from the perpendicular plate of the ethmoid bone.
7. Anosmia: This condition is rare and spurious, with a quoted incidence of 1 in 1,000,000.
8. Need for secondary/revision surgery: Such surgery might be required for persistent symptomatic obstruction.
9. Change in external appearance: Loss of height of the dorsal septum (mild saddle deformity) can result from disarticulation of the quadrangular cartilage from the perpendicular plate of the ethmoid bone at the keystone area (rhinion), from posterior settling of the caudal and dorsal septal struts, or from overly aggressive reduction of dorsal strut height. Although infrequent, a crushed cartilage onlay graft placed over the dorsal septum through an intercartilaginous incision can camouflage the external deformity.

Alternative Management Plan

1. Medical management
   a. Screening and evaluation for allergic rhinitis or inferior turbinate hypertrophy
   b. Trial of a topical nasal steroid spray and oral antihistamine if a history of allergic rhinitis is present
   c. Patients whose conditions warrant exception from a preoperative trial of medical therapy include those without obvious history of inflammatory disease and a significant anatomic deformity that suggests that surgical correction would be best suited for the patient.

DISCUSSION

Evidence-Based Medicine Question

Has septoplasty been shown to be an effective intervention for the relief of symptomatic nasal obstruction in patients with a deviated septum?

Prior to 2004, most reports of outcomes of septal surgery were limited by study design: They were often retrospective, relied only on chart reviews or telephone follow-up surveys, depended on physician-rated outcomes rather than patient-reported satisfaction, and used nonvalidated outcome measures. In 2004, Stewart et al. developed and validated a disease-specific outcome instrument to evaluate interventions in patients with nasal obstruction.[1] The nasal obstruction symptom evaluation (NOSE) scale has since become a useful tool in that regard. The NOSE scale has been used to show that patients undergoing primary[2] or revision[3] septoplasty demonstrate statistically significant improvements in nasal

obstruction and corresponding NOSE scores postoperatively, with high degrees of patient satisfaction. As with any operation, however, proper patient selection and an individualized surgical plan are paramount.

Editorial Comment

Drs. Gillman and Lee have written a very practical and useful review of the endonasal and endoscopic approach to septoplasty. During residency training it is often felt that septoplasty is a very "doable" procedure, even for junior residents with little prior exposure to nasal surgery. However, those of us who have struggled with a challenging septoplasty know this is not the case! Septoplasty surgery can be humbling to the surgeon and unsatisfying to the patient due to inadequate planning or execution. Many of the classical errors of septoplasty surgery can be avoided by heeding the conceptual pathways presented in this chapter. In addition to providing an overall approach to the procedure, the authors provide many nuanced points that are commonly gleaned only after years of experience. The section on endoscopic septoplasty will be of particular interest to surgeons not familiar with this approach.

Paul Leong

Access the review questions and additional sources list online at http://www.expertconsult.com

REFERENCES

1. Stewart MG, Witsell DL, Smith TL, et al. Development and validation of the Nasal Obstruction Symptom Evaluation (NOSE) scale. Otolaryngol Head Neck Surg 2004;130:157–163.
2. Stewart MG, Smith TL, Weaver EM, et al. Outcomes after nasal septoplasty: results from the Nasal Obstruction Septoplasty Effectiveness (NOSE) study. Otolaryngol Head Neck Surg 2004;130:283–290.
3. Gillman GS, Egloff AM, Rivera-Serrano CM. Revision septoplasty: a prospective disease-specific outcome study. Laryngoscope 2014;124(6):1290–1295.

REVIEW QUESTIONS

1. Disproportionate and increasing postoperative pain, congestion, and nasal swelling should make one think of which option?
   a. Septal perforation
   b. Excessive postoperative edema
   c. Munchausen syndrome
   d. Septal hematoma
   e. Drug-seeking behavior

2. The most common sites of failure in routine septoplasty surgery are persistent deviation within which of the following?
   a. Dorsal septum
   b. Maxillary crest
   c. Caudal septum
   d. Ascending process of the maxilla
   e. (a) and (c)

3. Which option is an intranasal anatomic reference point frequently used in endoscopic septoplasty?
   a. Crista galli
   b. Head of the inferior turbinate
   c. Septal body
   d. Axilla of the middle turbinate
   e. Infundibulum

ADDITIONAL SOURCES

Gillman GS. Septoplasty. In: Myers EN, Kennedy DW, editors. Masters Techniques in Otolaryngology—Head and Neck Surgery: Rhinology. Philadelphia, PA: Wolters Kluwer; 2016. p. 7–20.

Han JK, Stringer SS, Rosenfeld RM, et al. Clinical consensus statement: septoplasty with or without inferior turbinate reduction. Otolaryngol Head Neck Surg 2015;153(5):708–720.

96 Nasal Septal Perforation

Brian Lee, Thomas J. Willson, Stella E. Lee

INTRODUCTION

The nasal septum plays an important role in the structural and physiologic functions of the nose, contributing to nasal shape, appearance, and laminar airflow. The septum is made up of three distinct layers. Superficially, the mucosa is made up of ciliated respiratory epithelium. High in the nasal vault, in the region of the olfactory cleft, the mucosa is incorporated with specialized olfactory epithelium. Deep to this layer lies the mucoperichondrial/mucoperiosteal layers that contain the vascular network. Finally, the deepest layer is made up of a caudally located quadrangular cartilage and a confluence of bony projections posteriorly (vomer, perpendicular plate of the ethmoid, maxillary, and palatine bones).

The blood supply of the septum is a complex and robust anastomotic network derived from multiple sources. The primary supply is derived from terminal branches of the external carotid system, chiefly the internal maxillary artery, with secondary supply from the facial artery. The internal maxillary artery traverses the pterygopalatine fossa and enters the nose via the sphenopalatine foramen as the sphenopalatine artery. Posteriorly, the posterior septal branch of the sphenopalatine artery traverses the sphenoid rostrum to supply the septum. Inferiorly, the greater palatine artery, a branch of the internal maxillary artery, anastomoses with the inferior septal branches after traversing through the incisive foramen. Superiorly, the anterior and posterior ethmoid arteries, both branches of the ophthalmic artery, descend into the septum. Anteriorly, the superior labial artery, a branch of the facial artery, provides additional vasculature to the septum. Blood courses through this anastomosing network enveloped within the perichondrial and periosteal layers (Fig. 96.1).

Disruption of this blood supply to the underlying avascular cartilage may lead to subsequent necrosis. If this occurs bilaterally, in opposing locations, a perforation may form. A nasal septal perforation is a sagittal-oriented, three-dimensional defect that involves the quadrangular cartilage and/or bone (perpendicular plate of the ethmoid, vomer, maxillary, and palatine bones), as well as the bilateral overlying respiratory epithelium (mucoperichondrium and mucoperiosteum) (see Fig. 96.1). The numerous causes of septal perforations can be categorized into traumatic, iatrogenic, infectious, inflammatory, neoplastic, vasoconstrictive, and caustic etiologies (Box 96.1). Of all these listed, iatrogenic injury during septoplasty and nasal septal cauterization are the two most common causes.[1]

Nasal septal perforations can also be categorized by size (in largest diameter) and location. Small perforations are defined as less than 5 mm, medium-sized perforations between 5 and 20 mm, and large perforations greater than 20 mm. Perforations may be located posteriorly or anteriorly. The middle turbinate attachment to the lateral nasal wall can be used as a landmark to differentiate anterior from posterior perforations.

Symptoms of nasal septal perforations are dependent on both the size and location of the perforation. In general, large and anterior perforations are the most symptomatic. Perforations located posteriorly tend to be asymptomatic even when large due to the high intranasal humidification within the posterior nasal cavity. Symptomatic patients often present with paradoxical nasal obstruction due to airflow turbulence created by diversion through the perforation. A consequence of this alteration in flow is mucosal desiccation at the margin of the perforation. This often leads to additional symptoms, such as chronic nasal crusting (at the perforation margins), recurrent epistaxis (mild to moderate in severity), exposed cartilage, pain (low-grade chondritis), malodor/cacosmia (infection), and rhinorrhea (compensatory) (Box 96.2). Small anterior perforations can be a source of annoyance, causing nasal whistling, whereas large anterior perforations can lead to cosmetic deformity via loss of dorsal and columellar support. The reduction in nasal support leads to saddle nose deformity and columellar retraction respectively.

KEY OPERATIVE LEARNING POINTS

1. Freshening of the margin of the perforation is important in promoting re-epithelialization.
2. Elevation of intranasal flaps in the correct submucoperichondrial and submucoperiosteal plane is critical.
3. Tension-free closure of the mucosal flaps is important in preventing flap retraction.
4. Incorporation of an interposition graft during the repair of the septal perforations can provide a scaffold for re-epithelialization.

PREOPERATIVE PERIOD

History

1. "What symptoms are you experiencing?"
   a. Asymptomatic patients are not treated.
   b. Symptomatic patients may be treated with conservative therapy or surgical repair.
2. "How severely do your symptoms impact your quality of life?"
   a. Minor symptoms are treated conservatively.
   b. Significant symptoms that do not respond to medical therapy may be treated surgically.
3. "What is your surgical history?"
   a. This will determine whether the perforation was due to an iatrogenic injury and if there was a previous attempt at repair.
4. "What is your medical and facial trauma history?"
   a. This will determine if the perforation was due to a traumatic, infectious, inflammatory, or neoplastic etiology.
   b. In addition, significant comorbidities may reveal that a patient is not a candidate for a surgical procedure.
5. "Are you a smoker?" "Do you have a history of using cocaine, drug abuse, or the misuse of topical nasal medication?" "What is your occupation?"
   a. Current smoking, nasal drug abuse, topical nasal medication misuse, and exposures in the work environment will affect the outcome of surgical repair.
6. "What medications do you take?"
   a. Patients taking anticoagulants and herbal supplements that contribute to increased bleeding will make surgical repair difficult due to poor visualization.

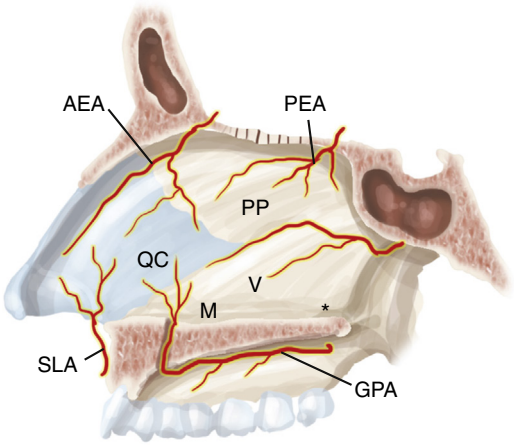

Fig. 96.1. Anatomy of the nasal septum. Quadrangular cartilage *(QC)*, perpendicular plate of the ethmoid bone *(PP)*, vomer *(V)*, maxillary bone *(M)*, palatine bone *(*)*, superior labial artery *(SLA)*, anterior ethmoid artery *(AEA)*, posterior ethmoid artery *(PEA)*, posterior nasal septal artery *(PNA)*, and greater palatine artery *(GPA)*.

Physical Examination

1. Nasal endoscopy is the most important part of the physical examination.
   a. Determine the location of the perforation.
      1) Is it anterior, posterior, superior, or inferior?
      2) Is there one perforation or multiple perforations?
   b. Determine the shape of the perforation.
      1) Is it circular or elliptical?
      2) If the latter, is the longest dimension oriented anteriorly-posteriorly or superiorly-inferiorly?
   c. Determine the size of the perforation.
      1) Place a ruler in one nostril with the markings toward the septum. Place an angled rigid nasal endoscope in the contralateral nostril, and visualize the ruler through the perforation.
   d. Assess the presence of underlying cartilage.
      1) Palpate the septum manually and with a cotton-tip applicator.
   e. Assess the mucosa.
      1) Identify abnormalities that may suggest an underlying infectious, granulomatous/inflammatory, or neoplastic process.

Based upon the patient's history and physical examination findings, we follow the treatment algorithm depicted in Fig. 96.2. The first decision point is determining if the patient requires treatment. Asymptomatic patients do not require treatment. The second decision point is determining whether the symptomatic patient is a surgical candidate. Poor surgical candidates include patients who have medical conditions that prevent safe surgery, who continue to abuse nasal drugs, continue to misuse topical nasal medication, have an active infection, have uncontrolled inflammatory disease, or have untreated sinonasal neoplasms.

Symptomatic patients who are poor surgical candidates are offered conservative management. Conservative management focuses on alleviating symptoms through the routine use of nasal saline irrigations, nasal saline sprays, nasal saline gels, water-based emollients, room humidification, and, if needed, intermittent office visits for débridement.

Conservative management also includes the insertion of a nasal prosthesis after excellent topical anesthesia. Low-profile grommet buttons are easily cut and shaped to the patient's needs and are typically well tolerated (see Chapter 1). Placement of the button is not difficult if done properly. The button may be purse-stringed using a suture or cut along one of the flanges so that it may be placed in a corkscrew fashion. Additional options include magnetic septal prosthetics that may allow easier clinic placement and removal, as well as adjustable two-piece buttons that accommodate multiple septal widths. Because

BOX 96.1 Causes of Nasal Septal Perforations (*Most Common)

1. Traumatic
   a. External
      1) Nasal septal fracture
      2) Septal hematoma
   b. Internal
      1) Chronic nose picking
      2) Nasal piercing
2. Iatrogenic*
   a. Cautery*
   b. Cranial base surgery
   c. Intranasal packing
   d. Nasal intubation
   e. Nasogastric tube
   f. Rhinoplasty
   g. Septal splints
   h. Septoplasty*
   i. Sinus surgery
   j. Turbinate surgery
3. Infectious
   a. Invasive fungal sinusitis
   b. Inflammatory
   c. Nasally inhaled drugs (acetaminophen, opioids, methamphetamines, topical nasal corticosteroids)
   e. Septal abscess (tuberculosis, syphilis, leprosy, rhinoscleroma, rhinosporidiosis)
   f. Systemic disease (granulomatosis with polyangiitis, systemic lupus erythematosus, sarcoidosis, Churg-Strauss, polychondritis)
   g. Vasculitides (granulomatosis with polyangiitis)
4. Neoplastic
   a. Adenocarcinoma
   b. Lymphoma
   c. Melanoma
   d. Squamous cell carcinoma
5. Vasoconstrictive
   a. Cocaine
   b. Topical nasal decongestants (oxymetazoline, phenylephrine)
6. Caustic
   a. Agricultural dust (rice, grain)
   b. Chemical (batteries, sulfuric acid, hydrochloric acid)
   c. Heavy metal (chromium)
   d. Industrial dusts (glass, lime)

BOX 96.2 Symptoms of Nasal Septal Perforations

1. Chronic nasal crusting
2. Cosmetic deformity (i.e., saddle nose, columellar retraction)
3. Malodor (cacosmia)
4. Nasal obstruction
5. Nasal whistling
6. Pain
7. Recurrent epistaxis
8. Rhinorrhea

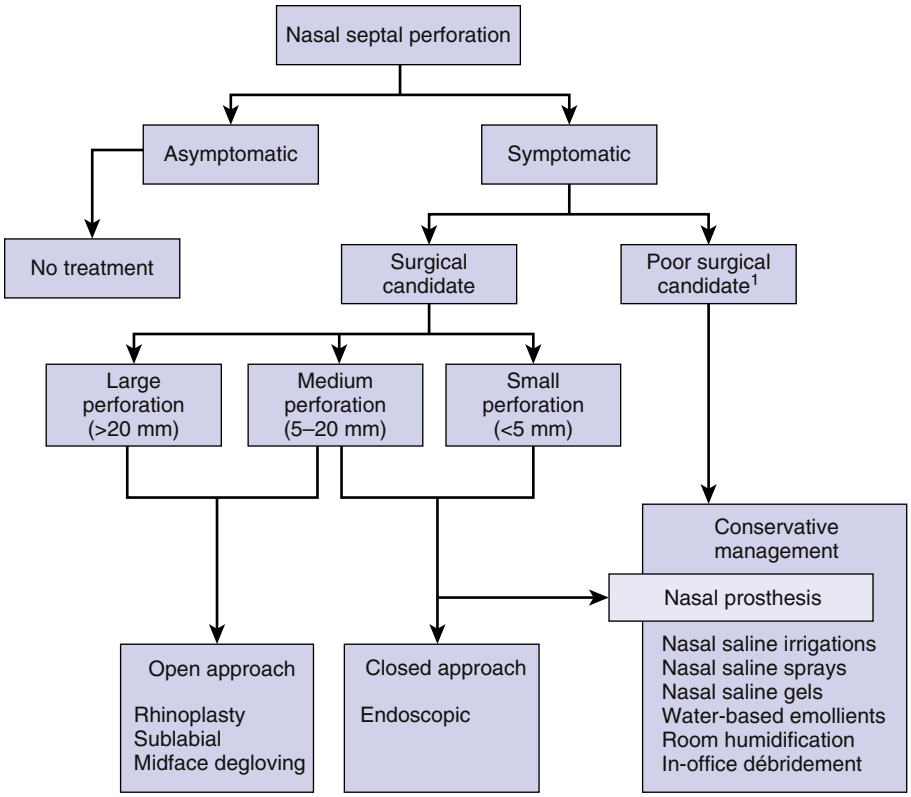

Fig. 96.2. Nasal septal perforation treatment algorithm. [1]Poor surgical candidate: has medical conditions that prevents safe surgery, continued nasal drug abuse, continued topical nasal medication misuse, acute infection, uncontrolled inflammatory disease, or untreated sinonasal malignancy.

septal buttons are foreign bodies, patients may experience nasal obstruction due to the thickness of the prosthesis, debris accumulation, or a local inflammatory reaction (i.e., mucosal edema, granulation tissue).

The third and final decision point is determining how to manage symptomatic patients who are surgical candidates. We recommend that small- and medium-sized perforations be treated with either a nasal prosthesis or through a closed (endoscopic) approach using intranasal flaps with an interposition graft. Large perforations are typically treated through an open approach using intranasal flaps with an interposition graft.

Imaging

1. None. Imaging is not routinely performed unless there is concern for an underlying systemic, granulomatous, or neoplastic process that may be contributing to the septal perforation.

Indications

1. Nasal obstruction
2. Recurrent epistaxis
3. Chronic nasal crusting
4. Pain
5. Malodor/cacosmia
6. Rhinorrhea
7. Nasal whistling
8. Cosmetic deformity (i.e., saddle nose, columellar retraction)

Contraindications

1. Medical comorbidities that would preclude general anesthesia
2. Continued nasal drug abuse (i.e., cocaine, opioids, methamphetamines)
3. Continued misuse of topical nasal medications (i.e., oxymetazoline, phenylephrine)
4. Acute infections (i.e., acute rhinosinusitis, invasive fungal sinusitis)
5. Uncontrolled inflammatory disease (i.e., granulomatosis with polyangiitis, sarcoidosis, systemic lupus erythematous)
6. Sinonasal malignancies

Relative Contraindications

1. Controlled inflammatory disease
2. Previous sinonasal radiation therapy
3. Active tobacco smoking

Preoperative Preparation

1. Discontinue antiplatelet drugs if possible
2. Discontinue herbal supplements that may increase the risk of bleeding.
3. Medical and cardiac clearance for high-risk patients

OPERATIVE PERIOD

Anesthesia

1. General anesthesia is preferred for patient comfort and protection of the airway from active bleeding.
2. 1% lidocaine with 1:100,000 epinephrine:
   a. Transnasal injections provide hemostasis and hydrodissection, which assist in elevating bilateral submucoperichondrial and submucoperiosteal flaps.
3. Oxymetazoline nasal pledgets:
   a. Inserted into both nasal cavities for decongestive and hemostasis purposes
   b. Acceptable alternatives that are also used include 1:1000 epinephrine and topical 4% cocaine.

Positioning

1. The patient is positioned as in an endoscopic sinus procedure with the head elevated slightly and turned slightly toward the surgeon.

Perioperative Antibiotic Prophylaxis

1. First-generation cephalosporin
2. Clindamycin if allergic to penicillin

Monitoring

1. None necessary

Instruments and Equipment to Have Available

1. Basic endoscopic sinus surgery set
2. Septoplasty set
3. #15 blade
4. #12 blade
5. Extended, needle tip, monopolar cautery (tip bent to a 30-degree angle)
6. Acellular human dermis (AlloDerm, LifeCell) × 1
7. Silastic sheets (0.02-inch thick) × 2
8. 5-0 fat-absorbing gut 4-0 plain gut on a straight 11-mm needle
9. 3-0 nylon

Key Anatomic Landmarks

1. Middle turbinate pneumatization
   a. The transverse level at which the vertical lamella of the middle turbinate begins to broaden. This marks the limit of the superior incision of the nasoseptal flap. Incisions superior to this line may compromise olfactory function postoperatively.
2. Hasner valve
   a. Located within the inferior meatus on the lateral nasal wall. This marks the lateral limit of a nasal floor flap. Incisions superior to this may result in postoperative epiphora.

Prerequisite Skills

1. Endoscopic sinus surgery
2. Endoscopic septoplasty
3. Open rhinoplasty

Operative Risks

1. Failure of the repair
2. Enlargement of the perforation
3. Creation of a new perforation
4. Intranasal synechiae
5. Dysosmia
6. Epiphora
7. Bleeding
8. Infection/abscess

Surgical Technique

Many surgical techniques, each with its own advantages and disadvantages, have been published since the 1970s (Box 96.3).[2-9] Techniques can be categorized in several ways: open versus closed (endoscopic); unilateral intranasal flaps versus bilateral intranasal flaps; primary closure versus healing by secondary intention; use of interposition grafts versus not; and single-stage procedures versus multistage procedures. Intranasal mucosal flaps are quite useful but can be both complex to elevate and translocate for closure. These must be meticulously planned so as not to cause unintended bilateral devascularization of support-bearing portions of healthy septum. It is also important to understand the limits of the selected flaps to ensure that appropriate length and mobility may be achieved. Furthermore, many different interposition graft materials have been described and used. Common graft materials include autografts (septal bone, auricular cartilage), homografts including acellular dermis, xenografts (porcine submucosa, bovine pericardium), and synthetic materials such as polyglactin. Grafts may also be placed as composite grafts or single layer grafts based primarily on surgeon preference and technique.

Although there is no consensus on how best to repair nasal septal perforations, we advocate the use of bilateral intranasal mucosal flaps (we prefer to use a combination of superior and inferior advancement flaps on one side and an anterior ethmoidal artery based flap contralaterally[3]), tension-free mucosal closure, and incorporation of an interposition graft (acellular dermis).

1. Hemostasis and hydrodissection
   a. Inject both sides of the nasal septum in a submucoperichondrial and submucoperiosteal plane and the nasal floor bilaterally with 1% lidocaine with 1:100,000 epinephrine. Inject in a posterior to anterior direction to prevent visual obstruction due to bleeding. Use the "pull-flash" technique to prevent intravascular injection. The mucosa will elevate away from the underlying cartilage and bone and will blanch. Injections should be performed not only along septal mucosa but also in the region of the columellar artery (caudal septum) and floor/inferior meatus region if an inferior advancement flap is to be used. If an open rhinoplasty approach will be used, then infiltration appropriate for that procedure should also be performed. Wait 10 minutes after injection to maximize the effect of vasoconstriction.
2. Nasal decongestion
   a. Insert cotton pledgets soaked in oxymetazoline into both nasal cavities for hemostasis and decongestive purposes. Remove the pledgets after adequate mucosal decongestion is achieved (2 to 3 minutes).
3. Nasal cavity débridement
   a. Using a 0-degree rigid nasal endoscope, examine both nasal cavities and the perforation site. Débride any intranasal crusting or dried blood using straight forceps and/or a Frazier tip suction. Irrigation with warm 0.9% nasal saline (110°F) may help to loosen debris and control bleeding, if present.
4. De-epithelialization of the perforation margin
   a. Use a straight through-cutting instrument to de-epithelialize the posterior margin of the perforation; use a #12 blade or curved beaver blade in a posterior to anterior direction to de-epithelialize the superior and inferior margins; use a backbiting antrum punch (backbiter) to de-epithelialize the anterior margin. Failure to de-epithelialize the perforation margin will lead to flap failure. Note: Take care to minimize the enlargement of the perforation during this step.
5. Hemitransfixion incision
   a. A left hemitransfixion incision is made using a #15 blade as in a septoplasty.
   b. Dissect posteriorly above and below the perforation directly on the cartilage remnant.
   c. Slowly and gently sweep the Cottle elevator inferiorly and superiorly to separate the flaps from each other at the margin of the perforation. Note: Caution is required

BOX 96.3 Nasal Septal Perforation Repair Techniques

Approaches, repair techniques, and interposition graft material

1. Approaches
   a. Open approaches
      1) Open rhinoplasty approach
      2) Sublabial approach
      3) Midface degloving approach
   b. Closed approach
      1) Endoscopic approach
2. Repair techniques
   a. Bilateral intranasal flaps (with or without primary closure; with or without an interposition graft)
      1) Bilateral, single advancement flaps
         a) Superior releasing incision high in the nasal vault or an inferior releasing incision in the inferior meatus
      2) Bilateral, bipedicled, double advancement flaps
         a) Superior and inferior releasing incisions
      3) Bilateral, unipedicled, posterior based (posterior nasal artery), rotational flaps
      4) Nasal floor flap rotated superior-medially with a contralateral nasoseptal flap rotated inferiorly
      5) Bipedicled, double advancement flap with a contralateral unipedicled, inferior based (superior labial artery), rotational flap
      6) Bipedicled, double advancement flap with an ipsilateral hinged flap (posterior perforation rim based) that is rotated into the contralateral side
      7) Cross-steal technique
         a) A right flap above the perforation and hinged on the right superior perforation margin is rotated inferiorly into the left nasal cavity. A left flap below the perforation and hinged on the left inferior perforation margin is rotated superiorly into the right nasal cavity.
   b. Unilateral intranasal flap (with or without primary closure; with or without an interposition graft)
      1) Unilateral, single advancement flap
      2) Unilateral, bipedicled, double advancement flap
      3) Unilateral, unipedicled, posterior-based (posterior nasal artery), rotational flap
      4) Unilateral, unipedicled, inferior-based (superior labial artery), rotational flap
      5) Unilateral, unipedicled, superior-based (anterior ethmoid artery), rotational flap
      6) Inferior turbinate, anterior-based flap (two-stage procedure)
      7) Bullous middle turbinate flap (two-stage procedure)
      8) Facial artery musculomucosal (FAMM) flap
      9) Radial forearm free flap with anastomosis to the ipsilateral facial artery
      10) Fascia lata free flap with anastomosis to the ipsilateral facial artery
   c. Flapless closure
      1) Posterior septum resection
      2) Posterior perforation redraping
         a) Posterior perforation margin cartilage is trimmed. Local mucosa is used to redrape the posterior perforation margin.
      3) Backwards extraction-reposition technique of the quadrangular cartilage
      4) Septal cartilage remnant is removed and reinserted backwards
      5) AlloDerm interposition graft insertion
      6) Titanium mesh interposition graft insertion
      7) Temporalis fascia interposition graft insertion
      8) Inferior turbinate mucoperiosteal interposition graft insertion
      9) Conchal cartilage with bilateral periochondrium interposition graft insertion
      10) Conchal cartilage and bilateral temporalis fascia composite interposition graft insertion
      11) Polydioxanone (PDS) plate, temporoparietal fascia, and deep temporal fascia composite interposition graft insertion
      12) Oral mucosa and auricular perichondrocutaneous composite interposition graft insertion
      13) Auricular chondrocutaneous composite interposition graft insertion
3. Interposition Graft Material
   a. Allograph
      1) Acellular human dermis (AlloDerm, LifeCell)
   b. Implant
      1) PDS plate
      2) Bioactive glass
      3) Titanium mesh
      4) Polyethylene orbital implant (MEDPOR, Stryker)
   c. Xenograft
      1) Porcine small intestine mucosa

when elevating flaps in post-septoplasty patients because there will be scarring between both layers, thus increasing the risk of tearing the mucosa.

6. Anterior ethmoid artery flap, with contralateral advancement flaps
   a. Mucosal flap margins are inspected endoscopically and then incised using a needle-tipped monopolar cautery at a setting of 15. b. For the anterior ethmoid artery flap, two vertical incisions are made.
   b. The posterior incision starts 0.5 to 1.0 cm posterior to the middle turbinate axilla. The incision is carried inferiorly to the nasal floor. The incision then traverses laterally into the inferior meatus. Care must be taken not to incise through the delicate bony septum into the contralateral nasal cavity during this step.
   c. The anterior incision starts high in the nasal vault in the sagittal plane that passes through the posterior aspect of the perforation. This incision is extended to match the length of the posterior incision.
   d. The incisions are connected by a joining incision in a posterior to anterior direction within the inferior meatus.
   e. A Cottle elevator is used to elevate the mucosal flap in the correct plane.
   f. On the contralateral side, an inferiorly based flap and a superior advancement flap may be required to allow straight line closure across the perforation. The margins of these flaps vary based on perforation size; however, the concept is to allow transposition of the superior septal mucosa and inferior nasal floor mucosa toward one another to meet at the perforation.
   g. The superior releasing incision can be made high in the nasal vault anterior to the axilla of the middle turbinate; however, if the defect dictates releasing posterior to this, the superior limit should drop to the level of the axilla to avoid injuring the olfactory epithelium. Inferiorly, the releasing incision can be made in the inferior meatus just below the axilla of the inferior turbinate.

Note: Not every perforation requires both of these flaps, although many do. The inferior flap is preferred, given lower morbidity of the donor site and relatively quick healing. Again, it is useful to confirm that the incisions are through the mucosa by mobilizing the flap's edges with a Cottle elevator.

7. Interposition graft insertion
   a. Rehydrate a thick sheet (>1 mm) of acellular human dermis (AlloDerm, LifeCell), and insert it between the septal cartilage and the flaps.
   b. Be sure that the interposition graft covers the entire perforation with at least 1 cm of overlap if possible.
   c. Secure the graft to the nasal cartilage remnant using 4-0 plain gut on a straight 11-mm needle. Place interrupted "tacking" mattress sutures posteriorly, superiorly, and anteriorly to secure the graft and prevent movement during final closure.
8. Hemitransfixion incision closure
   a. Close with 5-0 fast-absorbing gut suture in an interrupted fashion.
9. Reapproximation of the flap
   a. The anterior ethmoid artery flap is then sutured into position at the anterior edge of the perforation, followed by superior and then inferior sutures. The contralateral flaps are then closed in straight-line fashion, with interrupted or running technique.
   b. The bipedicled flaps are then sutured transseptally using a quilting 4-0 plain gut suture.
10. Insertion of Silastic sheets
    a. Trim two Silastic sheets (0.02-inch thick), insert into both nasal cavities, and lay them against the nasal septum and on the nasal floor. The Silastic sheets should cover all closure sites, incisions, and areas of denuded cartilage and bone. This helps to retain moisture, which will aid in reepithelialization. Secure with two 3-0 nylon interrupted sutures superiorly and inferiorly. Silastic sheets are maintained for 3 weeks and removed in the office.

Common Errors in Technique

1. Inadequate de-epithelialization of the margins of the perforation
2. Failure to elevate the intranasal flaps in the submucoperichondrial or submucoperiosteal plane. This is particularly difficult in patients who have had a previous septoplasty.
3. Creating a short or narrow intranasal flap. Not accounting for flap contracture especially in the anteroposterior dimension
4. Not suturing the interposition graft to the septal cartilage remnant resulting in graft displacement during closure
5. Not suturing the free edges of the mucosa together

POSTOPERATIVE PERIOD

Postoperative Management

1. Pain medication
   a. Pain may be managed with oral opioids or acetaminophen. Nonsteroidal anti-inflammatory drugs should be avoided.
2. Anticoagulant/antiplatelet medication
   a. Patients on anticoagulation may resume treatment 24 hours after surgery.
3. Nasal saline irrigations
   a. Patients are instructed to irrigate both nasal cavities with 240 mL of nasal saline twice daily starting the morning after surgery. They will continue this through the postoperative period until nasal mucosal healing is completed.
4. Nasal saline sprays/gels
   a. Patients are instructed to use nasal saline or saline gel in both nostrils 3 to 4 times daily to provide nasal moisturization and promote healing.
5. Mupirocin nasal ointment
   a. Patients are instructed to apply the ointment to both nostrils twice daily to provide nasal moisturization and prevent localized infection.
6. Oral antibiotics
   a. A first-generation cephalosporin is used to cover for *Staphylococcus aureus* while the splints are in place.

Complications

1. Hemorrhage
   a. Early intraoperative identification, control with cauterization, warm water irrigation, thrombin base products, and nasal packing
2. Septal hematoma/abscess
   a. Early postoperative identification, drainage, and elimination of dead space with mattress sutures
3. Synechiae
   a. Early postoperative identification and lysis in the office
4. Dysosmia
   a. Avoid nasal septum mucosal injury superior to the middle turbinate pneumatization.
5. Epiphora
   a. Avoid lateral nasal wall injury superior to Hasner valve.
6. Infection
   a. Patients are treated with postoperative oral antibiotics, such as a first-generation cephalosporin while splints are in place.
7. Flap failure, worsening of the perforation, or creation of a new perforation
   a. Insertion of a nasal septal prosthesis
   b. Second repair attempt after 6 months of healing. Consider an open rhinoplasty approach for improved exposure if an endoscopic approach was attempted first.

Alternative Management Plan

1. Conservation management
   a. Nasal saline irrigations, nasal saline sprays, nasal saline gels, water-based emollients, room humidification, in-office débridement, nasal septal prosthesis

DISCUSSION

Evidence-Based Medicine Question

Are nasal septal perforations best repaired with bilateral intranasal flaps with an interposition graft?

The majority of publications on nasal septal perforation describe various closure techniques dependent on the author's preference. Very few studies, all with low power, directly compare the outcomes of different closure techniques. Despite this, the general consensus is that long-term closure is best achieved through primary closure using bilateral mucoperichondrial flaps and an interposition graft.

Editorial Comment

The repair of a septal perforation remains a challenging procedure despite improved visualization techniques and biomaterials to support the reconstruction. The relative paucity of reconstructive tissue within the nose and the constant airflow dynamics are barriers to successful repair. Before any decision is made to undertake the repair of a septal perforation,

underlying conditions, such as autoimmune disease, repeated digital trauma, and the use of intranasal illicit drugs, must be controlled. In addition, prior surgical attempts can further limit the reconstructive options and should be considered before revision surgery. Finally, the benefits of the reconstruction must also be balanced against the drawbacks of the repair, namely the potential for worsening nasal airflow. Despite these challenges, successful repair of septal perforation can greatly reduce or eliminate noisy nasal breathing, epistaxis, and nasal crusting, resulting in a significant improvement in the patient's quality of life. As with any fistula closure, the use of opposing mucosal vascularized flaps, watertight interpositional grafts, and meticulous soft tissue handling optimize the chances of success.

Eric W. Wang


Access the review questions online at http://www.expertconsult.com

REFERENCES

1. Kridel RW. Considerations in the etiology, treatment, and repair of septal perforations. Facial Plast Surg Clin North Am 2004;12(4):435–450.
2. Andre RF, Lohuis PJ, Vuyk HD. Nasal septum perforation repair using differently designed bilateral intranasal flaps with nonopposing suture lines. J Plast Reconstr Aesthet Surg 2006;59(8):829–834.
3. Castelnuovo P, Ferreli F, Khodaei I, et al. Anterior ethmoid artery septal flap for the management of septal perforation. Arch Fac Plast Surg 2011;13(6):411–414.
4. Friedman M, Ibrahim H, Ramakrishnan V. Inferior turbinate flap for repair of nasal septal perforation. Laryngoscope 2003;113(8):1425–1428.
5. Kim SW, Rhee CS. Nasal septal perforation repair: predictive factors and systemic review of the literature. Curr Opin Otolaryngol Head Neck Surg 2012;20(1):58–65.
6. Kridel RW, Foda H, Lunde KC. Septal perforation repair with acellular human dermal allograft. Arch Otolaryngol Head Neck Surg 1998;124(1):73–78.
7. Raol N, Olson K. A novel technique to repair moderate-sized nasoseptal perforations. Arch Otolaryngol Head Neck Surg 2012;138(8):714–716.
8. Romo III T, Sclafani AP, Falk AN, et al. A graduated approach to the repair of nasal septal perforations. Plast Reconstr Surg 1999;103(1):66–75.
9. Watson D, Sarkdull G. Surgical management of the septal perforation. Otolaryngol Clin North Am 2009;42(3):483–493.

REVIEW QUESTIONS

1. Components of the nasal septum include all of the following, except
   a. Quadrangular cartilage
   b. Perpendicular plate of the ethmoid
   c. Nasal bone
   d. Vomer
   e. Maxillary crest

2. The nasal septum is vascularized by all of the following, except
   a. Anterior ethmoid artery
   b. Posterior ethmoid artery
   c. Superior labial artery
   d. Inferior palatine artery
   e. Sphenopalatine artery

3. Nasal septal perforation treatment strategies include all of the following, except
   a. Nasal saline sprays/gels
   b. Petroleum-based ointments
   c. Nasal septum prosthesis
   d. Intranasal pedicled flaps
   e. A and B

4. The most common cause of nasal septal perforations is:
   a. Chronic nose picking
   b. Intranasal medications/drugs
   c. Collagen vascular disease
   d. Septal hematoma
   e. Iatrogenic

5. Although there is no consensus on how to best repair nasal septal perforations, high closure rates have been achieved through:
   a. Unilateral flap with primary closure and contralateral healing by secondary intent
   b. Bilateral flaps with primary closure and incorporation of an interposition graft
   c. Use of an interposition graft only
   d. A and B
   e. All of the above

97 Surgery of the Turbinate

Bradley A. Otto, Christie Barnes

INTRODUCTION

Surgical therapy for the inferior or middle turbinates is most commonly indicated in the setting of turbinate hypertrophy and chronic nasal obstruction that has failed to improve with medical therapy. Surgery of the turbinate may be an isolated stand-alone procedure or carried out in conjunction with a nasal septoplasty in which compensatory inferior turbinate hypertrophy may be present on the concave side of a significantly deviated septum.

Abnormally large turbinates may be related to anatomic variance or due to pathophysiology, such as rhinitis or rhinosinusitis. The goals of turbinate surgery should include not only the improvement of nasal airflow but also the maintenance of normal physiology. Hence surgery should be performed in a manner that preserves the ability of the turbinate to condition inspired and expired air, assist in mucociliary flow, and sense nasal airflow.

One area of concern in turbinate surgery is overresection of the turbinates. This is theorized, though not proven, to damage the perception of airflow, possibly by disrupting innervation and mucosal surface receptors. This may result in the subjective paradoxical experience of nasal obstruction in an objectively widely patent nasal cavity, otherwise referred to as "empty nose" syndrome. Hence mucosal sparing techniques should be used whenever possible.

Many techniques have been described for reduction of the inferior turbinate, including diathermy, radiofrequency ablation (RFA), partial and complete turbinectomy, submucosal resection, and powered submucosal resection. The last is our preferred method.

Middle turbinate surgery may be necessary as part of a procedure to address nasal airway obstruction in the case of a concha bullosa and may also be necessary as a key complementary component of nasal septoplasty, as a large concha can prevent efforts to correct a septal deviation. In some cases, a large concha bullosa may be dissected to improved access to the uncinate process and ethmoid bulla during sinus surgery.

KEY OPERATIVE LEARNING POINTS

1. Nasal airflow studies have revealed that the majority of airflow occurs along the middle of the nasal cavity, across the superior surface of the inferior turbinate and body of the middle turbinate into the nasopharynx.
2. There appear to be marked changes in turbulent flow, negative pressure, and maximum shear stress in patients with turbinate hypertrophy in studies of nasal computational fluid dynamics.
3. Subjective nasal obstruction may not correlate with objective obstruction. The reverse is also true. Surgery to reduce turbinates in an already objectively patent airway is not likely to benefit patients with subjective obstruction. In such cases, an alternative etiology, such as nasal valve collapse, should be sought. Furthermore, especially in patients who have undergone multiple previous procedures, somatization or psychosocial issues that might contribute to the patient's complaints should be considered. In these situations, demonstrating to the patient an objectively patent airway, either with acoustic rhinometry or video endoscopy, may be of benefit. In addition, a lack of response to nasal decongestants may also help to convince this patient of the baseline patency of his or her nasal airway.
4. There are multiple techniques for reduction of the inferior turbinates, but there is no universally accepted best method. Contemporary methods of turbinate reduction should maintain a functional mucosal surface that conditions inspired and expired air and senses airflow.
5. Overresection of the inferior turbinate mucosa may lead to significant bony exposure with excessive crusting or could place the patient at risk for empty nose syndrome.
6. The approach to the patient with nasal obstruction should include an assessment of the external nasal framework, inferior turbinates, middle turbinates, and nasal septum.
7. It is essential to respect the uncinate process and ethmoid bulla during lateral laminectomy of a concha bullosa in order to prevent iatrogenic sinus disease.
8. Medial laminectomy has been demonstrated to be as effective as lateral laminectomy for aeration of the middle turbinate (i.e., a concha bullosa).[1]
9. Olfactory epithelium may be more prevalent on the lateral aspect rather than the medial aspect of a concha bullosa.

PREOPERATIVE PERIOD

History

1. History of present illness
   a. Is the nasal obstruction fixed or variable? Fixed obstruction may occur in the setting of severe septal deviation or hypertrophy of the inferior turbinate, nasal polyps, or tumor. Variable obstruction may occur due to the same factors already noted in less severe form, such that the nasal cycle and positioning of the patient contribute to further compromise of the nasal airway in varied proportions. Patients in whom obstruction is worse when the patient is supine likely are experiencing an increase in the size of the inferior turbinates due to sinusoidal engorgement, suggesting that turbinate hypertrophy is contributing to obstructive nasal symptoms. Variable obstruction may also be related to the intensity with which air is inspired. Patients with nasal valve collapse may complain of nasal obstruction that is most bothersome during more intense inspiration, such as sniffing or during exercise.
   b. Is the nasal obstruction unilateral or bilateral? If unilateral, which side? Unilateral nasal obstruction may be related to the etiologies already described. In some cases septal deviation toward the side of the complaint may be the underlying etiology. However, compensatory hypertrophy of the inferior turbinate contralateral to the side of a septal deviation may also be significant enough that it contributes to a perception of unilateral nasal congestion contralateral to the side of the deviation. In such cases, the obstruction may be more dynamic, with fluctuations in severity related to the nasal cycle. The patient with unilateral nasal obstruction, especially if new

and associated with epistaxis, deserves special attention in order to rule out neoplasia as the etiology.
   c. What are the aggravating factors? Nasal obstruction that worsens when the patient is supine may be related to turbinate hypertrophy, as noted earlier.
   d. What are the alleviating factors? Nasal obstruction that improves with topical decongestants may suggest that turbinate reduction should be a part of the overall surgical strategy, particularly soft tissue submucosal resection. Patients for whom external nasal manipulation has helped (tip elevation, Breathe-Right Strips, nasal cones) may benefit from alternative or complementary techniques that address the external nasal framework and/or nasal valves.
2. Past medical history
   a. Prior or current medical treatment:
      1) As noted earlier, the use of topical decongestants and the perceived efficacy by the patient give insight into the potential success of turbinate surgery.
      2) It is important to review the physician-directed medical therapy the patient has completed up to this point. It is prudent to first perform a trial of topical and/or oral therapy, as success with such medications may allow the patient to avoid surgery.
   b. Comorbid disorders
      1) Certain disorders, such as allergic rhinitis, contribute to nasal obstruction due to mucosal edema. Failure to appropriately manage comorbid inflammatory conditions with medication may decrease the long-term efficacy of nasal airway surgical procedures.
      2) See Box 97.1 for a list of some contributors to nasal obstruction that may require medical therapy in addition to surgical intervention.
   c. Vasculitis or other inflammatory conditions that affect mucosal integrity
      1) These patients may require more delicate dissection and resection to prevent tearing and bony exposure. Because of their underlying medical condition, these patients may be at risk for significant crusting.
3. Surgery
   a. Previous turbinate or other nasal airway surgery
      1) It is important to identify the specific procedures previously performed and to determine the perceived degree and period of efficacy experienced by the patient.
4. Medications
   a. Antiplatelet and anticoagulant medications should be identified. Decisions related to temporary suspension of these medications should be made in consultation with the prescribing physician.
   b. Herbal products that might lead to excessive bleeding, such as ginkgo biloba or ginseng, should be discontinued prior to surgery.
   c. In patients with rhinitis medicamentosa, discontinuing topical decongestants prior to surgery, with the addition of topical and/or oral steroids as a method to aid in weaning, might help improve efficacy of the topical decongestants used on the day of surgery.

BOX 97.1 Comorbidity Associated With Nasal Obstruction

1. Allergic rhinitis
2. Chronic rhinosinusitis
3. Mucositis related to chemotherapeutic drugs
5. Nasopharyngitis and/or adenoid hypertrophy
6. Nonallergic rhinitis
7. Rhinitis medicamentosa
8. Vasculitis and granulomatous disorders

Physical Examination

1. Observe restful and exaggerated inspiration. This may help to determine if dynamic nasal valve collapse contributes to the patient's nasal obstruction.
2. Perform an anterior rhinoscopy. This allows for assessment of the caudal septum and columella as well as the anterior nasal cavity structures, including the nasal valve.
3. Perform a sinonasal endoscopy. This procedure allows for a more detailed evaluation of the sinonasal cavity and the nasopharynx. Evaluate for concha bullosa, posterior septal deviation or spurs, nasal polyps, nasopharyngeal lesions or tumors, or other pathologic process that may contribute to nasal obstruction.
4. Examine the oral cavity. This may reveal other causes for generalized airway obstruction and snoring, such as tonsillar hypertrophy. Occasionally antrochoanal polyps will be visible on oropharyngeal examination.
5. See Table 97.1 for a list of some of the causes of nasal obstruction.

Imaging

- When surgery solely for the purposes of relieving nasal obstruction is being considered, imaging is generally not necessary.
- In certain situations, a maxillofacial computed tomography (CT) scan may aid in the accurate diagnosis of disorders such as chronic rhinosinusitis, which may contribute to nasal obstruction and other associated symptoms.

Indications

Inferior Turbinate

- Nasal obstruction due to hypertrophy of the inferior turbinate

Middle Turbinate

- Large concha bullosa causing nasal obstruction
- Large concha bullosa with obstruction of the ostiomeatal complex

Contraindications

1. Medical comorbidities with unacceptable risk for elective surgery
2. Previous turbinate surgery resulting in adequate objective nasal airway parameters but with subjective nasal obstruction. These patients likely suffer from a lack of sensation (empty nose syndrome) or other disorders, as noted earlier, rather than nasal obstruction.

TABLE 97.1 Causes of Nasal Obstruction

Common	Uncommon
Benign tumors	Adenoid hypertrophy
Inferior turbinate hypertrophy	Foreign body
Large concha bullosa	Malignant tumors
Nasal polyps	Septal abscess
Nasal valve collapse	Septal body edema
Septal deviation	Septal hematoma
	Synechiae (postsurgical, post-trauma, or disease-related)

3. The presence of sinonasal malignancy should warrant primary treatment of the tumor.

Preoperative Preparation

1. Institute a trial of medical therapy including management of comorbid disease that could contribute to nasal congestion.
2. Discontinue medications that could interfere with hemostasis as deemed appropriate via consultation with the prescribing physician.

OPERATIVE PERIOD

Anesthesia

- Submucosal resection of the turbinates, either with the microdébrider or through-cutting instruments, is best performed under general anesthesia. This optimizes patient comfort and protection of the airway.
- Awake sedation may be an option for less invasive procedures associated with minimal risk of hemorrhage, such as submucosal coblation. This may be best performed in the operating theater (monitored anesthesia care) in order to manage the airway optimally in the event of brisk bleeding and/or airway compromise due to the level of sedation.
- Local anesthesia may be an option for less invasive procedures associated with minimal risk of hemorrhage, such as submucosal coblation. In this situation, the patient should have full faculty to maintain a sufficient airway in the event of brisk bleeding.

Positioning

- The most appropriate position depends on the surgical technique and anesthetic used.
- For patients undergoing submucosal resection of the inferior turbinates or middle turbinate surgery, through-cutting instruments or a microdébrider may be used with the patient in the supine position and under general anesthesia.
- The beach-chair position may be an option in procedures performed with awake sedation or in-office procedures using local anesthesia.
- The sitting position may also be an option for patients having procedures using local anesthesia only.

Perioperative Antibiotic Prophylaxis

- Antibiotic prophylaxis is not definitively indicated for turbinate surgery without the use of packing material or splints.[2] If antibiotics are utilized, a first-generation cephalosporin (or clindamycin for penicillin-allergic patients) is appropriate.

Monitoring

- No monitoring specific to turbinate surgery is required.

Instruments and Equipment to Have Available

1. For inferior turbinate submucosal resection:
   a. Sharp-tipped periosteal elevator or scalpel to make initial incision (some prefer to use a needle-tip electrocautery needle)
   b. Elevator for submucoperiosteal elevation (the authors prefer a Cottle elevator)
   c. Through-cutting instruments (to remove turbinate bone if required)
   d. Microdébrider with 3.5-mm or smaller blades (turbinate-specific blades that are 2.9-mm in diameter may be used)
   e. Frazier tip suction
   f. Electrocautery on standby for hemostasis
   g. 0- and 30-degree endoscopes and camera
2. For middle turbinate surgery:
   a. Sickle knife to pierce middle turbinate
   b. Turbinate scissors
   c. Through-cutting forceps
   d. Microdébrider
   e. Cautery on standby for hemostasis
   f. Endoscopes and camera

Key Anatomic Landmarks

Inferior Turbinate

- Anterior head of the inferior turbinate. This forms the inferior portion of the internal nasal valve (INV). Hypertrophy of this portion of the inferior turbinate can significantly affect airflow, as the INV is the most restricted area of the nasal cavity. Hence appropriate reduction in this region can significantly affect airflow.
- Turbinate bone
- Path of the inferior turbinate branch of the posterior nasal artery. The arteries generally pass within the bone or in a mixed pattern within bone and submucosa in the majority of cases. The inferior aspect of the turbinate is comparatively void of major vessels.

Middle Turbinate

- Hiatus semilunaris and the associated uncinate process and ethmoid bulla. Minimal disruption of the ostiomeatal complex during removal of the lateral aspect of a concha bullosa will help maintain proper physiology of the middle meatus (Fig.97.1).

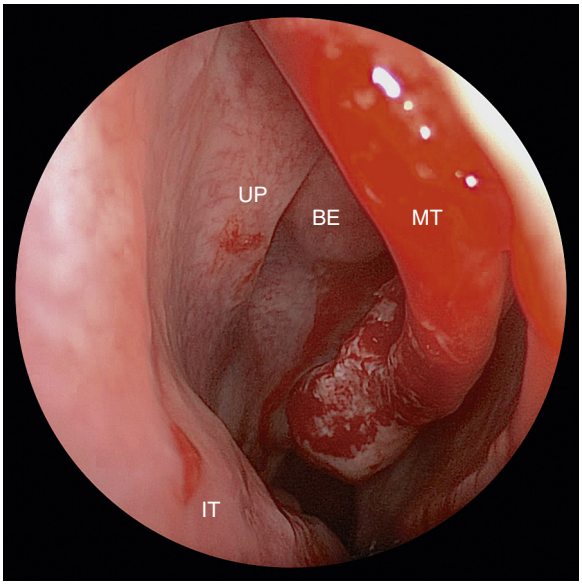

Fig. 97.1. Salient anatomy related to middle turbinate (MT) surgery. The lateral aspect of the right concha bullosa has been resected. Care should be taken to avoid damage to the uncinate process (UP) and bulla ethmoidalis (BE) in order to preserve the functional integrity of the hiatus semilunaris and ethmoid infundibulum. *MT*, middle turbinate, *IT*, inferior turbinate.

- Cribriform plate. It is essential to maintain visualization of and respect for the cribriform plate during resection of the concha bullosa in order to avoid damage to the horizontal or vertical plate of the cribriform plate with an associated leak of cerebrospinal fluid.
- The basal lamella of middle turbinate serves as a general landmark for the posterior limit of conchal dissection.

Prerequisite Skills

- Basic endoscopic sinus surgery skills. Although inferior turbinate surgery may be performed using a nasal speculum and headlight, we prefer to use endoscopes for optimal visualization of the turbinate tissue and surrounding structures.
- Epistaxis management skills

Operative Risks

Inferior Turbinate

- Intraoperative hemorrhage. This can be addressed with packing and/or selective cautery.
- Although rare, injury to the nasolacrimal duct can occur if the lateral wall of the inferior meatus is damaged 30 to 40 mm posterior to the nasal sill.
- Through-and-through injury to inferior turbinate: If this occurs, it may create a hole or window through which a patient may experience whistling and/or crusting. This can be avoided with careful dissection and judicious use of the microdébrider.

Middle Turbinate

- Avulsion of the middle turbinate from its attachment at the skull base during concha bullosa surgery can cause a leak of cerebrospinal fluid.
- Mucosal injury to the hiatus semilunaris, uncinate process, or ethmoid bulla can create synechiae and disrupt the maxillary sinus ostium or infundibulum, resulting in sinusitis.

Surgical Technique

Decongestion and Vasoconstriction

- Topical application of 0.05% oxymetazoline hydrochloride helps to decongest nasal tissue and aids in visualization.
- Injection of 1% lidocaine with 1:100,000 epinephrine helps with vasoconstriction. We prefer to inject the inferior turbinate along its inferomedial surface and at the anterior tip. The middle turbinate is usually injected near the anterior axilla, along the anterior face, and posteriorly at the inferior aspect of the basal lamella.

Inferior Turbinate Reduction: Surgical Technique

Incision and Elevation

- Use the sharp end of a Molt elevator or scalpel to make a stab incision in the anterior inferior turbinate at the level of the attachment to the lateral nasal wall. Some prefer to use a needle-tipped electrocautery device or turbinate-specific microdébrider blade to do this.
- Elevate the mucosa away from the medial, inferior, and superior aspects of the inferior turbinate.
- The turbinate bone is often irregular, and use of the endoscope to visualize the elevating instrument is critical at all times.

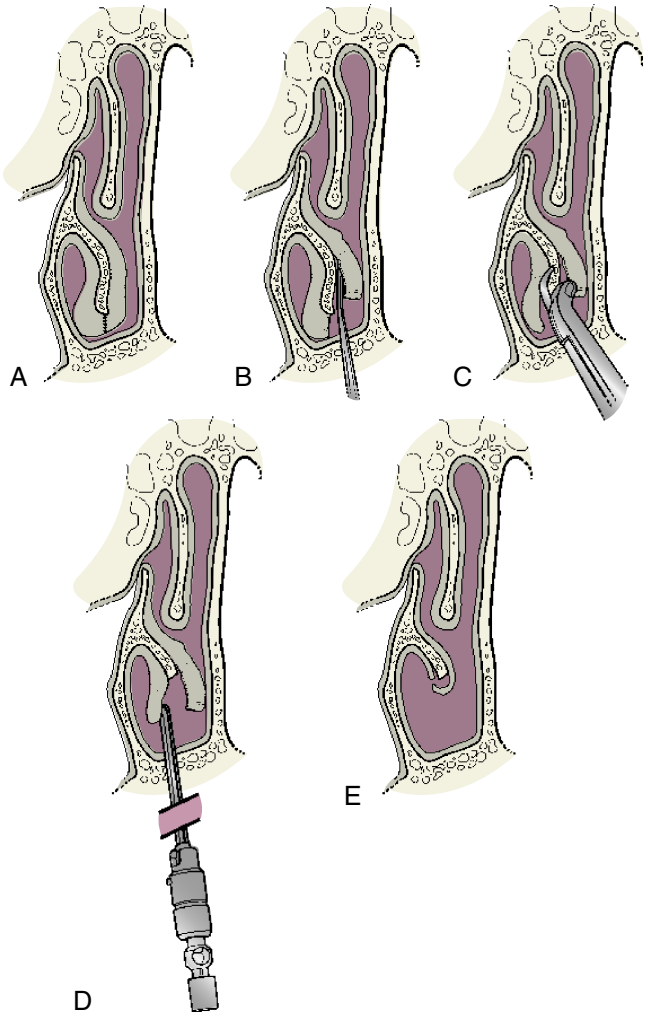

Fig. 97.2. A, Incision in the mucosa of the turbinate. **B,** The mucosa is elevated off the turbinate bone. **C,** The bone is removed with biting forceps. **D,** A microdébrider is used to remove the lateral wall. **E,** The medial mucosa is rolled laterally.

- While the mucoperiosteum is being elevated away, the bone may be outfractured as the dissection proceeds posteriorly. This helps to improve visualization for the remainder of the procedure.
- A turbinate-specific microdébrider blade may also be used to elevate in the submucosal plane.

Submucosal Resection

- Once the submucosa is elevated along the length of the turbinate, a 3.5-mm or smaller microdébrider blade is inserted into the trough thus created.
- The redundant mucosa laterally and/or bone is removed, ensuring that the blade is well visualized as it moves beneath the mucosal surface.
- If more aggressive turbinate reduction is required, the lateral mucoperiosteum of the anterior aspect of the inferior turbinate may be removed along with the bone. In these cases, it is usually more efficient to remove the bony aspect of the turbinate with through-cutting instruments. The medial mucoperiosteum may then be draped laterally to cover abraded tissue.
- See Fig.97.2.
- See Video 97.1: Inferior turbinate submucosal resection technique.

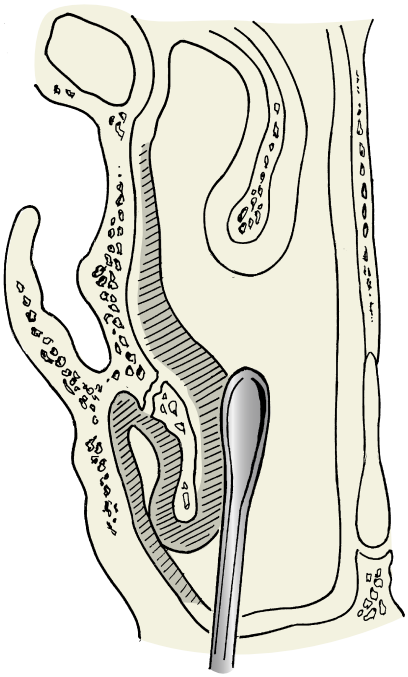

Fig. 97.3. Outfracture of a prominent inferior turbinate.

Outfracture

- With the use of an elevator or septal displacer, the turbinate may be outfractured. This maneuver is usually made easier when the turbinate has previously been outfractured from within the submucoperiosteal plane during the elevation phase, as noted previously. This maneuver should also be performed under direct visualization (Fig. 97.3).

Splint Placement

- If desired, splints may be placed to buttress the inferior turbinates.

Surgical Technique for Resection of the Concha Bullosa

Incision

- A sickle knife is used to incise the anterior head of the turbinate into the inner airspace of the concha bullosa. This is done lateral to the medial vertical attachment of the turbinate to avoid any torque at the cribriform plate.
- In cases where the airspace is more posterior, a lateral or medial insertion point may be required.
- The incision is then lengthened superiorly and inferiorly.

Removal

- Using a combination of through-cutting instruments and/or a microdébrider, the lateral or medial aspect of the concha bullosa is removed. This may be done in a piecemeal fashion, or a dominant portion may be removed via superior and inferior cuts extended in a posterior direction along the medial or lateral layer of the concha bullosa.
- The basal lamella serves as a general landmark for the posterior limit of dissection.
- When the lateral aspect of the concha bullosa is being removed, care should be taken to prevent damage to the uncinate process and ethmoid bulla. This may be facilitated by using a blunt elevator to gently infracture the lateral lamella of the concha bullosa as dissection proceeds posteriorly.
- The microdébrider is used to remove any free edges made by the cutting instruments.

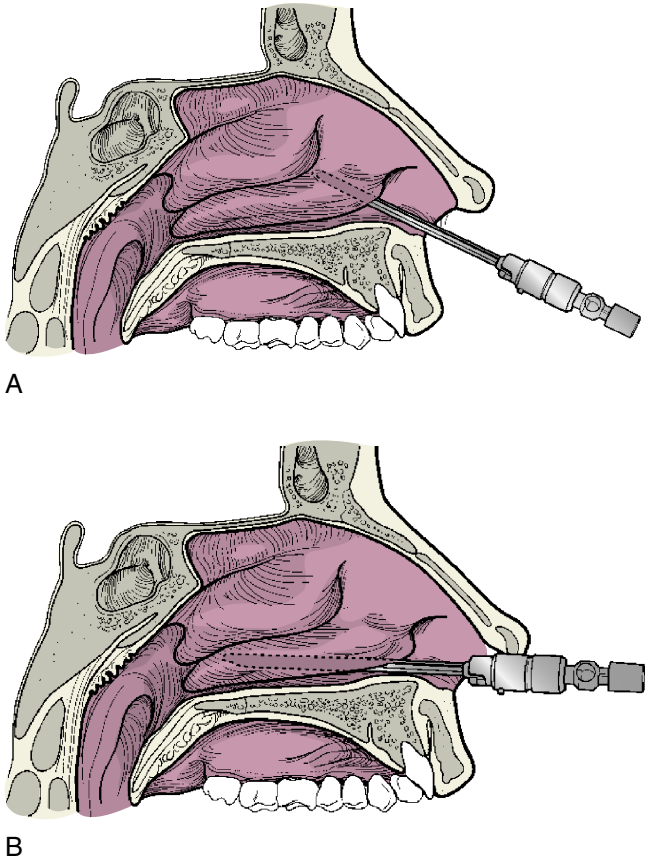

Fig. 97.4. **A,** A microdébrider is inserted into the inferior turbinate, inappropriately angled so that it will potentially go through inferior turbinate superiorly and engage middle turbinate. **B,** The microdébrider is inserted correctly into inferior turbinate pocket, minimizing risk of injury to the middle turbinate.

Common Errors in Technique

1. Inadequate removal of tissue (bony or soft) will lead to persistent nasal obstruction. In cases where the turbinate is very large, it may be necessary to conservatively remove the antero-lateral aspect of the turbinate, as noted previously.
2. Perforation of the mucosa is usually due to overresection or incorrect positioning of the microdébrider blade. It may also be due to inadequate elevation of the submucosal flap, which can lead to bleeding or crusting.
3. Perforation of the inferior turbinate can occur if the dissection is extended too far superiorly, leading to damage of the middle turbinate (Fig. 97.4).

POSTOPERATIVE PERIOD

Postoperative Management

- Pain management is usually easily achieved with a low-dose opioid or acetaminophen. Nonsteroidal anti-inflammatory drugs such as ibuprofen may be administered starting on postoperative day 7.

- Irrigation with saline solution helps to keep the nasal passages and/or splints clear of loose mucus, debris, and clot.
- If splints are being used for inferior turbinate surgery or concomitant septal surgery, we prefer to remove them on postoperative day 3 to 5 in most cases. We prefer to use splints to help minimize venous congestion and edema in the early postoperative period.

Complications

Inferior Turbinate

- Hemorrhage
  This may occur at the incision site or at sites of mucosal disruption, particularly at the posterior mulberry tip, as this is at high risk of bleeding. Intraoperatively, this may be controlled with pressure or selective electrocautery. Postoperative hemorrhage can usually be controlled in the office using targeted absorbable packing or cautery. Early studies suggest that this is the most common complication, in the range of 10%, followed closely by the formation of synechiae in 2.9% to 8.6% of cases.[3]
- Synechiae
  This complication is more common when the turbinate surgery is done in conjunction with septoplasty and there are apposing areas of excoriation that heal together. It is usually addressed with lysis of the adhesion in the office using topical or local anesthesia.
- Acute bacterial sinusitis
  This may be idiopathic or may occur if the superior aspect of the inferior turbinate is violated and the dissection continues into the middle meatus, leading to scarring and obstruction. Antimicrobial therapy is indicated. Endoscopically guided cultures may help guide antibiotic choice.
- Injury to the lacrimal duct
  This may occur if dissection extends beyond the lateral aspect of the inferior turbinate into the inferior meatus and lateral nasal wall. Dacryocystorhinostomy may be necessary and should be considered after referral to an Ophthalmologist.
- Empty nose syndrome
  With the use of contemporary techniques, this is an uncommon but potentially devastating complication of nasal airway surgery, characterized by diminished or absent sensation of airflow. Treatment is controversial and is beyond the scope of this chapter.

Middle Turbinate

- Hemorrhage
  This is uncommon but may occur along incision sites or from the middle turbinate branch of the sphenopalatine artery if exposed. Intraoperatively, this may be controlled with pressure in the form of Afrin-soaked pledgets or selective cautery.
- Synechiae
  This is an uncommon complication that is usually addressed with lysis of the adhesion in the office under topical anesthesia. Synechiae to the lateral nasal wall may lead to iatrogenic rhinosinusitis.
- Acute bacterial sinusitis
  As noted earlier, this may occur due to contamination during surgery or as a sequela of synechiae. It is treated in the same manner as described for the inferior turbinate.
- Leak of cerebrospinal fluid
  This may occur secondary to avulsion of the middle turbinate or if dissection is carried too superiorly on the middle turbinate. It should be repaired immediately with appropriate endoscopic techniques.

Alternative Management

- Medical management of concomitant inflammatory conditions, such as chronic rhinitis, should be undertaken prior to surgery. If effective, this is an excellent alternative to surgery.
- Immunotherapy may suffice in patients with significant allergic rhinitis.

DISCUSSION

Evidence-Based Medicine Question

Of the techniques used to address the inferior turbinate for the purposes of improving nasal airflow, which is best?

Alternative Inferior Turbinate Resection Techniques

The ideal inferior turbinate reduction procedure has enduring results, minimal side effects, and is straightforward to perform. No universally accepted consensus exists regarding a single approach to achieve these goals.

As noted by other authors, the sheer fact that multiple techniques exist without a clear preferred method points to no ideal technique without short- and long-term complications. It is felt that failures of inferior turbinate procedures may not be due to cross-sectional widening of the airway, as all techniques potentially do, but rather to mucosal dysfunction following the procedure.

Long-Term Results

Of the described techniques, submucosal resection has the best reported long-term results.[3,4] Partial turbinectomy has fallen out of favor due to potential devastating postoperative complications. Approaches that use diathermy or coagulation—such as laser, cryotherapy, coblation, radiofrequency ablation (RFA), and cautery—have poorer long-term rates of symptomatic control.[3-5]

Mucosal Function

Total and to some degree partial turbinectomies have fallen out of favor due to damage to the conditioning functions with these procedures, which may increase the risk for postoperative atrophic rhinitis. Submucosal turbinate reduction has been shown to lead to normalization of saccharin transit time at 6 months postoperatively, which is sustained to 3 years.[4] Additionally there have been histopathologic studies and mucociliary function testing with radiofrequency ablation and coblation that have demonstrated a negative impact on the postoperative function of the inferior turbinate.[3-5] Laser and ultrasonic bone aspirators still require further investigation into long-term, objective, and histopathologic findings.

Complications

Procedures involving the removal of mucosa not only increase risk of damage to function of the turbinate but also have potentially higher rates of bleeding and the formation of synechiae. Early reports of complications have noted higher rates of epistaxis and synechiae with partial and total inferior turbinoplasty than with submucosal procedures.

In summary, of the techniques described for inferior turbinate reduction, submucosal turbinate reduction has the desirable components of mucosal preservation, a low complication rate, and superior long-term results and, as a result, is our preferred technique.

Editorial Comment

Several techniques are advocated for reduction of the inferior turbinate. In appropriately selected patients, the procedure can be highly effective in relieving nasal obstruction due to hypertrophy of the inferior turbinate. Controversy still exists regarding the best technique, although preliminary studies suggest that submucosal resection is more effective in long-term symptomatic control compared with radiofrequency coblation, as discussed in this chapter. Techniques designed to spare the mucosa, careful preservation of the anterior head of the inferior turbinate, and avoidance of cautery are important to prevent injury to the cilia and maintain the important functions of the nasal cavities. The authors provide practical guidance regarding patient selection, preparation, and technique to perform safe and effective surgery involving the turbinates.

Stella E. Lee


Access the review questions and additional sources list online at
http://www.expertconsult.com

REFERENCES

1. Kumral TL, Yıldırım G, Çakır O, et al. Comparison of two partial middle turbinectomy techniques for treatment of concha bullosa. Laryngoscope 2015;125:1062–1066.
2. Smith EJ, Stringer S. Current perioperative practice patterns for minimizing surgical site infection during rhinologic procedures. Int Forum Allergy Rhino 2014;l4(12):1002–1007.
3. Brunworth J, Holmes J, Sindwani R. Inferior turbinate hypertrophy: review and graduated approach to surgical management. Am J Rhinology 2013;27:411–415.
4. Bhandarkar ND, Smith TL. Outcomes of surgery for inferior turbinate hypertrophy. Curr Opin Otolaryngol Head Neck Surg 2010;18(1):49–53.
5. Ye T, Zhou B. Update on surgical management of adult inferior turbinate hypertrophy. Curr Opin Otolaryngol Head Neck Surg 2015:1–5.

REVIEW QUESTIONS

1. What is the most common complication following turbinate reduction?
   a. Hemorrhage
   b. Hyposmia
   c. Atrophic rhinitis
   d. Nasolacrimal duct obstruction

2. Which of the following techniques has been found to have the best long-term results in terms of improving the nasal airway?
   a. Partial turbinectomy
   b. Radiofrequency ablation
   c. Submucosal resection
   d. Laser resection
   e. a and c
   f. Evidence is still lacking in this area, more studies are needed

3. A postoperative inferior turbinoplasty patient seen 2 weeks following the procedure complains of left maxillary sinus pressure, discolored postnasal drainage, and cough. Which of the following errors may have contributed to this uncommon postoperative complication?
   a. Avulsion of the middle turbinate
   b. The ostiomeatal complex has been injured, leading to acute bacterial rhinosinusitis (ABRS)
   c. Dissection into the inferior meatus
   d. Electrocautery to the mulberry tip
   e. Submucosal coblation

4. In which situation is a CT scan most likely to be of benefit to a patient considering inferior turbinate reduction surgery?
   a. To evaluate for posterior septal deviation that may contribute to nasal obstruction
   b. To evaluate the posterior aspect of the turbinate tissue
   c. To evaluate for chronic rhinosinusitis in a patient with nasal obstruction and other symptoms suggestive of chronic rhinosinusitis for whom nasal endoscopy is negative for signs of rhinosinusitis
   d. To evaluate adenoid hypertrophy

5. In which of the following circumstances is management of the middle turbinate indicated?
   a. Large concha bullosa with nasal obstruction
   b. Paradoxically curved middle turbinate
   c. Large bilateral concha bullosa
   d. Large concha bullosa with obstruction of the middle meatus
   e. Both b and c
   f. Both a and d

ADDITIONAL SOURCES

Acevedo JL, Camacho M, Brietzke SE. Radiofrequency ablation turbinoplasty versus microdebrider-assisted turbinoplasty: a systematic review and meta-analysis. Otolaryngol Head Neck Surg 2015;153(6):951–956.
Scheithauer MO. Surgery of the turbinates and "empty nose" syndrome. GMS Curr Top Otorhinolaryngol Head Neck Surg 2010;9. Doc03.

98 Sphenopalatine Artery Ligation for Epistaxis

Carl H. Snyderman, Aron Z. Pollack

INTRODUCTION

Most episodes of epistaxis are minor and self-limited and originate in the anterior nasal cavity. Posterior epistaxis, however, can be life threatening and is usually associated with bleeding from branches of the sphenopalatine artery (SPA). Rarely, the ethmoidal arteries or internal carotid artery (ICA) may be a source of severe epistaxis. Proper evaluation of the patient can usually reveal the source of the bleeding and identify contributing factors. Treatment options for severe epistaxis include nasal packing (anterior and posterior), angiography with embolization of branches of the external carotid artery, or surgical ligation/cauterization of the sphenopalatine artery and/or the anterior and posterior ethmoidal arteries. In comparison to nasal packing, surgical ligation is better tolerated and more cost-effective. Angiography with embolization is almost as effective as surgical ligation but cannot address the ethmoidal arteries and has significant potential risks (blindness, stroke, internal carotid injury). Although surgical ligation of the terminal branches of the SPA can be performed using open or endoscopic techniques, endoscopic ligation is the preferred technique. Ligation of the anterior ethmoidal artery (AEA), whether endoscopic or open via a Lynch incision, can be performed at the same time if necessary. The posterior ethmoid artery is rarely, if ever, the source of significant bleeding.

KEY OPERATIVE LEARNING POINTS

1. The sphenopalatine foramen is located at the posterosuperior corner of the maxillary sinus deep to the posterior attachment of the middle turbinate.
2. The SPA frequently branches proximal to the sphenopalatine foramen and may exit through separate foramina.
3. A maxillary antrostomy can facilitate exposure of the SPA and provides additional space for instrumentation.
4. The SPA can be occluded by bipolar electrocautery or placement of hemoclips.
5. If the source of the bleeding is not confirmed, endoscopic bipolar cautery of the AEA is performed at the same time.

PREOPERATIVE PERIOD

History

1. History of present illness
   a. How did it start?
      1) Epistaxis following external nasal trauma (blunt force) is more likely to originate from the AEA.
      2) Spontaneous severe epistaxis is more likely to originate from the SPA.
   b. Is it severe? The volume of the bleeding should be assessed: number of cups or tissues. What is the duration? Severe bleeding is usually from a larger vessel such as the AEA or SPA.
   c. What is the source of the bleeding?
      1) Is the bleeding on one side or both sides? Bleeding that is bilateral may indicate multiple sites or the blood is starting on one side and then crossing to the other side in the nasopharynx. Even with brisk posterior bleeding, one side usually predominates.
      2) When the patient is sitting upright, does the bleeding primarily run from the front or the back of the nose? Anterior drainage of blood may indicate bleeding from the AEA, and drainage into the pharynx may indicate posterior bleeding from the SPA. Severe epistaxis, however, often drains anteriorly and posteriorly at the same time.
   d. How is it controlled? If the epistaxis is controlled with anterior compression of the nose, then the source is likely to be the small vessels of the anterior nasal septum. If bleeding continues down the back of the throat with anterior nasal compression, the AEA and SPA are likely sources.
   e. Associated symptoms. It is important to ask about associated symptoms such as nasal obstruction, visual changes, facial hypesthesia, pain, or trismus. Such symptoms may indicate a neoplasm, and the epistaxis may be secondary to the tumor.
2. Past medical history
   a. Age. Severe epistaxis in a young patient (<20 years) is unusual and suggests a neoplasm or hereditary bleeding disorder. In older individuals, spontaneous hemorrhage is often associated with multiple medications, particularly anticoagulants.
   b. Prior treatment. Previous episodes of epistaxis should be explored. Were they similar in location and severity? What is the frequency? How were they treated? Failure of prior surgery or embolization may indicate improper identification of the source or incomplete occlusion and may affect treatment choices. Failure of surgical ligation is typically due to missed terminal branches or dislodgement of hemoclips. Failure of embolization suggests bleeding from the AEA.
   c. Medical illness. Medical illnesses such as liver or renal failure and hematologic cancers are associated with bleeding disorders due to impaired platelet aggregation and coagulation. Overt hypothyroidism has been linked to an increased risk of bleeding. Hypertension may contribute to epistaxis, but this theory is controversial. A cross-sectional, population-based study showed no association between hypertension and epistaxis; in a prospective study of patients with hypertension who had epistaxis, the incidence of epistaxis was not related to the severity of hypertension.
   d. Surgery. A history of recent sinus surgery should alert the surgeon to a possible injury to the ICA, especially if there is documentation of brisk intraoperative hemorrhage that required packing for control. A sphenoidotomy is also likely to injure the posterior septal branch of the SPA, which courses over the anterior face of the sphenoid sinus.
   e. Family history. A family history of recurrent epistaxis may indicate a bleeding diathesis from an inheritable coagulation disorder. In particular, a family history of epistaxis in the absence of other bleeding problems may be associated with hereditary hemorrhagic telangiectasia (HHT) or Osler-Weber-Rendu syndrome.

f. Medications. Many medications are associated with an increased risk of epistaxis. A thorough history is necessary to elicit this information because it is often not volunteered by patients. Categories of products with antiplatelet effects include the following:
   1) Antiplatelet drugs. These include over-the-counter nonsteroidal anti-inflammatory drugs as well as the newer long-acting antiplatelet prescription medications.
   2) Herbal products. Remember the 4 G's: garlic, ginger, gingko biloba, and ginseng. There are many other herbs and nutritional supplements (fish oil, vitamin E) that also affect bleeding.
   3) Alcohol. Episodes of epistaxis are often associated with recent alcohol ingestion.

Physical Examination

1. Nasal endoscopy
   Nasal endoscopy is the most important part of the examination. It may be limited by the presence of nasal packing or active bleeding. Prior attempts at treatment (cautery and packing) may result in secondary sources of bleeding.
   Examination of the nasopharynx is important to rule out cancer or other tumors such as angiofibromas. In the absence of active bleeding, a small clot may signify the site of the bleeding. A small angioma on a turbinate or lateral nasal wall can be easily overlooked. Multiple telangiectasias are indicative of HHT (see Chapter 100).
2. Oral cavity
   Examination of the oral cavity may reveal other causes of epistaxis such as HHT or a neoplasm of the palate or maxilla.
3. Orbit
   Proptosis or restriction of extraocular movements suggests a neoplasm with extension to the orbit.
4. Trigeminal nerve
   Neoplastic involvement of the trigeminal nerve may result in decreased sensation or weakness of the muscles of mastication (decreased contraction, jaw drift with forceful opening).
5. Neck
   Cervical metastases are a late presentation of sinonasal malignancy.

Imaging

None
Most patients with severe epistaxis do not require any imaging prior to surgical intervention.
Computed tomography
A computed tomography (CT) scan with contrast should be considered in patients with concerning symptoms or physical findings suggestive of a neoplasm.
Computed tomography angiogram
If there is a history of recent sinus surgery, a CT angiogram rules out a possible injury to the ICA with formation of a pseudoaneurysm.
Angiography is reserved for patients undergoing embolization or who have failed prior surgical therapy. Angiography is essential if there is concern for ICA injury following trauma or surgery.

Indications

1. Severe epistaxis from the posterior nasal cavity
   The primary indication for endoscopic ligation of the SPA is severe unilateral epistaxis that appears to be posterior or without an obvious source. It is often difficult to differentiate bleeding from the AEA and SPA in the absence of active bleeding, and both vessels may need to be addressed at the time of surgery. Rarely, an inability to localize the bleeding to one side of the nasal cavity requires bilateral SPA ligation.
2. Recurrent acute epistaxis from the posterior nasal cavity
   Some patients give a history of multiple episodes of significant unilateral epistaxis controlled with nasal packing and without treatable risk factors. In such cases, elective SPA ligation may be considered.
3. Vascular tumor
   As an alternative to embolization, SPA ligation may be used to devascularize a tumor prior to surgical excision. Most commonly, this is performed for early-stage angiofibromas but may be considered for sinonasal malignancies as well. Rarely, SPA ligation may be performed emergently for the treatment of a bleeding neoplasm prior to radiation therapy. This may be performed at the same time as a biopsy or palliative debulking of the tumor to relieve obstructive symptoms.
4. Transpterygoid surgical approach
   A transpterygoid approach is a common starting point for many endoscopic approaches to the skull base. Ligation of the SPA allows displacement of the contents of the pterygopalatine space to gain access to the base of the pterygoid and lateral recess of the sphenoid sinus.

Contraindications

1. Correctable coagulopathy
   In a patient with a correctable coagulopathy, nonoperative treatment is preferable.
2. Medical comorbidities with increased risk for general anesthesia
   If a patient is a poor medical risk for general anesthesia, alternative therapies for epistaxis should be considered (nasal packing or embolization).
3. Large vascular tumor with variable vascular supply
   A large vascular tumor may block access to the SPA and have multiple sources of vascular supply from branches of the external carotid artery and ICA. In such cases, angiography with embolization is preferred.

Preoperative Preparation

1. Discontinue antiplatelet drugs if possible. SPA ligation can be safely performed in patients who are anticoagulated or on antiplatelet drugs in an emergency situation. In an elective situation, these drugs and supplements should be discontinued prior to surgery.
2. Control acute bleeding with nasal packing. Bleeding from the SPA can be temporarily managed with anterior and posterior packing with an Epistat balloon or a Foley catheter and sponge/gauze packing.
3. Control the airway. If active bleeding persists, emergent intubation may be necessary to secure a safe airway.
4. Monitor hemoglobin/hematocrit, coagulation parameters, and transfuse if necessary.
5. Base-level hemoglobin and hematocrit are necessary, and type and cross for blood transfusion may be necessary based upon the results.

OPERATIVE PERIOD

Anesthesia

General
Although this procedure can be done with awake sedation, general anesthesia is preferred for patient comfort and protection of the airway. In an emergent situation, these

patients pose a risk for aspiration due to swallowed blood or active bleeding, and awake fiberoptic intubation or rapid sequence intubation may be indicated. An orogastric tube should be passed following intubation for suctioning of blood and stomach contents throughout the procedure. A throat pack is optional.

Positioning

Supine

The patient is positioned in the same way as for any endoscopic sinus procedure with the head turned slightly toward the surgeon. The endotracheal tube is positioned on the opposite side of the mouth. The reverse Trendelenburg position with at least 15 degrees of head elevation reduces mucosal bleeding during surgery.

Perioperative Antibiotic Prophylaxis

First-generation cephalosporin

A single dose of antibiotic is sufficient unless there is evidence of sinusitis secondary to nasal packing. In such cases, antibiotic coverage of *Streptococcus* species and *Streptococcus aureus* is preferred.

Use clindamycin if the patient is allergic to penicillin.

Monitoring

None necessary

Instruments and Equipment to Have Available

1. Basic endoscopic sinus surgery set
2. Monopolar suction electrocautery: Monopolar suction electrocautery can be used for surface bleeding within the nasal cavity.
3. Endoscopic bipolar electrocautery: A pistol-grip endoscopic bipolar electrocautery is the preferred instrument and is more effective than monopolar electrocautery for cauterization of larger vessels.
4. Pistol-grip endoscopic clip applier: Standard disposable clip appliers have a large shaft and are too cumbersome for endonasal surgery. Several companies make adjustable clip appliers (accommodate different clip sizes) with a flat shaft.

Key Anatomic Landmarks

1. Crista ethmoidalis: The crista ethmoidalis is a triangular projection of bone just anterior to the sphenopalatine foramen.
2. Sphenopalatine foramen: The sphenopalatine foramen is located at the posterosuperior corner of the maxillary sinus and is formed by the junction of the palatine bone and sphenoid bone (Fig. 98.1).
3. Greater palatine nerve (descending palatine nerve): The greater palatine nerve descends vertically in the lateral nasal wall, inferior to the sphenopalatine foramen.

Prerequisite Skills

1. Endoscopic antrostomy (see Chapter 103)

Operative Risks

1. Intraoperative hemorrhage from SPA:
   If the sphenopalatine foramen is approached directly, there is greater risk of injury to the branches of the SPA. This can be avoided by exposing the lateral nasal wall inferior to the sphenopalatine foramen. A 1-mm Kerrison rongeur should be used to enlarge the sphenopalatine foramen superficial to the SPA. If a larger rongeur is used, it is more likely to transect the vessel.
2. Injury to greater palatine nerve:
   The nerves are in a deeper plane than the vessels in the pterygopalatine space. The greater palatine nerve can be injured if the bone inferior to the sphenopalatine foramen is instrumented with a drill or rongeurs. Injury results in hypesthesia of the palate.
3. Injury to sphenopalatine ganglion or vidian nerve:
   The vessels are superficial to the nerves in the pterygopalatine space. Dissection or cauterization of tissues deep to the SPA can injure the sphenopalatine ganglion or vidian nerve. This can result in intranasal dryness and decreased lacrimation.

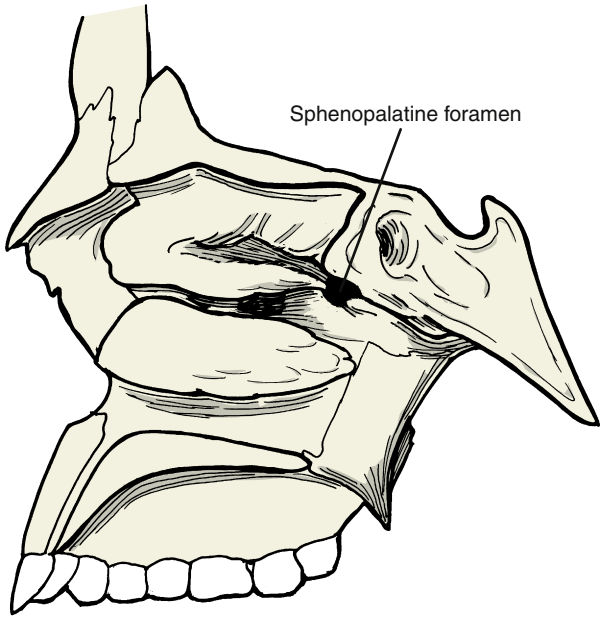

Fig. 98.1. Relationship of the sphenopalatine artery to the posterior attachment of the middle turbinate.

Surgical Technique

- Vasoconstriction of the nasal mucosa with oxymetazoline (0.05%)

Once anesthetic preparations are concluded, nasal packing is removed and replaced with cottonoids soaked in oxymetazoline (0.05%) solution. It is rare that patients continue to bleed actively at this time due to the effects of hypotensive anesthesia, head elevation, and topical vasoconstriction.

- Maxillary antrostomy (Fig. 98.2)

Nasal endoscopy with a 0-degree endoscope is performed to identify normal landmarks and look for evidence of active bleeding. If visualization is impaired due to active bleeding, temporary hemostasis can be achieved with monopolar suction electrocautery. The middle turbinate is medialized to gain access to the middle meatus. If there is obstruction secondary to a concha bullosa, it is partially resected to improve access. In the instance of severe septal deviation precluding visualization, septoplasty is performed to allow unhindered access to the middle meatus.

A maxillary antrostomy facilitates exposure of the proximal SPA and provides additional space for instrumentation. The uncinate process is resected with backbiting forceps, the

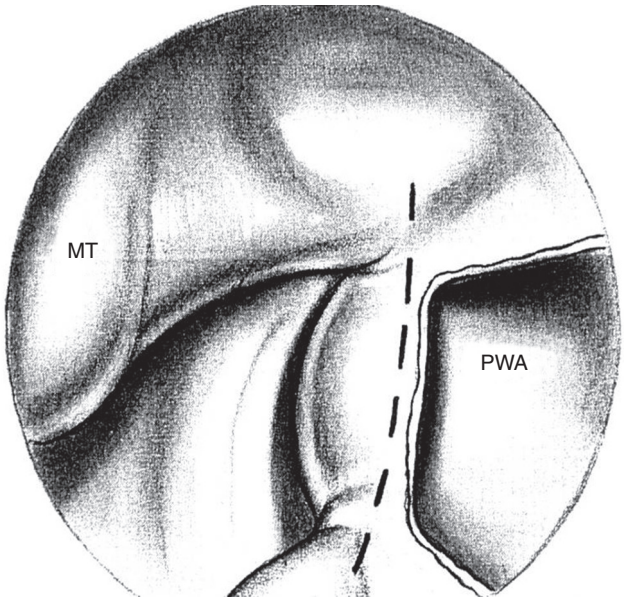

Fig. 98.2. After left middle meatal antrostomy, the mucoperiosteum posterior to the antrostomy is elevated from the lateral nasal wall. *MT*, Middle turbinate; *PWA*, posterior wall antrum. *(Reprinted with permission from Waring M, Padgham N: Osteologic classification of the SP foramen. Laryngoscope 108:125-127, 1998.)*

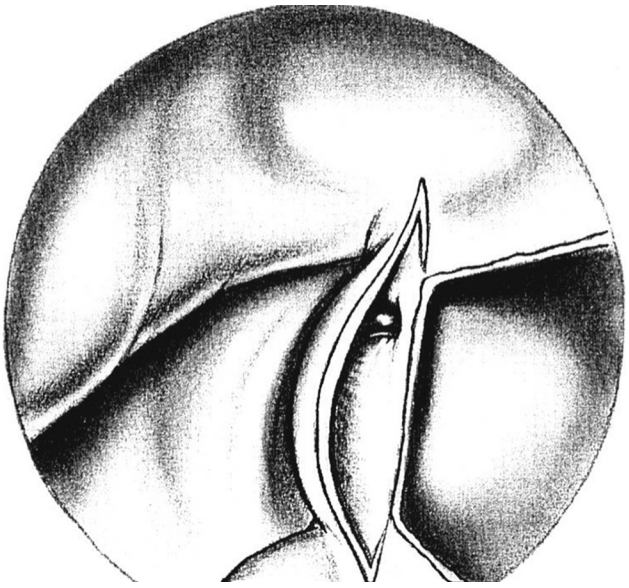

Fig. 98.3. The sphenopalatine artery is exposed at the posterosuperior corner of the maxillary sinus. *(Reprinted with permission from Waring M, Padgham N: Osteologic classification of the SP foramen. Laryngoscope 108:125-127, 1998.)*

natural ostium is identified, and the antrostomy is widened posteriorly and inferiorly.

- Identify the sphenopalatine foramen (Fig. 98.3).

A Cottle elevator is used to elevate the mucoperiosteum from the lateral nasal wall inferior to the antrostomy. Dissection continues posteriorly below the level of the sphenopalatine foramen. The projection of the crista ethmoidalis is superficial to the sphenopalatine foramen. The level of the foramen typically corresponds to the posterior attachment of the middle turbinate. As the periosteum is elevated, there is

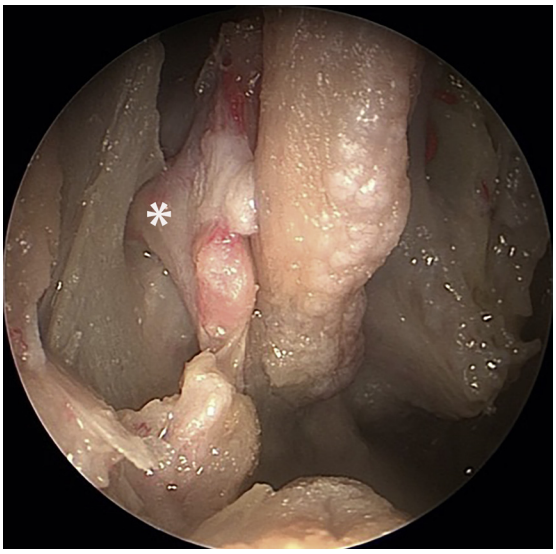

Fig. 98.4. Endoscopic view of the right sphenopalatine artery *(asterisk)* at the point where it exits the foramen.

stretching of the branches of the SPA, which aids in identification (Fig. 98.4). It is helpful at this time to replace the Cottle elevator with a 7-Fr Frazier suction, which maintains tension on the vessels and suctions blood from the surgical field. The suction can be left in this space unattended; this frees up the surgeon's hand for further instrumentation.

- Enlarge the sphenopalatine foramen (Fig. 98.5).

A 1-mm angled Kerrison rongeur is then placed into the sphenopalatine foramen superficial to the SPA, and the overlying bone is removed. Care is taken to avoid injury to the branches of the SPA by remaining superficial to the periosteum enveloping the pterygopalatine fossa (PPF) space contents. If active bleeding from the vessels is encountered, it can be temporarily controlled with bipolar or monopolar electrocautery. Cadaveric studies demonstrate that there is proximal branching of the SPA with separate foramina approximately 40% of the time. This is another advantage of a wide exposure; the surgeon is less likely to miss a branch exiting through a separate foramen. Removal of bone continues into the pterygopalatine space with partial removal of the posterior wall of the maxillary sinus. A 2-mm Kerrison rongeur is ideal for this step. Enough bone should be removed to identify the main trunk of the SPA.

- Dissect distal branches of the sphenopalatine artery.

A blunt dissector (Cottle instrument or nerve hook) is used to separate the adipose tissues surrounding the vessels. If necessary, bipolar electrocautery can be used to shrink the adipose tissue and achieve venous hemostasis. It is not necessary to dissect all of the branches of the internal maxillary artery.

- Place hemoclips or cauterize vessels (Fig. 98.6).

Using an adjustable clip applier, a medium-sized hemoclip is placed securely across the main trunk of the SPA lateral to the foramen. If possible, a second clip is placed. It is better to palm the hemoclip applier as it is introduced to avoid premature bending of the hemoclip, causing it to fall out of the clip applier. The two distal branches of the SPA are also identified and ligated. If the vessel is torn or the hemoclips cannot be applied securely, thorough bipolar electrocauterization of the vessel is performed.

- Cover with Gelfoam.

The surgical site is irrigated with warm saline and a small piece of Gelfoam is placed over the hemoclips at the

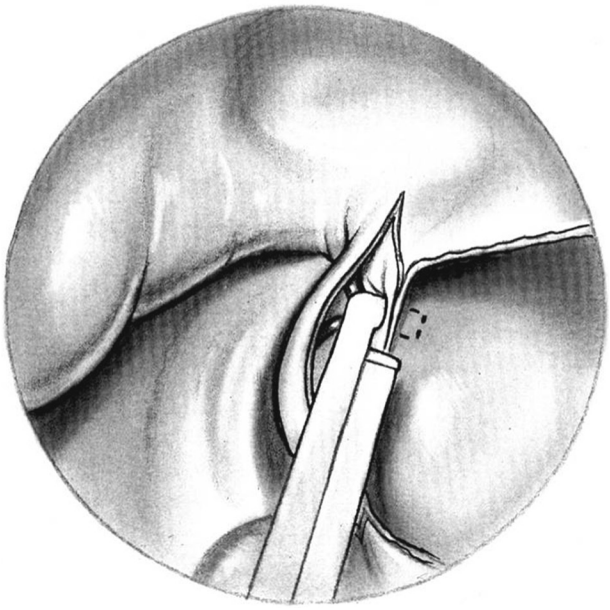

Fig. 98.5. The foramen is enlarged with a rongeur to expose the main trunk of the sphenopalatine artery. *(Reprinted with permission from Waring M, Padgham N: Osteologic classification of the SP foramen. Laryngoscope 108:125-127, 1998.)*

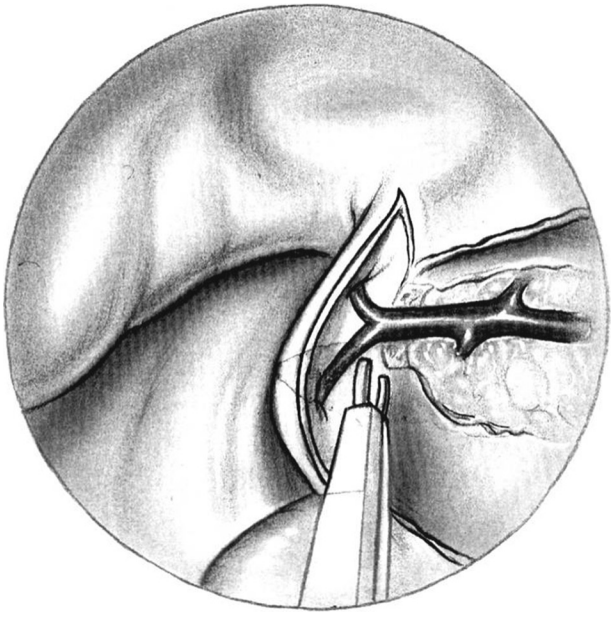

Fig. 98.6. Hemoclips are placed on the main trunk of the sphenopalatine artery and its terminal branches. *(Reprinted with permission from Waring M, Padgham N: Osteologic classification of the SP foramen. Laryngoscope 108:125-127, 1998.)*

surgical site. Silastic septal splints are sutured to the nasal septum to prevent synechiae. Nasal packing is usually not necessary. If packing (Merocel tampon) is placed for additional hemostasis due to nonarterial bleeding, it is important to do so under endoscopic visualization to avoid dislodging the hemoclips.

Common Errors in Technique

1. Inadequate exposure of the lateral nasal wall
   Inadequate exposure limits visualization and does not provide adequate room for instrumentation. A maxillary antrostomy can be helpful for exposure and access to the vasculature. If the middle turbinate is restricting access, the anterior-inferior portion can be resected without any adverse sequelae. A branch of the SPA may be missed if the proximal trunk is not identified before it branches.
2. Approaching the sphenopalatine foramen too high
   A direct approach to the sphenopalatine foramen makes identification of the vessels more difficult and risks further injury to the vessels. Rather, dissection in the subperiosteal plane inferior to the sphenopalatine foramen provides space for a suction instrument with stretching of the vessels. Occasionally, an aberrant branch of the SPA exits the bone in this area and may be a source of bleeding.
3. Using a Kerrison rongeur that is too large
   Attempting to use a 2-mm Kerrison rongeur to open the sphenopalatine foramen risks injury to the vessels; rather, a 1-mm angled Kerrison rongeur should be used.
4. Failure to identify both branches of the SPA
   Recurrent epistaxis can occur if only one of the terminal branches of the SPA is ligated. This is most commonly seen when the surgeon attempts to ligate the vessels with limited exposure (without performing an antrostomy).
5. Wrong hemoclip applier
   The disposable hemoclip applier that is used by general surgeons has a barrel-shaped shaft and is too large for intranasal use. An adjustable pistol-grip hemoclip applier with a flat shaft is preferred.
6. Hemoclips are not secure
   Hemoclips that are too small for the vessel will not completely occlude the vessel and may become dislodged. Hemoclips do not close completely at the apex of the clip. The proper technique is to use the distal part of the hemoclip for compression of the vessel.
7. Placement of a Merocel tampon (for nonarterial bleeding) at the end of the case may dislodge the hemoclips if it is done without visualization.

POSTOPERATIVE PERIOD

Postoperative Management

1. Monitor for acute blood loss anemia.
   Check hemoglobin/hematocrit postoperatively and follow guidelines for blood replacement. An iron supplement may be prescribed for several weeks if indicated.
2. Pain medication
   Patients are not expected to have much pain following this operation. Minor pain can be treated with acetaminophen. If bleeding is controlled, nonsteroidal anti-inflammatory drugs such as ibuprofen may be started several days following surgery.
3. Antibiotics
   Continuation of antibiotic therapy postoperatively is not necessary unless the patient had nasal packing and is being treated for sinusitis.
4. Saline irrigations
   Liberal use of saline spray and irrigations helps remove blood clots and maintain a clear nasal airway.
5. Resumption of anticoagulants/antiplatelet drugs
   Essential medications may be resumed on the first postoperative day if there is no active bleeding.

Complications

1. Hemorrhage
   Postoperative hemorrhage is usually due to mucosal trauma, and management depends on the severity. Minor epistaxis can be managed conservatively with topical decongestant spray or anterior nasal packing. Severe epistaxis indicates failure of the surgical ligation or bleeding from a different site. If nasal endoscopy suggests that the bleeding is from the SPA on the same side as the surgery, options include re-exploration in the operating room or angiography with embolization. The same considerations apply as discussed previously. Surgery provides the opportunity to address both the SPA and AEA. Common reasons for failure include a displaced hemoclip, bleeding from the SPA proximal to the hemoclip, or failure to recognize a branch of the SPA. Rarely, bleeding from the contralateral SPA will require SPA ligation on that side.
2. Synechiae
   Synechiae can be prevented with the use of silastic septal splints for 1 to 2 weeks. If synechiae form, lysis is not necessary unless they are symptomatic (airway or sinus obstruction).
3. Sinusitis
   Sinusitis may result from mucosal edema from nasal packing and instrumentation and can be managed with oral antibiotics, topical steroid spray, and saline irrigation. Chronic rhinosinusitis may occur secondary to postoperative scarring of the ostiomeatal complex.
4. Palatal hypesthesia from injury to the descending palatine nerve
   Most nerve damage is partial and transient. Patients are reassured that sensation will return over a period of weeks to months.
5. Septal necrosis
   Rarely, necrosis of the nasal septum will occur following SPA ligation. Potential risk factors include bilateral SPA ligation and extensive cauterization of the septum and nasal packing prior to surgery.

Alternative Management Plan

1. Angiography and embolization
   Embolization is preferred when the patient is not a candidate for general anesthesia due to medical comorbidities. The site of bleeding cannot be identified unless there is active bleeding at the time of angiography. For that reason, all of the contributing vessels on the side of the epistaxis are often embolized: internal maxillary artery and facial artery. The ethmoidal arteries cannot be embolized without risk of blindness. Further, embolization carries a small risk (<2%) of stroke, blindness, and soft tissue ischemia. Overall, embolization is less cost-effective than surgical ligation, and the required expertise is not available at many institutions. If someone has already failed SPA ligation, embolization is an option, but repeat surgery is preferred in most situations. If a patient is anticoagulated, embolization may have an advantage. Lastly, embolization avoids trauma to the nasal mucosa by avoiding surgical manipulation.
2. Transmaxillary ligation of the internal maxillary artery (IMA)
   An alternative to endonasal SPA ligation is transmaxillary ligation of the IMA. It has greater morbidity, however, and risks failure due to missed branches of the IMA with collateral circulation. An anterior maxillotomy via a sublabial approach provides access to the proximal trunk of the IMA behind the posterior and lateral walls of the maxilla. This approach can be used instead of embolization to devascularize small or medium-sized angiofibromas or for devascularization of a malignant neoplasm prior to biopsy or debulking.

DISCUSSION

Evidence-Based Medicine Question

Is SPA ligation as effective as other hemostatic techniques?

According to several case series and literature reviews, success rates for SPA ligation are equivalent to or better than success rates for embolization.

A comprehensive literature review of endovascular treatment for intractable posterior epistaxis reports an immediate success rate between 93% and 100%. However, this rate drops to 77% to 95% when early rebleeds were taken into account. Furthermore, when retrospective reviews that take late rebleeds into account are included, success rates drop further to between 71% and 89.2%.[1]

Reported success rates for SPA ligation range from 87% to 98%. The three largest retrospective series (50, 45, and 45 patients) report long-term success rates between 87% and 93%; in a pooled series of 127 patients from 11 case series, SPA ligation was reported to control epistaxis in 98% of cases. In these series, there were no major complications; minor complications included nasal crusting and paresthesias of the palate and nose. Furthermore, inability of SPA ligation to control epistaxis may represent an incorrect choice of procedure rather than a failure of the procedure: A significant number of rebleeds were successfully managed with subsequent anterior ethmoid artery ligation.[2]

In a review of data reported by hospitals to the Nationwide Inpatient Sample (2008–2010), comprising over 57,000 patients admitted with a primary diagnosis of epistaxis, no significant differences in clinical outcomes were noted between SPA ligation and embolization in the population studied. Total hospital costs, however, were significantly higher for patients undergoing embolization.[3]

A 2013 standard decision analysis model found first-line SPA ligation to be the most cost-effective strategy in management of posterior epistaxis when compared to current posterior nasal packing algorithms.[4]

The results from a recent modeling-based economic evaluation suggest that for patients with intractable epistaxis, when both SPA ligation and arterial embolization are viable options, SPA ligation is the more cost-effective treatment strategy. In a follow-up study examining the risk profile of various laddered management algorithms involving posterior packing, SPA ligation, and embolization, the lowest-risk strategies were found to be those that use SPA ligation as a first-line strategy. When risk outcomes were combined with cost-effectiveness data, the authors concluded that SPA ligation should be considered as the first-line strategy for intractable epistaxis, because it minimizes patient risk and promotes the most efficient use of health care resources.[5]

Editorial Comment

Transnasal endoscopic SPA ligation is a highly effective method for controlling refractory posterior epistaxis. SPA ligation appears to have a favorable outcome and increased cost-effectiveness compared to arterial embolization. The techniques described in this chapter provide practical guidance for safe and effective endoscopic SPA ligation, which in appropriately selected patients, is emerging as the preferred method for controlling intractable posterior epistaxis and in skull base surgery, a necessary skill for the transpterygoid approach.

Stella E. Lee

Access the review questions and additional sources list online at http://www.expertconsult.com

REFERENCES

1. Willems PWA, Farb RI, Agid R. Endovascular treatment of epistaxis. Am J Neuroradiol 2009;30:1637–1645.
2. McDermott AM, O'Cathain E, Carey BW, et al. Sphenopalatine artery ligation for epistaxis: factors influencing outcome and timing of surgery. Otolaryngol Head Neck Surg 2016;154(3):547–552.
3. Villwock JA, Jones K. Recent trends in epistaxis management in the United States 2008-2010. JAMA Otolaryngol Head Neck Surg 2013;139(12):1279–1284.
4. Dedhia RC, Desai SS, Smith KJ, et al. Cost-effectiveness of endoscopic sphenopalatine artery ligation versus nasal packing as first-line treatment for posterior epistaxis. Int Forum Allergy Rhinol 2013;3(7):563–566.
5. Leung RM, Smith TL, Rudmik L. Developing a laddered algorithm for the management of intractable epistaxis: a risk analysis. JAMA Otolaryngol Head Neck Surg 2015;141(5):405–409.

REVIEW QUESTIONS

1. Which option is *not* a landmark for the sphenopalatine foramen?
   a. Posterior attachment of the middle turbinate
   b. Crista ethmoidalis
   c. Pterygoid canal
   d. Posterosuperior corner of the maxillary sinus

2. Which option is *not* a potential complication of SPA ligation?
   a. Loss of emotional tearing
   b. Palatal numbness
   c. Septal necrosis
   d. Blindness

3. Which option is *not* a possible reason for failure of SPA ligation?
   a. Hypertension
   b. Limited exposure with clipping of only one vessel
   c. Bleeding from the anterior ethmoid artery
   d. Dislodged hemoclip

ADDITIONAL SOURCES

Floreani SR, Nair SB, Switajewski MC, et al. Endoscopic anterior ethmoidal artery ligation: a cadaver study. Laryngoscope 2006;116(7):1263–1267.

In this prospective analysis of computed tomography of the paranasal sinuses and endoscopic cadaver dissection, the radiologic and endoscopic anatomy of the anterior ethmoidal canal is described as is the feasibility of endoscopic ligation of the anterior ethmoidal artery.

Schlosser RJ. Epistaxis. N Engl J Med 2009;360:784–789.

This concise review begins with a case vignette highlighting a common presentation of epistaxis. It discusses anatomic features, predisposing causes, and associated medical conditions and presents evidence supporting various strategies of management, followed by review of formal guidelines and expert clinical recommendations.

99 Operative Otolaryngology: Anterior and Posterior Ethmoid Artery Ligation for Epistaxis

Andrew Thamboo, Evan S. Walgama*, Jayakar Nayak**

INTRODUCTION

Epistaxis is a common medical problem; however, the exact prevalence of this condition is unknown because patients themselves manage many cases conservatively. It is believed the prevalence may be as high as 30% in children younger than 5 years old and up to 50% in children aged between 6 and 15 years.[1] In adults, the prevalence of epistaxis has not been as well documented but most commonly occurs between the ages of 70 and 79 and in the winter months when the inhaled air is driest.[2]

The location and source of epistaxis can be quite variable, the majority occurring along the anterior nasal septum. The anterior septum contains a plexus known as Kiesselbach's plexus or Little's area, which is made up of minor vessels branching off of the anterior ethmoid artery (AEA), sphenopalatine artery (SPA), and facial artery. Posterior epistaxis arises primarily from the SPA and its associated branches, but the posterior ethmoid artery (PEA) may also be a possible source.[3] Although many of these nosebleeds are managed conservatively by pinching the nose, inserting absorbable or nonabsorbable packs, using topical vasoconstrictors such as adrenalin or oxymetazoline, or even warm water irrigation,[4,5] epistaxis coming directly off the AEA, SPA, and PEA may require more definitive management.

KEY OPERATIVE LEARNING POINTS

1. The AEA and PEA branch off the ophthalmic artery; therefore arterial embolization and/or endovascular coiling are not options because this may result in blindness.
2. When viewing the skull base from below, the AEA is best identified just posterior to the supraorbital ethmoid (SOE) cell.
3. The AEA neurovascular bundle can be approached externally as it enters the high ethmoid complex from the orbit approximately 20 to 24 mm posterior to the anterior lacrimal crest, and the PEA is approximately 9 to 16 mm posterior to the AEA foramen. The optic nerve is 4 to 7 mm posterior to the PEA foramen.
4. The AEA or PEA can be ligated using bipolar cautery, but hemoclips are preferred when possible for the PEA given its proximity to the optic nerve.
5. The direction of arterial blood flow through the AEA and PEA is lateral (orbital) to medial (skull base), making lateral control of the vessel essential during ligation. Retraction of either vessel laterally back into the orbit can contribute to rapid hematoma and intraocular pressure (IOP) shifts.

History

1. History of present illness
   a. Obtaining the history of presenting illness can be performed only after the patient is stable. In the unstable patient, institutional trauma protocols should be used to resuscitate the patient with appropriate fluid and/or blood.
   Determine the source of bleeding: Is the bleeding primarily arising anteriorly or posteriorly? On which side did the bleeding begin? If patients can provide a clear history that the bleeding is primarily occurring anteriorly, one should assess the anterior septum followed by the AEA, although rare, as the possible source. If the patient states that the bleeding seemed to arise "somewhere in the back," one should consider the source to be the SPA or its associated branches, followed by the PEA (rare). Patients often have difficulty identifying the side of the bleeding unless it is a recurrent or bleeding slowly, but if laterality can be determined, this may save time in managing the bleeding.
   b. Determine the severity and quality of the bleeding: How profuse was the bleeding—torrential, sudden, and aggressive (suggestive of an arterial source) or steady/continuous but low grade (perhaps more venous)? When did the bleeding begin? Does the patient feel weak or light headed? Is the bleeding experienced every winter and/or seasonal? Is this bleeding recurrent and readily managed? (The latter three points all suggest Kiesselbach plexus as the likely source from ambient air changes in humidity, seasonal allergies, and anterior, low-grade bleeding.)
   c. Patients are often anxious about events related to epistaxis, and therefore the general amount of blood lost might be requested in terms of "teaspoons," "tissues," "cups," or "buckets." The patient's presentation and how long he or she has been bleeding will also assist the clinician to determine the severity of the bleeding. If the severity is unclear, the associated symptoms may indicate how he or she is coping with the blood loss. Any symptoms such as light headedness, "hot and clammy," palpitations, or feeling weak should alert the clinician to hemodynamically assess and/or resuscitate the patient before completing the history.
   d. Determine where there are any associated symptoms: Do you have facial numbness/hypesthesia, unilateral nasal obstruction, or diplopia? Do you have fevers, sweats, or weight loss? Any of the aforementioned symptoms may indicate a possible more serious etiology as the underlying cause of the epistaxis. One should always consider nasopharyngeal cancer in those of Southeast Asian decent and juvenile nasopharyngeal angiofibroma in adolescent males as the source of persistent unilateral epistaxis.
   e. Additional questions should be asked based on clinical suspicion to help determine the etiology of the nosebleed (Table 99.1).
2. Past medical history
   a. Previous epistaxis: How often do you have episodes? Does the onset occur during a particular time of day, season, or activity? Do you know what aggravates your bleeding? How have you managed your previous episodes? Have you seen a doctor regarding epistaxis, and how was it managed?

***Disclosure Statement:** Drs. Thamboo, Walgama, and Nayak do not have any relevant commercial or financial conflicts of interests or funding sources.

TABLE 99.1 Common Etiologies of Epistaxis

Local Causes	Systemic Causes
Chronic rhinosinusitis	Congenital coagulopathies
Digital trauma	Hypertension
Foreign bodies	Leukemia
Irritants	Liver dysfunction
Neoplasm	Medications
Septal deviation	Platelet dysfunction
Septal perforations	
Trauma	
Vascular malformations	

b. Medical illness: Do you have a bleeding disorder? Do you have a history of bruising? Is there a history of liver disease, immunosuppression, or vitamin deficiency? If the underlying source of the bleeding is due to a medical source, a hematologist should be consulted to help in the management. Recurrent epistaxis despite management is another reason to consult a hematologist.
c. Surgery: Have you had sinonasal surgery or rhinoplasty? Recent surgery will guide the clinician in determining the possible source of the epistaxis. If a patient has had a septoplasty or rhinoplasty, one should be cautious when cauterizing the anterior septum because this may lead to a slightly increased chance of a septal perforation.
d. Family history: History of bleeding disorder?
e. Medication:
   1) Anticoagulants (numerous families of agents)
   2) Herbal products such as omega-3 supplements, garlic, ginseng, and ginkgo biloba
   3) Alcohol—heavy intake

Physical Examination

1. Self-protection/universal precautions
   Proper protective equipment including face shield, eye shield, gown, and gloves should be worn.
2. Preparing the nose for examination
   The entire nasal cavity should be copiously irrigated with saline solution to remove clots. This can be done with a 60-mL syringe or other squeeze bottle irrigation with the patient's head tilted over a large basin.
3. Anterior rhinoscopy and nasal endoscopy
   Anterior rhinoscopy followed by rigid nasal endoscopy with a 30-degree endoscope should be used to evaluate the entirety of the nasal cavity—anteriorly and posteriorly. Any site of anterior nasal crusting should be removed because the site of spot hemorrhage is often located underneath these "biologic dressings." The nasopharynx should always be assessed to rule out nasopharyngeal cancer. A rigid endoscope is used preferentially over a flexible scope because it allows the ability to suction and use instruments in the nasal cavity if a bleeding site is seen. Topical decongestants mixed with lidocaine/benzocaine can be placed after the first assessment. Placing a topical decongestant prior to one's first assessment may put the arterial source under temporary vasospasm, resulting in a negative examination.
   If the source of the epistaxis can be visualized, cautery (e.g., silver nitrate, bipolar electrocautery) can be used directly on the mucosa. If the bleeding is coming from a superior source, dressing material or any version of nasal packing placed under endoscopic visualization can help ensure that the appropriate site is tamponaded. In all cases, especially when the patient is coagulopathic with diffuse mucosal bleeding, minimizing trauma to the mucosa will help prevent further bleeding. It is advised to use absorbable packs in these individuals. If a direct source is seen in these patients and a nonabsorbable pack will not tamponade the source, cautery can be used but with caution because this may cause further bleeding. Alternatively, nasal balloon systems that atraumatically contain the active hemorrhage can be used.
4. Oral cavity
   Examination of the oropharynx will often reveal whether blood is draining posteriorly. The examination of the oral cavity should also be evaluated for telangiectasias or tumors of the hard palate, maxilla, or tonsil as the cause of the epistaxis.
5. Examination of the cranial nerves
   A complete neurologic examination should be performed to rule out malignancy extending from the sinonasal cavity.

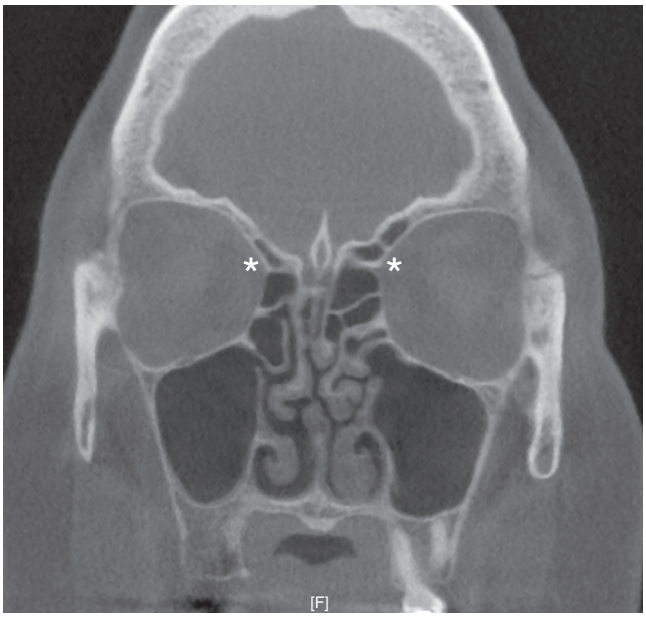

Fig. 99.1. Computed tomography (CT) landmark for anterior ethmoid artery. Coronal CT scan of sinuses, showing bilateral "nipple signs" *(*)* that typically arise between the superior oblique and medial rectus muscles.

Imaging

None necessary
External approaches do not require imaging.
Computed tomography (CT)
Those performing an endonasal approach should consider obtaining a CT scan to help localize the AEA. If the institution uses a navigation system, the CT scan can be registered to facial landmarks to help identify the artery intraoperatively. Using the coronal views, the "nipple" sign will help to identify the AEA (Fig. 99.1). This is a triangular evagination in the superomedial orbital wall that reliably falls between the densities of the medial rectus and superior oblique muscles. The PEA also has a nipple sign, which is nearly always in the skull base and not associated with any specific muscle group.
CT angiogram
Magnetic resonance imaging (MRI)
Angiography

Indications

1. Failed epistaxis management at bedside
   If the bleeding site can be visualized endoscopically, chemical or electrocautery can be performed. However, occasionally the exact area from which the bleeding arises cannot be seen due to anatomic obstruction (deviated septum, between the middle turbinate and septum) or the artery in question is

under vasospasm after the nasal pack has been removed. In these situations the approach to arterial ligation is institution dependent. In our institution, unilateral SPA ligation before AEA ligation is favored, but others perform combined SPA and AEA ligation as primary treatment. The clinical context may also change depending on history (i.e., facial trauma resulting in high suspicion for AEA injury, or recent SPA ligation been attempted), past medical history (anesthesia risk, requiring combined SPA and AEA ligations to prevent the need for any future general anesthesia), or even social history (i.e., patient lives alone in an area remote from access to medical care).

2. Refractory epistaxis
   As noted previously, if the rare patient fails a properly performed SPA ligation, and there is convincing evidence of unilateral epistaxis, we may then proceed with an AEA ligation. The PEA is rarely a cause of epistaxis but should be considered a source of epistaxis in the exceedingly rare situation of failure of both SPA and AEA ligations.
3. Tumors
   Resection of benign and malignant tumors may require ligation of the AEA and PEA before resection of particular anterior skull base tumors. These vessels are not amenable to endovascular approaches due to continuity with the internal carotid system.

Contraindications

Not medically fit for surgery (sometimes that consideration must also be waived in the setting of life-threatening epistaxis)

Preoperative Preparation

1. Stabilize the patient with nasal and, if necessary, postnasal packing.
2. Preoperative laboratory studies to assess hemoglobin/hematocrit, international normalized ratio, partial thromboplastin time
3. Rapidly reverse anticoagulation, if necessary, and optimize medically.
4. Reduce blood pressure (although data on the efficacy of this strategy are limited).
5. Obtain consent for surgery and possible transfusion.

OPERATIVE PERIOD

Anesthesia

General

Protection of the airway is a priority of the surgeon and anesthesiologists. If the bleeding is ongoing and severe, intubation may be difficult; this can become more challenging depending on the patient's body habitus. Therefore it important that the surgeon and the anesthesiologist agree on each patient's difficult airway management algorithm to secure the airway if problems arise.

Positioning

Supine

The patient is positioned the same as in any endoscopic sinus procedure with the head turned slightly toward the surgeon with the operating table in reverse Trendelenburg.

Perioperative Antibiotic Prophylaxis

First-generation cephalosporin
Second-generation cephalosporin
Clindamycin if the patient is allergic to penicillin

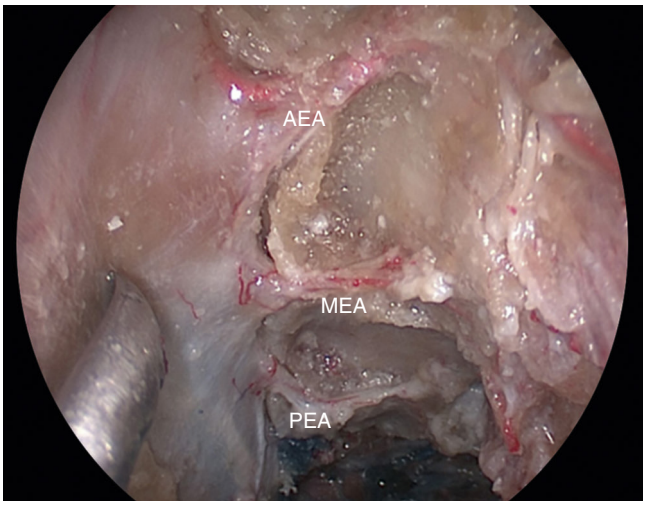

Fig. 99.2. Endoscopic view of anterior, middle, and posterior ethmoid arteries at skull base. *AEA*, Anterior ethmoid artery; *MEA*, middle ethmoid artery; *PEA*, posterior ethmoid artery. *(Image courtesy of Dr. Ricardo Carrau, Ohio State University, and used with permission from Wang L, Youseef A, Al Qahtani AA, et al: Endoscopic anatomy of the middle ethmoidal artery. Int Forum Allergy Rhinol 4(2):164-168, 2014.)*

Monitoring

None necessary

Instruments and Equipment to Have Available

1. Basic endoscopic sinus surgery set
   Management of the AEA and PEA may require angled instrumentation and angled telescopes and should be a part of the basic endoscopic sinus surgery set.
2. Endoscopic bipolar electrocautery
   A pistol-grip endoscopic bipolar electrocautery is preferred, given the proximity of the AEA and PEA to the dura. The use of monopolar cautery may result in excess current transmission through the dura and a challenging concurrent cerebrospinal fluid (CSF) leak. An angled pistol-grip endoscopic bipolar will assist in the uneventful management of the AEA.
3. Pistol-grip endoscopic clip applier
   Specific pistol-grip endoscopic clip applier made for the sinuses may be used as a substitute to pistol-grip endoscopic bipolar. If an external approach is performed, the clip applier may be the preferred option for the PEA given its proximity to the optic nerve.

Key Anatomic Landmarks

1. SOE air cell
   The degree of pneumatization of the frontal sinus or SOE can affect the position of the AEA, but the AEA is universally found posterior to the SOE.[6] Consequently, excellent understanding of frontal sinus and SOE anatomy will assist in accurate identification of the AEA, if endoscopic ligation is intended (Fig. 99.2). A middle ethmoid artery has also been identified between the AEA and PEA, but this is beyond the scope of this chapter.[7]
2. Basal lamella of the ethmoid bulla and axilla of middle turbinate
   Historically, the AEA has been closely associated with the skull base attachment of the basal lamella of the ethmoid bulla,[8] but more recently a number of reports have

effectively used other landmarks to identify the location of the AEA endoscopically. The relationship of the AEA to the axilla of the middle turbinate has been measured to be approximately 17 to 25 mm.[9,10]

3. Sphenoid face
   By contrast, the PEA is often not appreciated endoscopically. If present and visible, it is consistently (98% reliability)[9] found approximately 8.1 mm anterior to the sphenoid face. The caliber of the PEA is smaller than the AEA and often embedded in the skull base, whereas one-third of AEA can be found within a bony mesentery pendant in the sinus airspace, off of the skull base.
4. Anterior lacrimal crest
   The AEA and PEA can also be identified before entering the ethmoid cavity. The AEA foramen is approximately 20 to 24 mm posterior to the anterior lacrimal crest. The PEA can then be found approximately 9 to 16 mm posterior to the AEA. It is important to note that the optic nerve is closely approximated to the PEA, arising approximately 4 to 7 mm posterior to the PEA foramen (Fig. 99.3).

Prerequisite Skills

1. Endoscopic maxillary antrostomy (see Chapter 103)
2. Endoscopic ethmoidectomy (see Chapter 108)
3. Endoscopic frontal sinusotomy (see Chapter 112)

Operative Risks

1. Retro-orbital hematoma
   If unintentionally transected or avulsed before ligation, the AEA and PEA may retract into the orbit and potentially cause a retro-orbital hematoma. It is important that when applying cautery or hemoclips, the entire caliber of the vessel must be ligated 360 degrees. If a vessel retracts into the orbit, the surgeon should be prepared to perform an emergent lateral canthotomy and cantholysis if the affected orbit becomes asymmetrically proptotic or indurated.
2. CSF leak
   When working along the skull base, the process of exposing the AEA or PEA may inadvertently breach the skull base and meningeal linings, leading to CSF leak. Gentle peeling of the bone off the medial lamina paprycea and then slowly proceeding up to the AEA or PEA will reduce the chances of skull base breach.
3. Orbital injury
   The process of removing the lamina papyracea bone to expose the vessels puts the orbit at risk. The goal ideally is to keep the periorbital lining intact, which, if breached, may result in prolapse of orbital adipose tissue. Intraoperatively, it is important to identify orbital adipose tissue and work around the site of breach by protecting the area from further damage. Some practitioners gently bipolar cauterize the exposed adipose tissue to reduce the volume and cauterize any unnamed, minute orbital vessels in the process. Postoperatively patients are counseled to avoid the use of high-volume saline irrigation or cough or sneeze with their mouth closed to limit the possibility of air entry into the orbit.
4. Inability to control bleeding
   The surgeon must be prepared for the need for alternative methods. If all methods have been exhausted and bleeding persists, the patient should be kept intubated and have a formal packing placed with close observation in a high acuity unit. If packing and time alone do not resolve the situation, options include embolization versus consultation of a second surgeon for assistance.

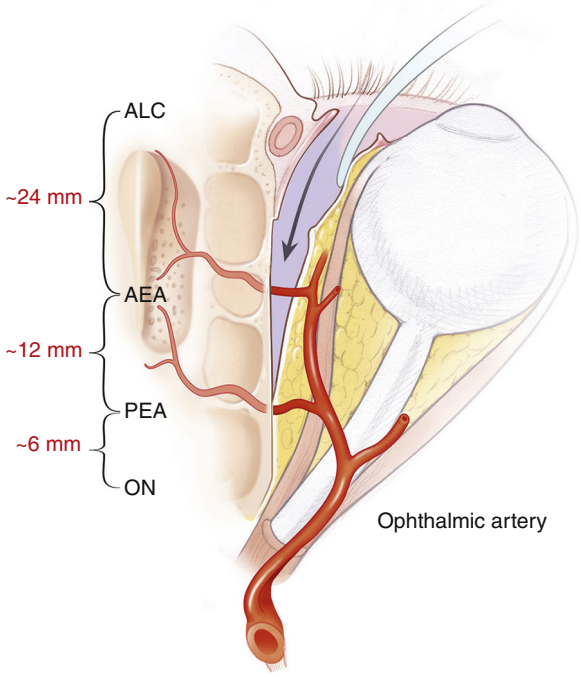

Fig. 99.3. Illustration in axial plane of the anterior and posterior ethmoid arteries and optic nerve. Distances of critical structures from the anterior lacrimal crest are shown on the left. *AEA*, Anterior ethmoid artery; *ALC*, anterior lacrimal crest; *ON*, optic nerve; *PEA*, posterior ethmoid artery.

Endoscopic Surgical Technique

- CT navigation system
  Before taking the patient to the operating room, a thin-cut CT scan (preferably <1.25 mm) can be obtained to help to identify the arteries. It should be calibrated to the patient after intubation.
- Nasal packs
  The nasal packs should be removed after intubation. The entire nasal cavity is then copiously irrigated with warm water to assist with endoscopic visualization of the nasal cavity. The nasal cavity should then be decongested with pledgets soaked in oxymetazoline or dilute topical epinephrine (1:1000 at the authors' institution).
- Uncinectomy
  A standard uncinectomy is carried out to provide access to the ethmoid bulla. We prefer a posterior to anterior approach during uncinate removal to limit orbital complications. A backbiter is then used to expose the natural ostia, and then the uncinate is dissected off of its attachment along the maxillary line with through-cutting instruments.
- Anterior ethmoidectomy
  The ethmoid bulla can be removed by placing the J-curette into the retrobullar space (also termed *hiatus semilunaris superior*) and the entire bulla cleanly resected through gentle push-pull maneuvers on the bulla using noncutting instruments. Remnant loose tissue edges can then be removed with use a microdébrider.
- Frontal sinus recess dissection—identifying frontal sinus and SOE
  The frontal sinus recess should be completely dissected, and the frontal sinus and SOE should be identified with angled endoscopes and instruments. The frontal sinus is always anterior and medial to the SOE. The impression, or actual pedicled mesentery, of the AEA will be seen posterior to the SOE, and its location can additionally be verified using the CT navigation system.

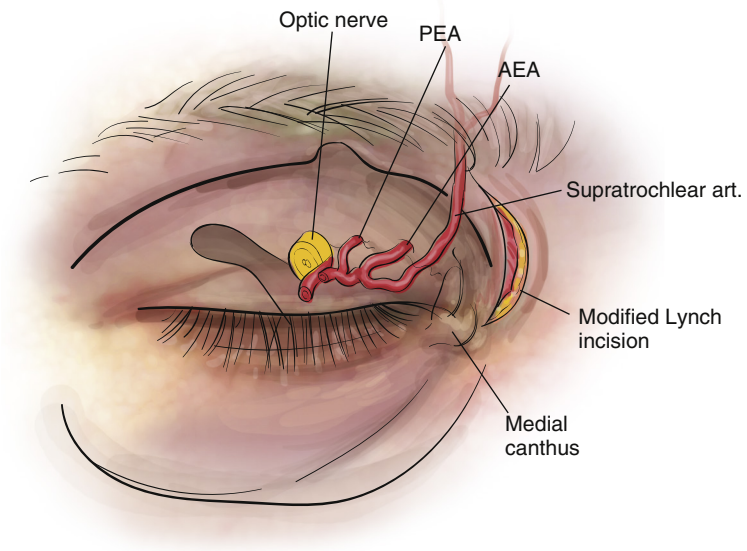

Fig. 99.4. Illustration in parasagittal view of the anterior and posterior ethmoid arteries and optic nerve. When using an external approach to ligate the AEA and/or PEA, the modified Lynch incision is typically used, which spans medial brow to level of medial canthus, within the shadow line of the orbit. The foramina to the AEA and PEA arise from within the frontoethmoid suture line. *AEA,* Anterior ethmoid artery; *PEA,* posterior ethmoid artery;

- AEA exposure
  If the AEA is hanging within a mesentery, it can be directly circumferentially ligated with bipolar cautery. If the AEA is encased in bone, the exit of the artery from the orbit is the safest manner for gaining arterial control. The lamina papyracea is gently fractured with a Cottle elevator, and the maxillary sinus seeker/Lusk probe is then used to tease the bone flakes off of the underlying periorbita. The pyramidal neurovascular bundle exiting the orbital vault should now be evident. Using angled Kerrisons, additional bone can be removed around the AEA, including a small segment of the cranial base cortical bone. Circumferential exposure of the AEA is important to achieve prior to ligation.
- Ligation of AEA
  After adequate exposure has been obtained, ligation can be performed either with two medium-sized hemoclips or, in the authors' department, bipolar electrocautery. Circumferential exposure ensures that the entire arterial vessel is ligated (Video 99.1).
- Ligation of PEA
  If the PEA is to be ligated endoscopically, a posterior ethmoidectomy is first required. The PEA is most commonly completely encased in bone; therefore the lamina papyracea needs to be removed in a similar fashion to that described for the AEA. (Video 99.2)
- Nasal packing
  No formal nasal pack is typically required after ligation, but at the completion of the dissection, the middle turbinate should be medialized as done in routine endoscopic sinus surgery to prevent lateralization and iatrogenic sinusitis in the future.

External Surgical Technique

- Corneal protection
  After the patient is intubated, the nasal packing is left in place and the cornea is protected with either a temporary tarsorrhaphy or a corneal protection shield.
- Local anesthetic
  The incision site is infiltrated with 1% lidocaine with 1:100,000 epinephrine. The incision site will be located midway between the nasal dorsum and medial canthus, along the course of the frontoethmoid suture line.
- Lynch incision (Fig. 99.4)
  A curvilinear incision is marked out in the "upper shadow line" of the orbit, between the medial brow margin and the medial canthus. The incision is made with a 15-blade scalpel down to the periosteum. A bipolar cautery should be available at this time because the angular artery may be transected during this incision. A Cottle elevator is then used to gently elevate the periosteum in a posterior direction off of the nasal bone, the frontal process of the maxilla bone, and the lamina payracea.
- Soft tissue elevation
  It is important to identify three different landmarks in the initial elevation. The superior limit of the elevation is just beyond the frontoethmoidal suture line, the inferior limit is the lacrimal sac, and the lateral elevation is to the junction between the anterior lacrimal crest and the frontoethmoidal suture line. The identification of this junction guides the direction of the elevation along the contour of the medial orbital wall. Elevation should occur along or parallel to the frontoethmoid suture line (although this "line" is never actually visualized under dissection). Occasionally, small commissural venules between the periorbita and the underlying bone may be encountered. These may be confused for the AEA neurovascular bundle but tend to appear evanescent and small in caliber. Only occasionally do these vessels require bipolar cautery for management.
- Identification of AEA
  The AEA should be identified approximately 24 mm from the anterior lacrimal crest, appearing as a thick "pyramid" of soft tissue surrounded by a fascia bundle clearly extending from lateral to medial through its foramen. The skin can be retracted with small skin hooks, and the orbital contents can be gently retracted laterally with a flat malleable retractor. After the AEA is identified, tissue planes should be elevated around and beyond the vessel to expose the AEA. At the authors' institution, we switch to a 3-mm endoscope to help to visualize and ligate the vessel.
- Ligation of AEA
  Ligation can be performed with two medium-sized hemoclips or bipolar cautery to control the entire caliber of the vessel in situ, without vessel retraction. The most proximal/lateral site of the AEA is essential to control (Video 99.3).
- Ligation of PEA
  If the PEA is also to be addressed through this approach, further periorbital elevation along the frontoethmoid

suture line is required, and increased soft tissue retraction in the orbital vault is required. The additional depth of dissection required would be approximately 12 mm from the AEA foramen. Extreme caution should be exercised when ligating the PEA, given its proximity to the optic nerve (6 mm away from the PEA foramen). Ligation of the PEA should preferably be accomplished with hemoclips to avoid inadvertent heat transmission to the adjacent optic nerve. Care should be taken not to traumatize the optic nerve with the hemoclips.

- Assessment of hemostasis
  The wound site should then be irrigated while the packing is removed from the nasal cavity. The nasal mucosa lining will be engorged and should be decongested with oxymetazoline-soaked pledgets before endoscopic assessment of the entire nasal cavity.
- Closure of the incision
  The wound is then closed using a two-layered closure technique. Steri-Strips and/or tissue glue are then applied to the incision site.

Common Errors in Technique

1. Inadequate identification of SOE
   If CT navigation is not used to help to identify the AEA, the ability to surgically identify the SOE should be a skill set comfortable for the individual surgeon to accurately identify the AEA.
2. Inadequate high or low soft tissue elevation
   Identification of the frontoethmoid suture line is paramount in finding the AEA and ensuring the soft tissue elevation is not performed too high or low.

POSTOPERATIVE PERIOD

Postoperative Management

1. If arterial ligation is done endonasally, standard ESS postoperative instruction should be given, including avoidance of nose blowing and strenuous activity.
2. Start saline irrigation on postoperative day 1.
3. Patients should expect to be seen postoperatively for débridement and removal of any middle meatal spacer placed during surgery (usually postoperative day 7 to 14).
4. Pain tolerance can vary, and a small course of narcotics is prescribed for the first few days. Many patients manage discomfort following this procedure with over-the-counter nonsteroidal anti-inflammatory drugs (NSAIDs) in conjunction with acetaminophen.
5. Resumption of anticoagulants/antiplatelet drugs on postoperative day 2 in our practice

Complications

1. Retro-orbital hematoma
   Remove all packs from the nasal cavity. The surgeon must be prepared to perform a lateral canthotomy and cantholysis. IOP measurements may be obtained. Additional agents such as dexamethasone and acetazolamide can be provided. Ophthalmology should be consulted immediately, but the treatment of the hematoma should not be delayed.
2. CSF leak
   Refer to Chapter 116.
3. Synechiae
   Routine postoperative assessment and débridement will help to decrease synechiae formation. Scar bands can typically be removed in the clinic with through-cutting instruments.
4. Iatrogenic sinusitis
   Patients should first be tried on medical treatment, including saline irrigation, antibiotics, and nasal steroids. If medical management fails, surgical correction may be considered if an anatomic concern/obstruction is identified, such as restenosis of a surgical maxillary antrostomy.
5. Facial scar contracture/web at the Lynch incision site
   This can be addressed with an in-office Z-plasty procedure.
6. Hypesthesia over external incision site
   Hypesthesia should resolve by 6 to 12 months. If there is no resolution by 1 year, hypesthesia is likely permanent.

Alternative Management Plan

1. Transcaruncular approach
   Ocular/oculoplastic surgeons generally perform this approach. This approach leaves no skin incision.
2. Embolization
   This alternate plan should be approached with extreme caution. Embolization of the AEA or PEA may result in visual loss. This should only be considered if all alternative plans have failed and has never been required in our institution.

DISCUSSION

Evidence-Based Medicine Question

In what conservative ways can one manage AEA epistaxis?

Epistaxis seen in the Emergency Department is primarily managed with some form of nasal packing. Absorbable packs are preferred because they result in less pressure to the surrounding nasal mucosa and do not require another visit to the emergency department for the removal of the pack; however, they may not be as efficient as nonabsorbable packs in controlling serious epistaxis. Commonly used nonabsorbable packs are gauzes, Merocel sponges, or some form of inflatable intranasal device for titratable tamponade.

Balloons may have an anterior balloon (e.g., Rapid Rhino), an anterior and posterior balloon (e.g., Epistat), or a posterior balloon (e.g., Foley). Unfortunately, balloons can result in a number of complications, such as mucosal, soft palate, or cartilage necrosis in addition to the obvious discomfort to the patient. Despite physicians being aware of the discomfort and complications of balloons, most otolaryngologists still use balloons despite knowing that ligation techniques are a superior intervention. In the authors' institution, if a balloon is required to stabilize a nosebleed, it then acts as a bridge to the operating room in performing a surgical ligation technique.

The best solution for patients occurs when no nasal packs are used. Warm water irrigation is a well-documented technique in addressing epistaxis. The temperature of the water should be between 46°C and 52°C. It is believed that the hemostatic effect is secondary to edema, decrease in intravascular pressure secondary to vasodilation and capacitance, and improved efficiency of the clotting cascade.

Patients who fail conservative management for epistaxis or require a balloon nasal pack should be considered for arterial ligation.

Editorial Comment

Knowledge of safe and effective surgical ligation techniques of the AEA and PEAs is important in the armamentarium of the otolaryngologist because the usual alternative for control of bleeding (i.e., arterial embolization) is not an option when patients present with epistaxis secondary to bleeding from these vessels or for anterior skull base approaches. The authors

describe both endoscopic and open approaches to surgical ligation, as well as useful adjuncts to achieve successful control of epistaxis.

Stella E. Lee

Access the review questions and additional sources list online at http://www.expertconsult.com

REFERENCES

1. Kubba H. Childhood epistaxis. Clin Otolaryngol 2006;31(3):212–213.
2. Pallin DJ, Chng Y-M, McKay MP, et al. Epidemiology of epistaxis in US emergency departments, 1992 to 2001. Ann Emerg Med 2005;46(1):77–81.
3. Lander MI, Terry O. The posterior ethmoid artery in severe epistaxis. Otolaryngol Head Neck Surg 1992;106(1):101–103.
4. Novoa E, Schlegel-Wagner C. Hot water irrigation as treatment for intractable posterior epistaxis in an out-patient setting. J Laryngol Otol 2012;126(1):58–60.
5. Schlegel-Wagner C, Siekmann U, et al. Non-invasive treatment of intractable posterior epistaxis with hot-water irrigation. Rhinology 2006;44(1):90–93.
6. Jang DW, Lachanas VA, White LC, et al. Supraorbital ethmoid cell: a consistent landmark for endoscopic identification of the anterior ethmoidal artery. Otolaryngol Head Neck Surg 2014;151(6):1073–1077.
7. Wang L, Youseef A, Al Qahtani AA, et al. Endoscopic anatomy of the middle ethmoidal artery. Int Forum Allergy Rhinol 2014;4(2):164–168.
8. Stammberger H, Posawetz W. Functional endoscopic sinus surgery. Concept, indications and results of the Messerklinger technique. Eur Arch Otorhinolaryngol 1990;247(2):63–76.
9. Han JK, Becker SS, Bomeli SR, et al. Endoscopic localization of the anterior and posterior ethmoid arteries. Ann Otol Rhinol Laryngol 2008;117(12):931–935.
10. Lee WC, Ming Ku PK, van Hasselt CA. New guidelines for endoscopic localization of the anterior ethmoidal artery: a cadaveric study. Laryngoscope 2000;110(7):1173–1178.

REVIEW QUESTIONS

1. What is the distance of the anterior ethmoid artery (AEA) from the anterior lacrimal crest?
   a. 20 to 24 mm
   b. 9 to 16 mm
   c. 4 to 9 mm
   d. 1 to 4 mm

2. What is the course of the AEA along the anterior skull base when viewed from below with an endoscope?
   a. Posterior medially, anterior laterally
   b. Anterior medially, posterior laterally
   c. No consistent course

3. On computed tomography (CT) imaging, which muscles are most closely approximated to the medial orbital exit site/nipple of the AEA?
   a. Superior rectus and superior oblique muscles
   b. Medial rectus and inferior oblique muscles
   c. Superior oblique and medial rectus muscles
   d. Inferior oblique and inferior rectus muscles

4. In which direction is the flow of blood through the AEA and posterior ethmoid artery (PEA) vessels?
   a. Lateral (orbital) to medial (cribriform skull base)
   b. Medial (cribriform skull base) to lateral (orbital)
   c. Bidirectional

ADDITIONAL SOURCES

Akdemir G, Tekdemir I, Altin L. Transethmoidal approach to the optic canal: surgical and radiological microanatomy. Surg Neurol 2004;62(3):268–274.

Floreani SR, Nair SB, Switajewski MC, et al. Endoscopic anterior ethmoidal artery ligation: a cadaver study. Laryngoscope 2006;116(7):1263–1267.

Stangerup SE, Thomsen HK. Histological changes in the nasal mucosa after hot-water irrigation. An animal experimental study. Rhinology 1996;34(1):14–17.

Tam S, Rotenberg B. Contemporary perspectives on the management of posterior epistaxis: survey of canadian otolaryngologists. J Otolaryngol Head Neck Surg 2011;40(3):249–255.

Vermeeren L, Derks W, Fokkens W, et al. Complications of balloon packing in epistaxis. Eur Arch Otorhinolaryngol 2015;272(10): 3077–3081.

100 Surgical Management of Hereditary Hemorrhagic Telangiectasia

*Li-Xing Man, Berrylin J. Ferguson**

INTRODUCTION

Hereditary hemorrhagic telangiectasia (HHT) is an autosomal dominant genetic disorder with incomplete penetrance that is characterized by arteriovenous malformations (AVMs) in various organs and mucocutaneous telangiectasias in the nose, oral cavity, gastric mucosa, and fingers. Diagnosis is based on the Curaçao criteria, established in 2000 (Table 100.1).[1] Recurrent epistaxis is the most common symptom, present in almost all patients who have HHT by the age of 40, and it is often the most troublesome manifestation for the majority of patients. Nevertheless, the severity of epistaxis is rarely immediately life threatening compared with other manifestations such as pulmonary or cerebral AVMs (Table 100.2). International guidelines for the workup and management of the various manifestations of HHT were established in 2011.[2] Therefore, it is useful to evaluate and manage patients with HHT or suspected HHT in a multidisciplinary setting.

A patient presenting with recurrent epistaxis and multiple telangiectasias should be referred to an HHT center, if possible, for comprehensive evaluation. The incidence of HHT occurs worldwide at approximately 1 in 5000 but is increased in some specific locations. Multiple genes have been implicated in HHT, but each family will have a constant genetic finding. Genetic tests are available for a few of the major mutations. Usually genetic testing is not required as the diagnosis may be made clinically.

The average age of onset for epistaxis is 12 years, and approximately 50% of patients will be affected by age 20.[2] Epistaxis may be unilateral or bilateral, minimally bothersome to life threatening. Mild epistaxis may be managed medically with humidification of the nasal mucosa, avoidance of anticoagulants, and application of nasal pressure. Iron supplementation may be necessary for resulting anemia. The vascular endothelial growth factor A (VEGF-A) inhibitor bevacizumab has been used in an off-label manner via intranasal spray, submucosal injection, or intravenously.[3,4] Although the use of this monoclonal antibody is promising, the degree of efficacy, safety profile, and optimal delivery method and dosage have yet to be firmly established. Specifically for bevacizumab, none of the life-threatening side effects of systemic administration have been reported with topical nasal application.[4] However, two randomized clinical trials of bevacizumab nasal spray did not reduce the duration[5] or frequency[6] of the epistaxis compared with placebo (0.9% saline). Other medical therapies with limited evidence of efficacy include estrogen, timolol, thalidomide, tranexamic acid, and *N*-acetylcysteine.[6,7] Surgical management of HHT should be considered when severe epistaxis results in blood transfusions, emergency department visits, and significantly reduced quality of life. Surgical treatment options include coagulation, radiofrequency ablation, septodermoplasty, and nasal closure (Young procedure). The Epistaxis Severity Score is a validated, disease-specific questionnaire that may be used to measure disease severity and assess the effect of treatment.[8]

KEY OPERATIVE LEARNING POINTS

- In-office coagulation of telangiectasias should be avoided.
- Choice of surgical treatment modality is tailored to the individual patient's disease severity.
- Patients should be assessed for other sites of potentially life-threatening telangiectasias, such as those in the brain, lungs, or gastrointestinal system.
- No surgical treatment technique is a cure for HHT-related epistaxis—telangiectasias will grow back with time. Many patients require coagulation, via laser, cautery, or radiofrequency ablation, under general anesthesia several times a year.
- The most invasive but durable procedure for controlling bleeding in HHT is the surgical closure of the nares (Young procedure). This controls epistaxis in approximately 80% of patients, but the patient must forgo nasal breathing.
- Topical or submucosal therapies with medications such as bevacizumab or tranexamic acid may be combined with surgery.

PREOPERATIVE PERIOD

History

1. History of present illness

Many of the following considerations are included in the Epistaxis Severity Score questionnaire:

   a. Is the epistaxis unilateral or bilateral? When surgical management is being considered, epistaxis is typically bilateral, but bleeding from one side may be more severe.
   b. How frequent are the nosebleeds? How long does the typical nosebleed last? Frequency and duration of the epistaxis are important to determine its effect on the patient's quality of life.
   c. Is the epistaxis gushing or pouring?
   d. How much blood is lost? The volume of bleeding should be assessed: for example, number of tissues, cups of blood, duration.
   e. How is the typical nosebleed stopped? Although HHT patients are usually quite skilled at controlling epistaxis, newly diagnosed patients may require education on preventive measures, as well as techniques to manage acute epistaxis.
   f. Is the patient anemic? Has he or she received red blood cell transfusions specifically for nosebleeds?
   g. Determine if the patient meets criteria for HHT based on Table 100.1.

2. Past medical history

   a. Prior medical and surgical treatments for episodes of epistaxis
   b. Family history: First-degree relatives with recurrent epistaxis or HHT?
   c. Medications:
      1) Antiplatelet drugs
      2) Herbal products and supplements
      3) Alcohol use

*Deceased

TABLE 100.1 Diagnosis of Hereditary Hemorrhagic Telangiectasia: The Curaçao Criteria

HHT DIAGNOSIS IS	
Definite	if 3 criteria present
Possible or suspected	if 2 criteria are present
Unlikely	if fewer than 2 criteria are present
CRITERIA	
Epistaxis	spontaneous and recurrent
Telangiectasias	lips, oral cavity, fingers, and/or nose
Visceral lesions	pulmonary, hepatic, cerebral, gastrointestinal, or spinal AVMs
Family history	first-degree relative with HHT

AVMs, Arteriovenous malformations; *HHT,* hereditary hemorrhagic telangiectasia

TABLE 100.2 Prevalence of Hereditary Hemorrhagic Telangiectasia Manifestations

Manifestation	Prevalence
Epistaxis	78% to 96%
Cerebral vascular malformations	23%
Pulmonary arteriovenous malformations	15% to 50%
Gastrointestinal	
Gastric or small intestinal telangiectasias	80%
Symptomatic gastrointestinal bleeding	25% to 30%
Hepatic	
Liver venous malformations	32% to 78%
Symptomatic liver venous malformations (e.g., high-output heart failure, portal hypertension, biliary necrosis)	8%
Spinal arteriovenous malformations	1%

Physical Examination

1. Face

There may be fine telangiectasias on the surface of the facial skin.

2. Oral cavity

   Telangiectasias are common in the mucous membranes of the oral cavity, especially on the lips, palate, and buccal mucosa.

3. Nasal cavity



   Nasal endoscopy is useful to document the size and number of AVMs (Video 100.1). Are the telangiectasias limited to the septum (Fig. 100.1), or do they extend along the lateral nasal wall and inferior turbinate? Is the middle turbinate involved (Fig. 100.2)? Is there a significant septal deviation that may limit surgical access to some of the telangiectasias? If the diagnosis of HHT is questionable, nasal endoscopy is helpful to assess for other causes of epistaxis, such as juvenile nasopharyngeal angiofibroma or other lesions. It is not always prudent to perform nasal endoscopy in the office because the procedure itself may precipitate difficult-to-control bleeding.

Imaging

1. None

   No maxillofacial imaging is necessary when it is clear that the epistaxis is secondary to HHT and the patient has already received an evaluation to assess for visceral AVMs.

2. Computed tomography (CT) or magnetic resonance imaging (MRI) of the sinuses

   If the diagnosis of HHT is doubtful and the epistaxis is thought to be secondary to a sinonasal or anterior skull base tumor, imaging of the sinuses or head may be indicated.

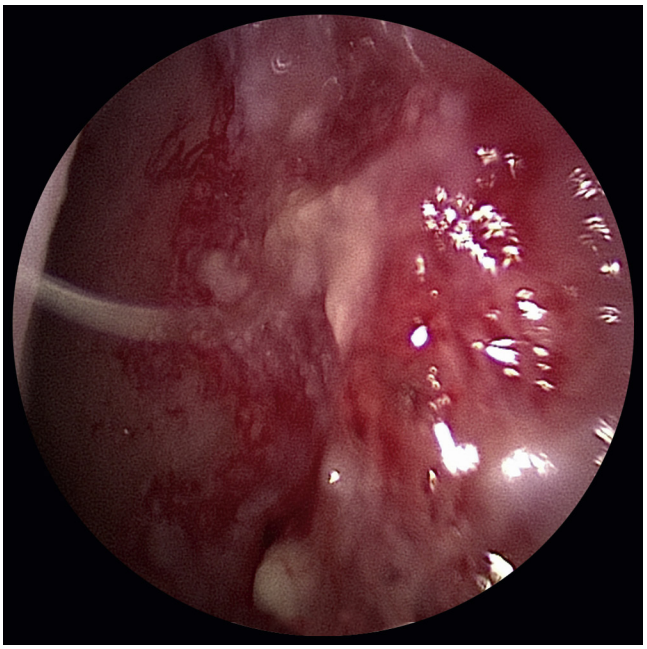

Fig. 100.1. Conglomeration of telangiectasias on the right anterior septum of a hereditary hemorrhagic telangiectasia patient.

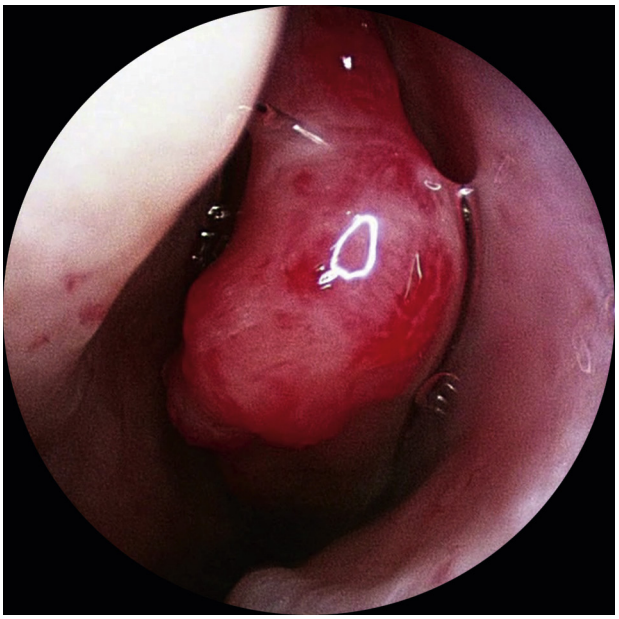

Fig. 100.2. Telangiectasias involving the left middle turbinate.

3. Brain MRI

   Adults with definite or possible HHT who have not undergone previous workup should receive a screening brain MRI with and without contrast to screen for cerebral vascular malformations. Children with definite or possible HHT who have not undergone previous evaluation should undergo unenhanced brain MRI to screen for cerebral vascular malformations.[2]

4. Transthoracic contrast echocardiography (TTCE)

   Patients with definite or possible HHT who have not been previously evaluated should receive a TTCE examination to screen for pulmonary AVMs. Screening may need to be repeated every 5 to 10 years.[2]

Indications

1. Severe, recurrent, and debilitating epistaxis refractory to conservative medical management, such as humidification and nasal emollients, may require cautery or coagulation. Topical or submucosally injected medications such as bevacizumab may be also considered.
2. Severe, recurrent epistaxis requiring blood transfusions may suggest a more aggressive surgical approach, such as septodermoplasty or nasal closure.

Contraindications

- Medical comorbidities with increased risk for general anesthesia
- Presence of other contributors to epistaxis, such as coagulopathy or hypertension, that ideally should be optimized preoperatively

Preoperative Preparation

1. Identify the dominant bleeding side and site, if possible.
2. Control acute bleeding with direct pressure or nasal packing. If nasal packing is necessary, material that would cause trauma upon removal should be avoided. We prefer absorbable hemostatic dressing, such as Surgicel Fibrillar (Ethicon US, Somerville, New Jersey) or a lubricated low-pressure pneumatic packing (Rapid Rhino, Smith & Nephew, Inc., Austin, Texas). In-office techniques to control epistaxis, such as silver nitrate ($AgNO_3$), are best avoided to prevent time-consuming and difficult-to-control worsening of acute epistaxis.
3. Discontinue antiplatelet drugs, especially if visceral AVMs are present or suspected to be present.
4. Check hemoglobin and hematocrit. Transfuse with blood products if necessary.
5. Type and crossmatch if the patient is anemic and significant intraoperative blood loss is anticipated.

OPERATIVE PERIOD

Anesthesia

- General anesthesia with oral endotracheal intubation is preferred for patient comfort and protection of the airway if there is active bleeding. If the anesthesiologist is comfortable with total intravenous anesthesia (TIVA), this may be preferable as there is usually less vasodilation compared to inhalational anesthesia. There is a lack of literature regarding the use of TIVA in the surgical management of HHT, and a few systematic reviews comparing the use of TIVA to inhalational anesthesia on the surgical field in endoscopic sinus surgery have shown mixed results.[9,10]
- If photocoagulation with a laser is planned, the segment of the endotracheal tube protruding from the oral cavity should be covered with wet gauze sponges. Taping of the endotracheal tube should be limited to the lower lip. For the right-handed surgeon an oral Ring-Adair-Elwyn (RAE) tube placed to the left of the tongue and taped to the left lower lip provides ideal access to the nares. This is reversed for the left-handed surgeon.

Positioning

- The patient is positioned supine in the same way as an endoscopic sinus surgery procedure per surgeon preference. A slight reverse Trendelenburg position can be desired because it may decrease blood loss. The head should be turned slightly toward the surgeon so that the patient, surgeon, and monitor are coaxial.

Perioperative Antibiotic Prophylaxis

- There is no evidence-based indication for intraoperative antibiotics, although frequently a first-generation cephalosporin (or clindamycin if patient is penicillin or cephalosporin allergic) is used at induction per surgeon preference.
- If postoperative packing material is used, the surgeon may elect to prescribe a first- or second-generation cephalosporin. The first author will often prescribe 1 week of cefadroxil, a first-generation cephalosporin with twice daily dosing, to improve patient adherence rather than the more commonly prescribed cephalexin.
- For septodermoplasty, a broader-spectrum antibiotic with coverage for *Staphylococcus,* such as amoxicillin/clavulanic acid or sulfamethoxazole/trimethroprim, may be prescribed.

Monitoring

- No monitoring is necessary.

Instruments and Equipment to Have Available

1. Basic endoscopic sinus surgery set
2. Endoscopic bipolar electrocautery

A small bayonet bipolar may be effective for anterior nasal telangiectasias. However, for more posterior AVMs, a pistol grip endoscopic bipolar is preferred and is more effective than monopolar electrocautery.

3. Endoscopic clip applier

Although it is unusual to have to perform a sphenopalatine artery ligation, a specially angled clip applier may be useful. Note that sphenopalatine artery ligation usually *does not* result in elimination of telangiectasias.

4. Coagulation
   a. Laser (neodymium-doped:yttrium-aluminum-garnet [Nd:YAG] or potassium titanyl phosphate [KTP])
   b. Radiofrequency ablation (Coblator II Surgery System, Smith & Nephew, Inc., Austin, Texas)
   c. Traditional Bovie or suction Bovie electrocautery, if neither laser nor radiofrequency ablation is effective
5. Septodermoplasty
   a. Straight microdébrider
   b. Suction Freer elevator
   c. Dermatome

Key Anatomic Landmarks

- Common sites of intranasal AVMs include the nasal septum, inferior turbinate, anterior floor of the nasal cavity, and the head of the middle turbinate.
- The septal perichondrium should be preserved in septodermoplasty.
- A septoplasty may be required to obtain adequate access to telangiectasias that are obstructed secondary to deviations or spurs.

Prerequisite Skills

- Basic endoscopic sinus surgery skills, if performing under endoscopic visualization
- Skill with headlight and instrumentation, if performing in the absence of an endoscope
- Laser safety course, if a laser is to be used

Operative Risks

- Intraoperative hemorrhage from AVMs
- Inability to control bleeding
- Injury to the septal cartilage resulting in septal perforation

Surgical Technique

Coagulation

For limited telangiectasias, bipolar cautery is a useful option. Laser photocoagulation is a popular option for more extensive AVMs. Usually a laser with deeper tissue penetration, such as the Nd:YAG (1064 nm) laser, or a laser with a wavelength that is well absorbed by hemoglobin, such as the KTP (532 nm) laser, is used. Diode and argon lasers also have been used for HHT epistaxis.

The endotracheal tube and eyes are protected with moist gauze or towels. Oxymetazoline 0.05% is applied intranasally either via spray or by ½-inch × 3-inch neurosurgical patties. If patties are placed, they must be inserted gently to avoid mucosal trauma. The greater palatine arteries may be vasoconstricted with lidocaine 1% with epinephrine 1:100,000 via the greater palatine foramen using a 25- to 27-gauge needle bent at 45 degrees 2.5 cm from the distal tip. The anterior palatine and facial artery vessels entering the nasal floor at the pyriform aperture also may be injected by submucosally advancing a 27-gauge needle for approximately 1 cm along the nasal floor. Under endoscopic guidance, a 22-gauge spinal needle bent at 45 degrees 1.5 from the tip on a 3-mL syringe is used to inject the area of the sphenopalatine artery at the lateral attachment of the middle turbinate to the palatine bone. It is important to draw back before injection to avoid direct administration into a vessel.

If the KTP laser is used, the laser is initially set to 8 watts, 20 milliseconds, and 2 pulses per second. The laser fiber is threaded through a straight suction or a curved olive-tipped suction depending on the desired angle. Telangiectasias seen on the septum, inferior turbinate, lateral nasal wall, middle turbinate, and nasal floor are spot lasered. Lesions that are raised and broad are more resistant to laser coagulation and should be approached by applying the laser to the surrounding mucosa and the edges before moving in toward the center of the AVM.

Radiofrequency ablation, commercially termed as coblation (i.e., "controlled ablation"), may be used as an alternative to laser coagulation. This method uses radiofrequency energy to excite electrolytes in a conductive medium, typically saline solution. The energized sodium ions form a plasma field with sufficient energy to break molecular bonds in tissues at relatively low temperatures (typically 40°C to 70°C) while minimizing injury to surrounding tissues. In our experience, the coblation wand is more facile to use relative to the laser and often provides superior intraoperative results. The PROcise EZ View wand (EICA8875-01, Smith & Nephew, Inc., Austin, Texas) is a low-profile wand with a slightly angled tip designed for sinonasal procedures (Fig. 100.3, Video 100.2). Initially, the default settings are lowered to Coblate-4, Coagulate-2. These settings may be increased as the surgeon becomes more accustomed to the tissue properties of the patient during the procedure. The disadvantage of the low-profile wand is that it tends to clog more readily than thicker wands designed for tonsillectomy and adenoidectomy. The char that collects between the three wires and within the wand may be carefully cleaned using the stylet of the 22-gauge spinal needle used to inject the sphenopalatine artery area.

The nasal cavity is irrigated with saline after completing the coagulation. If bevacizumab is used, this may be injected submucosally or applied topically via surgical patties. An absorbable dressing may be placed, or a fibrin sealant (Evicel, Ethicon US) or topical gelatin-thrombin matrix (FloSeal Hemostatic Matrix, Baxter Healthcare Corporation, Deerfield, Illinois) may be applied at the end of the procedure.

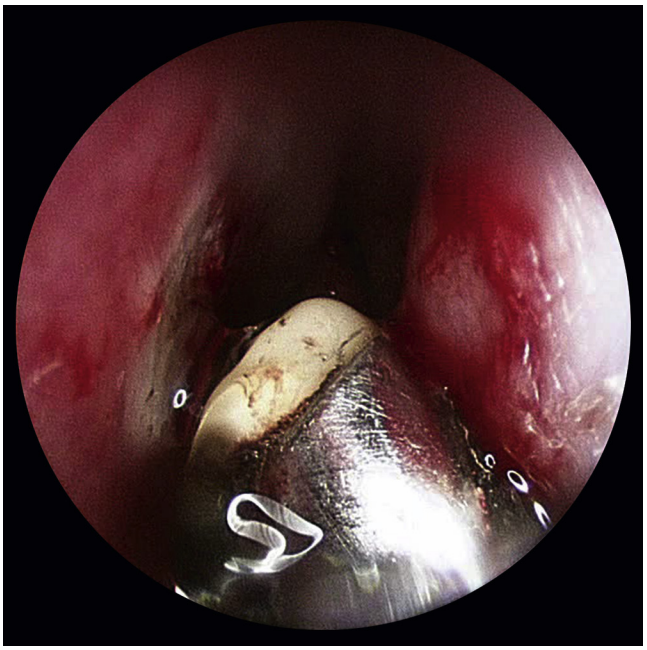

Fig. 100.3. Radiofrequency ablation of intranasal telangiectasias.

Septodermoplasty

Septodermoplasty is considered when a patient continues to have severe epistaxis despite laser or radiofrequency coagulation of AVMs. The nasal cavity is decongested in the same way as it is described for coagulation. Lidocaine 1% with epinephrine 1:100,000 is injected along the septum in a submucosal plane. A split-thickness skin graft is obtained with an electric dermatome, with the donor site dependent on surgeon preference. The size of the graft is dependent on the desired septodermoplasty area. This may be measured, but usually a 6-cm × 3-cm graft is adequate to cover the septum and extend posteriorly to the anterior face of the middle turbinate. If bilateral septodermoplasty is performed, a 12-cm × 3-cm graft may be obtained and divided in two. The split-thickness skin graft is placed on paraffin gauze dressing with the skin side down and then fenestrated.

Using a 0-degree endoscope, a straight 4-mm microdébrider is used to remove the septal mucosa, working from posterior to anterior starting just anterior to the anterior face of the middle turbinate so that blood does not obscure the surgical field. Gentle pressure is applied to remove the mucosa while *preserving the perichondrium*. This step can result in significant blood loss, and therefore bleeding may be controlled with a mix of topical epinephrine and thrombin. Although there are no HHT procedure-specific studies regarding systemic absorption, concentrated topical (1:1000) epinephrine has been shown to be safe and efficacious in endoscopic sinus surgery.

The split-thickness skin graft is then inserted intranasally, along with the paraffin gauze dressing for support. After the graft is maneuvered to its desired location, the paraffin gauze is removed. A 4-0 plain gut suture is used to quilt the suture to the nasal septum. Tacking sutures should be placed as superiorly as possible to prevent the graft from slipping inferiorly. Fibrin glue is used at the anterior edge of the graft to hold it in place. Either a Doyle splint or a bioresorbable dressing, such as NasoPore (Stryker Corporation, Kalamazoo, Michigan), is placed to support the graft. If a silastic splint is used, it is removed in the clinic 10 to 14 days postoperatively. Absorbable dressings do not have to be removed.

Alternatively, anterior clusters of telangiectasias may be treated with a buccal mucosal graft. This can be easily harvested from telangiectasia-free buccal mucosa of the desired size. The donor site is closed primarily with absorbable suture. Next, an incision as for a septoplasty is made anteriorly or anterior to the telangiectasias. Using a sharp elevator, the mucosa is elevated in a supraperichondrial plane. The buccal graft is secured, similar to a split-thickness skin graft, with through-and-through absorbable suture, and tacking sutures are placed at the anterior edges.

Septodermoplasty may be performed unilaterally or bilaterally. However, if there is question of injury to the cartilaginous septum, the contralateral side should be done as a staged procedure. If there are significant AVMs on the nasal floor or inferior turbinate, the graft may be extended to cover the nasal floor and lateral nasal wall. Resection of the inferior turbinate may be necessary to allow the graft to drape tension-free along the lateral nasal wall.

Nasal Closure (Young Procedure)

Young procedure, or surgical closure of the nares, is performed with the patient under general anesthesia. Lidocaine 1% with epinephrine 1:100,000 is injected into the lateral nares and septum for vasoconstriction. A circumferential incision is created in the mucocutaneous junction in the anterior nasal vestibule. This is divided into three approximately equal separate anterior-based flaps. These flaps are elevated to the alar rim. Absolute hemostasis must be achieved before a tension-free approximation of the flaps is performed using dissolvable suture with vertical mattress stitches. Antibiotic ointment is placed on the suture line. The procedure may be performed either unilaterally or bilaterally. There is rarely bleeding behind the flaps, but if significant bleeding does occur, the closure will need to be opened to stop the bleeding source.

As a test of the patient's tolerance for the closure, one can try a Vaseline-coated cotton ball inserted into the nostrils, changing it three times a day. This form of occlusion is very useful for decreasing the bleeding dramatically by preventing airflow over the telangiectasias and is readily reversible. This form of occlusion may be used indefinitely.

Common Errors in Technique

Coagulation

- The laser fiber must be placed close enough to the AVM such that the vessel absorbs the energy but not so close that the resulting char sticks to the fiber, as this will invariably result in unwanted bleeding.
- Laser and radiofrequency ablation on both sides of the septum should be avoided to decrease the risk of septal perforation. Likewise, bevacizumab injected along the cartilaginous septum may cause septal perforation, especially if opposing sides of the septum are injected.

Septodermoplasty

- The surgeon should work swiftly when removing septal mucosa using the microdébrider to limit blood loss.
- Inadvertent removal of the perichondrium will result in graft loss and potential septal perforation.

All Surgical Techniques

- No matter what the procedure, avoid nonabsorbable packing that will require postoperative removal.
- If significant blood loss occurred during surgery, check postoperative hemoglobin and hematocrit. If these have fallen significantly from preoperative levels, then transfuse to bring the patient back to his or her baseline. At baseline, many patients have low hemoglobin (i.e., 8 g/dL).

POSTOPERATIVE PERIOD

Postoperative Management

- These surgical procedures are typically performed on an outpatient basis.
- Check hemoglobin/hematocrit if significant intraoperative blood loss was encountered.
- Patients may perform saline irrigations after coagulation procedures and administer saline nasal spray after septodermoplasty.
- Patients undergoing coagulation procedures follow up 2 to 3 weeks after surgery, whereas those who undergo septodermoplasty or nasal closure follow up after 10 to 14 days.
- Septodermoplasty patients may require ongoing cleaning of intranasal crusting long term.

Complications

1. Hemorrhage
2. Synechiae
3. Septal perforation
4. Graft loss, nasal congestion, nasal dryness, decreased sense of smell, and foul-smelling endonasal crusting may occur after septodermoplasty.
5. Dehiscence of the closure, bleeding posteriorly into the nasopharynx and oropharynx, xerostomia, anosmia, and decreased sense of taste may occur after Young procedure.

Alternative Management Plan

- Endovascular embolization is rarely recommended for the treatment of epistaxis in HHT, and there is limited evidence to support its use as a management option.[7]
- Sphenopalatine artery ligation is unlikely to affect bleeding from telangiectasias.
- Bevacizumab may be used topically or intravenously with or without surgical techniques.

DISCUSSION

Evidence-Based Medicine Question

What forms of bevacizumab have been shown in small studies to be effective, and what is the mechanism of action?

- Answer: Low-dose systemic (intravenous), submucosal intranasal injections, and topical sprays

What is and how durable is the Young procedure? What percentage of patients benefit from the Young procedure?

- Answer: Young procedure is the surgical closure of the nose, either unilaterally or bilaterally. It is effective in approximately 80% of patients.

Editorial Comment

There is a need for better understanding of the etiology of HHT to develop effective therapeutics in the treatment of this disorder, which not only affects the nasal cavity but multiple organ systems requiring a multidisciplinary approach. The establishment of HHT Centers of Excellence seeks to provide comprehensive care for the HHT patient. The authors describe several techniques for managing epistaxis in this challenging patient population.

Stella E. Lee

Access the review questions and additional sources list online at http://www.expertconsult.com

REFERENCES

1. Shovlin CL, Guttmacher AE, Buscarini E, et al. Diagnostic criteria for hereditary hemorrhagic telangiectasia (Rendu-Osler-Weber syndrome). Am J Med Genet 2000;91(1):66–67.
2. Faughnan ME, Palda VA, Garcia-Tsao G, et al. International guidelines for the diagnosis and management of hereditary haemorrhagic telangiectasia. J Med Genet 2011;48(2):73–87.
3. Karnezis TT, Davidson TM. Treatment of hereditary hemorrhagic telangiectasia with submucosal and topical bevacizumab therapy. Laryngoscope 2012;122(3):495–497.
4. Arizmendez NP, Rudmik L, Poetker DM. Intravenous bevacizumab for complications of hereditary hemorrhagic telangiectasia: a review of the literature. Int Forum Allergy Rhinol 2015;5(11):1042–1047.
5. Dupuis-Girod S, Ambrun A, Decullier E, et al. Effect of bevacizumab nasal spray on epistaxis duration in hereditary hemorrhagic telangiectasia: a randomized clinical trial. JAMA 2016;316(9):934–942.
6. Whitehead KJ, Sautter NB, McWilliams JP, et al. Effect of topical intranasal therapy on epistaxis frequency in patients with hereditary hemorrhagic telangiectasia: a randomized clinical trial. JAMA 2016;316(9):934–951.
7. Chin CJ, Rotenberg BW, Witterick IJ. Epistaxis in hereditary hemorrhagic telangiectasia: an evidence based review of surgical management. J Otolaryngol Head Neck Surg 2016;45:3.
8. Hoag JB, Terry P, Mitchell S, et al. An epistaxis severity score for hereditary hemorrhagic telangiectasia. Laryngoscope 2010;120(4):838–843.
9. Kelly EA, Gollapudy S, Riess ML, et al. Quality of surgical field during endoscopic sinus surgery: a systematic literature review of the effect of total intravenous compared to inhalational anesthesia. Int Forum Allergy Rhinol 2013;3(6):474–481.
10. DeConde AS, Thompson CF, Wu EC, et al. Systematic review and meta-analysis of total intravenous anesthesia and endoscopic sinus surgery. Int Forum Allergy Rhinol 2013;3(10):848–854.

REVIEW QUESTIONS

1. Approximately what percentage of patients with HHT will have epistaxis as a symptom?
   a. 35%
   b. 55%
   c. 75%
   d. 95%

2. Which of the following is NOT routinely recommended in the workup of HHT?
   a. Hemoglobin/hematocrit to screen for gastrointestinal bleeding and anemia
   b. Pulmonary CT or angiography to screen for pulmonary arteriovenous malformations
   c. Brain MRI for cerebral vascular malformations
   d. Directed endoscopic gastrointestinal evaluation should be undertaken in patients with anemia disproportionate to epistaxis.

3. Common complications of septodermoplasty include all of the following, except
   a. Nasal dryness
   b. Endonasal crusting
   c. Chronic rhinosinusitis
   d. Recurrence of arteriovenous malformations

4. The following statements are all characteristics of the transmission and epidemiology of HHT, except
   a. Various gene mutations cause an increase in vascular endothelial growth factor.
   b. HHT occurs worldwide with an incidence of approximately 1 in 5000.
   c. HHT is inherited in an autosomal dominant manner with complete penetrance.
   d. Genetic testing is available for common forms of HHT.

5. The following are recommended surgical techniques for controlling HHT-associated epistaxis, except
   a. Sphenopalatine artery ligation
   b. Coagulation of telangiectasias with laser or radiofrequency ablation under anesthesia
   c. Septodermoplasty
   d. Closure of the nares

ADDITIONAL SOURCES

Epistaxis Severity Score for Hereditary Hemorrhagic Telangiectasia Online Tool. <https://www2.drexelmed.edu/HHT-ESS/>

Gunaratne DA, Barham HP, Christensen JM, et al. Topical concentrated epinephrine (1:1000) does not cause acute cardiovascular changes during endoscopic sinus surgery. Int Forum Allergy Rhinol 2016;6(2):135–139.

Guthrie CC, Karnezis TT, Orosco RK, et al. The effect of anterior palatine blocks on bleeding in hereditary hemorrhagic telangiectasia nasal surgery. Laryngoscope 2013;123(11):2598–2600.

HHT Foundation International, Inc. <http://curehht.org/resources/physician-resources/>

HHT Treatment Centers. <http://curehht.org/resources/hht-treatment-centers/treatment-centers/>

Korkmaz H, Yao WC, Korkmaz M, et al. Safety and efficacy of concentrated topical epinephrine use in endoscopic endonasal surgery. Int Forum Allergy Rhinol 2015;5(12):1118–1123.

Luk L, Mace JC, Bhandarkar ND, et al. Comparison of electrosurgical plasma coagulation and potassium-titanyl-phosphate laser photocoagulation for treatment of hereditary hemorrhagic telangiectasia-related epistaxis. Int Forum Allergy Rhinol 2014;4(8):640–645.

101 Rhinectomy

Sefik A. Hosal, Canset Aydin

INTRODUCTION

The nose is the most prominent part of the face defining an individual's unique identity. It plays an important role functionally and aesthetically. However, the prominent position of the nose also accounts for its constant exposure to sunlight and thus for its predisposition to the development of cancer of the overlying skin. Thus surgical resection of the nose, rhinectomy, presents a difficult problem for both the patient and the surgeon. Rhinectomy is defined as the removal of the vast majority of the nasal framework and soft tissue. Rhinectomy involves not only surgical resection with adequate tumor margins but also reconstruction of the nose for satisfactory cosmesis. Surgical resection of the nose can be classified as a partial or total rhinectomy based on the extent of the excision. In head and neck surgery, the classical assumption of a wide surgical resection with control of margins is usually preferred; however, this may not be applicable for rhinectomy, due to anatomic limitations such as the orbit, skull base, and brain. Additionally, extensive resection may result in an unacceptable cosmetic defect that may cause rejection, depression, and other psychosocial problems.

The anterior nasal cavity is bounded by the bony pyriform aperture, hard palate, and external framework of the nose. The external nose is composed of bone and cartilage. The nasal septum divides the nasal cavity and connects with the nasal bones. It is continuous with the upper lateral cartilages anteriorly and medial crura of the alar cartilages inferiorly. The anterior nasal septum, lower lateral cartilages, and columella form the nasal vestibule. The nasal cavity is lined by ciliated mucosa and the nasal vestibule with stratified squamous epithelium.

Malignant tumors of the nose are quite rare and can be classified as internal and external cutaneous tumors. The majority of nasal tumors comprise external cutaneous cancers including basal cell carcinoma, squamous cell carcinoma, and melanoma,[1] which commonly occur along the ala and dorsum of the nose.[2] Most cancers of the nasal cavity are squamous cell carcinoma and adenocarcinoma.[3] Among these cancers, squamous cell carcinoma is the most frequently encountered pathology that requires rhinectomy.

Rhinectomy is indicated only for extensive, aggressive, and recurrent cancers, including multicentric or large cancer, radiotherapy failures, or recurrent squamous cell carcinoma, or for palliative reasons such as in metastatic disease. In contrast to other locations, cancers originating from the columella or nasal vestibule behave aggressively. Because of the thin subcutaneous tissue along the columella and the vestibule, there is little soft tissue resistance against tumor spread. Therefore, cancers can easily invade bone and cartilage through periosteum or perichondrium and spread into the skin of the face. Infiltration of surrounding structures such as the upper lip, cheeks, and medial canthal regions may increase the risk of recurrence. Tumor eradication is much more complex, particularly in the medial canthal area due to the risk of orbital invasion. On the other hand, regional lymphatic metastasis is uncommon for both internal and external cancers of the nose.[4] Neck dissection is only considered in clinically or radiographically evident lymph node involvement, except for cutaneous melanomas in which sentinel lymph node biopsy should be performed.

KEY OPERATIVE LEARNING POINTS

- Rhinectomy is not technically difficult, but reconstruction of the nasal framework is challenging.
- The procedure is usually reserved for extensive or recurrent cancers of the nose, particularly in multicentric or large tumors, radiation failures, recurrent cancer, or for palliation in metastatic cancer.
- Soft tissue invasion of the medial canthal region is challenging, due to the close proximity of the orbital structures.
- Intraoperative assessment of the surgical margins by frozen sections is critical in the prevention of recurrence.
- The patient should be informed preoperatively about the anticipated postrhinectomy defect and plans for reconstruction.
- Neck dissection is not a routine part of the procedure. However, possible metastasis to cervical lymph nodes should be evaluated carefully preoperatively and in postoperative follow-up, particularly in squamous cell carcinomas.

PREOPERATIVE PERIOD

The important functions of the nose, including olfaction, respiration, humidification, and filtration, as well as aesthetics, when compromised may give rise to psychologic and functional problems. The decision to proceed with rhinectomy should be taken only after the patient is informed regarding the extent of the excision and the types of reconstruction available. History of the presenting problems, physical examination, and imaging is essential to accurately plan the surgery. Invasion of the following structures should also be evaluated prior to surgical resection:

- **Adjacent structures of the nose:** The hard palate, medial canthus, orbit, maxillary sinus, and skull base that broadens the extent of the dissection and results in extended rhinectomy
- **Regional lymph node metastasis:** Though regional lymph node metastasis is rarely reported, examination must be done carefully. Examination should include all levels of the neck as well as the parotid lymph nodes. Depending on the presence of lymph node involvement, unilateral or bilateral neck dissection must be added to the primary surgery. This depends on the tumor type, which is particularly important in squamous cell carcinoma.
- **Distant metastasis:** Positron emission tomography (PET)-CT is helpful to define the presence of regional lymphatic metastasis and rule out distant metastasis.

Once a rhinectomy has been performed, the greatest challenge is providing an acceptable nasal reconstruction plan. Preoperative planning for the type of the reconstruction is very important. Either reconstruction with a nasal prosthesis or flaps may be indicated.

History

- History of present illness
  - Risk factors:
    - Tobacco and alcohol consumption
    - Radiation exposure

- Occupational exposure to chemicals and particulates, such as nickel, wood dust, radium, mustard gas, and asbestos
- Drug abuse

- Symptoms and signs:
  - The otolaryngologist must be cognizant of the potential for a nasal malignancy in patients presenting with chronic symptoms, which may also present in benign and inflammatory diseases of the nose. These symptoms include nasal congestion, nasal obstruction, nasal discharge, epistaxis, nasal crusting, intermittent bleeding, septal perforation, epiphora, headache, and erythema of the skin.
  - Other more obvious symptoms or signs include a visible nasal mass, ulceration, loss of vision, swelling of the palate, and problems with denture fit.
- Past medical history
  - In recurrent cancer, details of the previous treatment modality should be determined, including the extent and duration of surgery as well as treatment with chemoradiotherapy.
  - Comorbid diseases including systemic diseases and hemorrhagic diatheses
  - Family history
  - Medications, herbal products, and supplements taken by the patient

Physical Examination

- Face
  Inspection of the face, particularly for extension of the cancer from the nose to surrounding structures such as the medial canthus or upper lip
- Nose
  Palpation of the nose is critical because even with normal appearing skin, there may be tenderness or induration that may indicate a more insidious process.
  Anterior rhinoscopy and bilateral nasal endoscopy are important for a comprehensive evaluation of the patient presenting with a nasal mass.
  Before nasal endoscopy, appropriate decongestion and application of a topical anesthetic should be performed to provide optimal examination of the nasal cavity, nasopharynx, and sinus outflow tracts.
- Oral cavity
  Examination may reveal a soft tissue submucosal mass, ulceration, or erosion of the bone of the hard palate.
  Inspection of the teeth and detection of dental disease are important for the patient being considered for adjuvant radiotherapy.
- Neck
  Palpation of the neck for detection of lymph node metastasis is of vital importance.

Imaging

1. Computed tomography (CT) scan with and without contrast
   - A dedicated maxillofacial CT should be performed to evaluate the bony structures of the nose and involvement of the paranasal sinuses.
   - Used to detect tumor extension to the cartilage and bone
   - CT scan of the neck is necessary to evaluate whether there is cervical lymph node metastasis.
2. Magnetic resonance imaging (MRI)
   - Should be performed in all cases and is complementary to the information that the CT scan provides
   - Can help determine tumor extension to the soft tissues
   - Evaluate for intracranial extension
   - Evaluate for perineural invasion
   - Differentiate inflammatory tissue from the cancer
   - Complementary to CT for evaluation of lymph nodes in the neck
3. Chest radiograph
   - Important for preoperative assessment
   - Detection of pulmonary metastases or primary cancer of the lung
4. PET-CT
   - Not performed in all cases
   - To detect distant metastases in recurrent cases, radiotherapy failure, and aggressive primary tumors with extensive regional involvement

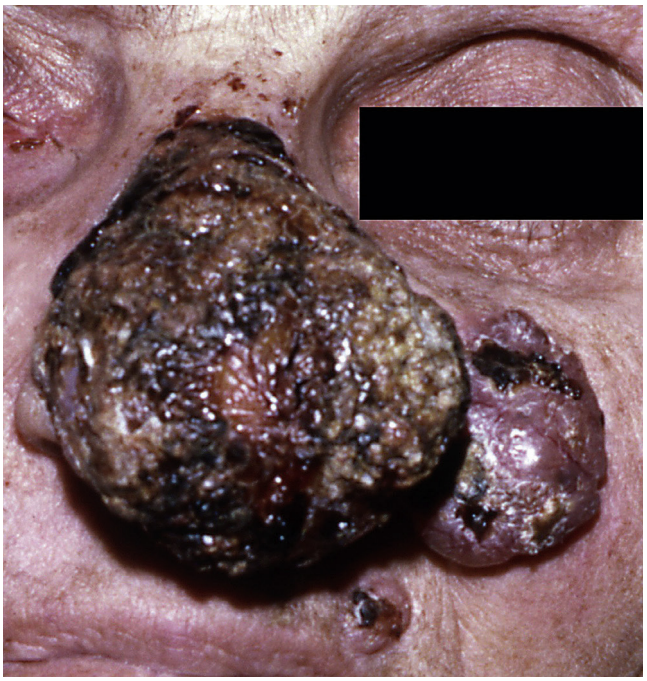

Fig. 101.1. Extensive skin cancer of the nose extending through the cheek and the upper lip.

Indications

- Extensive skin cancers of the external nasal framework (Fig. 101.1)
  - The most common cutaneous basal cell and squamous cell carcinomas and rarely melanomas, adnexal tumors, and Merkel cell carcinomas
- Extensive malignant tumors such as SCCs and adenocarcinomas of the nasal cavity, columella, nasal vestibule, septum, or the lateral nasal wall
- Recurrent or multifocal cancers after surgery or radiation therapy (Fig. 101.2)
- Palliative treatment, including cases in which there are distant metastases to the nose from a distant site

Contraindications

- Distant metastasis (Relative) It may be appropriate for palliation for patients who have bleeding or severe pain in the primary site.
- Comorbid diseases with unacceptable risk for general anesthesia
- Patient preference for nonsurgical therapy



Fig. 101.2. Recurrent tumoral defect on the lateral side of the nose.

Preoperative Preparation

- Incisional or punch biopsy to confirm the diagnosis
- Routine laboratory tests and preparation for transfusion, if necessary
- Cessation of antiplatelet/anticoagulant drugs, supplements, and herbal products
- The patient with cervical lymph node metastasis should be counseled regarding the need for neck dissection, alternatives, and expectations after the surgical resection and neck dissection.
- Consultation with an experienced maxillofacial prosthodontist for immediate reconstruction, with a prosthesis
- The patient should be counseled regarding the expected cosmetic deformity.
- The patient should discontinue smoking tobacco if a flap reconstruction is planned.

The decision of the reconstruction method depends on many factors:

- A prosthesis may be preferred in the following situations.
  - Age: Younger patients may find that a prosthetic has more acceptable aesthetic results. Older patients who may have significant comorbidities would benefit from shorter surgery duration and avoid the need for multistage procedures.
  - Size of defect: Cases without sufficient tissue to restore a large facial defect, especially in recurrent tumors or in cases with a compromised local vascular bed
  - Patients with poor prognosis, including the need for palliative surgery
  - Aggressive cancers, such as squamous cell carcinomas of the columella, which require close oncologic examination of the surgical bed, or in patients with planned postoperative radiation therapy
  - Patients who have compromise in vasculature due to comorbid conditions and/or continued tobacco use, which increases the risk of flap failure
  - Patient's preferences
  - Experience of the surgical team
- Flap reconstruction may be preferred in the following situations:
  - Patients with psychiatric illness who may not be able to tolerate a prosthesis
  - Patients who cannot manage the daily care of a prosthesis
  - Patients with previous prosthesis-related complications
  - Patient's preferences
  - Experience of the surgical team

Nasal Prosthetics

- There are many methods for placement of the prosthesis to the nasal region:
  - Medical adhesives, mainly of silicone-based adhesives, are used to attach the prosthesis to the skin.
  - Anatomic undercuts are natural anatomic indents in the surgical area for physical retention of the prosthetic. In the presence of stable tissue support, an anatomic undercut is the most suitable choice for the patient. It is a noninvasive, easy-to-use, low-cost, and tissue-tolerant method.
  - Eyeglass frames are used for retention of the prosthesis. The prosthesis is fixed to an eyeglass frame, and they should be used together. The primary disadvantage is that the patient cannot remove the eyeglasses without also removing the attached prosthesis.
  - Osseointegrated implants are used to attach the prosthesis to span the nasal defect. Implants can be placed along the zygoma, floor of the nose, glabella, orbital rim, and maxilla. Implant failure is more common at the orbital rim and maxilla due to poor quantity and quality of bone and in patients with previous radiation therapy treatment.[5] Preoperative CT scans are useful to determine whether there is sufficient bone (at least 3 mm) for implant placement. Implants are contraindicated in locations with the potential for persistent tumor involvement.

Advantages

- Better surveillance of the wound bed for recurrence
- A staged procedure is still possible with flap reconstruction performed after prosthesis placement
- Technically easier to perform than a flap reconstruction
- Inexpensive care
  - Anatomic undercuts, adhesives, and eyeglasses are preferred by the patients because of their low cost. However, a prosthesis with osseointegrated implants costs are much higher and may be comparable to the cost of free flap reconstruction.[6] Therefore there may be some cost differences between institutions or countries.
- Avoid additional surgical procedures and corresponding potential morbidity.
- Minimize psychologic distress to the patient if placed intraoperatively, which can mitigate the aesthetic repercussions of the surgery
- Shorter surgery duration

Disadvantages

- Potential dislodgement of the prosthesis
- Requirement of regular cleaning and maintenance
- Poor function, including humidification and filtration with potential obstruction of nasal breathing
- Infection in the implant region that may cause failure to retain the prosthesis

- Replacement of the prosthesis may be required due to changes from patient-related factors such as skin atrophy, radiotherapy sequelae, dissatisfaction with the appearance, or related to the prosthesis itself, including color changes, material degradation with exposure to ultraviolet light, problems with fit, localized rhinorrhea, and dermatitis.
- Patients usually need one prosthesis for summer and one for winter, based on the tanning effect from exposure to sunshine.
- Need for an experienced maxillofacial prosthodontist

Flap Reconstruction

Advantages

- Provides a better match in terms of skin color, thickness, and texture, with less variation from the rest of the face (i.e., the paramedian forehead flap).

Disadvantages

- Requirement of donor site or sites with potential related complications
- Need for multistage surgery
- Increased risk of surgical morbidity
- Final aesthetic outcome may be unsatisfactory.
- May cause a delay in the initiation of postoperative adjuvant radiation if needed
- Multidisciplinary team may be required with experience in reconstructive surgery.

OPERATIVE PERIOD

Anesthesia

- General anesthesia with orotracheal intubation

Positioning

- Supine position
  - The patient is placed in the reverse Trendelenburg position, with the head turned slightly toward the surgeon.

Perioperative Antibiotic Prophylaxis

- Rhinectomy is classified as a clean-contaminated surgical procedure, so a combination of antibiotic regimens covering anaerobes, gram-positive and gram-negative bacteria should be used.
  - First-generation cephalosporines + metronidazole
  - Clindamycin + gentamycin (in patients allergic to penicillin)
  - Our preference is ampicillin sodium/sulbactam sodium.

Monitoring

- Routine anesthesia monitoring

Instruments and Equipment to Have Available

- Standard neck dissection set
- Standard instruments for septoplasty/rhinoplasty set
- Bone cutting forceps
- Osteotomes/mallet
- Saws
- Drill
- Headlight
- Rigid endoscopes with high-definition camera/monitor

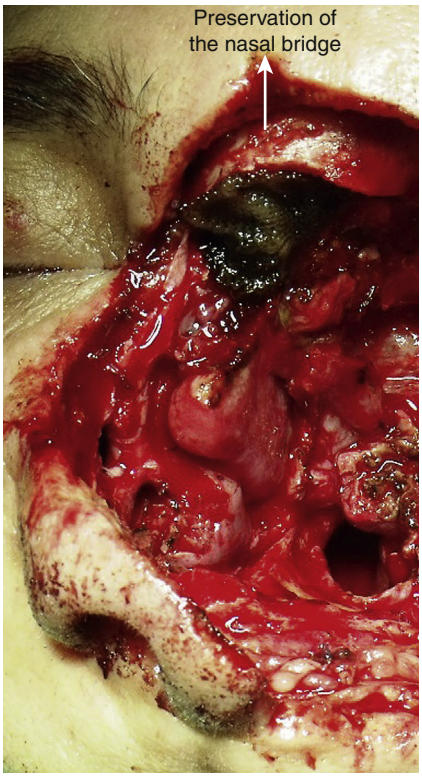

Fig. 101.3. *Arrow* indicates preservation of the nasal bone after resection.

- Bipolar electrocautery
- Monopolar electrocautery
- Bone wax
- Suture (usually 3/0 Vicryl)

Key Anatomic Landmarks

- Preservation of the nasal bone is helpful for prosthetic rehabilitation (Fig. 101.3); it does not interfere with surgical margins.

Prerequisite Skills

- Experience in head and neck surgery including the necessary soft tissue skills and experience in nasal reconstruction and/or collaboration with a reconstructive surgeon and/or a maxillofacial prosthodontist is critical.

Operative Risks

- Intraoperative hemorrhage from alar and septal branches of the facial artery, ophthalmic, and maxillary arteries
- Cerebrospinal fluid leak
- Inadvertent injury of the hard palate during osteotomies

Surgical Technique

- The surgical site should be marked appropriately, including the bilateral lateral rhinotomy incision lines that join together at the dorsum superiorly and base of the columella inferiorly (Figs. 101.4 and 101.5).
- Injection of local anesthetic with epinephrine subcutaneously under the skin incision lines, along the bilateral nasal vestibules, alar regions, gingivobuccal sulcus, and pyriform aperture

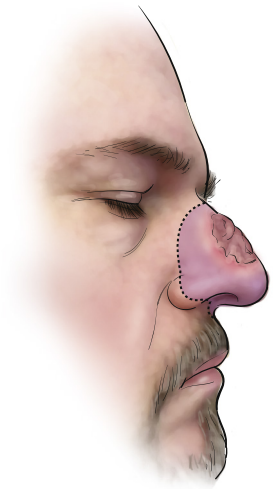

Fig. 101.4. Lateral rhinotomy incision extending to the base of the columella.

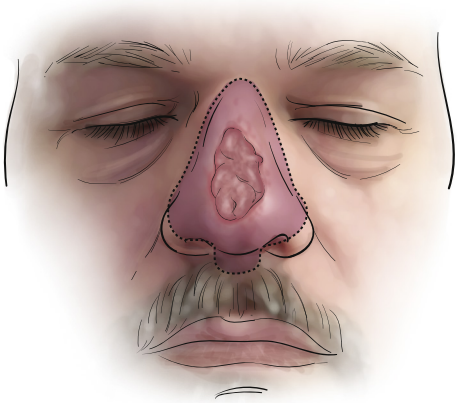

Fig. 101.5. Bilateral lateral rhinotomy incision lines joining together at the dorsum superiorly and the base of the columella inferiorly.

- Oxymetazoline pledgets are placed into the nasal cavity.
- The skin incision is initiated along the lateral edge of one nostril (Fig. 101.6).
- The incision is carried through the dorsum of the nose and joined with the inferior skin incision.
- The dissection is started from the lateral edge of one nostril, in which the alar cartilage is separated from the bony structures (lateral alatomy). Minor subcutaneous bleeding can easily be controlled with bipolar cautery.
- Retraction of both lateral sides of the nose allows identification of the septum and provides direct visualization of the extension of the cancer.
- The base of the columella is then next incised, and the caudal cartilaginous septum is exposed with monopolar cautery or scissors, according to the surgeon's preference (Fig. 101.7).
- Osteotomies along the bony septum and nasal bones are completed by through-cutting instruments.
- Resection is then completed with these osteotomies in caudo-cranial direction or vice versa.
- The remaining nasal cavity is examined with the aid of rigid endoscopes in order to detect any remaining tumor.
- Tumor margins are evaluated with frozen sections, and additional margins are obtained if necessary (Fig. 101.8).

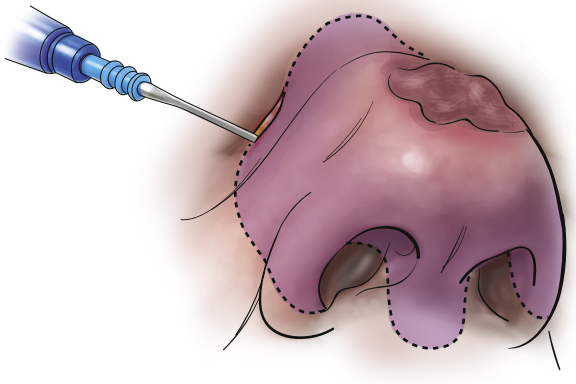

Fig. 101.6. Initial skin incision along the lateral edge of one nostril using electrocautery.

- Mucosal bleeding is controlled with cautery, and bleeding along the bone edges may require bone wax.
- The skin and mucosal edges are sutured together primarily with 3/0 Vicryl (Fig. 101.9).
- Placing Gelfoam around the cavity may prevent postoperative bleeding, and packing may not be necessary. The cavity may also be packed with gauze soaked in antibiotic ointment, according to the surgeon's preference. This can be removed in 3 days.
- The cavity is left open for healing via secondary intention; we do not use skin grafting (see Fig. 101.3).
- Rehabilitation with a prosthesis or reconstruction with flaps is then required to address the defect; the details for these procedures are beyond the scope of this chapter.
- If the rehabilitation method chosen is a prosthesis with osseointegrated implants, implants are placed at the end of surgery.
  - The estimated points should be defined preoperatively with CT.
  - The anterior part of maxillary crest, pyriform aperture, and inferior turbinates are removed in order to provide a smooth surface for implant retention.

Common Errors in Technique

- Inadequate exposure as a result of starting the dissection from midline rather than the lateral edge of the nares
- Failure to manage bleeding, which may compromise visualization and resection margins. Intraoperative delicate cauterization is needed to control bleeding from the branches of facial, maxillary, and ophthalmic vessels.
- Fragmentation and seeding of the tumor due to inaccurate resection or handling of tissue margins
- Excessive resection of nasal bones results in instability of a potential base for a nasal prosthesis. If total nasal bone resection is required because of cancer invasion, and there is resulting inadequate nasal bone present for a prosthetic base, then it may be appropriate to reconstruct with flaps rather than prosthesis.

POSTOPERATIVE PERIOD

Postoperative Management

- Cool mist humidification and saline irrigations of the nasal cavity at least twice daily to prevent crusting and facilitate débridement

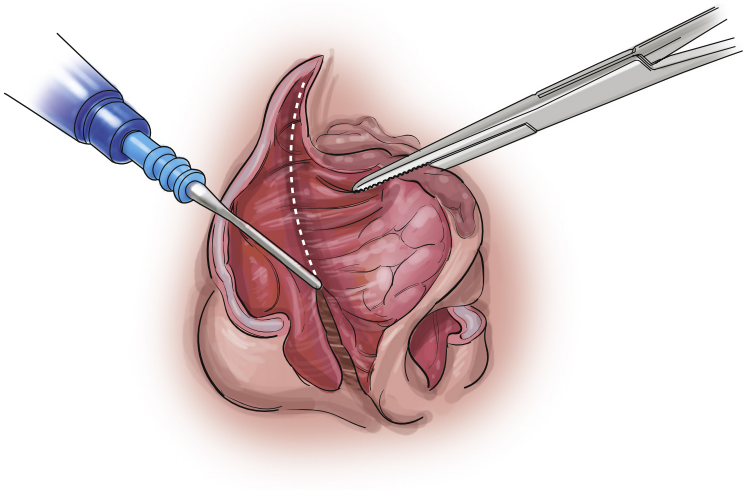

Fig. 101.7. Excision of the septum with monopolar cautery.

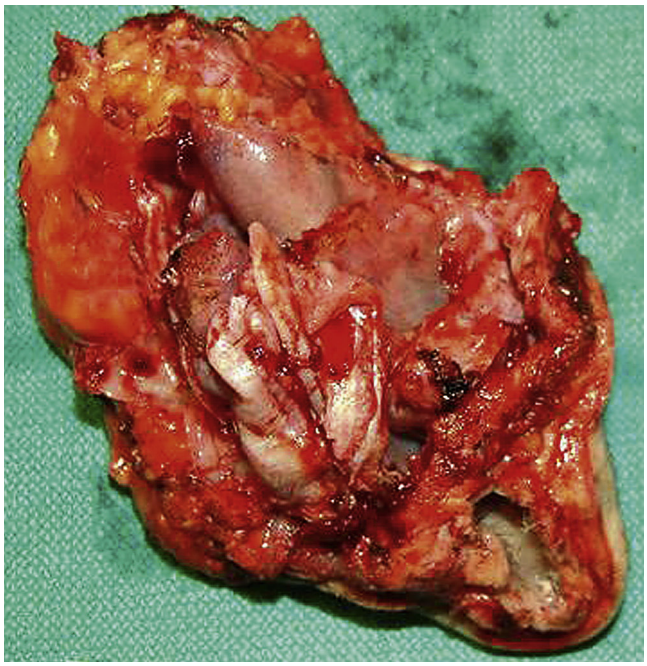

Fig. 101.8. En-bloc excision of tumor.

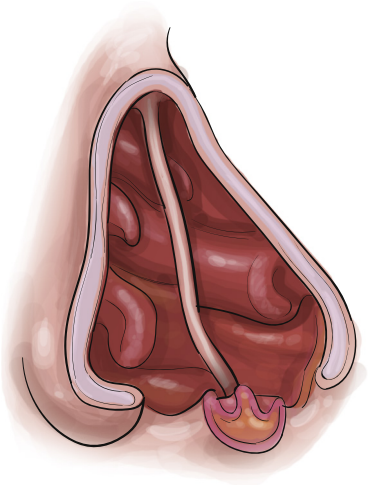

Fig. 101.9. Nasal cavity and defect after suturing skin edges; packing may not be necessary.

- Prophylactic intravenous or oral antibiotics in the perioperative period
  - First generation cephalosporines + metronidazole
  - Clindamycin + gentamycin (in patients allergic to penicillin)
- We prefer ampicillin sodium/sulbactam sodium.
- Assessment of hemoglobin and hematocrit levels
- Elevation of the head of the bed and ice application in order to minimize local edema
- Pain management: Opioid analgesics are used to control pain. Nonsteroidal anti-inflammatory drugs are avoided in the early postoperative period.
- Psychologic support for functional and cosmetic problems

Complications

- Hemorrhage
- Cerebrospinal fluid leak: This can occur with excessive manipulation or torque on the perpendicular plate of the ethmoid bone. It is important to recognize and reconstruct the defect promptly during the operation. Delayed diagnosis can lead to serious intracranial complications such as meningitis, encephalitis, or brain abscess.

Alternative Management Plan

- Radiation therapy
- Concurrent chemoradiotherapy
- Chemotherapy is usually considered in unresectable tumors or in palliative treatment.

DISCUSSION

Evidence-Based Medicine Question

When is rhinectomy necessary in the management of nasal tumors?

Rhinectomy is an effective treatment in extensive cancer of the nasal framework. However, it is generally performed after failed radiation therapy or prior inadequate surgery, since there are significant cosmetic consequences to this procedure. Because of the rarity of patients needing this type of procedure, there are only several small series in the literature, and to our knowledge there are no published randomized trials regarding

different treatment regimens. Stanley and Olsen reported a recurrence rate of 43% and a mortality rate of 25% in 51 rhinectomy cases. They also noted that 61% of these patients had previous unsuccessful surgical attempts.[7] Mignogna and Garay reported a cure rate of 36% at 5 years in recurrent invasive squamous cell carcinoma of the columella with partial or total rhinectomy.[8] Chipp et al. presented a 50% survival rate in 14 patients.[9] Teichgraeber and Goepfert proposed that extensive rhinectomy is indicated in recurrent multicentric cancers, involvement of the ala, and squamous cell carcinoma greater than 4 cm. They found a 30% rate of recurrence and two-thirds of recurrences occurring within 2 years. On the basis of their findings, they recommended prosthetic rehabilitation and a 2-year wait prior to proceeding with definitive reconstruction.[2]

Editorial Comment

The authors have produced a highly detailed, very readable chapter on rhinectomy. Total rhinectomy is reserved for patients presenting with advanced cancer involving the skin, soft tissue, and bone, which makes up the nasal framework. Since most cancers of the nose do not present in such an advanced state, partial rhinectomy offers an opportunity for complete excision of these cancers, most often squamous cell carcinoma, with reconstruction employing a wide variety of techniques including skin grafts, composit grafts, and bilobed, nasolabial, and forehead flaps. The key to success in curing these cancers lies in achieving clean surgical margins. For cancers involving skin, only excision with frozen section control using traditional surgical technique or Mohs cutaneous technique can provide this information so that immediate reconstruction can be carried out. However, when the cancer is very large or involves bone, it is best to delay reconstruction until clean margins can be ensured by a permanent pathologic report. If the margins are close or not clear, the patient must be returned to the operating room for further ablative surgery. Only when the margins are clear can reconstruction or the fabrication of a prosthesis proceed.

Patients who will undergo total rhinectomy should be seen preoperatively by a maxillofacial prosthodontist who will make a facial moulage from which a nasal prosthesis can be fabricated. Of course, the prosthesis may require modification based upon the facial configuration of the defect. No doubt in the future 3-D imaging will be used to create these prostheses.

A few words should be said about preparing the surgical defect for the prostheses. The standard technique described in the surgical literature is that once the specimen is removed and hemostasis is obtained the skin edges are sewn to the nasal mucosa. While this results in rapid epithelialization of the margin of the defect, it results in a very abnormal appearance of the mid face (Fig. 101.10).

My personal modification of the standard technique that avoids the distorted appearance includes the use of a split-thickness skin graft sutured laterally to the skin edge and medially to the nasal mucosa bilaterally. Silk sutures are used to stabilize the skin edges, and some are left long and are tied over a Xeroform bolster to immobilize the graft. The bolsters and the sutures are removed on the fifth postoperative day, and any excess skin graft is trimmed. Filling in the gap between the skin and the mucosa with a skin graft results in a re-epithelized wound without any distortion of the midface.

My experience with advanced cancer of the head and neck has led me to believe that individuals who let an obvious cancer destroy their nose, which is the keystone of the face, have some severe self-destructive instinct. It may be true that other factors may play a role such as fear, ignorance, and limited access to medical care, either geographic or financial, but regardless of the possibility of these factors being the entire cause, I strongly suggest that a psychiatrist or psychologist can play an important role in the management of these patients.

Eugene N. Myers



Fig. 101.10. Skin edges and mucosa sutured together results in distortion of the midface.

Access the review questions online at http://www.expertconsult.com



REFERENCES

1. Mydlarz WK, Weber RS, Kupferman ME. Cutaneous malignancy of the head and neck. Surg Oncol Clin N Am 2015;24:593–613.
2. Teichgraeber JF, Goepfert H. Rhinectomy: timing and reconstruction. Otolaryngol Head Neck Surg 1990;102:362–369.
3. Banuchi V, Mallen J, Kraus K. Cancers of the nose, sinus and skull base. Surg Oncol Clin N Am 2015;24:563–577.
4. Shockley WW. Special problems associated with carcinoma of the nose. Otolaryngol Clin North Am 1993;26(2):247–264.
5. Ethunandan M, Downie I, Flood T. Implant-retained nasal prosthesis for reconstruction of large rhinectomy defects: the Salisbury experience. Int J Oral Maxillofac Surg 2010;39(4):343–349.
6. Scott N, Kittur MA, Evans PL, et al. The use of zygomatic implants for the retention of nasal prosthesis following rhinectomy: the Morriston experience. Int J Oral Maxillofac Surg 2016;45(8):1044–1048.
7. Stanley RJ, Olsen KD. Rhinectomy for malignant disease. A 20-year experience. Arch Otolaryngol Head Neck Surg 1988;114:1307–1311.
8. Mignogna FV, Garay KF. Surgical rescue of recurrent carcinoma of the nasal columella. Am J Surg 1995;170:453–456.
9. Chipp E, Prinsloo D, Rayatt S. Rhinectomy for the management of nasal malignancies. J Laryngol Otol 2011;125:1033–1037.

REVIEW QUESTIONS

1. The anatomic part of the nose that should be preserved for prosthetic rehabilitation after total rhinectomy includes which of the following?
   a. Nasal spine
   b. Nasal bone
   c. Pyriform aperture
   d. Bony septum

2. The true starting point of the dissection in order to obtain adequate exposure of the septum and visualize extension of the tumor includes one of the following:
   a. Rhinion
   b. Midline of the nose
   c. Lateral edges of nares
   d. Columella

3. Among the typical signs and symptoms of squamous cell carcinomas of the nasal cavity, all of the following are *true,* except
   a. Regional lymphatic metastasis is common
   b. Epiphora
   c. Erythema of the skin
   d. Bleeding

102 Balloon Sinus Dilation

Nadim Bikhazi, Andrew N. Goldberg

INTRODUCTION

Sinus surgery continues to evolve, greatly enhanced by technological innovations. Thirty years ago, largely due to advances in endoscopic visualization, functional endoscopic sinus surgery (FESS) became less extirpative than traditional operative sinus surgery. Now another stage in this evolution is occurring toward minimally invasive sinus procedures such as office-based balloon sinuplasty. This technique, performed under local/topical anesthesia, affords several distinct benefits over sinus surgery under general anesthesia: less patient down-time, less bleeding, reduced need for postprocedure pain medication, and more rapid return to work. These advantages of balloon-sinuplasty, when coupled with equal efficacy for similar chronic sinusitis disease severity, provide a valuable alternative for patients and otolaryngologists.

KEY OPERATIVE LEARNING POINTS

1. Balloon sinus dilation (BSD) is an operative procedure performed for medically recalcitrant recurrent acute sinusitis and chronic rhinosinusitis.
2. It can be safely performed in both the outpatient and inpatient settings.
3. Principles of BSD rely on expansion of narrowed sinus tracts while preserving sinus mucosa.
4. Success of the procedure requires appropriate patient selection and the use of proper technique.
5. Rate of success and revision of BSD are comparable to those achieved for FESS for properly selected patients.

PREOPERATIVE PERIOD

History

1. History of present illness
   a. Has the patient experienced symptoms of chronic rhinosinusitis: nasal congestion, facial pressure, and/or nasal discharge?
   b. Are these symptoms chronic (>12 weeks) or recurrent with four or more episodes per year?
   c. Are there factors such as infections of high severity or duration, antibiotic intolerance, or associated medical conditions that warrant early intervention?
   d. What medical therapy has the patient tried? This may include nasal saline rinses, both oral and topical decongestants, antihistamines, nasal steroids, and antibiotics. Have these medical therapies been successful? Ask for the length of the symptom-free period.
   e. Has the patient undergone any prior imaging (computed tomography [CT] scan of the sinuses)?
   f. Has the patient undergone allergy testing?
   g. Does the patient have a dental (odontogenic) source of sinus pain?
2. Past medical history
   a. Are there associated medical conditions? Ask for history of allergies, gastroesophageal reflux, and headaches (particularly migraine).
   b. Surgical history. Have there been previous septal surgery and/or sinus surgical procedures?
   c. Family history
   d. Allergies to local anesthetics (lidocaine, bupivicane)
   e. Medications:
      1) Anticoagulants
      2) Antihypertensive

Physical Examination

1. Anterior rhinoscopy
   a. Are there enlarged inferior turbinates or anterior septal spurs that account for additional nasal obstruction? These may need to be addressed at the same time as the BSD and, if severe enough, may require that the procedure be done under general anesthesia.
2. Nasal endoscopy
   a. Are there other middle meatal anomalies that will make access to the meatus difficult? Examples include nasal polyps, concha bullosa, lateralized middle turbinate, and superior septal deviation.
   b. Is there polypoid tissue along the bulla ethmoidalis that will need to be addressed at the same time as the balloon dilation with a limited anterior ethmoidectomy? Limited nasal polyps may not preclude BSD, but more extensive polyposis may require consideration of larger sinus openings through FESS.

Imaging

1. CT of the sinuses without contrast
   a. Pay attention to narrowing of the ostiomeatal complexes and the nasofrontal recesses. Also note any large obstructive polyps that may make BSD inappropriate. Also, diffuse ethmoid disease (anterior and posterior) would preclude BSD and make FESS more appropriate. Hyperdense regions in the sinuses may indicate that fungal elements are present such as in a mycetoma or allergic fungal rhinosinusitis, making FESS more appropriate.

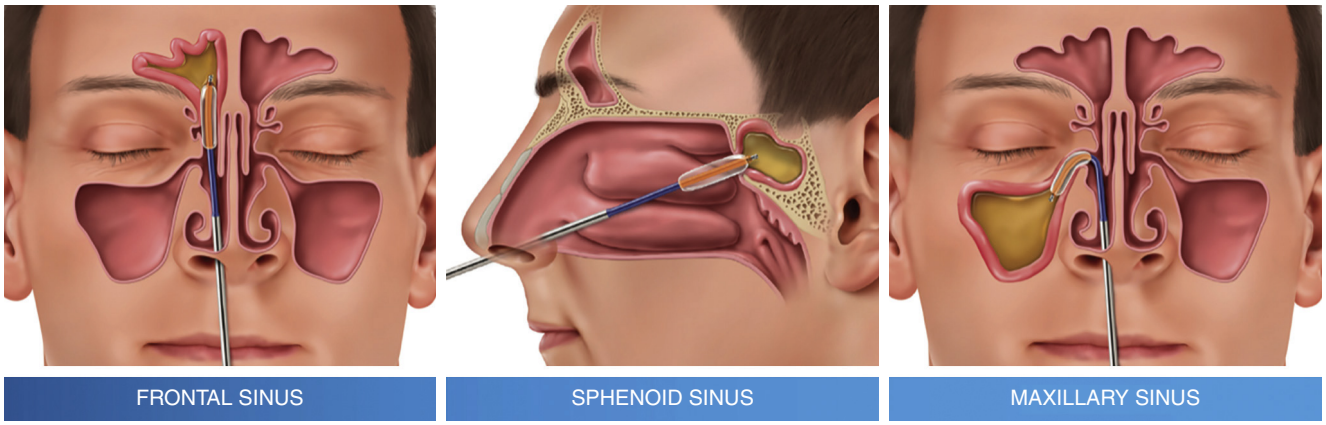

Fig. 102.1. Balloon sinus dilation of major sinuses.

Indications

1. Mild to moderate chronic rhinosinusitis of the maxillary, frontal, or sphenoid sinuses recalcitrant to medical therapy (Fig. 102.1)
2. Recurrent acute sinusitis of the maxillary, frontal, or sphenoid sinuses
3. Revision cases of scarring or stenosis of the maxillary, frontal, or sphenoid ostia
4. Can be used as a stand-alone technique or in conjunction with other sinus surgery (known as a hybrid technique)
5. Specific application to those with patients unfit for surgery: on anticoagulants, pregnant, age-related medical conditions (heart or lung problems)

Contraindications

1. Diffuse nasal polyposis or granulation tissue
2. Severe ethmoid disease (anterior and posterior)
3. Anatomic nasal obstruction that otherwise would require general anesthesia (large obstructive septal deviation)
4. Fungal sinusitis where removal of fungal debris is necessary
5. Concerns for sinus masses that need removal (large maxillary mucocoele)

Preoperative Preparation

1. Preoperative consent: Discuss risks of injury to the orbit, bleeding, cerebrospinal fluid (CSF) leak, scarring, and rates of revision.
2. For awake sedation
   a. Preoperative dosing of benzodiazepine (Valium 10 mg) and narcotic (hydrocodone 7.5 mg) 90 minutes prior to procedure
   b. Counseling that the patient may hear loud noises (cracking bones) during the procedure

OPERATIVE PERIOD

Anesthesia

1. General
   a. BSD under general anesthesia would follow the same preparation as for FESS. Local anesthetic and epinephrine would be used in similar doses.
2. Awake sedation
   a. Topical decongestion/anesthesia: Using either cotton balls or ½- × 3-inch cotton pledgets, 2% pontocaine/phenylephrine is used. These are placed on the anterior surface of the inferior turbinate, the anterior surface of the middle turbinate, and the superior septum opposing the middle turbinate. They are left in place for 10 minutes.
   b. After this is done, topical 1:1000 epinephrine solution is placed on pledgets into the same locations. Care should be taken to wring the pledget out to make it damp and not saturated. These are left in place for 5 minutes.
   c. Local anesthetic: 2% lidocaine without epinephrine can then be selectively injected into the root of the middle turbinate, the posterior attachment of the middle turbinate, the superior septum, and the uncinate process superiorly. This field localization blocks all the nerves to sensation of the maxillary, frontal, and anterior ethmoid sinuses. If the sphenoid dilation is being performed, an inferior injection along the inferior sphenoid face/posterior septum can block nerve sensation in this area.
3. Local: Some patients are relaxed enough that BSD can be performed with local anesthesia only.

Positioning

Supine: A low Fowler (semi-Fowler) position, which best approximates the position used in sinus surgery, provides the best position for BSD.

Perioperative Antibiotic Prophylaxis

No perioperative antibiotics are needed during BSD.

Monitoring

While monitoring is not required during BSD, having an oxygen tank and a pulse oximeter available is recommended. Some of the topical anesthetics, if used more than maximum dose (such as pontocaine), can cause seizures and airway distress. The surgeon should check for the maximum dose that can be used of each topical/injectable anesthetic.

Instruments and Equipment to Have Available

1. A basic endoscopic sinus surgery set with a Freer elevator, S-shaped double-ball probe, and Blakesley sinus forceps. A 30-degree nasal endoscope is used for maxillary and frontal sinus dilation, and a 0 degree is used for the sphenoid.
2. A television monitor

3. A BSD device. These come in various forms but should have the capacity to illuminate the sinus and pass a balloon over a probe/wire.
4. Additional equipment: A sinus microdébrider that can selectively remove solitary polyps and reduce enlarged inferior and middle turbinates.

Key Anatomic Landmarks

1. Root of the middle turbinate: The superior attachment of the middle turbinate bone
2. Bulla ethmoidalis: The anterior-most projection of the ethmoidal air cells, lateral to the middle turbinate
3. Maxillary ostium: The opening to the maxillary sinus, guarded laterally by the uncinate process
4. Uncinate process: The crescent-shaped lateral nasal wall projection that guards the opening of the maxillary sinus
5. Middle meatus: Curved anteroposterior passage lateral to the middle turbinate and medial to the uncinate process
6. Frontal recess: The spiral-shaped outflow tract of the frontal sinus
7. Ostiomeatal complex: A common channel that links the frontal sinus, anterior and middle ethmoid sinuses, and the maxillary sinus to the middle meatus that allows airflow and mucociliary drainage
8. Sphenoethmoidal recess: The space between the posterior nasal septum and the superior turbinate into which the natural ostium of the sphenoid sinus drains

Prerequisite skills

Thorough understanding of the surgical anatomy of the sinus

Operative Risks

The risks of BSD are the same as those of FESS, but they occur with reduced frequency. These include injury to the orbit with potential loss of vision, entering the CSF space with resultant CSF leak, bleeding, and scarring.

Surgical Technique

Often the balloon sinus probe is bent to perform the frontal sinus dilation, first followed by the sphenoid and then finally the maxillary sinus.

Maxillary Balloon Dilation

1. Medialization of the middle turbinate.
2. Probe the maxillary sinus outflow tract with an S-shaped double ball probe. This creates space between the uncinate process and the posterior ostial wall.
3. Insertion of the balloon dilator probe at a 120-degree angle with transillumination of the maxillary sinus.
4. Bend the probe to 120 degrees using the bending device.
5. Balloon dilation three times at 12 atmospheres of pressure for 5 seconds each. The three dilations should be pulling anteriorly, inferiorly, and posteriorly.
6. Confirm the expanded maxillary ostial patency with a 30-degree rigid endoscope.
7. Suction any blood or mucus if indicated.

Frontal Balloon Dilation

1. Medialization of the middle turbinate
2. Clear visualization of the bulla ethmoidalis. Always stay *anterior* to the bulla ethmoidalis to find the nasofrontal outflow tract. This avoids inadvertent penetration of the roof of the ethmoid or cribiform plate.
3. Starting lateral to the middle turbinate and posterior to the uncinate process, probe the various superior recesses superiorly and laterally. Start on the medial most recess and work laterally illuminating the tracts along the way.
4. The probe should advance to the 2-cm mark on the probe prior to dilation.
5. Transillumination of the frontal sinus with rotation of the light source to confirm presence *within* the sinus
6. Balloon dilation once at 12 atmospheres of pressure for 5 seconds. A second dilation can be performed more distally to confirm adequate patency of the nasofrontal duct.
7. Suction away blood or mucus from the frontal sinus recess.

Sphenoid Balloon Dilation

1. Using a 0-degree rigid endoscope, lateralize the middle turbinate.
2. Identify the superior turbinate superiorly in the sphenoethmoidal recess.
3. Identify the sphenoid ostium. This is found medial to the superior turbinate.
4. Place the balloon probe within the opening and dilate to 12 atmospheres of pressure for 5 seconds.
5. Confirm patency of the dilated ostium with the endoscope.
6. Suction any blood or mucus from the opening.

Common Errors in Technique

1. Inadequate vasoconstriction resulting in excessive bleeding and poor visualization
2. Inadequate local anesthesia resulting in patient discomfort and movement
3. In sphenoid sinus dilation, not lateralizing the middle turbinate enough to provide adequate visualization
4. Poor patient selection due to severe anatomic restriction (severe septal deviation)
5. Inadequate confirmation of ostial dilation

POSTOPERATIVE PERIOD

Postoperative Management

1. Advise patients to sneeze with the mouth open for 1 week and to avoid nose blowing for 1 week.
2. Postoperative examination at 1 week
3. Begin nasal saline irrigations at 1 week postoperatively.

Complications

1. Inability to cannulate the sinus
   a. BSD should not be forced, as this can lead to inadvertent entry into unwanted spaces (orbital injury, CSF leak).
   b. If difficulty is encountered, the cannulation of that sinus should be abandoned.
2. Hemorrhage
   a. If bleeding is encountered during the procedure, use topical 1:1000 epinephrine solution (damp) on a cotton pledget on the area.
   b. If there is continued oozing, a variety of dissolvable middle meatal packs can be used to tamponade the bleeding site.
   c. Postoperative bleeding can be managed with topical decongestant sprays (vasoconstrictors) as needed.

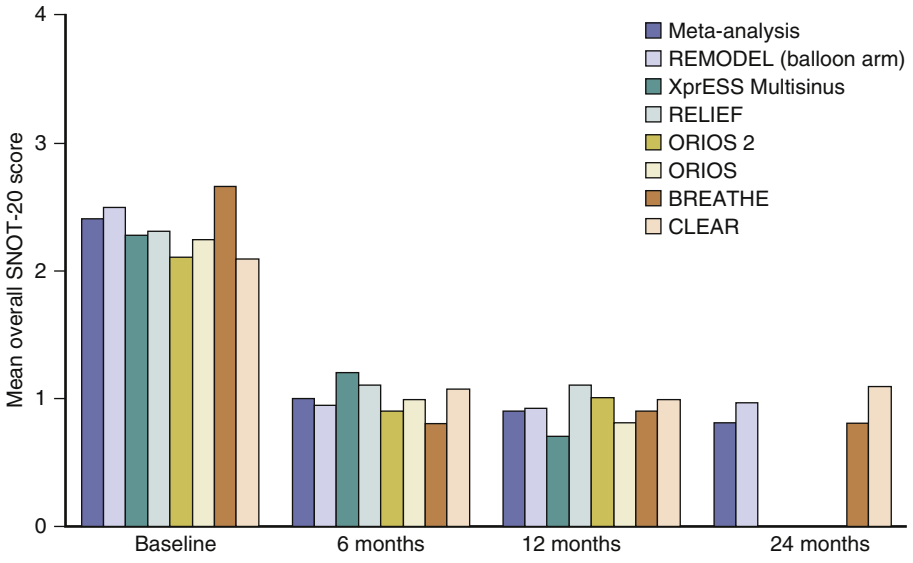

Fig. 102.2. Reduction in SNOT scores across multiple balloon sinus dilation studies.

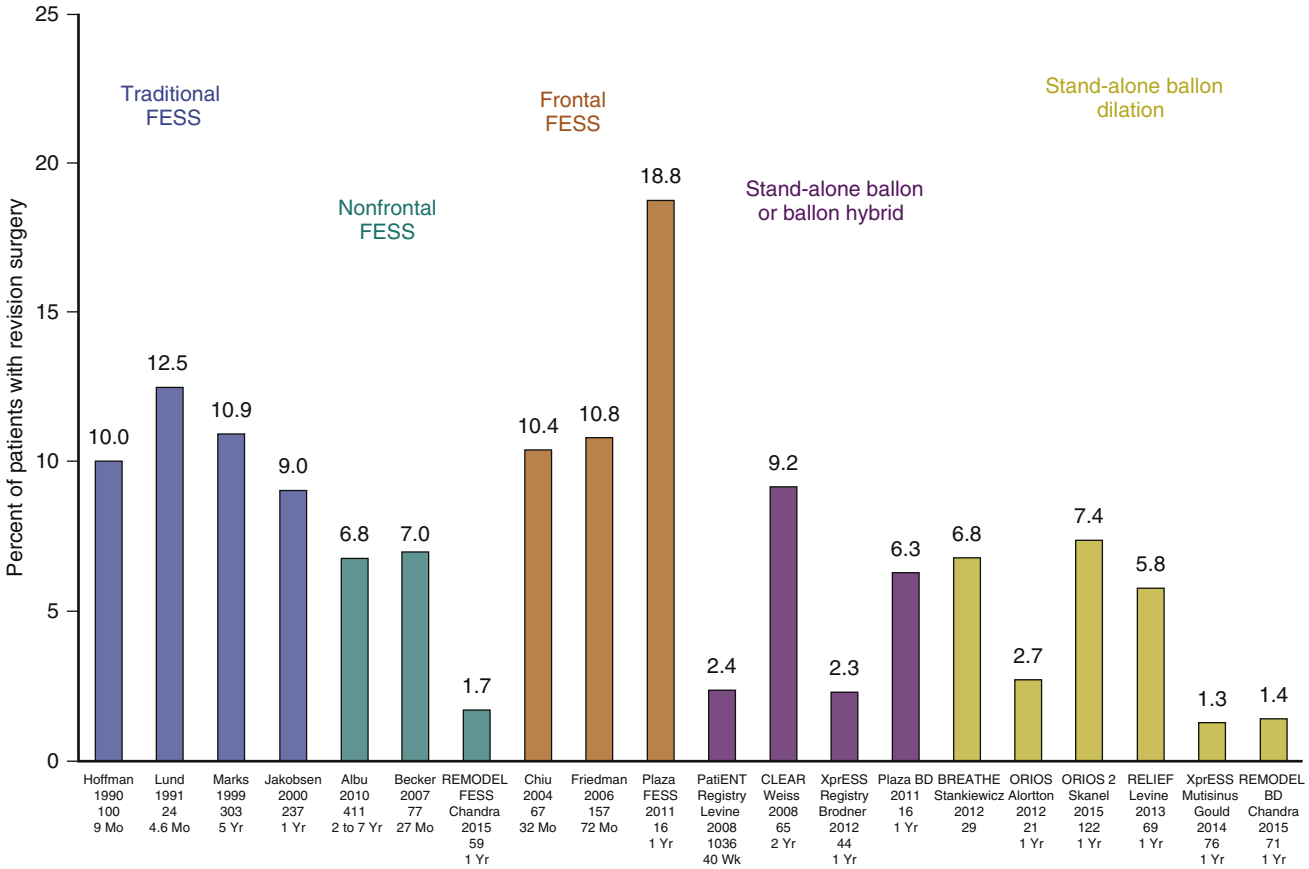

Fig. 102.3. Revision rates of functional endoscopic sinus surgery (FESS) versus balloon sinus dilation across multiple studies.

3. Congestion
   a. This can occur postoperatively resulting in facial pressure.
   b. First-line treatment would be oral decongestants.
   c. A short course of oral steroids (prednisone) can be given for 3 to 5 days.
4. Synechiae/stenosis of sinus openings
   a. These are less common with BSD than with FESS, due to reduced disruption of the mucosa.
   b. A true-cut forceps can be used to take these down, using a dissolvable middle meatal pack to separate opposing tissue.
   c. Repeat BSD may be necessary to enlarge a stenotic ostium.

Alternative Management Plans

1. Consider an endoscopic sinus surgery approach (FESS or hybrid).
   a. Significantly restricted anatomy (septal deviation, nasal polyps)

DISCUSSION

Evidence-Based Medicine Question

Is BSD as effective as FESS for appropriate selected patients?

The gold standard for the management of medically refractory chronic rhinosinusitis is FESS. Any technique that seeks to add to or replace FESS has to demonstrate equivalent efficacy and safety, and BSD fits these requirements in properly selected patients.

There are many prospective, randomized controlled trials (RCTs) indicating that BSD is equally efficacious as FESS for like-sinus sufferers.[1-7] Consistently, BSD studies in patients with chronic maxillary sinusitis/limited anterior ethmoid disease have equivalent reductions in sinonasal outcome test (SNOT)-20 scores beyond 1 year after the procedure (Fig. 102.2). Additionally, revision rates in BSD are comparable or better than those of FESS patients in a variety of studies (Fig. 102.3).

Success of BSD is not only limited to the maxillary sinuses but also holds true for chronic frontal sinusitis. In the double-blind randomized controlled Plaza study in 2011,[6] patients with frontal sinus polyposis underwent BSD as a hybrid procedure with anterior ethmoidectomy compared to a Draf I frontal sinus procedure. After greater than 1 year follow-up, BSD patients experienced equivalent reductions in Lund McKay CT scores and equivalent patency while having lower revision rates.

Limited anterior ethmoid disease does not seem to preclude success in balloon dilation of the maxillary sinuses. Many studies have revealed up to 40% of patients with limited anterior ethmoid disease clear these sinuses after BSD of the maxillary sinus.[7]

Finally, the improvement in sinusitis among BSD appears to be long lasting. In a meta-analysis of six studies including 358 patients followed for at least 24 months, the improvements in SNOT-20 scores persist.[8]

Editorial Comment

BSD is increasingly used in the management of recurrent acute and chronic rhinosinusitis. By standard quality of life measures, such as the SNOT-22, BSD is effective in the management of select patients with chronic rhinosinusitis. Additionally, this intervention is increasingly used in an office-based setting, avoiding general anesthesia. The goal of these procedures is principally ventilation of the sinus with minimal mucosal disruption. In contrast, FESS can provide both ventilation as well as access to topical medications. The specific goals of the surgical intervention should be determined preoperatively to establish whether BSD is an appropriate intervention. As such, the indications for BSD continue to evolve and be refined with increasing experience and time.

Eric W. Wang

Access the review questions and additional source list online at http://www.expertconsult.com



REFERENCES

1. Bikhazi N, Light J, Truitt T, et al. Standalone balloon dilation versus sinus surgery for chronic rhinosinusitis: a prospective, multicenter, randomized, controlled trial with a 1 year follow-up. Am J Rhinol Allergy 2014;28:323–329.
2. Hathorn I, Pace-Asciak P, Habib A, et al. Randomized controlled trial: hybrid technique using balloon dilation of the frontal sinus drainage pathway. Int Forum Allergy Rhinol 2015;5:167–173.
3. Bizaki A, Taulu R, Numminen J, et al. Quality of life after endoscopic sinus surgery or balloon sinuplasty: a randomized clinical study. Rhinology 2014;52:300–305.
4. Marzetti A, Tedaldi M, Passali F. The role of balloon sinuplasty in the treatment of sinus headache. Otolaryngol Pol 2014;68:15–19.
5. Achar P, Duvvi S, Kumar B. Endoscopic dilatation sinus surgery (FEDS) versus functional endoscopic sinus surgery (FESS) for treatment of chronic rhinosinusitis: a pilot study. Acta Otorhinolaryngol Ital 2012;32:314–319.
6. Plaza G, Eisenberg G, Montojo J, et al. Balloon dilation of the frontal recess: a randomized clinical trial. Ann Otol Rhinol Laryngol 2011;120:511–518.
7. Gould J, Alexander I, Tomkin E, et al. In-office, multisinus balloon dilation: 1-year outcomes from a prospective, multicenter, open label trial. Am J Rhinol Allergy 2014;28:156–163.
8. Chandra RK, Kern RC, Cutler JL, et al. REMODEL larger cohort with long-term outcomes and meta-analysis of standalone balloon dilation studies. Laryngoscope 2016;126:44–50. http://dx.doi.org/10.1002/lary.25507.

REVIEW QUESTIONS

1. Potential complications of BSD include:
   a. Bleeding
   b. Orbital injury
   c. CSF leak
   d. Stenosis of sinus openings
   e. All of the above

2. The most important anatomic relationship when performing frontal BSD is:
   a. To stay posterior to the posterior-most ethmoid cell
   b. To stay anterior to the bulla ethmoidalis
   c. To stay medial to the middle turbinate
   d. To stay anterior to the uncinate process
   e. To stay lateral to the inferior turbinate

3. Contraindications of BSD include all of the following, except
   a. Diffuse nasal polyposis
   b. Fungal sinus disease
   c. Severe septal deviation causing poor visualization
   d. Limited anterior ethmoid disease
   e. Need for excision of a sinus mass

4. Evidence-based medicine comparing BSD to FESS for properly selected patients with similar disease indicates:
   a. BSD is inferior to FESS in efficacy
   b. BSD results in higher revision rates than FESS
   c. BSD shows equivalent efficacy to FESS
   d. BSD results in higher complication rate than FESS
   e. BSD cannot be used in any cases with anterior ethmoid disease

5. Which of the following statements is *true* regarding BSD?
   a. Solitary polyps are a contraindication to BSD
   b. Transillumination is necessary to confirm safe entry prior to BSD
   c. A septal deviation prevents BSD
   d. Topical epinephrine 1:1000 should never be used in BSD
   e. Patients who have undergone BSD can blow their nose freely right after the procedure

ADDITIONAL SOURCE

Entellus Medical Balloon Sinus Dilation Clinical Dossier. Clinical evidence for balloon sinus dilation for the treatment of chronic rhinosinusitis. September 2015.

103 Antral Lavage; Endoscopic Middle Meatal Antrostomy/Antrochoanal Polyp

Nicholas R. Rowan, Nivedita Sahu, Barry Schaitkin

INTRODUCTION

Since the 1980s, the surgical approach to the maxillary sinuses has been revolutionized by the endoscopic endonasal approach. The goals of treatment of maxillary sinus disease are aeration and resumption of normal mucociliary flow. Additionally, there is an increasing number of surgeons who now operate with a goal of access for topical medications. Although often believed to be the one of the most straightforward steps of endoscopic sinus surgery, the surgical approach to the maxillary sinus is not without potential complications and controversy.

Many primary cases without nasal polyps can be managed with a minimally invasive approach that marsupializes the natural ostium into the nose using an uncinate window. For more complex cases or in the setting of more advanced disease, endoscopic middle meatal antrostomy can facilitate long-term management of patients with chronic maxillary sinusitis by allowing for easy in-office and home antral lavage. These antrostomies are also the treatment of choice for other middle meatal pathologies such as antrochoanal polyps and can serve as a corridor to the middle fossa in skull base surgery.

Antrochoanal polyps were first described by Killian in 1906.[1] The polyp originates within the maxillary sinus and eventually is extruded through the natural ostium into the nasal cavity, obstructs the choana, and is characterized by the symptoms of unilateral nasal obstruction, rhinorrhea, and postnasal drainage. It is more common in the pediatric age group and represents the most common nasal and sinus growth in children. In the general population it is said to account for 4% to 6% of all nasal polyps, and in one study of 24 patients the mean age was 23 years (range, 11 to 40).[1]

The etiology of antrochoanal polyps remains controversial, and both allergic and infectious causes have been suggested.[2] Although medical treatment such as antibiotics, decongestants, and steroids may provide temporary relief, the treatment of choice for antrochoanal polyps is complete surgical excision. We prefer an endoscopic approach to these lesions, but in cases of recurrence or in those where the stalk of the polyp is not clearly visualized, the endoscopic approach may be combined with a canine fossa puncture or inferior meatal antrostomy for placement of an endoscope or instruments or a mini-Caldwell Luc.

KEY OPERATIVE LEARNING POINTS

1. The natural ostium of the maxillary sinus is located in a parasagittal plane and is identifiable after an uncinectomy is performed.
2. In cases that require a maxillary antrostomy, the natural ostium of the maxillary sinus must be incorporated into the maxillary antrostomy to prevent recirculation.
3. The best results occur when operating with adequate vasoconstriction resulting in minimal bleeding, proper visualization, and minimal trauma to the mucosa.
4. Antrochoanal polyps are often found exiting an accessory os in the posterior fontanelle. Polyps exiting the natural os should raise suspicion for other pathologies including inverted papilloma.

PREOPERATIVE PERIOD

History

1. History of present illness:
   a. What are the patient's presenting complaints?
      1) The four cardinal symptoms of sinusitis are nasal obstruction, discolored nasal drainage, facial pain, or pressure and hyposmia.
      2) Duration of symptoms should also be elicited.
      3) Odontogenic infections that ascend into the maxillary sinus should also be considered and evaluated.
2. Past medical history:
   a. Prior treatment:
      1) Medical therapy: Has this patient previously been treated with oral antibiotics? Has he or she used intranasal or systemic corticosteroids? Have other nasal sprays or saline irrigations been tried?
      2) Surgical history: Prior sinonasal surgery, including septoplasty and prior sinus surgery
      3) Dental history: Prior infections, root canals, implants, or "sinus lifts"
   b. Trauma history: Prior nasal bone fracture or trauma to the orbital rim, floor, lamina papyracea, or nasal septum
   c. Medical illness:
      1) Systemic illnesses that may have sinonasal manifestations such as sarcoidosis, granulomatosis with polyangiitis (formerly Wegener granulomatosis), or vasculitis
   d. Family history of coagulopathy or anesthesia complications
   e. Medications:
      1) Antiplatelet medications or other blood thinners
      2) Herbal products or supplements (e.g., vitamin E, ginseng, gingko biloba, garlic)
   f. Social history:
      1) Tobacco and alcohol history
      2) Environmental exposures (e.g., woodworking and heavy metals)

Physical Examination

1. All patients evaluated by an otolaryngologist should undergo a comprehensive examination of the head and neck.
2. Nasal endoscopy
   a. The nose should be examined before and after being decongested with oxymetazoline and anesthetized with topical lidocaine to achieve an adequate examination while minimizing patient discomfort.
   b. What anatomic factors may be contributing to the patient's complaints or limit future surgical intervention?

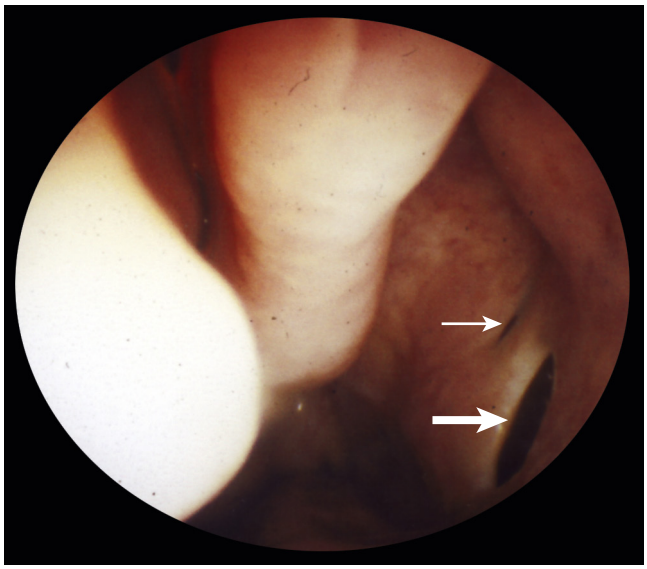

Fig. 103.1. Endoscopic view of accessory ostia *(arrows)* in the left posterior fontanelle.

1) Is the nasal septum deviated? Is there a concha bullosa? Is there an accessory os and if so, is there evidence of recirculation?
   a) The natural ostium is the only functional ostium within the sinus, and the inferior meatus will be ignored by mucociliary activity. Patients who have a patent inferior meatal antrostomy can easily be examined in the office through that opening with 0- and 30-degree endoscopes, and not infrequently, an obstructed natural ostium can be seen despite a surgically patent inferior meatal antrostomy (Fig. 103.1).

c. What is the health of the mucosal lining? Is there evidence of active infection?
   1) This can only be appreciated if the patient has previous surgery or an accessory ostium.
   2) Abnormal secretions can be sampled endoscopically for culture-directed therapy, and abnormalities that might impact surgical access to the ostiomeatal complex should be noted.

d. Detailed notes of the nasal endoscopy and, if possible, clinical photographs allow better preoperative surgical planning.

e. Are there signs of prior surgical intervention?

f. Diagnostic information about nasal tumors, as well as diseases of the mucous membranes such as Kartagener syndrome, cystic fibrosis, and granulomatosis with polyangiitis, can be gleaned from nasal endoscopy.

Imaging

1. When should imaging be completed?
   a. Patients whose symptoms persist despite adequate medical therapy should undergo imaging. Fine-cut coronal computed tomography (CT) without contrast enhancement is the most informative. High-quality coronal scans effectively delineate the area of the maxillary sinus ostium or ostiomeatal complex and provide verification of anatomic abnormalities that may be contributing to the sinus obstruction. When using the standard window approach described in the 1980s, no mucosa should be apparent, so any amount of mucosal thickening seen within the boundaries of the maxillary sinuses is considered abnormal.
2. Correlation of endoscopic findings with those on CT allows further evaluation of the anatomy and function of these highly variable and important structures.

Indications

1. Chronic rhinosinusitis refractory to medical management
2. Recurrent acute sinusitis refractory to medical management
3. Nasal polyposis
4. Antrochoanal polyp
5. Maxillary sinus mucocele
6. Fungus ball
7. Benign or malignant tumors involving the maxillary sinus
8. Endoscopic endonasal access to the pterygopalatine fossa or infratemporal fossa

Contraindications

1. Inadequate trial of medical management of rhinosinusitis
2. Odontogenic etiology that will predictably resolve (>60% of the time) once the dental issue has been addressed
3. Asymptomatic maxillary opacification or mucus retention cyst

Preoperative Preparation

1. Coronal CT scans are mandatory for preoperative planning in patients who are expected to undergo endoscopic surgery. The surgeon should review the CT scans with particular emphasis on the important structures that lie adjacent to the sinus cavities. For the maxillary sinus, this primarily entails a thorough evaluation of the lamina papyracea and the floor of the orbit to look for anatomic anomalies or any areas of dehiscence. Additionally, intramaxillary ethmoid cells (Haller cells) should be identified preoperatively. Radiographic evaluation of an antrochoanal polyp reveals unilateral opacification of the maxillary sinus and antrum along with rarely associated opacification of the ethmoid sinuses (Fig. 103.2).
2. Discontinue blood thinning and antiplatelet agents if possible
3. Controversy continues regarding the optimal extent of surgery that should be performed in patients with chronic sinusitis, and surgical treatment of the maxillary sinus is no exception. Some surgeons recommend wide antrostomy to improve sinus drainage and access for topical medications. Others maintain that the goal of maxillary sinus surgery should be removal of a minimal amount of tissue necessary to restore patency of the outflow tract.[3] Practitioners of both schools continue to espouse their own philosophies, and these approaches appear to achieve comparable results. We believe that the extent of surgery should be dictated by, and individualized, for each patient's pathology. This should be carefully planned preoperatively.

OPERATIVE PERIOD

Anesthesia

1. We prefer endotracheal intubation and general anesthesia for patient comfort and airway protection. This is mandatory in patients with reactive airway disease.
2. Total intravenous anesthesia (TIVA) and deliberate hypotension may improve visualization during surgery; however, this is a controversial topic.[4]

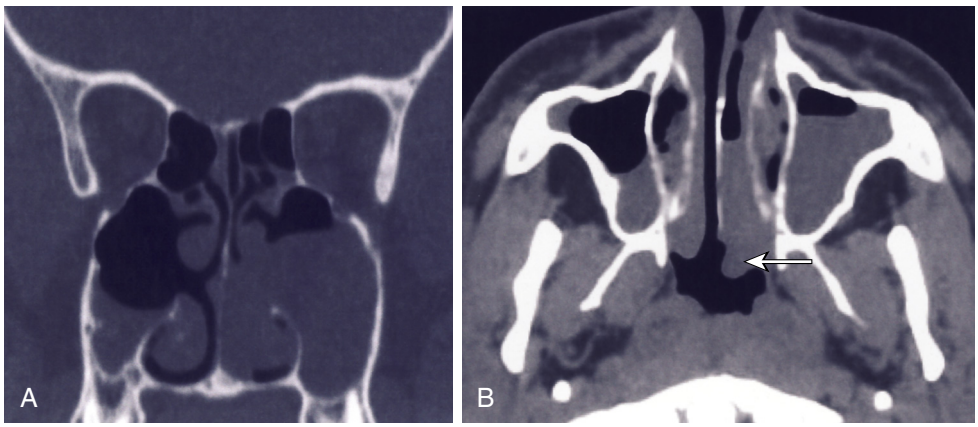

Fig. 103.2. CT scan demonstrating an antrochoanal polyp from a left radiopaque antrum into the nose on the coronal image, **A,** and extending into the nasopharynx on an axial image, **B** *(arrow)*.

Positioning

1. The patient is placed supine on the operating table with the head rotated slightly toward the surgeon. The head remains midline when using the four-handed technique. Some surgeons prefer the reverse Trendelenburg position or the head rotated slightly toward the surgeon.
2. Careful attention should be paid to the ergonomic positioning of surgical monitors and image guidance systems if used.
3. The endotracheal tube should be secured to the lower lip to prevent loss of the airway during surgery.

Preoperative Antibiotic Prophylaxis

1. The sinonasal tract is considered a contaminated site. We typically use a single perioperative dose of first-generation cephalosporin.
   a. Consider a broader-spectrum antibiotic if the patient is currently infected and obtain intraoperative cultures.
   b. Clindamycin is an acceptable alternative if the patient has an allergy to cephalosporin.
   c. Antibiotic treatment may also be guided by preoperative cultures.

Monitoring

1. None required
2. In cases where more extensive surgery is required, image guidance systems may be used.

Instruments and Equipment to Have Available

1. Basic endoscopic sinus surgery set
   a. 0-, 30-, and 45-degree endoscopes are usually adequate to visualize the natural ostium and most aspects of the maxillary sinus, but a 70-degree scope maybe useful for complete visualization in the case of antrochoanal polyps and other maxillary sinus–occupying lesions (Fig. 103.3).
   b. Bipolar and suction monopolar cautery should be available.

Key Anatomic Landmarks

1. The maxillary sinus is typically a single air cell bounded by the orbit superiorly, the zygomatic process laterally, the hard palate inferiorly, the fontanelles and uncinate medially, and thin layers of bone anteriorly and posteriorly that separate the sinus from the soft tissue of the cheek and the pterygopalatine fossa, respectively. Normal mucociliary function from birth results in continuous removal of mucus against gravity through the natural ostium of the maxillary sinus. This ostium is bounded by the uncinate process and the ethmoid bulla, forming the hiatus semilunaris and draining into the infundibulum.
2. Haller cells: In some cases (Fig. 103.4), additional cells on the floor of the orbit known as Haller cells can also contribute to obstruction.

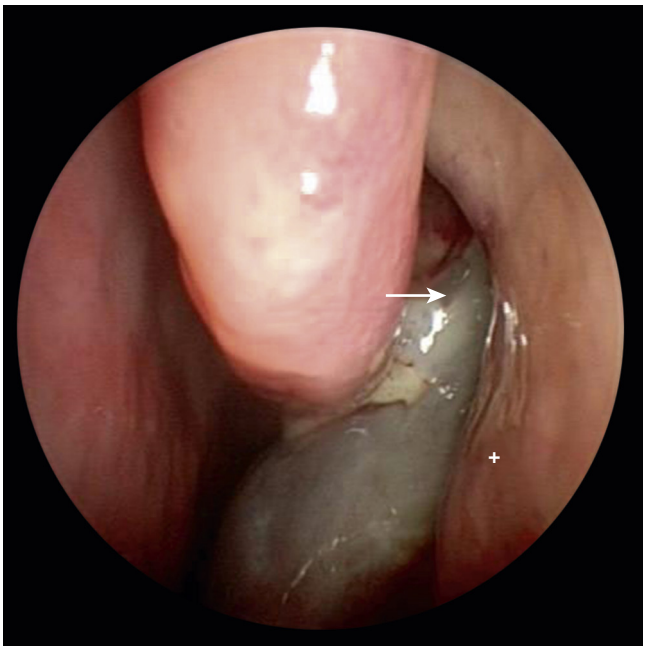

Fig. 103.3. Endoscopic view of the left nasal vault demonstrating an antrochoanal polyp *(arrow)* exiting into the nose via an accessory ostium behind an intact uncinated process *(cross)*.

Prerequisite Skills

1. Basic nasal endoscopy and use of the two-handed surgical technique

Operative Risks

1. Epistaxis
   a. Minor bleeding can result from trauma to the nasal septum. However, significant bleeding is rare and occurs when the turbinate has been partially or totally



Fig. 103.4. Haller cell *(asterisk)* on a coronal CT scan and natural ostium of the right maxillary sinus *(arrow)*.

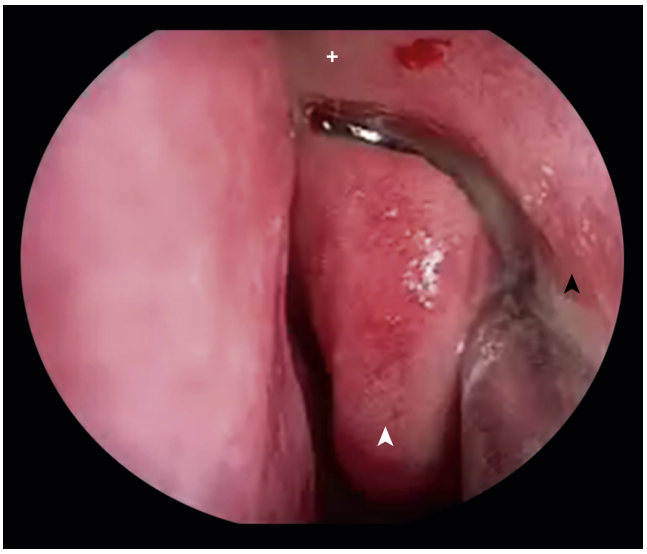

Fig. 103.5. Injection sites for maxillary sinus surgery ("+" represents superior attachment of middle turbinate, *black arrowhead* represents inferior aspect of uncinate process, and *white arrowhead* represents tail of middle turbinate).

resected or the sphenopalatine artery has been violated. See Chapter 98 for the sphenopalatine artery ligation technique.

2. Injury to the nasolacrimal duct
   a. Injury may occur when performing an uncinectomy and should be prevented by differentiating between the maxillary line and the uncinate process.
3. Orbital injury
   a. We found that the orbit is entered most commonly during uncinectomy, primarily as a result of the tip of the sickle knife being driven through the lamina papyracea.
4. Injury to the infraorbital nerve
   a. This injury is rare but can occur while working within the maxillary sinus space, especially when there has been prior maxillofacial trauma involving the orbit.

Surgical Technique

1. The procedure begins in the holding area with the application of topical decongestants 30 minutes before the procedure, and repeat topical therapy is given at 15 minutes and on call in the operating room.
   a. If the surgeon prefers to use 1:1000 epinephrine intraoperatively for topical vasoconstriction, this step should be avoided because these decongestants compete for the same adrenergic receptor, thereby making the 1:1000 solution less effective.
2. Surgical preference will dictate the manner in which the operating room and Mayo stand are organized. A two-handed or four-handed technique is acceptable. We use a four-handed technique, which is particularly helpful for teaching and in patients with acute inflammation and bleeding.
3. There are many ways to clean the lens of the endoscope and prevent fogging. In the two-surgeon technique, the assistant instills saline into the nose via a 60-mL syringe with a blunt 18-gauge needle or a curved suction. Some soft tissue shavers irrigate the lens by squirting water from the tip of the dissecting instrument. An endoscopic scrubber or sleeve can be placed as a sheath over the endoscope to irrigate the tip. Antifog agents are also available from multiple manufacturers. Such agents are helpful but should not be used if an irrigating sleeve is on the endoscope because the film prevents irrigation of the tip of the scope. A clean endoscope and a dry field will enable surgical precision and decrease frustration and complications.
4. To maintain a dry field, oxymetazoline or 1:1000 topical adrenaline is applied on ½- by 3-inch radiopaque neuro patties. Both are poured by the circulator into labeled basins. The adrenalin is dyed with a single drop of methylene blue to further decrease the risk of confusing it with local anesthetic and injecting it in the nose.
5. Many different systems of powered instrumentation, popularized by Reuben Setliff, are available. Optimal settings may vary, but in general, the device in oscillating mode is more effective at a slower speed, which allows a greater time for soft tissue to be entrained into the window of the device.
6. Local anesthesia is provided by injecting 1% lidocaine (Xylocaine) with 1:100,000 epinephrine as a vasoconstrictor before all procedures. The injection sites are the superior attachment of the middle turbinate, the inferior aspect of the uncinate process, and the tail of the middle turbinate (Fig. 103.5). The procedure is begun after 5 minutes has elapsed.
7. A right-handed surgeon stands on the right side of the patient. The scope is positioned in the superior aspect of the nasal vault so that placement of surgical instruments is inferior and unencumbered.
8. The middle turbinate is gently medialized with attention paid to transmission of force to the lateral lamella of the cribriform plate. With a bulky, paradoxically curved turbinate, and certainly for the concha bullosa, access may be achieved by lateral reduction of the middle turbinate with a soft tissue shaver. Most patients do not require more than just gentle retraction of the middle turbinate. The narrowest part of the ethmoid labyrinth is located between the anterior portion of the middle turbinate and the uncinate and lacrimal processes. Care should be taken in this area to avoid damage to the mucosa and subsequent formation of synechia.
9. We espouse a retrograde dissection of the uncinate with a pediatric back-biting forceps as the safest approach to the infundibulum (Fig. 103.6).
10. After confirming the location of the free edge of the uncinate process, retrograde dissection is performed approximately one-third of the way from the attachment of the uncinate process to the ethmoidal process of the inferior turbinate. A powered instrument is then used to remove

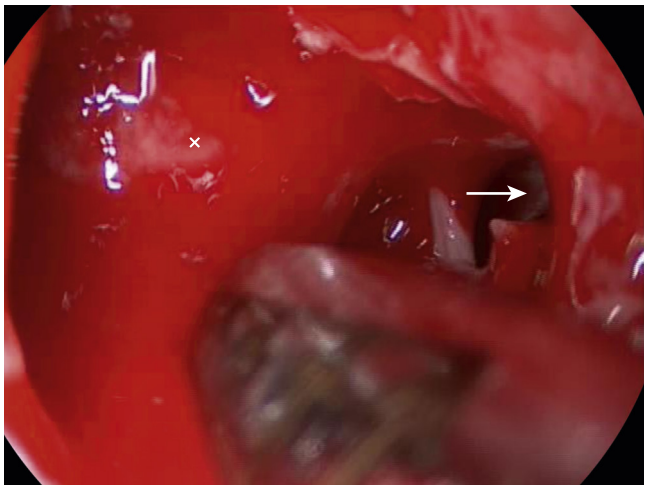

Fig. 103.6. Uncinate window created by retrograde dissection on the left side with pediatric back-biting forceps to reveal natural os *(arrow)*. The inferior portion consists of the remaining uncinate attached to the ethmoidal process of the inferior turbinate and the mucosa medially and laterally. (The x marks the middle turbinate.)

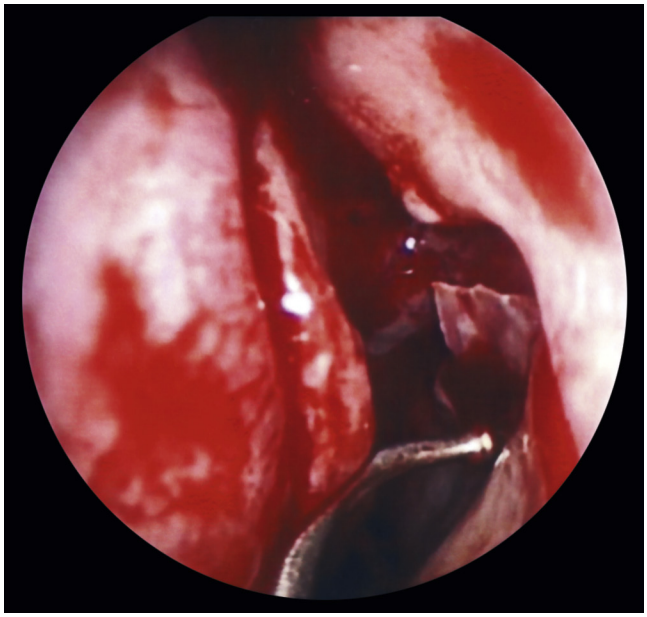

Fig. 103.7. Submucosal dissection of the uncinate process on the left side with a double-ball probe seeker.

the uncinate process superior to the surgically created uncinated window up to the level of the agger nasi, or as dictated by the remainder of the procedure. The portion inferior to the uncinate window then consists of the nasal mucosa, the residual bone of the uncinate process, which inserts into the inferior turbinate, and the mucosa on the sinus side. The mucosa on the nasal side is gently removed with the microdébrider to expose the uncinate bone, which is dissected and elevated submucosally with a double-ball probe seeker (Fig. 103.7). This instrument is used to deliver the uncinate out of the mucosal pocket while leaving the maxillary ostium intact (Fig. 103.8). This allows the microdébrider to bring the mucosal flap to meet the nasal side. Removing the uncinate process in this submucosal fashion permits the natural ostium of the maxillary sinus to be enlarged without damage to the entire mucosal

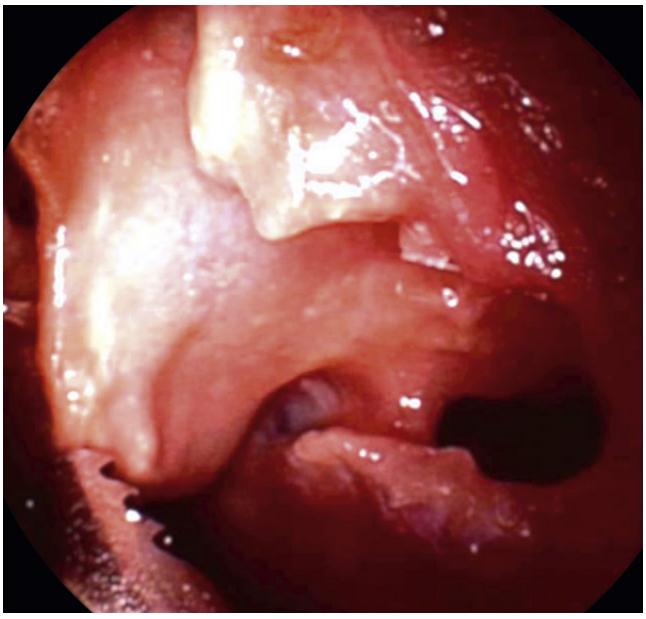

Fig. 103.8. Mucosal preservation of 360 degrees of the left natural ostium.

circumference of the ostium. The parasagittal orientation of the sinus opening is also maintained. Care is taken not to damage any of this mucosa, which could result in at least obstruction and edema with resultant infection and, at worst, stenosis of the maxillary ostium.

11. If antral lavage is required, it is performed by passing a small pediatric suction through the natural ostium in an atraumatic fashion for use as irrigation. Irrigation can also be performed through an accessory ostium if present or via an inferior meatal puncture. This technique is used for standard cases of recurrent acute sinusitis and chronic maxillary sinusitis (Video 103.1).
12. In cases in which a maxillary antrostomy is prudent, the verified natural ostium can be enlarged posteriorly into the posterior fontanelle while preserving the maxillary sinus mucosa 270 degrees anteriorly around the ostium. A ball probe seeker or curved suction can be used to accomplish this. Once the decision has been made to create an antrostomy, it should be a large one. A tear-shaped antrostomy may be ideal for the restoration of normal mucociliary clearance. Secretions can be managed by suctioning and lavage. Polypoid mucosa is not removed but can be reduced to allow for removal of trapped secretions. Care should be taken when dissecting posteriorly as injury to branches of the sphenopalatine artery or the descending palatine nerve can occur.
13. Depending on the pathology of the maxillary sinus, the degree of required access may differ. Studies have demonstrated that small-hole techniques severely limit the accessibility to the sinus. Similarly in our own study, we found that instruments with increasing curvatures allowed for greater access to the sinus, but no single instrument could reach the entire maxillary sinus wall through an endoscopic antrostomy.[5]

Surgical Technique: Antrochoanal Polyps

1. Antrochoanal polyps must be completely excised to avoid recurrence. Endoscopically, this can sometimes be performed exclusively endonasally; however, even with 30- and 70-degree telescopes, it is often necessary to also approach the maxillary sinus component via an extended or external approach.

2. The nasal component can easily be removed endoscopically. A maximal maxillary antrostomy allows full view of the sinus component and usually the stalk, which has a variable location within the sinus but is most often found attached to the lateral wall of the sinus. The polyp often has a "neck," which can be grasped with a 90-degree ethmoid forceps to remove the bulk of the antrochoanal polyp. A standard curved 4-mm soft tissue shaver is used to eliminate the remainder of the polyp.
3. If the stalk is not readily accessible through the transnasal route, a canine fossa puncture is performed. A standard 4-mm soft tissue shaver can thus be placed with visualization of the sinus with an angled transnasal endoscope, or a 30-degree telescope can be introduced through the puncture and a curved instrument placed transnasally with a minimally invasive technique.
4. In some cases a double-barrel canine fossa puncture is performed to allow both the shaver and scope to be introduced, the scope through the trocar sleeve and the shaver directly through the front face of the maxilla. For the shaver, a standard canine fossa puncture is performed above the gingivobuccal sulcus superior to the canine tooth in the palpated fossa. An extended finger on the cheek prevents perforation of the posterior wall of the maxillary sinus after breeching the anterior wall. The nondominant hand may be kept on the orbital rim to prevent the trocar complex from sliding too superiorly on the front face of a dense maxilla and damaging the orbit.
   a. Once the trocar and sleeve are within the sinus, the trocar can be removed and a telescope placed for full exposure. Best results with the shaver occur with removal of both the sleeve and trocar and placement of the device through the created surgical tract. A 30-degree scope is ideal for complete inspection of the maxillary sinus via the canine fossa. No packing or dressings are needed, and additional surgery on the ethmoid sinus is almost never required.
5. Though increasingly less common, external approaches using a Caldwell Luc operation may also be employed for antrochoanal polyp (see Chapter 104).

Common Errors in Technique

1. Mucus membrane stripping
   a. The hallmark of all endoscopic techniques is preservation of the mucosa. The excellent studies of Moriyama and colleagues from the 1990s demonstrated that once this lining is removed, the subsequent reparative lining is never organized in a ciliated pattern that can return to normal. Furthermore, stripping of the mucosal lining creates a favorable environment for osteitis and postoperative scarring. Thus, all current endoscopic sinus procedures are predicated on an improved ability to preserve the mucous membrane.
2. Failure to incorporate the natural ostium
   a. Patients may have multiple openings in their posterior fontanelle (accessory ostia). These openings will lie in the sagittal plane and appear as though the fontanelle had a punched-out area in its membrane (see Fig. 103.1). They will be round and lack the anterior elliptical extension that only the natural ostium provides. Patients are frequently symptomatic when there is circular movement of secretions between the natural ostium and an accessory ostia, known as recirculation. Such patients will complain of thick postnasal discharge, as well as symptoms of recurrent infection. Examination in the office with a 30-degree nasal endoscope pointed laterally will often demonstrate these secretions, which frequently contain bubbles moving between the two ostia. CT will demonstrate these bubbles on the floor of the maxillary sinus. When faced with an additional opening, obvious recirculation seen endoscopically, and bubbles on CT scan, the decision is usually made preoperatively to enlarge the natural ostium into these accessory ostia.

POSTOPERATIVE PERIOD

1. Postoperative management
   a. Postoperative pain should be minimal and is typically managed with Tylenol or low-dose narcotics.
   b. Large-volume saline irrigations are started on postoperative day 0.
   c. Nasal steroid sprays and other intranasal medications are typically started 1 week after surgery or after the completion of systemic steroids if used.
   d. There is currently no strong evidence to support the routine use of postoperative antibiotics. Certainly, if infection is encountered, a culture should be taken, and the patient should be placed on empiric antibiotic therapy.
   e. Generally, the patient is cautioned against nose blowing and weight lifting is limited to less than 10 pounds postoperatively.
2. For the endoscopic approach, nasal saline irrigation usually serves as adequate postoperative care. Wide postoperative evaluation of the surgical site is afforded by the maxillary antrostomy. Thirty-degree telescopes and even flexible laryngoscopes allow wide surveillance. In cases of recurrence, performing a maximal maxillary antrostomy aids in irrigation, medication delivery, and postoperative surveillance.
3. Complications
   a. Failure to resolve facial pain. In many patients, the lack of a clear diagnosis and indication for surgery can result in unwarranted and unsuccessful surgery. It is difficult to know how to manage patients who have major symptoms and no objective endoscopic or CT evidence of sinus disease. This group creates a great deal of confusion diagnostically, and ideally they should undergo multiple nasal endoscopic examinations in an attempt to ascertain what is occurring in the nose when they are sick. The patients should be re-evaluated during exacerbation of symptoms so that a correct diagnosis can be made. Patients with facial pain in the absence of other symptoms are rarely offered surgery unless every other avenue has been undertaken and the patient understands that no guarantee can be made.
   b. Persistent disease. This can be continued infection, recurrence of polyposis, retained secretions, and a residual fungus ball or antrochoanal polyp.
   c. Formation of synechia remains the main pitfall, and the use of powered instrumentation has minimized mucosal trauma and thus has avoided the vast majority of these problems. Powered instruments allow preservation of most or the entire mucosal ring of the natural ostium. If the mucosal preservation technique is used without a formal antrostomy, the middle turbinate will not obstruct the sinus even if it does lateralize (see Fig. 103.8). The sinus does not become obstructed because the natural os that remains in the anatomic parasagittal plane and its outflow tract are inaccessible to obstruction by the lateralized middle turbinate. This is not the case if a formal antrostomy is performed that converts the antrostomy into a true sagittal plane and lateralization of the turbinate can cause obstruction (Fig. 103.9). A lateralized middle turbinate may result in unilateral sinus obstruction (Fig. 103.10). Complications are minimal when an antrostomy is not performed.

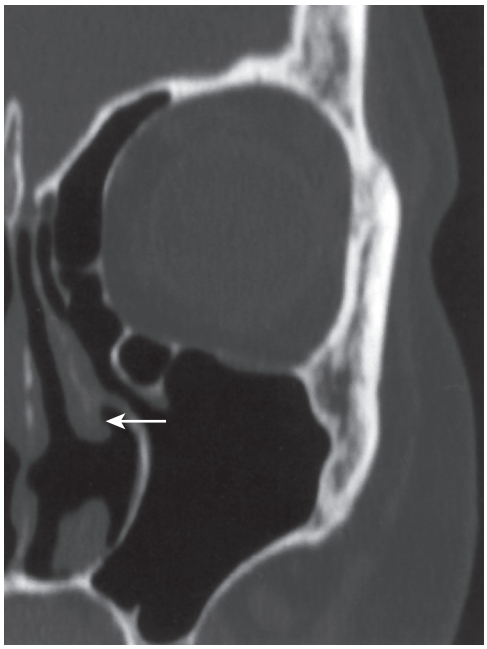

Fig. 103.9. The lateralized middle turbinate *(arrow)* on the left side cannot obstruct the maxillary sinus because the undisturbed maxillary ostium is left in the parasagittal plane.

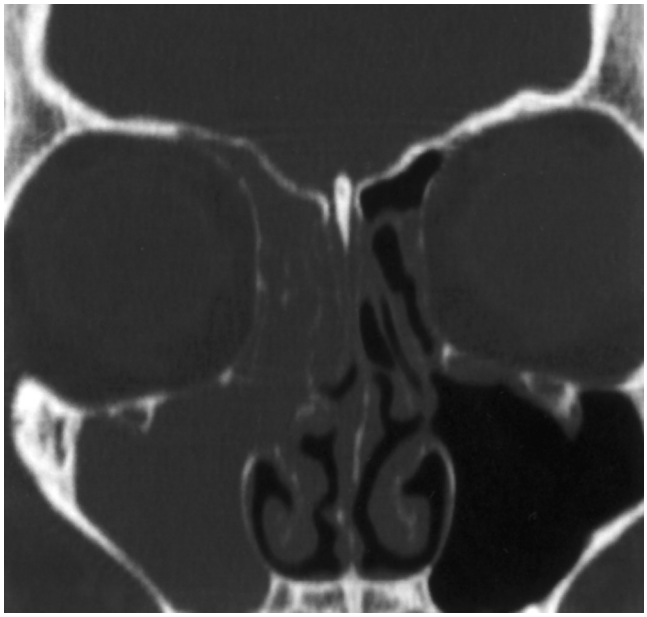

Fig. 103.10. Computed tomography shows a scarred lateralized middle turbinate causing right maxillary obstruction after antrostomy.

d. Stenosis of the ostium can occur if the surrounding mucosa is not preserved, subsequently leading to scar formation and an obstructed sinus.
e. Both injury to the lacrimal system and entry into the orbit are most commonly encountered during an uncinectomy and can be avoided with meticulous dissection in a dry operative field.
f. Recirculation of mucus as a result of failure to incorporate the natural ostium into a surgically created antrostomy
g. Bleeding is not usually a major problem with maxillary sinus surgery unless one violates the posterior limit of dissection with subsequent injury to the sphenopalatine artery or from some element of interior turbinate resection. Typical postoperative bleeding resolves with topical decongestants (e.g., oxymetazoline) or local pressure.
h. The pitfall in surgery for an antrochoanal polyp is recurrence, which has been noted after limited surgical procedures such as polypectomy. Complete removal, most commonly via an endoscopic (or rarely through a Caldwell-Luc) approach, has been shown to minimize the likelihood of recurrence of the polyp in adults and children. The advantage of these techniques is that the polyp and involved antral mucosa are removed as a unit under direct visualization, thereby reducing the possibility of recurrence.

4. Alternative management plan
   a. Continued medical management
   b. Intranasal corticosteroids and other topical medications for chronic rhinosinusitis
   c. Given that this is a symptom-driven procedure and that there is no risk of malignant transformation, all surgical interventions should be as minimal as possible.

DISCUSSION

Evidence-Based Medicine Question

What is the role of antibiotic usage following routine maxillary antrostomy?

The evidence for the use of routine postoperative antibiotics is poor. Several studies have shown no difference between control groups and those who were given amoxicillin or amoxicillin with clavulanic acid postoperatively. We advocate the use of nasal saline sprays and/or irrigations to clear clots and remove crusting.

Editorial Comment

Uncinectomy and middle meatal antrostomies are the standard surgical therapy used for patients with chronic rhinosinusitis unresponsive to medical management. Because it is increasingly understood that this represents an inflammatory rather than infectious disease, access for topical medications and ventilation have become the dual goal of this intervention in the management of chronic rhinosinusitis. The exception to this paradigm is odontogenic sinusitis, an increasingly recognized cause in maxillary sinusitis. Although disease limited to the maxillary sinus can often resolve with treatment of the primary dental pathology, a wide middle meatal antrostomy is an effective option in more extensive or recalcitrant disease to alleviate the symptoms and aid in the treatment of these infections. In contrast, middle meatal antrostomies are generally ineffective in the presence of ciliary dysfunction such as cystic fibrosis. Because a middle meatal maxillary antrostomy is dependent upon mucociliary clearance, it is generally ineffective in these conditions with persistent pooling of thickened secretions in the inferior aspects of the maxillary sinus.

Eric W. Wang

Access the review questions and additional sources list online at http://www.expertconsult.com

REFERENCES

1. Kamath MP, Hegde MC, Sreedharan S, et al. Antrochoanal polyps and allergy—a comparative study. Indian J Otolaryngol Head Neck Surg 2002;54:7–12.
2. Magit AE. Tumors of the nose, paranasal sinuses and nasopharynx. In: Bluestone CD, Stool SE, editors. Pediatric Otolaryngology. 4th ed. Philadelphia, PA: WB Saunders; 2003. p. 1054–1055.

3. Albu S, Tomescu E. Small and large middle meatus antrostomies in the treatment of chronic maxillary sinusitis. Otolaryngol Head Neck Surg 2004;131:542–545.
4. Boonmak S, Boonmak P, Laopaiboon M. Deliberate hypotension with propofol under anaesthesia for functional endoscopic sinus surgery (FESS). Cochrance Database Syst Rev 2013;(6). CD006623.
5. Beswick DM, Rodriguez KD, Olds CE, et al. Quantification of maxillary sinus accessibility via a middle meatal antrostomy. Am J Rhinol Allergy 2015;29:394–396.

REVIEW QUESTIONS

1. To prevent recirculation problems, which of the following must be accomplished during a maxillary antrostomy?
   a. Complete uncinectomy
   b. Identifying the natural ostium
   c. Entering the maxillary sinus through the posterior fontanelle
   d. Irrigating the maxillary sinus

2. A polyp stemming from an accessory os is most likely to be which of the following?
   a. Antrochoanal polyp
   b. Inverted papilloma
   c. Allergic fungal sinusitis
   d. Polyp associated with cystic fibrosis

3. Unilateral maxillary sinusitis is most likely due to which of the following causes?
   a. Immunodeficiency
   b. Allergy
   c. Exposure to sick people
   d. Dental disease

ADDITIONAL SOURCES

Kennedy DW, Adappa ND. Endoscopic maxillary antrostomy: not just a simple procedure. Laryngoscope 2011;121:2142–2145.

Kennedy DW, Zinreich SJ, Shaalan H, et al. Endoscopic middle meatal antrostomy: theory, technique, and patency. Laryngoscope 1987; 97(8 Pt 3 Suppl 43):1–9.

Moriyama H, Yanagi K, Ohtori N, et al. Healing process of sinus mucosa after endoscopic sinus surgery. Am J Rhinol Allergy 1996; 10(2):61–66.

Schaitkin BM, Mester SJ, May M. Orbital penetration and endoscopic sinus surgery. Am J Rhinol 1993;7:49–52.

104 Anterior Antrostomy: The Caldwell-Luc Operation

Andrew C. Urquhart

INTRODUCTION

The Caldwell-Luc procedure was named after two surgeons, Caldwell and Luc. They both described a similar procedure, with Caldwell advocating an inferior meatal antrostomy and Luc advocating enlargement of the natural ostium in the middle meatus. Caldwell practiced in New York and published a report on anterior antrostomy in the *New York Medical Journal* in 1896. Luc was French, practiced in Paris, and independently reported his procedure in 1897.[1]

The Caldwell-Luc approach has been used extensively in the past with excellent exposure and classic anatomic landmarks. It was the standard surgical technique for chronic maxillary sinus disease and used gravitational drainage through the inferior meatus (Fig. 104.1). With the development of endoscopic sinus surgery for the treatment of chronic sinusitis as well as facilitating an approach for other conditions, including skull base surgery, most younger surgeons will have had a very limited exposure to this procedure.

Open approaches were also used in a number of situations, apart from chronic sinusitis, including a corridor for the transantral ligation of vessels in the pterygopalatine fossa for epistaxis; in Vidian neurectomy, for the repair of fracture of the floor of the orbit, the repair of oroantral fistulas, and the removal of antrochoanal polyps; and as part of the surgical approach in a maxillectomy. While needed less frequently today, it is certainly important to understand and be able to perform the procedure in cases that are not suitable for an endoscopic approach.

KEY OPERATIVE LEARNING POINTS

1. The maxillary sinus is entered anteriorly through the thin bone of the canine fossa, which lies lateral to the canine tooth root.
2. The contents of the maxillary sinus can be viewed directly and removed with enlargement of the antrostomy.
3. The inferior meatal antrostomy (if required) is made below the inferior turbinate 1 to 2 cm behind the anterior tip of the inferior turbinate.

PREOPERATIVE PERIOD

History

1. History of present illness
   a. Dependent on indications for surgery
   b. Chronic sinusitis with previous surgeries
   c. Immunosuppressed patient with invasive sinusitis, overall medical condition, and underlying coagulopathies
2. Past medical treatment
   a. Prior treatment and surgical approaches
   b. Medical illness: specifically a history of bleeding disorders and hypertension. Depending on indications for surgery, the patient may be neutropenic and coagulopathic if surgery is being performed for invasive fungal infection.
3. Surgery
   a. Specific details regarding previous sinus surgeries or dental surgery (i.e., odontogenic cysts, maxillary tooth extractions)
4. Family history
5. Medications
   a. Antiplatelet drugs
   b. Anticoagulation drugs
   c. Herbal products
   d. Alcohol

Physical Examination

1. Age and general appearance of patient
2. Oral cavity

Note whether edentulous or not; the condition of teeth, especially the upper incisors; the site and location of an oroantral fistula, if present. Examine the upper gingivobuccal sulcus.

3. Nasal

Examine the nasal cavity and perform an endoscopy; check the septum alignment; note the anatomic findings, if previous surgery; check the inferior turbinate location and the relationship to the lateral wall.

4. Orbit

Document the vision and extraocular movement. If surgery is indicated for a fracture of the orbital floor, document the findings and any muscle entrapment.

5. Trigeminal nerve

Examine and document the sensation of V2, particularly with regard to the infraorbital nerve.

Imaging

Computed tomography (CT) with contrast (maxillofacial). Images in both the coronal and axial planes define the size and extent of the sinus as well as its relationship to the surrounding structures.

Indications

1. Inflammatory disease: chronic maxillary sinusitis, fungal sinusitis, and antrochoanal polyp (Figs. 104.2 and 104.3)
2. Neoplastic disease: biopsy of maxillary sinus tumors, removal of dental tumors, and staging of maxillary carcinoma
3. Access to pterygopalatine fossa
4. Initial step in medial maxillectomy
5. Access to orbital floor for orbital decompression and repair orbital floor fractures
6. Closure of oroantral fistula

Contraindications

1. Medical complications including uncontrolled hypertension and coagulopathy
2. Pediatric patients without secondary dentition
3. Initial approach to sinus disease (Functional endoscopic sinus surgery [FESS] should be the initial surgical treatment.)
4. Aplastic and hypoplastic maxillary sinus

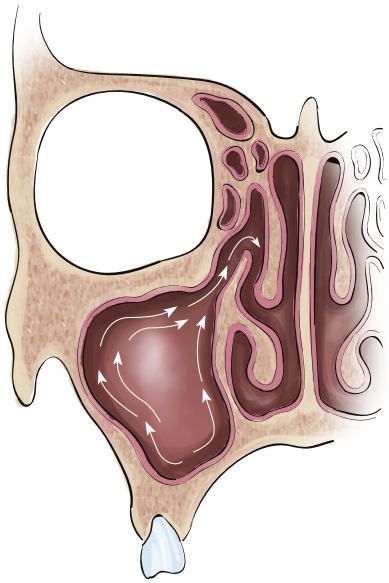

Fig. 104.1. Mucociliary flow through the natural ostium. The Caldwell-Luc procedure uses an antrostomy through the inferior meatus, which is essentially drained by gravity.

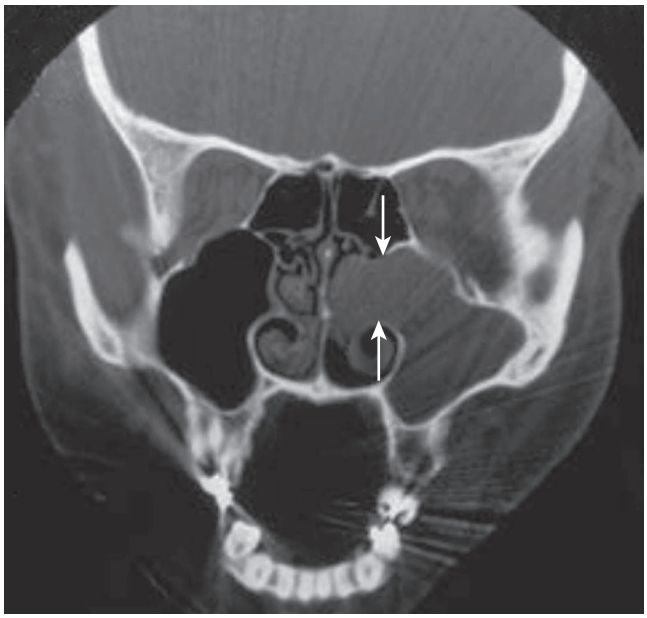

Fig. 104.2. Coronal computed tomography scan in a patient with an antrochoanal polyp. Note the expansion of the natural ostium *(arrows)* by the polyp.

Preoperative Preparation

1. Preoperative medical clearance with optimum stability for elective procedure
2. Discontinue antiplatelets and anticoagulants.
3. If patient has invasive fungal disease and is immunosuppressed with coagulopathy, a transfusion as needed. Risks of surgery versus disease progression need to be weighed.

OPERATIVE PERIOD

Anesthesia

General anesthesia is preferable for patient comfort and protection of the airway; however, the procedure can be done with local anesthesia and sedation. A nasotracheal or transoral endotracheal tube may be placed in the side opposite the operative site and secured to the surrounding soft tissue with adhesive tape.



Fig. 104.3. Coronal computed tomography scan in a patient with chronic sinusitis and calcified foreign body ("sinolith").

Positioning

- Supine: The patient is positioned in a neutral position with the head in the midline position or turned slightly toward the surgeon.

Perioperative Antibiotic Prophylaxis

While perioperative antibiotics can be given, there is no evidence that there is any benefit or decrease in postoperative infections.

Monitoring

The usual procedure for general anesthesia

Instruments and Equipment to Have Available

1. Headlight (surgeon)
2. Periosteal or elevator
3. Osteotome/mallet
4. Kerrison forceps
5. Blakesley forceps
6. Bone-cutting forceps

Key Anatomic Landmarks

1. Gingivobuccal sulcus: located at the upper reflection of the buccal and gingival mucosa, just lateral to the midline labial frenulum
2. Canine tooth roots: prominent bony protuberance covering the root of the canine tooth, next to the lateral incisor
3. Canine fossa: slight indentation just lateral to the canine tooth root, over the anterior face of the maxilla. The bone is thin and sometimes translucent in this area.

4. Infraorbital nerve: lies at the superior aspect of the surgical field, where it lies in the midline, just below the infraorbital rim
5. Inferior meatus: intranasal, lying below the inferior turbinate, with entry needed 1 to 2 cm behind the anterior end of the turbinate
6. The floor of the sinus is made up of the palatine and alveolar process of the maxilla; in adults, it extends approximately 4 to 5 mm inferior to the floor of the nasal cavity.[2]

Prerequisite Skills

1. Endoscopic sinus surgery (see Chapter 10)

Operative Risks

1. Injury to tooth roots
2. Injury to orbital floor with potential injury to the eye and blindness
3. Infraorbital nerve injury with numbness of the face, nasal ala, and upper lip
4. Injury to the nasolacrimal duct
5. Injury to the superior alveolar nerve with numbness of the maxillary teeth
6. Oroantral fistula
7. Ill-fitting dentures postoperatively
8. Persistent discomfort of the gingivobuccal sulcus

Surgical Technique

- The procedure is usually performed under general anesthesia, although local anesthesia is possible with blocking of the posterosuperior alveolar and greater palatine nerves.
- While transfusions are rarely necessary, immunocompromised and pancytopenic patients are at risk for bleeding, and any measures deemed necessary should be undertaken in these situations, which are usually life threatening.
- General anesthesia is obtained with the endotracheal tube taped off to the opposite corner of the mouth.
- Illumination using a headlight is important.
- Blood pressure should be kept normal or slightly lower than normal.
- The nose is packed with three cotton pledgets moistened in oxymetazoline (Afrin) or 0.25% phenylephrine (Neo-Synephrine).
- Using an assistant with two Army-Navy retractors, the sublabial region is exposed and injected with approximately 3 cc of 1% lidocaine with 1/100,000 adrenaline.
- With a needle-tip Bovie, the mucosa is incised horizontally along the alveolar bone for 2 to 3 cm, lateral to the midline above the tooth sockets (Fig. 104.4).
- The incision should be inferior to the gingivobuccal sulcus so that approximately 0.5 cm of mucosa is preserved for later closure. In edentulous patients, the incision should be made over the attached gingiva to ensure proper fitting of dentures.
- The soft tissue is elevated off the bone of the maxilla using a broad periosteal elevator (Fig. 104.5). In the correct plane, this is easily performed and, using a sponge, can be gently swept superiorly over the anterior wall of the sinus.
- The canine fossa is a slight indentation just lateral to the tooth root, which is usually very prominent.
- Elevate the soft tissue superiorly enough to expose an area of approximately 2 × 2 cm^2 of the anterior wall of the maxilla. Be careful to avoid the terminal branches of the infraorbital nerve as it exits the canal, in the midline, just below the inferior orbital rim (Fig. 104.6).
- Using a small mallet and osteotome, create an opening over the canine fossa into the sinus (Fig. 104.7). Use a rongeur to remove the bone edges, further enlarging the opening and providing a good view into the sinus cavity.
- Depending on the indications for the procedure, the mucosa may be spared or removed in situations such as an antrochoanal polyp or severe chronic sinus disease (e.g., fungal sinusitis). When dealing with an antrochoanal polyp, the mucosa of the antrum is elevated and bluntly dissected toward the natural ostium, to facilitate its removal intact with the polypoid component, which is then grasped in the posterior choana through the nasopharynx. Using gentle traction, it is removed with the antral mucosa intact. Maximum hemostasis must be obtained using the needle-tip Bovie.

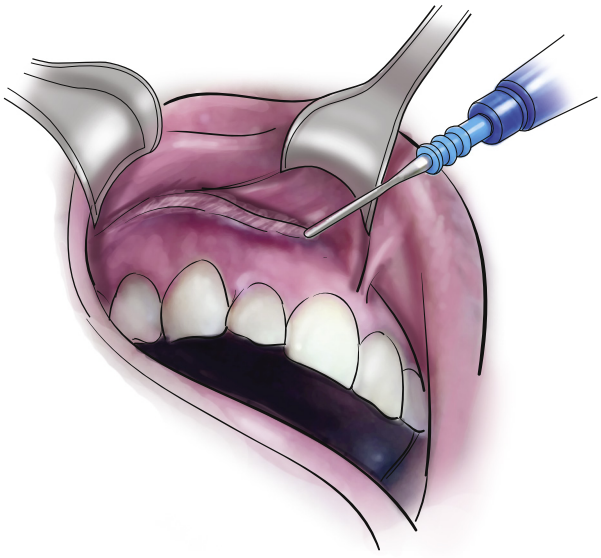

Fig. 104.4. Incision is made in the buccogingival sulcus.

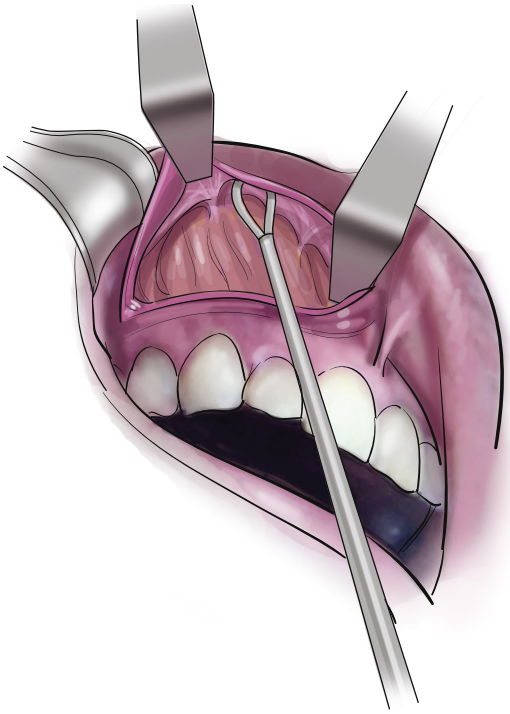

Fig. 104.5. Exposure of the canine fossa with elevation and blunt dissection of the overlying soft tissue.

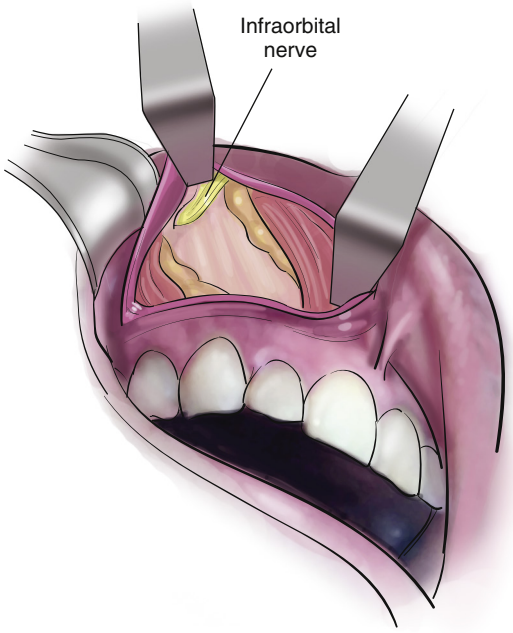

Fig. 104.6. The infraorbital nerve is identified and preserved at the point where it exits the infraorbital foramen.

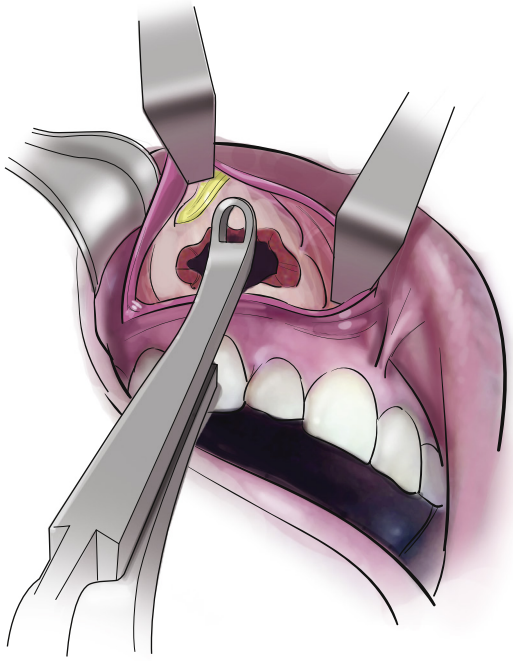

Fig. 104.7. The sinus is carefully opened with an osteotome and widened with a Kerrison rongeur.

- If the Caldwell-Luc procedure is used to access the floor of the orbit, excellent visualization is obtained superiorly.
- If the posterior wall needs to be breached to gain access to the pterygopalatine fossa, this can be easily done with gentle fracturing of the bone, using a mallet and osteotome.
- Once incised, the periosteum behind this thin bone provides direct access to the contents of the pterygopalatine fossa.
- Creating an antrostomy is part of the original description of the procedure but may not be required in certain situations.

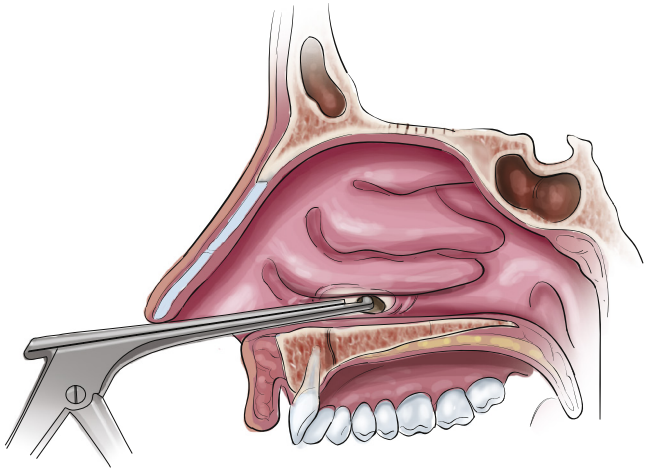

Fig. 104.8. The inferior meatal antrostomy is created inferior to the inferior turbinate after gentle medial mobilization of the turbinate.

- With visualization through the nose, the inferior turbinate is outfractured, gaining access to the inferior meatus. A small window of mucosa is incised with a needle-tip Bovie and reflected inferiorly with exposure of the underlying bone (medial wall of the sinus; Fig. 104.8).
- The sinus can be entered using a curved hemostat or elevator, with gentle pressure on the bone at the most superior point under the attachment of the inferior turbinate. Stay slightly more superior, where the bone is thinner, approximately 1 to 2 cm behind the anterior aspect of the inferior turbinate.
- This window can be widened with a Takahashi forceps or a curved rasp creating a wide 2 × 1 cm^2 window with direct communication with the sinus. The inferior rim should be lowered as much as possible to facilitate gravitational drainage. An olive-tip curved suction can be introduced through the opening into the maxillary sinus.
- Depending on the indications for surgery, the sinus may need to be packed with ribbon gauze impregnated with Bacitracin. This is led out through the antrostomy into the nose. Make sure that the edges of the antrostomy are smooth and the packing is layered in the sinus cavity to avoid any difficulty with removal of the pack.
- If packing is required, another option is to place a Foley catheter through the nose and antrostomy site, into the sinus, and gently inflate the balloon with saline. This is very effective in tamponading any bleeding from the sinus cavity.
- The sublabial incision is closed with interrupted 3-0 Vicryl sutures.
- The packing or Foley catheter is removed 1 to 2 days postoperatively.
- Minor edema of the cheek will be noted postoperatively, which resolves in 4 to 5 days.

Common Errors in Technique

- Incorrect placement of the sublabial incision. Maintain 0.5 cm of mucosa to facilitate closure.
- Incorrect entry into the maxillary sinus. Stay lateral to the canine tooth root, entering into the soft bone forming the canine fossa.
- Avoid injury to the tooth roots by identifying landmarks and avoiding excessive removal of bone from the anterior wall.
- Avoid excessive elevation of soft tissue superiorly so that the infraorbital nerve is not injured, thereby avoiding associated numbness.

- Ensure adequate hemostasis using electrocautery and use packing to avoid bleeding.
- Inadequate intranasal antrostomy without smooth edges and prominent ledge hinders drainage and pack removal.

POSTOPERATIVE PERIOD

Postoperative Management

- Patients generally have moderate pain, and in the past they were kept overnight for observation.
- In the current health care environment, outpatient surgery is appropriate.
- Facial edema is treated with cold packs to the cheek.
- Liquid and a soft diet should be advised while the sublabial incision heals.
- If packing was inserted, it can be removed on the second or third postoperative day. This may be fairly uncomfortable for the patient, and care should be taken to avoid "catching" on bony fragments. If a Foley catheter is used, the balloon can be deflated and observed for any bleeding before removal.
- When the mucosa is removed, all bleeding points in the bone should be cauterized to prevent postoperative bleeding.
- The sublabial sutures usually dissolve in 7 to 10 days, but not infrequently a few remaining sutures may need to be removed.
- Avoid nose blowing for at least a week.
- Upper dentures should be replaced as soon as possible to avoid obliteration of the buccogingival sulcus.

Complications

- Bleeding: While this is usually controlled by initial packing, there is often fairly brisk bleeding after the pack is removed. This will usually stop spontaneously, but occasionally direct intervention with cautery and packing may need to be performed. Using a Foley catheter initially is very helpful in this situation, as the balloon can be deflated and the patient observed for any bleeding before removal of the catheter.
- Injury to tooth apices and their innervation: The teeth apices and their innervation can be damaged, which can affect dental sensation and, rarely, devitalization and discoloration of the teeth.
- Numbness of the canine and premolar teeth: Some patients may experience numbness of their canine and premolar teeth due to injury to the superior alveolar nerve as it passes the inferior aspect of the anterior wall of the maxilla.
- Numbness and injury of the infraorbital nerve: This is typically secondary to dissection and traction of the infraorbital nerve during the initial exposure or rarely with direct injury to the nerve within the roof of the maxillary sinus.
- Orbital injury
- Damage to the nasolacrimal duct
- Oroantral fistula: Oroantral fistula, while rare, can occasionally occur and may require surgical intervention. Osteomyelitis of the maxillary bone is more of a historical complication and not something normally seen.
- Ill-fitting dentures can be avoided by correct placement of the incision.

Alternative Management Plan

1. Endoscopic technique if surgically feasible

DISCUSSION

Evidence-Based Medicine Question

In the era of FESS, what are the common indications and uses for an external approach to the maxillary sinus?

- Since endoscopic sinus surgery was introduced, the indications for an external approach to the maxillary sinus have dramatically changed.[3]
- Most sinus procedures are safely and effectively managed endoscopically with the advantage of excellent illumination and relatively little tissue damage. The principle of mucociliary flow through the natural ostea in the middle meatus is well accepted.
- The indications for this approach include removal of foreign bodies, closure of oroantral fistula, biopsy of suspected antral masses and malignancy, removal of dental cysts, as part of a medial maxillectomy, access to the orbital floor, removal of antrochoanal polyps, elevation and stabilization of the orbital floor in blowout fractures, and as part of the approach to the pterygomaxillary fissure and sphenopalatine fossa.[4]
- There still may be a role for the Caldwell-Luc procedure in chronic sinusitis after failed endoscopic approaches.[5]

Editorial Comment

In the latter part of the 19th century, transatlantic communication was slow, unlike today when a call to Europe is made in seconds using a smart phone. Dr. George Caldwell, an otolaryngologist in New York City, reported a new operation in 1896 that he called a maxillary antrostomy, which he used in the management of chronic maxillary sinusitis—a common problem in the preantibiotic era. Dr. Henri Luc, an otolaryngologist in Paris, reported a similar but not identical operation in 1897. When the news of these two similar operations eventually crossed the Atlantic, the names of the two surgeons were kindly applied to the operation, which became known as the Caldwell-Luc operation (procedure).

While the operation was originally designed to eliminate chronic maxillary sinusitis, it has been adapted by a series of imaginative surgeons to provide an entrance to the maxillary antrum to solve a variety of other problems. This remarkably versatile approach can be used to remove antrochoanal polyps intact, to reduce "blowout" fractures of the floor of the orbit, to retrieve foreign bodies, to close oroantral fistulae, to remove the floor of the orbit for decompression of thyroid exophthalmus, to remove mucoceles or small tumors, and to provide access for medial and total maxillectomy. The maxillary antrostomy also provides a corridor to the ethmoid to perform a transantral ethmoidectomy and to the pterygoid fossa for *sectioning* the Vidian nerve, for ligation of the internal maxillary artery and its branches, and for exposure of the skull base.

In the days before technology brought improvements in our management of certain problems—such as the introduction of the CT scan, the instruments for carrying out and monitoring FESS, interventional radiology with embolization in the treatment of epistaxis and juvenile angiofibroma of the nasopharynx (JNA)—the Caldwell-Luc operation provided a means of managing these problems. I used this approach to remove the posterior wall of the antrum and to ligate branches of the internal maxillary artery in the management of epistaxis. I also used this technique as a means of devascularizing the JNA as the first step in removing them. Fortunately, the interventional radiologists were able

to make this step unnecessary by preoperative intra-arterial embolization.

The Caldwell-Luc procedure is still alive and well in parts of the world where modern technology is not available. The operation is also used in situations where the endoscopic approach has not yet solved the particular problem. Unfortunately, many otolaryngologists trained in the modern era have little or no experience with this operation, which should be part of the required curriculum in residency training programs.

Eugene N. Myers


Access the review questions online at http://www.expertconsult.com

REFERENCES

1. McBeth R. Caldwell, Luc, and their operation. Laryngoscope 1971;81:1652–1657.
2. Van Alyea OE. Nasal Sinuses: An Anatomic and Clinical Consideration. 2nd ed. Baltimore: Williams & Wilkins; 1951.
3. Senior BA, Kennedy DW, Tanabodee J, et al. Long-term results of functional endoscopic sinus surgery. Laryngoscope 1998;108:151–157.
4. Stammberger H, Zinreich SJ, Kopp W, et al. Surgical treatment of chronic recurrent sinusitis–the Caldwell-Luc versus a functional endoscopic technic. HNO 1987;35:93–105.
5. Cutler JL, Duncavage JA, Matheny K, et al. Results of Caldwell-Luc after failed endoscopic middle meatus antrostomy in patients with chronic sinusitis. Laryngoscope 2003;113:2148–2150.

REVIEW QUESTIONS

1. The correct site to enter the maxillary sinus is
   a. Medial to the canine root
   b. Above the canine root
   c. The canine fossa
   d. Just below the orbital rim

2. Potential complications of the Caldwell-Luc procedure include all of the following, except
   a. Numbness of the cheek
   b. Injury to the nasolacrimal duct with tearing
   c. Blindness
   d. Anosmia

3. Correct statements regarding the inferior meatal antrostomy include all of the following, except
   a. Placement 3 cm behind the anterior aspect of the inferior turbinate (correct answer 1 to 2 cm behind the anterior aspect of the inferior turbinate)
   b. Below the inferior turbinate
   c. The inferior edge of the antrostomy should be as low as possible.
   d. The edges of the antrostomy should be as smooth as possible.

105 Oroantral Fistulas

Michael D. Chambers, William Chung

INTRODUCTION

An oroantral communication occurs when there is an abnormal connection between the maxillary sinus and the oral cavity. The communication may be the result of trauma, osteomyelitis, pathologic lesions, or foreign bodies such as dental implants or endodontic material. However, the most common cause of an oroantral communication is the extraction of a posterior maxillary tooth. The root apices are in close proximity to the floor of the maxillary sinus and, in some cases, are only separated by a thin layer of lamellar bone or sinus mucosa. The teeth most commonly involved in communication are the maxillary molars.[1-3] If left untreated, this communication can result in unsuccessful healing of the Schneiderian membrane and progress to an epithelial-lined tract known as an *oroantral fistula,* which will not heal spontaneously.

Closure of the fistula is dependent on the size of the bony defect. Healing may occur spontaneously if the defect is less than 5 mm in diameter.[4] However, primary soft tissue closure at the time of the extraction and the use of a collagen plug stabilized with a figure-of-eight suture can promote clot formation and spontaneous healing of the defect. For defects greater than 5 mm, closure using various intraoral flaps in conjunction with functional endoscopic sinus surgery increases the chance for long-term success.

KEY OPERATIVE LEARNING POINTS

1. Extraction of a posterior maxillary molar tooth is the most common cause of an oroantral fistula.
2. Long-term success in healing requires débridement of necrotic bone, soft tissue, and the fistulous tract.
3. Crossing the buccal vestibule with a flap can obliterate the sulcus and interfere with denture use.
4. Fabrication of an acrylic splint can protect the flap and palate.

PREOPERATIVE PERIOD

History

1. History of present illness
   a. Presence of a communication or fistula can be confirmed by asking the patient if regurgitation of fluid from the nose occurs after drinking liquids.
   b. Fetid odor/drainage due to oroantral communication
   c. Chronic pain from the defect
2. Past medical history
   a. History of chronic sinusitis
3. Past surgical history
   a. Previous attempts at closure of the oroantral fistula
4. Medications
   a. Antibiotics
   b. Antiplatelet agents
   c. Anticoagulant therapy
   d. Immune suppression
   e. Over-the-counter (OTC)/herbal medications
5. Allergies
6. Social history
   a. Alcohol use/abuse
   b. Cigarette smoking
   c. Illicit drug use/abuse

Physical Examination

1. Oral and nasal examination may reveal erythema of the mucosa, intraoral or intranasal infection, oralantral fistula, or a compromised ostiomeatal complex (Fig. 105.5).

Imaging

1. Panorex (Fig. 105.1)
   a. First choice of radiograph, especially if the fistula occurred after dental extraction(s)
   b. Assess the size of the bony defect adjacent to the fistula.
   c. Assists in treatment planning and flap design, since there is no scatter from any existing maxillary dental restorations
2. Computed tomography (CT) scan (maxillofacial or sinuses; Fig. 105.2)

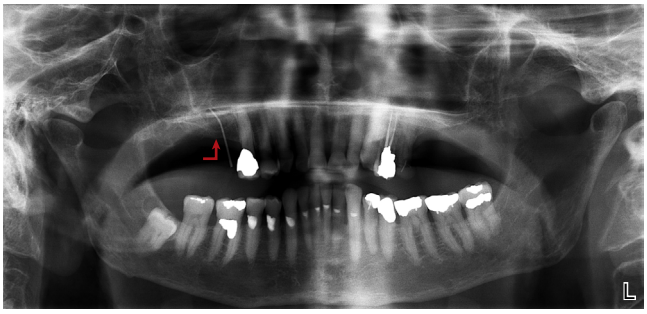

Fig. 105.1. Panorex radiograph depicts gutta percha point within oroantral bony defect associated with extraction site tooth #3 *(arrow)*. *(Radiograph courtesy Dr. Richard Bauer, University of Pittsburgh School of Dental Medicine.)*

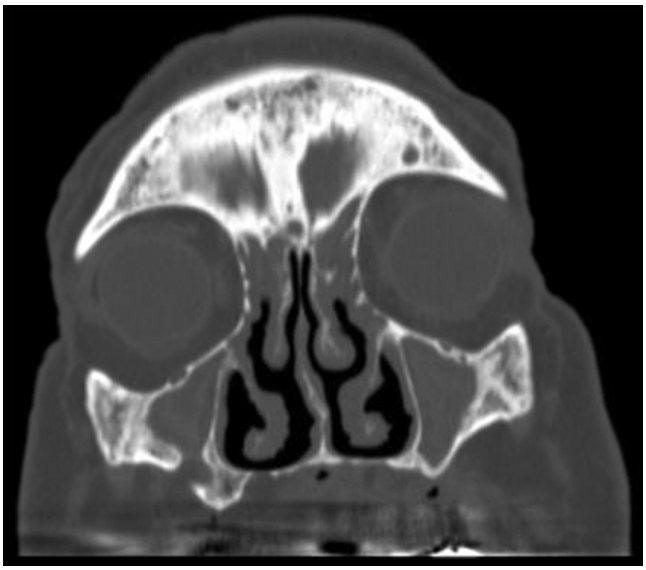

Fig. 105.2. Coronal computed tomography scan of patient from Fig. 105.1. Bony defect in right maxilla forms a communication between the maxillary sinus and the oral cavity.

a. Not necessary as a first-line choice of imaging
b. Recommended with larger defects (>1 cm) or cases of chronic fistula from repeated failure of fistula closure
c. Assess for mucosal thickening, maxillary opacification, and obstruction of the ostiomeatal complex.
d. Intrasinus injections or oral rinse with water-soluble contrast may further enhance the imaging by providing the surgeon with a better understanding of the oroantral fistula's path between the oral cavity and antrum.[5]

Indications

1. Nasal regurgitation of liquids through fistula
2. Foul odor or chronic purulent drainage from the fistula
3. Air leakage through the fistula
4. Chronic pain in the fistulous site

Contraindications

1. Acute oral infection or acute maxillary sinusitis
2. Medically unstable for anesthesia or surgery (immune compromised, severely malnourished)
3. Multiple failures with no further tissue options available to close the defect (patient may require prosthesis/obturator to cover the defect)
4. Patient is unable to consent or declines surgical repair

Preoperative Preparation

1. Preoperative management with antibiotics, antihistamines, nasal decongestants, and irrigation of the fistulous tract to reduce the risk of failure
2. Discontinue antiplatelet or anticoagulant therapies, if possible.
3. After flap design has been chosen, diagnostic impressions with alginate can be used to fabricate a clasp-retained acrylic partial denture. The denture protects the surgical site from oral trauma, improves patient comfort, and maintains adequate depth of the buccal vestibule during the healing phase.

OPERATIVE PERIOD

Anesthesia

1. Request nasotracheal intubation with the endotracheal tube in the side of the nose opposite the fistula to allow for concurrent functional endoscopic sinus surgery (FESS).
2. If the endotracheal tube cannot be passed as desired, then place an oral Ring, Adair, and Elwyn (RAE) tube in the side opposite the oroantral fistula.
3. Paralysis is not necessary, unless the oral opening is limited due to the patient clenching teeth.

Positioning

1. Patient is placed supine with mid- and lower face appropriately prepped and draped
2. Oral prep with chlorhexidine rinse or clindamycin-infused normal saline

Perioperative Antibiotic Prophylaxis

1. Appropriate intravenous antibiotics with sinus coverage desired:
   a. Unasyn
   b. Clindamycin, if allergic to penicillin
   c. Ciprofloxacin, if there is a history of antibiotic-associated colitis with clindamycin and penicillin allergy
   d. Moxifloxacin, if there is a history of antibiotic-associated colitis with clindamycin and penicillin allergy

Monitoring

1. Routine

Instruments and Equipment to Have Available

1. Appropriate surgical retractor(s) of surgeon's preference (Minnesota, Seldon, Obwegesser, Wieder)
2. Periosteal elevator (no. 9)
3. No. 15 and 11 blades
4. Molt or double-ended dental curettes
5. Rongeurs, preferably fine-tipped
6. Bone file
7. Sutures:
   a. 4.0 Vicryl
   b. 4.0 chromic gut
8. FESS surgery set
9. Nasal endoscopes

Key Anatomic Landmarks

1. The location and size of the defect, presence of adjacent teeth, topography of surrounding bone, and potential plans for dental restoration once the fistula is removed must all be considered when developing a surgical plan.
2. The buccal adipose tissue pad is a large lobulated mass:
   a. Consists of a central body and four processes, including the buccal, pterygoid, pterygopalatine, and temporal extensions
   b. Derives its blood supply from the buccal and deep temporal branches of the maxillary artery, the transverse branch of the superficial temporal artery, and several branches of the facial artery

Prerequisite Skills

1. Familiarity of the relationship of maxillary teeth with maxillary sinus
2. Previous experience with creating, mobilizing, and advancing flap(s) in a tension-free manner
3. Familiarity with the location of the buccal adipose tissue pad

Surgical Technique

- Combined *intraoral and endoscopic* approaches increase the chances of long-term success of fistula closure.
- *Intraoral therapy* involves removal of the epithelialized fistulous tract and surrounding necrotic bone, followed by soft tissue closure using one of a variety of surgical flaps (Fig. 105.3).

Flap design: Surgical closure of the fistula from the oral cavity is typically accomplished with traditional soft tissue flaps such as the Rehrmann buccal advancement flap[6] or a palatal rotation flap. While numerous treatment modalities have been described in the literature (Fig. 105.4), Visscher et al. have found that the buccal and palatal flaps remain the primary treatment of choice due to both cost and the simplified approach of closure.[7]

1. Buccal advancement flap technique
   - Simple and safe procedure with low postoperative morbidity (Figs. 105.6 and 105.7)
   - Ideal for smaller defects; enhanced by including the pedicled buccal adipose tissue pad

- Two divergent vertical incisions, which extend from the extraction site to the buccal vestibule, allow for a broad base to ensure an adequate blood supply.
- Upon elevation, an additional incision of the periosteum at the base of the flap is created to allow for maximal advancement to cover the defect with a tension-free closure.

2. Buccal adipose tissue pad technique
   - Small vertical incision in the reflected periosteum posterior to the zygomatic buttress, allowing adequate exposure of the buccal adipose tissue pad and advancement over the bony defect.

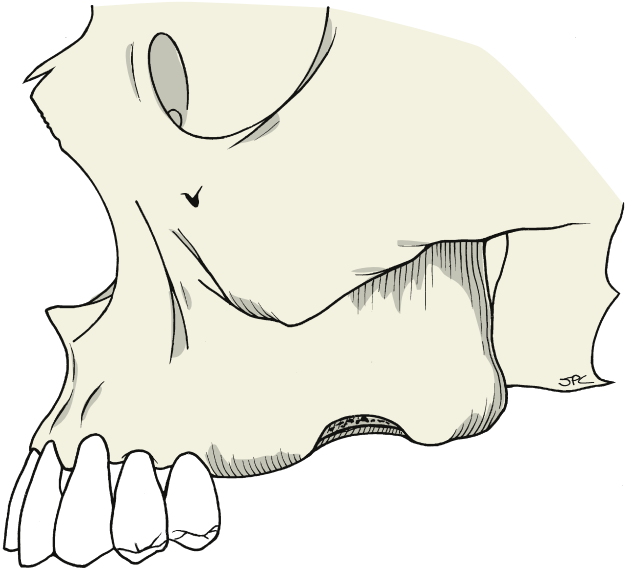

Fig. 105.3. The bone is recessed superiorly to ensure removal of all necrotic bone and epithelial elements of the fistulous tract. This, in turn, enhances primary closure of the fistula.

   - The adipose tissue pad is secured to the palatal mucosa with absorbable sutures, followed by repositioning of the reflected oral mucosa.
   - The mucosal flap does not need to be advanced over the adipose tissue pad covering the defect, preventing loss of vestibular depth.
   - The rapid epithelialization of the uncovered adipose tissue with stratified squamous cells from adjacent soft tissue is a distinctive feature of the pedicled buccal adipose tissue pad flap.[8-10]
3. Palatal rotation (finger) flap
   - Rotational, full-thickness mucoperiosteal palatal flap still widely used and ideal for larger defects (Figs. 105.8 and 105.9)
   - The flap design should not include tissue from the median palatal raphe or be in close proximity to the gingival tissue, as this tissue is much thinner and friable.
   - Once the flap has been mobilized, rotated into position, and secured, the exposed palatal bone will heal by secondary intention.
   - Does not obliterate the buccal vestibule and uses keratinized tissue that is more resistant to trauma and dehiscence
4. Tongue flap
   - Available when previously mentioned techniques have failed
   - Endoscopic surgery includes removal of polypoid mucosa and any foreign bodies in the sinus, along with enlargement of the maxillary sinus ostium to ensure adequate sinus drainage.

Common Errors in Technique

1. Flap design insufficient in length
2. Flap closure under tension
3. Fistulous tract or residual necrotic tissue incompletely removed
4. Using buccal advancement flap for larger defects—more prone to dehiscence and recurrence of the oroantral fistula due to limited mobility and thin tissue

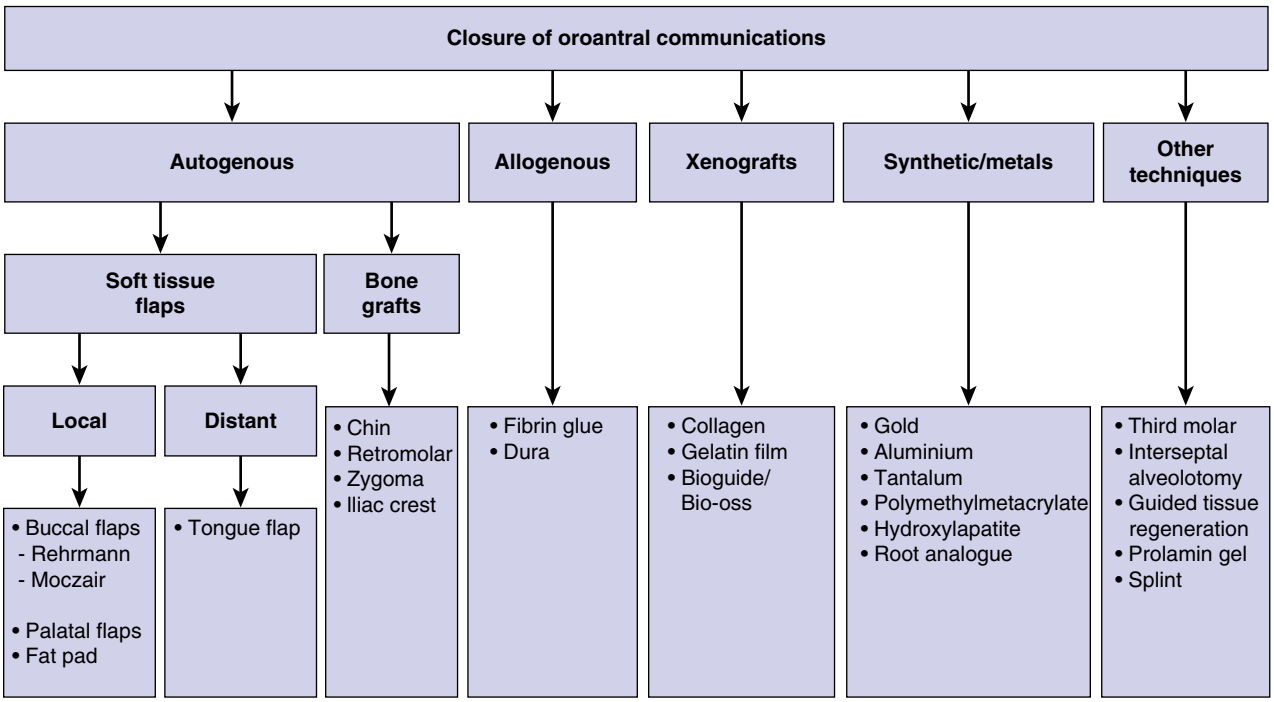

Fig. 105.4. Overview of the treatment modalities of oroantral communications. *(With permission from Visscher S, van Minnen B, Bos R. Closure of oroantral communications: a review of the literature. J Oral Maxillofac Surg 68:1384-1391, 2010.)*



Fig. 105.5. Clinical photo of the patient in Figs. 105.1 and 105.2. Purulent drainage from oroantral fistula noted in alveolar crest associated with tooth #3.

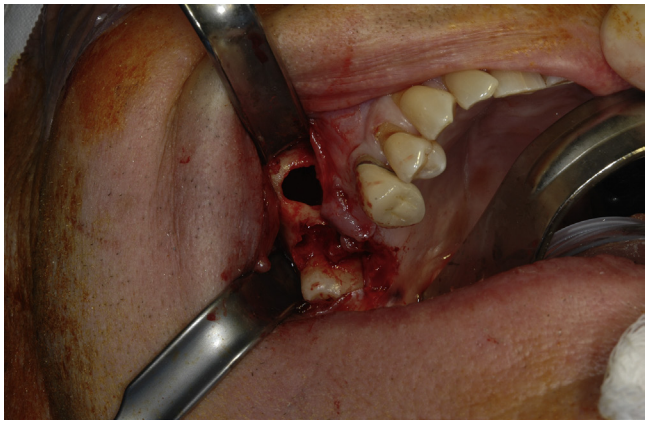

Fig. 105.6. Flap elevated, exposing bony defect associated with oroantral fistula.

5. The flap can also obliterate the depth of the buccal vestibule after advancement.

POSTOPERATIVE PERIOD

Postoperative Management

1. Oral antibiotics for *7 days*
   a. Augmentin
   b. Clindamycin, if penicillin allergic
   c. Avelox, if history of antibiotic-associated colitis to clindamycin and resistance to penicillins
   d. Chlorhexidine (Peridex) oral rinses bid
2. Strict sinus precautions for *14 days*
   a. No tobacco products
   b. Avoid forcibly blowing of the nose or sneezing
   c. No use of straws
3. Use of acrylic, clasp-retained postoperative splint, if fabricated, to protect the palatal tissues for *14 days*
4. Soft diet for *14 days*
5. Avoidance of wearing a pre-existing denture for *14 days*, since the denture may apply excess pressure on the surgical site

Complications

1. Hematoma
   a. Drain to avoid pressure ischemia.

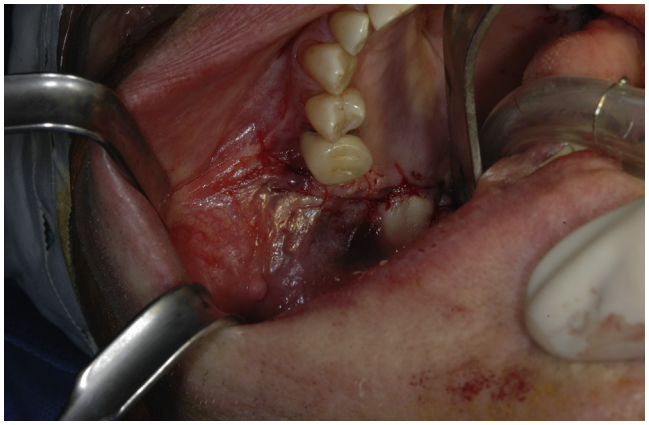

Fig. 105.7. Buccal advancement flap technique. Flap advanced over defect and closed with vicryl sutures.

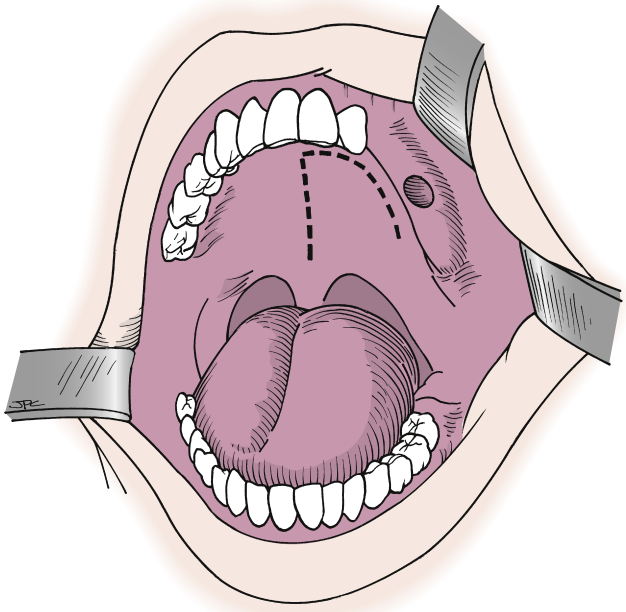

Fig. 105.8. Design of a posteriorly based palatal flap.

2. Dehiscence
   a. Gentle irrigation adjacent to opening with saline solution. If closure completely opens, plan for secondary closure with alternative flap design.
3. Infection
   a. Implement an appropriate antibiotic after incision and drainage, culture, and assessment of the sensitivity of purulence.
4. Obliteration of buccal vestibule/sulcus from flap
   a. Specific flap design can avoid/minimize this condition.
   b. Patient may require adjustment of existing denture or fabrication of new denture

Evidence-Based Medicine Question

Does concurrent FESS aid in the repair and successful closure of oroantral fistula?

Successful management of an oroantral fistula should address both the fistula and the chronic infectious process within the maxillary sinus (see Fig. 105.9). The well-known Caldwell-Luc procedure, which was first described in the

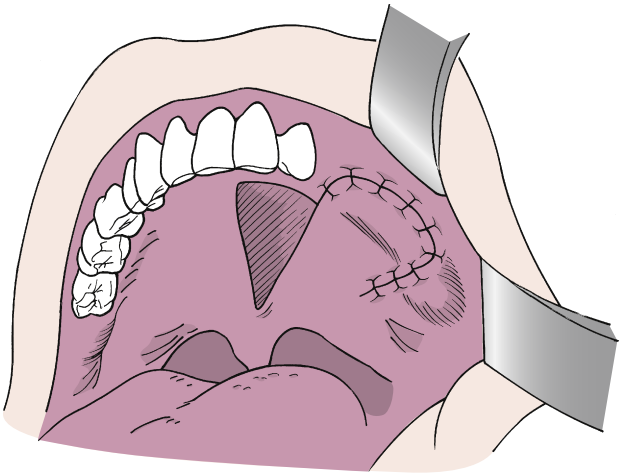

Fig. 105.9. Mobilization and rotation of the palatal flap to cover the fistula. The resulting mucosal defect in the palate is allowed to granulate and heal by secondary intention. An acrylic splint fabricated preoperatively can improve patient comfort over the palate, particularly during eating.

1890s, includes a transoral approach via the canine fossa. While this operation is still used today, it is usually reserved for more complex cases or when FESS surgery is not available. As the physiologic drainage and anatomy of the maxillary sinus became clear, an intranasal approach to management of chronic sinusitis has become the standard of care through FESS. The use of endoscopic sinus surgery in the management of sinusitis caused by complications arising from oral surgical procedures is relatively new (Fig. 105.10).

The FESS is a minimally invasive approach with relatively low morbidity and a high success rate, making it ideal for management of chronic sinusitis caused by an oroantral fistula.

The FESS involves dislocation of the middle turbinate toward the septum and a complete uncinectomy for visualization of the surgical field, followed by a maxillary antrostomy to reestablish drainage of the maxillary sinus. Additional evaluation of the anterior ethmoid cells is necessary to ensure removal of residual disease and to prevent recurrence. True inflammatory polyps and foreign bodies such as tooth roots are subsequently removed from the maxillary sinus.

Editorial Comment

In larger oroantral fistula defects, vascularized tissue reconstruction is vital to long-term success. Similar to fistulas present in the upper aerodigestive tract and skull base, the use of vascularized reconstruction has increased the overall success rate of the procedure. This efficacy is balanced with donor site morbidity. In the case of a palatal rotational finger flap, the exposed hard palate will re-epithelialize quickly if the appropriate postoperative precautions are taken. The role of concurrent maxillary antrostomy is increasingly recognized in larger defects, as this allows for physiologic management of the sinus and prevents postoperative mucosal inflammation and secondary obstruction from hindering the repair.

Eric W. Wang

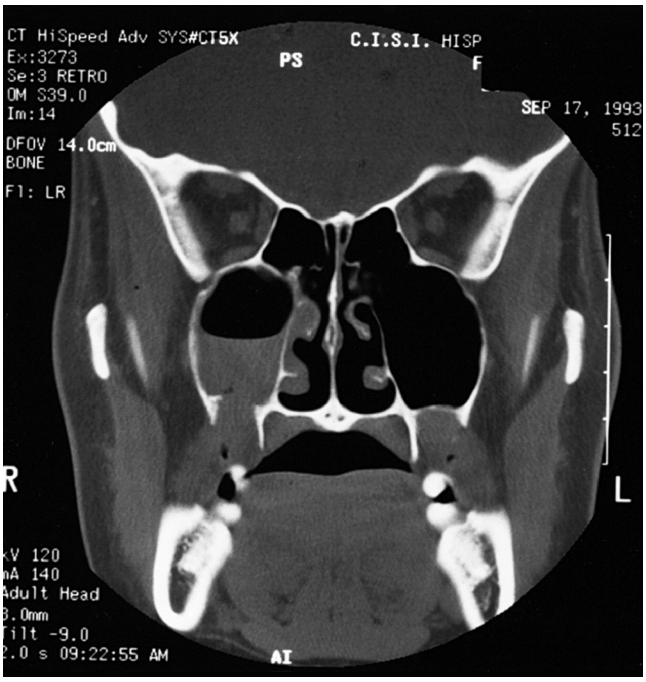

Fig. 105.10. Computed tomography scan demonstrating an oralantral fistula with obstruction of the maxillary sinus. Adequate intranasal drainage to either the middle meatus or the inferior meatus must be achieved to ensure success when the fistula is closed.

Access the review questions and additional sources list online at http://www.expertconsult.com

REFERENCES

1. Von Bondsdorff P. Untersuchungen uber Massverhaltnisse des Oberkiefers mit spezieller Berucksichtigung der Lagebeziehungen zwischen den Zahnwurzeln und der Kieferhohle. Helsinki: Thesis; 1925.
2. Punwutikorn J, Wailkakul A, Pairuchvej V. Clinically significant oroantral communications—a study of incidence and site. Int J Oral Maxillofac Surg 1994;23:19–21.
3. Abuabara A, Cortez A, Passeri L, et al. Evaluation of different treatments for oroantral/oronasal communications. Int J Oral Maxillofac Surg 2006;35:155.
4. von Wowern N. Correlation between the development of an oroantral fistula and the size of the corresponding bony defect. J Oral Surg 1973;31:98.
5. Petty B, Bezerra R, Berkowitz F, et al. Novel diagnostic method for oroantral fistulas. Otolaryngol Head Neck Surg 2013;149(5): 791–792.
6. Rehrmann A. A method of closure of oroantral perforation. Dtsch Zahnarzti Z 1936;39:1136.
7. Visscher S, van Minnen B, Bos R. Closure of oroantral communications: a review of the literature. J Oral Maxillofac Surg 2010;68:1384–1391.
8. Bauman A, Ewers R. Application of the buccal fat pad in oral reconstruction. J Oral Maxillofac Surg 2000;58:389–392.
9. Samman N, Cheung LK, Tideman H. The buccal fat pad in oral reconstructions. Int J Oral Maxillofac Surg 1993;22:2–6.
10. Chao CK, Chang LC, Liu SY, Wang JJ. Histologic examination of pedicled buccal fat pad in oral submucous fibrosis. J Oral Maxillofac Surg 2002;60:1131–1134.

REVIEW QUESTIONS

1. Reasons for failure of oroantral fistula repair include each of the following, except
   a. Creation of a flap of insufficient length
   b. Incomplete removal of infected tissue or bone at the site of the defect
   c. A narrow flap base as a result of converging releasing incisions in the flap design
   d. Scoring the periosteum to allow for advancement of the flap in a tension-free manner

2. Each of the following postoperative instructions improves successful closure of the defect, **except**
   a. Avoidance of tobacco products
   b. Strict sinus precautions
   c. Consumption of a regular diet
   d. Use of an acrylic palatal splint

3. Each of the following can contribute to flap breakdown, **except**
   a. Not removing all epithelial remnants of the fistulous tract
   b. Not reestablishing drainage of the sinus by widening the ostium in the middle meatus
   c. Not removing all of the polypoid sinus tissue at the time of surgery
   d. Not removing all of the necrotic bone or mucosa adjacent to the fistula

4. Management of an oroantral fistula must take into consideration the degree of disease within the involved maxillary sinus. Concurrent FESS allows the surgeon which of the following advantages?
   a. Removal of chronically inflamed sinus mucosa within the entire antrum
   b. Exploration of the anterior ethmoid cells
   c. Removal of any foreign bodies or tooth roots via an endoscopic approach
   d. Create a new functional ostium to assist in drainage of the antrum
   e. All of the above

ADDITIONAL SOURCES

Albu S, Baciut M. Failures in endoscopic surgery of the maxillary sinus. Otolaryngol Head Neck Surg 2010;142:196–201.

Costa F, Emanuelli E, Robiony M, et al. Endoscopic surgical treatment of chronic maxillary sinusitis of dental origin. J Oral Maxillofac Surg 2007;65:223–228.

Hajiioannou J, Koudounarakis E, Alexopoulou K, et al. Maxillary sinusitis of dental origin due to oroantral fistula, treated by endoscopic sinus surgery and primary fistula closure. J Laryngol Otol 2010;124:986–989.

Ramadan HH. Surgical causes of failure in endoscopic sinus surgery. Laryngoscope 1999;109:27–29.

Richtsmeier WJ. Top 10 reasons for endoscopic maxillary sinus surgery failure. Laryngoscope 2001;111:1952–1956.

106 Medial Maxillectomy

Ehab Hanna

INTRODUCTION

Medial maxillectomy is most commonly indicated for resection of tumors of the nasal cavity, lateral nasal wall, and medial maxillary sinus. The incision most commonly used for exposure is the lateral rhinotomy. This offers the best exposure for a medial maxillectomy and can be combined with a transcranial approach for an anterior craniofacial resection commonly used for removal of advanced tumors of the anterior skull base. Alternatively, a midfacial degloving procedure may be used. The midfacial degloving approach is most commonly used in the management of large benign lesions of the sinonasal region and skull base such as juvenile nasopharyngeal angiofibroma, for selected malignancy in this area, and to afford access to the nasopharynx and infratemporal fossa. The main advantage of the "degloving" approach is that an external facial incision is avoided. Another advantage is providing simultaneous exposure to the inferior and medial maxilla, bilaterally. This is particularly helpful when approaching tumors with bilateral involvement of the nasal cavity and maxillary sinus. A major disadvantage, however, is the limited superior and posterior exposure and the need for constant retraction of the soft tissue envelope for continued adequate exposure. Endonasal endoscopic medial maxillectomy and sphenoethmoidectomy may be also performed and provide excellent visualization for appropriately selected tumors. Regardless of the approach, medial maxillectomy includes removal of the lateral nasal wall and the medial aspect of the maxillary bone bounded laterally by the infraorbital nerve. In addition, a complete sphenoethmoidectomy is usually performed.

KEY OPERATIVE LEARNING POINTS

- The lateral rhinotomy offers the best exposure for a medial maxillectomy.[1]
- The midfacial degloving is most suited for bilateral or midline lesions but provides limited superior and posterior exposure.
- The endoscopic approach may be used in selected cases, offers excellent visualization, and avoids a facial incision.[2]

PREOPERATIVE PERIOD

History

- Small intranasal tumors are often completely asymptomatic or mimic more common benign conditions such as chronic sinusitis, allergy, or nasal polyposis.
- Common symptoms include nasal obstruction, "sinus pressure" or pain, nasal discharge that may be bloody, epistaxis, or anosmia.
- Failure of these symptoms to respond to adequate medical therapy or the presence of unilateral signs and symptoms should alert the physician to the possibility of malignancy and warrants further investigation by high-resolution imaging.
- Orbital symptoms such as tearing, double vision, or proptosis are a concern for malignancy with extension to the orbit.

Physical Examination

- Comprehensive examination of the nasal cavity should be done after topical decongestion and anesthesia using rigid or flexible endoscopy (Fig. 106.1). The presence of intranasal masses, ulcers, or areas of contact bleeding may suggest a malignant tumor. Although unilateral "polyps" may be inflammatory, they are more commonly neoplastic.
- Tumors may also present as a submucosal mass without changes in the mucosa.
- Any suspicious lesions should be biopsied, preferably after high-resolution imaging has been obtained, to avoid severe bleeding from highly vascular tumors and/or cerebrospinal fluid (CSF) leak in cases of intracranial extension.
- Extension of sinonasal tumors to adjacent structures renders the diagnosis obvious but is a late manifestation of the disease. Soft tissue swelling of the face may indicate tumor extension through the anterior bony confines of the nose and sinuses. Inferior extension toward the oral cavity may present with an ulcer or a submucosal mass in the palate or the alveolar ridge. Middle ear effusion may indicate tumor involvement of the nasopharynx, Eustachian tube, or tensor veli palatini muscle. Extension of the tumor to the skull base may lead to involvement of the cranial nerves producing anosmia, blurred vision, diplopia, or hypothesia along the branches of the trigeminal nerves.
- Orbital involvement is common in patients with cancer arising from the ethmoid, maxillary sinuses, or the nasal cavity. Epiphora usually indicates involvement of the nasolacrimal duct. Diplopia may result from compression or infiltration of ocular nerves or muscles. Proptosis may be the result of displacement or invasion of the globe. Visual loss secondary to optic nerve involvement is usually a late sign, although more subtle signs of optic nerve dysfunction, including afferent pupillary defect, loss of color vision, and visual field defects, are more frequently encountered. Finally, orbital involvement may be asymptomatic and is only discovered on computed tomography (CT) or magnetic resonance imaging (MRI) evaluation of patients with sinonasal complaints.

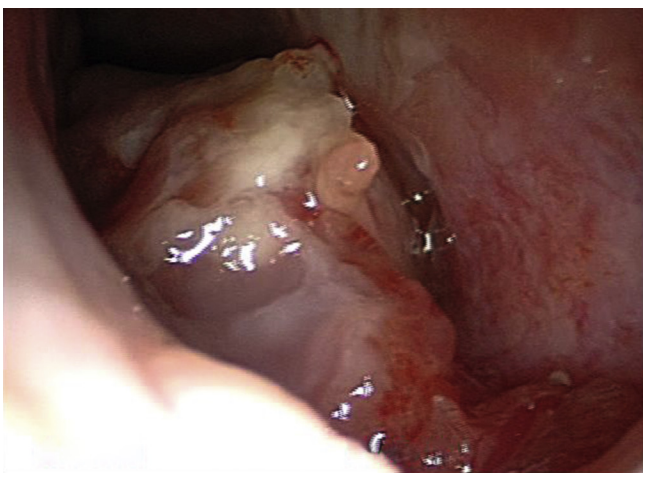

Fig. 106.1. Endoscopic view of a tumor arising from the floor of the right nasal cavity. Biopsy revealed squamous cell carcinoma.

- The presence of a mass in the neck usually represents metastatic cancer to the cervical lymph nodes.

Imaging

- Imaging is very helpful in obtaining pretreatment information regarding the location, size, and extent of the primary tumor, as well as the presence of regional and distant metastasis. Such information is critical in deciding on therapeutic options and for proper preoperative planning of the optimal surgical approach.
- Both CT and MRI might be needed for optimum radiologic assessment of sinonasal malignancy, particularly in assessing the cranial base, orbit and pterygopalatine, and infratemporal fossae. Coronal images best delineate involvement of the orbital walls and invasion of the skull base, particularly the cribriform plate. Axial images are particularly helpful in demonstrating tumor extension through the posterior wall of the maxillary sinus into the pterygopalatine fossa and infratemporal fossae. Sagittal images are particularly helpful in evaluating extension along the cribriform plate, planum sphenoidale, and clivus.
- The main advantage of CT scans is in delineating the architecture of the bones, especially in "bone windows." The addition of contrast enhancement increases tumor definition from adjacent soft tissue, especially intracranially. Bone destruction and invasion of soft tissue suggest an aggressive lesion, usually a malignant neoplasm. Widening or sclerosis of the foramina of the infraorbital, Vidian, mandibular, or maxillary nerves may indicate perineural spread.
- MRI with its superior soft tissue contrast and multiplanar capability is superior to CT in pretreatment evaluation of primary malignant tumors of the sinonasal cavity.[3] MRI is unsurpassed in delineating soft tissue detail, both intra- and extracranially. Obliteration of adipose tissue planes in the pterygopalatine fossa, infratemporal fossa, and nasopharynx usually indicates tumor transgression along these boundaries. Dural thickening or enhancement is usually an indication of tumor involvement, and evaluation of critical structures such as the brain and carotid artery is best delineated by MRI. Similarly, enhancement or thickening of cranial nerves suggests perineural spread, which is better detected on MRI than CT.[4] Perhaps one of the most significant advantages of MRI is the ability to distinguish tumor from retained secretions secondary to obstruction of sinus drainage (Fig. 106.2).
- *Angiography* is not indicated in the routine assessment of patients with neoplasms of the nose and paranasal sinuses. In certain selected cases, however, angiography may be necessary. These cases include vascular neoplasms of the sinonasal region such as juvenile angiofibroma, where angiography will not only delineate the tumor extent and the blood supply but also permit the use of selective embolization of the vascular supply to the tumor. This reduces intraoperative blood loss, facilitating surgical resection.

Indications

1. Medial maxillectomy is indicated for resection of tumors of the lateral nasal wall, nasal cavity, nasal septum, or the medial wall of the maxillary sinus.[1]
2. Medial maxillectomy may also be used for exposure of and access to the pterygopalatine fossa, pterygoid plates, nasopharynx, sphenoid sinus, clivus, and the medial infratemporal fossa.[5]
3. Medial maxillectomy can be combined with resection of the floor of the nose, palate, or upper gingiva (inferior maxillectomy).
4. Medial maxillectomy may also be combined with a transcranial approach for resection of the anterior skull base.

Contraindications

Medial maxillectomy is not adequate if the tumor extends laterally to the infraorbital nerve, palate, or facial soft tissue.

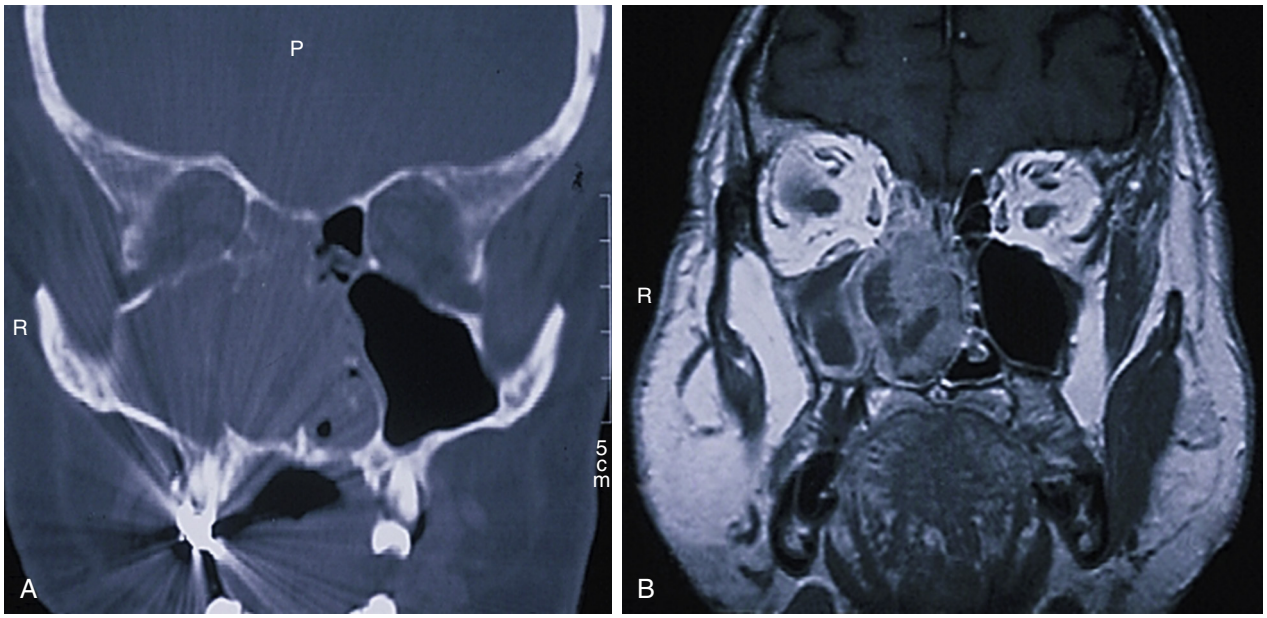

Fig. 106.2. A, Coronal computed tomography scan demonstrating opacification of the right nasal cavity, the maxillary and ethmoid sinuses. There appears to be destruction of the lateral nasal wall and the nasal septum. The lesion is abutting the orbital floor and the cribriform plate, but it is unclear whether or not these structures are involved. **B,** Coronal T1-weighted magnetic resonance imaging with gadolinium of the same patient revealing that the lesion is limited to the nasal cavity and ethmoid sinuses and that the changes in the maxillary sinuses are due to retained secretions secondary to obstruction of the ostium, rather than soft tissue involvement. It also demonstrates that the lesion does not invade the orbit or the cranial base.

Preoperative Preparation

- A thorough preoperative assessment should determine the candidacy of a patient for surgical management of his or her neoplasm. This involves a careful "mapping" of the tumor extent, as well as the patient's general medical condition and functional status.
- This is usually accomplished by a detailed history and a comprehensive examination of the head and neck region including sinonasal endoscopy.
- Examination of the cranial nerves as well as ophthalmologic evaluation should be done to evaluate the cranial base and orbital extension, respectively.
- Evaluation by a maxillofacial prosthodontist is required in most patients to obtain preoperative dental impressions and to design surgical obturators or splints for maintenance of proper dental occlusion and oral rehabilitation.
- Consultations with medical and radiation oncology colleagues should be done to consider incorporation of chemotherapy or radiation in the treatment plan. Radiation and/or chemotherapy may be used preoperatively as induction (neoadjuvant) or postoperatively as adjuvant therapy. Such decisions are best discussed in the format of a multidisciplinary tumor board.
- If surgery is chosen as a treatment modality, the plan for the surgical approach, the extent of resection, and reconstructive options should then be formulated.
- Careful assessment of the patient's general medical condition should be carried out prior to surgery. Preoperative chest radiograph, blood counts, liver and renal function tests, blood sugar, electrolytes, coagulation studies, and an electrocardiogram (ECG) should be performed routinely. Appropriate consultations from internal medical colleagues should be obtained in order to optimize the patient's medical status before surgery and help in the postoperative management.
- Finally, the surgical team should discuss with the patient and the family the nature of the disease, the evaluation, and the indications, risks, possible complications, sequelae, and any alternative plans of management. The expected postoperative course including length of stay in the hospital, feeding, rehabilitation, and the need for adjuvant therapy should be described. This ongoing communication should be maintained in a clear, honest, and sympathetic fashion throughout the course of the patient's care.

OPERATIVE PERIOD

Anesthesia

1. General endotracheal anesthesia is needed to provide monitored, controlled, deep anesthesia needed for soft tissue dissection and bone removal during medial maxillectomy.
2. Orotracheal intubation with a reinforced endotracheal tube taped and secured to the contralateral oral commissure offers the best working area for a medial maxillectomy.

Positioning

1. Supine with a shoulder roll to extend the neck
2. The head of bed should be elevated about 30 degrees. This reduces blood loss and allows better visualization of the surgical field.

Perioperative Antibiotic Prophylaxis

Prophylactic antibiotics should be given approximately 30 minutes prior to making the incision and for 24 hours after surgery. Antibiotics should be broad spectrum covering the aerobic and anaerobic bacterial flora of the nasal and oral cavities. Intraoperative topical antibiotic irrigation of the surgical field greatly reduces postoperative infections.

Monitoring

Routine monitored anesthesia control is usually all that is needed.

Instruments and Equipment to Have Available

1. Soft tissue dissection set
2. Bone resection set including various size rongeurs and both cutting and diamond high-speed irrigating drills
3. Sinus instrument set including optional endoscopic set

Key Anatomic Landmarks

1. Infraorbital nerve
2. Nasolacrimal duct
3. Anterior and posterior ethmoid arteries
4. Cribriform plate
5. Fovea ethmoidalis
6. Opticocarotid recess in the sphenoid sinus

Prerequisite Skills

1. Meticulous soft tissue technique
2. Familiarity with bone resection including facial osteotomies and drilling techniques
3. Expert knowledge of sinonasal and skull base anatomy

Operative Risks

1. Inadvertent corneal injury. This should be avoided by performing a temporary tarsorrhaphy to protect the eye during the procedure. Alternatively, a corneal shield may be used.
2. Injury to the infraorbital nerve during soft tissue elevation and dissection or during bone drilling or osteotomies. Excessive retraction of the infraorbital nerve may cause temporary neuropraxia of the nerve resulting in hypoesthesia of the cheek and/or the teeth.
3. Injury to the nasolacrimal duct leading to postoperative epiphora. If the nasolacrimal duct is sacrificed, a wide marsupialization of the lacrimal sac into the nasal cavity should be done.
4. Inadvertent skull base entry leading to CSF leak. The most common site of injury is the cribriform plate and the point of insertion of the middle turbinate. This can be avoided by studying the details of the patient's skull base anatomy on preoperative imaging. The middle turbinate insertion to the skull base should not be fractured or pulled by force but rather sharply incised with scissors or other cutting forceps.
5. Injury to the orbita due to inadvertent entry through the periorbita. Peri- or intraorbital hemorrhage may result from inadequate control of the anterior or posterior ethmoid arteries that should be coagulated using bipolar cautery or clipped prior to their division.
6. Injury to the optic nerve or carotid artery in the sphenoid sinus. Careful assessment of the anatomy of the sphenoid sinus, its septal insertions, and the opticocarotid recess should be noted on the preoperative imaging. Bony dehiscence of the carotid or optic canals should be noted. Sphenoid sinus septa frequently insert into the opticocarotid recess and should not be fractured.

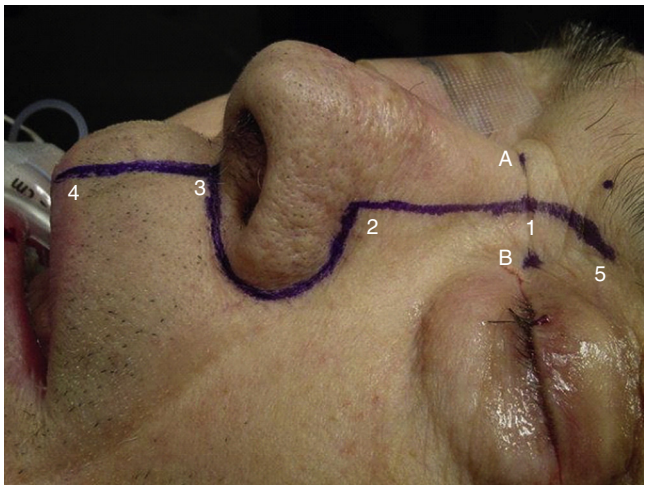

Fig. 106.3. Lateral rhinotomy incision *(1,2,3)* and its extensions (*4* and *5*). A temporary tarsorrhaphy protects the ipsilateral globe. The basic lateral rhinotomy incision is outlined by connecting three surface points. The first point *(1)* is marked halfway between the nasion *(A)* and the medial canthus *(B)*. The second point *(2)* is where the alar crease begins, and the third point *(3)* is at the base of the columella. The basic incision provides adequate exposure for a medial maxillectomy. The basic incision may be extended to include a lip splitting extension *(4)* or a "Lynch" type extension *(5)* if further exposure is necessary. The extended incision provides adequate exposure for a total maxillectomy.

Surgical Technique

1. Soft tissue approaches
   a. Lateral rhinotomy
      - The *lateral rhinotomy* is the standard incision for performing a medial maxillectomy (Fig. 106.3).
      - Elevation of the soft tissues of the cheek is done in a subperiosteal plane over the maxilla and around the inferior orbital nerve (Fig. 106.4A).[6]
      - The attachment of the medial canthal tendon to the nasal bone is released.
      - The periorbita is elevated over the medial orbital wall exposing the lacrimal crest, the lamina papyracea, and the frontoethmoidal suture. This suture serves as a landmark for the position of the floor of the anterior cranial fossa and, when followed posteriorly, leads to the anterior and posterior ethmoidal foramina.
      - The anterior and posterior ethmoidal arteries are cauterized with the bipolar electrocautery, clipped or ligated, and transected (see Fig. 106.4B).
      - The optic nerve is located 4 to 5 mm posterior to the posterior ethmoidal artery.
      - The orbital floor should be dissected as far laterally as the inferior orbital fissure.
      - The lacrimal sac is identified in its fossa between the anterior and posterior lacrimal crests.
      - If the lacrimal duct is transected, the lacrimal sac should be marsupialized into the nasal cavity to provide adequate drainage of the lacrimal system and to prevent stenosis and postoperative epiphora (see Fig. 106.4C).
   b. Midfacial degloving
      - The midfacial degloving approach requires a basic level of proficiency and understanding of closed rhinoplasty incisions.
      - It involves a complete transfixion incision of the membranous septum.
      - This is joined endonasally with a bilateral intercartilaginous incision, with soft tissue elevation over the nasal dorsum as far superior as the nasal root. A gingivobuccal incision extends bilaterally across the midline to both maxillary tuberosities laterally.
      - The nasal skeleton is therefore "degloved" from overlying soft tissues as far laterally as the pyriform aperture.
      - Subperiosteal dissection is continued cephalad over the anterior wall of both maxillae to the level of the inferior orbital rims.
      - The dissection joins the nasal degloving using sharp dissection over the pyriform aperture attachments.
   c. Osteotomies and resection
      - *Osteotomies* are done as shown in Fig. 106.4D, and the anterior wall of the maxillary sinus above the level of tooth roots and medial to the infraorbital nerve is removed. Lateral to the infraorbital foramen, the anterior wall antrostomy may be enlarged to expose the zygomatic recess of the antrum. Resection of the lateral nasal wall begins with an inferior osteotomy along the floor of the nose below the attachment of the inferior turbinate, starting at the pyriform aperture, and carried posteriorly to the posterior maxillary wall.
      - With the orbital contents retracted laterally and protected with a malleable brain retractor, the lamina papyracea is identified and, if necessary, resected.
      - A complete sphenoethmoidectomy is done, staying below the level of the frontoethmoidal suture to avoid injury to the floor of the anterior cranial fossa.
      - The superior attachment of the middle turbinate is then transected along the roof of the nose.
      - Posteriorly, the lateral nasal wall osteotomies are connected with right-angled scissors behind the turbinates. The specimen is thus delivered and examined for adequacy of the margins using frozen section control.
      - If the tumor involves the nasal septum, it should be included in the resection specimen by adding appropriate septal cuts to allow for tumor-free margins.
   d. Closure
      - Closure is begun by reattachment of the medial canthal tendon to the nasal bone in its anatomic position.
      - Meticulous multilayered closure of the lateral rhinotomy is performed and usually results in excellent healing and acceptable postoperative appearance (see Fig. 106.4E).
      - If a sublabial approach is done, the mucosal incisions are closed with absorbable suture.
      - Adequate nonadherent nasal packing may be left in place for 1 to 2 days.

Common Errors in Technique

- Failure to properly drain the lacrimal sac after transecting the nasolacrimal duct
- Failure to properly reattach the medial canthal ligament
- Excessive traction on the infraorbital nerve leading to numbness of the cheek
- Failure to properly execute a complete sphenoethmoidectomy with adequate drainage and ventilation to avoid recurrent sinusitis

POSTOPERATIVE PERIOD

Postoperative Management

- Overnight recovery to observe for bleeding, CSF leak, or orbital complications
- Pain management

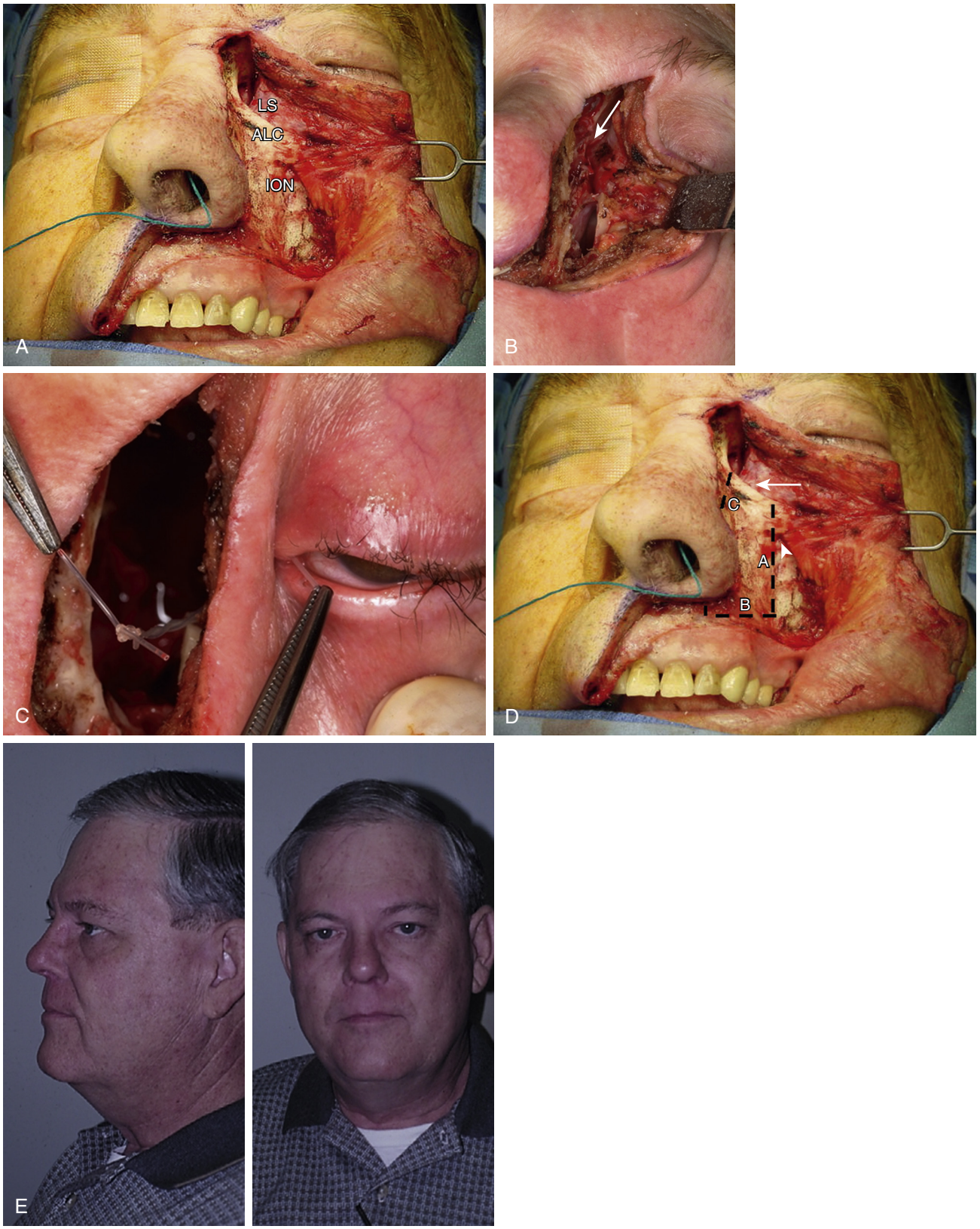

Fig. 106.4. Medial Maxillectomy. **A,** Elevation of the soft tissues of the cheek is done in a subperiosteal plane over the maxilla and around the inferior orbital nerve *(ION)*. The periorbita is elevated over the anterior lacrimal crest *(ACL)* to expose the lacrimal sac *(LS)*. **B,** Dissection of the medial periorbita over the lamina papyracea reveals the anterior ethmoid artery *(arrow)* at the level of the frontoethmoid suture line, which marks the level of the anterior cranial floor. The artery is coagulated by bipolar electrocautery, clipped or ligated, then transected. **C,** After the lacrimal sac is transected, it is marsupialized into the surgical cavity as a dacryocystorhinostomy. Silicone stents are placed through the upper and lower canaliculi and brought into the nasal cavity to prevent postoperative epiphora. These stents are removed in about 3 to 6 months. **D,** Osteotomies: *(A)* vertically medial to the infraorbital foramen *(arrowhead)*, *(B)* horizontally above the level of tooth roots and into the pyriform aperture, and *(C)* obliquely along the nasomaxillary suture line. If the lateral nasal wall is to be resected, the lacrimal sac *(arrow)* is transected and marsupialized into the nasal cavity. **E,** Postoperative appearance of a patient who had lateral rhinotomy incision.

- Elevate the head of bed 30 degrees to reduce postoperative swelling and bleeding.
- Patient to avoid strenuous activity
- Broad-spectrum antibiotics for 24 hours
- Nasal pack (if placed) to be removed within 24 to 48 hours
- Liberal saline nasal irrigation to minimize postoperative crusting

Complications (See Section on Operative Risk for Prevention)

- Postoperative bleeding
- Cheek or dental numbness from injury to the infraorbital nerve
- Orbital complications may include
  - Corneal injury during the procedure
  - Epiphora due to nasolacrimal duct injury or stenosis
  - Telecanthus from failure to reattach the medial canthal tendon in its anatomic location if detached
  - Orbital hematoma from the anterior or posterior ethmoidal arteries
  - Extra-ocular muscle swelling or injury may cause postoperative diplopia.
  - Optic nerve injury
- Skull base injury with CSF leak and risk of meningitis

Alternative Management Plan

Alternative management plan for patients who are not good surgical candidates will depend on the pathology. Benign and asymptomatic lesions may be observed for some time. Vascular lesions with repeated epistaxis may be managed with palliative embolization, coiling, or other endovascular interventional techniques. Malignant tumors can be managed with palliative radiation or chemotherapy.

Evidence-Based Medicine Question

Medial maxillectomy can be performed through an entirely endonasal endoscopic approach in well-selected cases with good outcomes: True or False

Answer: True

The lateral rhinotomy has been shown to be the gold standard for performing an adequate and safe resection of sinonasal tumors involving the nasal cavity, nasal septum, lateral nasal wall, and paranasal sinuses with significantly lower recurrence rates compared to other more limited approaches. (1) There has been an ongoing debate about the efficacy of endonasal endoscopic techniques in management of sinonasal tumors, particularly those that are malignant. Evidence suggests, however, that in carefully selected cases that predominantly involve the medial maxillary wall, the oncologic outcomes are equal to a similar procedure performed through a lateral rhinotomy (2).

Editorial Comment

Whether visualization is accomplished through a lateral rhinotomy or endoscopically using an endonasal corridor, the principals of the procedure are the same. As clearly outlined in this well-written chapter, removal of the medial maxillary wall, inferior turbinate, and the lateral nasal wall in carefully selected patients is associated with excellent oncologic outcomes with modest aesthetic impact. Additionally, this approach can be combined with both endoscopic and open craniofacial approaches to achieve an oncologically sound resection.

Beyond its use in oncology, increasing the endoscopic medial maxillectomy is used in the treatment of benign tumors and inflammatory conditions. Classically described for inverted papilloma of the medial maxillary wall, an endoscopic medial maxillectomy can provide both access for the complete removal of the soft tissue component of this tumor as well as remove the bony attachment site. Based upon the success of this procedure for this pathology, it is now used in a variety of benign tumors of the maxillary sinus and access to the pterygopalatine and infratemporal fossa.

An endoscopic medial maxillectomy is also used in recalcitrant maxillary sinusitis, typically when there is a significant disruption of mucociliary clearance. Because of its superior location in relation to the remainder of the maxillary sinus, a middle meatal antrostomy is dependent upon mucociliary clearance to clear secretions and to be effective. In conditions such as cystic fibrosis and primary ciliary dyskinesia where cilia are ineffective, a standard middle meatal maxillary antrostomy has limited effectiveness. In contrast, an endoscopic medial maxillectomy minimizes pooling of secretions and inflammatory debris in the floor of the maxillary sinus, allowing for clearance by nasal saline irrigations. When used for inflammatory pathology, maintaining the anterior one-third of the inferior turbinate is advocated to prevent empty nose syndrome.

The medial maxillectomy is an increasingly versatile surgical intervention for a variety of pathology. Understanding the anatomy and surgical techniques of this procedure is critical for head and neck oncologic surgeons, rhinologists, and skull base surgeons.

Eric W. Wang

Access the review questions online at http://www.expertconsult.com



REFERENCES

1. Myers EN, Fernau JL, Johnson JT, et al. Management of inverted papilloma. Laryngoscope 1990;100(5):481–490.
2. Hanna E, DeMonte F, Ibrahim S, et al. Endoscopic resection of sinonasal cancers with and without craniotomy: oncologic results. Arch Otolaryngol 2009;135(12):1219–1224.
3. Gomaa MA, Hammad MS, Abdelmoghny A, et al. Magnetic resonance imaging versus computed tomography and different imaging modalities in evaluation of sinonasal neoplasms diagnosed by histopathology. Clin Med Insights Ear Nose Throat 2013;6:9–15.
4. Hanna E, Vural E, Prokopakis E, et al. The sensitivity and specificity of high-resolution imaging in evaluating perineural spread of adenoid cystic carcinoma to the skull base. Arch Otolaryngol 2007;133(6):541–545.
5. DeMonte F, Hanna E. Transmaxillary exploration of the intracranial portion of the maxillary nerve in malignant perineural disease. Technical note. J Neurosurg 2007;107(3):672–677.
6. Vural E, Hanna E. Extended lateral rhinotomy incision for total maxillectomy. Otolaryngology 2000;123(4):512–513.

REVIEW QUESTIONS

1. Medial maxillectomy is indicated in resection of the following
   a. Tumors of the lateral nasal wall
   b. Tumors of the nasal septum
   c. Tumors of the medial maxillary sinus
   d. All of the above

2. Medial maxillectomy can be achieved through which of the following approaches?
   a. Lateral rhinotomy
   b. Facial degloving
   c. Endoscopic endonasal
   d. All of the above

107 Complete Maxillectomy

Adam Zanation

INTRODUCTION

Both benign and malignant tumors may originate within or around the maxillary sinus and hard palate. These tumors may arise from the epithelial surfaces of the oral cavity (hard palate or alveolar ridge) or the sinonasal mucosa (within the maxillary sinus or lateral nasal wall). Tumors that involve the maxillary sinus can also arise from adjacent structures such as the skin, orbit, lacrimal system, infratemporal fossa, ethmoid sinuses, and anterior skull base. Squamous cell carcinoma is the most common malignant histology encountered in the maxillary sinus.[1] The second most common malignant pathology is a variety of adenocarcinomas.[1]

The primary treatment paradigm for all tumors of the maxillary sinus involves surgical resection, once appropriate clinical evaluation and staging have been completed. The exceptions to this management plan are lymphomas or plasmacytomas, which are very radiosensitive tumors and do not require surgery. In addition, symptomatic or rapidly growing benign tumors may often need surgery but do not require obtaining wide margins or having radical resection as a surgical goal. Regarding surgical planning, complete removal of the tumor with negative margins is the goal, but one must also consider concurrent reconstructive planning. Reconstruction depends on the extent of the defect, but the mainstays of reconstructive techniques include palatal obturator or vascular tissue reconstruction. After primary surgery, malignant tumors of the maxillary sinus often undergo postoperative radiation or chemoradiation.

KEY OPERATIVE LEARNING POINTS

1. Surgical goals depend on the tumor histology and tumor location.
2. Types of maxillectomy include:
   a. Infrastructure (mainly used in the treatment of tumors of the oral cavity that involve the maxillary sinus)
   b. Superstructure (mainly used to treat tumors of the anterior facial skin without palate involvement or rarely tumors from the lacrimal system/orbit)
   c. Medial (mainly used to treat tumors from the nasal cavity that come from or extend to the lateral nasal wall such as inverted papillomas)
   d. Complete (primarily used to treat tumors that originate within and fill the maxillary sinus). This chapter will focus on a complete maxillectomy with obturator placement.
   e. Complete with orbital exenteration
   f. Extended (complete that also includes significant adjacent structures such as facial skin, anterior skull base, and/or infratemporal fossa)
3. Accurate preoperative assessment of the extent of disease is important, and the complementary information provided by computed tomography (CT) and magnetic resonance imaging (MRI) should not be underestimated.

PREOPERATIVE PERIOD

History

May present with primary symptoms including but not limited to nasal congestion, lesion of the palate or alveolar ridge, epistaxis, facial numbness, abnormal tearing diplopia, or loss of vision. Patients may present with nodal metastasis (<10% of time), although the metastasis rate for squamous cell carcinoma of the alveolar ridge and hard palate may be as high as 35%. Symptoms of advanced disease include trismus, airway compromise, complete loss of vision or ophthalmoplegia, and lower cranial nerve palsies.

Physical Examination

1. A complete examination of the head and neck must be carried out. Special attention should be paid to:
   a. Examination of the oral cavity including the dentition, hard palate, buccal mucosa, and soft palate mobility. Loss of sensation of the palate is an important finding, since it would suggest either perineural spread into the palatine canals or involvement of the pterygopalatine fossa. Trismus is associated with invasion of the infratemporal fossa.
   b. Cranial nerve examination: Special attention should be paid to cranial nerves III, IV, V, and VI, with a focus on testing extraocular motion and infraorbital nerve function.
   c. Eye examination: Hyperglobus may represent lesion expansion and not necessarily invasion; however, severe extra ocular muscle restriction and loss of visual acuity are almost always due to direct intraconal invasion. Abnormal tearing can be due to invasion of the lacrimal system or invasion of the pterygopalatine fossa by disruption of Vidian nerve supply.
   d. Examination of the neck: The rate of metastasis to the cervical lymph nodes is generally low for squamous cell carcinoma (10% to 35%) but can be present. Usually levels 1 or 2 and facial nodes are the levels most commonly involved.
   e. Facial skin changes: Invasion through the anterior wall of the maxillary sinus represents advanced cancer and is important for postsurgical reconstructive considerations.
2. Nasal endoscopy is also warranted to examine the floor of the nose (nasal side of the hard palate) and the lateral nasal wall. Additionally, involvement of the ethmoid can be identified in the middle meatus. If there is a tumor present in the nasal cavity, endonasal biopsy may be warranted.

Imaging

Accurate preoperative assessment of the extent of disease is important, and the complementary information provided by CT and MRI should not be underestimated. This will drive the extent of any planned surgery and should be reviewed with the

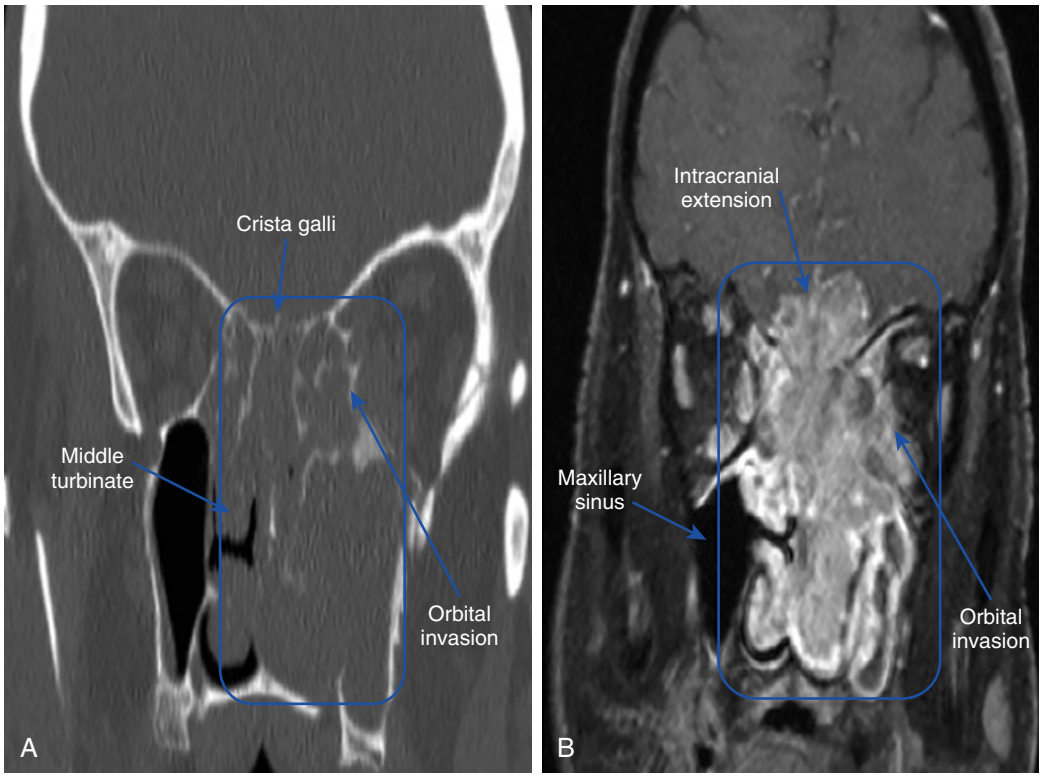

Fig. 107.1. Radiographic imaging of a maxillary sinus and skull base neoplasm. A, Coronal computed tomography demonstrating bone destruction of the medial maxillary wall and ethmoid cavities. Note the limited information obtained on intraorbital or intracranial extent of disease. **B,** Coronal magnetic resonance imaging of the same patient, showing much better soft tissue differentiation, where the full extent of the spread of the cancer into the orbit and intracranial cavity can be appreciated.

patient so he or she understands the extent of the operation, as well as any functional consequences that should be expected, such as oral competency, eye involvement, potential for vision loss, or hypoglobus.

1. CT (Fig. 107.1A): Defines the bony boundaries as well as bone invasion of the palate and posterior wall of the maxillary sinus or orbital floor
   a. Ohngren's line (Fig. 107.2): An imaginary line drawn from the medial canthus of the eye to the angle of the mandible. It divides the maxillary sinus into an anterior/inferior portion and a posterior/superior portion. This line helps give relative prognostic value (with anterior/inferior being better) as well an idea of adjacent structures at risk for potential spread.
2. MRI (see Fig. 107.1): Delineates affected soft tissue and provides information on perineural spread, characteristic of some malignant neoplasms. This study provides the best information regarding the orbit, skull base, intracranial extension, and anterior facial skin.
3. Regional and distant staging: Usually completed with either contrasted CTs of the neck and chest or positron emission tomography (PET) CT.
4. Angiography: Rarely indicated—only needed when there is a presumed vascular malformation or if the tumor has invaded the carotid artery on the primary site imaging

Indications for Surgery

1. Malignant tumors
2. Benign tumors that are either symptomatic or growing
3. Symptom relief

Contraindications to Surgery

1. Patient factors: Inability to undergo general anesthesia or have major blood loss
2. Unresectable tumors (unless palliative surgery indicated)
3. Diffuse distant metastasis
4. Lymphomas, plasmacytomas, or other tumors that are highly radiation or chemotherapy sensitive

Preoperative Preparation

1. Full staging evaluation (see "Imaging" section)
2. Presentation to a multidisciplinary tumor board
3. Reconstructive considerations
   a. Preoperative consultation with prosthodontist (obturator fitting)
   b. Head and neck microvascular surgeon for consideration of reconstruction using a free flap
4. Full informed consent: In particular, a full discussion of risks and postoperative expectations should be had with the patient. Importantly, hypothetical, intraoperative possibilities need to be discussed with the patient and appropriately added to the informed consent including but not limited to: more involvement of the eye than what is seen in imaging, involvement of the anterior facial skin, or potentially positive lymph nodes when performing neck exposure for microvascular anastomosis requiring a neck dissection. If the patient's wishes in these situations are well documented and known prior to the operation, intraoperative decisions including more or less extensive surgical dissection can be made much more swiftly if such situations are encountered.

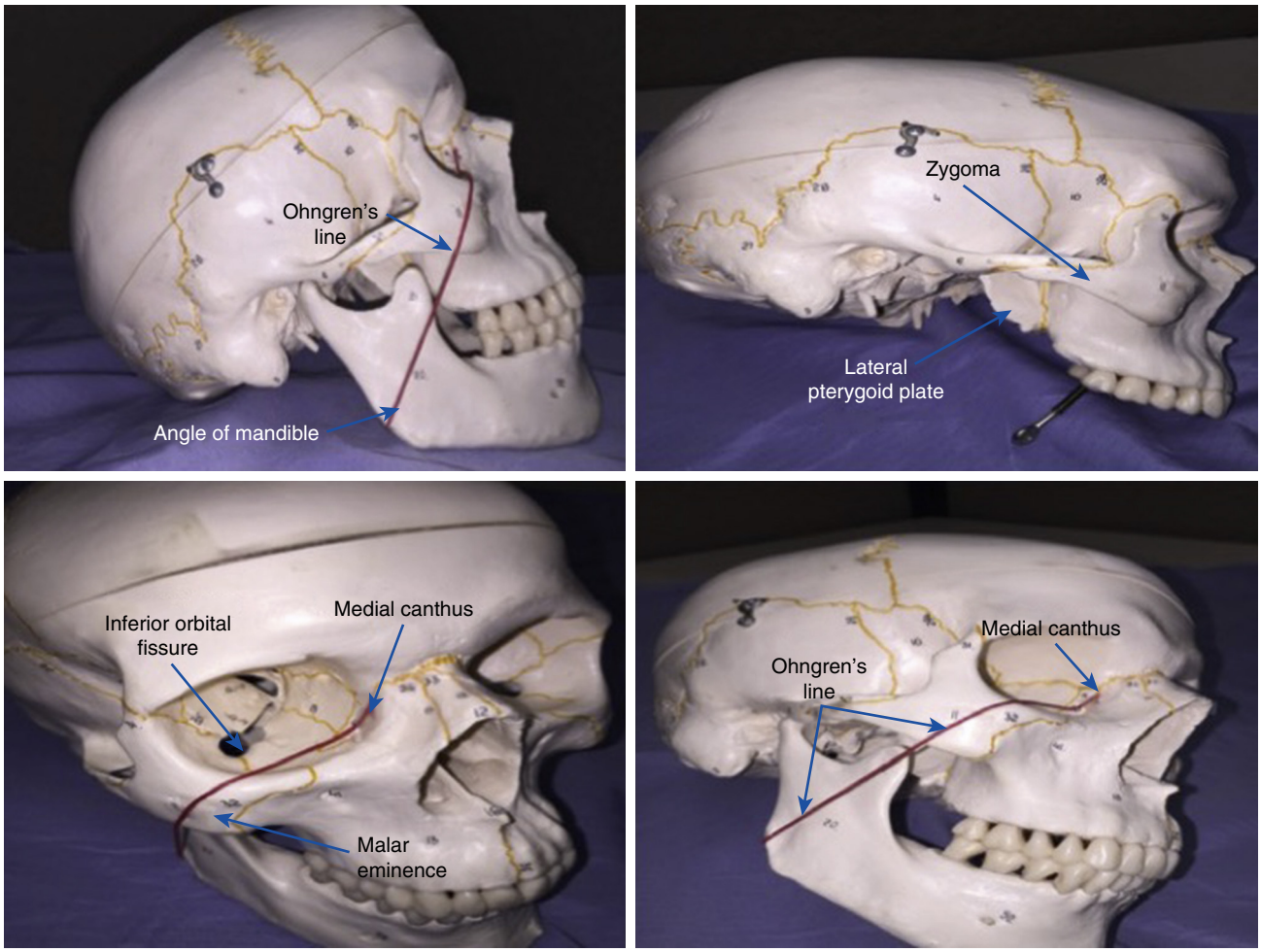

Fig. 107.2. Ohngren's line. A line defined from the medial canthus of the eye to the angle of the mandible. It divides the maxillary sinus into an anterior/inferior portion (better prognosis) and a posterior/superior portion (worse prognosis).

5. Preoperative laboratory evaluation: Complete blood count (CBC), coagulation markers (PTT and PT/INR), complete metabolic panel (CMP). Although large volume blood loss is rare in these cases, all patients are typed and screened for this possibility.
6. Plan for airway management and, if complex, a preoperative discussion with the patient and the anesthesia team about options and an intraoperative action plan should an emergent situation arise. For most maxillary tumor surgery, the patient can be managed with an oral intubation and extubation. Exceptions to this rule may include patients with severe trismus, patients who require large pharyngeal or soft palate resections, and patients that will need free flap reconstructions of the palate defect. These patients may require an awake or elective tracheostomy for safe airway management.
7. Need for preoperative embolization is rare but would be necessary for vascular tumors such as arteriovenous malformations (AVMs) or juvenile nasopharyngeal angiofibromas (JNAs) that involve the maxillary sinus. The internal maxillary artery is the primary blood supply in this area; however, the inferolateral trunk of the carotid artery can also provide blood supply into the infratemporal fossa. Balloon test occlusion for carotid sacrifice is very rarely indicated, and there is virtually no role for carotid resection in the setting of high-grade epithelial malignancy.

OPERATIVE PERIOD

Anesthesia

See the previous section on airway planning. General anesthesia is standard. Paralysis is generally acceptable unless a parotidectomy or neck dissection is needed with the maxillectomy, in which case it would be contraindicated. We try to maintain the patient with normal blood pressures, as there is no need for planned hypotension. We also try to be thoughtful about the fluid intake over the course of these operations, since they can be lengthy. If the operation is being done with an ET tube only, then the tube is taped to the side opposite the lesion.

Positioning and Intraoperative Setup

1. Either 180 degrees rotation (our preferred) or a little past 90 degrees to the side of the proposed maxillectomy. This removes the anesthesia team from the head and allows the surgical team to be on all sides of the head, allowing for better sight lines and retraction.
2. Tarsorrhapy sutures are generally placed to protect the eyes.
3. The neck is always prepped into the field in case proximal vessel control or neck dissection is needed. The thigh is prepped for taking a skin graft.
4. Sterile preparation of the surgical field is always done with betadine, since we are prepping around the eyes. Minimize

exposure of betadine solution to the eyes, and at the end of the case, the eyes must be washed out with balanced salt solution.
5. Incisions are marked with the natural skin creases in mind, along with the planned needs for exposure.
6. Perioperative antibiotic prophylaxis: Standard first- or second-generation cephalosporin or penicillin-based antibiotics are given 30 minutes before the incision. They are continued for 24 hours after the operation. If the patient is allergic to penicillin, clindamycin is generally used.
7. Monitoring: Usual general anesthesia monitoring

Instruments and Equipment to Have Available

- Soft tissue and neck dissection set
- Small bone saws
- Side cutting pencil drill
- Bone chisels
- Dental extraction set
- Oral retractors
- Monopolar and bipolar cautery
- Endoscopic equipment: 0- and 30-degree Hopkins-rod nasal endoscopes and endoscopic tower should be available

Key Anatomic Landmarks

En bloc resection and achieving negative margins remain a steadfast principles in oncologic surgery and are often the key to the best patient outcomes. However, achieving this goal can be difficult within the orbit and along the periorbita, if the cancer has extended either intraconally or posteriorly into the infratemporal fossa. As outlined later in this chapter, a keen understanding and awareness of crucial landmarks in the maxillectomy approach allow for an easier dissection when working with advanced tumors.

Prerequisite Skills

Head and neck oncologic and/or skull base training

Operative Risks

Blood loss, inherent risk with general anesthesia, ocular risks (including possible vision loss or diplopia), facial numbness (other than in the V2 distribution that is often expected), and parapharyngeal carotid injury are risks but rare.

Surgical Technique

1. The facial incisions are carried down to bone with the assistance of electrocautery (if there is no anterior soft tissue invasion present).
   Incision types include:
   a. Sublabial incision only
   b. Sublabial incision with partial or full degloving incision
   c. Lateral rhinotomy incision. It is the preference of the senior author to make our nasal incision between the dorsal nasal subunit and the lateral nasal wall (Fig. 107.3).
   d. Extended lateral rhinotomy incisions (see Fig. 107.3)
2. Fully expose the anterior bony surface of the midface, inferior and lateral orbit, and buccal space. Dissect out V2 and obtain neural margins.
3. Make an incision along the piriform aperture into the intranasal cavity, and retract the nose to the opposite side.
4. Make palatal incisions and obtain intraoral margins. If the soft palate is being salvaged, then dissect it free from the hard palate so there is full access into the nasopharynx. Control bleeding from palatine vessels with bipolar electrocautery.
5. Dissect the periorbita away from the orbital rim and from the orbital floor. Closely examine the orbital floor and periorbita to ensure that the cancer has not invaded into these structures.
6. Using a 1-mm side cutting pencil grip drill and copious irrigation, the anterior and periorbital osteotomies can be made. These osteotomies usually extend from the superior piriform aperture through the orbital rim for a complete maxillectomy. A metal retractor is used to protect the eye during dissection. At the same time as the globe is retracted superiorly, a thin, sharp osteotome is used to connect the medial and lateral orbital rim osteotomies extending posteriorly into the orbit freeing the floor of the orbit.
7. Using the same pencil drill, an osteotomy is made from the lateral orbit, through the rim, and extending across the malar process or occasionally through the zygomatic arch. This osteotomy extends posteriorly toward the pterygoid plates and all the way through the lateral buttress.
8. Using a thin reciprocating saw, the palatal osteotomy is made in a posterior to anterior direction and subsequently extended into the anterior nasal cavity.
9. At this point, the last bony attachment is at the pterygoid plates. The standard way to remove the plates is by using a curved osteotome placed behind the plates and angled up into the infratemporal fossa. This technique has two limitations, including lack of proximal control of the internal maxillary artery and inadvertent fracture at the level of the pterygopalatine fossa instead of behind the plates. Given these limitations, it is generally recommended that the osteotomy should be made from the lateral position. In this approach, the mandible is initially retracted inferiorly and posteriorly. Using blunt dissection, the pterygoid plates and muscles can be identified, and often the internal maxillary artery can be palpated and directly controlled with a hemostat if necessary. The junction of the fused portion of the pterygoid plates can be palpated at the base of the middle cranial fossa. Using a sharp straight osteotome, this fused portion can be fractured from the underside of the sphenoid bone, and the entire maxilla can be rocked medially and inferiorly.
10. The infratemporal fossa is now exposed so that the internal maxillary artery can be fully controlled and the pterygoid muscles can be dissected from the bone with bipolar electrocautery, which allows for freeing of the entire maxilla and pterygoid plates from the infratemporal fossa. V3 can often be identified, and, if needed, neural margins can be taken from the skull base.
11. Using large curved scissors, the remainder of the medial maxillary wall is cut posteriorly from the medial orbital osteotomy, across the duct and inferiorly toward the torus tubarius, and the entire specimen is removed.
12. Intraoperative soft tissue margins are then sent for frozen section examination, and bleeding is subsequently controlled.
13. A medium-thickness split thickness skin graft is taken from the thigh, placed over the exposed buccal contents, and draped posteriorly into the infratemporal fossa defect.
14. Gauze packing is placed and the temporary obturator (Fig. 107.4) is placed and secured with wires and screws. The facial incisions are then closed in several layers, with care taken to reapproximate the orbicularis oris and oculi.

Common Errors in Technique

- Obtaining insufficient and superficial bony margins (which should extend at least 1 to 1.5 cm from involved tumor)
- Incomplete removal of the posterior wall and ptyergoid plates is a common error in dissection.

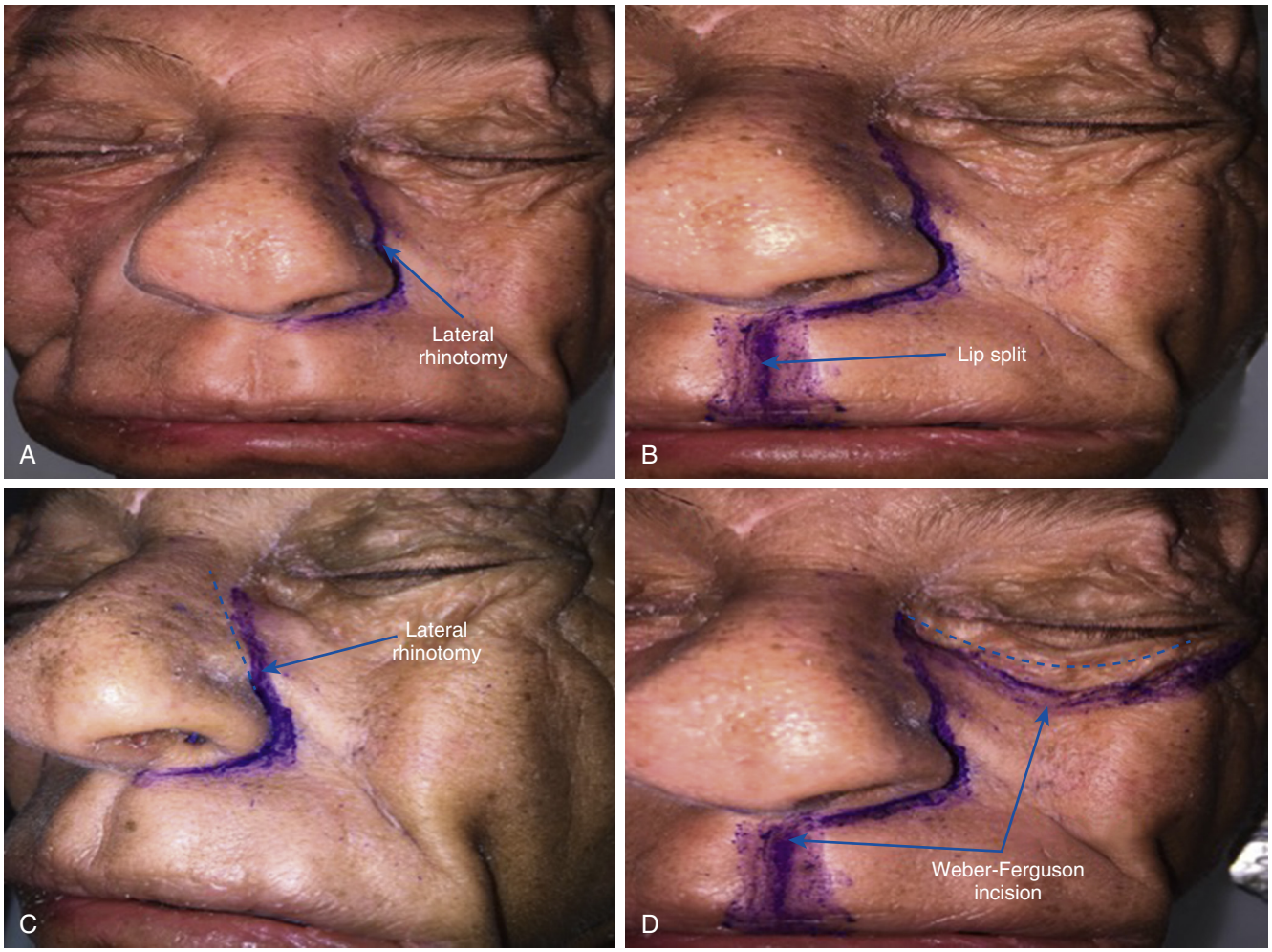

Fig. 107.3. Facial incisions for complete maxillectomy. **A** and **C,** Lateral rhinotomy incision, **B,** lateral rhinotomy with lip split incision and **D,** modified Weber-Ferguson incision. Several modifications of the incisions can be made: **B** is a lip-splitting extension with dart, and the dart provides some potential benefits for lip notching. **A** and **C** are the senior authors' preferred lateral rhinotomy incisions, where instead of being in the nasolabial crease (purple marking), the incision is carried up onto the nose at the junction of the dorsum and the lateral nasal wall *(dashed blue line).* This has potential cosmetic benefits, in addition to placing the incision over the nasal bones, an area that will have less contact with the intranasal air containing spaces. **D** is the periocular extension (a Weber-Ferguson incision) that allows for lateral and orbital access. In the elderly, such as in this cadaveric specimen, the author makes this incision at the inferior orbital rim; however, in a younger patient, a subciliary or transconjunctival incision is preferred *(dashed blue line).*

- Underestimating the difficulty in dissecting and clearing tumor margins if the lesion has periorbital or ethmoid sinus invasion
- If microvascular free flap reconstruction with bony palatal repair is indicated, then the coronoid process is routinely removed to prevent bony fixation of the mandible to the repaired palate.

POSTOPERATIVE PERIOD

Postoperative Management

Fastidious wound and eye care, dietary restrictions including either a clear liquid diet or strict NPO with a nasogastric tube if a free flap used for reconstruction, and early ambulation toward normalization take precedence. DVT prophylaxis is routinely used during the postoperative hospital course, given increased risk for venous thromboembolism secondary to relative immobilization. Lastly, beginning trismus therapy early in the postoperative period is important, since the muscles of mastication can scar during the healing period.

Complications

1. Wound complications from facial incisions
2. Free flap failure
3. Corneal ulceration
4. Bleeding or hematoma formation
5. Vision loss and/or diplopia

This requires emergent ophthalmology consultation to evaluate for elevated pressures or optic neural loss. Full visual field testing with an evaluation of extraocular muscles is required. If orbital pressures are more than 30 and the patient has loss of visual acuity, an emergent canthotomy and cantholysis may be warranted. Additionally, imaging may be required to evaluate for a retrobulbar hematoma and plan for any needed decompressive operations.

DISCUSSION

Evidence-Based Medicine Question

What effect do surgical margins have on outcomes following resection of sinonasal malignancy?

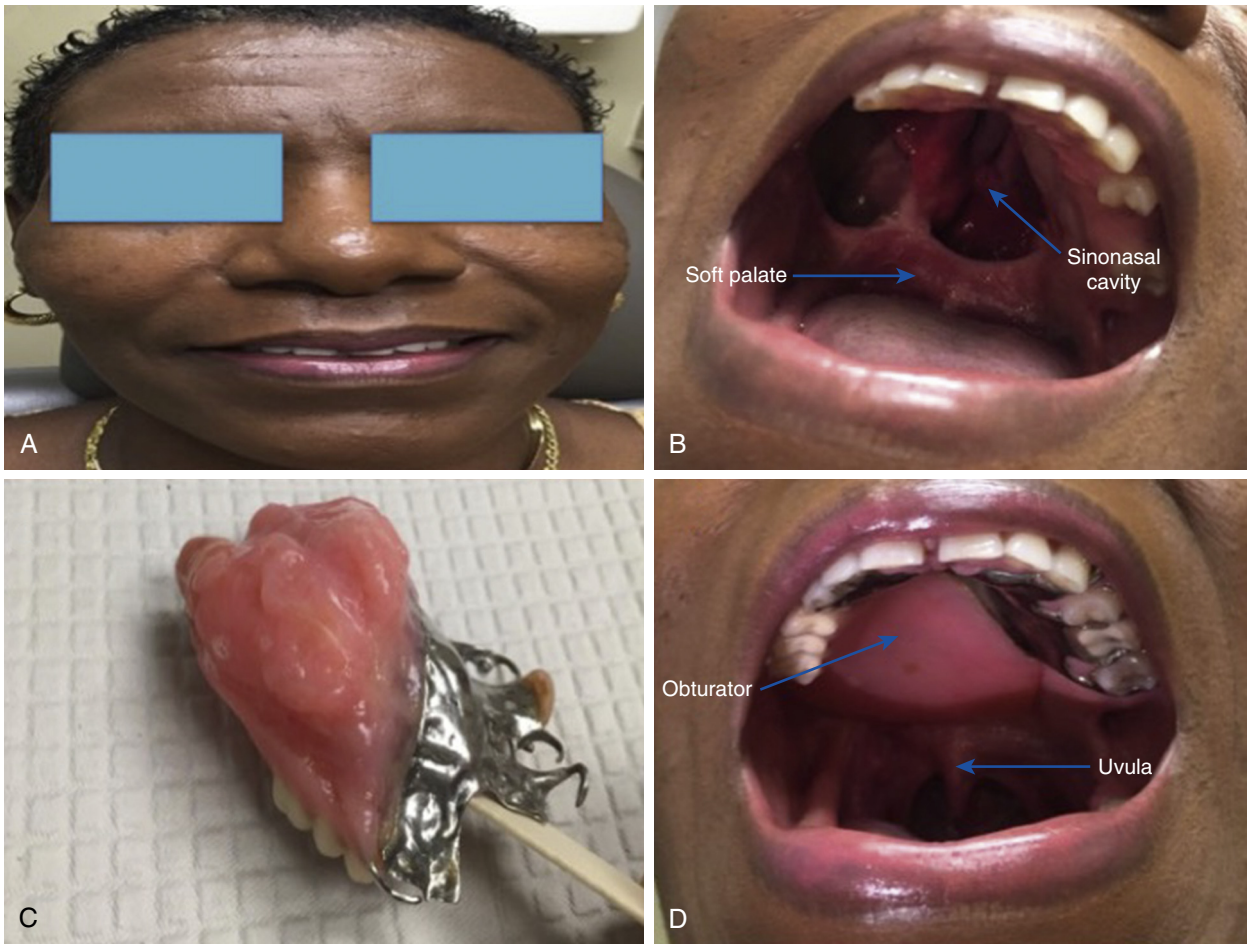

Fig. 107.4. Healed complete maxillectomy defect with obturator reconstruction. A, Healed frontal view of a patient 5 years after a Weber-Ferguson incision and complete maxillectomy. Note the good alignment of the nose and lip and the dental rehabilitation that the final obturator gives. **B,** Intraoral view of complete maxillectomy defect with obturator removed. **C,** View of the actual obturator. **D,** Intraoral view of the same patient with the obturator in place.

One of the central principles of oncologic surgery is that tumor resection must be complete at both the microscopic and macroscopic level, which is generally achieved intraoperatively via obtaining frozen sections to confirm negative surgical margins. With regard to sinonasal and anterior skull base malignancies, obtaining surgical margins can be technically challenging and sometimes may not be feasible given the proximity of critical neurovascular structures. Subsequently, it has been shown that in 30% and 24% of sinonasal neoplasms resected via open and endoscopic approaches, respectively, residual microscopic disease has been left due to the proximity to such structures as the internal carotid artery and optic nerve.[2] However, in these situations, it is important to understand the effect of surgical margins on prognosis and outcome following the resection of a sinonasal malignancy, including those requiring a maxillectomy approach.

Although the literature is generally consistent on the concept that leaving residual gross cancer during resection will result in local recurrence and increase overall mortality rate, findings regarding the role between positive microscopic margins and decreased survival rates historically remain fairly equivocal.[3,4] Recently, in a large, multiinstitutional retrospective review from the International Collaborative Study Group, it was found that the status of the surgical margins was a critical predictor for overall, recurrence-free, and disease-specific survival. Specifically, a statistically significant decrease in 5-year survival was observed in the studied population, when comparing patients with negative margins with those with positive surgical margins on histology. In another retrospective review from a single institution, Manjunath et al. showed that regional and distant recurrences were increased and disease-free survival was significantly decreased in patients with positive surgical margins compared with negative margins following resection of their sinonasal or anterior skull base malignancy.[5]

Conclusively, this central, oncologic tenet in head and neck surgery is crucial when approaching tumors requiring complete maxillectomy. Often requiring dissection of the face, sinonasal cavity, orbit, and anterior and middle cranial fossa, the complete maxillectomy is a technically challenging surgical approach, in which obtaining surgical margins can be equally difficult. Although we have delineated the significance of obtaining negative margins given its importance in patient outcomes, safe dissection and taking of circumferential margins in the complete maxillectomy approach may often not be feasible, given vital adjacent structures such as the optic nerve, globe, and internal carotid artery. Thus this element of the operation must be discussed at length with the patient, where the benefits and risks of obtaining surgical margins must be highlighted when discussing the procedure. With regard to the surgical technique in a complete maxillectomy, surgical margins must be obtained in a three-dimensional space, which often involves taking margins from varying forms of tissue. Lastly, as surgical margins often dictate long-term outcomes for these patients, its importance cannot be understated.

Editorial Comment

Preoperative imaging using both CT and MRI is invaluable in evaluating the patient for a total maxillectomy. As outlined by the authors, achieving negative surgical margins is critical for oncologic control and can be challenging in this anatomic site. Additionally, the surgery often results in a significant change in the patient's function in regard to oral competence and the potential for hypoglobus if the orbit is preserved. Accurate preoperative assessment of the extent of disease is important, and the complementary information provided by CT and MRI should not be underestimated.

Eric W. Wang

Acknowledgment

I would like to thank Satyan B. Sreenath, MD for his work on this chapter and figure production



Access the review questions and additional sources list online at http://www.expertconsult.com

REFERENCES

1. Banuchi V, Mallen J, Kraus D. Cancers of the nose, sinus, and skull base. Surg Oncol Clin North Am 2015;24(3):563–577.
2. Batra PS, Luong A, Kanowitz SJ, et al. Outcomes of minimally invasive endoscopic resection of anterior skull base neoplasms. Laryngoscope 2010;120(1):9–16.
3. Carrillo JF, Guemes A, Ramirez-Ortega MC, et al. Prognostic factors in maxillary sinus and nasal cavity carcinoma. Eur J Surg Oncol 2005;31(10):1206–1212.
4. Wong LY, Lam LK, Fan YW, et al. Outcome analysis of patients with craniofacial resection: Hong Kong experience. ANZ J Surg 2006;76(5):313–317.
5. Manjunath L, Derousseau T, Batra PS. Prognostic value of surgical margins during endoscopic resection of paranasal sinus malignancy. Int Forum Allergy Rhinol 2015;5(5):454–459.

REVIEW QUESTIONS

1. What is the most common malignancy encountered in the maxillary sinus?
   a. Adenocarcinoma
   b. Inverted papilloma
   c. Squamous cell carcinoma
   d. Esthesioneuroblastoma
   e. Mucosal melanoma

2. Which artery represents the primary arterial supply to the posterior maxilla?
   a. Ethmoidal artery
   b. Facial artery
   c. Internal maxillary artery
   d. Internal carotid artery
   e. Occipital artery

3. What is Ohngren's line?
   a. An imaginary line drawn from the nasion to the angle of the mandible
   b. An imaginary line drawn from the lateral canthus of the eye to the angle of the mandible
   c. An imaginary line drawn from the medial canthus of the eye to the body of the mandible
   d. An imaginary line drawn from the medial canthus of the eye to the angle of the mandible

ADDITIONAL SOURCES

Bentz BG, Bilsky MH, Shah JP, Kraus D. Anterior skull base surgery for malignant tumors: a multivariate analysis of 27 years of experience. Head Neck 2003;25(7):515–520.

Bhattacharyya N. Factors affecting survival in maxillary sinus cancer. J Oral Maxillofac Surg 2003;61(9):1016–1021.

Ganly I, Patel SG, Singh B, et al. Craniofacial resection for malignant paranasal sinus tumors: report of an International Collaborative Study. Head Neck 2005;27(7):575–584.

Spiro RH, Strong EW, Shah JP. Maxillectomy and its classification. Head Neck 1997;19(4):309–314.

108 Endoscopic Ethmoidectomy

Garret Choby, Stella E. Lee

INTRODUCTION

The decision to proceed with ethmoidectomy in the context of endoscopic sinus surgery (ESS) should be based on the patient's pathology, degree of symptoms, and response or lack of response to appropriate medical therapy. The goal is to eliminate chronic disease and restore function to the ethmoid sinuses and frequently to the frontal and maxillary sinuses, which can be secondarily infected or diseased because of obstruction in the anterior ethmoid air cells. Knowledge of the ethmoid sinus and its relationship to the orbit, skull base, anterior/posterior ethmoid arteries, and the frontal outflow tract is crucial to prevent complications. For patients with pansinusitis due to chronic rhinosinusitis (CRS), the endoscopic sinus surgeon should perform a complete ethmoidectomy by removing all ethmoid partitions in a mucosal sparing fashion. This allows for appropriate access for topical therapy and surveillance. A landmark-based approach is discussed in this chapter to perform endoscopic ethmoidectomy in a safe and effective manner.

KEY OPERATIVE LEARNING POINTS

1. Removal of the ethmoid bulla allows for identification of the lamina papyracea (medial orbital wall), which should be clearly identified in order to prevent injury to the orbit.
2. The basal lamella should be traversed in an inferior-medial fashion with the goal of identifying the superior turbinate and the skull base.
3. The junction of the skull base, medial orbital wall, and the anterior face of the sphenoid is the superior/lateral "corner" from which the dissection proceeds anteriorly along the skull base.
4. Careful study of the maxillofacial computed tomography (CT) scan should precede any surgical intervention. The key anatomic structures that should be identified include the following:
   a. Ethmoid bulla and relationship to the medial orbital wall
   b. The superior turbinate and relationship of the posterior ethmoid sinus to the skull base
   c. Identification of the anterior and posterior ethmoid arteries
   d. Height of the ethmoid sinus in relationship to the maxillary sinus to understand the slope and proximity of the skull base when performing ESS
   e. Anatomic variations such as Onodi cells and suprabullar cells

PREOPERATIVE PERIOD

History

1. History of present illness
   a. Primary symptoms most bothersome to the patient
      1) Identification of these symptoms allows for effective counseling of what surgery can and cannot achieve, thus framing patient expectations.
   b. Duration of symptoms
   c. Specific symptoms
      1) Nasal obstruction
      2) Hyposmia
      3) Facial pressure/pain
      4) Nasal discharge/postnasal drip
   d. Previous attempts at treatment including systemic antibiotic and steroid therapies, topical therapies, and surgery
2. Past medical history
   a. Prior management: Medical and surgical
   b. Medical illness
      1) Comorbidities
      2) Allergies
      3) Asthma/reactive airway disease
         a) Patients with reactive airway disease or asthma frequently have concomitant sinonasal disease. Surgery should be postponed until asthma is under good control and consultation with a pulmonologist is completed.
      4) Cystic fibrosis
         a) Similarly, planning for ESS in cystic fibrosis patients should be completed in consultation with a qualified pulmonologist comfortable managing the pre- and postoperative care of these patients.
         b) Perioperative antibiotics are usually necessary to prevent infectious complications in this patient group.
      5) Aspirin/nonsteroidal anti-inflammatory drug (NSAID) sensitivity
   c. Medications
      1) Anticoagulants/aspirin/NSAIDs
      2) Supplements that can increase the risk of bleeding

Physical Examination

1. Nasal endoscopy is completed in an office setting using a topical anesthetic and decongestant. Documentation should be made of any polyps, mucopurulent exudate, anatomic abnormalities including septal deviation, and any sinonasal masses. Use of 0-degree and 30-degree endoscopes can help fully visualize the sinonasal cavity. The classic endoscopic evaluation involves three "passes" of the endoscope.
   a. The first pass is along the floor of the nose with special attention paid to the inferior turbinate, inferior meatus, nasolacrimal duct, and nasopharynx (fossa of Rosenmuller and eustachian tube orifice).
   b. The second pass is toward the middle turbinate (MT), examining the middle meatus, ethmoid bulla, uncinate, lateral nasal wall, sphenoethmoidal recess, superior turbinate, and sphenoid os.
   c. The third pass is made (often with a 30-degree endoscope) to visualize superiorly toward the olfactory cleft.

Imaging

1. Maxillofacial CT scan
   a. A dedicated maxillofacial CT scan is a prerequisite for ESS. At our institution the scans are performed under a navigation protocol with at least 1-mm slice thickness

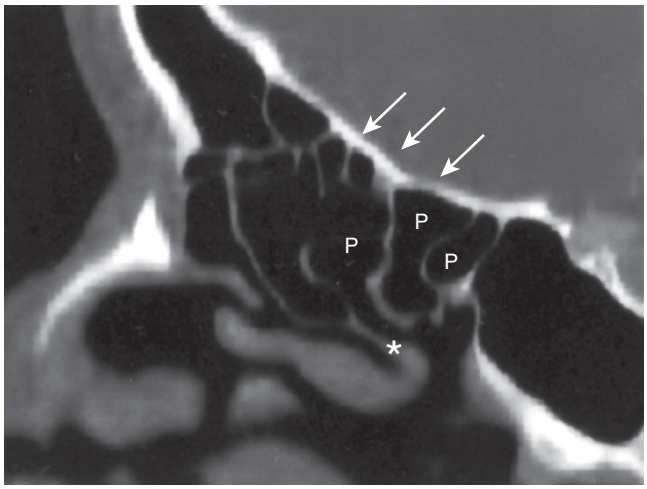

Fig. 108.1. This sagittal view of a CT scan demonstrates the slope of the skull base. Posterior ethmoid cells are marked with *P*. The basal lamella of the middle turbinate is marked with an *asterisk*.

and corresponding coronal and sagittal reformatting. These images can then be linked to conceptualize the sinus anatomy in three dimensions. Specific anatomic landmarks should be identified to prevent complications of cerebrospinal fluid (CSF) leak and orbital or vascular injury during endoscopic ethmoidectomy. Thus particular attention should be paid to these areas in preoperative CT evaluation and intraoperative dissection.

1) The skull base should be assessed for its height, thickness, and slope (Fig. 108.1). The roof of the ethmoid cavity tends to be thicker laterally and becomes thin medially near the lateral lamella of the cribriform plate. The Keros classification has divided the anatomic arrangement of the skull base based on the depth of the olfactory sulcus into type I (1 to 3 mm), type II (4 to 7 mm), and type III (8 to 16 mm), with increased depth representative of increased risk of skull base injury and subsequent CSF leak (Fig. 108.2).[1]
2) The anterior and posterior ethmoid arteries should be carefully inspected on CT for relative position to the skull base. Those that course in a mesentery inferior to the skull base are at greater risk of injury than those contained within the bony skull base (Fig. 108.3: anterior/posterior ethmoid arteries). The anterior ethmoid artery can be reliably identified on CT scan on coronal images just posterior to the globe (Fig. 108.4: CT anterior ethmoid artery).[1]
3) The medial orbital wall should also be closely examined for erosion or previous trauma that may pose a risk to the orbital contents. Frequently, there is posterior/superior pneumatization of a posterior ethmoid cell over the sphenoid (an Onodi cell), bringing this ethmoid cell close to the optic nerve and cavernous sinus/carotid.

2. In cases of skull base tumors or sinonasal malignancies, a skull base magnetic resonance imaging (MRI) with and without contrast may be indicated.
   a. MRI with contrast can help differentiate tumors from surrounding inflamed mucosa and inspissated secretions.
   b. This imaging modality also helps determine perineural spread of disease toward the skull base in malignancies such as adenoid cystic carcinoma.

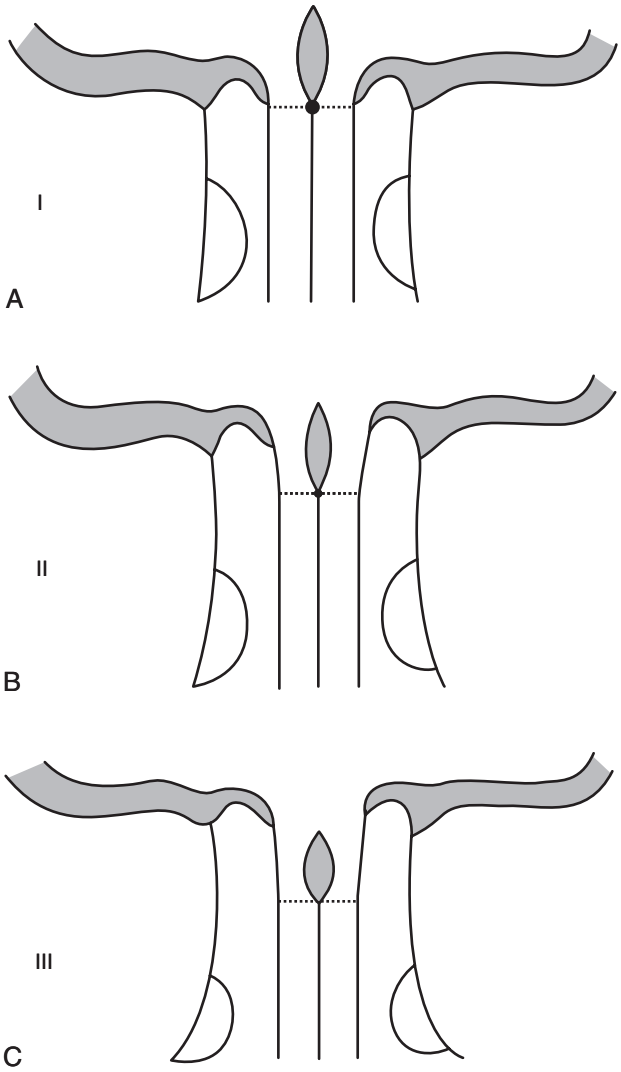

Fig. 108.2. Keros classification of the depth of the olfactory fossa. A, Keros type I—olfactory fossa is 1 to 3 mm in depth. **B,** Keros type II—olfactory fossa is 4 to 7 mm in depth. **C,** Keros type III—olfactory fossa is 8 to 16 mm in depth. *(Modified from Stammberger H: Functional endoscopic sinus surgery: the Messerklinger technique. Philadelphia, PA, BC Decker, St Louis, 1991, p 75).*

Indications

1. Patients selected for functional ethmoidectomy should demonstrate symptomatic and significant mucosal disease, causing anatomic obstruction. Other indications for endoscopic ethmoidectomy include mucocele formation or access to the other sinuses. Ethmoid mucoceles, which can cause erosion of the lamina papyracea and produce orbital symptoms such as proptosis and diplopia, are usually secondary to scarring from prior surgery or associated with hyperplastic mucosal diseases such as allergic fungal rhinosinusitis. Access to the sphenoid sinus may be gained via an anterior and posterior ethmoidectomy, but this is not always required. Approaching the sphenoid via the posterior ethmoid cavity preserves the vertical stability of the MT, which may be lost if the MT is lateralized to approach the natural ostium of the sphenoid, which usually lies medial to the middle and superior turbinate.

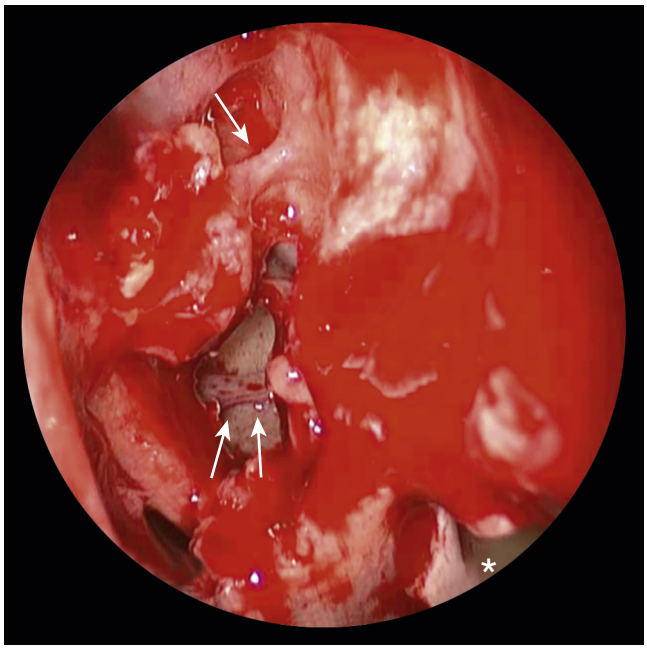

Fig. 108.3. Endoscopic view of anterior *(single arrow)* and posterior *(double arrows)* ethmoid arteries. Left maxillary antrostomy is marked with an *asterisk*.

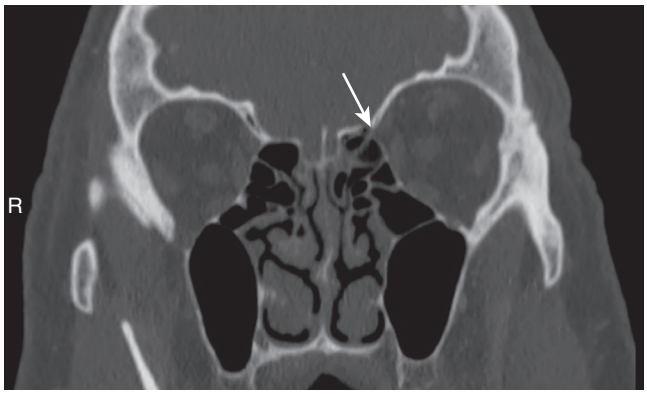

Fig. 108.4. Coronal CT scan showing left anterior ethmoid artery just posterior to the globe *(white arrow)*.

2. Ethmoidectomy is often performed for access to the frontal sinuses with removal of the agger nasi and associated suprabullar cells, which will be discussed further in Chapter 112, "Endoscopic Approach to the Frontal Sinus."

Contraindications

1. Medical comorbidities that would prevent the patient from safely undergoing general anesthesia. Patients should be appropriately screened for potential risks that outweigh the benefits of an elective surgery.
2. Uncontrolled asthma or reactive airway disease should be adequately controlled prior to ESS.

Preoperative Preparation

1. Dedicated maxillofacial CT scan should be obtained and carefully reviewed prior to surgery as discussed in the "Imaging" section.
2. Patients should stop taking aspirin, nonsteroidal anti-inflammatories, or other anticoagulants and supplements at least 7 days preoperatively. If there is a history of bleeding with prior surgery or trauma, then a coagulation profile is obtained. Profuse intraoperative bleeding precludes safe endoscopic visualization and is a contraindication to continuation of an endoscopic dissection.
3. Preoperatively, patients are counseled regarding the procedure, risks, and complications. This informed consent should be detailed and include the following risks: loss of smell, worsening of symptoms, bleeding, infection, CSF leak, and orbital injury, including diplopia and loss of vision.
4 Imaging studies and pathology slides from previous surgery done elsewhere should be obtained and reviewed by in-house experts.

OPERATIVE PERIOD

Anesthesia

1. Close communication with the anesthesiologist in the perioperative period is critical to ensure that blood loss is minimized and that surgery can be performed with optimal visualization.
2. In most cases, it is recommended that ethmoidectomy be performed under general anesthesia if possible in order to achieve the best surgical outcome in a safe manner due to close dissection near the orbit as well as the skull base.
3. Total IV anesthesia (TIVA) can potentially limit bleeding, especially in cases of severe nasal polyposis.
   a. A prospective randomized controlled trial suggests that TIVA results in better surgical field visualization compared with inhalation anesthesia.[2]
4. The anesthesiologist and the sinus surgeon must also be aware of the potential dangers of using beta-blockers concurrently with the use of topical alpha agonists (oxymetazoline, phenylephrine) due to the risk of potential unopposed alpha stimulation and cardiogenic shock.

Positioning

1. The surgeon, the patient, and the screens from which the surgeon is operating (image guidance and endoscopic view) should form a common axis for optimal ability of instrumentation in the nasal cavities and visualization (Fig. 108.5: room setup).
2. The head of the bed is elevated to 20 to 30 degrees to reduce venous congestion and tilted 15 degrees to the surgeon's side.
3. In patients who require extensive frontal dissection, a shoulder roll can be helpful for slight extension of the patient's head for access to this region.

Perioperative Medications

1. Patients undergoing endoscopic sinus surgery often have been treated with antibiotics and oral and topical steroids without significant benefit. If a culture is available, it is ideal to use the appropriate antibiotic to cover culture positive organisms.
   a. This is critical in the patient who has cystic fibrosis to prevent perioperative infectious complications.
2. If cultures have been negative and patients do not present with an infectious component to their sinus disease, cefazolin 1 g is administered preoperatively and can be dosed upwards to 2 g, depending on the patient's weight.



Fig. 108.5. Patient positioning. The surgeon stands to the right of the patient. The navigation system is placed just above the patient's head *(black arrow)*. The endoscopic projection screen is placed coaxial to the surgeon across from the patient's head *(asterisk)*. The anesthesia setup is to the left of the patient. Notice the patient's head is elevated 20 to 30 degrees and tilted 15 degrees toward the surgeon.

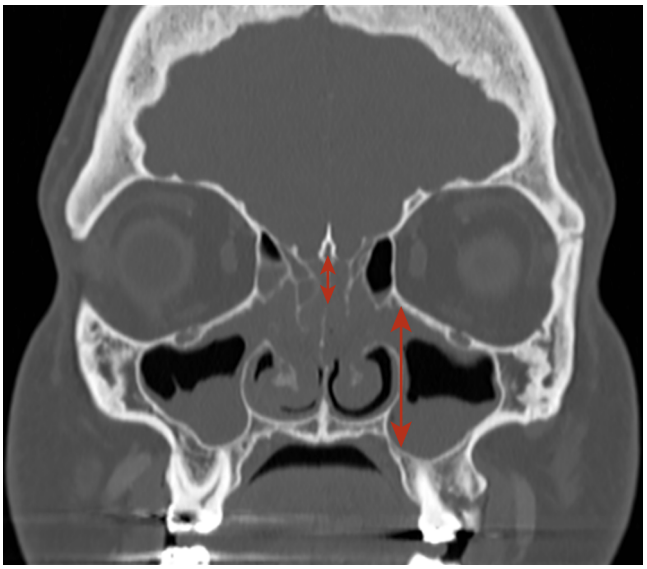

Fig. 108.6. Relative ethmoid height. This coronal CT scan demonstrates a case where the relative short height of the ethmoid cavity *(short red arrow)* compared with the height of the well-pneumatized maxillary sinus *(long red arrow)* makes the skull base "closer than it may appear."

3. Treatment with systemic steroids in patients with eosinophilic polyposis can significantly improve inflammation prior to surgery, therefore minimizing blood loss. Patients should be counseled regarding the risks of antibiotic and steroid therapy, including *Clostridium difficile* infection and avascular necrosis of the hip, respectively.

Monitoring

1. Standard hemodynamic monitoring is required by anesthesia during surgery.
2. Although exceptions may be made due to a particular patient's cardiovascular status and medical history, maintaining an otherwise healthy patient's heart rate to 60 beats per minute and mean arterial pressure to 60 beats per minute is felt to be safe and effective at reducing bleeding in the operative field.[3]

Instruments and Equipment to Have Available

1. Key instruments necessary to perform a successful ethmoidectomy include through-cutting straight and 45-degree upturned mucosal-sparing forceps. The senior author prefers fine flat jaws in comparison to the pointed Blakesley shape when removing partitions from the skull base. The smaller caliber through-cutting instruments, which are 1 mm in size, can be easier to maneuver in a narrow ethmoid cavity, compared with the standard size.
2. A double-ended "J" curette with curved oval tips can be helpful to remove anterior ethmoid partitions and the ethmoid bulla.
3. Kerrison rongeurs or a sphenoid punch can be helpful in removing partitions along the lamina papyracea, which are often oriented in the coronal plan.
4. Computer-assisted navigational technology
   a. Computer-assisted navigational technology does not replace a thorough knowledge of anatomy and is not required in the majority of ESS cases. However, this technology may be helpful in revision ESS in which landmarks are distorted or absent, in extensive nasal polyposis, and for disease abutting the skull base, optic nerve, or carotid artery (as in an Onodi cell).

Key Anatomic Landmarks

1. The key to performing safe and effective ethmoidectomy is understanding the ethmoid cavity anatomy and identifying critical landmarks in a stepwise fashion. The maxillofacial sinus CT scan should be carefully studied prior to the procedure to understand the anatomy and variations that could pose hazards during surgery, including the anterior/posterior ethmoid arteries, Onodi cells, dehiscences, and the surrounding borders, including the orbit and skull base.
   a. Although the Keros classification is commonly described and is important for understanding the location of the lateral lamella of the cribriform plate, the most useful relationship in a practical sense is the relative height of the maxillary sinus to the height of the ethmoid cavity. The patient with a short ethmoid height due to a largely pneumatized maxillary sinus will require increased awareness that the skull base is closer than it may appear (Fig. 108.6: relative ethmoid height).
2. The initial step is to identify the ethmoid bulla. Once removed, the lamina papyracea or medial orbital wall is the first landmark that should be identified and further dissected and preserved.
3. The basal lamella is the second important landmark, which is the lateral attachment of the MT and serves as the divider between the anterior and posterior ethmoid cavities.
4. Once the vertical basal lamella has been traversed, the third important landmark is the superior turbinate.
5. Once the superior turbinate is identified, the fourth landmark is the skull base in the posterior ethmoid sinus. The "corner" is a useful term to describe the junction of the face of the sphenoid, the skull base, and the orbit. If this point is reached, then the surgeon can be confident that a complete ethmoidectomy can be performed in a safe manner.

Prerequisite Skills

1. Endoscopic sinus surgeons should be knowledgeable of medical therapy that precedes the decision to move forward with surgery.
   a. Patients should be appropriately counseled that surgery for diseases that involve chronic inflammation and

infection including polyposis and cystic fibrosis is only an adjunct for a broader strategy to provide effective medical therapy to the sinuses in a topical fashion and facilitate the use of nasal saline irrigations as well as débridements if necessary. At this time there is no known cure for CRS with polyposis or cystic fibrosis, and therefore it is crucial that patients are advised of the importance of continued medical therapy and postoperative follow-up.

2. The endoscopic sinus surgeon must also have a good working knowledge of the sinonasal anatomy and be skilled in the use of not only 0-degree Hopkins telescopes but also angled telescopes to facilitate dissection of the sinuses.
3. Mucosal preservation is crucial in performing a "functional" surgery, since the functioning component of the sinuses is the ciliated lining that allows for mucous clearance and innate immune regulation. Therefore the ability to accurately use through-cutting instruments is important in removing ethmoid partitions without stripping the lining. Meticulous technique by removing partitions, avoiding stripping, and making distinct cuts through mucosa-bone-mucosa limits bleeding and scarring.

Operative Risks

1. CSF leak
2. Orbital injury either at the lamina or at the orbital apex
3. Vascular injury to anterior/posterior ethmoid arteries, resulting in orbital hematoma
4. Hyposmia
5. Bleeding
6. Infection

Surgical Technique

1. Perform endoscopic injections with 1% lidocaine with epinephrine 1:100,000 (Fig. 108.7: preoperative injections).
   a. Region of the sphenopalatine artery (approximately 1 cm from the posterior edge of the MT along the lateral nasal wall)
   b. Axilla of the MT
   c. Uncinate process
   d. Medial aspect of the MT
2. The mucosa should be anesthetized and decongested with pledgets soaked in a 50/50 mixture of 0.05% oxymetazoline for vasoconstriction and 4% lidocaine for topical anesthesia. Alternatively, some surgeons prefer pledgets soaked in 1:1,000 topical epinephrine.
   a. These pledgets should be left in place for at least 10 minutes to maximize topical decongestion.
   b. One of the pledgets should specifically be placed between the MT and lateral nasal wall to gently medialize the MT and decongest the region of the ethmoid bulla.
3. Identify the ethmoid bulla and maneuver the J-curette posterior to the bulla with the 90-degree side upward, removing the entirety of the bulla using an anterior motion (Fig. 108.8: dissection of ethmoid bulla). It is important to maneuver the curette in only the anterior plane to prevent entry into the skull base (superior) or orbit (lateral).
4. Alternatively a sickle knife can be used to enter the bulla with the point facing inferiorly, and through-cutting forceps are used to dissect the bulla from the lamina papyracea.
5. Remove residual partitions along the lamina papyracea with a sphenoid punch or Kerrison rongeurs.
   a. As one dissects from anterior to posterior, care should always be made to enter cells inferiorly and medially, thus avoiding inadvertent injury to the skull base or orbit.
6. Identify the basal lamella as well as the roof of the maxillary sinus to determine the trajectory for entering the posterior ethmoid sinus. The straight portion of the J-curette or a sickle knife is used to traverse the basal lamella and dissect out the bony portion of this structure.
   a. The horizontal basal lamella should be preserved to allow continued stability to the MT. A destabilized MT may have a tendency to lateralize postoperatively, thus obstructing the osteomeatal complex and frontal outflow tract.
7. The superior turbinate should be identified through the basal lamella. Using a microdébrider, the remaining soft tissue of the basal lamella is removed to further define the anterior head of the superior turbinate. This can be accomplished by using the microdébrider in a controlled sweeping motion from a 6 to 9 o'clock fashion on the patient's left side and 3 to 6 o'clock on the right side.
8. Remove the ethmoid partitions with 45-degree upturned through-cutting forceps, taking care to identify the skull base in the most posterior ethmoid sinus. Partitions that are oriented axially or sagittally can be removed with a straight through-cutting forceps.
9. Identify the junction of the skull base, anterior face of the sphenoid sinus, and the medial orbital wall.
10. At this juncture, it is safest to use an angled telescope, either at 30 or 45 degrees, to help remove the remaining ethmoid partitions along the skull base, taking care to identify the anterior and posterior ethmoid arteries if they are exposed in a mesentery (see Fig. 108.3: figure anterior/posterior ethmoid arteries and Fig. 108.9: removal of ethmoid partitions).
    a. Once the skull base is clearly identified at the "corner" of the orbit and sphenoid, it is safest to remove these remaining partitions in a posterior to anterior fashion, following the slope of the skull base.

Common Errors in Technique

1. Incomplete removal of the ethmoid bulla and residual partitions left along the lamina papyracea. This will limit access to the posterior ethmoid sinuses.
2. Failure to identify the superior turbinate completely by inadequately removing the medial portion of the basal lamella as described
3. Overly aggressive removal of the basal lamella causing MT instability and potential lateralization
4. Failure to fully identify the posterior ethmoid sinuses and the skull base leading to incomplete ethmoidectomy
5. Incomplete removal of ethmoid partitions secondary to prior steps not being performed correctly
6. Pointing the open portion of the microdébrider toward the orbit or skull base when a bony dehiscence is present

POSTOPERATIVE PERIOD

Postoperative Management

1. Counsel the patient to avoid nose blowing and, if sneezing, to keep the mouth open to prevent increased pressure in the sinus cavities.
2. Start nasal saline irrigations three times daily, preferably the day of or the day after surgery.
   a. We prefer a "high volume, low pressure" irrigation (total of 240 mL of saline split between each nostril).
3. Antibiotics at the discretion of the surgeon
4. Corticosteroids if patients have CRS with polyposis
   a. Patients with nasal polyposis at our institution are treated postoperatively with methylprednisolone 32 mg daily for 7 days and then a ~3-week taper (32 mg every other day for 3 doses, 24 mg every other day for 3 doses, 16 mg every other day for 3 doses, and off).

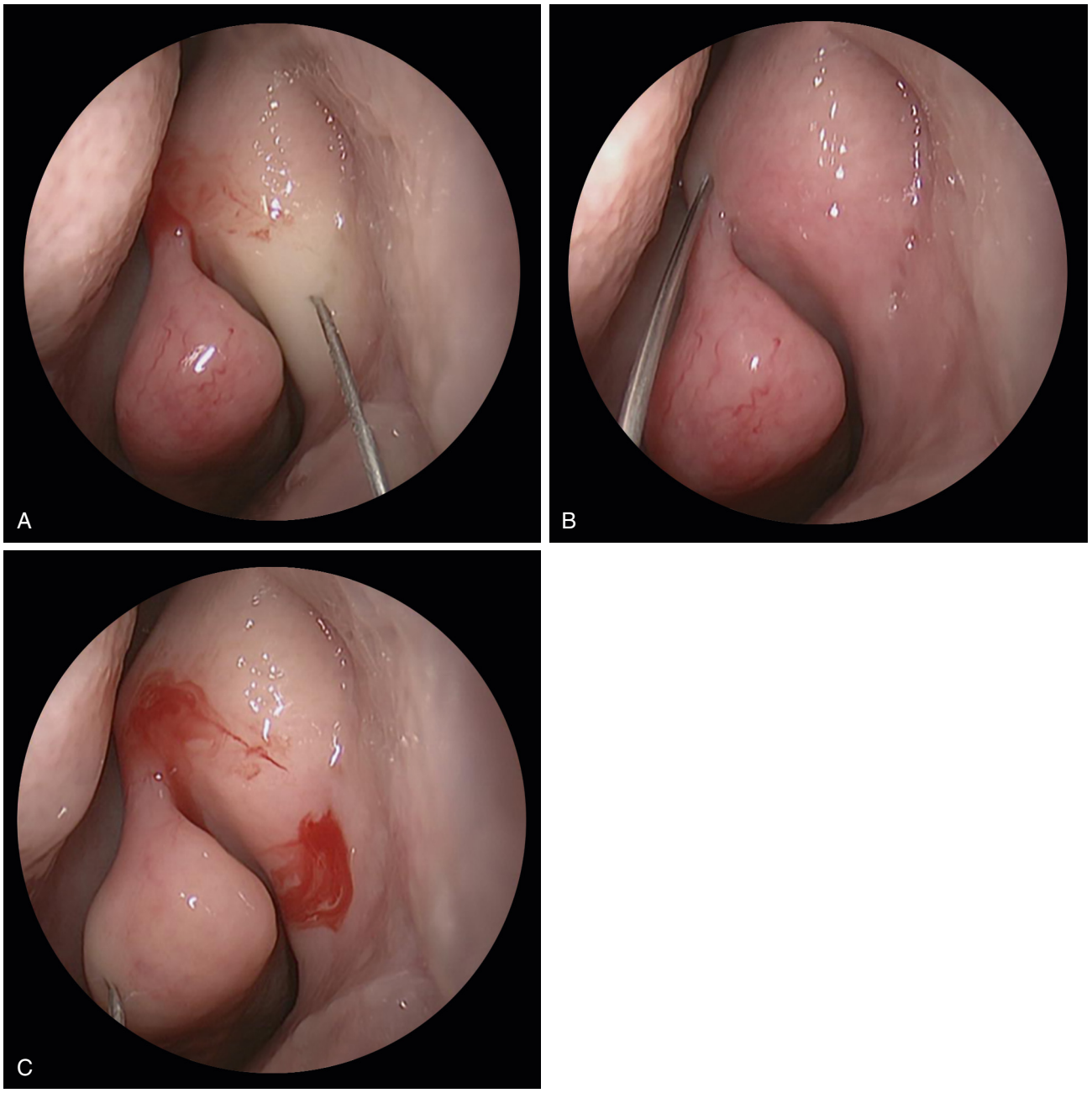

Fig. 108.7. Preoperative injections of the left **A,** lateral nasal wall, **B,** MT axilla, **C,** medial aspect of MT.

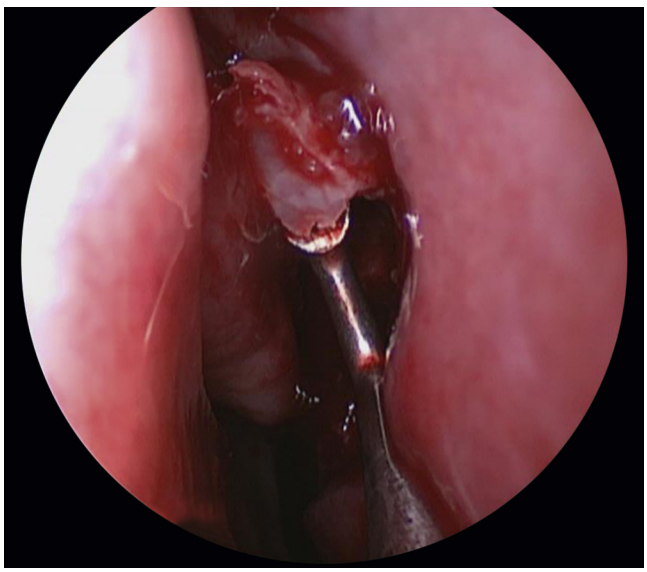

Fig. 108.8. Dissection of the left ethmoid bulla with a J-curette.

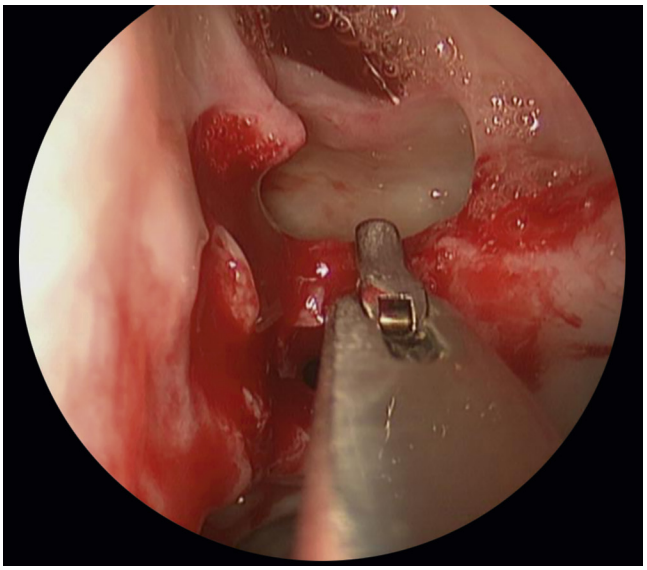

Fig. 108.9. Removal of ethmoid partitions along the skull base with a through-cutting instrument.

5. Follow up within 1 week to perform débridement and assess healing.
6. Provide short-term and long-term medication strategies depending on the patient's pathology.

Complications

1. Orbital injury
   a. This most often occurs from failure to identify the lamina papyracea at the onset of surgery as well as with obstructive nasal polyposis and bleeding.
2. CSF leak
   a. May occur from failure to identify skull base landmarks, improper use of through-cutting instruments or curettes in areas of significant osteitis, aggressive "rocking" of the MT, obstructing polyps, or significant bleeding
3. MT instability and lateralization from causing mucosal trauma during dissection or from removing a significant portion of the basal lamella, thus destabilizing the MT

Alternative Management Plan

1. Medical management
   a. Surgery is generally only offered after failure of attempted appropriate medical management, as discussed previously.
   b. Symptomatic patients should undergo directed medical therapy prior to surgical consideration. At a minimum, this usually includes culture-directed antibiotics given for as long as patients are steadily improving (often 3 to 4 weeks), nasal steroid sprays, a short course of systemic steroids, and occasionally topical antimicrobials.[4]
   c. Medical treatment efforts should be directed at the particular patient's pattern of disease with consideration of mitigating factors, including presence of polyps and previous treatment efforts.[4]
   d. Patients whose conditions warrant exception from a preoperative trial of medical therapy include those with impending orbital complications, those with mucocele, and those with unilateral disease in which a diagnosis is required to evaluate for diseases other than chronic nonspecific sinus inflammation.
      1) In patients with unilateral maxillary disease, a dental origin should always be considered (i.e., periapical abscess with secondary involvement of the sinus).

DISCUSSION

Evidence-Based Medicine Question

What is the evidence supporting or refuting MT resection in patients with nasal polyposis?

The MT is an important anatomic and physiologic structure that is often carefully preserved in ESS. In general, the MT should be preserved if it is not affected by disease, because it serves as a useful landmark and provides underlying physiologic function. However, there may be a role for MT resection in cases of MT destabilization, polypoid degeneration, or obstruction. A recent systematic review examined the role of MT resection in cases such as this. It suggested no difference in quality of life outcomes, nasal airway resistance, or rates of postoperative frontal sinusitis in patients undergoing MT resection during ESS when compared with MT preservation. Postoperative olfaction scores were generally better in the MT resection group. In regard to postoperative endoscopic examinations, some studies note greater improvement in the MT resection group compared with MT preservation, while others were equivalent.[5] This topic remains an active area of debate.

Editorial Comment

Endoscopic ethmoidectomy, primary and revision, remains a source of complications and medicolegal issues for the otolaryngologist. Stankiewicz drew early attention to this problem (Stankiewicz JA: Complications of intranasal ethmoidectomy. *Laryngoscope* 97(11):1270-1273, 1987), and it remains the most common cause of litigation for the specialty (Tolisano AM, Justin GA, Ruhl DS, et al.: Rhinology and medical malpractice: an update of the medicolegal landscape of the last ten years. *Laryngoscope* (1):14-19, 2016). The authors' thorough review of the indications and contraindications allow the reader to arrive at good surgical decision making, and the technique outlined documents a safe surgical approach to avoid complications.

Barry Schaitkin

Access the review questions and additional sources list online at http://www.expertconsult.com



REFERENCES

1. Amine MA, Anand V. Anatomy and complications: safe sinus. Otolaryngol Clin North Am 2015;48(5):739–748.
2. Wormald PJ, van Renen G, Perks J, et al. The effect of the total intravenous anesthesia compared with inhalational anesthesia on the surgical field during endoscopic sinus surgery. Am J Rhinol 2005;19(5):514–520.
3. Sieskiewicz A, Lewczuk A, Drozdowski A, et al. Is it safe to decrease hemodynamic parameters to achieve bloodless surgical field during transnasal endoscopic procedures? Our experience in fifteen patients. Clin Otolaryngol 2013;38(4):326–329.
4. Rosenfeld RM, Piccirillo JF, Chandrasekhar SS, et al. Clinical practice guideline (update): adult sinusitis. Otolaryngol Head Neck Surg 2015;152(Suppl. 2):S1–39.
5. Choby GW, Hobson CE, Lee S, et al. Clinical effects of middle turbinate resection after endoscopic sinus surgery: a systematic review. Am J Rhinol Allergy 2014;28(6):502–507.

REVIEW QUESTIONS

1. The Keros classification describes
   a. The position of the basal lamella of the middle turbinate
   b. The anatomic arrangement of the skull base with respect to the depth of the olfactory sulcus
   c. The pneumatization pattern of the posterior ethmoid air cells

2. The anterior ethmoid artery can be seen on coronal CT scan
   a. Just posterior to the last CT cut of the globe
   b. At the junction of the face of the sphenoid sinus and the skull base
   c. At the level of the head of the middle turbinate

3. Aggressive resection of the horizontal portion of the middle turbinate may result in
   a. Medialization of the middle turbinate toward the septum
   b. Lateralization of the middle turbinate, thus blocking the frontal outflow tract
   c. Inferior displacement of the middle turbinate

4. Endoscopic sinus surgery without a preceding trial of medical management is indicated in which of the following?
   a. Chronic rhinosinusitis without polyps
   b. Chronic rhinosinusitis with polyps
   c. Mucocele
   d. Recurrent acute rhinosinusitis

5. Complications of endoscopic ethmoidectomy include all of the following except
   a. CSF leak
   b. Epistaxis
   c. Orbital injury
   d. Eustachian tube dysfunction

ADDITIONAL SOURCES

Kennedy DW, Zinreich SJ, Rosenbaum AE, et al. Functional endoscopic sinus surgery. Theory and diagnostic evaluation. Arch Otolaryngol 1985;111:576–582.

Senior BA, Kennedy DW, Tanabodee J, et al. Long-term results of functional endoscopic sinus surgery. Laryngoscope 1998;108(2):151–157.

Stankiewicz JA, Lal D, Connor M, Welch K. Complications in endoscopic sinus surgery for chronic rhinosinusitis: a 25-year experience. Laryngoscope 2011;121:2684–2701.

Zinreich BJ, Kennedy DW, Rosenbaum AE, et al. Paranasal sinuses: CT imaging requirements for endoscopic surgery. Radiology 1987;163:769–775.

109 External Ethmoidectomy

Carl H. Snyderman

INTRODUCTION

In many countries, external ethmoidectomy is rarely performed due to the widespread adoption of endoscopic techniques. However, in some clinics where endoscopic equipment is not available, the external ethmoidectomy approach is still an important technique used in the management of ethmoid disease. It also still has value for the management of sinonasal tumors, epistaxis, orbital infection, and trauma in special circumstances. It may be used in combination with other approaches (transnasal and transcranial) to provide additional exposure. An open approach may be preferred for some highly vascular tumors.

KEY OPERATIVE LEARNING POINTS

- The incision should be placed at the junction of aesthetic units, midway between the nasal dorsum and medial canthus.
- The frontoethmoidal suture line defines the level of the skull base (roof of the ethmoid sinus).
- The anterior and posterior ethmoidal arteries are at the level of the frontoethmoidal suture line. Injury to these arteries can result in a retrobulbar hematoma.
- The posterior lacrimal crest is the anterior limit of the ethmoid sinus and defines the lacrimal fossa. Avoidance of trauma to the nasolacrimal duct will avoid postoperative epiphora.
- The cribriform plate is medial to the middle turbinate and may be at a lower level than the frontoethmoidal suture line. Violation of the lateral lamella can result in a cerebrospinal fluid (CSF) leak.
- The optic nerve is in close proximity to the posterior ethmoidal artery.

PREOPERATIVE PERIOD

History

- Orbital swelling
- Diplopia
- Epiphora
- Nasal obstruction
- Sinus pain/pressure
- Epistaxis

Physical Examination

- Widening of the nasal bones
- Orbital swelling or proptosis
- Nasal mass
- Purulent nasal discharge

Imaging

- Computed tomography (CT) with or without contrast
  Contrast is indicated for neoplastic conditions. An image-guidance protocol is used in anticipation of surgery with navigation

Indications

- Subperiosteal orbital abscess
  An external ethmoidectomy approach is a suitable approach for a subperiosteal abscess that is located medially or superiorly.
- Osseous tumor of ethmoid region with obstruction of the frontal sinus (osteoma)
- Neoplasm in the ethmoid sinus
- Vascular tumor
- Skull base trauma with CSF leak from the roof of the ethmoid, cribriform plate, or frontal sinus
- Meningoencephalocele of the anterior cranial base or frontal sinus

Contraindications

- Biopsy of malignant tumors
  Sinonasal neoplasms should be biopsied intranasally if possible to avoid tumor seeding of the external soft tissues. If there is tumor involvement of the skin, an external incision is optional.
- Bilateral disease

Preoperative Preparation

- Cessation of antiplatelet drugs according to guidelines
- Antibiotic therapy for concomitant sinus infection

OPERATIVE PERIOD

Anesthesia

- Local anesthesia with intravenous sedation may be considered for biopsy or drainage of an abscess.
- General anesthesia is preferred for most cases.

Positioning

- Supine

Perioperative Antibiotic Prophylaxis

- Second-generation cephalosporin or penicillin
- Third-generation cephalosporin with CSF penetration if there is an intraoperative CSF leak

Monitoring

- None

Instruments and Equipment to Have Available

- Image-based navigation (optional)
- Needle-tip electrocautery
- Periosteal elevator (Cottle)
- Sinus surgery set
- Kerrison rongeurs
- Drill with 4-mm coarse diamond bit



Fig. 109.1. The incision is equidistant between the nasal dorsum and the medial canthus. A Z-plasty can be incorporated into the incision at closure to prevent scar contracture.

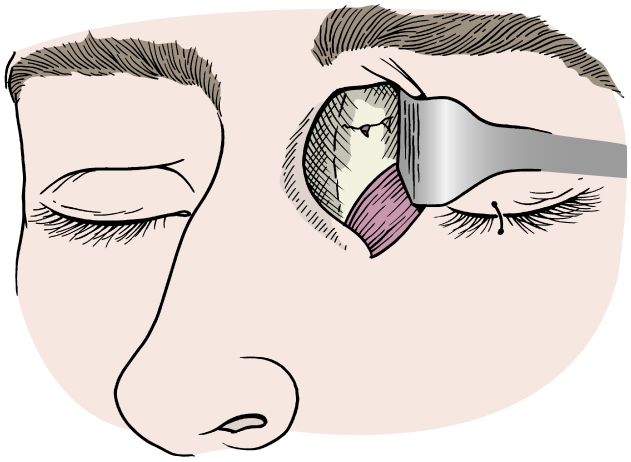

Fig. 109.2. The periosteum is elevated from the lamina papyracea, and the ethmoidal arteries are identified along the frontoethmoidal suture line.

- Bipolar electrocautery
- Nasal tampons (Merocel)

Key Anatomic Landmarks[1]

- Frontoethmoidal suture line
- Posterior lacrimal crest
- Anterior ethmoidal artery
- Posterior ethmoidal artery
- Lamina papyracea
- Middle turbinate

Prerequisite Skills

- Familiarity with Caldwell-Luc and other sinonasal procedures

Operative Risks

- Orbital injury
  The medial rectus muscle is at greatest risk of injury if there is violation of the periorbita

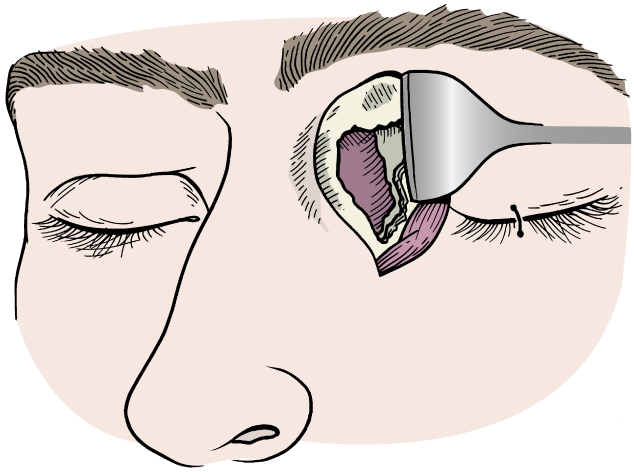

Fig. 109.3. The bone of the lamina papyracea is removed with bone rongeurs to the frontoethmoidal suture line superiorly and to the posterior lacrimal crest anteriorly. The posterior ethmoidal artery is a landmark for the optic canal.

- Hematoma of the orbit
  Orbital hematoma is usually associated with violation of the periorbita. Failure to adequately cauterize the anterior ethmoidal artery can allow it to retract into the orbital tissues and cause a retrobulbar hematoma.
- CSF leak
  A CSF leak may result from removal of bone superior to the frontoethmoidal suture line or disruption of the attachment of the middle turbinate to the skull base.

Surgical Technique

- A temporary tarsorrhaphy suture is placed to protect the eye during surgery. Alternatively, a protective lens with lubrication can be placed.
- The incision site is injected with 1% lidocaine with 1:200,000 epinephrine solution.
- The skin is prepped with ophthalmic Betadine solution.
- A linear incision is made equidistant between the nasal dorsum and medial canthus and extends for approximately 1 cm above and below the level of the medial canthus (Figure 109.1).[1]
- Superficial vessels (angular artery branch of facial artery) are best controlled with bipolar electrocautery.
- The periosteum is elevated from the underlying bone using a Cottle elevator, and the frontoethmoidal suture line is identified and followed posteriorly to the anterior ethmoidal artery (Figure 109.2).[2]
- Inferiorly, the periosteum is elevated to the superior aspect of the lacrimal fossa and the attachment of the medial canthal ligament.
- The orbital contents are retracted with a narrow malleable ribbon retractor, and the anterior ethmoidal artery is identified and cauterized with bipolar electrocautery. This is more secure than clipping the vessel. The artery is then transected to allow further subperiosteal dissection posteriorly. Dissection is not carried out beyond the posterior ethmoidal artery due to proximity to the optic nerve.
- If there is violation of periorbita with herniation of orbital adipose tissue, it can be gently cauterized with bipolar electrocautery to shrink the adipose tissue.
- The lamina papyracea is easily fractured with a Cottle elevator, and the ethmoid air cells are opened.[3] The opening is enlarged with Kerrison rongeurs to the level of the frontoethmoidal suture line superiorly and to the posterior lacrimal crest anteriorly (Fig. 109.3).

- The contents of the ethmoid sinus are removed with standard sinus instruments in a medial and inferior direction until there is communication with the nasal cavity. The middle turbinate is the medial limit of dissection for inflammatory disease and care is taken to avoid injury to its attachment at the skull base (lateral lamella of the cribriform).
- Removal of ethmoidal air cells continues posteriorly to the basal lamella or anterior wall of the sphenoid sinus. The dissection may be carried to the posterior ethmoid cells to expose the anterior wall of the sphenoid sinus (see Chapter 110). Visualization is limited without endoscopy, and the plane of the skull base must be carefully followed as it slopes inferiorly.
- If exposure of the frontal sinus is necessary, the nasofrontal recess can be followed superiorly with a Kerrison rongeur. Drilling of thick bone may be necessary, depending on the degree of exposure needed. Excessive bone removal may result in obstruction of the outflow tract from herniation of orbital tissue.
- Following removal of pathology, it is imperative to confirm adequate hemostasis. The superficial tissues are approximated in two layers using absorbable suture. A Z-plasty may be incorporated into the incision to minimize scar contracture. Steri-Strip dressings are applied longitudinally along the incision. Nasal packing with a Merocel tampon may be used if there is mild bleeding.

Common Errors in Technique

- Incision too high (above frontoethmoidal suture line)
- Avulsion of anterior ethmoidal artery without hemostatic control
- Violation of periorbita
- CSF Leak

POSTOPERATIVE PERIOD

Postoperative Management

- Careful observation of the eye in the minutes to hours following surgery is necessary to detect orbital hematoma.
- Nasal packing can be removed in the recovery room if there is no bleeding.
- The patient is discharged on a regimen of saline spray and is instructed to avoid nose blowing or excessive exertion for at least 1 week.

Complications

- Orbital hematoma
  If there is bleeding from the anterior ethmoidal artery intraoperatively, it needs to be thoroughly cauterized using bipolar electrocautery. If proptosis from a retrobulbar hematoma is discovered intraoperatively or postoperatively, gentle massage of the closed orbit may halt the bleeding. Nasal packing should be removed immediately. Ophthalmology should be consulted emergently for measurement of ocular pressures and further management. The surgeon should be prepared to perform a lateral canthotomy if there is progression of proptosis, deterioration of vision, or absent afferent pupillary reflex.
- CSF leak
  Whenever there is an unanticipated intraoperative CSF leak, it is important to confirm that there is no associated intracranial vascular injury. Additional removal of bone with visualization of dural margins is necessary. Surrounding mucosa should be removed, and the defect can be repaired with fascia or adipose tissue grafts. Neurosurgery should be consulted postoperatively for further management, and a CT scan of the head should be obtained to rule out an intracranial complication (hemorrhage or tension pneumocephalus).
- Injury to the orbit
  Injury to the extraocular muscles can result in diplopia. Consultation with an ophthalmologist is necessary.
- Medial canthal tendon
  Detachment of the medial canthal tendon is usually not a problem unless the underlying bone is removed or mobilized. Failure of the tendon to reattach can result in "rounding" of the medial canthus.
- Injury to the nasolacrimal sac
  Dissection anterior to the posterior lacrimal crest can injure the lacrimal sac. Postoperative scarring can result in epiphora. If there is intraoperative injury, Silastic nasolacrimal stents can be left in place for several weeks to prevent stenosis.
- Scar contracture
  A long linear incision can form a cicatrix with healing. This can be avoided by using a minimal incision or placing a small Z-plasty in the center of the incision.

Alternative Management Plan

- Endoscopic sinus surgery is preferred for most ethmoid pathology.
- Subperiosteal orbital abscesses can be drained endoscopically if favorably located or through a transorbital (eyelid crease or transcaruncular) approach.

DISCUSSION

Evidence-Based Medicine Question

What is the best approach for drainage of a subperiosteal orbital abscess?

Most subperiosteal orbital abscesses occur in children as a complication of sinusitis. Although most surgeons have adopted endoscopic techniques for drainage of abscesses that are favorably located (medial), there is sparse literature comparing endoscopic and external approaches.

In a retrospective review of 38 children treated surgically for subperiosteal abscess associated with acute ethmoid sinus infection, Rubin et al.[2] compared the outcomes based on surgical approach: 12 endoscopic (32%), 21 external (55%), and 5 combined (13%). There were no surgical complications in any of the groups, but the percentage of surgical failures requiring additional drainage was almost twice as high after endoscopic surgery (failure rate: 25%) than after an external approach (failure rate: 14.3%); this difference was not significant.

This review and other literature[3] demonstrate the continued need for external ethmoidectomy, especially if a first attempt with endoscopic drainage fails.

Editorial Comment

Many years ago while training as a resident, I never saw or was exposed in any way to surgery of the ethmoid sinuses. Once in practice as chief of the department in an academic referral center, otolaryngologists in the community referred patients whom they could not manage. These included orbital to me abscess secondary to acute ethmoiditis and massive nasal polyposis causing proptosis as well as sinonasal neoplasms. So what to do? Well, I recalled that during my fellowship in head and oncologic surgery, I did have a brief introduction to the lateral rhinotomy and medial maxillectomy procedure for tumors of the lateral nasal wall and ethmoid sinuses. That

memory, aided by a glimpse into *Gray's Anatomy,* was my segue into performing external ethmoidectomy.

Using the modified lateral rhinotomy incision rather than the classical semicircular incision eliminated the unsightly scar which sometimes developed. Using a headlight, a #15 blade, ribbon retractors, a Cottle elevator, and a Takashi forceps, I was able to identify the landmarks and thoroughly remove polyps and tumors—usually inverted papillomas—and drain orbital abscesses. With a bit of experience I added transantral sphenoidotomy and transethmoidal hypophsectomy (used in cases of metastatic breast cancer for pain control) to my repertoire.

Of course all of this took place before Professor Messerklinger, of Graz, Austria, introduced functional endoscopic sinus surgery (FESS) and in collaboration with industry developed advanced endoscopes and improved instrumentation. This has resulted in most of the external techniques being replaced by endonasal endoscopic surgery. The endonasal endoscopic method of skull base surgery, developed by Dr. Carl H. Snyderman, uses various surgical corridors to approach a variety of neoplasms arising at the skull base. This technique replaced the transfacial-craniotomy approach that we had used for several decades.

Endoscopic endonasal surgery has largely replaced external ethmoidectomy in many areas in the world. However, there are still hospitals that do not have the financial resources to purchase the necessary equipment, or there are government restrictions in place for the surgeons' training even if the equipment could be purchased. In these areas, external ethmoidectomy remains a versatile procedure that can be incorporated into the training of young surgeons for the benefit of their patients.

Eugene N. Myers

Access the review questions and additional source list online at http://www.expertconsult.com

REFERENCES

1. Petruzelli GJ: Orbit anatomy. http://emedicine.medscape.com/article/835021-overview. Accessed Nov 19, 2016.
2. Rubin F, Pierrot S, Lebreton M, et al. Drainage of subperiosteal orbital abscesses complicating pediatric ethmoiditis: comparison between external and transnasal approaches. Int J Pediatr Otorhinolaryngol 2013;77(5):796–802.
3. Erickson BP, Lee WW. Orbital cellulitis and subperiosteal abscess: a 5-year outcomes analysis. Orbit 2015;34(3):115–120.

REVIEW QUESTIONS

1. Which of the following statements about the anterior ethmoidal artery is false?
   a. It is situated 4 to 7 mm anterior to the optic canal.
   b. It is found along the frontoethmoidal suture line.
   c. Injury can result in a retrobulbar hematoma.
   d. Sacrifice of the artery provides greater access to the medial orbit.

2. Indications for an external ethmoidectomy include all of the following, except
   a. Subperiosteal orbital abscess
   b. Cerebrospinal fluid (CSF) leak from cribriform plate
   c. Osteoma of ethmoid sinus
   d. Inverted papilloma of maxillary sinus

3. Which of the following statements is false?
   a. The posterior lacrimal crest is the anterior limit of an external ethmoidectomy.
   b. The cribriform plate is superior to the frontoethmoidal suture line.
   c. The middle turbinate separates the ethmoid roof from the cribriform plate.
   d. The posterior limit of an external ethmoidectomy is the posterior ethmoidal artery.

ADDITIONAL SOURCE

Johnson JT. External ethmoidectomy. In: Myers EN, editor. Operative Otolaryngology-Head & Neck Surgery. 2nd ed. Philadelphia: Elsevier; 2008. p. 99–105.

110 Endoscopic Sphenoidotomy

Evan S. Walgama, Jayakar Nayak

INTRODUCTION

The paired sphenoid sinuses are the most posteriorly positioned of the paranasal sinuses. Due to this location, endoscopic approaches to the sphenoid sinus are preferred to address most pathology that may arise in this location. The pathology may be isolated within the sphenoid sinus or may be part of inflammatory sinonasal disease involving the ethmoid or other paranasal sinuses. The sphenoid sinus is also the gateway to many extended endonasal procedures, including approaches to pituitary lesions, other sellar and parasellar lesions, and petroclival lesions amenable to an endonasal approach.

The two main endoscopic pathways to the sphenoid sinus are the transseptal and transethmoid approaches. Both require identification of the natural sphenoid ostium medial to the superior turbinate (ST) and enlargement of this ostium for endoscopic access. These approaches may be combined with a posterior septectomy for simultaneous access to both sphenoid sinuses, most commonly indicated for extended endonasal approaches (Figs 110.1 and 110.2).

The transseptal approach proceeds through the sphenoethmoidal recess, in the geometrically narrow airspace between the nasal septum medially and the middle turbinate laterally. This corridor rarely requires ethmoid dissection or resection of the ST and thus has the advantage of a simpler dissection with preservation of olfactory fibers. This is the most direct endoscopic approach and is most commonly used for isolated sphenoid pathology and for access to the sphenoid sinus for extended endoscopic approaches in the sagittal plane.

The transethmoid approach to the sphenoid sinus proceeds lateral to the middle turbinate and requires dissection of the uncinate process, anterior and posterior ethmoid sinus labyrinths, and typically resection of the inferior one-fifth to one-third of the ST. The approach affords a larger corridor for improved endoscopic visualization and instrumentation and provides for early identification of the skull base and lamina papyracea landmarks prior to enlarging the sphenoid ostium and taking down the rostrum. This approach is most commonly used as part of functional sinus surgery in the management of chronic sinusitis.

In some patients, the sphenoid sinus may have pneumatization of a lateral recess between the vidian and trigeminal nerves, and selected lesions in this part of the sphenoid, such as a meningoencephalocele, may be approached endoscopically with the addition of a transpterygoid dissection. The latter approach requires a transethmoid corridor to the sphenoid sinus, combined with a wide maxillary antrostomy with posterior maxillary wall/pterygopalatine fossa dissection to allow unobstructed endoscopic access to the lateral recess of the sphenoid sinus.

KEY OPERATIVE LEARNING POINTS

1. The two main endoscopic approaches to the sphenoid sinus are transnasal and transethmoid.
2. The preferred point of entry to the sphenoid sinus is through the natural ostium, always located medial to the ST and just lateral to the articulation of the nasal septum into the face of the sphenoid sinus/sphenoid rostrum.
3. The sphenoid sinus is in close proximity to critical structures, including the internal carotid artery, optic nerve, orbital apex and intraconal musculature, posterior ethmoid artery, pituitary gland, and skull base, any of which may be injured during endoscopic surgery.

History

1. History of present illness
   a. The nature, severity, and duration of symptoms related to sphenoid pathology should be obtained. In chronic rhinosinusitis, this may include cardinal symptoms of nasal obstruction, postnasal drip or chronic drainage, loss of the sense of smell, or facial pain. Sphenoid sinusitis classically, though not reliably, produces headaches felt at the scalp vertex and/or deep-seated retro-orbital pain.
   b. Determine if there are associated symptoms, especially if noninflammatory disease is suspected. This may include ophthalmologic deficits such as visual loss, decreased color vision, diplopia, or xerophthalmia. Look for signs of orbital apex syndrome (decreased vision, ophthalmoplegia, proptosis) or superior orbital fissure syndrome (ophthalmoplegia, proptosis). Evaluate any neurologic complaints, including changes in mental status, facial numbness, and severe headache.
   c. For chronic sinusitis, the history should include recent requirements for antibiotic or oral steroid therapy, current use of topical nasal medications including saline lavage, clinical response to these medications, previous medications trialed for control of symptoms, and any associated asthma, allergies, aspirin sensitivity, or immunodeficiency.
   d. Additional questions may be tailored to the suspected pathology. For example, for sphenoid sinus meningocele, whether there is any antecedent history of unilateral rhinorrhea, or history of meningitis, assess for risk factors for chronic invasive fungal sinusitis, including immunocompromise, history of diabetes, and country of origin.
2. Past medical history
   a. Determine the patient's current level of general health, including the history of major systemic disease, history of cardiopulmonary disease, and fitness for general anesthesia.
   b. Survey for systemic disease that may present with sinonasal complaints. These include granulomatosis with polyangiitis (formerly known as Wegener's granulomatosis), sarcoidosis, Churg-Strauss disease, aspirin-exacerbated respiratory disease (Samter's triad), and/or cystic fibrosis.
   c. Elicit any history of previous sinus, nasal, or skull base procedures, and whether there were any associated complications with these procedures. Revision endoscopic surgery often proceeds through distorted anatomy which increases the complexity of the procedure.
   d. Family history: History of coagulopathy or atopy

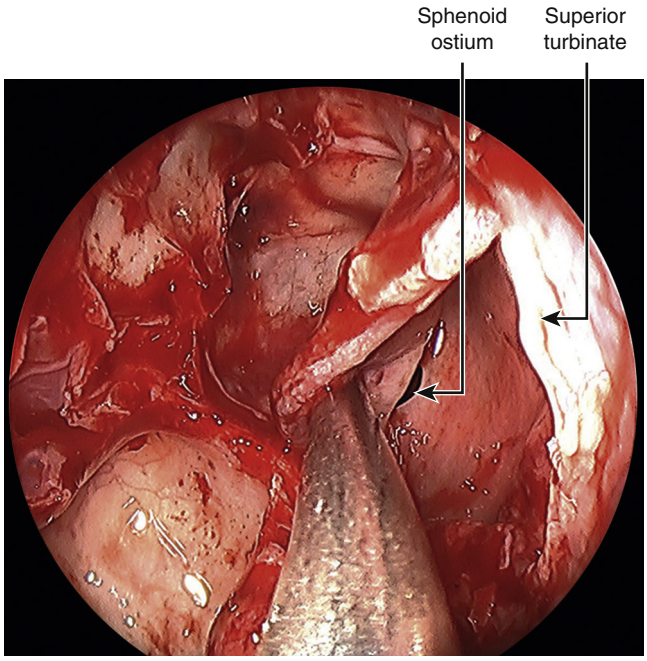

Fig. 110.1. Endoscopic view of right sphenoid ostium medial to superior turbinate (retracted laterally in this image). Previous total ethmoidectomy and maxillary antrostomy have been performed.

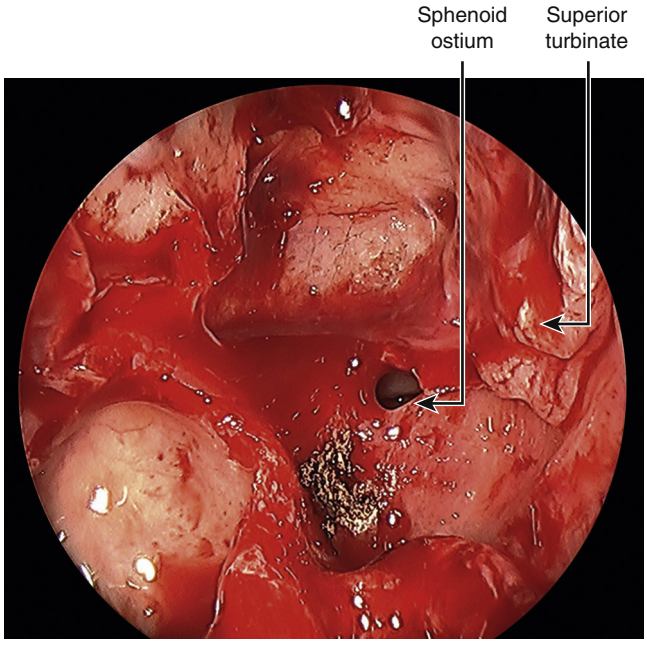

Fig. 110.2. Right sphenoid ostium is visible following resection of the inferior one-third of the superior turbinate.

e. Medications:
   1) Antiplatelet drugs
   2) Herbal products such as garlic, ginseng, and gingko

Physical Examination

1. A complete examination of the head and neck should be performed on all patients.
2. Preoperative, diagnostic nasal endoscopy should be performed on all patients undergoing endoscopic sphenoidotomy. The nose should be prepared with topical anesthetic with decongestant. Endoscopic visualization of the sphenoethmoid recess in the unoperated nose is best tolerated with a 30-degree endoscope angled superiorly and passed posterior along the floor of the nose, following the course of the inferior turbinate. In the setting of ongoing inflammation, is sometimes not possible to visualize the sphenoid ostium without manipulation of the turbinates. A trail of purulence arising from the sphenoid sinus and/or posterior ethmoid complex can sometimes be seen in this recess.

Imaging

Computed Tomography Imaging

Computed tomography imaging (CT) best defines the pneumatization and bony confines of the sphenoid sinus, including the presence of dehiscent bone of the optic nerve canal, internal carotid artery canal, and/or skull base. A deviated septum, ethmoid disease, and the lateral recess that may be encountered during an endonasal approach may be identified preoperatively. CT may be paired with a computer-assisted intraoperative navigation system for assistance in endoscopic identification of landmarks, including the natural ostium. The sphenoid sinus should be evaluated on axial, coronal, and sagittal views, preferably with cuts of less than 1 mm. Bone windowing is useful, and, in the case of opacification, soft tissue-windowing should be studied to evaluate the contents of the sinus. Heterogeneous opacification of the sphenoid sinus could signal the presence of a fungal ball, eosinophilic mucin, or a sinonasal tumor.

Magnetic Resonance Imaging

Magnetic resonance imaging (MRI) is indicated in select cases to further characterize the internal contents of the opacified sphenoid sinus or soft tissue lesions found in this cavity or to identify extrasinus extension of disease. This includes suspected neoplasm, encephalocele or meningocele, and complicated rhinosinusitis.

Indications

1. Chronic, symptomatic sphenoid sinusitis after failure of a trial/several trials of maximal medical therapy
2. Neoplasm involving the sphenoid sinus, for biopsy and/or definitive management
3. Cerebrospinal fluid leak, with or without associated meningoencephalocele, for endoscopic repair of the skull base
4. Access for expanded endonasal approaches to the cranial base or orbit

Contraindications

1. Not medically fit for surgery
2. Largely dehiscent carotid artery (relative)

Preoperative Preparation

1. A course of oral steroids and antibiotics may be considered for 3 to 5 days prior to surgery to reduce inflammation and bleeding and to improve endoscopic visualization.
2. Preoperative medical clearance, if necessary
3. Reverse/manage anticoagulation, if necessary
4. Obtain consent for surgery, including discussion of possible risks, benefits, and alternatives to surgery.

OPERATIVE PERIOD

Anesthesia

General

The use of total intravenous anesthesia (TIVA) may reduce intraoperative blood loss and improve endoscopic visualization. Blood pressure and heart rate should be controlled in the lower range of what is tolerated by the patient, to reduce mucosal bleeding and improve endoscopic visualization. However, in endoscopic skull base surgery where there is preexisting compromise of the optic nerve, mean arterial pressures should be maintained in the normal range.

Local

Topical anesthesia may be used in the office for the revision endoscopic sphenoidotomy that shows restenosis from synechiae formation.

Positioning

Supine

The operating table should be placed in reverse Trendelenburg position to about 20 degrees from the floor to improve endoscopic visualization. The patient's head should be turned slightly toward the surgeon.

Perioperative Antibiotic Prophylaxis

First-generation cephalosporin
Second-generation cephalosporin
Clindamycin if allergic to penicillin

Monitoring

None necessary

Instruments and Equipment to Have Available

1. Basic endoscopic sinus set including Cottle elevator, J curette, mushroom punches, Kerrison punches, straight through-cutting forceps, image navigation probe
2. Zero-degree, 4-mm endoscope
3. Powered shaver/microdébrider
4. Computer-assisted, intraoperative system
5. Topical 1:1000 epinephrine with cotton pledgets

Key Anatomic Landmarks

1. ST. The anterior pole is identified by lateralization of the middle turbinate during the transnasal approach or in the superior meatus just posterior and medial to basal lamella of middle turbinate during transethmoid approach. The sphenoid ostium is universally located medial to the ST.
2. Planum sphenoidale. The roof of the sphenoid sinus just anterior to the thickened tuberculum sellae bone of the skull base. The sphenoid ostium is on average 11 mm inferior to the skull base[1] and is approximately halfway between the floor of the sphenoid sinus and planum sphenoidale. It can be closer to the skull base in sinuses that are poorly pneumatized.
3. Optic nerve and lamina papyracea. The face of the sphenoid inserts laterally on one or both of these structures. The optic nerve may be dehiscent in an Onodi cell, which is a posterior ethmoid air cell with pneumatization posterior to the coronal plane of the face of the sphenoid sinus.
4. Posterior septal branch of the sphenopalatine artery. This artery serves as the vascular pedicle for nasoseptal reconstructive flaps. The vessel runs 2 to 6 mm inferior to the sphenoid ostium, within the mucosa superior to the choana. Unfortunately this vessel can be encountered during enlargement of the sphenoid ostium in an inferior direction toward the nasal floor.
5. Sphenoid face/rostrum. The face of the sphenoid may appear convex by comparison to the ethmoid skull base in the unopened sphenoid sinus. The ostium is located in the medial and inferior quadrant of the rostrum.
6. Choanal arch. The sphenoid ostium is typically found 2 cm superior to the arch of the choana, at the nasopharyngeal inlet.

Prerequisite Skills

For transethmoid approach, see the chapter on endoscopic ethmoidectomy (Chapter 108).

Operative Risks

1. Cerebrospinal fluid (CSF) leak
2. Orbital or optic nerve injury
   This may occur due to imprecise lateral dissection of the face of the sphenoid, an unrecognized Onodi cell containing the optic nerve, or improper entry into the sphenoid sinus at a site distinct from the natural sphenoid ostium. This is a devastating complication and is difficult to manage and/or correct but should lead to an immediate ophthalmology referral for an evaluation of the patient's vision.
3. Arterial hemorrhage
   Care should be taken upon widening of the sphenoid ostium inferiorly, as the posterior septal branch of the sphenopalatine artery may be encountered. The involved mucosa over the sphenoid face/superior choana should be cauterized if this issue is encountered.
4. Internal carotid artery injury
   The artery may be dehiscent within the sphenoid sinus in up to 22% of patients. The sphenoid intersinus septum may insert on the face of the carotid artery in 16% of patients and should be reduced or removed with sharp through-cutting instruments and with great caution.

Endoscopic Transnasal Surgical Technique

- Review of CT scan
  Prior to taking the patient to the operating room, a CT scan with thin cuts (preferably <1.25 mm) is reviewed in all three planes. It may be calibrated to the patient with an intraoperative computer-assisted navigation platform once the patient is intubated.
- Topical nasal preparation
  Placement of decongestant-soaked pledgets (e.g., 1:1000 epinephrine) on the mucosa medial to the middle turbinates to chemically vasoconstrict and reduce the caliber of the nasal mucosal blood vessels and reduce sites of intraoperative bleeding.
- Lateralization of the middle turbinate is carefully performed with a Freer elevator placed onto the inferior aspect of the turbinate head. Pressure is sequentially applied posteriorly until the basal lamella of the middle turbinate is displaced laterally, exposing the anterior pole of the ST.
- Lateralization of the ST with identification of the sphenoid ostium. This may be performed via direct endoscopic visualization and gentle turbinate adjustment using a straight navigation probe or with the Cottle elevator.

- Removal of the most-inferior one-fifth to one-third of the ST that may lie inferior to the sphenoid ostium and obstruct its drainage. A limited posterior ethmoidectomy may be performed by removing cells within the superior meatus to create additional exposure for sphenoidotomy or to help in early identification of landmarks, including the lamina papyracea and ethmoid skull base.
- Blunt dissection to enter the sphenoid ostium and enlarge it
- Widening of the ostium laterally toward the lamina papyracea and superiorly toward planum sphenoidale to ensure long-term patency

Endoscopic Transethmoid Surgical Technique

- Review of CT scan
  Prior to taking the patient to the operating room, a CT scan with thin cuts (preferably <1.25 mm) is reviewed in all three planes. Special attention is given to findings in the ethmoid cavity, the position of the anterior and posterior ethmoid arteries, and the integrity and shape of the orbit and skull base. It may be calibrated to the patient with an intraoperative computer-assisted navigation platform once the patient is intubated.
- Topical nasal preparation
  Placement of decongestant-soaked pledgets (e.g., 1:1000 epinephrine) on the nasal mucosa to chemically vasoconstrict the nasal mucosa and reduce sites of intraoperative bleeding.
- Total ethmoidectomy (see Chapter 108)
  Of note, the basal lamella of the middle turbinate is lowered to allow visualization of the inferior aspect of the ST. The posterior ethmoid cells in the superior meatus are removed to allow manipulation and resection of the ST and identification of the sphenoid ostium.
- Lateralization of the ST with identification of the sphenoid ostium. This may be performed via direct endoscopic visualization and gentle turbinate adjustment using a straight navigation probe or with the Cottle elevator. If a maxillary antrostomy has been performed, the floor of the orbit can be used as the superior limit when searching for the sphenoid ostium, as the sphenoid ostium lies below the level of the floor of the orbit.
- Removal of the most-inferior one-fifth to one-third of the ST that may lie inferior to the sphenoid ostium and obstruct its drainage. This may be accomplished with a straight through-cutting or powered instrument.
- Blunt dissection to enter the sphenoid ostium and enlarge it using J-curette or Cottle elevator
- Widening of the ostium laterally toward the lamina papyracea and superiorly toward planum sphenoidale to ensure long-term patency

Common Errors in Technique

1. Failure to identify the true natural ostium of the sphenoid sinus
2. Dissection inferiorly, through the posterior septal branch of sphenopalatine artery
3. Inadequate blunt dissection of the ostium, leading to difficulty passing the Kerrison or mushroom punch into the ostium
4. Contact with the posterior wall of the sphenoid sinus during ostial identification or dissection may lead to inadvertent injury to the carotid artery or optic nerve.
5. Limited mucosal preservation technique (except in tumor surgery), which can lead to scarring and restenosis of the sinus
6. Insufficient sphenoid ostial enlargement, which may also risk postoperative restenosis
7. Confusion of an Onodi cell/posterior ethmoid air cell for the sphenoid sinus
8. During sphenoidotomy, stripping of the mucosa of the anterior face of the sphenoid away from the rostrum bone, with displacement into the sphenoid sinus proper. This surgical maneuver can lead to loss of landmarks and significant bleeding within the sinus cavity.

POSTOPERATIVE PERIOD

Postoperative Management

1. Standard postsinus surgery instructions should be given.
2. Start saline irrigations on postoperative day 1.
3. In-office débridement and clearance of material from within the sinus cavity (usually performed on postoperative day 7 to 14)
4. Typical medications include antistaphylococcal antibiotics, oral prednisone, and a short course of analgesic medications.
5. In-office endoscopic surveillance for evidence of ongoing inflammation and/or restenosis as indicated

Complications

1. Synechiae
   Postoperative initial follow-up typically helps limit the extent of synechiae formation. If it occurs and also becomes symptomatic, cicatricial scar can often be resected in the office with through-cutting and powered instruments. If circumferential stenosis develops, this can sometimes be enlarged in office under local anesthesia with an elevator and mushroom punch.
2. Loss of olfaction. May result from overresection of ST containing olfactory filiae

Alternative Management Plan

1. Balloon sinuplasty. This procedure allows gentle widening of the ostium through the action of balloon-based dilation of the sphenoid ostium. Sinuplasty has the advantage of performance under local anesthesia in the office as an initial procedure or also in the operating room when combined with other sinonasal interventions. In-office/intraoperative image guidance platforms are available to confirm entry and placement of the balloon tip within the sinus airspace. This procedure may be indicated in patients suffering from chronic sinusitis without nasal polyps or diagnosed with recurrent acute sinusitis.
2. Ongoing medical therapy/observation. In most patients with inflammatory disease of the sphenoid sinus, continued medical therapy is an alternative.

DISCUSSION

Evidence-Based Medicine Question

What is the risk of loss of olfaction with routine endoscopic sphenoidotomy?

Many rhinologic surgeons resect the inferior portion (one-fifth to one-third) of the ST to provide improved access to the sphenoid ostium. The ST has been shown to contain olfactory filae that are responsible for detection of odorants. Loss of olfaction has been associated with a decrease in quality of life.[2] Furthermore, it may result in practical dangers such as failing to detect spoiled food, smoke, natural gas, or other harmful substances.

Olfactory fibers emanate from perforations in the cribriform plate and innervate the olfactory epithelium located in the olfactory region of the nasal cavity, which includes the superior portions of the nasal septum and the medial surfaces of the superior and middle turbinates. A postmortem analysis of tissue from the superior and middle turbinates has shown the greatest concentration of olfactory neuroepithelium to be present in the posterior portion of the ST.[3] Previous authors have expressed concern that overzealous resection of the ST may lead to postoperative hyposmia or anosmia, but nonetheless these authors advocated partial inferior resection of the ST for improved, unobstructed access to the sphenoid ostium.[4]

In perhaps the most directed study on this question to date, histologic analysis of the olfactory neuroepithelium was performed on the inferior portion of the ST taken during endoscopic sinus surgery.[5] Olfactory fibers were detectable in only 16% of specimens. Twelve percent of patients in this cohort had complaints of olfactory loss after surgery, but none of the latter patients had olfactory neurons detectable on histology.

Much is still unknown about the effects on olfaction of endoscopic sinus surgery, including endoscopic sphenoidotomy. At present the available data suggest that resection of the inferior portion of the ST during sphenoidotomy provides a low risk for adverse olfactory outcomes (Fig. 110.3).

Editorial Comment

A third option for opening the sphenoid sinus is to approach in the midline. The posterior septum is disarticulated from the sphenoid rostrum with a Cottle instrument, and the rostral bone is removed with rongeurs or a drill to open both sides of the sphenoid sinus. The opening into the sphenoid sinus is then maximized with Kerrison rongeurs. This approach is advantageous when bilateral access is needed (skull base surgery) or when the natural sphenoid ostium is not visible due to mucosal edema or polypoid tissue. The anterior face of the sphenoid sinus can be safely punctured with a Frazier suction inferomedial to the sphenoid ostium where the bone is thinnest in most cases.

In patients with chronic inflammatory disease and osteitis of the bone, circumferential stenosis of the sphenoidotomy is common postoperatively. A wide sphenoidotomy that extends to the floor of the sinus or crosses the rostrum and intersinus septum will help prevent circumferential scarring and stenosis.

Carl H. Snyderman

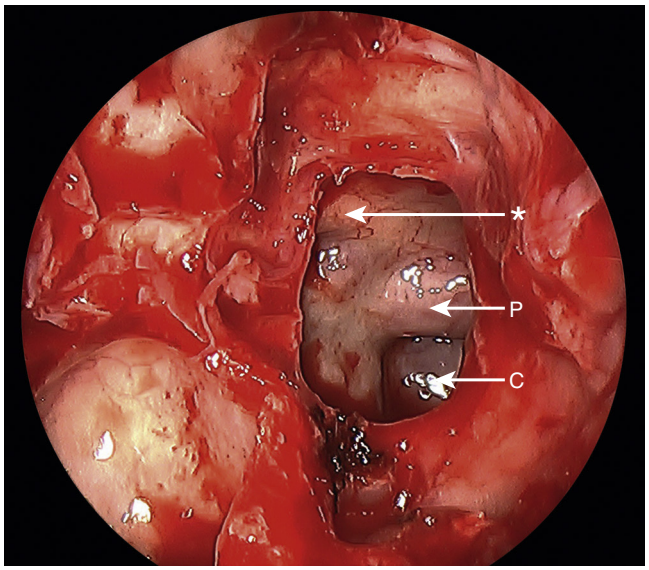

Fig. 110.3. Endoscopic view of right sphenoid sinus after completion of endoscopic sphenoidotomy procedure. The clival recess *(C)* and the pituitary gland *(P)* can be readily observed along the posterior wall of this sinus cavity, and the impression of optic nerve *(*)* is seen in the superolateral corner of this sinus.

Access the review questions online at http://www.expertconsult.com

REFERENCES

1. Halawi AM, Simon PE, Lidder AK, et al. The relationship of the natural sphenoid ostium to the skull base. Laryngoscope 2015;125(1):75–79.
2. Miwa T, Furukawa M, Tsukatani T, et al. Impact of olfactory impairment on quality of life and disability. Arch Otolaryngol Head Neck Surg 2001;127(5):497–503.
3. Pinna Fde R, Ctenas B, Weber R, et al. Olfactory neuroepithelium in the superior and middle turbinates: which is the optimal biopsy site? Int Arch Otorhinolaryngol 2013;17(2):131–138.
4. Orlandi RR, Lanza DC, Bolger WE, et al. The forgotten turbinate: the role of the superior turbinate in endoscopic sinus surgery. Am J Rhinol 1999;13(4):251–259.
5. Say P, Leopold D, Cochran G, et al. Resection of the inferior superior turbinate: does it affect olfactory ability or contain olfactory neuronal tissue? Am J Rhinol 2004;18(3):157–160.

REVIEW QUESTIONS

1. In what quadrant of the sphenoid face is the sphenoid natural ostium located?
   a. Inferior and medial
   b. Inferior and lateral
   c. Superior and medial
   d. Superior and lateral

2. Onto what structure does the sphenoid face insert laterally?
   a. Planum sphenoidale
   b. Lamina papyracea, sometimes optic nerve
   c. Carotid artery
   d. Superior turbinate

3. What artery may be encountered during inferior enlargement of the sphenoid ostium?
   a. Internal carotid artery
   b. Maxillary artery
   c. Posterior septal branch of the sphenopalatine artery
   d. Posterior ethmoid artery

111 Trephination of the Frontal Sinus

Phillip Huyett, Barry Schaitkin

INTRODUCTION

Trephination of the frontal sinus can be used in three ways. Traditionally, it was used for the drainage of acute processes such as a Pott's puffy tumor or bacterial frontal sinusitis. Second, trephination can be combined with transnasal endoscopic approaches to the frontal sinus for severe inflammatory disease or challenging frontal recess anatomy, frequently referred to as a minitrephine.[1] Finally, it can potentially obviate the need for an osteoplastic flap to introduce endoscopes and/or instruments to access far superior and far lateral inflammatory and noninflammatory conditions of the frontal sinus in select cases. This chapter discusses the use of trephination to instill water (minitrephine) or of the trephine as a portal to aid in the performance or outcome of an endoscopic sinus procedure.

KEY OPERATIVE LEARNING POINTS

1. Three-dimensional computed tomography (CT) analysis of the frontal sinus is essential before performing a frontal trephine (Fig. 111.1A).
2. The landmarks for the trephine are the two supraorbital nerve foramina. A line connecting these two points is drawn, with an entry site ideally placed in the medial brow (see Fig. 111.1B).
3. Computer navigation can be helpful in performing a frontal sinus trephine.[2]

PREOPERATIVE PERIOD

History

1. History of present illness
   a. The patient being considered for frontal sinus trephination is one who has failed medical therapy and is a candidate for endoscopic sinus surgery with a current frontal sinus component.
2. Past medical history
   a. Prior endoscopic surgery
   b. Status of the bony boundaries of the frontal sinus and orbits
   c. History of facial trauma or external surgery for the frontal sinus

Physical Examination

1. Nasal endoscopy to assess visualization of the outflow tract of the frontal sinus. This should include the presence of ipsilateral septal deviation and the size and configuration of the middle turbinate.
2. Palpation of the forehead will give a general indication of the bony prominence of the frontal sinus and its likely extent above the brow.
3. Palpation of the supraorbital foramina and testing of sensory function

Imaging

- Maxillofacial CT scan reconstructed in three planes, preferably with navigation capability (see Fig. 111.1B)
- The dimensions of the frontal sinus in sagittal, axial, and coronal planes should be reviewed on CT to establish the safe external position and depth of safe penetration for the trephine burr.

Indications

As endoscopic techniques have improved, so too has the ability of sinus surgeons to address frontal sinus pathology endonasally. The utility of frontal sinus minitrephine, therefore, has become increasingly limited. Frontal sinus trephination does, however, remain a valuable tool as a stand-alone procedure, as an adjunct to frontal sinus endoscopy, and also as a combined endonasal and external approach for the following indications[3,4]:

1. Inflammatory frontal sinus pathology that meets criteria for endoscopic sinus surgery after medical therapy has failed
   a. Acute frontal sinusitis
   b. Chronic frontal sinusitis
   c. Pott's puffy tumor (subperiosteal abscess due to osteomyelitis of frontal bone)
   d. Mucocele
   e. Mucopyocele
2. Inability to resolve pathology with conventional endoscopic technique due to
   a. Inspissated secretions
   b. Altered nasofrontal anatomy (obstructing frontal cells, frontal recess scarring/stenosis and ossification)
   c. Inaccessible pathology (far lateral and superior)
3. Noninflammatory pathology of the frontal sinus
   a. Osteomas
   b. Fibrous dysplasia
   c. Inverted papilloma
   d. Repair of cerebrospinal fluid leak (CSF)
   e. Posterior table frontal sinus fracture
   f. Meningioma

Contraindications

1. Frontal sinus trephination is contraindicated in the patient with a small shallow frontal sinus due to the risk of unintentional drilling through the posterior table. Approximately 15% of nonhypoplastic frontal sinuses will not accommodate safe trephination.[5]

Preoperative Preparation

1. Prepare the nose for traditional endoscopic surgery.
2. Prepare the forehead to include surgical landmarks.
3. Adjust the position of image guidance hardware if necessary to provide full access to trephine landmarks.

OPERATIVE PERIOD

Anesthesia

- General: Although this procedure can be done with local anesthesia with awake sedation, general anesthesia is preferred for patient comfort.

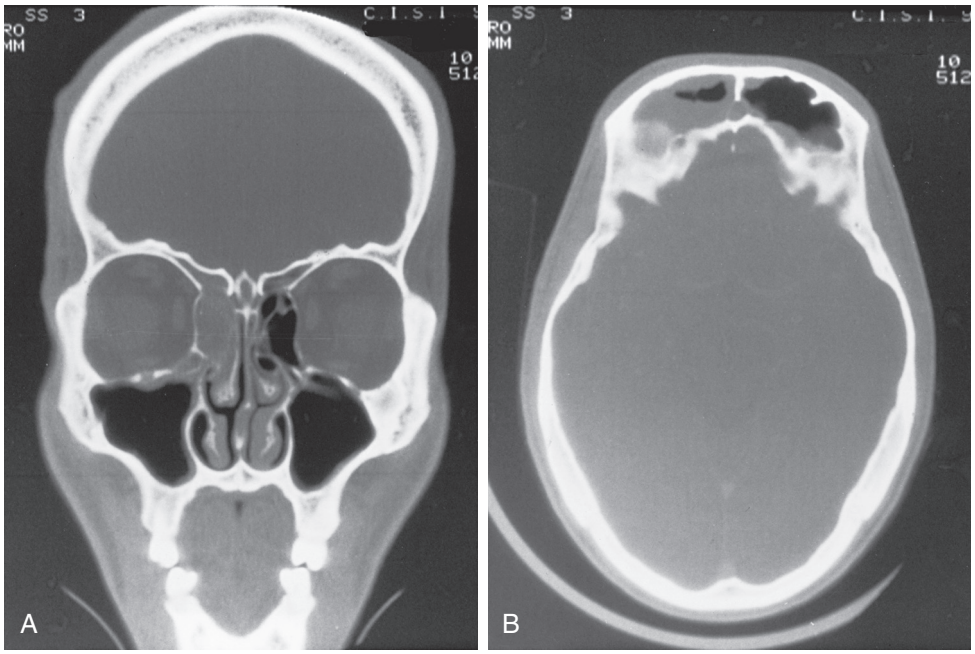

Fig. 111.1. A, Coronal computed tomography (CT) scan demonstrating right-sided frontal opacification with involvement of the anterior ethmoid sinus. **B,** Axial CT scan displaying the air-fluid level in the right frontal sinus.

Positioning

- Supine: The patient is positioned the same as any endoscopic sinus procedure with the head turned slightly toward the surgeon.
- Palpation of the globe during instillation of saline is of utmost importance, so the use of a corneal shield is contraindicated.

Perioperative Antibiotic Prophylaxis

- First-generation cephalosporin to cover skin organisms unless a preoperative sinus culture suggests alternative coverage

Monitoring

- No routine monitoring required

Instruments and Equipment to Have Available

1. A #15 blade for incision
2. Most powered instrument companies manufacture a kit for frontal sinus trephination. Any drill can be used, but a kit will allow for the following advantages:
   a. Protection of the forehead soft tissue with a sleeve
   b. Ability to set a maximal depth of penetration
   c. The sleeve has teeth to grip the periosteum of the frontal bone, allowing for preservation and cannulation of the drill hole by the surgeon.
   d. A metal stylet for Seldinger technique
   e. A fluted irrigation canula to allow for a tight fit of the grommet to the frontal bone
3. Intravenous connecting tube
4. A 60-mL syringe
5. Culture swab
6. Normal saline for irrigation
7. Fast-absorbing 6-0 suture for closure

Key Anatomic Landmarks

1. A line connecting the supraorbital notches on each side guides the surgeon to a safe zone within which to enter the pneumatized portion of the frontal bone just above the medial brow (see Fig. 111.1).

Prerequisite Skills

1. Endoscopic techniques
2. Drilling skills

Operative Risks

1. Soft tissue burn of the skin of the forehead
2. Infection of the bone of the trephine site
3. Depression of the soft tissues into the trephine site if the trephine is large enough to allow for a scope and instrumentation and not just for the instillation of fluids
4. CSF leak if the posterior table is violated
5. Eye injury via irrigation into orbit from frontal bone dehiscence or corneal abrasion from working near globe

Surgical Technique

Mini–frontal sinus trephination (see video 111.1)

- Complete endoscopic nasofrontal dissection to the extent necessary to ensure trephination.
- Confirm anatomic landmarks with navigation, if available, or use palpable landmarks.
- Inject 1 mL of local anesthetic with epinephrine in planned incision site to provide vasoconstriction.
- Make a stab incision with a #15 blade in the medial brow along a line connecting the supraorbital foramina on a flat portion of the frontal bone.
  - The elasticity of the skin in this region will allow for the sinusotomy to be placed superiorly in the anterior table of the frontal sinus.

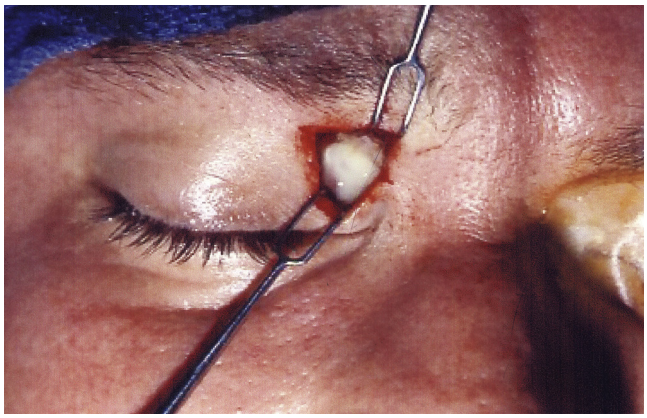

Fig. 111.2. Trephination of the frontal sinus for acute frontal sinusitis.

- While elevating the brow with the nondominant hand, dissect bluntly down to the frontal bone, leaving the periosteum in place.
- Place the soft tissue sleeve with the nondominant hand, and engage the soft periosteum with the teeth of the sleeve.
- Drill at a relatively slow speed with constant irrigation using preoperative sinus dimensions to guide maximum allowable penetration.
- Remove drill, maintaining the position of soft tissue sleeve.
- Insert a metal stylet, remove the sleeve, and, using the Seldinger technique, place the fluted frontal sinus grommet.
- Connect a 60-mL saline syringe and withdraw to confirm no clear fluid or blood.
- A diseased sinus may yield purulent material, a sample of which can be sent for culture. Air will be aspirated from an aerated sinus. Either confirms placement in the sinus.
- Slowly instill water, monitoring orbital tension with palpation and simultaneously observing endoscopically for confirmation of the frontal sinus outflow tract.
- Depending on indication, proceed with endonasal work on frontal recess or complete irrigation of sinus.
- The skin is closed with a single 5-0 or 6-0 fast gut suture. Alternatively, the grommet can be left in place for continued frontal sinus irrigation and removed at a later time.

Traditional frontal sinus trephination

- Once the need for a frontal sinus trephination has been determined, local anesthetic with epinephrine is injected into the medial brow.
- A 1-cm incision is made with a #15 blade in the medial brow.
  - Alternatively, if the trephine is being used to insert instruments, including scopes, many authors will use a Lynch incision and a more inferior approach, where the bone is thinner.
- Blunt dissection is performed down to the periosteum while retracting the brow superiorly with the nondissecting hand Fig. 111.2.
- The periosteum is incised with a #15 blade and elevated with a Freer elevator or cottle.
- A cutting burr is used to drill through the anterior table of the frontal sinus with care not to violate the posterior table Fig. 111.3.
- If a portal is to be used for instrumentation, create an adequate portal to
  - Visualize instrument endonasally
  - Or visualize frontal sinus via trephine and pass instrument endonasally
  - Or make an adequate portal for both instrument and endoscope and address lateral pathology via the trephine portal
- Two-layer closure with a 4-0 absorbable suture deep and 5-0 or 6-0 fast gut suture superficially

Common Errors in Technique

1. Loss of brow hair follicles by beveling knife during incision
2. Inability to find drill hole after drill bit is removed because of slippage of sleeve protecting soft tissue or lack of use of a sleeve
3. Failure to irrigate or excessive drill speed leading to increased heat and a thermo injury to bone and soft tissue
4. Failure to prevent burr penetration beyond inner aspect of anterior frontal sinus table, causing CSF leak
5. Poor patient selection (patient with small sinus) or inability to reach pathology

POSTOPERATIVE PERIOD

Postoperative Management

1. Standard postoperative antibiotics, ideally culture-directed
2. Wound care to include 5 days of topical antibiotic cream to frontal suture site
3. Pain medication as in normal endoscopic sinus surgery
4. Saline irrigations
5. Resumption of anticoagulants/antiplatelet drugs
6. Rarely, a patient will be discharged home with the trephine grommet or catheter in place to perform self-irrigation, usually with antibiotics.

Complications

1. If soft tissue burn occurs from the drill, excise and close soft tissue.
2. If posterior table injury occurs with CSF leak, manage by whichever route may be required to provide adequate exposure, including, if necessary, conversion to open technique. Always obtain a postoperative CT scan to ensure that there is no intracranial extension.
3. If, during instillation of saline, the orbit begins to protrude, stop irrigation and withdraw. The body will reabsorb the saline fairly quickly with gentle orbital massage with no need for canthotomy. If, upon extubation, the patient has visual complaints, an ophthalmology consult should be obtained.
4. Continued frontal sinus process due to recurrent disease or scar
5. Forehead hypoethesia related to excessive retraction or inappropriate incision location in traditional trephination
6. Infection related to improper skin care postoperatively

Alternative Management Plan

1. Advanced frontal sinus technique (Draf 1 to 3)[6] (see Chapter 113)
2. Balloon sinuplasty (see Chapter 102)
3. Bicoronal incision with osteoplastic flap (see Chapter 114)

DISCUSSION

Evidence-Based Medicine Question

Is minitrephination of the frontal sinus beneficial in identifying the frontal sinus outflow tract in the era of advanced endoscopic techniques?

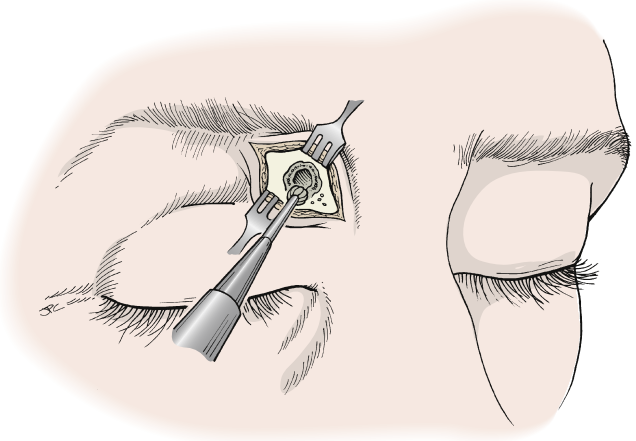

Fig 111.3. Trephination is performed through an incision made in the medial aspect of the brow. The floor of the frontal sinus is exposed, and a drill with a cutting burr is used to create an opening in the floor of the frontal sinus. The lateral wall of the nasal frontal recess is then removed to provide communication between the frontal sinus and the middle meatus.

Yes, in a retrospective case series of 163 patients, the frontal sinus outflow tract was successfully identified in all cases.[7] There were a total of 149 bilateral and 39 unilateral frontal sinus minitrephines performed in patients undergoing frontal sinus surgery for severe inflammatory disease (mean Lund-Mackay score 17.5) Fig. 111.2. Minitrephine was indicated based on severe edema (n = 50), a narrowed frontal recess (n = 35), obstructing frontal cells (n = 26), and to assist in frontal sinus drill out (n = 77). There were seven patients who experienced complications, most commonly trephine site infection (n = 4). Follow-up was a mean of 25.5 months, with a 92% frontal sinus patency rate.

Editorial Comment

Frontal sinus trephine was more commonly performed prior to image guidance and more refined frontal sinus instrumentation. With this minimal incision, instillation of liquid via a trephination can aid in the identification of the frontal outflow tract as well as the irrigation of trapped secretions. Because extended endoscopic frontal sinus procedures are increasingly used and commonplace, the ability to manage frontal sinus disease via an endonasal corridor has also increased. However, in certain anatomic locations, problematic cases of chronic frontal sinusitis remain challenging. When frontal sinus pathology is present lateral to the midpupillary line, external approaches to the frontal sinus, such as a trephine, are used to access the lateral frontal recess. Familiarity with this safe and effective technique remains invaluable for the Otolaryngologist who treats frontal sinus disease.

Barry M. Schaitkin

Access the review questions online at http://www.expertconsult.com



REFERENCES

1. Batra PS, Citardi MJ, Lanza DC. Combined endoscopic trephination and endoscopic frontal sinusotomy for management of complex frontal sinus pathology. Am J Rhinol 2005;19(5):435–441.
2. Zacharek MA, Fong KJ, Hwang PH. Image-guided frontal trephination: a minimally invasive approach for hard-to-reach frontal sinus disease. Otolaryngol Head Neck Surg 2006;135(4):518–522.
3. Patel AB, Cain RB, Lal D. Contemporary applications of frontal sinus trephination: a systematic review of the literature. Laryngoscope 2015;125(9):2046–2053.
4. Cohen AN, Wang MB. Minitrephination as an adjunctive measure in the endoscopic management of complex frontal sinus disease. Am J Rhinol 2007;21(5):629–636.
5. Lee AS, Schaitkin BM, Gillman GS. Evaluating the safety of frontal sinus trephination. Laryngoscope 2010;120(3):639–642.
6. Wormald PJ. Salvage frontal sinus surgery: the endoscopic modified Lothrop procedure. Laryngoscope 2003;113(2):276–283.
7. Seiberling K, Jardeleza C, Wormald PJ. Minitrephination of the frontal sinus: indications and uses in today's era of sinus surgery. Am J Rhinol Allergy 2009;23(2):229–231.

REVIEW QUESTIONS

1. Landmarks for frontal sinus trephination include
   a. The lateral eyebrow
   b. A line drawn between supratrochlear notches
   c. A line drawn between supraorbital notches
   d. A line drawn between the infraorbital foramina

2. Potential complications of frontal sinus trephination include all of the following, except
   a. Anosmia
   b. Increased intraocular pressure due to irrigation
   c. CSF leak
   d. Soft tissue burn

3. What percentage of frontal sinuses will not accommodate trephination?
   a. 5%
   b. 15%
   c. 40%
   d. 80%

112 Endoscopic Approach to the Frontal Sinus

Barry M. Schaitkin, Li-Xing Man

INTRODUCTION

The endoscopic approach to the frontal sinus is predicated on understanding the anatomy of the frontal recess. The frontal sinus outflow tract is dependent on the anatomic relationships of various structures, including the uncinate process, middle turbinate, agger nasi, and frontoethmoid cells. Most commonly, the uncinate process ascends from its inferior and anterior attachments to the inferior turbinate and lacrimal bone, respectively, to blend in with the medial wall of the agger nasi cell (Fig. 112.1).[1] In such cases—85% of the time—the frontal sinus will drain between the uncinate process and the middle turbinate. In the remaining cases, the uncinate attaches to the middle turbinate or the skull base, resulting in the frontal sinus draining directly into the infundibulum. If the uncinate attaches both medially to the middle turbinate and laterally to the agger nasi, the frontal sinus will drain posteriorly.

KEY OPERATIVE LEARNING POINTS

- Excellent understanding of frontal sinus anatomy is imperative to achieve optimal surgical outcomes.
- Preoperative preparation with review of computed tomography (CT) scan anatomy using imaging software capable of three-dimensional multiplanar reconstructions similar to the software incorporated by image guidance systems is strongly encouraged.
- Proper exposure and visualization are fundamental to good frontal sinus surgery.

PREOPERATIVE PERIOD

History

1. History of present illness
   a. Patients with chronic frontal sinus disease are considered surgical candidates according to the same criteria as for other endoscopic sinus surgery. They should have significant symptoms of sinusitis in accordance to the criteria proposed by the American Academy of Otolaryngology–Head and Neck Surgery despite maximal medical therapy.
   b. Those with isolated or severe forehead/frontal pain relative to other symptoms should be counseled that their main complaint may not improve with endoscopic sinus surgery even when imaging reveals frontal disease.
2. Past medical history
   a. Relevant comorbidities include the presence or absence of aspirin sensitivity, asthma, atopy, and eosinophilia.
   b. New or continued frontal sinus problems despite prior history of sinus surgery may suggest chronic inflammatory disease of the sinonasal mucosa or scarring of the frontal recess such as from synechiae between the middle turbinate and the lateral nasal wall or between the middle turbinate and the anterior face of a suprabullar cell.

Physical Examination

1. Nasal cavity
   Nasal endoscopy may reveal significant inflammation in the middle meatus such as from nasal polyps. Patients who have previously undergone sinus surgery may have visible scarring in the frontal recess or anterior ethmoid cells. The location and quality of secretions should be noted.
2. Face
   Although thankfully rare, complications from frontal sinusitis may present with abnormal findings on physical examination. Orbital complications may present as proptosis or orbital cellulitis. Visible, palpable swelling of the forehead may suggest osteomyelitis and subperiosteal abscess of the anterior table (Pott's puffy tumor).

Imaging

1. CT scan of the sinuses
   All patients undergoing frontal sinus surgery should have a CT scan of the sinuses performed. Modern radiation dose-reducing CT scanners, which reduce radiation exposure by up to 40%, may be used to obtain fine-cut images (0.6 to 1.0 mm) through the sinuses that are adequate for creating multiplanar reconstructions for preoperative planning, as well as intraoperative image guidance with negligible increase in overall radiation dosage. Most frequently, fine-cut axial images are used to reconstruct coronal and sagittal images for image guidance, but some systems have the ability to reconstruct from coronal slices as well. Preoperatively, review of images in both the coronal and sagittal planes may be useful. When intraoperative image guidance is considered, we strongly encourage preparation with the use of imaging software capable of multiplanar reconstruction, often abbreviated as MPR, which allows the surgeon to review all three planes simultaneously with crosshairs in each plane much like what is provided during surgery.[2]

   Radiographs should be reviewed carefully before surgery to evaluate the uncinate process, agger nasi region, and the size and depth of the frontal sinus. The most important aspect of surgical planning is accurate understanding of the three-dimensional impact of the size and configuration of all cells surrounding the frontal recess. Images should be reviewed to note the position of the anterior ethmoid artery and the presence or absence of supraorbital ethmoid cells. Patients should be suspected of having supraorbital ethmoid cells if multiple septations are seen within the frontal sinus on coronal images. Preoperative three-dimensional

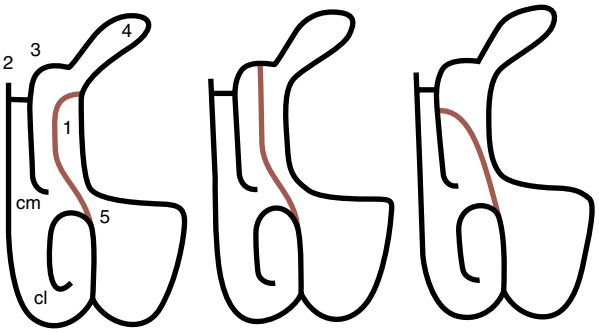

Fig. 112.1. Line diagram of the uncinate attachment.

models may also be created to further understand the frontal sinus drainage pathway in preparation for surgery.[2]
2. Magnetic resonance imaging (MRI)
Although MRI is not routine, it may be helpful in patients with known or suspected tumors or mucoceles involving the frontal sinuses.

Indications

1. Chronic frontal sinusitis refractory to maximal medical therapy, including the following:
   a. Eosinophilic or noneosinophilic inflammatory chronic rhinosinusitis with or without nasal polyposis
   b. Mechanical obstruction
      1) Anatomic variants of frontal recess structures
      2) Osteomas
   c. Frontal sinus mucoceles
2. Acute frontal sinusitis with
   a. Severe disease refractory to medical management (i.e., intravenous antibiotics)
   b. Intracranial or orbital complications
3. Limited tumors involving the frontal sinus that do not require an open procedure

Contraindications

1. Uncomplicated acute frontal sinusitis
2. Extensive tumors involving the frontal sinus that may benefit from open surgery
3. Medical comorbidities with increased risk for general anesthesia
4. Inadequate surgical instrumentation or surgeon expertise

Acute frontal sinusitis is *not* usually a good indication for endoscopic frontal sinus surgery. These patients have significant hyperemia and inflammation, and there is a high likelihood of creating symptomatic scarring in the frontal recess. If there are intracranial or orbital complications from acute frontal sinusitis that are refractory to intravenous antibiotics, the decision to intervene surgically via a classic frontal sinus trephination versus an endoscopic approach may be considered on a case-by-case basis.

Preoperative Preparation

1. Discontinue antiplatelet drugs.
2. Systemic steroids and/or antibiotics may be used to decrease vascularity and edema in the frontal recess. Given the limited confines of the frontal recess, bleeding and the resultant decreased visibility may compromise the surgical dissection.

OPERATIVE PERIOD

Anesthesia

- General anesthesia with oral endotracheal intubation is preferred for patient comfort and protection of the airway. Compared with monitored anesthesia, general anesthesia also minimizes the risk of unexpected patient movement during delicate dissection of the frontal recess.
- Taping of the endotracheal tube should be limited to the lower lip. For the right-handed surgeon an oral Ring-Adair-Elwyn (RAE) tube placed to the left of the tongue and taped to the left lower lip provides ideal access to the nasal cavity.

Positioning

- The patient is positioned supine in the same way as any endoscopic sinus surgery procedure, per surgeon preference. The head may be turned slightly toward the surgeon.
- Elevating the head by 30 degrees may decrease intraoperative bleeding.
- The eyes should be undraped and available for visualization and palpation.

Perioperative Antibiotic Prophylaxis

- There is no evidence-based indication for intraoperative antibiotics, although frequently a first-generation cephalosporin (or clindamycin if patient is penicillin or cephalosporin allergic) is used at induction per surgeon preference.
- If postoperative packing material is used, the surgeon may elect to prescribe a first- or second-generation cephalosporin. The junior author will often prescribe 1 week of cefadroxil, a first-generation cephalosporin with twice daily dosing, to improve patient adherence rather than the more commonly prescribed cephalexin.

Monitoring

- No monitoring is necessary.

Instruments and Equipment to Have Available

1. Basic endoscopic sinus surgery set
2. Frontal sinus surgery set
3. 0-, 30-, 45-, and 70-degree endoscopes; "reverse-post" angled endoscopes are helpful to allow the light cord to up and away from instruments
4. Angled microdébrider tips and/or drill burs, if the use of powered instrumentation is anticipated
5. Navigation system, if image guidance is to be used. Some authors prefer to use navigation in all frontal sinus cases and others just in revision or difficult cases. There is currently no evidence that image guidance improves outcomes.

Key Anatomic Landmarks

- The endoscopic approach to the frontal recess is predicated upon dissecting and navigating around surrounding structures, including the following:
  - Anterior—uncinate, agger nasi, and Kuhn-type frontal cells
  - Posterior—ethmoid bulla, suprabullar, and supraorbital ethmoid cells
  - Lateral—uncinate, agger nasi, and Kuhn-type frontal cells prior to dissection and lamina papyracea after removal of anterolaterally based cells
  - Medial—attachment of the middle turbinate and lateral lamellae of the cribriform plate
- The axilla of the middle turbinate as it attaches to the lateral nasal wall marks the anteroinferior limit of the agger nasi region.
- The slope of the posterior table of the frontal sinus as it joins the ethmoid skull base determines the anterior-to-posterior dimension of the frontal recess after frontal sinusotomy.
- If a supraorbital ethmoid cell is present, the true frontal recess will be medial and anterior to the opening of the supraorbital ethmoid cell.
- The anterior ethmoid artery is often at the posterior margin of the frontal recess (Fig. 112.2).

Prerequisite Skills

- Advanced endoscopic sinus surgery skills, including the facile ability to use angled 45- and 70-degree endoscopes

- Capability to integrate axial, coronal, and sagittal CT images into a three-dimensional understanding of the anatomy

Operative Risks

- Intraoperative hemorrhage, including injury of the anterior ethmoid artery
- Cerebrospinal fluid (CSF) leak
- Stripping of mucosa will increase the risk of postoperative synechiae formation

Surgical Technique

- To maintain a dry field, oxymetazoline 0.05% spray may be given at 10-minute intervals in the preoperative holding area for 30 minutes. Alternatively, the oxymetazoline 0.05% may be applied via ½- by 3-inch radiopaque neurosurgical patties in the nasal cavity after induction while the patient is being positioned for surgery.
- All procedures are done with the injection of local anesthetic, 1% lidocaine, and a vasoconstrictor, 1:100,000 epinephrine. The injections may include the superior attachment of the middle turbinate, the inferior aspect of the uncinate process, and the junction of the middle turbinate basal lamella with the palatine bone.
  - The junior author bends the needle at 45 degrees approximately 1.5 cm from the tip and enters the lateral nasal wall along the maxillary line just above the inferior turbinate, advancing the needle submucosally superiorly toward the axilla of the middle turbinate. The injection is performed while withdrawing the needle slowly (Video 112.1 Maxillary line injection). This results in a single puncture site inferiorly, away from the area of frontal sinus surgery.
  - A 25- to 27-gauge needle on a 3-mL syringe is ideal for the superior attachment of the middle turbinate and uncinate injection, and a 22-gauge spinal needle bent at 45 degrees 1.5 cm from the tip on a 3-mL syringe allows for more rigidity and easy access to the area of the sphenopalatine artery branches as they exit the palatine bone (Video 112.2 Sphenopalatine area injection).
- Neurosurgical patties with oxymetazoline and/or adrenaline are then placed in the middle meatus and over the nasal swell body after the local is injected.
- The surgery commences after local anesthetic and vasoconstrictor have had 5 minutes to take effect.

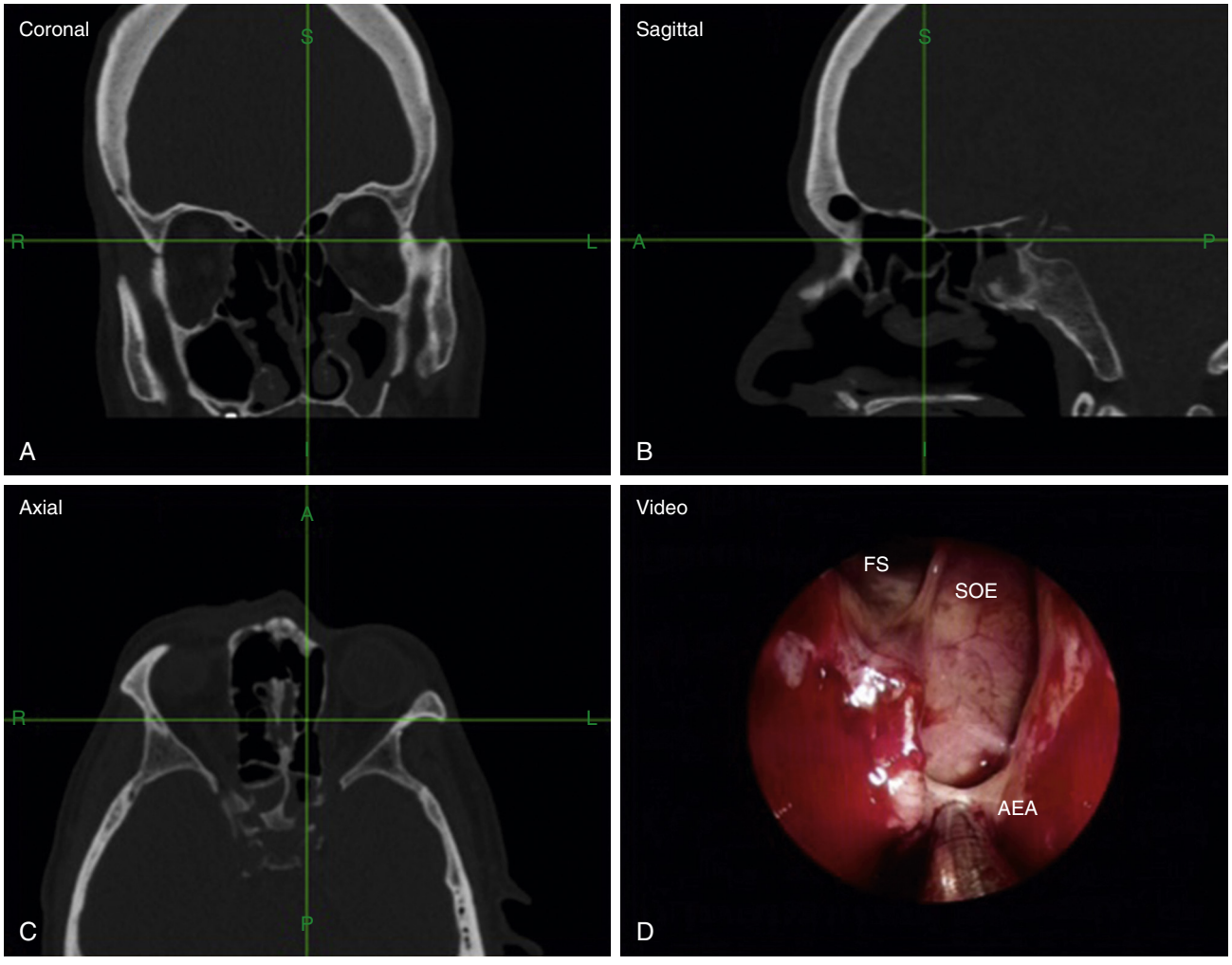

Fig. 112.2. Image guidance localization of the anterior ethmoid artery (AEA) at the posterior border of the opening to the frontal sinus (FS) and supraorbital ethmoid (SOE) cell in the coronal **A**, sagittal **B**, and axial **C** planes. The endoscopic **D** view shows the image guidance suction on the AEA. The suction navigator and crosshairs are localized on the bone surrounding the anterior ethmoid artery. Note the partition between the frontal recess and the supraorbital ethmoid cell. The frontal recess is medial and anterior to the supraorbital ethmoid cell opening.

Basic Endoscopic Surgery of the Frontal Recess

- The approach to the frontal sinus starts with uncinectomy. There are various techniques for uncinectomy that may be used depending on surgeon preference, including removal using (1) a backbiter and 90-degree Blakesley forceps; (2) microdébrider; and (3) sickle knife. A Hosemann punch or an angled Stammberger mushroom punch may be used to remove bone from the nasofrontal process between the anterior superior attachment of the middle turbinate and lamina papyracea, which forms the anterior wall of the agger nasi region (Fig. 112.3).[3] This allows the use of less-angled endoscopes in the initial dissection and may be understood conceptually as a simplified version of the axillary flap technique[4] when a mucosal flap is unnecessary.
- Dissection of the frontal recess requires frontal sinus instruments and a precise appreciation of the patient-specific anatomy of this region. Readers should review and understand the classification of frontoethmoid cells by Kuhn et al.[5] It is also useful to learn some of the other, more recently proposed, nomenclature systems.[6,7] An ethmoidectomy based on the extent of disease should be performed prior to dissection of the frontal recess to provide adequate space for instruments to work along the ethmoid skull base from a posterior-to-anterior direction.
- The frontal recess is approached from a posterior-to-anterior and a medial-to-lateral direction, staying anterior, lateral, and inferior to the thin lateral lamella of the cribriform plate and posterior table of the frontal sinus.
  - Generally a 30-degree reverse-post endoscope is used in the initial more posterior and inferior limits of dissection, gradually switching to more angled endoscopes as the dissection proceeds anteriorly and superiorly.
  - The anterior ethmoid artery is often identified at the posterior border of the supraorbital ethmoid cell (when present) or at the posterior aspect of the frontal recess as one advances from posterior to anterior.
  - If intraoperative image guidance is used, an angled 70- or 90-degree navigational seeker may be gently slipped into the frontal sinus to confirm the frontal drainage outflow pathway even before significant dissection has commenced (Fig. 112.4).
- Because the frontal sinus most commonly drains between the middle turbinate and the agger nasi-uncinate complex, the drainage pathway is most frequently medial and posterior to the posterior wall of the agger nasi. The medial and posterior walls of the agger nasi and type I or II frontal cells are removed because they are not involved in the skull base. These cells may be resected either sharply with angled frontal sinus punches (Fig. 112.5, Video 112.3) or fractured in a posterior-to-anterior direction using 55- or 90-degree curette under visualization with a 45- or 70-degree endoscope. Bone fragments are then removed using angled non-cutting "giraffe" forceps or an angled microdébrider, taking care to avoid grabbing and stripping mucosa (Fig. 112.6, Video 112.4). During challenging dissections, sometimes changing the angle of view (e.g., from a 45- to 70-degree endoscope) may allow the surgeon to understand the anatomy in a new light and progress with the surgery.

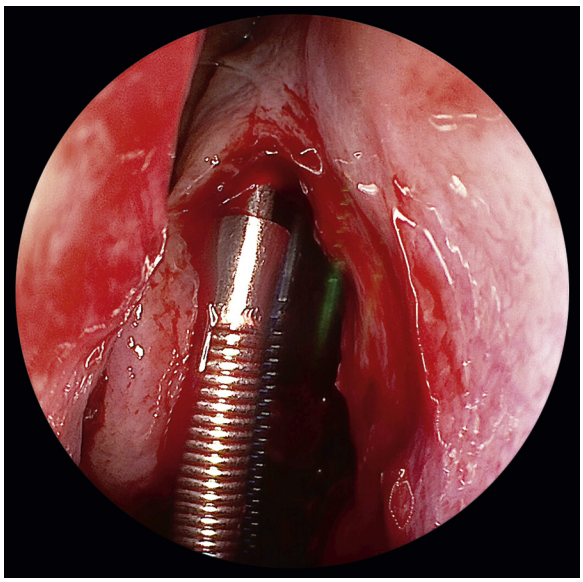

Fig. 112.3. Removal of bone from the nasofrontal process using a Hosemann punch.

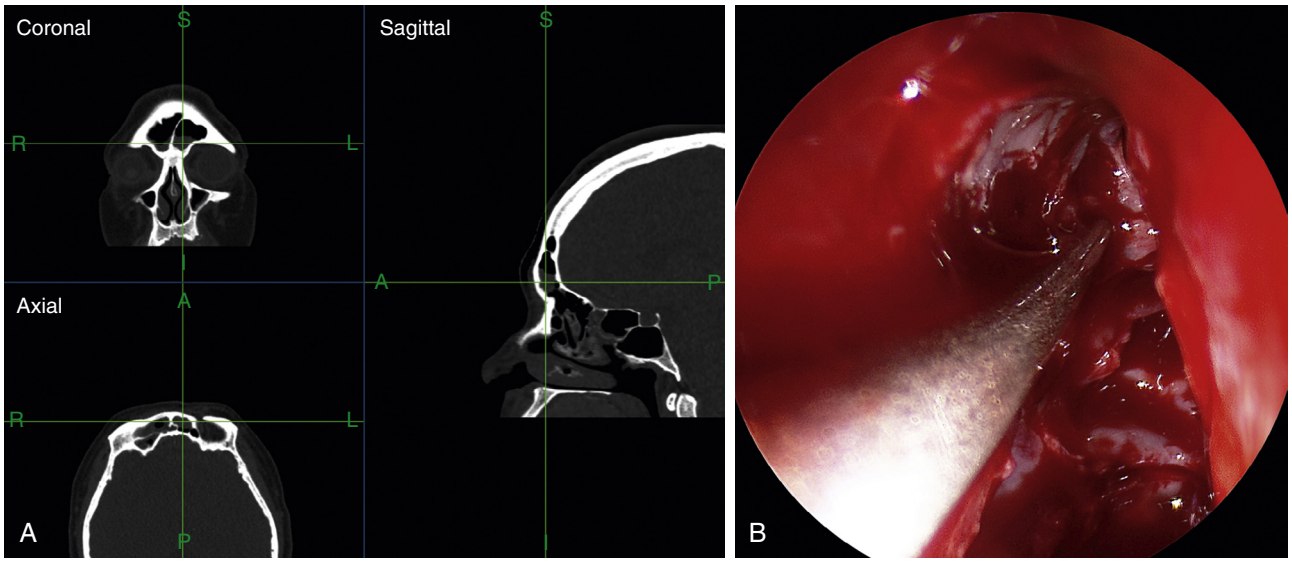

Fig. 112.4. Image guidance using tri-planar computed tomography imaging **A** with 45-degree endoscopic view **B**. Insertion of an angled image guidance seeker into the frontal sinus may help delineate the frontal outflow pathway even before significant dissection has occurred.

- After the agger nasi and any Kuhn frontal cells are removed, the opening to the frontal sinus may be enlarged anteriorly and laterally using a Hosemann frontal sinus punch (Karl Storz, Tuttlingen, Germany) or an angled Kerrison (Bachert) punch (Fig. 112.7). The frontal sinus is then typically left alone.
- Rarely, the frontal sinus opening is stented, depending on the diameter of the frontal sinus opening and degree of mucosal inflammation. Relative indications for stenting include (1) narrow ostial diameter (<5 mm); (2) extensive or circumferential mucosal trauma with bone exposure; (3) severe polyposis or mucosal hyperplasia; (4) destabilized or lateralized middle turbinate; and (5) frontoethmoid mucoceles indicative of long-standing chronic sinus disease or prior surgical failures.[8,9]

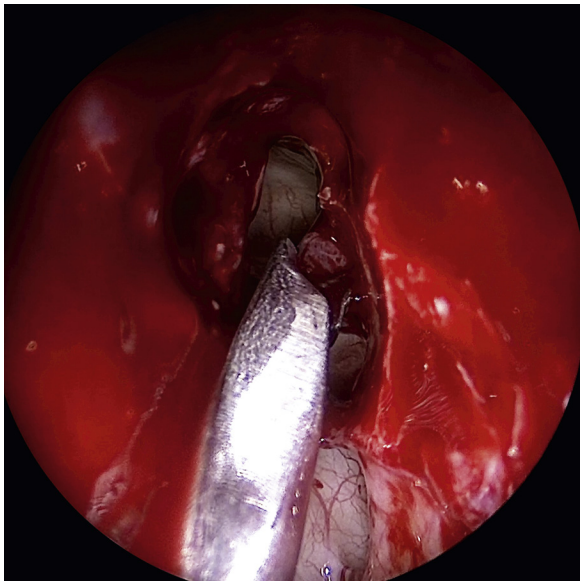

Fig. 112.5. Intraoperative photo demonstrating the use of a frontal sinus punch to remove a bony partition.

Frontal Sinus Rescue

- Surgeons should have multiple techniques in their armamentarium for coping endoscopically with a troublesome frontal sinus. One of the most common problems encountered in revision endoscopic surgery of the frontal sinus is a lateralized middle turbinate stump when a previous surgeon has removed the inferior aspect of the middle turbinate. This may be effectively dealt with using the frontal sinus procedure as described by Kuhn et al.[10]
  - This procedure involves a mucoperiosteal flap rotation. The middle turbinate stump may be scarred to the agger nasi, Kuhn-type frontal cells, or the lamina papyracea.
  - The synechiae between the middle turbinate and lateral structures is removed, and the frontal recess is identified and entered.
  - The nasal mucosa and sinus mucosa are dissected off the medial and lateral aspects of the bony middle turbinate remnant, respectively.
  - Next, the middle turbinate bone and nasal mucosa are resected at the skull base. The flap of the frontal sinus mucosa is subsequently rotated superiorly and medially to cover the roof of the nasal vault.

Common Errors in Technique

- Through-cutting instruments should be used whenever possible to avoid stripping of mucosa.
- Punches such as the Hosemann should be cleaned regularly during the procedure to maintain sharp cutting surfaces and to avoid spillage of loose bone and mucosa in the surgical field.
- The angled scopes do not have to be constantly in the 12-o'clock position. The light post may be moved slightly to rotate the angle of view for improved visualization.
- Oozing of blood in the tight confines of the frontal recess may limit visualization. Rather than continue with dissection through this blood, the oozing is usually easily controlled by temporarily placing oxymetazoline- and/or adrenaline-soaked neurosurgical patties prior to continuing with surgery.

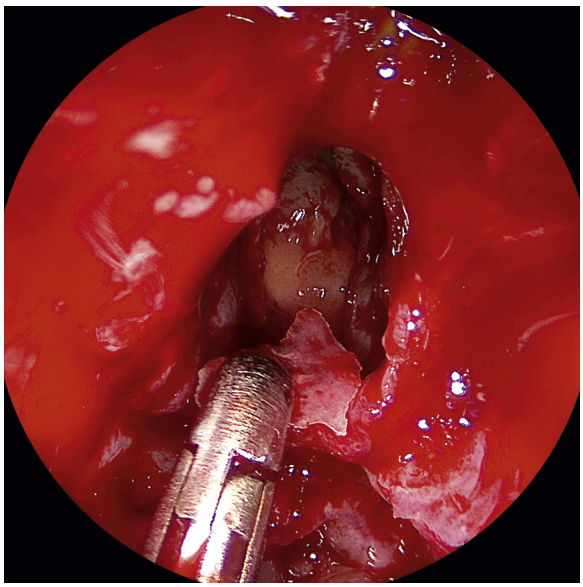

Fig. 112.6. Intraoperative photo demonstrating the use of an angled non-cutting forceps to remove a bone fragment.

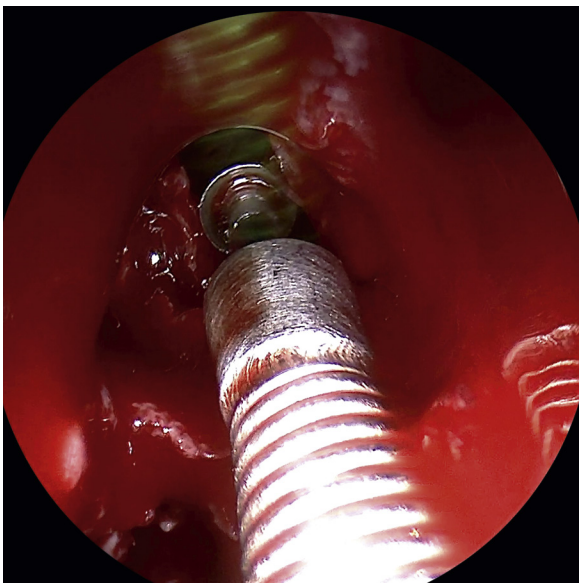

Fig. 112.7. Intraoperative photo demonstrating the use of a Hosemann punch to enlarge the frontal sinus opening.

POSTOPERATIVE PERIOD

Postoperative Management

- These surgical procedures are typically performed on an outpatient basis.
- No packing, an absorbable or nonabsorbable dressing, or a steroid-eluting stent may be placed at the end of surgery, depending on surgeon preference. The authors typically use either no dressing or a self-absorbing dressing in the middle meatus and anterior ethmoid area, below the frontal recess. A dressing may be considered, especially if the middle turbinate has been destabilized during surgery or if treatment with topical steroids in the immediate postoperative period is desired.
- Frequent isotonic saline irrigations using a low-pressure, high-volume (240 mL) squeeze bottle, multiple times per day, are started on postoperative day 1.
- Meticulous and gentle postoperative débridement is performed in the clinic approximate 1 and 2 weeks after surgery. With respect to the frontal sinus, these procedures provide the opportunity to lyse early synechiae and to remove fibrinous debris from the frontal recess.

Complications

1. Hemorrhage
2. Synechiae
3. Unintended entry into the central nervous system and resultant cerebrospinal fluid rhinorrhea
4. Unintended entry into the orbit

Alternative Management Plan

- Limited frontal sinus disease may be addressed using balloon dilation techniques (see Chapter 102).
- Severe, complicated acute frontal sinusitis may be managed with classic frontal sinus trephination (see Chapter 19).
- More significant chronic frontal sinus disease may be managed with frontal sinus drill out procedures (Draf IIB, Draf III) (see Chapter 24).
- Select cases may require frontal sinus obliteration or cranialization, although the indications for such procedures are shrinking as endoscopic instrumentation and skills become more widespread.
- Patient disease, surgeon comfort and expertise, as well as the availability of surgical instrumentation may dictate that open frontal sinus surgery be performed.

DISCUSSION

Evidence-Based Medicine Question

Does the use of image guidance for frontal sinus surgery reduce complications or improve outcomes?

Answer

Although navigation is often used for primary or revision frontal sinus surgery, most individual studies on image-guided surgery (IGS) do not show evidence of benefit to the patient or surgeon with the use of this technology. However, when data from multiple studies are pooled, there is evidence that the use of image guidance in endoscopic sinus surgery may reduce the risk of complications. In a meta-analysis of 14 studies comparing IGS versus non-IGS patient cohorts, major complications—defined as inadvertent entry into areas beyond the nasal cavity and/or paranasal sinuses, postoperative bleeding requiring surgical or angiographic intervention, and the need to abort the procedure for a surgical reason—were greater in the non-IGS group (relative risk [RR] 0.48; 95% confidence interval [CI] 0.28 to 0.82; P = .007). Total complications were also more common in the non-IGS group (RR 0.66; 95% CI 0.47 to 0.94; P = .02).

Reference: Dalgorf DM, Sacks R, Wormald PJ, et al. Image-guided surgery influences perioperative morbidity from endoscopic sinus surgery: a systematic review and meta-analysis. Otolaryngol Head Neck Surg 149(1):17-29, 2013.

Editorial Comment

The indications for an endoscopic frontal sinusotomy remain an area of investigation. Endoscopic frontal sinusotomy has traditionally been classified using the Draf system. Draf I essentially is an ethmoidectomy without manipulation of the frontal recess. This chapter describes a Draf IIA, the most common endoscopic frontal sinus surgery. By removing the bony partitions of the frontal recess between the middle turbinate and the orbit, the maximum bony dimensions of the frontal recess are created with preservation of normal structures, specifically the middle turbinate. In general, this is a highly effective procedure in most cases of chronic rhinosinusitis. In cases of severe polyposis, some surgeons advocate extended frontal sinus procedures, such as a Draf IIb and Draf III procedure, which extend the surgical resection beyond the frontal recess and resect part or all of the floor of the frontal sinus. However, there are limited data to determine when extended approaches should be favored over a Draf IIa frontal sinusotomy.

Eric W. Wang

Access the review questions and additional sources list online at http://www.expertconsult.com

REFERENCES

1. Wormald PJ. The agger nasi cell: the key to understanding the anatomy of the frontal recess. Otolaryngol Head Neck Surg 2003;129(5):497–507.
2. Agbetoba A, Luong A, Siow JK, et al. Educational utility of advanced three-dimensional virtual imaging in evaluating the anatomic configuration of the frontal recess. Int Forum Allergy Rhinol 2016. http://dx.doi.org/10.1002/alr.21864 (Epub ahead of print).
3. May M, Schaitkin B. Frontal sinus surgery: endonasal drainage instead of an external osteoplastic approach. Op Tech Otolaryngol Head Neck Surg 1995;6(3):184–192.
4. Wormald PJ. The axillary flap approach to the frontal recess. Laryngoscope 2002;112(3):494–499.
5. Kuhn FA, Bolger WE, Tisdal RG. The agger nasi cell in frontal recess obstruction: an anatomic, radiologic and clinical correlation. Op Tech Otolaryngol Head Neck Surg 1991;2(4):226–231.
6. Lund VJ, Stammberger H, Fokkens WJ, et al. European position paper on the anatomical terminology of the internal nose and paranasal sinuses. Rhinol 2014;(Suppl. 24):1–34. Available at http://www.rhinologyjournal.com/Documents/Supplements/supplement_24.pdf. accessed 02 February 2017.
7. Wormald PJ, Hoseman W, Callejas C, et al. The International Frontal Sinus Anatomy Classification (IFAC) and Classification of the Extent of Endoscopic Frontal Sinus Surgery (EFSS). Int Forum Allergy Rhinol 2016;6(7):677–696.
8. Kanowitz SJ, Jacobs JB, Lebowitz RA. Stenting in revision sinus surgery. In: Kountakis SE, Jacobs JB, Gosepath J, editors. Revision Sinus Surgery. Berlin: Springer; 2008. p. 301–308.
9. Man LX, McLean CC, Pierce ML, et al. Endoscopic trans(naso)orbital management of supraorbital mucoceles with biliary T-tube stenting. Laryngoscope 2013;123(2):326–330.
10. Kuhn FA, Javer AR, Nagpal K, et al. The frontal sinus rescue procedure: early experience and three-year follow-up. Am J Rhinol 2000;14(4):211–216.

REVIEW QUESTIONS

1. Approximately what percentage of the time will the frontal sinus drain between the uncinate process and middle turbinate?
   a. 65%
   b. 75%
   c. 85%
   d. 95%

2. Which of the following is NOT a contraindication to the endoscopic approach to the frontal sinus?
   a. Squamous cell carcinoma involving the dermis of the forehead eroding into the frontal sinus
   b. Bony dehiscence of the posterior table of the frontal sinus
   c. Severe medical comorbidities resulting in general anesthesia putting the patient at high risk for poor outcome
   d. Isolated acute frontal sinusitis with cerebritis and seizures despite broad-spectrum intravenous antibiotics

3. All of the following are boundaries of the frontal recess, except
   a. Middle turbinate basal lamella
   b. Superior portion of the uncinate process
   c. Agger nasi
   d. Lamina papyracea

4. All of the following are ideal candidates for frontal sinus surgery, except
   a. Patient with frontal headache
   b. Patient with frontal sinus mucocele
   c. Patient with symptomatic frontal sinus obstruction from synechiae
   d. Patient with an osteoma occluding the frontal recess

5. The frontal sinus rescue procedure is designed to endoscopically manage which problem?
   a. A dehiscent posterior table
   b. A tier of frontoethmoid cells
   c. A lateralized middle turbinate stump
   d. A Keros type 3 configuration

ADDITIONAL SOURCES

Citardi MJ, Javer AR, Kuhn FA. Revision endoscopic frontal sinusotomy with mucoperiosteal flap advancement: the frontal sinus rescue procedure. Otolaryngol Clin North Am 2001;34(1):123–132.

Côté DW, Wright ED. Triamcinolone-impregnated nasal dressing following endoscopic sinus surgery: a randomized, double-blind, placebo-controlled study. Laryngoscope 2010;120(6):1269–1273.

Smith TL, Singh A, Luong A, et al. Randomized controlled trial of a bioresorbable steroid-releasing implant in the frontal sinus opening. Laryngoscope 2016;126(12):2659–2664.

113 Draf III, Endoscopic Modified Lothrop

Eric W. Wang, Chirag R. Patel

INTRODUCTION

Chronic frontal sinusitis continues to be a challenge to treat both medically and surgically. Despite the advances in endoscopic sinus surgery, the wide variety of surgical options necessary for treatment of frontal sinusitis speaks to the difficult nature of managing disease in this location. Refractory frontal sinusitis in particular has challenged sinus surgeons for years.

In the early 1900s, ablation of the frontal sinus by removing the anterior table and stripping all of the mucosa was tried. This left a marked cosmetic deformity and carried a high failure rate. A period of conservative approaches followed, with a number of intranasal procedures being described to try to avoid the cosmetic defect; however, these were fraught with complications, including intracranial injuries. In 1914 Lothrop described a procedure in which an intranasal ethmoidectomy combined with an external ethmoid approach allowed him to create a common frontal nasal communication. He felt that this large frontal drainage pathway would prevent stenosis and closure, which was a problem with the other approaches in that time period. Unfortunately the lack of visualization made the procedure dangerous, and resection of the medial orbit resulted in enophthalmos.

Several authors at that time also described what has come to now be known as the osteoplastic approach. Little attention was paid to this approach due to the difficulty replacing the bone flap to its original position. It was not until the 1950s that an osteoplastic flap with frontal sinus obliteration was popularized, and it ultimately can be considered the gold standard in the treatment of refractory frontal sinusitis.

As endoscopic sinus surgery evolved in the 1980s, endoscopic frontal sinus surgery also advanced. In 1991 Wolfgang Draf published a graduated approach to the frontal sinus that he classified as Draf I, II, and III. This classification system is now accepted as the standard for describing the extent of surgery performed during endoscopic frontal sinus procedures. Draf III is an adaptation of the Lothrop procedure performed completely endonasally and consists of forming a single large frontal neo-ostium by removing the floor of the frontal sinus, superior septum, intersinus septation, and nasofrontal beak. As such, it has also come be known as an endoscopic modified Lothrop procedure (EMLP).[1]

KEY LEARNING POINTS

- The limits of the Draf III are the first olfactory fibers posteriorly, the anterior table of the frontal sinus anteriorly, and the periosteum over the frontal process of the maxilla laterally.
- Proficiency with revision sinus surgery and endoscopic frontal sinus surgery should be achieved prior to attempting Draf III.
- Careful patient selection will help avoid complications and rates of postoperative stenosis.
- Extending the head with a shoulder roll can improve the angle of approach and alleviate having the patient's chest as an obstacle.
- An anterior to posterior (AP) diameter neo-osteum greater than 1.5 cm will reduce the chances of stenosis.
- A small superior septectomy will limit visualization and increase the likelihood of postoperative crusting.
- The use of stents has not been clearly shown to reduce the rate of postoperative stenosis.

PREOPERATIVE PERIOD

History

1. History of present illness
   a. Document a detailed account of the patient's current symptoms.
      1) Up to 16% of people have no change in symptoms after Draf III, and 1.2% have worsening symptoms.[2]
      2) Asymptomatic recurrent frontal sinus opacification does not necessarily require surgery.
   b. For patients with a history of inflammatory sinus disease, document a thorough review of their sinusitis history, including prior and current medical management.
      1) Presumed origin of underlying mucosal disease
      2) Symptoms and their duration including forehead or frontal pressure
      3) History of nasal polyps
      4) Hyposmia or anosmia.
      5) Previous culture results
      6) Use of oral and/or topical antibiotics
      7) Use of oral and/or topical steroids
      8) Use of oral and/or topical antifungals
      9) Use of nasal saline irrigations
      10) Evaluation and treatment of allergy
      11) Results of any immunologic studies performed
      12) Document compliance to therapies, and ensure that proper techniques have been employed by the patient for topical drug delivery.
      13) Response to medical management
   c. Document any prior paranasal sinus surgeries with special attention to open or endoscopic frontal sinus surgeries.
   d. Document any history of trauma.
2. Past medical history
   a. Comorbidities, particularly those that may affect postoperative healing and portend poor outcome:
      1) Asthma
      2) Allergies
      3) Nasal polyposis
      4) Aspirin-exacerbated respiratory disease (Samter's triad)
      5) Autoimmune disease
      6) Mucociliary disease
         a) Primary ciliary dyskinesia/Kartagener's syndrome
         b) Cystic fibrosis
      7) Immunodeficiency
      8) Endocrine disorders
      9) Coagulopathies
      10) History of severe or refractory CRS
   b. Social and family history
      1) Tobacco smoking or frequent smoke exposure
      2) Risk factors for malignancy

Physical Examination

1. Complete examination of the head and neck
   a. Examination should always begin with a thorough examination of the head and neck, including a full examination of the cranial nerves.
   b. Make note of the patient's intercanthal distance as a narrow intercanthal distance is associated with increased likelihood of stenosis postoperatively.
2. Nasal endoscopy
   a. In patients with a neoplasm of the frontal sinus or mucocele where no prior surgery has been performed, nasal endoscopy may be completely normal.
   b. Patients with inflammatory sinus disease will likely have had sinus surgery prior to being considered for Draf III.
      1) Identify existing/remaining landmarks.
      2) Is middle turbinate or uncinated process scarred laterally?
      3) Take note of the degree of inflammatory sinus disease present.
      4) Try to identify a frontal recess on either side.

Imaging

1. Computed tomography (CT) scan
   a. CT is the imaging study of choice for recurrent inflammatory sinus disease and revision endoscopic sinus surgery. It helps delineate residual sinus anatomy and the degree of sinus disease present. It also provides key information with regard to being able to successfully complete and maintain an open Draf III cavity.
      1) Assess AP diameter. Studies have shown that patients with an AP diameter less than 1.5 cm have increased rates of stenosis.[3]
      2) A thick nasofrontal beak will make it more difficult to complete the Draf III.
      3) Presence of osteitis, particularly of the nasofrontal beak, will also increase the likelihood of stenosis.
   b. CT can identify areas of bony erosion where the likelihood of cerebrospinal fluid (CSF) leak may be higher.
2. Magnetic resonance imaging (MRI)
   a. MRI can help differentiate between a mucocele, encephalocele, tumor, and mucosal edema. MRI can help better delineate the extent of the tumor versus trapped secretions due to obstruction by the tumor.

Indications

1. Recalcitrant *symptomatic* frontal sinus disease despite prior endoscopic frontal sinus surgery
2. Difficult revision sinus surgery
3. Failed prior obliteration surgery
4. Mucociliary disease
   a. Primary ciliary dyskinesia/Kartagener's syndrome
   b. Cystic fibrosis
5. Access to frontal sinus tumors such as inverted papilloma, fibrous dysplasia, and osteoma
6. Select trauma cases
7. Posterior table CSF leak
8. Anterior exposure for an endoscopic endonasal approach to the anterior skull base

Contraindications

1. Poor patient selection: The patient has narrow intranasal anatomy that would be considered a contraindication to performing a Draf III.
2. Medical comorbidities that place the patient at high risk for general anesthesia
3. Anterior-posterior diameter less than 1.5 cm
4. Thick osteitic nasofrontal beak (relative)
5. Deep radix
6. Asymptomatic inflammatory disease
7. Isolated disease located lateral to the mid-pupillary line
8. Poorly pneumatized/hypoplastic frontal sinus

Preoperative Preparation

1. Maximize medical management of inflammatory sinus disease.
2. Prepare for skull base reconstruction if necessary.
3. Prepare for possible trephination to help identify the frontal ostium intraoperatively.
4. If using image guidance, make sure imaging is done with the appropriate protocol and appropriate navigation capable frontal sinus instruments will be available.

OPERATIVE PERIOD

Anesthesia

General—The Draf III procedure should be performed under general anesthesia due to the length of the procedure, the need for drilling, and the potential for skull base injury and CSF leak.

Positioning

Supine—The patient is positioned the same as any endoscopic sinus procedure, with the head turned slightly toward the surgeon. Extending the head using a shoulder roll can improve the angle of approach and alleviate having the patient's chest as an obstacle.

Perioperative Antibiotics Prophylaxis

1. If prior culture data are available, perioperative antibiotics should be chosen according to the susceptibilities reported.
2. If no prior cultures have been performed, use a first-generation cephalosporin.

Monitoring

Somatosensory evoked potentials (SSEPs) may be useful for anterior skull base/intracranial tumor resection; otherwise no monitoring is necessary.

Instruments and Equipment to Have Available

1. Basic endoscopic sinus set (see Chapter 108)
2. Angled telescopes with reverse light posts
3. Frontal sinus surgery set (see Chapter 112)
4. Suction-irrigating drill
5. 4- or 5-mm drill bits
   a. Coarse diamond bits offer the best balance of efficient bone removal and control.
   b. Surgeons experienced with the Draf III procedure may consider the use of cutting burrs.
   c. A variety of angles should be available and selected based on choice of approach and patient's anatomy.
6. Instruments for potential trephination (see Chapter 111)
7. Image guidance system with navigation capable frontal sinus instruments

Key Anatomic Landmarks

1. Lateral limits of Draf III: Periosteum over the frontal process of the maxilla
2. Posterior limit of Draf III: First olfactory fibers
   a. The first olfactory fibers on both sides mark the anterior extent of the cribriform plate and thus demarcate the posterior limit of dissection.
3. Anterior limit of Draf III: Anterior table of the frontal sinus
4. Both middle turbinates, if present, and their attachment sites to the skull base
5. Lamina papyracea: This marks the location of the orbit. Identifying the lamina papyracea will help avoid inadvertent orbital injury.
6. Posterior table of the frontal sinus: The posterior table of the frontal sinus should be visualized early in the procedure to help prevent inadvertent injury to the skull base when commencing any drilling. However, the first olfactory fibers and the cribriform plate mark the true posterior limit of dissection.
7. Posterior aspect of the frontal recess: Care should be taken not to damage the mucosa of the posterior aspect of the frontal recess in order to avoid circumferential scarring and stenosis postoperatively. It also helps to avoid inadvertent skull base injury and CSF leak.
8. Anterior ethmoid artery: The anterior ethmoid artery is located at the posterior limit of the frontal recess. Injury to these vessels can result in significant bleeding. If injured laterally, the vessel can retract into the orbit, resulting in retrobulbar hematoma.
9. Cribriform plate: The first olfactory fibers mark the anterior limit of the cribriform plate on either side of midline. It should be noted, however, that the midline portion of the cribriform plate may extent slightly more anterior, and care should be taken when removing bone in this area.

Prerequisite Skills

1. Revision endoscopic sinus surgery
2. Primary and revision endoscopic frontal sinus surgery

Operative Risks

1. Cerebrospinal fluid leak
2. Hemorrhage
3. Orbital injury
4. Retrobulbar hematoma
5. Cosmetic deformity due to excessive bone removal
6. Saddle deformity due to excessive septum removal

Surgical Technique

There are two approaches to the Draf III: inside-out and outside-in.

Inside Out

1. Identify the frontal recess on at least one side, typically the less diseased side.
   a. This can be done using standard endoscopic sinus techniques with or without the assistance of image guidance.
   b. A trephine can also be performed to allow for irrigation of the sinus from above, with saline or fluorescein-dyed saline solution to help identify the frontal recess.
2. Resect the head of the middle turbinate up to the posterior aspect of the identified frontal ostium.
3. Remove the floor of the frontal sinus from the identified ostium to the nasal septum (Draf IIb). This will help to clearly identify the posterior table of the frontal sinus and prevent inadvertent skull base injury (Fig. 113.1).
4. Resect approximately the superior 1 cm of bony septum from the frontal recess posteriorly to approximately 1 cm anteriorly. In general, the root of the contralateral middle turbinate and the upper one-third to one half of the turbinate should be easily visible. This allows wide binarial access to the frontal sinus floor and greater visualization (Fig. 113.2).
   a. Like septal perforations, smaller septectomies tend to cause frequent crusting and impact patient quality of life, whereas larger septectomies tend to be asymptomatic.
5. Resect the head of contralateral middle turbinate to match the ipsilateral side.

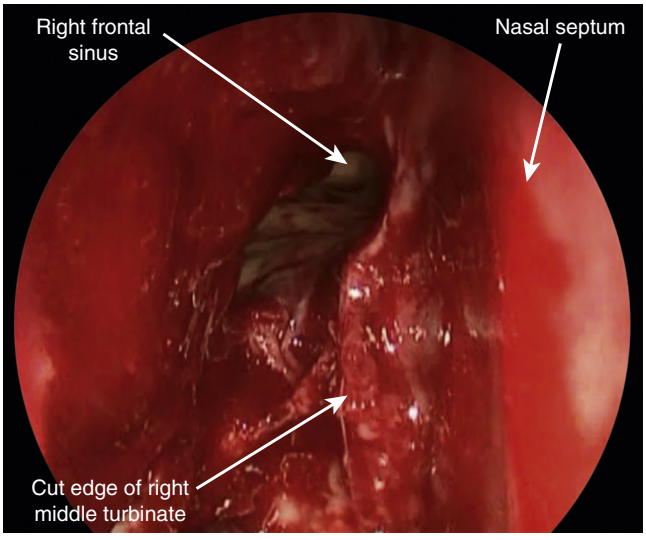

Fig. 113.1. Draf IIb completed on right side. Note the posterior table of the frontal sinus is clearly visible.



Fig. 113.2. Diagram of the septal window. *(May M, Schaitkin B: Frontal sinus surgery: Endonasal drainage instead of an external osteoplastic approach. Op Tech Otolaryngol Head Neck Surg 31:184-192, 1995.)*

6. Try to identify the contralateral frontal recess (Fig. 113.3).
7. Use the drill to remove the nasofrontal beak and remaining floor of the frontal sinus in a horseshoe shape. A wide opening should be achieved from one lamina papyracea to the other, and a large anterior-posterior diameter is created without violating the glabella anteriorly or skull base posteriorly (Fig. 113.4).
8. Be careful not to disrupt the mucosa of the posterior aspect of the frontal recess or posterior table unless bone removal of that area is anticipated for tumor resection.
9. Residual superior septum anterior to the cribriform can be resected with cutting instruments or the drill. Identifying the first olfactory fibers by elevating the mucosa off of the posterior septal remnant toward the olfactory cleft can help to identify the posterior limit of dissection.

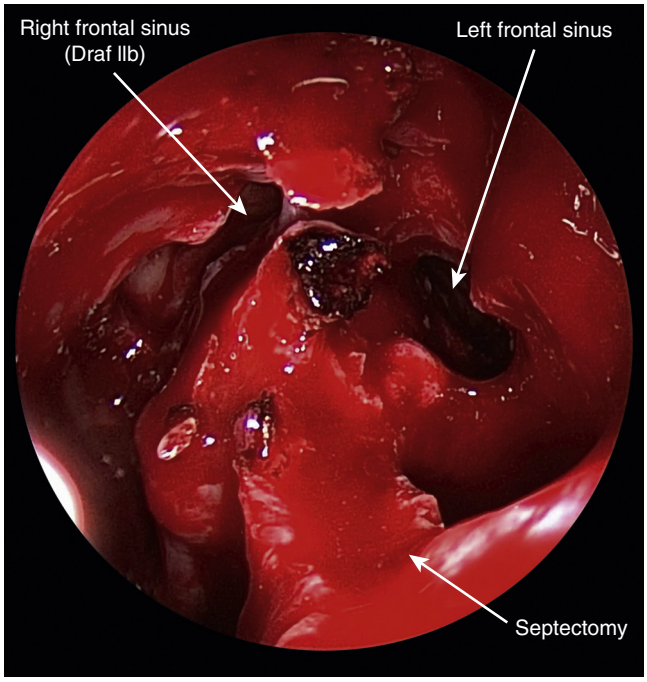

Fig. 113.3. Completed exposure of frontal sinus floor from an inside-out approach. Note a Draf IIb has been completed successfully on the right, the left frontal recess and sinus have been identified, a large septectomy has been completed to allow a view of both frontal recesses from one side, and the head of the middle turbinates has been trimmed.

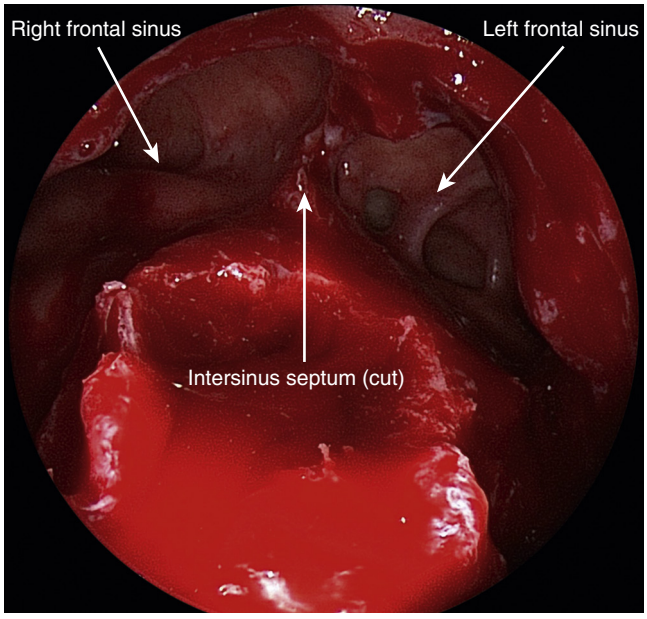

Fig. 113.4. Completed inside-out Draf III. The remaining floor and intersinus septation have been removed in a horseshoe pattern to connect both frontal sinus recesses and form a single common drainage pathway.

Outside-In (Video 113.1)

1. In some cases, a frontal recess may not be easily identifiable on either side, due to scarring, osteoneogenesis from prior surgery, or tumor. This approach avoids initial identification and dissection of a narrow frontal recess by working below the frontal sinus floor initially to create wide exposure and identify the limits of the dissection.
2. When possible, an ethmoidectomy can be completed on both sides to identify the medial orbit laterally and skull base posteriorly.
3. A superior septectomy can be performed at this time. It can also be performed in conjunction with the following steps.
   a. The incision starts at the nasal septal angle just opposite the superior attachment of the middle turbinate.
   b. A full-thickness incision is then carried down on the septum angled anteriorly so that the incision ends 5 to 10 mm anterior to the head of the middle turbinate at the level of the upper third or one half of the turbinate. This marks the anterior aspect of the superior septectomy.
   c. The inferior septal incision can be carried posteriorly to the level of the head of middle turbinate or middle meatus if the turbinate is missing.
   d. The posterior incision extends vertically back up to the start of the septectomy, staying close to the anterior edge of the middle turbinate to avoid damaging olfactory mucosa (Fig. 113.5).
   e. Through-cutting instruments or a microdébrider can now be used to remove the septal window.
   f. An adequate septectomy allows visualization of both middle turbinates and their attachment sites from either nasal cavity (Fig. 113.6).

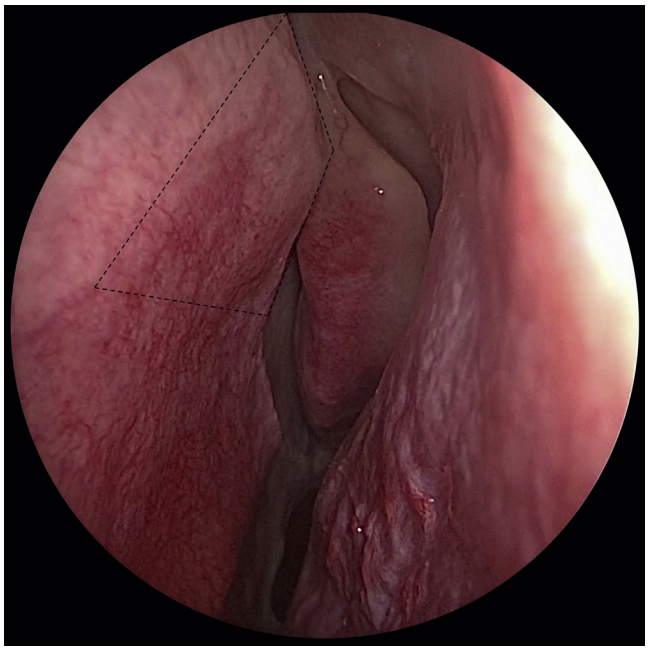

Fig. 113.5. A view of the left nasal cavity with anticipated superior septectomy outlined *(black dotted line)*.

4. The mucosa of the nasofrontal beak and frontal sinus floor is elevated to identify the first olfactory fiber on both sides.
   a. Bilaterally, an incision is made on the lateral nasal wall from just anterior to the attachment of the middle turbinate and taken superiorly to the nasal septal angle (Fig. 113.7).
   b. If a superior septectomy was already performed, the incision is carried to meet with the septectomy. If a septectomy is being performed at the same time as this step:
      1) A full-thickness incision is then carried down on the septum angled anteriorly so that the incision ends 5 to 10 mm anterior to the head of the middle turbinate at the level of the upper third or one half of the turbinate. This marks the anterior aspect of the superior septectomy.
      2) The inferior septal incision can be carried posteriorly to the level of the head of middle turbinate or middle meatus if the turbinate is missing (Fig. 113.8).
   c. An elevator can now be used to elevate the mucosa bilaterally, starting at the apex and elevating it off of the septum and lateral nasal wall to allow posterior dissection. The mucosal flap is elevated posteriorly and folded back into the olfactory cleft until the first olfactory fiber is identified (Fig. 113.9).

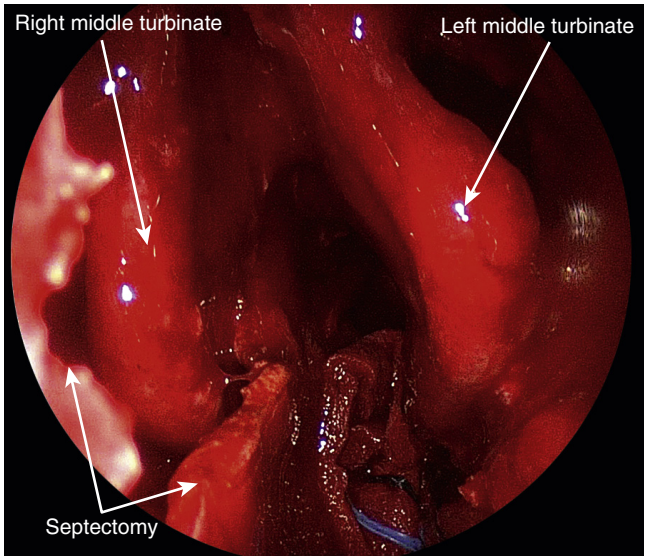

Fig. 113.6. View of both middle turbinates after septectomy. Notice how the heads of both middle turbinates are easily viewed from one side. Additional posterior septum has been removed for an anterior skull base approach in this particular case.

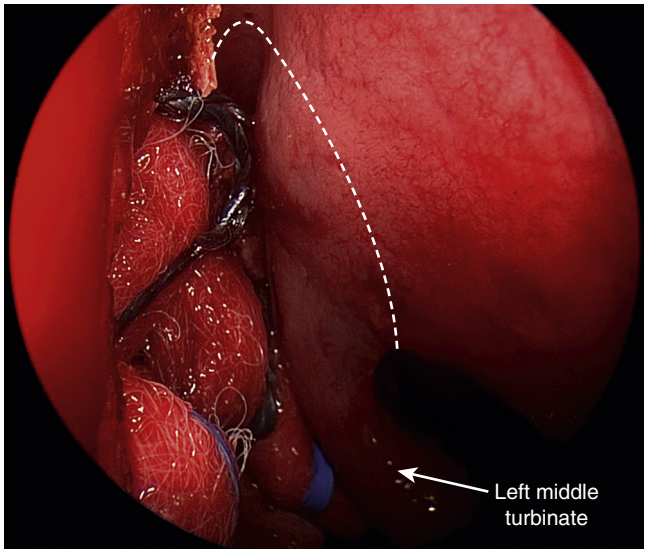

Fig. 113.7. A view of the left nasal cavity after septectomy. Cottonoid patties have been placed in the right nasal cavity for hemostasis and are clearly visible from the left. The mucosal incision has been outlined *(white dotted line),* which will expose the frontal process of the maxilla laterally, nasofrontal beak superiorly, and allow posterior dissection to identify the first olfactory fiber.

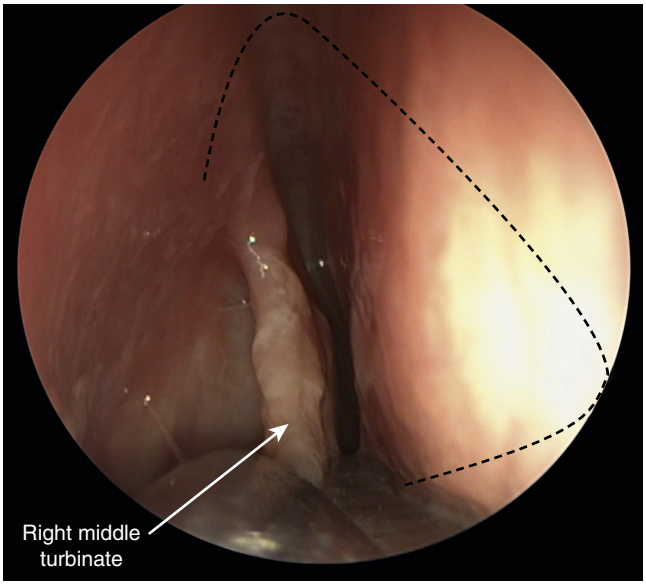

Fig. 113.8. Diagram outlining the mucosal incisions in the right nasal cavity when combining the lateral nasal wall incision with the septectomy. Note the septal incision angles anteriorly to allow clear view of the contralateral middle turbinate and its attachment site. The inferior incision is carried posteriorly to approximately the level of the anterior edge of the middle turbinate.

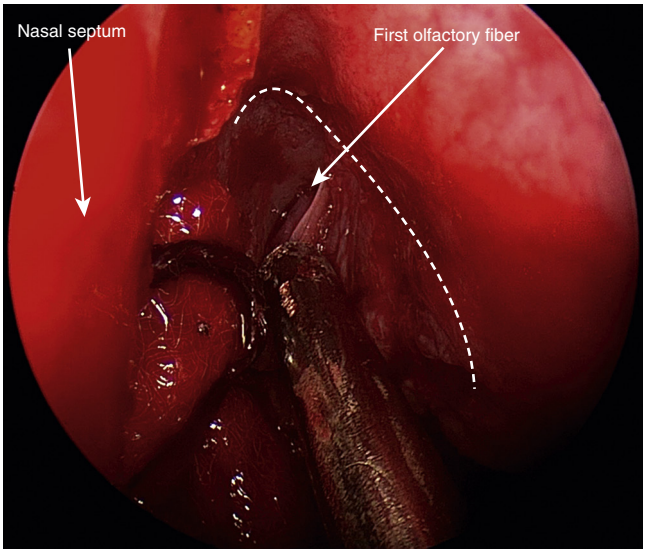

Fig. 113.9. Identifying the first olfactory fiber. The lateral and superior nasal mucosa are reflected posteriorly until the first olfactory fiber is identified. Note that the fiber is rather large and tightly adherent to the skull base. The *white dotted line* corresponds to the mucosal incision previously demonstrated in Fig. 24.7.

   d. A small emissary vein is often seen prior to the first olfactory fiber. This is usually small, runs laterally, and dissects away easily from the skull base. The olfactory fiber is larger and more tightly adherent to the skull base, so it is not easily dissected away in careful hands.
   e. These olfactory fibers on each side now mark the posterior limit of dissection. The redundant mucosa that was elevated can be resected with through-cutting instruments or a microdébrider. The superior septal window can be completed staying anterior to the olfactory fibers.
5. Drilling begins in the midline to bring the residual crest of nasal septum flush with the lateral nasal walls at the apex (Fig. 113.10). Drilling then continues in a wide and meticulous fashion.
6. The bone of the lateral nasal wall is removed until the periosteum is identified. It often appears white compared with the yellow bone.
7. Once the periosteum is identified laterally, all of the limits of the Draf III have been identified. By staying anterior to the olfactory fibers, the skull base should not be entered unintentionally. Bone can now be removed in a wide horseshoe movement to approach the frontal recesses in a smooth controlled manner.
8. The mucosa of the floor of the frontal sinus in the midline will likely be identified early in the drilling process. If possible, this mucosa should be left intact to avoid unnecessary bleeding. However, if there is any concern about the posterior limits of bone removal, opening this mucosa can provide a view into the sinus and help with identification of the posterior table.
9. With continued bone removal laterally, the natural frontal recess will be encountered (Fig. 113.11). Once the bone is thin enough, rongeurs can be used to remove the remaining bone and connect the frontal recess to the remaining surgical cavity.
10. Intersinus septations can be removed.
11. Residual posterior superior bony septum can be carefully drilled away closer to the first olfactory fibers. This helps maximize the anterior posterior diameter in the midline. Keep in mind that the midline cribriform can sometimes project more anterior than the first olfactory fibers (Fig. 113.12).

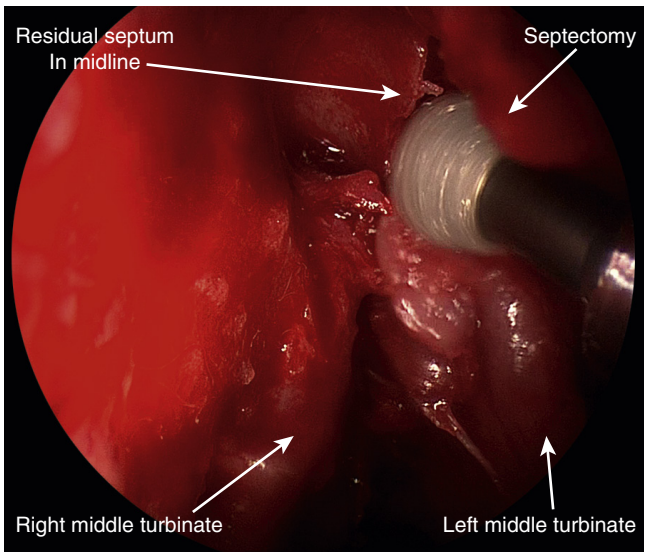

Fig. 113.10. Drilling with a 4-mm coarse diamond drill bit begins in the midline in order to bring the remainder of the nasal septum flush with the lateral nasal walls at the apex. The use of suction-irrigating drills improves visualization.

Stenting

1. The use of stents has been described in the literature for more than 100 years.
2. A variety of stenting options exist, which can be left in place for 1 to 6 weeks depending on the type of stent used. Some examples include:
   a. Silastic tubing
   b. Custom-shaped Silastic sheeting
   c. Rubber finger stall with sponge packing
   d. Dissolvable packing
   e. Steroid-eluting stents
   f. Steroid-coated dissolvable packing material
   g. Chitosan
3. Prolonged stenting carries the risk of biofilm formation, which can form as early as 1 week postoperatively. The impact of biofilms in CRS and surgical failure is well established.[4]

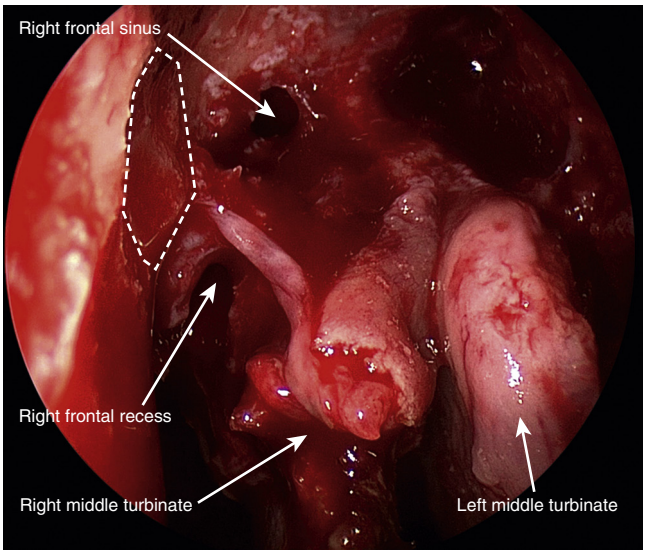

Fig. 113.11. The right frontal process of the maxilla has been drilled down to the periosteum. The right frontal recess has been exposed. The right frontal sinus has also been entered more medially by drilling through the nasofrontal beak and frontal sinus floor. Kerrison rongeurs can now be used to combine these areas and further widen the opening if the bone is thin enough.

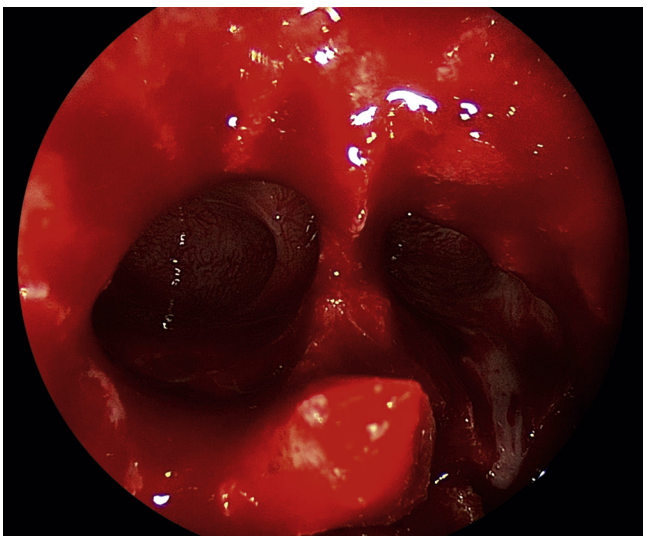

Fig. 113.12. Completed Draf III.

4. The current literature suggests that stents are used infrequently after Draf III.
5. The current data on stenting in Draf III are limited and have not shown any difference in the rate of stenosis.[2,4]

Mucosal Grafting

1. There have been reports in the recent literature on mucosal grafting of exposed bone to try and reduce the rates of stenosis.
2. Two papers to date discuss free grafting to the exposed bone of the nasofrontal beak.[5,6]
   a. One author updated his outcomes after 1 year of follow-up. Of 96 patients undergoing Draf III, only 2 cases developed more than 50% stenosis, neither of which required interventions.[7]
3. One paper reports a pedicled septal graft based on the anterior ethmoid artery to cover the posterior table.[8]
4. These studies suggest a reduction in the rate of osteoneogenesis and stenosis; however, the data are currently limited to these small case series.

Common Errors in Technique

1. Inadequate superior septectomy
2. Excessive circumferential mucosal loss
3. Inadequate removal of residual superior posterior bony septum, leaving a narrower AP diameter
4. Inadequate removal of the nasofrontal beak leaving a narrow AP diameter

POSTOPERATIVE CARE

Postoperative Management

1. Continued aggressive medical management of inflammatory mucosal disease
2. Saline irrigations
3. Oral antibiotics and oral steroids may be considered in select patients.
4. Frequent follow-up for removal of packing/stents, débridement, lysis of synechiae, or polyp removal (Fig. 113.13)

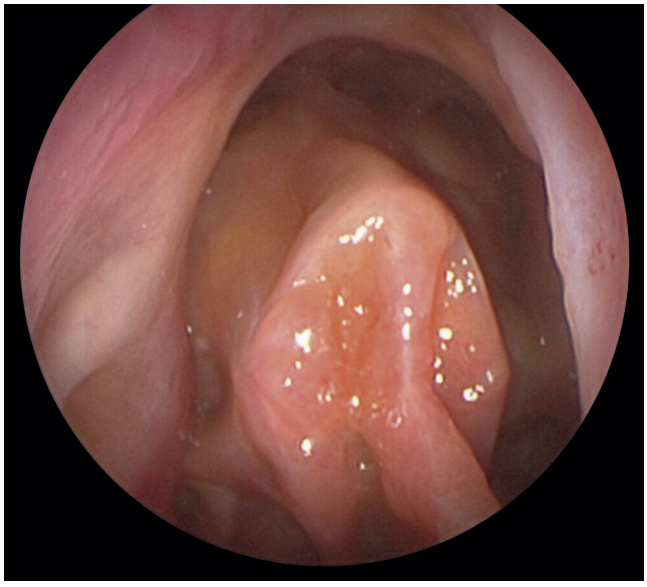

Fig. 113.13. Endoscopic view of a well-healed Draf III cavity 3 years after surgery.

Complications

Major Complications (<1%)

1. CSF leak (6% to 11%)
   a. Can be repaired endoscopically
2. Tension pneumocephalus
   a. Just as in a CSF leak, there is violation of the skull base and the dura, resulting in a fistula. This can be identified and repaired endoscopically.
3. Posterior table dehiscence

Minor Complications (4%)

1. Hemorrhage: The most significant and likely source of bleeding as a result of Draf III would be from the anterior ethmoid artery. Other sources such as posterior ethmoid artery, sphenopalatine artery, and distal branches of the sphenopalatine should be considered as possible sources if other sinuses were addressed in the same setting. Anterior ethmoid artery bleeding is difficult to control with packing. Endoscopic ligation or open ligation may be necessary.
2. Orbital injury/retrobulbar hematoma: This may occur as a result of direct injury of orbital fat or muscle or by retraction of an avulsed anterior ethmoid artery into the orbit. Management of this complication would be the same as with endoscopic sinus surgery (see Chapter 109).
3. Saddle nose deformity: This may occur if too much septum is removed during the superior septectomy, particularly if the septectomy is brought too far anteriorly into the dorsal cartilaginous strut.
4. Anosmia/hyposmia
5. Increased nasal crusting
6. Stenosis

Alternative Management Plan

1. Trephination
2. Osteoplastic flap approach with removal of floor of the frontal sinus
3. Frontal sinus obliteration
4. Frontal sinus cranialization

DISCUSSION

Evidence-Based Medicine Question: Is Draf III Superior To Open Approaches Such As Osteoplastic Flap With Obliteration?

Frontal sinus obliteration was first described in the 1950s. It is considered by some to be the gold standard of treatment for patients with symptomatic refractory frontal sinusitis. Success rates have been reported to be as high as 93% at 8 years. However, complication rates are also relatively high, with major complications exceeding 20% in some series. Major complications include exposure of the dura, dural tears, CSF leak, and orbital injuries. Minor complications can include forehead paresthesia, pain, osteomyelitis of the bone flap, and mucocele formation due to incomplete obliteration.

A review of the literature in 2009 by Anderson and Sindwani[2] found that the Draf III procedure carried a major complications rate of less than 1% when performed by experienced surgeons. It was well tolerated and efficacious in the treatment of refractory frontal sinusitis, with 82% of patients reporting significant improvement or total resolution of preoperative symptoms. Sixteen percent reported no significant change, and 1.2% reported worsening symptoms; however, details

regarding which symptoms worsened were not available. Fourteen percent of patients required further surgery, with 80% undergoing revision Draf III and 20% having an obliteration. No data were available as to improvement of symptoms after revision; however, it is likely the overall success of Draf III is greater when including revision cases. The majority of stenosis of the neo-ostium after Draf III seemed to occur within the first year after surgery in the majority of studies. The use of the Draf III procedure still preserves the option of obliteration in the future should it be unsuccessful. Interestingly, a Draf III can also be used to rescue a failed case of obliteration in the highly selected patients.

While this paper suggests comparable outcomes with obliteration, the literature lacks a significant volume of data with regard to Draf III, given its relatively recent advent, technically challenging nature, and applicability. Moreover, these data are lacking in long-term follow-up, with most series limited to 2 to 4 years. A series published by Ting et al.[9] in 2014 was the first to have follow up greater than 10 years and consisted of 204 patients with a mean follow-up time of 10.2 years (range 0.9 to 17 years). This relatively large series provided an update to a previously reported cohort, and they found that the initially reported success rate decreased from 80% to 70% due to some patients developing late recurrences well beyond 2 years and extending as far as 10 years. This is believed to be from the ongoing process of mucosal inflammation present in patients with refractory frontal sinusitis. Nevertheless, the majority of failures requiring revision surgery occurred in the first 2 years.

A more recent publication by Morrissey et al.[10] in 2016 reported on 213 patients undergoing Draf III from January 2001 to December 2013. In this series, only 19 patients (8.9%) failed primary Draf III, requiring revision surgery. A majority of stenosis was reported as soft tissue or polyp obstruction, with only four demonstrating osteoneogenesis requiring drilling. Of the 19 revisions, four went on to have multiple revisions. The average time to revision was 44 months in contrast to the prior studies reporting 24 months. Risk factors associated with failure of primary Draf III were the presence of intraoperative purulence at time of primary surgery, more than 5 sinus surgeries prior to primary Draf III, and presence of aspirin exacerbated respiratory disease. Sex, age at time of primary Draf III, asthma, presence of nasal polyps, ostium size, and preoperative Lund-Mackay score were not found to be statistically significant. The only major complications in this group were two patients with minor intraoperative CSF leaks, which were successfully repaired at the time of surgery. One key difference with this study was that the mean follow-up time was reported as only 36 months.

In summary, it is felt that Draf III offers success rates similar to obliteration with significantly less morbidity, while still preserving the option for obliteration in the future if necessary. More long-term data are needed to determine how durable it is as a treatment option. Overall it is a valuable intervention to consider in the treatment ladder in the management of refractory frontal sinusitis.

Editorial Comment

The frontal sinus remains the most challenging anatomic region for surgical intervention for chronic sinusitis. It is the only dependent sinus without a fontanelle, and therefore its bony confines make it less forgiving and more prone to stenosis. The nasofrontal recess anatomy is highly variable, and the important anatomic neighbors cannot be ignored. This chapter succinctly highlights the key points and limitations of advanced frontal sinus surgery. Wolfgang Draf perfected the transnasal drillout procedure beginning with a microscope in the prenavigation era (the Fulda concept). It was a classic and very effective operation, but it was done with irrigation making visualization difficult, and teaching the procedure was challenging. It was transitioned to a modern teachable endoscopic frontal sinus drillout procedure, which continues to be associated with his name, even though many refer to it as a modified Lothrop procedure. The procedure provides wide access for hygiene and topical therapy. It has become the gold standard, replacing the frontal sinus osteoplastic flap, which was always plagued by long-term failures with mucoceles and difficulty evaluating complaints postoperatively by imaging. Mastering the anatomy and using the key chapter information of indications, contraindications and surgical techniques coupled with significant cadaveric dissection will allow for the adoption of safe advanced frontal sinus surgery.

Barry Schaitkin

Access the review questions online at http://www.expertconsult.com

REFERENCES

1. Ramadan HH. History of frontal sinus surgery. Arch Otolaryngol 2000;126(1):98–99.
2. Anderson P, Sindwani R. Safety and efficacy of the endoscopic modified Lothrop procedure: a systematic review and meta-analysis. Laryngoscope 2009;119(9):1828–1833.
3. Gross CW, Schlosser RJ. The modified Lothrop procedure: lessons learned. Laryngoscope 2001;111(7):1302–1305.
4. Chen PG, Wormald PJ, Payne SC, et al. A golden experience: fifty years of experience managing the frontal sinus. Laryngoscope 2016;126(4):802–807.
5. Hildenbrand T, Wormald PJ, Weber RK. Endoscopic frontal sinus drainage Draf type III with mucosal transplants. Am J Rhinol Allergy 2012;26(2):148–151.
6. Conger Jr BT, Riley K, Woodworth BA. The Draf III mucosal grafting technique: a prospective study. Otolaryngology 2012;146(4):664–668.
7. Illing EA, Cho DY, Riley KO, et al. Draf III mucosal graft technique: long-term results. Int Forum Allergy Rhinol 2016;6(5):514–517.
8. Seyedhadi S, Mojtaba MA, Shahin B, et al. The Draf III septal flap technique: a preliminary report. Am J Otolaryngol 2013;34(5):399–402.
9. Ting JY, Wu A, Metson R. Frontal sinus drillout (modified Lothrop procedure): long-term results in 204 patients. Laryngoscope 2014;124(5):1066–1070.
10. Morrissey DK, Bassiouni A, Psaltis AJ, et al. Outcomes of revision endoscopic modified Lothrop procedure. Int Forum Allergy Rhinol 2016;6(5):518–522.

REVIEW QUESTIONS

1. Which of the following is *not* a contraindication to Draf III?
   a. Thick osteitic nasofrontal beak
   b. AP diameter less than 1.5 cm
   c. Mucociliary disease (e.g., Cystic fibrosis or Kartagener's)
   d. Asymptomatic inflammatory disease

2. Which of the following statements is true?
   a. Patients with a narrow intercanthal distance have a decreased likelihood of stenosis.
   b. The midline portion of the cribriform plate extends more anterior than the first olfactory fibers.
   c. The lateral limit of a Draf III is the periosteum over the lacrimal sac.
   d. Stenting is a common practice and has been shown to reduce the rates of stenosis.

3. According to a recent publication by Morrissey et al., which of the following is not a risk factor for failure of Draf III?
   a. Ostium size
   b. More than five sinus surgeries prior to primary Draf III
   c. Purulence at the time of surgery
   d. Aspirin-exacerbated respiratory disease

4. The majority of Draf III failures occur within what time frame?
   a. 1 year
   b. 2 years
   c. 5 years
   d. 10 years

5. The majority of stenosis of the Draf III neo-ostium seems to occur within what time frame?
   a. 3 months
   b. 6 months
   c. 12 months
   d. 18 months

114 Osteoplastic Obliteration of the Frontal Sinus

Matthew Mifsud, John R. De Almeida

INTRODUCTION

In the preendoscopic era, the osteoplastic flap procedure was the accepted method of management of frontal sinusitis.[1,2] Initial approaches described in the late 19th century (e.g., the Reidel procedure) conceptualized the complete exenteration of the sinus, including the anterior wall, which of course resulted in a significant cosmetic deformity, reserved for only the most severe disease processes.[2,3] The more modern osteoplastic obliteration (using abdominal adipose tissue) was described in the 1940s and popularized by the 1970s.[1,2] It is a versatile surgical approach that provides wide exposure of the frontal sinus and allows for the definitive management of inflammatory, infectious, and neoplastic disease processes. The procedure has maintained a reputation for reliability, with long-term success rates greater than 90% in most reports, even when used in patients with refractory chronic frontal sinusitis.[1,2]

Advances in endoscopic techniques have largely replaced open sinus surgery.[4] Instead of an obliterative approach, transnasal surgery allows the restoration of function to a diseased sinus, by establishing a permanent drainage pathway.[1,4,5] This approach is preferred, as it avoids external scars and unlike open procedures maintains normal sinus physiology. However, there remain certain situations—for example, neoplasms of the frontal sinus or extreme lateral based pathology—in which endoscopic visualization is limited. The osteoplastic flap procedure continues to be an essential surgical approach in these instances.[4,5]

KEY OPERATIVE LEARNING POINTS

1. The osteoplastic flap procedure should be considered in cases that are inaccessible to endoscopic techniques, particularly in the setting of refractory chronic sinusitis after previous surgical failure.
2. A bicoronal flap, raised in the subgaleal plane, is generally used to prevent injury to the scalp neurovasculature.
3. To prevent intraoperative complications, the frontal sinus must be accurately outlined using plain x-ray film, minitrephination technique, or image guidance, prior to making the osteotomies.
4. For noninflammatory pathology, sinus obliteration may not be necessary; instead an endoscopic procedure can be used to create a patent nasofrontal outflow tract.
5. When sinus obliteration is necessary, key principles must be adhered to for long-term success.[1,6]
   a. Meticulous removal of all visible sinus mucosa
   b. Removal of the inner cortex of the anterior wall of the sinus with a cutting and/or diamond burr
   c. Permanent occlusion of the nasofrontal outflow tract
6. While abdominal adipose tissue is currently considered the standard tissue for obliteration of the frontal sinus, more recently described techniques including a rotational pericranial flap or tissue-engineered materials may also be considered.[6-8]

PREOPERATIVE PERIOD

The key to the preoperative patient evaluation is determining which patient would be best served by an open surgical approach given the advanced instrumentation, surgeon comfort, and ease of access to the frontal sinus with standard endoscopic approaches. The osteoplastic flap approach will be of particular use in situations where wide surgical exposure for direct instrumentation of the sinus is necessary. It may be applied in multiple clinical settings (e.g., trauma, neoplasm, or chronic sinusitis), and thus the preoperative evaluation must address the particular disease process at hand.

Successful endoscopic sinus surgery requires the establishment of an appropriate corridor to fully visualize the disease process and establish a patent sinus drainage pathway. Findings such as significant scar formation or osteoneogenesis within the frontal recess (usually due to previous surgical procedures) often portend poor long-term results with transnasal approaches. An anatomically inaccessible pathology located in the far lateral or anterior table of the sinus as well as large fibro-osseous lesions (e.g., osteoma) are difficult to remove endoscopically and may benefit from an osteoplastic approach.[4]

The indications for osteoplastic obliteration will likely continue to evolve over time, with advancement of endoscopic techniques and instrumentation. Perioperative planning requires the combination of a detailed examination of the head and neck, including endoscopy, and high-resolution imaging (usually computed tomography [CT]) to define the most appropriate surgical approach.

History

1. History of present illness
   a. A focused history should include questions about common symptoms of frontal sinus and nasal pathology, including frontal pressure/pain, headache, hyposmia/anosmia, nasal obstruction, epistaxis, generalized fatigue, or a sensation of postnasal drainage.
   b. For presumed chronic inflammatory disease, review the current medical regimen (e.g., nasal corticosteroids or saline irrigations) and the effectiveness of these nonsurgical treatments for control of symptoms.
   c. Signs of intraorbital pathology such as diplopia or decreased visual acuity should be specifically evaluated.
   d. Red flags for a malignant or acute life-threatening illness, such as mental status changes, weight loss, clear (cerebrospinal fluid [CSF]) rhinorrhea, sensory deficits along trigeminal nerve distribution, current history of immune suppression, or severe/progressive pain, should be considered.
2. Past medical history
   a. Prior treatment
      - All previous sinonasal procedures must be detailed, to help determine if an open frontal sinus procedure is indicated. This should include a review of past sinus procedures and pathologic specimens.
      - Previous scalp incisions or surgical incisions are important to assess, as this may limit the viability of the standard bicoronal approach typically used for the osteoplastic flap procedure.

b. Medical illness
   - Review for systemic comorbidities (particularly cardiac disease, chronic pulmonary disease, diabetes mellitus)
c. Past surgical history
d. Family history
e. Allergy assessment
f. Review of current medications

Physical Examination

1. Head/face:
   a. Standard facial assessment, with a particular focus on facial symmetry and facial nerve function. Sensory examination particularly along V1 and V2 territories should be documented.
   b. Palpation along the orbital rim and frontal bone should be carried out, both to assess for point tenderness and to address the integrity of the anterior table of the frontal sinus and the presence of a mucocele. The position of the eyes should be examined, and any displacement should be noted.
   c. In the case of recent traumatic injury, a thorough inspection should be undertaken to review for facial lacerations, bruising, or bony step-offs that could be indicative of fracture sites. The overall stability of the midface and mandible should also be assessed.
2. Orbit:
   a. Extraocular motion
   b. Visual field assessment
   c. Assess the position of the globe (i.e., proptosis or enophthalmos).
   d. A referral to ophthalmology for any concerning abnormal findings is strongly suggested.
3. Nasal examination:
   a. Standard external nasal examination with assessment of external/internal nasal valves. Note presence/absence of significant septal deformity or hypertrophy of the inferior turbinates.
   b. Intranasal examination should evaluate for an intranasal mass, polypoid/inflammatory changes, or obvious purulence. If purulent sinonasal discharge is identified, a specimen should be taken for culture and sensitivities.
4. Nasal endoscopy:
   a. This examination is critical to define the surgical approach for frontal sinus disease, particularly in the previously operated nose. Adequate topical anesthesia should be applied for patient comfort. This examination is often best performed with 0- and 30-degree rigid endoscopes, as additional instruments (i.e., curved suctions) can be used to clear debris when present.
   b. The presence/absence of key anatomic landmarks should be noted, particularly the middle turbinate (and its basal lamella), uncinate process, and bulla ethmoidalis.
   c. With an angled telescope, an attempt should be made to visualize the frontal recess. Particularly note the presence of polypoid disease or synechiae formation if previous surgery has been performed.
5. Comprehensive head/neck and general medical examination:
   a. Overall health and mental status
   b. A thorough examination of the head and neck should be carried out.
   c. Cardiovascular, pulmonary, and neurologic examination
   d. Skin assessment

Imaging

1. CT imaging:
   a. A high resolution CT scan of the sinuses is the most useful method in the evaluation of frontal sinus disease. This provides an optimal assessment of the position of the frontal sinus in relation to key landmarks such as the anterior skull base, crista galli, and frontal lobes. The interface between inflammatory pathology and the bony anatomy of this region is also clearly delineated (Fig. 114.1).

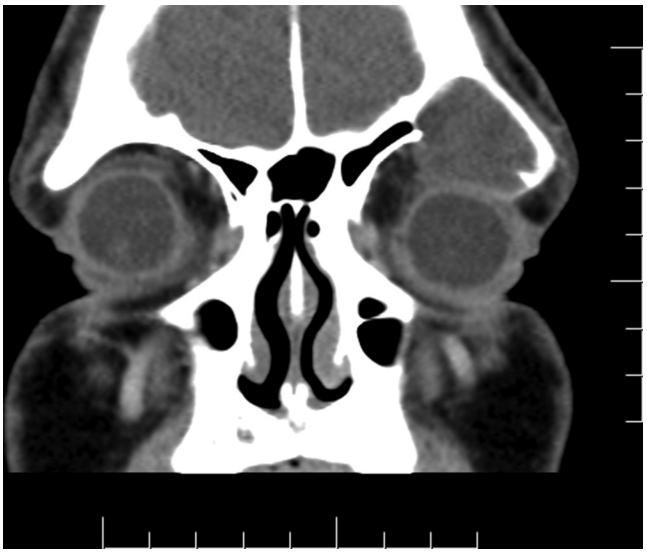

Fig. 114.1. Coronal computed tomography scan demonstrating a large lateral frontal sinus mucocele with erosion of the floor of the frontal sinus and encroachment on the orbit.

   b. The structure of the anterior and posterior table of the sinus should be visualized. Significant defects in the bony structure of the sinus may prevent safe obliteration of the sinus and require the use of a different surgical approach.
   c. If surgical image guidance is considered, image slice thickness should generally not exceed 2 to 3 mm.
   d. Evaluation of the bony anatomy of the frontal recess is best performed with CT. This will help classify the pattern of frontal cells on the basis of the Kuhn classification, which may indicate a more challenging endoscopic dissection.
      - Type I: Single frontal recess cell above the agar nasi
      - Type II: Tier of cells above the agar nasi
      - Type III: Large cell pneumatizing from the frontal recess into the sinus
      - Type IV: Isolated frontal sinus cell
   e. CT is also particularly useful for evaluating traumatic maxillofacial injuries and identifying benign fibro-osseous lesions (e.g., osteomas).
2. Magnetic resonance (MR) imaging:
   a. Due to lack of detailed bony definition, MR is usually considered as an adjunctive modality. It is, however, particularly beneficial in certain situations due to the ideal soft tissue definition provided.
      - Identifying benign/malignant neoplasms of the frontal sinus, with gadolinium-enhanced imaging
      - For differentiating solid tumors from inflammatory secretions or expansile mucoceles that have specific signal characteristics, particularly on T2-weighted or contrast-enhanced imaging (Fig. 114.2)
   b. MR is also particularly useful in the evaluation and diagnosis of pathology that has spread to intraorbital or intracranial compartments.
3. Radiography:
   a. Traditionally a 6-foot Caldwell view plain film radiograph has been used for surgical guidance prior to the osteoplastic flap procedure.[3,9]



Fig. 114.2. Coronal contrast enhanced T1-weighted magnetic resonance imaging of the same lateral frontal sinus mucocele. Note the classic hyperintense appearance of the mucocele, which helps define this entity.

b. From this film, a template of the frontal sinus dimensions can be made to help with the proper placement of the osteotomies along the anterior table of the sinus.

Indications

1. Recurrent chronic sinusitis after failed endoscopic sinus surgery
2. Inaccessible frontal mucoceles, usually lateral to the midpupillary line and superior to half the height of the posterior table
3. Severe trauma involving the frontal sinus outflow tract or with CSF leak, not amenable to endoscopic management
4. Benign or malignant tumors of soft tissue or bone (osteomas) of the frontal sinus, unable to be completely resected via an endoscopic approach

Contraindications

1. Any disease process amenable to endoscopic management
2. Cases in which greater than 25% of the anterior or posterior table of the frontal sinus is absent. In these cases, obliteration will likely be unsuccessful due to a limited vascular supply. For anterior table defects, the Reidel procedure may be necessary, while frontal sinus cranialization should be considered for posterior table defects.
3. Patients whose medical comorbidities preclude a general anesthetic

Preoperative Preparation

1. Standard perioperative evaluation with history-directed preoperative testing and medical consultations, if indicated
2. Patient counseling and surgical consent
3. Review preoperative imaging, and ensure adequacy for image guidance, if deemed necessary.
4. Review pathology from any previous surgery.
5. A template outlining the frontal sinus should be made using the x-ray film from the 6-foot Caldwell view. The film should be sterilized for intraoperative use.

OPERATIVE PERIOD

Anesthesia

- A general anesthetic with endotracheal intubation is required for this procedure.
- The patient can be positioned with head toward or rotated 180 degrees away from the anesthesia team based on surgeon and institutional preference.

Positioning

- The patient should be supine for the entire case.
- The entire scalp should be prepped down below the nasal tip, with both orbits exposed to ensure adequate visualization.
- Hair on incision lines may be trimmed for ease of access.
- Eye protection (e.g., bilateral tarsorraphies or corneal shields) should be used.
- The endotracheal tube should be positioned and secured away from the surgical field.
- The abdomen should be prepped and draped in a sterile fashion for harvest of abdominal adipose tissue.
- If an endoscopic approach to the frontal sinus is to be combined with the osteoplastic procedure, monitors must be able to be positioned at the head of the patient for appropriate surgeon comfort.
- If image guidance is necessary, a frameless system should be used to avoid interference with the planned incision sites.

Perioperative Antibiotic Prophylaxis

- There are no high-quality data to help clearly dictate the ideal prophylactic regimen for osteoplastic obliteration.
- As this procedure is considered "clean contaminated," due to exposure of sinonasal contents to a skin incision, empiric coverage against typical flora in the sinonasal tract such as gram-positive and anaerobic organisms is appropriate.
- Appropriate antibiotic choices include:
  - First-generation cephalosporin and metronidazole
  - Amoxicillin-clavulanate
  - Clindamycin (penicillin/cephalosporin allergic patient)
- For patients with chronic sinusitis, prolonged culture-directed antibiotics should be considered postoperatively in select cases.

Monitoring

- No specialized monitoring is required unless the osteoplastic procedure is to be combined with an intracranial procedure, in which case appropriate monitoring for the intracranial procedure should be used (e.g., somatosensory evoked potentials, motor evoked potentials).

Instruments and Equipment to Have Available

- Standard head and neck set
- Raney clips for hemostasis
- Image guidance system
- Powered saw and osteotomes to create the osteotomies

- Cutting and diamond burrs for removal of frontal sinus mucosa
- Craniomaxillofacial plating system

Key Anatomic Landmarks

- *Galea*: The surgical flap should be elevated in the subgaleal plain to prevent injury to the scalp neurovasculature.
- *Temporalis fascia/muscle*: The temporalis fascia blends with the pericranium of the skull. The temporal branch of the facial nerve is located in the loose areolar tissue, superficial to this temporalis fascia. If requiring extensive lateral dissection below the level of the temporal adipose tissue pad, elevation of the flap should proceed deep to the temporalis fascia to prevent injury to the nerve.
- *Subraorbital rim*: This marks the inferior border of the frontal sinus.
- *Neurovascular bundle*: This exits the orbit through a foramen roughly 2 to 3 cm from the midline. It can often be palpated as a subtle indentation along the supraorbital rim.
- *Frontal sinus outflow tract*: This will be found in the floor of the medial aspect of the opened frontal sinus. This region must either be widely opened using a transnasal route or completely obliterated from above, to prevent recurrent sinusitis and mucocele formation.

Prerequisite Skills

- Standard open otolaryngologic head and neck surgical technique.
- Ability to perform endoscopic approaches to the frontal sinus (Draf II and Draf III procedures; see Chapters 112 and 113)
- Comfort with the anatomy of the bicoronal incision
- Techniques of skull base reconstruction
  - Craniomaxillofacial plating
  - Pericranial flap
  - Harvest of an adipose tissue graft from the abdomen

Operative Risks

- Inappropriate placement of the superior or lateral osteotomies with the potential for injury to the dura, CSF leak, and injury to the superior sagittal sinus
- Periorbital injury and exposure of orbital adipose tissue can occur with fracture of the floor of the frontal sinus. This is generally, however, of little consequence if recognized intraoperatively and orbital adipose tissue is not manipulated.
- Unintentional fracture of the anterior frontal sinus wall can occur while doing the osteotomies, which may require miniplate fixation.
- Injury to the facial nerve (temporal branch) can occur if significant dissection within the preauricular area is required for exposure.

Surgical Technique: Osteoplastic Flap

1. Mark the surgical incision.
   - A bicoronal incision is the standard approach, performed using an incision within the hairline that extends from helix to helix. This provides wide exposure and protects the scalp neurovasculature (Fig. 114.3).
   - Alternate incisions:
     - Midforehead incision, utilizing an existing forehead skin fold, can be used in cases of male-pattern baldness.
     - Upper brow ("gull wing") incision provides the most direct approach and requires less operative time and blood loss. May be of particular benefit for patients who are not ideal candidates for prolonged general anesthesia.
     - The brow incision will, however, require division of the scalp neurovascular bundle, causing permanent anesthesia of the forehead.
2. Raise the bicoronal flap.
   - The bicoronal flap is raised in a subgaleal plane inferiorly to the level of the supraorbital rim, preserving the scalp neurovasculature.
3. Incise the pericranium.
   - The pericranial incision should be made above the site of the expected superior osteotomy so that when the bone flap is replaced, the osteotomy will be covered by pericranium (Fig. 114.4).
   - Elevate the pericranium inferiorly to expose the frontal bone. The remainder of the pericranium can be left in place on the planned frontal bone flap. This will allow the bone flap to be pedicled on the pericranium, maintaining a more robust vascular supply.
   - A more generous pericranial flap can also be elevated at this point if desired (e.g., to be used for obliteration of the sinus).
4. Mark the dimensions of the frontal sinus.
   - This has traditionally been done by sterilizing a template derived from tracing a 6-foot Caldwell view (occipitalfrontal) radiograph. This provides an accurate definition of the frontal sinus.

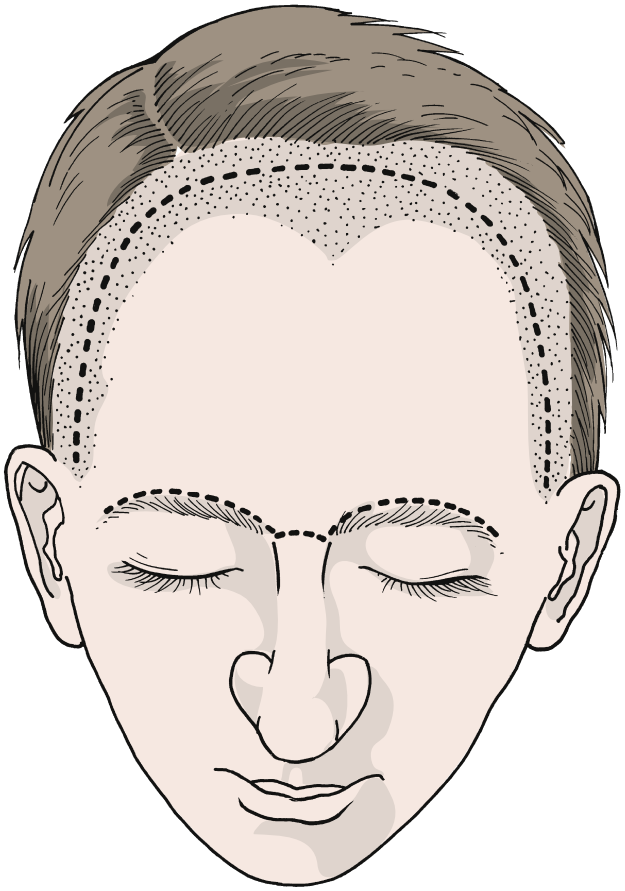

Fig. 114.3. A bicoronal or brow incision can be used to approach the frontal sinus. An incision within a midforehead rhytid (not shown) may also be of use in an older patient with significant male pattern baldness.

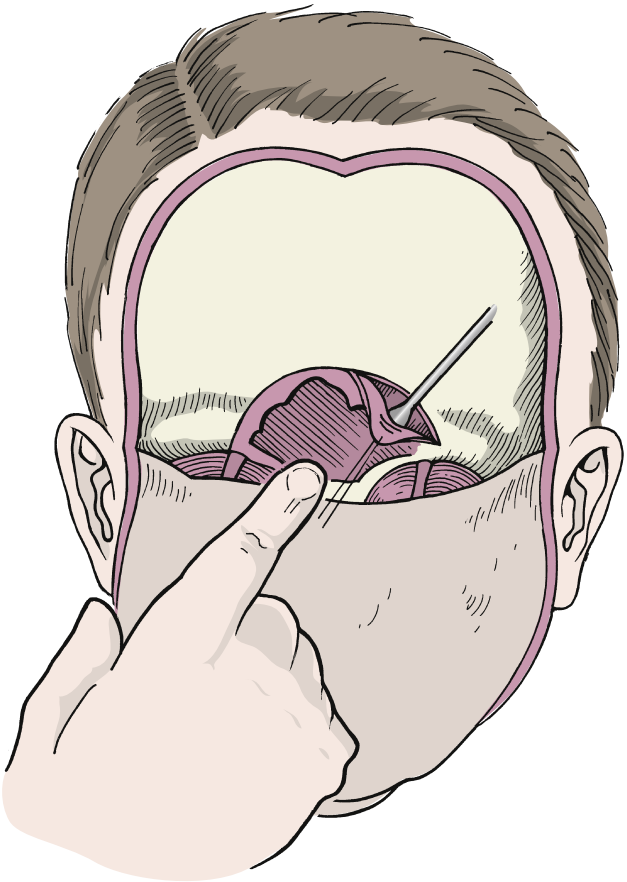

Fig. 114.4. After the template has been used to demonstrate the extent of the frontal sinus, the pericranium is elevated off of the planned osteotomies. The osteotomies can then be mapped on the frontal bone. The pericranium is maintained on the bone flap for closure at the end of the procedure.

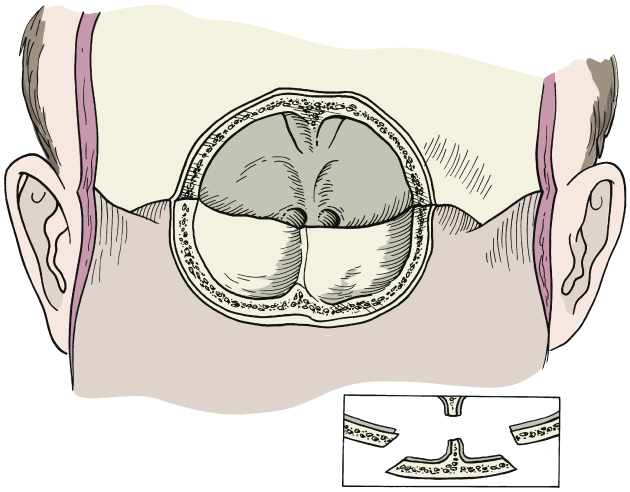

Fig. 114.5. Once the osteotomies have been outlined, a saw is used in a beveled fashion. This must be carried through the supraorbital rims inferiorly. An osteotome is then used to fracture the intersinus septum *(inset)*. Ideally the bone flap is then greenstick fractured downward (hinged on the remaining supraorbital rim), opening the sinus.

- More recently, a variety of other techniques have been described, which likely can be employed to more accurately map out the frontal sinus dimensions.
  - Mini-trephination followed by probing of the sinus
  - Trans-illumination of the sinus via a combined endoscopic approach
  - Image guidance systems

5. Opening of the frontal sinus
   - Generally a sagittal saw is used for this step, beveled at a 30- to 45-degree angle.[3,9] This creates a beveled edge that is useful for establishing a stable closure of the sinus at the end of the procedures.
   - The osteotomies must be carried into the supraorbital rims along the lateral aspects of the frontal sinus. An osteotome is then used to cut through the intersinus septum and pry forward the anterior wall of the frontal sinus (Fig. 114.5).
   - This maneuver will create a greenstick fracture through the supraorbital rims, allowing the osteoplastic flap to be hinged inferiorly. In practice, the fracture through the supraorbital rim may be more complete, creating a free-floating bone fragment. If no longer adequately attached to the overlying periosteum, this bone flap should be stored in saline and replaced before the end of the procedure.
6. Obliteration versus nonobliteration
   - In situations where the nasofrontal outflow tract is not compromised, sinus obliteration is generally not required. Examples include frontal sinus osteomas, other benign neoplasms, or lateral mucoceles that can be easily marsupialized for drainage into the sinus. In these cases, a combined endoscopic frontal sinusotomy is often performed to ensure long-term patency of the nasofrontal outflow tract and allow postoperative examination of the frontal sinus.
   - In the setting of chronic inflammatory disease, obliteration is required to prevent recurrence. Thorough removal of all sinus mucosa, using magnification, is a fundamental principle of this surgery required for successful outcomes. This requires the use of a cutting burr along thick bone and potentially a diamond burr along the orbital roof or any area of exposed dura.
   - The frontal outflow tract is specifically plugged using a multilayered plug combining bone dust or cartilage with an additional connective tissue layer (e.g., temporalis fascia).
7. Abdominal adipose tissue harvest
   - A curvilinear periumbilical incision is generally used. The incision is taken through the skin/dermis until the subcutaneous abdominal adipose tissue is encountered.
   - The skin flaps are made inferiorly and laterally (avoiding the umbilicus) until a suitable volume of tissue can be harvested.
   - The adipose tissue is then retracted out of the incision with a soft tissue clamp (e.g., Allis clamp), and scissors are used to remove the graft as a single block of tissue.
   - Hemostasis is obtained with bipolar cautery, and the wound is irrigated and closed over a small rubber drain with absorbable sutures. Steri-Strips are applied to complete the closure of the abdominal wound.
   - The tissue is cleaned with saline and trimmed appropriately. The adipose tissue graft is then brought into the head/neck operative field to completely obliterate the frontal sinus.
8. Replace the osteoplastic flap.
   - The osteoplastic flap is then replaced to close the frontal sinus.
   - The pericranium is closed using 4-0 chromic catgut sutures.

- Miniplates are then applied for stability.
- Some authors, however, advocate the use of fibrin glue alone to secure the bone flap, if adequately beveled osteotomies were initially performed.[9]

9. Skin closure
   - Multilayer closure of the bicoronal incision over a suction drain
   - To prevent brow ptosis, the soft tissue of the scalp flap should be resuspended to the superior, unelevated pericranium.

Reidel's Procedure

- Originally described in the 1890s, this is a radical/early variant of the osteoplastic approach.[10] The classic description includes complete exenteration of the contents of the frontal sinus, along with resection of the anterior wall and floor of the sinus. The forehead skin flap was then draped onto the exposed bony posterior wall of the frontal sinus, creating a significant cosmetic deformity, which has prevented widespread adoption of this technique.[1-3,10]
- More modern modifications of the original Reidel procedure (e.g., as proposed by Killian and Lothrop) may, however, continue to be applicable, in those rare instances when the anterior wall of the frontal sinus requires resection.[10]
- Indications:
  - Recalcitrant frontal sinusitis that has failed attempted osteoplastic obliteration
  - Chronic osteomyelitis of the anterior wall of the frontal sinus
  - Benign or malignant neoplasm causing significant erosion/remolding of the anterior table requiring its resection

Surgical Technique: Reidel's Procedure

1. Mark the skin incision.
   - Once again, the bicoronal incision is optimal to provide wide exposure and to allow preservation of the anterior scalp neurovasculature.
2. Raise the bicoronal flap, incise the periosteum, and open the frontal sinus.
   - The initial steps are completed in much the same fashion as the osteoplastic procedure described previously.
   - The osteotomies into the frontal sinus are now performed with the intention of removing the anterior wall and thus need not be precisely beveled.
   - To maintain the aesthetic contour of the brow region, it is essential to leave a supraorbital rim of bone (unless resection is absolutely required for disease clearance).
3. Contour edges of bony defect
   - The edges of the surgical defect are now contoured with a polishing burr, to create a gentle symmetrically sloping surface toward the posterior wall of the frontal sinus.[10]
   - The supraorbital rim is preserved, including the supraorbital and supratrochlear neurovascular bundles.
4. Closure of the incision
   - A standard multilayered closure is performed with the skin flap, allowing it to fit directly onto the posterior wall, thereby obliterating the frontal sinus.
   - The aesthetic defect can further be improved by augmenting the surgical site with an abdominal adipose tissue and/or pericranial graft.[5]
   - In appropriate patients, reconstruction of the anterior wall can also be considered. Split calvarial grafts are particularly useful in this situation, given proximity to the operative site, ease of harvest, limited patient morbidity, and natural contour to the defects.[5] Free grafts should, however, be used with caution in causes of sinonasal malignancy, given the need for radiotherapy. In patients with extensive bone defects, free tissue reconstruction of the frontal region would be required.

Common Errors in Technique

- Failure to bevel the initial skin incision in the direction of hair follicles, with a higher risk of localized alopecia
- Inaccurate definition of the frontal sinus, with improper placement of osteotomies
- Performing osteotomies that are not appropriately beveled (osteoplastic flap procedure), which makes closure of the sinus more challenging
- Inadequate removal of the mucosa of the frontal sinus (assuming sinus obliteration) leading to high likelihood of mucocele formation
- Failure to resuspend soft tissue of the scalp flap, with an ensuing risk of brow ptosis

POSTOPERATIVE PERIOD

Postoperative Management

- Standard inpatient management of the drain
- Pain control as necessary
- Resume normal diet and activity as tolerated.
- Generally no need for specialized wound or nursing care at the time of discharge
- After frontal sinus obliteration, physical examination will not adequately assess for surgical failure and mucocele formation. Magnetic resonance imaging (MRI) is considered an ideal technique for postoperative surveillance, particularly when abdominal adipose tissue is used for obliteration. In a series of 82 patients, Weber et al. in particular advocate scheduled MRI scans at 1, 2, and 5 years after surgery.[1]

Complications

1. Acute:
   - Hematoma, wound site infection, or surgical site dehiscence
     - Identified as swelling, redness, or breakdown of the incision
     - Will generally require reoperation with drainage of the hematoma, irrigation of the wound, and reclosure
     - Prolonged (at least 2 to 4 weeks) culture-directed antibiotics will be required if active infection is identified.
   - Fracture of the bone flap requiring operative repair or bone grafting
   - Dural injury and CSF leak
     - Common presenting symptom will be clear rhinorrhea or oropharyngeal drainage, often with a salty taste.
     - Definitive diagnosis often requires fluid collection and testing for beta-2 transferrin. CT or MR techniques may also be used to help localize the site of the leak.
     - Depending on the severity of the leak, initial treatment is often CSF diversion via lumbar drainage.
     - If unsuccessful, operative exploration and repair are necessary.
   - Periorbital injury with possible orbital hematoma
     - This is a true postoperative emergency that will pre sent with proptosis and limitation in eye movement and can progress to irreversible loss of visual acuity if not managed.

- Immediate surgical treatment within the postoperative care unit or surgical ward is required with a formal lateral canthotomy to relieve intraorbital pressure.
- It is then prudent to proceed to formal reoperative exploration and evacuation of the hematoma.

- Scalp paralysis (facial nerve injury)
  - If identified intraoperatively, direct nerve repair should be performed to improve the outcome.
  - If no obvious evidence of nerve transaction, an observation approach is often used given the likelihood of neuropraxia.
- Temporary anesthesia of the scalp

2. Chronic:
   - Failure of operation or extrusion/infection of the obliterative material
     - Recurrent sinusitis with mucocele formation occurs in roughly 10% of patients.
     - This is first managed with culture-directed antibiotics to control the acute infection and inflammation.
     - This can often be salvaged with an endoscopic approach to the frontal sinus.
     - If this is unsuccessful, a revision osteoplastic versus Riedel procedure will be required.
   - Frontal embossment or depression, due to resorption of the frontal bone
     - Over time, a depression at the surgical defect will be noted with increasing cosmetic deformity.
     - This will require operative exploration with removal of scarring. Cranioplasty either with autogenous bone or alloplastic grafts can then be performed to improve the aesthetic contour.
   - Poor aesthetic result (e.g., brow ptosis, hypertrophic scar, or localized alopecia)
   - Permanent anesthesia of the scalp (supraorbital/supratrochlear nerve injury)

Alternative Management Plan

1. Medical management of inflammatory frontal sinus disease
2. Endoscopic approaches to frontal sinus (e.g., Draf II and Draf III procedures; see Chapters 112 and 113)
3. Frontal sinus trephination
4. Frontal sinus cranialization

DISCUSSION

Evidence-Based Medicine Question

What materials can be used for frontal sinus obliteration?

The goal of sinus obliteration is to completely seal the nasofrontal outflow tract.[9] Abdominal adipose tissue was widely popularized for this indication, and thus there is a long clinical experience. The success of this material is attributed to its ability to promote vascular in-growth, with eventual replacement of the adipose tissue with stable fibro-osseus tissue.[6] While successful in most cases, osteoplastic procedures with obliteration using abdominal adipose tissue have an approximately 10% risk of long-term failure. Harvest of abdominal adipose tissue is also associated with a not insignificant donor site morbidity.[8]

A variety of autologous materials were initially investigated to potentially improve the limitations of abdominal adipose tissue. Animal studies comparing adipose tissue, autogenous muscle, and cancellous bone have failed to show significant differences in successful sinus obliteration.[5,6] Consequently autogenous muscle and cancellous bone have never been widely used clinically. Exogenous materials (e.g., hydroxyapatite bone cement) have also been used, with some initial success. However, these materials seem to promote a higher rate of extrusion/infection and thus should be used with caution.[1,4-6,8]

With advances in skull base surgery and reconstructive techniques, novel approaches have been more recently described. A vascularized pericranial flap is a particularly attractive obliterative material due to its location within the operative field.[8] This is a well-vascularized flap, which does not depend on vascular in-growth from potential diseased/osteitic frontal sinus bone for survival. Moshaver et al., for example, reported a series of 12 patients, successfully managed with pericranial flaps for obliteration, with no long-term treatment failures (average 5-year follow-up).[8] Tissue-engineered materials, specifically platelet-rich/fibrin-rich composite matrix, are also potentially attractive due to the lack of donor site morbidity and success within other regions of the craniomaxillofacial skeleton. A small series by Mendonça-Caridad et al. demonstrated promising results with no surgical failures reported.[7]

As there are no high quality comparative clinical data, no "ideal" obliterative material can be considered to exist. Due to long-term clinical use with reliable (but imperfect) results, abdominal adipose tissue graft should be considered the standard material of choice. However, initial evidence suggests that localized vascularized flaps and tissue-engineered materials may also be appropriate for frontal sinus obliteration.

Editorial Comment

The management of frontal sinusitis and its complications prior to the widespread use of antibiotics following World War II was challenging to say the least. Not only did patients suffer from infection confined to the sinus itself but often from severe complications such as meningitis, brain abscess, periorbital abscess, and osteomyelitis of the frontal bone.

Montgomery reported a series of 250 consecutive cases of osteoplastic frontal sinus operations performed at the Massachusetts Eye and Ear Infirmary from 1956 to 1972 and found that 12% of the patients in this series had presented with one or more of the previously mentioned complications. Obviously many of these patients would have died of these complications prior to the widespread use of antibiotics.

Surgery in the preantibiotic era for frontal sinusitis and its complications was limited to drainage procedures such as trephination or obliteration procedures such as the Reidel procedure (1898) described in this chapter, which was designed to eliminate chronic osteomyelitis of the frontal bone. However, removing the entire anterior wall and floor of the frontal sinus was quite disfiguring. Killian's operation (1904) was similar to the Reidel procedure but left a portion of the supraorbital rim that resulted in less alteration of the contour of the forehead but was also less effective in obliterating the sinus. The Lynch frontal operation (1920) became the most frequently employed operation for the treatment of chronic frontal sinusitis. The procedure consisted of an ethmoidectomy, removal of the middle turbinate, and resection of the entire floor of the frontal sinus. A tube was placed between the frontal sinus and the nasal cavity to establish drainage, and there was no resultant disfigurement.

Full credit should be given to William W. Montgomery, MD, Professor of Otolaryngology in the Harvard Medical School and Senior Surgeon at the Massachusetts Eye and Ear Infirmary, for reintroducing and modifying the osteoplastic frontal sinus operation. Attributed to Beck, of Chicago (1903), the anterior wall of the sinus becomes a "hinged boney trapdoor flap" that affords total visualization of the interior of the frontal sinus, thereby allowing complete removal of the disease, whether it is chronic sinusitis, mucoceles, or osteomas,

and without deformity. In Montgomery's series of osteoplastic frontal sinus operations, 42% of 250 patients had failed previous frontal sinus surgery, including Lynch and Reidel procedures and trephination.

Since the osteoplastic flap procedure has been around for a long time, what contributed to its success when Montgomery reintroduced it? Obliteration of the sinus cavity with adipose tissue taken from the abdominal wall made the difference. Montgomery's experimental work obliterating the frontal sinus with abdominal adipose tissue using the feline model demonstrated that varying amounts of the tissue survived due to revascularization of the adipose tissue by in-growth of blood vessels from the osseous sinus walls.

However, no operation is perfect, and in Montgomery's series, 20 of the 208 patients with follow-up required revision frontal sinus surgery from 4 days to 14 years after the osteoplastic procedure. It is of interest that only 4% of those patients whose sinus was obliterated with abdominal wall adipose tissue were later revised, compared with 10% of those patients whose sinus was not obliterated. In the modern era it is well known that adipose tissue from the abdominal wall is the richest source of stem cells, and I wonder if the introduction of stem cells into the frontal sinus was the secret of soft tissue healing so well in a bony cavity.

Eugene N. Myers



Access the review questions and additional source list online at http://www.expertconsult.com

REFERENCES

1. Weber R, Draf W, Keerl R, et al. Osteoplastic frontal sinus surgery with fat obliteration: technique and long-term results using magnetic resonance imaging in 82 operations. Laryngoscope 2000;110(6):1037–1044.
2. Chen PG, Wormald P, Payne SC, et al. A golden experience: fifty years of experience managing the frontal sinus. Laryngoscope 2016;126(4):802–807.
3. Salamone FN, Seiden AM. Modern techniques in osteoplastic flap surgery of the frontal sinus. Oper Tech Otolaryngol Head Neck Surg 2004;15(1):61–66.
4. Ochsner MC, DelGaudio JM. The place of the osteoplastic flap in the endoscopic era: indications and pitfalls. Laryngoscope 2004;125(4):801–806.
5. Bockmuhl U. Osteoplastic frontal sinusotomy and reconstruction of frontal defects. In: Kountakis S, Brent S, Draf W, editors. The Frontal Sinus. Heidelberg: Springer Publishing Co; 2005. pp. 281–289.
6. Rohrich RJ, Mickel TJ. Frontal sinus obliteration: in search of the ideal autogenous material. Plast Reconstr Surg 1995;95(3):580–585.
7. Mendonça-Caridad J, Lopez PJ, Fayos FV, et al. A novel approach to human cranial tissue regeneration and frontal sinus obliteration with an autogenous platelet-rich/fibrin-rich composite matrix: 10 patients with a 6-10 years follow-up. J Tissue Eng Regen Med 2013;7(6):491–500.
8. Moshaver A, Harris JR, Seikaly H. Use of anteriorly based pericranial flap in frontal sinus obliteration. Otolaryngol Head Neck Surg 2006;135(3):413–416.
9. Isa AY, Mennie J, McGarry GW. The frontal osteoplastic flap: does it still have a place in rhinological surgery? J Laryngol Otol 2011;125(2):162–168.
10. Raghavan U, Jones NS. The place of Riedel's procedure in contemporary sinus surgery. J Laryngol Otol 2004;118(9):700–705.

REVIEW QUESTIONS

1. Which of the following is not a typical indication for the osteoplastic flap procedure?
   a. Chronic frontal sinusitis
   b. Osteoma of the frontal sinus
   c. Mucocele within the far lateral aspect of the frontal sinus
   d. Large inverting papilloma of the frontal sinus

2. Which obliteration material has a relatively high rate of postoperative infection and extrusion?
   a. Abdominal adipose tissue
   b. Autogenous muscle
   c. Bone cement
   d. Pericranial flap

3. Each of the following are known acute complications of the osteoplastic flap procedure with frontal sinus obliteration, except
   a. Dural injury and CSF leak
   b. Cosmetic depression of frontal scalp
   c. Anesthesia of the scalp
   d. Periorbital/orbital injury

4. When raising a bicoronal flap, where is the temporal branch of the facial nerve located within the temporal region?
   a. Subcutaneous tissue
   b. Deep to the temporoparietal fascia
   c. Deep to the true temporal fascia
   d. Deep to the temporalis muscle

5. What complication is prevented by raising a bicoronal flap in the subgaleal plane?
   a. Brow ptosis
   b. Wound infection
   c. Postoperative hematoma
   d. Anesthesia of the scalp

ADDITIONAL SOURCE

Montgomery W. Surgery of the frontal sinus. In: 2nd ed. Montgomery W, editor. Surgery of the Upper Respiratory System, vol. 1. Philadelphia: Lea and Febiger; 1975.

115 Frontal Sinus Cranialization

Amit Goyal, Ramachandra P. Tummala, Emiro Caicedo-Granados

INTRODUCTION

The first description of frontal cranialization was in 1978 by Donald and Bernstein.[1] It consists of meticulous removal of the mucosa of the frontal sinus, eliminating the posterior wall of the sinus and allowing the frontal lobe to come to rest against the anterior table of the frontal sinus.

Historical Perspective

The concept of cranialization came from the evolution of treatment of extensive wounds in the frontal sinus and anterior skull base. The initial paradigm in the management of complex fractures of the frontal sinus was to remove all the bone fragments, resulting in a defect that allowed for expansion of the edematous frontal lobes. As a result, cosmetic issues were significant because of the resultant deformity of the forehead. With this paradigm, mucocele formation and mucocele-related infections remained a serious issue. In an attempt to address these issues, the surgery of the frontal sinus evolved into "cranialization." The anterior table is maintained, thereby avoiding a deformity of the forehead. The posterior table of the frontal sinus and the mucosa of the frontal sinus are meticulously removed. The anterior cranial fossa is permanently separated from the frontal recess. This eliminates the presence of the frontal sinus, provides additional space for the brain to expand, and decreases the risk of mucocele formation.

Initial reports by Donald[2] in 1982 and Luce[3] in 1987 concluded that the mucosa of the frontal sinus should be removed and the sinus ostia occluded in order to isolate the frontal sinus from the nasal cavity. Donald introduced the term "cranialization" in 1982, referring to removal of the posterior table of the frontal sinus, leaving the brain and dura to expand into the former frontal sinus cavity.[2] Rodriguez (in 2008) clarified the debate between cranialization and frontal sinus obliteration with a seminal work summarizing his 26-year experience with fractures of the frontal sinus. He reported a complication rate for cranialization of 10%, compared with 22% for frontal sinus obliteration.[4]

KEY OPERATIVE LEARNING POINTS

Knowledge of frontal sinus embryology and anatomy is critical for the surgical management of the frontal sinus.

- Secondary pneumatization of the frontal sinus commences between 1 and 4 years of age.
- The frontal sinus can be defined as a cavity after 4 years of age and will become more pneumatized by the age of 8 years.
- Significant pneumatization occurs during early adolescence and continues until the age of 18 years.[5]
- The frontal sinus can be divided in three surgical anatomic regions: the frontal sinus cavity, the frontal sinus ostium, and the frontal sinus recess. Frontal sinus cranialization will address the first two anatomic regions.
- It is important to understand the pneumatization and the posterior wall of the frontal sinus in addition to the variants of frontal sinus cells—mainly frontal sinus types II, III, and IV.[6] These frontal sinus cell variants need to be addressed, if present, when cranializing the frontal sinus.
- It is important to understand that there is no anatomic structure known as a naso-frontal duct, and by recent international agreement, the use of this term is now strongly discouraged.[7]
- The veins of Breschet transverse the posterior table of the frontal sinus through small foramina.[8] Meticulous removal of this mucosa within these foramina is critical for reducing the risk of postoperative formation of a mucocele.

PREOPERATIVE PERIOD

History

Patients who require frontal sinus cranialization classically present with a history related with the following:

- Patients with a malignant tumor of the anterior skull base usually have a history of nasal obstruction, epistaxis, hyposmia or anosmia, diplopia, facial pain, or sinus pressure associated with purulent rhinorrhea.
- Regarding patients with facial trauma, it is important to determine the type of trauma, either penetrating or blunt trauma. The history in these patients should include symptoms such as visual loss, diplopia, clear rhinorrhea (CSF leak), neurologic symptoms of meningitis, and mass lesions such as intracranial hematoma.
- Patients with inflammatory processes (chronic sinusitis) usually present with purulent rhinorrhea, facial pain, or pressure.

Physical Examination

Physical examination for patients requiring frontal sinus cranialization should emphasize the underlying pathology mentioned earlier.

- A complete examination of the head and neck must be performed, including the cranial nerves.
- It is important to evaluate for cervical metastasis in those patients with suspected underlying malignant disease.
- The use of nasal endoscopy is critical to obtain valuable information on tumor characteristics such as vascularity and extent.
- In patients with trauma, a complete examination of the orbit is mandatory, including checking pupillary reflexes and extraocular movements. In addition, the examiner should check for ptosis, chemosis, and proptosis.
- In trauma patients, one must be suspicious for CSF rhinorrhea.
- Ophthalmologic consultation should be obtained in patients with abnormal signs/symptoms involving the eyes.
- Examination of the anterior wall of the frontal sinus will determine its integrity.
- In patients with suspected frontal sinus inflammatory disease, palpation of the anterior table of the frontal sinus is important to rule out bone erosion or soft tissue mass (e.g., Pott's puffy tumor).

Imaging

Patients with tumors of the anterior skull base require both a computed tomography (CT) scan and magnetic resonance imaging (MRI) with and without contrast. These studies complement each other in determining the bony anatomy, bone erosion, extension of tumor, involvement of the dura, and edema of the brain. In patients with facial trauma, MRI should be obtained in selected cases. Sinus or head CT scan should be obtained to evaluate the following:

- Anatomy and integrity of the frontal sinus, with particular attention to the integrity of the anterior and posterior tables.
- Anatomy and integrity of the frontal sinus recess, especially with fractures through the frontal recess. This will allow the surgeon to predict stenosis of the frontal recess.
- Integrity of the facial bones and orbit.
- Acute neurosurgical sequelae of facial trauma, including pneumocephalus or intracranial hemorrhage that may need emergent management.

Indications

The main indication for frontal sinus cranialization is determination that the frontal sinus drainage cannot be restored. Examples of indications for cranialization are as follows:

- Severe traumatic injury of the frontal sinus with involvement of both anterior and posterior tables
- Displaced fracture of the frontal recess (outflow tract)
- Displaced fracture of the posterior wall of the frontal sinus with the presence of a CSF leak
- Need for neurosurgical intervention
- Cranialization should be considered as the final remedy for refractory chronic frontal sinusitis.
- Tumors of the anterior skull base or frontal sinus with erosion of the posterior table of the frontal sinus

Contraindications

- Patients who are poor surgical candidates because of associated injuries or severe medical comorbidities should not undergo this procedure.
- Patients with unresectable tumor determined by invasion of the brain, cavernous sinus, or orbit may not benefit from this surgical procedure.
- If the posterior table component is nondisplaced or minimally displaced with an intact frontal sinus outflow tract, consider a less aggressive procedure such as open reduction and internal fixation (ORIF) of the anterior table and close follow-up leaving salvage surgery using endoscopic frontal sinus procedures in reserve.

Preoperative Preparation

- Because most patients are unfamiliar with the concept of this operation, the surgeon must provide a detailed explanation. It is important to discuss with the patient the expectations, risk, and benefits of this surgical procedure. The patient needs to be aware of potential acute and long-term complications.
- MRI and sinus CT scan with and without contrast are critical for preoperative planning. In the case of a benign or malignant tumor, the extent of the disease should be determined in detail. MRI is an excellent tool to differentiate between tumors and retained sinus secretions. MRI and CT help evaluate involvement of the orbit, brain, cavernous sinus, and dura. This information is critical in planning the surgical procedure and in counseling the patient.
- In cases where the tumor is readily accessible through the nose or sinuses, a preoperative biopsy is indicated to aid in securing a diagnosis and planning for definitive resection.
- Patients with ophthalmologic or neurologic symptoms should be seen in consultation by ophthalmology and neurosurgery.

OPERATIVE PERIOD

Anesthesia

- Patients are placed under general endotracheal anesthesia. Administration of paralysis is recommended, and the endotracheal tube can be secured to the teeth using a wire or a 2-0 silk suture.
- Placement of an arterial line provides accurate and instantaneous hemodynamic monitoring.

Positioning

- The patient is placed in the supine position. The head is secured in the neutral position. If an endoscopic endonasal approach is expected, the head should be slightly hyperextended for better access to the frontal sinuses. The head can be positioned on a foam pad or a horseshoe or fixated in a head clamp.
- Frameless stereotactic navigation may be useful, especially in cases of distorted anatomy.
- Lower extremity compression devices are applied, and a Foley catheter is inserted.
- Bilateral tarsorraphies are placed.
- The patient's head and face are prepped and draped in a sterile fashion.
- A narrow strip of hair (about 2 cm) is shaved behind the anterior hairline.

Perioperative Antibiotic Prophylaxis

- A third-generation cephalosporin (e.g., ceftriaxone) is used as the main prophylactic antibiotic.
- If the patient is allergic to penicillin or cephalosporin, vancomycin and metronidazole are used.

Monitoring

There is typically not a need for intraoperative neurologic monitoring. Rarely, electromyography (EMG) may be useful for monitoring the extraocular cranial nerves in cases of orbital extension.

Instruments and Equipment to Have Available

A standard neurosurgical craniotomy and endoscopic sinus set. An operating microscope should be available if a transcranial intradural approach is planned.

Key Anatomic Landmarks

- The frontal branch of the facial nerve runs immediately deep to the temporoparietal fascia.
- The zygomatic arch has to be identified by palpation to plan the incision of the temporalis fascia. This incision is usually 2 cm above the zygomatic arch.

Prerequisite Skills

- Knowledge of the anatomy of the frontal sinus, anterior cranial fossa, and orbits
- Proficiency with the endoscope, operative microscope, and high-speed electric drill

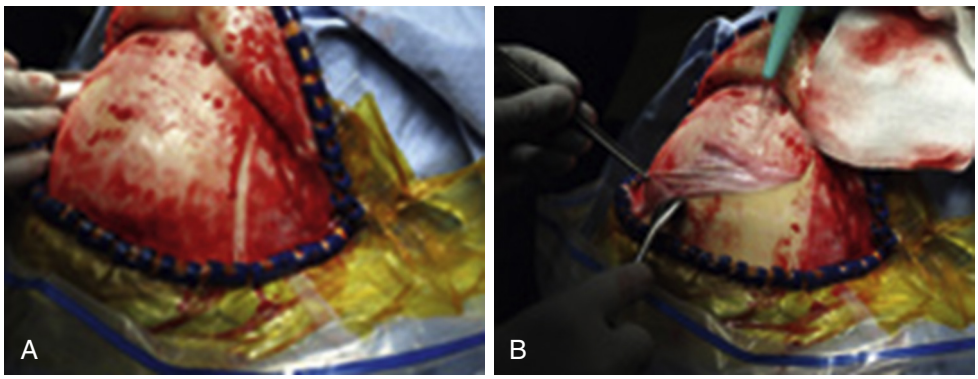

Fig. 115.1. Scalp flap. A, Scalp flap is elevated, and Raney scalp clips are applied. The pericranium is still attached to the calvarium. An incision is made at the transition between the pericranium and the superficial temporoparietal fascia. **B,** Elevation of the pericranial flap. The pericranial flap is elevated using a wide elevator. Gentle elevation and dissection are a must to maintain the integrity of the flap.

Operative Risks

- Damaged hair follicles: This can be avoided by using a knife blade to incise the scalp instead of an electrocautery. The incision has to be parallel to the hair follicles to minimize this risk.
- Injury to the frontal branch of the facial nerve (see section "Surgical Technique")
- Injury to the supraorbital or supratrochlear vessels, which will compromise the vascular supply of the pericranial flap
- Cerebrospinal fluid leak: Use the appropriate drill when performing burr holes and craniotomy to avoid injury to the underlying dura.
- Careful separation of the bone flap from the dura is critical to avoid dural tears or injury to the superior sagittal sinus.

Surgical Technique

- A bicoronal incision beginning just anterior to each tragus is made behind the hairline.
- The planned incision can be directed more posterior if a large pericranial flap is required.
- The incision can be linear or parallel to the hairline.
- The incision is carried down through the galea, and the scalp is dissected sharply with a scalpel along the loose areolar plane. This will reveal the pericranium overlying the frontal bone and the temporalis fascia in the temporal region (Fig. 115.1A).
- The pericranium is incised laterally on each side, just above the superior temporal line. The posterior incision in the pericranium is placed a few centimeters posterior to the initial skin incision.
- The vascularized pericranial flap is elevated off of the skull and carried anteriorly, with its blood supply preserved (see Fig. 115.1B).
- Any defects in the pericranium can be repaired with absorbable sutures.
- The degree of elevation of the scalp depends on how anterior an exposure is necessary (i.e., close to the nasion).
- If a very anterior exposure is needed, the temporalis fascia is incised, and a subfascial dissection is performed to retract the scalp and temporalis fascia as one flap. This dissection reduces the risk of injury to the temporal branch of the facial nerve.
- The dissection can be carried anteriorly enough so that the superior orbital rims are exposed bilaterally.
- For routine cranialization procedures, such low exposure is unnecessary.
- After the pericranial flap has been elevated, a bifrontal craniotomy is performed.
- The extent of the craniotomy varies, depending on how much exposure is necessary.
- Access to the frontal sinus can be gained through a relatively small craniotomy, but a large craniotomy flap is usually made for cosmetic purposes.
- The posterior aspect of a large craniotomy flap will lie behind the level of the hairline.
- A burr hole is typically placed at each keyhole, with one in the midline.
- For cosmetic reasons, placing burr holes low on the forehead is avoided.
- The midline burr hole is placed at the level of the hairline (Fig. 115.2A).
- If the dura is densely adherent to the inner table of the skull, additional burr holes are made to facilitate separation of the dura. This is especially important if the superior sagittal sinus is adherent to the skull.
- A high-speed craniotome is used to complete the single, bifrontal bone flap (see Fig. 115.2B).
- Once the bone flap has been removed, the frontal sinus is exposed bilaterally (Fig. 115.3A).
- The dura of the frontal lobe is dissected off the posterior wall of the frontal sinus.
- If necessary, the frontal lobes can be relaxed with head elevation, administration of osmodiuretics such as mannitol, or hyperventilation.
- Additional relaxation can be achieved with cerebrospinal fluid drainage from a ventricular or lumbar catheter.
- In the postoperative period, these drains may augment any repair of a CSF leak.
- If the frontal sinus has not been entered with the craniotomy, the posterior wall can be drilled off at this point. The remainder of the posterior wall is removed with a drill or rongeurs (see Fig. 115.3B).
- The mucosa of the frontal sinus is removed entirely using curettes, diamond burrs, and blunt dissectors.
- A diamond burr is used to take down boney prominences within the sinus, which allows hidden areas of mucosa to be removed. The frontal sinus infundibulum is obliterated using a combination of pieces of temporalis muscle, fascia, and fibrin glue.
- The pericranial flap is then laid down and reinforced with fibrin glue such that it covers the defect in the posterior wall of the frontal sinus and provides an additional layer of separation between the frontal sinus and the dura.
- In order to adequately employ the pericranial flap for this purpose, it should be laid down along the floor of the anterior fossa between the bone and dura.

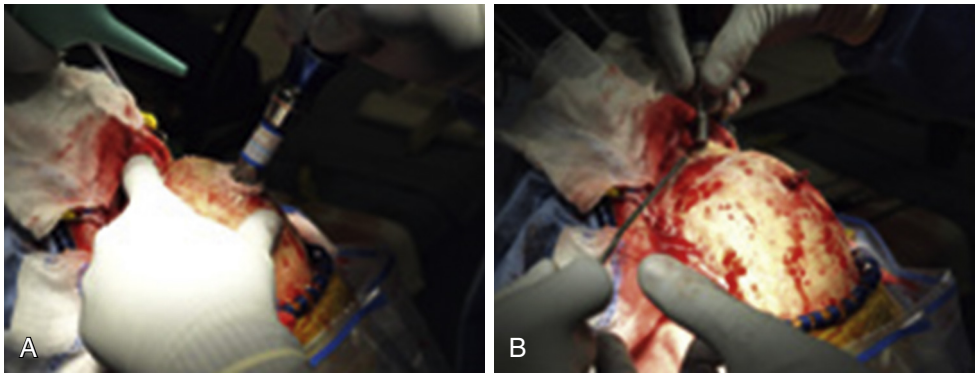

Fig. 115.2. Frontal craniotomy. A, A high-speed drill is used to create three burr holes, as described in the "Surgical Technique" section. The picture shows the creation of a midline burr hole at the level of the hairline. Notice the perpendicular orientation of the drill shaft and continuous irrigation. **B,** A high-speed craniotome is used to complete the single, bifrontal bone flap.

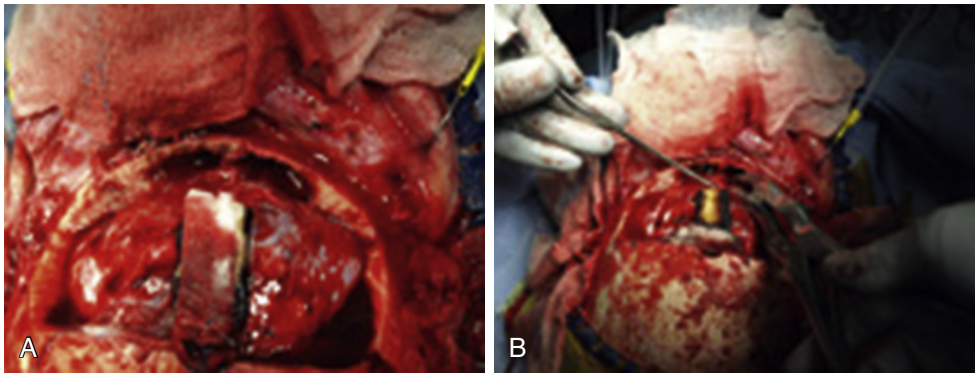

Fig. 115.3. Exposure of the frontal sinus. A, The frontal sinus is exposed, and, **B,** the posterior wall of the frontal sinus is removed using rongeurs and a high-speed drill as needed.

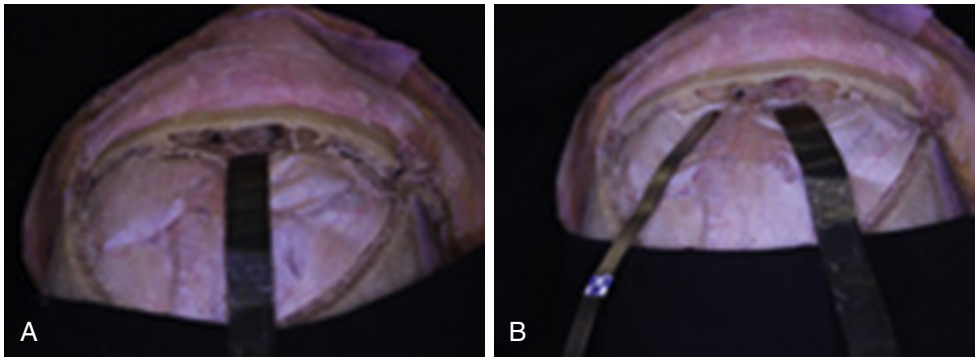

Fig. 115.4. Exposure of the frontal sinus infundibula. A, The posterior wall of the frontal sinus has been removed, and both frontal sinus infundibula are exposed. **B,** Occlusion of the right frontal sinus infundibulum with muscle and fascia.

- Care must be taken during this critical step to avoid any tearing or bunching up of the pericranial flap.
- Any dural defects are repaired directly with suture or indirectly with dural grafts and fibrin glue.
- The bone flap is repositioned and secured using mini-plates and screws once the fibrin glue has congealed (Fig. 115.4).
- The bone flap is replaced in such a way that will not crush and devascularize the pericranial graft.
- Leaving too much of a gap for the pericranial flap may create a cosmetic defect in the forehead.
- Any defect encountered or created in the anterior wall of the frontal sinus can be repaired using a combination of split calvarial bone graft, titanium mesh, and mini-plates.
- The scalp is closed in two layers after hemostasis has been ensured.
- Placement of a subgaleal drain can reduce postoperative periorbital edema. However, a drain is avoided if durotomies or CSF leaks are encountered in order to reduce the risk of a persistent CSF fistula.



Fig. 115.5. Reconstruction of bone flap. The frontal bone flap is replaced in the anatomic position and is secured with mini-plates.

Common Errors in Technique

- Making the skin incision perpendicular to the hair follicles
- Not extending the scalp incision down to the root of the helix will limit the rotation of the scalp.
- Dissecting between the temporoparietal fascia and the superficial layer of the deep temporal fascia will increase the risk of injury to the frontal branch of the facial nerve.
- Failure to harvest an adequate pericranial flap: The flap must be large enough to cover the resected posterior wall of the frontal sinus.
- Cosmetic defects low on the forehead: The craniotomy should be low on the forehead, but the thickness of the frontal sinus cavity will prevent the craniotomy drill from advancing too low. Attempts to go lower than what the sinus will allow will simply erode the anterior aspect of the frontal bone, leaving an unsightly gap upon replacement of the bone flap.
- Inadequate removal of the mucosa from the frontal sinus: A microscope or endoscope should be used to visualize and illuminate the depths of the frontal sinus and remove as much mucosa as possible. Using a diamond burr will allow the rest of the mucosa to be removed.
- Devascularization of the pericranial flap: The bone flap should be replaced in a manner that the pericranial flap is not crushed by the anterior edge of the bone flap (Fig. 115.5).

POSTOPERATIVE PERIOD

Postoperative Management

- Depending on the extent of the surgical procedure, patients are admitted to the neurosurgical intensive care unit or a step-down unit.
- A #15 flat Jackson-Pratt drain connected to a small lower pressure suction bulb and a pressure dressing is used. Usually the drain and the pressure dressing are removed within 2 to 3 days.
- The patient is usually discharged to the next level of care in 3 to 5 days.
- Skin sutures are removed 7 to 10 days after surgery.

Complications

- Postoperative alopecia
  - Prevention: Skin incision should be parallel to the hair follicles; avoid using electrocautery for skin incision.
  - Diagnosis: Physical examination will demonstrate alopecia along the incision line.
  - Treatment: Observation; dermatology consultation is an option
- Hematoma
  - Prevention: Ensure good hemostasis throughout the surgical procedure.
  - Diagnosis: Physical examination will demonstrate a subgaleal fluid collection.
  - Treatment: Incision and drainage
- Loss of the skin flap
  - Prevention: Avoid dissection in the subcutaneous plane. Make sure that the dissection of the skin flap is done in the subgaleal plane.
  - Diagnosis: Physical examination will demonstrate ischemia of the skin.
  - Treatment: Débridement and consultation with a reconstructive surgeon
- Paralysis of the forehead muscles due to injury to the frontal branch of the facial nerve
  - Prevention: When 2 cm above the zygomatic arch, the dissection transitions under the superficial layer of the deep temporal fascia.
  - Diagnosis: Postoperative physical examination will demonstrate brow ptosis. Patients may also complain of decreased visual fields and tension headaches and report seeing their eyebrows in their visual field.
  - Treatment: Surgical reanimation by an experienced reconstructive surgeon
- CSF leak
  - Prevention: Watertight closure of any dural tears is a must. The pericranial flap should rest on bony structures such as the roof of the orbita and planum.
  - Diagnosis: Evidence of clear rhinorrhea and a positive beta-2 transferrin test
  - Treatment: Spinal fluid diversion (lumbar drain) or surgical revision of the skull base closure
- Meningitis
  - Prevention: Prophylactic antibiotics
  - Diagnosis: Physical examination showing findings compatible with meningitis
  - Treatment: Antibiotic therapy accordingly with culture results
- Contour defect
  - Prevention: Usually a result of trauma, not surgical technique
  - Diagnosis: Physical examination
  - Treatment: Split thickness calvarial or alloplastic grafts for cranioplasty to correct the deformity
- Frontal sinus mucocele or mucopyocele
  - Prevention: Remove the entire mucosa from the frontal sinus.
  - Diagnosis: Most of the mucoceles are asymptomatic and are diagnosed with follow-up imaging. A group of patients will develop acute infection in a mucocele (mucopyocele).
  - Treatment of the mucopyocele is with antibiotics, followed by incision and drainage (usually done endoscopically). If not infected, the recommendation is to remove the mucocele to prevent problems in the future.
- Frontal bone osteomyelitis
  - Prevention: Prophylactic antibiotics
  - Diagnosis: Patient history and physical examination supplemented by CT and MRI scans
  - Treatment: Aggressive intravenous (IV) antibiotics and possible surgical débridement with sequestrectomy of frontal bone if necessary
- Brain abscess
  - Prevention: Prophylatic antibiotics
  - Diagnosis: Patient history and physical examination supplemented with MRI scan

  - Treatment: For epidural and subdural empyemas, surgical evacuation followed by IV antibiotics; intracerebral abscess warrants needle aspiration followed by IV antibiotics
- Temporal wasting if adipose tissue pad was elevated and devascularized
  - Prevention: Dissection in the correct plane when elevating the temporalis muscle, while ensuring not to injure the frontal branch of the facial nerve
  - Diagnosis: Physical examination
  - Treatment: Because this primarily presents as a cosmetic deformity, many times it can be left untreated; otherwise, an adipose tissue graft can be used to help with cosmesis.

Alternative Management Plan

Currently, with the establishment of advanced endoscopic skull base techniques, cranialization has been increasingly replaced by Draf III frontal sinusotomy.

DISCUSSION

Evidence-Based Medicine Question

Does frontal sinus cranialization decrease the rate of postoperative complications when compared with frontal sinus obliteration in the treatment of frontal sinus tumors?

There is a lack of literature comparing the results between frontal sinus obliteration and cranialization. Horowitz et al.[9] analyzed 69 patients who underwent excision of benign frontal sinus lesions by an open approach using frontal sinus obliteration in 41 patients (59%) and frontal sinus cranialization in 28 patients (41%).

The frontal sinus lesions treated were osteoma, mucocele, encephalocele, and fibrous dysplasia. The complication rate in the obliteration group was 29.2% and 17.8% in the cranialization group. In the obliteration group mucocele formation happened at a median time of 4.3 years. Patients who developed mucocele in the obliteration group were treated with frontal sinus cranialization, and none of those patients required a second revision surgery. Statistical analysis demonstrated that frontal sinus cranialization is not inferior to obliteration in preventing secondary mucocele formation.

Editorial Comment

Frontal sinus cranialization is a critical technique in the management of both frontal sinus trauma and malignancies of the anterior cranial base. Despite the advent of endoscopic techniques, severe traumatic disruption of the posterior table and malignancies that extend anteriorly in the frontal sinus are often best managed with this procedure. While conceptually straightforward, the many nuances highlighted in this chapter, including careful placement of the craniotomy, differential dissection to preserve the adipose tissue pad containing the frontal branch of the facial nerve, and allowing adequate space for the vascular pedicle of the pericranial flap below the anterior table, are critical for the functional and aesthetic outcome of the procedure. Meticulous removal of the entire posterior table and the mucosa from the frontal sinus is critical and is generally the most challenging in highly pneumatized frontal sinuses with large supraorbital ethmoid cells. Finally, obliteration of the frontal outflow tract can be performed with a variety of substrates and is often surgeon dependent. However, autologous grafts are generally favored, as exposure of porous foreign material to the sinonasal cavity can result in long-term infectious complications.

Eric W. Wang

Access the review questions online at http://www.expertconsult.com



REFERENCES

1. Donald PJ, Bernstein L. Compound frontal sinus injuries with intracranial penetration. Laryngoscope 1978;88:225–232.
2. Donald PJ. Frontal sinus ablation by cranialization. Report of 21 cases. Arch Otolaryngol 1982;108:142–146.
3. Luce EA. Frontal sinus fractures: guidelines to management. Plast Reconstr Surg 1987;80:500–510.
4. Rodriguez ED, Stanwix MG, Nam AJ, et al. Twenty-six-year experience treating frontal sinus fractures: a novel algorithm based on anatomical fracture pattern and failure of conventional techniques. Plast Reconstr Surg 2008;122:1850–1866.
5. Duque CS, Casiano RR. Surgical Anatomy of the Frontal Sinus. Berlin-Heidelberg: Springer; 2005.
6. Kuhn FA. Chronic frontal sinusitis: the endoscopic frontal recess approach. Oper Tech Otolaryngol Head Neck Surg 1996;7:222–229.
7. Pollock RA, Hill Jr JL, Davenport DL, et al. Cranialization in a cohort of 154 consecutive patients with frontal sinus fractures (1987-2007): review and update of a compelling procedure in the selected patient. Ann Plast Surg 2013;71:54–59.
8. Messerklinger W. On the drainage of the normal frontal sinus of man. Acta Otolaryngol 1967;63:176–181.
9. Horowitz G, Amit M, Ben-Ari O, et al. Cranialization of the frontal sinus for secondary mucocele prevention following open surgery for benign frontal lesions. PLoS One 2013;8:e83820.

REVIEW QUESTIONS

1. A key anatomic feature of the posterior wall of the frontal sinus is:
   a. The lack of bone marrow
   b. It is usually a flat surface
   c. Its vascular supply is mainly from branches of the middle cerebral artery
   d. The presence of the veins of Breschet
   e. All of the above

2. The following are indications for frontal sinus cranialization, except
   a. Recalcitrant frontal sinusitis
   b. Severe frontal trauma with displaced fracture of the posterior table
   c. Benign tumor located in the frontal recess
   d. Malignant tumor of the anterior skull base with erosion of the posterior table of the frontal sinus
   e. None of the above

3. The frontal branch of the facial nerve in the temporal region runs
   a. Deep to the deep layer of the deep temporal fascia
   b. Superficial to the deep layer of the deep temporal fascia
   c. Within the temporal adipose tissue pad
   d. Superficial to the temporoparietal fascia
   e. Deep to the temporoparietal fascia

4. Which of the following is the least likely complication following frontal sinus cranialization?
   a. CSF leak
   b. Seizures
   c. Mucocele formation
   d. Blindness
   e. Brain abscess formation

5. All of the following can be used to relax the brain, except
   a. Mannitol
   b. Reverse Trendelenburg position
   c. Hypercarbia
   d. Hyperventilation
   e. Lumbar drain

116 Endoscopic Management of Cerebrospinal Fluid Leaks

Christopher J. Chin, Ricardo Carrau, Carl H. Snyderman, Allan Vescan

INTRODUCTION

A cerebrospinal fluid (CSF) leak defines a fistula between the subarachnoid space and the sinonasal tract. Patients with CSF leaks present with symptoms such as clear nasal discharge and headache or complications such as pneumocephalus, meningitis, or brain abscess. The main indication for repairing a CSF leak is to prevent these potentially life-threatening complications.

CSF leaks can be classified in a number of ways; etiology and anatomic site are commonly used to classify CSF leaks. Etiologic classification can be subdivided into traumatic and nontraumatic origin. Within the traumatic group, leaks can be either accidental or iatrogenic. Most CSF leaks are caused by traumatic fractures of the cranial base or by injuries produced during endoscopic sinus surgery (ESS) or cranial base surgery. CSF leaks are diagnosed in 3% of patients suffering closed head injuries and in up to 30% of patients with a fracture of the skull base.[1] Iatrogenic trauma, such as traditional cranial base surgery and ESS, can also be associated with CSF leaks. ESS remains one of the most common etiologies for CSF rhinorrhea, despite an overall incidence of less than 1% in patients undergoing ESS.[2,3] Nontraumatic CSF leaks may occur secondary to tumors of the skull base, congenital malformations, and/or high-pressure hydrocephalus (HPH). The etiology of HPH includes tumors, trauma, infections, and hemorrhagic cerebrovascular accidents (CVAs). Occasionally, no etiology is identified for the HPH, and it is therefore deemed "idiopathic."

Multiple techniques have been reported for the repair of a CSF fistula. The modern era of CSF leak repair was ushered in when, in 1985, Calcaterra[4] described the use of free muscle or fascia grafts to treat CSF fistulas. This was followed in 1989 by Papay et al.,[5] who described an endoscopic technique that has become the standard of care. Recently, a vascularized nasoseptal flap has been devised to reconstruct skull base defects of various etiology, and early follow-up data reveal a remarkable improvement in CSF fistula rates following expanded endonasal approaches to the skull base.[6] The endoscopic endonasal approach has become the standard repair option and has been shown to have low complication rates with high success rates.[7]

The availability of the biologic material and the experience and familiarity of the operating surgeon with various techniques are the most predominant factors influencing the choice of which is used during the endoscopic endonasal closure of CSF fistulas. Most techniques yield similar results in experienced hands, as confirmed by a meta-analysis of the literature by Hegazy et al.[8] After analyzing all reports in the English literature, these authors found no significant differences in outcome regardless of which surgical technique or which homologous material was used for the repair.

KEY OPERATIVE LEARNING POINTS

- Biochemical confirmation is essential in diagnosing CSF leaks.
- After the diagnosis is confirmed, imaging can be used to help to localize the lesion.
- Complete exposure of the skull base, and the site of the leak, will facilitate a more thorough repair.
- Image guidance can be used to help to confirm the location of the leak if it is seen on preoperative imaging.
- The underlying cause of the leak should be addressed; if the patient has intracranial hypertension, this should be treated to prevent failure of the repair.
- The first-line treatment for a spontaneous CSF fistula should not include a lumbar drain.

PREOPERATIVE PERIOD

History

- The diagnosis and management of a CSF leak involves three critical steps:
  - Distinguishing a CSF leak from other sources of rhinorrhea
  - Locating the fistula
  - Ruling out high intracranial pressure secondary to altered CSF dynamics
    - Demographic information can help to guide the workup; spontaneous CSF leaks are most commonly seen in young or middle-aged obese females.
    - Hydrocephalus can be the result of posttraumatic, postsurgical, and postinfectious scenarios due to obstruction of the arachnoid villi.
- A clinical diagnosis of a CSF leak is based on a history of rhinorrhea:
  - Clear, watery nasal drainage
  - Usually the rhinorrhea is unilateral.
  - Commonly associated with headache
  - Increased rhinorrhea when the patient leans over, tilts the head forward, or performs a Valsalva maneuver
- History of tumor, trauma, or previous surgery involving the paranasal sinuses or cranial base heightens the level of suspicion.

- Occasionally, a life-threatening complication arising from the CSF leak, such as pneumocephalus, or ascending bacterial meningitis may be the initial presentation.
- Conditions such as vasomotor rhinitis and sympathetic denervation can cause profuse rhinorrhea that may be confused with a CSF leak.
- Nasal irrigations during ESS (or used as part of the postoperative care) may accumulate in the paranasal sinuses and later present as postoperative rhinorrhea.

Physical Examination

- A full examination of the head and neck, including endoscopic examination of the nasal cavity, should be completed to attempt to identify the source of CSF rhinorrhea.
- Having the patient "provoke" the leak, by bending over in a "head down" position, can sometimes help to identify the site of an active leak.
- When CSF rhinorrhea develops after sinus surgery, the endoscopic surgeon typically has an impression as to the possible site of injury to the cranial base.
  - A thorough endoscopic office examination of the nasal cavity may corroborate the site of the leakage.
  - Fistulas with low-pressure leaks are difficult to identify, especially in the presence of postoperative tissue edema and blood clots.

Imaging

- Biochemical testing is indicated to confirm the true nature of the nasal drainage and should be done prior to ordering expensive imaging tests.
  - CSF will typically be high in glucose and low in protein.
  - Normal nasal discharge has been shown to be falsely positive for glucose in 45% to 75% of cases.
  - β_2-Transferrin is a protein found in CSF, aqueous humor, and perilymph but not in blood or nasal secretions; therefore β_2-transferrin is a reliable chemical marker of CSF leakage.
  - A second protein, β-trace protein, is also available but not as widely used as β_2-transferrin.
- Multiple imaging modalities have been advocated for the diagnosis of CSF leak, each with their own advantages and disadvantages.
  - Scintigraphy with indium (In-111) is one test that has been advocated for the identification of a CSF leak.
  - Radiotracing is a very sensitive test; however, it is associated with a high false-positive rate and has poor resolution that precludes establishing the specific point of leakage; at our institution, scintigraphy is rarely performed.
- In our practice, the presence of the CSF leak is typically confirmed with β_2-transferrin electrophoresis, and its site of origin is identified by computed tomography (CT), magnetic resonance (MR) or CT cisternography (Fig. 116.1), and/or endoscopy.
- An important consideration in a patient presenting with spontaneous rhinorrhea or rhinorrhea after skull base trauma is to distinguish whether the CSF rhinorrhea arises from the sinonasal tract or from other sites, such as the middle ear or mastoid (Fig. 116.2).
- A CSF fistula in the temporal bone may drain into the nose through the eustachian tube.
- Radiographically, a high-resolution computed tomography (HRCT) can be used to identify a cranial base defect.
  - HRCT is our preferred initial imaging study to aid in the identification of the site of injury and its extent (see Fig. 116.1).

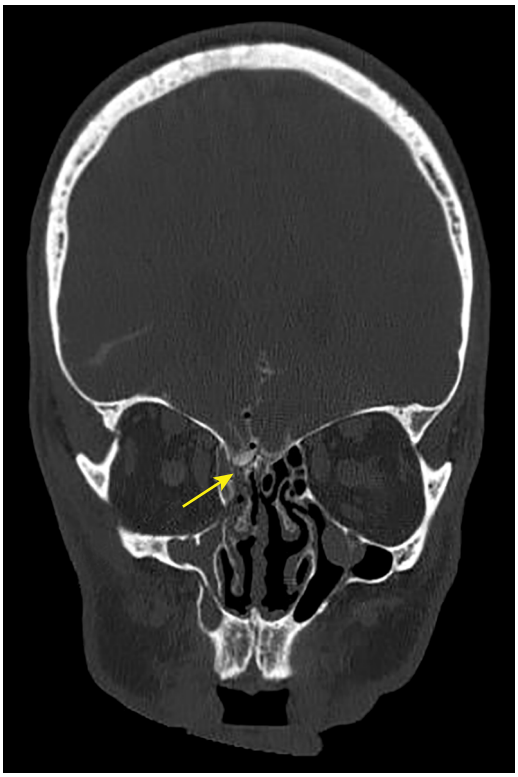

Fig. 116.1. Coronal computed tomography cisternogram demonstrating a posttraumatic cerebrospinal fluid fistula *(arrow)* of the right cribriform plate.

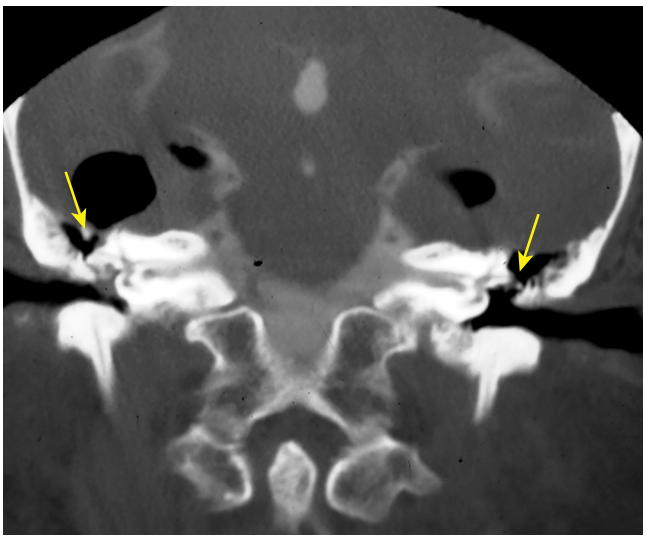

Fig. 116.2. Coronal computed tomography cisternogram demonstrating bilateral tegmen defects with contrast penetrating existing defects *(arrows)*.

  - HRCT with contrast also provides information about the possibility of intracranial complications, such as hematoma or brain contusion, that occur in the setting of acute trauma (iatrogenic or accidental).
  - HRCT with cuts taken in the coronal and sagittal planes is essential to evaluate the integrity of the bony wall in question.
  - Coronal CT views are best to evaluate defects of the cribriform plate, fovea ethmoidalis, or planum sphenoidale,



Fig. 116.3. Sagittal magnetic resonance imaging demonstrating a large meningoencephalocele *(arrows)* of the anterior cranial base.

whereas axial views are superior to evaluate the posterior wall of the frontal or sphenoid sinuses.
  - Indirect signs of a CSF leak include collection of fluid in a sinus and pneumocephalus.
- We use magnetic resonance imaging (MRI) to differentiate meningocele and meningoencephalocele (Fig. 116.3), as well as to better delineate the vascular anatomy, which is important when considering a surgical repair.
- HRCT, although an excellent first imaging choice, may not identify small areas of surgical trauma or linear nondisplaced fractures.
  - HRCT can be used in conjunction with intrathecal contrast to identify the fistula, a so-called CT cisternogram; this test has been documented to be both sensitive and reliable.
  - However, identification of the fistula using contrast studies requires the presence of an active leak, which is not always the case clinically.
  - Intermittent leaks that are temporarily sealed by edema, inflammation, or brain herniation may yield a false-negative result.
  - Intrathecal injection of saline solution to increase the CSF pressure, a "saline challenge," enhances the sensitivity of the test.
- MR cisternography has been suggested to complement the information offered by an HRCT; however, in our experience this technique has yielded inconsistent results.

Indications

- CSF leak with biochemical confirmation

Contraindications

- Failure to confirm the presence of a CSF fistula on biochemical testing
- Patient medically unfit for general anesthetic
- Active infection of the sinonasal tract

Preoperative Preparation

- Intrathecal fluorescein may be used to aid in the diagnosis and localization of the CSF leak.
- During this test, 0.15 mL of fluorescein, of a concentration no greater than 5%, is diluted with 10 mL of CSF, obtained through a lumbar puncture, and is then injected slowly intrathecally over 3 to 5 minutes.
- Fluorescein is neurotoxic and a low concentration–low volume injection is mandatory to avoid the neurologic complications associated with higher concentrations.
- After intrathecal injection of the fluorescein solution, the CSF leak may be visualized using the nasal endoscope.
  - Under a Wood lamp (i.e., black light), fluorescein will appear as bright yellow-green; nonetheless, the yellowish color of fluorescein may be identified without the need for special lighting.
- Some clinicians have been discouraged from using fluorescein because of:
  - The logistics of performing a lumbar puncture in an outpatient setting
  - Medicolegal considerations (the fluorescein drug package insert includes an advisory warning against intrathecal use)
- Intrathecal injections, in any case, are rarely critical to the identification of the CSF fistula.
- Exceptional patients are those with multiple fistulas, such as those who suffered skull base fractures, and the rare patient who presents with repeated episodes of meningitis in the absence of an apparent cranial base defect or other predisposing factors, such as rhinosinusitis or otitis media.
- Others have advocated the intrathecal injection of air, which can "bubble" out at the fistula site, thus aiding in its identification.
  - Of note, air is an irritant to the brain and may induce seizures.
  - Alternatively, normal saline solution may also be injected into the intrathecal space to increase the pressure within the subarachnoid space and increase flow at the site of the leak.

OPERATIVE PERIOD

Anesthesia

- As with all ESSs, controlled hypotension is beneficial in improving visualization.
- An oral Ring, Adair, Elwyn (RAE) tube may be beneficial to ensure the anesthesia circuit does not interfere with the surgery.
- The use of topical vasoconstrictors is essential to improve visualization, and communication with anesthesia is important because of their vasoactive properties.
- It is important to communicate with the anesthetist and anesthesia team that theoretically there is a risk of pneumocephalus with an open skull base defect and positive pressure mask ventilation should be avoided; a nasal airway can be considered.

Positioning

- The patient should be supine, in reverse Trendelenburg position, to decrease bleeding and improve visualization.
- Extension of the neck provides increased access to the anterior cranial base.
- The eyes should be covered with clear tape and exposed during the surgery.

Perioperative Antibiotic Prophylaxis

- Although commonly used, the evidence for antibiotic use is limited (see Evidence-Based Medicine Question later).

- If an antibiotic is used, it is recommended to use an antibiotic with good penetration of the blood-brain barrier, such as ceftriaxone.

Monitoring

- Routine anesthesia monitoring should be used.
- Muscle paralysis can be used because no intraoperative nerve stimulation is anticipated.

Instruments and Equipment to Have Available

- Standard ESS set
- If a fascia lata graft is to be harvested, a soft tissue set should be available.
- A full complement of angled endoscopes, including a 30- and 70-degree scope, is often helpful for visualizing the skull base.
- A "needle tip" cautery is useful when planning to raise a nasoseptal flap.
- An image guidance system is useful for identifying the site of the leak.
- If intraoperative intrathecal fluorescein is to be used, a lumbar puncture (± lumbar drain insertion) must be performed preoperatively.

Key Anatomic Landmarks

- The site of the leak determines which landmarks are most important.
  - The lateral lamella of the cribriform plate is a frequent site for iatrogenic leaks; the middle turbinate, anterior ethmoidal artery, and bulla ethmoidalis are important landmarks.
  - If the leak is in the sphenoid sinus, the optic nerve and internal carotid artery (ICA) are important to identify, in addition to potential exposure of the lateral recess of the sphenoid, foramen rotundum, and the vidian nerve (which acts as a reliable landmark for the ICA).

Prerequisite Skills

- The surgeon should have the ability to perform a thorough endoscopic sinus operation, including a wide sphenoidotomy and frontal sinusotomy.
- Comfort with skeletonizing the skull base

Operative Risks

- As with any surgery, risks include postoperative bleeding, infection, and the standard risks with general anesthesia (such as myocardial infarction and pulmonary embolism).
- Injury to the rectus muscles and/or optic nerve can result in diplopia, decreased visual acuity, or blindness.
- Injury to the brain or dura can result in neurologic impairment or meningitis.
- Injury to the carotid artery can result in life-threatening bleeding.

Surgical Technique

Ethmoid Sinus Roof and Cribriform Plate

- If a CSF leak is suspected during ESS, the overlying mucosa should be reflected away to closely examine the area and to determine the extent of injury.
- If the injury is iatrogenic from a microdébrider, it is important to rule out an intracranial vascular injury, highlighting the importance of preoperative imaging.
- An inlay or onlay free tissue graft may be used to patch the site of injury; entire exposure of the defect is essential.
- Fascia lata, temporalis fascia, abdominal adipose tissue, septal or middle turbinate mucosa or composite grafts, periosteum, and perichondrium are all suitable grafting tissues.
- Whenever possible, the dural edges are undermined with a small elevator, and the edges of the graft are tucked between the dura and the bone (i.e., epidural inlay graft).
  - Mucosa should not be used as an inlay graft; it should be reserved for use as an onlay graft.
  - Alternatively, the dura may be separated from the brain, and the inlay graft may be placed in the subdural space.
  - When an inlay graft is not possible due to technical difficulties or because the fistula involves a linear fracture that does not expose the dural defect, the graft is placed as an onlay over the defect (i.e., outside the cranial cavity).
  - Free muscle or adipose tissue grafts can also be used as a dumbbell-type plug.
- Fibrin glue, platelet-rich serum, or other biologic glue may be used to increase the adhesiveness of the muscle or fascia graft.
- The graft is typically supported in place with layers of Gelfoam (Pharmacia and Upjohn Co., Kalamazoo, Michigan), followed by packing with bacitracin-impregnated gauze, sponge packing, or the inflated balloon of a Foley catheter.
- Gelfoam prevents adherence of the packing material to the graft, preventing accidental avulsion when the packing is removed, 3 to 7 days after the surgery.
- Alternatively, a vascularized tissue flap may be designed and harvested transnasally using mucoperichondrium from the middle turbinate or septum.[6]
- If the fistula involves the cribriform plate, the mucosa and bone of the medial aspect of the middle turbinate are removed and the remaining mucoperiosteal flap is rotated to cover the defect or to cover a muscle or free fascial graft.
  - Similarly, the mucosa and bone of the lateral aspect of the middle turbinate may be removed and the remaining mucoperiosteal flap is rotated to cover a defect of the fovea ethmoidalis.
  - An additional option includes the removal of mucosa from a portion of the ipsilateral septum, removal of the corresponding septal cartilage or perpendicular plate of the ethmoid, and rotation of the contralateral mucoperichondrial flap to cover the defect. However, this will result in a septal perforation.
- The flap is then supported by Gelfoam and bacitracin-impregnated gauze.
- The Hadad-Bassagasteguy flap consists of a septal mucoperichondrial/mucoperiosteal flap based on the posterior septal artery and can be used to effectively cover very large defects of the skull base.[6]

Sphenoid Sinus

- The sphenoid sinus is most commonly approached transnasally with endoscopic visualization, as when performing pituitary surgery (see Chapter 117).
- CSF leaks involving the sphenoid sinus are amenable to a repair that includes obliteration of the sinus.
- After proper identification of surgical landmarks, such as the carotid canal, optic nerve canal, and optic carotid recesses, and identifying the leak, the mucosa of the sphenoid sinus is thoroughly removed.
  - This helps with establishing the extent of the defect and preparing the sinus for obliteration.
  - Onlay or inlay free tissue, nonmucosal grafts are placed, and the sinus is then obliterated with an abdominal adipose tissue graft.

- Anteriorly the exposed adipose tissue is covered with a layer of Surgicel (Ethicon, Neuchatel, Switzerland) followed by Gelfoam, and the nose is packed with ½-inch nasal strip that has been impregnated with antibiotic ointment or with the inflated balloon of a Foley catheter.
- An intraoperative CSF leak arising from the sella turcica during pituitary surgery most often can be repaired by obliterating the sella with adipose tissue and reconstructing the floor of the sella with a free bone or cartilage graft harvested during the endoscopic approach.
  - It does not require postoperative packing or the removal of the entire mucoperiosteum of the sinus.
- Alternatively, standard techniques such as inlay grafts with fascia lata, followed by the previously described nasoseptal flap, have been very effective in repairing these defects.
- The risk of accidental injury to adjacent neurovascular structures is a critical consideration when dealing with defects of the lateral wall of the sphenoid sinus; adequate visualization of this area is mandatory.
- Leaks that arise in the lateral recess present technical difficulties due to their poor visualization after a traditional sphenoidotomy (Fig. 116.4).
- Repair often requires ligation of the sphenopalatine artery and extension of the sphenoidotomy toward the pterygopalatine fossa.
- The transpterygoid approach can be combined with an endoscopic medial maxillectomy as necessary, to allow adequate range of motion and visualization of even the most lateral of sphenoid defects.
  - Through this extended lateral approach to the sphenoid sinus, the endoscopic surgeon is now able to use a zero-degree scope and straight instruments to replace angled scopes and working around corners.
  - In addition, a contralateral approach with removal of the sphenoid rostrum can facilitate instrumentation and access.

Frontal Sinus

- CSF leaks involving the frontal sinus are usually repaired using an open, transfrontal sinus approach.

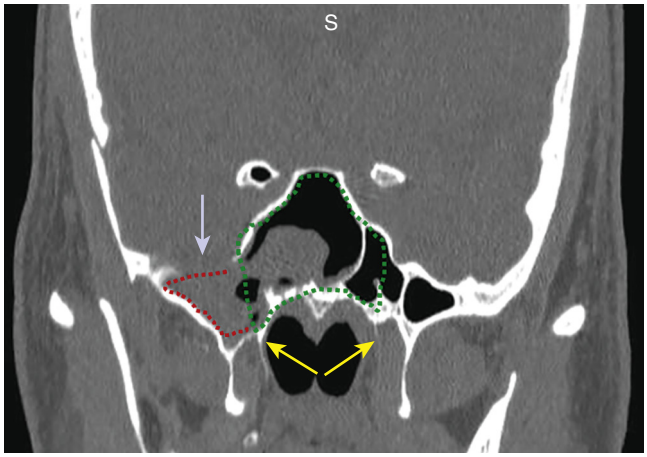

Fig. 116.4. Coronal computed tomography scan of the sphenoid sinus depicts the limits of visualization of a traditional sphenoidotomy *(green dots)*. The medial pterygoid plates *(yellow arrows)* are useful anatomic landmarks and a defect in the skull base *(grey arrow)*. The lateral recess of the sphenoid sinus can be visualized with a trans-pterygoid approach *(red dots)*, and dissection is facilitated with a bilateral approach with removal of the sphenoid rostrum and posterior septum.

- The Draf III approach, which involves medial widening of the frontal recesses and removal of the superior nasal septum and inferior intersinus septum, may provide exposure of leaks around the frontal recess, thus allowing an endoscopic repair.

Common Errors in Technique

- Failure to adequately identify the site of the leak on preoperative imaging
- Failure to recognize a vascular injury, especially in the iatrogenic setting
- Failure to completely remove all sphenoid mucosa before obliterating with adipose tissue
- Failure to adequately expose the site of the leak, particularly in the lateral recess of the sphenoid sinus
- Failure to use meticulous technique when placing the graft may lead to an unsuccessful repair.
- When harvesting the nasoseptal flap, injury to the posterior nasal artery can compromise the vascularity of the flap. Failure to use the full length of the nasal septum may lead to a flap of inadequate length.

POSTOPERATIVE PERIOD

Postoperative Management

General Principles

- The general principles of managing a CSF fistula include adjunctive measures that may facilitate healing of the repair, including:
  - Avoidance of activities that raise the intracranial pressure, such as straining, bending forward, coughing, or lifting weights greater than 15 lbs
  - Bed rest
  - Stool softeners
  - 30 to 45-degree elevation of the head of bed
  - Sneezing with an open mouth
  - Absolute avoidance of nose blowing
  - "Deep extubation," to prevent straining and coughing, is encouraged, and positive pressure mask ventilation is contraindicated.
- The use of prophylactic antibiotics for the prevention of meningitis in patients with CSF fistulas continues to be controversial; however, the use of antibiotics when the patient has an active sinus infection is warranted.
- Nasal irrigations with nasal saline solution and gentle débridement of crusting are started postoperatively.
- In patients with indwelling lumbar spinal catheters, prophylactic antibiotics are routinely administered and, although the concept is not universally accepted, antibiotics are thought to decrease the incidence of catheter-related infections.
- However, the routine use of antibiotics for traumatic CSF leaks is not of proven efficacy, and they may select resistant bacteria.
  - We favor the use of perioperative prophylactic antibiotics during the repair of the CSF leak.
  - Antibiotics, usually aimed at gram-positive bacteria, are continued until nasal packing is removed.
- A postoperative CT scan without contrast within the first 24 hours after surgery is important to rule out evidence of intracranial bleeding, parenchymal injury, or tension pneumocephalus.
  - We favor a routine CT scan of the brain, even in the absence of any neurologic deficit.
- In our practice, we usually work in conjunction with a neurosurgical team during the repairs, although we do not consider it necessary in all cases.

- Neurosurgical consultation provides an important perspective on intraoperative and postoperative management, especially on the need for a CSF drain or a shunt.
- A lumbar drain is helpful to control intracranial pressure with a designated amount of CSF removed daily based on CSF production but is only used for those patients suspected to have HPH.
  - Overdrainage should be avoided because this creates a negative intracranial pressure that may result in pneumocephalus and promote bacterial contamination of the CSF with resultant meningitis.

High-Pressure Hydrocephalus

- Normal intracranial pressure ranges from 5 to 15 cm of water when the patient is in supine position.
  - Intracranial pressure increases with positional changes, with Valsalva maneuver, and during rapid eye movement (REM) sleep.
- An increased intracranial pressure (i.e., HPH) is defined as sustained or intermittent pressures of 20 to 30 cm of water.
- Posttraumatic, postsurgical, and postinfectious hydrocephalus can result from the obstruction of the arachnoid villi, thus preventing adequate CSF reabsorption with subsequent increased intraventricular pressures.
- In post-CVA and posttraumatic and postsurgical hydrocephalus, the obstruction arises from subarachnoid hemorrhage, whereas in the case of infection, inflammatory changes are responsible for obstructing the arachnoid villi (Fig. 116.5).
- Radiation therapy causes vascular changes in the brain and elevation of CSF protein, scarring, and adhesions, all of which may contribute to the impairment of the CSF reabsorption.
- Likewise, meningitis causes scarring of the CSF cisterns and absorptive sites, thus leading to chronic hydrocephalus.
- Patients with recurrent CSF leaks, a past history of head and/or cranial base trauma, a history of cranial base surgery, and those with "spontaneous" CSF leaks are considered at high risk for HPH and are enrolled in the following protocol (Fig. 116.6):
  - The CSF leak is repaired via an endonasal endoscopic approach following surgical principles such as adequate exposure, hemostasis, preparation of the fistula for grafting, and stabilization of the graft.
  - A lumbar spinal drain is inserted intraoperatively or immediately after the surgery.
  - Three to 5 days postoperatively, the lumbar spinal drain is clamped, and if no CSF leak is identified for 24 hours, the lumbar drain is removed.
  - Twenty-four to 48 hours later, a lumbar puncture is performed to measure the CSF opening pressure.
  - A Ventriculoperitoneal (VP) shunt is recommended if the CSF opening pressure is elevated.
  - If the CSF opening pressure is normal, the patient is discharged home and followed in our outpatient office.
- Patients with CSF leaks in the sphenoid sinus are treated with obliteration of the sinus using an abdominal adipose tissue graft, which is then stabilized with nasal packing.
  - A postoperative lumbar spinal drain is not required.
  - A lumbar puncture is performed 3 to 5 days postoperatively to measure the opening pressure and establish the need for a VP shunt.
- In those patients with normal CSF opening pressure, a CT scan of the brain is performed 6 weeks after the surgical closure.
  - Ventriculomegaly of the temporal horns or transependymal edema will identify those patients with HPH who may have escaped identification (false negative).
- CSF leaks in patients who did not present with any of the previously mentioned high-risk factors are repaired endoscopically and without the use of a spinal drain.

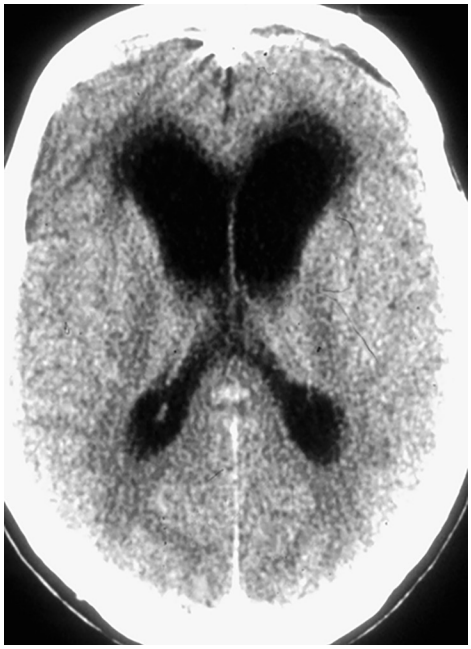

Fig. 116.5. Axial computed tomography scan of the head in a patient with high-pressure hydrocephalus and ventriculomegaly of the temporal horns.

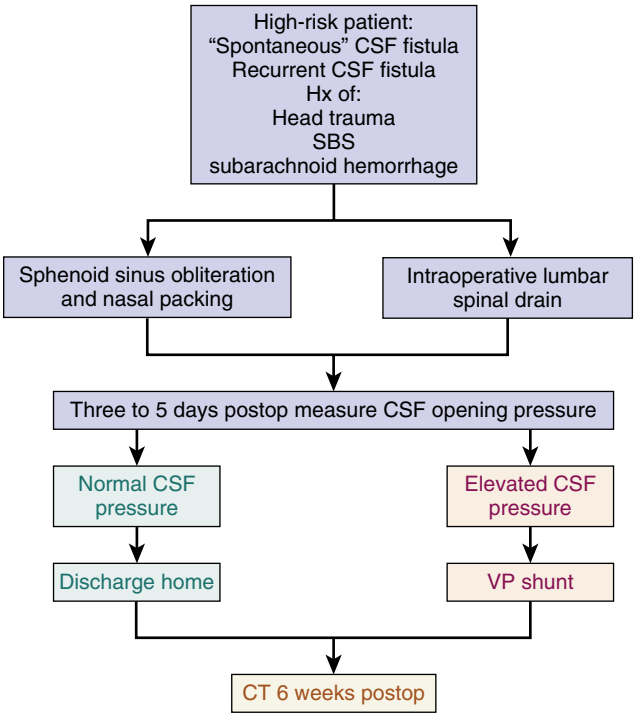

Fig. 116.6. Management algorithm for patients at high risk for failure of cerebrospinal fluid (CSF) fistula repair. *CT*, Computed tomography; *postop*, postoperatively; *SBS*, skull base surgery; *VP*, ventriculoperitoneal.

Complications

- Postoperative epistaxis may require packing if ongoing and uncontrolled with topical decongestants.
  - This is typically from an artery (i.e., the sphenopalatine artery) that has been transected at the time of surgery and was in vasospasm, allowing it to escape detection at the time of surgery.
- Retrobulbar hematoma: Immediately remove the packing, and, if in the recovery room, perform a lateral canthotomy and cantholysis.
  - Return to the operating room for medial orbital wall decompression.
  - This complication typically results when the anterior ethmoidal artery is transected and retracts into the orbit, allowing blood to accumulate in the closed space and increasing intraocular pressure rapidly.
- Meningitis: Treat with antibiotics.
- CSF rhinorrhea: Collect a sample of fluid to send for β_2-transferrin to confirm the diagnosis.
  - Conservative management (bed rest, stool softeners) should be instituted.
  - Consider lumbar drain.
  - Return to the operating room if failure of medical management.

Alternative Management Plan

- A conservative approach with medical management can be considered for any patient with a CSF leak, although this should not be used as first-line treatment in cases of spontaneous CSF leak due to the risk of meningitis and high failure rate; delaying surgical repair may inadvertently increase the risk of developing meningitis.
- Conservative management includes:
  - Bed rest
  - Stool softeners
  - Lumbar drain
  - The use of acetazolamide
    - Acetazolamide can cause electrolyte disturbances, and it is generally recommended that the electrolytes are monitored while on this medication.
    - Acetazolamide therapy should be avoided in cases of adrenal insufficiency and cases of hepatorenal failure.

DISCUSSION

Evidence-Based Medicine Question

What is the evidence of prophylactic antibiotics in CSF leak repair?

- Intuitively, a patent connection between a clean-contaminated area (the nasal cavity) and a sterile region (the subarachnoid space) predisposes the patient to meningitis, and therefore antibiotic prophylaxis should be used.
- However, the evidence supporting the routine use of antibiotics is limited.
  - A recently updated Cochrane review did not find evidence to support the use of antibiotic prophylaxis in patients who had basilar skull fractures (with or without CSF leak).[9]
  - A recent review by Oakley[10] found that the evidence does not support the routine use of prophylactic antibiotics; however, they were unable to comment on intraoperative or postoperative antibiotic use.
- Based on these reviews, our practice is to not prescribe prophylactic antibiotics for CSF leaks, but we routinely use perioperative antibiotic prophylaxis.

Editorial Comment

One of the biggest errors in the initial management of patients with spontaneous CSF leaks is to treat with CSF diversion (spinal drain). Spontaneous leaks will not close without surgical management. Surgical delay predisposes the patient to meningitis.

Small CSF leaks can be effectively repaired using a variety of techniques. For larger defects, superior results are achieved using vascularized tissue for reconstruction. Although some surgeons choose to add cartilage or bone for rigid reconstruction, it is not necessary.

Carl H. Snyderman

Access the review questions and additional source list online at http://www.expertconsult.com

REFERENCES

1. Dagi FT, George ED. Management of cerebrospinal fluid leaks. In: Schmidek HH, Sweet WH, editors. Operative Neurosurgical Techniques: Indications, Methods and Results. Orlando: Grune & Stratton; 1988. p. 49–69.
2. Ramakrishnan VR, Kingdom TT, Nayak JV, et al. Nationwide incidence of major complications in endoscopic sinus surgery. Int Forum Allergy Rhinol 2012;2:34–39.
3. Vleming M, Middelweerd RJ, de Vries N. Complications of endoscopic sinus surgery. Arch Otolaryngol Head Neck Surg 1992;118:617–623.
4. Calcaterra TC. Diagnosis and management of ethmoid cerebrospinal rhinorrhea. Otolaryngol Clin North Am 1985;18:99–105.
5. Papay FA, Maggiano H, Dominquez S, et al. Rigid endoscopic repair of paranasal sinus cerebrospinal fluid fistulas. Laryngoscope 1989;99:1195–1201.
6. Hadad G, Bassagasteguy L, Carrau RL, et al. A novel reconstructive technique after endoscopic expanded endonasal approaches: vascular pedicle nasoseptal flap. Laryngoscope 2006;116:1882–1886.
7. Psaltis AJ, Schlosser RJ, Banks CA, et al. A systematic review of the endoscopic repair of cerebrospinal fluid leaks. Otolaryngol Head Neck Surg 2012;147:196–203.
8. Hegazy HM, Carrau RL, Snyderman CH, et al. Transnasal-endoscopic repair of cerebrospinal fluid rhinorrhea: a meta-analysis. Laryngoscope 2000;110:1166–1172.
9. Ratilal BO, Costa J, Pappamikail L, et al. Antibiotic prophylaxis for preventing meningitis in patients with basilar skull fractures. Cochrane Database Syst Rev 2015;4:CD004884.
10. Oakley GM, Orlandi RR, Woodworth BA, et al. Management of cerebrospinal fluid rhinorrhea: an evidence-based review with recommendations. Int Forum Allergy Rhinol 2016;6(1):17–24.

REVIEW QUESTIONS

1. Where is β_2-transferrin found in the body?
   a. CSF
   b. Aqueous humor
   c. Perilymph
   d. All of the above

2. Which of the following adjuncts is helpful for improving visualization during a CSF leak repair?
   a. Trendelenburg position
   b. Controlled hypertension
   c. The use of topical vasoconstrictors
   d. None of the above

3. Which of the following statements is false?
   a. There is limited evidence to support the use of preoperative antibiotic use.
   b. "Deep extubation," to prevent straining and coughing, is encouraged, and positive pressure mask ventilation is contraindicated.
   c. A mucosal inlay graft is a good first-line repair and should be covered with a vascularized flap if possible.
   d. Retrobulbar hematoma is a serious emergency, and, if it occurs in the recovery room, the nasal packing should be removed as soon as possible.

ADDITIONAL SOURCE

Oakley GM, Alt JA, Schlosser RJ, et al. Diagnosis of cerebrospinal fluid rhinorrhea: an evidence-based review with recommendations. Int Forum Allergy Rhinol 2016;6(1):8–16.
This systematic review summarizes the diagnostic tests and workup for suspected CSF rhinorrhea. Beta-2 transferrin was found to be the most reliable confirmatory test and HRCT was noted to be the best initial imaging study.

117 Endonasal Approach to the Sella and Parasellar Areas

Eric W. Wang, J. Kenneth Byrd

INTRODUCTION

Surgery of the central cranial base has evolved over the past several decades from open transcranial or transfacial approaches that require significant retraction or disruption of normal anatomy, to endoscopically assisted approaches that maintain surgical principles, improve visualization, and preserve normal function. Surgical approaches to the sella and parasellar areas exemplify this principle and are the keystone to other endoscopic approaches to the anterior skull base. The sella was traditionally approached via a microscopic sublabial or transnasal, transseptal approach. The problem with this approach included limited visualization and freedom of movement of instruments, incomplete tumor resection and limited ability to deal with severe complications, such as carotid artery injury. The advent of endoscopic approaches to the paranasal sinuses in the 1980s, followed by widespread adoption in otolaryngology, gradually led to the expansion of endonasal techniques beyond inflammatory sinus disease. After neurosurgeons experimented with endoscopic assistance for microscopic pituitary surgery for several years, a solely endoscopic approach to the sella was described in the mid-1990s.[1]

Subsequent improvements in technology have included improved optics, high-definition displays, navigation systems, and better instrumentation for endoscopic cranial base surgery. The next step using techniques devised for endoscopic pituitary surgery was the resection of suprasellar pathologies, cavernous sinus dissection, and more advanced procedures in the sagittal and coronal planes. The team approach, involving neurosurgeons and otolaryngologists, has led to excellent patient outcomes with a midline transnasal approach.[2] For the purposes of this chapter, discussion will be limited to the sellar and parasellar regions.

KEY OPERATIVE LEARNING POINTS

1. The sella lies in the midline of the posterior wall of the sphenoid sinuses, bounded laterally by the cavernous internal carotid artery (ICA) siphon and superiorly by the superior intercavernous sinus and optic nerves. Recognition of the medial and lateral opticocarotid recesses is important to prevent injury to these structures.
2. The need for a vascularized nasoseptal flap reconstruction should be considered prior to sphenoidotomy in order to preserve the vascular pedicle.
3. Exposure of the cavernous sinuses lateral to the sella is a safe way to identify the course of the parasellar ICA.

PREOPERATIVE PERIOD

History

1. History of present illness
   a. A thorough history should be taken to elicit visual changes, including decreased visual fields or diplopia, endocrine symptoms, headaches, clear rhinorrhea, and frequent urination.
   b. Specifically, symptoms of Cushing's syndrome and acromegaly should be elicited.
   c. A rapid onset of headache and visual symptoms may represent pituitary apoplexy, which is a surgical emergency.
2. Past medical history
   a. Prior treatment:
      1) Medical treatment for pituitary tumor (dopamine antagonists)
      2) Prior radiation therapy (stereotactic or intensity-modulated)
   b. Medical illnesses:
      1) Heart disease
      2) Intracranial hypertension (may be undiagnosed in obese patients)
      3) Diabetes mellitus
      4) Diabetes insipidus
      5) Recurrent acute or chronic rhinosinusitis, particularly nasal polyposis with pulmonary symptoms
         a. Cystic fibrosis
         b. Allergic fungal rhinosinusitis
         c. Samter's triad
   c. Surgery:
      1) Prior endoscopic, transseptal, sublabial, or transcranial approach to the sella
      2) Nasal surgery including septoplasty or functional endoscopic sinus surgery
   d. Family history:
      1) Bleeding disorders
      2) Pituitary tumors (multiple endocrine neoplasia Type 1)
   e. Medications:
      1) Anticoagulants or antiplatelet drugs
      2) Dopamine antagonists
      3) Insulin or oral hypoglycemic agents
      4) Steroids
      5) Nasal steroids
      6) Topical nasal decongestants (intraoperative topical decongestant is less effective)
   f. Social history: alcohol, tobacco, or illegal drugs
      1) A history of or active cocaine abuse may result in perforation, submucosal cartilage loss, and/or submucosal scarring of the septum; topical decongestants are less effective.

Physical Examination

1. General
   a. Features of Cushing's syndrome: abnormal distribution of adipose tissue, "buffalo hump" or "moon facies"
   b. Features of acromegaly: frontal bossing, macroglossia, prognathism, enlarged hands and feet
2. Eyes

Assessment of visual fields, visual acuity, and proptosis or abnormal position of the globe. Full examination by an ophthalmologist is warranted if there is any involvement of the optic nerve, chiasm, or orbit on imaging.

3. Neurologic
   A thorough cranial nerve examination should be performed with particular attention to nerves III, IV, V, and VI.
4. Skin
   Note the presence of striae, abnormal pigmentation, or ecchymoses suggesting Cushing's syndrome.
5. Nasal endoscopy
   Assess for intranasal pathology, including septal deviations or perforations, polyps, purulence, or intranasal masses. If prior surgery has been performed, assess for adequacy of nasoseptal flap pedicles.

Imaging

1. Maxillofacial computed tomography (CT) with contrast
   a. Allows for delineation of bony anatomy of paranasal sinuses, orbits, and skull base
   b. Coronal and sagittal reconstructions are helpful to evaluate the slope of the skull base, the position of the anterior ethmoid arteries, and the presence of posterior ethmoid cells associated with the optic nerve (Onodi cells).
   c. Contrast angiography allows for delineation of the interface with intracranial vessels and improved visualization of the ICA.
2. Magnetic resonance imaging of skull base with gadolinium
   a. Extent of tumor
   b. Location of residual pituitary gland and stalk
   c. Cavernous sinus invasion
   d. ICA anatomy
   e. Relation to optic chiasm

Indications

- Infectious/inflammatory sphenoid sinus disease
- Sinonasal tumors involving the sphenoid sinus
- Fibro-osseous lesions
- Pituitary adenoma
  - Functional tumors uncontrolled with medical therapy
  - Macroadenomas with visual compromise
  - Interval growth of macroadenoma
- Craniopharyngioma
- Rathke's cleft cyst or pituitary cysts with headaches or visual compromise
- Meningoceles/meingoencephaloceles
- Planum sphenoidale or tuberculum meningioma
- Select lesions extending into the medial or anterior compartments of the cavernous sinus
- Medial optic nerve and orbital apex decompression

Absolute Contraindications

- Cardiopulmonary disease that prohibits surgery
- Pathology that is on the deep side of a nerve or vessel

Relative Contraindications

- Significant lateral extent
- Bleeding disorder
- Prolactinoma that has not been trialed on medical therapy
- Vascular encasement

Preoperative Preparation

- Evaluation by otolaryngology and neurosurgical teams
- Endocrine consultation for pituitary tumors
- Ophthalmologic consultation for visual disturbances
- Discontinue aspirin and anticoagulants prior to surgery.
- It is important to manage acute bacterial rhinosinusitis before endoscopic endonasal skull base surgery.

OPERATIVE PERIOD

Anesthesia

- General endotracheal anesthesia should be induced. If nerve monitoring is to be performed, only short-acting paralytics should be used during induction.
- For medically fragile patients, and for cases in which significant vascularity is involved, an arterial line should be placed, and adequate venous access should be obtained.
- If a dural defect is present or will be created, the anesthesia team should be notified that mask ventilation is contraindicated.
- An orogastric tube placed at induction allows the stomach to be suctioned at the end of the case to prevent vomiting.
- In cases with visual compromise, mean arterial pressures should be maintained at greater than 80 mmHg. Adjunctive corticosteroids should also be considered (Solu-Medrol 100 mg or Decadron 10 mg intravenous [IV]).
- Stress dose steroids also should be administered to patients with hypopituitarism.

Positioning

- Supine
- Mayfield head pins or a horseshoe may be used based on the surgeon's preference.
- The head of the bed should be rotated to allow both surgeons access to the face and nose.
- Reverse Trendelenburg position can be used to reduce venous bleeding.

Perioperative Antibiotic Prophylaxis

- Ceftriaxone 2 g IV
- Clindamycin 600 mg IV or vancomycin 1 gm IV if the patient has a cephalosporin allergy

Monitoring

- Somatosensory evoked potentials are monitored for all cases to identify impending ischemic events and prevent permanent neurologic sequelae.
- If cavernous sinus dissection is performed, electromyography of the relevant cranial nerves is performed by the neurophysiology team.

Instruments and Equipment to Have Available

- Oxymetazoline (0.05%) or epinephrine (1:1000) on cotton pledgets for decongestion
  - Not used when the dura is violated to avoid the introduction of alpha agonists into the cerebrospinal fluid (CSF)
- Endoscopes: 0 and 45 degrees
- Endoscopic sinus instruments
- Endoscopic neurosurgical dissectors
- Endoscopic drill: 4- or 5-mm coarse diamond bur
- Transnasal Doppler probe
- Endoscopic bipolar electrocautery
- Two suction setup
- Image guidance navigation system
- Needle-tip cautery can be used for nasoseptal flap elevation.
- Suction monopolar electrocautery

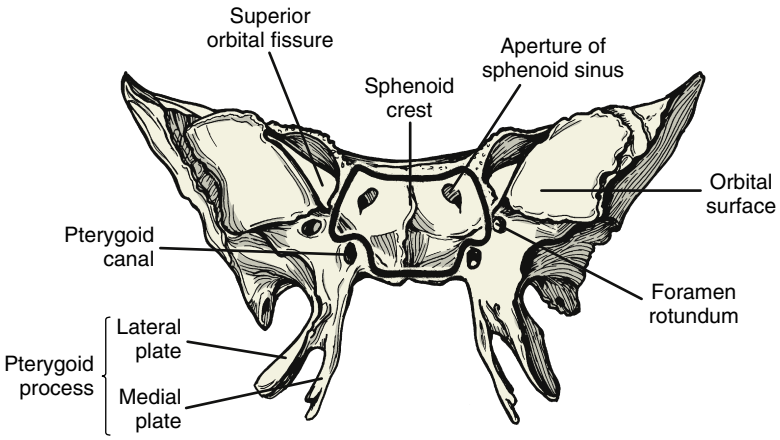

Fig. 117.1. Anterior view of the sphenoid bone with bony landmarks identified. The extent of the sphenoidotomy is outlined; it extends between the foramen rotundum and the pterygoid canal and includes the lateral recess.

Key Anatomic Landmarks

- Fig. 117.1 demonstrates the anatomy of the sphenoid bone.
- The natural ostium of the sphenoid sinus is located approximately one-third of the way between the arch of the choana and the skull base, behind the superior turbinate.
- The midline face, or rostrum, of the sphenoid forms the "keel" at its attachment to the vomer.
- The roof of the sphenoid sinus is the planum sphenoidale and is continuous with the ethmoid roof and cribriform plate anteriorly.
- Initial visualization of the structures within the sphenoid sinus depends on the pattern of sellar pneumatization: conchal, presellar, or sellar.
- The optic nerves lie lateral and superior and track posteriorly over the sella turcica in the midline. The optic canal may lie within an Onodi cell, which is most easily recognized on sagittal imaging. Bony dehiscence around the optic nerve is common in an Onodi cell.
- The clival recess is inferior to the sella.
- Superiorly, the face of the sella meets the planum at the tuberculum sellae, which overlies the superior intercavernous sinus.
- After exiting the petrous segment, the ICA courses superomedially from the lacerum segment into the paraclival segment before entering the cavernous sinus immediately lateral to the sella. The ICA then enters the paraclinoidal segment, which is the most medial and prominent segment of the artery (anterior protuberance). This segment is just medial to the lateral opticocarotid recess.
- The intersinus septum often deviates laterally to insert on the anterior protuberance of the carotid.
- The lateral opticocarotid recess lies between this portion of the cavernous carotid and the optic nerve superolaterally. This represents the pneumatization of the optic strut between the ICA and floor of the optic canal. The medial opticocarotid recess is less well defined in most patients. Fig. 117.2 demonstrates the anatomy of this region.
- Inferolaterally, the vidian nerve traverses the floor of the sphenoid sinus toward the foramen lacerum and crosses over the petrous segment of the carotid artery. With a very well-pneumatized lateral recess, one can appreciate the protuberance of V2 superolateral to the pterygoid canal.

Prerequisite Skills

- Endoscopic sinus surgery: sphenoidotomy, ethmoidectomy
- Reconstruction: free mucosal graft, nasoseptal flap
- The otolaryngologist and neurosurgeon should both be skilled in endoscopic anatomy and dissection and should have experience working together as a four-handed team.

Operative Risks

- CSF leak
- Carotid artery injury
- Cavernous sinus hemorrhage
- Optic nerve injury
- Cranial nerve injury
- Endocrinopathies including diabetes insipidus
- Epistaxis
- Postoperative hematoma, especially with incomplete tumor resection

Surgical Technique

Approach

- The nasal cavity is decongested with topical oxymetazoline or epinephrine on pledgets.
- The 0-degree endoscope is used to visualize intranasal structures.
- The right middle turbinate can be medialized or transected at the junction of its upper and middle two-thirds (below the skull base).
  - Resection allows for additional working space for the endoscope and the neurosurgeon's left-handed instrumentation.
  - The branch of the sphenopalatine artery (SPA) to the middle turbinate is cauterized carefully without damaging the main artery.
  - The mucosa of the middle turbinate can be harvested for a free mucosal graft, if needed.
- A nasoseptal flap is elevated if the need is anticipated.
  - Dural violation or carotid exposure
  - For sellar and parasellar approaches, a left or right nasoseptal flap may be used based on the surgeon's preference and pre-existing septal deviations.
- Superior turbinates are either lateralized or partially resected. Bilateral sphenoidotomies are performed exposing the planum and orbit bilaterally.
  - The intersinus septum is removed conservatively with cutting hand instruments until the two-team approach is used to drill the septum until it is flush with the sphenoid bone.
- A posterior septectomy exposes the anterior sphenoid rostrum, which may be removed with rongeurs or the drill allowing for binarial access.
  - A Cottle elevator is used to separate the junction of the vomer with the anterior sphenoid rostrum.
  - Additional anterior exposure is obtained by resecting the posterior margin of the septum with a backbiting forceps. Care should be taken to avoid resecting olfactory mucosa from the nasal septum, which extends approximately 1 cm inferiorly from the skull base.

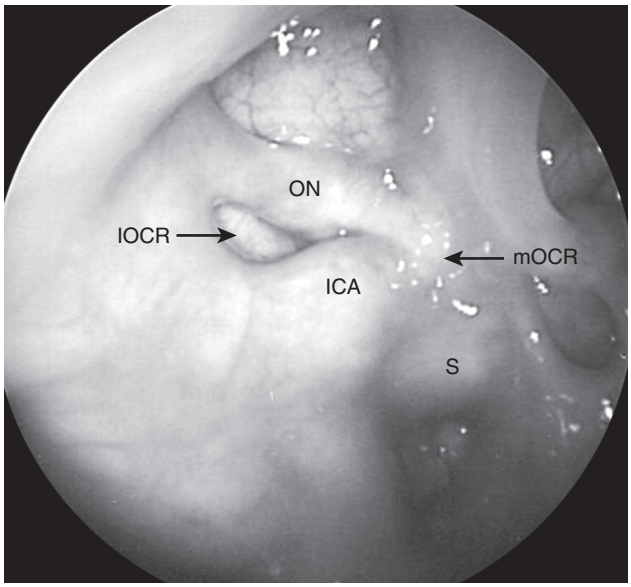

Fig. 117.2. Cadaveric dissection with a view of the right optic nerve (ON) and internal carotid artery (ICA). The pneumatization of the anterior clinoid forms the lateral optic-carotid recess (lOCR). The medial junction of the ON and ICA is the medial optic-carotid recess (mOCR). *S*, sella.

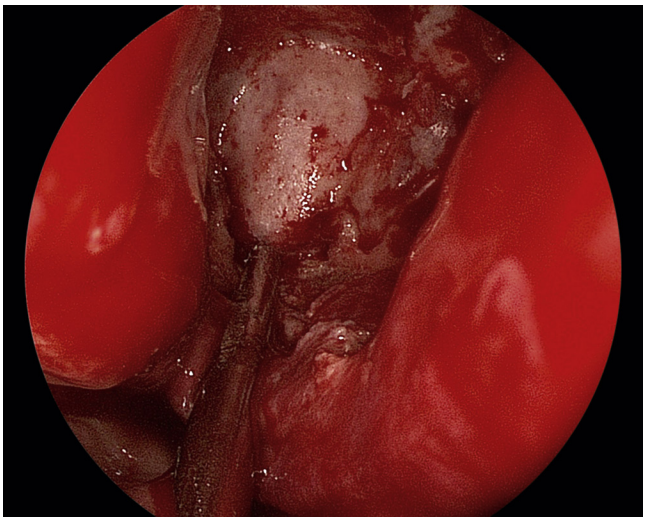

Fig. 117.4. Both sphenoid sinuses have been opened widely and the intersinus septum removed. The right middle turbinate has been preserved and is seen on the left. A rescue flap (inferior to the suction) has been maintained by preserving the nasoseptal artery in case a nasoseptal flap is needed.

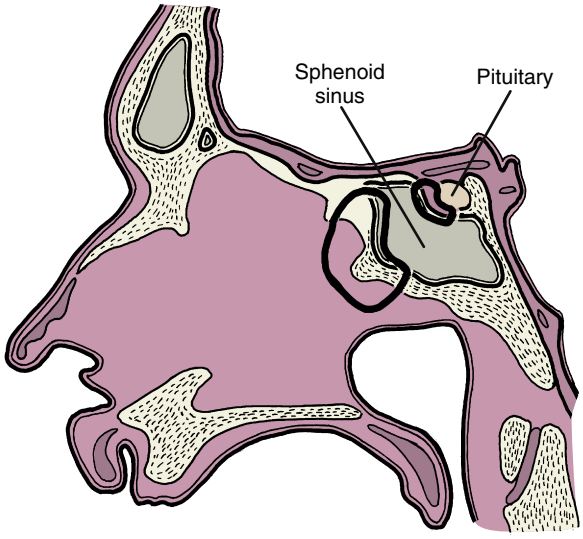

Fig. 117.3. Bone is removed from the sphenoid face, posterior nasal septum, and sella for standard sellar surgery.

  - The size of the septectomy depends on the lateral and anterior extent of dissection.
- Fig. 117.3 demonstrates the sphenoid and sellar exposure required for tumors confined to the sella.
- Additional inferior exposure may be obtained by drilling the rostrum and floor of the sphenoid.
  - The sacrifice of one posterior septal artery may be helpful for inferior exposure, but it is not always required.
  - Alternatively, a releasing incision or window in the posterior septum can be created. Subsequently the mucosa of the face of the sphenoid below the sphenoid ostium can be mobilized and displaced inferiorly to preserve the posterior septal branch of the SPA, the arterial supply to the nasoseptal flap.
  - Fig. 117.4 demonstrates the bilateral wide sphenoidotomy with exposed sella and a preserved nasoseptal artery pedicle, or "rescue flap," on the right side.
- The posterior ethmoid air cells can be removed to expose the skull base anterior to the planum sphenoidale.
  - A posterior ethmoidectomy on the right allows for scope positioning superior to the working corridor of the neurosurgeon.
  - The extent of posterior ethmoidectomy depends on the anterior limit of dissection. For sellar cases, a conservative posterior ethmoidectomy should allow for a three-handed technique with clear visualization.
  - A more complete posterior ethmoidectomy should be performed when access beyond the planum is required.

Exposure of the Sella

- Image guidance is used to confirm the location of the sella, ICAs, and optic nerves.
- The intersinus septations are drilled until they are flush with the bone.
  - Team surgery with a three-handed technique is advisable from this point forward.
- Mucosa is removed over the sella with a Cottle elevator and suction.
  - Additional mucosal stripping may be necessary for visualization of bony structures or if extrasellar access requires drilling of the planum, lateral sphenoid, or clivus.
  - Fig. 117.5 demonstrates a wide-angle view of the sella after bony septations have been drilled.
- The bone over the sella is carefully thinned and removed with an elevator or Kerrison rongeur.
  - Rather than biting with the Kerrison rongeur, it should be used to elevate the thinned bone to avoid injury to the carotid artery.
- Drilling is carried out laterally to expose the margin of the cavernous sinus dura on each side. Fig. 117.6 demonstrates the exposed sellar dura, as well as the blue hue of each cavernous sinus.

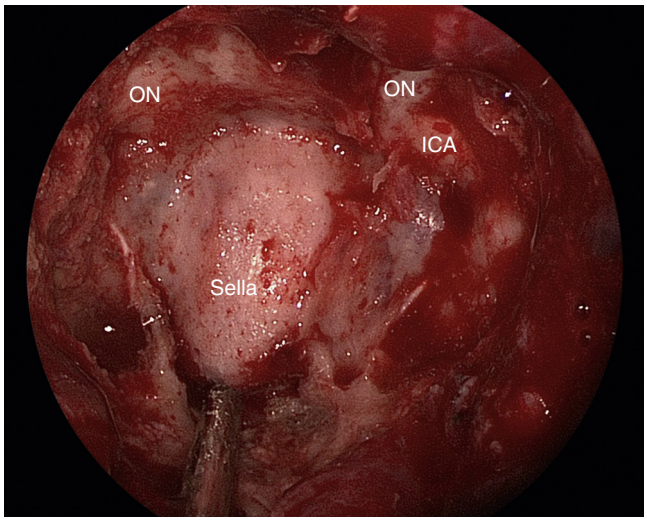

Fig. 117.5. A wide-angle view of the sella after partitions have been drilled posteriorly. The suction is in the remaining clival recess. The left internal carotid artery siphon is visualized (ICA), as are both optic nerves (ON).

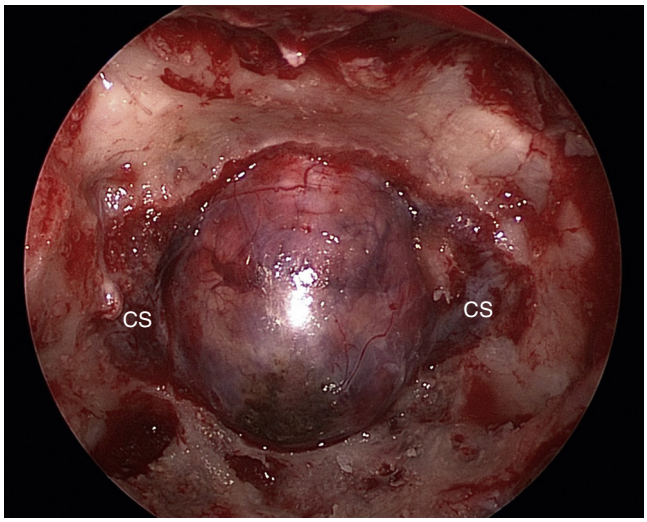

Fig. 117.6. The bone over the sella has been drilled to expose the sellar dura. The cavernous sinuses (CS) are visible on each side.

Suprasellar Exposure

- If suprasellar access is needed, bone should be carefully drilled in the midline superiorly with visual or image guidance confirmation of the ICA position.
  - The ICA is prone to injury at the medial opticocarotid recess.
  - The planum is drilled until it is the thickness of an eggshell and is removed in an anterior to posterior fashion.
  - The bone of the tuberculum must be very thin before it is carefully removed to avoid CSF leak or bleeding from the superior intercavernous sinus.
- Fig. 117.7 demonstrates the additional bony exposure required for tumors with suprasellar extension.

Lateral Recess Access

- Transpterygoid dissection is usually required to access the lateral recess of a well-pneumatized sphenoid sinus.

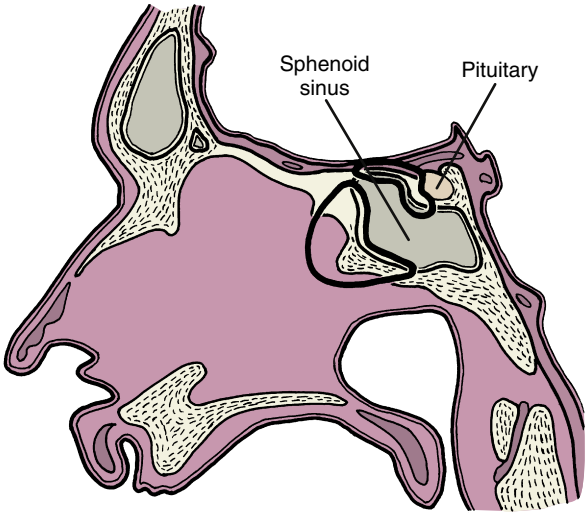

Fig. 117.7. The planum sphenoidale and sella may be removed in continuity to provide access to tumors with suprasellar extension.

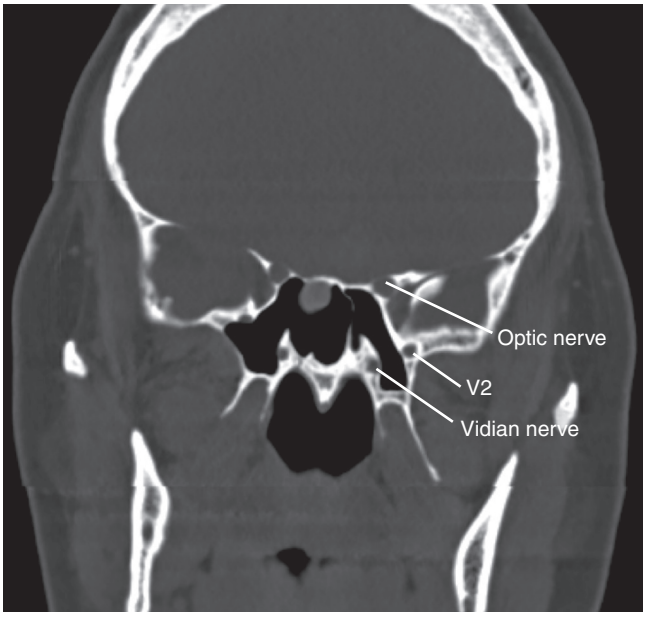

Fig. 117.8. Coronal non-contrasted computed tomography of the sphenoid sinus demonstrating the lateral recess, the opening to which is bounded by the vidian nerve and V_2.

  - Fig. 117.8 demonstrates the lateral recess, bounded by the vidian nerve and V_2 branch of the trigeminal nerve.
- If a nasoseptal flap is used in conjunction with a transpterygoid approach, the contralateral side is preferentially harvested due to the sacrifice of the SPA.
- The crista ethmoidalis is palpated with the Cottle elevator, and a mucosal flap is elevated superiorly and posteriorly to expose the SPA at the sphenopalatine foramen, which is cauterized and divided.
- A 1-mm Kerrison rongeur is used to remove the bone of the posterior wall of the maxillary sinus, starting from the sphenopalatine foramen. After it is enlarged, a larger rongeur may be used.
- The pterygopalatine fossa (PPF) contents are exposed after the posterior maxillary wall is removed. Lateral displacement of the contents reveals the Vidian artery and nerve entering the PPF from the pterygoid canal.

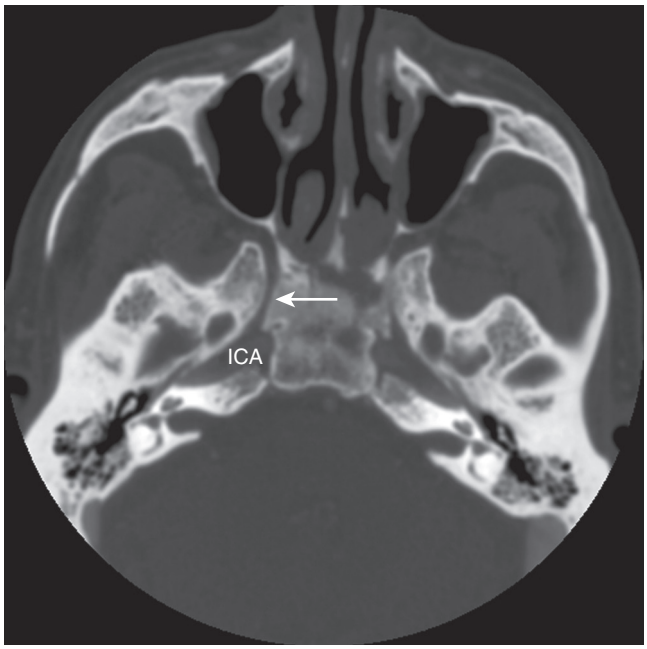

Fig. 117.9. The pterygoid canal *(arrow)* is a reliable landmark for locating the petrous internal carotid artery (ICA) at the second genu.

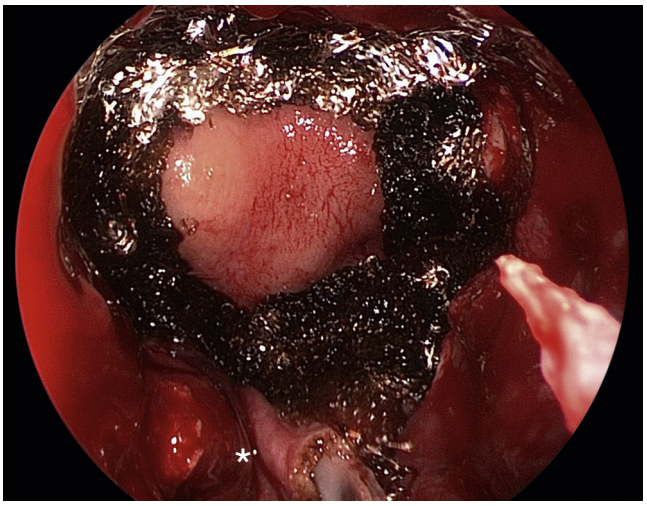

Fig. 117.10. A right nasoseptal flap held in position by Surgicel covers the sellar defect. The pedicle containing the nasoseptal artery *(*)* is visible.

- Dividing the Vidian nerve allows further lateral retraction of PPF contents to reveal V2 superolaterally on its course through the foramen rotundum.
- The floor of the sphenoid and the base of the pterygoid may be drilled as needed for exposure to the lateral recess.
  - Following the Vidian nerve posteriorly leads to the foramen lacerum and the lacerum segment of the ICA (Fig. 117.9).
  - The Vidian nerve crosses superolaterally over the petrous segment of the ICA.
- If additional inferior exposure is required in the sphenoid, a medial maxillectomy may be performed. After a maxillary antrostomy is performed, the posterior ⅔ of the inferior turbinate is removed and the antrostomy is taken to the floor of the nose with hand instruments or the drill. Care is taken not to injure the greater palatine neurovascular bundle.

Reconstruction

- Pituitary surgery without significant vascular or arachnoid exposure may be reconstructed with a free mucosal graft from the harvested middle turbinate or the nasal floor.
  - Surgicel is placed around the edges of the graft to overlap with the remaining mucosa to hold it in place and is reinforced with Gelfoam.
  - Nasal packing with Merocel tampons or a balloon catheter inflated with saline is unnecessary after routine pituitary surgery.
  - If significant diaphragmatic herniation is noted and there is concern for benign intracranial hypertension, an adipose tissue graft may be placed in the defect for support. However, this makes revision surgery more difficult due to fibrosis.
- If the ICA is exposed, a significant dural defect is present, or significant cavernous sinus dissection is performed, the nasoseptal flap is used for coverage.
  - The flap should be rotated so that the entire length is in contact with the dura and bone.
  - Different arcs of rotation (oblique lateral orientation vs. a midline orientation) may be used depending on the bony anatomy and length needed.
  - The distal (anterior) flap is the thickest portion of the flap and is best used at the site of greatest risk.
  - If there is doubt about which side is the mucosal side, restore the flap to its native position and mark with a surgical marker prior to reconstruction. Torsion of the pedicle should be avoided.
  - The edges of the flap are held with Surgicel and Gelfoam, as described above.
  - Fig. 117.10 demonstrates a right-sided nasoseptal flap reconstruction of a sellar defect.
- Dural defects should be closed in a layered fashion, with a collagen graft underlay, followed by the mucosal graft or nasoseptal flap.
  - Consider a three-layered closure for high-flow or very large defects.
  - Fascia lata, acellular dermis, porcine intestine, and other grafts have been used successfully as an interposed middle layer.
- When there is reconstruction of a dural defect, or when a nasoseptal flap is used, packing is left in place for 5 to 7 days.
  - Merocel tampons or a Foley balloon catheter may be used when there is an intraoperative CSF leak, concern for the development of a postoperative leak, or for a perceived high-risk reconstruction (carotid exposure).
  - If the optic nerves are exposed, Merocels should be carefully placed and balloon packing avoided so that the optic nerves are not compressed. Vision checks should be performed regularly in the postoperative setting to ensure that optic nerve ischemia is not occurring.
- Doyle splints are sewn to the anterior septum and left for 3 weeks when a nasoseptal flap is used to promote healing.
  - A free mucosal graft (from a resected middle turbinate or nasal floor) to the anterior septum may speed septal mucosalization.

Common Errors in Technique

- A high trajectory to the sphenoid sinus may result in violation of the skull base and subsequent CSF leak.
- Opening the sphenoid sinus inferiorly may result in injury to the vascular pedicle of a nasoseptal flap.

- Inadequate superolateral exposure in the posterior ethmoids leads to poor visualization and fighting for space for the two-surgeon team.
- Failure to remove the sphenoid rostrum does not allow instrumentation in the clival recess or lower sella.
- Inadequate opening of the sella limits access to the medial cavernous sinus and margins of the tumor.

POSTOPERATIVE PERIOD

Postoperative Management

- Vision should be evaluated as soon as the patient is cooperative.
- Oral antibiotics should be continued as long as packing is in place.
- Pituitary function should be assessed with postoperative laboratory studies if the gland is manipulated.
- Nasal saline irrigations may be started as soon as a CSF leak is no longer a concern.
- Patients should return for scheduled in-office débridements after packs are removed.
  - These may need to be performed frequently in the first month and continued for up to 3 months when a nasoseptal flap is used.
  - Care should be taken not to disrupt the dural repair during débridement.
- If a CSF leak is suspected, fluid should be collected and tested for β_2 transferrin.
  - Postoperative CSF leaks should be repaired within 12 to 24 hours.

Complications

- Epistaxis: Mild epistaxis is usually secondary to mucosal trauma. Brisk, immediate postoperative bleeding can be secondary to arterial injury, usually from a branch of the SPA or the proximal stump of a resected middle turbinate. Significant delayed bleeding may be a sentinel bleed for a carotid pseudoaneurysm that would require emergent angiography.
- Nasal synechiae: Mucosal trauma is generally the cause of nasal synchiae and is diagnosed on postoperative nasal endoscopy. This can be minimized in the nasal cavity with the use of silastic splinting in the nasal cavity postoperatively. If the patient is symptomatic, lysis of synchiae can be performed in the office under local anesthesia.
- Septal perforation: This typically occurs in the setting of a nasoseptal flap harvest when a tear is created in the contralateral nasal mucosa.
- Iatrogenic chronic sinusitis: a rare complication that can generally be managed with medical interventions, such as topical nasal steroids. In some cases, a secondary functional endoscopic sinus surgery is warranted after a trial of maximal medical therapy as per the American Academy of Otolarynology—Head & Neck Surgery guidelines.
- CSF leak: Clear watery drainage that increases with straining or bending forward is the typical presentation of CSF rhinorrhea. Biochemical confirmation with β_2 transferrin can be obtained, but clinical history remains critical. We advocate emergent exploration with repair of the CSF fistula rather than observant therapy with lumbar drainage.
- Meningitis: Meningitis occurs almost exclusively in patients with postoperative CSF rhinorrhea. Closure of the leak and treatment with broad-spectrum IV antibiotics are warranted.
- Diabetes insipidus/panhypopituitarism: Overmanipulation or injury to the anterior and/or posterior part of the pituitary gland can result in transient or permanent endocrinopathies and diabetes insipidus, respectively. Careful tumor resection with preservation of the native structures is critical. In some tumor pathology, such as craniopharyngioma, sacrifice of the pituitary stalk is indicated and will result in these postoperative outcomes.
- Optic nerve/orbital injury: Optic nerve injury can occur secondary to direct injury, adjacent thermal injury, or vascular injury. Direct injury is generally avoided by identifying the intrasphenoidal landmarks. Thermal injury is mitigated by drilling on the optic canal with constant irrigation. Vascular injury generally occurs in the suprasellar space with injury to a branch of the superior hypophyseal artery or, rarely, the ophthalmic artery.
- Cranial nerve injury: Precise identification of the cranial nerve is critical. This can be supplemented with neurophysiologic monitoring of potentially involved cranial nerves.
- Injury of the ICA: Care must be taken with removing the bone of the carotid canal. Inadvertent injury can occur with dissecting instruments or high-powered drills. Identifying and coagulating the inferior hypophyseal artery, rather than avulsion of this vessel, can prevent a significant arterial bleed that can mimic an ICA injury.

Alternative Management Strategies

- Medical management
  - Growth hormone (GH) receptor antagonist or somatostatin analogue
  - Dopamine agonists
- Stereotactic radiation

DISCUSSION

Evidence-Based Medicine Question

How do outcomes of endoscopic endonasal pituitary resection compare with the microscopic approach?

No prospective, randomized trials have been performed to compare microsurgical approaches to the sellar and parasellar regions to the endoscopic endonasal approach (EEA). However, systematic review and meta-analyses of retrospective studies favor EEA over sublabial and microscopic approaches for completeness of tumor resection and septal perforation[3,4] and EEA over the sublabial approach for CSF leaks and epistaxis. Other complications, including meningitis, diabetes insipidus, and endocrine dysfunction were not significantly different between groups. Other retrospective studies comparing outcomes for adrenocorticotropic hormone (ACTH)-secreting tumors report equivalent biochemical cure rates between microscopic and endoscopic techniques.[5] GH-secreting tumors tend to be larger and have a higher degree of cavernous sinus invasion; therefore, one would postulate that endoscopy would provide better visualization and safer dissection. Direct comparison between microscopic technique and EEA is difficult because of a more stringent definition of biochemical cure, which was adopted in 2010. Evidence suggests that EEA is equal to or superior for GH-secreting tumors, although a significant number of patients will require medication and/or radiosurgery in addition to surgery.[6,7]

Sinonasal-specific quality of life appears to be equal or better in patients undergoing endoscopic sellar surgery compared to microscopic surgery according to a multicenter, prospective study.[8] However, expanded approaches necessitating Vidian nerve sacrifice, large septectomy, aggressive skull base drilling, or extended nasoseptal flaps lead toward prolonged recovery and decreased sinonasal quality scores, at least temporarily.

Editorial Comments

The endonasal approach to the sella has been greatly enhanced by endoscopic visualization and multidisciplinary team surgery. Wide exposure provides direct visualization and instrumentation of tumor margins without the need for blind dissection. Wide exposure with improved visualization of critical structures can also minimize the risk of injury. Experience gained by the surgical team performing pituitary surgery (functioning as a team, hemostasis, dural reconstruction) can then be applied to other skull base surgeries outside the sellar area.

Carl H. Snyderman

Access the review questions online at http://www.expertconsult.com

REFERENCES

1. Carrau RL, Jho HD, Ko Y. Transnasal-transsphenoidal endoscopic surgery of the pituitary gland. Laryngoscope 1996;106(7):914–918.
2. Snyderman C, Kassam A, Carrau R, et al. Acquisition of surgical skills for endonasal skull base surgery: a training program. Laryngoscope 2007;117(4):699–705.
3. DeKlotz TR, Chia SH, Lu W, et al. Meta-analysis of endoscopic versus sublabial pituitary surgery. Laryngoscope 2012;122(3):511–518.
4. Gao Y, Zhong C, Wang Y, et al. Endoscopic versus microscopic transsphenoidal pituitary adenoma surgery: a meta-analysis. World J Surg Oncol 2014;12:94.
5. Shin SS, Gardner PA, Ng J, et al. Endoscopic endonasal approach for ACTH-secreting pituitary adenomas: outcomes and analysis of remission rates and tumor biochemical activity with respect to tumor invasiveness. World Neurosurg 2017;102:651–658.
6. Shin SS, Tormenti MJ, Paluzzi A, et al. Endoscopic endonasal approach for growth hormone secreting pituitary adenomas: outcomes in 53 patients using 2010 consensus criteria for remission. Pituitary 2013;16(4):435–444.
7. Hazer DB, Isik S, Berker D, et al. Treatment of acromegaly by endoscopic transsphenoidal surgery: surgical experience in 214 cases and cure rates according to current consensus criteria. J Neurosurg 2013;119(6):1467–1477.
8. Little AS, Kelly DF, Milligan J, et al. Comparison of sinonasal quality of life and health status in patients undergoing microscopic and endoscopic transsphenoidal surgery for pituitary lesions: a prospective cohort study. J Neurosurg 2015;123(3):799–807.

REVIEW QUESTIONS

1. The following is a contraindication to an endoscopic approach to the sella:
   a. Secreting pituitary adenoma
   b. Cavernous sinus extension
   c. Suprasellar extension
   d. None of the above

2. What is the intracranial structure correlating to the lateral opticocarotid recess?
   a. Sella turcica
   b. Chiasmatic groove
   c. Optic strut
   d. Middle clinoid

3. The nasoseptal artery is a branch of which artery?
   a. Sphenopalatine
   b. Angular
   c. Internal carotid
   d. Posterior ethmoidal

118 Transcranial and Endonasal Approaches to the Anterior Cranial Base

Lee A. Zimmer

INTRODUCTION

Surgery of the anterior cranial base is often fraught with anxiety and concern because of the close proximity of major neurovascular structures. Often these tumors are extracranial; however, when tumors extend intracranially or invade into the brain parenchyma, a team effort of Neurosurgeons and Otolaryngologists is needed for surgical management. Most lesions of the anterior cranial base arise from the nasopharynx, nasal cavity, or paranasal sinuses, and a wide range of pathologic types are encountered (Box 118.1).[1]

Malignant tumors of the anterior cranial base are rare, accounting for only 3% of all tumors of the head and neck. A linkage between cigarette smoking and squamous cell carcinoma has been reported.[2] Well-known risks of developing sinonasal malignancy include exposure to wood dust (adenocarcinoma), nickel-refining processes, leather tanning, mineral oils, chromium and chromium compounds, isopropyl oils, lacquer paint, soldering and welding, and radium dial painting.

KEY LEARNING POINTS

1. Because of the location of tumors of the anterior cranial base, the initial clinical symptoms may be subtle and are often very similar to chronic inflammatory sinusitis.
2. Preoperative confirmation of histopathology is critical because of the wide variety of pathology of the anterior cranial base and the treatment options available.
3. Careful preoperative evaluation of imaging is important for planning the surgical approach (open, endoscopic, or combined).
4. Tumor invasion of the anterior table of the frontal sinus, orbital adipose tissue, floor of the nasal cavity, or carotid artery or gross parenchymal invasion precludes an endoscopic approach.
5. Care must be taken when elevating a bicoronal flap to preserve the blood supply from the supraorbital and supratrochlear vessels to the pericranial flap.
6. Elevation of the bicoronal flap must occur in a plane deep to the superficial layer of the deep temporal fascia in order to avoid injury to the temporal branches of the facial nerve.
7. Failure to preserve the superficial temporal vessels may forfeit the use of a temporoparietal flap for reconstruction.
8. A basal subfrontal approach is preferred to avoid excessive retraction of the frontal lobe.
9. If endoscopic resection of pathology of the anterior cranial base is being undertaken, oncologic principles should never be compromised, and the same resection must be achieved endoscopically as would be done through a traditional approach.
10. All frontal sinus mucosa should be drilled away to avoid late complications such as the formation of a mucocele.
11. Lack of a watertight barrier separating the intracranial contents from the paranasal sinuses may lead to cerebrospinal fluid (CSF) leakage or infection.
12. In the postoperative period, endoscopic manipulation can disrupt the reconstruction and cause an iatrogenic CSF leak.

PREOPERATIVE PERIOD

History

1. History of present illness
   a. Tumors often grow undetected and present late.
      1) Subtle signs and symptoms are present.
         a) Nasal obstruction, rhinorrhea, and epistaxis are often overlooked.
      2) Tumor progression
         b) Cranial nerve involvement leads to more alarming symptoms, such as anosmia, diplopia, vision loss, numbness of the face, dysarthria, and facial weakness. Invasion of the brain with frontal lobe involvement leads to subtle headaches and mood changes.

Physical Examination

1. Orbit
   Proptosis, chemosis, and impairment of extraocular muscles suggest a space-occupying lesion in or invading the orbit.
2. Face
   Widening of the nasal dorsum and swelling of the cheek indicate a lesion in the nasal cavity and maxillary sinus, respectively, with bone erosion by tumor.
3. Ear
   Serous effusion in the middle ear with conductive hearing loss often occurs with obstruction or invasion of the lateral wall of the nasopharynx.
4. Oral cavity
   Swelling of the gingiva or gingivobuccal sulcus and loose dentition suggest the presence of an advanced sinonasal tumor.
5. Nasal endoscopy
   If the tumor is not obstructing the nasal cavity, nasal endoscopy may provide useful information as to the location and, in some cases, the suspected pathology. For instance, a tumor medial to the middle turbinate is often an esthesioneuroblastoma. Biopsy of intranasal masses in an office setting should proceed cautiously owing to the relative inability to control bleeding from a highly vascular lesion or for fear of a CSF leak.

Imaging

1. Computed tomography (CT) with contrast
   Thin-cut (1 mm) CT with contrast is preferred for evaluation of the bony confines of the sinonasal tract and relative vascularity of the tumor.
2. Magnetic resonance imaging (MRI) with and without contrast
   Contrast-enhanced MRI can distinguish tumor from soft tissue and trapped mucus and also evaluate dural involvement. Furthermore, in some cases MRI can identify perineural extension.
3. CT or MR angiography is a helpful adjunctive imaging modality for tumors involving the cavernous sinus and intracranial components of the carotid artery and circle of Willis.
4. Positron emission tomography (PET)/CT
   If biopsy reveals a malignant neoplasm, PET combined with CT is preferred to evaluate for regional or distant metastases.

BOX 118.1 Tumors of the Sinonasal Tract

EPITHELIAL

Benign

Adenoma
Columnar papilloma
Exophytic papilloma
Inverted papilloma

Malignant

Adenocarcinoma
Adenoid cystic carcinoma
Melanoma
Olfactory neuroblastoma
Squamous cell carcinoma
Transitional cell carcinoma
Undifferentiated carcinoma

NONEPITHELIAL

Benign

Chondroma
Fibroma
Hemangioma
Neurilemmoma
Neurofibroma
Osteoma

Malignant

Connective tissue sarcoma
  Chondrosarcoma
  Giant cell tumor
  Lymphoma
Lymphoreticular tumors
  Osteosarcoma
  Plasmacytoma

METASTATIC CARCINOMA

Soft tissue sarcoma
  Angiosarcoma
  Fibrosarcoma
  Hemangiopericytoma
  Leiomyosarcoma
  Liposarcoma
  Myxosarcoma
  Rhabdomyosarcoma

Indications

1. Benign and malignant tumors of the anterior cranial base
   a. Prior to any intervention, it is recommended to review cases with a multidisciplinary tumor board. For the purpose of this chapter, most benign and malignant tumors of the anterior cranial base can be removed surgically.
   b. After treatment planning is finalized, approaches are determined by the surgical team.
2. Lateral rhinotomy (Fig. 118.1)
   The lateral rhinotomy incision is useful in combination with a bicoronal transcranial approach for tumors of the maxillary and ethmoid sinuses with extension into the anterior cranial fossa, orbit, and pterygoid fossa. It is limited though to unilateral tumors and includes a facial incision.
3. Midfacial degloving (Fig. 118.2)
   The midfacial degloving technique is appropriate for bilateral tumors of the nasal cavity and paranasal sinuses. Although limited in approach to the ethmoid roof and frontal sinuses, these limitations can be resolved with the addition of a bicoronal approach.
4. Endoscopic transnasal techniques
   With improved optics and high-definition resolution, endoscopic transnasal techniques may be appropriate for tumors involving the nasal cavity, paranasal sinuses, and cranial base with minimal intracranial involvement or in combination with the bicoronal approach.

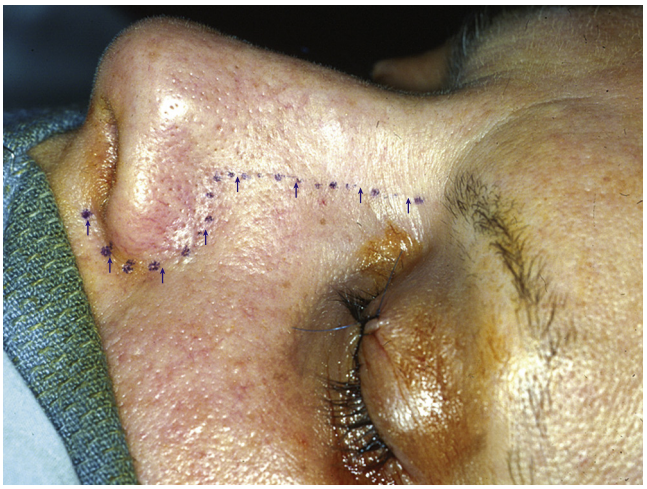

Fig. 118.1. The lateral rhinotomy incision affords excellent exposure of the ipsilateral nasal cavity and paranasal sinuses with a good cosmetic result.

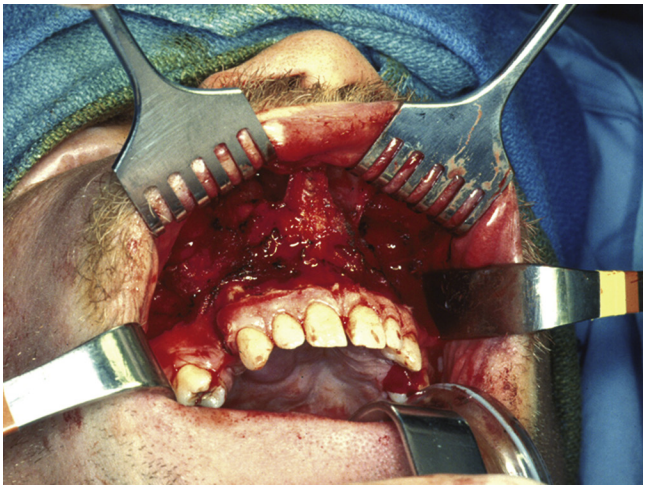

Fig. 118.2. The midfacial degloving approach is useful for tumors involving the sinonasal cavity bilaterally.

Contraindications

1. Bilateral orbital involvement
2. Bilateral cavernous sinus or carotid artery involvement
3. Gross intracranial extension
4. Distant metastatic disease
5. The overall functional and health status of the patient must be considered.

Preoperative Preparation

1. Consent
   After a review of tumor type, location, and choice of intervention, the patient is presented with the plan, in which

the risks and benefits are defined. Risks discussed should include intracranial bleeding, stroke, diplopia, blindness, CSF rhinorrhea, meningitis, epistaxis, facial nerve weakness, facial parasthesias, epiphora, and nasal obstruction.
2. Medications
   All medications and supplements with antiplatelet or anticoagulating properties should be discontinued a week prior to surgery.
3. Prophylaxis of deep venous thrombosis with pneumatic compression stockings is provided throughout the surgery and hospital stay.

OPERATIVE PERIOD

Anesthesia

General
All procedures for the open and endoscopic resection of skull base tumors are performed under general anesthesia.

Positioning

Supine
With the patient in a lateral position, a lumbar drain is placed to remove CSF prior to intracranial exposure for open procedures. This relaxes the brain and limits the need for parenchymal retraction as well as the risk of encephalomalacia. Although the drain is usually removed after completion of the case, some surgeons may prefer to leave it in place for 48 to 72 hours to lower intracranial pressure as the reconstruction heals. The patient is placed supine on a Mayfield head holder without pins for ease of rotation and repositioning during the procedure. If a bicoronal approach is planned, the eye are protected with a suture tarsorraphy to prevent inadvertent injury to the corneas. The intranasal cavity, including the inferior and middle turbinates, basal lamella, and anterior wall of the sphenoid sinus medial to the middle turbinate are infiltrated with 1% xylocaine with 1:100,000 epinephrine, and 0.05% oxymetazoline-soaked pledgets are placed in the nasal cavity. The patient is then prepped and draped in routine fashion.

Perioperative Antibiotic Prophylaxis

Ceftriaxone
Antibiotics used for prophylaxis should have a broad spectrum and CSF penetrance.
Vancomycin if the patient is allergic to penicillin or cephalosporins

Monitoring

None necessary

Instruments and Equipment to Have Available

1. Open cranial base set including vascular instruments
2. Basic endoscopic sinus surgery set
3. Nasal endoscopes (4 mm) with 0-, 45-, and 70-degree lenses
4. Basic endoscopic skull base surgery set
5. Variable high-speed drill with diamond and cutting attachments. Various handpieces and drill bit sizes are available for open, craniotomy, and skull base access.
6. Reciprocating saw for skull base bone cuts
7. Endoscopic, pistol- or pencil-grip bipolar electrocautery instruments
8. Endoscopic pistol-grip Hemoclip applier

Key Anatomic Landmarks

1. Bone: The anterior cranial fossa includes the frontal bone with orbital roof, the crista galli, cribriform plate, ethmoid bone, chiasmatic sulcus, and the lesser wing of the sphenoid bone including the anterior clinoid process.
   a. Tumors that arise in this region may extend into the orbit, paranasal sinuses, or nasal cavity (e.g., esthesioneuroblastoma). Conversely, tumors arising from the paranasal sinuses and nasal cavity may also extend or invade through the anterior cranial fossa to involve intracranial structures (e.g., sinonasal undifferentiated carcinoma or squamous cell carcinoma).
2. Nerves: When surgical resection of tumors in this region is being considered, one should be aware of the complex anatomy, including cranial nerves I, II, III, IV, VI, and the frontal branch of VII.
3. Orbit and extraocular muscles
4. Arteries: The anterior and posterior ethmoid arteries, the sphenopalatine and other distal branches of the internal maxillary artery, and foremost the carotid artery

Prerequisite Skills

1. Fellowship: The head and neck surgeon must be trained in both open and endoscopic approaches to the anterior cranial base. This requires detailed understanding of skull base and sinonasal anatomy. Although extra training in a head and neck surgical oncology or rhinology fellowship is not required, it is highly recommended.

Operative Risks

1. Intraoperative hemorrhage: Care must be taken to control small to medium-size arteries early with vascular clips or bipolar cautery including the Sphenopalatine artery (SPA) and anterior ethmoid arteries to avoid unnecessary blood loss. The team must be prepared to control massive bleeding, although rare, from the carotid artery.
2. Fluid resuscitation: Communication with anesthesiology on blood loss and length of surgery is mandatory for appropriate management of fluid and blood products during surgery to prevent hypotension and underperfusion of the brain.
3. Seizure: Stress from CSF loss, brain retraction, and tumor removal may cause seizures. Preoperative and scheduled dosing of antiseizure medications such as levetiracetam may be useful in certain cases.
4. Parenchymal damage
5. Scalp and flap necrosis: Protection of the supraorbital arteries and hydration of the pericranial flap with saline-soaked gauze will limit injury.
6. Facial nerve injury: The temporal branches are at risk with elevation of the scalp.
7. Orbital injury: Inadvertent injury to the ophthalmic artery can lead to blindness. Injury to the periorbita may cause enophthalmos and diplopia.

Surgical Technique

Bicoronal Approach

- Vasoconstriction
  The planned incision is infiltrated with 0.5% xylocaine with 1:200,000 epinephrine to allow large amounts (20 mL) of infiltration without toxicity.
- Skin incision

Allows access to the frontal lobes of the brain, orbital roof; frontal, ethmoid, and sphenoid sinuses; and cribriform plate. The planned incision site is marked at least 2 cm behind the hairline. It can be extended further to increase the length of the pericranial flap (Fig. 118.3). The incision is continued into a preauricular skin crease anterior to the helix.

- Pericranial flap and frontal bone exposure
  Superiorly, the incision is carried down to the layer of loose areolar tissue without incising the pericranium. Dissection in the subgaleal plane posteriorly provides a longer pericranial flap. Using a curved hemostat to separate the tissue layers, the lateral incision is extended to the fascia of the temporalis muscle (deep temporal fascia). Careful attention is paid to the variable branching patterns of the superficial temporal artery. Preservation of the artery is important for maintaining the blood supply to the temporoparietal fascial flap and to the scalp in revision surgery and post-radiation therapy. Raney clips are placed on skin edges for hemostasis. The pericranial flap is incised in a U-shaped fashion based on the supraorbital and supratrochlear vessels. The flap may extend beyond the scalp incision depending on the length required. The pericranium is elevated from the cranium to the level of the brow; laterally, it is separated from the deep temporal fascia at the margin of the muscle (Fig. 118.4A and B).

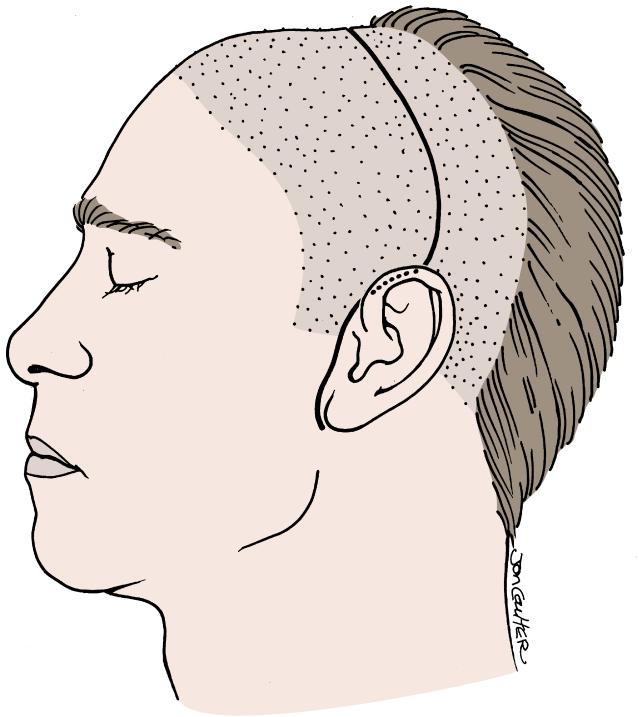

Fig. 118.3. The coronal scalp incision may be extended in a preauricular skin crease to provide additional lateral exposure.

At the medial half of the superior orbital rim, the supraorbital vessels and nerves are found (Fig. 118.5) and released from the bony foramina with a 2- to 3-mm osteotome in an inferior direction if surrounded by bone. If exposure of the lateral orbital rim is necessary, a horizontal incision is made in the outer layer of the deep temporal fascia several centimeters above the zygomatic arch. Elevation continues in this adipose layer to the zygomatic arch, thereby avoiding injury to the frontozygomatic branches of the facial nerve. If the orbital rim must be removed for a subfrontal approach, the periorbita is elevated in a subperiosteal plane medially to the frontoethmoid suture line and laterally to the inferior orbital fissure.

The temporalis muscle is elevated from the temporal bone toward the temporal fossa. A small cuff of periosteum is left at the margins to reapproximate the muscle during closure. Traction sutures or hooks are then used to reflect the scalp, pericranium, and temporalis muscle and secured to the surgical drapes for consistent exposure. A wet laparotomy towel is placed over these tissues to avoid desiccation and loss of tissue.

- Frontal craniotomy
  A variety of craniotomy options are available to expose the anterior cranial fossa (Fig. 118.6). Neurosurgical techniques for exposure of intracranial contents are beyond the focus of this chapter but may be found in various textbooks on neurosurgery.[3]
- Lateral rhinotomy or facial degloving
  Once the frontal craniotomy has been completed, further extracranial exposure of the tumor margins and anterior cranial fossa may be completed using a lateral rhinotomy or facial degloving approach (see Chapters 106 and 109). Exposure allows release of the septum from the anterior cranial base, and removal of the lamina papyracea detaches the lateral nasal wall and maxilla from the orbital roof. Bilateral

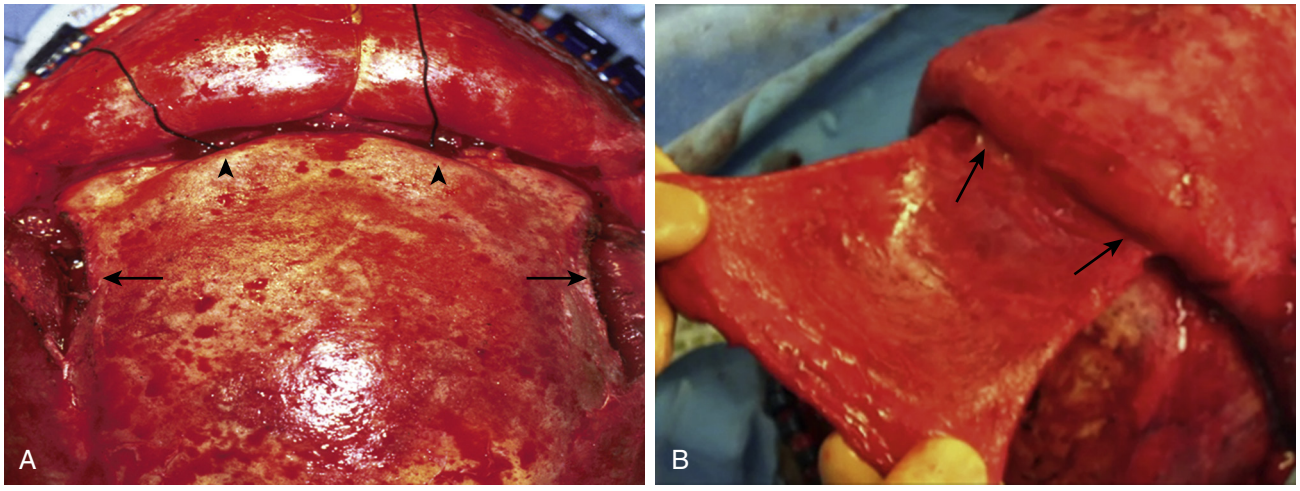

Fig. 118.4. The pericranial flap is dissected from the galea by sharp dissection to the level of the orbital rim. **A.** The scalp is elevated to the orbital rims with preservation of the supraorbital neurovascular bundle *(arrowheads)*. Laterally, the pericranium is separated from the temporalis muscles *(arrows)*. **B.** The vascular pedicle of the pericranial flap is dependent on the supraorbital vessels *(arrows)*.

sphenoidotomies and removal of the vomer with a high-speed diamond drill allows release of the specimen from the anterior wall of the sphenoid sinus. The large defect results in direct communication between the cranial cavity and the nasopharynx (Fig. 118.7).

- Reconstruction
  A watertight closure is critical to decrease the chances of pneumocephalus, CSF leak, and meningitis. The most commonly used flap for this closure is the pericranial flap, as discussed earlier. The pericranial flap can cover the anterior skull base, including the cribriform plate, planum sphenoidale, fovea ethmoidalis, and orbital roof. The arc of rotation of the pericranial flap can be increased by using a unilateral blood supply or incising the base of the flap. The flap is then placed into the wound. The distal edge of the flap is secured to the edge of the intact dura at the posterior border of the skull base defect. Suturing is then performed from posterior to anterior along the cut dural edges or periorbita to form a watertight seal. The use of split calvarial bone grafts is not needed to support the reconstruction and could lead to osteomyelitis or osteoradionecrosis if radiation is planned. Skin grafts are not needed, as remucosalization will occur on the nasal side of the pericranium. Prior to replacement of the bone grafts, all remaining mucosa within the frontal sinuses must be removed in order to allow cranialization of the frontal sinus. Blunt stripping of the mucosa with a Freer elevator and then "polishing" all edges and crevasses with a 3- to 4-mm high-speed diamond drill with continuous irrigation are recommended. This will help to prevent postoperative mucocele formation. This dissection is carried into the frontal recess bilaterally, and temporalis muscle plugs are used to obliterate the recess.

The craniotomy and supraorbital bones are then replaced. Care must be taken not to compress the pericranial flap at the inferior edge of the supraorbital bone. It is recommended to remove an extra 2 to 3 mm of bone to avoid this complication. The bone flaps are secured with titanium microplates and 3- to 4-mm self-tapping screws. Burr-hole plates can be used to prevent postoperative cosmetic defects (Fig. 118.8). Prior to closure, a 7-mm Jackson-Pratt drain is

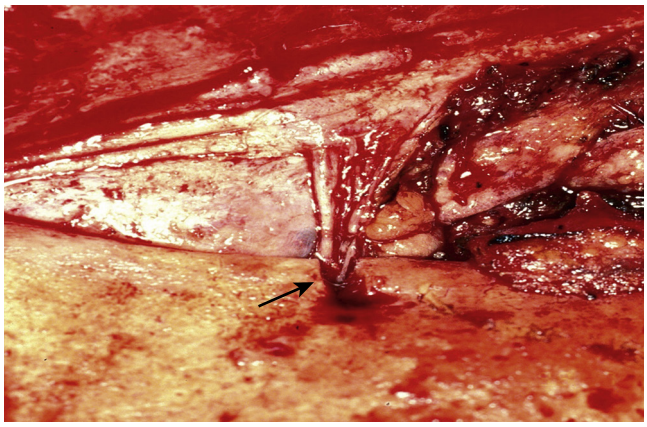

Fig. 118.5. Subperiosteal elevation of the frontal scalp reveals the supraorbital nerve exiting from a completely enclosed bony foramen. The bone inferior to the nerve has been removed *(arrow)*.

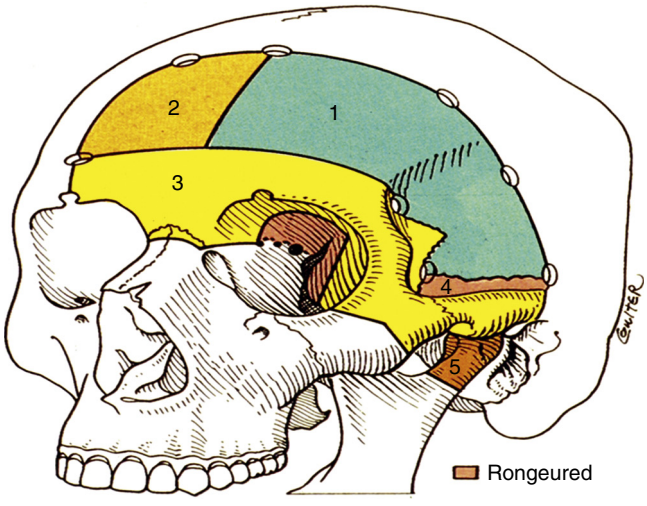

Fig. 118.6. Various segments of the frontal bone and supraorbital rims may be removed to provide adequate exposure of the anterior cranial base. *1*, frontotemporal craniotomy; *1 & 2*, bifrontal craniotomy; *3*, subfrontal approach with orbitozygomatic osteotomy; *4*, subtemporal craniectomy; *5*, mandibular condylectomy

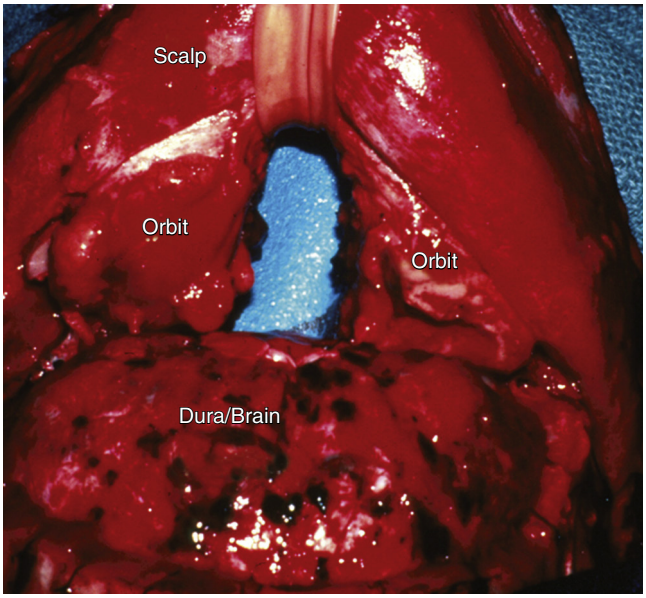

Fig. 118.7. After resection of the neoplasm, a large defect of the anterior cranial base remains and communicates with the paranasal sinuses.

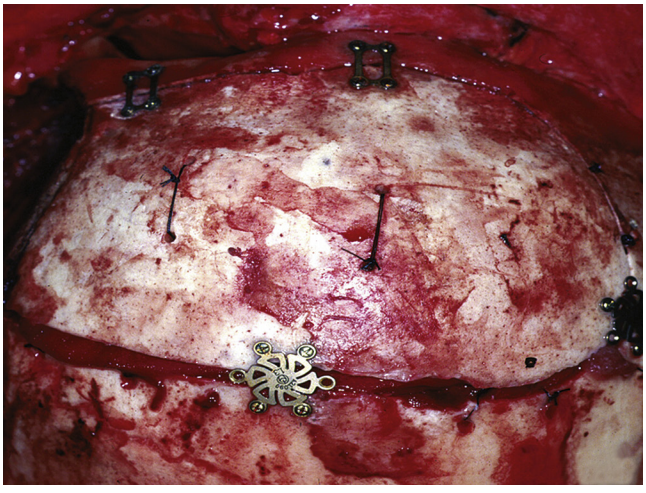

Fig. 118.8. Bone defects may be covered with titanium burr-hole covers to prevent a postoperative deformity.

placed into the wound. The drain exit should be posterolateral to the bicoronal scalp incision and secured with a 2-0 Prolene suture. The drain should never be placed on wall suction in order to prevent excess removal of CSF fluid if there is a leak in the repair. The scalp is then repaired in layered fashion with 3-0 Vicryl sutures to reapproximate deep tissues and staples to reapproximate the skin edges.

Endoscopic Approach

Endoscopic techniques can be used to approach malignant and benign tumors of the ethmoid roof and cribriform region of the anterior cranial base.[4,5] Endoscopic techniques or corridors to other regions of the anterior skull base have been described and are presented in other chapters (see Chapters 117, 119, 120, and 122). All of these techniques may be combined with open approaches per surgeon preference.

- Vasoconstriction
  After receiving three rounds of 0.05% oxymetazoline spray in the preoperative holding area, the patient is positioned in a supine position on the operating table. Using a headlight, approximately 10 mL of 1% lidocaine with 1:100,000 epinephrine is injected into the septum, middle turbinate, uncinate process, and the anterior wall of the sphenoid sinus. Pledgets soaked in 0.05% oxymetazoline are placed into the nasal cavity.
- Image guidance
  At this time registration is performed for image guidance, and the patient is draped in routine fashion without a skin prep.
- Nasal approach
  Pledgets are removed and a nasal endoscopy is performed to evaluate the extent of the tumor. A Cottle elevator is often used to discern tumor attachment to the septum or middle turbinates. This helps to determine whether intranasal tissues such as the septal flap or middle turbinate mucosa may be used for reconstruction at the end of the operation.

  Using a 0-degree endoscope and a 4-mm microdébrider, the tumor is quickly debulked to localize where it is attached in the nasal cavity. Epinephrine pledgets (1:1000) are then placed for rapid hemostasis. Exposure of noninvolved sinuses is performed as previously described, including maxillary antrostomy, total ethmoidectomy, and sphenoidotomy (see Chapters 103, 108, and 110) to identify the lateral and posterior margins. A Draf 3 frontal sinus approach (see Chapter 113) is performed to evaluate the anterior margins. If not involved by tumor, a nasal septal flap can now be elevated for use in closure of the defect (see Chapter 124). Detachment of the vomer from the sphenoid rostrum is performed with a 3-mm high-speed diamond drill. Through-cutting rongeurs may be used to detach the septum from the rostrum to the frontal sinuses anteriorly (Draf 3 exposure) (Fig.118.9A).
- Ethmoid arteries
  The anterior and posterior ethmoid arteries are exposed laterally where the fovea ethmoidalis attaches to the lamina papyracea and are either clipped or cauterized with bipolar cautery.
- Craniotomy
  Using a 30-degree endoscope and 3-mm high-speed diamond drill with continuous irrigation, the posterior table of the frontal recess is drilled anterior to the olfactory fibers in a horizontal fashion until the dura is exposed. This is repeated along the fovea ethmoidalis in a posterior-to-anterior fashion to connect the anterior craniotomy. Horizontal drilling of the planum sphenoidale anterior to the optic canals completes the craniotomy (see Fig.118.9B). This provides a rectangular craniotomy. The underlying dura may then be opened with a knife or fine scissors, allowing intracranial visualization of the tumor. Anteriorly, the crista galli is dissected free from the adjacent dura. Release of the specimen anteriorly requires transection of the falx cerebri in an anterior-to-posterior direction (see Fig.118.9C). Often the crista galli is thick, and meticulous thinning with a 3-mm high-speed diamond drill is needed to remove the crista and deliver the tumor (see Fig.118.9D). The olfactory bulbs and nerves can then be dissected from the surface of the brain and resected with the tumor-involved dura. It is recommended to obtain frozen section margins from the olfactory nerves because of "skip" lesions. Hemostasis is then obtained with endoscopic bipolar electrocautery, and the wound is reconstructed.
- Reconstruction
  Multiple reconstructive techniques are possible, including pedicled flaps, fascia lata, and free grafts, which are often placed in multiple layers: intradural, extradural but intracranial, and extracranial. This is discussed in another chapter (see Chapters 124 and 166).

Common Errors in Technique

1. Pericranial flap is too short
   Inadequate length of the pericranial flap will not allow adequate closure and a watertight seal of the cranial base defect. Examine preoperative imaging to calculate the proper length of the flap.
2. Injury to the supraorbital artery
   Loss of blood supply to the pericranial flap would lead to flap necrosis and failure to separate the nasal cavity from the intracranial contents.
3. Injury to the temporal (frontal) branches of the facial nerve
   Dissection superficial to the temporalis muscle could lead to permanent paralysis of the upper third of the face.
4. Failure to identify and preserve the superficial temporal artery
   This artery is the blood supply to the temporoparietal flap, which may be needed in revision surgery when a pericranial flap is not available.
5. Frozen sections
   Frozen-section analysis of tumor margins is essential to perform gross total resection of disease.
6. Periorbita injury
   Injury to the lining of the orbit may lead to herniation of adipose tissue, diplopia, and enophthalmos.
7. Anterior ethmoid artery
   Unrecognized injury of the anterior ethmoid artery may cause a retro-orbital hematoma and loss of vision.
8. Frontal sinus cranialization
   Removal of the posterior table of the frontal sinus with complete removal of mucosa from the frontal sinus is essential to prevent delayed mucocele formation.
9. Falx cerebri
   Cutting the falx in a superior direction instead of posteriorly may cause intraparenchymal injury and bleeding.

POSTOPERATIVE PERIOD

Postoperative Management

1. Intensive care unit
   After extubation, patients are transferred to the postanesthesia care unit (PACU) and then either the neurosurgical intensive care unit or a variable care unit.
2. Neurologic assessment
   Close nursing care, including neurologic assessment every hour, is critical. Appropriate pain management without oversedation is important for neurologic examination.

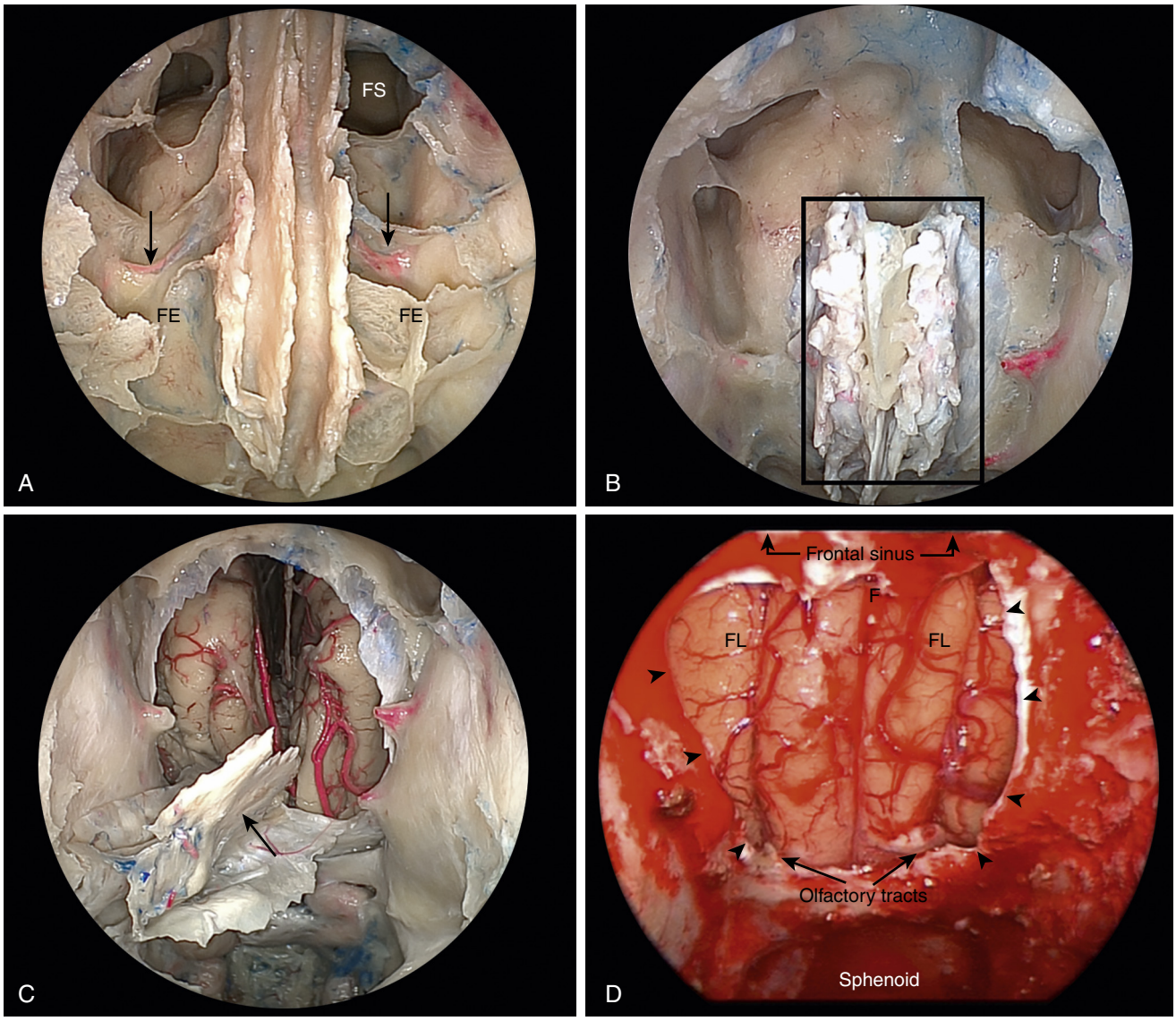

Fig. 118.9. A, Endoscopic visualization of the anterior cranial base in an anatomic specimen with a 30-degree endoscope. The ethmoid sinuses are broadly opened and the fovea ethmoidalis (FE) is exposed. A portion of the middle turbinates and septum remains (center). The anterior ethmoid arteries are identified *(arrows)*. **B,** A rectangular craniotomy is performed along the FE (lateral), planum sphenoidale, and frontal recess. **C,** Visualization of the attachment of the falx cerebri to the crista galli *(arrow)*. **D,** Intraoperative view of the cranial defect *(arrowheads)* during endoscopic surgery for esthesioneuroblastoma. Cut edges of dura *(arrowheads) FL,* Frontal lobes; *FS,* frontal sinus.

3. Fluids and vital signs
   Continuous monitoring of vital signs and volume shifts within the first 24 hours may lead to the identification of common metabolic disorders following surgery. Fluid replacement including blood products is not uncommon following skull base procedures.
4. Drain management
   Hemovac drain management for open procedures is measured every 4 hours on the first postoperative day and every 8 hours thereafter. Drains should be placed only to self-suction to avoid inadvertent diversion of CSF. We aim to remove drains within 48 to 72 hours following surgery to avoid a CSF fistula. If a lumbar drain is used in cases of open or endoscopic surgery, 5 to 10 mL of CSF is released every hour. Often the drain is clamped 48 to 72 hours after surgery and removed 12 hours later if no CSF leak is noted.
5. Imaging
   A CT or MRI scan is obtained on postoperative day 1 or 2 depending on the patient's acuity. This gives an objective measure of tumor clearance and aids in looking for intracranial complications such as hemorrhage or pneumocephalus.
6. General
   Patients are advised not to blow the nose, sneeze with the mouth open, lift nothing heavier than 10 pounds, and avoid the use of straws for at least 4 weeks following surgery. Patients are advised to use oxymetazoline nasal spray every 8 hours in each nostril for 3 to 4 days to decrease postoperative nasal bleeding. Saline nasal spray is provided for nasal moisture; its use is recommended every 2 hours while awake. Routine follow-up in the office is scheduled for postoperative day 7 and after 1, 2, and 3 months to allow for endoscopic débridement of the nasal cavity and monitoring of nasal healing.

Complications

1. Intracranial hemorrhage
   A rapid decrease in consciousness is concerning for an intracranial hemorrhage in the postoperative period. Careful manipulation of intravascular structures with sharp dissection of tumor without retraction prevents this complication. Immediate CT imaging of the head and operative exploration are warranted.
2. Facial nerve injury
   The patient's inability to elevate the brow or crease the forehead skin is a sign of injury to the frontal branch of the facial nerve. Careful dissection of the bicoronal flap in the correct plane prevents injury.
3. Orbital injury
   Diplopia, enophthalmos, or exophthalmos is concerning for an orbital injury. Preservation of the periorbita and careful cautery of the anterior ethmoid artery helps to prevent this complication. An immediate Ophthalmology consult is warranted to help identify the injury and provide possible interventions.
4. Visual loss
   Postoperative examination of the patient with a basic vision examination is recommended. Loss of vision may be due to injury to the optic nerve, ophthalmic artery, superior hypophyseal arteries, or intracranial bleeding with optic nerve compression. A CT scan of the head without contrast can help to identify the cause. If there is concern for intracranial bleeding and compression, immediate operative exploration is warranted.
5. Olfactory loss
   Loss of olfaction in some cases is unavoidable. However, aggressive resection of the septum for visualization of the planum sphenoidale or excessive superior mucosal dissection for a nasoseptal flap may cause permanent olfactory loss. When possible, care must be taken to preserve at least 1 cm of septal mucosa in the olfactory cleft to avoid this complication.
6. Syndrome of inappropriate antidiuretic hormone (SIADH)
   Stress or retraction of the pituitary gland may lead to SIADH. Confusion and lethargy are common symptoms. Sodium levels should be checked frequently.
7. Diabetes insipidus
   Although uncommon, decreased vasopressin production from the pituitary gland may follow brain retraction. Urine outputs are then measured, and appropriate fluid management is provided.
8. Deep venous thrombosis (DVT)
   Operations on the skull base are inherently long, with decreased patient activity postoperatively. Prevention of DVT includes compression stockings and, in high-risk cases, subcutaneous heparin in the postoperative period.
9. Seizures
   Intracranial manipulation increases the chance of postoperative seizures. Prevention includes minimizing trauma to normal parenchyma; perioperative prophylactic dosing of antiseizure medications such as levetiracetam may be useful.
10. Pneumocephalus
    A meticulous, watertight closure of the dura after surgery lowers the risk of this life-threatening complication. A rapid decrease in patient responsiveness following surgery should be evaluated quickly with a CT scan of the head and immediate intraoperative repair.
11. CSF leak
    As with pneumocephalus, a meticulous watertight closure prevents postoperative CSF leaks. If a patient shows signs of CSF rhinorrhea, bedside endoscopy may help to confirm the diagnosis and determine the site of the leak. Other causes include failure of free grafts, pedicled flaps, and microvascular free tissue flaps. Immediate identification with surgical repair is warranted.
12. Wound infections
    As with any surgical approach, a wound infection is possible. Good sterile technique and the use of preoperative prophylactic antibiotics such as ceftriaxone or vancomycin are recommended. Erythema around the incision site with or without purulent exudate is highly suspicious for infection. Although antibiotics may resolve the infection, operative drainage and thorough irrigation of the infected site may be necessary.
13. Scalp necrosis
    Decreased blood supply to the scalp after a bicoronal approach may lead to necrosis of the overlying skin. This complication can be avoided by preserving the vascular supply and not including the superficial layers of the scalp in the pericranial flap.
14. Chronic rhinitis
    The removal of normal sinus and nasal cavity mucosa, particularly after radiation, may lead to chronic inflammation, mucous crusting, and nasal obstruction. Emollient nasal sprays and saline irrigations may improve sinonasal quality of life.

Alternative Management Plan

1. Induction chemotherapy and radiation
   Some patients may choose nonsurgical therapies. Induction chemotherapy followed by radiation is an option in select malignancies squamous cell carcinoma (SCCa), sinonasal undifferentiated carcinoma (SNUC) and nasopharyngeal carcinoma (NPC). If nonsurgical management fails, surgery may be an option.

DISCUSSION

Evidence-Based Medicine Question

Is there evidence for either equivalent or superior results with endoscopic resection of skull base malignancies versus traditional open approaches?

Despite aggressive surgical management, radiation, and in some cases chemotherapy, primary malignancies of the anterior cranial fossa remain difficult to cure. A low volume of primary cases prohibits high-volume, multiarmed, prospective trials to optimize overall care. The advent of endoscopic techniques does show promise, particularly in the case of early-stage tumors. A recent systematic review of the published literature for olfactory neuroblastoma and sinonasal adenocarcinoma has been published.[6,7] These results demonstrate equivalent if not superior results with the endoscopic approaches in dealing with oncologic cases and postoperative complications. However, the limitations of these studies compared with prospective, multi-institutional trials must be understood before a final conclusion can be drawn.

Editorial Comment

The anterior cranial base may be resected using a completely transcranial approach, combined transcranial and transfacial/endoscopic approach, or completely endoscopic endonasal approach. Equivalent oncologic results for sinonasal malignancy can be achieved with all of these approaches, and the choice of approach depends on both the patient and surgeon.

For olfactory neuroblastoma, superior oncologic results have been noted with endoscopic endonasal surgery, even when adjusting for Kadish stage and Hyams grade.[6]

Carl H. Snyderman

Access the review questions and additional source list online at http://www.expertconsult.com

REFERENCES

1. Zimmer LA, Carrau RL. Neoplasms of the nose and paranasal sinuses. In: Johnson JT, Rosen CA, editors. Head and Neck Surgery–Otolaryngology. 5th ed Philadelphia: Lippincott Williams & Wilkins; 2014. p. 2044–2062.
2. Caplan LS, Hall I, Levine RS, et al. Preventable risk factors for nasal cancer. Ann Epidemiol 2000;10:186–191.
3. Di Maio S, Sekhar LN. Skull base approaches. In: Ellenbogan RG, Abdulrauf SI, Sekhar LN, editors. Principles of Neurological Surgery. 3rd ed Philadelphia: Elsevier; 2012. p. 667–679.
4. Kassam A, Snyderman CH, Mintz A, et al. Expanded endonasal approach: the rostrocaudal axis. Part I. Crista galli to the sellaturcica. Neurosurg Focus 2005;19(1):E3.
5. Cavallo LM, Messina A, Cappabianca P, et al. Endoscopic endonasal surgery of the midline skull base: anatomical study and clinical considerations. Neurosurg Focus 2005;19(1):E2.
6. Fu TS, Monteiro E, Muhanna N, et al. Comparison of outcomes for open versus endoscopic approaches for olfactory neuroblastoma: a systematic review and individual participant data meta-analysis. Head Neck 2015;38(suppl 1):E2306–E2316.
7. Meccariello G, Deganello A, Choussy O, et al. Endoscopic nasal versus open approach for the management of sinonasal adenocarcinoma: a pooled-analysis of 1826 patients. Head Neck 2016;38(Suppl 1): E2267–E2274.

REVIEW QUESTIONS

1. As the pericranial flap is extended to the root of the helix, arterial bleeding is noted. The artery is then sacrificed. Which pedicled flap has been lost for reconstruction?
   a. Pericranial
   b. Nasal septal
   c. Temporalis muscle
   d. Temporoparietal

2. Potential intraoperative complications of open anterior cranial base surgery include all of the following, except
   a. Seizure
   b. Facial nerve injury
   c. Blood loss
   d. Pneumocephalus

3. After the completion of surgery, you are called to the PACU to evaluate your patient. His blood pressure is stable, postoperative hematocrit is 28, and he is somnolent. No pain medications have been given, and the nurse states that he was following commands until a few minutes ago. What is your next step in management, diagnosis, determination of cause, and intervention?
   a. Plain CT of the head, tension pneumocephalus, lumbar drain not clamped, clamp drain and wait
   b. MRI of the head, intracranial bleeding, pseudoaneurysm, interventional radiology with embolization
   c. Plain CT of the head, tension pneumocephalus, lumbar drain not clamped, return to operating room to identify the source of reconstructive failure
   d. MRI of the head, tension pneumocephalus, inadequate postoperative fluid management, burr hole in the PACU

4. Postoperative complications include all of the following, except
   a. Diplopia
   b. CSF leak
   c. Necrosis of the scalp
   d. Hearing loss

5. Common errors in intraoperative technique include all of the following, except
   a. Injury to the supraorbital artery, leading to necrosis of the temporoparietal flap
   b. Injury to the frontal branch of the facial nerve with paralysis of the frontalis muscle
   c. Failure to identify and preserve the superficial temporal artery
   d. Not checking multiple frozen sections to determine the extent of surgical resection

ADDITIONAL SOURCE

Fu TS, Monteiro E, Muhanna N, et al. Comparison of outcomes for open versus endoscopic approaches for olfactory neuroblastoma: a systematic review and individual participant data meta-analysis. Head Neck 2015;38(Suppl 1):E2306–E2316.

119 Endoscopic Endonasal Transpterygoid Approaches to the Middle Cranial Fossa

Ricardo Carrau, Daniel M. Prevedello

INTRODUCTION

- Endoscopic endonasal approaches (EEAs) provide direct access to pathologies near the median and paramedian ventral skull base. A major principle of endoscopic endonasal surgery is the use of anatomical corridors to safely access skull base lesions with low associated morbidity. To access the middle cranial fossa, the maxillary sinus and the pterygopalatine fossa (PPF) are traversed to encounter and remove the pterygoid process, partially or completely; hence, the name transpterygoid approach.
- These approaches provide access to Meckel's cave with the trigeminal nerve and its associated foramina and branches, cavernous sinus, petrous and parasellar segments of the internal carotid artery (ICA), PPF, infratemporal fossa (ITF), and fossa of Rosenmüller (i.e., nasopharynx).[1-5]

The pterygoid process is a paired bony projection comprised of two plates (medial and lateral) that project posteriorly and a common anterior wall and base (Fig. 119.1). It extends inferiorly and perpendicularly from the junction of the body and greater wing of the sphenoid bone. At its anterior face, one can identify two prominent foramina: the foramen rotundum where the maxillary nerve exits and the Vidian canal that transmits the preganglionic parasympathetic fibers to the sphenopalatine ganglion as well as the postsynaptic sympathetic fibers from the deep petrosal nerve (Fig. 119.2).[5-10]

KEY OPERATIVE LEARNING POINTS

- The pterygoid process is part of the surgical corridor to the middle cranial fossa, ITF, and nasopharynx.
- The Vidian canal and foramen rotundum are fixed anatomical landmarks that help with intraoperative orientation.
- The ICA and its relationship to the tumor will dictate the extent and direction of the approach.

PREOPERATIVE PERIOD

History

- Mass effect or facial swelling
- Pain
- Trismus
- Double vision
- Dry eye
- Corneal ulcers
- Numbness
- Facial paralysis or weakness
- Medications:
  - Antiplatelet drugs
  - Herbal products
  - Vitamin E
  - Fish oil
- Prior surgery or radiation therapy

Physical Examination

- Thorough evaluation of cranial nerves (CN), specially CN 1–7;
- Ocular function
- Mouth opening
- Nasal endoscopy including nasopharynx
- Olfactory function

Imaging

- Computed tomography (CT)
- CT angiogram (CTA)
- Magnetic resonance imaging (MRI)
- Angiography
- An initial differential diagnosis is based on the appearance and site of origin of the lesion as demonstrated by MRI and/or CT. These imaging studies are considered complementary, as MRI is best in determining soft tissue relationships, whereas CT is best to show the bony architecture.
  - MRI demonstrates the interface between the tumor and the surrounding soft tissues, differentiating the tumor from secretions or inflammatory sinonasal disease, assessing the presence and extent of perineural spread, and the degree of involvement of the dural, brain, or orbit.
  - In addition, imaging studies allow the surgeon to estimate the extent of surgical exposure necessary. One

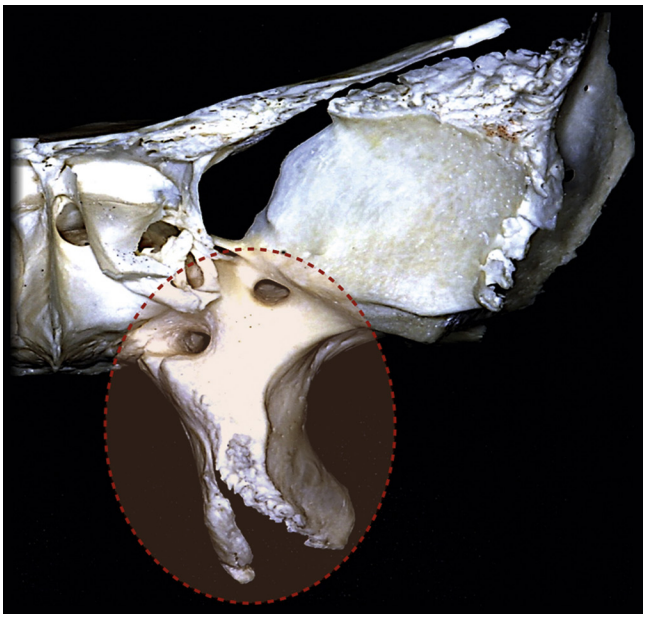

Fig. 119.1. Anterior view of the left sphenoid bone. Shaded area corresponds to the pterygoid process. The term transpterygoid responds to the fact that these approaches have to transgress part or all the pterygoid process.

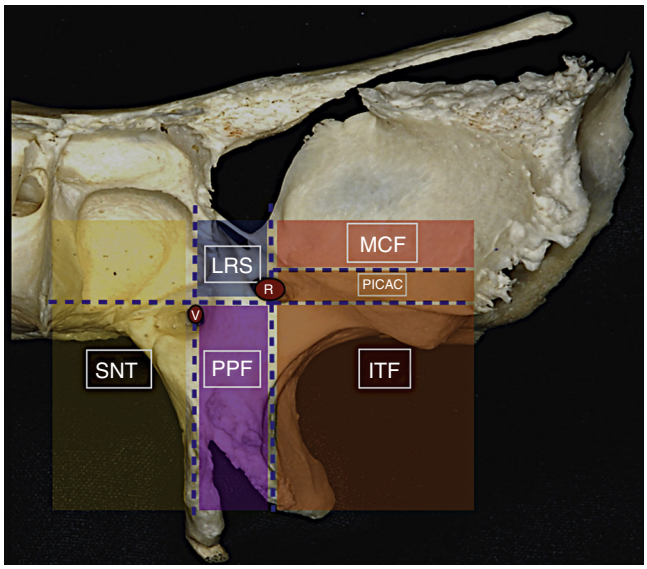

Fig. 119.2. Anterior view of the left sphenoid bone. The foramen rotundum *(R)* and vidian *(V)* canal are useful landmarks in the anterior face of the pterygoid process. Horizontal lines, in the coronal plane, drawn through the lower level of foramen rotundum and vidian canal, approximate the locations of the middle cranial fossa (MCF), the lateral aspect of the petrous temporal bone (i.e., petrous segment of the ICA [PICAC]), and the infratemporal fossa (ITF). The spaces between the vertical lines are further divided by the horizontal line through the vidian canal into two regions: the lateral sphenoid recess (LRS), and the pterygopalatine fossa (PPF) and sinonasal tract (SNT).

may draw imaginary vertical lines in the coronal plane intersecting these foramina; thus, dividing the region into the sinonasal tract medially; the middle cranial and ITFe laterally; and the PPF in between. Imaginary horizontal lines, in the coronal plane, drawn through the lower level of foramen rotundum and the Vidian canal, approximate the locations of the middle cranial fossa, the lateral aspect of the petrous temporal bone (i.e., the petrous segment of the ICA), and the ITF. The spaces between the vertical lines are further divided by the horizontal line through the Vidian canal into two regions: the lateral sphenoid recess above this horizontal line, and the PPF below it (see Fig. 119.2). Matching a lesion height and width in relation to these landmarks helps the surgeon to estimate the surgical corridor required to expose any particular lesion (Fig. 119.3A and B).[4]

- A full body positron emission tomography (PET) scan, or a fused PET/CT scan helps to identify the presence of regional or distant metastasis in patients presenting with a malignant tumor.
- Additionally, a high-resolution CTA appraises the course of the ICAs and their intracranial branches, evaluates the skull base bony anatomy, and may improve the accuracy of the intraoperative navigation.
- Using the intraoperative navigation software, MRI can be fused to the CT or CTA scan to plan the approach preoperatively.
- If there is involvement of the ICA, the patient must be assessed by one of the various balloon occlusion tests to determine the degree of collateral flow and to evaluate the tolerance to the loss of one ICA. Areas of hypoperfusion on imaging mandate an extracranial-to-intracranial artery bypass or stenting of the vessel.
  - Patients with benign lesions who can be operated on electively may benefit from ICA stenting as a protective measure. However, stenting requires antiplatelet therapy for 6 to 12 weeks; thus, ICA stenting is not a practical approach for patients with malignant tumors.

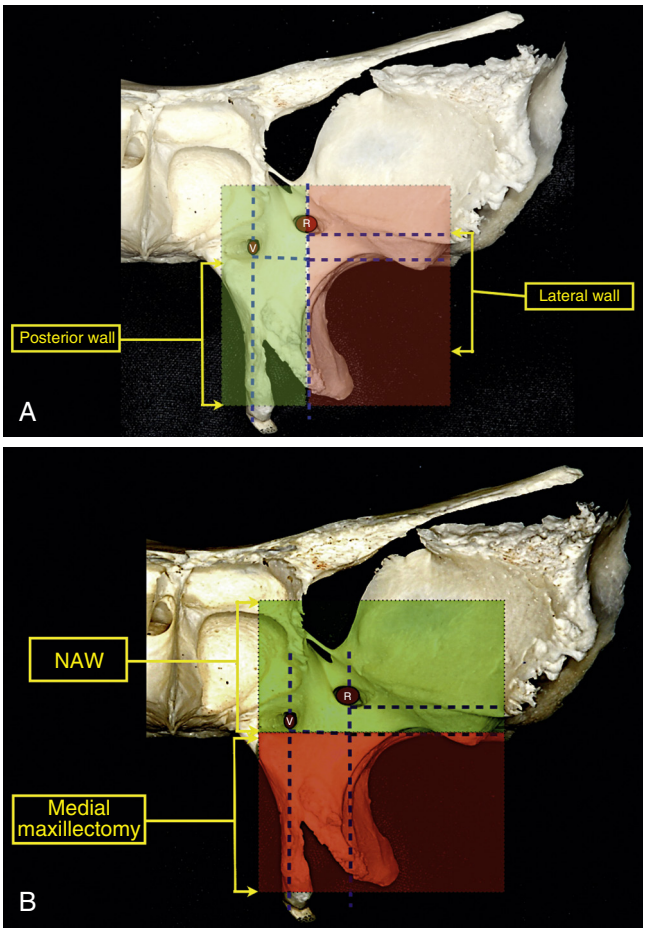

Fig. 119.3. (A) Lesions that are medial to a vertical line crossing the foramen rotundum *(R; green shaded area)* may be resected after removing the posterior wall of the antrum; however, lesions that are lateral to this line *(pink shaded area)* will need an extended approach including the resection of the lateral wall of the antrum. **(B)** Lesions that are superior to a horizontal line crossing the vidian *(V)* foramen may be resected via a large nasoantral window (NAW); however, lesions that extend inferior to this line require a full medial maxillectomy.

Indications

- Endoscopic endonasal transpterygoid approaches (EETPA) were first used to access pathologies in the lateral sphenoid sinus such as bony defects associated with CSF leaks and meningo/meningoencephaloceles.[1]
- Multiple extensions and modifications of the EETPA followed, addressing select pathologies arising in the PPF, the petrous apex, the anterior aspect of Meckel's cave, the cavernous sinus, the ITF, and the medial aspect of the middle cranial fossa.[2-10]
  - Meningiomas, chordomas, chondrosarcomas, and trigeminal schwannomas, are tumors commonly affecting these regions.
  - Other less common pathologies that may be approached via a transpterygoid corridor include select sinonasal carcinomas, juvenile nasopharyngeal angiofibromas, aggressive pituitary macroadenomas, and metastatic neoplasms.

- One must consider the goals of surgery (cure vs. gross total resection vs. debulking or decompression), the relationship of the lesion to neurovascular structures (one must not cross a critical CN or vessel), expected sequelae, and the experience and expertise of the surgical team to decide whether to use an endoscopic endonasal technique or any other alternative approach.
  - Surgery for a benign tumor usually strives for a total resection; however, a partial resection may be preferred to avoid significant morbidity.
  - Even a malignant tumor involving critical structures may require compromising the resection and settling for just a gross total resection (as opposed to a wide resection) to be followed by adjuvant treatment.
- The use of multiple lesser approaches (concomitant or staged) may produce less morbidity than a massive resection with a single approach.

Contraindications

- Despite its perceived minimally invasive nature, an EETPA yields a resection equivalent to that of an open approach, albeit through a smaller access; thus, any uncontrolled comorbidity that would preclude an open approach also applies to the EETPA. Cardiopulmonary, infectious, or other systemic comorbidities should be taken into consideration.
- One must use the approach that will achieve the most complete and safest resection adjusted according to the histopathology and extent of the tumor, but not the other way around; thus, the resection should not be compromised because the surgical approach is inadequate.
- The presence of an active bacterial infection in the sinonasal tract is a contraindication for an intradural approach, as it can seed the bacteria in the subarachnoid space.
- Tumor histopathology and goals of surgery (i.e., wide resection, gross total resection, or decompression) geographical extent (within the realm of the approach limits), and the relationship to neurovascular structures (the lesion should not be attached or posterior to the ICA or functioning CN) are important considerations in choosing a surgical approach.

When a tumor encases the ICA, the risk of intraoperative vascular injury is significant. If a surgical resection is mandatory, one should consider alternatives including the sacrifice of the ICA, the use of a different approach, or a partial resection followed by adjunctive therapy.

Preoperative Preparation

- The patient's symptoms and comorbidities, coupled with the histopathology and imaging characteristics of the lesion, are the most important determinants for establishing the goals of surgery and for estimating potential sequelae and risks.
- An informed consent should explain the risks involved, present clear goals, and set realistic expectations.
- Anticipate and plan for the social, financial, and psychological ramifications of the expected sequelae and potential complications of surgery.
- Skull base neoplasms frequently mandate a multimodal treatment. Evidence of perineural spread, aggressive bone, or dural invasion mandates adjuvant radiation therapy with or without chemotherapy. Occasionally, decompression of the orbit, the optic nerve, or the optic chiasm may warrant a palliative resection or debulking. Any remaining disease may have to be treated with adjuvant therapy. Therefore, it is important to discuss the clinical plan of management with radiation and medical oncologists in a multidisciplinary setting, such as a Tumor Board.

OPERATIVE PERIOD

Anesthesia

- General
- Awake sedation
- Local

Positioning

- Supine
- Prone
- Lateral recumbent
- Following the induction of general anesthesia (preferably intravenous) and orotracheal intubation, the patient's head is placed in a horseshoe-type holder with the neck tilted slightly to the left and rotated slightly to the right.
  - We use a three-pin head holder for patients who require electromyography (EMG; i.e., cannot be paralyzed) or when a lengthy surgery is anticipated.

Perioperative Antibiotic Prophylaxis

- Third- or fourth-generation cephalosporin
- Wide spectrum antibiotics, with adequate cerebrospinal fluid (CSF) penetration, are administered before the beginning of the surgery and are continued for 48 to 72 hours postoperatively.

Monitoring

- Somatosensory evoked potential (SSEP)
- EMG
- Electroencephalography
- Image guidance
- Doppler acoustic sonography
- Image guidance is an important adjunct during EEA and its need should be anticipated.
  - We prefer a CTA for intraoperative guidance for EETPA, as it provides a map of the bony structures as well as the vasculature.
  - In addition, a CTA can be fused with MRI to provide better definition of the soft tissue interfaces.
- Other adjuncts, like acoustic Doppler or diagnostic ultrasonography, can provide real-time and complementary information to that of the navigation system.
- Intraoperative neurophysiologic monitoring of SSEPs is prudent, as the ICA will be at risk with most EETPA. Similarly, electrophysiological monitoring of CN using EMG, and brain stem evoked responses (BSERs) are used according to the extent of the resection and the relationship to the neurovascular structures.

Instruments and Equipment to Have Available

- Basic endoscopic sinus surgery set
- Extended insulated needle tip electrocautery
- Suction electrocautery
- Endoscopic bipolar electrocautery
- High-speed drill
- Microsurgical instruments

Key Anatomic Landmarks

- Sphenopalatine foramen
- Foramen rotundum
- Vidian canal
- Eustachian tube (ET)
- Lateral pterygoid plate (LPP)
- Foramen ovale and V3

Prerequisite Skills

- Sphenoidotomy
- Endoscopic sphenopalatine artery ligation
- Optic nerve decompression
- Repair of CSF leak
- Nasoseptal flap

Operative Risks

- Catastrophic hemorrhage from ICA
- Injury to the greater palatine nerve
- Injury to V1, V2, or V3
- Injury to the vidian nerve
- Injury to the ET
- Injury to the pterygoid muscles
- Injury to the orbital
- Injury to the brain

Surgical Technique

General Principles

- Considering the goals and anatomical intricacies of EETPAs, they can be classified in five main types[5]:
  - Type A: Partial removal of the medial and/or LPPs, indicated for the transposition of a temporoparietal fascia flap.
  - Type B: Removal of the medial aspect of the base of the pterygoid process, indicated for lesions (e.g., CSF leaks) at the lateral recess of the sphenoid sinus above the level of the Vidian canal.[1,2,4]
  - Type C: Dissection of the Vidian canal removing the base of the pterygoid plates to reach the petrous apex (infra- or retro-petrous), Meckel's cave, or cavernous sinus.[2,3,5,7,8]
  - Type D: Provides access to the ITF and requires a variable removal of the pterygoid plates.[2,5-7]
  - Type E: Removal of the medial pterygoid plate or even the entire pterygoid process, and medial third of the ET to expose the lateral nasopharynx (fossa of Rosenmüller) or the lateral aspect of the craniocervical junction.[3]
- EETPA begins with the expansion of the sinonasal corridor. All EETPA lateral to the vidian canal require traversing the maxillary sinus.
  - The degree of resection of the mucosa and the medial, posterior, and lateral walls is dictated by the extent of exposure necessary to address the pathologic process (see Fig. 119.3A and B).
- Endonasal access to the infratemporal or middle cranial fossae requires a substantial lateral extension of the maxillary sinus corridor, which may involve the addition of a Denker's or Sturman-Canfield's extension to the medial maxillectomy (anterior extension including the removal of the piriform aperture and an anterior maxillotomy). This latter modification provides an extended line of sight toward the structures within the ITF (Fig. 119.4).[3,5,7]

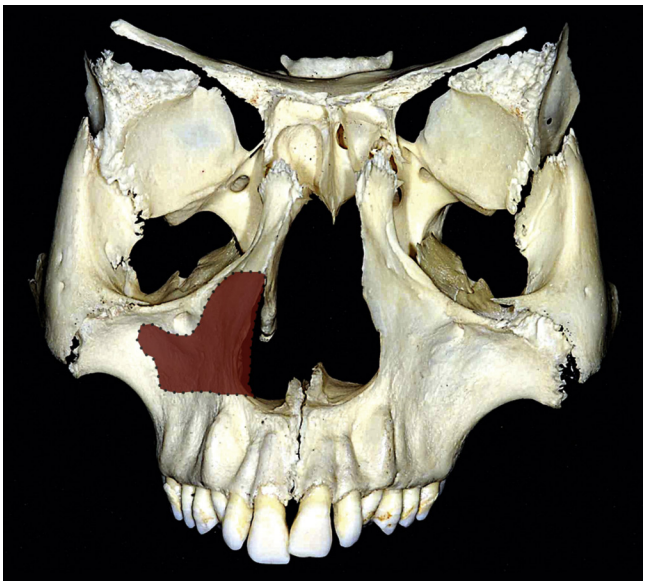

Fig. 119.4. An endoscopic Denker's or Sturman-Canfield approach involves the anterior extension of a medial maxillectomy, including the removal of the piriform aperture and an anterior maxillotomy. This provides an extended line of sight toward lateral structures within the infratemporal fossa.

Nasal Preparation

- A povidone solution is applied to the perinasal and periumbilical areas (in the event that an autologous adipose tissue free graft is required for reconstruction).
  - If the tumor or corridor approaches the ICA, we also prep the lateral thigh for possible harvesting of muscle (i.e., to patch the ICA if injured).
- The nose is decongested using:
  - Topical adrenaline 1/10,000 solution applied with cottonoids.
  - Injection of 1% lidocaine with epinephrine (1:100,000–1:200,000) in the anterior and inferior septum; and anterior middle meatuses.

Nasal Corridor

- The nasal corridor may be ipsilateral (e.g., CSF leak at the lateral recess of the sphenoid); however, both nasal cavities are more commonly used to allow for a two-surgeon, four-handed technique and to provide a cross-court approach that enhances the line of sight to the lateral aspect of the corridor.
- A zero-degree rod lens endoscope provides visualization for most of the surgery (Karl Storz, Tuttlingen, Germany) and may be coupled with straight instruments (the line of sight matches the geometry of the instruments).
  - Angled-lens endoscopes allow to "look around the corner"; however, they are more difficult to use, as they distort the view and require angled instruments to match their path to the visual field.
  - The endoscope is coupled to a high-definition (HD) endoscopic camera and monitor (Karl Storz Endoscopy; Tuttlingen, Germany).
  - Manual irrigation or an endoscope-irrigating sheath maintains a clean lens.
- Expansion of the sinonasal corridor starts with the out-fracturing of the inferior turbinates bilaterally, and out-fracturing of the contralateral middle and superior turbinates.
- Sinus surgery begins as an uncinectomy and is performed using a backbiting rongeur and microdébrider.
- The natural ostium to the maxillary sinus is identified and it is enlarged:
  - Posteriorly towards the posterior wall of the antrum (PWA)
  - Superiorly to reach the inferior and medial orbital walls
  - Inferiorly to reach the inferior turbinate
- A partial middle turbinectomy and complete anterior and posterior ethmoidectomies augment the nasal corridor ipsilateral to the transpterygoid approach.

- Removal of the ipsilateral middle turbinate also provides a mucosal free graft, which can be used for the reconstruction.
- At this point, a microdébrider is used to exenterate the anterior and posterior ethmoid sinuses, identifying and preserving the lamina papyracea and anterior skull base.
  - The cells of the ethmoid sinuses may be exenterated completely or partially to allow visualization of the surgical landmarks or to expand the space needed for instruments.
- Anticipating the possibility of a CSF leak and the need to expose and subsequently protect the ICA, a pedicled nasoseptal flap is harvested from the contralateral side, as the blood supply of the ipsilateral pedicle would be at risk during an EETPA.
- A "reverse" flap is harvested ipsilaterally to immediately cover the donor site of the nasoseptal flap (denuded septum).
  - The remaining septum and reverse flap are protected with silicone splints to avoid injury or avulsion during the passage of instruments.
- Bilateral wide sphenoidotomies facilitate bilateral and bimanual instrumentation, and the identification of anatomical landmarks for surgical orientation.
- The natural os of the sphenoid sinus is enlarged superiorly and laterally until the opening is in plane with the roof and the lateral wall of the sphenoid sinus.
  - Alternatively, the sphenoid sinus can be accessed at the junction of the nasal septum and the sphenoid rostrum.
  - Regardless of the technique, the goal is to achieve wide bilateral sphenoidotomies so there is sufficient space for the instrumentation, with satisfactory freedom of movement, and proper visualization of anatomical landmarks (sella, ICAs, optic nerves).
- The basopharyngeal fascia can be dissected from the inferior floor of the sphenoid sinus to allow the drilling of the floor posteriorly towards the clival recess, and laterally in the direction of the foramen lacerum.
- Once bilateral sphenoidotomies are completed, the ipsilateral sphenopalatine foramen (or foramina) and associated arteries are cauterized with bipolar electrocautery and divided.

Antral Corridor

- EETPAs to the PPF (Type A), lateral recess of the sphenoid sinus (Type B), petrous apex and Meckel's cave (Type C) target areas above the level of the vidian canal; therefore, only a wide nasoantral window (NAW) is required.
  - An adequate NAW should expose the superior half of the posterior wall of the maxillary sinus when using a zero degree endoscope.
  - A maximal NAW extends anteroposteriorly from the nasolacrimal duct to the posterior antral wall, and cephalocaudally from the inferior orbital wall to the superior aspect of the inferior turbinate.
- Access to the ITF (Type D) and lateral nasopharynx (Type E) exposes a target that extends below the Vidian canal; thus, it requires a medial maxillectomy to expose the entire height of the PWA.
  - A medial maxillectomy should extend from the nasolacrimal duct to the PWA (anteroposteriorly) and from the inferior orbital wall to the floor of the nasal cavity (cephalo-caudally).
- Extended approaches to the ITF and/or middle cranial base or fossa may require an endoscopic Denker's approach (i.e., Sturman-Canfield approach; Fig. 119.4).
  - Maximal exposure includes the removal of the remaining inferior turbinate, anterior aspect of the inferior meatus, piriform aperture, ascending process of the maxilla, and sharp transection of the lacrimal duct to extend the medial maxillectomy anteriorly and laterally.

Pterygopalatine Fossa

- The anterior compartment of the PPF contains the internal maxillary artery and its terminal branches; whereas the posterior neural compartment contains neural structures, that is, sphenopalatine ganglion, Vidian nerve, greater and lesser palatine nerves, orbital branches (sympathetic and parasympathetic fibers to the lacrimal gland) and a branch from the ganglion to the infraorbital nerve (Fig. 119.5).
- The sphenopalatine and posterior nasal arteries dominate the anatomy of the superomedial aspect of the PPF (Fig. 119.6).
  - These arteries should be identified and clipped/cauterized as they entered the nasal cavity at the level of the sphenopalatine foramen. It should be noted that the terminal branches of the internal maxillary artery are often more than two, and most commonly enter the nose through different foramina.
- Using a 1 to 2 mm Kerrison or Citelli rongeur, remove the anterior aspect of the sphenopalatine foramen for better exposure and control of the arteries.
- Removal of the PWA is extended as needed to expose the PPF (i.e., to the level of the superior aspect of the inferior turbinate after opening a NAW, or to the antral floor after a medial maxillectomy; Fig. 119.7). The periosteum is preserved to avoid injuring the vascular structures within the PPF.
  - Laterally, the resection of the PWA should be extended to reach the level of the inferior orbital fissure. The infraorbital nerve should be identified at the point where it exits from the PPF and before it enters the infraorbital canal (located in the roof of the maxillary sinus).
  - A meticulous dissection of the inferomedial aspect of PWA is necessary to avoid injury to the descending palatine artery and greater palatine nerve, which run together into the greater palatine canal, which is formed by the oblique junction of the posteroinferior aspect of the maxillary bone and the greater palatine groove.
    - The dissection should extend inferiorly to the greater palatine foramen, as this will facilitate the lateral mobilization of the soft tissues of the PPF (Figs. 119.8 and 119.9**).**
- Following a wide NAW or medial maxillectomy, the mucoperiosteum must be dissected off of the perpendicular plate of the palatine bone.

Resection of the Pterygoid Process

- Removal of the orbital process of the sphenopalatine foramen and anterior aspect of the perpendicular plate of the palatine bone provides access to the medial aspect of the PPF.
  - Inferiorly, the bony walls of the greater palatine canal are removed to expose and release the descending palatine artery and the greater palatine nerve (see Figs. 119.8 and 119.9).
  - Subsequently, the sphenoid process of the palatine bone is also removed to expose the palatovaginal canal.
  - The palatovaginal artery (i.e., pharyngeal artery) is identified and sacrificed to allow the lateralization of PPF soft tissue contents and expose the Vidian canal.
- The periosteum of the anterior aspect of the pterygoid plates may be dissected leaving the contents of the PPF enclosed in a periosteal sac formed by the periosteum of the posterior maxilla and that of the pterygoid plates.[8]

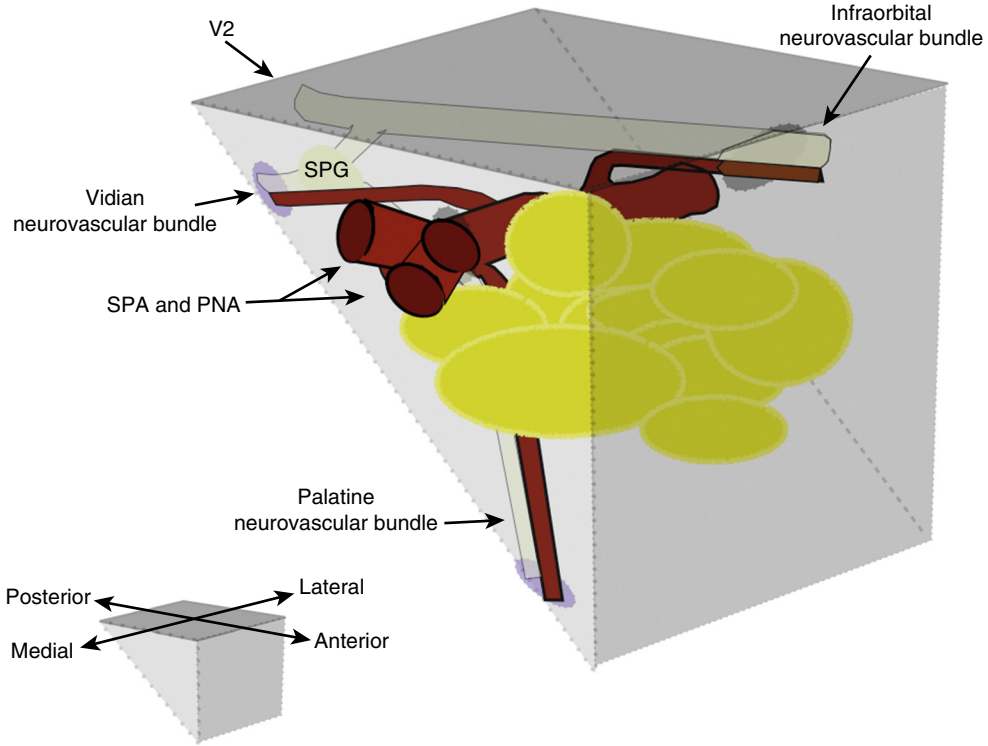

Fig. 119.5. Simplified schematic representation of the inverted pyramidal shape of the pterygopalatine fossa *(left).* A vascular compartment is anterior to the neural compartment, both surrounded by adipose tissue and a vascular plexus. *PNA,* posterior nasal artery; *SPA,* sphenopalatine artery; *SPG,* sphenopalatine ganglion.

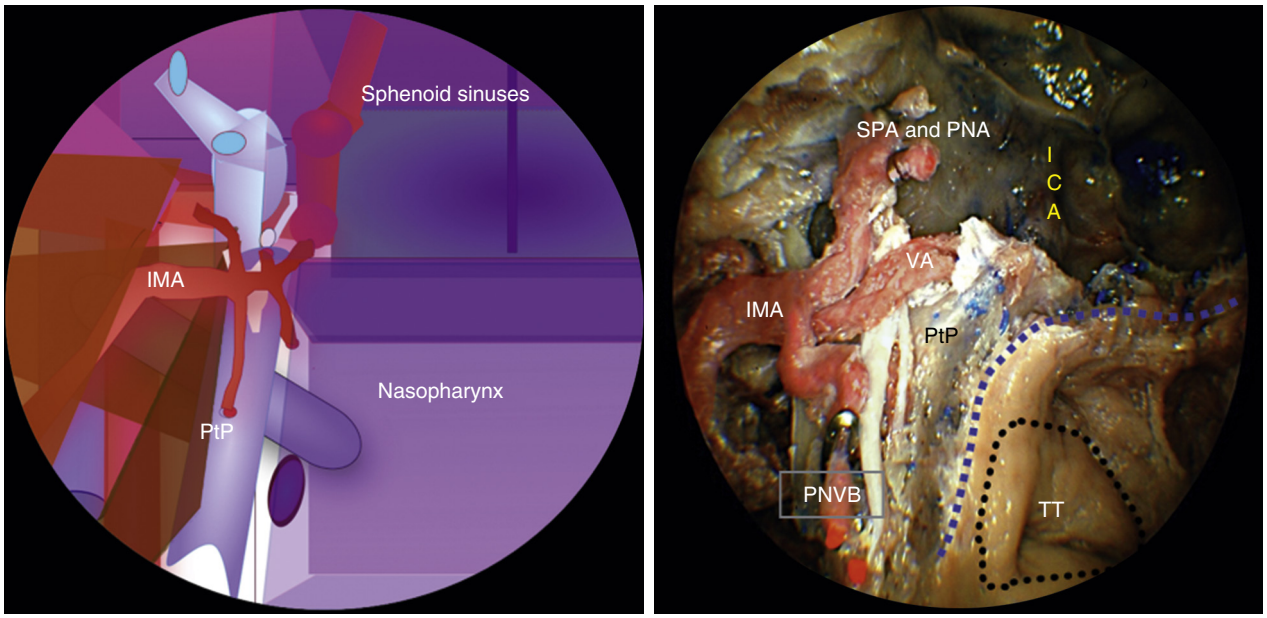

Fig. 119.6. Right pterygopalatine fossa with exposed vascular compartment (schematic representation *[left]*, and cadaveric dissection *[right]*). *ICA,* internal carotid artery; *IMA,* internal maxillary artery; *PNA,* posterior nasal artery; *PNVB,* palatine neurovascular bundle (includes the palatine artery anteriorly; greater and lesser palatine nerves posteriorly); *PtP,* pterygoid process; *SPA,* sphenopalatine artery; *SPG,* sphenopalatine ganglion; *TT,* torus tubarius; *VA,* vidian artery.

  - However, the vidian neurovascular bundle will tether the lateral mobilization of the fossa. Therefore, it must be cauterized and divided in most cases (see Fig. 119.9).
  - Preservation of the Vidian nerve is possible for select approaches to the infrapetrous ICA and Meckel's cave.
- Further lateral and superior dissection of the periosteum over the pterygoid process, exposes the base of the pterygoid process with the foramen rotundum and the maxillary branch of the trigeminal nerve (V2) (Fig. 5.10; see also Fig. 119.9).
- Exposure of the lateral aspect of the ITF in some patients requires extending the medial maxillectomy anteriorly (endoscopic Denker's or Sturman-Canfield approach to obtain an adequate line of sight laterally) (see Fig. 119.4).

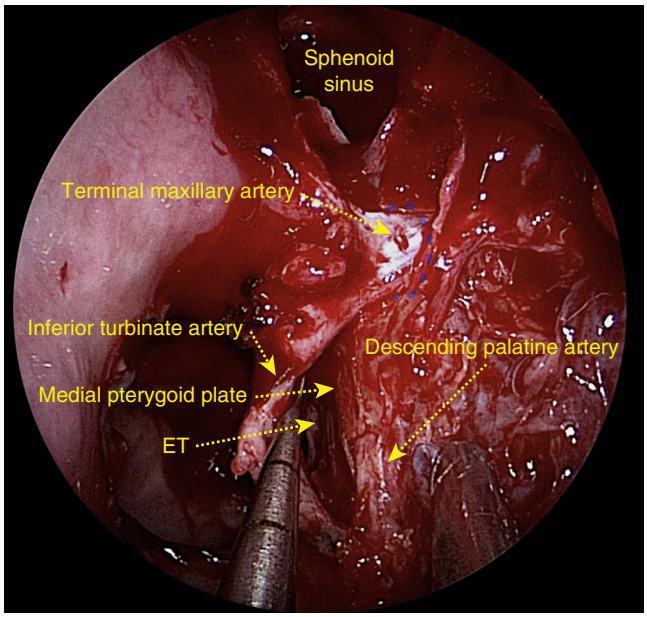

Fig. 119.7. Intraoperative photograph of the left pterygopalatine fossa. The elevator is reflecting the mucoperiosteum over the remaining ascending process of the palatine bone and medial pterygoid plate to expose the Eustachian tube (ET).

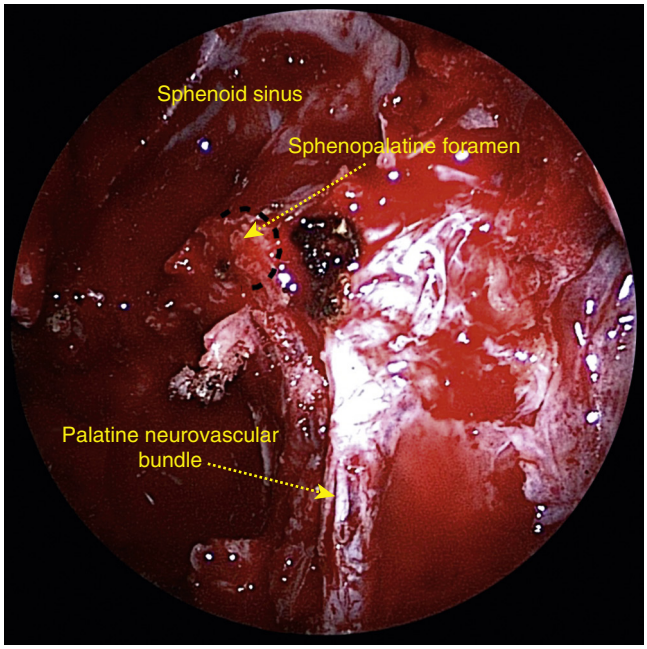

Fig. 119.8. Intraoperative photograph of the left pterygopalatine fossa demonstrating the palatine neurovascular bundle, which includes the palatine artery anteriorly, as well as the greater and lesser palatine nerves posteriorly.

- This includes removing the remaining inferior turbinate and anterior aspect of the inferior meatus with backbiting rongeurs, osteotomes, or drill.
- Exposure of the piriform aperture requires a vertical incision right on the edge of the aperture, which can be palpated just anterior to the head of the inferior turbinate.
- A full exposure requires removing the piriform aperture and ascending process of the maxilla, including the dissection and sharp transection of the lacrimal duct.

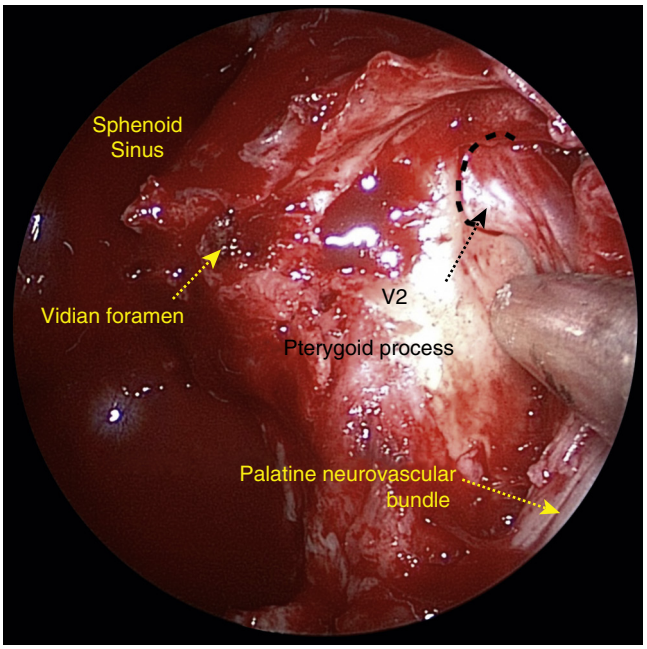

Fig. 119.9. Intraoperative photograph of the left pterygopalatine fossa demonstrating the lateral displacement of the palatine neurovascular bundle to expose the pterygoid process posteriorly. Notice the vidian and rotundum foramina (with V2).

  - According to the surgical exposure requirements and the anatomy of the individual patient, the removal may be confined to the area inferior to the nasolacrimal opening.
  - A subperiosteal dissection exposes the anterior maxilla, which is then removed to expose the entire lateral wall of the antrum.
  - This modification allows a straight line of sight that encompasses the lateral aspect of the ITF.
- During a Type B approach (lateral recess of the sphenoid sinus), the sphenoidotomy can be extended laterally, removing the anterior wall of the lateral recess (i.e., pneumatized base of the pterygoid process) above the level of the Vidian canal.
  - Occasionally, if the pneumatization of the pterygoid process extends to the greater wing of the sphenoid, the Vidian neurovascular bundle needs to be sacrificed to allow further lateral mobilization of the soft tissues of the PPF.
- During a Type C approach (petrous apex or Meckel's cave approaches), it is usually sufficient to remove the medial aspect of the pterygoid process base.
  - The floor of the sphenoid sinus floor is removed, using a high-speed drill with a 4 mm hybrid or rough diamond burr, until it is flush with the clival recess.
  - The medial pterygoid plate is drilled using a coarse diamond 3 mm burr, and the Vidian canal should be followed to identify and preserve the horizontal segment of the petrous ICA.
  - The Vidian canal is dissected, drilling circumferentially around the Vidian canal to reach the foramen lacerum.
  - A lateral transposition of the vidian nerve may expose the base of the pterygoid process while preserving the neurovascular bundle.
    - To preserve the integrity of the Vidian nerve, the Vidian canal is drilled until it is eggshell thin. A dissector can be used to out fracture the thin residual bone while preserving the periosteum of the canal, as it protects the nerve during its manipulation.

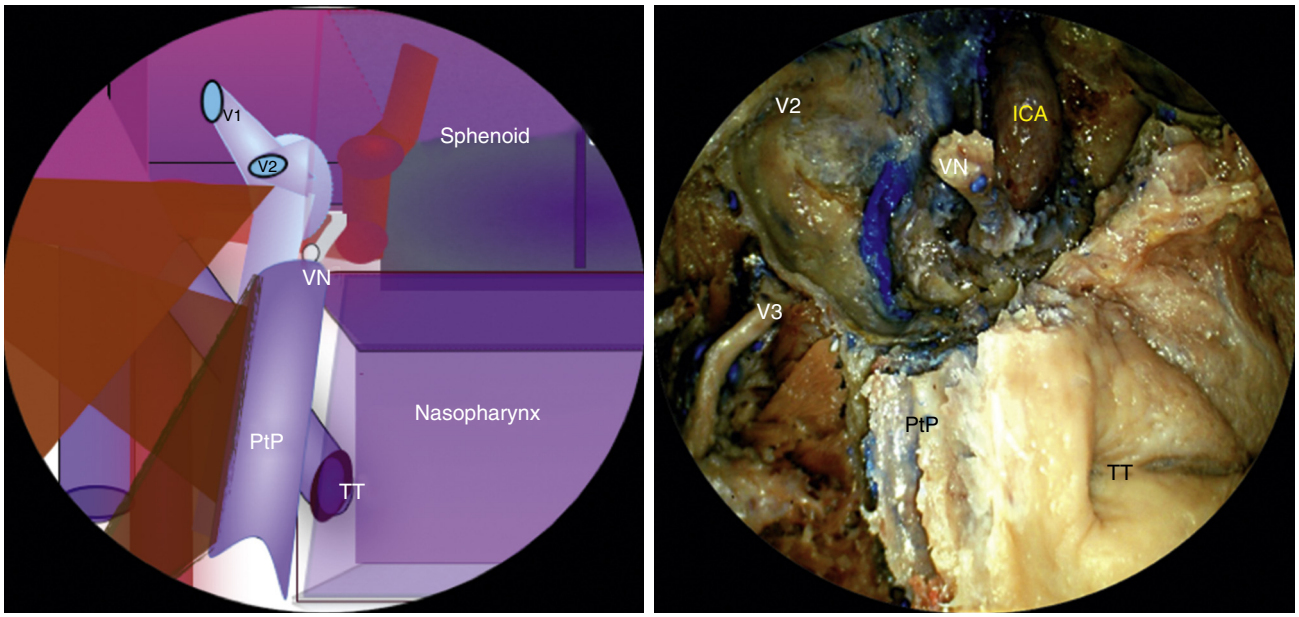

Fig. 119.10. Right pterygoid process after displacement of the soft tissues of the pterygopalatine fossa (schematic representation *left*, and cadaveric dissection *right*). *ICA,* internal carotid artery; *PtP,* pterygoid process; *TT,* torus tubarius; *VN,* vidian nerve; *V2,* maxillary nerve; *V3,* mandibular nerve.

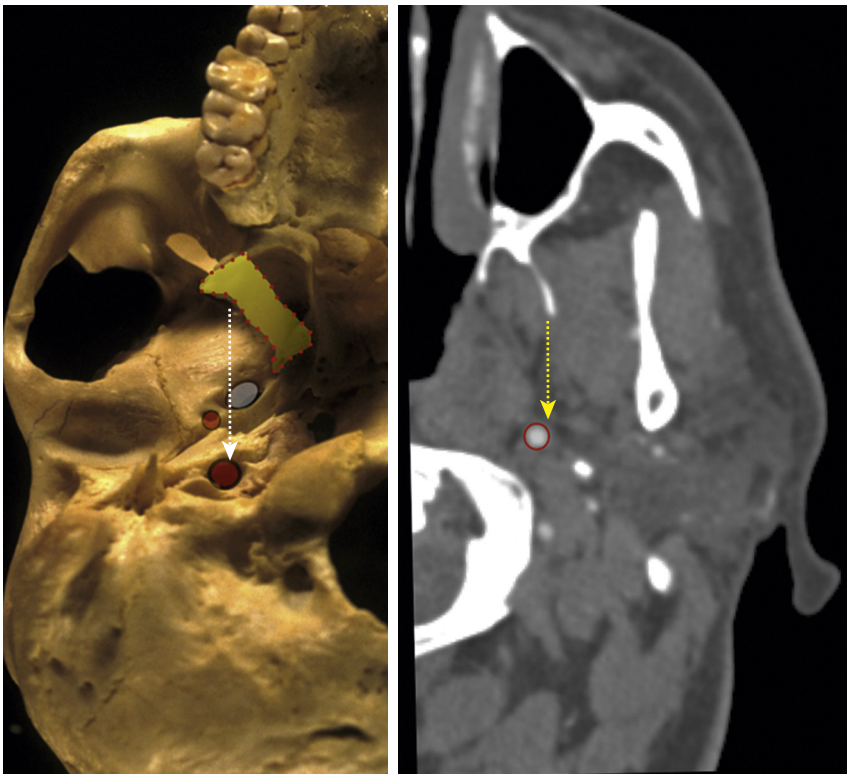

Fig. 119.11. Basal view of the skull base (left photograph) demonstrating the alignment (sagittal plane) of the lateral pterygoid plate, the foramen ovale (i.e., V3) and the carotid canal (i.e., internal carotid artery [ICA]). These structures mark specific depths and safety checkpoints during an endoscopic transpterygoid approach. The lateral pterygoid plate may serve as a proxy landmark to establish the position of the parapharyngeal ICA. However, this needs to be confirmed with imaging *(right photograph)*, as the parapharyngeal ICA can be very tortuous.

- During a Type D EETPA to the ITF, the internal maxillary artery should be divided at the level of the pterygomaxillary fissure. The Vidian neurovascular bundle and the branch of the sphenopalatine ganglion to V_2 are divided.
  - This allows the inferior and lateral displacement of the soft tissues of the PPF, and therefore exposes the entire height of the pterygoid process (see Figs. 119.9 and 119.10).
- Surgical landmarks that are important to approach the ITF include V3 and foramen ovale (identified just posterior to the base of the LPP), and the tensor veli palatini muscle (at the interpterygoid fossa and just anterior to the ET). The petrous ICA is posterior to the foramen ovale (V3) and the ET (Fig. 119.11).[3-7]
- In select cases, one may continue drilling further laterally into the LPP until it is in plane with the middle cranial fossa and foramen ovale. This transpterygoid corridor can be extended or curtailed according to the needs of the surgery.

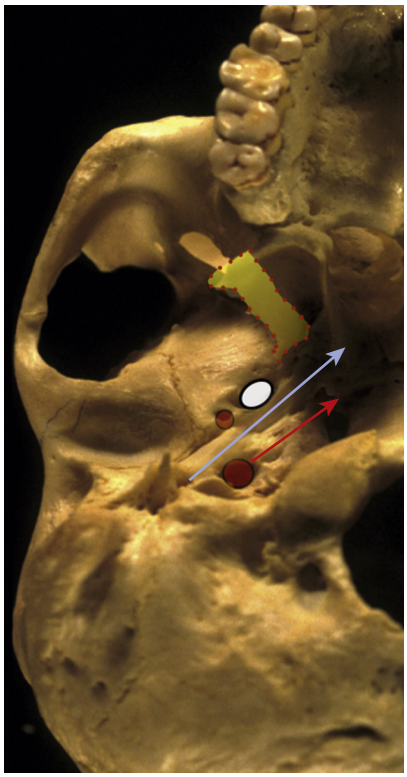

Fig. 119.12. Basal view of the skull base demonstrating the alignment of the Eustachian tube *(gray arrow)* and the petrous portion of the internal carotid artery *(red arrow)*. *Yellow shaded area*, lateral pterygoid plate; *white circle*, foramen ovale.

- Extensive lesions of the ITF, with or without involvement of the middle cranial base, may require the removal of the entire pterygoid process (Type E EETPA).
- Access to the ITF requires cauterization, clipping, or division of the internal maxillary artery as it enters the pterygomaxillary fissure, detachment of the lateral and medial pterygoid muscles, and removal of the LPP.
  - It is important to follow a subperiosteal plane to avoid bleeding from the pterygoid plexus (Figs. 119.12–119.14).
- Removal of the ET in a lateral and superior direction, including its bony canal, directs the surgeon to the carotid canal, which is just posterior.

Common Errors in Technique

1. Inadequate exposure
2. Confusing the superior orbital fissure with the foramen rotundum
3. Inadequate instrumentation

POSTOPERATIVE PERIOD

Postoperative Management

- EEAs are associated with a shorter inpatient hospital stay and a lower incidence of surgical complications. However, close monitoring during the perioperative period is essential for the early identification of complications regardless of the approach.
  - Most patients spend the first 24 hours in the intensive care or step-down care unit.
  - Immediate mobilization and administration of chemoprophylaxis for deep venous thrombosis, unless there is an absolute contraindication.

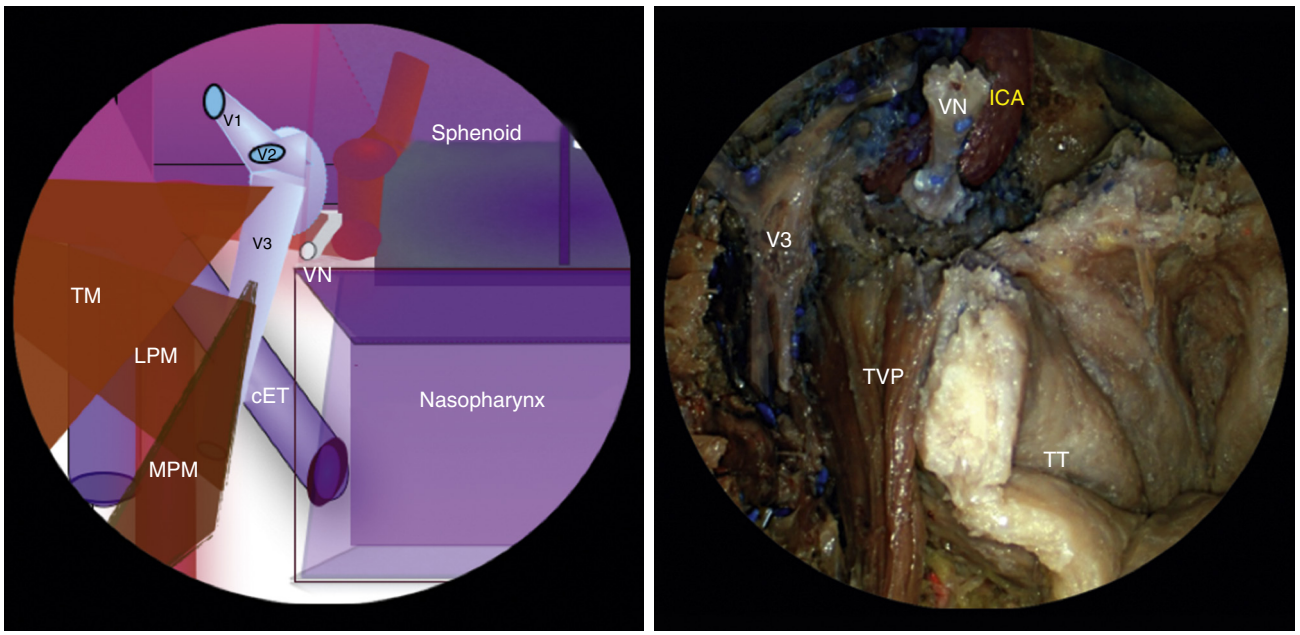

Fig. 119.13. Middle cranial fossa with exposed vascular compartment (schematic representation *left*, and cadaveric dissection *right*). The right pterygoid process has been removed exposing the tensor veli palatine muscle (TVP) just anterior to the Eustachian tube. *cET,* cartilaginous Eustachian tube; *ICA*, internal carotid artery; *LPM,* lateral pterygoid muscle; *MPM,* medial pterygoid muscle; *TM*, temporalis muscle; *TT,* torus tubarius; *VN,* Vidian nerve; *V1,* ophthalmic nerve; *V2,* maxillary nerve; *V3,* mandibular nerve.

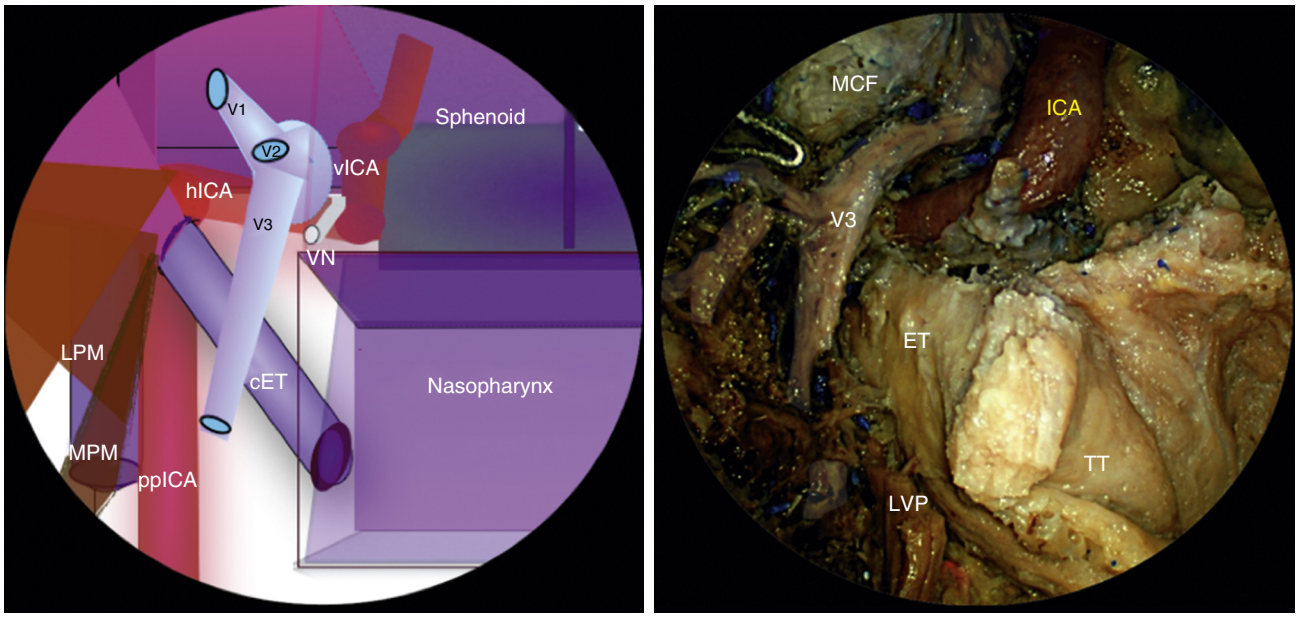

Fig. 119.14. This dissection is subsequent to Fig. 119.13. The tensor veli palatine muscle has been removed exposing the Eustachian tube and V3 in an alignment that follows that described in Fig. 119.11. (schematic representation *left* and cadaveric dissection *right*). *cET,* cartilaginous Eustachian tube; *hICA,* horizontal internal carotid artery (petrous); *LPM,* lateral pterygoid muscle; *MPM,* medial pterygoid muscle; *ppICA,* parapharyngeal internal carotid artery; *TM,* temporalis muscle; *TT,* torus tubarius; *VN,* vidian nerve; *vICA,* vertical internal carotid artery (paraclival).

- Neurologic evaluation is required for patients with CSF loss, neurovascular manipulation, and electrolyte and acid-base disturbances.
- Maintaining the systolic blood pressure below 160 mm Hg (an arterial line is used as needed)
- Correcting endocrinopathies
  - For example, diabetes insipidus requires the monitoring of hourly fluid intake and output, serum sodium and osmolality, and urine-specific gravity at least every 6 hours.
- Patients with sleep apnea, requiring continuous positive airway pressure (CPAP) therapy at home, will only be able to have supplementary oxygen by facemask following a transdural surgery; therefore, cardiac monitoring and pulse oximetry is highly recommended in these patients.

- An immediate noncontrasted CT of the head allows early identification of intracranial complications. Although rare, tension pneumocephalus and acute intracranial hemorrhage can occur.
- Following oncologic resections, we also order an MRI of the brain, with and without contrast, within 24 hours after surgery to assess the degree of tumor resection.
  - As a secondary gain, one can ascertain the position and viability of the reconstructive flap.
- The rate of infection and CSF leak following EEA is less than 2% and 6%, respectively.[9-10]
  - To minimize these complications, patients are instructed to avoid any activities that increase intra-abdominal, intrathoracic, or intracranial pressure, thus avoiding bending, heavy lifting, straining, and squatting. Also, stool softeners should be taken to avoid increased intra-abdominal pressure associated with constipation and straining to defecate. In addition, we ask our patients to cough and sneeze with an open mouth.
  - Despite its relatively low incidence, patients are closely monitored for the presence of a postoperative CSF leak, which can be associated with significant morbidity, such as pneumocephalus and meningitis.
    - Clear nasal drainage, or a sensation of salty fluid in the throat, should prompt an immediate investigation.
    - The reservoir sign, where the patient tilts his or her chin toward the chest for at least 1 minute to observe for drainage of CSF, is a screening test that should be performed at least daily.
      - If "suspicious," a CT of the head should be obtained to assess the degree of pneumocephalus. Increased intradural air, compared with the immediate postoperative scan, strongly suggests the presence of a CSF fistula and calls for immediate intervention.
    - Testing for β-2 transferrin or beta trace may help to confirm the presence of a CSF leak but is not very practical, as the test for β-2 transferrin is time-consuming and not available at all sites, and beta trace protein assay is not available in the United States.
  - Therefore, patients in whom a postoperative CSF leak is strongly suspected should be explored and repaired immediately.
- In addition to the administration of intravenous prophylactic antibiotics, such as a third-generation cephalosporin for 24 to 48 hours postoperatively, our practice is to continue wide spectrum oral antibiotics while nasal packing is in place.
- Patients who require dissection of the ITF frequently present with postoperative trismus or masticatory dysfunction. Early rehabilitation should be provided with active stretching exercises and devices.
- Barring complications, patients remain in the hospital for two to three nights prior to discharge.
- Normal saline solution sprays are initiated immediately after the surgery and nasal lavages with normal saline solution are started 3 to 5 days later.
- Nasal cavity débridements are performed every 1 to 4 weeks, as needed.

Complications

- Intraoperative bleeding from internal maxillary artery or pterygoid venous plexus.
- Significant bleeding is commonly encountered. It is most effectively controlled with bipolar electrocautery.
- Reduced lacrimation from the sacrifice of the sphenopalatine ganglion or the vidian nerve.
- Reduction of lacrimation is usually asymptomatic and requires no further attention. However, patients presenting with prior xerophthalmia and those with V1 or V2 cranial neuropathies may develop corneal ulceration requiring aggressive treatment.
- Facial hypoesthesia from V2, V3 injury.
- These deficits are usually temporary but can be permanent, and approximately 15% of patients develop deafferentation pain. The latter requires treatment with anti-seizure medications such as gabapentin or carbamazepine.
- During an approach to the petrous apex, Meckel's cave or nasopharynx, the ICA may be injured resulting in catastrophic and potentially fatal bleeding.
- Immediate control is best achieved with the application of a crushed muscle patch followed by endovascular stenting or occlusion.
- Postoperative CSF leak. The incidence of a CSF leak has significantly diminished since the adoption of pedicle flaps for the reconstruction. A postoperative CSF leak is best managed by immediate exploration and repair.
- CN V1 palsy. CN V1 is sensitive to manipulation. A permanent deficit requires management with prism lenses or strabismus surgery.

Alternative Management Plan

There are multiple open approaches to the middle cranial fossa and the nasopharynx. For example, the medial aspect of the middle cranial fossa may be accessed by temporal, frontotemporal, or temporal-subtemporal approaches. More recently described by Moe's study group, the transorbital approach seems to be a significant addition to the skull base armamentarium. Similarly, the ITF and nasopharynx may be approached from lateral (e.g., preauricular-subtemporal, postauricular-transtemporal) or anterior (e.g., LeForte I, facial translocation, maxillary swing) aspects. In addition, a multicorridor surgery combining an endonasal endoscopic approach with any of the aforementioned approaches or with lesser approaches, such as a transoral or transmaxillary approach to the ITF may yield an adequate resection while decreasing morbidity.

DISCUSSION

Evidence-Based Medicine Question

Is a transpterygoid endoscopic approach equivalent to a traditional open approach?

Selecting a surgical approach is based on multiple factors that include the origin and histopathology of the tumor; the regional extent and invasiveness; the association with CN and ICA; the idiosyncratic patient needs; and the surgeon's training and bias. Taking these elements into account, it is difficult to compare adequacy of one approach over the other, even for similar lesions. However, Youssef and colleagues compared the exposure of the preauricular and transterygoid approaches to the ITF. The authors concluded that the endonasal endoscopic transpterygoid approach provides superior visualization and a more direct exposure of median structures, such as the nasopharynx, ET, sella, and clivus. Patients with benign lesions and some with select malignancies seem to be ideal candidates for the endonasal endoscopic transpterygoid approach. However, open approaches continue to play an important role, especially in patients with extensive malignant tumors. Similarly, Fahmy et al. and Kapucu et al. compared open and EEAs to the ITF and nasopharynx, respectively. Invariably, the EEA provided similar volumetric exposure compared to the open approaches with less sacrifice of normal anatomy, suggesting the potential for less morbidity; however, the entry gate for instrumentation was limited and restricted the ease of motion. Shidoh and colleagues compared their results after the removal of clival chordomas via transoral-transpalatal (TO-TPA) and EEAs, concluding that the removal was more radical and less invasive in the EEA group than the TO-TPA group. However, tumors extending below the craniovertebral junction required using the transoral or combined approach.

Anatomically, the endoscopic approaches seem equivalent to the open traditional approaches for the median skull base. However, they require different instrumentation, skills, and institutional resources.

Editorial Comment

The transpterygoid approach is the surgical corridor to EEAs that involve the middle and inferior coronal planes. It is essential for surgical modules that involve the petrous segment of the ICA. As the authors demonstrated, the transpterygoid approach provides access to multiple areas, including the lateral recess of the sphenoid sinus; Meckel's cave, lateral cavernous sinus and middle cranial fossa; and the infrapetrous and infratemporal skull base. The classification of the transpterygoid approach into five types provides a useful construct for a graded approach to skull base tumors.

Carl H. Snyderman

Access the review questions and additional sources list online at http://www.expertconsult.com



REFERENCES

1. Bolger WE. Endoscopic transpterygoid approach to the lateral sphenoid recess: surgical approach and clinical experience. Otolaryngol Head Neck Surg 2005;133(1):20–26.
2. Kassam AB, Gardner P, Snyderman C, et al. Expanded endonasal approach: fully endoscopic, completely transnasal approach to the middle third of the clivus, petrous bone, middle cranial fossa, and infratemporal fossa. Neurosurg Focus 2005;19(1):E6.
3. Al-Sheibani S, Zanation AM, Carrau RL, et al. Endoscopic endonasal transpterygoid nasopharyngectomy. Laryngoscope 2011;121(10):2081–2089.
4. Kasemsiri P, Solares CA, Carrau RL, et al. Endoscopic endonasal transpterygoid approaches: anatomical landmarks for planning the surgical corridor. Laryngoscope 2013;123(4):811–815.
5. Van Rompaey J, Suruliraj A, Carrau R, et al. Meckel's cave access: anatomic study comparing the endoscopic transantral and endonasal approaches. Eur Arch Otorhinolaryngol 2014;271(4):787–794.
6. Theodosopoulos PV, Guthikonda B, Brescia A, et al. Endoscopic approach to the infratemporal fossa: anatomic study. Neurosurgery 2010; 66(1):196–202. discussion 203.
7. Youssef A, Carrau RL, Tantawy A, et al. Clinical correlates of the anatomical relationships of the foramen ovale: a radioanatomical study. J Neurol Surg B Skull Base 2014;75(6):427–434.
8. Raza SM, Amine MA, Anand V, et al. Endoscopic endonasal resection of trigeminal schwannomas. Neurosurg Clin N Am 2015; 26(3):439–473.
9. Kassam AB, Prevedello DM, Carrau RL, et al. Endoscopic endonasal skull base surgery: analysis of complications in the authors' initial 800 patients. J Neurosurg 2011;114(6):1194–1568.
10. Kassam AB, Thomas A, Carrau RL, et al. Endoscopic reconstruction of the cranial base using a pedicled nasoseptal flap. Neurosurgery 2008;63(1 Suppl. 1):ONS44–52.

REVIEW QUESTIONS

1. Transpterygoid approaches provide access to:
   a. Meckel's cave
   b. Nasopharynx
   c. Lateral recess of the sphenoid sinus
   d. a and c
   e All of the above

2. Identify the false statement regarding the anatomy of the pterygoid process:
   a. The pterygoid process is part of the temporal bone
   b. The pterygoid process contains the Vidian canal
   c. The pterygoid process contains the foramen rotundum
   d. The pterygoid process has two plates with a common base
   e. The pterygoid process is posterior to the terminal branches of the internal maxillary artery

3. The best imaging for lesions in the ITF is provided by:
   a. CT scan
   b. Water's view radiograph
   c. Scintigraphy
   d. MRI
   e. a and d

4. The following structures are contained in the PPF except for:
   a. Terminal branches of the internal maxillary artery
   b. Sphenopalatine ganglion
   c. Vidian nerve
   d. Greater and lesser palatine nerves
   e. V3

5. To locate the position of the ICA, one must consider the position of:
   a. V3
   b. LPP
   c. ET
   d. Foramen lacerum
   e. All of the above

ADDITIONAL SOURCES

Bly RA, Ramakrishna R, Ferreira M, et al. Lateral transorbital neuroendoscopic approach to the lateral cavernous sinus. J Neurol Surg B Skull Base 2014;75(1):11–17.

Fahmy CE, Carrau R, Kirsch C, et al. Volumetric analysis of endoscopic and traditional surgical approaches to the infratemporal fossa. Laryngoscope 2014;124(5):1090–1096.

Kapucu B, Gun R, Kirsch C, et al. Volumetric analysis of nasopharyngectomy via endoscopic endonasal maxillary transposition, and lateral temporal-subtemporal approaches. J Craniofac Surg 2015; 26(7):2136–2141.

Shidoh S, Toda M, Kawase T, et al. Transoral vs. endoscopic endonasal approach for clival/upper cervical chordoma. Neurol Med Chir (Tokyo) 2014;54(12):991–998.

Youssef A, Carrau RL, Tantawy A, et al. Endoscopic versus open approach to the infratemporal fossa: a cadaver study. J Neurol Surg B Skull Base 2015;76(5):358–364.

120 Endoscopic Petrosal Approaches

Camilo Reyes, David Jang, Arturo Solares

INTRODUCTION

The petrous portion of the temporal bone is a pyramid-shaped bone wedged between the greater wing of the sphenoid and the occipital bone. Its base is composed of the bony labyrinth (semicircular canals and cochlea); its anterosuperior surface makes up a large portion of the floor of the middle cranial fossa; its posterosuperior surface forms the anterolateral wall of the posterior cranial fossa; and its apex is joined to the clivus. The carotid canal, containing the petrous portion of the internal carotid artery (ICA), traverses the petrous pyramid anterior to the petrous apex. The internal auditory canal divides the petrous bone into anterior and posterior compartments (Fig. 120.1).

Most petrosal lesions are located in the petrous apex anterior and medial to the internal auditory canal. Moreover, lesions in the petrous apex often bulge medially into the sphenoid sinus and, therefore, are potentially amenable for an extended endonasal approach (EEA), as opposed to an external approach. The EEA can offer preservation of anatomic structures, less morbidity, improved cosmetics, and utmost control of the surgical target. Technological innovations, such as extended-length micro instruments, high-definition angled endoscopes, powered instruments, and image guidance systems, among others, allow for an EEA to the petrous apex.

Lesions of the petrous apex can be cystic or solid. The most common benign lesions of the petrous apex are cholesterol granulomas, followed by mucoceles and cholesteatomas, while chondrosarcoma and chordoma are the most common primary malignant tumors (Table 120.1). Because of its close proximity to the clivus, the sella, and the sinonasal cavity, lesions in these adjacent areas may involve the petrous apex secondarily. The petrous apex may also be a site of metastasis from distant sites.

KEY OPERATIVE LEARNING POINTS

- The petrous apex is deep to the paraclival segment of the ICA.
- The Vidian nerve is a key anatomic landmark to identify the second genu of the ICA.
- The abducens nerve is susceptible to injury in Dorello's canal during drilling or tumor removal deep to the paraclival ICA.
- The superior border of the petrous apex is the floor of the middle cranial fossa.

PREOPERATIVE PERIOD

Preoperative evaluation of patients with petroclival lesions includes an extensive history and physical examination.

History

Many lesions of the petrous apex are small benign lesions that may remain asymptomatic for years and are often incidentally diagnosed on imaging done for other reasons. Therefore, symptoms can be vague, but larger lesions may cause the following symptoms:

1. Diplopia: most commonly due to lateral rectus palsy as a result of compression of cranial CN VI at the level of Dorello's canal
2. Headache: often retro-orbital
3. Hearing loss, imbalance
4. Facial pain or numbness: involvement of trigeminal ganglion in Meckel's cave
5. Lower cranial nerve neuropathies: dysphagia, dysarthria
6. Gradenigo's syndrome (otorrhea, diplopia due to ipsilateral lateral rectus palsy and retro-orbital headache)
7. Meningitis
8. Syncope, stroke, and amaurosis fugax: secondary to occlusion of the carotid artery
9. Unilateral nasal symptoms, such as persistent nasal obstruction, epistaxis, and/or rhinorrhea must raise the suspicion of a mass in the nasal cavity.

Physical Examination and Other Tests

1. Cranial nerve examination: While CN VI is affected most commonly (leading to lateral gaze palsy), any of the cranial nerves may be affected depending on the extent of the lesion.
2. The neck should always be examined to rule out metastases to the cervical lymph nodes in cases of malignancy.
3. Rigid or flexible laryngoscopy when lower cranial nerve compromise is suspected
4. An Ophthalmologist should evaluate any patient with visual symptoms to detect more subtle findings.
5. Nasal endoscopy: This is usually normal; however, it is important to assess for the presence of the following:
   a. Septal deviations, concha bullosa, and other anatomic variations that can hinder access
   b. Scarring or crusting from prior surgery and/or radiation
   c. Active sinusitis that can increase the risk of meningitis
   d. Viability of a nasoseptal flap: Prior surgery or septal perforation may obviate the use of the flap. In such cases, other reconstructive techniques need to be considered.
6. Examination of the ears and audiogram: Because of their close proximity to the middle ear, Eustachian tube, and hearing/vestibular apparatus, petroclival lesions can produce abnormalities in hearing and balance.

Imaging

1. Computed tomography (CT)
   a. Delivers information regarding bone erosion/remodeling, osteitis, and sinusitis
   b. High resolution CT (1 mm) with stealth protocol for image guidance
   c. CT angiography should be used to highlight the course of the ICA for image guidance navigation if CT/magnet resonance imaging (MRI) fusion is not being used.

   d. Contrast is typically not necessary if concurrent MRI with contrast will be performed.
2. Videofluoroscopy
   If dysphagia is present preoperatively, videofluoroscopic evaluation of swallowing function should be performed.
3. MRI with gadolinium
   a. Best delineates tumor size, extent, and the intrinsic characteristics of the tumor
   b. CT and MRI are used in complementary fashion.
4. Vascular and interventional radiology
   a. Angiography, angio-MRI, or angio-CT has a cardinal role in outlining vascular anatomy and ruling out aneurysm, thrombosis, or compromise to adjacent arteries or veins.
   b. Although not common for petrous apex pathology, preoperative embolization of specific pathology can decrease intraoperative bleeding.
5. Balloon test occlusion (BTO)
   A BTO can be done if the scans are suspicious for carotid invasion. Following a standard angiogram, a temporary balloon is placed in the ICA to be tested. A neurologist evaluates the patient for the next 20–25 minutes. Some centers, in the effort to enhance the prognostic validity of a BTO with clinical surveillance, use additional evaluations, such as hypotensive challenge to mimic physical activity, stump pressure measurements, electroencephalography and evoked potentials, cerebral oximetry by using near-infrared spectroscopy, blood velocity measurements applying transcranial Doppler ultrasonography (TCD), evaluation of cerebral blood flow with xenon-enhanced CT, positron-emission tomography (PET), xenon-enhanced CT, and/or MR perfusion imaging. While a normal BTO reduces the morbidity and mortality associated with permanent ICA occlusion, unfortunately, it does not eliminate it. With BTO there is a risk of 0.4%–1.2% transitory and permanent complications, respectively. The incidence of stroke after permanent ICA occlusion is between 17% and 30%.
6. PET is often necessary for staging malignant lesions that are prone to regional and distant metastasis.

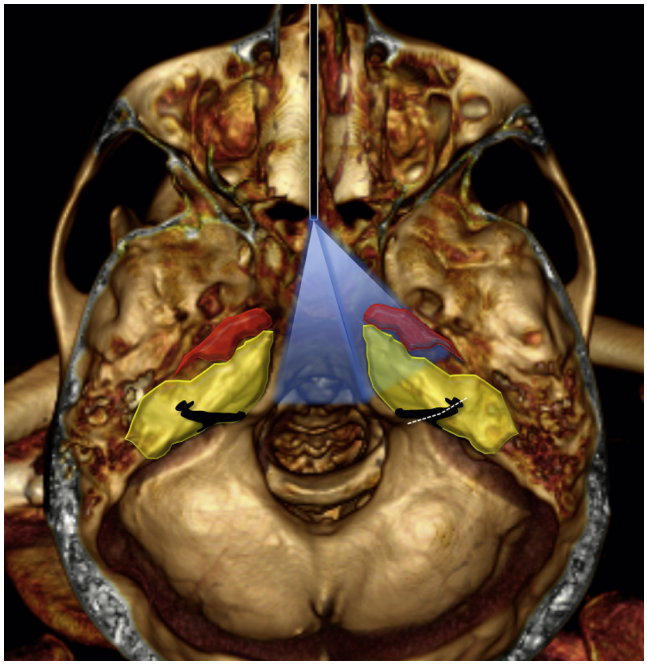

Fig. 120.1. Axial 3D reconstruction of the skull base viewed from above. Marked in yellow is the petrous portion of the temporal bone; the internal carotid artery (ICA) is anterior to it, in red. The image shows an endoscopic approach and the anterior relationship of the ICA to the petrous apex. A line through the modiolus of the cochlea and the internal auditory canal *(dashed white line)* divides the petrous bone into an anterior and posterior compartment. Most lesions are located anterior to this line because about 10%–30% of patients have anterior compartment pneumatization; in contrast, the posterior petrous bone (osseous labyrinth) rarely pneumatizes.

Indications

1. It is fundamental to adapt the surgical approach to the patient and not the other way around. Individual risks and benefits based on symptoms, extent of disease, and natural history of the disease must be considered. Small lesions in asymptomatic patients can be followed up every 6 months with serial imaging.
2. A multidisciplinary team with an experienced Otolaryngologist and Neurosurgeon is necessary.
3. The EEA is ideal when lesions are located medial to and below important neurovascular structures, namely the ICA (Figs. 120.2 and 120.3).
4. Compared to lateral approaches, the advantages of EEA are better access to deeply seated lesions, better exposure of the midline, preservation of hearing, and no manipulation of the facial nerve.
5. Lesions with lateral extension and those with involvement of critical neurovascular structures should be analyzed for an open or combined approach. Lateralization of the ICA is an option, but it should be reserved only for experienced skull base surgeons.
6. Stereotactic radiosurgery (SRS) or image-guided intensity modulated radiotherapy are options for patients who are poor surgical candidates or are at high risk for a vascular complication.

TABLE 120.1 Imaging Characteristics of Petrous Apex Pathology

Pathology	MRI (T1)	MRI (T2)	Contrast
Cholesterol granuloma*	Hyperintense	Hyperintense	None
Cholesteatoma	Iso or hypointense	Hyperintense	None
Petrous apicitis	Iso or hypointense	Hyperintense	Peripheral enhancement
Chordoma	Iso or hypointense	Hyperintense	Heterogeneous
Chondrosarcoma†	Iso or hypointense	Hyperintense	Heterogeneous
Meningioma	Iso or hypointense	Hypointense	Strong
Schwannoma	Iso or hypointense	Hypointense	Strong
Nasopharyngeal carcinoma	Isointense	Isointense to hyperintense	Heterogeneous

*Most common cystic lesion.
†Most common solid lesion.
MRI, Magnetic resonance imaging.

Contraindications

1. If the tumor is encasing vital vascular structures (i.e., ICA or perforating vessels), nonsurgical therapy (i.e., SRS) or an open approach, which allows for better vascular control, should be considered, especially if the tumor is of a hard consistency.

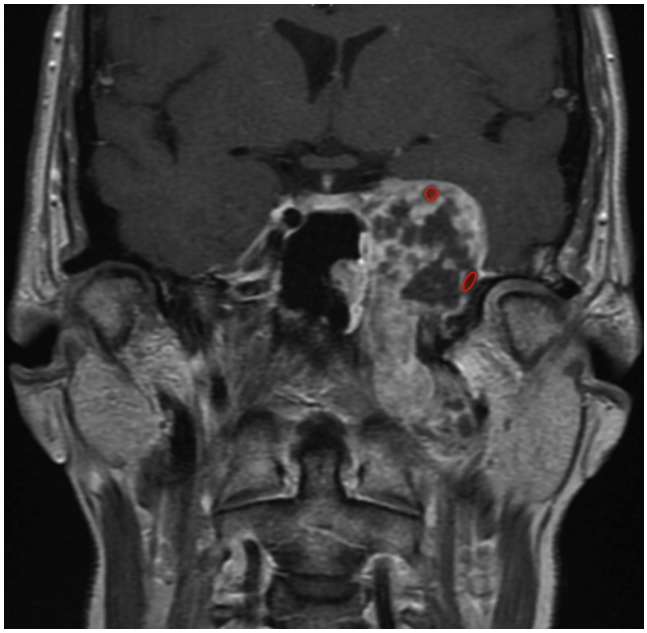

Fig. 120.2. Magnetic resonance imaging of a left petroclival chondrosarcoma. Note how the lesion eroded the bone over the carotid and displaced from its location the paraclival and petrous segments of the internal carotid artery superiorly and laterally *(red circles)*, making an endonasal endoscopic approach ideal for this type of case.

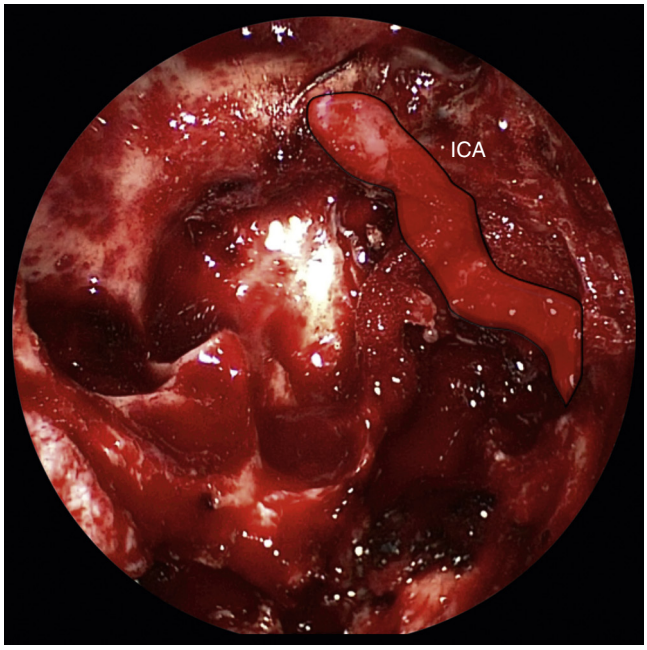

Fig. 120.3. Endoscopic view post-resection of a left petroclival chondrosarcoma. Surgical cavity with left internal carotid artery (ICA) outlined in red. Note how the lesion displaced the paraclival and petrous segments of the ICA superiorly and laterally.

2. In cases where neurovascular shunting is necessary, an open or combined endoscopic-assisted approach is favored.
3. A lateral component of the lesion may be better accessed through a lateral approach.

Preoperative Preparation

1. Patients should be informed about the risks associated with tumor excision, including vascular and neural injury, as well as the possibility of skull base reconstruction and the need to convert to an open procedure.
2. Concomitant rhinosinusitis should be optimally treated before an EEA is done.
3. If there is risk of vascular injury, a neurointerventionalist must be available.
4. Preoperative angiography with BTO should be considered for cases with high risk of ICA injury.
5. Antiplatelet therapy and anticoagulants should be discontinued prior to surgery at the discretion of the patient's medical team. Low-molecular-weight heparin can be used as a bridge if indicated. Dietary supplements such as vitamin E, fish oil, Echinacea, aloe, and garlic extract also can be a source of bleeding disorders, and their use should be discontinued.

OPERATIVE PERIOD

Anesthesia

The knowledgeable anesthesiologist provides optimum conditions that will minimize bleeding yet maintain hemodynamic stability of the patient.

1. Controlled hypotension
   a. Mean arterial pressure of 65–70 mm Hg
   b. Caution must be used for intradural lesions. Adequate blood pressure is needed to maintain perfusion through the circle of Willis and the collateral circulation.
2. Ventilation
   a. Hypercapnia produces vasodilatation, while normocapnia or mild hypocapnia minimizes bleeding and optimizes the surgical field during endoscopic endonasal surgery.[1]
3. Pain, nausea, emesis, and Valsalva during emergence can cause bleeding or cerebrospinal fluid (CSF) leak.

Positioning

1. Meticulous care with positioning is important to avoid pressure ulcers or traction on the brachial plexus with head positioning.
2. A reverse Trendelenburg position improves hemostasis of the surgical field when compared to the supine position.[2]
3. If a Mayfield skull clamp system is used, it should be positioned at the level or above the temporal line.
4. For the right-handed surgeon standing on the patient's right side, the patient's head should be slightly flexed, turned to the right, and tilted to the left. This allows the surgeon to operate comfortably in an ergonomic position.

Perioperative Antibiotic Prophylaxis

The risk of meningitis following EEA surgery can be as low as 1.8%, especially if there is no CSF leak.[3] Nonetheless, cefazolin 1–2 g IV is routinely given in the perioperative period. This can be re-dosed every 8 hours. For patients who are allergic to penicillin, clindamycin and vancomycin are reasonable alternatives. For patients with a history of chronic bacterial rhinosinusitis, prior culture results should guide perioperative antibiotic use.

Monitoring

1. Blood loss must be accurately monitored, as underestimating blood loss may result in poor fluid resuscitation with subsequent shock and organ damage.
2. Neurophysiologic monitoring (somatosensory evoked potentials): early detection of ischemia/hypoxia before irreversible damage occurs. This may also indicate the need for operative intervention (i.e., carotid shunt).
3. Electrophysiologic monitoring of cranial nerves, especially the abducens nerve

Instruments and Equipment to Have Available

1. Advanced endoscopic sinus surgery and endonasal microsurgery instrument set
2. Two flat panel monitors for a four-hand technique
3. Microdébrider with 4 mm blade
4. Radiofrequency ablation (i.e., Coblator with tonsillectomy tip) allows for hemostasis with minimal thermal injury.
5. High-speed extended length drill. An ultrasonic bone aspirator is also an option, but cost may be prohibitive.
6. Monopolar suction electrocautery
7. Extended length needle-tip Bovie for dissection of the nasoseptal flap
8. Image guidance system: optical or electromagnetic image guidance system with stealth merge capability
9. Intraoperative Doppler probe: helpful for identifying the ICA[4]
10. Hemostatic material, such as Surgicel (Johnson & Johnson, New Brunswick, New Jersey), thrombin-soaked gelatin foam (Floseal Baxter International Inc., Deerfield, IL, USA)
11. Reconstructive materials:
    a. DuraGen (Integra Lifescience Corporation, Plainsboro, New Jersey) and Alloderm (Lifecell Corporation, Branchburg, New Jersey) can be used for dural reconstruction.
    b. Fibrin glue, such as DuraSeal (Confluent Surgical, Inc., Waltham, Massachusetts) is also commonly used.

Key Anatomic Landmarks

1. Sphenoid sinus
    a. Intersinus septum: may insert posteriorly on the ICA or optic nerve (ON)
    b. Bone covering the ICA or ON can be dehiscent.
    c. Ethmoid-sphenoidal cell (Onodi cell) must be identified on imaging and endoscopy to avoid injuries to the ON.
    d. Categories of sphenoid sinus pneumatization: sellar, presellar, conchal. A well-pneumatized sphenoid sinus (i.e., sellar) facilitates identification of important anatomic landmarks. However, conchal pneumatization makes this difficult. In such cases, dissection should proceed from a medial to a lateral direction, starting at the anterior margin of the floor of the sphenoidal sinus with identification of the Vidian canal and foramen rotundum laterally.
2. Pterygoid plates
    a. The pterygoid process is closely associated with three foramina that must be identified prior to the drilling of the pterygoid plates:
        1) Palatovaginal canal
        2) Vidian canal
        3) Foramen rotundum
    b. Drilling and resection of the base of the pterygoid plates allow access to the inferior aspect of the petrous bone.
3. Vidian artery—nerve
    a. Located at the junction of the sphenoid floor and the medial pterygoid plate
    b. It is deep to the sphenopalatine and palatovaginal/palatosphenoidal vessels.
    c. The Vidian nerve "protects" the ICA, as it runs along the floor of the sphenoid sinus.
    d. The ICA will be reached with drilling superior to the pterygoid canal, which contains the Vidian nerve. Drilling inferior to the canal exposes the lacerum synchondrosis.
4. ICA
    a. Review preoperative imaging, and rule out bony dehiscence of the ICA.
    b. The anterior genu of the ICA is located at the foramen lacerum, where the petrous segment of the ICA turns superiorly to form the paraclival segment.
    c. If an expanding lesion does not remodel the petrous apex medially, the anterior genu of the ICA guards access to the petrous apex.
    d. The horizontal petrous portion of the ICA is covered by thin bone.
    e. The petrous segment of the ICA is located approximately 4.3–4.8 mm anterior to the foramen ovale.[5]
    f. The most lateral limit of dissection is the horizontal petrous segment of the ICA, which cannot be retracted laterally.

Prerequisite Skills

1. Septoplasty
2. Functional endoscopic sinus surgery
3. Endonasal endoscopic approach to the pituitary using the four-handed technique
4. Nasoseptal flap or other reconstructive technique

Operative Risks

1. CSF leak: may be unanticipated
2. Meningitis and other intracranial infection
3. Hemorrhage: ICA, sphenopalatine artery
4. Cranial nerve injury: most commonly CN VI
5. Injury to the contents of the pterygopalatine fossa (greater palatine nerve, infraorbital nerve, vidian nerve)
6. Injury to the orbit (i.e., extraocular muscles, optic nerve)

Surgical Technique

The surgeon must select the ideal surgical corridor for each individual lesion. Basic and advanced sinonasal and skull base anatomy must be mastered. For complex procedures, anticipation and preparation are critical. All surgical instruments must be ready before the procedure begins.

1. The nasal mucosa is topically decongested with 0.05% oxymetazoline, 4% cocaine or 1:1000 epinephrine-soaked pledgets before the sterile drapes are positioned.
2. The image guidance system is set up, calibrated, and accuracy confirmed. A stealth merge between the CT and MRI can be used for the entire procedure, especially to verify complete excision of tumors.
3. A 0-degree, 4-mm, rigid nasal endoscope attached to a high-definition video system is used for the majority of the operation. Thirty-, 45-, 70-, and 90-degree endoscopes should be available for evaluation of laterally extending lesions.
4. Sterile normal saline irrigations tempered between 40°C and 42°C
    a. Prevents fogging of the endoscope

   b. Aids in hemostasis as it activates the coagulation cascade
   c. Temperature above 48°C may predispose to mucosal tissue damage.
5. If a large surgical defect is anticipated, a vascularized nasoseptal flap based on the posterior nasal branch of the sphenopalatine artery is raised via electrocautery. The flap should be harvested from the contralateral side, if the ipsilateral sphenopalatine artery is clipped during a transpterygoid approach.
6. The petrous apex can be approached through a bilateral paraseptal approach or a transpterygoid approach.

Bilateral Paraseptal Transphenoidal Approach

Allows for access to the medial aspect of the petrous apex

1. Bilateral sphenoidotomies with 1–2 cm posterior septectomy are performed. This allows for a binostril approach with a four-handed technique. A more extensive septectomy can be considered for larger lesions.
2. The entire anterior wall of the sphenoid sinus along with the intersinus septum, sphenoid rostrum, and vomer is removed with Kerrison rongeurs and high-speed drill with a 3- or 4-mm coarse diamond burr. Incomplete removal of bony edges of the anterior wall of the sphenoid and within the sphenoid may limit the mobility of the instruments.
3. To reach the petrous apex, the medial aspect of the pterygoid process and the medial pterygoid plate are exposed superior to the Eustachian tube, and the Vidian canal is identified.
4. Drilling begins medially and inferiorly along the vidian canal back to the level of the ICA and the posterior wall of the sphenoid sinus. The palatovaginal artery can be cauterized where it exits the pterygopalatine space.
5. For inferior extension, a transclival approach can be performed in conjunction with this approach. For lateral extension, a transethmoidal-sphenoidal or a transethmoidal-pterygo-sphenoidal approach can be used.

Transethmoidal-Pterygo-Sphenoidal Approach

This allows for additional access laterally to the inferior aspect of the petrous bone (infrapetrous approach). In addition to the bilateral transphenoidal approach, the following steps are taken:

1. Unilateral middle turbinate resection may facilitate access.
2. Unilateral total ethmoidectomy and maxillary antrostomy are performed.
3. The antrostomy is extended posteriorly to the level of the pterygoid process, and the posteromedial wall of the maxillary sinus is removed.
4. The contents of the pterygopalatine fossa are exposed, and the sphenopalatine artery and its branches are cauterized or ligated.
5. The contents of the pterygopalatine space are displaced laterally, and CN V2 and the Vidian nerve are identified exiting the foramen rotundum and the Vidian canal, respectively. The greater palatine nerve and artery are also identified entering the greater palatine foramen.
6. This exposes the pterygoid process and both medial and lateral pterygoid plates. The pterygoid plates are then removed inferior to the Vidian canal.
7. Dissection along the posterior edge of the lateral pterygoid plate exposes V3 as it exits the foramen ovale.
8. The inferior surface of the petrous apex is reached by drilling the bone between the horizontal segment of the petrous ICA and the Eustachian tube, medial to V3 and staying inferior to the Vidian canal.
9. To positively identify the ICA, one can consider exposing the paraclival segment of the ICA and following it inferiorly to the anterior genu and the petrous portion. It may be necessary to transect the dense fibrocartilage between the foramen lacerum and the eustachian tube with scissors.

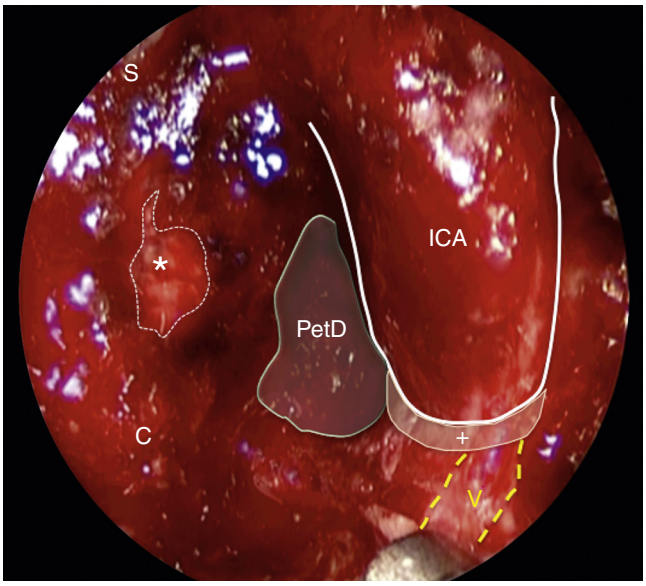

Fig. 120.4. Left petrous apex adenocarcinoma post-resection viewed with 30-degree angle scope. *, Bony erosion by tumor with exposed dura; *C*, clivus; *ICA*, internal auditory canal; *PetD*, petrous apex defect; *S*, sella; +, foramen lacerum cartilaginous portion; *V*, vidian nerve.

Lateralization of the Carotid Artery

1. After performing the transethmoidal-pterygo-sphenoidal approach, the vidian artery and nerve are traced posteriorly to the anterior genu of the ICA.
2. The bone of the vertical paraclival segment of the ICA is thinned with a 3-mm diamond burr and removed to the anterior genu.
3. The bone lateral to the ICA is also removed (Meckel's cave region), allowing up to several millimeters of lateral translocation of the vessel without compressing it.
4. Once the ICA is lateralized, lesions posterior to the paraclival and petrous ICA can be accessed (Fig. 120.4).

TUMOR REMOVAL AND RECONSTRUCTION

The suspected pathology and surgical access required would dictate how much bone is removed over the lesion. The bone is "egg-shelled" with a diamond burr, and small pieces are removed with a small Kerrison rongeur or dissector (e.g., 1 or 2 mm). For cystic lesions, such as cholesterol granulomas and mucoceles, a sharp sickle knife is used to open the wall of the cyst and drain the contents. The cavity is irrigated with saline to remove any additional debris. A stent or mucosal graft can be positioned through the opening to help maintain patency. For solid lesions, such as chondrosarcoma and chordoma, removal with a ring curette and suction is often feasible, as these tumors are typically gelatinous. An ultrasonic aspirator is also an option. For fibrous tumors, such as meningioma, the use of dissectors and scissors, along with careful hemostasis, should be considered.

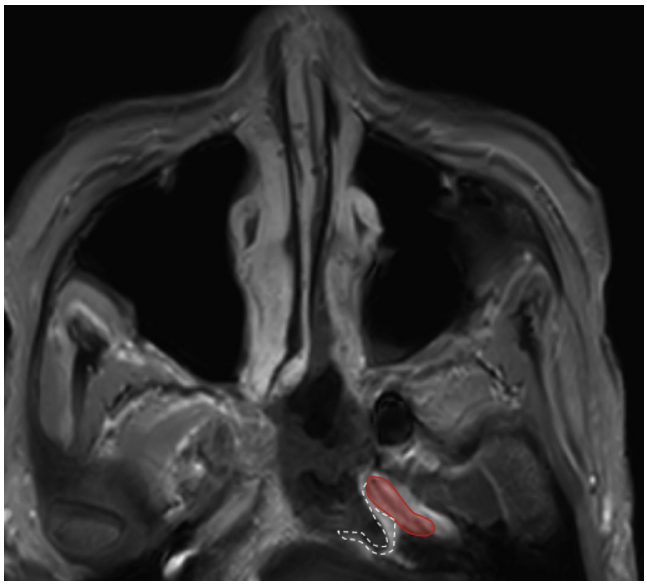

Fig. 120.5. Left petrous apex adenocarcinoma. Postoperative T1-weighted magnetic resonance imaging with gadolinium shows complete resection. The dotted white line shows nasoseptal flap covering the petrous apex defect. The internal carotid artery is highlighted in red.

For large surgical defects with or without CSF leak, a nasoseptal flap with or without an abdominal adipose tissue graft is an excellent reconstructive option (Fig. 120.5). The surgeon should anticipate this ahead of time so the flap can be raised and safeguarded in the nasopharynx or maxillary sinus. The nasoseptal flap must be elevated on the contralateral side, as the sphenopalatine artery is often ligated on the ipsilateral side. A small nasoseptal flap also can be inserted into the cavity of a marsupialized cholesterol granuloma as a substitute for a temporary silastic stent to keep the opening of the cyst patent.

Common Errors in Technique

1. Small exposure from a unilateral approach
2. Small opening for cholesterol granulomas
3. Inability to differentiate the vidian artery from the palatovaginal artery
4. Inadequate hemostasis that can compromise visualization
5. Inability to identify and expose the ICA may prevent optimal exposure of the lesion.
6. Careful ligation of internal maxillary artery branches will help to prevent postoperative epistaxis.
7. For extradural lesions, preserving the dura of the middle and posterior cranial fossae can prevent a CSF leak.

POSTOPERATIVE PERIOD

Postoperative Management

1. Antibiotics should be administered while nasal packing is in place.
2. Imaging should be considered 24 hours after surgery when an intraoperative CSF leak is encountered to rule out complications, such as pneumo-encephalus or intracranial hemorrhage.
3. Patients should have at least 24-hour neurosurgical intensive care unit (ICU) observation.
4. Pain medication: Patients would not be expected to have much pain following this operation. Avoid opioid-derived medications, especially in patients prone to sensitivity to these medications, so they do not develop nausea and emesis.
5. High-volume saline irrigations on postoperative day 1 if no CSF leak is seen. If a CSF leak is repaired and packing is placed, irrigations can begin as soon as the packing is removed on postoperative days 6–7.
6. Nasal splints placed during the procedure to avoid synechia can be removed in about 3 weeks.
7. Resumption of anticoagulants/antiplatelet drugs on postoperative days 3–5
8. Normoglycemia should be achieved. Insulin and glucose infusions should be used to titrate the patient to a near-normoglycemic level.
9. Nasal débridement is typically performed at weeks 3, 6, and 12.

Complications

1. CSF leak
2. Cranial nerve injury, in this case CN VI
   a. Resolution of CN VI palsy depends upon whether the lesion was caused by manipulation vs. section of the nerve. When the palsy is caused by manipulation, observation can be an option, and spontaneous resolution usually can be seen after 6 months. Patients with CN VI palsy can benefit from consultation with a neurologist, ophthalmologist, or neuroophthalmologist, especially if the lesion does not resolve.
3. Dry eye due to vidian nerve injury/sacrifice
   a. The incidence of dry eye syndrome is 12%–30% after vidian nerve neurectomy. When the sphenopalataine ganglion is preserved, the risk of dry eye syndrome is reduced; those patients that are symptomatic usually improve 30 days postoperatively. For symptomatic patients, treat with sodium hyaluronate eye drops.
4. Epistaxis
   a. Careful ligation of posterior nasal arteries will avoid this complication.
5. Intracranial hemorrhage
   a. Intracranial hemorrhage must be treated in conjunction with neurosurgery and the ICU.
6. ICA injury
   a. Carotid artery injury remains one of the most devastating complications in endoscopic skull base surgery. A well-defined protocol should be in place in the event of such a complication. Immediately following injury, the bleeding site should be tamponaded with focal packing if identified, and the nose should be packed bilaterally. Compression of the ICA in the neck may help to minimize blood loss. The blood bank should be mobilized, and the neurointerventionalist should be called. Hypotension should be avoided to maintain cerebral perfusion pressure. If the injury site is identified and bleeding initially controlled, repair with a crushed muscle graft can be attempted. The patient must then be transferred to the angiography suite for possible BTO and permanent occlusion if definitive repair is still required. If BTO leads to electroencephalogram changes, stenting or a carotid bypass must be considered. For unstable patients, intraoperative angiography is an option.

EVIDENCE-BASED MEDICINE QUESTION

Which is the best approach for petrous apex cholesterol granulomas?

Over the years, several authors have researched the feasibility of the EEA for drainage of cholesterol granulomas of the

petrous apex. In a recent systematic review of surgical outcomes after endoscopic management of cholesterol granulomas, Eytan et al.[6] included a total of 53 patient cases from 1996 to 2013, where a symptom resolution or improvement was reported in 84.4% and 13.3% of cases, respectively, at a mean follow-up of 20 months. Recurrence rate in stent versus no stent use was also analyzed. Although the recurrence rate was higher in the nonstent group (10.7%) compared to the stent group (4.3%), the difference was not statistically significant. In the same study, the complication rate in open approaches (n = 134) ranged from 0% to 60% (mean 24.3%), where the most common was hearing loss and CSF leak; in contrast, the most common complication in the EEA group was epistaxis (13.2%). Success and complication rate, poor or inadequate reporting, and selective outcome reporting could be potential biases for their results. In addition to this, Scopel et al.[7], in an anatomic and radiologic study, showed how the EEA provided a wide surgical field with the preservation of important otologic structures. They showed how the EEA provided a large drainage window (3 times bigger) when compared to a transcanal infracochlear approach. Also, their results showed how the EEA to the petrous apex was more consistent, as it provided exposure to all the petrous ICA. As previously stated in this chapter, it is fundamental to adapt the surgical approach to the patient and not the other way around. The petrous apex is one of the least accessible areas of the skull base. Some pathology can be approached by one modality independently or by a combination of both. Each of us should critically analyze and acknowledge our own reach, limitations, and surgical skills for the benefit of our patients.

Editorial Comment

This chapter demonstrates the evolution of surgical approaches for the management of benign and malignant disease involving the petrous apex. The modern skull base surgeon must consider all approaches (transtemporal, middle fossa, and endonasal) and choose the approach that is best suited for the pathology and the patient. Close communication with colleagues in otology and neurosurgery is essential.

Although the risks and morbidity of other approaches are avoided with an endonasal approach, this approach has its own unique set of risks and morbidities. The most serious risk is injury to the ICA. Expansile lesions of the petrous apex, such as a cholesterol granuloma, provide a larger window for exposure, and the risk of carotid injury is minimal. Lesions that are less accessible require lateralization of the carotid artery or a combined medial and infrapetrous approach. With good exposure and knowledge of anatomic relationships, surgery can be safely performed in such situations. Dissection of the carotid artery is best performed by a team of skull base surgeons.

Carl H. Snyderman

Access the review questions online at http://www.expertconsult.com

REFERENCES

1. Nekhendzy V, Lemmens HJM, Vaughan WC, et al. The effect of deliberate hypercapnia and hypocapnia on intraoperative blood loss and quality of surgical field during functional endoscopic sinus surgery. Anesth Analg 2007;105:1404–1409. http://dx.doi.org/10.1213/01.ane.0000282781.56025.52. table of contents.
2. Ko M-T, Chuang K-C, Su C-Y. Multiple analyses of factors related to intraoperative blood loss and the role of reverse Trendelenburg position in endoscopic sinus surgery. Laryngoscope 2008;118:1687–1691. http://dx.doi.org/10.1097/MLG.0b013e31817c6b7c.
3. Lai LT, Trooboff S, Morgan MK, et al. The risk of meningitis following expanded endoscopic endonasal skull base surgery: a systematic review. J Neurol Surg Part B Skull Base 2014;75:18–26. http://dx.doi.org/10.1055/s-0033-1353365.
4. Dusick JR, Esposito F, Malkasian D, et al. Avoidance of carotid artery injuries in transsphenoidal surgery with the Doppler probe and micro-hook blades. Neurosurgery 2007;60:322–328. http://dx.doi.org/10.1227/01.NEU.0000255408.84269.A8. [discussion 328–329].
5. Mason E, Gurrola 2nd J, Reyes C, et al. Analysis of the petrous portion of the internal carotid artery: landmarks for an endoscopic endonasal approach. Laryngoscope 2014;124(9):1988–1994. http://dx.doi.org/10.1002/lary.24594.
6. Eytan DF, Kshettry VR, Sindwani R, et al. Surgical outcomes after endoscopic management of cholesterol granulomas of the petrous apex: a systematic review. Neurosurg Focus 2014;37(4):1–7.
7. Scopel TF, Fernandez-Miranda JC, Pinheiro-Neto CD, et al. Petrous apex cholesterol granulomas: endonasal vs. infracochlear approach. Laryngoscope 2012;122(4):751–761.

REVIEW QUESTIONS

1. Which is the most common solid lesion of the petrous apex?
   a. Meningioma
   b. Chondrosarcoma
   c. Chordoma
   d. Cholesterol granuloma

2. Which of the following statements is incorrect?
   a. A clival chordoma is a destructive midline tumor centered on the clivus with high T2 signal intensity.
   b. Chondrosarcomas are seen along the lateral aspect of the clivus.
   c. Cholesterol granulomas are cystic lesions with high T1 and T2 signals.
   d. The T2 signal intensity of chondrosarcomas is low to intermediate.

3. Which statement regarding the vidian nerve is correct?
   a. The Vidian nerve is a motor nerve.
   b. The Vidian canal is located at the junction of the sphenoid floor and the medial pterygoid plate.
   c. The Vidian canal is lateral to the foramen rotundum.
   d. The Vidian canal is an important landmark for the cavernous carotid artery.

121 Surgical Approaches to the Infratemporal Fossa

Neal M. Jackson, Meghan N. Wilson, Daniel W. Nuss

INTRODUCTION

A variety of surgical approaches to the infratemporal fossa (ITF) have been developed to address pathologies in specific areas while attempting to preserve the function of key neurovascular structures.[1-5] Indeed, intimate knowledge of the anatomy and a multidisciplinary evaluation are of foremost importance when considering a surgical approach to this complex area. The boundaries of the ITF are shown in Table 121.1. Tumors may arise in the ITF or invade it by direct extension from surrounding structures, such as the parotid gland, the upper aerodigestive tract, the temporal bone, and the parapharyngeal space. A multidisciplinary approach, including review at a tumor conference, is important for proper evaluation and treatment, ensuring both effective treatment of disease and acceptable function and cosmesis.

KEY OPERATIVE LEARNING POINTS

- The surgeon must have detailed knowledge of key structures in the ITF.
- There are a variety of approach options (open vs. endoscopic; preauricular vs. postauricular) to the ITF.
- Tumor location within ITF, benign versus malignant pathology, and the potential risk to neurovascular structures should all guide multidisciplinary treatment planning, including the choice of surgical approach.

PREOPERATIVE PERIOD

History

History of Present Illness

1. Ask about any neurologic deficits, emphasizing dysfunction of any cranial nerves.
   a. Dysfunction of the trigeminal nerve is common for tumors in the ITF. This may present as localized numbness or dysesthesia in V1, V2, or V3 distribution and/or dysfunction of mastication, including malocclusion or deviation of the jaw due to mass effect or weakness/atrophy of the masticator muscle.
   b. Weakness of the face suggests tumor involvement either by compression or by direct invasion. However, it is important to counsel patients that intact preoperative function does not assure sparing of the nerve, and some approaches may lead to permanent weakness after manipulation or transposition of the nerve.
   c. Tumors approaching the jugular foramen may result in deficits of the lower cranial nerves (IX–XII), and tumors invading the temporal bone or posterior fossa may lead to sensorineural hearing loss and vestibular dysfunction.
   d. Patients with preoperative dysphagia and aspiration should be counseled that surgery may worsen these problems, and consideration may be given to placement of a feeding tube and/or tracheostomy.
   e. Conductive hearing loss due to unilateral Eustachian tube (ET) dysfunction with middle ear effusion may indicate compression of the ET by a tumor.
2. Ophthalmologic history is important, including any visual loss or diplopia.

Past Medical History

1. Any history of prior lesions, cancers, or other tumors in the head and neck or distant locations is important, particularly the details of management including head and neck surgery or radiation.
2. The medical health and functional status of the patient are important, as surgery of the ITF may be a significant physiologic stress, depending on the pathology and reconstructive needs.
3. If the patient smokes, counseling and cessation are important for both perioperative healing and long-term survival.

Physical Examination

1. The infratemporal space is relatively inaccessible to direct visualization and palpation on physical examination. Subtle swelling of the temporal area above the zygomatic arch may be evident. It is essential to perform a thorough examination of the head and neck, with special attention to cranial nerve function, to assess both the tumor extent and the existing dysfunction.
2. Evaluate for trismus, as this may provide information about possible spread into the pterygoid musculature or the temporomandibular joint (TMJ). Preoperative airway planning is essential as some patients with significant trismus may need fiberoptic intubation or even tracheostomy if a major resection and reconstruction are planned.
3. Evaluate visual function and document visual acuity; evaluate hearing and document audiometric testing.
4. If considering an endonasal endoscopic approach, perform nasal endoscopy to assess the anatomy and adequacy of the surgical corridor.

Imaging

1. Because direct physical examination of the ITF is limited, radiographic imaging plays an essential role in precise tumor location and may suggest the type of pathology. Computed tomography (CT) and magnetic resonance imaging (MRI) are complementary, and often both are needed. The demonstration of bone involvement and widening of foramina is best seen on CT, while the evaluation of soft tissue planes and tumor extension along neural structures is best seen on MRI.
2. It is critical to evaluate the functional status of the internal carotid artery (ICA) and its precise anatomic relationship to tumors of the ITF as these influence the selection of the approach. If there is any concern for ICA involvement following CT and MRI imaging, a magnetic resonance angiogram (MRA) or angiogram should be considered. If intraoperative manipulation of the ICA is likely, the team should consider preoperative evaluation of collateral cerebral blood flow with a balloon occlusion test. Consultation with a Neurovascular Surgeon may be warranted if intraoperative vascular bypass is a possibility.
3. Evaluation of regional and distant metastatic disease is dictated by the histology and stage of the tumor.

TABLE 121.1 Boundaries of the Infratemporal Fossa

	Superior	Medial	Lateral	Anterior	Posterior
Bone	Temporal bone, greater wing of sphenoid	Lateral pterygoid plate, pterygopalatine fissure	Mandible, zygoma	—	Articular tubercle of the temporal bone, glenoid fossa, and condyle, styloid process
Muscle	—	Superior constrictor, pharyngobasilar fascia	Masseter, temporalis	Medial and lateral pterygoids, masseter	Prevertebral fascia
Foramina	Carotid canal, jugular foramen, foramen ovale, foramen spinosum, foramen lacerum	—	—	—	—
Nerves	Mandibular division of trigeminal nerve (V3), Pars nervosa of jugular foramen	—	—	—	CN IX, X, XI; sympathetic plexus
Arteries	Internal carotid artery	Internal maxillary artery	—	—	Internal carotid artery
Veins	Internal jugular vein	Pterygoid venous plexus	—	—	Internal jugular vein
Other	—	—	Parotid gland	—	—

Indications

1. A wide variety of conditions can affect the ITF, including benign and malignant tumors, infections that arise from the dentition, paranasal sinuses and salivary glands (which may be fungal, bacterial, or polymicrobial), and other destructive or infiltrative pathologies (e.g., fibromatosis, soft-tissue radionecrosis). Not all lesions of the ITF require surgery, and the "radicality" of surgery will be different depending on the pathology at hand. Surgery for infectious problems of the ITF is reserved for those cases in which appropriate, culture-directed antimicrobials have not resolved the problem.
2. Common neoplastic indications for ITF surgery include benign lesions, such as schwannomas, pleomorphic adenomas, vascular lesions (arteriovenous malformations, paragangliomas), and meningiomas (which may or may not have intracranial origin) and malignant tumors, such as rhabdomyosarcoma, malignant salivary tumors (from aerodigestive tract, parotid, or microscopic minor salivary rests), and extensions of mucosal cancers from the oral cavity, sinuses, or nasopharynx.
3. Tissue biopsy with pathologic confirmation of the biologic behavior (benign vs. malignant) is necessary prior to any major extirpative surgery and may guide the degree to which aggressive measures (e.g., nerve sacrifice) are indicated. Open or transnasal endoscopic biopsy is often possible, but if the tumor is limited to a deep location, an image-guided fine-needle aspiration biopsy should be considered. Biopsies are usually not indicated for highly vascular lesions with characteristic imaging findings, such as glomus tumors. Open/invasive biopsy may be necessary to diagnose certain lesions, justified by noting that some pathologic processes (e.g., hematologic proliferative disorders, such as lymphoma, plasmacytoma, and metastasis from distant sites) will not benefit from surgical resection.
4. If imaging reveals skull base or intracranial invasion, neurosurgical consultation is essential.
5. When assessing the indications for tumor removal, also assess the medical fitness of the patient to have the surgery and the reconstructive needs and options.

Contraindications

1. Medical comorbidities with a high risk for general anesthesia
2. ICA involvement with failed balloon occlusion test
3. Extensive invasion of brain parenchyma by a malignant lesion
4. Lesions whose biologic behavior deems them not to be appropriate for surgical therapy (e.g., lymphoma, plasmacytoma)

Preoperative Preparation

1. Depending on the approach, image-guided navigation based on high-resolution, thin-cut CT images and/or MRI may be used to assist with the confirmation of anatomic landmarks and tumor boundaries and may assist in planning the surgical trajectory.
2. Blood products should be available, especially for highly vascular lesions, as the internal maxillary artery traverses the ITF, and the ICA is in close proximity. Preoperative embolization of the internal maxillary artery may be considered to minimize blood loss, although this may compromise reconstructive options.
3. If a large defect is anticipated after extirpation, preoperative consultation with a microvascular reconstructive surgeon is essential. Additional testing (Allen's test, vascular studies) may be necessary.
4. A lumbar drain should be inserted if a significant intradural dissection with risk of cerebrospinal fluid (CSF) leak is anticipated.

OPERATIVE PERIOD

Anesthesia

1. General anesthesia is required. Preoperative evaluation of the airway is critically important to the safe induction of anesthesia. Depending on the patient, traditional induction and laryngeal exposure may be possible. In patients with trismus, preoperative aerodigestive abnormalities, or anticipated postoperative airway compromise, fiberoptic intubation or tracheostomy may be necessary.
2. If neurophysiologic monitoring will be performed, it is important to communicate with the anesthesia team regarding the need for avoidance of paralytic agents.

Positioning

1. The patient should be positioned supine. The head should be supported on an appropriate head holder or in Mayfield pins if intracranial neurovascular work is anticipated, depending on the needs of resection and the preference of the Otolaryngologist and Neurosurgeon.

2. Access to the neck for vascular control is important if the ICA/internal jugular vein (IJV) are at risk.

Perioperative Antibiotic Prophylaxis

1. Antibiotic prophylaxis should provide coverage against flora of the skin and upper aerodigestive tract. If intracranial surgery is anticipated, the use of an antibiotic with good penetration of the blood–brain barrier should be considered. Our patients without drug allergies receive intravenous cefazolin and metronidazole.

Monitoring

1. Facial nerve electromyography (EMG) is helpful for all preauricular and postauricular approaches.
2. Select cranial nerve monitoring (e.g., vagus nerve via laryngeal EMG endotracheal tube) is indicated in some cases.

Instruments and Equipment to Have Available

Open Approaches

1. Rainey clips
2. Drill, saw, osteotome
3. Midface/cranial plating system
4. Vascular instrument set if the carotid artery is at risk
5. Head and neck surgical set

Endoscopic Approaches

1. Stereotactic navigation system (recommended)
2. Standard O-degree and angled endoscopes, endoscopic sinus surgery instruments, and video camera with monitor
3. Endoscopic bipolar and suction monopolar electrocautery
4. Vascular clip appliers
5. High-speed surgical drill with extended-tip burs to reach depth of surgery
6. Cottonoid pledgets and additional hemostatic agents including absorbable gelatin sponge (Gelfoam) with thrombin, oxidized regenerated cellulose (Surgicel), or Floseal (or comparable hemostatic gelatin/thrombin matrix)

Key Anatomic Landmarks

Preauricular Subtemporal Infratemporal Approach

1. Frontal (temporal) branch of the facial nerve (See Table 121.1): During elevation of the scalp flap, one must incise to the deep temporalis fascia at a level above the superior orbital rim and follow this plane inferiorly to prevent injury to this nerve (Fig. 121.1D).
2. Main trunk of facial nerve (as in standard parotidectomy)
3. Vascular anatomy, including the internal maxillary artery and the carotid artery
4. Lower cranial nerves IX–XII
5. The lateral pterygoid plate can be followed posteriorly to identify the foramen ovale, foramen spinosum, and the spine of the sphenoid bone. These structures are valuable landmarks for guiding the surgeon to V3, middle meningeal artery, and carotid canal, respectively.

Postauricular (Transtemporal) Approach

1. Spine of Henle for mastoidectomy (See Table 121.1)
2. Facial nerve through intratemporal course and at stylomastoid foramen
3. Bony-cartilaginous junction of external auditory canal (EAC) (if EAC is to be closed permanently)
4. Vascular structures (common, internal, and external carotid arteries; IJV) are identified in the neck.
5. CN X, XI, and XII are identified in the neck.

Prerequisite Skills

For open approaches, proficiency with the following skills is necessary:

1. Bicoronal scalp incision and flap elevation
2. Parotidectomy and facial nerve dissection
3. Craniomaxillofacial plating
4. Harvest of abdominal adipose tissue
5. Otomicroscopy with standard microsurgical temporal bone dissection
6. Ligation of great vessels at the skull base or inferiorly in the neck

Endonasal Endoscopic Approach

1. Extended maxillary antrostomy and visualization of the orbital floor
2. Exposure of Sphenopalatine artery (SPA), internal maxillary artery, and V2 nerve branches after removal of the posterior wall of the maxillary sinus

For endoscopic approaches, proficiency with the following skills is necessary:

1. Advanced endoscopic sinus surgery including functional endoscopic surgery of the maxillary, ethmoid, and sphenoid sinuses
2. Septoplasty, if needed for access
3. Endoscopic medial maxillectomy and/or Caldwell-Luc approach
4. Endoscopic vessel control and ligation
5. Endoscopic and/or open reconstruction techniques including nasoseptal flap, free grafts, and temporalis muscle flap

Operative Risks

1. Temporary or permanent dysfunction of cranial nerves
2. CSF leak
3. Injury to the orbit
4. ICA injury or other vascular injury with resultant cerebrovascular accident, death

Surgical Technique

Preauricular Approach (Infratemporal Subtemporal Approach)

- This approach is suitable for many tumors arising in the ITF and intracranial tumors that arise in the greater wing of the sphenoid or anterior temporal bone (see Fig. 121.1)[1,2].
- It does not allow safe resection of the entire temporal bone or control of the infratemporal facial nerve or jugular bulb.

Steps

1. Make a hemicoronal or bicoronal incision across the vertex of the scalp. Ipsilateral preauricular incision is extended inferiorly. The scalp incision can be extended contralaterally to enable broader rotation of the flap (see Fig. 121.1A–D).
2. Extend the incision through the subcutaneous tissue, galea, and pericranium, and elevate the flap anteriorly in a subpericranial plane. Raney clips can be applied to the edges of the scalp to decrease bleeding according to the surgeon's preference. Preserve the anterior branches of the superficial temporal artery, as these supply the frontal scalp flap.

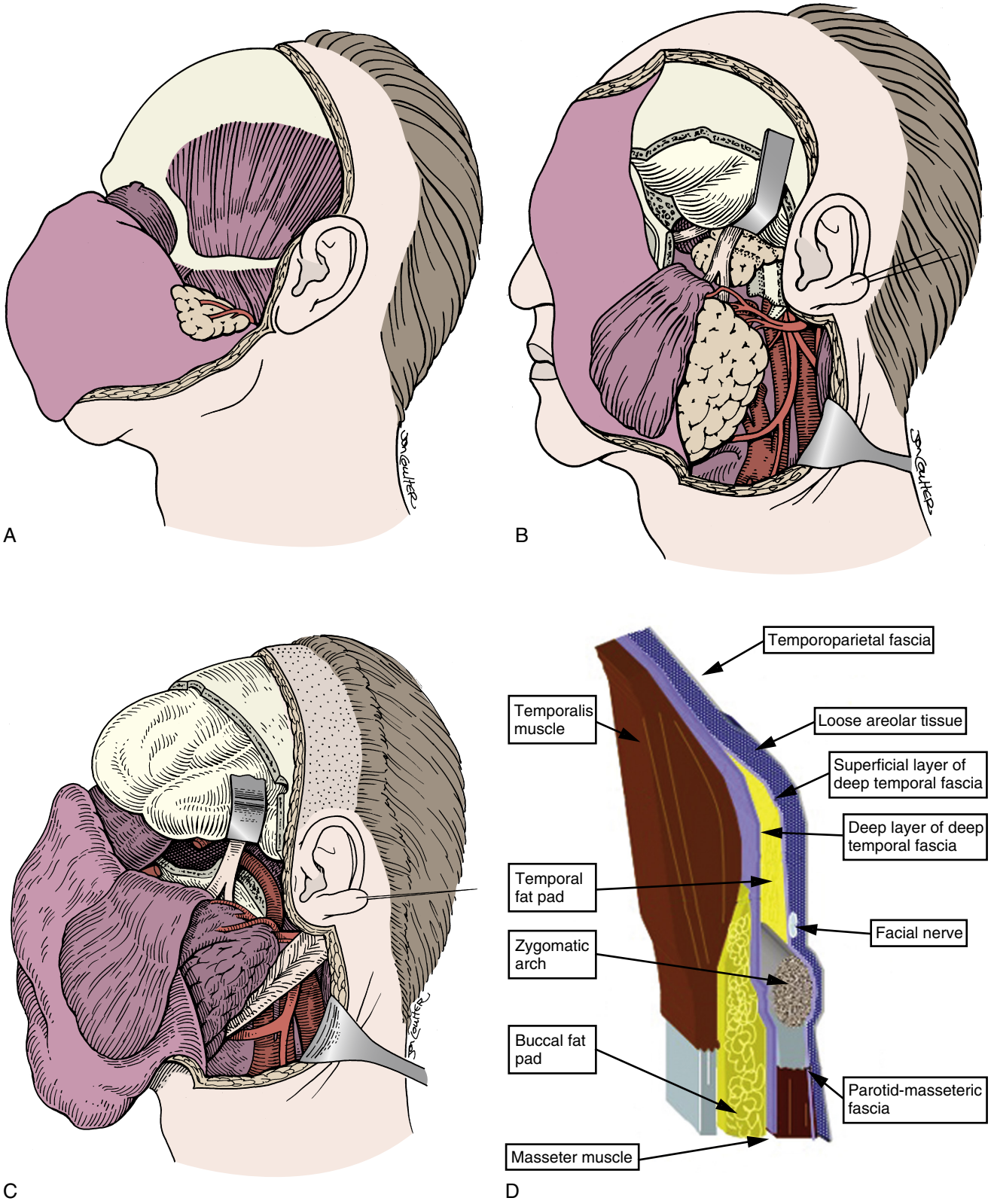

Fig. 121.1. Preauricular subtemporal infratemporal approach. A, Bicoronal incision extended preauricularly reveals temporalis muscle and orbitozygomatic (OZ) bone. The facial nerve can be identified entering the parotid tissue in the standard parotidectomy technique. **B,** The reflection of the temporalis muscle anteriorly, the removal of the OZ bone, and temporal craniotomy enhance superior access, while extension of the incision into the mid-neck allows the dissection to reach the internal jugular vein, hypoglossal nerve, and internal carotid artery. Under the brain retractor, a beige-colored tumor is seen deep to V3. **C,** Further dissection reveals the petrous carotid (visualized just left of the auricle from this perspective) passing behind V3. The two cut ends of the transected V2 are seen. **D,** The coronal cut-through view of the temporal region. The temporal adipose tissue pad lies between the two layers of the deep temporal fascia. Note the temporal branch of the facial nerve, which lies in the superficial layer of the deep temporal fascia. *(From: Carrau R, Vescan A, Snyderman C, Kassam A: Surgical approaches to the infratemporal fossa. In: Myers EU (ed). Operative Otolaryngology: Head and Neck Surgery, 2nd ed. Philadelphia: Saunders Elsevier; 2008, specific figures: Figure 101-106, Figure 101-120, Figure 101-121, Figure 101-105.)*

3. As the temporalis muscle is exposed from posterior to anterior, an incision is made in the superficial layer of the deep temporal fascia (the *interfascial incision)* to deepen the plane of dissection to include and elevate the temporal adipose tissue pad.
4. Further dissection anteriorly-inferiorly should proceed deep to this adipose tissue pad in order to protect the frontal branch of the facial nerve, which runs in the superficial layer of the deep temporal fascia (see Fig. 121.1D).
5. The temporal adipose tissue pad and superficial layer of fascia are reflected anteriorly with the scalp flap until the orbitozygomatic (OZ) complex is exposed sub-periosteally.
6. To access the anatomy deep to the OZ complex, first elevate the periosteum off both sides of the zygoma and elevate the periorbita from the lateral orbit to expose the area from the orbital roof to the inferior orbital fissure. A reciprocating saw is used to make beveled cuts at the root of the zygoma, zygomaticofrontal suture, and zygomaticomaxillary buttress to free the OZ bone segment. The bone is saved in saline for later reattachment with plating. Many advocate prebending and drilling screw holes before detachment to facilitate replacement and securing of the graft at the end of the procedure.
7. Identify and preserve the main trunk of the facial nerve with a standard parotidectomy technique. Other soft tissue structures anterior to the temporal bone can be transected to increase the rotation of the flap for better exposure.
8. The temporalis muscle is elevated off the temporal fossa, still attached at its inferior pedicle. (The temporalis is supplied by deep temporal artery branches of the internal maxillary artery on its deep surface near the attachment to the coronoid process of the mandible. Care is taken to preserve these vessels.) If it will be reattached, leave a rim of fascia on the cranium at the superior attachment of the temporalis muscle for suturing during closure.
9. The ITF is now exposed, and resection of the tumor can begin.

A subtemporal craniectomy can be performed to aid in the identification and exposure of the foramina.

10. If access to the petrous portion of the ICA is required, the glenoid fossa must be accessed by either dislocating or resecting the condyle of the mandible. A temporal craniotomy may be needed for exposure of the superior aspect of the glenoid fossa. Remember, the ICA is located medial to the glenoid fossa (see Fig. 121.1C).
11. Closure must ensure that dead space is obliterated and there is no communication to the aerodigestive tract. The temporalis muscle, either in full or its anterior portion, may be transposed into the defect. If a portion of the temporalis muscle remains free, it should be placed in the anterior temporal defect to preserve cosmesis.
12. The OZ bone complex is now reattached with a midface plating system.
13. Free tissue transfer with microvascular anastomosis may be required if the temporalis muscle is not viable or if there is a large defect, such as when maxillectomy with or without orbital exenteration is performed in conjunction with the ITF resection.
14. Standard closure of soft tissue is performed. A suction drain is left in place under the scalp flap.

Other Considerations

In children, the distance from the mandibular body to the infratemporal skull base is less than in adults, and the infratemporal skull base can sometimes be adequately exposed using a transcervical approach with identification and preservation of the facial nerve.

Postauricular (Transtemporal) Approach

- Suitable for lesions involving the temporal bone primarily but extending into the ITF (see Fig. 121.2)[1,2]

Steps

1. A C-shaped or question-mark-shaped postauricular incision is started superiorly in the temporal area, brought over the mastoid region, and extended inferiorly into a natural crease in the mid-neck to allow access to the great vessels and lower cranial nerves.
2. The EAC may be transected and sewn closed (as depicted in Fig. 121.2A) if pathology dictates sacrifice of the middle ear and there is risk of CSF leak. Otherwise, the auricle may be reflected anteriorly, and incisions around the tragus and conchal bowl will allow anterior rotation of the auricle and preauricular tissues while leaving the EAC on the temporal bone. These incisions will facilitate closure of the soft tissue without incisions in the EAC that risk canal stenosis.
3. The cervicofacial flap is elevated in a subplatysmal plane in the cervical area, superficial to the superficial muscular aponeurotic system (SMAS) over the parotid and along the deep layer of the deep temporal fascia over the cranium. The cervicofacial flap can then be reflected anteriorly.
4. The main trunk of the facial nerve is identified by standard parotidectomy methods. It is advisable to leave a cuff of soft tissue around the facial nerve to minimize direct traction on the nerve. Parotid tissue may be resected if needed for exposure or if dictated by a malignant epithelial parotid pathology.
5. Mastoidectomy and dissection of the intratemporal facial nerve can allow mobilization of the nerve for wider access to the ITF, the jugular bulb, and the lower cranial nerves.
6. Attention is directed next at the midlevel of the neck to obtain vascular control of the common, internal, and external carotid arteries and IJV.
7. The sternocleidomastoid muscle and posterior belly of the digastric muscle are separated from the mastoid bone.
8. The styloid process is identified by palpation, the stylohyoid and stylopharyngeus muscles are transected, and the styloid process is removed. CN IX may now be subtly visible crossing over the exposed ICA.
9. Temporal craniotomy and OZ osteotomy can be performed as described previously, exposing the rest of the infratemporal skull base (see Fig. 121.2B).
10. Tumor removal as dictated by tumor borders can then proceed with reconstruction as described in the previous section.

Fisch Lateral Infratemporal Fossa Approaches

Professor Ugo Fisch described multiple transtemporal approaches (types A–C) that focus on drilling through the temporal bone and re-routing the intratemporal facial nerve for enhanced subtemporal dural exposure (See Fig. 121.3)[3]. These three approaches were primarily otologic, microsurgical procedures for which detailed descriptions can be found in otologic texts. Their general uses are as follows:

Fisch type A is often used for glomus jugulare surgery or other tumors limited to the middle ear cleft. Type B includes reflection of the zygomatic arch and temporalis muscle inferiorly, extensive temporal bone dissection (referred to as a subtotal petrosectomy), and disarticulation of the TMJ to provide complete exposure of the ICA and foramen ovale.

Type C extends type B by resection of the pterygoid plates to provide access to the ET orifice, nasopharynx, and posterior

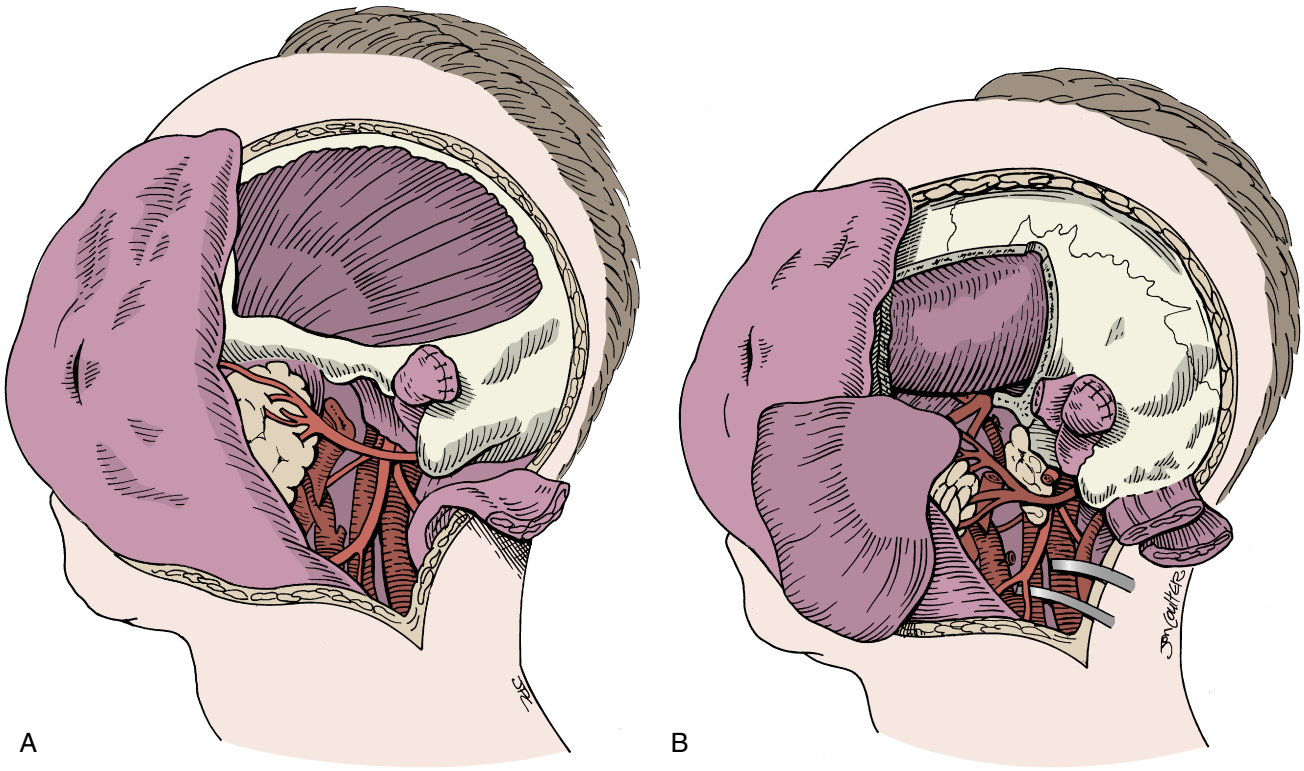

Fig. 121.2. Postauricular approach to allow temporal bone dissection. A, The cervicofacial flap has been reflected forward to expose the temporalis muscle, the orbitozygomatic (OZ) bone, the closed external auditory canal, the main trunk of facial nerve entering parotid gland, the hypoglossal nerve, and the great vessels (deep). **B,** The temporalis muscle has been reflected forward, the OZ bone removed, and the temporal bone craniotomy reveals the extent of the approach to the infratemporal fossa. *(From: Carrau R, Vescan A, Snyderman C, et al. Surgical approaches to the infratemporal fossa. In: Myers EU (ed). Operative Otolaryngology/Head and Neck Surgery. 2nd ed. Philadelphia: Saunders Elsevier; 2008, specific figures: Figure 101-133, Figure 101-135.)*

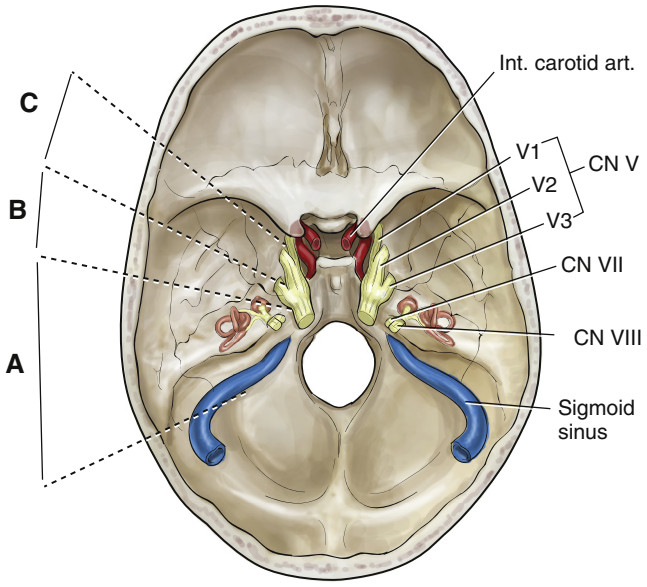

Fig. 121.3. Diagrammatic representation of Fisch infratemporal approaches, showing the approximate degree of cranial base access each provides. See text for details. *(From Persky M, Manolidis S. Vascular tumors of the head and neck. In: Johnson J, Rosen C (eds). Bailey's Head and Neck Surgery—Otolaryngology, 5th ed, Chapter 127, Philadelphia: Lippincott Wolters Kluwer; 2014.)*

maxillary sinus. A later "type D" described a modification, which is essentially a preauricular approach that does not remove middle ear/ET structures, reroute the facial nerve, or fully expose the ICA.

Facial Translocation Approach

This is the dedicated topic of Chapter 44 and will only briefly be discussed here. This approach is generally reserved for very extensive lesions of the ITF, masticator space, pterygomaxillary fossa, and paraclival region and certain tumors of the nasopharynx extending into the ITF (See Fig. 121.4)[4].

Steps

1. Hemicoronal incision with preauricular extension is made on the affected side. The elevation of the scalp proceeds as described in the preauricular approach section (see Fig. 121.4A).
2. A modified Weber-Ferguson incision is made and extended down to the periosteum; lip-split is not usually needed but may be added to provide access.
3. A horizontal incision connects the previous two incisions, extending from the lateral canthus aspect of the Weber-Ferguson incision posteriorly to the preauricular/scalp incision at the superior attachment of the auricle.
4. In making this incision, frontal branches of the facial nerve will be identified, tagged, and transected. EMG stimulation/monitoring is helpful in this pursuit. These nerves will be reapproximated at the end of the case.

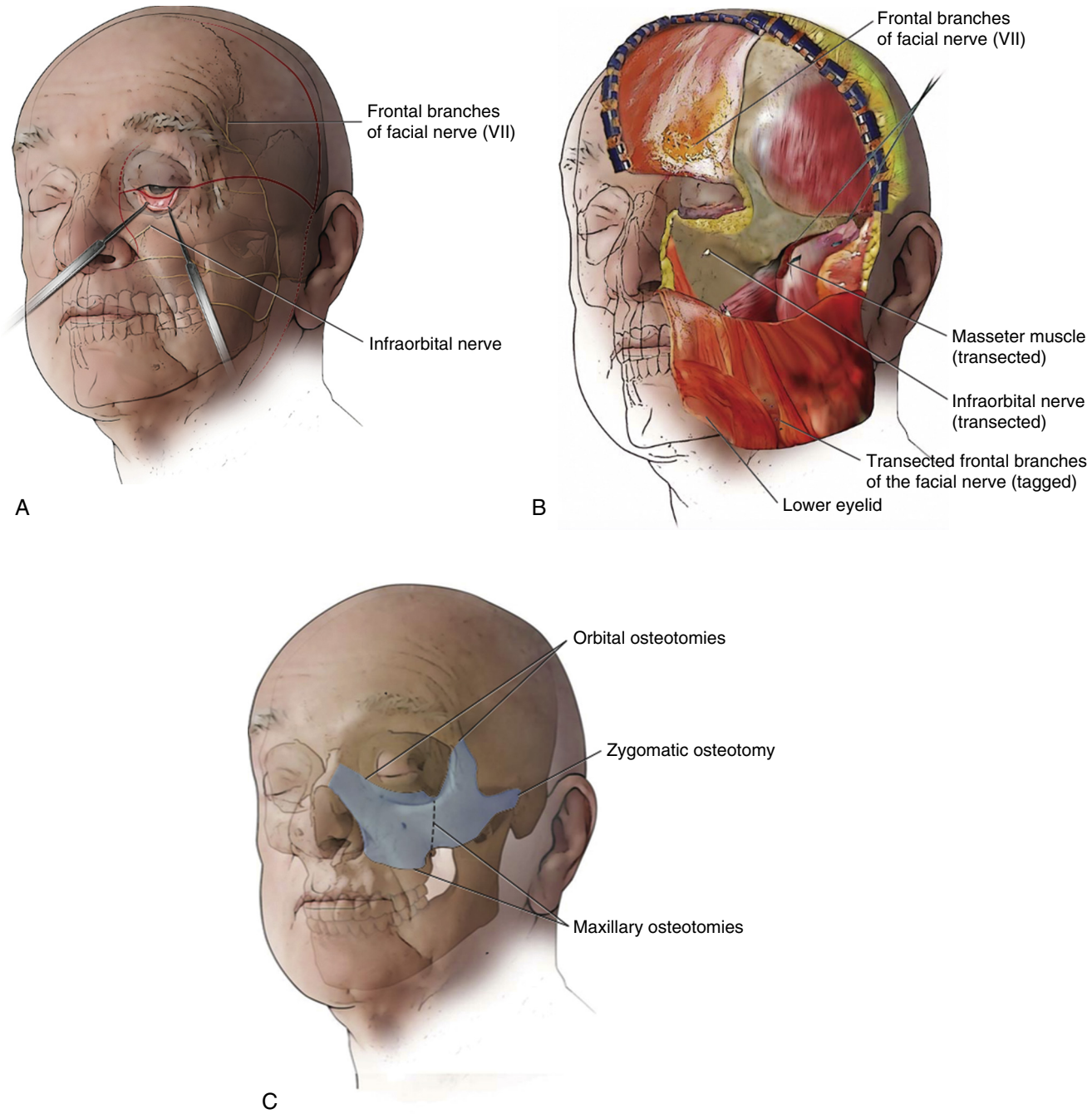

Fig. 121.4. Facial translocation approach. A, The incision design for facial translocation (see text for details). **B,** Exposure of the craniofacial skeleton after reflection of the soft tissue envelope. **C,** Diagram of the osteotomies of the orbital-zygomatico-maxillary (OZM) skeleton.

5. The middle and lower face flap is reflected inferiorly.
6. The infraorbital nerve (V2) is transected and tagged. If not involved in the tumor, it can be reapproximated at the end of the procedure.
7. The frontotemporal scalp flap is elevated in a subpericranial plane as previously described, and the OZ osteotomies are performed (see Fig. 121.4B). In addition, unilateral maxillary Le Fort I or II osteotomies are completed as needed to free the anterior face of the maxilla with the OZ complex (see Fig. 121.4C and D).
8. The temporalis muscle is reflected inferiorly. Osteotomy of the coronoid process can be performed to increase the arc of rotation, taking care to protect the nearby deep temporal arteries.
9. At this juncture, the anterior, medial, and lateral boundaries of the ITF should be completely exposed, and tumor removal can proceed. If further access to the medial ITF or nasopharynx is needed, the pterygoid plates can be removed.
10. If intracranial access is needed, a temporal/subtemporal craniotomy can be performed (see Fig. 121.4E).
11. For reconstruction, the temporalis muscle may be used to obliterate the defect (see Fig. 121.4F), versus additional free tissue transfer.
12. A temporary tarsorrhaphy for 10–14 days may be placed to prevent lower lid ectropion.
13. Soft tissue is carefully closed in layers. If the lacrimal system was transected, the lacrimal canaliculi should be stented with silicone stents secured in the nasal cavity.

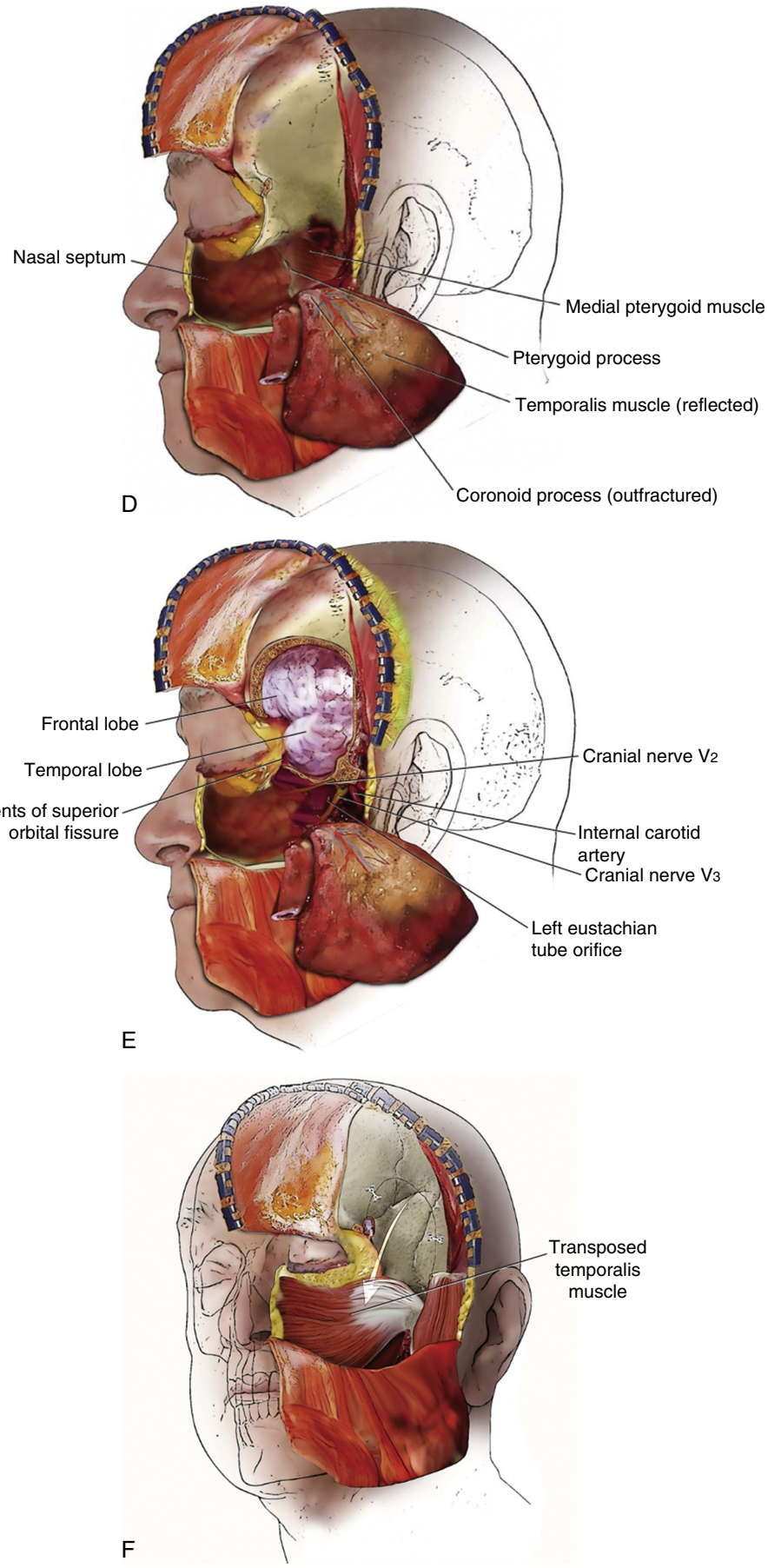

Fig. 121.4, Cont'd D, The exposure achieved after OZM osteotomies and the reflection of the temporalis muscle from the skull, revealing the view through the infratemporal fossa toward the nasopharynx. **E,** Frontotemporal craniotomy provides additional access to intracranial compartments. For extensive tumors, this additional access will enable extirpation of tumor extensions involving the foramen ovale, the foramen spinosum, and the orbital apex, as well as drilling of the clivus if needed. **F,** The temporalis muscle transposed for reconstruction of the cranial base defect after FTA. *(Reproduced with permission from Gardner P, Snyderman C. Master Techniques in Otolaryngology—Head and Neck Surgery: Skull Base Surgery, Chapter 20, Philadelphia Wolters Kluwer; 2015)*

Endoscopic Endonasal Approaches

This minimally invasive technique may be used for biopsy and/or resection of tumors in the medial ITF (see Fig. 121.5A-H)[5].

We use 3D stereotactic navigation based on thin-cut CT images obtained immediately prior to surgery.

Steps

1. After the face is prepped with betadine solution (with the eyes lubricated but accessible for monitoring of the pupils and globes), the nasal cavity is prepared with pledgets saturated with a topical decongestant.
2. The navigation system is calibrated using reliable external surface anatomy.
3. The endoscopic procedure is begun with bilateral diagnostic endoscopy. Lidocaine with epinephrine can be injected at this time to minimize bleeding. If a septal deviation impairs surgical access to the ITF, a septoplasty can be performed first.
4. A generously wide maxillary antrostomy is created endoscopically to access the posterior wall of the maxillary sinus, which is then gently removed to reveal the pterygomaxillary fissure.
5. The sphenopalatine artery is then identified and ligated with either a vascular clip or bipolar cautery. Dissection continues to the pterygopalatine fossa.
6. The mandibular division of the trigeminal nerve (V3) is the next key structure to identify, and stereotactic navigation is helpful in identifying its neural foramen (ovale) and in navigating to the lesion in a safe, precise way.
7. If additional lateral exposure or better 3D access is needed, consider a traditional, sublabial Caldwell-Luc antrostomy.
8. Removal of the posterior portion of the inferior turbinate or medial maxillectomy may provide additional visual access or space for instrumentation.
9. Dissection can proceed posteriorly to the pterygoid plates and the ET.

Common Errors in Technique

- Adequate exposure is essential in both open and endoscopic techniques.
- Careful attention to tissue planes while elevating the flap is essential to prevent inadvertent injury to the branches of the cranial nerves (e.g., frontal branch of the facial nerve).
- Preservation of reconstructive tissues and their blood supply during exposure is important to maintain reconstructive options.
- Similarly, careful attention to re-establishing these tissue planes in reconstruction is essential for restoring form and function.
- Vascular control is essential in all cases.

POSTOPERATIVE PERIOD

Postoperative Management

Monitoring in an intensive care unit is recommended for at least the night following surgery due to the proximity of dissection to the skull base and neurovascular and intracranial structures.

In all open approaches, the facial nerve is at risk, and postoperative surveillance of the nerve function is essential. If volitional eye closure is incomplete (lagophthalmos), keratoconjuntivitis and even blindness may occur. Moisturization techniques including lubrication, humidity chambers, and taping of the eyelids should be initiated as needed. Tarsorrhaphy or gold/platinum weight placement also may be considered in these patients to prevent chronic exposure.

In endoscopic techniques, patients should be monitored for epistaxis, and nasal bleeding should be evaluated carefully to rule out bleeding from the internal maxillary artery or its branches. Consideration should be given to packing the nasal cavity to reduce the risk of epistaxis and to stabilize any endoscopically placed tissue grafts if used.

In open or endoscopic approaches in which the dura is opened, early recognition of CSF leak is important. Lumbar drainage or re-operation may be indicated.

Complications

- A significant morbidity relates to dysfunction of the trigeminal nerve. Sacrifice of V2 and/or V3 may be required for tumor resection; facial anesthesia puts the patient at risk for self-injury, especially when chewing food and shaving. V1 anesthesia carries a high risk of corneal ulcer and must be managed aggressively. Loss of V3 motor function will lead to malocclusion and mandibular drift but usually does not negatively affect the diet unless numbness is also present.
- Injury to the main trunk of the facial nerve may be caused by transection or excessive traction. It is essential to protect the eye from exposure keratitis in these cases to prevent further morbidity.
- Trismus is common postoperatively, both immediately due to pain and chronically due to pterygoid musculature scarring/fibrosis. Patients should regularly perform jaw-opening exercises to prevent permanent trismus.
- Vascular complications can be severe, especially during or following dissection along the ICA. Bleeding is a risk and can be challenging to control. In cases of ICA injury, ischemic brain injury is possible even with a satisfactory preoperative balloon occlusion test. These patients must be managed diligently to minimize complications.
- Dissection in proximity to the dura places the patient at risk of immediate or delayed postoperative CSF leak.
- Cosmetic deformities may arise even with careful planning of incisions and reconstruction. If the temporalis muscle is sacrificed or transposed, this leads to a depression in the temple that should be reconstructed with a free graft or implant at the time of surgery or at a later date.

Alternate Management Plan

Some neoplasms in this area are susceptible to treatment with external beam radiation with or without chemotherapy. Discussion at a multidisciplinary tumor board will assist in deciding the best and alternate treatment plans.

DISCUSSION

We emphasize that every patient with a lesion involving the ITF deserves an individualized and comprehensive evaluation by a multidisciplinary team, as the biologic behavior and precise extent of the tumor determine the appropriate management. Unless the imaging and clinical picture are pathognomonic (as in glomus tumor cases), it is imperative to attempt to obtain a biopsy-proven pathologic diagnosis prior to undertaking major open or endoscopic surgery.

Evidence-Based Medicine Question

What is the optimal surgical treatment of schwannomas in the infratemporal and parapharyngeal space?

Schwannomas are some of the most common tumors affecting the ITF and parapharyngeal space (PPS). Historically there have been varied philosophies of how schwannomas should be resected; these range from radical resection (of the tumor and the nerve of origin) to partial resection and nerve-sparing

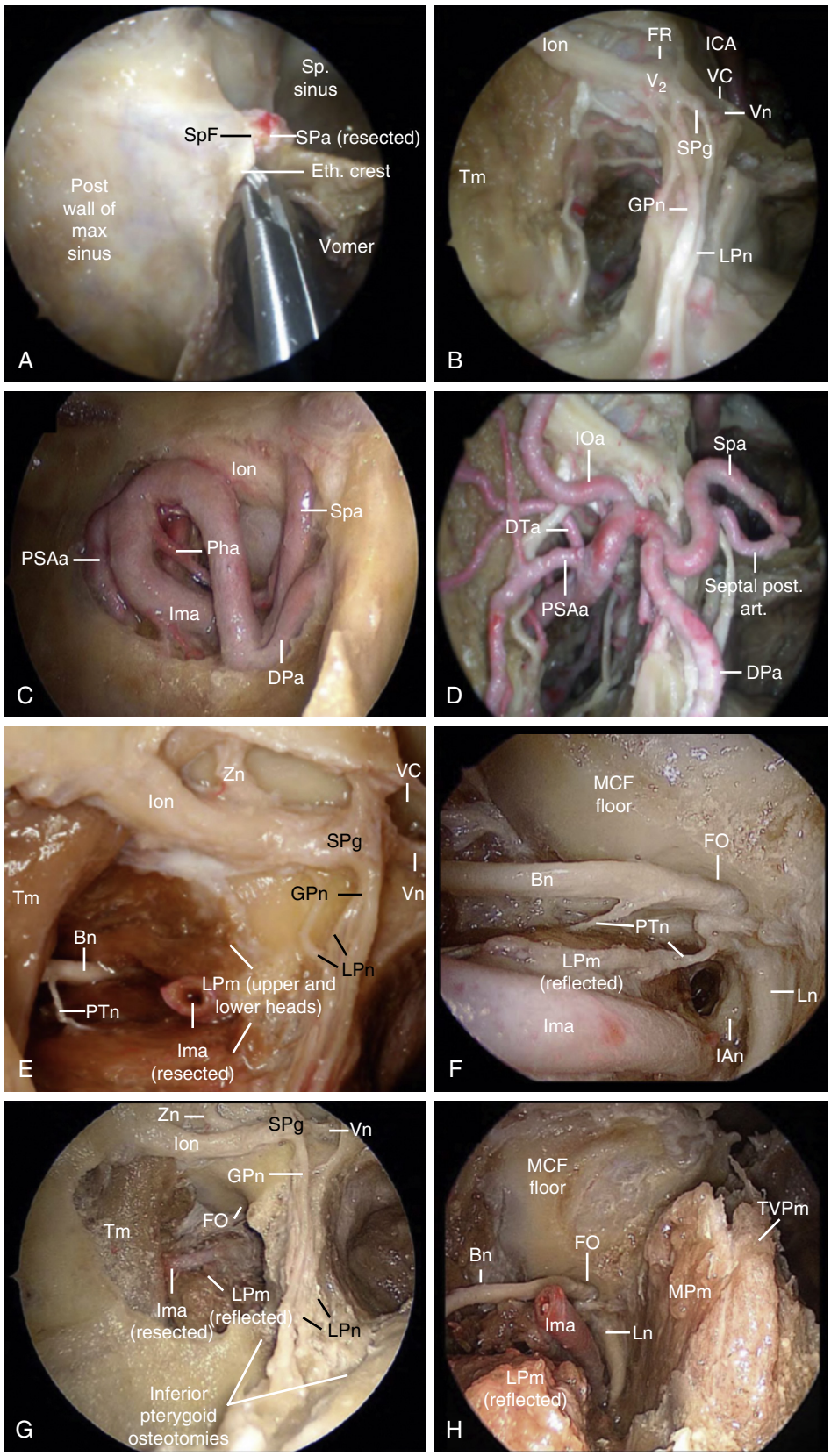
Sp. sinus
SpF
SPa (resected)
Eth. crest
Post wall of max sinus
Vomer
A
Ion
FR
ICA
V2
VC
Vn
SPg
Tm
GPn
LPn
B
Ion
Spa
PSAa
Pha
Ima
DPa
C
IOa
Spa
DTa
PSAa
Septal post. art.
DPa
D
Zn
Ion
VC
SPg
Vn
Tm
GPn
Bn
LPn
LPm (upper and lower heads)
PTn
Ima (resected)
E
MCF floor
FO
Bn
PTn
LPm (reflected)
Ln
Ima
IAn
F
Zn
Ion
SPg
Vn
GPn
Tm
FO
Ima (resected)
LPm (reflected)
LPn
Inferior pterygoid osteotomies
G
MCF floor
TVPm
Bn
FO
MPm
Ima
Ln
LPm (reflected)
H

Fig. 121.5. Endoscopic endonasal approach to the infratemporal fossa *(right side)*. A, The posterior wall of the maxillary sinus and sphenopalatine foramen (SpF) seen after wide antrostomy. The resected sphenopalatine artery is also visualized. **B,** View of the infratemporal fossa (ITF) after removal of the internal maxillary artery and branches. **C,** After removal of the posterior wall of the maxillary sinus, the pterygopalatine fossa is viewed with prominent blood vessels. **D,** The view of the distal third of the internal maxillary artery branches seen after further removal of bone and fat. **E,** The right ITF seen with the transected internal maxillary artery as well as the upper and lower heads of the lateral pterygoid muscles. **F,** V3 is seen exiting from foramen ovale and dividing into the lingual nerve, the inferior alveolar nerve, the buccal nerve, and the lateral pterygoid nerves. The internal maxillary artery is prominently seen. **G,** The view from the nasal cavity into the ITF is enhanced with the removal of the pterygoid plates and the reflection of the lateral pterygoid muscles. **H,** The perspective with the endoscope in ITF showing the transected internal maxillary artery, V3 exiting the foramen ovale with early branching of the buccal nerve and the lingual nerve. Medial pterygoid muscles and tensor veli palatine muscle reflected. art, artery; *Bn*, Buccal nerve; *DPa*, descending palatine artery; *DTa*, deep temporal artery; *Eth*, ethmoid; *FO*, foramen ovale; *FR*, foramen rotundum; *GPn*, greater palatine nerve; *IAn*, inferior alveolar nerve; *ICA*, internal carotid artery; *Ima*, internal axillary artery; *IOa*, infraorbital artery; *Ion*, infraorbital nerve; *Ln*, lingual nerve; *LPm*, lateral pterygoid muscle; *LPn*, lesser palatine nerve; *MCF*, middle cranial fossa; *MPm*, medial pterygoid muscle; *Pha*, pharyngeal artery; *Post*, posterior; *PSAa*, posterosuperior alveolar artery; *PTn*, medial and lateral pterygoid nerves; *Sp*, sphenoid; *Spa*, sphenopalatine artery; *SpF*, sphenopalatine foramen; *SPg*, sphenopalatine ganglion; *Tm*, temporalis muscle; *TVPm*, tensor veli palatine muscle; *VC*, vidian canal; *Vn*, vidian nerve; *Zn*, zygomatic nerve. *(Reproduced from Falcon RT, Rivera-Serrano CM, Miranda JF, et al. Endoscopic endonasal dissection of the infratemporal fossa. Anatomic relationships and importance of eustachian tube in the endoscopic skull base surgery. Laryngoscope, 2011 121:31–41.* http://dx.doi.org/10.1002/lary.21341*. This composite figure, labeled A–H, is borrowed from the following eight figures: Figure 2A, Figure 2B, Figure 3A, Figure 3B, Figure 6A, Figure 6B, Figure 7A, Figure 7B.)*

techniques. Intuitively, radical resection would seem to have the advantage of a lower likelihood of tumor recurrence but often leads to major morbidity, especially when the nerve of origin is functionally complex, as in the case of the high vagus nerve, the facial nerve, or the trigeminal nerve.

Netterville and Groom[6] reviewed their experience with 43 schwannomas, including cervical and parapharyngeal tumors, and reported improved outcomes using a "function-sparing intracapsular enucleation" technique.

The technique involved enucleation of bulky tumors, with sparing of the functionally significant portions of the involved nerve. This was accomplished using EMG in cases of vagal tumors. In such cases, careful EMG mapping allowed the sparing of functionally significant fibers, which were often located near the surface of the tumors, while still achieving adequate resection. The majority of those patients had normal or nearly normal voice outcomes, and no recurrences were observed with 36 months of follow-up. The authors advocated this technique for cervical plexus schwannomas as well.

The authors concluded that "intracapsular enucleation of cervical schwannomas appears to be an effective long-term oncologic treatment while providing significant improvement in functional outcomes. Neural monitoring of motor function provides guidance in neural mapping of the location of the motor nerve fibers on the surface of the tumor. This provides further accuracy in preventing injury to the primary nerve during enucleation. One should consider function-sparing intracapsular enucleation as the treatment of choice for cervical schwannomas in which the primary nerve of origin still has significant neural function."

Whether this approach can be extrapolated, with comparable outcomes, to patients who have high infratemporal or parapharyngeal schwannomas is unclear, but the argument for function-sparing is compelling. Additional considerations for decision making in schwannoma treatment have been summarized by other authors.[7]

Editorial Comment

This chapter captures the complexity and variety of approaches to the ITF. As with most complex areas, there is no single best approach; therefore, a combination of approaches may provide the best exposure with the least morbidity. Although some of these approaches are less familiar, surgeons should be aware of all approaches and be prepared to enlist other surgeons with complementary expertise. The development of endoscopic techniques has had a major positive impact on the management of tumors in the ITF and allows histologic confirmation of most tumors before planning a major operation.

Carl H. Snyderman

Access the review questions and additional sources list online at http://www.expertconsult.com

REFERENCES

1. Carrau R, Vescan A, Snyderman C. Surgical approaches to the infratemporal fossa. In: Myers EN, editor. Operative Otolaryngology: Head and Neck Surgery. 2nd ed. Philadelphia: Saunders Elsevier; 2008, pp. 997–1022.
2. Carrau RL, Kassam AB, Arriaga MA. Anterior and subtemporal approaches to the infratemporal fossa. In Brackmann DE, Shelton C, Arriaga MA (eds). Otologic Surgery, 3rd ed. Philadelphia: Elsevier; 2009, pp. 649–665.
3. Fisch U, Pillsbury HC. Infratemporal fossa approach to lesions in the temporal bone and base of the skull. Arch Otolaryngol 1979;105:99–107.
4. Nuss D. Facial translocation approach to the central cranial base. In: Snyderman C, Gardner P, editors. Master Techniques in Otolaryngology—Head and Neck Surgery: Skull Base Surgery. Philadelphia: Wolters Kluwer; 2015.
5. Rivera-Serrano CM, Terre-Falcon R, Fernandez-Miranda J, et al. Endoscopic endonasal dissection of the pterygopalatine fossa, infratemporal fossa, and post-styloid compartment. Anatomical relationships and importance of the eustachian tube in endoscopic skull base surgery. Laryngoscope 2010;120. S244–S244.
6. Netterville JL, Groom K. Function-sparing intracapsular enucleation of cervical schwannomas. Curr Opin Otolaryngol Head Neck Surg 2015;23:176–179.
7. Burke E, Nuss D. Schwannomas of the skull base. In: Hanna EY, DeMonte F, editors. Comprehensive Management of Skull Base Tumors. New York: Informa Healthcare; 2008. pp. 513–538.

REVIEW QUESTIONS

1. Which of the following structures is in the ITF?
   a. V2
   b. V3
   c. Internal carotid artery
   d. All of the above
   e. b and c only

2. Which of the following are important considerations in choosing a surgical approach to the ITF?
   a. Exact location of the tumor
   b. Involvement of the internal carotid artery
   c. Involvement or dysfunction of cranial nerves V, VII, IX–XII
   d. Biologic behavior of the tumor
   e. All of the above

3. You have just taken down the posterior wall of the maxillary sinus. What space is now exposed and which important vascular structure should be identified next?
   a. ITF, anterior ethmoid artery
   b. ITF, sphenopalatine artery
   c. Pterygopalatine fossa, anterior ethmoid artery
   d. Pterygomaxillary fissure, sphenopalatine artery
   e. ITF, internal maxillary artery

ADDITIONAL SOURCES

Falcon RT, Rivera-Serrano CM, Miranda JF, et al. Endoscopic endonasal dissection of the infratemporal fossa. Anatomic relationships and importance of eustachian tube in the endoscopic skull base surgery. Laryngoscope 2011;121:31–41. http://dx.doi.org/10.1002/lary.21341.

Janecka IP, Sen CN, Sekhar LN. Arriaga M: Facial translocation: a new approach to the cranial base. Otolaryngol Head Neck Surg 1990;103:413–419.

Netterville JL, Groom K. Function-sparing intracapsular enucleation of cervical schwannomas. Curr Opin Otolaryngol Head Neck Surg 2015;23:176–179.

Persky M, Manolidis S. Vascular tumors of the head and neck. In: Johnson J, Rosen C, editors. Bailey's Head and Neck Surgery—Otolaryngology. 5th ed. Philadelphia: Lippincott Wolters Kluwer; 2014.

Sekhar LN, Schramm VL, Jones NF. Subtemporal-preauricular infratemporal fossa approach to large lateral and posterior cranial base neoplasms. J Neurosurg 1987;67:488–499.

122 Juvenile Angiofibroma

Carl H. Snyderman, Harshita Pant, Paul A. Gardner

INTRODUCTION

Juvenile angiofibroma (JNA) is a rare, benign tumor that is found almost exclusively in adolescent males.[1] The pathogenesis of JNA remains undefined, although hormonal and genetic factors have been implicated. JNA arises in the lateral nasopharynx near the sphenopalatine foramen and can spread in multiple directions to the nasal cavity, oropharynx, paranasal sinuses, orbit (via inferior orbital fissure), and infratemporal fossa (via pterygomaxillary fissure). Intracranial extension occurs through the skull base foramina and by the erosion of bone. Early symptoms include unilateral nasal obstruction and recurrent unilateral epistaxis. Large tumors can displace normal structures, resulting in facial swelling, proptosis, diplopia, visual loss, and facial hypesthesia. The primary treatment is surgical excision, with endoscopic surgery replacing open approaches for most tumors. The greatest challenge in surgery is bleeding caused by the hypervascular nature of JNA. Treatment options for recurrent tumor include surgery or radiation therapy (RT).

KEY OPERATIVE LEARNING POINTS

- Unilateral nasal obstruction and recurrent epistaxis in an adolescent male is suggestive of angiofibroma.
- Diagnosis can be established radiographically without biopsy in most cases.
- Staging and surgical planning should consider residual vascularity following embolization.
- Preoperative embolization of the tumor's blood supply reduces intraoperative bleeding.
- The base of the pterygoid plate is a frequent site of recurrence and should be drilled to remove all remnants of the tumor.
- An anterior endoscopic approach can be augmented with a transmaxillary approach.
- A lateral infratemporal approach can be combined with an anterior approach to provide access to the middle cranial fossa.
- Large tumors should be divided into vascular segments and may require multiple staged surgeries.
- Residual tumor on follow-up scans should be observed for growth; not all residual tumors require additional treatment.

PREOPERATIVE PERIOD

History

- Nasal obstruction (unilateral or bilateral)
- Recurrent epistaxis
- Facial swelling
- Diplopia
- Numbness of the face (V2 distribution)
- Pain in the face/sinus pressure
- Hearing loss.

Physical Examination

- Nasal endoscopy: reddish, smooth lobulated mass occupying the posterior nasal cavity
- Swelling of the cheek or temporal area
- Proptosis or displacement of the globe
- Middle ear effusion with conductive hearing loss
- Hypesthesia of the maxillary division of the trigeminal nerve.

Imaging

- Computed tomography (CT) with contrast (Fig. 122.1)
  CT is the preferred initial imaging modality since it demonstrates the vascular nature of the tumor and the bony architecture of the sinuses, orbit, and skull base. A characteristic feature of JNA is widening of the pterygopalatine space with remodeling of the posterior wall of the maxillary sinus. For surgical planning, a CT angiogram is obtained (skull base protocol with navigation protocol) for demonstration of the carotid artery and bony landmarks.
- Magnetic resonance imaging (MRI) (Fig. 122.2)
  MRI shows the interface of tumor with soft tissues (orbit, masticator space, dura) when there is bony erosion or extension of the tumor through the foramina. It can also differentiate the tumor from obstruction of a sinus with retained secretions. Without MRI, CT can be misleading, suggesting an aggressive neoplasm, such as a sarcoma.
- Angiography
  Angiography is not necessary in most cases but helps to confirm the diagnosis (characteristic hypervascularity of JNA) and demonstrates the blood supply of the tumor. The blood supply is usually derived from branches of the external carotid artery (internal maxillary and ascending pharyngeal arteries) and is often bilateral in larger tumors. Advanced tumors also



Fig. 122.1. Computed tomography (CT) scan of juvenile angiofibroma (JNA) (UPMC stage V) demonstrates bony erosion with extension of tumor to the orbits and cranial cavity. CT is superior for the visualization of bone and for estimating the vascularity of the tumor.

receive blood supply from the internal carotid artery (ICA) via the vidian artery and cavernous branches (Fig. 122.3). For advanced tumors with skull base involvement and proximity to the ICA, angiography is important to assess collateral intracranial circulation (competency of the circle of Willis).

Indications

- Surgery is the treatment of choice for all JNA, even advanced tumors with intracranial extension.



Fig. 122.2. Magnetic resonance imaging (MRI) of juvenile angiofibroma (JNA) (UPMC stage V) is superior for the interface of the tumor with soft tissue planes. The internal carotid arteries *(arrows)* and tumor vasculature appear as flow voids.

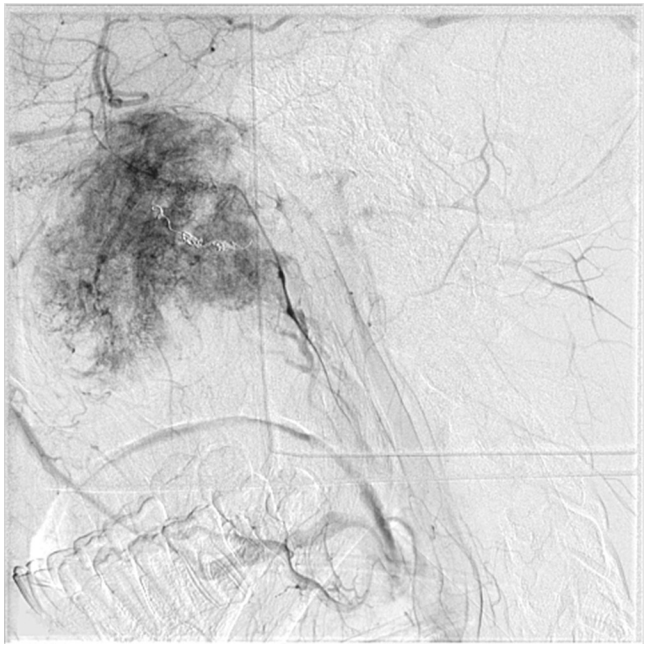

Fig. 122.3. Angiography demonstrates a large amount of residual vascularity from the internal carotid artery following embolization of the internal maxillary artery (see coils in proximal trunk).

Contraindications

- Residual or recurrent tumor that is not growing can be observed.
- A prohibition against blood products (Jehovah's Witness) is a relative contraindication for an advanced tumor with residual vascularity following embolization.
- Medical condition that precludes surgery.

Preoperative Preparation

- Biopsy
  Histologic confirmation is not necessary unless there are atypical radiological features suggestive of malignancy (sarcoma). If a biopsy is necessary, it should be performed under general anesthesia with control of the airway.
- Embolization of the tumor
  Bilateral angiography is performed the day before surgery to identify and embolize the blood supply to the tumor. We prefer to use Onyx due to its superior penetration of tissues.[2] Coils are placed in the proximal internal maxillary arteries. For small tumors, an alternative to embolization is surgical ligation of the internal maxillary artery lateral to the tumor margin at the beginning of the operation.
- Staging
  A variety of staging systems have been proposed over the years for JNA. Only one staging system considers the vascularity of the tumor (University of Pittsburgh Medical Center (UPMC) staging system).[3,4] There are five stages based on tumor extent and residual vascularity following the embolization of blood supply from the external carotid artery (Table 122.1). Bleeding from the tumor is the greatest risk factor for complications during surgery, and the UPMC staging system provides superior prediction of intraoperative blood loss and risk of residual/recurrent tumor.
- Balloon test occlusion of ICA
  If there is tumor encasement of the ICA, assessment of the adequacy of collateral circulation can be done with balloon test occlusion with neurological monitoring. This knowledge can guide the management of the patient in case there is injury to the ICA during surgery. Fortunately, most young patients can tolerate sacrifice of the ICA if necessary.
- Perioperative blood loss
  Despite adequate embolization, packed red blood cells should be available for transfusion. If desired, directed donors can be used for homologous transfusions. In older patients, surgery can be delayed for several weeks to allow banking of autologous blood for transfusion. When a large amount of blood loss is anticipated, a cell-saver device may be used to recycle the patient's own blood collected during surgery.

OPERATIVE PERIOD

Anesthesia

- General anesthesia with oral intubation.

Positioning

- Supine
- Mayfield headholder
  If intraoperative navigation is used for skull base involvement, the head can be fixed in a Mayfield head holder to maintain accuracy of navigation, to stabilize the head for the drilling of bone, and to improve positioning.

Perioperative Antibiotic Prophylaxis

- Second-generation cephalosporin
- Third-generation cephalosporin if there is a risk of opening the dura.

TABLE 122.1 UPMC Staging System for Juvenile Nasopharyngeal Angiofibroma

Stage	UPMC Staging System
I	Nasal cavity, medial pterygopalatine fossa
II	Paranasal sinuses, lateral pterygopalatine fossa No residual vascularity
III	Skull base erosion, orbit, infratemporal fossa No residual vascularity
IV	Skull base erosion, orbit, infratemporal fossa Residual vascularity
V	Intracranial extension, residual vascularity M: medial extension L: lateral extension

Monitoring

- Somatosensory evoked potentials (SSEPs)
  SSEPs provide a measure of cortical function and are a sensitive indicator of ischemia due to changes in blood pressure. SSEPs are measured when dissection of the ICA is anticipated.
- Electromyography (EMG)
  EMG of the cranial nerves, most commonly III, IV, VI, and V_3, aids in identification and preservation of function.

Instruments and Equipment to Have Available

- Endoscopic sinus surgery set
- Maxillofacial instruments for transmaxillary approach
- Doppler probe for identification of ICA
- Nerve stimulator for EMG
- Endoscopic bipolar electrocautery
- Endoscopic drill
- Harmonic scalpel
- Navigation system.

Key Anatomic Landmarks

- Pterygoid canal
  The pterygoid base is the site of origin of JNA and must be drilled to prevent recurrence from the tumor infiltrating the spaces in the bone (Fig. 122.4). The pterygoid canal containing the vidian nerve and artery is located inferomedial to the lateral recess of the sphenoid sinus and is immediately behind the sphenopalatine foramen. The pterygoid canal with the vidian nerve is an important landmark for exposure of the petrous segment of the ICA.[5]
- Greater palatine nerve
  The greater palatine nerve contains sensory branches of the maxillary nerve and parasympathetic fibers from the pterygopalatine ganglion. It descends in a bony canal just deep to the sphenopalatine foramen. The nerve is often stretched over the surface of the tumor and the contents of the pterygopalatine space must be dissected from the surface of the tumor in a medial to lateral direction to preserve this nerve. Injury to the greater palatine nerve results in ipsilateral numbness of the palate.
- Infraorbital nerve
  The infraorbital nerve is often displaced superiorly by the tumor eroding the floor of the orbit. This sensory nerve is a terminal branch of the maxillary nerve and must be preserved to prevent numbness of the cheek.
- Foramen rotundum
  The maxillary nerve exits foramen rotundum superolateral to the lateral recess of the sphenoid sinus.
- Foramen ovale
  The mandibular nerve exits the foramen ovale inferior to the foramen rotundum and posterior to the lateral pterygoid plate.

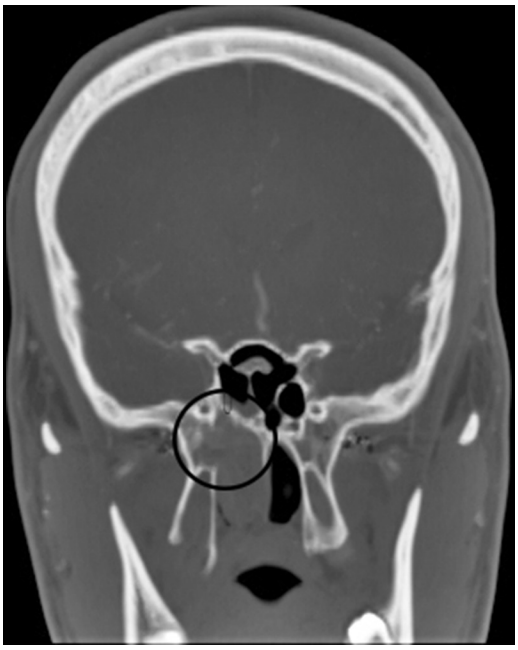

Fig. 122.4. Coronal computed tomography (CT) demonstrating characteristic tumor invasion of the base of the pterygoid *(black circle)* around the pterygoid canal. The normal relationship of the pterygoid canal and foramen rotundum are visible on the contralateral side.

Prerequisite Skills

- Endoscopic sinus surgery
- Caldwell Luc approach
- Medial maxillectomy.

Operative Risks

- Numbness of the palate (greater palatine nerve)
- Facial hypesthesia (infraorbital nerve) of the middle third of the face
- Injury to the mandibular nerve resulting in facial hypesthesia of the lower third of the face and weakness of the muscles of mastication
- Acute anemia due to blood loss
- ICA injury
- Dry eye (loss of emotional tearing) due to sacrifice of the vidian nerve
- Cerebrospinal fluid leak.

Surgical Technique

The choice of surgical approach depends on the stage of the tumor (extent and vascularity). UPMC stage I and II tumors can be removed using a completely endoscopic endonasal approach. Larger tumors with residual vascularity will require augmentation with a transmaxillary approach. Tumors with lateral extension to the middle cranial fossa or infratemporal area may benefit from a combined anterior and lateral (infratemporal) approach. Palatal incision, LeFort I osteotomy, lateral rhinotomy, and facial translocation are approaches that have been largely supplanted by endoscopic techniques. The choice of approach also depends on the characteristics of the patient (age, size) and the experience of the surgeon with different approaches.

Endoscopic Endonasal Approach

- The nasal cavity is decongested with cottonoid pledgets soaked in 0.05% oxymetazoline.

- Nasal endoscopy is performed to assess the extent of the tumor.[6] (Video 122.1)
- A large middle meatal antrostomy is performed on the side of the tumor.
- The antrostomy is enlarged posteriorly and the sphenopalatine foramen is identified. Overlying bone is removed with Kerrison rongeurs (1 to 2 mm) to expose the pterygopalatine space. The bone is often remodeled by the tumor and is very thin. The removal of bone extends lateral to the margin of the tumor and superiorly toward foramen rotundum.
- An ethmoidectomy is performed on the side of the tumor. The inferior portion of the middle turbinate is resected with sinus scissors or thru-cutting ethmoid forceps. Removal of ethmoid air cells continues posteriorly with exposure of the roof of the ethmoid and the medial wall of the orbit. If possible, the anterior wall of the sphenoid sinus is opened superior to the tumor. Care is taken to avoid any instrumentation of the tumor, although its surface can be bluntly dissected from the anterior cranial base and gently displaced inferiorly.
- If there is bleeding from the surface of the tumor, it is best controlled with bipolar electrocautery.
- On the contralateral side, the mucosa of the posterior septum is cauterized and transected to expose the sphenoid rostrum. A sphenoidotomy is performed with removal of the rostrum to provide binarial access.
- Mucosal margins in the nasopharynx are incised with needle-tip monopolar electrocautery. This facilitates final detachment of the tumor as it is delivered into the nasopharynx.
- Now that there is circumferential access to the tumor, the pterygopalatine space is dissected to expose the lateral margin of the tumor. The overlying tissues are dissected from medial to lateral in order to preserve the greater palatine nerve, which is often displaced anteriorly by the tumor. Dissection proceeds on the surface of the tumor with delivery of nodules of tumor from the masticator space and posterior to the maxilla.
- The sphenoid component of the tumor is separated from the walls of the sphenoid sinus using blunt dissection. It is important to have good visualization of the optic canal and the course of the ICA.
- The last area of attachment is the pterygoid base where there is often infiltration of the tumor into the spaces of the bone, and there may be some blood supply from the vidian artery. The tumor is bluntly dissected from the bone and the vidian artery (and nerve) is cauterized using bipolar electrocautery.
- The entire tumor can then be delivered transorally or cut into smaller pieces. Large tumors can be divided into vascular segments using ultrasonic (Harmonic scalpel, Ethicon) and radiofrequency (Coblation, Smith & Nephew) ablation.
- The last step is to drill the bone of the pterygoid circumferentially around the pterygoid canal to remove all vestiges of the tumor. If necessary, the bone can be drilled to the plane of the petrous ICA.
- Hemostasis is obtained with bipolar electrocautery, topical application of absorbable gelatin powder (Surgifoam, Ethicon), and warm saline irrigation. Exposed surfaces are covered with fibrin glue (Tisseal).

Transmaxillary Approach

- A medial maxillectomy is performed endoscopically (see Chapter 106). The inferior turbinate is cauterized and transected with straight sinus scissors. The posterior stump is cauterized with suction electrocautery.
- The medial wall of the maxillary sinus is resected with backbiting forceps and drilled to the level of the floor of the nose. The nasolacrimal duct is preserved anteriorly.
- If additional lateral access is necessary, an anteromedial maxillotomy is performed. The soft tissues at the pyriform aperture are incised with electrocautery and the periosteum is elevated with a Cottle elevator from the edge of the bone and the anterior wall of the maxilla.
- The vertical edge (1 to 2 cm) of the anteromedial maxilla is removed by drilling or the use of a bone rongeur. Bone removal extends across the anterior wall of the maxilla.
- An alternative to an anteromedial maxillotomy is an anterior maxillotomy (Caldwell Luc approach—see Chapter 104).
- Additional bone is removed from the posterolateral wall of the maxilla to gain access to the masticator space and the lateral limit of the tumor. The tumor can be dissected off the infraorbital nerve and the floor of the orbit.

Infratemporal Skull Base Approach

- A hemicoronal scalp incision is made with extension to the pre-auricular area (see Chapter 121).
- The scalp is elevated superficial to the deep temporal fascia with preservation of the temporal branches of the facial nerve.
- The periosteum is incised along the lateral orbital rim and zygomatic arch. The masseter muscle is separated from the inferior margin of the zygomatic arch with electrocautery. The periorbita is elevated from the lateral wall of the orbit and the inferior orbital fissure is identified.
- A reciprocating saw is used to make an osteotomy in the zygomatic arch posteriorly and the lateral wall of the orbit. The final osteotomy across the malar eminence, connecting to the inferior orbital fissure, releases the orbitozygomatic bone segment for removal as one unit.
- The temporalis muscle is reflected inferiorly.
- A subtemporal craniectomy is performed to gain access to the middle cranial fossa. Foramen ovale and V3 are identified and preserved.
- The infratemporal extension of the tumor is identified and a plane of dissection is developed deep to the temporalis muscle and pterygoid muscles.
- If coverage of the ICA or dura is needed following the removal of the tumor, the anterior half of the temporalis muscle can be transposed into the defect (see Chapter 168).

Common Errors in Technique

- Inadequate exposure
  Exposure is enhanced with a medial maxillectomy and bilateral sphenoidotomies. A Caldwell Luc approach provides added room for instrumentation, especially the introduction of bipolar electrocautery forceps.
- Early violation of the tumor capsule
  Dissection of the tumor before the margins have been completely exposed results in troublesome bleeding.
- Failure to find a plane of dissection in the pterygopalatine space
  In order to preserve the sensory branches of V2, it is necessary to find the plane of dissection medially and to dissect the contents of the pterygopalatine space from the surface of the tumor in a medial to lateral direction.
- Incomplete drilling of pterygoid base
  It is easy to miss small remnants of tumor hidden in the spaces of the pterygoid base.
- Missing tumor nodules behind the maxilla
  Small tumor nodules may extend inferior to the plane of the maxilla in the pterygopalatine space and must be delivered into the surgical field with grasping forceps. It is sometimes helpful to manually palpate the soft tissues intraorally to help to deliver the tumor into the surgical field.

POSTOPERATIVE PERIOD

Postoperative Management

- Nasal packing can be removed after 1 to 2 days if there is no bleeding.
- Antibiotics are continued as long as nasal packing is in place.
- Silastic septal splints are removed at 1 week.
- An oral diet is resumed on the first postoperative day. If a Caldwell Luc approach was used, oral hygiene with a chlorhexidine rinse is prescribed.
- Saline nasal sprays are instituted immediately postoperative and are continued until healing is complete. Saline rinses are started 1 week later.
- Patients are seen in the office at 1 week and then at increasing intervals for debridement of intranasal crusts.
- If trismus is present, patients are encouraged to do gentle stretching exercises.

Complications

- Intraoperative hemorrhage[6]
  Advanced-stage tumors with residual vascularization (UPMC stage IV/V) can bleed briskly. Bipolar electrocautery is more effective than monopolar electrocautery. Vascular segments of the tumor should be addressed sequentially to control blood loss. If intraoperative blood loss is excessive, the surgery may need to be staged by packing the surgical cavity.
- ICA injury
  The greatest risk for vascular injury is poor visualization due to bleeding. When the tumor is in close proximity to the ICA, avulsion of tumor vessels should be avoided since this may cause a perforation on the surface of the ICA. A small hole on the surface of the ICA can be controlled with bipolar electrocautery. The vidian nerve within the pterygoid canal is an important landmark for the petrous ICA.
- Cerebrospinal fluid (CSF) leak
  Dural invasion is rare and most tumors are easily separated from the dura. If a dural tear occurs, this can be repaired using inlay and onlay fascial graft techniques with the placement of an adipose tissue graft to provide support.
- Postoperative hemorrhage
  Postoperative hemorrhage is usually due to unembolized branches of the external carotid artery and can be controlled with nasal packing. A sentinel bleed from the ICA should be ruled out with angiography if there was intraoperative injury to the ICA.
- V2 injury
  Hypesthesia of the midface and palate is the most common complication of surgery. The greater palatine and infraorbital nerves should be identified early and protected to avoid injury.
- V3 injury
  Injury to V3 results in hypesthesia of the lower face and weakness of the muscles of mastication. The nerve is at risk with large tumors that invade the middle fossa or extend posterior to the pterygoid plates.
- Orbital injury
  The extraocular muscles may be injured when dissecting tumors that involve the infraorbital nerve canal or extend into the inferior orbital fissure.
- Visual loss
  The optic nerve is at risk when there is erosion of the optic canal within the sphenoid sinus or tumor extension into the orbital apex. Electrocautery should be avoided in proximity to the nerve, and the drilling of bone over the optic canal should be done with constant irrigation.
- Dry eye
  Sacrifice of the vidian nerve decreases emotional tearing from that eye. Although most patients will not notice a difference, dryness of the eye may result in patients with decreased tearing due to other causes.
- Trismus
  Dissection of the pterygoid muscles will cause transient trismus from inflammation. Late trismus due to scarring can be overcome with stretching devices (Therabite).
- Residual tumor[7]
  The risk of residual tumor is associated with stage. Most common sites for residual tumor include the cavernous sinus, middle cranial fossa, and masticator space. Risk factors include inadequate exposure, poor visualization due to bleeding, failure to dissect on the plane of the tumor, large multilobulated tumors, and prior treatment (surgery or RT).

Alternative Management Plan

- Surgery is the preferred treatment due to the benign nature of the disease and the long-term sequelae of RT in a young population. If a complete resection is not possible due to proximity to critical structures, a subtotal resection may be entertained. Small remnants of tumor may not grow and can be monitored until significant growth is observed.
- RT is rarely indicated for JNA. It may be considered for a poor surgical candidate due to medical co-morbidities or refusal of surgery. Patients with advanced-stage tumors who refuse transfusion of blood products may be offered RT. Tumors that are considered unresectable due to intracranial extension or involvement of critical structures may be candidates for RT, but subtotal resection with RT for the residual component may be a strategy to limit the field and dose. However, resectability is a subjective judgment, and patients should be referred to Centers of Excellence that have extensive surgical experience with the management of JNA.
- Chemotherapy and hormone therapy are not effective.

DISCUSSION

Evidence-Based Medicine Question

Are surgical outcomes better with endoscopic surgery for JNA?

Boghani Z, Husain Q, Kanumori VV, et al: Juvenile nasopharyngeal angiofibroma: a systematic review and comparison of endoscopic, endoscopic-assisted, and open resection in 1047 cases. Laryngoscope 2013;123:859–869.

This is a systematic review of treatment outcomes for JNA that compared endoscopic, endoscopic-assisted, and open surgical approaches. Endoscopic resection had decreased blood loss and a lower recurrence rate compared with open resection. However, after adjusting for tumor grade (Radkowski/Sessions tumor stage), there was no difference in recurrence rates.

Editorial Comment

The greatest challenge of surgery for JNA is dealing with intraoperative hemorrhage, especially for advanced-stage tumors with residual vascularity from the ICA following embolization of the external carotid artery system. These tumors are best treated by a team of skull base surgeons so that one surgeon has two hands free for tumor dissection while the second provides endoscopic visualization. Experience with treating other skull base tumors in proximity to neurovascular structures is valuable in translating expertise to the management of JNA.

Eric W. Wang

Access the review questions and additional sources list online at http://www.expertconsult.com

REFERENCES

1. Lopez F, Triantafyllou A, Snyderman C, et al. Nasal juvenile angiofibroma: current perspectives with emphasis on management. Head Neck 2017 May;39(5):1033–1045.
2. Lutz J, Holtmannspötter M, Flatz W, et al. Preoperative embolization to improve the surgical management and outcome of juvenile nasopharyngeal angiofibroma (JNA) in a single center: 10-year experience. Clin Neuroradiol 2016;26(4):405–413.
3. Snyderman CH, Pant H, Carrau RL, et al. A new endoscopic staging system for angiofibromas. Arch Otolaryngol Head Neck Surg 2010;136(6):588–594.
4. Alshaikh NA, Eleftheriadou A. Juvenile nasopharyngeal angiofibroma staging: an overview. Ear Nose Throat J 2015;94(6):E12–E22.
5. Kasemsiri P, Solares CA, Carrau RL, et al. Endoscopic endonasal transpterygoid approaches: anatomical landmarks for planning the surgical corridor. Laryngoscope 2013;123(4):811–815.
6. Snyderman CH, Pant H. Endoscopic management of vascular sinonasal tumors, including angiofibroma. Otolaryngol Clin North Am 2016;49(3):791–807.
7. Rowan NR, Stapleton AL, Heft-Neal ME, et al. The natural growth rate of residual juvenile nasopharyngeal angiofibroma. J Neurol Surg B 2016;77(S1):S17–S18.

REVIEW QUESTIONS

1. The most important prognostic factor for the staging of JNA is:
   a. Size of the tumor
   b. Erosion of the skull base
   c. Vascular supply from the ICA
   d. Bilateral extension

2. Which of the following are absolute indications for RT?
   a. Blood supply from the ICA
   b. Intracranial extension
   c. Patient refusal of blood products
   d. Residual tumor in the cavernous sinus
   e. None of the above

3. Strategies for minimizing blood loss during surgery include all of the following except:
   a. Preoperative embolization
   b. Early debulking of the tumor
   c. Bipolar electrocautery
   d. Dividing large tumors into vascular territories

4. Which of the following statements is false?
   a. The pterygoid canal is an important landmark for the petrous ICA
   b. It is important to drill the base of pterygoid to remove all remnants of tumor
   c. The pterygoid canal transmits the greater palatine nerve
   d. Sacrifice of the vidian nerve causes vasomotor rhinitis

5. Which of the following is most likely after surgery for JNA?
   a. Loss of ipsilateral emotional tearing
   b. Anesthesia of the palate
   c. Diplopia
   d. Horner syndrome

ADDITIONAL SOURCES

Ashour R, Aziz-Sultan A. Preoperative tumor embolization. Neurosurg Clin North Am 2014;25(3):607–617.
This review provides a comprehensive summary of embolization materials and techniques for the management of a variety of vascular tumors, including JNA.
Carrau R, Snyderman C, Kassam A. Juvenile angiofibroma. In: Myers E, editor. Operative Otolaryngology Head and Neck Surgery. 2nd ed. Philadelphia: Elsevier; 2008. p. 39–50.
The chapter on JNA from the previous edition of *Operative Otolaryngology Head And Neck Surgery* provides an excellent description of non-endoscopic approaches.

123 Transnasal and Transoral Approaches to the Cervical Spine

Carl H. Snyderman, Paul A. Gardner

INTRODUCTION

The superior aspects of the cervical spine (C1 and C2) and the craniovertebral junction are difficult to access via a transcervical approach. Traditionally, a transoral/transpalatal approach has been used, but is associated with significant morbidity. With the advent of endoscopic techniques, a transnasal approach may be used with improved visualization and avoidance of the morbidity associated with a transoral approach.[1,2] For lesions that require access from the lower clivus to C3, a combined approach can be employed.

Transnasal and transoral approaches to the upper cervical spine and craniovertebral junction are most commonly performed for basilar invagination with brainstem compression. This may be the result of rheumatoid degeneration with pannus formation, or traumatic fracture and dislocation of the odontoid. A transodontoid approach also provides access to tumors at the jugular foramen and adjacent areas.

KEY OPERATIVE LEARNING POINTS

- With a transnasal route, resection of the posterior nasal septum as far as the nasal floor is necessary to provide adequate lateral access.
- Resection of the nasopharyngeal mucosa and underlying muscle and fascia improves the exposure of C1 and C2.
- Removal of a thickened pannus should be performed until transmitted pulsations are evident; complete removal risks a cerebrospinal fluid (CSF) leak.
- The inferior extent of the transnasal approach is limited by the posterior edge of the hard palate.
- A palatal incision can usually be avoided by retraction of the soft palate into the nasopharynx.
- A paramedian palatal incision preserves the blood supply to the palate and minimizes scar retraction of the palate.
- Patients with preoperative pharyngeal dysfunction are at increased risk for airway problems and should have a tracheostomy performed at the time of their operation.
- Patients with cervical instability should undergo neurophysiological monitoring during positioning and throughout surgery to avoid injury to the spinal cord.
- Retropharyngeal dissection lateral to the Eustachian tube should be avoided because of the risk of injury to the internal carotid artery (ICA).

PREOPERATIVE PERIOD

History

- Prior nasal or sinus surgery
- Cranial nerve dysfunction: hoarseness, aspiration, dysphagia, dysarthria
- Symptoms of spinal compression: long-tract signs with weakness

Physical Examination

- Nasal cavity: septal deviation, inflammatory sinus disease, prior sinus surgery
- Nasopharynx: velopharyngeal closure, retropharyngeal carotid pulsations
- Oral cavity: dentition, palate
- Larynx: laryngeal function
- Cranial nerves: X, XI, XII

Imaging

- Computed tomography (CT) scan. CT provides evidence of bone destruction from infection or neoplasm. CT angiography for navigation is preferred for the demonstration of the carotid and vertebral arteries.
- Magnetic resonance imaging (MRI) (Fig. 123.1). This is superior for soft tissue imaging, especially of the pannus and brain stem compression. Chordomas and chondrosarcomas appear bright on T2-weighted images.

Indications

- Infection
  - Localized retropharyngeal abscess
- Trauma
  - Displaced fracture of C1 and C2 with spinal cord compression



Fig. 123.1. Sagittal plane magnetic resonance imaging demonstrates basilar invagination and brainstem compression (arrow).

- Inflammation
  - Rheumatoid pannus with basilar invagination and compression of the brainstem (Fig.123.1)[3]
- Neoplasms (Fig. 123.2)
  - Chordoma
  - Chondrosarcoma
  - Meningioma
  - Nasopharyngeal carcinoma

Contraindications

- Intranasal Approach
  - Neoplastic involvement of the spine inferior to the nasopalatine line.
  - Intradural dissection should be avoided in the presence of active infection. Sinusitis should first be treated medically or surgically, if possible.
- Transoral Approach
  - Trismus
  - Fully restored teeth
  - Excessive soft tissue in the pharynx

Preoperative Preparation

- Treatment of sinusitis
- Treatment of aspiration pneumonia

OPERATIVE PERIOD

Anesthesia

- The airway should be evaluated preoperatively for potential difficulty of intubation and consideration of airway options. Increased difficulty of intubation because of cervical instability may be encountered. There is also a risk of accidental extubation with the repositioning of the patient for posterior cervical fusion if performed during the same operative setting.

Positioning

- The patient's head is fixed in a Mayfield clamp in a neutral position. Neurophysiological monitoring is performed before and after positioning.



Fig. 123.2. Neoplasms at the level of the foramen magnum *(arrow)* are most commonly chordomas, chondrosarcomas, or meningiomas.

Perioperative Antibiotic Prophylaxis

- Third-generation cephalosporin with CSF penetration.

Monitoring

- Somatosensory evoked potentials (SSEP) provide an overall measure of cortical brain function. Baseline responses should be established before positioning if there is brainstem compression or cervical instability.
- Brainstem evoked responses (BSER) to monitor brain stem function also may be indicated. Cervical instability during repositioning requires continued monitoring.
- Electromyography (EMG) of lower cranial nerves can help with intraoperative identification of nerves and prevention of injury.
- Navigation system: the cervico-medullary junction is included in the imaging.

Instruments and Equipment to Have Available

- Intranasal Approach
  - Basic endoscopic sinus surgery set
  - Endoscopic surgical drill with 4 mm coarse diamond burs
  - Ultrasonic aspirator (optional)
- Transoral Approach
  - Dingman or Crockard mouth retractor
  - Red rubber tube
  - Cloward-style soft tissue retractor

Key Anatomic Landmarks

- The nasopharynx is bounded by the Eustachian tubes and parapharyngeal carotid arteries laterally. The arteries are deep to the fossa of Rosenmüller. Ectatic arteries may protrude into the retropharyngeal space.
- Passavant's ridge is a U-shaped muscular sphincter of the pharynx that forms the contact point for the soft palate with swallowing.
- The nasopalatine line is a virtual line from the inferior aspect of the nasal bones to the posterior edge of the hard palate. Extension of this line posteriorly crosses C2 and defines the inferior limit of the endoscopic endonasal approach.
- The dominant blood supply to the palatal mucosa is derived from the greater palatine arteries. The greater palatine foramen is adjacent to the second molar.
- The dens or odontoid process is covered by the arch of C1 anteriorly.
- The vertebral bodies are covered by the paraspinal muscles anteriorly (longus capitis and longus colli).
- The bone of the clivus thins as it approaches the foramen magnum.

Prerequisite Skills

- Endoscopic sinus surgery
- Tonsillectomy

Operative Risks

- CSF leak
  With the transnasal approach, there is a greater risk of a dural opening and CSF leak if dissection is performed in the region of the occipital condyle superolaterally.
- Injury to the parapharyngeal ICA
  The extracranial parapharyngeal segment of the ICA is lateral to the fossa of Rosenmüller and deep to the Eustachian

tube. On occasion, a tortuous ICA may course medially in the retropharyngeal area. This is a relative contraindication to a transoral approach, but would not preclude a transnasal approach.

- Injury to the vertebral artery
  Far lateral dissection at the level of C1 and C2 may injure the vertebral artery and should be performed only under image guidance.

Surgical Technique

Transnasal Approach

- The inferior turbinates are lateralized to improve access to the nasopharynx.
- Landmarks are identified with the aid of navigation to identify the proximity of the ICAs and the level of the arch of C1.
- Needle-tip electrocautery is used to incise the nasopharyngeal mucosa to expose the underlying paraspinal muscles (longus capitis and longus colli) (Video 123.1).
- The soft tissues and muscles are then resected to expose the underlying pharyngobasilar fascia (Video 123.2). Resection of this dense fascia is facilitated by using a drill with a 3 mm coarse diamond bur to remove the cortical bone of the clivus starting at the inferior margin of the sphenoid rostrum (and progressing inferiorly [Video 123.3]). The limits of exposure include the Eustachian tubes laterally, the floor of the sphenoid sinus superiorly, and the level of the soft palate inferiorly.
- The posterior edge of the nasal septum is resected with backbiting forceps, and the attachment of the septum to the hard palate is drilled in the midline until it is flush with the plane of the hard palate. This allows instrumentation to reach the lateral limit of the surgical field from the contralateral side.
- An image guidance system is used to identify the level of the ring of C1, and the bone is then exposed (Fig. 123.3). The inferior edge of the clivus is thinned with a drill and resected with a Kerrison rongeur. The central portion of C1 is then removed with the drill, and the defect is widened laterally with a bone rongeur (Fig. 123.4; Video 123.4).
- The location of the underlying dens is confirmed with image guidance, and the central portion of the dens is drilled (Video 123.5). When only a shell of outer cortical bone remains, the base of the dens is detached from the body of C2. Blunt and sharp dissection of the attachments of the dens to the surrounding pannus allows mobilization and removal of the remaining bone (Fig. 123.5; Video 123.6).
- Although resection of the pannus may not be necessary, we prefer to partially resect the pannus with an ultrasonic aspirator until pulsations transmitted from the brain stem are observed (Video 123.7). No reconstruction is necessary if the dura has not been violated. The defect is covered with fibrin glue (Video 123.8).
- Silastic nasal splints are sutured to the nasal septum.
- Because of the inherent instability of the craniovertebral junction in these patients, posterior fusion of the cervical spine to the occiput is usually performed during the same operative event.

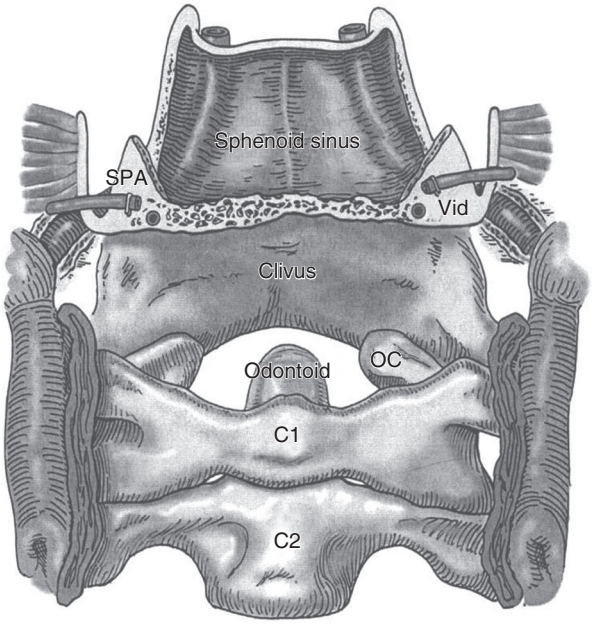

Fig. 123.3. The nasopharyngeal soft tissues are resected to expose the lower clivus and ring of C1. It is not necessary to open the sphenoid sinus in all cases. *OC*, occipital condyle; *SPA*, sphenopalatine artery; Vid, vidian artery. *(Reprinted with permission from Kassam AB, Snyderman CH, Gardner PA, et al: The expanded endonasal approach: A fully endoscopic transnasal approach and resection of the odontoid process: Technical case report. Neurosurgery 2005; 57: E213, discussion E213.)*

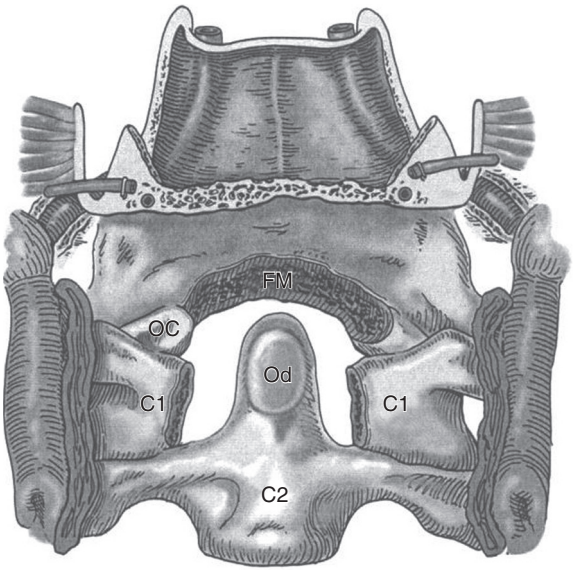

Fig. 123.4. The central ring of C1 is removed with a drill and the gap is widened with a Kerrison rongeur. *FM*, foramen magnum; OC, occipital condyle; Od, odontoid. *(Reprinted with permission from Kassam AB, Snyderman CH, Gardner PA, et al: The expanded endonasal approach: A fully endoscopic transnasal approach and resection of the odontoid process: Technical case report. Neurosurgery 2005; 57: E213, discussion E213.)*

Transoral Approach

- Various retractors (Dingman, Crockard) are available and allow self-retained retraction of the mandible and tongue, as well as the lateral oral commissure (Fig. 123.6). One of the biggest challenges is finding a proper fit of the tongue blade so that the base of tongue does not bulge into the field. During lengthy cases, the retractor should be released for several minutes intermittently to prevent excessive

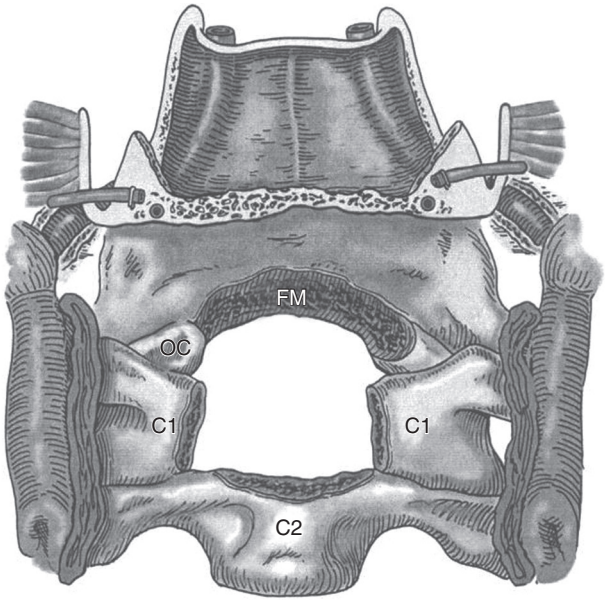

Fig. 123.5. The odontoid is removed with a drill and dissection of the ligamentous attachments. *FM*, foramen magnum; OC, occipital condyle. *(Reprinted with permission from Kassam AB, Snyderman CH, Gardner PA, et al: The expanded endonasal approach: A fully endoscopic transnasal approach and resection of the odontoid process: Technical case report. Neurosurgery 2005; 57: E213, discussion E213.)*

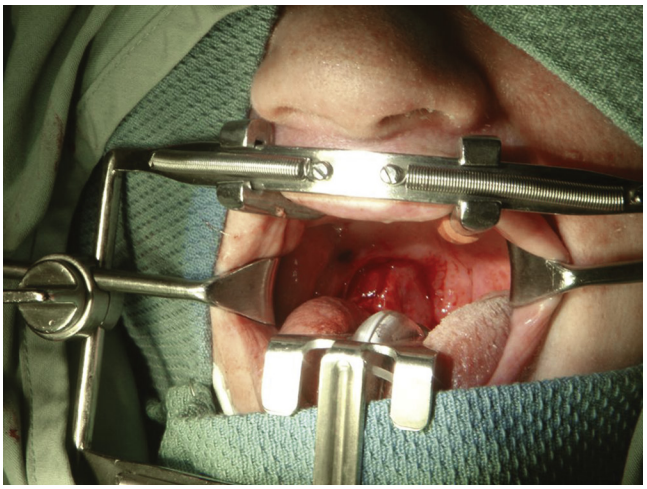

Fig. 123.6. A Dingman retractor distracts the mandible and maxilla, and displaces the endotracheal tube, the tongue, and the cheeks.

pressure on the tongue and the potential for ischemic necrosis or edema.

- If the superior extent of the resection is the odontoid, incision of the palate is not necessary. A red rubber catheter is passed transnasally and sutured to the soft palate adjacent to the uvula. It is then retracted to pull the soft palate into the nasopharynx and secured to the drapes.
- If the exposure needs to extend to the rostrum of the sphenoid, incision of the palate is generally necessary. A paramedian incision is made adjacent to the uvula and curves in a lazy "S" fashion behind the maxillary alveolus so that the majority of the palatal flap is based on one greater palatine artery.
- The mucoperiosteal flaps are elevated laterally to the edge of the greater palatine foramen with preservation of the blood supply. The posterior edge of the hard palate may be resected to provide additional exposure superiorly.
- Electrocautery is used to make a vertical midline incision in the posterior pharyngeal wall from the level of C3 to the nasopharynx. The incision continues through the soft tissues in the midline between the longus capitis and longus colli muscles.
- The paraspinal muscles are elevated from the vertebral bodies and ring of C1. Excessive lateral dissection is avoided because of the risk of injuring the vertebral artery.
- A self-retaining retractor is placed and the bone work is then performed with a drill and Kerrison rongeurs. Visualization is enhanced with use of the operating microscope or endoscopes.
- After completion of the decompression, the pharyngeal incision is closed in two layers: a deep layer of interrupted 3-0 polyglycolic acid suture and a superficial layer of 3-0 polyglycolic acid suture placed with a vertical mattress technique. Obtaining watertight closure can be difficult at the superior and inferior limits of the incision. If a palatal incision has been made, the soft palate incision is closed in two layers: a deep intramuscular layer of interrupted 4-0 polyglycolic acid suture and a superficial layer of interrupted 4-0 polyglycolic acid suture. The mucoperiosteal flap over the hard palate is thin and is closed in a single layer with a vertical mattress technique. A paraffin nasal splint can be molded to the contour of the hard palate and secured with sutures around the teeth. This protects the palatal mucosa during mastication.

Common Errors in Technique

- Limited exposure
  The nasopharyngeal tissues, including the paraspinal muscles, should be widely resected to provide good visualization of the bone. Drilling of the bone of the hard palate in the midline improves lateral access at the level of C1. Attempts to preserve the mucosa of the nasopharynx by elevating a flap are futile as the flap is insufficient for reconstruction and interferes with visualization.
- Detachment of odontoid
  The transition from the ring of C1 to the dens is not always apparent and it is easy to prematurely drill into the dens. Detachment of the dens at its base before drilling the tip makes it difficult to dissect the tip from the ligamentous attachments.

POSTOPERATIVE PERIOD

Postoperative Management

- These patients are at increased risk for aspiration postoperatively, and reintubation can be difficult because of posterior neck fusion. Consideration should be given to leaving the patient intubated postoperatively until a safe airway can be ensured, or a temporary tracheostomy should be performed. With the transnasal approach, tracheostomy is only necessary in patients with significant preoperative pharyngeal dysfunction.
- Patients may start a full liquid diet and progress to a soft diet as soon as they are able to swallow without aspiration. Formal evaluation with a modified barium swallow may be helpful in determining swallowing capability. With the transnasal approach, patients can resume an oral diet immediately. Return of swallowing function is often delayed for several days when the transoral route is used.
- If used, nasal septal or palatal splints are removed 1 week postoperatively.

Complications

- Palatal dysfunction
  Palatal dysfunction following a transnasal approach is mild and transient since the trajectory of the approach is superior to Passavant's ridge. A transoral approach results in a greater loss of bone volume because of the trajectory with a greater separation of the palate and posterior pharyngeal wall. If a palatal incision is performed, scar contracture can shorten the soft palate, contributing further to velopharyngeal incompetence with hypernasal speech and nasal reflux. Dehiscence of the palatal closure can result in an oronasal fistula.
- CSF leak
  Aggressive resection of a rheumatoid pannus can result in a CSF leak. With a transnasal approach, this can be effectively stopped using a multilayer repair, including fascia, adipose tissue, and possibly a nasoseptal flap. With a transoral approach, it is more difficult to repair a CSF leak due to the trajectory and limited visualization. Closure of the pharyngeal incision is difficult after a transoral approach, and ongoing contamination of the wound by saliva with heavy bacterial flora can occur, increasing the risk of meningitis.
- Vascular injury
  The extracranial parapharyngeal segment of the ICA is susceptible to injury from electrocautery lateral to the fossa of Rosenmüller. A tortuous ICA that courses medially in the retropharyngeal area is a relative contraindication to a transoral approach, but it would not preclude a transnasal approach. When recognized, the nasopharyngeal soft tissues can be displaced inferiorly to protect the vessels. Far lateral dissection at the level of C1 and C2 may injure the vertebral artery and should be performed only under image guidance.
- Miscellaneous
  Other potential risks of a transoral approach include injury to the teeth, edema or necrosis of the tongue, upper airway obstruction secondary to edema, dysphagia, pain with swallowing, retropharyngeal hematoma or abscess, and temporomandibular joint syndrome secondary to excessive opening of the mouth.

Alternative Management Plan

- Patients with a rheumatoid pannus have inherent instability of the craniovertebral junction and this contributes to the formation of the pannus. Anterior decompression is not necessary in the majority of patients, and stabilization of the spine with a posterior fusion alone will allow the pannus to resolve.
- Neoplasms that extend laterally from the lower clivus or involve the vertebral artery can be approached with a far lateral or anterior transcervical approach.

DISCUSSION

Evidence-Based Medicine Question

What are the complication rates of transoral and transnasal odontoidectomy?

A systematic review and meta-analysis by Shriver et al.[4] reviewed the literature for rates of complications and outcomes for transoral and transnasal odontoidectomy. Twenty-six articles met the inclusion criteria. The only statistically significant difference was the incidence of postoperative tracheostomy, which was significantly higher after transoral odontoidectomy 8.4% (95% CI 4.9% to 11.9%) compared to transnasal odontoidectomy 0.8% (95% CI 1.0% to 2.9%). Due to inconsistent reporting, it was not possible to demonstrate the differences in important outcomes, such as arterial injury, CSF leak, pneumonia, velopharyngeal insufficiency (VPI), wound infection, and meningitis.

A systematic review of the literature for endoscopic endonasal approaches to the craniovertebral junction identified 71 cases.[5] Seven of 71 patients required an airway intervention (9.9%). The majority of patients (81.7%) had additional posterior decompression or fusion before or after the endonasal procedure. The authors concluded that the endonasal approach is an effective and safe alternative for most pathologies of the craniovertebral junction.

Editorial Comment

The endonasal corridor to the craniovertebral junction is another example of how enabling technology (endoscopy) has transformed surgery. Improved visualization facilitates more complete surgery with less morbidity. Endoscopic endonasal surgery is also team surgery, requiring close cooperation between surgical specialties. Each specialty benefits from the knowledge and expertise of the other. Endoscopic technology can be applied to traditional procedures (transoral approach to the cervical spine) to transform them. Modern head and neck surgeons need to be versatile in the adoption of new techniques and technologies.

Eric W. Wang

Access the review questions and additional source list online at
http://www.expertconsult.com

REFERENCES

1. Kassam AB, Snyderman CH, Gardner PA, et al. The expanded endonasal approach. A fully endoscopic transnasal approach and resection of the odontoid process: Technical case report. Neurosurgery 2005;57:E213, discussion E213.
2. Zwagerman NT, Tormenti MJ, Tempel ZJ, et al. Endoscopic endonasal resection of the odontoid process–clinical outcomes in 34 patients. J Neurosurg May 2017;12:1–9.
3. Nayak JV, Gardner PA, Vescan AD, et al. Experience with the expanded endonasal approach for resection of the odontoid process in rheumatoid disease. Am J Rhinol 2007;21:601–606.
4. Shriver MF, Kshettry VR, Sindwani R, et al. Transoral and transnasal odontoidectomy complications: A systematic review and meta-analysis. Clin Neurol Neurosurg 2016;148:121–129.
5. Fujii T, Platt A, Zada G. Endoscopic endonasal approaches to the craniovertebral junction: asystematic review of the literature. J Neurol Surg B Skull Base 2015;76:480–488.

REVIEW QUESTIONS

1. Anatomical limits of the transnasal approach to the craniovertebral junction include all of the following except:
   a. Parapharyngeal internal carotid arteries
   b. Eustachian tubes
   c. Nasopalatine line
   d. Pituitary gland

2. Relative contraindications of the transnasal approach to the craniovertebral junction include all of the following except:
   a. Trismus
   b. Untreated sinusitis
   c. Tumor involving vertebral body of C3
   d. Tumor encasement of vertebral artery

3. Advantages of a transnasal approach compared to a transoral approach include all of the following except:
   a. Decreased risk of hypernasal speech
   b. Earlier resumption of oral diet
   c. Stabilization of the spine
   d. Increased access to the clivus

ADDITIONAL SOURCE

Snyderman CH, Gardner PA. Endoscopic endonasal approach to the craniocervical junction and odontoid. In: Snyderman CH, Gardner PA, editors. Master Techniques in Otolaryngology-Head and Neck Surgery: Skull Base Surgery Volume. Philadelphia: Wolters Kluwer; 2015. p. 373–380.

124 Reconstruction After Skull Base Surgery

Patrick Colley, Adam Zanation

INTRODUCTION

Over the past 15 years, significant improvements in surgical techniques coupled with technological advancements have led to the ability to remove complex skull base tumors using endoscopic endonasal surgery (EES).[1,2] EES is applicable for a wide variety of surgical pathology, including everything from sinonasal cancers to intradural primary brain tumors.[3] When EES was first developed, proper repair of the skull base and prevention of subsequent cerebrospinal fluid (CSF) leak was one of the primary challenges faced by the surgeon. This review describes how surgical techniques to address these issues have advanced from early free tissue grafting techniques to the current use of vascularized flaps for large skull base defects. We will focus on endoscopic techniques in this chapter.

Open transcranial anterior skull base reconstruction is usually accomplished with an anteriorly based pericranial flap (see Chapter 166).

KEY OPERATIVE LEARNING POINTS

1. Measuring the size of the defect and attempting to create a smooth surface for repair are vital first steps in all skull base reconstructions.
2. A multilayered reconstruction with vascular repair is favored over a single layer whenever possible, especially in fields that have previously received or will be receiving radiation therapy.
3. Postoperative care, including bed rest, bowel regimen, elevation of the head of the bed, and maintenance of airway pressures, plays an important role in successful reconstruction of any skull base defect.

PREOPERATIVE PERIOD

History

1. History of present illness
   a. The location of the skull base pathology can possibly be elicited by asking if the patient has any sinonasal complaints, such as nasal obstruction, rhinorrhea, change in their sense of smell, facial pressure/pain, or epistaxis.
      Sinonasal etiologies of potential skull base defects often present with nasal obstruction, discharge, or epistaxis. Planar and perisellar etiologies are more likely to present with headache or ophthalmologic symptoms, such as visual field cuts, ophthalmoplegia, or ptosis.
   b. Postoperative CSF leaks are typically noted within a week following sinonasal or skull base surgery. The patient's history is most suggestive and often diagnostic. Primary symptoms include clear, persistent rhinorrhea with an often salty taste. Postoperative encephaloceles are also potential causes of CSF leak further out from the original surgery.
   c. A history of previous sinonasal, head, and neck or neurosurgical procedures or prior radiation therapy should be elicited.
      Vascularized flap reconstruction relies on axial blood flow and tissue planes that may have been disrupted during previous surgeries. Identifying this before the surgery allows for proper planning should the patient require an extranasal flap for reconstruction.
2. Past medical history
   a. Prior treatment: Does the patient have a known history of skull base pathology? How was this previously treated? Radiation therapy?
   b. Medical illnesses
   c. Prior surgeries: Has the patient ever had endoscopic sinus surgery, a septoplasty, craniotomy, rhytidectomy, or other head and neck surgery?
   d. Family history
   e. Medications:
      1) Antiplatelet drugs
      2) Anticoagulants
      3) Herbal products
      4) Alcohol

Physical Examination

1. Nasal endoscopy
   Nasal endoscopy is a key component of the physical examination. It may be limited preoperatively due to tumor or septal deviation. Identifying the size of the tumor and potential involvement of surrounding structures, particularly the septum or rostrum, can be helpful in planning the resection and reconstruction.
   Postoperatively, nasal endoscopy plays a vital role in tumor surveillance and helps monitor for potential CSF leaks. In addition to nasal endoscopy, physical examination findings of a CSF leak include a positive reservoir sign and increased rhinorrhea with a Valsalva maneuver. In the early postoperative period, absorbable packing often remains in place, making visualization of the skull base defect difficult. Intermediate timed CSF leaks (2 to 6 weeks) are less common and usually present with intermittent low flow leaks from a pinpoint dural opening. Late CSF leaks (>6 weeks) are very rare and present in a similar manner to intermediate timed leaks. Both the intermediate and late CSF leaks can typically be visualized with a nasal endoscopy.
2. Orbit
   A thorough ophthalmologic examination may reveal tumor involvement of the extraocular muscles, optic nerve, or cranial nerves. While involvement of these structures may not limit the surgical resection, their preoperative function should be noted.
3. Trigeminal nerve
   The path of this cranial nerve and its location in the sinonasal cavity frequently lead to involvement by skull base tumors or injury during resections of these lesions. These nerves will not serve as surgical limits, but their preoperative function provides information as to the size and location of the skull base tumor.
4. Neck
   Sinonasal tumors have a low rate of lymphatic metastasis, but their drainage basins are typically in the cervical lymph node chain, making examination of the neck an important preoperative assessment. Cervical vasculature could also play a role in potential skull base reconstruction depending on the size of the defect or the technique of reconstruction.

Imaging

Computed Tomography

Bony anatomy and the extent of skull base involvement are crucial information to obtain during the preoperative assessment. A CT scan can typically provide this detail as well as some information regarding soft tissue involvement (Fig. 124.1). If the planned resection will involve the use of image guidance, proper formatting is required when obtaining these scans.

Magnetic Resonance Imaging

Skull base tumors frequently abut or involve intracranial structures making soft tissue detail particularly important for proper surgical planning. Other important structures, such as the carotid arteries and optic nerves, must be identified and preserved during skull base procedures. The soft tissue detail that MRI provides is typically the most accurate means of accomplishing this task (see Fig. 124.1). The use of contrast

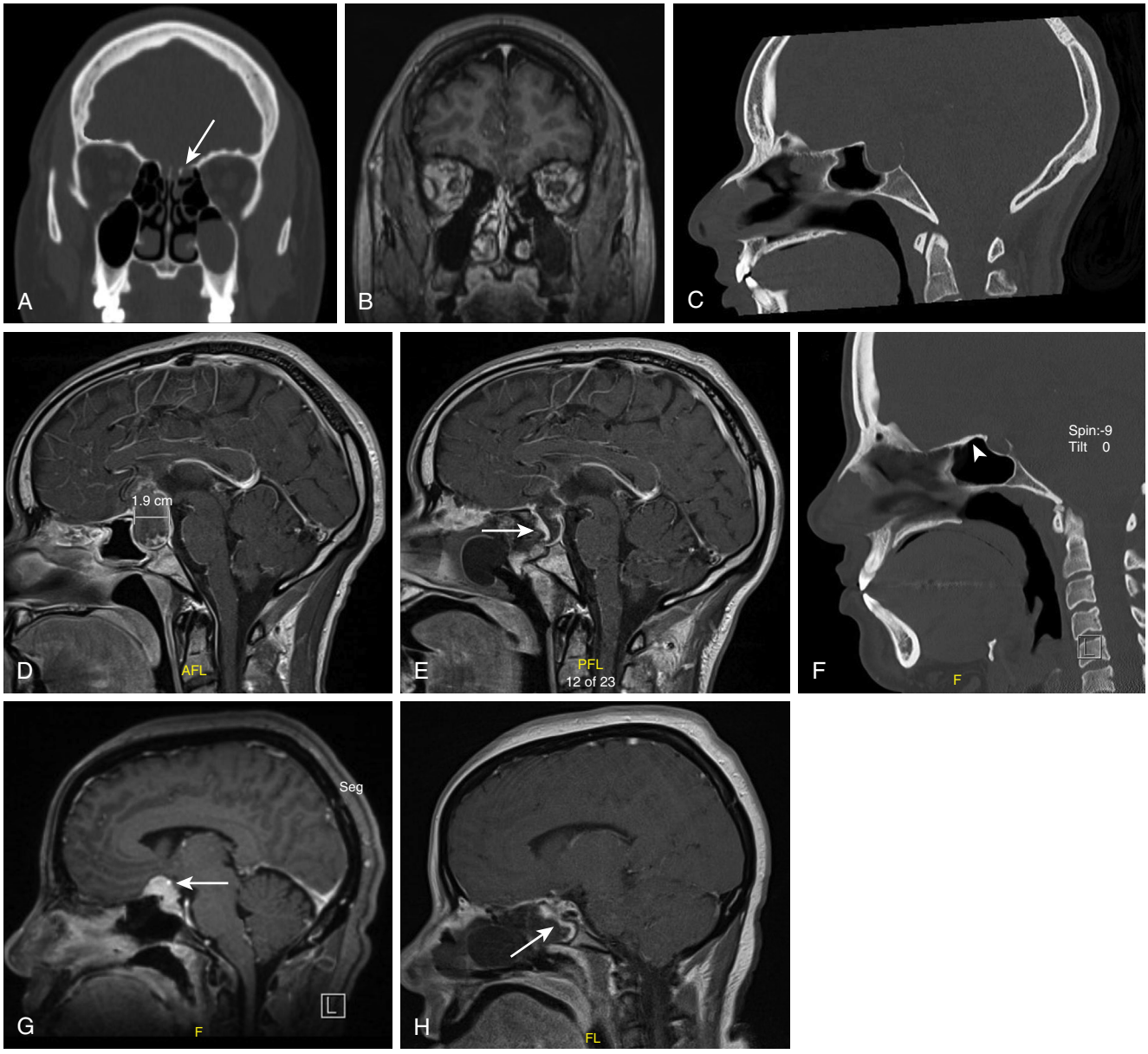

Fig. 124.1. Types of endonasal skull defects. Computed tomography (CT) demonstrates bony anatomy and allows planning of the approach corridor and sizing of the craniectomy defect for reconstruction. Magnetic resonance imaging (MRI) provides superior visualization of intracranial extent of disease and the relationship of neurovascular structures relative to the planned endoscopic corridor. **A,** Coronal CT (bone window) of a small encephalocele of the left ethmoid *(arrow)* with pooling of the cerebrospinal fluid in sinus cavities on the ipsilateral side. **B,** Coronal T1 contrasted MRI of a small encephalocele of the left ethmoid in the same patient as Fig. 124.1A. **C,** Sagittal CT (bone window) of a patient with a large pituitary adenoma. Note the expanded sella and thinning of the dorsum sellae (superior clivus). **D,** Sagittal T1 contrasted MRI of the same patient in 1C. Note the suprasellar extent and posterior expansion of the tumor. **E,** Immediate postoperative sagittal T1 contrasted MRI of the patient in 1C and 1D. Note the gross total resection of the tumor and the good placement and vascularity of the nasoseptal flap reconstruction at the arrow. A Foley balloon catheter is in place. **F,** Sagittal CT (bone window) of a patient with a tuberculum and planar meningioma. Note the tumor-related hyperostosis of the planum extending back to the tuberculum at the arrowhead. **G,** Sagittal T1 contrasted MRI of same patient in 1F. Note the tumor extending into the sella and the anterior communicating and A2 arteries running along the superior edge of the tumor but not fully encased in the tumor at the arrow. **H,** Immediate postoperative sagittal T1 contrasted MRI of the patient in 1F and 1G. Note the good placement and vascularity of the nasoseptal flap reconstruction at the arrow.

can provide excellent detail regarding the vasculature within the skull base and should be included whenever the surgical field will involve vascular structures. Proper formatting should be applied to these scans as well if they are to be used for image guidance during the surgical resection.

Angiography

Preoperative angiography and intervention play an important role in the treatment of vascular tumors that can involve the skull base, such as juvenile nasopharyngeal angiofibromas. However, its routine use is not necessary in the treatment of most skull base tumors and does not aid in the skull base reconstruction.

Indications for Skull Base Reconstruction

1. Dural defect after the excision of a skull base tumor or encephalocele (Figs. 124.1 and 124.2)
   Any tumor involving the anterior skull base has the potential to require reconstruction after surgical resection. The size of the defect can often be anticipated based on the preoperative imaging and should be planned for accordingly.
2. A postoperative CSF leak is identified after sinonasal surgery.
   A major complication of endoscopic sinus surgery is damage to the skull base and dura with resultant CSF leak. Injury to the skull base during endoscopic sinus surgery is approached in a similar manner as that of a planned skull base resection.
3. Large extradural defects to promote healing
   Many extradural tumor resections require reconstruction to promote healing, especially in the setting of postoperative radiation therapy. In these situations, the primary reason for reconstruction is not prevention of a CSF leak but is proper healing with the reduction of potential intracranial infections and the protection of vital structures.

Contraindications

1. Medical comorbidities with unacceptable risk for general anesthesia
   Patients with lesions involving their skull base who are not medically stable enough to undergo general anesthesia have a variety of treatment options, including observation, medical management of the tumor, or possibly radiation therapy.
2. Unresectable skull base tumor
   Skull base tumors that are not resectable should be considered for medical management of their tumor unless surgery is the last palliative measure.

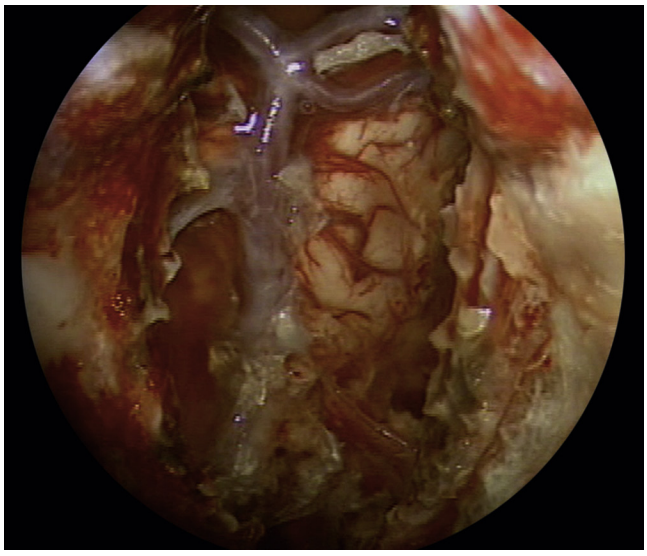

Fig. 124.2. Endoscopic view of a skull base defect from an endonasal approach following resection of a posterior fossa meningioma. The basilar artery and basilar tip can been seen through the transclival defect.

Preoperative Preparation

1. The entire surgical team must understand and agree with the plan for resection and repair.
2. If a lumbar drain is planned as part of the reconstruction, this should be included on the consent form and discussed with the patient and the surgical team.
3. Confirm that the imaging, CT and/or MRI, is compatible with the image guidance and that these scans are loaded before the surgery.
4. Discontinue all antiplatelet drugs.

OPERATIVE PERIOD

Anesthesia

General anesthesia: This procedure often involves irrigation with the drainage of blood and potentially CSF into the oropharynx that would pose an airway risk should the airway not be secured with an endotracheal tube. The procedure itself is also intricate involving small movements in an area near many important structures, making patient movement potentially very dangerous. The anesthesiologist should be made aware when operating around or near the optic nerves or carotid arteries to ensure complete anesthesia and reduce the possibility of any patient movement.

Positioning

Supine: The patient is positioned in the supine position with access to the entire head, abdomen, and potentially upper leg from the iliac crest to the patella. This often requires turning the patient 90 or 180 degrees away from anesthesia. If an extranasal flap is part of the reconstructive plan, the patient should also be positioned appropriately in order to harvest this flap.

The patient's eyes should be protected in a manner that provides access for examination but protects from corneal abrasions.

Perioperative Antibiotic Prophylaxis

A discussion regarding preoperative medications, including antibiotics, should take place with Neurosurgery if they are involved in the procedure. Additionally, the potential need for CSF antibiotic penetration should be considered for cases with significant intra-arachnoidal dissections.

If the tumor or defect is primarily extradural or sellar without a high-flow CSF leak:

First-generation cephalosporins: These medications are typically sufficient for EES if there is no active infection identified in the preoperative evaluation.

Clindamycin: If the patient is allergic to penicillin, clindamycin is an acceptable substitute and has the advantage of a higher rate of bone penetration.

If the tumor or defect has a significant intra-arachnoidal dissection, then third-generation cephalosporin or vancomycin for the patients who are allergic to penicillin should be considered.

Monitoring

Cranial and peripheral nerve monitoring: Monitoring cranial nerves and peripheral nerves can play a role in the resection of skull base tumors but has no role in reconstruction after these surgeries.

Instruments and Equipment to Have Available

1. An endoscopic sinus surgery set
2. Guarded monopolar electrocautery: Monopolar suction electrocautery should be used with caution near the skull base due to the spread of heat and electrical current to surrounding structures. We usually prefer bipolar or advanced energy technology.
3. Bipolar electrocautery: There are many types of endoscopic bipolars available that are all designed for use in skull base reconstruction. The use of bayonet bipolars is usually limited by the nasal aperture.
4. Endoscopic microsurgical dissection instruments: Dissection in and around neurovascular structures often requires a wide variety of instruments. Dissecting sets, such as Rhoton dissectors, provide the surgeon with a number of choices when operating at the skull base.
5. Image guidance: Using preoperative imaging for image guidance during EES supplies the surgeon with important information regarding skull base anatomy that can become distorted during the resection.
6. Allograft or collagen matrix material: This material can be used as an inlay or onlay graft during reconstruction. The size and thickness of the material should be confirmed before the start of the procedure.
7. Thrombin/Gelfoam mixture for hemostasis, fibrin or biologic glues for a potential sealant over the reconstruction
8. Endoscopic suture devices can be useful in selected cases but are difficult to use. Additionally, endoscopic carotid clips and aneurysm clips can be useful for catastrophic bleeding.

Key Anatomic Landmarks

1. The sphenopalatine artery and the sphenoid sinus natural ostium
   The nasoseptal flap (Fig. 124.3) has become the flap that is most often used for skull base reconstruction and will be the primary reconstructive option discussed in this chapter. The primary blood supply is from the distal external carotid artery via the sphenopalatine artery to the posterior nasal branches that cross over the choana.[4] The sphenoid ostium is an important landmark when elevating this flap. Dissection along the anterior inferior face of the sphenoid is discouraged until the septal flap has been elevated, if it is the planned means of reconstruction.
2. Bony edge of the skull base defect
   Measuring the skull base defect and identifying the bony edges is important for successful reconstruction. Inlay grafts must be placed behind these edges, and any onlay graft must cover these edges in order to properly reconstruct a skull base defect.

Prerequisite Skills

1. Endoscopic sphenoidotomy
2. Endoscopic septoplasty

Operative Risks

Damage to the flap pedicle or perforation of the flap

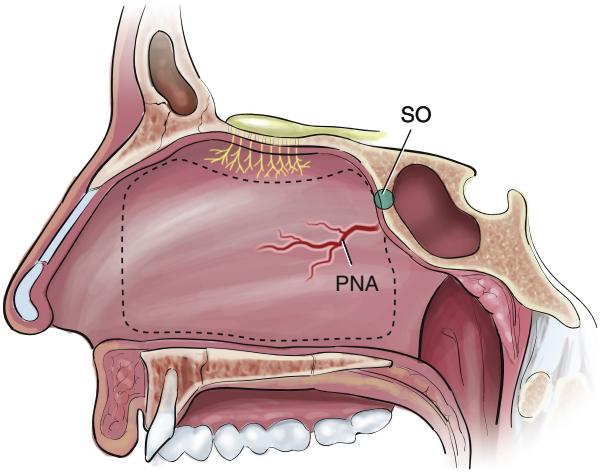

Fig. 124.3. Nasoseptal flap anatomy and standard incisions *(dotted lines)*. Note the incision is approximately 1.5 cm below the olfactory groove to preserve neural fibers. The incision can be modified to include the nasal floor or extend more anteriorly to the mucocutaneous junction. The pedicle is based on the posterior nasal artery (PNA) from the sphenopalatine artery. The arterial pedicle always runs between the free edge of the choana and the sphenoid ostium (SO).

If a pedicled flap is the planned means of reconstruction, care must be taken when incising and elevating the flap to avoid damage to the tissue. When using the nasoseptal flap, injuries to the pedicle typically occur while enlarging the sphenoid ostium, making the inferior choanal incision or dissecting the flap free from the anterior face of the sphenoid. This can be avoided by ensuring proper visualization and hemostasis during the initial flap incisions and while elevating the flap. The position of the natural ostium of the sphenoid should be confirmed prior to making the inferior incision. Once the flap is dissected free, it should be protected from possible damage from a drill by placing it in the nasopharynx or maxillary sinus (via antrostomy).

Perforation of the flap mucosa can lead to failure of the repair due to loss of a watertight seal. Dissection in the proper sub-mucoperichondrial plane for a nasoseptal flap reduces the risk of perforation of the flap. This plane should be established at the anterior portion of the dissection, and all incisions should be made prior to proceeding posteriorly with the dissection. If the incision is not made all the way through the mucoperichondrium, sharp cutting instruments should be used to complete the incisions.

Surgical Technique

This section will provide details regarding skull base repair using free mucosal grafts and the nasoseptal flap.[1,2] Details of skull base reconstruction using particular extranasal flaps, such as the pericranial, temporalis, or temporoparietal fascia flaps, can be found in Chapters 166, 167, 168, respectively. Defects that persist despite these techniques may require the use of free tissue transfer with microvascular techniques.

- Topical vasoconstriction with oxymetazoline (0.05%)
  Topical decongestion is an important part of the procedure and should be given adequate time in the nose to maximize the effect. Decongestants provide a larger endoscopic surgical cavity by reducing mucosal congestion as well as reducing bleeding. Topical epinephrine also can be used as long as the surgeon remains aware of the risk of potential rebound bleeding after this medication stops functioning. We do not routinely inject with lidocaine ± epinephrine.

- Lateralization of the inferior and middle turbinates
  The inferior and middle turbinates are out-fractured to allow visualization of the entire height of the nasal septum from the olfactory sulcus to the nasal floor.
- Harvest of the free mucosal graft
  If a free mucosal graft will be used for skull base reconstruction, it can be harvested from many sites, including (but not limited to) the nasal floor, the middle turbinate, or the nasal septum. Measurement of the skull base defect prior to collecting the graft is important in order to ensure that the graft harvested is the appropriate size. Many surgeons advise marking the mucosal side of the graft prior to removal in order to ensure that this side is positioned facing into the nasal cavity to allow vascularization.
  If the middle turbinate is chosen as the donor site for a mucosal graft, the entire turbinate should be adequately visualized up to the axilla prior to beginning the harvest. Using a cutting instrument, such as a septal scissor or thru-cut, the middle turbinate should be cut in an anterior to posterior fashion just below the axilla. Care must be taken to avoid extending this incision superiorly and injuring the skull base. Once this incision has been made, the horizontal portion of the basal lamella should be transected as well taking care to cauterize the middle turbinate branch of the sphenopalatine artery without injuring the main trunk of the sphenopalatine artery in case it is needed in the future. The mucosa can then be harvested on the back table by separating it from the underlying middle turbinate bone using a Freer or Cottle elevator. This bone should be kept for possible use later in the reconstruction.
  Nasal floor grafts can be harvested from the nasal floor between the septum and the inferior meatus. These grafts can encompass a large area when they are extended into the inferior meatus, along the lateral nasal wall, and can even be extended onto the nasal septum. Posteriorly, the graft should not extend past the hard palate in order to avoid damage to the musculature of the soft palate. Anteriorly, care should be taken around Hasner's valve and the mucocutaneous junction. Once all incisions have been made, the graft should be raised in a submucoperiosteal plane. All mucosal grafts should be kept in saline or saline-soaked gauze.
- If a nasoseptal flap (see Fig. 124.3) will be used for reconstruction, the sphenoid ostium is identified and entered on the side of the flap harvest.
  The side of the flap is determined by several factors. First, if the skull base lesion requires dissection of the lateral pterygoid recess or the pterygomaxillary fossa, then the vascular supply of the flap will be compromised; thus, a flap from the opposite side is used. Similarly, lesions that invade the rostrum of the sphenoid or the septal mucosa will mandate harvesting a flap on the contralateral side. If the skull base lesion is in the midline, and no significant lateral dissection is required, then sharp or large septal spurs that place the flap at risk for perforation during dissection may dictate the side from which the flap is harvested. The patient's right side is usually an easier dissection for the right-handed surgeon.
- The inferior incision begins inferolateral to the sphenoid ostium below the floor of the sphenoid sinus and is extended medially to cross the posterior choana.
  These incisions are typically made with needle-tip electrocautery and are ideally made in one smooth motion to stay in the same incision line. Suction should be placed at the edge of the nose in order to remove the smoke generated by the cautery.
- This inferior incision should be continued over the posterior aspect of the nasal septum curving inferiorly toward the floor of the nose to the level of the hard palate.
- The inferior incision should be continued anteriorly in a straight line along the junction of the septum and floor of the nose.
  The incision should be continued anteriorly as far as needed in order to create a flap that is large enough to cover the anticipated skull base defect. The entire ipsilateral mucoperiosteum and mucoperichondrium may be harvested to cover anterior skull base defects as large as from the posterior wall of the frontal sinus to the sella turcica and from orbit to orbit. Additionally, a wider flap may be harvested by extending the incision to include the mucoperiosteum of the floor of the nose.
- The superior incision begins at the sphenoid ostium and proceeds across the face of the sphenoid sinus medially with an upward slant over the rostrum.
- The incision should be carried anteriorly along the nasal septum approximately 10 to 15 mm below the most superior aspect of the septum.
  Preserving this mucosa is designed to leave olfactory epithelium in place, in order to preserve olfaction.
- The two parallel incisions are joined anteriorly by a vertical incision at a level that is anterior to the plane of the anterior head of the inferior turbinate.
  If the defect is larger or a longer flap is required, this incision can be made as far forward as the mucocutaneous junction; and wider flaps can be extended onto the nasal floor. The flap is designed according to the size and shape of the anticipated defect, although it is best to slightly overestimate the size, and trim the flap if needed.
- Flap elevation starts anteriorly with a Cottle elevator or a small suction dissector.
  It is advantageous to complete all incisions before elevating the flap as it is difficult to orient the tissue and maintain tension once it has been elevated. Septal incisions may be completed with scissors or other sharp instruments as necessary. Elevation of the flap from the anterior face of the sphenoid sinus is completed with preservation of its posterolateral neurovascular pedicle.
- The flap is then placed in the nasopharynx or maxillary sinus (middle meatal antrostomy) until it is needed for reconstruction at the end of the procedure.
- Once the ablative portion of the procedure is complete, all mucosa is removed from around the defect, and attempts are made to create a planar surface for reconstruction.
  A planar surface results in better adhesion by the flap and makes placement of the inlay graft somewhat easier. Occasionally, creation of a planar surface requires obliteration of dead space with an adipose tissue graft. The mucosa surrounding the defect is removed before the flap is placed to prevent nonhealing or mucocele formation.
- Allogenic material or collage matrix is then placed as a subdural inlay graft.
  This inlay graft helps to obliterate the intradural dead space. The pliability and texture of cellular matrix often work well here and allow for safe manipulation around neurovascular structures. Ideally, this subdural graft should extend 5 to 10 mm beyond the dural margins in all directions.
- A subsequent inlay graft of allogeneic material (either acellar dermis or collagen matrix) is then placed in the epidural space between the bone and dura edges if needed. Occasionally, the bony ledges are not adequate to support an inlay graft.

- The free mucosal graft or nasoseptal flap is placed as an onlay graft over the bony edges of the skull base defect (Fig. 124.4).
  Sealants are never used between the grafts or under the flap as this prevents direct tissue contact and proper healing.
- The edges of the flap are bolstered intranasally with oxidized cellulose absorbable packing.
  It is critical to separate the grafts from the nasal packing using some type of nonadherent material, such as absorbable gelatin sponge or film, as this will prevent traction on the grafts when the packing is removed. In addition, shifting of the underlying inlay/onlay grafts may occur during the placement of the packing; thus, the surgeon must be vigilant and perform placement of the packing under direct visualization with the endoscope.
- Placement of a 12-French Foley catheter balloon or 10-cm expandable tampon-type packing sponges is performed under direct endoscopic visualization.
  This packing is used to stabilize and bolster the inlay/onlay grafts and counteract intracranial pressure. Placement and inflation of the balloon catheter using 7 to 10 mL of saline are performed under direct endoscopic visualization. Care is taken to avoid over-inflation as this may result in excessive compression of intracranial structures.

Common Errors in Technique

- Graft or flap placed over a nonplanar defect or dead space (Fig. 124.5)
  Planar defects are particularly important when using a free mucosal graft, but an irregular surface can affect the success of the repair regardless of the technique. Closure of dead space with an adipose tissue graft can be used to create a planar defect and facilitate placement of the onlay graft. We are using dermal adipose tissue grafts more often since they have a smoother dermal surface that can face outward.
- Mucosa left around the skull base defect
  Mucosa trapped under an onlay graft can lead to poor healing and mucocele formation.
- Flap or graft not adequately covering the bony edges of the skull base defect
  Grafts or flaps should be placed in a manner to provide complete coverage of the defect ensuring that all edges rest on skull base bone. This leads to a watertight seal and encourages healing with direct tissue contact. If there is a tear or perforation in the flap, we try to not place that over the dural defect. If this is unavoidable, then we may plug the flap defect with dermal grafts.
- Movement of the flap with packing placement (see Fig. 124.4)
  Placement of packing materials, such as a Foley catheter or Merocel tampon, can cause significant movement of the onlay graft and should be performed only under direct visualization, taking care to place the catheter tip in the nasopharynx prior to inflating the balloon.

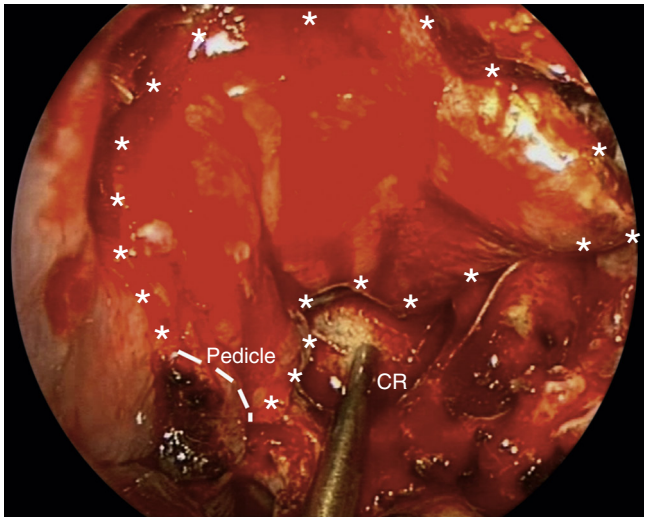

Fig. 124.4. Intraoperative photo of a right-sided nasoseptal flap onlay over a sellar and planar defect (astericks mark outline of flap). The pedicle was rotated, and the flap was placed above the clival recess (CR) to provide a flatter surface for reconstruction. Without a planar defect, the flap is usually transposed through the clival recess and sits more upright.

POSTOPERATIVE PERIOD

Postoperative Management

1. Forty-eight hours of bed rest if there is a high-flow intraoperative CSF leak
2. We do not routinely use lumbar drains in the postoperative period.
3. Elevation of the head of the bed to 30 to 45 degrees
4. A stool softener to prevent elevations of CSF pressure during bowel movements is important for proper graft healing.
5. Nasal packing or balloon is removed 3 to 5 days after the skull base repair.
6. Saline irrigations are started after removal of the packing or balloon.
7. The first débridement takes place 2 weeks after the surgery and consists of gentle removal of packing that is not adherent to the repair.
8. The second débridement takes place 4 weeks after surgery and consists of near complete removal of all remaining absorbable packing.

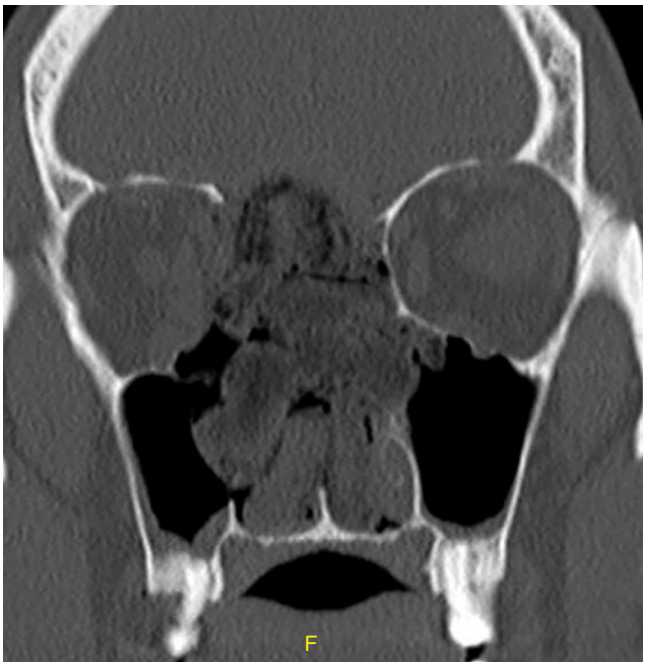

Fig. 124.5. Displacement of reconstruction into a craniofacial defect following the resection of a sinonasal cancer. Note that this patient was not leaking but was re-explored, and the reconstruction was revised to place the flap at the level of the anterior skull base.

9. Activity restrictions and cessation of continuous positive airway pressure (CPAP) use are maintained until 6 weeks after surgery.

Complications

1. CSF leak
   Clear rhinorrhea in the postoperative period should be concerning for a CSF leak. The presence of a leak can be confirmed with endoscopic examination, beta-2-transferrin, topical placement of fluorescein-soaked pledgets into the nose, or by the use of intrathecal fluorescein.
2. Pneumocephalus
   Some degree of postoperative pneumocephalus is expected after surgery. Asymptomatic patients can be managed expectantly and monitored closely. Increasing pneumocephalus on serial CT scans is indicative of a CSF leak and requires early exploration and repair. Tension pneumocephalus is most often seen when positive pressure ventilation is used after the surgery. Patients with symptomatic tension pneumocephalus can be managed by returning to the operating room for take down of the skull base reconstruction and release of the pneumocephalus.
3. Hemorrhage
   Injury to a major blood vessel, such as the carotid artery, can result in life-threatening hemorrhage and requires prompt control. Packing the nasal cavity can temporarily control bleeding until hemostasis can be achieved. Reconstruction with a nasal septal flap provides coverage of an injured vessel. Delayed reconstruction may be necessary after angiographic treatment and removal of nasal packing.
4. Mucocele
   Repair of a skull base defect by a graft or flap that covers sinonasal mucosa or obstructs the outflow tract of a sinus can lead to mucocele formation.[5] All attempts should be made during the surgery to remove mucosa surrounding the skull base repair prior to placement of the graft or flap. Depending on the location of the defect, the surrounding sinuses should be opened widely to allow for drainage around the repair site. This may require that a wide sphenoidotomy, posterior septectomy, or modified Lothrop procedure be performed prior to the skull base repair. If a mucocele develops, it can be addressed via endoscopic drainage and marsupialization once the skull base repair has had adequate time to heal.

Alternative Management Plan

1. Extranasal flaps
   If the defect is large or the nasoseptal flap is not available, the use of flaps from outside of the sinonasal cavity may be required.[2] Scalp flaps, such as the pericranial, temporalis, or temporoparietal flap, are other vascularized flaps that can be used and brought into the nasal cavity for skull base repair. Free tissue from elsewhere in the body, such as the radial forearm flap, also can be used in the sinonasal cavity to repair cranial vault defects. Placement of these flaps typically requires an open approach to the skull base to allow the pedicle to be brought out to the donor vessels and in order for the large tissue bulk to be placed into the sinonasal cavity.
2. Lumbar drain and medical management
   The removal of CSF via a lumbar drain can help remove pressure from the intracranial side of the skull base and aid in the repair of cranial vault defects. However, complications from these drains can be severe should they not be managed properly. As surgical technique for skull base repair has improved, there has been a shift away from using lumbar drains on small defects with low flow leaks.

DISCUSSION

Evidence-Based Medicine Question

1. Should CSF diversion techniques, such as lumbar drains, be used routinely on high-flow CSF leaks?
   High-flow CSF leaks are typically the result of entry into a basal cistern or the third ventricle. These leaks present an increased risk for a postoperative CSF leak and previously prompted many surgeons to place a lumbar drain for CSF diversion in the hopes of relieving stress from the reconstructed site. However, lumbar drains carry with them a 5% rate of minor complications and a 3% rate of major complications. This has prompted some surgeons to move away from the routine use of these drains as evidenced by multiple case series of high-flow leak repairs without the use of CSF diversion. A recent review by Tien et al. revealed that data on lumbar drain use are limited to nonrandomized, prospective, or retrospective data.[6]

   However, recent data suggest no significant difference in the CSF leak rate after skull base repair when lumbar drains are used in addition to a multilayer skull base repair with vascularized tissue. This review suggests that the decision to use a lumbar drain should be made on a case-by-case basis and not used routinely even in the presence of a high-flow CSF leak. There are factors that would prompt a surgeon to consider the use of CSF diversion in a high-flow CSF leak. The presence of intracranial hypertension, an early postoperative CSF leak, previous radiation therapy, or the need for intrathecal fluorescein (which is delivered much more uniformly into the cranial CSF by a drain compared with a puncture) is a factor that should push a surgeon to consider placing a lumbar drain.
2. Does the use of a vascularized mucosal flap improve the rate of postoperative CSF leak after skull base repair when compared to a free mucosal graft?
   When EES was first developed, skull base repair was primarily performed using free mucosal grafts or exogenous grafting materials. Early postoperative CSF leak rates ranged from 5% to 35%. Through improved surgical techniques, the leak rate has decreased to 8.5% in recent reviews of skull base repair after EEA. This is believed to be due, in large part, to the increased use of vascularized mucosal flaps. Large systematic reviews performed by Harvey et al. and Soundry et al. demonstrate an improvement in postoperative CSF leak rates with the use of vascularized mucosal flaps.[5,7] Harvey et al. reported a statistically significant difference in the CSF leak rate between vascularized reconstruction (6.7%) and free graft reconstruction (15.6%).[7] Soundry et al. showed that in high-flow CSF leaks, an 82% success rate was found with free graft use while vascularized repairs were associated with a 94% success rate.[5] These reviews, and many others, demonstrate that skull base reconstruction after EES can be accomplished in multiple ways. However, the use of vascularized, multilayer closures is the mainstay for the repair of complex skull base defects and high-flow CSF leaks.

Editorial Comment

Historically, reconstruction of dural defects was one of the greatest challenges of EES. As surgical techniques and technology continue to improve, the rate of postoperative CSF leaks has declined. This chapter describes the key techniques of skull base reconstruction using free grafts and nasoseptal flaps, the two most commonly used techniques. Other local flaps include the middle and inferior turbinate (lateral nasal wall) flaps, which have limited applications. High success rates are observed using a wide variety of materials and

techniques. The use of lumbar drains remains controversial but is generally reserved for large high-flow leaks or patients with risk factors for postoperative CSF leak. Our experience demonstrates that large defects of the anterior and posterior cranial fossae benefit from CSF diversion, whereas sellar/suprasellar defects do not.

Other chapters in the Cranial Base Section describe the rationale for choosing a reconstructive method based on the site of the defect as well as regional flaps when local flaps are not available. The endoscopic skull base surgeon needs to be able to choose the best reconstruction based on the defect and the needs of the patient. Familiarity with both endoscopic and open techniques is necessary, especially when the first reconstruction fails.

Carl H. Snyderman


Access the review questions and additional sources list online at http://www.expertconsult.com

REFERENCES

1. Thorp BD, Sreenath SB, Ebert CS, et al. Endoscopic skull base reconstruction: a review and clinical case series of 152 vascularized flaps used for surgical skull base defects in the setting of intraoperative cerebrospinal fluid leak. Neurosurg Foc 2014;37(4):E4.
2. Zanation AM, Thorp BD, Parmar P, et al. Reconstructive options for endoscopic skull base surgery. Otolaryngol Clin North Am 2011;44:1201–1222.
3. Hachem RA, Elkhatib A, Beer-Furlan A, et al. Reconstructive techniques in skull base surgery after resection of malignant lesions: a wide array of choices. Curr Opin Otolaryngol Head Neck 2016;24(2):91–97.
4. Zhang X, Wang EW, Wei H, et al. Anatomy of the posterior septal artery with surgical implications on the vascularized pedicled nasoseptal flap. Head Neck 2015;37(10):1470–1476.
5. Soudry E, Psaltis AJ, Lee KH, et al. Complications associated with the pedicled nasoseptal flap for skull base reconstruction. Laryngoscope 2015;125:80–85.
6. Tien DA, Stokken JK, Recinos PF, et al. Cerebrospinal fluid diversion in endoscopic skull base reconstruction: an evidence-based approach to the use of lumbar drains. Otolaryngol Clin North Am 2016;49(1):119–129.
7. Harvey RJ, Parmar P, Sacks R, et al. Endoscopic skull base reconstruction of large dural defects: a systematic review of published evidence. Laryngoscope 2012;122(2):452–459.

REVIEW QUESTIONS

1. Postoperative management after skull base reconstruction includes all the following, except
   a. Head of bed elevation to 30 to 45 degrees
   b. Bed rest
   c. Avoiding CPAP for at least 2 to 4 weeks
   d. Stool softeners

2. An ipsilateral nasoseptal flap may not be possible if tumor involves the following area(s):
   a. Rostrum
   b. Ethmoid sinus
   c. Pterygopalatine fossa
   d. a and c
   e. All of the above

3. Factors that may prompt a surgeon to use a lumbar drain after EES with skull base reconstruction include:
   a. Prior radiation therapy to the skull base
   b. Intracranial hypertension
   c. Postoperative CSF leak
   d. All of the above

ADDITIONAL SOURCES

Bleier BS, editor. Comprehensive Techniques in CSF Leak Repair and Skull Base Reconstruction. Basel: Karger; 2013.
Snyderman CH, Gardner PA, editors. Skull Base Surgery. Philadelphia, PA: Wolters Kluwer; 2015.

125 Office-Based Procedures in Otology

Mark Whitaker

INTRODUCTION

In the practice of otology, the various surgical procedures extend along a spectrum from the clinic to the operating room. The procedures performed in the clinic recapitulate the same surgical techniques used in the operating room. For this reason, the process of refining one's surgical techniques begins in the clinic. The methodology, preparation, and calming bedside manner while performing procedures in the clinic can lead to a trusting patient-physician relationship.

In an era of medicine that is highly focused on cost-containment, the ability to perform procedures in an outpatient setting is encouraged. There are, however, situations where an office-based approach is not suitable. Sedation-based or general anesthesia will likely be required for children, anxious or uncooperative adults, the patient with a narrow ear canal, and for complex or time-consuming procedures. A thorough discussion with the patient regarding expectations regarding the duration of the procedure, levels of pain, noise involved, and the possibility of vertigo will have a positive impact on overall satisfaction.

ANESTHESIA

Prescient planning for an office procedure includes thorough attention to anesthesia considerations. A properly anesthetized surgical site will help maintain a calm patient and in turn, steady the surgeon's hands. As the surgical site expands in size, the options for anesthesia advance from topical agents and local anesthesia to regional blocks.

Topical Anesthesia of the Tympanic Membrane

A number of topical agents have been studied for use on the intact tympanic membrane (TM). There are several considerations when choosing a topical agent. The ear must be meticulously cleaned in order for a topical agent to be effective. A thickened TM related to acute otitis media may require an extended treatment time or make a topical anesthetic ineffective. A perforated TM will allow the anesthetic agent to contact the middle ear structures, which may contribute to temporary facial nerve paralysis or vertigo.

Phenol

Phenol works as an effective topical anesthetic by creating a chemical burn that both anesthetizes the TM and provides hemostasis. This is the preferred topical anesthetic used for the TM. Excess use may contribute to scarring or irritation. It is used sparingly in a linear focal region for myringotomy and small focal regions for intratympanic injections. There are three options for application. A phenol applicator acts like a quill pen to deliver a precise amount of phenol. Other options include use of a small wisp of cotton on a metal applicator or via a disposable phenol kit with a sponge tipped applicator (Fig. 125.1). Care must be taken to ensure that the TM is dry in order to maintain a focal application. The patient must be informed that this method will cause a temporary burning sensation lasting seconds. Blanching of the TM is noted as immediately indicating the expected effect.

Tetracaine or Lidocaine

There are no standard concentrations of topical lidocaine or tetracaine. However, solutions of 4% to 10% lidocaine (amide) in saline or 8% to 10% tetracaine (ester) in isopropyl alcohol are the most commonly described preparations.

With the patient positioned supine with the head turned away, the medial half of the ear canal is filled with the predetermined anesthetic agent. The tympanic membrane must be treated for approximately 15 minutes for lidocaine and 60 minutes for tetracaine. Use of a cotton pledget or an otowick placed in the ear will allow the patient to ambulate while allowing the allotted time to lapse. Before commencing with the surgical procedure, the solution should be removed completely from the canal and the site should be tested to ensure proper anesthesia.

Eutectic Mixture of Local Anesthesia Cream

Eutectic mixture of local anesthesia (EMLA) cream is an emulsion containing lidocaine 2.5% and prilocaine 2.5%, which is pH buffered to 9. This is easily applied to the TM with minimal risk of entry to the middle ear; however, it does not always provide adequate anesthesia. Furthermore, at least 1 hour is required for EMLA to be absorbed and take effect.

Anesthetic Options for the External Ear and Canal

Procedures involving the external ear generally can be performed in the outpatient setting. Depending on the site and extent of the procedure, topical, local, or regional anesthetics could be considered.

Topical Anesthesia

The benefit of providing an anesthetic without the need of a needle stick is favorable in children and in certain adults. EMLA or lidocaine-epinephrine-tetracaine (LET) can be used on intact or broken skin. LET is a combination of lidocaine (4%), epinephrine (0.1%), and tetracaine (0.5%) in an aqueous solution or gel.



Fig. 125.1. Options for application of phenol to the tympanic membrane. A, Prepackaged kit with sponge tip. **B,** Cotton on a metal applicator and Phenol applicator.

These agents are applied directly to the surgical field and are covered with an occlusive dressing for a minimum of 30 minutes for LET and 60 minutes for EMLA. The site is then tested with a pinprick in order to ensure that an appropriate level of anesthesia has been achieved.

Local Injection of Lidocaine With Epinephrine

The hemostatic benefits of added epinephrine in injected local anesthetic agents are well recognized. Several studies have demonstrated the safe use of injectable lidocaine with epinephrine in the external ear. Diluting the solution with a 1:10 ratio of bicarbonate to lidocaine will reduce burning at the injection site.

The injection site is swabbed with an alcohol swab. A smaller syringe (1 to 3 mL) will facilitate ease of injection, and a 25-gauge needle or smaller is recommended. The pain associated with injection will be minimized by injecting slowly, through use of distracting measures, and by minimizing the total number of skin punctures. The maximum dose of 1% lidocaine with epinephrine is 7 mg/kg up to 500 mg or 50 mL. The maximum dose of lidocaine without epinephrine is 4.5 mg/kg. The desired effect is generally noted in 2 minutes and should last for 4 to 6 hours.

Regional Anesthesia

Regional anesthesia can be employed for procedures involving the TM, the external auditory canal (EAC), and the pinna. The pinna and meatus of the EAC receive their sensory innervation from the third cervical nerve and from the trigeminal, facial, and vagal nerves (Fig. 125.2). The great auricular nerve and the lesser occipital nerves are branches of the third cervical nerve and cervical plexus. The great auricular nerve provides sensory innervation to the skin overlying the mastoid process and the inferior pinna. The lesser occipital nerve provides sensation to the middle section of the pinna. The auriculotemporal nerve, which is a branch of the mandibular branch of the trigeminal nerve, innervates the superior portion of the pinna. The auditory branch of the vagus supplies the concha and EAC. The EAC also receives innervation from the trigeminal and facial nerves and from the cervical plexus.

There are two regional blocks that are frequently used in order to facilitate procedures of the pinna, EAC, and TM. A four-quadrant EAC block will provide anesthesia to the canal and TM but not the pinna. An outer ear block will provide anesthesia to the pinna but not the EAC or TM.

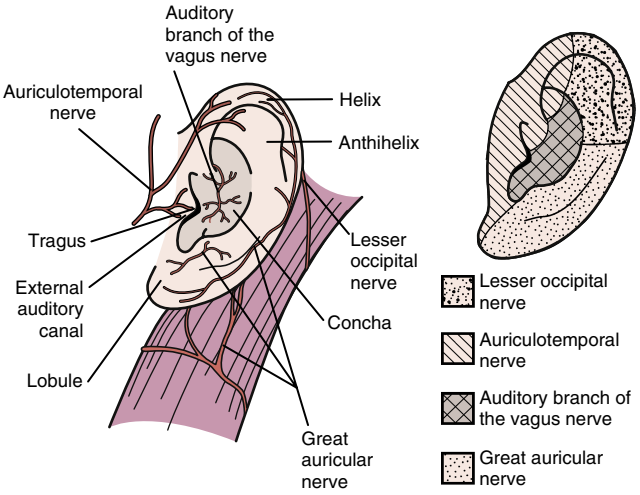

Fig. 125.2. Innervation of the auricle. *(Adapted from Roberts R, Hedges JR, editors. Clinical Procedures in Emergency Medicine, 4th ed. Philadelphia, PA: WB Saunders; 2004.)*

External Ear Block

Providing anesthesia to the entire pinna may be helpful for treatment of large auricular hematomas, laceration repairs, or excisions. This may be performed with only two injection entry sites, one each at the superior and inferior junction of the attachment of the pinna to the head (Fig. 125.3). A 10-mL syringe is filled with 1% lidocaine with epinephrine, and a 25-gauge needle is attached. The injection sites are swabbed with alcohol. The needle is advanced fully in a subcuticular plane while drawing back on the syringe in order to ensure that the injection is not administered intravascularly. While the needle is withdrawn, approximately 2 to 3 mL is injected. Without removing the needle completely from the injection site, the direction of the needle is altered to treat the posterior aspect of the pinna. Again, 2 to 3 mL is injected. This same procedure is repeated for the inferior pole of the pinna.

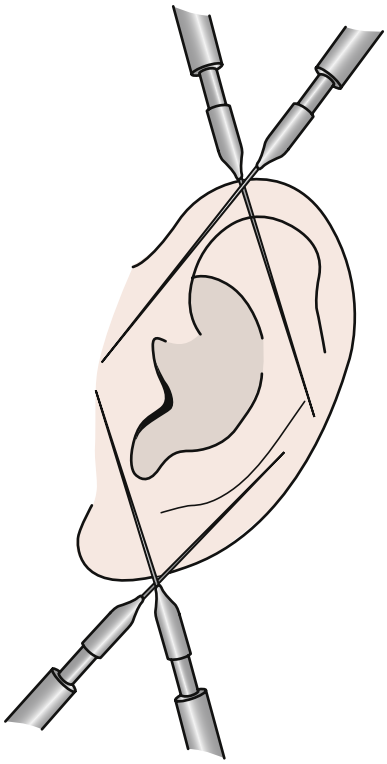

Fig. 125.3. Regional block of the pinna and external ear. *(Adapted from Roberts R, Hedges JR, editors. Clinical Procedures in Emergency Medicine, 4th ed. Philadelphia: WB Saunders; 2004.)*

Four Quadrant Canal Block

This technique again uses 1% lidocaine with 1:100,000 epinephrine. A smaller syringe, 1 to 3 mL, is used in order to provide greater dexterity and visibility with a 27-gauge needle. The needle is inserted at the bony cartilaginous junction with the needle advanced a few millimeters along the bone. An aural speculum is held with slight pressure applied to the canal wall lateral to the injection site in order to encourage medial diffusion of the anesthesia. The injection is performed with direct visualization of the medial canal in order to watch for blanching. Careful observation is employed to detect early signs of bleb formation, which is to be avoided.

DISIMPACTION OF CERUMEN

Obstruction of the ear canal with cerumen is the most likely cause of a conductive hearing loss in adults. The ear canal is naturally self-cleaning. Excess cerumen, dirt, dust, hair, and exfoliated squamous cells are expelled through gradual outward migration of the epithelium of the TM and external auditory canal. This process of self-cleaning can be interrupted by a narrow ear canal, use of a hearing aid, use of cotton swabs, and a prior history of radiation therapy to this region. If the self-cleaning process is not effective, physical débridement of cerumen by a clinician may be required. The task of removing cerumen generally falls on primary care physicians; however, there are instances where these techniques may not be effective or appropriate. Flushing the ear canal in the face of a perforated, retracted, or atrophic TM is not recommended.

Technique

Under microscopic vision, cerumen is removed with suction, wax curettes, Hartman forceps, or picks. In a large canal with a favorable shape, cerumen may be grasped easily with Hartman or small alligator forceps. In a narrow canal or if the canal is occluded by cerumen, the interface between the cerumen and canal wall should be identified. The contour of the canal is followed to the medial aspect of the cerumen or TM. The consistency of the cerumen will dictate the choice of suction, picks, alligator forceps, or curettes. A small right angle pick is helpful in identifying the interface between the canal and the cerumen and for removal of cerumen impacted against the TM. For wet or soft cerumen, aspiration of cerumen is generally the most efficient method of removal. Generally, 5F suction is employed. The size of suction device should be reduced to 3F when working adjacent to the TM. A 7F suction device should be limited to the onset of the procedure if the canal is completely obstructed and should be quickly replaced with a 5F device in order to minimize noise exposure. Treating the cerumen with Colace may facilitate removal. To do this, the lateral canal is filled with Colace solution (docusate sodium liquid, 100 mg/10 mL) and should remain for 15 minutes prior to proceeding with removal.

Mastoid cavity débridement employs similar principles. Review of the prior operative note is helpful in order to determine the status of the TM, middle ear structures, horizontal semicircular canal, facial nerve, and tegmen. The degree of difficulty noted with mastoid cavity care is greatly dependent on the postoperative anatomy of the meatus and mastoid. It is important to remove all squamous and ceruminous debris. Some moisture medial to the debris may be revealed, which may be dusted with Boric acid powder in order to prevent infection. Excessive moisture may be cleared with suctioning; however, this commonly leads to complaints of dizziness. Swabbing the mastoid cavity with cotton held by an alligator forceps or metal applicator may limit the need for suction. The use of a smaller diameter suction device will minimize dizziness.

DRAINAGE OF A HEMATOMA OF THE AURICLE

Hematoma of the auricle is most commonly noted in wrestlers but is also seen in other sports such as boxing and rugby. Hematoma of the auricle is formed by a shearing force, which separates the skin and perichondrium from the underlying cartilage. Wrestling headgear and rugby scrum caps help reduce the incidence of auricular hematomas.

Cartilage receives its blood supply from the overlying perichondrium. A shearing injury will cause a collection of blood separating the vascular supply from the cartilage, which will result in cartilage necrosis. "Cauliflower ear" is the term used to describe the altered appearance of the pinna related to subsequent fibrosis, contracture, and formation of reactive or calcified perichondrium. The urgent treatment of auricular hematoma is encouraged in order to reestablish the blood supply to the cartilage and avoid this sequela. The resulting deformity of the pinna is primarily a cosmetic concern; however, thickening of cartilage in the conchal region may lead to a collapsing ear canal and hearing loss.

Preoperative Period

A careful history is obtained in order to determine the mechanism of injury as well as the duration of time that has lapsed since the injury. Athletes may be unwilling to miss practice or competition during the healing process. In this instance, bulky dressings and simple needle aspiration should be avoided. Open exploration may be required in recurring hematomas.

Surgical Technique

Incision and drainage is the preferred method of treatment, as this technique provides a lower risk of recurrence compared



Fig. 125.4. Penrose drain and Silastic bolsters in place for treatment of auricular hematoma.

to needle aspiration. All hematomas, including those that are multiloculated and intracartilaginous, can be successfully treated with this technique. The pinna is treated with surgical preparation solution. Anesthesia of the pinna is obtained by using a regional nerve block. An incision is created in the helical or antihelical fold to conceal the scar. Blood and serous fluid are expressed from the incision facilitated by digital compression. A fine hemostat may be introduced into the incision in order to ensure that any loculations are incorporated into the pocket. Once the hematoma is completely evacuated, a small sterile rubber band or a Penrose drain may be placed. The success of this procedure relies on proper placement of a compression dressing. A bolster dressing has been demonstrated to be effective against recurrence despite immediate return to contact sports. A dental roll is cut to the size of the hematoma with a similar or slightly smaller size used on the medial surface of the pinna. This can also be supported using Silastic sheeting (0.04-inch thickness). 3-0 nylon or silk suture on a Keith needle is inserted through the dental roll and passed through the pinna in a lateral to medial fashion. It is then passed through the medial dental roll and back through the medial roll again. The suture is then passed through the pinna in a medial to lateral fashion and then through the lateral dental roll. The dental rolls and incision site are coated liberally with an antibiotic ointment. This creates a mattress suture, which is then tied to secure the bolster (Fig. 125.4).

Postoperative Period

After draining the hematoma, the patient is monitored for signs of recurrence or infection. Oral antibiotics are used while the bolster is in place. The bolster is removed in 5 to 7 days. Patients are instructed to watch for evidence of recurrence of the hematoma.

INCISION AND DRAINAGE OF AN EAR ABSCESS

The external ear is a common site of local infections that require incision and drainage of a fluctuant collection of purulent exudate and necrotic tissue. These infections can be as small as a furuncle in the canal or as extensive as a subperiosteal abscess. They will sometimes drain spontaneously or after treatment with warm compresses and manual manipulation. Antibiotics are seldom necessary but should be considered in cases with significant concomitant cellulitis.

Perichondritis, or inflammation of the perichondrium, and chondritis, or inflammation of the cartilage, may lead to true abscess formation and require incision and drainage. Débridement may be necessary to contain or resolve the infection. The auricular cartilage is relatively avascular, with a consequent diminished capacity to clear an infection and limited delivery of systemic antibiotics at adequate minimal inhibitory concentrations.

All patients with an acute formation of a painful fluctuant mass in the ear require drainage. Although some furuncles can be managed with warm compresses and manual expression, incision and drainage may be required. In the early stages of infection of the ear, a true abscess may not have formed. High-dose systemic antibiotics can sometimes prevent abscess formation. These patients will require close monitoring in order to determine if the infection resolves or if an abscess requiring drainage has developed.

Preoperative Period

Antibiotic prophylaxis should be considered in transplant or other immunocompromised patients, diabetics, alcoholics, and patients receiving chemotherapy or steroids.

The size and cause of the abscess will determine what type of drainage procedure is appropriate. A small abscess may require only a small drain for a few days, while a larger abscess will likely require a more elaborately planned procedure and postsurgical plan. The incision should be planned so that it does not hinder future reconstructive procedures when treating infections that are likely to cause destruction of cartilage.

Surgical Technique

Injection of local anesthetic at several points lateral to the abscess generally suffices for incision and drainage of furuncles. An abscess involving the pinna may be incised with a no. 11 blade. An abscess situated in the EAC may be accessed more readily with a myringotomy blade.

For a larger abscess, a regional ear block may be required. The abscess is incised with a no. 15 blade along the natural contour of either the helical or antihelical fold. The purulent exudate is collected and sent for culture. The abscess cavity must be completely evacuated with all loculations incorporated into the main abscess cavity. The cartilage is examined and any necrotic cartilage is débrided. It is possible that the cartilage may need to be débrided again, but staged débridement helps to minimize the size of the helical rim deformity. If extensive necrosis of the cartilage is noted, performing the procedure in the operating room may be advised. Once the cavity is adequately débrided, it is flushed with saline. The incision is not closed and use of a drain should be considered.

Postoperative Management

Furuncles do not generally require follow-up, but the patient should return if the pain or swelling worsens, recurs, or if the infection has not resolved in 1 week. Patients with an abscess of the auricle should be instructed that it may take several weeks for the infection to clear completely and that they are at risk for recurrence during this time. If the infection recurs, it should again be drained immediately with débridement of necrotic tissue. If a defect in the auricular rim develops, the patient should be offered consultation for reconstruction of the rim.

BOX 125.1 Masses in the External Ear Canal

BENIGN

Cholesteatoma
Eosinophilic granuloma
Exostosis
Fibrous dysplasia
Keratosis obturans
Neurofibroma
Osteoma
Paraganglioma/schwannoma
Stenosis
Temporomandibular joint herniation
Vascular lesions

MALIGNANT

Adenocystic carcinoma
Basal cell carcinoma
Cerumen gland tumor
Malignant melanoma
Metastatic cancer
Soft tissue sarcoma
Squamous cell carcinoma

BIOPSY OF A MASS IN THE EXTERNAL AUDITORY CANAL

Detection of a mass in the EAC may occur during routine otologic examination. A mass may also be associated with hearing loss, otalgia, otorrhea, or bleeding. Masses in the EAC may be benign or malignant (Box 125.1). Certain lesions may be diagnosed by otologic examination alone. For example, osteomas and exostosis can be diagnosed based on their classic appearance and by gentle palpation. Patients presenting with recent onset of pain and drainage may have lesions best treated with topical drops containing both an antibiotic as well as a steroid prior to considering biopsy.

Polyps may arise from a tympanic membrane perforation or related to cholesteatoma. Caution should be used with polyps arising from the posterior canal wall or if the site of origin is not easily identified. Approximately 13% of facial nerve schwannomas present as a mass in the ear canal.[1] If the site of origin cannot be identified, CT imaging is recommended in order to evaluate the facial nerve prior to removing a polyp. When safe to proceed, removing a polyp should be followed by treatment with steroid/antibiotic drops. Treatment in this fashion will reduce inflammation, which will facilitate a definitive surgical procedure. Removal of an inflammatory polyp can typically be performed without anesthesia. Cupped forceps are used to remove the polyp.

Malignant otitis externa must be considered in the differential diagnosis regarding a mass in the ear canal, particularly in patients with diabetes. Granulation tissue noted at the bony-cartilaginous junction is characteristic of malignant otitis externa; however, biopsy of the granulation tissue is recommended in order to rule out a malignancy. Of special consideration is the pulsatile mass as seen in large glomus tumors. Biopsy of these lesions in the office is strongly discouraged, due to the high vascularity of this tumor, resulting in bleeding that is difficult to control in the office setting.

Instruments and Equipment to Have Available

The surgeon should have the following readily available: appropriate sized speculums, 5F suction devices, fine cupped forceps, Belucci scissors, epinephrine diluted to 1:10,000 or silver nitrate for topical application, specimen collection container, and bacitracin for topical application after the procedure.

Postoperative Management

Topical therapy with antibiotic and steroid drops is recommended for inflammatory processes. Follow-up in one week should be arranged for evaluation of the biopsy site and in order to discuss the results of the biopsy.

INTRATYMPANIC INJECTIONS

Intratympanic injections of gentamicin and corticosteroids have become very popular outpatient treatments for conditions such as Meniere disease (MD) and sudden idiopathic sensorineural hearing loss (SSNHL). This treatment is very well tolerated, is not time consuming, does not require an extended time of convalescence, and is repeatable. The puncture site typically closes in a few weeks. There is a low risk of associated infection or persistent perforation.

The round window is the main site of chemical diffusion to the inner ear. Obstruction of the round window membrane reduces absorption of the medication.[2] There are various delivery techniques described in the literature. Intratympanic injection is the method preferred by the author.

Intratympanic Gentamicin

The treatment of MD-related vertigo generally proceeds in a stepwise approach. When patients fail to respond to conservative measures with dietary changes and diuretics, more aggressive measures are employed. Intratympanic gentamicin (IT- GENT) is a favored treatment. It can be used as a standard (high-dose regimen) or a low-dose regimen for partial or total chemical vestibular ablation. This treatment is a repeatable, low cost ablative therapy, which selects the involved ear, and may eliminate the need for surgical intervention.

Gentamicin is the most commonly used aminoglycoside due to the fact that it has a relatively greater vestibular toxicity compared to its cochlear toxicity. It causes a partial destruction of the vestibular hair cells and of the dark cells. Streptomycin is not generally used because it has been demonstrated to cause a poorer hearing outcome and lower rate of control of vertigo.[3] This treatment affords a 90% rate of control of MD-related vertigo. The incidence of hearing loss has been listed between 30% and 17%.[4] The higher incidence of hearing loss was noted with an ablative high-dose treatment regimen as opposed to the currently favored conservative low-dose regimen.

Intratympanic Corticosteroids

Intratympanic steroid injection has been advocated for treatment of both SSNHL and MD. It has been demonstrated that intratympanic administration provides a higher steroid concentration compared to systemic therapy.[5] It has been described as a salvage therapy for SSNHL; however, some clinicians are offering this as first-line treatment.

Indications

Intratympanic Gentamicin

As an ablative procedure, conservative therapies should have been tried and failed prior to considering IT-GENT.

Furthermore, the diagnosis of MD should be confirmed with careful discussion and review of the characteristics of the vertigo episodes. Other potentially similar causes of vertigo, such as vestibular migraine, benign paroxysmal positional vertigo, and superior semicircular canal dehiscence, should be ruled out by history, physical, audiometric and vestibular testing, and imaging. Other nonablative options should be reviewed, including subcutaneous histamine injections and use of a Meniett device (Medtronic), as well as surgical options such as endolymphatic sac decompression, labyrinthectomy, and vestibular nerve section. The risks of IT-GENT need to be discussed, including persisting TM perforation, permanent hearing loss, increased tinnitus, and chronic disequilibrium and their associated implications. The risk of MD affecting the contralateral ear should be reviewed. Patients should be counseled to expect the possibility of disequilibrium for several days after treatment. Vestibular physical therapy could be initiated prior to the IT-GENT if possible. Caution should be used prior to treating elderly patients, visually impaired individuals, and patients with peripheral neuropathy due to the increased difficulty compensating for the unilateral weakness. Gentamicin should not be used in patients who have MD affecting the only hearing ear.

Intratympanic Dexamethasone

A recent multicenter trial has demonstrated similar hearing responses with use of oral and intratympanic steroids.[6,7] Intratympanic dexamethasone (IT-DEX) may be used in combination with prednisone, as a salvage therapy for those with persisting sudden sensorineural hearing loss,[8] or in patients who may not tolerate systemic steroid therapy.

Preoperative Preparation

Pure tone audiometry should be performed before each injection of either gentamicin or dexamethasone. Vestibular testing should be performed prior to treatment with IT-GENT in order to ensure that the contralateral ear does not demonstrate hypofunction, which would be a contraindication to ablative therapy. In MD, elevated thresholds are often noted on vestibular evoked myogenic potentials. Patients with SSNHL should undergo contrast-enhanced magnetic resonance imaging (MRI) in order to rule out a retrocochlear process such as a vestibular schwannoma. The first treatment with IT-DEX should not be delayed until after the MRI is obtained, as prompt initiation of treatment is associated with a better prognosis for hearing recovery.

Surgical Technique

The patient is positioned supine with his or her head turned 45 degrees away with the treatment ear up (Fig. 125.5). The tympanic membrane is anesthetized with topical phenol applied to focal regions anterior superiorly and posterior inferiorly. A tuberculin syringe with a 1.5-inch 25-gauge needle is filled with 0.6 mL. A fully filled tuberculin syringe is difficult to handle due to the position of the plunger being beyond the reach of the thumb of the injecting hand. The needle is gently bent in order to provide adequate visualization of the TM and the rising air fluid level (Fig. 125.6). A puncture is made in the anterior superior TM, which provides a means for air to escape from the mesotympanum during the injection. Through the posterior inferior puncture, roughly 0.4 mL of solution is injected into the middle ear space. The gentamicin solution is buffered with sodium bicarbonate at a final concentration of 30 mg/mL. Depending on the availability of a compounding pharmacy for preparation, the concentration of dexamethasone solution is from 10 mg/mL to 24 mg/mL. Methylprednisolone has been used but is associated with a greater sense of discomfort during the injection. The medication is slowly injected into the middle ear space, while the air fluid level is followed to the level of the anterior superior puncture site. The injection is completed once the middle ear is filled and a small efflux of medication is noted in the ear canal. The needle is withdrawn and the patient remains supine for 25 minutes. A basin and tissues are provided to the patient, who is instructed to spit secretions and to avoid swallowing in order to minimize rapid clearance of the medication from the middle ear space.



Fig. 125.5. The injection is performed with the patient's head turned 45 degrees away from the affected ear. He remains in this position for 25 minutes and is provided with tissues to handle saliva to avoid swallowing.

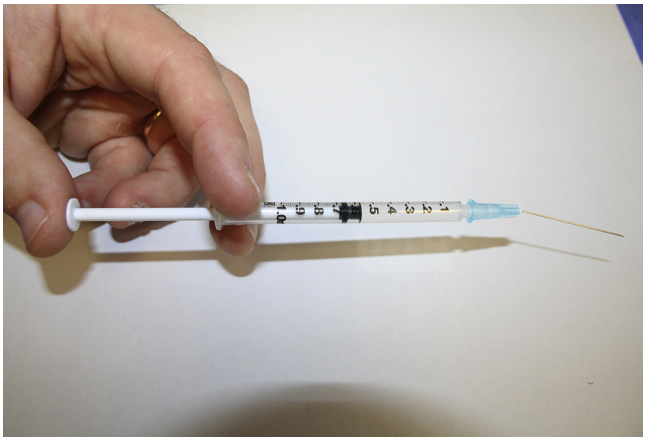

Fig. 125.6. Bending the needle slightly allows better visualization during the injection.

Postoperative Management

Intratympanic Gentamicin

Dry ear precautions are recommended until follow-up in 4 weeks. At the follow-up visit, if the patient continues to complain of episodes of vertigo, the injection can be repeated. Audiometry is repeated before each injection and 2 months

after the last injection. Diuretic therapy and dietary recommendations are maintained during the course of treatment.

Intratympanic Dexamethasone

Dry ear precautions are recommended and follow-up in 1 week is arranged for repeat audiometric testing. If an improvement is noted without return to baseline, repeat injection is performed. Injections are performed on a weekly basis for 3 weeks until the hearing returns to baseline or improvement plateaus.

MYRINGOTOMY AND INSERTION OF TUBES

Myringotomy with or without tube insertion is commonly performed in the outpatient setting for management of chronic otitis media with effusion, complicated acute otitis media, and for eustachian tube dysfunction. Other less common indications are for access of the middle ear for medication delivery and to provide ventilation for hyperbaric oxygen therapy in patients who are unable to clear their ears. Most adults and many older children are able to tolerate myringotomy and tube insertion in the clinic with use of local anesthesia. The choice of tube style is generally determined by physician preference; however, smaller tubes are chosen for short-term therapy, midsize tubes are used for chronic otitis media with effusion, and larger lumen tubes are considered for patients with mucoid effusions. Longer lasting Goode T-tubes may be placed in the clinic setting with local anesthesia in a cooperative patient with a favorably sized ear canal; however, placement of the T-tube may require sedation in an operative setting due to its size and the relative technical difficulty associated with proper placement.

Preoperative Preparation

All patients are examined using an operating microscope. Pneumatic otoscopy should be included, as this will occasionally reveal evidence of an effusion that may not otherwise be noted. Tuning fork testing will help confirm a conductive hearing loss; however, formal audiometric testing is recommended for diagnostic and medico-legal purposes. Any adult with a unilateral effusion should undergo examination of the nasopharynx in order to evaluate for possible adenoid hypertrophy or mass lesion. The need for water precautions is discussed prior to tube placement, and avid swimmers may prefer either to be fit with custom earplugs or to continue nonsurgical treatments.

A myringotomy without tube insertion will generally close spontaneously in days and is therefore not recommended for chronic otitis media with effusion. Acute serous effusions in the setting of allergies or upper respiratory tract infections usually resolve spontaneously, and therefore, tube insertion is not recommended. Treatment of allergy symptoms, frequent autoinsufflation, and use of decongestants are recommended. Myringotomy is not recommended for initial treatment of acute otitis media; however, it may be considered for pain relief. Myringotomy and tube insertion are recommended when acute otitis media does not respond to antibiotic therapy. It is also recommended for acute otitis media complicated by facial nerve paralysis, vertigo, sensorineural hearing loss, mastoiditis, or intracranial complications. Vascular anomalies (aberrant carotid artery or dehiscent jugular bulb) and glomus tumors may be mistaken for effusion and may need to be ruled out with imaging prior to myringotomy in order to avoid the risks of bleeding and neurovascular complications.

Instruments and Equipment to Have Available

The surgeon should have the following readily available: appropriate sized ear speculums, cerumen curettes, phenol, phenol applicator, myringotomy knife, 3F and 5F suction devices, fine alligator forceps, a fine right-angled or gently curved pick, and an assortment of different style tubes, depending on the indication for placement. Topical epinephrine should also be accessible for bleeding related to an inflamed tympanic membrane.

Surgical Technique

Positioning the patient from a sitting to a fully recumbent position is based on clinician preference. The procedure is performed with use of lower magnification on the operating microscope in order to provide greater ease of instrument handling. It is important to be mindful of the walls of the ear canal in order to avoid bleeding or discomfort. Myringotomies are performed either in an anterior inferior or a posterior inferior location. The posterior superior quadrant is avoided in order to avoid trauma to the ossicles. The anterior superior quadrant may be difficult to access if there is a prominent anterior canal wall overhang. Phenol is applied directly to the planned myringotomy site, and a radial myringotomy is performed. The type of tube used will dictate tube handling for placement. Generally, bobbin style tubes are grasped on their lateral flange and are positioned partially in the myringotomy. A fine pick is used to gently insert the medial flange through the TM. Some tubes may be placed with one fluid motion; however, a stepped technique will allow less tension to be applied to the TM and therefore less discomfort for the patient.

Postoperative Management

Serous effusions do not require treatment with antibiotic drops. However, if bleeding is encountered, with evidence of infection, or if a thick mucoid effusion is identified, use of antibiotic drops with or without steroids for 5 to 7 days may help resolve the infection more rapidly and prevent obstruction of the tube. Follow-up in 1 month followed by every 6 months is recommended until the tube extrudes. Very close monitoring is recommended in patients with complications of acute otitis media requiring tube insertion.

Editorial Comment

As reviewed by the author, a significant varied list of otologic procedures can be performed in the office or clinic. In order to avoid complications or anxiety and pain to the patient, it is important for the surgeon to realize the limitations imposed by the procedure and tolerance of the patient. The operative skills of the surgeon can be more critical and demanding in this setting. Training and experience in this regard comes from procedures performed in the operating room, where techniques can be mastered in a controlled environment.

Intratympanic therapies have transformed the delivery and outcomes of previously limited treatment options. Gentamicin instilled into the middle ear has provided an excellent means of controlling vertigo attacks from Meniere disease, avoiding more complicated operative interventions.

Since the patient is fully awake, it is important to have the office equipped with anticipated medications, dressings, and instruments needed to complete these procedures.

The physician should have a reassuring demeanor to put the patient at ease in this potentially challenging setting.

Barry Hirsch

Access the review questions online at http://www.expertconsult.com

REFERENCES

1. Lipkin AF, Coker NJ, Jenkins HA, et al. Intracranial and intratemporal facial neuroma. Otolaryngol Head Neck Surg 1987;96:71–79.
2. Silverstein H, Rowan PT, Olds MJ, et al. Inner ear perfusion and the role of round window patency. Am J Otol 1997;18:586–589.
3. Blakley BW. Clinical forum: a review of intratympanic therapy. Am J Otol 1997;18:520–526.
4. Wu IC, Minor LB. Long-term hearing outcome in patients receiving intratympanic gentamicin for Menere's disease. Laryngoscope 2003;113:815–820.
5. Chandrasekhar SS. Intratympanic dexamethasone for sudden sensorineural hearing loss: clinical and laboratory evaluation. Otol Neurotol 2001;22:18–23.
6. Rauch SD, Halpin CF, Antonelli PJ, et al. Oral vs intratympanic corticosteroid therapy for idiopathic sudden sensorineural hearing loss. J Am Med Assoc 2011;305:2071–2079.
7. Halpin C, Shi H, Reda D, et al. Audiology in the sudden hearing loss clinical trial. Otol Neurotol 2012;33:907–911.
8. Haynes DS, O'Malley M, Cohen S, et al. Intratympanic dexamethasone for sudden sensorineural hearing loss after failure of systemic therapy. Laryngoscope 2006;117:3–15.

REVIEW QUESTIONS

1. Which of the following agents can be used for topical anesthesia for office-based procedures in otology?
   a. Phenol
   b. LET
   c. EMLA
   d. All of the above

2. Which of the following lesions of the ear canal does not require biopsy for diagnosis?
   a. Paraganglioma
   b. Exostosis
   c. Adenocystic carcinoma
   d. Squamous cell carcinoma

3. What is the incidence of hearing loss with low-dose intratympanic gentamicin treatment for Meniere disease?
   a. 90%
   b. 50%
   c. 30%
   d. 17%

126 Foreign Bodies of the External Auditory Canal

Douglas M. Hildrew, Barry Hirsch

INTRODUCTION

The acute event resulting from entrapment of a foreign body in the ear canal will bring most patients to the attention of a physician, physician's assistant, or nurse practitioner. Patients may be treated in a variety of settings including an emergency room, clinic, or office. It is important to note that different age- and gender-specific patterns emerge in describing the specific types of foreign bodies found within the external auditory canal.[1] A recent review of the National Electronic Injury Surveillance System (NEISS), a database that tracks injuries caused by consumer products, revealed that children between the ages of 2 and 8 were the most common age group affected. Jewelry was by far the most common foreign body seen in the young population, with beads and earrings being the most frequently identified types.[1] Among adults and senior citizens, the most common offenders were cotton swabs and first aid supplies.[1] After ear cleaning, a person may realize that the cotton tip is no longer attached to the end of the applicator. Senior citizens are also uniquely vulnerable to the accidental insertion of disk batteries owing to altered cognition, reduced tactile sensation, and the more frequent use of hearing aids.[1]

Adolescents and/or adults may become immediately aware that an object that they were using to clean or manipulate the ear has become dislodged and remains in the external auditory canal. The most common inorganic object creating this problem, as already stated, is the end of a cotton-tipped applicator. Similarly, other materials (e.g., facial tissue and paper) can be rolled in an elongated fashion and used to either probe, clean, or pack the ear. Institutionalized adults and children may use these materials instead of cotton-tipped applicators, medical packing, or earplugs. In this population, if drainage, infection, or odor has not developed, such material may be found only on routine physical examination.

Along with using instrumentation to clean their ears, adults also place objects in the ear canal for protection, including devices to minimize water exposure because of recurrent otitis externa or perforation of the tympanic membrane. Materials used for hearing protection can become lodged or break off and remain in the external canal. Examples of such products include silicone putty used for sound or water protection and Silastic occlusive plugs or foam inserts for sound protection. Again, patients become acutely aware of broken off materials remaining in the ear canal.

The list of objects that children put in their ears is endless. Unless a witness observes a child placing a foreign body in the canal, its presence may not be discovered until routine physical examination detects the object or problems arise because of its presence. Objects that occlude the ear canal can produce hearing loss. This is a common chief complaint in an aware child or adult. Inflammation caused by the foreign object may result in infection and drainage. Localized aural discharge, cellulitis of the concha and external meatus, or serosanguineous otorrhea would prompt further evaluation. Some materials are more difficult to extract from the ear canal. Once water enters the external canal, vegetable materials such as beans and peas can swell and cause obstruction, pain, and maceration. Other materials that have been found in the ear canal include small toys, beads, erasers, crayons, pits from fruit, disk batteries, nuts, and stones. Disk batteries should be removed as soon as possible to avoid the liquefaction necrosis that results when moisture and secretions permit the flow of electrons.[2] Irrigation of the ear canal should be avoided to minimize the risk of generating an electric current. Similarly, unsuccessful attempts at removal of the battery that result in trauma and bleeding in the ear canal would also allow flow of current and thus lead to further tissue destruction.

Insects occasionally find their way into the ear canals of children and adults alike. These are usually flying insects, but crawling insects may also enter the canal, especially when a person is sleeping. Patients become acutely aware of such a situation because of the noise generated by the insect and the associated pain. Management in this situation becomes more urgent than that called for by inanimate objects.

KEY OPERATIVE LEARNING POINTS

1. Aural irrigation to remove foreign bodies (other than insects) in the external auditory canal should be avoided because the object is rarely flushed out and skin maceration often results.
2. Firm, rounded objects are notoriously difficult to grasp and remove.
3. Live insects should be drowned with alcohol, mineral oil, or topical anesthetics (Pontocaine, Xylocaine).
4. A large nasal suction (10-12 French) device may make sufficient contact with the object to remove it from the canal.
5. Passing a right-angled hook parallel to the object and then beyond it allows optimal placement of instruments for extraction.
6. Injection of a local anesthetic followed by canal dilatation with progressively larger specula may facilitate removal of the foreign body.
7. Ease of extraction is directly proportional to the number of previous failed attempts.

PREOPERATIVE PERIOD

History

1. History of present illness
   a. Risk factors: Infants and children
   b. Onset: Was the foreign body insertion observed?
   c. Location: What items were around the infant/child at the time of insertion?
   d. Duration: Approximately how long has the foreign body been in place?
   e. Other: Are there any disk batteries and/or hearing aids in the house?
   f. Pain
   g. Drainage/odor
   h. Bleeding
   i. Hearing loss
   j. How many times has extraction been attempted and by whom?

2. Past medical history
   a. Prior treatment
      1) If there is a history of previous foreign bodies and infection (Beware of canal stenosis.)
      2) If there is a history of recurrent infection and drainage, the foreign body may have been present for weeks or months.
      3) If there is a history of recurrent infection, the ear canal skin may be friable and hypervascular.
   b. Medical illness
      1) Diabetes mellitus
   c. Surgery
      1) If there has been previous otologic surgery, determine its extent and type.
         a) Canal wall down can put the facial nerve at risk.
         b) Congenital anomalies can cause canal stenosis.
   d. Family history
      1) Clotting disorders can be inherited.
   e. Medications
      1) Antiplatelet/anticoagulant drugs

Physical Examination

1. Binocular microscopic otoscopy
   a. Evaluation of both ears
2. Anteroposterior rhinoscopy
   a. Evaluation for coexisting foreign body
3. Larynx
   a. Specifically listen to and observe breathing patterns.
      1) If concern arises for a coexisting foreign body, consider flexible fiberoptic laryngoscopy.
4. Pulmonary
   a. Auscultate for evidence of a coexisting aspirated foreign body.
      1) If concern arises for a foreign body, consider chest radiography.

Imaging

1. Chest radiograph
   a. Not routinely necessary
   b. Consider if there is concern for a coexisting foreign body in the tracheobronchial tree
2. Computed tomography (CT) scan
   a. Not routinely necessary
   b. Consider if patient has a history of extensive otologic surgery, disease, or the medial extent of the foreign body is in question
3. Magnetic resonance imaging (MRI)
   a. Not routinely necessary
   b. Consider if patient has a history of extensive otologic surgery or disease and there is concern for meningoencephalocele or cerebrospinal fluid (CSF) otorrhea
4. Audiogram
   a. A baseline audiogram should be obtained if it is anticipated that removal of the foreign body requires monitored anesthesia care (MAC) or general anesthesia.

Indications

1. Painful or draining ear
2. Concern for a foreign body
3. Hearing loss

Contraindications

1. An uncooperative patient may require MAC or general anesthesia.

Preoperative Preparation

1. In most situations, removal of a foreign body is an elective event.
   a. Permits planning in terms of the appropriate instrumentation, lighting, the type of anesthesia (if needed), and the method of extraction
2. The patient should be relaxed and calm.
   a. Facial grimacing contracts and moves the external auditory canal.
   b. Uncooperative patients may suffer iatrogenic trauma.
3. Exploration of the ear under intravenous sedation or general anesthesia should be considered for patients who may have damage to the ossicular chain or inner ear.
   a. General anesthesia will probably be necessary for most children and anxious, uncooperative adults.
   b. Patients with acute hearing loss and dizziness should be suspected of injury transmitted to the inner ear.
      1) An audiogram and CT scan should be obtained for suspicion of violation of the tympanic membrane.

OPERATIVE PERIOD

Anesthesia

- Extraction of a foreign body is most frequently performed in the clinic without anesthesia.
- A particularly anxious, difficult, or mentally challenged patient may require MAC anesthesia.
- If there is severe acute infection from prolonged exposure to a foreign body, general anesthesia may be required.

Positioning

- Position the patient so that a head rest is seated comfortably, stabilizing the head.
- A papoose may be necessary for uncooperative infant/children, but this inevitably exacerbates patient anxiety and should be avoided if possible.
- Extraction can be accomplished with the patient in either a supine or upright position.

Preoperative Antibiotic Prophylaxis

- Clean contaminated procedure
- Preoperative antibiotics are generally not required.
  - Consider if the patient shows signs of cellulitis
- Postoperative antibiotics may be needed.
  - Traumatized external auditory canal
  - Otitis externa or surrounding cellulitis
- Antibiotic choices
  - Systemic: Amoxicillin, amoxicillin-clavulanate, clindamycin, cepahlosporin
  - Ototopical: Ofloxacin, ciprofloxacin/dexamethasone, neomycin/polymyxin-B/hydrcortisone

Monitoring

- Routine anesthesia monitoring only if patient required MAC or general anesthesia

Instruments and Equipment to Have Available

- Binocular otologic microscope
- Hydrogen peroxide, isopropyl alcohol, mineral oil
- Injectable lidocaine with epinephrine, syringe, and 25-gauge needle
- Otologic specula

  - Size: 3, 4, 5, and 6 mm
- Suction and suction tips
  - Size: 3, 5, 7, 10, and 12 French
- Forceps
  - Small alligator and Hartman-style forceps
- Right-angled hook
- Cerumen curette
- Wire cerumen loop
- Silver nitrate
- Cotton-tipped applicator
- Ear wick
- Ear irrigation kit (rarely used)

Key Anatomic Landmarks

1. Pinna, conchal bowl, and external auditory canal
2. Tympanic membrane and ossicles
3. If previous otologic canal wall down surgery or congenital anomalies, one must ensure they are oriented to the facial nerve, lateral canal, oval window and round window

Prerequisite Skills

1. Binocular microscopic otoscopy and fine motor skills
2. Thorough understanding of the anatomy of the ear

Operative Risks

1. Laceration to the skin of the external auditory canal
   a. Cellulitis
   b. Bleeding
2. Perforation of the tympanic membrane
3. Ossicular trauma
   a. Ossicular dislocation
   b. Conductive hearing loss
   c. Fractured stapes
   d. Perilymphatic fistula
   e. Sensorineural hearing loss
   f. Vertigo
4. Postoperative canal stenosis
5. Infection
   a. Adult or pediatric patients with otorrhea, hearing loss, and obstruction or occlusion of the ear canal who fail to respond to topical and systemic therapy may have pathology of the middle ear and mastoid or foreign bodies causing their symptoms and findings.
   b. If medical therapy fails to reduce the inflammation that limits visualization of the medial canal and tympanic membrane, a CT scan would be appropriate to assess the status of the external canal, middle ear, and mastoid.

Surgical Technique

Foreign bodies can be categorized not only by their chemical composition but also by their shape and consistency. Understanding the physical properties of a foreign body facilitates the choice of method for removal. Soft and wet objects similar to cerumen can be suctioned or flushed from the canal. Firm or hard foreign bodies require specific instruments for extraction. Round objects may become wedged at the bony isthmus or the junction of cartilage and bone. Small foreign bodies may shift to the medial canal and become caught in the anteroinferior sulcus between the tympanic membrane and the bony canal.

The success and/or difficulty of foreign body extraction from the external auditory meatus is strongly influenced by the number of previous failed attempts.[3] Since removal of a foreign body may be attempted first by emergency department personal and pediatricians, the otolaryngologist may encounter significant edema of the canal skin.[3] One may also find that the foreign body is located medial to the bony cartilaginous junction as a result of previous failed attempts—a situation that can be particularly challenging.



Fig. 126.1. A large-gauge suction is usually successful in removing most objects from the external auditory canal. Care must be taken to not push the foreign body more medially.

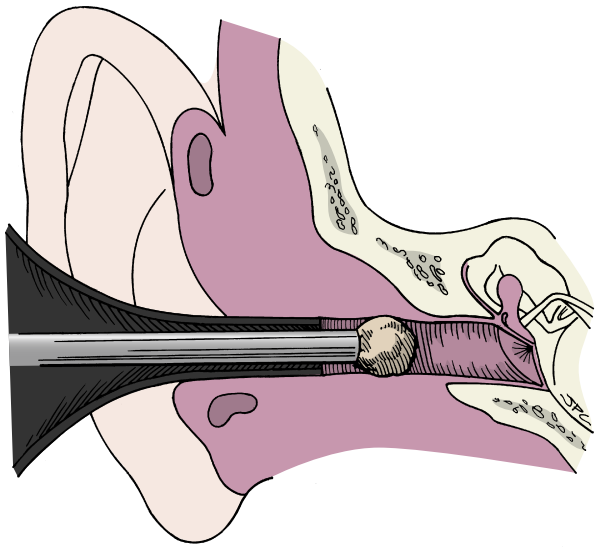

Fig. 126.2. A right-angled hook is passed beyond the object, which is then extracted laterally.

- *Removal of jewelry*
  - Removal should not be unnecessarily delayed.
    - Timely treatment reduces the opportunity for resultant edema of the external auditory canal and otitis externa
  - Beads can be hard and smooth, making them difficult to remove because they cannot be readily grasped.
  - A large nasal suction (10-12 French) device can be most useful if it is possible to create a seal between the suction tip and the foreign body (Fig. 126.1).
  - A right-angled hook placed behind the foreign body can be a well-suited method of extraction (Fig. 126.2).
- *Removal of disk batteries*
  - Do not irrigate, as this will cause a flow of current, leading to further tissue destruction.

- Do not lacerate the external auditory canal skin, as blood will allow a flow of current, thus leading to further tissue destruction.
- The orientation of the battery in the external auditory canal can make it difficult to grasp.
- The combined use of a forceps or right-angled hook is often successful.
- Most disk batteries are magnetic, and access to a strong magnet can assist greatly in atraumatic extraction.

- ***Removal of insects***

Management of insects in the ear canal requires additional material. A live insect can be difficult and painful to extract. Various solutions, including ether, isopropyl alcohol, and mineral oil, are effective in drowning the insect before flushing or extraction. Topical tetracaine (Pontocaine) or lidocaine (Xylocaine) solution can also be used to submerge and paralyze the insect in the ear canal.[3] These are readily available in all emergency room settings.

- A live, moving insect can cause pain, irritation, and potential trauma to the tympanic membrane.
- Thorough inspection should help to identify the insect and evaluate for potential trauma.
- Place patient in the supine position with the involved ear facing up.
- Drown and/or paralyze insect by filling the ear canal with ether, isopropyl alcohol, mineral oil, tetracaine, or lidocaine.
  - This may lead to a flurry of activity as the insect drowns.
  - Should the patient have severe pain, the skin of the external canal can be infiltrated with a local anesthetic.
- The insect is extracted from the canal with suction, which also removes the excess solution.
- Once the insect has been removed, the canal is carefully inspected.
  - Loose appendages such as wings or legs should be carefully removed with forceps or a fine cotton-tipped applicator.
  - The integrity of the skin of the ear canal and the tympanic membrane is verified.

- ***Any vegetable material is removed.***
  - If the object is relatively dry and intact, extraction with suctioning may remove it.
  - It may be necessary to place a small, right-angled hook medial to the object to manipulate it into the lateral canal.
  - Irrigation should be avoided so as to minimize swelling, maceration, and disruption of the integrity of the foreign object.
    - Peas, beans, nuts, and corn have the potential to swell owing to exposure to sebaceous secretions from the canal, water from swimming or showering, or attempts at irrigating the ear canal.
  - If the object is soft, crumbling, and friable and cannot be extracted with suction, irrigation may be necessary.
    - Mixing hydrogen peroxide with an equal volume of warm tap water mechanically facilitates aural irrigation.
    - An irrigating system is most effective.
    - Other systems would include a large-gauge angiocatheter attached to a syringe.
      - Large metal ear syringes are also available for this purpose.
    - Care is taken to avoid directing excessive hydraulic pressure at the tympanic membrane.

- Surgical Removal
  - A wedged foreign object may completely occlude the canal, prohibiting instrumentation and extraction. Access can be afforded through a relaxing 12-o'clock incision at the incisura, which widens the meatus (Fig. 126.3). First local anesthetic must be injected into the ear canal. This may best be done in the operating room. On rare occasions, a postauricular approach will be necessary if the object is wedged at the bony isthmus of the canal. A prominent spine of Henle or tympanomastoid suture may have to be removed or recontoured (Fig. 126.4). This is done under intravenous (IV) sedation or general anesthesia.

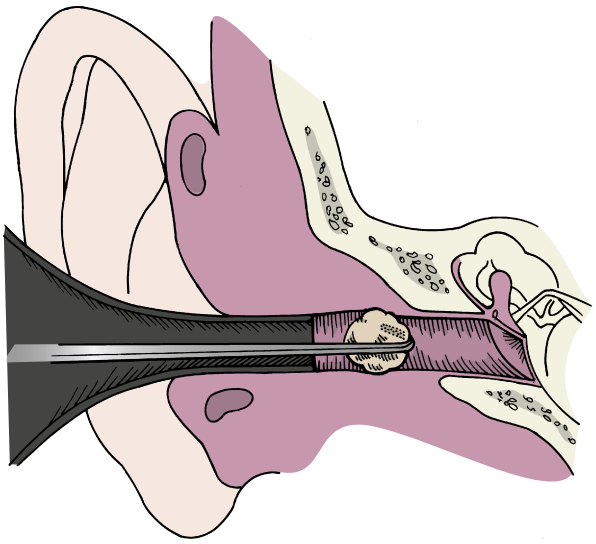

Fig. 126.3. An incision is made in the incisura (12-o'clock position) of the external auditory meatus to widen the meatus and permit an instrument to be passed medial to the foreign body.

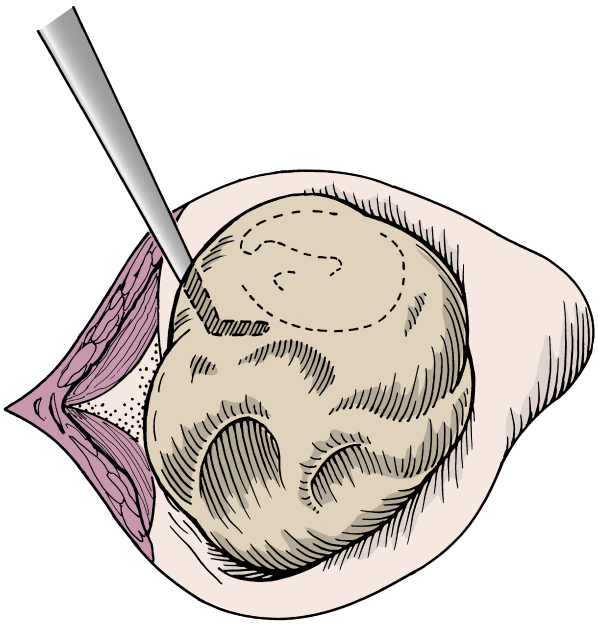

Fig. 126.4. The ear has been reflected anteriorly to expose the lodged foreign object medially.

Common Errors in Technique

1. Instrumented removal of a live insect without first drowning it can intensify the pain and stimulation experienced by the patient.

2. Instrumentation directed medially along the posterior ear canal may contact and traumatize the tympanic membrane.
3. Aggressive manipulation may result in more medial impaction and possible injury to the tympanic membrane and ossicular chain.
4. Failure to recognize and properly reapproximate lacerated canal skin may lead to trapped epithelium and the development of a cholesteatoma in the canal.
5. Repeated unsuccessful attempts at removing the foreign body will result in canal trauma, further obstruction, and an uncooperative, irritable patient.

POSTOPERATIVE PERIOD

Postoperative Management

- Atraumatic extraction
  - Atraumatic extraction of a foreign body with no associated inflammation requires no further treatment.
- Traumatic extraction
  - Should maceration or cellulitis preexist or laceration and inflammation occur during extraction, topical eardrops are advised.
  - Should there be moderate edema and concern for laceration of the canal, a wick may have to be placed.
    - Wicks, such as a Pope otowick, are meant to be placed for a short time and are generally removed after 3 days.
      - The patient may be instructed to remove the wick and continue applying topical drops.
    - If there is severe inflammation or laceration of the ear canal skin, the wick should remain for 1 week.
    - Topical drops are then continued for a few more days.
  - Topical otic antibiotics, usually containing steroids, are instilled twice daily, depending on the severity of inflammation.
  - The patient is instructed to avoid further water contamination by keeping the ear dry (free of swimming-pool or shower water) for 1 to 2 weeks.
  - Vaseline applied to a cotton ball is usually effective in keeping the ear canal dry while showering.
  - Traumatic injury to the tympanic membrane or middle ear requires early follow-up and intervention for repair, based on the nature and degree of damage.
    - Patients experiencing infection, complicated extraction, or complications related to the foreign body or its removal should be seen in follow-up within the week.

Complications

1. Infection
   a. If significant cellulitis has developed or the patient is diabetic, systemic antibiotics may be required.
   b. *Staphylococcus aureus* and *Pseudomonas aeruginosa* are the organisms most likely to be involved.
   c. Oral ciprofloxacin should be effective in treating cellulitis of the external canal.
2. Edema of the external auditory canal
   a. Patients who require stenting or packing of the external canal are also treated with topical antibiotic drops.

Alternative Management Plan

A foreign object should not be left in the canal. Successful extraction of a foreign body in the external auditory canal frequently requires a combined approach. Unless contraindicated, irrigation, suction, forceps, and a right-angled hook may be used in combination. Also, a strong magnet may assist in the extraction of a disk battery.

DISCUSSION

Evidence-Based Medicine Question

- ***Question:*** When should a patient with a foreign body in the ear canal be immediately referred to an otolaryngologist instead of having removal first attempted by a primary care physician, pediatrician, urgent care facility, and/or emergency room physician?
- ***Answer:*** In a series of 698 pediatric patients with foreign bodies in the external auditory canal, Schulze and colleagues proposed indications for referral for otomicroscopy-guided removal. These indications were categorized by the type of foreign body (spherical or sharp-edged shape, disk batteries, and vegetable matter), location of the foreign body (adjacent to the tympanic membrane), time in the ear (>24 hours), patient description (<4 years of age, with difficulty visualizing the foreign object, agitation, or both), and a history of previous attempts at removal.[4]

Editorial Comment

Most often a foreign body in the ear canal becomes manifest by pain, otorrhea, or hearing loss. Children are much more likely to place objects in their ears. This may go unnoticed until there is a routine physical examination or sequelae develop. Adults are not excluded from this problem. Cotton buds from applicators can break off. Domes from hearing aid receivers may become lodged in the canal. Like children, adults may not be aware of the problem, thinking that the dome may simply have fallen off.

There may only be a single opportunity to remove the object, especially in the case of a child. Repeated attempts will cause the patient to become uncooperative. If the child can be restrained quickly and efficiently, extraction may be done in the office, clinic, or emergency room. Otherwise brief sedation or general anesthesia will be necessary.

Irrigation is rarely needed unless the material is friable and pasty. Use of a wider-diameter suction can be successful in extracting larger objects. This may result in excessive noise and, rarely, trauma to the tympanic membrane or inner ear.

As with all minor medical procedures, the physician or surgeon must be experienced and know his or her skill set as well as the instruments needed. It is also important to be able to gauge the patient's tolerance of the procedure.

Barry Hirsch

Access the review questions online at http://www.expertconsult.com



REFERENCES

1. Svider PF, Vong A, Sheyn A, et al. What are we putting in our ears? A consumer product analysis of aural foreign bodies. Laryngoscope 2015;125:709–714.
2. Capo JM, Lucente FE. Alkaline battery foreign bodies of the ear and nose. Arch Otolaryngol Head Neck Surg 1986;112:562–563.
3. Thompson SK, Wein RO, Dutcher PO. External auditory canal foreign body removal: management practices and outcomes. Laryngoscope 2003;113:1912–1915.
4. Schulze SL, Kerschner J, Beste D. Pediatric external auditory canal foreign bodies: a review of 698 cases. Otolaryngol Head Neck Surg 2002;127:73–78.

REVIEW QUESTIONS

1. Which type of foreign body of the external auditory canal poses the greatest risk for potential tissue destruction?
   a. Jewelry
   b. Living insects
   c. Vegetable matter
   d. Disk batteries

2. Which of the following is not a safe technique for removing a disk battery?
   a. Using suction in a dry ear to create a seal between the tip of the suction and the battery
   b. Applying hydrogen peroxide in an attempt to get the battery to dislodge
   c. Gently passing a right-angled hook behind the battery in an attempt to lateralize it
   d. Passing a strong magnet in the meatus of the external auditory canal

3. Which of the following is true?
   a. A living insect within the external auditory canal can be extracted the following day.
   b. One should never use irrigation in extracting vegetable matter.
   c. If a foreign body easily enters the external auditory canal, it will typically fall out on its own.
   d. Beads are the most common type of jewelry item to enter the external auditory canal in a child.

127 Osteomas and Exostoses of the External Auditory Canal

Michele Hargreaves

INTRODUCTION

Osteomas and exostoses are benign bone growths found in the temporal bone, most commonly in the bony external auditory canal (EAC). The structure of the EAC takes a tortuous route from the external auditory meatus to the tympanic membrane (TM), through the cartilaginous lateral third to the medial bony two-thirds.

The S-shaped structure of the canal provides a protective mechanism to the TM. The function of the EAC serves not only to protect the TM, but it also conducts sound to the TM and middle ear. In conjunction with the concha, the EAC amplifies sound from 5 to 20 dB from the free field to the TM due to the resonance of both structures. Occlusion of the EAC, whether congenital or acquired, causes conductive hearing loss.

The EAC is normally self-cleansing due to the epithelial migration from the surface of the TM to the EAC. Unimpeded epithelial migration acts similar to a conveyor belt to carry cerumen and desquamated epithelial cells out to the lateral aspect of the canal, where this debris can easily be removed. Lesions that cause partial or complete occlusion of the EAC can impede epithelial migration, leading to an accumulation of cerumen and/or epithelial debris medial to the lesion. This can trigger recurrent episodes of acute otitis externa (OE) as the skin of the EAC becomes inflamed. Conductive hearing loss can also develop due to of impaction of debris if the debris is made inaccessible for cleaning by the presence of these bony growths.

Exostoses are bilateral, lamellar outgrowths of the bone of the medial EAC, typically triggered by reactive hyperemia of the EAC skin following exposure to cold water (Fig. 127.1). Reactive hyperemia is seen following the initial vasoconstriction that occurs with cold exposure and is a hallmark of first-degree frostbite injury. The hyperemia reflects the attempt of the tissue to protect from further thermal injury due to recurrent exposure to cold water. The condition was originally described as "surfer's ear" and is commonly seen in cold water surfers, kayakers, divers, and swimmers. There is a male predilection. Formation of the exostoses occurs in a time-dependent fashion, with a greater degree of EAC occlusion seen with longer durations of exposure and increasing age. Exostoses can develop along the anterior, posterior, and superior bony EAC, with anterior and posterior exostoses commonly exhibiting a sessile structure.[1]

Osteomas are relatively rare when compared with exostoses. These are solitary, unilateral bone lesions located more laterally in the bony EAC, often pedicled to the tympanosquamous or tympanomastoid suture line. Osteomas are considered true neoplasms of bone (Fig. 127.2).[1]

Treatment of osteomas and exostoses is symptom dependent. Most patients with osteomas or exostoses are diagnosed incidentally on routine examination of the ear. If the degree of EAC occlusion is less than 80%, most patients require either no treatment or conservative management with periodic débridement of the EAC to prevent cerumen impaction, OE, or conductive hearing loss.[2] Use of earplugs when exposed to cold water may slow progression of the disease in the case of exostoses.

Surgical treatment should be reserved for symptomatic patients, including patients who develop frequent OE and/or frequent cerumen impactions causing hearing loss, patients who desire a more permanent treatment to avoid the need for repeated débridement, and patients in whom the EAC has become completely occluded.[3] The latter condition requires surgical treatment due not only to the resulting conductive hearing loss, but these patients are also at risk for cholesteatoma formation and its complications in the medial EAC due to trapped epithelial debris.

KEY OPERATIVE LEARNING POINTS

1. Reserve surgical treatment for symptomatic patients.
2. Structures at risk for injury include the tympanic membrane, ossicular chain, temporomandibular joint (TMJ) anteriorly, and the facial nerve posteroinferiorly.
3. Surgery is most commonly performed with a high-speed otologic drill, but the use of osteotomes can be considered as an alternative.
4. Preservation of medially based skin flaps provides more rapid healing and a reduced risk of soft tissue stenosis postoperatively.

PREOPERATIVE PERIOD

History

1. History of present illness
   a. Question the patient regarding the presence of frequent cerumen impactions, OE, or persistent hearing loss.
   b. A careful history should be taken to elicit symptoms related to obstruction of the EAC, such as the need for frequent débridement of the impactions, frequent pain or otorrhea suggesting recurrent OE, and frequent or persistent hearing loss. An attempt should be made to determine the frequency and severity of symptoms and how bothersome they are to the patient.
   c. Question the patient regarding prior treatment and willingness to return for periodic ear cleaning.
   d. Determine how frequently the patient has required treatment for OE or removal of impacted cerumen, if at all. Patients in whom OE and/or cerumen impactions are occurring very often should be offered surgical treatment as an option. Also, if it is highly impractical for a patient to return for periodic ear cleaning as a form of conservative management, this is also an indication for surgical therapy.
   e. The patient should be questioned regarding participation in water sports.
   f. If the patient is an active participant in cold water sports, the patient should be counseled regarding the use of ear plugs to help slow the progression of existing exostoses and to help prevent recurrence postoperatively.

2. Past medical history
   a. Need for prior treatment with débridement of cerumen and/or ototopical drops for OE
   b. Medical illness, including any contraindications to general anesthesia
   c. Prior surgical history, with attention to any prior ear surgery
   d. Family history, including any reactions to anesthesia
   e. Medications, including anticoagulants or antiplatelet drugs



Fig. 127.1. View of the right external auditory canal revealing multiple broad-based exostoses located medially near the tympanic membrane.



Fig. 127.2. Excised osteoma of the external auditory canal with its narrow pedicle located on the right side of the bony tumor.

Physical Examination

1. Binocular microscopic examination of the ears
   Binocular microscopy should be performed to determine the location and extent of any exostoses or osteoma present. Attention should be paid to the percentage of obstruction of a cross section of the EAC caused by the lesions. Additionally, binocular microscopy enables the surgeon to determine whether the ear may be adequately cleaned in its present state or whether there are locations medially, anteriorly, or posteriorly that are inaccessible and therefore at risk for cholesteatoma formation or persistent trapped debris.
2. Otologic endoscopy
   This can be performed as an adjunct to binocular microscopy to assess the medial EAC for trapped debris and to determine the medial extent of exostoses or osteoma, if not visible due to severe stenosis.
3. Audiometry and tuning fork testing
   Tuning fork testing should be performed on all patients to screen for a conductive hearing loss. A full audiogram with tympanometry and acoustic reflex testing should be performed preoperatively on all surgical candidates to assess the type and degree of any pre-existing hearing loss and to counsel the patient on expected improvement following surgery. Audiometry may also document a pre-existing high frequency sensorineural hearing loss (SNHL). As high frequency SNHL can be a surgical complication due to noise exposure from the high-speed drill and/or contact with the ossicular chain, any pre-existing SNHL must be documented for patient counseling and medicolegal purposes.
4. Head and neck examination
   A full otolaryngologic examination should be performed to ensure there are no other factors that could potentially impact the decision for surgery, including the presence of a difficult airway or craniofacial anomalies that could portend an aberrant anterior course of the facial nerve.

Imaging

Computed Tomography

A high-resolution temporal bone computed tomography (CT) should be obtained preoperatively in cases of osteoma extensive enough to prevent visualization of the medial EAC (Fig. 127.3). The CT confirms the diagnosis, evaluates for possible medial cholesteatoma, and determines the location and width of the pedicle. Osteomas have the appearance of a well-circumscribed bony lesion pedicled at the tympanosquamous or tympanomastoid suture line, slightly hypodense compared to cortical bone of the mastoid. The location of the pedicle is usually readily identified to allow for surgical planning (Fig. 127.4).

In cases of severe exostoses with near complete or complete closure of the EAC, temporal bone CT should also be performed to evaluate for the presence of a cholesteatoma medially that would need to be addressed surgically. The preoperative CT can also indicate the medial extent of the exostoses, as the growths can abut the TM, requiring special care during removal to avoid trauma to the TM.

Indications

1. Complete or near complete occlusion of the EAC, causing accumulation of epithelium that cannot be débrided in the office
2. Persistent conductive hearing loss caused by occlusion of the EAC or by persistent entrapment of cerumen or epithelial debris

3. Recurrent acute OE poorly controlled with medical management, particularly if reactive soft tissue stenosis is noted
4. Frequent cerumen impactions requiring an unacceptably high number of office visits for treatment

Contraindications

1. Medical comorbidities that put the patient at an unacceptably high risk of general anesthesia
   Surgery for exostoses frequently requires a postauricular approach and is typically performed under general anesthesia, which may be contraindicated in the case of severe cardiopulmonary disease. Surgical removal of a single osteoma, particularly if on a narrow pedicle, is often possible under local anesthesia.

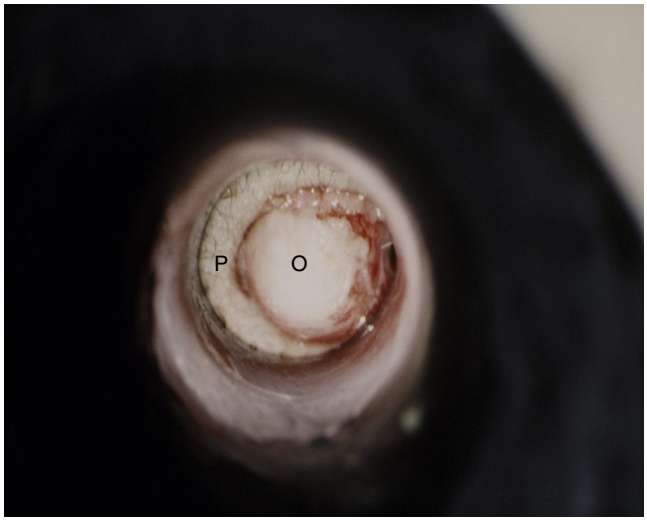

Fig. 127.3. Right external auditory canal with a posteriorly based osteoma *(O)* obstructing complete examination of the medial canal and tympanic membrane. *P,* Posterior.

2. Active OE
   Attempts should be undertaken prior to surgery to eradicate or maximize control of any OE present in the operated ear. Active OE at the time of surgery can increase the risk for cellulitis and exuberant granulation tissue during the healing process, which can lead to soft tissue stenosis of the EAC.

Preoperative Preparation

1. Discontinue any anticoagulants/antiplatelet medications for at least 7 days preoperatively if possible or as directed by the prescribing physician.
2. Treat any active or ongoing OE with ototopical antibiotics until the time of surgery.
3. Evaluate preoperative imaging, if obtained, to help determine the surgical approach and type of anesthesia to be used.

OPERATIVE PERIOD

Anesthesia

General

For removal of exostoses, a postauricular approach is frequently required. In this case, general anesthesia is recommended to prevent pain and to avoid patient discomfort due to the noise of the otologic drill.

Local With/Without Sedation

For select osteomas that are laterally based with a very narrow pedicle, removal can be accomplished under local anesthesia via a transcanal approach. Sedation can be added based on patient preference.

Positioning

Supine

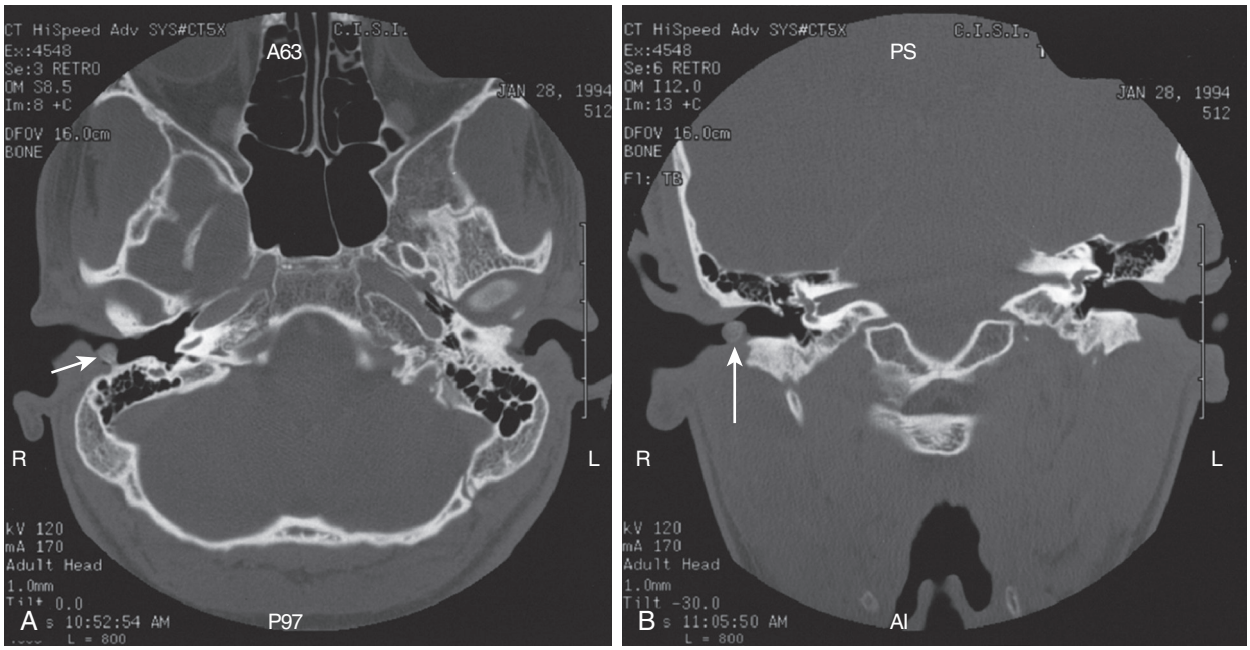

Fig. 127.4. Axial, **A,** and coronal, **B,** bone-windowed computed tomography images demonstrating a pedunculated attachment to the lateral posterior canal wall *(arrows).* The remaining external auditory canal and middle and inner ear are normal.

The patient's head should be positioned on a foam "doughnut," turned partially toward the nonoperative ear. Ensure that the contralateral pinna is not compressed during positioning.

Perioperative Antibiotic Prophylaxis

None necessary

Perioperative antibiotic prophylaxis is not necessary unless the ear is actively infected at the time of surgery. If this is the case, then a preoperative intravenous dose of an antipseudomonal penicillin or cephalosporin is recommended.

Monitoring

Electromyography (EMG)

Using a facial nerve monitor should be strongly considered during surgery for exostoses or osteoma. The facial nerve frequently courses lateral to the tympanic annulus in the posteroinferior bony EAC and can be injured during surgery.[4]

Instruments and Equipment to Have Available

1. Operating microscope
2. Standard middle ear/mastoid instrument
3. High-speed otologic drill, with 3, 2, and 1 mm extended length fluted ball or coarse diamond burs for bone removal and fine diamond burs for polishing
4. Suction irrigation system
5. Facial nerve monitor
6. Silastic sheeting and/or sterile foil suture packs to protect critical structures during drilling
7. #10 blade and scalpel in case a split-thickness skin graft is needed
8. Optional: 1–3 mm straight and curved osteotomes and mallet
9. Optional: otologic endoscope

Key Anatomic Landmarks

1. Tympanic annulus: demarcates the medial extent of dissection if exostoses extend up to the TM
2. TMJ: The TMJ is located just anterior to the bony EAC, approximately halfway between the bony-cartilaginous junction and the anterior annulus. Care must be taken to avoid entry into the soft tissues of the TMJ when drilling along the anterior wall of the EAC.
3. Facial nerve: The facial nerve courses lateral to the tympanic annulus in the posterior-inferior bony EAC in approximately 70% of patients. The distance between the annulus and the vertical segment of the nerve ranges from 2 to 5 mm. In some patients, the facial nerve is located anterior to the most posterior point of the annulus as well. There are no external landmarks within the EAC to identify the course of the facial nerve, so care must be taken during bone removal in the posteroinferior EAC.
4. Short process of the malleus: Avoid contacting the malleus with the otologic drill to prevent conductive or sensorineural hearing loss.
5. Posterior wall of the EAC: Care must be taken not to extend the dissection too deeply along the posterior wall of the EAC, lest entry to the mastoid air cells occurs.

Prerequisite Skills

1. Proficiency in otologic surgery
2. Proficiency with the high-speed otologic drill
3. Familiarity with the structure and landmarks of the EAC
4. Familiarity with the postauricular, transcanal, and endaural approaches

Operative Risks

1. Inadequate bone removal
2. Soft tissue stenosis of the EAC
3. Injury to the TM
4. Conductive hearing loss
5. Sensorineural hearing loss
6. Mastoid fistula
7. TMJ violation and dysfunction
8. Facial nerve injury

Surgical Technique

1. Place facial nerve monitor electrodes prior to sterile preparation. Prep and drape the patient as for routine otologic surgery.
2. Perform four quadrant canal injections with xylocaine with epinephrine for vasoconstriction.
3. Determine the surgical approach to be used: Endaural or transcanal approaches are appropriate for a single, laterally based osteoma, whereas a postauricular approach is more appropriate for extensive medial exostoses.
4. Perform the postauricular approach in the standard fashion, creating a laterally based Koerner's flap via a posterior vertical incision in the lateral bony EAC with lateral releasing incisions at 6 and 12 o'clock (Fig. 127.5). As the individual anatomy of each patient, as well as surgeons' individual preferences, impact the exact location of the Koerner's flap incisions and postauricular incisions, more exact details would not be appropriate as exact positioning of the incisions is best left to the surgeon's discretion at the time of surgery. This provides a general outline of appropriate incisions. Back elevate

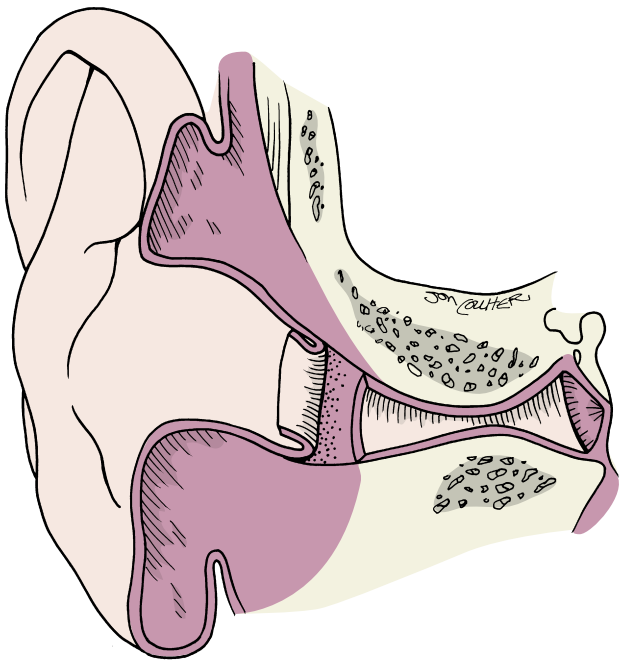

Fig. 127.5. Through the external auditory meatus, a Koerner's (conchal) flap is incised and back elevated. Note the narrowed bony canal medially.

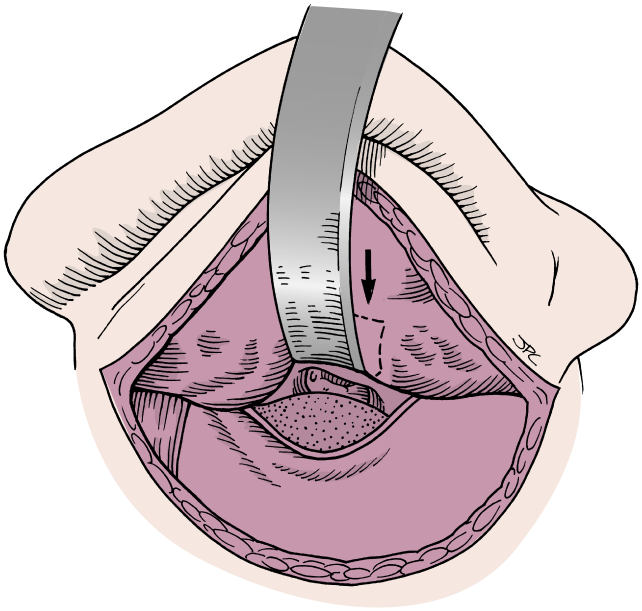

Fig. 127.6. A postauricular incision has been made, and a tracheostomy tape is placed to evert the Koerner's flap within the canal *(arrow)*. A self-retaining retractor (not shown) provides the necessary exposure.

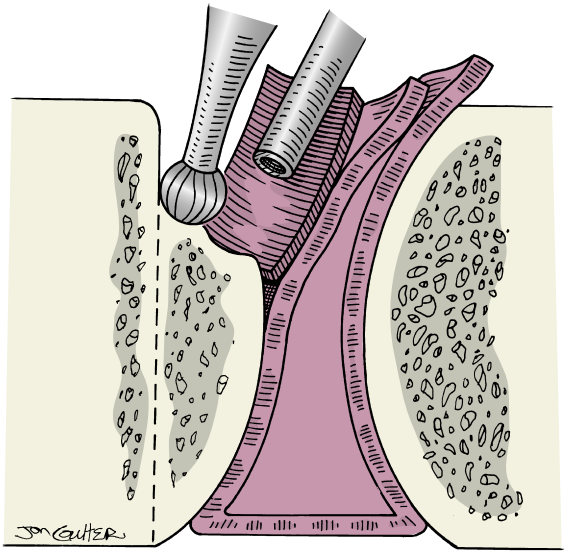

Fig. 127.7. Beginning laterally, the posterior canal wall skin is elevated and protected with a sheet of suture pack foil or Silastic. The suction tip is used to retract the skin and maintain a clean surgical field. The bony exostosis is drilled to contour the canal.

the Koerner's flap and then create a postauricular incision, and connect the two incisions. Retract the auricle anteriorly using a Penrose drain or twill (tracheotomy) tape and place self-retaining retractors (Fig. 127.6).

5. For exostoses: Create medially based skin flaps around each exostosis to be removed. For the posterior exostosis, the same circumferential incision should be used as for the Koerner's flap. Separate circumferential incisions should be made for anterior exostoses. Vertical releasing incisions are then made, and the skin is elevated medially. Skin flaps should be folded over the TM and protected with Silastic sheeting or foil cut from a sterile suture pack (Fig. 127.7).

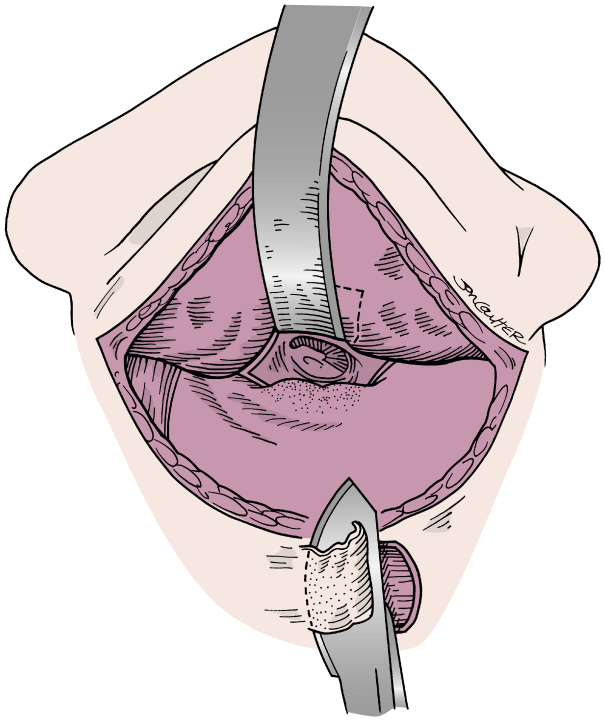

Fig. 127.8. Excessive loss of canal skin should be replaced. A free-hand split-thickness Thiersch graft is harvested from the postauricular skin overlying the mastoid.

6. For exostoses: Remove the exostoses in a lateral to medial fashion using a high-speed otologic drill with 3, 2, and 1 mm coarse and fine diamond burs and copious irrigation. Care must be taken when drilling along the scutum to avoid entry into the attic and trauma to the ossicular chain. Avoid contact with the short (lateral) process of the malleus as well. Avoid entry into the TMJ anteriorly; if the periosteum of the glenoid fossa is seen, avoid further dissection in this area. Use caution when drilling in the posterior inferior bony EAC, as the vertical segment of the facial nerve is often lateral to the annulus in this location. It may be necessary to use a 1-mm chisel and osteotome to remove exostoses that extend to the annulus or excavate under a thin lip of bone and then gently fracture it away from its connection near the annulus.
7. Take care to preserve the skin flaps. If the skin flaps are intact, they may be laid back in anatomic position without the need for free skin grafts. If the skin flaps have been damaged, a free Thiersch skin graft may be harvested from the postauricular region using a #10 blade, trimmed, and placed in denuded regions of the EAC (Fig. 127.8).
8. If no free skin grafts were required, the EAC may be packed with Gelfoam soaked in ototopical antibiotic solution. If free skin grafts were required, lateral and medial rosebud packing should be placed in the EAC to avoid soft tissue stenosis during the healing process (Fig. 127.9).
9. For osteomas: Many osteomas that are based on a narrow pedicle can be removed with a bone curette via a transcanal or endaural approach (Fig. 127.10). For a broad-based osteoma, a skin flap should be elevated and preserved as for removal of exostoses (Fig. 127.11A and B). The bone pedicle can then be smoothed with a high-speed drill and coarse diamond burs so it is level with surrounding bone. If only a small area of skin is denuded, it can be left to heal by secondary intention. Skin flaps are replaced and held in position with Gelfoam or a silk strip (see Fig. 127.11C).

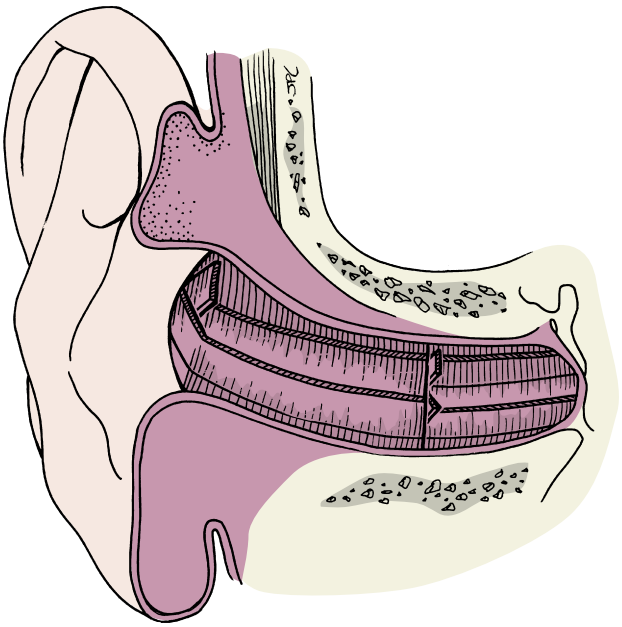

Fig. 127.9. Double-rosebud packing is used to secure skin that was replaced in sections.

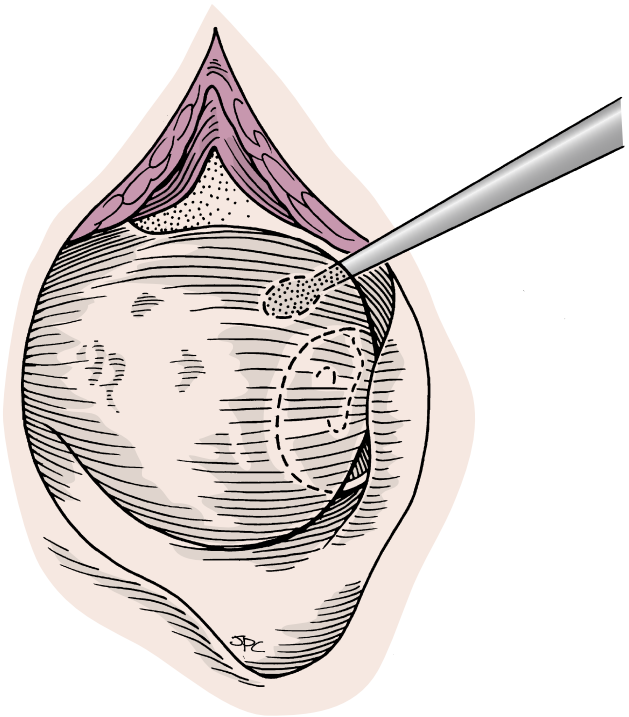

Fig. 127.10. An incision made in the incisura widens the aperture to the external auditory meatus. A curette is positioned medial to the osteoma in preparation for removal. The tympanic membrane is ghosted in.

Common Errors in Technique

1. Failure to preserve adequate skin flaps during drilling, leaving large areas of the bony EAC denuded
2. Failure to protect medially based skin flaps and the TM using Silastic sheeting or foil trimmed from a suture pack
3. Attempting a transcanal approach for extensive exostoses, limiting visualization during drilling
4. Overly aggressive drilling along the anterior, posterior, or superior EAC, resulting in complications described above

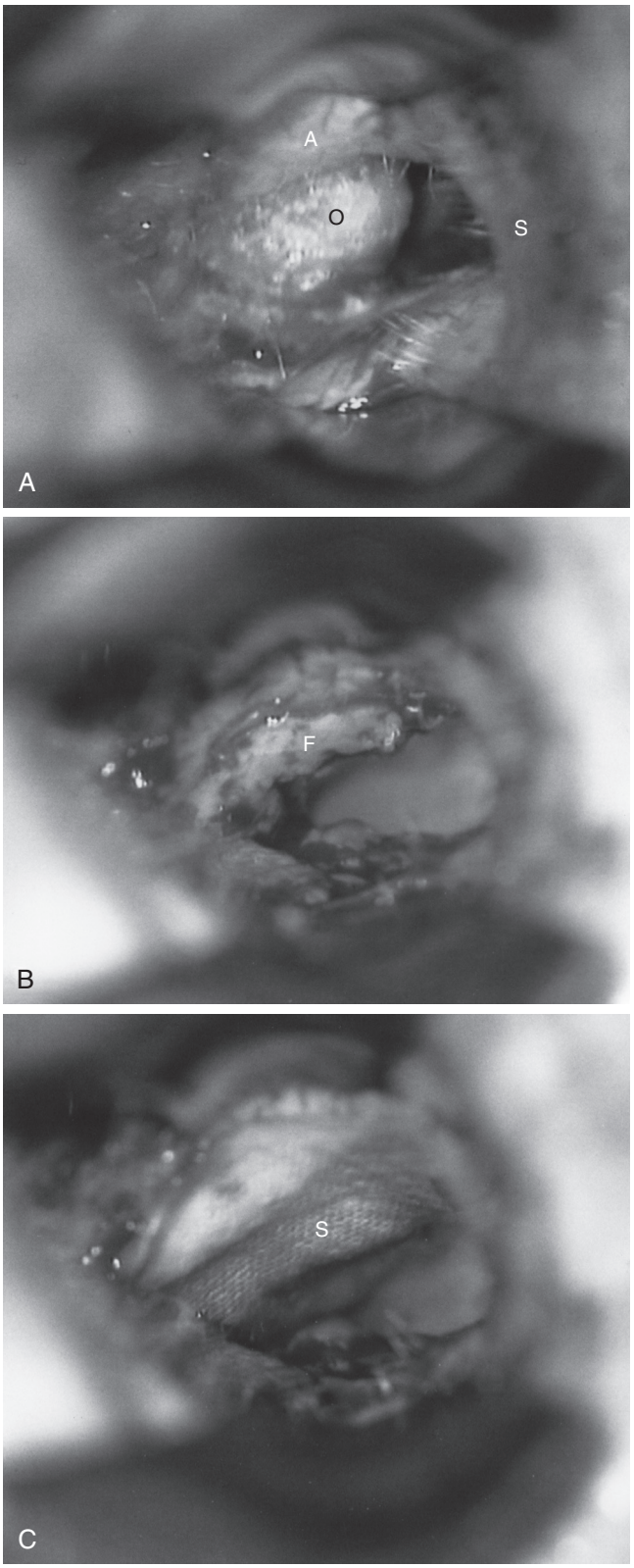

Fig. 127.11. A, Broad-based osteoma *(O)* of the left ear located on the anterior external auditory canal wall. *A,* Anterior; *S,* superior. **B,** A skin flap *(F)* based medially was created and returned to cover the exposed bone. **C,** A strip of silk *(S)* is positioned on the anterior canal wall to secure the skin flap.

5. Inadequate irrigation, causing thermal injury to the underlying bone

POSTOPERATIVE PERIOD

Postoperative Management

1. Initiate antibiotic ototopical drops twice a day (BID), beginning on the day of surgery.
2. Provide adequate postoperative pain control with oral narcotic analgesics if necessary.
3. If a postauricular incision was made, it should be kept dry for 1 week. Thereafter, the patient may shower/bath as usual, keeping the EAC dry by placing a cotton ball covered in Vaseline in the conchal bowl.
4. The first postoperative visit should occur at 7 to 10 days, at which time, packing may be removed if free skin grafts were not placed. Packing should remain in place for 14 days if free skin grafts were used to supplement pedicled skin flaps.
5. Observe for granulation tissue or hypertrophic scar formation. Granulation tissue can be treated with topical silver nitrate, and hypertrophic scarring in the EAC can be treated with corticosteroid injections. Vigilance is necessary to prevent soft tissue stenosis if these conditions arise. The patient should be seen weekly, and a Merocel stent should be kept in the ear canal until full epithelialization has occurred.
6. Once full healing of the EAC has occurred, the patient may discontinue dry ear precautions and resume water sports activities. Use of earplugs may prevent recurrence of exostoses.
7. After full healing has occurred, a postoperative audiogram should be performed to document any improvement in conductive hearing loss and assess for any new sensorineural hearing loss.

Complications

1. Inadequate bone removal
   Failure to fully remove exostoses can lead to early recurrence. In addition, if a bony lip remains medially, the patient may experience a recurrence of symptoms due to persistent trapped debris or conductive hearing loss from contact between the bone and TM.
2. Soft tissue stenosis of the EAC
   If a significant surface area of the EAC is denuded or if extensive free split-thickness skin grafts are required, soft tissue stenosis of the EAC can develop during the healing process. This can be managed as described above using silver nitrate cautery, corticosteroid injections, and/or stenting of the EAC during the healing process. Late soft tissue stenosis may require revision surgery.
3. Injury to the TM
   The annulus can be avulsed during medial drilling. The TM can also be torn by the drill directly or by rotating and removing segments of bone detached by fracturing with an osteotome. Risk can be minimized with awareness of surgical landmarks and by protecting the TM with a layer of Silastic sheeting or foil trimmed from a sterile suture pack. Small tears in the TM can be medially supported with Gelfoam and usually heal spontaneously. Large tears should be repaired at the time of surgery.
4. Conductive hearing loss
   Disruption of the ossicular chain due to overly aggressive drilling along the scutum and entry into the attic may occur. Care must be taken when drilling along the posterosuperior EAC not to enter the attic or contact the short process of the malleus.
5. Sensorineural hearing loss
   Noise-induced hearing loss from the high-speed otologic drill may occur. This can be due to sound transmission through contact with the short process of the malleus but can occur in the absence of contact with the ossicular chain. Short breaks from drilling will likely reduce the incidence of noise-induced hearing loss. New SNHL in the immediate postoperative period can be treated with high-dose corticosteroids.
6. Mastoid fistula
   Overly aggressive drilling along the posterior bony EAC can cause entry into the mastoid air cell system. If not recognized and repaired, this can eventually lead to cholesteatoma formation if epithelium migrates into the mastoid.
7. TMJ dysfunction
   Drilling along the anterior EAC can cause disruption of the soft tissues of the TMJ if the inner periosteum of the glenoid fossa is violated. This can cause prolapse of the soft tissues of the TMJ into the EAC, TMJ pain, TMJ dysfunction, and/or popping or clicking sounds in the ear with jaw movement.
8. Facial nerve injury
   Drilling along the posterior inferior EAC can cause inadvertent injury to the vertical segment of the facial nerve while it occasionally courses lateral to the annulus. Caution must be taken when using the drill or osteotome in this location. Copious irrigation should be used to avoid thermal injury to the nerve. If facial stimulation occurs on EMG monitoring, dissection should cease immediately. Management of facial nerve paresis or paralysis should follow the same principles as for iatrogenic injury during any otologic procedure.

Alternative Management Plans

1. Nonsurgical management: appropriate for osteomas or exostoses that are not fully occluding the EAC and that allow for full débridement of the EAC in the office with the use of a binocular microscope. The patient may be seen periodically for débridement to prevent medial entrapment of cerumen or epithelial cells causing conductive hearing loss and to prevent OE due to resulting irritation of the EAC skin.
2. Alternative surgical techniques have been espoused, such as limiting bone removal to the anterior wall of the EAC in the case of exostoses or use of osteotomes for exostosis removal.[5] Rationale for limiting drilling to the posterior inferior wall of the EAC includes a significantly lower risk of facial nerve injury, and some authors note that the goals of a patent EAC, resolution of conductive hearing loss, and access for débridement in office can be met by removing anterior exostoses only. Rationale for use of osteotomes instead of the otologic drill includes lower risk of sensorineural hearing loss, less damage to pedicled skin flaps, and potentially lower risk to the facial nerve. An endoscopic approach may also be undertaken to visualize the medial limits of exostoses and help guide osteotome placement.

DISCUSSION

Evidence-Based Medicine Question

Does removal of EAC exostoses and osteomas improve patient quality of life?

A recent retrospective study sought to assess patients' health related quality of life following surgery for exostoses and osteoma.[6] The motivation for this review was the relatively high complication rates cited in the medical literature coupled with relatively low reported rates of symptom relief. Thirty-nine patients undergoing surgery for exostoses or osteomas were retrospectively reviewed using the Glasgow Benefit Inventory. The majority of the patients were male, with an average age of 50. The majority suffered from exostoses, and preoperative complaints included hearing loss, cerumen impactions, and recurrent OE.

In addition, 76.9% of the patients returned the survey, and 83.3% of the patients surveyed received quality of life benefit from the surgery. Ninety percent of the patients were satisfied with their postoperative outcome. Also, 70% of patients were asymptomatic following surgery. Only three patients indicated dissatisfaction with the surgical outcome; in all three cases, the patients had suffered complications. Two of the three complications involved damage to the inner ear with or without tinnitus. The authors concluded that surgery for exostoses and osteomas improves patients' quality of life in most cases with the caveat that only symptomatic patients should be surgical candidates. The authors also cautioned that surgical complications are the most significant contributing factor to patients' dissatisfaction with postoperative outcomes.

Editorial Comment

Bony obstruction of the external ear canal can result in cerumen impaction which may lead to recurrent OE, conductive hearing loss, and medial entrapment of cholesteatoma. Asymptomatic subtotal occlusion does not require surgical intervention. Physical examination of the ear canal, with an operating microscope, provides a preliminary assessment or the status of the EAC. Bone lesions located laterally giving the impression of having a narrowed pedicle are suggestive of osteoma. These are typically amenable to transcanal removal with a curette or osteotome. CT imaging should still be obtained to confirm the location and origin of the lesion and to determine whether additional disease is present in the medial canal. The CT scan also provides information as to the relationship of the glenoid fossa anteriorly and the course of the vertical portion of the facial nerve and aeration of the mastoid near the ear canal posteriorly.

It is also common to see partial bone obstruction of the EAC in patients having concomitant pathology such as chronic otitis media, TM perforation, or conductive hearing loss. If access to the TM is limited, a staged approach to the TM or middle ear may be warranted. Correction of the obstruction of the EAC is undertaken as the principle procedure before addressing problems such as otosclerosis.

Meticulous attention to preserving the native skin of the EAC reduces the likelihood of healing problems such as the development of granulation tissue in the canal and subsequent stenosis. The surgeon must decide if exposed bone can be covered with a temporalis fascia graft or needs a split-thickness (Thiersch) graft.

The surgeon must also be vigilant in the postoperative period in looking for problems of healing. Small area of granulation tissue can be cauterized with silver nitrate. Larger areas should be stented with a wick and monitored on a weekly basis. On occasion, the patient may need to return to the operation room for débridement, skin grafting, or replacement of conforming packing.

The author has nicely summarized the process of assessment, diagnosis, planning, execution, and postoperative management. All are important steps in achieving success in correcting this pathology.

Barry Hirsch

Access the review questions list online at http://www.expertconsult.com



REFERENCES

1. Kim HJ, Patronas NJ, Goldstein BS, et al. Imaging studies of the temporal bone. In: Bailey BJ, editor. Head & Neck Surgery—Otolaryngology. 3rd ed. Philadelphia: Lippincott Williams & Wilkins; 2001. p. 1693.
2. Whitaker SR, Cordier A, Kosjakov S, et al. Treatment of external auditory canal exostoses. Laryngoscope 1998;108:195–199.
3. Vasama JP. Surgery for external auditory canal exostoses: a report of 182 operations. ORL J Otorhinilaryngol Relat Spec 2003;65:189–192.
4. Adad B, Rasgon BM, Ackerson L. Relationship of the facial nerve to the tympanic annulus: a direct anatomic examination. Laryngoscope 1999;109(8):1189–1192.
5. Hetzler DG. Osteotome technique for removal of symptomatic ear canal exostoses. Laryngoscope 2007;117(Suppl. 113):1–14.
6. Hempel JM, Forell S, Krause E, et al. Surgery for outer ear canal exostoses and osteomata: focusing on patient benefit and health-related quality of life. Otol Neurotol 2011;33:83–86.

REVIEW QUESTIONS

1. What surgical techniques can safely be used to remove osteomas and/or exostoses?
   a. High-speed otologic drill
   b. 1- to 3-mm osteotomes
   c. Bone curette
   d. All of the above

2. Where is the facial nerve most at risk when removing bone from the EAC?
   a. Anterior superior
   b. Anterior inferior
   c. Posterior superior
   d. Posterior inferior

3. What structure lies immediately anterior to the anterior bony EAC at its midpoint and can be injured during bone removal?
   a. Facial nerve
   b. Temporomandibular joint
   c. Parotid gland
   d. Tympanic annulus

4. Which of the following is not a surgical indication for removal of exostoses/osteoma?
   a. Persistent conductive hearing loss
   b. Medial canal cholesteatoma
   c. Recurrent OE
   d. Cerumen impaction once a year

128 Keratosis Obturans and Canal Cholesteatoma

Yu-Lan Mary Ying

INTRODUCTION

Keratosis obturans (KO) and external auditory canal cholesteatomas (CC) are uncommon diseases of the external auditory canal that share the common characteristic of a buildup of desquamated keratin in the ear canal. Since the 19th century, KO and CC have been considered variants of the same disease until 1980, when Piepergerdes et al. classified these diseases as separate entities, often requiring distinct management plans.[1,2] Distinguishing between these two disease entities remains clinically challenging because of the overlap in disease presentation with involvement of the wall of the ear canal, which is commonly observed in both KO and CC.

CC may appear as a keratin "pearl" often on the floor of the ear canal. More extensive involvement causes deeper irregular erosion of the bony ear canal, which is usually restricted in the area lateral to the annulus. There is often thinning of the skin that exposes bone within the canal. KO is also lateral to the annulus but encompasses the circumference of the canal skin. There is diffuse failure of epithelial desquamation and migration creating a laminar keratin plug that widens the diameter of the ear canal. It can cause occlusion of the ear canal resulting in a conductive hearing loss.

KEY OPERATIVE LEARNING POINTS

1. High-resolution computed tomography (CT) scan can help to differentiate the two conditions by the presence of focal bony erosion, seen only in CC, versus a widened bony canal, seen typically in KO.
2. External auditory CC should be distinguished from squamous cell carcinoma by histologic examination of the ulcerated skin edges.
3. When performing canaloplasty for either disease condition, drilling of the medial posteroinferior canal wall may expose the mastoid segment of the facial nerve.
4. Complete removal of unhealthy canal skin and devitalized bone, with the smooth contouring of the bony canal defect and relining the denuded bone with fascia or skin graft, is the definitive surgical management of external auditory CC.
5. Exposed mastoid air cells need to be obliterated with fascia or adipose tissue to avoid persistent otorrhea or fistula formation resulting in recurrent cholesteatoma formation.

PREOPERATIVE PERIOD

History

1. History of present illness
   Clinical difference between KO and CC can be distinguished by the following characteristics:
   a. KO
      1) Conductive hearing loss may be present.
      2) Otorrhea is rare.
      3) Bilateral pain can occur.
      4) It is often seen in young or middle-aged individuals.
   b. CC
      1) Unilateral chronic and dull ache
      2) Otorrhea is common.
      3) Bleeding from the ear canal
      4) Normal hearing
      5) Older individuals
2. Past medical history
   a. KO
      1) Excessive cerumen accumulation
      2) Medical illness: There is an association with abnormal or immotile cilia conditions—chronic sinusitis and bronchiectasis, particularly in children.[3]
   b. CC
      1) Idiopathic
      2) Secondary:
         a) Congenital
            i) Auditory atresia
         b) Acquired
            i) Recurrent infections in the ear canal
            ii) Recurrent disruptions of external auditory canal skin
            iii) External auditory canal/stenosis
            iv) Posttraumatic or postoperative external auditory canal wall defects

Physical Examination

An examination of the ear using a microscope is the most important part of the physical examination for both conditions.

1. KO
   a. Accumulation of large plugs of circumferential, desquamated, laminar keratin in the ear canal due to a defect in lateral epithelial migration (Figs. 128.1 and 128.2)[4]
   b. Widening of the bone wall of the ear canal secondary to constant circumferential pressure induced by the keratin plug resulting in bony resorption, without focal erosion of the bone
   c. Canal epithelium typically remains intact but can become thickened or inflamed.
   d. Tympanic membrane is usually intact but may be involved
   e. Conductive type of hearing loss
2. CC
   a. Invasion of squamous tissue into a localized area of the bony canal with localized osteitis, focal erosion, and bone sequestration[5]
   b. Trapping and tunneling of epithelium may occur beneath the skin of the external auditory canal.
   c. The most commonly reported site is the posteroinferior aspect of the canal (Fig. 128.3); however, it can extend into the middle ear and mastoid.
   d. Surrounding epithelium can appear ulcerated with bleeding and granulation tissue present at the site of bone erosion (Fig. 128.4).

Imaging

A high-resolution CT scan of the temporal bone scan can help to differentiate the two conditions.

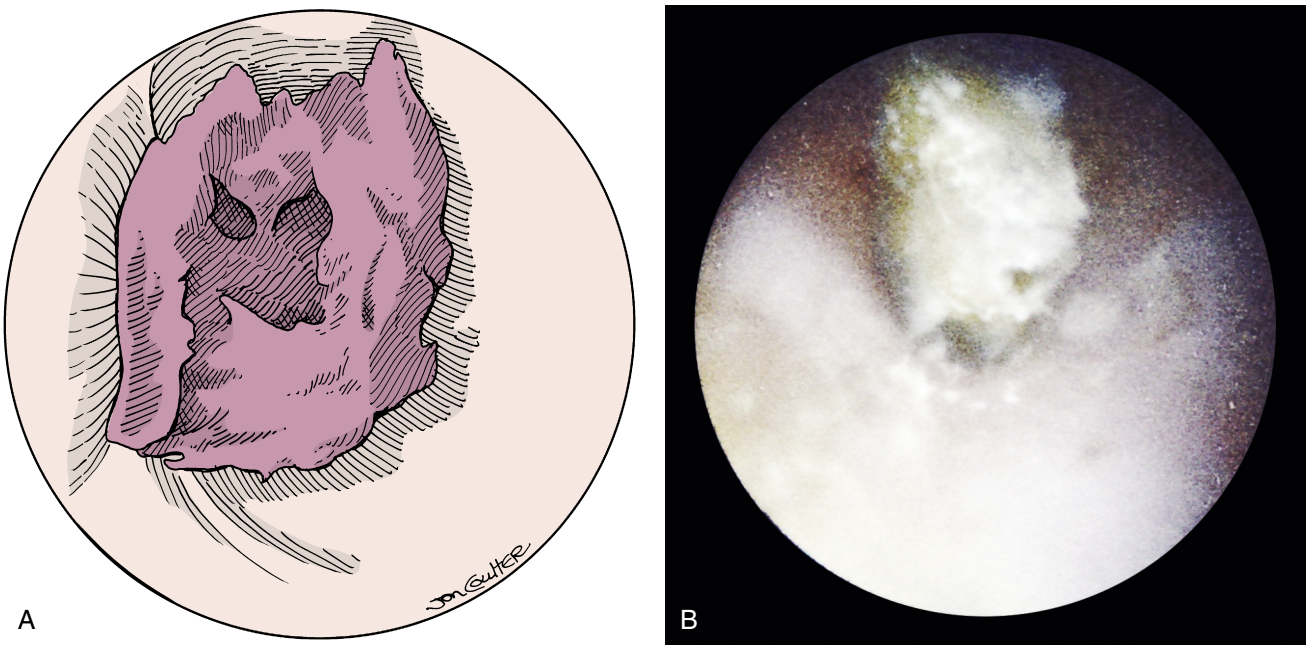

Fig. 128.1. A and **B,** Views of the external auditory meatus showing complete obstruction with a keratin plug.

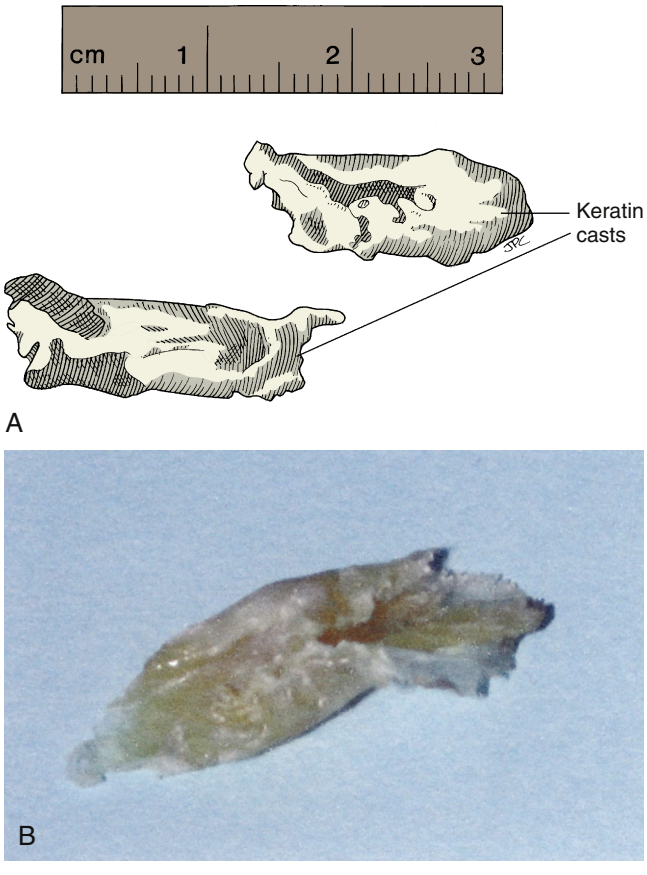

Fig. 128.2. A and **B,** Keratin plugs after removal from the ear canals.

1. KO
   a. Widening of the external auditory canal
   b. Intact bony contour of external auditory canal
   c. Possible disease progression into the middle ear space via a diseased or perforated tympanic membrane
2. CC
   a. Focal bone erosion of the external auditory canal
   b. Identify the extent of disease invasion into the mastoid from the erosion and destruction of the posterior bony external auditory canal.
   c. Identify the potential for involvement of the facial nerve.

Indications

1. Persistent "clogged" ear sensation with otalgia, otorrhea, and hearing loss
2. Inflammatory granulation tissue in the external auditory canal that requires a biopsy to rule out other pathologies, including carcinoma of the auditory canal or malignant otitis externa. This is more commonly seen in cases of CC.
3. CT of the temporal bone can identify tissue extension into middle ear and/ormastoid space, with or without facial nerve involvement.

Contraindications

1. Medical comorbidities with increased risk for general anesthesia
2. Greater risk when surgery is performed in the only hearing ear

Preoperative Preparation

1. Audiogram to determine hearing threshold
2. CT scan of the temporal bone to determine disease extension in relation to important anatomic landmarks and the integrity of the bony external auditory canal
3. KO: emollients and lubricants to soften the keratin plug a few days in advance for ease of removal
4. CC: topical antibiotic ear drops to minimize epithelial infection at the site of bony canal erosion

OPERATIVE PERIOD

Anesthesia

1. General: In instances where the KO has been long standing and there is extensive widening of the medial external

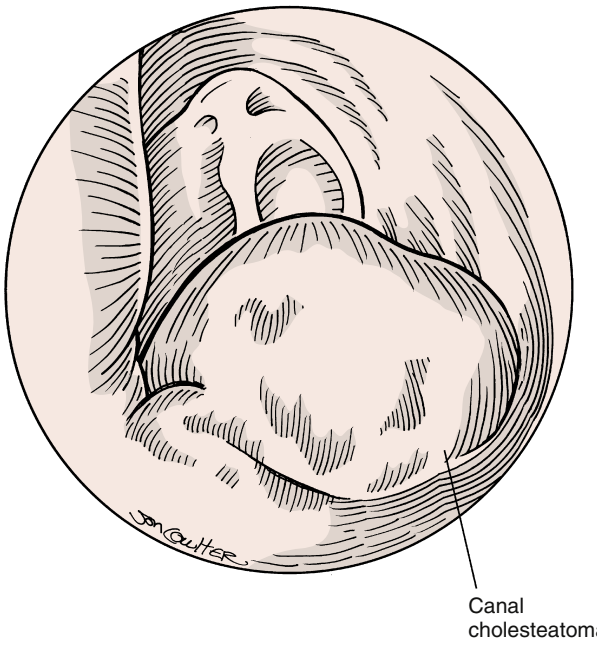

Fig. 128.3. Otoscopic view of a canal cholesteatoma forming in the inferior canal wall.

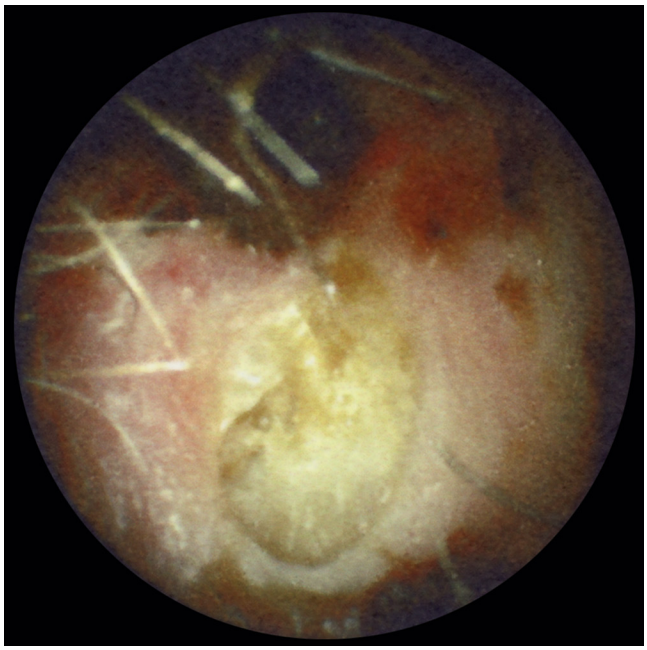

Fig. 128.4. Otoscopic view of exposed and eroded bone after removal of a cholesteatoma matrix.

auditory canal, removal of squamous debris can be difficult and not well tolerated by the patient.

For these cases, débridement can be performed under intravenous (IV) sedation or general anesthesia in the operating room. Rarely, canalplasty has been described for intractable KO.

For more extensive CC complicated by recurrent or persistent infections with mastoid bone involvement, a formal tympanomastoidectomy is almost always required to excise the trapped epithelium and cholesteatoma in the mastoid bone. This will require general anesthesia.

2. Awake sedation: Débridement can be performed under awake sedation.
3. Local: rarely performed as the ear canal is too sensitive for the patient to tolerate local anesthetic injection without any sedation
4. None: Both KO and small CC can be managed conservatively in the office without anesthesia administration, if pathology is well visualized and easily accessed for débridement. It is not uncommon to require repeated office visits.

Positioning

Supine: The patient is positioned on his/her back, and the head is turned away from the surgeon placing the ear under direct microscopic view.

Perioperative Antibiotic Prophylaxis

First-generation cephalosporin

Monitoring

Facial electromyography (EMG) monitoring is advisable if drilling of the medial canal wall or mastoid is anticipated.

Instruments and Equipment to Have Available

1. Operating microscope
2. Middle ear set
3. Otologic surgery drill and drill bits
4. Suction and irrigator
5. Dermatome for harvesting a split-thickness skin graft

Key Anatomic Landmarks

1. The external auditory canal is divided into a medial two-thirds with the bony canal covered by a very thin layer of skin adherent to the underlying periosteum and a lateral one-third cartilage canal covered with thick skin. This division connects at the isthmus (narrowest portion), and the ear canal terminates at the tympanic membrane.
2. The mastoid segment of the facial nerve can be located just medial to the posterior inferior tympanic annulus.
3. Recognize the medial extent of the CC and its proximity to the tympanic membrane and middle ear.

Prerequisite Skills

1. Familiarity with the temporal bone, external auditory canal, and middle ear anatomy
2. Experience with the ossicular chain and facial nerve pathway in the temporal bone
3. Familiar with middle ear instruments and the use of an otologic drill
4. Microsurgical dissection skills and experience with reconstruction of the ear canal, middle ear, and mastoid

Operative Risks

1. Injury to the facial or chorda tympani nerves
2. Drilling through the bony external auditory canal into the mastoid
3. Injury to the tympanic membrane
4. Injury to the ossicles
5. Postoperative external auditory canal stenosis
6. Failure to excise the CC completely

Surgical Technique

Limited disease can be addressed by a transcanal procedure. For more extensive disease in either condition, a postauricular

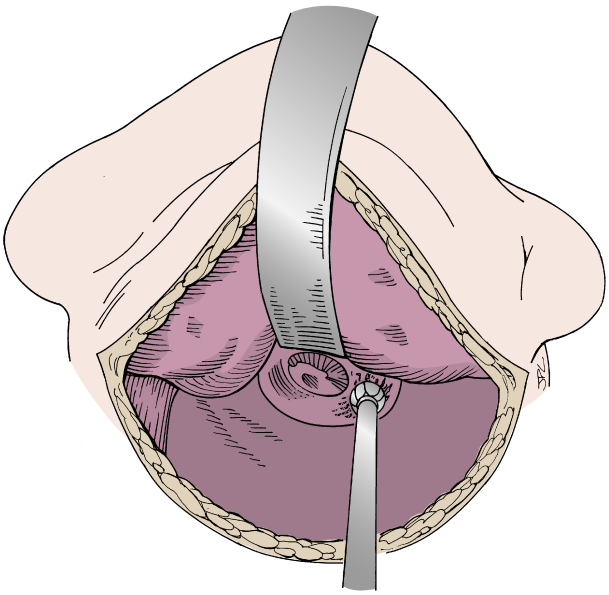

Fig. 128.5. Postauricular approach for the resculpting and grafting of a canal wall defect.

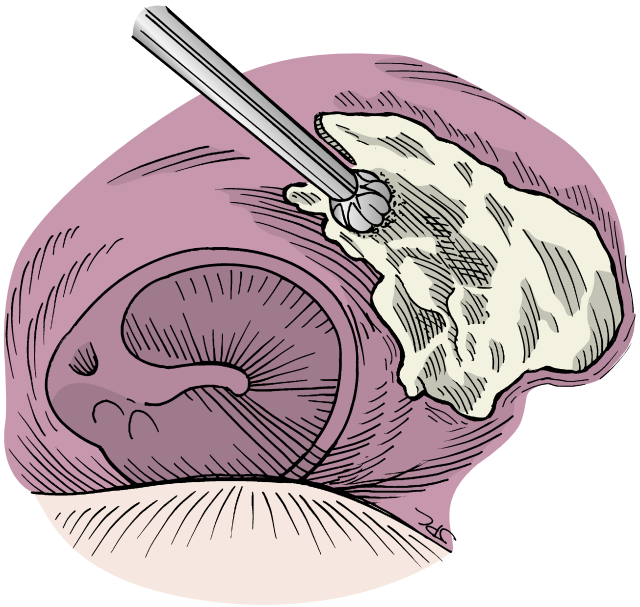

Fig. 128.6. Use of cutting and diamond burs to remove sequestrum and expose fresh, viable bone.

tympanoplasty approach under general anesthesia is safer and provides better exposure.

1. Incisions in the ear canal are made at the 12 and 6 o'clock positions connected vertically, creating a conchal flap extended to the level of the defect in the ear canal. A standard postauricular C-shaped skin incision, a vascular strip extending to the level of the canal defect, is made, and the pinna is reflected anteriorly with a tracheotomy tape and self-retaining retractor (Fig. 128.5).
2. After exposing the bony canal erosion defect, the transition between healthy and unhealthy tissue is demarcated. Unhealthy tissue is débrided, and healthy skin adjacent to the defect is elevated for optimal exposure of the healthy underlying bone.
3. Using appropriately sized cutting and diamond drill burs, devitalized bone of the ear canal is carefully removed until healthy bleeding bone is encountered. The canal defect is contoured to a smooth surface avoiding pits and craters (Fig. 128.6).
4. For larger CC that erodes the posterior bony ear canal and extends into the mastoid bone, facial nerve involvement must be considered, even with normal preoperative facial nerve function. *Consequently, a transcanal approach in which the nerve is not definitively identified may present greater risk for facial nerve paralysis.*
5. The sac extending into the mastoid air cells must be completely excised in order for the operation to be curative. *Sometimes, a canal wall down tympanomastoidectomy is necessary if reconstruction of the canal wall cannot be achieved.*
6. After removal of diseased skin and bone, the final surgical step is relining the denuded area of the exposed bony canal. If minimal coverage is required, temporalis fascia can be used to line the bony canal tucking the edge of the fascia beneath the surrounding healthy skin. If greater coverage is required, a split-thickness skin graft (up to 0.008 inches thick) can be harvested from the outer thigh or upper inner aspect of the arm.

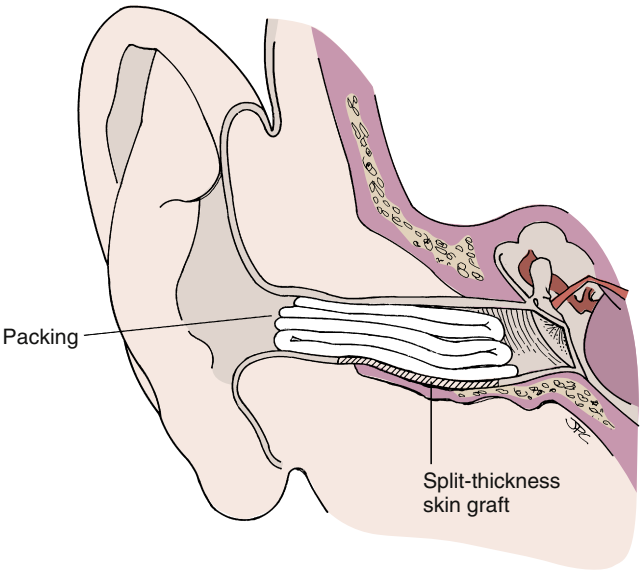

Fig. 128.7. Packing is placed in the canal to stabilize the split-thickness skin graft.

7. If large aerated mastoid air cells are exposed after performing a tympanomastoidectomy, fascial or adipose tissue should be used to obliterate the air cells prior to applying a skin graft. This will enhance survival of the graft, minimize potential development of a draining fistula from the mastoid air cells, and diminish the risk of recurrent cholesteatoma.
8. Elevated healthy adjacent canal skin is replaced, and the conchal or vascular strip is returned to its original position. A strip of silk or rayon mesh is laid over the skin graft to protect it and prevent movement. Gelfoam soaked in antibiotic solution is layered into the canal for continuous ear canal packing followed by the instillation of antibiotic ointment (Fig. 128.7).
9. The postauricular canal incision is closed in the usual manner, followed by a mastoid dressing.

Common Errors in Technique

1. Inadequate exposure of the external auditory canal defect leading to failure to completely eradicate CC
2. Violating the bony canal wall. It should be repaired with adipose tissue, fascia, a cartilage graft or hydroxyapatite reconstruction to avoid a fistula from the ear canal to the mastoid. Larger defects may require converting the procedure to a canal wall down tympanomastoidectomy.
3. It is important to assure that the edges of a split-thickness skin graft are laid flat and not folded upon itself.

POSTOPERATIVE PERIOD

Postoperative Management

1. Use topical antibiotic ear drops to dissolve the Gelfoam packing. On follow-up visits, Gelfoam packing can be débrided, and the silk mesh will be removed.
2. Simple débridement of skin edges may be carried out in the office until healing is complete, which normally occurs within 6 to 10 weeks.
3. Desquamation from the skin graft is common and may continue even after appropriate healing. Topical mineral oil or antibiotic ointment may lessen the accumulation of desquamated epithelium and make serial débridement easier.
4. Pain medication, including narcotics, should be provided for postoperative pain management.

Complications

1. Failure to excise the CC adequately. This may be due to poor surgical exposure or deep extension of the disease into the mastoid cells and will result in persistence or recurrence of disease. Erosion or aggressive drilling into the mastoid air cell system may require a canal wall down tympanomastoidectomy.
2. Injury to the mastoid segment of the facial nerve. With the use of facial nerve monitoring, this should be a very rare occurrence. Appropriate management options depend on the type and degree of facial nerve injury. (See Chapter 138 on facial nerve injury and decompression.)
3. Injury to the tympanic membrane and ossicular chain. This will require reconstruction of the tympanic membrane using a fascial graft and ossicles using an incus interposition or prosthesis. (See Chapter 132.)
4. Large bony canal defect requiring reconstruction with a cartilage graft or hydroxyapatite
5. Exposed bony external auditory canal secondary to failure of the skin graft to take
6. External auditory canal stenosis secondary to scar formation requiring a revision canaloplasty procedure

Alternative Management Plan

1. KO: Ototopical steroid drops may reduce the rate of epithelial cell turnover and consequently decrease the frequency of microscopic débridement.

   In the majority of cases, KO can be managed effectively by removing the keratin plug in the office, if done at regular intervals.

   Surgical intervention to remodel the external auditory canal may be necessary for intractable cases.
2. CC: For limited lesions, local curettage with the application of topical antimicrobial drops may be suitable. Focal areas may be managed with intraoperative curettage and débridement with repair of the epithelium using a postauricular fascial graft. Occasionally, formal tympanomastoid surgery and canalplasty (as described above) will be necessary for more extensive disease.

DISCUSSION

Evidence-Based Medicine Questions

a. What is the underlying pathology of KO and CC?
   KO is a plug of keratin, secondary to an abnormality of epithelial migration, causing obstruction and expansion of the bony external auditory canal.

   External auditory CC is invasion of squamous epithelium with localized periosteitis and bone erosion/sequestration.

b. What are the histological differences between KO and CC?
   KO consists of subepithelial inflammation without bony erosion and keratin squamous epithelium layered in a lamellar pattern.

   CC consists of keratin in loosely packed and random distribution with sequestration of the adjacent bone.

Editorial Comment

Both KO and ear CC are relatively rare otologic diseases. Given that they are disorders of the skin of the ear canal they may create difficulty in definitively diagnosing the processes. Distinguishing features of KO are the often bilateral nature of the disease and the prevalence for occurrence in young patients. Thickening of the keratin layer of the skin in the ear canal can also involve the epithelial layer of the tympanic membrane. This may present with a sensation of fullness in the ear and a conductive hearing loss. Complete ear canal involvement results in a cast outlining the contour of the ear canal and tympanic membrane, which, when extracted, can appear as a cylindrical bullet casing. Fortunately, the use of emollient oils or topical steroid drops can decrease the adhesiveness of the desquamated lining that fails to properly migrate. Removal of the cast reveals the widened ear canal and better visualization of the tympanic membrane.

CC can be focal in origin and respond to débridement in the office. Topical ear drops can reduce the surrounding inflammation and granulation tissue, which may result in otorrhea and bleeding. Some patients can tolerate local curettage following an injection of local anesthetic. Conservative treatment with meticulous removal of the lesion may be all that is necessary to maintain control. Often patients must be taken to the operating room for additional sedation and comfort. Discrete areas of epithelial burrowing and erosion can be removed with a curette for débridement and biopsy. A small microdrill can be used through an ear speculm to smooth and contour irregularities of the bone or spicules created by the erosive skin. As described, this exposed bone must be covered with fascia or a split-thickness skin graft.

More extensive CC can progress medially and burrow under the tympanic annulus and enter the middle ear. It can erode the bony canal posteriorly entering into the mastoid or more rarely anteriorly into the glenoid fossa. Such aggressive invasion should not be managed conservatively and merits operative removal and reconstruction.

Barry Hirsch

Access the review questions and additional sources list online at http://www.expertconsult.com

REFERENCES

1. Piepergerdes MC, Kramer BM, Behnke EE. Keratosis obturans and external auditory canal cholesteatoma. Laryngoscope 1980;90:383–391.
2. Persaud RA, Hajioff D, Thevasagayam MS, et al. Keratosis obturans and external ear canal cholesteatoma: how and why we should distinguish between these two conditions. Clin Otolaryngol 2004;29:577–581.
3. Park SY, Jung YH, Oh JH. Clinical characteristics of keratosis obturans and external auditory canal cholesteatoma. Otolaryngol Head Neck Surg 2015;152(2):326–330.
4. Corbridge RJ, Michaels L, Wright A. Epithelial migration in keratosis oburans. Am J Otolaryngol 1996;17:411–414.
5. Shire JR, Donegan JO. Cholesteatoma of the external auditory canal and keratosis obturans. Am J Otol 1986;7:361–364.

REVIEW QUESTIONS

1. What imaging modality is helpful to differentiate between the two disease entities?
   a. Radiograph of the skull
   b. CT of the temporal bone
   c. Magnetic resonance imaging of the internal auditory canal
   d. Positron emission tomography scan

2. What important key feature(s) on the imaging study helps to differentiate between the two disease entities?
   a. Erosion of bony external auditory canal (EAC)
   b. Widening of bony EAC
   c. Invasion into middle ear cavity and mastoid cavity
   d. All of the above

3. What is the first-line management option for KO?
   a. Topical antibiotic ear drops
   b. Débridement of keratin plug from external auditory canal in the office
   c. Tympanomastoidectomy
   d. Canal wall down tympanomastoidectomy

4. What important landmark needs to be monitored to avoid facial nerve injury when performing a canalplasty?
   a. Drilling the anterior superior ear canal wall
   b. Drilling the scutum at the superior ear canal wall
   c. Drilling the posteroinferior ear canal wall
   d. Drilling the inferior ear canal wall

5. When treating for EAC cholesteatoma (EACC), what is an important step?
   a. Excisional biopsy with histologic examination of the ulcerated skin edges to rule out malignancy that can mimic EACC
   b. Obtain skin graft from the inner arm or thigh
   c. Completely eradicate underlying bone by extending into the mastoid air cells
   d. Obliteration of mastoid air cells

ADDITIONAL SOURCES

Paparella MM, Goycoolea MV. Canalplasty for chronic intractable external otitis and keratosis obturans. Otolaryngol Head Neck Surg 1981;89:440–443.

129 Otitis Media, Myringotomy, Tympanostomy Tube, and Balloon Dilation

Sanjay Prasad, Roya Azadarmaki

INTRODUCTION

Otitis Media

Acute otitis media (AOM) and chronic otitis media with effusion are conditions well known to all otolaryngologists. Infants are predisposed to otitis media because of their immune-compromised state and altered angulation of the eustachian tube (ET). Later in life, adenoid enlargement with ET obstruction may also play a role. Children with craniofacial and cleft palate disorders are also more likely to develop otitis media because of altered anatomy and physiologic function of the ET.

- AOM refers to rapid onset of middle ear inflammation.
- Recurrent AOM is defined as three episodes of AOM in 6 months or 4 episodes in 12 months with at least 1 episode occurring in the past 6 months.[1]
- Persistent AOM is defined as an infection that fails to resolve with proper antibiotic therapy or when two episodes of otitis media occur in 1 month.[1]
- Chronic otitis media (OM) with effusion refers to an effusion that persists longer than 3 months.[1]
- With severe chronic OM, tympanic membrane retraction and middle ear atelectasis occur.
- Eosinophilic OM implies viscous eosinophilic middle ear fluid (allergic mucin).

Eustachian Tube Dysfunction

Dysfunction of the ET can result from anatomic, physiologic, or inflammatory causes. The middle 8 to 12 mm of the cartilaginous ET serves as a valve that is collapsed at rest and opens with contraction of the tensor veli palatini muscle.[2] Mucosal inflammation from rhinosinusitis, upper respiratory infection, laryngopharyngeal reflux, and exposure to "second-hand" smoke can prevent opening of the valve and results in poor ventilation of the middle ear.

KEY OPERATIVE LEARNING POINTS

1. Tympanostomy tubes are placed in the pars tensa of the tympanic membrane away from the posterior superior quadrant to avoid injury to the ossicular chain and chorda tympani nerve.
2. Tympanostomy tubes should be positioned for easy office evaluation.
3. The torus tubarius marks the nasopharyngeal opening of the ET and is posterior and slightly inferior to the posterior aspect of the inferior turbinate.
4. Lateralization of the inferior turbinate with a Freer elevator or serial balloon dilations can improve access of the posterior nasal cavity in narrow passageways.
5. The catheter in eustachian tuboplasty should not extend beyond the isthmus at the time of dilation. Dilation is focused on the valvular portion of the cartilaginous ET.

PREOPERATIVE PERIOD

History

1. History of present illness
   a. Presence of fever, otalgia, otorrhea, headaches, nausea and vomiting, anorexia, sleepless nights, ear tugging, subjective hearing loss, and balance disturbance
   b. Presence of ear popping, fullness, discomfort with barometric challenge, or autophony
   c. Duration of middle ear effusion if previously diagnosed
   d. Number of episodes of AOM
2. Past medical history
   a. Prior treatment: Previous history of antibiotic, allergy desensitization, nasal steroid, nasal antihistamine, oral antihistamine, oral steroid, or use of a topical or oral decongestant
   b. Medical illness: Concurrent rhinitis, rhinosinusitis, adenoid hypertrophy, laryngopharyngeal reflux, craniofacial disorders, syndromes, ciliary dysfunction, granulomatous disease, tympanic membrane rupture or perforation, cholesteatoma and tympanic membrane retraction, and atelectasis
   c. Surgery: History of previous myringotomy, tympanostomy tube placement, middle ear and mastoid surgery, or ET surgery
   d. Family history: History of parents or siblings with tympanostomy tubes
   e. Social history: Exposure to tobacco smoke directly or through second-hand exposure
   f. Medications:
      1) Antibiotics
      2) Nasal or oral steroids
      3) Nasal or oral antihistamines
      4) Topical or oral decongestants
      5) Antireflux medication

Physical Examination

Examination may reveal a normal tympanic membrane, retraction pocket with or without cholesteatoma, severe atelectasis, or adhesive otitis media. Nasopharyngoscopy

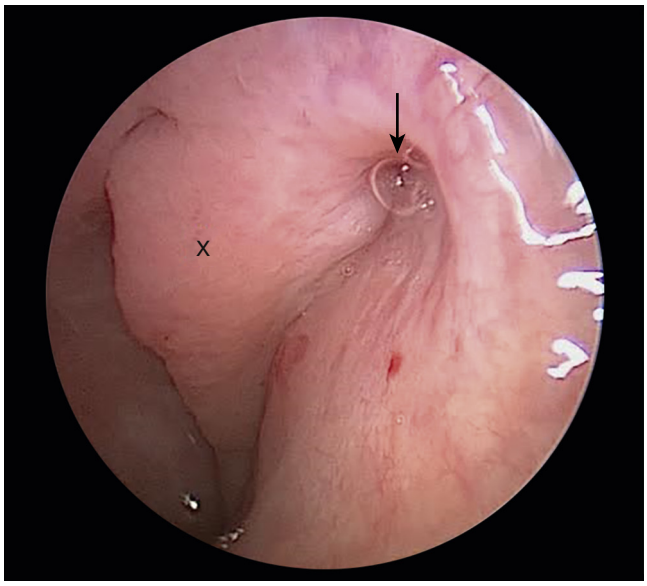

Fig. 129.1. Endoscopic view of the nasopharyngeal opening of a left eustachian tube showing significant peritubal inflammation. *X*, posterior cushion lined with hypertrophic mucosa. *Arrow*, collapsed lumen of the eustachian tube with secretions.

may reveal peritubal inflammation or adenoid hypertrophy (Fig. 129.1).

An ideal test to measure ET function has yet to be designed. The appearance of a retracted tympanic membrane (TM) on microscopy, presence of negative middle ear pressure on tympanometry, and absence of normal ET opening during nasopharyngoscopy with the patient swallowing may suggest ET dysfunction.

1. Pneumatic otoscopy and otomicroscopy: This is the gold standard test for otitis media. Patients are evaluated for an opaque, bulging, or perforated TM, active otorrhea, TM atelectasis and retraction with or without cholesteatoma, and TM mobility.
2. Flexible endoscopy: To assess for ET mucosal hypertrophy and inflammation, adenoidal hypertrophy, sinonasal disease, laryngopharyngeal reflux, or other forms of inflammatory or granulomatous disease
3. Rigid endoscopy: A 30- or 45-degree rigid endoscope can be used. Evidence of hypertrophic inflamed mucosa and hyperemia along the anterior and posterior cushions, excessive mucus, or adenoidal hypertrophy impacting on the posterior cushion of the ET can be seen in patients with ET dilatory dysfunction (see Fig. 129.1). Videoendoscopy is helpful to differentiate obstructive disease from dynamic dysfunction. Having the patient repeat the letter "K" and swallow or yawn causes contraction of the levator veli palatini. Palatal elevation leads to medial rotation of the posterior cushion as contraction of the tensor veli palatini acts on the lateral cartilaginous lamina to open the ET. During the active phase, the resting S-shaped lumen opens to a more rounded patent one.

Testing

Audiogram

- Conductive hearing loss can result from chronic effusion or ossicular chain erosion from chronic atelectasis.

Tympanometry

- A type B or C curve may be seen in chronic or recurrent middle ear disease.

Imaging

Myringotomy and Tube Placement

A computed tomography (CT) scan of the temporal bone is recommended when cholesteatoma, granulation, acute mastoiditis, tumors, tegmen defect, encephalocele, or vascular anomalies are suspected.

Balloon Eustachian Tuboplasty

CT scan of the temporal bone is recommended prior to balloon eustachian tuboplasty (BET) to rule out anatomic abnormalities of the skull base especially dehiscence of the carotid artery encroaching on the tubal lumen. Sinonasal disease should also be evaluated.

Indications

Myringotomy and Tympanocentesis

- Obtain cultures in patients with AOM accompanied by high fever and sepsis and in patients with complications of OM. Tube insertion is recommended.
- Pain and pressure relief of AOM (not commonly performed)

Myringotomy and Tube Placement

Tympanostomy tube insertion is the most common ambulatory surgery performed in children in the United States. This procedure helps to improve middle ear ventilation and can help patients with poorly functioning ETs.

Common indications include persistent otitis media with effusion resulting in hearing loss, recurrent otitis media, or persistent otitis media that fails to resolve with conservative treatment. Based on guidelines by the American Academy of Otolaryngology-Head and Neck Surgery, tympanostomy tubes are recommended in children aged 6 months to 12 years, with bilateral otitis media with effusion for 3 months or longer with documented hearing loss, and in children with recurrent AOM with effusion on one or both sides.[1] The guidelines also recommend treating at-risk children with baseline sensory, physical, cognitive, or behavioral problems with otitis media with effusion and recurrent AOM.[1] The guidelines do not address treatment of patients with retracted TMs, complications of otitis media, or barotrauma.

Indications for tube placement:

- AOM that fails to resolve with antibiotic therapy
- Recurrent AOM with presence of effusion and children with high fevers and discomfort regardless of clinical examination
- AOM with complications such as coalescent mastoiditis, meningitis, intracranial abscess, sigmoid sinus thrombosis, and facial nerve paresis. Mastoidectomy may also be needed.
- Chronic OM with effusion and documented hearing loss for 3 months or longer
- Chronic OM with adherent or nonadherent TM atelectasis, ossicular chain erosion, and TM retraction with or without cholesteatoma
- Eosinophilic otitis media: For ventilation and topical steroid treatment

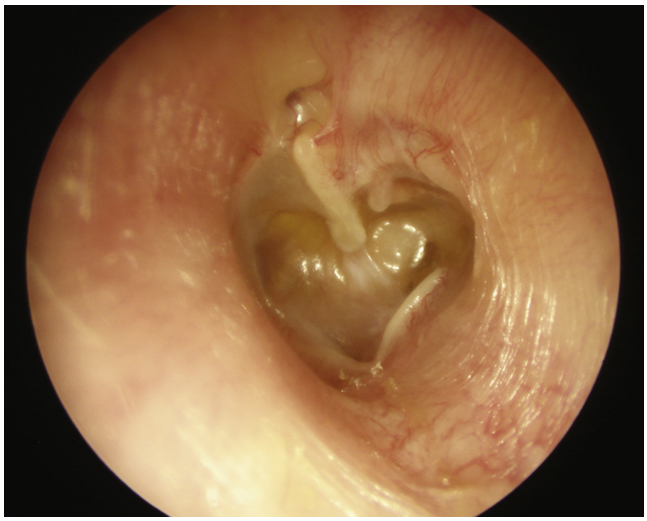

Fig. 129.2. Severe atelectasis with a natural type II/III tympanoplasty. Ventilation of the middle ear aims to lateralize the tympanic membrane off the promontory and ossicles.

- ET dysfunction with aural fullness, ear popping, and otalgia not responding to conservative therapy
- ET dysfunction with otalgia and hearing loss with barometric challenge as with air travel or hyperbaric oxygen therapy

Balloon Eustachian Tuboplasty

- Chronic and persistent otitis media with effusion (OME)
- Nonadherent TM atelectasis
- Symptomatic ET dilatory dysfunction including conductive hearing loss, otalgia, and aural fullness with pressure change
- Symptomatic patients with type B or C tympanograms
- Flight and scuba diving baro-challenge
- Past demonstration of symptom improvement with tube placement

In patients with adherent atelectasis, progression of disease can lead to ossicular chain erosion with type II or III tympanoplasty (Fig. 129.2) and in severe cases, cholesteatoma. Tube placement may not be possible and BET may not restore middle ear aeration. Tympanoplasty with tube placement (with consideration for BET) may help restore middle ear ventilation, arrest progression, and improve ET function. Observation alone is also an option in some patients.

Contraindications

Myringotomy and Tube Placement

1. Cerebrospinal fluid (CSF): If clear fluid is encountered during myringotomy, the tympanostomy tube should not be placed.
2. Vascular anomaly: If a high-riding jugular bulb or aberrant carotid artery is suspected, great caution should be exercised and CT imaging obtained.
3. Anesthesia contraindications

Balloon Eustachian Tuboplasty

1. Dehiscent carotid artery in the osseous ET canal
2. Anesthesia contraindications

Preoperative Preparation

Audiogram and tympanogram

OPERATIVE PERIOD

Anesthesia

Myringotomy and Tube Placement

- Topical: Phenol or trichloroacetate can be applied topically to the tympanic membrane using a fine cotton-tipped applicator. The tympanic membrane develops a white blanch. Patients may experience a burning sensation for up to several minutes. After a few minutes, myringotomy and tube placement can be performed.
- Local injection of the ear canal: 1% lidocaine with 1:100,000 epinephrine
- General: The procedure is performed under general anesthesia in children and anxious adults.
- Awake sedation: Alternative option

Balloon Eustachian Tuboplasty

- General: General anesthesia can be administered via laryngeal mask airway.

Positioning

Myringotomy and Tube Placement

- Local: Semirecumbent, supine position, or sitting with the head turned slightly away from the side of intervention
- General anesthesia or sedation: Supine position with the head turned slightly away from the side of intervention

Balloon Eustachian Tuboplasty

- Supine position with the head turned slightly toward the surgeon. The head of the bed may be turned 90 degrees.

Perioperative Antibiotic Prophylaxis

Tympanocentesis

- Clean-contaminated surgery
- Perioperative antibiotic prophylaxis is not recommended.

Myringotomy and Tube Placement

- Clean-contaminated surgery
- Perioperative antibiotic prophylaxis is not recommended.

Balloon Eustachian Tuboplasty

- Clean-contaminated surgery
- Perioperative antibiotic prophylaxis is not recommended.

Monitoring

Tympanocentesis

- None necessary

Myringotomy and Tube Placement

- None necessary

Balloon Eustachian Tuboplasty

- Cardiac monitoring is recommended.

Instruments and Equipment to Have Available

Tympanocentesis

1. Alden-Senturia trap (Storz Instrument Co.) attached to an 18-gauge needle
2. Tuberculin syringe and 18-gauge needle

Myringotomy and Tube Placement

1. Operating microscope or 0-degree endoscope
2. Ear speculums of various sizes
3. Cup forceps; cerumen loops; curettes, 3, 5, and 7F suction; and cotton-tipped applicators for removal of ear canal debris and cerumen
4. Myringotomy knife
5. Alligator forceps for tympanostomy tube guidance into the ear canal and myringotomy site
6. Curved pick and right-angled hook for completion of tube insertion and orientation
7. 3F, 5F, and 7F suctions to clear middle ear content and tube orifice
8. Selected tympanostomy tube(s)

Tympanostomy Tube Options

Tympanostomy tubes are typically made of plastic, although silicone, metal, and hydroxyapatite tubes are still used. Biocompatibility and resistance to clogging and extrusion are important factors.

Retention and patency are related to tube design (Fig. 129.3). Short-term tubes are typically retained from 6 to 12 months and long-term tubes retained more than 12 months. Short-term tubes are shaped like a grommet. They may have the configuration of an hourglass (Shepard-type tube) or have beveled inner flanges (Armstrong-type tube). The latter tend to be retained longer. Long-term tubes are typically T-tubes with long inner flanges to prevent early extrusion and are placed in patients who have a history of early extrusion or in patients with the need for prolonged middle ear ventilation. Sometimes the inner flanges need to be shortened.



Fig. 129.3. Tympanostomy tubes. (*Left*, short-term Armstrong Beveled Grommet Tube. *(Reprinted with the permission of Medtronic, Inc. © 2016.) Right*, long-term Richards Modified T-Tube. *(GYRUS ACMI, with permission.))*

Balloon Eustachian Tuboplasty

1. 30- or 45-degree endoscope
2. Pledgets soaked in Afrin, 1:1000 epinephrine, or a decongestant of choice
3. Bayonet forceps and nasal speculum for pledget placement
4. Freer elevator
5. 9 or 10F suction
6. Balloon catheter system
7. 70-degree introducer for selected balloon systems

Key Anatomic Landmarks

1. Myringotomy and tympanostomy tube placement should be located in the pars tensa and away from the posterior-superior quadrant, so as not to harm the ossicular chain (Fig. 129.4).
2. Torus tubarius: This marks the nasopharyngeal opening of the ET and can be identified posterior and slightly inferior to the posterior aspect of the inferior turbinate (Videos 129.1 and 129.2).
3. ET isthmus: This is the narrowest portion of the ET and marks the bony-cartilaginous junction. When advancing a balloon catheter, the isthmus can be felt as an area of resistance.

Prerequisite Skills

1. Dexterity using the operating microscope or otoendoscopes
2. Dexterity and experience using nasal endoscopes and balloon dilation procedures

Operative Risks

Both procedures are relatively safe; however, the following operative risks exist.

Myringotomy and Tube Placement

1. Minor bleeding: Avoid contact of the canal skin with instruments. This is usually controlled with topical use of cotton soaked with 1:1000 epinephrine.
2. Major bleeding: The ear canal should be filled with thrombin-soaked Gelfoam and the head should be slightly raised.

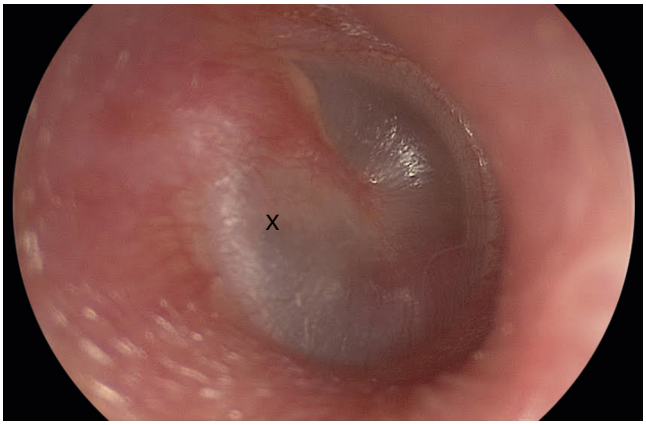

Fig. 129.4. Endoscopic view of right tympanic membrane. *X*, posterior superior quadrant and area of the ossicular chain to be avoided at the time of myringotomy and tube placement.

Hypertension should be medically treated. If profuse bleeding persists, the ear canal should be packed tightly and prompt transfer to a tertiary care hospital should be considered.
3. Infection: Otorrhea should be treated with antibiotic drops.
4. Tympanic membrane perforation: An atrophic tympanic membrane is at risk for perforation.
5. Middle ear tympanostomy tube: Rarely, the tube may fall into the middle ear space. The tube should be removed through the myringotomy site. If the tube is not retrievable, a new tube should be placed. Management of the medialized tube is discussed in the complications section.
6. Avoiding the posterior-superior quadrant will prevent harm to the ossicular chain and chorda tympani nerve.
7. Risk of general anesthesia

Balloon Eustachian Tuboplasty

1. Injury to nasal structures including the septum and inferior turbinates with associated immediate bleeding and delayed scar band formation
2. False passage of the balloon catheter with laceration of the ET mucosal lining and soft tissue emphysema
3. Tympanic membrane rupture from the pressure associated with balloon dilation
4. Risk of general anesthesia
5. In theory, advancement of the catheter past the bony isthmus with dilation, in the presence of a dehiscent carotid canal, can cause injury leading to dissection, aneurysm formation, bleeding, stroke, and death. However, these complications have never been reported in the current era of BET. Clinically significant sinus tachycardia, bradycardia, and premature ventricular contractions (PVCs) have been experienced and are believed to be related to stimulation of the carotid plexus. In these situations, the procedure should be aborted.

Surgical Technique

Myringotomy and Tube Placement

1. Performed in the office or operating room
2. Using the operating microscope and appropriately sized ear speculum or 0-degree endoscope (4.0 mm or 2.7 mm), the ear canal and tympanic membrane are visualized.
3. Removal of cerumen and squamous epithelium at the time of the procedure will facilitate access and postoperative care.
4. With a myringotomy knife, an incision of approximately 2 mm is made. The site of the myringotomy should avoid the posterior-superior quadrant, avoid contact with the malleus handle, and not extend to the annulus.
5. The incision can be widened using alligator forceps if needed.
6. Middle ear effusion is aspirated using a 5F suction. A smaller suction should be used if there is risk of perforation due to TM atrophy. 7F suction with or without saline irrigation should be used if viscous fluid is encountered.
7. Cultures should be obtained when appropriate.
8. The tympanostomy tube is inserted into the myringotomy site.
9. The tube can be optimally positioned using a pick. Ideally, the middle ear mucosa should be visualized through the tube orifice.
10. Hemostasis can be achieved using cotton soaked in 1:1000 epinephrine. Hemostasis reduces the risk of postoperative tube obstruction.
11. Antibiotic-steroid drops are applied when middle ear effusion, infection, or bleeding is present to treat the disease process and prevent tube obstruction.

Operative Challenges in Myringotomy and Tube Placement

1. Atelectatic tympanic membrane: Injection of 0.1 to 0.2 cc of air with a 27-gauge needle can help aerate the middle ear and create an area for tube placement.
2. Stenotic meatus: Serial dilations of the stenotic meatus with increasing speculum size can be helpful. In cases where a small-diameter speculum is used, the tube can be placed into the medial ear canal independent of the ear speculum and then maneuvered to the myringotomy site.

Myringotomy and Tympanocentesis

Alcohol or betadine irrigation can be used to sterilize the ear canal before the myringotomy incision or tympanocentesis.

Myringotomy and culture: Steps 1 to 4 of the myringotomy and tube placement technique are followed. Once the myringotomy is made, the middle ear content is cultured using a sterile swab. A small syringe attached to a 3F or 5F Fraser suction can also be used to collect a specimen for culture.

Tympanocentesis: Steps 1 to 3 of the myringotomy and tube placement technique are followed. An 18-gauge Rosen suction needle attached to a tuberculin syringe or an Alden-Senturia trap system is subsequently used to aspirate middle ear content. The posterior-superior quadrant should be avoided.

Balloon Eustachian Tuboplasty

1. Following laryngeal mask airway intubation, the table is turned 90 degrees.
2. Cottonoids soaked in decongestant medication (Afrin, 1:1000 epinephrine) are inserted into the nasal cavity.
3. After removal of cottonoids, the nasal cavity is inspected using a 30- or 45-degree scope.
4. The balloon catheter tip is bent to 70 degrees prior to placement in the nasal cavity. The angle may need adjustment based on the anatomy.
5. The balloon catheter is guided to the posterior nasal cavity (tip up or down). With some balloon systems, a 70-degree curved guiding catheter is required to access the ET.
6. Serial balloon dilation between the septum and inferior turbinate or gentle lateralization of the inferior turbinate with a Freer may be necessary for exposure.
7. If the catheter and endoscope cannot fit through the same side, the angled endoscope can be used from the contralateral side.
8. Once the balloon catheter reaches the ET opening, it is rotated laterally into the ET. If a guiding catheter is used, it is appropriately positioned to allow for balloon insertion.
9. The balloon catheter can be used to gently rotate the posterior cushion medially to inspect the proximal ET lumen (Video 129.1).
10. The balloon is carefully advanced with care not to create a false passage. If resistance is encountered at the isthmus, the balloon should not be advanced.
11. The balloon is inflated for 2 minutes (Video 129.2 and 129.3).
12. Some patients experience PVCs and systolic hypertension, which is believed to be secondary to stimulation of the carotid sympathetic plexus. In these cases, the balloon should be immediately deflated and the procedure aborted.

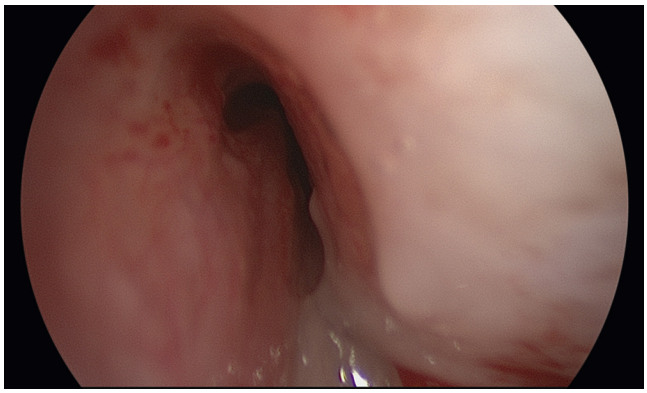

Fig. 129.5. Endoscopic view of the lumen of the cartilaginous left eustachian tube post balloon dilation.

13. Once the catheter is removed, the lumen of the cartilaginous ET can be inspected for mucosal tears or false tracts using an angled scope (Fig. 129.5).
14. A micro-cottonoid soaked with Decadron, 10 mg/mL, can be placed into the lumen of the ET for several minutes when mucosal edema or hypertrophic mucosa is encountered.

In September 2016 the Acclarent Aera Eustachian Tube Balloon System was introduced as the first balloon catheter device with the U.S. Food and Drug Administration's approval for BET. Subsequently, in April 2017 the Entellus XprESS balloon dilation device system received the U.S. Food and Drug Administration's approval for the same indication.

The Acclarent Aera Eustachian Tube Balloon system contains a guide and balloon catheter. The balloon dimensions with this device are 6 x 16 mm. The guide catheter tip is aligned with the ET's nasopharyngeal opening trajectory and the balloon catheter is advanced through the guide catheter. A marking point is set to indicate the level of balloon catheter advancement however advancement is stopped if resistance is encountered and the bony isthmus is reached prior to the expected mark.

The Entellus XprESS balloon system approved for Eustachian tube dilation comes in different dimensions. We recommend that balloons with a length greater than 18 mm are not initially used until experience with the procedure and respect for the tactile feedback from the bony isthmus are achieved.

The authors use the XprESS Entellus Balloon Device with dimensions of 6 x 18 mm. The malleable tip is bent to accommodate the angulation of the ET's nasopharyngeal opening. This is normally achieved with a 55o to 70o bend.

Balloon length of up to 18 mm is adequate to pass beyond the valve of the cartilaginous ET and short enough to minimize the risk of entry into the bony ET. (Videos 129.1 to 129.3).

Common Errors in Technique

Myringotomy and Tube Placement

1. Aggressive débridement or impingement of the canal wall with instruments resulting in canal wall hematoma and bleeding
2. Myringotomy that is too small resulting in difficulty with tube insertion
3. Improper loading of the tube onto the alligator forceps, leading to difficult insertion. Serrated alligator forceps offer a more secure grasp of the tube than a smooth forceps.

Balloon Eustachian Tuboplasty

1. Incorrect angulation of the catheter tip resulting in difficulty with ET insertion
2. Inadequate nasal cavity decongestion causing poor visualization
3. Not performing out-fracture of the inferior turbinate resulting in poor visualization

POSTOPERATIVE PERIOD

Postoperative Management

Myringotomy and Tube Placement

1. No ear drops are needed if there is no middle ear effusion, purulent secretions, or bleeding.
2. Steroid-fluoroquinolone drops or fluoroquinolone drops alone for 3 days in patients with serous effusion or bleeding
3. Steroid-fluoroquinolone drops or fluoroquinolone drops alone for up to 10 days in cases with mucoid or purulent effusion
4. Follow up in 1 to 2 weeks if mucoid or purulent effusion is encountered; otherwise, follow-up can be scheduled up to 4 weeks postoperatively.
5. Postoperative audiogram and tympanogram
6. Routine follow-up every 3 to 6 months after initial postoperative visit
7. Water precautions: Literature does not support the use of water precautions in the form of earplugs, headbands, or avoidance of water activities. We recommend water precautions if patients are exposed to lake, river, or ocean water or are involved in shallow diving. Water precautions should be recommended for individuals who develop otalgia or otorrhea after water exposure.

Balloon Eustachian Tuboplasty

1. No nose blowing for 1 week to avoid the risk of soft tissue emphysema.
2. Nasal steroid spray for a minimum of several weeks. Prolonged use is recommended with concurrent sinonasal disease and mucosal inflammation.
3. If a modified Valsalva maneuver, which involves the traditional Valsalva maneuver accompanied by a simultaneous swallow, cannot be performed after the first postoperative week, a Politzer maneuver can be attempted and may be helpful.
4. If a patient has undergone a tympanoplasty, mastoidectomy, and ossicular chain reconstruction in conjunction with the BET, we do not recommend the modified Valsalva maneuver for 3 to 4 weeks.
5. Follow up 2 to 4 weeks postoperatively.
6. Postoperative audiogram and tympanogram
7. Long-term monitoring after BET is required as efficacy and outcomes are still evolving.

Complications

Myringotomy and Tube Placement

1. Otorrhea (>20%)[1]: Treated with antibiotic drops with or without steroids. Patients with persistent otorrhea after culture-based treatment should be evaluated for cholesteatoma and other sources of middle ear/mastoid disease.
2. Tube obstruction (7%)[1]: Treated with drops or hydrogen peroxide

3. Granulation (4%)[1]: Treated with antibiotic-steroid drops. In patients with persistent granulation, the tube should be removed to resolve the foreign-body reaction.
4. Premature tube extrusion (4%)[1]: Seen in some patients with obstructive sleep apnea on continuous positive airway pressure (CPAP). Lowering the pressure setting may be helpful.
5. TM perforation following extrusion (1% to 6%)[1]: Observation, myringoplasty, or tympanoplasty can be recommended. A small perforation can be observed because it is functioning like a ventilation tube.
6. Middle ear tube (0.5%)[1]: Rarely the tube can fall into the middle ear. Tube retrieval should be attempted through the myringotomy site. In patients where retrieval is not possible or the TM has healed, exploratory tympanotomy with tube retrieval should be considered in the presence of an inflammatory reaction.
7. TM tube retention beyond 2 to 2.5 years: Tube replacement or tube removal with myringoplasty should be considered.
8. Myringosclerosis, tympanosclerosis, TM atrophy, and atelectasis changes are generally irreversible.

Balloon Eustachian Tuboplasty

1. False passage, typically along the anterior and medial ET wall
2. Epistaxis
3. Subcutaneous emphysema: Usually self-limiting; however avoidance of nose blowing will prevent exacerbation
4. Patulous ET
5. Tympanic membrane perforation from excessive middle ear pressure effect
6. Tinnitus
7. Cardiac dysrhythmia: PVCs, bradycardia, and clinically significant tachycardia should prompt the surgeon to abort the procedure.
8. Systolic hypertension: Usually responds to medical treatment
9. Worsening ET function from scarring: Very rare
10. Injury to the internal carotid artery: Very unusual in carefully selected patients

Alternative Management Plan

1. Culture-based antibiotic treatment in cases of recurrent AOM or persistent otitis media. Infectious disease consultation with possible intravenous antibiotics may be useful.
2. Aggressive medical treatment of concurrent laryngopharyngeal reflux and rhinosinusitis as a source of ET dysfunction and otitis media
3. Treatment of ET mucosal inflammation with topical nasal steroids alone or in conjunction with oral steroids
4. Adenoidectomy alone or in conjunction with tympanostomy tube placement and/or BET when adenoid hypertrophy is present
5. Myringotomy with tympanostomy tube placement and BET can serve as each other's alternatives.
6. Microdébrider eustachian tuboplasty in patients with concurrent hypertrophic and inflamed mucosa along the posterior cushion. This can be combined with tube placement and/or BET.

Evidence-Based Medicine Question

Is BET an effective procedure for improving eustachian tube function?

In addition to widening the opening of the ET, replacement of irreversibly damaged mucosa and submucosal lining of the ET with thin scar is believed to be the mechanism by which balloon dilation affects the ET and improves its function.[3] Kivekas et al. report that biopsies of ET lining in 13 patients before, immediately after, and in a few (5 to 12) weeks post balloon dilation revealed a reduced inflammatory effect on the mucosa and submucosa.[3]

A systematic review of nine case series revealed a need for randomized controlled trials to determine the efficacy of BET. However, several studies have shown promising outcomes with BET. Silvola et al. demonstrated an 80% BET success rate in 37 patients with a history of multiple tympanostomy procedures for otitis media with effusion, tympanic membrane nonadherent atelectasis, type B or C tympanograms, and in patients unable to perform the Valsalva maneuver.[4] Success was defined as the ability to perform the Valsalva maneuver postoperatively.[4] In 2015 Schröder et al. reported their outcomes in management of 622 patients and 1076 ETs in patients 7 to 84 years of age.[5] The overall success rate, based on ET scores, was over 70%, with 82% improvement at 5 years.[5] Overall the data are promising, suggesting a possible revolution in the management of ET dysfunction.

Literature on BET in children is currently limited. BET can be considered in individuals 7 years of age and older as the ET is close to adult length by this age. The safety and efficacy of BET in children less than 7 years of age have yet to be demonstrated. Use of shorter balloons should be considered in children.

Editorial Comment

Myringotomy with or without tubes is the most common procedure performed by otolaryngologists. Following the use of antibiotics for recurrent AOM, placement of myringotomy tubes is the mechanical means of ventilating the middle ear. This provides a short-term solution to problems attributed to poorly functioning ETs. Drainage of AOM that is causing complications such as mastoiditis and facial paralysis provides immediate benefit toward recovery. Ventilation is advocated for individuals with carbon monoxide toxicity or those following acute barotrauma who cannot equilibrate their middle ear pressure. Ventilation tubes are placed prior to the initiation of treatment in the pressure chamber.

Various factors influence the ability of the ET to ventilate the middle ear including the horizontal orientation of the tube, compromised mucosal disease, or sinonasal inflammation causing dysfunction or obstruction. The advent of endoscopic surgery on ETs may hold promise toward providing a more physiologic means of reversing ET dysfunction. Additional experience with both children and adults will ascertain if such procedures are successful and their duration of efficacy.

Barry Hirsch

Access the review questions and additional sources list online at http://www.expertconsult.com

REFERENCES

1. Rosenfeld RM, Schwartz SR, Pynnonen MA, et al. Clinical practice guideline: tympanostomy tubes in children. Otolaryngol Head Neck Surg 2013;149(Suppl. 1):S1–35.
2. Poe DS, Silvola J, Pyykko I. Balloon dilation of the cartilaginous eustachian tube. Otolaryngol Head Neck Surg 2011;144:563–9.
3. Kivekäs I, Chao WC, Faquin W, et al. Histopathology of balloon-dilation eustachian tuboplasty. Laryngoscope 2015;125(2):436–41.
4. Silvola J, Kivekas I, Poe DS. Balloon dilation of the cartilaginous portion of the eustachian tube. Otolaryngol Head Neck Surg 2014;151:125–30.
5. Schröder S, Lehmann M, Ebmeyer J, et al. Balloon eustachian tuboplasty (BET): our experience of 622 cases. Clin Otolaryngol 2015;40(6):629–38.

REVIEW QUESTIONS

1. Landmarks for the nasopharyngeal eustachian tube opening include all of the following except which option?
   a. Posterior attachment of the middle turbinate
   b. Posterior aspect of the inferior turbinate
   c. Posterior cushion
   d. Torus tubarius

2. Tympanostomy tube placement should be avoided in which of the following tympanic membrane quadrants?
   a. Posterior-inferior
   b. Anterior-inferior
   c. Posterior-superior
   d. Anterior-superior

3. Which of the following is a tympanostomy tube complication that is least likely to occur?
   a. Otorrhea
   b. Tube obstruction
   c. Tympanic membrane perforation
   d. Tube falling into the middle ear

4. Which of the following is the major vascular structure parallel to the osseous segment of the eustachian tube?
   a. Petrous carotid artery
   b. Cavernous carotid artery
   c. Cervical carotid artery
   d. Jugular bulb

ADDITIONAL SOURCES

Adil E, Poe D. What is the full range of medical and surgical treatments available for patients with eustachian tube dysfunction? Curr Opin Otolaryngol Head Neck Surg 2014;22:8–15.

Kay DJ, Nelson M, Rosenfeld RM. Meta-analysis of tympanostomy tube sequelae. Otolaryngol Head Neck Surg 2001;124(4):374–80.

Randrup TS, Ovesen T. Balloon eustachian tuboplasty: a systematic review. Otolaryngol Head Neck Surg 2015;152(3):383–92.

Schröder S, Abdel-Aziz T, Lehmann M, et al. Bacteriologic investigation of the eustachian tube and the implications of perioperative antibiotics before balloon dilation. HNO 2015;63(9):629–33.

130 Intracranial Complications of Otitis Media

Dennis J. Kitsko, Kavita Dedhia

INTRODUCTION

Complications from acute otitis media or chronic otitis media can be divided into extracranial complications (i.e., facial nerve paralysis, labyrinthitis, and subperiosteal abscess) and intracranial complications. Intracranial complications of otitis media include meningitis, epidural abscess, subdural abscess (empyema), brain abscess, lateral sinus thrombophlebitis/sigmoid sinus thrombosis, otitic hydrocephalus, and Gradenigo's syndrome (Fig. 130.1). On occasion, an intracranial complication may be the initial symptom in a patient with a history of untreated otitis media. It is also important to understand that multiple complications may often occur concomitantly, and the existence of one intracranial complication warrants investigation into the presence of others. Despite broad-spectrum antibiotics, complications of otitis media can result in high morbidity and even mortality, and surgical management is often necessary.

The spread of otitis media to intracranial structures may occur either directly or hematogenously. Direct extension can occur via multiple mechanisms: pre-existing congenital abnormalities (e.g., a Mondini deformity), posttraumatic bony defects from a fracture of the temporal bone, erosion of bony barriers as a result of cholesteatoma, normal communicating vein pathways from the mastoid to the intracranial space, and spontaneous or iatrogenic dehiscence of bone. Historically, meningitis has been and continues to be the most common intracranial complication of otitis media in children and adults, both in developed and underdeveloped countries. Epidural abscess and lateral sinus thrombosis have been reported as the next most common complications in children. Brain abscess, a rare complication in children in developed countries, is seen more commonly in the adult population and in less developed countries.

Patients may initially have the classic signs of otogenic infection, such as foul-smelling otorrhea, otalgia, headache, fever, vertigo, and sudden hearing loss. As the disease progresses, later signs include changes in mental status, such as confusion, obtundation or seizures, and cranial nerve palsies. Many patients with intracranial complications will have multiple complications, such as meningitis in addition to an intracranial abscess, and the Otolaryngologist should seek to diagnose and treat all of these complications. Patients may have concurrent intratemporal complications, such as subperiosteal abscess, labyrinthitis, and facial nerve paresis. When evaluating for the possibility of intracranial complications of otitis media, magnetic resonance imaging (MRI) provides better detail of intracranial structures than computed tomography (CT). The frequency of various intracranial complications in a number of case series is presented in Table 130.1.[1-5]

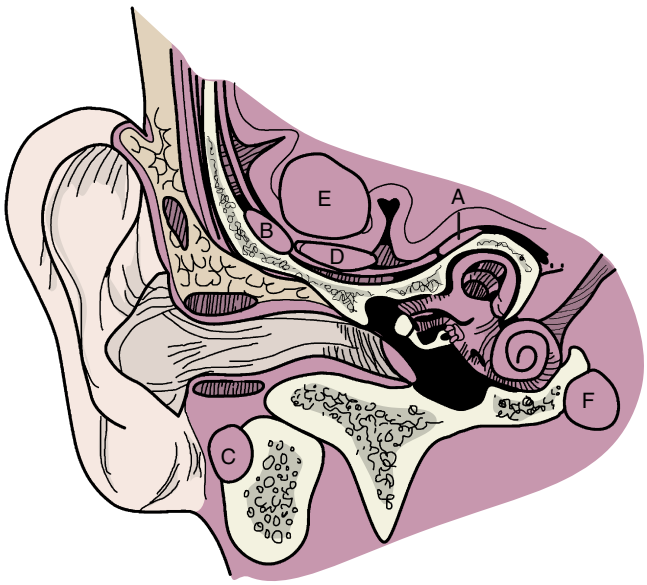

Fig. 130.1. Intracranial complications of otitis media include meningitis *(A)*, epidural abscess *(B)*, lateral sinus thrombosis *(C)*, subdural empyema *(D)*, brain abscess *(E)*, and petrous apicitis *(F)*. *(Adapted from Vazquez E, Castellote A, Piqueras J, et al: Imaging of complications of acute mastoiditis in children. Radiographics, 2003, 23:359-372.)*

KEY OPERATIVE LEARNING POINTS

- Meningitis due to otitis media is initially treated with myringotomy and tube insertion and antibiotics.
  - For those who fail conservative treatment, a complete mastoidectomy is performed when medically stable.
  - Close follow-up for possible sequelae, including labyrinthitis ossificans
- An isolated epidural abscess secondary to coalescent mastoiditis requires a mastoidectomy with unroofing of the affected bone.
  - Great caution is given not to enter the dura.
- Lateral sinus thrombosis requires a mastoidectomy.
  - A thrombectomy may be required if there is gross infection of the sinus.
- Subdural and brain abscesses are surgical emergencies and must be evacuated immediately, requiring neurosurgical intervention.
- Surgical management of otitic hydrocephalus depends on the extent of the disease.
- Initial management of petrous apicitis is a trial of intravenous (IV) antibiotics.
  - If no improvement or imaging shows coalescence and bone septate destruction, surgery is indicated.
  - Surgical intervention can range from a mastoidectomy with tympanostomy tube placement to performing a subtotal petrosectomy.

PREOPERATIVE PERIOD

History

- Classic symptoms
  - Headache
  - Photophobia
  - Spiking fevers
  - Mental status changes
  - Nausea and vomiting

Physical Examination

- Classic physical signs, such as Kernig's sign, Brudzinski's sign, and nuchal rigidity are not consistently present.
- May have typical physical findings of acute otitis media, such as otorrhea or bulging of the tympanic membrane
- Clinical suspicion of a more chronic underlying cause should also be high, particularly in the setting of an otherwise innocuous otologic physical examination.
- Diagnosis is via lumbar puncture (LP).
- *Streptococcus pneumoniae* and *Haemophilus influenza* are the primary organisms.[6]
- MRI or fine-cut contrast-enhanced CT of the temporal bone can rule out other intracranial complications.
- Typical LP findings in bacterial meningitis
  - Elevated opening pressure
  - Elevated white blood cell count
  - Elevated protein
  - Decreased glucose
  - Elevated cerebrospinal fluid (CSF) lactate

Imaging

- Due to the risk of LP-induced cerebral herniation, current practice guidelines recommend CT prior to LP in the setting of:
  - Immunocompromised state
  - History of central nervous system (CNS) disease (i.e., stroke)
  - New onset seizure
  - Papilledema
  - Altered level of consciousness
  - Focal neurologic deficit
- Empiric therapy should include a third-generation cephalosporin and vancomycin.
- Hearing should be monitored closely after meningitis with consideration given to early cochlear implantation if bilateral severe hearing loss is accompanied by radiologic evidence of labyrinthitis ossificans.

TABLE 130.1 Recent Reported Series of Intracranial Complications of Otitis Media in Children, Adults, and Combined Groups of Children and Adults

Reference and Total Number of Patients	Patients with ICCOM	Meningitis	Epidural Abscess	Subdural Abscess/ Empyema	Brain Abscess	Lateral Sinus Thrombophlebitis or Sigmoid Sinus Thrombosis	Otitic Hydrocephalus	Other*
PEDIATRIC SERIES								
Zanettiand Nasiff,[1] 2006, *N* = 45	13	6	3	0	1	7	0	2
Migirov et al., 2005, *N* = 28 (11 children)	11	5	3	0	0	1	0	2
Leskinenand Jero, 2004, *N* = 33	1	1	1	0	0	0	0	0
Luntz et al., 2001, *N* = 223 (214 children)	19	7		1	1	6	0	5
Go et al.,[2] 2000, *N* = 118	8	1	4	6	0	0	0	0
Kaftanand Draf, 2000, *N* = 22 (3 of 22 <18 years old)	3	3	0	0	0	0	0	0
Schwagerand Carducci, 1997, *N* = 124	11 (4 patients had >1 ICCOM)	5	5	0	2	5	0	0
ADULT SERIES								
Leskinenand Jero,[3] 2005, *N* = 50	9	4 (1 death)	0	0	4	1	0	0
Migirov et al., 2005, *N* = 28 (17 adults)	17	8	2	2	5	2 (1 transverse, 1 sigmoid)	0	0
Kaftanand Draf, 2000, *N* = 22 (19 of 22 >18 years old)	19	12	0	1	5	0	0	1 (Gradenigo's syndrome)
Barry et al., 1997, *N* = 79 with otogenic meningitis	79	79	4	2	4	2	2	8
SERIES WITH COMBINED CHILDREN AND ADULTS; RESULTS NOT SEPARATED								
Seven et al., 2005, *N* = 32 with 59 ICCOMs	32	7	7	2	14	10	1	11
Penido et al.,[4] 2005, *N* = 33	33	21	1	2	26 (3 deaths)	5	0	1
Matanda et al., 2005, *N* = 343 (215 patients <20 years old)	24	12	0	0	9	2	1	0
Goldstein et al.,[5] 1998, *N* = 100 intratemporal complications of otitis media	16	2	7		1	5	7	2
Osma et al., 2000, *N* = 93, 57 with ICCOMs (58% <20 years old)	57	41	4	0	10	1	0	

*Other includes cavernous sinus thrombosis, perisinus abscess, meningocele, petrous apex suppuration, internal jugular thrombosis, cerebritis, presuppurative encephalitis, and ventriculitis. Some patients had more than one intracranial complication.
ICCOM, Intracranial complication of otitis media.

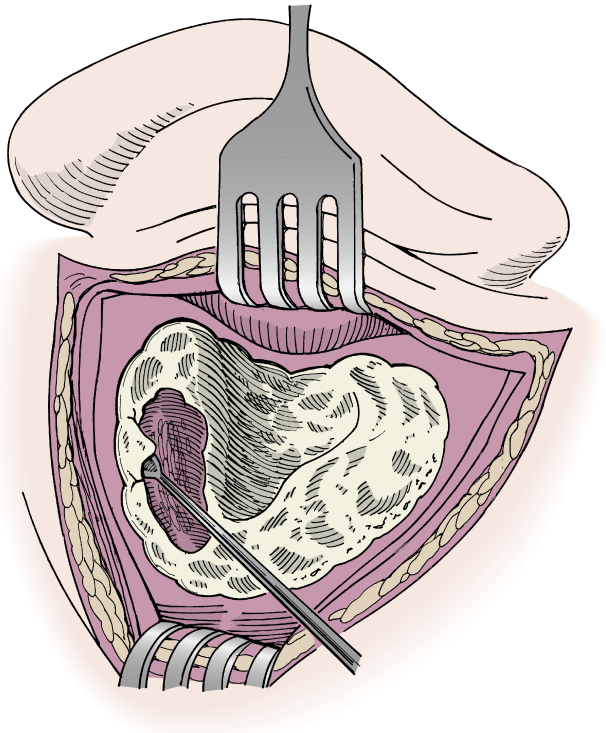

Fig. 130.2. Exposure and drainage of an epidural abscess with wide exposure of the middle fossa dura.

Surgical Technique

- Myringotomy and tube insertion are the initial management of choice.
- Close monitoring
- If the patient fails to respond to conservative management then a complete mastoidectomy should be performed when the patient is medically stable.

EPIDURAL ABSCESS

Indications and Preoperative Period

- May occur secondary to acute coalescent mastoiditis or chronic suppurative otitis media with cholesteatoma erosion
- Otogenic source less common than paranasal sinuses
- May often be asymptomatic
- Signs and symptoms:
  - Low-grade fevers
  - Otalgia
  - Malaise
  - Deep temporal headache
  - Otorrhea
  - Bulging tympanic membrane
- Diagnosis made via fine-cut CT or MRI with contrast
- Consider MR venography to rule out lateral sinus thrombosis.

Surgical Technique

- An isolated epidural abscess secondary to mastoiditis can usually be evacuated by a complete mastoidectomy (see Chapter 134), with careful unroofing of the affected bony plates to expose but not enter the dura (Fig. 130.2).
- Adequate exposure will drain the abscess.
- Excess granulation tissue should be removed with blunt dissection.
- Purulent material and granulation tissue should be sent for immediate Gram stain, culture, and sensitivity testing.
- The mastoid is then irrigated with antibiotic solution.

LATERAL SINUS THROMBOSIS

Indications and Preoperative Period

- May occur with an associated epidural or subdural abscess or otitic hydrocephalus (Fig. 130.3)[7]
- Symptoms:
  - Headache
  - Fever (classically, "picket-fence" spiking fevers)
  - Photophobia
- MRI and MR venography are considered the gold standard for diagnosis.
- IV antibiotic therapy should cover typical AOM flora but also cover gram-negative and anaerobic bacteria.

Surgical Technique

- Historically, the standard of care for lateral sinus thrombosis (LST) has been IV antibiotics and surgical intervention with or without anticoagulation.
- The surgical intervention consists of a tympanomastoidectomy with or without needle aspiration or thrombectomy (Fig. 130.4).
  - No improvement in prognosis has been noted after incising the sigmoid and removing the blood clot on recent studies.
  - Opening of the sinus plus removal of the clot is not necessary unless the sinus is grossly infected.
  - If incision and drainage and/or thrombectomy are performed, extraluminal packing of the sinus can help to control bleeding (Fig. 130.5).
- The role of postoperative anticoagulation is controversial.[8]
  - Preventing embolization and septic thrombi, possible reduction of neurologic sequelae, recanalization on follow-up imaging, and relative safety are some reasons cited by those supporting anticoagulation.
  - Some oppose routine use due to bleeding complications and evidence of recanalization without anticoagulation and recovery despite thrombus.[4]
- In cases of non-coalescent mastoiditis, a conservative approach, including immediate myringotomy, tube placement, and topical and IV antibiotics, is reasonable.
- The patient is monitored closely, and mastoidectomy and sigmoid sinus exploration are performed if the patient fails to improve.

SUBDURAL ABSCESS (EMPYEMA)

Indications and Preoperative Period

- Otitis media is a much less common source of subdural abscess than previously thought (9% in one large series).[5]
- Signs and symptoms:
  - Fever
  - Severe headache
- CNS findings:
  - Seizure
  - Somnolence
  - Eye deviation
  - Stiff neck
  - Sensory deficits
  - Hemiparesis
  - Papilledema
- High CSF pressure, pleocytosis, and increased polymorphonuclear leukocytes on LP

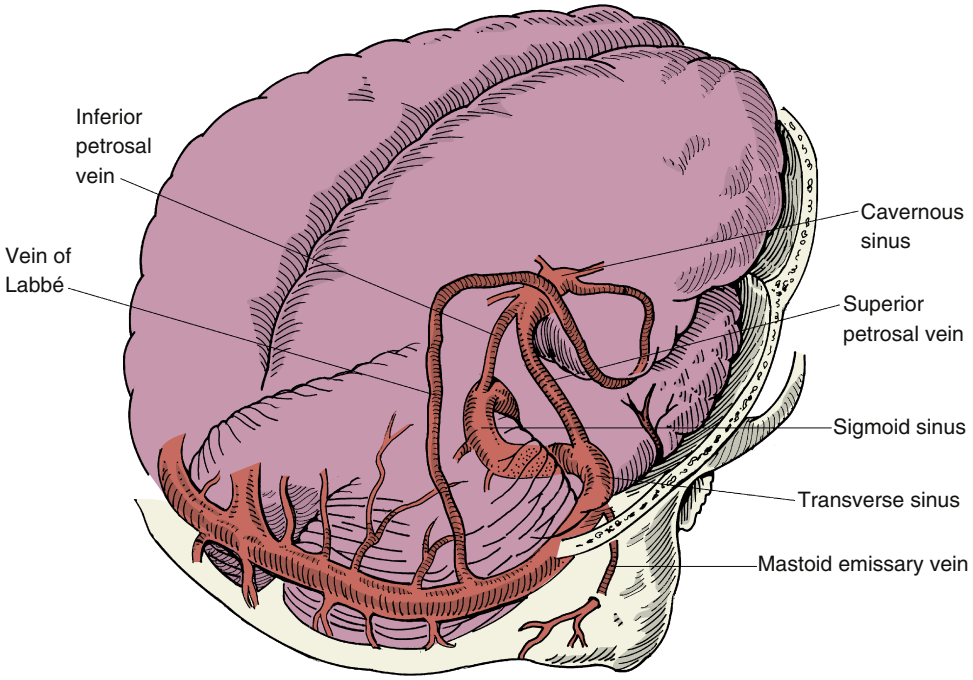

Fig. 130.3. Anatomic relationship between the dural sinuses and the temporal bone.

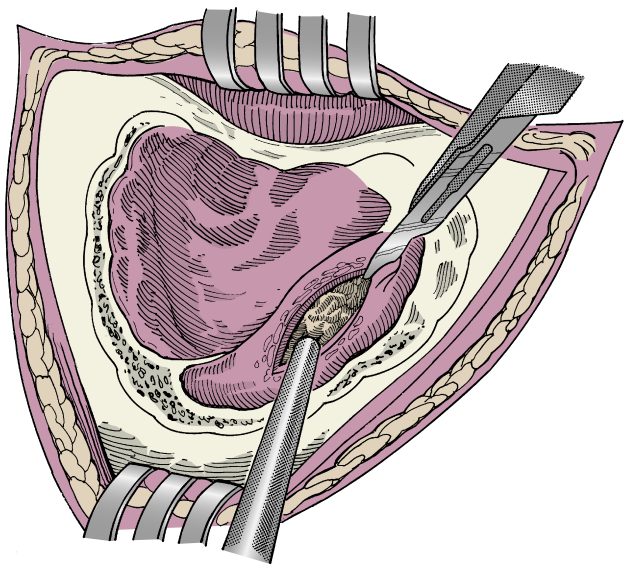

Fig. 130.4. Incision and drainage of a thrombophlebitic dural sinus.

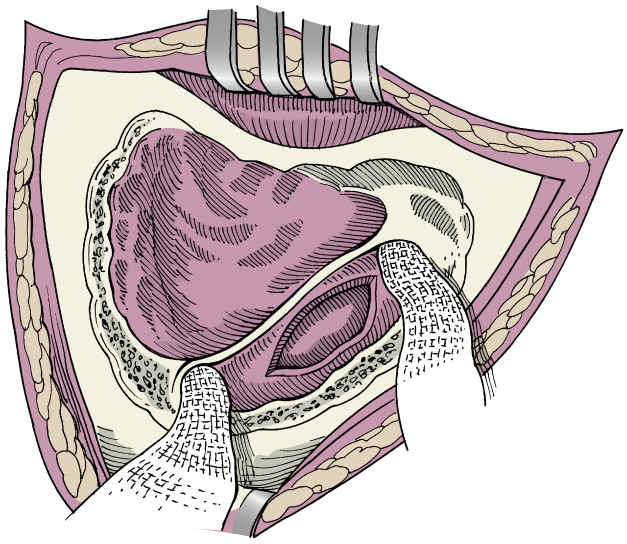

Fig. 130.5. Extraluminal packing is used to control bleeding from the dural sinus.

- CT with contrast versus diffusion-weighted MRI for diagnosis

Surgical Technique

- Subdural empyema should be emergently evacuated and the frequently accompanying increase in intracranial pressure (ICP) carefully monitored via LP, along with IV antibiotics.
- Drainage can be achieved by burr holes, craniotomy, or CT-guided aspiration, in consultation with the neurosurgical service.
- A complete mastoidectomy with removal of excess granulation tissue is also indicated in these patients.

BRAIN ABSCESS

Indications and Preoperative Period

- Much more common in developing countries
- Most commonly from an otogenic source and associated with cholesteatoma
- Temporal lobe is the most common location
- Indolent course may not include symptoms
- CNS signs:
  - Headache
  - Vomiting
  - Drowsiness
  - Seizure
  - Personality change
  - Meningismus
  - Vertigo
  - Nystagmus
  - Visual field deficits
- Papilledema, coma, and cardiovascular changes are ominous late signs.
- Mortality rates up to 40% have been reported.

- Broad-spectrum antibiotics are required.
- CT with contrast of the temporal bone and brain is diagnostic (may also consider MRI).
- Temporal bone imaging alone may miss an intracranial abscess; suspicion should prompt dedicated brain CT or MRI with contrast enhancement.

Surgical Technique

- The abscess itself must be addressed on an emergency basis before rupture, which can lead to septicemia and death.
- This is usually done by either burr holes or craniotomy by the neurosurgical team.
- After the abscess is addressed and the patient is stabilized, a mastoidectomy with removal of granulation tissue and purulent material is performed.
- Studies in the literature have described success by drainage of the abscess and treatment of the mastoid disease with a transmastoid approach.
- One study describes draining the abscess by a transmastoid approach by extending the mastoid posterior to the sigmoid, opening up the bony plate over the dura, and aspirating the contents of the abscess.
  - All of the patients were treated with long-term IV antibiotics; only one patient required further surgery to remove the residual abscess.
- Sennaroglu and Sozeri reported draining the abscess via mastoidectomy after preparing the dura with povidone-iodine, followed by irrigation and placement of drainage tubes, which are used for ongoing irrigation until the cavity shows collapse on follow-up CT.
- Antibiotics are adjusted to the results of the aspirated culture.

OTITIC HYDROCEPHALUS

Indications and Preoperative Period

- Believed to occur secondary to lateral sinus thrombosis, although the exact mechanism is unknown[9]
- Symptoms:
  - Nausea, vomiting
  - Diplopia
- Signs:
  - Papilledema
  - Ipsilateral abducens nerve palsy
- LP: High opening pressure with otherwise normal CSF findings
- MRI and MR venography will demonstrate sinus thrombosis.
- Medical management similar to lateral sinus thrombosis
- Long-term sequelae are rare, but vision loss has been reported.

Surgical Technique

- The goal is the eradication of ear disease in conjunction with lowering the ICP.
- High-dose IV antibiotics should be administered, but anticoagulants are controversial.
- The type of surgery depends on the extent of the disease.
  - Intervention ranges from only complete mastoidectomy with myringotomy and tubes to requiring drainage of perisinus abscess or removal of infected clot.
  - Consideration should be given for ligating the internal jugular vein only if symptoms do not resolve despite adequate surgical and medical intervention.
- ICP should be treated with a combination of mannitol, acetazolamide/other diuretics, and steroids.
- There is controversy as to whether these patients should or should not undergo repeated LPs.

PETROUS APICITIS/GRADENIGO'S SYNDROME

Indications and Preoperative Period

- Gradenigo's triad: suppurative otitis media, abducens paralysis, deep facial/retrobulbar pain
  - Only 42% may have the complete triad.
- The petrous apex generally communicates with mastoid air cells, providing a route of spread for infection.
- May occur with other intracranial complications
- Cavernous sinus and trigeminal ganglion may also be involved.
- CT with contrast can show bony erosion, fluid-filled opacification, and possibly abscess.
- MRI helps distinguish petrous apicitis from other lesions, such as cholesteatoma, cholesterol granuloma, and arachnoid cysts.[10]

Surgical Technique

- If a trial of IV antibiotics does not lead to the resolution of petrositis, or if imaging shows areas of coalescent bone erosion, surgical management is indicated.
- Several reports in the literature have reported detailed resolution of Gradenigo's syndrome with high-dose broad-spectrum antibiotics with or without myringotomy with tube placement.
- The petrous apex has been described as the least surgically accessible portion of the temporal bone.
- Mastoidectomy and tympanostomy tube placement may be sufficient to allow drainage of the petrous apex air cell tracts.[5]
- Surgical approaches to an inflamed petrous apex depend on the patient's hearing status and temporal bone anatomy and on the surgeon's training and include the infralabyrinthine, transcanal infracochlear, transsphenoidal, translabyrinthine or subtotal petrosectomy, and middle fossa approaches (discussed in Chapter 143).

Postoperative Care/Complications

- Postoperative complications and care following mastoidectomy are described in a previous chapter on mastoidectomy in Chapter 134.
- Monitor for CSF otorrhea/rhinorrhea, cerebral edema, seizure-increased ICP, and pneumocephalus.
- Consider intensive care unit monitoring for 24 hours postoperatively.
- Consider anticoagulation prophylaxis given prolonged bed rest and possible neurologic impairment.
- Neurosurgery and infectious disease consultation are recommended.
- Long-term IV antibiotics may be indicated.

Evidence-Based Medicine Question

What is the role of thrombectomy and anticoagulation in the management of lateral sinus thrombosis?

It is generally agreed that the initial management of lateral sinus thrombosis involves IV antibiotic therapy and tympanomastoidectomy. However, the role of surgical thrombectomy and/or postoperative anticoagulation is controversial. Manolidis[1] reported good outcomes with embolectomy or sinus resection. Ropposch et al.[2] and Sitton and Chun[3] recently showed that incising the sigmoid sinus and removing the clot had no improvement in prognosis. Regarding anticoagulation, Bradley et al.[4] showed no difference in mortality in the non-anticoagulated group versus anticoagulation. Proponents of anticoagulation suggest possibly increased recanalization rates, but this was not shown in a recent

systematic review by Wong et al.[5] In addition, although anticoagulation is relatively safe, it is not without its own morbidity as shown by Funamura et al.[6] who had a patient with intracranial hemorrhage while on anticoagulation. Overall, it is unclear whether anticoagulation or thrombectomy truly affects recanalization rates in these patients, as all of the aforementioned series are very small. Better research is necessary before a definitive conclusion can be made.

1. Manolidis S, Kutz JW Jr: Diagnosis and management of lateral sinus thrombosis. Otol Neurotol 2005, 26:1045-1051.
2. Ropposch T, Nemetz U, Braun EM, et al: Management of otogenic sigmoid sinus thrombosis. Otol Neurotol 2011, 32(7):1120-1123.
3. Sitton MS, Chun R: Pediatric otogenic lateral sinus thrombosis: role of anticoagulation and surgery. Int J Pediatr Otorhinolaryngol 2012, 76:428-432.
4. Bradley DT, Hashisaki GT, Mason JC: Otogenic sigmoid sinus thrombosis: what is the role of anticoagulation? Laryngoscope 2002, 112:1726-1729.
5. Wong B, Hickman S, Richards M, et al: Management of pediatric otogenic cerebral venous sinus thrombosis: asystematic review. Clin Otolaryngol 2015, 40;704-714.
6. Funamura JL, Nguyen AT, Diaz RC: Otogenic lateral sinus thrombosis: case series and controversies. Int J Pediatr Otorhinolaryngol 2014, 78(5):866-870.

Editorial Comment

Intracranial complications of acute and chronic otitis media have a higher incidence in the first 2 decades of life. This includes both extracranial and intracranial complications. Children remain more susceptible to otitis media likely due to lower resistance and more frequent exposure to the causative bacteria, particularly *S. pneumonia* and *H. influenza*. Persons presenting quite ill, with headaches and nuchal rigidity, are suspected as having meningitis. Prior to obtaining a needed LP, CT imaging initially should be obtained to verify the status of the intracranial space. Identifying a focal abscess warrants urgent neurosurgical consultation and drainage. Aspiration of the cavity provides fluid for Gram stain and culture.

Coalescent mastoiditis describes mucoperiosteal disease in the mastoid bone causing a breakdown of the septae or cell walls. This suggests an aggressive infection that can readily spread beyond the confines of the temporal bone. Many of the particular complications outlined in this chapter have a root source based on an infection in the mastoid. Evacuation of infected mucosa and opacified air cells along with middle ear ventilation with tympanostomy tubes are core to reversing the disease.

Barry Hirsch

Access the review questions and additional sources list online at http://www.expertconsult.com

REFERENCES

1. Zanetti D, Nassif N. Indications for surgery in acute mastoiditis and their complications in children. Int J Pediatr Otorhinolaryngol 2006;70:1175–1182.
2. Go C, Bernstein JM, de Jong AL, et al. Intracranial complications of acute mastoiditis. Int J Pediatr Otorhinolaryngol 2000;52:143–148.
3. Leskinen K, Jero J. Acute complications of otitis media in adults. Clin Otolaryngol 2005;30:511–516.
4. Penido NDO, Borin A, Iha LCN, et al. Intracranial complications of otitis media: 15 years of experience in 33 patients. Otolaryngol Head Neck Surg 2005;132:37–42.
5. Goldstein NA, Casselbrant ML, Bluestone CD, et al. Intratemporal complications of acute otitis media in infants and children. Otolaryngol Head Neck Surg 1998;119:444–454.
6. Thigpen MC, Whitney CG, Messonnier NE, et al. Bacterial meningitis in the United States, 1998-2007. Emerging Infections Programs Network. N Engl J Med 2011;364(21):2016–2025.
7. Syms MJ, Tsai PD, Holtel MR. Management of lateral sinus thrombosis. Laryngoscope 1999;109:1616–1620.
8. Bradley DT, Hashisaki GT, Mason JC. Otogenic sigmoid sinus thrombosis: what is the role of anticoagulation? Laryngoscope 2002;112:1726–1729.
9. Kuczkowski J, Dubaniewicz-Wybieralska M, Przewozny T, et al. Otitic hydrocephalus associated with lateral sinus thrombosis and acute mastoiditis in children. Int J Pediatr Otorhinolaryngol 2006;70:1817–1823.
10. Singh ML, Rejee R, Varghese AM. Gradenigo's syndrome: findings on computed tomography and magnetic resonance imaging. J Postgrad Med 2002;48:314–316.

REVIEW QUESTIONS

1. A 40-year-old male with a chronic draining left ear presents to your office with an intense headache and difficulty with abducting his left eye, and he is otherwise stable. How would you manage this patient?
   a. IV antibiotics
   b. IV antibiotics with myringotomy and tube placement
   c. CT only
   d. MRI only
   e. CT and MRI

2. A 7-month-old male with meningitis was recently discharged from the hospital. His parents noticed that he was not responding to sounds appropriately, and he previously passed his newborn hearing screen. An outpatient hearing test showed bilateral severe to profound hearing loss. An MRI was also ordered, which showed fibrosis in the cochlea. How would you manage this patient?
   a. Stat CT scan
   b. Repeat CT scan in 1 month.
   c. Repeat MRI in 1 month.
   d. Discuss hearing aids.
   e. Discuss a cochlear implant.

3. A 65-year-old male presents with high fever, headache, and nuchal rigidity. A CT scan is sometimes indicated prior to lumbar puncture in patients with suspected meningitis due to the risk of cerebral herniation. Current practice guidelines suggest a CT scan prior to a lumbar puncture in all of the following instances, except
   a. New onset seizure
   b. Papilledema
   c. Focal neurologic deficit
   d. Chronic obstructive pulmonary disease
   e. Immunocompromised state

4. Which intracranial complication is thought to be the cause of otitic hydrocephalus?
   a. Lateral sinus thrombosis
   b. Petrous apicitis
   c. Epidural abscess
   d. Subdural abscess
   e. Brain abscess

ADDITIONAL SOURCES

Alaani A, Coulson C, McDermott AL, et al. Transtemporal approach to otogenic brain abscesses. Acta Otolaryngo 2010;l130(11):1214–1219.

Barry B, Delattre J, Vie F, et al. Otogenic intracranial infections in adults. Laryngoscope 1997;109:483–487.

Choi J, Choi JI, Kim SD. Management of otogenic brain abscess using the transmastoid approach. J Korean Neurosurg Soc 2014;55(3):178–180.

Harker LA, Shelton C. Complications of temporal bone infections. In: Cummings CW, Flint PW, Haughey BH, et al., editors. Cummings' Otolaryngology Head and Neck Surgery. 4th ed. St Louis, MO: Elsevier Mosby; 2005. p. 3013–3039.

Hippargekar PM, Shinde AD. Trans-mastoid needle aspiration for otogenic brain abscesses. J Laryngol Otol 2003;117:422–423.

Kaftan H, Draf W. Otogene endokranielle Komplikationen—trotz aller Fortschritte weiterhin ein ernst zu nehmendes problem. Laryngorhinootologie 2000;79:609–615.

Kempf HG, Wiel J, Issing PR, et al. Otogenic brain abscess. Laryngorhinootologie 1998;77:462–466.

Leskinen K, Jero J. Complications of acute otitis media in children in southern Finland. Int J Pediatr Otorhinolaryngol 2004;68:317–324.

Luntz M, Brodskky A, Nusem J, et al. Acute mastoiditis—the antibiotic era: a multicenter study. Int J Pediatr Otorhinolaryngol 2001;57:1–9.

Matanda RN, Muyunga KC, Sabue MJ, et al. Chronic suppurative otitis media and related complications at the University Clinic of Kinshasa. B-ENT 2005;2:57–62.

Migirov L, Duvdevani S, Kronenberg J. Otogenic intracranial complications: a review of 28 cases. Acta Otolaryngol 2005;125:819–822.

Nathoo N, Nadvi SS, van Dellen JR, et al. Intracranial subdural empyemas in the era of computed tomography: a review of 699 cases. Neurosurgery 1999;44:529–535.

Osma U, Cureoglu S, Hosoglu S. The complications of chronic otitis media: report of 93 cases. J Laryngol Otol 2000;114:97–100.

Schwager K, Carducci F. Endokranielle Komplikationen der akuten und chronischen otitis media bei Kindern und Jugenlichen. Laryngorhinootologie 1997;76:335–340.

Seven H, Coskun BU, Calis AB, et al. Intracranial abscesses associated with chronic suppurative otitis media. Eur Arch Otorhinolaryngol 2005;262:847–851.

131 Myringoplasty and Tympanoplasty

Rebecca Chiffer, Douglas Chen

INTRODUCTION

Myringoplasty and tympanoplasty are surgical procedures designed to address pathology of the tympanic membrane and the middle ear, respectively. Both procedures restore the integrity of a perforated tympanic membrane, while tympanoplasty also addresses pathology in the middle ear, such as chronic infection, cholesteatoma, or ossicular chain problems. This most often implies and requires raising a tympanomeatal flap to facilitate middle ear manipulation. Zollner[1] and Wullstein[2] provided a classification of tympanoplasty based on the type of ossicular chain reconstruction required.

Acute tympanic membrane perforation or laceration may occur from a variety of causes. Local trauma, such as a slap on the ear, a cotton-tipped applicator inserted too far in the external canal, or barotrauma can cause a perforation of the tympanic membrane. Water compression, either from diving, falling onto a body of water, a wave hitting the ear, or even forceful irrigation during cerumen removal can also cause trauma. After acute trauma, the tympanic membrane may heal spontaneously or may require myringoplasty only. In contrast, patients requiring tympanoplasty often have a long-standing history of hearing loss, tympanic membrane perforation, and/or chronic otitis media with or without otorrhea.

Tympanoplasty and myringoplasty aim to eliminate recurrent disease, provide a dry ear canal and middle ear space with an intact tympanic membrane, and maintain or improve hearing. Achieving an intact tympanic membrane eliminates the need for patients to maintain strict water precautions.

KEY OPERATIVE LEARNING POINTS

- The most important factor in the success of tympanoplasty, regardless of method, is the skill and precision of the surgeon.
- Anticipate and inform patients who may not achieve successful tympanoplasty results, including those with multiple failed previous procedures, persistent eustachian tube dysfunction, severe contralateral ear disease, or abnormalities of the soft palate.
- In any technique, rimming the edges of the perforation is essential to ensure adequate healing.
- Cartilage butterfly grafts avoid canal incisions, though these must be precisely sized to the perforation to ensure a secure fit.
- Leaving remnants of squamous epithelium medial to the graft, or tucked edges of canal skin, can result in intratympanic or canal cholesteatoma.
- Inadequate enlargement of the bony canal, and/or placement of a lateral graft onto the anterior or inferior canal wall, creates a high risk of blunting.
- Injury to the chorda tympani nerve results in disturbance in taste noticeable to the patient.
- Diligent postoperative care is necessary to recognize and treat early or late complications.

PREOPERATIVE PERIOD

History

1. History of present illness
   a. Hearing loss: Sudden versus gradual
   b. Drainage: Chronic or recurrent
   c. Trauma
   d. Pain should raise concern for other processes in the head and neck and prompt a thorough evaluation.
   e. Vertigo should be thoroughly investigated prior to surgery to avoid operating on an ear with an ongoing vestibulopathy.
2. Past medical and surgical history
   a. Chronic or recurrent ear infections
   b. Previous ear surgeries, including PE tubes
   c. History of cleft palate surgery should raise concern for Eustachian tube dysfunction and chronic or recurrent infections.
3. Medications
   a. Anticoagulants need to be addressed prior to surgery and stopped if possible.
4. Allergies
   a. Severe seasonal allergies should raise concern for Eustachian tube dysfunction.
5. Social history
   a. Smoking can lead to complications with general anesthesia and wound healing.

Physical Examination

Physical examination with a microscope enables thorough inspection of the canal and middle ear space.

1. Problematic ear
   a. Size of perforation: Small, near-total, total
   b. Location of perforation: Central versus marginal
      1) Marginal perforations with a "trail sign," or keratin migrating from the edge, suggest squamous epithelium in the middle ear.
   c. Draining versus dry
   d. Evaluate status of middle ear mucosa, if possible: Cholesteatoma, mucosal hypertrophy, or extensive granulation tissue suggest the need for concurrent mastoidectomy.[3]
2. Contralateral ear
   a. Look for signs of previous surgery and/or chronic Eustachian tube dysfunction, such as retraction of the tympanic membrane and negative middle ear pressure (atelectasis), otitis media with effusion, and/or tympanosclerosis, which may indicate chronic infections.
   b. Evidence of otitis media with effusion or negative middle ear pressure (atelectasis) in the contralateral ear demonstrated to be poor prognostic findings in a study of pediatric patients by Collins et al.,[4] and surgery in these children was less successful.

Audiogram

Not all tympanic membrane perforations are accompanied by conductive hearing loss. Small perforations may be associated with normal hearing, whereas a near-total perforation may cause a 35- to 40-dB conductive hearing loss. This amount of hearing loss in the setting of a small perforation should raise concern for a disrupted or fixed ossicular chain. The potential need for ossicular chain reconstruction must be anticipated prior to surgery.

Patients with mixed hearing loss require a different approach. Although surgery may close the air-bone gap, a sensorineural component may still require amplification, and surgery may not be in the patient's best interest. If, however, a severe mixed loss precludes adequate gain and comfort from a hearing aid, surgical correction of the conductive component may better facilitate aural rehabilitation.

Imaging

1. Computed tomography (CT) scan: Not routinely necessary prior to tympanoplasty or myringoplasty, unless evaluating for cholesteatoma and/or concurrent mastoid disease
2. Magnetic resonance imaging (MRI): Not routinely necessary prior to tympanoplasty or myringoplasty; however, should be included if patient complains of chronic imbalance or vertigo or for evaluation of asymmetric sensorineural hearing loss

Indications

1. Repair of tympanic membrane (TM) perforation to lift water restrictions
2. Prevention of recurrent otorrhea and/or recurrent ear infections
3. Attempt to improve hearing

Contraindications

1. Extreme caution must be exercised if planning to operate on an only-hearing ear. Unless significant active disease exists, despite maximal medical therapy, aural amplification should be recommended.
2. Avoid operating on an ear with an active vestibulopathy.

Preoperative Preparation

1. An attempt should be made to achieve a dry ear prior to surgery with otic drops and/or systemic antibiotics.
2. Preoperative medical clearance prior to anesthesia is recommended for all patients.
3. Preoperative testing (laboratory tests, electrocardiogram, chest radiograph) per hospital guidelines
4. Informed consent
   a. Risks: Worsening of hearing or complete hearing loss, vertigo, temporary or permanent changes in taste due to disruption of the chorda tympani nerve, facial paresis or paralysis, infection, failure of the graft to heal causing persistent or recurrent perforation, and/or numbness of the superior auricle if undergoing a postauricular approach
5. Review of all previous otologic operative reports
   a. Reminder: After several procedures, local tissue for grafting may not be readily available and alternative sources should be considered, such as perichondrium, periosteum, or even tissue from the contralateral ear.
6. Determine if the patient will be compliant and return for postoperative care.

OPERATIVE PERIOD

Anesthesia

1. Sedation: Intravenous (IV) sedation with local anesthesia is an option for uncomplicated tympanoplasty or myringoplasty with limited dissection, as long as the patient is cooperative and willing to remain immobile.

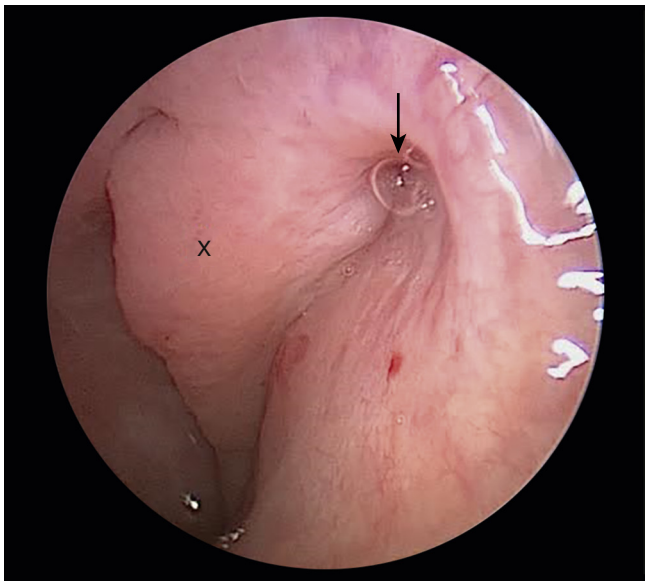

Fig. 131.1. With a Lempert speculum, local anesthetic is injected in a four-quadrant fashion into the external auditory meatus. The needle tip is placed just lateral to the bone-cartilage junction, and the solution is infiltrated until the skin blanches. *(Redrawn from Bluestone CD, Stool S: Atlas of Pediatric Otolaryngology, 3rd ed: Philadelphia, PA: WB Saunders; 1996.)*

2. General anesthesia: We perform the majority of our cases under general endotracheal anesthesia to ensure that the patient remains still for the entire procedure.
3. Local anesthesia: Four-quadrant external canal block injected at the bony-cartilaginous junction with 1% to 2% lidocaine with 1:100,000 epinephrine (Fig. 131.1). Additional injection behind the ear should be infiltrated for harvesting fascia or a planned postauricular approach.

Positioning

- Bed turned 180 degrees with feet toward anesthesia
- Supine with head turned to the contralateral side

Perioperative Antibiotic Prophylaxis

- Generally not indicated for routine tympanoplasty or myringoplasty
- For grossly infected ears or if a prosthesis will be placed, one dose of Ancef, or clindamycin if the patient is allergic to penicillin, may be given.

Monitoring

- We use facial nerve monitoring for nearly all otologic cases being performed under general anesthesia; however, nerve monitoring is elective and not considered the standard of care for myringoplasty or tympanoplasty.

Instruments and Equipment to Have Available

- Routine middle ear instrument set
- Ossicular prostheses if ossicular reconstruction is planned
- High-speed drill if a lateral graft for canaloplasty and/or mastoidectomy is planned

Key Anatomic Landmarks

- Temporal bone anatomy
  - Tympanomastoid and tympanosquamous suture lines
  - Linea temporalis
  - Bony-cartilaginous junction of the external auditory canal
- Tympanic membrane components
  - Pars tensa and pars flaccida
  - Outer epithelial layer
  - Middle fibrous layer
  - Inner mucosal layer
  - Fibrous and bony annulus
- Ossicles
  - Malleus: Head, neck, manubrium (handle), lateral process, anterior process
  - Incus: Short and long processes, body
  - Stapes: Capitulum, anterior and posterior crura, footplate
- Facial Nerve Anatomy
  - Tympanic and mastoid segments

Prerequisite Skills

- Surgeons should be proficient at raising tympanomeatal flaps, harvesting cartilage grafts, and precise middle ear dissection techniques.

Operative Risks

- Worsening of hearing or complete hearing loss
- Tinnitus
- Vertigo, usually temporary
- Taste disturbance due to injury to the chorda tympani nerve
- Facial paresis or paralysis: Allow local anesthesia to wear off before proceeding with further testing and/or exploration.
- Graft failure, causing persistent perforation or recurrent middle ear infections
- Infection of the skin incision

Surgical Technique

Surgical technique for tympanic membrane repair can be categorized as inlay, underlay (medial), and overlay (lateral) procedures. All of these techniques are successful in experienced hands. Inlay or medial grafts are generally chosen for patients with infrequent otorrhea, or for small nonmarginal perforations, or when there is minimal middle ear disease. Lateral grafts are preferred in cases of prior failed surgeries, total or near-total perforations, or in patients with severely diseased tympanic membranes with myringosclerotic plaques or remnants that must be resected prior to reconstruction.

Myringoplasty by definition addresses only the tympanic membrane, whereas tympanoplasty incorporates inspection of the middle ear and reconstruction of the ossicular chain when necessary. If limited mobility of the lateral chain and/or fixation of the incus-stapes complex is noted, then separation of the incudostapedial joint or further inspection for malleal head fixation may be necessary. Other common pathologic processes found in the middle ear include:

- Granulation tissue and hyperplastic mucosa
  - Require reconstruction of an aerated middle ear space and assessment of Eustachian tube patency, with a need for possible mastoidectomy
- Cholesteatoma
  - Requires complete and meticulous removal, with a need for possible mastoidectomy

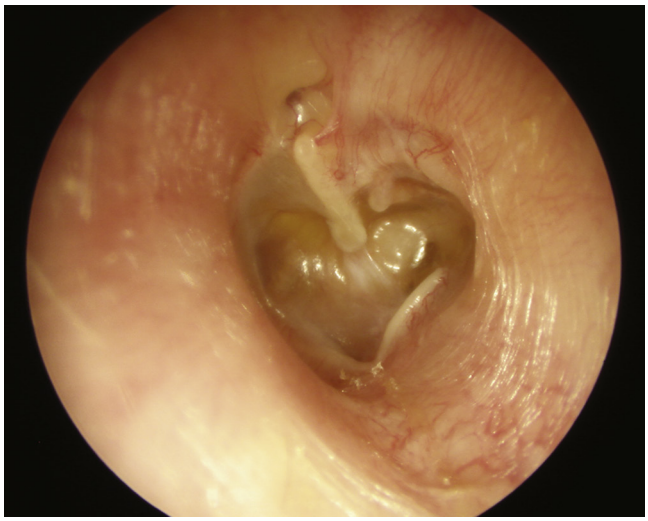

Fig. 131.2. The edges of a fresh stellate perforation are everted from the medial surface of the tympanic membrane. When squamous epithelium is no longer present in the middle ear, the edges are reapproximated.

- Tympanosclerosis
  - A brittle chalk-like plaque found within the tympanic membrane, the ossicles, and on the medial wall of the middle ear. Sclerosis should be removed prior to tympanic membrane reconstruction if it is restricting the mobility of the TM.

Ossicular chain reconstruction and mastoidectomy details can also be found in Chapters 132 and 134, respectively.

Myringoplasty

- For small or acute traumatic tympanic membrane perforations or lacerations:
  - Unfold the edges of the TM to remove squamous epithelium from the medial surface (Fig. 131.2).
  - Place small pieces of Gelfoam soaked in ciprofloxacin solution, with or without dexamethasone, medial to the laceration or perforation.
  - Place a cigarette paper patch, Steri-Strip, or silk patch on the lateral surface of the TM (Fig. 131.3).
- For small chronic perforations:
  - Apply topical phenol or trichloroacetic acid to the edges of the perforation with a cotton-tipped or phenol applicator.
  - Freshen the margins of the perforation with a sharp pick to remove any squamous epithelium that may have migrated under the medial surface of the TM. This also stimulates bleeding from the local vascular supply (Fig. 131.4).
  - Apply a patch to the lateral surface of the tympanic membrane.
- If paper patching has failed, small central perforations may be repaired using autogenous tissue:
  - Prepare the perforation as noted previously; then use adipose tissue from the earlobe to dumb-bell through the perforation. Alternatively, use compressed and dehydrated loose areolar tissue or fascia from the postauricular region.
- For medial myringoplasty grafts, place Gelfoam through the perforation into the middle ear space to act as a bolster. Then place a fascia graft medial to the perforation and place Surgicel or Gelfoam lateral to the grafted perforation to further secure the graft. Fill the medial external canal with additional Gelfoam (Fig. 131.5).



Fig. 131.3. The edges of the stellate perforation are approximated and supported with a cigarette paper patch or a Steri-Strip.

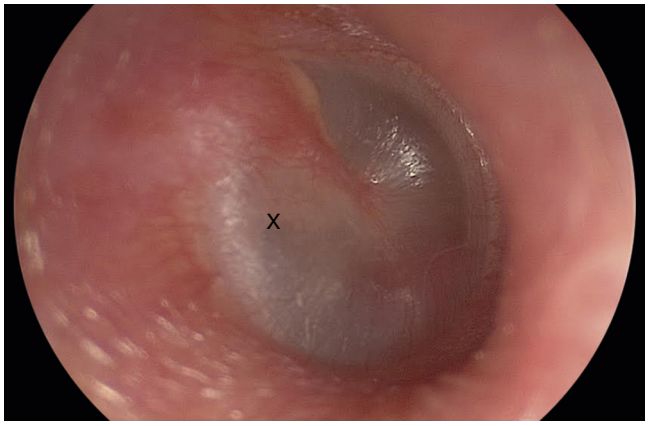

Fig. 131.4. The edge of the perforation is circumferentially freshened to remove epithelium from the medial margin and promote local bleeding. The *inset* emphasizes that the medial edge of the perforation must be removed to eliminate squamous epithelium from the middle ear.

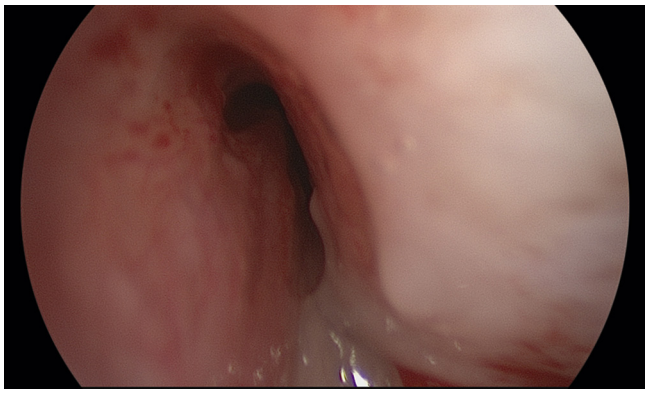

Fig. 131.5. A, Myringoplasty of the right tympanic membrane with a posteroinferior perforation. The edges of the perforation are freshened, Gelfoam is placed in the middle ear, and an areolar or compressed adipose tissue graft *(stippled area)* is placed through the perforation, positioned medial to the tympanic membrane, and supported by the Gelfoam. **B,** Gelfoam supports the graft on the medial surface of the tympanic membrane.

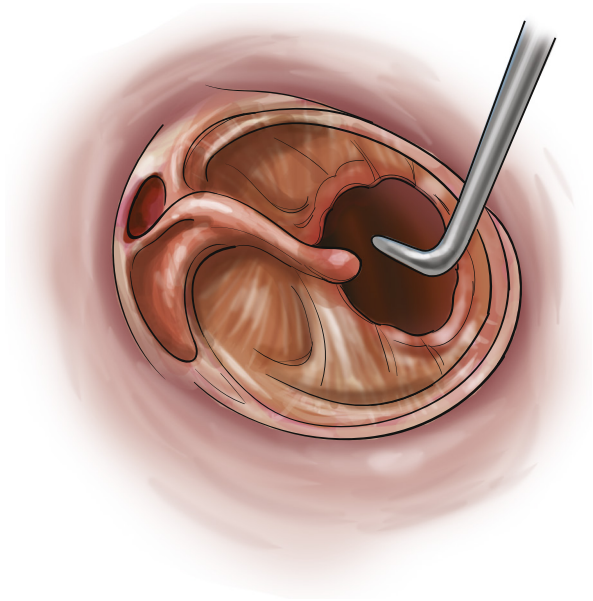

Fig. 131.6. A right-angled hook is used to estimate the size of the perforation. Note the exposed malleus and tympanosclerosis serve to interlock the graft. *(Adapted from Eavey RD: Inlay tympanoplasty: the cartilage butterfly technique. Laryngoscope 1998.108:657-661)*

Tympanoplasty

1. **Cartilage inlay technique (Videos 131.1 and 131.2)**

- Described in 1998 by Eavey, termed the cartilage butterfly graft for use in small to medium tympanic membrane perforations.[5] This is a transcanal approach with specific advantages:
  - Less postoperative pain since canal incisions are avoided
  - Immediate hearing improvement since canal packing is avoided
  - Shorter operative times, which generally translates to lower expense
- In order for this technique to be successful, all edges of the perforation must be visualized through the canal, either directly using an operating microscope or indirectly using a middle ear endoscope.
- Note, although Eavey's original article describes this technique as a tympanoplasty, since this procedure is done through the TM and a tympanomeatal flap is not raised, some experts consider this a myringoplasty technique.
- Positioning and local anesthesia are the same as described previously. Infiltrate the tragus with local anesthesia as well.
- Rim the perforation with a curved pick to remove a thin layer of squamous epithelium and freshen the edges for the graft. This step may slightly enlarge the perforation; be careful not to enlarge it beyond transcanal visualization.
- Precisely measure the perforation size with a right-angled instrument or a round knife (Fig. 131.6).
- Harvest tragal cartilage (Video 131.3):



Fig. 131.7. Tragal cartilage is harvested with perichondrium preserved on one or both surfaces. The graft size and shape are reproduced using the same right-angled hook previously used to measure the perforation but deliberately exaggerated by 1 to 2 mm. A blade scores the entire cartilage edge circumferentially, and the edges curl apart, creating an appearance similar to butterfly wings. *(Adapted from Eavey RD: Inlay tympanoplasty: the cartilage butterfly technique. Laryngoscope 1998.108:657-661)*

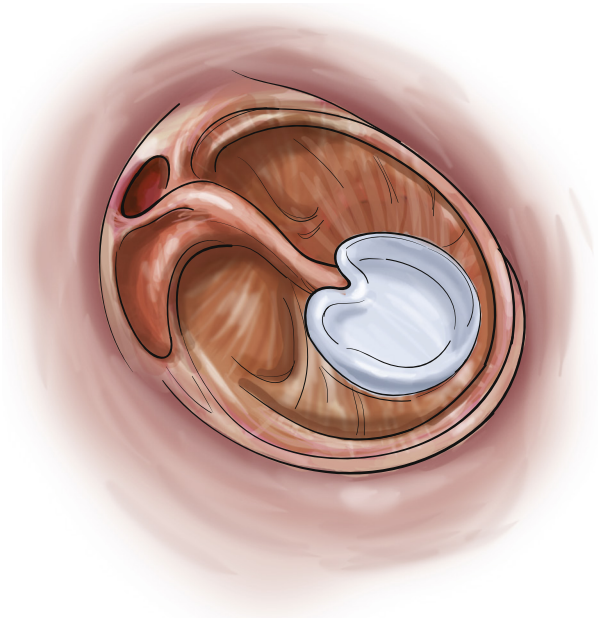

Fig. 131.8. The graft in place viewed transcanal with one edge elevated for purposes of illustration. *(From Eavey RD: Inlay tympanoplasty: the cartilage butterfly technique. Laryngoscope 108:660, 1998.)*

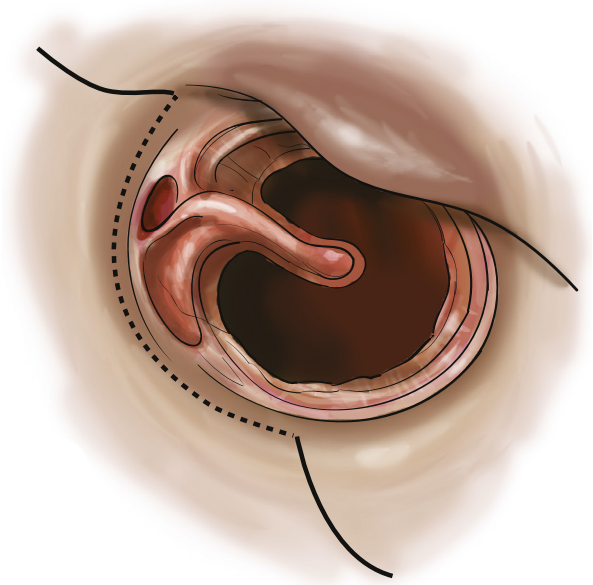

Fig. 131.9. Vascular strip incisions are made along the tympanomastoid and tympanosquamous suture lines. *(From Fayad JN, Sheehy JL: Tympanoplasty—outer surface grafting technique. In Brackmann DE [ed]: Otologic Surgery, 3rd ed. Philadelphia, PA: Saunders; 2010, p. 121.)*

- Make an incision in the posteromedial aspect of the tragus with a no. 15 blade, making sure to incise through the skin, soft tissue, and cartilage in one motion. This ensures a clean edge and preserves the tragal cartilage dome for cosmesis. Dissect the cartilage free from the soft tissue and remove using a sharp scissor. Perichondrium is left on one or both sides of the cartilage graft. Close the incision with 1 to 2 interrupted plain gut sutures.

- Size the cartilage:
  - Cut the cartilage 1 to 2 mm larger than the perforation to allow for the trough. Use the same instrument that was used to size the perforation to size the cartilage.
  - Cut the cartilage to the exact shape of the perforation. If the perforation is oval, for example, then the graft should also be oval.
  - Sizing the cartilage is an important step; a graft too large will not snap into the perforation, whereas a graft too small will risk its falling into the middle ear.
- Cut a trough:
  - Use a no. 15 or curved beaver blade to cut a 2-mm deep circumferential trough into the edge of the cartilage, being sure to keep the flanges equal width the entire way around the graft (Fig. 131.7).
- Introduce the cartilage graft through the canal and carefully place into the perforation such that one flange is medial to the rim of the perforation and the other flange, with perichondrium, is lateral (Fig. 131.8).
- Check all edges to ensure that the medial flange is medial to the drum remnant in all locations, such that when the surgeon gently presses on the center of the cartilage graft, then entire drum moves.
- Slight variations to this technique have been described for large or marginal perforations.

2. Lateral grafting technique[6] (Video 131.4)

- Position as described previously and shave the hair 1 to 2 cm superior and posterior to the auricle. Prep and drape in usual sterile fashion and inject local anesthesia as described previously. Infiltrate the postauricular region as well.
- Under the operating microscope, rinse excess betadine and local anesthetic from the canal and middle ear, and create transmeatal vascular strip incisions along the tympanomastoid and tympanosquamous suture lines. (Fig. 131.9).
- A semilunar incision connecting the vascular strip incisions can be made, if the surgeon prefers, immediately lateral to the annulus. We advocate making only the vascular strip incisions, therefore allowing the lateral epithelial layer of the tympanic membrane to be elevated off of the TM remnant with the vascular strip.
- Make a postauricular skin incision several millimeters posterior to the postauricular crease to allow for proper skin closure at the end of the procedure. The inferior extent of the incision is just inferior to the lobule; always be careful not to extend beyond the mastoid tip and risk injury to the facial nerve.

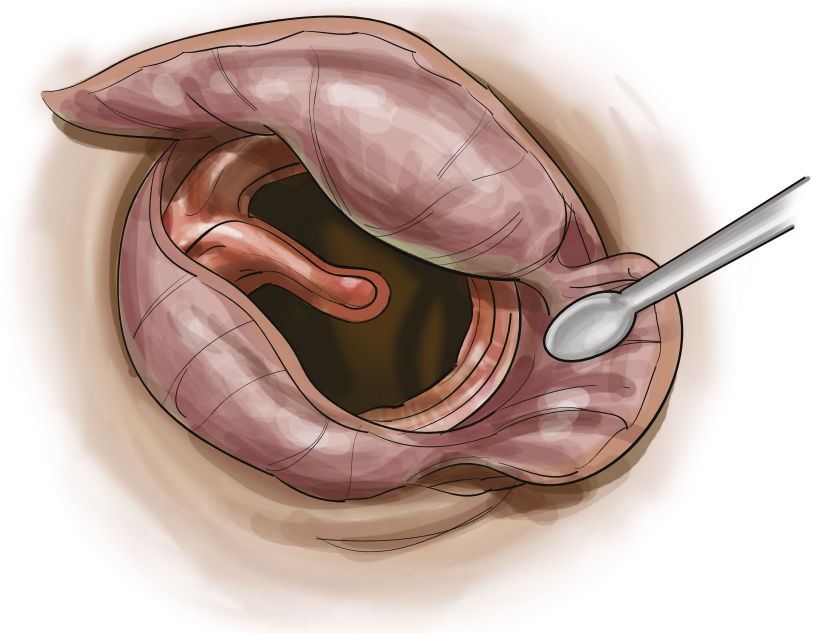

Fig. 131.10. The periosteum and canal skin are elevated from medial to lateral starting at the annular ligament. *(From Fayad JN, Sheehy JL: Tympanoplasty—outer surface grafting technique. In Brackmann DE [ed]: Otologic Surgery, 3rd ed. Philadelphia, PA: Saunders; 2010, p. 123.)*

- Continue soft tissue dissection medially through the subcutaneous tissue with either a knife or electrocautery and anteriorly in the plane of the loose areolar tissue overlying the temporalis fascia until the posterior canal skin is several millimeters thick. Place a self-retaining retractor to facilitate exposure and hemostasis.
- Harvest temporalis fascia:
  - Make a 2-cm incision through the fascia, but not through muscle, at the inferior extent of the temporalis. Use a Freer elevator to elevate the fascia off the underlying muscle; then cut a 2 × 2 cm piece of true fascia to use for grafting.
  - Alternatively, the loose areolar tissue (fool's fascia) overlying the true fascia may be used as graft material if it is sufficiently thick and well defined.
  - Immediately spread the fascia on a cutting block and clean off any remaining muscle or adipose tissue; then press the fascia and allow it to dry under an operating lamp.
- Make periosteal incisions along the linea temporalis from the ear canal, anteriorly, to the skin incision, posteriorly, then carry the periosteal incision inferiorly, following the skin incision to create the shape of a "7" or a "T."
- Elevate the periosteal flap and place it within the self-retaining retractor with the auricle.
- Under the operating microscope, complete the elevation of the vascular strip with a Freer elevator. Reflect the vascular strip out of the ear canal and place it within the self-retaining retractor.
- Elevate the remaining canal skin and periosteum in a medial to lateral direction using a large round knife, starting at the annulus and elevating laterally to the bony-cartilaginous junction (Fig. 131.10). The canal skin is kept attached at the bony-cartilaginous junction and gently folded laterally out of the canal. In Sheehy's classic description, the outer squamous layer of the tympanic membrane remnant is elevated with the vascular strip; however, if this layer remains attached, it must be removed and discarded separately, either before or after enlarging the bony canal.
- Enlarge the bony canal with a size 3 cutting bur, followed by a size 2 diamond bur, along with continuous suction irrigation to remove the anterior and inferior bony canal bulges (Fig. 131.11).
  - It is very important to enlarge the canal medially and laterally enough to visualize the entire circumference of the annulus. Opening the anterior acute angle also helps prevent postoperative blunting. Care must be taken when drilling posteriorly to avoid the facial nerve and anteriorly to avoid drilling into the temporomandibular joint.

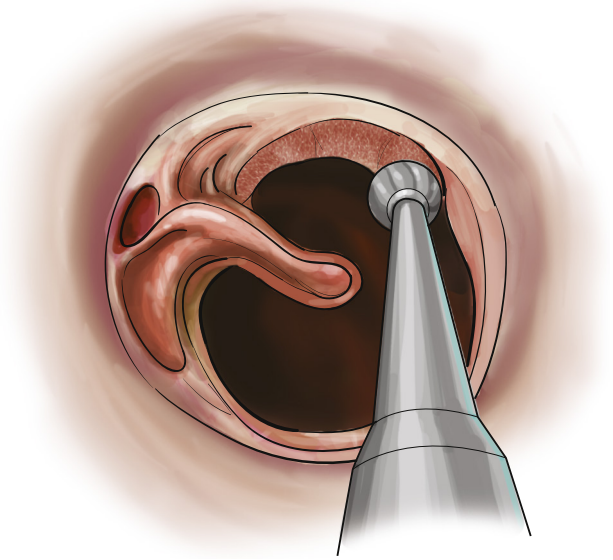

Fig. 131.11. A drill and continuous suction-irrigation are used to enlarge the bony canal and remove the anterior and inferior canal wall bulges. *(From Fayad JN, Sheehy JL. Tympanoplasty—outer surface grafting technique. In Brackmann DE [ed]: Otologic Surgery, 3rd ed. Philadelphia, PA: Saunders; 2010, p. 123.)*

- Continue de-epithelialization:
  - Begin anteriorly with a round knife placed along the bony annulus and drum remnant, and scrape the squamous epithelium away circumferentially superiorly and inferiorly, leaving the annular ligament and middle fibrous layer of the drum remnant intact.
  - Remove squamous epithelium along the rim of the perforation with a small cup forceps.
  - Pay close attention to the de-epithelialization process, since any trapped skin that remains medial to the laterally placed graft is at risk of developing into a middle ear or intratympanic cholesteatoma.
- For a total or near-total perforation, or if the fascia graft is unusually thin, fill the middle ear with small Gelfoam pledgets to bolster the graft.
- For large perforations, the graft will be placed medial to the manubrium of the malleus. For small perforations in which the drum remnant surrounds the manubrium, either the surgeon can separate the remnant from the manubrium, or the graft can be placed lateral to the manubrium in a "lateral patch" technique.
- Trim the dehydrated fascia graft to an oval shape, measuring approximately 1.3 × 1.5 cm, and cut a slit into the graft at the 12 o'clock position to allow for placement medial to the malleus handle (Fig. 131.12).
- Dip the graft in saline just prior to insertion, then place the graft lateral to the annulus and de-epithelialized TM remnant (Fig. 131.13).
- In the presence of a perforation surrounding the malleus handle, tuck the slit medial to the exposed umbo and manubrium; then bring the edges of the fascial slit laterally to overlap each other, or alternatively, fold the anterior flap posteriorly over the remaining malleus (Fig. 131.14). Sheehy describes placing the graft such that the apex of the slit comes into contact with the tensor tendon.
- Place the remaining fascia along the annulus edge anteriorly and inferiorly, paying close attention to keep the graft off the bony canal, as this will cause postoperative blunting. Any excess graft is brought onto the posterior canal wall.
- If the malleus is absent, Sheehy describes an alternate technique in which two slits are cut into the fascia in order to create a fascial flap that can be tucked under the scutum and into the epitympanum. The remaining lateral fascial flaps are then swung into position to overlap the superior aspect of the graft and create a secure seal over the middle ear (Figs. 131.15 and 16).
- Once the graft is in good position, carefully unfold and replace the canal skin onto the bony canal (Fig. 131.17). Care must be taken to ensure that the edges of the epithelium are not folded under, as this can cause postoperative epithelial cysts.
- Place a dry, rolled up (cigar-shaped) piece of Gelfoam into the anterior sulcus. Alternatively, place a properly sized piece of thick Silastic sheeting lateral to the graft to keep it in good position during the healing process. Lay Gelfoam pieces onto the graft or Silastic.
- Release the self-retaining retractors and replace the vascular strip to its posterior-superior position along the bony canal. We recommend then placing one suture to close the postauricular periosteal flap and stabilize the auricle.
- Examine the vascular strip transmeatally using a Lempert speculum to ensure that it was replaced to its original position and all epithelial edges are everted.
- Fill the ear canal with Gelfoam packing and place a cotton ball in the outer meatus.
- Close the periosteal flap with interrupted absorbable sutures, and close the skin incision in layers with absorbable sutures followed by skin glue. A mastoid dressing is applied for 24 hours.

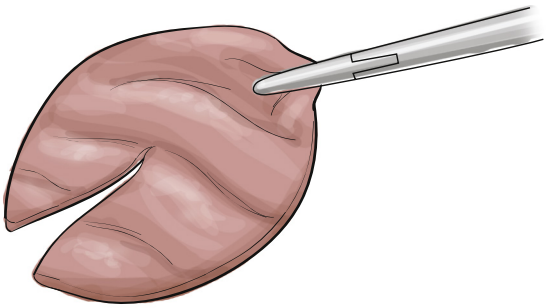

Fig. 131.12. The dehydrated fascia is trimmed to an oval shape, and a slit is cut to allow for placement medial to the manubrium. *(From Fayad JN, Sheehy JL. Tympanoplasty—outer surface grafting technique. In Brackmann DE [ed]: Otologic Surgery, 3rd ed. Philadelphia, PA: Saunders; 2010, p. 123.)*

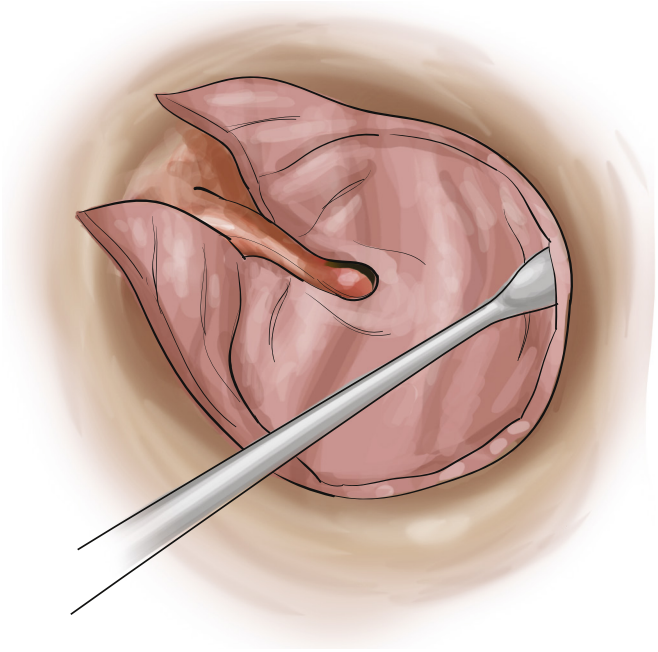

Fig. 131.13. The fascia graft is placed over the perforation, lateral to the annulus with the slit medial to the manubrium. *(From Fayad JN, Sheehy JL. Tympanoplasty—outer surface grafting technique. In Brackmann DE [ed]: Otologic Surgery, 3rd ed. Philadelphia, PA: Saunders; 2010, p. 123.)*

3. Medial grafting technique (Video 131.5)

- Inject the external canal and rim the edges of the perforation as described earlier, to create fresh edges for the graft.
- Make vascular strip incisions, as described earlier, and connect with a semilunar incision approximately 4 mm lateral to the annulus.
- Make postauricular and periosteal incisions, and harvest a fascia graft, as described earlier.
- Retract the auricle and periosteum anteriorly with a self-retaining retractor, and elevate and retract the vascular strip out of the canal.
- Note: If the entire perforation can be visualized transcanal, then the surgeon may choose to proceed with medial grafting via a transcanal approach. A small postauricular incision is used to harvest fascia; however, the remainder of the procedure is performed via transcanal elevation of a tympanomeatal flap.

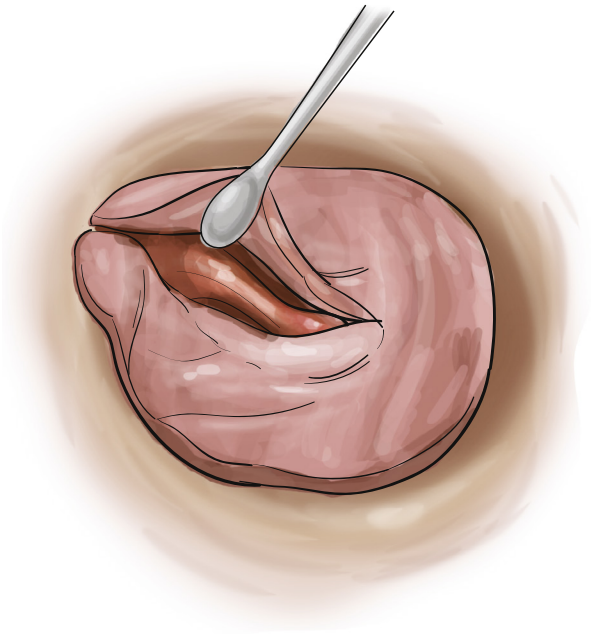

Fig. 131.14. The anterior flap can be folded posteriorly to cover the exposed manubrium. Alternatively, both flaps can be pulled to overlap each other, leaving only an exposed umbo. *(From Fayad JN, Sheehy JL. Tympanoplasty—outer surface grafting technique. In Brackmann DE [ed]: Otologic Surgery, 3rd ed. Philadelphia, PA: Saunders; 2010, p. 123.)*

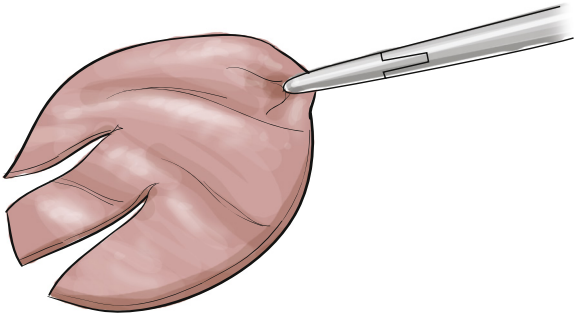

Fig. 131.15. In the case of an absent malleus, the fascia can be cut twice to create a flap to be tucked into the epitympanum. *(From Fayad JN, Sheehy JL. Tympanoplasty—outer surface grafting technique. In Brackmann DE [ed]: Otologic Surgery, 3rd ed. Philadelphia, PA: Saunders; 2010, p. 123.)*

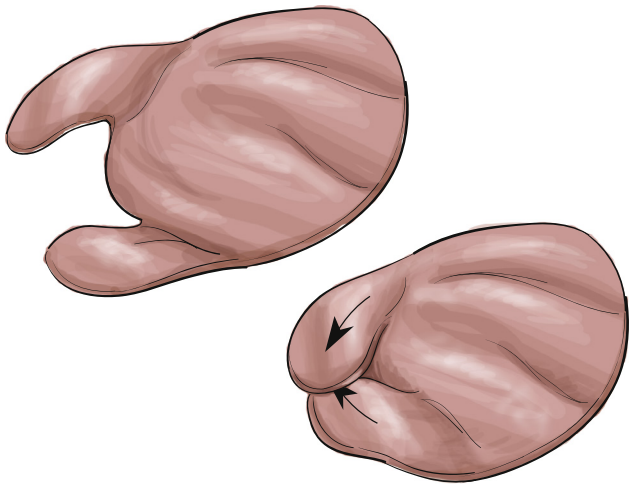

Fig. 131.16. Once the flap is tucked within the epitympanum, the edges are pulled to overlap each other and cover the edge of the graft. *(From Fayad JN Sheehy JL. Tympanoplasty—outer surface grafting technique. In Brackmann DE [ed]:* Otologic Surgery, *3rd ed. Philadelphia, PA, Saunders, 2010, p. 123.)*

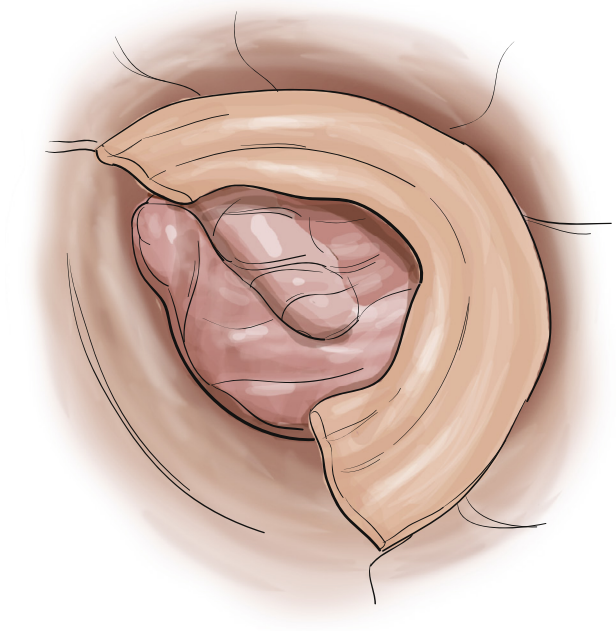

Fig. 131.17. The canal skin is replaced over the bone and is allowed to overlap the fascia by approximately 1 mm. *(From Fayad JN, Sheehy JL. Tympanoplasty—outer surface grafting technique.* In *Brackmann DE [ed]: Otologic Surgery, 3rd ed. Philadelphia, PA: Saunders; 2010, p. 123.)*

- Elevate the tympanomeatal flap and annulus with a round knife until the middle ear is entered. The chorda tympani nerve should be identified and preserved during this step.
- Inspect and palpate the ossicular chain as mentioned earlier.
- Dip a properly sized fascia graft in saline and place up against the medial aspect of the tympanic membrane perforation. Place Gelfoam packing within the middle ear space for support (Fig. 131.18).
- If the perforation incorporates the malleus handle, then the authors prefer the "over-under" grafting technique (Video 131.6):
  - Rim the perforation as before, and remove the periosteum and any drum remnant from the manubrium. It is helpful to make an incision through the periosteum of the malleus with a sickle knife in order to peel the tissue off from the umbo toward the lateral process. Once the manubrium is prepped, place the graft in the middle ear lateral to, or "over," the handle of the malleus and medial to, or "under," the annulus and drum remnant.
- Once the graft is in good position, return the tympanomeatal flap to its anatomic position, and place Gelfoam over the drum remnant and graft complex to hold it in position. If the over-under technique was used, then Gelfoam is also placed over the malleus handle to help adhere the new graft to the bone.
- Replace the vascular strip, and close the wound as described earlier. Place a cotton ball in the meatus and apply a mastoid dressing for 24 hours.

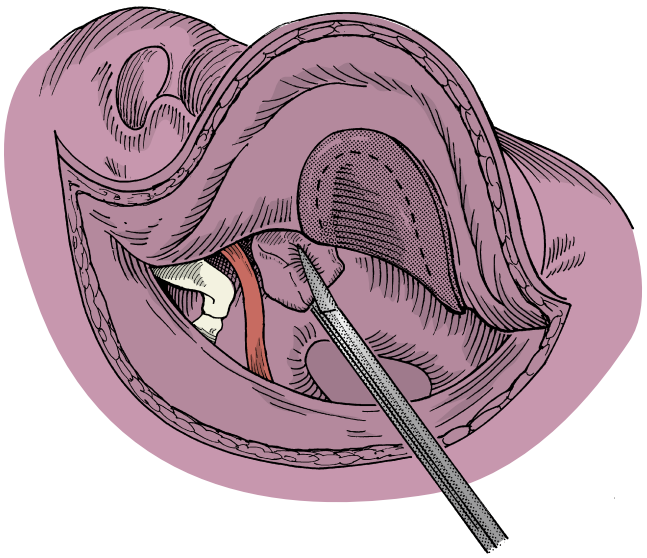

Fig. 131.18. Medial grafting technique. After the edges of the tympanic membrane perforation are freshened, a tympanomeatal flap is elevated. A tissue graft *(shaded area)* is positioned medial to the perforation and supported by packing Gelfoam into the middle ear.

Common Errors in Technique

- Inadequate rimming of the perforation will risk graft failure.
- Inadequate drilling of the bony canal during lateral grafting will inhibit exposure and risk postoperative blunting.
- Squamous epithelium left medial to the graft, or tucked under the canal skin flaps, will risk postoperative epithelial pearls or cholesteatoma.

Postoperative Management

- After myringoplasty, remove any packing in 7 to 10 days. After a lateral paper patch, monitor the patient until the patch migrates onto the skin of the bony canal wall, usually 6 to 12 weeks. Water precautions are maintained during this time.
- After cartilage inlay grafting, no drops are necessary and patients follow up in approximately 3 weeks. Water precautions are maintained until the graft heals, usually 3 to 4 weeks.
- After lateral or medial grafting, remove the mastoid dressing the next day. If skin glue was used, patients may get their postauricular incision wet in 24 hours; however, they should keep the inside of the ear dry from shower water by placing a cotton ball with Vaseline in the meatus. Topical eardrops are used twice daily, starting 1 week prior to their follow-up appointment, which is approximately 3 weeks after surgery. The drops help dissolve the Gelfoam packing and make it easier for the surgeon to suction out any remaining packing and blood clot on the first postoperative visit.
- After lateral grafting, the thick Silastic can be removed at the first postoperative visit or can be left in place as a stent for 6 to 8 weeks if there is concern for medial canal stenosis, blunting, or early graft lateralization.
- After lateral grafting, the ear canal may attempt to heal with cicatricial midcanal soft tissue stenosis, which can progress to complete stenosis and give the appearance of lateralization. Early in-office débridement and stenting should be performed if necessary, and any granulation tissue should be cauterized with silver nitrate.
- The tympanic membrane should be intact by the third postoperative week, and mobility can be checked with pneumatic otoscopy.
- Tuning fork testing can be performed on the first postoperative visit to obtain preliminary hearing results.
- Water restrictions are lifted once the graft appears well healed, usually by 2 months following medial grafting and by 3 to 4 months following lateral grafting.
- Audiometric testing is usually performed 2 to 3 months after surgery if the graft appears well healed.

COMPLICATIONS

- Graft failure
  - Results in recurrent or persistent perforation
  - More likely in patients who have had prior otologic operations and/or patients with significant mucosal disease or compromised eustachian tube function
  - Identifying and counseling these patients preoperatively will lead to more realistic outcomes for both the patient and the surgeon.
- Lateralization
  - Usually occurs 6 to 12 months after lateral grafting
  - Occurs when the graft is not placed medial to the malleus
  - Patients will complain of reduced hearing.
  - Treatment usually requires reoperation.
- Blunting of the anterior sulcus
  - Occurs after lateral grafting in the anterior-superior quadrant from the formation of scar tissue
  - Patients complain of reduced hearing.
  - Prevented by complete removal of the anterior bony canal hump and ensuring the graft is placed directly onto the anterior annulus and not onto the anterior canal wall
  - Reoperation is necessary if hearing is significantly affected.
- Epithelial cysts
  - Canal cysts/pearls occur if skin flap edges are tucked under during closure.
  - Cysts can occur between the graft and the drum remnant if the squamous epithelium is not completely removed from the drum remnant prior to graft placement.
  - If noticed early, keratoma pearls can usually be opened and marsupialized in the office.

ALTERNATIVE MANAGEMENT PLAN

All patients should be offered the option of conservative management, including observation and/or amplification with a hearing aid.

If the conductive hearing loss is greater than 30 to 35 dB, the patient is often functionally compromised, and observation may not be reasonable. Patients reluctant to undergo surgery may opt for aural amplification. Although this avoids the anesthesia and surgical risks, patients must accept the problems inherent with hearing aid use, including frequent battery replacement, instrument malfunction, background noise amplification, and occasionally noisy feedback.

DISCUSSION

Evidence-Based Medicine Question

Is one tympanoplasty technique the best?

Outcomes of tympanoplasty cited in the literature average greater than 90% success rates regardless of method used, as long as the surgeon is skilled and careful in his/her technique. Rizer's large study in 1997 favors lateral grafts over medial grafts by a small but statistically significant margin,[7] although other

authors found no significant difference. Other studies comparing all three methods (cartilage button, overlay, and underlay) cite no statistically significant difference in healing between techniques, with success rates ≥97%.[8] The question of which graft material is best was addressed in a recent systematic review, citing no statistically significant difference in hearing outcomes between materials, although cartilage, with or without perichondrium, gave a better morphologic outcome.[9] The general consensus in the literature is to consider cartilage tympanoplasty (i.e., button, island, or palisading) for high-risk perforations, such as those in an atelectatic ear or with cholesteatoma.[10]

The role of mastoidectomy in improving the success rate of tympanoplasty is controversial. McGrew et al.[3] found similar success rates in two groups of patients undergoing tympanoplasty with or without mastoidectomy; however, the authors note the need for revision surgery was decreased in patients who had undergone mastoidectomy at their initial procedure. We do not advocate routine mastoidectomy with tympanoplasty unless severe middle ear disease, or cholesteatoma, is found intraoperatively.

Editorial Comment

Myringoplasty and tympanoplasty remain the sole operative purview performed by otolaryngologists. There is a long learning curve to mastering interpretation of the tympanic membrane and middle ear findings and the operative techniques needed to successfully achieve an intact tympanic membrane, aerated middle ear space, and minimal conductive hearing loss. With experience in executing the intraoperative steps and managing the postoperative care, the surgeon comes to anticipate what intervention will be needed to achieve the desired outcomes.

The authors have shared their experience with operative repair of the tympanic membrane. They identified factors that are necessary to achieve successful grafting of the tympanic membrane. The status of the middle ear mucosa and functional integrity of the Eustachian tube are important issues that should be identified. Of paramount importance are the skills and experience of the surgeon. There are key steps in executing tympanic membrane repair that must be precise. In lateral graft techniques, placement of a healthy fascial graft onto but not extending beyond the annulus minimizes the complication of blunting and persistent conductive hearing loss. It was pointed out that despite restoration of the conductive component of a mixed hearing loss, amplification may still be necessary due to the residual sensorineural component. The patient should be made aware during the discussion of the procedure of the potential limitations of the surgery.

On occasion a staged procedure is necessary in which efforts are made to initially obtain an intact tympanic membrane and potential middle ear space by placing Silastic sheeting in the middle ear. Anticipating the need for this course of action should be shared with the patient when the operative procedure and postoperative course are explained.

As mentioned, surgery of the tympanic membrane is often done in conjunction with mastoidectomy and ossicular chain reconstruction. The reader is encouraged to review Chapters 132 and 134 for more information about ossicular chain reconstruction and mastoidectomy.

Barry Hirsch

Access the review questions and additional sources list online at http://www.expertconsult.com

REFERENCES

1. Zollner F. The principles of plastic surgery of the sound-conducting apparatus. J Laryngol Otol 1955;69:637–652.
2. Wullstein H. Theory and practice of tympanoplasty. Laryngoscope 1956;66:1076–1093.
3. McGrew BM, Jackson CG, Glasscock 3rd ME. Impact of mastoidectomy on simple tympanic membrane perforation repair. Laryngoscope 2004;114:506–511.
4. Collins WO, Telischi FF, Balkany TJ, et al. Pediatric tympanoplasty: effect of contralateral ear status on outcomes. Arch Otolaryngol Head Neck Surg 2003;129:646–651.
5. Eavey RD. Inlay tympanoplasty: the cartilage butterfly technique. Laryngoscope 1998;108:657–661.
6. Fayad JN, Sheehy JL. Tympanoplasty—outer surface grafting technique. In: Brackmann DE, editor. Otologic Surgery. 3rd ed. Philadelphia, PA: Saunders; 2010. p. 119–129.
7. Rizer FM. Overlay versus underlay tympanoplasty. Part II: the study. Laryngoscope 1997;107:26–36.
8. Abdelghany AM. The button graft technique for perforations affecting less than 25% of the tympanic membrane: a non-randomised comparison of a new modification to cartilage tympanoplasty with underlay and overlay grafts. Clin Otolaryngol 2013;38:208–216.
9. Mohamad SH, Khan I, Hussain SS. Is cartilage tympanoplasty more effective than fascia tympanoplasty? A systematic review. Otol Neurotol 2012;33(5):699–705.
10. Dornhoffer J. Cartilage tympanoplasty: indications, techniques, and outcomes in a 1,000-patient series. Laryngoscope 2003;113:1844–1856.

REVIEW QUESTIONS

1. Which of the following is a contraindication for tympanoplasty?
   a. Active mucoid drainage
   b. Occasional episodes of vertigo of unknown origin lasting less than 30 seconds
   c. A 55 dB conductive hearing loss
   d. Mixed hearing loss

2. Rimming of the perforation is a required step in which of the following tympanoplasty techniques?
   a. Cartilage inlay grafting
   b. Underlay grafting
   c. Overlay grafting
   d. All of the above

3. Blunting after lateral grafting can be avoided by
   a. Adequate rimming of the perforation
   b. Removal of the fibrous annulus
   c. Removal of the anterior bony canal bulge
   d. Placement of the graft lateral to the manubrium

4. Which of the following is a risk factor for postoperative intratympanic cholesteatoma?
   a. Inadequate de-epithelialization of the drum remnant
   b. Concurrent mastoidectomy
   c. Separation of the incudostapedial joint
   d. A near-total perforation

Bonus images for this chapter can be found in the ebook at ExpertConsult.com



ADDITIONAL SOURCES

Gersdorff M, Gérard JM, Thill MP. Overlay versus underlay tympanoplasty. Comparative study of 122 cases. Rev Laryngol Otol Rhinol 2003;124(1):15–22.

Ghanem MA, Monroy A, Alizade FS, et al. Butterfly cartilage graft inlay tympanoplasty for large perforations. Laryngoscope 2006;116:1813–1816.

Hall JE, McRackan TR, Labadie RF. Does concomitant mastoidectomy improve outcomes for patients undergoing repair of tympanic membrane perforations? Laryngoscope 2011;121:1598–1600.

132 Ossicular Chain Reconstruction

Douglas M. Hildrew, Barry Hirsch

INTRODUCTION

Conductive Hearing Loss

Conductive hearing loss results from restriction of sound wave energy in displacing the basilar membrane of the organ of Corti. Conductive hearing loss not of middle ear or tympanic membrane origin can result from obstruction in the external auditory canal and possibly from fluid distention within the inner ear, such as that seen in early Meniere's disease. Inner ear conductive hearing loss also occurs when a "third window" exists in the otic capsule. Dehiscence of the superior semicircular canal provides a site for expansion of inner ear fluid, which prevents the fluid wave from providing full stimulation to the basilar membrane of the cochlea. This may result in conductive hearing loss even though acoustic reflexes will still be present.

Conductive hearing loss of middle ear origin may be congenital or acquired and results from ossicular chain fixation, erosion, dislocation, or fracture. Mass effect from reactive soft tissue processes, tumors within the middle ear, and cholesteatoma can also dampen the transmission of sound energy to the oval window. Ossicular chain reconstruction (OCR) reestablishes the sound-transforming mechanism to provide a mobile connection from the tympanic membrane through an aerated middle ear space to the perilymph via the oval window. This chapter focuses on the surgical techniques for OCR. Tympanic membrane grafting, surgery for stapes fixation secondary to otosclerosis, and chronic otitis media with cholesteatoma are addressed in other chapters (Chapters 131 and 133).

Tympanoplasty

The term *tympanoplasty* describes procedures that address the status of the middle ear from the tympanic membrane to the vestibule. OCR is frequently performed in conjunction with tympanic membrane grafting for eliminating middle ear and mastoid disease. Zollner and Wullstein were early pioneers in the concepts of middle ear reconstructive surgery.[1,2] Wullstein provided a classification system consisting of five types (I to V) of tympanoplasty that focus on reconstruction with the remaining ossicular chain. Each type refers to the most lateral intact structure that remains connected to the inner ear on which the tympanic membrane is grafted or the ossicular chain reconstructed. Type I tympanoplasty indicates that all three ossicles are present and mobile. Thus, OCR is not needed. In type II tympanoplasty, the tympanic membrane is grafted to an intact incus and stapes. In practice, the need for type II tympanoplasty is rarely encountered. According to Wullstein, a type III tympanoplasty exists when an intact mobile stapes superstructure is present and the tympanic membrane or graft remains directly on the stapes superstructure. Type IV tympanoplasty describes an absent or eroded superstructure, with the graft or tympanic membrane lying on a mobile stapes footplate. Type V tympanoplasty refers to a fenestration created in the horizontal semicircular canal (Fig. 132.1), a procedure no longer in active use today due to the superior outcomes afforded through other techniques—largely as a result of modern instrumentation, the otomicroscope, and a wide array of readily available commercial prostheses.

Use of this classification system was subsequently encouraged by Farrior,[3] who clarified the terminology by basing the type of OCR on the pathologic anatomy at the completion of surgery rather than the method of reconstruction used. According to Farrior, type III tympanoplasty refers to establishing continuity of the stapes to the more lateral tympanic membrane or malleus by interposing a sculpted ossicle, bone, or other alloplastic material. A type IV tympanoplasty denotes reconstruction of the ossicular chain from a mobile stapes footplate to the malleus, tympanic membrane, graft, or, rarely, the incus. Type V tympanoplasty has been subdivided into types Va and Vb. Type Va designates a true fenestration procedure into the horizontal canal, whereas type Vb implies that the footplate is fixed or absent. After the vestibule is sealed with a tissue graft, continuity is restored from the oval window to the incus, malleus, tympanic membrane, or graft. Technically, stapedectomy would be characterized as a type Vb tympanoplasty, but this terminology is not proposed for otosclerosis surgery.

This classification system is supplemented by describing the method of reconstruction used for each case. This is applied particularly to type III tympanoplasty. A frequently performed type III tympanoplasty is an incus interposition with the patient's own incus (autograft). A type III tympanoplasty with stapes augmentation entails increasing the height of the stapes above the Fallopian canal when a canal wall–down mastoidectomy is performed and the malleus is absent. This technique frequently uses the body of the incus, the head of the malleus, or a cortical bone graft. The term *partial ossicular replacement prosthesis* (PORP) is used when a synthetic biocompatible prosthesis is positioned from the stapes superstructure to the tympanic membrane, graft, or malleus. Types IV and Vb tympanoplasty are performed with either a *total ossicular replacement prosthesis* (TORP) or the patient's own incus from the footplate or grafted oval window to the malleus, tympanic membrane, or graft.

KEY OPERATIVE LEARNING POINTS

1. The surgeon should be prepared to manage all reconstructive problems within the middle ear by being familiar with the various techniques for OCR, should unanticipated problems arise.
2. Careful palpation plus inspection of the tympanic membrane and all ossicles is critical for determining whether myringosclerosis and tympanosclerosis, separately or in combination, have caused the conductive hearing loss.
3. To avoid restriction of movement, an interposed ossicle or prosthesis should not make direct contact with the surrounding tympanic ring or rest on the cochlear promontory.
4. Reconstruction of the ossicular chain demands a precise connection between the tympanic membrane, graft, or malleus and the stapes, footplate, or vestibule.
5. The terms *PORP* and *TORP* are used for a broad range of ossicular reconstruction prostheses and techniques and used synonymously with incus replacement prosthesis and incus-stapes replacement prosthesis.
6. In order to have effective continuity, anticipate the final resting place of the tympanic membrane and tension with the middle ear prosthesis.

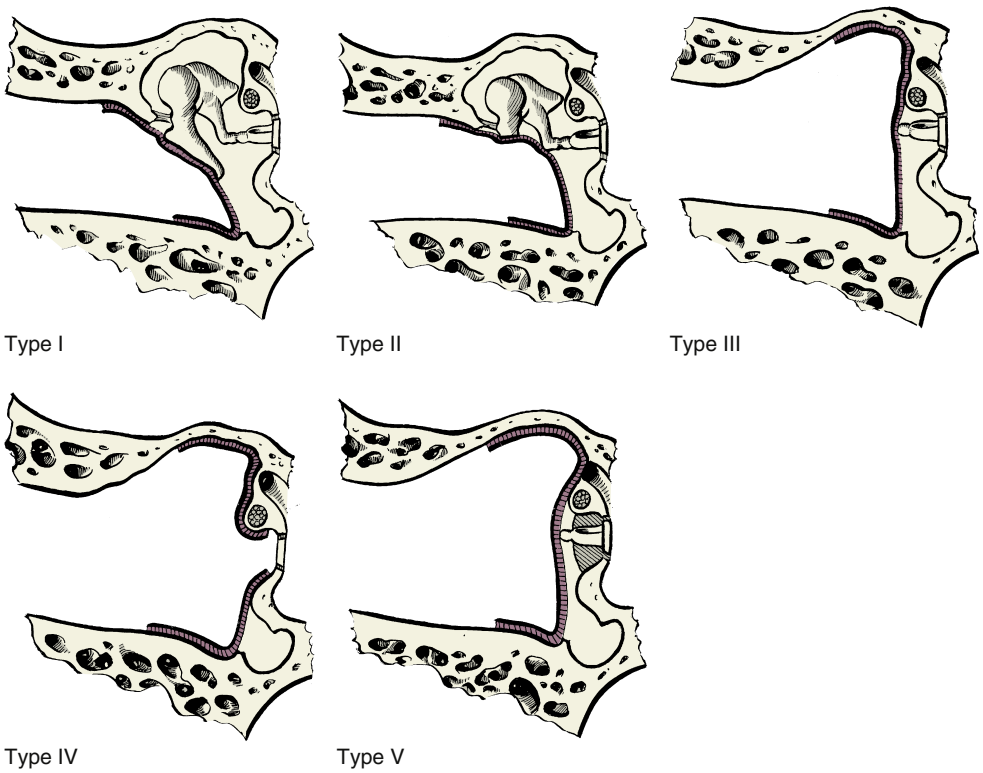

Fig. 132.1. The Wullstein classification of types of tympanoplasty. *(With permission from Kley W: Surgical treatment of chronic otitis media and its immediate consequences. In Naumann HH [ed]: Head and Neck Surgery, vol 3: Ear. Stuttgart, Germany: Georg Thieme; 1982, p 221.)*

   a. The prosthesis should not only touch the tympanic membrane but should also be under slight tension to create minimal tenting of the tympanic membrane over the prosthesis (Fig. 132.2).
      1) A prosthesis that is too short will have a tendency to fall or become displaced.
      2) Excessive length of the prosthesis and/or poor Eustachian tube function sets the stage for extrusion of the prosthesis.
7. Reconstruction is done with the patient supine and the ear facing up toward the operating room ceiling. Anticipate the effect of gravity when they are upright.

PREOPERATIVE PERIOD

History

1. History of present illness
   a. Risk factors: Previous surgery, Eustachian tube dysfunction, trauma, inflammatory/granulomatous disease, congenital malformation, cholesteatoma, middle ear tumors, and ossicular chain fixation resulting from tympanosclerosis
   b. Onset: Did this occur suddenly or slowly over time?
   c. Location: If this occurred suddenly, what/when was the scenario?
   d. Duration: Has hearing stabilized, or is it actively worsening?
   e. Character: What type of hearing loss is present and to what extent?
   f. Associated factors: Is there any associated tinnitus, aural fullness, distortions in hearing, pain, drainage, infection, vertigo, or instability?
   g. Relieving factors: Does anything seem to improve symptoms?
   h. Temporal factors: Is the hearing loss constant or fluctuating in nature?
   i. Other: Are there any other associated symptoms, like autophony or the Tullio phenomenon?
2. Past medical history
   a. Medical illness
      1) Is there a previous history of perforated tympanic membrane, pressure equalization tubes, otitis externa, otitis media, or cholesteatoma?
      2) Are there any known autoimmune, inflammatory, or granulomatous diseases?
      3) Is the Eustachian tube function compromised from allergy or other nasal disease?
   b. Surgical history
      1) If the patient has undergone previous otologic surgery, determine the extent and type. Obtaining previous operative reports may be of some value.
         a) History of previous tympanoplasty, ossicular reconstruction, or stapes procedure
         b) If there is a history of cholesteatoma, one should consider recurrent disease.
         c) A previous canal wall–down procedure may put the facial nerve at risk for future surgeries.
         d) Congenital anomalies could increase the risk of complications.
   c. Family history
      1) Explore otologic/audiologic history of immediate family
   d. Smoking history: May compromise ventilation and healing

Physical Examination

1. Binocular microscopic otoscopy
   a. Evaluation of both ears
      1) The integrity of the tympanic membrane and middle ear space is evaluated.
      2) It is important to examine the contralateral ear, which provides a means of predicting the likelihood

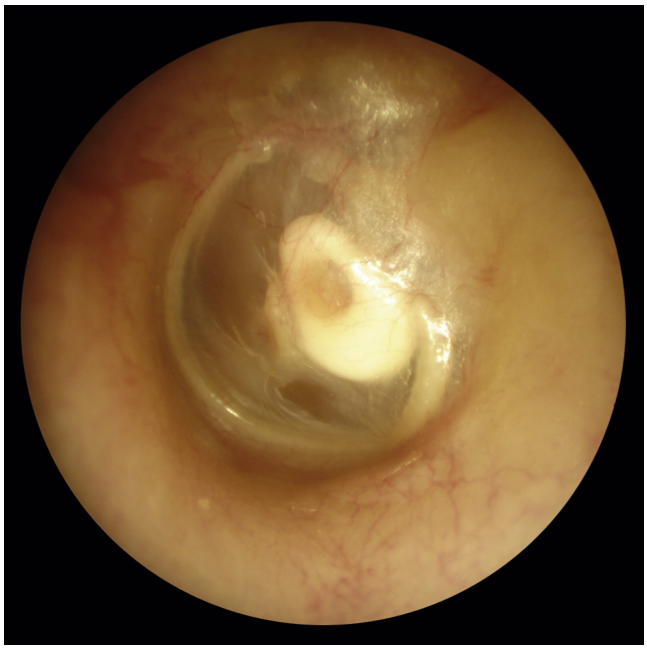

Fig. 132.2. Hydroxyapatite partial ossicular replacement prosthesis making direct contact with the tympanic membrane. Note the very slight tenting over the prosthesis.

of successful tympanoplasty and OCR when eustachian tube function is compromised.
3) Fixation of the lateral ossicular chain is relatively uncommon.
a) While an astute clinician may detect decreased mobility of the malleus during pneumatic otoscopy, it is typically diagnosed at the time of exploratory tympanotomy.
b) The cause may be congenital, but delayed lateral chain fixation is probably due to tympanosclerosis secondary to chronic inflammation of the middle ear.

2. Tuning fork examination
a. Tuning fork testing with 256-, 512-, and occasionally a 1024-Hz fork is performed to determine whether conductive hearing loss is present and to estimate the degree of loss.
1) The most commonly used tuning fork frequency is 512 Hz.

3. Pneumatic otoscopy
a. Assess movement of both tympanic membranes.

4. Audiogram
a. Bilateral audiogram with air and bone conduction, speech reception threshold, and word discrimination done with recorded voice
1) Mandatory to determine the degree of conductive hearing loss and the quality of cochlear function (word recognition)
2) Patients demonstrating a large mixed hearing loss should be considered surgical candidates for OCR in order to bring hearing to an aidable level.

Imaging

1. CT scan
a. Most commonly ordered, dedicated axial temporal bone scan with fine cuts (0.6 mm); coronal and sagittal reconstructions
1) Superior for demonstration of the status of the otic capsule, ossicles, mastoid aeration, erosion, and middle ear space. Disruption of the ossicular chain can be demonstrated in these scans.

2. MRI
a. Superior demonstration of glial tissue, cerebrospinal fluid, and dura
b. Diffusion weighted imaging techniques can be used for diagnosis of cholesteatoma in difficult cases.

Indications

Conductive hearing loss may result from trauma, chronic Eustachian tube dysfunction, congenital anomalies, chronic otitis media, cholesteatoma, tumors of the middle ear space, or ossicular chain fixation resulting from tympanosclerosis. Physical examination may demonstrate an intact or perforated tympanic membrane.

1. Conductive hearing loss of known or suspected ossicular etiology
2. When the ossicular chain must be disarticulated for access to other middle ear pathology
3. Extruding prosthesis from previous surgery

Contraindications

1. An only hearing ear
2. Conductive hearing loss that is present due to middle ear tumors or infection with involvement of the dura or brain
3. Contracted middle ear space when aeration is compromised and OCR is not likely to improve hearing
4. Limited AB gap in revision cases; success is unlikely
5. Medical comorbidities

Preoperative Preparation

1. Primary inflammation of the skin of the external canal or inflammation secondary to disease from the middle ear requires medical management to optimize postoperative healing.
a. A few weeks of topical and systemic antibiotics may be necessary.
b. Patients with an intact tympanic membrane, no history of chronic ear disease, and progressive conductive hearing loss most likely have otosclerosis (see Chapter 133).
2. Review the chart for the history, physical findings, and audiometric results.
3. Review obtained images.
4. Review previous operative reports, if available.
5. Confirm the OR has the prostheses that may be necessary for OCR.
6. Medical status
a. Patients with compromised health should have medical clearance by their PCP and evaluation by anesthesia.
b. Discontinue anticoagulant and antiplatelet drugs if possible.

OPERATIVE PERIOD

Anesthesia

1. Ossicular reconstruction is most commonly done under general anesthesia.
2. Monitored anesthesia care (MAC anesthesia) can be used in cases with a compliant patient and an experienced surgeon and anesthesiologist.
3. Minor adjustment or replacement of an existing prosthesis can be done under MAC.

Positioning

1. The patient is in supine position with the head rotated away from the affected ear.
2. Adjust the height of the table and microscope so that the surgeon is comfortable in a seated position, with his or her arms in a relaxed position and not fully extended.

Perioperative Antibiotic Prophylaxis

1. Procedure designated as clean or clean-contaminated
2. Preoperative antibiotics are routinely given.
   a. Cefazolin is most commonly used due to excellent staphylococcal and streptococcal coverage.
   b. In cases involving a penicillin allergy, consider clindamycin.

Monitoring

1. Routine anesthesia monitoring
   Facial nerve monitoring is not routinely used for reconstruction of the ossicular chain unless combined with mastoidectomy or during repair of congenital aural atresia (see Chapters 134 and 208).

Instruments and Equipment to Have Available

1. Binocular microscope
2. Complete mastoid and middle ear set
3. Monopolar and bipolar electrocautery
4. Full complement of otologic prostheses in stock

Key Anatomic Landmarks

1. Bony-cartilaginous junction of external auditory canal
2. Annulus
3. Tympanic membrane—pars tensa, pars flaccida
4. Chorda tympani
5. Ossicles or prosthesis that may be present
6. Facial nerve (horizontal segment)
7. Round window
8. Oval window
9. Jugular vein (beware high riding or dehiscent jugular bulb)
10. Pyramidal eminence
11. Cochleariform process

Prerequisite Skills

1. Binocular microscopic otoscopy
2. Thorough understanding of temporal bone anatomy
3. Tympanoplasty techniques
4. Stapedectomy and/or stapedotomy techniques

Operative Risks

1. Hearing loss and/or failure to improve hearing
2. Ossicular trauma
   a. Ossicular dislocation
   b. Unresolved conductive hearing loss
   c. Fractured stapes
3. Inner ear trauma
   a. Perilymphatic fistula
   b. Sensorineural hearing loss
   c. Tinnitus
   d. Vertigo
4. Perforation of tympanic membrane
5. Dysgeusia or ageusia
6. Infection
7. Facial nerve paresis or paralysis
8. Cerebrospinal fluid leak
9. Postoperative canal stenosis

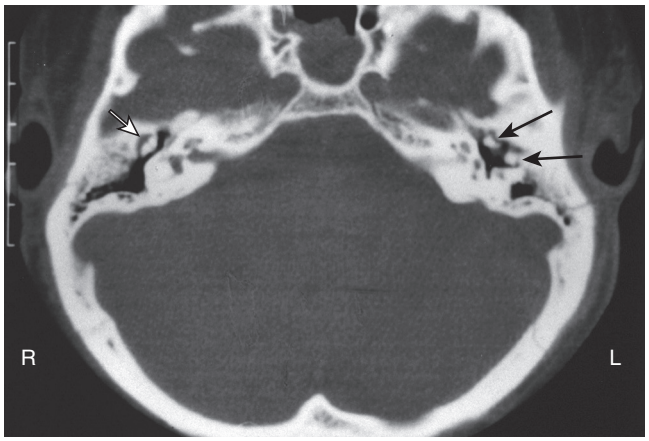

Fig. 132.3. The tympanomeatal incision for exploratory tympanotomy should be 4 to 5 mm away from the posterosuperior annulus. *L*, Left; *R*, right.

Surgical Technique

The approaches to and methods for tympanic membrane grafting are reviewed in Chapter 131. Frequently, the preoperative status of the ossicular chain is unknown when correction of conductive hearing loss is undertaken. The surgeon must be prepared to have access to the entire ossicular chain.

- Tympanomeatal flap
  - The superior limb of the incision should be superior to the pars flaccida and approximately 5 mm from the posterosuperior annulus (Fig. 132.3).
    - The extension of the flap in this area permits removal of bone to provide exposure of the neck of the malleus, body of the incus, and the entire stapes footplate.
      - Removal of this bone permits extraction of the incus if necessary.
- Problems with the malleus

A relatively uncommon source of conductive hearing loss is fixation of the malleus and incus, also known as lateral chain fixation. This may include ankylosis of the head of the malleus and body of the incus to the scutum, immobility of the incudomalleal joint, or calcification of the anterior malleus ligament restricting its movement.

- Malleus fixation
  - Tympanomeatal flap designed to be superior to pars flaccida
  - Flap is elevated anterior to the neck of the malleus.
  - Palpation of malleus to confirm immobility
  - Separate incudostapedial joint
    - Palpate again to verify absence of otosclerosis.
  - Disarticulate the incudomallear joint with a curved pick to allow entire incus to be removed (Fig. 132.4) (see Video 132.1).
  - If malleus fixation persists, a 1-mm micro drill is used to divide the head of the malleus from its handle at the neck of the malleus.
    - Creates a mobile malleus handle

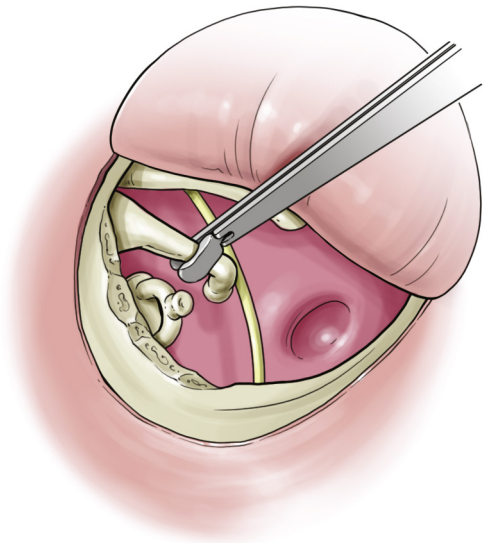

Fig. 132.4. The body of the incus is disarticulated from the head of the malleus and extracted with cup forceps.

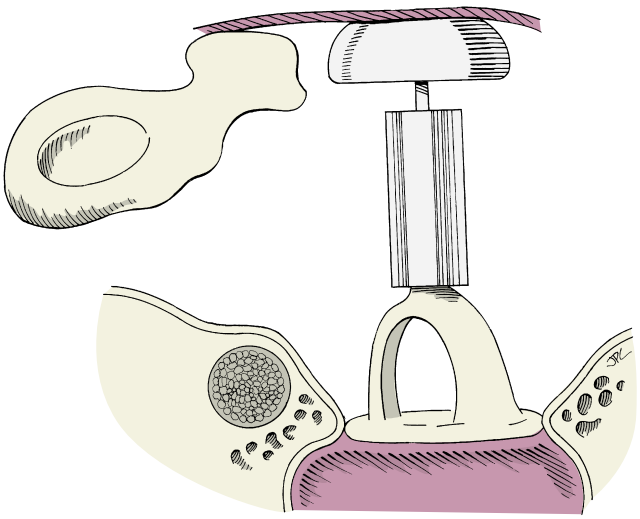

Fig. 132.5. Type III tympanoplasty with a partial ossicular replacement prosthesis when the malleus is absent (stapes to the tympanic membrane or graft).

- Malleus handle supported by attachment to tympanic membrane and tensor tympani tendon
- Incus is sculpted and interposed between the head of the stapes and the handle of malleus.
- A PORP can be placed on the stapes and make contact with the malleus handle or directly to the tympanic membrane (TM).

- Absent or deficient malleus handle
  - The surgeon must decide if the length of the malleus is adequate for reconstruction.
  - Satisfactory closure of the air-bone gap is compromised when the malleus is shortened beyond one-third of its length, unless the prosthesis makes direct contact with the tympanic membrane.
  - Incus interposition is sculpted to maintain sufficient height for connecting stapes superstructure to the intact or grafted tympanic membrane.
    - Improved transmission can be achieved by directing the position of the short process of the incus toward the center of the tympanic membrane.
  - Synthetic prostheses are used more commonly when the malleus handle is absent.
    - A PORP is used if a stapes superstructure is present (Fig. 132.5).
    - A TORP is used if a stapes superstructure is absent but the footplate is present and mobile.
- Total or near-total perforation of tympanic membrane with missing ossicles (mobile footplate still present)
  - Tympanic membrane grafted, and TORP placed from footplate to newly placed graft
    - Challenges/complications
      - The final position of grafted tympanic membrane is not known.
        - Medialization of the graft is possible.
        - Lateralization of the graft is possible but less likely.
      - This presents potential uncertainty in choosing the appropriate length of a prosthesis.
  - An option is a staged procedure. The tympanic membrane is grafted, and a thick piece of Silastic sheeting (0.04 inch) is placed in the middle ear.
    - Ossicular reconstruction is then performed approximately 6 months later (staged procedure).
- Fractured malleus handle
  - Occurs rarely
  - Preoperative pneumatic otoscopy may demonstrate hypermobility of the tympanic membrane and malleus.
  - Reconstruction performed either by incus interposition or with a PORP (see Video 132.2)

- Problems with the incus

The most commonly encountered abnormality in the ossicular chain involves the incus. More commonly, the long process and lenticular process of the incus are eroded or connected by a fibrous union. In patients with an intact mobile malleus and stapes, incus interposition is a commonly used method for OCR. A variety of techniques are available for modification of the incus to provide a mobile yet firm connection from the stapes superstructure to the malleus. The surgeon should note the status of the middle ear mucosa and the relationship of the malleus to the stapes. A cartilage interface with the TM is not necessary when using the incus for OCR.

- The incus can be mechanically sculpted to be interposed between the stapes and malleus (Fig. 132.6).
  - Relative anatomy
    - The stapes may be located directly medial to the handle of the malleus.
    - The malleus may be located anterior to the vertical plane of the stapes.
    - The height of the stapes relative to the promontory and facial nerve is noted.
    - This is especially important when performing reconstruction in a canal wall–down mastoidectomy.
  - Technique for removing the incus:
    - The autograft body of the incus is usually available for reconstruction.
      - It is often necessary to remove additional bone from the posterosuperior canal to extract the incus.
    - A right-angled hook or curved needle is used to disarticulate any remaining attachments of the body of the incus to the malleus head.
    - Cup forceps are used to grasp the proximal long process of the incus.
    - A rotating downward maneuver is used to extract the incus from the attic.
      - Avoid displacement of stapes and injury to chorda tympani.

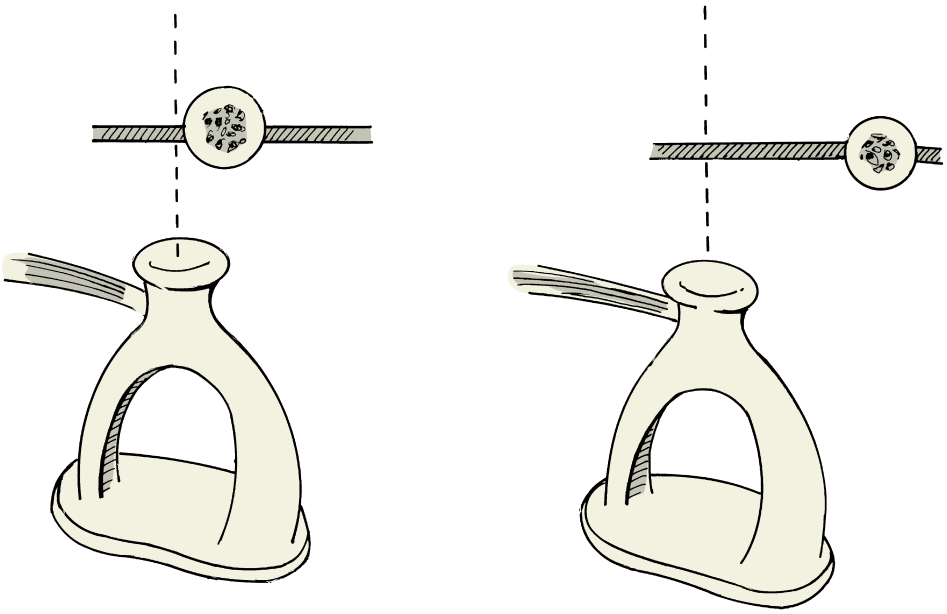

Fig. 132.6. The position of the malleus relative to the stapes determines how the incus will be sculpted to perform an interposition. *Left*, The malleus is located lateral to the stapes. *Right*, Reconstruction requires augmenting the vertical height of the stapes and its anterior span to the malleus.

- Sculpting the incus autograft
  - Various designs for sculpting an incus for interpositioning between the stapes and the malleus are demonstrated in Fig. 132.7.
  - The incus should be held with an instrument such as a fine hemostat or forceps designed for holding ossicles.
    - If a mastoidectomy had been performed, the same variable high-speed drill is used for incus sculpting.
    - A battery-powered micro drill may also be used (see Video 132.3).
  - When the stapes and malleus are in a nearly vertical plane, height is needed to connect the two ossicles (see Fig. 132.7A).
    - The acetabulum for the stapes head is drilled into the short process of the incus.
    - A groove for the malleus handle is created in the articulating surface of the body of the incus.
  - When the malleus is located anterior to the vertical plane of the stapes, both height and horizontal span are needed (Fig. 132.8A; see also Fig. 132.7B).
    - The acetabulum for the stapes is created in the body of the incus near its junction with the long process (see Fig. 132.7B).
    - This is initially positioned under the malleus handle, and the malleus–incus complex is lifted and rolled onto the stapes superstructure (see Fig. 132.8A).
    - A more oval aperture can be drilled to accommodate the shoulder of the crura (see Fig. 132.8B).
  - When considerable height needs to be bridged, the incus is configured as shown in Fig. 132.7C.
  - Occasionally, the incus is eroded just at the incudostapedial joint.
    - Rather than removing the incus, an alternative method for reconstructing this joint is to use an Applebaum hydroxyapatite prosthesis.
    - This prosthesis fits on the stapes superstructure and supports the remaining long process of the incus (Fig. 132.9) (see Video 132.4).
    - Another option is to use hydroxyapatite bone cement to reattach the long process of the incus to the stapes.[4]
- Insetting the incus
  - Care must be taken to ensure that the undersurface of the short process of the incus is not resting on the promontory of the cochlea.
  - With all interpositioning techniques, placement of the incus superior or inferior to the chorda tympani nerve can provide further support to the sculpted ossicle (see Fig. 132.8C).
- Synthetic PORP prosthesis
  - A PORP is used if the incus is inadequate, such as in the setting of significant erosion or infiltration by cholesteatoma.
  - Products containing hydroxyapatite for the interface with the TM and titanium with the stapes are well tolerated.
    - A cartilage interface between the dense hydroxyapatite prosthetic head and the tympanic membrane or graft is not needed. It is necessary, however, with a titanium-topped prosthesis.
  - An adjustable PORP can be shortened to provide the appropriate reconstruction.
- Reconstruction of the ossicular chain in patients undergoing a canal wall–down mastoidectomy may also require a type III tympanoplasty.
  - After the head of the malleus is removed, a connection from the stapes to the malleus handle is necessary.
    - This can be accomplished with incus interposition techniques or with a synthetic prosthesis.
    - The membrane could be grafted directly onto the stapes superstructure as described by Wullstein.
    - Greater surface contact is achieved when an ossicular prosthesis is placed on the stapes.
      - The body of the incus, the head of the malleus, or a small cortical bone graft harvested from the root of the zygoma or the outer table of the squamosa portion of the temporal bone can

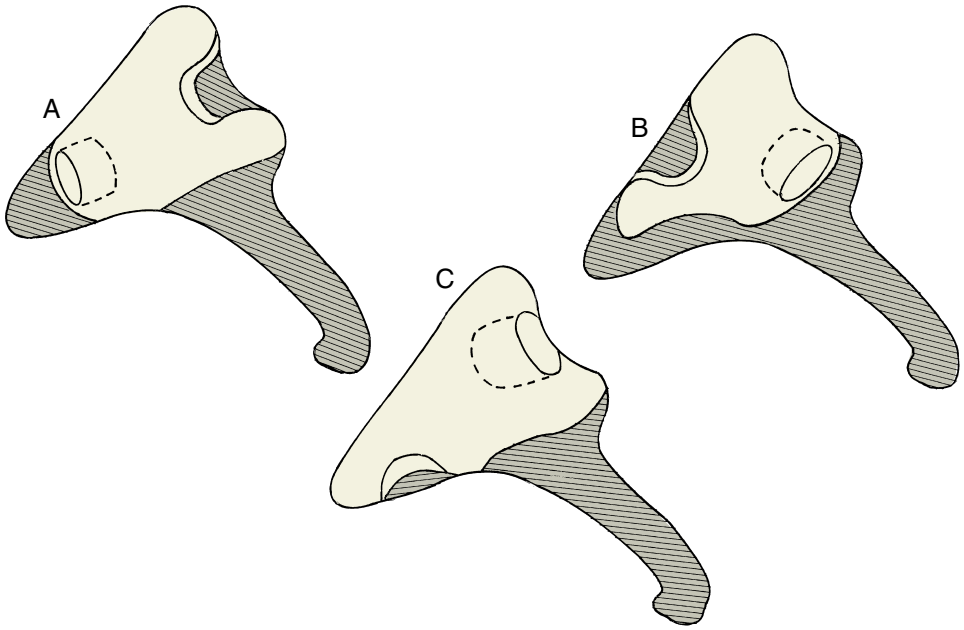

Fig. 132.7. The body of the incus can be sculpted in a variety of forms to accommodate each particular relationship between the malleus and stapes. A, Gains vertical height. **B,** Gains some vertical height and mostly horizontal span. **C,** Gains mostly vertical height and some horizontal span.

be drilled to form a dome for the stapes superstructure.
- The concave surface of a conchal cartilage graft can also be used as a dome for the stapes superstructure. The height and surface area of the head of the stapes can be augmented to make better contact with the tympanic membrane. This can be done with a PORP or a hydroxyapatite (HA) mushroom cap prosthesis (Fig. 132.10).

- Problems with the stapes
  - If the stapes superstructure is partially eroded, interposing an ossicle or prosthesis from the stapes arch or one of its crura will probably fail. Reconstruction from the undersurface of the malleus to the mobile stapes footplate provides a more secure connection of the ossicular chain. An autograft incus occasionally provides adequate length to meet these requirements. The distance should be measured before sculpting the incus. The length of the sculpted incus can be varied based on use of the short or long process from the footplate to the body of the incus. A groove in the articulating surface of the incus is further defined to secure the incus to the medial surface of the malleus (Fig. 132.11A).
  - Additional length is available when the long process of the incus remains.
  - The lenticular process is removed, and the groove for the malleus is drilled on the superior surface of the incus (see Fig. 132.11B) (see Video 132.5).
  - Insetting the incus
    - The sculpted ossicle is placed on the footplate between the remaining crura.
    - While the malleus handle is lifted, the incus is rotated into position.
    - The chorda tympani nerve can be positioned to further stabilize the ossicular assembly.
  - When the oval window niche is narrow and deep, the incus is often too wide to fit between the promontory and the facial nerve.
    - More commonly, a synthetic TORP is necessary.
    - We currently use a prosthesis with a dense HA head attached to an adjustable titanium shaft.
    - The TORP requires temporary support from the stapes footplate to the malleus or tympanic membrane (Fig. 132.12).
  - Titanium prostheses are available in fixed lengths or with adjustable shafts.
    - A sizing set is used to determine the proper length needed.
    - The video demonstrates use of a 5-mm sizing prosthesis to verify the appropriate length needed for the prosthesis to be implanted (Video 132.6).
    - Wet Gelfoam is placed around the base of the shaft up to the level of the facial nerve if the malleus handle is present.
    - When the prosthesis is in direct contact with the tympanic membrane, Gelfoam is positioned around the entire prosthesis to the level of the tympanic membrane (see Video 132.7).
    - The base of the shaft can also be supported by fascia or a footplate shoe.[5]
- Problems with the footplate

The most common cause of fixation of the stapes footplate is otosclerosis. If a fixed footplate is identified while repairing a perforation of the tympanic membrane, it is best to stage the reconstruction to avoid opening the vestibule to a potentially contaminated middle ear space. The same philosophy applies to extensive tympanosclerosis of the footplate when a tympanic membrane perforation or chronic otitis media is present.

- Tympanosclerosis describes deposition of sclerotic plaque after recurrent acute or chronic otitis media.
  - This calcification can restrict the tympanic membrane and ossicular chain.
    - It can be confirmed by gentle palpation of the stapes while observing for a round window reflex.
- If the tympanic membrane is perforated, it should be repaired and the operation staged for a subsequent procedure.
  - Healing is typically complete within 4 to 6 months, at which time the footplate can be safely addressed.
  - There is controversy about how to best manage the stapes when it becomes fixed by tympanosclerosis.

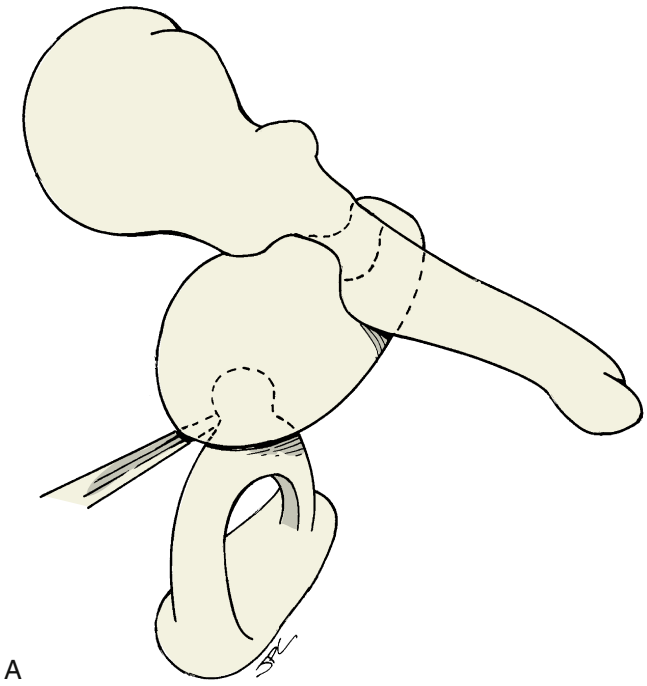

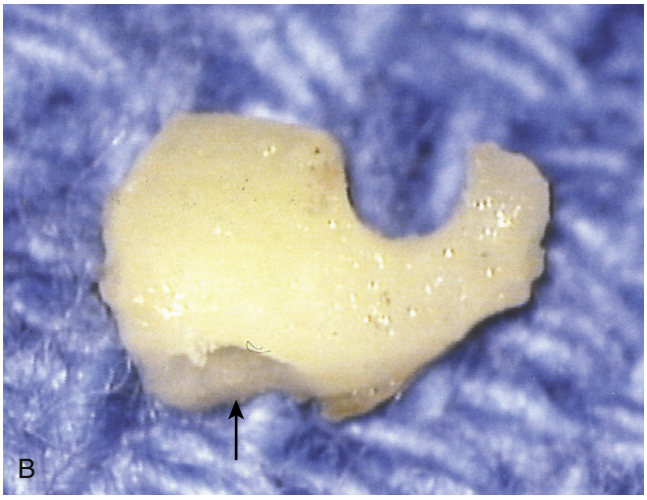

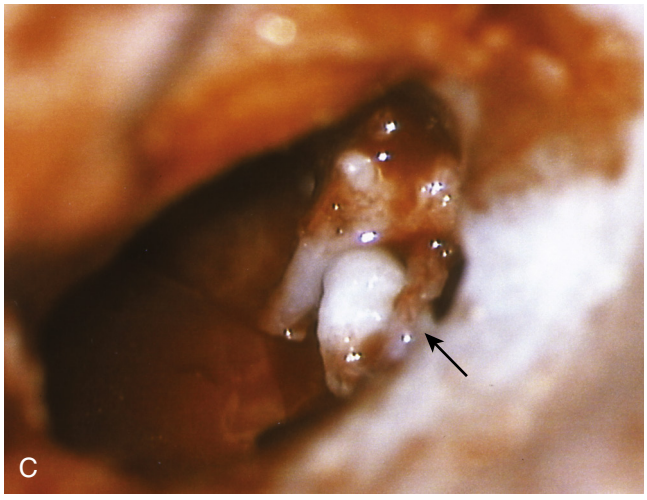

Fig. 132.8. A, Incus interpositioning to gain some height and mostly horizontal span. **B,** The sculpted incus has an oval aperture that fits snugly on the stapes *(arrow).* **C,** In a left ear, the incus has been positioned superior to the stapes and medial to the malleus handle. The chorda tympani nerve provides additional support *(arrow).*

- Options include not intervening surgically and providing amplification, performing stapes mobilization, or removing a portion of the footplate (partial stapedectomy) and placing a prosthesis.
- The concern for mobilization is based on the possibility of refixation of the stapes by new plaque formation.
  - If the status of the ear disease is stable, both short- and long-term hearing results are similar, thus indicating that refixation is unlikely to occur after mobilization.
  - The sclerotic plaque can also be removed away with fine microdissection from the footplate.
- It has also been shown when tympanosclerosis affects the footplate, stapedectomy in a sterile middle ear is a safe and effective procedure.[6]

- In cases of chronic otitis media with cholesteatoma, the stapes footplate may be eroded.
  - If the vestibule is opened inadvertently or by disease, OCR is warranted at that time.

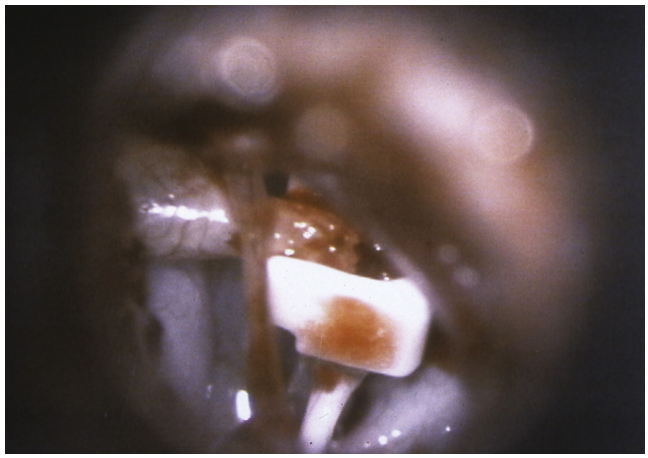

Fig. 132.9. Intraoperative photograph of an Applebaum prosthesis placed between the stapes and an eroded long process of the incus.

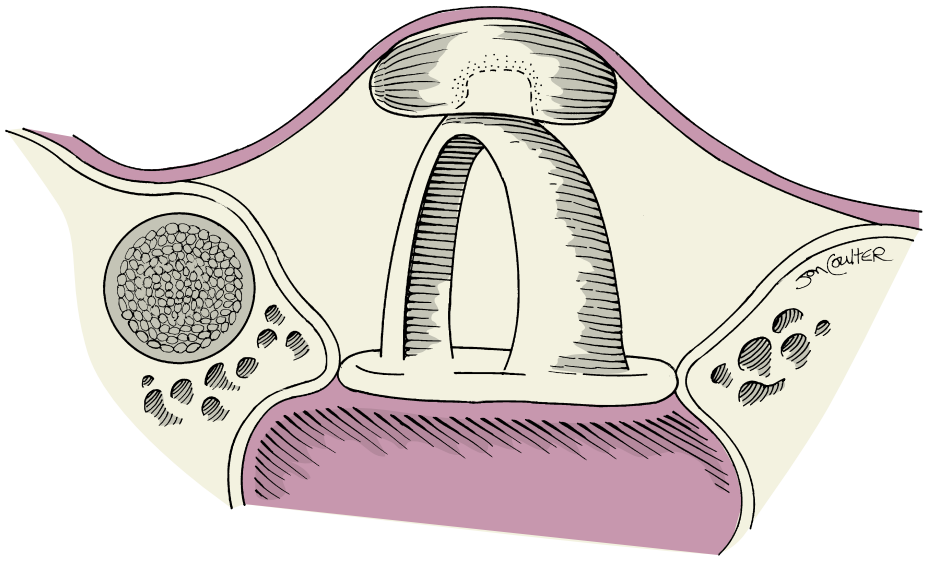

Fig. 132.10. Ossicular chain reconstruction in a canal wall–down cavity. The stapes has a greater area of contact with the tympanic membrane or graft. This is a type III tympanoplasty with stapes augmentation.

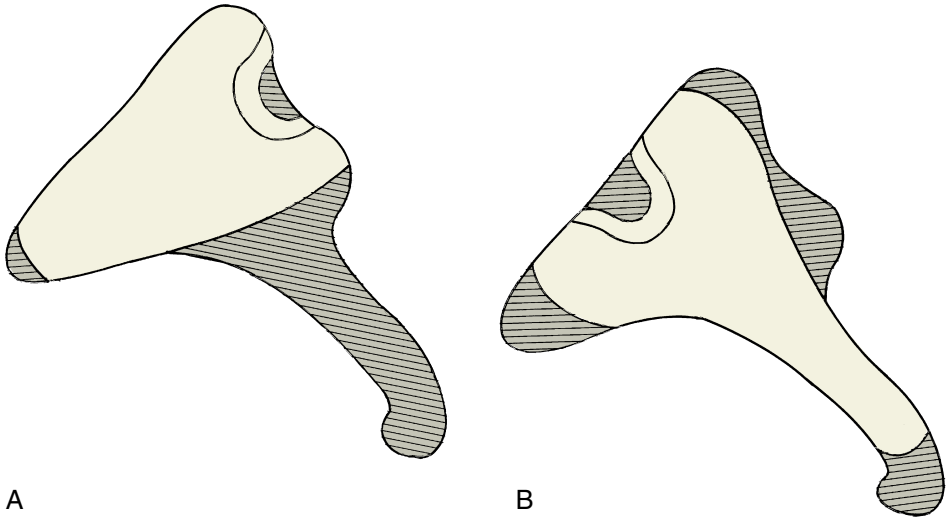

Fig. 132.11. Techniques for sculpting the incus for a type IV tympanoplasty. A, The short process of the incus is flattened. The long process is removed and a groove drilled for the malleus handle. **B,** The long process is flattened, and the notch for the malleus handle is on the superior surface of the incus.

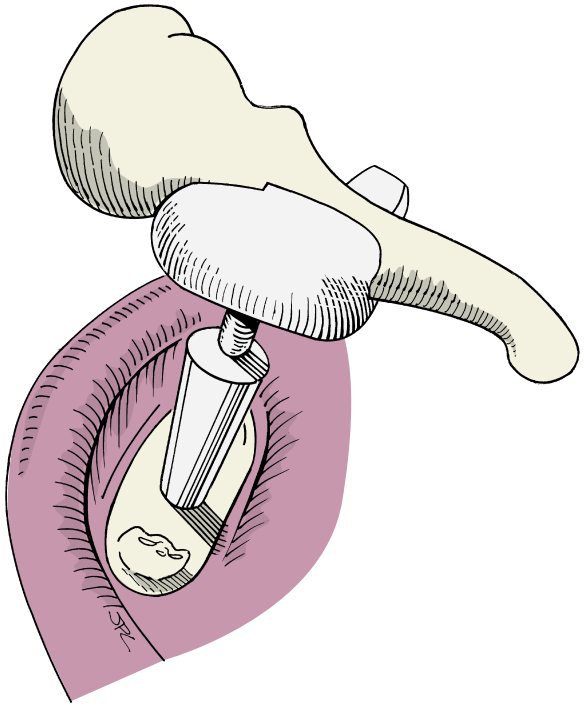

Fig. 132.12. Type IV tympanoplasty from the footplate to the malleus with an incus-stapes replacement prosthesis (total ossicular replacement prosthesis).

- It is rare to have such extensive disease yet still have an intact incus.
  - Reconstruction is frequently done from the vestibule to the malleus, tympanic membrane, or graft (type Vb tympanoplasty).
- The vestibule is covered with a thin but strong graft that will support a prosthesis.
  - True fascia is obtained from the temporalis muscle.
  - The graft is air-dried, cut to approximately 3 to 4 mm, and placed over the vestibule.
- The shaft of the prosthesis is placed in the center of the graft, and the head is positioned under the malleus handle or directly to the grafted tympanic membrane (Fig. 132.13).
  - The grafted tympanic membrane may heal in a more medial position when exposed to the negative pressure of the middle ear space.
    - This puts further demand on the support needed from the oval window graft.
    - If there is concern that the prosthesis may sublux into the vestibule, a perichondrial graft is harvested from the posterior conchal cartilage or the tragus and placed over the open oval window.

COMMON ERRORS IN TECHNIQUE

- Normal mobility must be confirmed by palpation of the malleus and incus because lateral ossicular chain fixation may be missed by an inexperienced surgeon.
- Reconstruction with a partially eroded stapes (type III tympanoplasty) may not provide adequate support of a PORP, and the reconstruction may need to be taken medially from the footplate.
- Excessive manipulation of the stapes when tympanosclerosis is present on the footplate may result in fracture, unanticipated removal of the stapes, or footplate fenestration.
- A prosthesis will become displaced unless there is adequate tension between its medial site of contact (footplate or stapes) and the tympanic membrane or intervening cartilage.
- Excessive removal of the scutum without the support of a block of cartilage may result in retraction into the attic and development of cholesteatoma.
- A prosthesis that rests on the promontory or abuts the bony canal wall dampens needed vibration and sound transmission.

POSTOPERATIVE PERIOD

Postoperative Management

1. Activity
   a. Patients are instructed to keep the ear free of water and avoid blowing the nose or other forms of Valsalva maneuvers.
   b. Patients should avoid significant changes in atmospheric pressure, such as during an air flight, for several weeks postoperatively.
   c. Minimize vigorous head movement in the postoperative period. Parents are encouraged to restrict pediatric patients from engaging in gymnastic or other excessive physical activities.
   d. Patients undergoing a type V reconstruction (prosthesis to the vestibule) are to avoid heavy lifting.
2. Packing
   a. Patients with an intact tympanic membrane who are undergoing OCR have packing of Gelfoam or a silk sleeve supported by small cotton balls with ointment. The packing is removed 7 to 10 days postoperatively.
   b. Patients requiring lateral graft tympanoplasty (tympanic membrane reconstruction) usually have an outer and inner rosebud packing in place.
      1) The outer pack is removed in 1 week, and topical eardrops are prescribed.
      2) The second medial pack is removed 1 week later. Topical drops are continued twice daily for 1 week.
      3) Patients are seen a few weeks later to assess healing of the canal and tympanic membrane.
         - When the tympanic membrane inflammation has resolved and it is thin and mobile, audiometric testing is performed.
           - A residual conductive hearing loss of 15 to 20 dB is still considered a success in the setting of a Type III or IV tympanoplasty.

Complications

1. General surgical risks
   a. Bleeding, infection, pain, scar, damage to adjacent structures, need for revision procedures
2. Otologic risk factors
   a. Hearing loss (permanent or temporary, sensory or conductive), dizziness, instability, vertigo, middle ear infection, extrusion of prosthesis, dislodgement of prosthesis, ossicular erosion, tympanic membrane perforation, cholesteatoma perilymphatic leak, taste disturbances, facial nerve weakness

Alternative Management Plan

1. Frequent aural toilet for chronic otitis media with perforation
2. Amplification
   a. Traditional hearing aids
   b. Bone-anchored hearing aid

DISCUSSION

Evidence-Based Medicine Question

Is it the middle ear disease or the reconstruction material that determines the functional outcome in OCR?

In a recent retrospective case review of 110 patients, it was found that the success rate was highly correlated with the pathophysiologic status of the middle ear and did not depend on the type of replacement, regardless of the technique used.[7]

Editorial Comment

This chapter addresses the concepts and techniques of OCR. The procedure has been executed for the past 65 years, with the biggest change being the design and materials of the prostheses used. Time has shown this to be an evolving process trying to maximize successful surgery and hearing results. The concept of staging a procedure for the purpose of optimizing the position of the tympanic membrane and health of the middle ear space has become increasingly important in patients with chronic otitis media or cholesteatoma.

The ongoing influence of Eustachian tube function must be anticipated during the postoperative and long-term periods following tympanoplasty and ossicular reconstruction. The learning curve for execution can be brief, but achieving consistent well-healed outcomes, with excellent hearing results, is the career focus of otolaryngologists performing this surgery.

Barry Hirsch

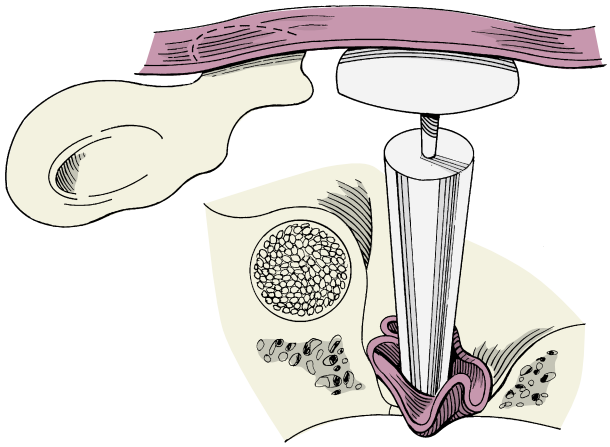

Fig. 132.13. Type Vb tympanoplasty with a total ossicular replacement prosthesis. A graft covers the vestibule on which the shaft of the prosthesis is embedded. The head of the prosthesis tents the grafted tympanic membrane. The malleus handle is absent.

Access the review questions online at http://www.expertconsult.com

REFERENCES

1. Zollner F. The principles of plastic surgery of the sound-conducting apparatus. J Laryngol Otol 1955;69:637–652.
2. Wullstein H. Theory and practice of tympanoplasty. Laryngoscope 1956;66:1076–1093.
3. Farrior JB. Classification of tympanoplasty. Arch Otolaryngol 1971;93:548–550.
4. Iseri M, Topdağ DÖ, Ustundag E, et al. Ossicular reconstruction for incus long-process defects: bone cement or partial ossicular replacement prosthesis. Otolaryngol Head Neck Surg 2014;151(3):468–472.
5. Fayad JN, Ursick J, Brackmann DE, et al. Total ossiculoplasty: short- and long-term results using a titanium prosthesis with footplate shoe. Otol Neurotol 2014;35(1):108–113.
6. Teufert KB, De La Cruz A. Tympanosclerosis: long-term hearing results after ossicular reconstruction. Otolaryngol Head Neck Surg 2002;126:264–272.
7. Demir UL, Karaca S, Ozmen OA, et al. Is it the middle ear disease or the reconstruction material that determines the functional outcome in ossicular chain reconstruction? Otol Neurotol 2012;33:580–585.

REVIEW QUESTIONS

1. What type of pathology would not cause a conductive hearing loss?
   a. Myringosclerosis
   b. Superior semicircular canal dehiscence
   c. Perilymphatic fistula
   d. Malleus fixation

2. A good result for a type I tympanoplasty is closure of the air-bone gap within 5 to 10 dB.
   a. True
   b. False

3. A good result for a type III tympanoplasty is closure of the air-bone gap within 15 to 20 dB.
   a. True
   b. False

4. What is the typical time span for waiting before performing a second stage procedure to correct a conductive hearing loss?
   a. 3 months
   b. 6 months
   c. 12 months
   d. 18 months

5. What type of hearing loss is expected with superior semicircular canal dehiscence, and what would you expect the acoustic reflex to reveal?
   a. Sensory hearing loss, acoustic reflex absent
   b. Sensory hearing loss, acoustic reflex present
   c. Conductive hearing loss, acoustic reflex absent
   d. Conductive hearing loss, acoustic reflex present

133 Otosclerosis

Alexander Rivero, Noriko Yoshikawa

INTRODUCTION

Definition

Otosclerosis is a disease of the otic capsule characterized by both resorption and bony deposition with associated neovascularization. This abnormal bony growth of the otic capsule will eventually result in fixation of the ossicles, frequently at the stapes footplate or the incudostapedial joint. The disease was first identified by Valsalva in 1704 and later termed *otosclerosis* by Politzer in 1894.[1] Histologically the sclerotic foci appear as dense mineralized bone or well-vascularized bone that appears spongiotic. The characteristic blue mantles of Manasse represent the most recently remodeled bone.[1]

Epidemiology and Etiology

Most cases of otosclerosis appear to be familial, inherited in an autosomal dominant fashion with variable penetrance, and are more common in females (frequently reported as a 2:1 ratio). The mean prevalence is 0.2% to 0.4%, with a mean presentation in the third decade of life. Several polymorphisms in the COL1A1, BMP2, BMP4, TGFB1, and RELN genes have been associated with sporadic otosclerosis. Altered expression of the bone specific osteoprotegerin is believed to play an inflammatory role in otosclerotic foci.[2] There have been multiple studies finding immunohistochemical evidence of virus-induced inflammation in temporal bones with otosclerosis suggesting a role in pathogenesis.[3] Hormonal changes have also been implicated, as is seen in the development of clinical otosclerosis during pregnancy. Despite these findings, the overall pathophysiology of otosclerosis remains unclear and is likely multifactorial.

Racial/Ethnic Presentation

The vast majority of patients with otosclerosis are Caucasian and of European descent. Recent studies have found an increasing incidence (perhaps due to increase in diagnosis) of otosclerosis in both Japanese and Chinese patients though the disease process seems milder in these populations.[4] Autopsy dissections of temporal bones demonstrate histologic evidence of otosclerosis 10 times more frequently than clinical otosclerosis, suggesting a certain amount of otosclerosis is tolerated without symptomatic correlation.[3] This may help elucidate the increase in diagnosis in other races and ethnicities, as well as explain their lack of clinical presentation. Case reports of presentation in other races have been published, although the incidence remains low for these populations.

Treatment and Outcomes

The surgical treatment of otosclerosis involves bypass of the fixed stapes footplate. This may be accomplished via stapedotomy or stapedectomy. As laser and microdrills have been introduced, the precision of stapes surgery has improved, and surgeons have largely adopted stapedotomy as the standard of care.

Good outcomes for this surgery have been well documented.[5-9] The guidelines of the Committee on Hearing and Equilibrium recommend an air-bone gap closure of less than 10 dB as an effective measure of success of surgical intervention. Several systematic reviews have demonstrated the safety and efficacy of laser-assisted stapedotomy, resulting in improved visualization due to bloodless intraoperative view, less risk of mobilization of the footplate, and avoidance of inner ear injury.[5,7-9]

KEY OPERATIVE LEARNING POINTS

- Preoperative counseling is essential, particularly in cases with mixed hearing loss.
- Optimize a bloodless field with a good local injection and topical epinephrine, if needed.
- Presence of stapedial reflexes should lead one to consider superior semicircular canal dehiscence (SCCD).
- Adequate surgical exposure is key for safety and efficiency.
- Separation of the incudostapedial joint should be performed in the posterior to anterior direction to take advantage of the countertraction provided by the stapedius tendon.
- Avoid suctioning over the stapedotomy.

PREOPERATIVE PERIOD

History

1. History of present illness
   a. Conductive hearing loss: Clinical otosclerosis arises from the bony deposition causing ossicular fixation typically resulting in unilateral or bilateral conductive hearing loss. Mixed and purely sensorineural hearing loss (resulting from cochlear otosclerosis) may also be present, though these presentations are rare. Tinnitus may be associated with hearing loss.[6]
   b. Patients typically present in their third decade, though this may range from patients in their teens to those in their sixties.[2]
   c. Hearing loss is inevitably progressive, given continued bone resorption and deposition.
2. Past medical history
   a. Assess for history of vertigo, particularly symptoms suggestive of Meniere disease or SCCD. The Tullio phenomenon, vertigo induced by loud noises, may suggest SCCD.
   b. Anesthesia risk factors: Cardiopulmonary disease, renal or liver failure
   c. Alcohol dependence or substance abuse
3. Past surgical history
   a. Previous ear surgery. Previous stapes surgery increases risk of poor hearing outcomes and vertigo.
4. Family history
   a. Family members with middle-age onset hearing loss or having had surgery for hearing loss
5. Medications
   a. Anticoagulation—Surgeons should reinforce the discontinuation of medications that inhibit coagulation approximately 7 days prior to surgery.
   b. Seasonal allergies—Optimize medications and timing of surgery.

6. Psychosocial consideration
   a. Ability to comprehend an informed consent
   b. Employment—Particularly if the patient's job involves frequent flying or heavy lifting, make plans for restrictions in the postoperative period.

Physical Examination

1. Typically the examination of the ear is normal. Bilateral otomicroscopy should be performed on all patients with suspected otosclerosis. Confirmation of normal external auditory canals and healthy appearing tympanic membranes should be performed. This helps distinguish any other external or middle ear pathology as sources for possible conductive hearing loss.
2. Schwartz sign: Occasionally, slight redness may be seen behind the tympanic membrane due to the increased vascularity over the promontory during active remodeling or otospongiosis.
3. Tuning fork examination is also critical. Classic findings for conductive hearing loss using 256 and 512 Hz tuning forks involve a negative Rinne in which bone conduction is greater than air conduction (classically termed "flipped forks") and a Weber examination that lateralizes to the affected ear (if one ear has greater conductive loss than the other). These findings suggest that at least a 15 dB air-bone gap will exist on formal audiometric testing.

Audiometric Findings

1. Conductive hearing loss—An air-bone gap of at least 20 dB should be appreciated prior to offering surgery. Hearing loss less than this should prompt nonoperative management and re-evaluation at a later date.
2. Carhart notch—An audiologic finding consisting of a discreet decrease in bone conduction at 2000 Hz thought to result from loss of the resonant frequency of the ossicular chain. Other conditions such as middle ear effusion and primary malleus fixation may lead to similar findings, and thus Carhart notch is suggestive but not pathognomonic of otosclerosis (Fig. 133.1).
3. Stapedial reflexes—In cases of early otosclerosis, the stapedial reflexes may still be intact. However, the presence of preserved stapedial reflexes should lead one to consider alternate diagnoses such as superior canal dehiscence, where conductive loss can also be present due to a "third window" effect.

Imaging

1. Imaging is not necessary for routine conductive hearing loss.
2. A CT scan is indicated if conductive hearing loss with intact reflexes is present to rule out SCCD.
3. CT scan findings in otosclerosis may include a lucency of the otic capsule near the oval or round window, resulting from demineralization during the active otospongiosis phase. Extensive cochlear demineralization may result in the double ring or halo sign. A mixed loss is often present (Fig. 133.2).
4. MRI with gadolinium may enhance active foci of otospongiosis.

Indications

1. Progressive conductive hearing loss the in setting of absent reflexes
2. Air-bone gap greater than 20 dB in at least three frequencies
3. Tympanosclerosis with stapes footplate fixation
4. Trauma-induced footplate fracture or subluxation

Contraindications

1. Tympanic membrane perforation. It is necessary that an intact tympanic membrane be present prior to stapes surgery. This helps prevent contamination of the vestibule by external ear flora. Similarly, it is recommended that patients with ventilation tubes undergo removal of the tubes and healing of the tympanic membrane prior to stapedotomy.
2. Air-bone gap less than 20 dB in at least three frequencies
3. Meniere disease: Relative contraindication due to increased incidence of vertigo and sensorineural hearing loss
4. Active external or middle ear disease
5. Only or better hearing ear

Preoperative Preparation

A standard preoperative history and physical examination are pertinent. Appreciating several factors preoperatively may help lead to a successful operation.

1. Neck mobility—The ability to manipulate patient positioning intraoperatively is key to providing optimal visualization. A lack of mobility may inhibit the patient's ability to undergo surgery.
2. Narrow external auditory canal—Recognizing this early may help direct the approach. An ear canal that accommodates a 5.0-mm speculum is sufficient for surgical intervention. Smaller canals or those with large anterior lips may require a postauricular approach or a 12 o'clock releasing incision in the incisura.
3. As is key with any operative procedure, an appropriate informed consent process should be undertaken. Patients should be counseled on risks and expectations. The list is outlined below in the "Operative Risks" section. A detailed version of the operative risks discussed with each patient is provided in Table 133.1.
4. In cases of mixed hearing loss, patients should be aware that improvement in their hearing will be limited to the level of their underlying sensorineural hearing loss. For patients who are unsure whether they would like to proceed with surgery, the alternative of a hearing aid trial should be presented. This allows the patient to remain functional while determining whether surgical correction is appropriate for them.
5. A key operative principle of otologic surgery remains true in stapedotomy and management of otosclerosis—always operate on the poorer hearing ear. Conversely, avoid operating on the only hearing ear.

OPERATIVE PERIOD

Anesthesia

Local versus general. Understanding a patient's mobility and comorbidities may help guide the determination of local monitored anesthesia care versus general anesthesia with endotracheal intubation. In patients with poor mobility or who are unable to sit still for an extended period of time, general anesthesia may prove more useful. Similarly, in patients who have extensive comorbidities where general anesthesia poses a greater risk, local sedation should be considered.

1. Local anesthesia with sedation. Benefits of this include being able to verify hearing improvement intraoperatively. Patients can also report vertigo. However, patients may be

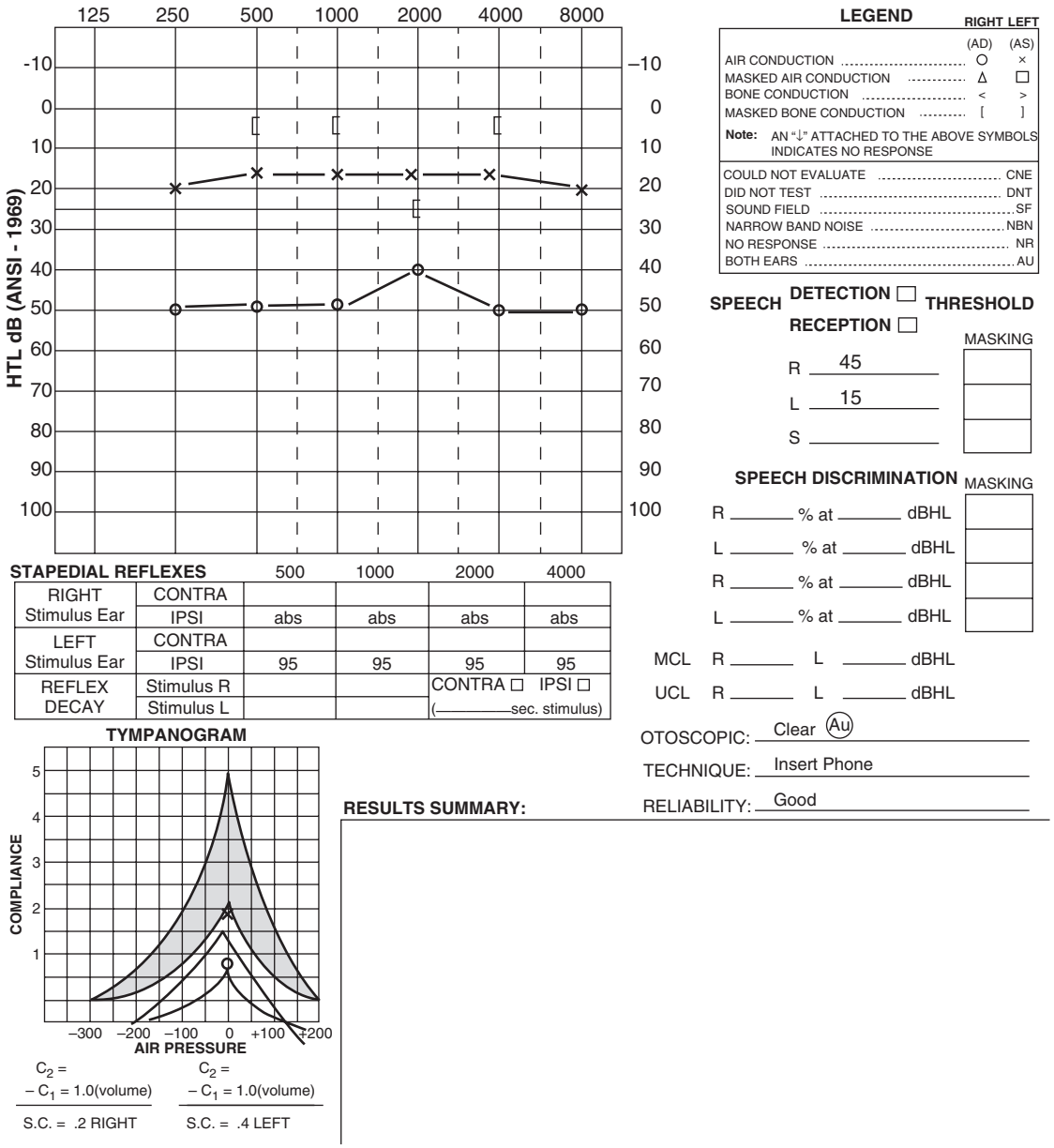

Fig. 133.1. Audiogram showing right conductive hearing loss and a sensorineural dip at 2000 Hz indicative of Carhart notch.

startled and move during surgery. This also may not be well tolerated in patients with poor neck mobility.
2. General anesthesia allows for more ease of positioning and reduces the risk of unexpected movements, though it also precludes intraoperative verification of hearing improvement or vertigo complications.

Positioning

1. Patients are typically positioned in the supine position with the head turned away, exposing the operative ear.
2. If lateral neck rotation is limited, then table tilt can be employed. A horseshoe headrest, or a positioning bump/roll under the torso and hip on the operative side, can improve access.
3. Pad arms and knees.
4. If a vein graft is to be taken, the contralateral hand should be positioned with padding under the wrist and fingers, exposing the dorsum of the hand. This area should be prepped and draped carefully so to not contaminate the area as the primary drape is being pulled over the body.

Perioperative Antibiotic Prophylaxis

Not indicated[10]

Monitoring

Facial nerve monitoring is not indicated. The risk of facial nerve injury is very low. However, if the patient is under general anesthesia, it is advisable to not use long-acting paralytics so that stimulation of the nerve would be an option if concern arose during the case.

Instruments and Equipment to Have Available

1. Otologic surgery set

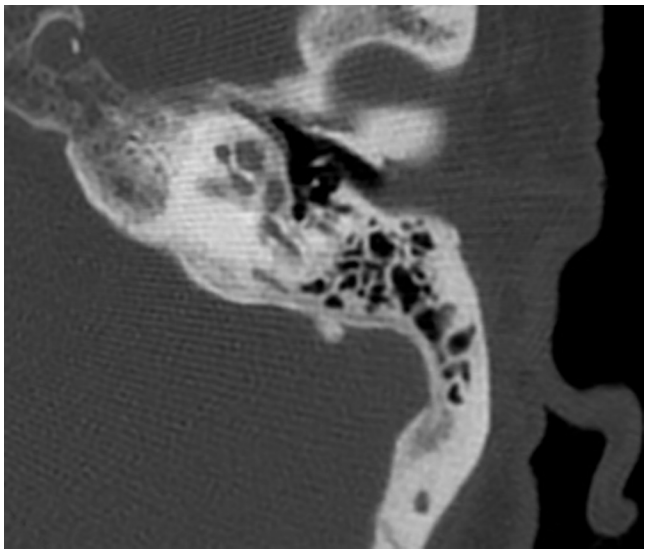

Fig. 133.2. Extensive cochlear demineralization may result in the double ring or halo sign.

2. Stapes specific instruments such as curettes, measuring rod, footplate picks
3. Laser and micro-otologic drill (e.g., Skeeter)
4. Crimper if necessary for prosthesis
5. Operating microscope
6. Stapes prostheses

Key Anatomic Landmarks

1. Horizontal segment of the facial nerve
2. Pyramidal eminence
3. Promontory
4. Malleus/cochleariform process
5. Round window, if in view

Exposure of these five anatomic landmarks will ensure that the stapes and lenticular process of the incus are adequately visualized.

Prerequisite Skills

1. Microsurgical fine motor skills

Operative Risks

1. Hearing loss (See Table 133.1 for Detailed Review)
2. Tinnitus
3. Dizziness/vertigo/imbalance
4. Taste disturbance and dryness of the mouth
5. Facial paralysis
6. Extrusion of prosthesis
7. Tympanic membrane perforation
8. Wound infection
9. Brain complication and cerebrospinal fluid leak

TABLE 133.1 Detailed List of the Operative Risks Reviewed With Patients Prior to Surgery for Otosclerosis

Risks	
Hearing	Surgery may fail to improve hearing. Rarely, further loss of hearing develops due to the extent of the disease or problems in the healing process; this may be permanent. In 1% of patients, a severe loss of hearing may result in the operated ear; if that happens, nothing further can be done to correct the loss.
Tinnitus	Tinnitus (head noise) may be more pronounced after surgery and usually correlates with the further impairment of hearing. It is usually not corrected by surgery.
Dizziness	Dizziness may occur due to irritation of the inner ear structures. Some unsteadiness may persist for weeks postoperatively. Rarely is the dizziness severe and prolonged.
Taste disturbance and mouth dryness	Taste disturbance and dryness of the mouth are common for a few weeks following surgery. In 5% of patients, this disturbance is prolonged or permanent.
Facial paralysis	Rarely, temporary paralysis on the operated side of the face may occur. This usually subsides spontaneously. If it is prolonged, further surgery may be considered.
Extrusion of prosthesis	Sometimes a prosthesis made of synthetic material is used to reconstruct the bony chain of hearing. The body will occasionally reject a foreign material. Reoperation may be necessary.
Perforation	A perforation may develop in the eardrum after surgery. A perforation may be due to infection or problems in the healing process. Often it will heal spontaneously; if it does not heal, further surgery may be an option.
Wound infection	Infection (drainage, swelling, and pain) may develop following surgery due to poor healing. Rarely, a more serious infection can extend to the fluid around the brain causing meningitis. Prolonged hospitalization or additional surgery may be necessary to treat the infection.
Cerebrospinal fluid leak	On rare occasions, the fluid surrounding the brain may leak after surgery. This leads to a risk of meningitis and hospitalization with possibly further surgery to close the leak.
Brain complications	Meningitis, brain abscess, and stroke were commonly caused by ear disease prior to the use of antibiotics. They can still occur with or without surgery but have become very rare.

Surgical Technique: Stapedectomy With Bucket-Handle Prosthesis

1. Inject the canal with 1% lidocaine with 1:100,000 or 2% lidocaine with 1:50,000 epinephrine with a 27-g needle. Care should be taken to inject slowly to avoid ballooning of the skin. A blanch should be seen extending down onto the tympanic membrane; this is best seen if injection is performed under the microscope. Injection should be performed circumferentially, ending with the anterior canal to minimize blood dripping into the field. This step is still performed even when the patient is under general anesthesia to assist with vasoconstriction.
2. Tympanomeatal flap incisions are made at 12 o'clock and 6 o'clock, connecting in the posterior lateral ear canal. (Fig. 133.3) This flap should be made long enough to cover the defect that will be made by curetting the scutum (Fig. 133.4).
3. Elevate the flap.
4. Lift the annulus inferiorly to avoid unintentional trauma to the chorda tympani.
5. Identify the chorda tympani nerve.
6. Curette the scutum for adequate exposure of the previously mentioned landmarks. Care should be made to avoid injury to the chorda tympani. Leaving a thin lip of bone adjacent to the chorda, to be removed at the end, can help protect the chorda during the majority of this step (Fig. 133.5).
7. Palpate the ossicular chain by gently lifting laterally on the malleus, looking for movement of the incus; then push on

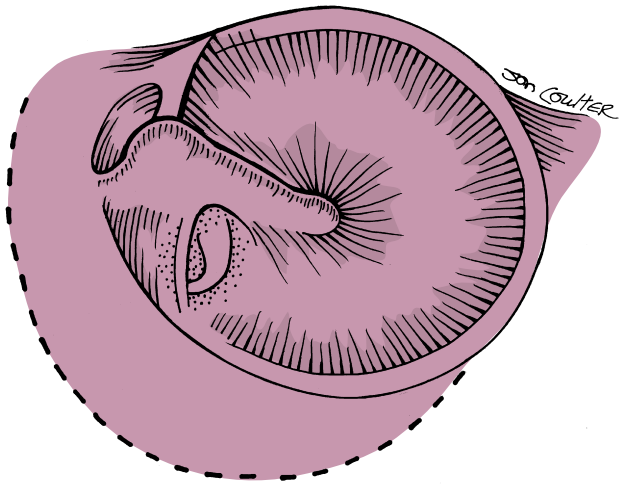

Fig. 133.3. Correct incision in the canal allows adequate removal of bone and exposure of the ossicular chain.

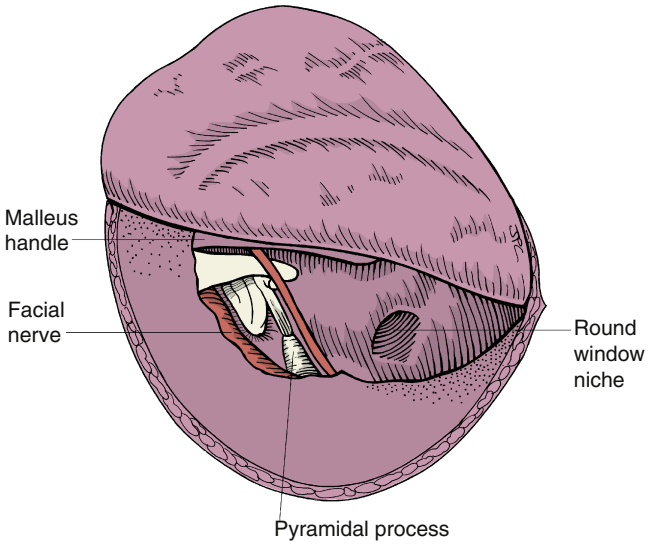

Fig. 133.5. Demonstrating adequate middle ear exposure for management of any conductive problem encountered.

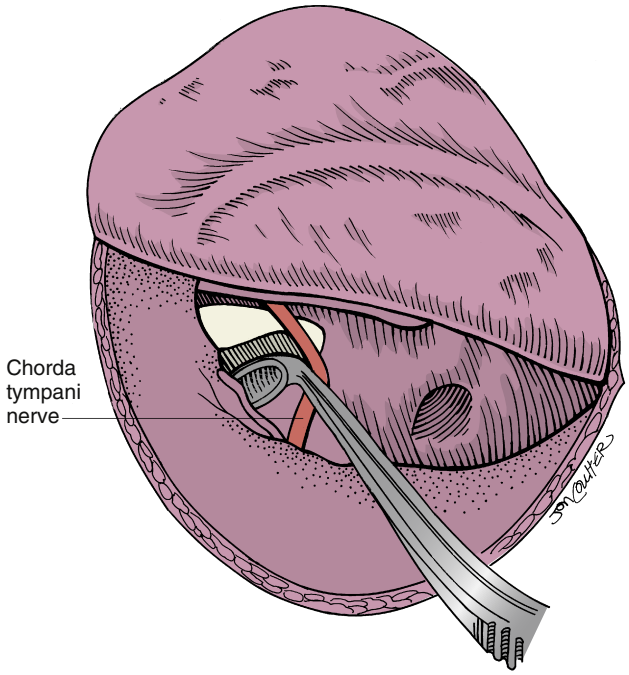

Fig. 133.4. Curetting the posterosuperior bony canal wall with preservation of the chorda tympani nerve.

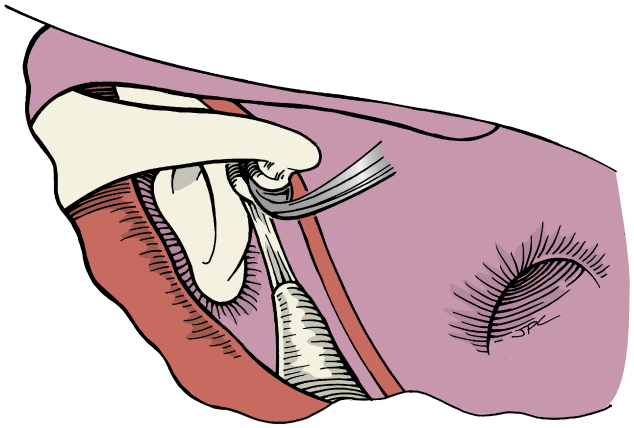

Fig. 133.6. Separation of the incudostapedial joint while being careful to preserve the lenticular process of the incus.

the distal incus and look for compression at the incudostapedial joint or for movement of the stapes.

8. Separate the incudostapedial joint. This can be achieved using an IS joint knife or angled pick. This should be done from a posterior to anterior direction to utilize the stabilization/counter traction provided by the stapedius tendon (Fig. 133.6).
9. Palpate the ossicular chain again to ensure it *is* the stapes that is fixed and the lateral chain is mobile.
10. If performing a large stapedotomy or a stapedectomy, harvest a soft tissue graft or vein graft and allow it to dry. The vein graft is taken from the dorsum of the contralateral hand. A straight vein section without branches can be marked, injected, and prepped for potential use. Make an incision through the dermis transverse to the axis of the vein. Spread bluntly with tenotomy scissors parallel to the vein, and isolate the vein. Tie off the vein with 4-0 Vicryl or chromic sutures; 1 cm in length is ideal to allow for redundancy, but a smaller graft can still be used. Clean any adipose tissue or adventia off of the vein, thread it over one tine of the tenotomy scissors, and cut the lumen open. Lay the vein out to dry (Fig. 133.7A to C).
11. Test the laser on a tongue depressor to ensure that the laser is focused and aligned with the aiming beam, if present, and the burn is satisfactory.
12. A fenestration or control hole has two functions: first, to identify a perilymphatic gusher, and second, to allow access for a hook or pick to extract a floating footplate (Fig. 133.8).
13. Divide the stapedial muscle tendon. The laser or Bellucci scissors are useful instruments for this step (Fig. 133.9).
14. Laser the posterior crus of the stapes (Fig. 133.10; Video 133.1).
15. Down fracture the stapes superstructure inferiorly onto the promontory with a Rosen pick. Push the freed superstructure down onto the promontory and remove it with cupped or alligator forceps (Fig. 133.11).
16. Measure distance and select prosthesis. The measuring technique varies for different prostheses. For the classic

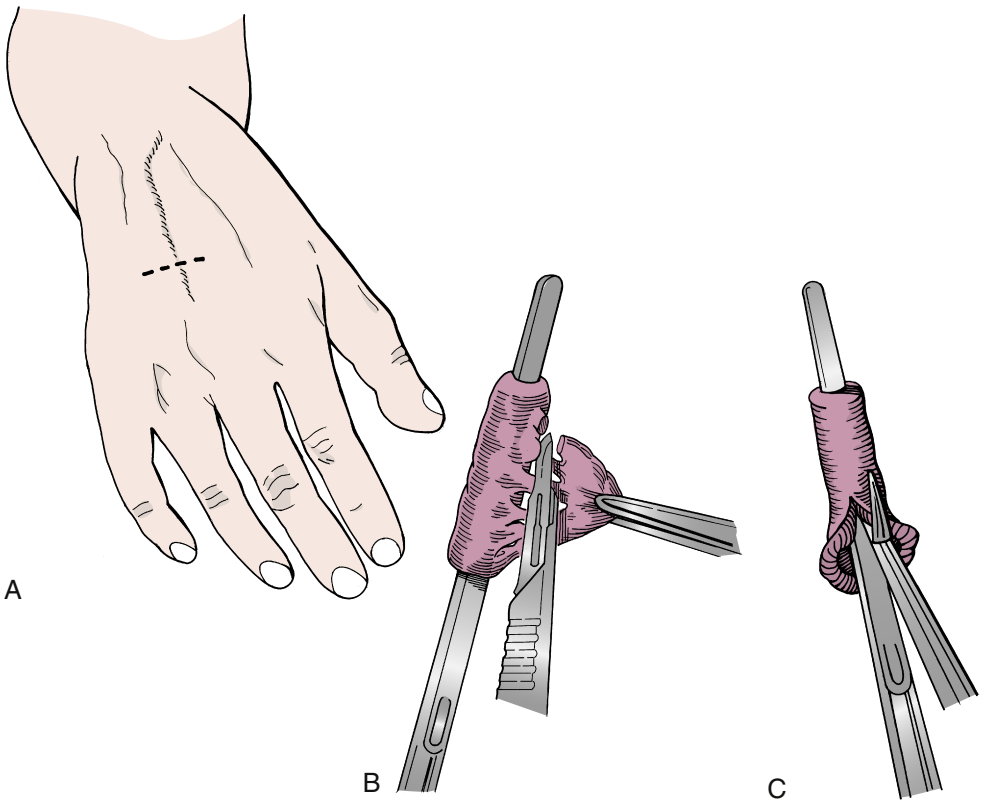

Fig. 133.7. A, 2-cm transverse incision is made on the dorsum of the hand for harvesting the vein graft. **B,** Removal of connective tissue from the vein graft. **C,** Opening the vein graft.

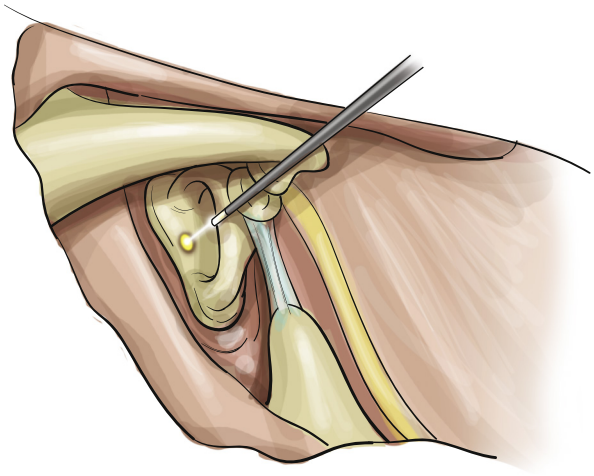

Fig. 133.8. Fenestration of the superior central area of the stapes footplate with a laser.

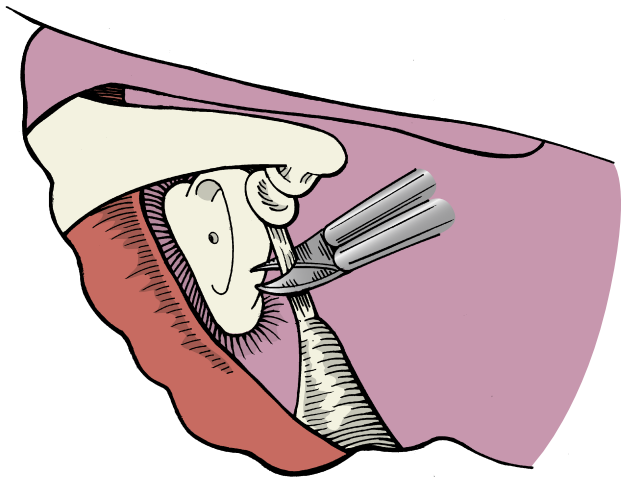

Fig. 133.9. Sectioning of the stapedial tendon.

bucket-handle type prosthesis, measure from the vestibule to the medial edge of the incus (Fig. 133.12). If measuring is done prior to the stapedotomy, measure from the footplate to the mid-thickness of the incus.

17. Make the stapedotomy. The laser is used to enlarge the fenestration control hole by vaporizing the edges of the hole creating a rosette pattern. This helps prevent floating fragments of footplate bone. A footplate pick or rasp can be used to remove fragments or to enlarge the stapedotomy (Fig. 133.13).
18. Place vein graft. Trim the graft so the edges are clean. The vein graft should cover the stapedotomy completely and ideally drape onto the facial nerve as well as the promontory. Typically this is about 5 × 4 mm. Push the vein down in the center, over the stapedotomy, to help "visualize" where the prosthesis should go, even though the stapedotomy is covered (Fig. 133.14).
19. With alligator forceps holding the posterior lip of the bucket with the handle inferiorly, place the piston end into the depression made in the vein graft overlying the stapedotomy. Rest the bucket against the incus, and remove the alligator forceps. Using a right-angle hook to gently retract/stabilize the incus, and with a Rosen needle in the well of the bucket, gently push the prosthesis medially to slip the bucket well under the lenticular process of the incus (Fig. 133.15). Elevate the bucket handle over the

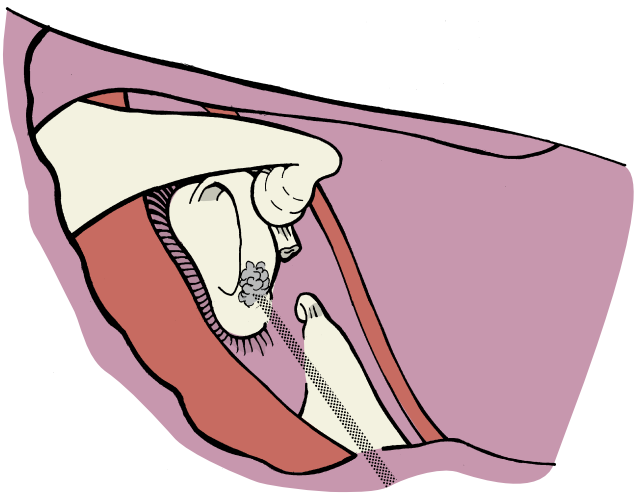

Fig. 133.10. Vaporization of the posterior crus with the laser.

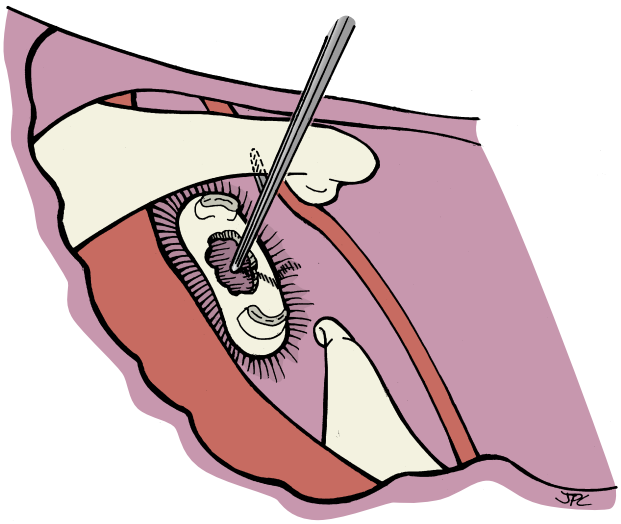

Fig. 133.12. Measurement is from the vestibule to the undersurface of the incus for the Robinson prosthesis.

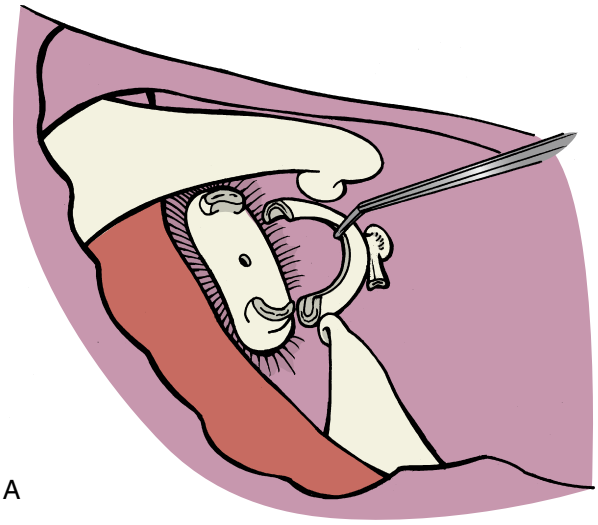

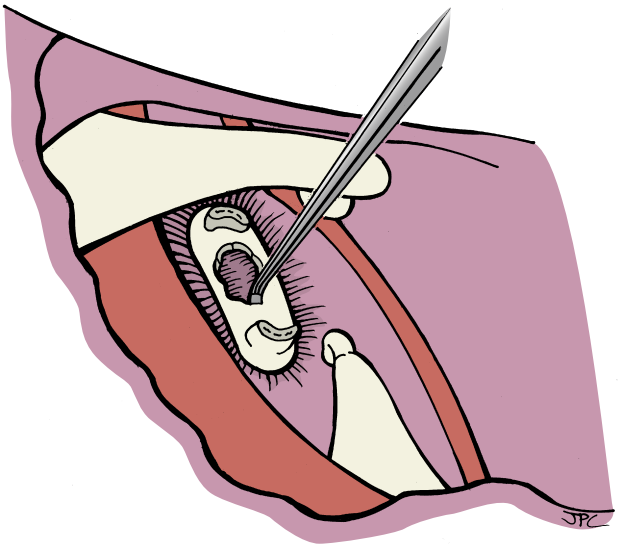

Fig. 133.13. Removal of the central area of the footplate.

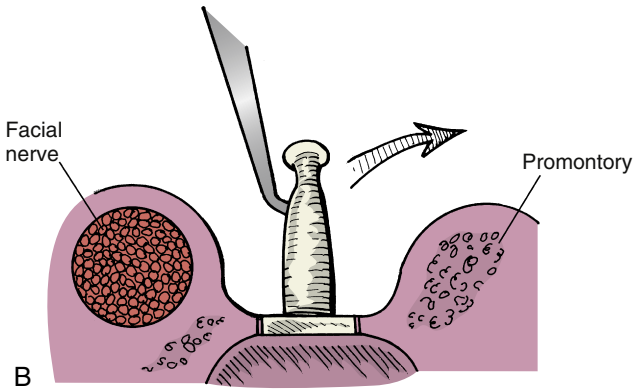

Fig. 133.11. Down-fracturing of the stapes superstructure toward the promontory. **A,** Surgeon's view. **B,** alternate view with relation to the facial nerve.

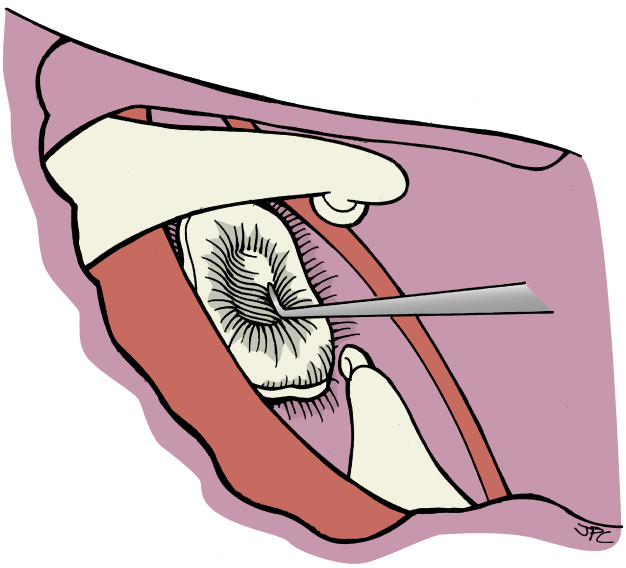

Fig. 133.14. Placement of the vein graft over the stapedotomy in the footplate.

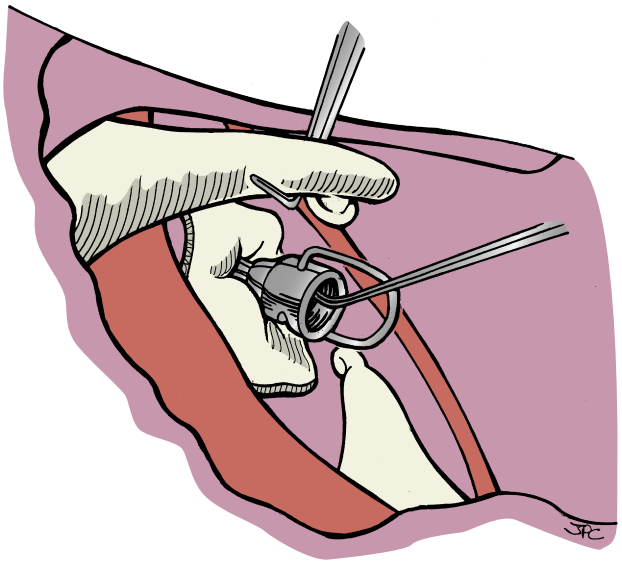

Fig. 133.15. Placement of the Robinson prosthesis using a two-handed technique.

distal end of the incus. If the bail of the handle is loose, a small piece of vein can be placed over the bucket handle to help secure it in place.

20. Check the mobility of the prosthesis—Look for a round window reflex; replace the tympanomeatal flap with care to ensure the edges are not curled under. If awake, check hearing.
21. The flap can be stabilized with Gelfoam soaked in Floxin laid over the incision line.

Surgical Technique—Stapedotomy With Crimped Wire Piston Prosthesis

1. Steps 1 to 16 are identical in this technique. When making the stapedotomy, the size of the opening of the footplate is created to be 0.1 mm larger than the diameter of the piston. Intraoperative judgment is advised.
2. The piston is then placed in the oval window fenestra, and the wire or ribbon is crimped over the incus. Crimping is most easily performed using a specialized crimping instrument. Nitinol prostheses (e.g., SMart pistons by Olympus) are crimped using the laser to heat the hook portion, causing the prosthesis to tighten and curve around the incus. Care should be taken to avoid overcrimping. Overcrimping may lead to necrosis of the long process of the incus in the long term.
3. Some otologic surgeons then place a drop of freshly drawn blood or Gelfoam around the fenestra and prosthesis to further seal the stapedotomy and gently support the prosthesis in place.
4. Confirmation of prosthesis placement and flap closure as described previously in steps 20 and 21

Common Errors in Technique

1. Insufficient length of the tympanomeatal flap, which fails to cover the posterior bony canal wall in the setting of needed extra curettage of the scutum
2. Improper exposure of the necessary landmarks may lead to increased operative time.
3. Mis-identifying the IS joint. Take care to feel and identify the joint space before trying to separate the IS joint. A novice mistake is to assume the IS joint is more lateral than it is and accidentally cutting the lenticular process. This is more pertinent when a bucket prosthesis is used.
4. Excessive mobilization of the incus
5. Inadequate crimping of wire-piston prosthesis. Failure to crimp or tighten the hook adequately can lead to mobilization of the prosthesis and erosion of the long process of the incus from excessive motion. Overcrimping may lead to necrosis of the long process of the incus (Fig. 133.16).
6. Suctioning near the vestibule. Even when there is blood in the oval window niche, the suction should be pointed away from the vestibule to remove the blood.

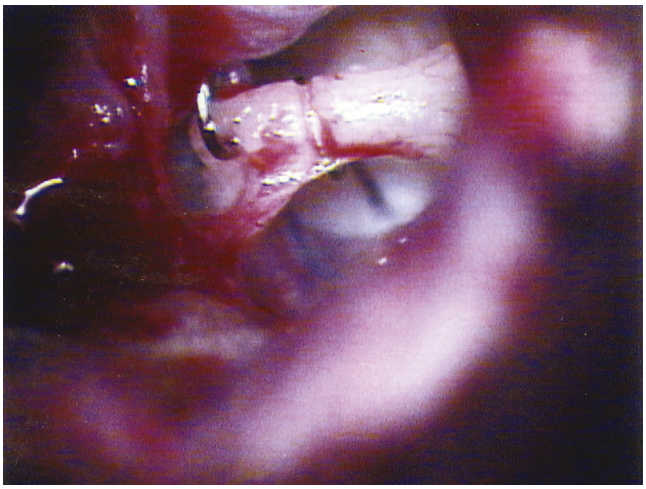

Fig. 133.16. Left ear showing a crimp-on prosthesis that had eroded the long process of the incus.

POSTOPERATIVE PERIOD

Postoperative Management

1. General
   a. Ambulatory surgery—Patients will be discharged the same day. Consider one night admission of older patients with poor mobility or advanced comorbidities.
   b. Avoid brisk head movements.
   c. Avoid heavy straining/lifting or nose blowing.
   d. Air travel should be avoided until the ear is well healed.
   e. Patients should return for follow-up in 1 to 2 weeks for removal of the packing.
   f. Postoperative audiogram is typically done between 1 and 3 months postoperatively; however, there can be continued mild improvement after that point.
   g. MRI—Patients should be notified of what type of prosthesis they have and the MRI compatibility for the particular prosthesis.
2. Medications
   a. Appropriate pain control with low-dose combination acetaminophen and opioids may be necessary.
   b. Postoperative antibiotics are not indicated.

Complications

1. Tympanic membrane perforation: If an iatrogenic perforation is small, then the surgeon can consider intraoperative medial graft tympanoplasty. However, if the perforation is large, then one should consider performing only the tympanoplasty and return at a future date to complete the stapedectomy/stapedotomy so as to reduce risk of vestibular contamination.

2. Nerve injury: Both the chorda tympani and facial nerves are at risk during this procedure. In order to avoid injury to the chorda tympani, care should be taken with elevation of the tympanomeatal flap, annulus, and entering the middle ear. Clear identification of the nerve makes injury less likely. In rare instances, the chorda tympani carries a tortuous course and may disrupt the operative view; then consideration to complete sectioning should be given. In this case, or in the case of iatrogenic injury to the nerve, care should be taken to reapproximate the nerve fibers at the conclusion of the case. Most patients will complain of temporary dysgeusia, which usually resolves over the course of several months. Injury of the facial nerve is rare. In cases where the nerve is dehiscent or overhangs the oval window, usually fastidious technique can ensure appropriate stapedotomy without injury to the nerve.
3. Ossicular dislocation: Careful elevation of the tympanomeatal flap can helps to avoid this possible complication. Ossicular dislocation may also occur in cases of aggressive palpation of the ossicles. More commonly, this issue arises when the incus is laterally displaced during placement of the prosthesis.
4. Vertigo and sensorineural hearing loss: Aggressive manipulation of the stapes can result in damage to the vestibule and cochlea, resulting in sensorineural hearing loss. Furthermore, misplacement of the prosthesis or excessive loss of perilymph can result in significant vertigo.
5. Floating stapedial footplate: This occurs as a result of down-fracture of the stapedial superstructure with resultant detachment of the remnant annular ligamentous attachment of the footplate and its displacement into the vestibule. A floating footplate can be avoided if, prior to down-fracturing, a control fenestration hole is made in the footplate. The control hole facilitates extraction of the footplate if needed with a right-angle hook. If a control hole is not made, drilling of the promontory may be necessary to engage large fragments of the footplate and subsequent extraction (Fig. 133.17A and B). Smaller fragments should be left in place, as they rarely cause hearing loss though may contribute to positional vertigo. Multiple attempts to externalize the footplate or suctioning over the vestibule may lead to untoward outcomes, including increased risk of postoperative vertigo and iatrogenic sensorineural hearing loss. If the floating stapedial footplate is not easily removed, consider applying the tissue graft and prosthesis and terminating the surgery.
6. Perilymphatic gusher: Occasionally a widely patent cochlear aqueduct may lead to excessive flow of perilymph after the vestibule is opened with the stapedotomy. In this case, the head of the bed should be elevated to decrease flow. Some authors suggest suctioning of the fluid until the reservoir at the cerebellopontine cistern is exhausted. Ultimately, a fascia, fat, or vein graft is placed over the oval window and the prosthesis positioned to hold it in place (Fig. 133.18A to C). Rarely is a lumbar drain necessary to aid in decreasing flow postoperatively.
7. Reparative granuloma: This is a rare complication occurring in approximately 0.1% of cases. Typically it occurs 1 to 6 weeks postoperatively and can be associated with vertigo, sensorineural hearing loss, and roaring tinnitus. Treatment options include steroids and antibiotics versus exploratory surgery in which the granulation tissue, prosthesis, and graft (if used) are removed and replaced.

ALTERNATIVE MANAGEMENT PLAN

As previously discussed, alternatives to surgery include dispensing of a hearing aid. Patients are able to remain functional while deciding if they want surgery. There is some literature suggesting the use of sodium fluoride and, in rare cases, bisphosphonates in the treatment of cochlear or progressive otosclerosis. Sufficient level 1 evidence is lacking to support use of these treatments, although they remain as an alternative when having a comprehensive discussion with patients.

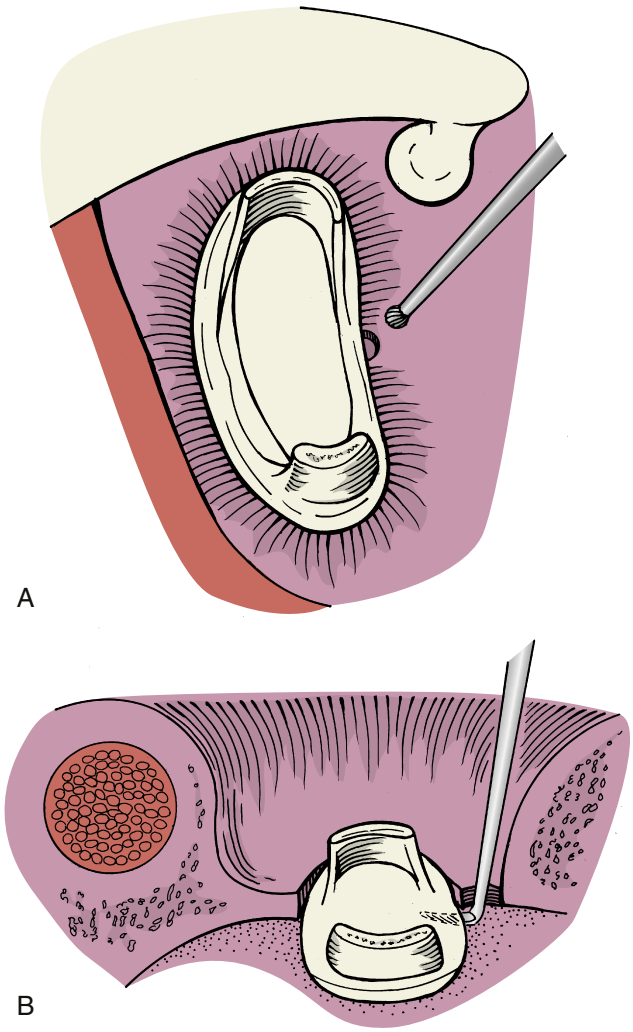

Fig. 133.17. A, Creation of a small "rescue hole" in the vestibule for removal of a floating footplate. **B,** Insertion of a fine right-angled pick through the rescue hole for retrieval of the footplate.

DISCUSSION

Evidence-Based Medicine Question

Stapedotomy versus stapedectomy—What other options exist?

More important in a historical context, stapedectomy refers to the complete removal of the stapes footplate. Currently, most otologic surgeons perform fenestration of the footplate, leaving most of it intact, a term known as *stapedotomy*. There are many variations of this surgery. We perform the surgery with a CO_2 laser, since laser appears to be a less traumatic method of entering the vestibule and carries a lower risk of footplate mobilization when compared with conventional methods, such as microdrill or manual perforation. We feel that the CO_2 laser has the advantage over other lasers of being absorbed by water and thus does not penetrate deep into the vestibule. A systematic review by Wegner et al. suggests that lasers carry

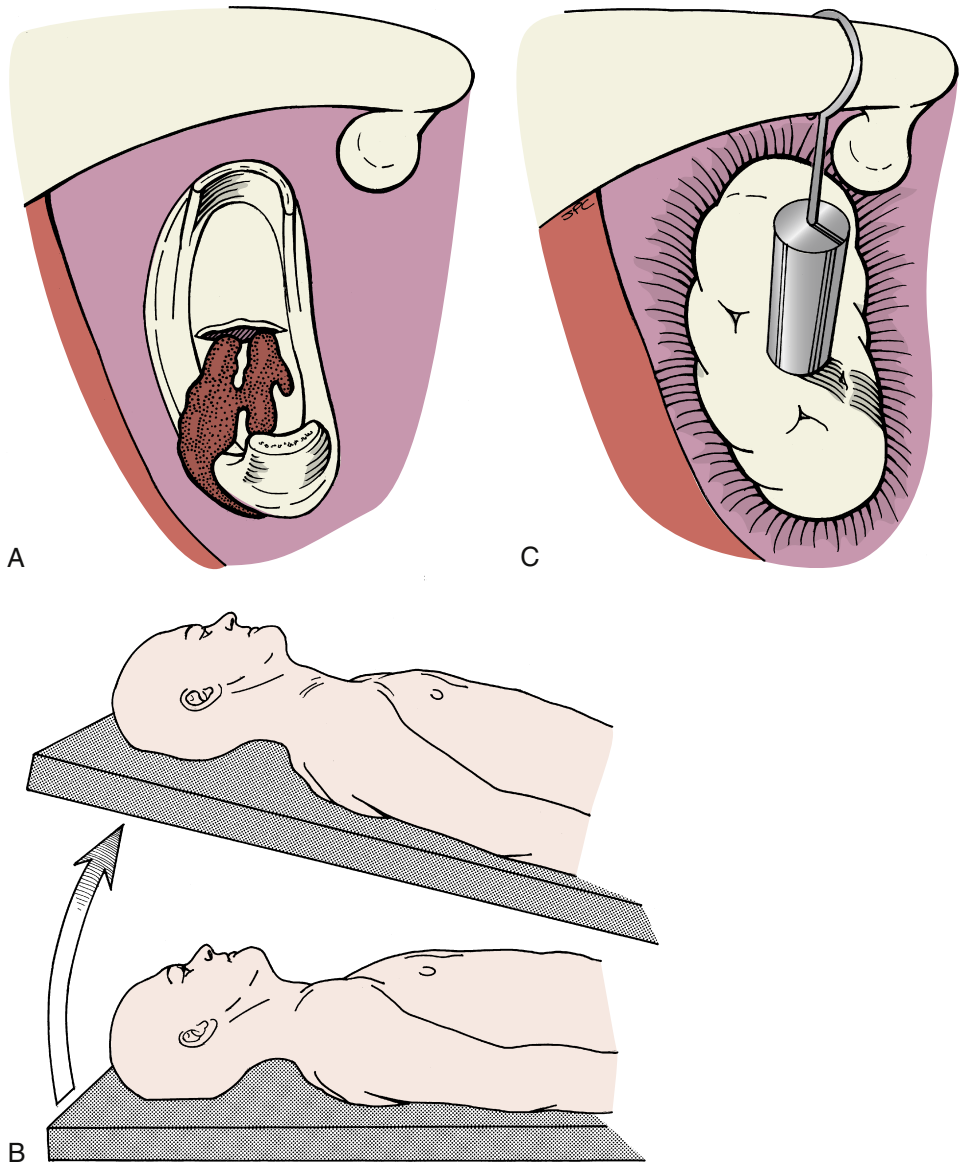

Fig. 133.18. A, A gusher of perilymph through the footplate fenestra. **B,** Reverse Trendelenburg position for relief of the perilymphatic gusher. **C,** Use of a piston prosthesis with an adipose tissue graft to seal the perilymphatic gusher.

a lower risk of sensorineural hearing loss and footplate fractures compared with conventional methods; however, studies are limited by bias and variability in methods.[7] These findings regarding improved hearing outcomes were further corroborated by Fang et al., although unfortunately they were unable to perform subgroup analysis on different laser types (KTP, Ar, Erb-YAG, CO_2) due to the small number of studies.[8] A study by Szyfter et al. comparing Er-Yag and CO_2 lasers did not show a significant difference in hearing outcomes. Farrior et al. looked at Teflon-wire pistons versus stainless-steel bucket stapes prosthesis and did not see a statistically significant difference in hearing improvement. There was a nonrandomized study by Bittermann et al. that examined vein graft versus non–vein graft and did find better results with a vein graft; however, this study was not randomized and may have been influenced by which surgeon was performing the surgery and which techniques were used, as the non–vein graft group was predominantly micropick, whereas the vein-graft group was predominantly KTP and Skeeter drill. Weit et al. compared the hearing results using adipose tissue, fascia, and vein and did not find a statistically significant difference between these three tissue types. There does not seem to be any overwhelming evidence that one method or prosthesis type is superior over all other options in terms of closure of the air-bone gap. The data that we currently have are affected by variables that are difficult to control for. Likely the most important factor is the surgeon's familiarity and comfort with a particular method and prosthesis.

Editorial Comment

Surgery of the stapes footplate remains the sole domain of the Otolaryngologist. Basic otologic skills must be mastered before proficiency in overcoming footplate fixation is achieved. Facile execution of microscopic bimanual dexterity skills are the foundation for middle ear surgery. During training, residents and fellows typically complete parts of the operative procedure. It is usually not until the surgeon has full responsibility for the patient that he/she ascends the steep learning curve to achieve enough confidence and expertise to perform the entire procedure.

The use of the laser has been of tremendous benefit in minimizing trauma to the footplate and inner ear. A floating

footplate is less likely if laser vaporization can create a fenestration, providing access for a footplate pick. Improvements in footplate drills not having "whip" provides smoother controlled thinning in obliterative otosclerosis.

Each stage in the operation must be accomplished with limited variance to avoid subsequent difficulties in the sequential steps. Inadequate patient positioning, improper design of the flap, trauma to the tympanic membrane, inadequate exposure, excessive bleeding, and a nonsedated patient are a few issues that can cascade into frustrating or unsuccessful surgery. Just as important as the execution of stapes surgery is knowing who the surgery should be offered to and predicting the postoperative anticipated results, which comes with time and experience.

Successful stapedectomy for otosclerosis is one of the most rewarding procedures we can offer. Improved hearing results are noted immediately and hopefully last a lifetime.

Barry Hirsch

Access the review questions and additional sources list online at http://www.expertconsult.com

REFERENCES

1. Chole RA, McKenna M. Pathophysiology of otosclerosis. Otol Neurotol 2001;22(2):249–257.
2. Priyadarshi S, Ray CS, Biswal NC, et al. Genetic association and altered gene expression of osteoprotegerin in otosclerosis patients. Ann Hum Genet 2015;79(4):225–237. http://dx.doi.org/10.1111/ahg.12118.
3. Ferlito A, Arnold W, Rinaldo A, et al. Viruses and otosclerosis: chance association or true causal link? Acta Otolaryngol 2003;123(6):741–746.
4. Huang TS, Lee FP. Surgically confirmed clinical otosclerosis among the Chinese. Arch Otolaryngol Head Neck Surg 1988;114(5):538–544.
5. Acar GO, Kivekäs I, Hanna BM, et al. Comparison of stapedotomy minus prosthesis, circumferential stapes mobilization, and small fenestra stapedotomy for stapes fixation. Otol Neurotol 2014;35(4):e123–e129. http://dx.doi.org/10.1097/MAO.0000000000000280.
6. Bernardo MT, Dias J, Ribeiro D, et al. Long term outcome of otosclerosis surgery. Braz J Otorhinolaryngol 2012;78(4):115–119.
7. Wegner I, Kamalski DMA, Tange RA, et al. Laser versus conventional fenestration in stapedotomy for otosclerosis: a systematic review. Laryngoscope 2014;124(7):1687–1693. http://dx.doi.org/10.1002/lary.24514.
8. Fang L, Lin H, Zhang T-Y, et al. Laser versus non-laser stapedotomy in otosclerosis: a systematic review and meta-analysis. Auris Nasus Larynx 2014;41(4):337–342. http://dx.doi.org/10.1016/j.anl.2013.12.014.
9. Vincent R, Sperling NM, Oates J, et al. Surgical findings and long-term hearing results in 3,050 stapedotomies for primary otosclerosis: a prospective study with the otology-neurotology database. Otol Neurotol 2006;27(8 Suppl. 2):S25–47. http://dx.doi.org/10.1097/01.mao.0000235311.80066.df.
10. Gupta S, Heman-Ackah SE, Lalwani AK. Are prophylactic antibiotics necessary for otologic surgery? Laryngoscope 2012;122(6):1183–1184. http://dx.doi.org/10.1002/lary.23302.

REVIEW QUESTIONS

1. Landmarks for appropriate exposure during stapedotomy include all of the following, *except*
   a. Eustachian tube
   b. Pyramidal eminence
   c. Chorda tympani
   d. Facial nerve

2. The presence of which of these findings is inconsistent with otosclerosis?
   a. Normal stapedial reflexes
   b. Air-bone gap greater than 20 dB
   c. Mixed hearing loss
   d. Normal tympanic membrane

3. Which imaging study is a prerequisite to stapedotomy?
   a. MRI with and without gadolinium
   b. CT without contrast
   c. CT with contrast
   d. No imaging study is required

ADDITIONAL SOURCES

Bittermann AJN, Vincent R, Rovers MM, et al. A nonrandomized comparison of stapes surgery with and without a vein graft in patients with otosclerosis. Otol Neurotol 2013;34(5):827–831. http://dx.doi.org/10.1097/MAO.0b013e31828bb523.

Cruise AS, Singh A, Quiney RE. Sodium fluoride in otosclerosis treatment: review. J Laryngol Otol 2010;124(6):583–586. http://dx.doi.org/10.1017/S0022215110000241.

Farrior JB, Temple AE. Teflon-wire piston or stainless-steel bucket stapes prosthesis: does it make a difference? Ear Nose Throat J 1999;78(4):252–53, 257–260.

House HP. The evolution of otosclerosis surgery. Otolaryngol Clin North Am 1993;26(3):323–333.

Roland PS, Meyerhoff WL. Intraoperative electrophysiological monitoring of the facial nerve: is it standard of practice? Am J Otolaryngol 1994;15(4):267–270.

Szyfter W, Mielcarek-Kuchta D, Miętkiewska-Leszniewska D, et al. Comparison between 2 laser systems, Er-Yag and CO2, in stapes surgery. Otol Neurotol 2013;34(1):29–35. http://dx.doi.org/10.1097/MAO.0b013e31827853c3.

Ueda H, Kishimoto M, Uchida Y, et al. Factors affecting fenestration of the footplate in stapes surgery: effectiveness of Fisch's reversal steps stapedotomy. Otol Neurotol 2013;34(9):1576–1580. http://dx.doi.org/10.1097/MAO.0b013e3182a473eb.

Uppal S, Bajaj Y, Coatesworth AP. Otosclerosis 2: the medical management of otosclerosis. Int J Clin Pract 2010;64(2):256–265. http://dx.doi.org/10.1111/j.1742-1241.2009.02046.x.

Wiet RJ, Battista RA, Wiet RM, et al. Hearing outcomes in stapes surgery: a comparison of fat, fascia, and vein tissue seals. Otolaryngol Head Neck Surg 2013;148(1):115–120. http://dx.doi.org/10.1177/0194599812463184.

134 Mastoid Surgery

Charles B. MacDonald, Joshua W. Wood

INTRODUCTION

The early indications for mastoid surgery involved drainage procedures for acute, life-threatening infections. In current practice, acute coalescent mastoiditis is infrequent and most mastoidectomies are done for chronic infection, usually with cholesteatoma—the focus of this chapter. In the modern era, mastoidectomy is an initial step in neurotologic procedures such as cochlear implantation, surgery of the endolymphatic sac and facial nerve, labyrinthectomy, temporal bone resection, and cranial base approaches to the posterior fossa and petrous apex. For all indications, competent mastoid surgery requires precise surgical sculpting of bone and sequentially identifying and delineating anatomic landmarks. Preoperative planning based on all available information is necessary and yet is usually somewhat open-ended. As disease is exposed, intraoperative decisions must be made. Should the canal wall remain up, down, or reconstructed? Should the cavity be obliterated? Should there be a second-look procedure and/or staged tympanoplasty? What is the best option for ossicular reconstruction?

Subtle variants of normal anatomy and disease extension challenge the surgeon to make appropriate pre- and intraoperative surgical decisions for optimal outcome, which should include the best possible hearing and minimal chance of recurrent/recidivistic disease.[1–4]

KEY OPERATIVE LEARNING POINTS

- In chronic ear surgery, preoperative planning, though essential, may be altered by decisions made based intraoperative findings.
- The status of the contralateral ear will influence the decisions regarding surgical options for the management of cholesteatoma.
- Skilled use of the operating microscope, otologic drill, otologic endoscopes, and micro instruments are best developed in the temporal bone dissection laboratory.
- Astute awareness of the tegmen, sigmoid sinus, otic capsule, and the vertical segment of the facial nerve must be maintained throughout the procedure.

PREOPERATIVE PERIOD

History

1. History of present illness
   - Presence and duration of hearing loss, otorrhea, otalgia, dizziness
   - Factors associated with onset of symptoms: local trauma, water exposure, barotrauma
   - Chronic or recurrent symptoms
   - Efficacy of previous medical intervention
   - Rapid progression of symptoms may require expedited surgical intervention
   - Headache or mental status change may indicate an intracranial complication
2. Past otologic history
   - Childhood ear infections or surgery
   - Hearing ability prior to the onset of current symptoms
   - Occupational or other noise exposure
   - Ototoxic medications
   - Past radiotherapy with fields including the temporal bones
   - Previous mastoid surgery
   - Otologic implant: cochlear implant, reconstructed ear canal, stapedectomy prosthesis
   - Use of amplification for either ear should be noted.
3. Status of the contralateral ear
   - Contralateral middle disease, perforation, Eustachian tube dysfunction
   - Bilateral cholesteatoma
   - Contralateral hearing loss
   - The patient may benefit from contralateral amplification prior to surgery
4. Past medical history
   - Conditions involving referred otalgia can complicate postoperative pain control
   - Past vestibular symptoms should be considered carefully
5. Medical illness
   - Conditions adversely affecting wound healing
   - Bleeding disorders
   - Conditions posing increased risk for general anesthesia
6. Medications
   - Anticoagulants
   - Drug allergy
7. Mental and social issues
   - Ability to comprehend an informed consent
   - Ability to tolerate postoperative otologic instrumentation such as mastoid cavity care
   - Compliance with long-term otologic care and likeliness to return following staged surgery

Physical Examination

- A complete otolaryngology examination including the nasopharynx and cranial nerves
- Microscopic examination of the ears with appropriate debridement
- Repeat microscopic examination after treating suppuration may be enlightening
- The ear canal may require canaloplasty for surgical exposure and postoperative care
- The contralateral ear should be carefully examined with an otologic microscope
- Photo documentation of the otologic findings may be helpful
- Rinne and Weber tuning fork tests should be recorded preoperatively
- Postauricular swelling and erythema indicate an abscess and requires emergent intervention
- Acute facial palsy or other local cranial neuropathies require rapid intervention
- Papilledema may indicate an intracranial complication

Audiometry

- Standard bilateral behavioral audiometry is strongly recommended for diagnosis and management
- Children or mentally impaired adults may require auditory evoked brainstem testing to obtain side-specific thresholds.
- Emergent surgery for intracranial complications should not be delayed for audiometry

Imaging

- When planning elective mastoid surgery, imaging is generally obtained to assist in performing safe and expeditious surgery. Nevertheless, imaging is not essential to perform mastoidectomy. For example, if unexpected cholesteatoma is encountered during tympanoplasty, a surgeon may safely proceed with appropriate mastoid surgery without preoperative images.
- Computed tomography (CT) imaging in axial and coronal planes is the standard anatomic study of the temporal bone.
  - Axial images demonstrate the extent of mastoid pneumatization and the position of the sigmoid sinus
  - Coronal images indicate the contour and level of the tegmen mastoideum and tympani
  - CT is excellent in the delineation of congenital ear malformation
  - CT demonstrates bone erosion: horizontal semicircular canal, tegmen, Fallopian canal, malleus/incus
  - CT cannot usually establish the status of the stapes in the presence of chronic ear disease
  - CT may not distinguish cholesteatoma from other soft tissue or fluid, unless bone expansion or erosion of the scutum is identified
- Magnetic resonance imaging (MRI) is the standard study to demonstrate retrocochlear pathology
  - MRI (T2 coronal) will identify an encephalocele, Gadolinium enhancement of tumor, and intracranial complications of mastoiditis
  - MRI (T2 weighted) will identify the membranous labyrinth and nerves in the internal auditory meatus
  - MRI (diffusion weighted imaging) can differentiate cholesteatoma from fluid and thickened mucosa
  - MRI does not demonstrate fine details of the middle ear and mastoid anatomy
- CT and MRI may be required for glomus tumors or lesions of the petrous apex
- CT guided surgical navigation systems may be used in select cases such as lesions of the petrous apex

Indications

- Acute coalescent mastoiditis with or without temporal bone/intracranial complications
- Cholesteatoma involving the epitympanum or mastoid
- Chronic suppurative mastoiditis without cholesteatoma
- Temporal bone resection for malignant disease
- Approach to the facial nerve for tumor, decompression, or cable grafting
- As an initial step in the majority of neurotologic surgical procedures
- Intact canal wall
  - Drainage of acute coalescent mastoiditis
  - Cholesteatoma surgery in which disease is removed or a second look is planned
  - Facial nerve surgery, cochlear implantation.
- Canal wall down (CWD)
  - Limited exposure and underdeveloped pneumatization
  - Unfavorable anatomy with disease affecting the tegmen, sigmoid sinus, and mastoid tip.
  - Cholesteatoma cannot be fully removed, requiring "exteriorization" of disease
  - Risk of surgical complication from repeat procedures is elevated
    - Horizontal canal or other otic capsule fistula
    - In the case of an only hearing ear, CWD mastoidectomy may be wise
    - Cholesteatoma matrix on an eroded footplate or widely dehiscent facial nerve
- Reconstruction of the canal wall may provide excellent exposure without long-term cavity issues. However, this may involve the use of foreign material in a contaminated field. A second look is generally advised.
- Obliteration of the mastoid cavity may make long-term care much easier but have some risk of burying cholesteatoma matrix. If foreign material such as hydroxyapatite cement is used, it will be inserted into a potentially contaminated field.

Contraindications

Patient Factors

- Excessive risk of general anesthesia
- Poor wound healing

Disease Factors

- Mastoidectomy alone is inadequate for cholesteatoma extending beyond the boundaries of the temporal bone
- Auto-epitympanotomy or auto-mastoidectomy may enable adequate exposure for debridement in the office.

Preoperative Preparation

- Control of infection with systemic/topical antibiotics and debridement when possible
- Informed consent includes understanding the chronicity of the disease, risks, and hearing outcomes
- Staged tympanoplasty or second-look procedures should be included in the consent
- The possible role of postoperative amplification should be discussed
- Optimize medical fitness for general anesthesia
- The surgeon should review clinical, audiometric, and imaging data prior to surgery.
- Imaging studies should be available for intraoperative review

OPERATIVE PERIOD

Anesthesia

- General: This procedure is performed under general anesthesia. Pharmacologic muscle relaxation should be avoided whether or not facial monitoring is employed.

Positioning

- Positioned supine with the head turned to the contralateral side, protecting the auricle and allowing the surgeon to be seated.
- The neck is in neutral position or slightly flexed to allow better line of sight down the external auditory canal (EAC).
- The facial nerve monitoring electrodes are placed and tested, if employed.
- The patient is strapped to the bed at multiple points, as rotation of the bed is likely during the procedure.

- The surgical assistant and microscope are positioned to facilitate easy access to the field and passing instruments.

Perioperative Antibiotic Prophylaxis

- A first-generation cephalosporin is usually used.
- Patients who are allergic to penicillin derivatives may receive either clindamycin or vancomycin.

Monitoring

- Facial nerve monitoring is often used.

Many surgeons routinely use facial nerve monitoring, although its use does not substitute for knowledge of and respect for the pertinent anatomy.

Instruments and Equipment to Have Available

- Tympanoplasty/mastoidectomy set—most surgeons have favorite preferences
- Otologic drill with various cutting and diamond burs
- Operating microscope, with appropriate lens (usually 225 to 300 mm)
- An otologic endoscope may be useful to view difficult areas

Key Anatomic Landmarks

Key External Landmarks

- MacEwen's triangle
- Linea temporalis
- Spine of Henle
- Cribriform fossa

Key Internal Landmarks

- Tegmen mastoideum
- Sigmoid sinus
- Posterior ear canal wall
- Digastric ridge
- Horizontal semicircular canal (HSC)
- Fossa incudis and incus
- Facial recess

Prerequisite Skills

- The most important skill to have is a detailed three-dimensional knowledge of the anatomy of the temporal bone and common variants.
- The surgeon requires otologic microsurgical skills.
- Most teaching facilities have access to a temporal bone laboratory. Dissection of specimens in the temporal bone laboratory is valuable for the acquisition and maintenance the skills needed to excel in mastoid surgery. The role of computer simulation of temporal bone surgery is evolving.

Operative Risks

- Tympanic membrane (TM) perforation
- Altered taste
  - Stretching or cutting the chorda tympani nerve results in dysgeusia. The symptoms often resolve within a few months.
- Vertigo, sensorineural hearing loss (SNHL)
  - Either, or both, can occur from dislocating the stapes footplate or violating the otic capsule.
  - Touching the incus with the drill can also cause SNHL
- Facial paralysis
  - Caused by direct trauma or thermal injury
  - If facial nerve weakness is identified postoperatively, the surgeon should wait to allow any infiltration of local anesthesia to dissipate.
  - In the case of paresis, the patient should be treated with corticosteroids and closely monitored.
  - In a case of paralysis, if the surgeon is confident that the nerve was spared, corticosteroids and electroneuronography (ENoG) are appropriate.
  - In a case of paralysis in which the integrity of the nerve is in question, then electromyography (EMG) and temporal bone CT are performed.
    - Surgical reexploration should be performed as indicated by EMG or CT scan (see Chapter 138).
- Injury to the tegmen or dura
  - Bony defects that are larger than 1 cm, or any dural injury, should be repaired to prevent the development of a CSF leak or encephalocele.
- Injury to the ossicular chain
  - All of the ossicles are at risk during the procedure, but the incus and stapes are at highest risk.
  - Dissection on the stapes should be from a posterior to anterior direction to take advantage of stabilization provided by the stapedius tendon.
- Hemorrhage from the sigmoid sinus
  - Hemostasis can often be achieved by applying pressure with Surgicel or Gelfoam soaked in epinephrine.

Surgical Technique

- The operative field, including the ear canal, is prepared with povidone-iodine or other appropriate preparative antibacterial solution.
- The surgical drapes, suction and irrigation tubing, otologic drill, and operating microscope are moved into position.
- The canal and tympanic membrane are examined and fully debrided using the operating microscope, confirming the preoperative findings.
- If a tympanomeatal flap is to be elevated in conjunction with the mastoidectomy, a four-quadrant injection is done using lidocaine with epinephrine. The proper location for this injection is the bony-cartilaginous junction (estimated by the medial-most aspect of the hair-bearing canal skin). A 1.5-inch, 25-gauge needle is used with the bevel aimed toward the bone to ensure the injection is in the proper subperiosteal plane. If the injection is performed properly, the canal skin will blanch down to the tympanic membrane.
- Topical epinephrine (1:1000) on cotton pledgets or Gelfoam can be applied as needed during middle ear and mastoid surgery. If cotton pledgets are used, they should be counted at the termination of surgery.
- If a tympanomeatal flap is to be elevated, an H-shaped vascular strip is established via an endaural approach (Fig. 134.1). The superior (12 o'clock) incision and inferior (6 o'clock) incisions are connected with a vertical incision approximately halfway between the annulus and the bony-cartilaginous junction.
- The postauricular incision is made just superior and posterior to the root of the helix and extends to the mastoid tip and is positioned several millimeters behind the postauricular crease. The incision is carried down to the loose areolar tissue overlying the temporalis fascia.
  - When a mastoidectomy is performed for access for neurotologic surgery, the incision is often placed more posteriorly to give better posterior access.
  - In children, the inferior limb of the incision is farther posterior to avoid damage to the facial nerve.



Fig. 134.1. Skin flaps within the external auditory canal. An H-shaped skin incision creates a laterally based vascular strip-type flap and a medially based tympanomeatal flap.

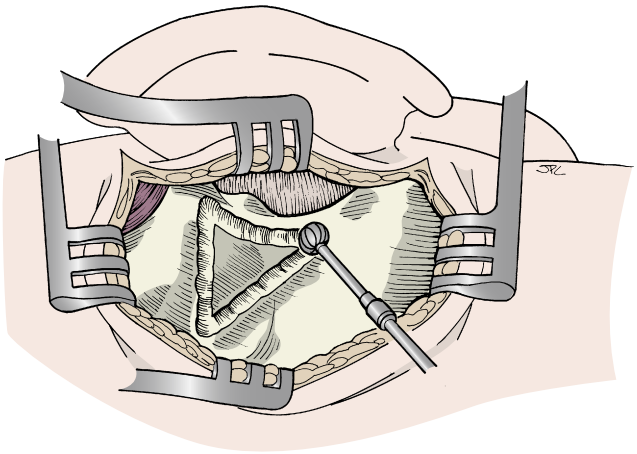

Fig. 134.2. Location and direction of the bone cuts on the mastoid cortex. The initial bone cuts roughly outline the linea temporalis, posterior external auditory canal, and sigmoid sinus.

- The mastoid cortex is exposed by incising the periosteum along the linea temporalis, and a vertical limb in a "T" or "7" shape. The posterior ear canal is then exposed, and the vascular strip is elevated. The pinna is then retracted anteriorly with a Penrose drain or tracheotomy tape placed through the postauricular incision and brought out through the EAC.
  - The external landmarks including the spine of Henle and cribriform fossa should be identified.
- A temporalis fascia graft can be harvested at this point and set aside.

Intact Canal Wall Mastoidectomy

- The initial drilling on the mastoid cortex should form a triangle, as shown in Fig. 134.2. The cortex is removed and the air cell system is exposed.
- As drilling progresses, the deepest portion should always be over the antrum, which is approximated by MacEwen's triangle. This will ensure that the antrum will be entered before reaching the plane of the facial nerve.
- The tegmen will be visible as a pink color change in the bone superiorly in the mastoid cavity, and often small veins indicate close proximity to the dura. The sigmoid sinus likewise will be indicated by a blue color change posteriorly.
- Using the tegmen as the superior landmark and the EAC as the anterior landmark, Koerner's septum is removed and the antrum is entered.
- The bur is downsized and drilling continues toward the root of the zygoma until the HSC and incus within the fossa incudis are seen (Fig. 134.3).
- If a vascular strip was elevated, this should be replaced into the canal, and the canal should be packed with either Telfa or Gelfoam.
- The wound is closed in multiple layers.
  - The mastoid periosteum should be reapproximated to avoid retraction of the skin into the postauricular defect.
  - The deep layer of the skin is closed with 3-0 or 4-0 Vicryl, and the superficial skin is closed with 5-0 fast-absorbing plain gut suture.
  - The incision is then dressed as desired, and a Glasscock cup is applied for 24 hours.

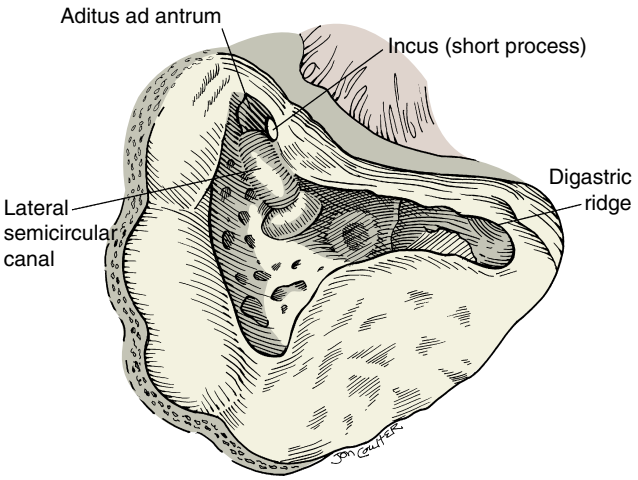

Fig. 134.3. Completed intact canal wall mastoidectomy. The aditus ad antrum, the short process of the incus, the horizontal semicircular canal, and the digastric ridge are all visible.

Drilling the Facial Recess

- Defined by the incus buttress, the other boundaries of this potential triangular space are the vertical facial nerve and the chorda tympani nerve. The facial recess allows access into the middle ear via a posterior tympanotomy.
- One must identify the landmarks for the facial nerve, including the HSC, fossa incudis, and the digastric ridge. The short process of the incus points to the second genu of the facial nerve and is in the same plane as the facial nerve. The second genu of the facial nerve is just inferior and medial to the HSC. The cephalic edge of the digastric ridge leads to the stylomastoid foramen.
- Removal of bone proceeds just inferior to the incus buttress by drilling parallel to the course of the facial nerve. Adequate thinning of the posterior wall of the ear canal is an essential element in the facial recess approach. Copious irrigation prevents thermal damage and enhances visualization by removal of bone dust.
- The safest point of entry is the superior aspect of the recess, as it is widest at this point.

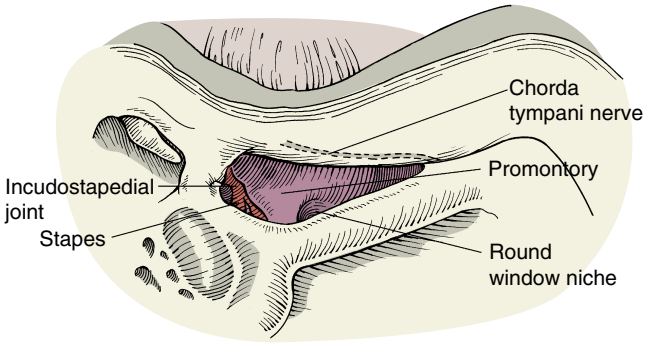

Fig. 134.4. Exposure of middle ear structures through the completed facial recess.

- Once the recess has been entered, drilling can continue medial to the chorda tympani to expand the view into the middle ear. Bone can also be removed as needed from the facial recess.
- The recess can be further expanded to view the middle ear structures including the incudostapedial joint, round window niche, and promontory (Fig. 134.4).
  - Sacrificing the chorda tympani in an extended facial recess approach enables removal of bone as far as the inferior tympanic annulus, exposing the medial surface of the TM and the hypotympanum.

Canal Wall Down Mastoidectomy

- It is especially important to saucerize the bony edges of the mastoidectomy superiorly and posteriorly to reduce the size of the mastoid cavity.
- The bone over the second genu and vertical portion of the facial nerve is thinned.
  - Inadequate removal of bone leads to a high facial ridge, which makes subsequent cleaning of the mastoid cavity difficult.
- The EAC can now be removed, typically with a 4-mm cutting burr, as shown in Fig. 134.5. The area to be drilled can be conceived as the anterior buttress (tympanosquamous suture line and lateral wall of the epitympanum), the posterior buttress (the facial ridge), and the intervening bridge of bone.
- Addressing the incus is an important step.
  - Frequently, the disease requires the incus to be removed. In this case, the incudostapedial joint should be separated before removing the canal wall.
  - If the incus can be left, a thin bridge of bone is left overlying the short process and is removed with a pick or curette.
- Reconstruction of the middle ear space is accomplished by packing the middle ear with Gelfoam.
  - The previously harvested and dried fascia is then placed in an underlay fashion by draping the graft onto the horizontal facial nerve superiorly and onto the facial ridge posteriorly, followed by further packing lateral to the residual TM and graft.

Bondy-Modified Radical Mastoidectomy

- Bondy mastoidectomy refers to the removal of the posterior canal for attic disease, without entering the middle ear space. It is usually used in the presence of attic cholesteatoma, which developed lateral to the ossicular chain without violating the pars tensa of the TM.
- The epitympanic cholesteatoma can be exteriorized through an endaural approach.

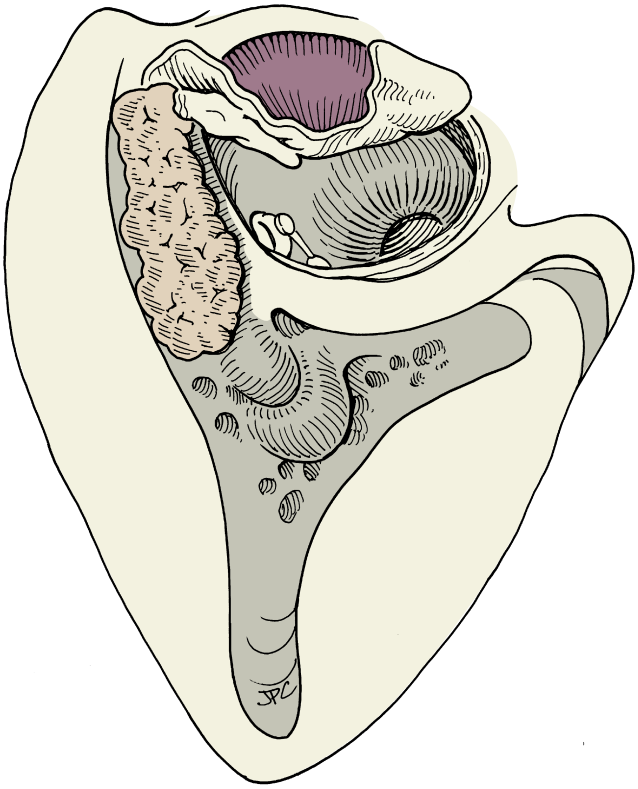

Fig. 134.5. Completed canal wall down mastoidectomy cavity.

- The anterior buttress (as described previously) is removed, and the superior canal wall is lowered to the level of the incus.
- The cholesteatoma matrix is left in place as the epithelial lining of the exteriorized epitympanum.

Radical Mastoidectomy

- This procedure is used in cases where the middle ear disease is irreversible and cannot be fully addressed with a CWD procedure.
- The procedure started with a CWD mastoidectomy
- The malleus, incus, and TM are removed, and reconstruction is not attempted.
- The middle ear mucosa is removed, and the Eustachian tube orifice is obliterated with a soft-tissue graft such as muscle, adipose tissue, or fascia
- The entire middle ear cavity is thus exteriorized into the EAC and mastoid bowl.

Meatoplasty

- This should always be performed when the posterior canal wall is removed, and ensures easy access to the mastoid cavity for in-office cleaning.
- Any meatoplasty will change the orientation of the pinna to some degree and may lead to a cosmetic defect.
  - The meatus should be sized to allow access to the superior, posterior, and inferior portions of the mastoid bowl.
  - Meatoplasty should be made with the expectation of some contracture during wound healing.
- An incisural meatoplasty involves extending the superior radial incision of the vascular strip into the incisura. The conchal bowl can then be pulled posterior and the secured to the postauricular area with 3-0 Vicryl sutures.

- This technique is limited in that aggressive enlargement of the size of the meatus may create a cupped ear deformity.
- Another technique involves removal of a crescent of conchal bowl cartilage.
  - The conchal cartilage is exposed at its medial aspect from posterior to the pinna, elevated from the anterior overlying skin, incised, and removed.
  - The subcutaneous skin of the conchal bowl is then pulled posteriorly, and 3-0 Vicryl sutures are used to secure the posterior meatal skin to the deep periosteal tissue posterior to the mastoidectomy cavity.
- The meatus is then typically stented with a roll of Telfa, a meatal expansile wick, or continuous antibiotic impregnated gauze for 10 to 14 days.

Common Errors in Technique

- Inappropriate choice of drill burs
  - Generally, larger burs are easier to control.
  - If a cutting bur touches bone on more than one side, then it will vibrate and be difficult to control.
  - Cutting burs do not work well at the depth of the mastoid tip.
  - Diamond burs can contact bone on more than one side and can be used at the tip.
  - Diamond burs generate heat rapidly.
- Inadequate saucerization
  - It is important to saucerize the edges of a CWD mastoid cavity to lower the profile of the cavity and provide adequate visualization of deeper structures.
  - In CWD mastoidectomy procedures, inadequate saucerization willprevent the soft tissues from collapsing into the mastoid cavity. This will ultimately lead to a larger mastoid cavity.
- Inadequate meatoplasty
  - This will result in accumulation of debris and contributes to chronic otorrhea.

POSTOPERATIVE PERIOD

Postoperative Management

- Evaluation of facial nerve, tuning fork tests, and dizziness/nystagmus in the recovery room area
- Restricted activity levels during the early postoperative period
- Home application of topical antibiotic or lavage with appropriate rinses once packing is removed
- Periodic office debridement

Complications

- Hematoma or bleeding require surgical control. The most common bleeding complication occurs from the sigmoid sinus or jugular bulb and is easily controlled with gentle pressure with Surgicel or Gelfoam in most instances.
- Conductive or SNHL. Conductive hearing loss can occur from damage to the ossicular chain or tympanic membrane, which should be repaired by ossicular chain reconstruction or tympanoplasty. SNHL can occur from damage to any part of the inner ear, including oval and round windows, or semicircular canals. Should the inner ear be violated, the area of injury should be packed with soft tissue to prevent further damage to the inner ear.
- Facial paresis or paralysis. This can occur from direct or indirect damage. The management options are complex and hingers on the integrity of the facial nerve. This complication is discussed in greater detail in the Operative Risks and Evidence-Based Medicine sections of this chapter.
- Injury to the dura creating a CSF leak. Any bony defect that are larger and 1 cm, or any dural injury, should be repaired to prevent the development of a CSF leak or encephalocele.
- Early postoperative infection. This is relatively uncommon but requires aggressive antibiotic therapy to ensure proper healing of the operated field.

Alternative Management Plan

- If surgery for cholesteatoma is deferred, periodic debridement with home lavage of the ear may control disease. Topical and systemic antibiotics may be required intermittently.

DISCUSSION

Evidence-Based Medicine Question

How can the risk of facial nerve injury be minimized during mastoid surgery?

Damage to the facial nerve is a serious and feared complication of mastoid surgery. Although the risk is quite low, reported as less than 1% for primary cases and 4% to 10% for revision cases, it is nonetheless important for any ear surgeon to understand how to minimize the risks of this potentially devastating complication.[5] Otological surgery represented 17% of all iatrogenic facial nerve injuries, and mastoid surgery was responsible for 82% of these otologic iatrogenic injuries.[6]

The most fundamental technique in mastoid surgery is identification of landmarks. In this regard, the knowledge of the complex anatomy of the temporal bone is the most important protection against facial nerve injury. The major landmarks for identification of the facial nerve include the lateral semicircular canal, the short process of the incus, and the posterior bony external ear canal. The minor landmarks are the digastric ridge, the cochleariform process, and the oval window. The major landmarks should be exposed in each case, and minor landmarks used in selected cases.[7] It is our contention that the stapes/oval window is a major landmark for the facial nerve. The surgeon should also be familiar with the normal variants of the facial nerve.

The surgeon must ensure identification of MacEwen's triangle and drill strictly over this area until the mastoid antrum and lateral semicircular canal are identified. Novice surgeons have a tendency to drill inferiorly and posteriorly to the antrum, which puts the facial nerve at risk. In cases where the antrum is difficult to identify, drilling in an anterior and superior direction is advocated. The second genu of the facial nerve is the most commonly damaged segment during mastoid surgery and is found at the posterior edge of the oval window and medial to the short process of the incus.[7]

Over the past few decades, the use of intraoperative nerve monitoring has become more prevalent. Although monitoring can help with identification of the nerve and give a warning signal, it is not a substitute for anatomical landmarks. A recent publication showed that 49% of respondents felt that facial nerve monitoring should be used as the standard of care in chronic ear surgery. There is a trend among academic faculty and younger surgeons to use nerve monitoring more regularly.[5]

Editorial Comment

Mastoidectomy is the key approach providing initial entry to many otologic procedures. Chronic inflammation of the mastoid and middle ear requires cleaning of the diseased cells and mucosa to achieve removal and provide healthy aeration.

Extensive cholesteatoma may require removal of the posterior canal wall to provide access both at the time of the procedure and post operatively for care of the cavity.

Mastoidectomy is the essential procedure needed for placement of a cochlear implant, gaining access to repair a mastoid tegmen defect for encephalocele or CSF leak, facial nerve decompression for lateral trauma, access to the mastoid and hypotympanum for excision of a glomus tumor, endolymphatic sac decompression, labyrinthectomy for vertigo, and resection of vestibular schwannoma via a translabyrinthine approach. The surgeon must appreciate the 3-dimensional anatomy as the dissection proceeds from lateral to medial. Critical structures include the dura, sigmoid sinus, facial nerve, ossicles, and otic capsule. The authors emphasize the benefit achieved with repetitive hands on experience gained in the temporal bone laboratory. In the clinical setting, CT imaging provides the road map for varied anatomy that should be identified in the films and anticipated during the surgery. Repetition of the mastoid procedure builds experience and provides greater comfort with subsequent approaches. However, to avoid complications, focused vigilance must be maintained throughout the procedure.

Barry Hirsch


Access the review questions and additional sources list online at http://www.expertconsult.com

REFERENCES

1. Sheehy JL. Otolaryngology. In: English GL, editor. Surgery for Chronic Otitis Media. Philadelphia: JB Lippincott; 1989.
2. Sheehy JL, Patterson ME. Intact canal wall tympanoplasty with mastoidectomy. A review of eight years' experience. Laryngoscope 1967;77:1502–1542.
3. Gantz BJ, Wilkinson EP, Hansen MR. Canal wall reconstruction tympanomastoidectomy with mastoid obliteration. Laryngoscope 2005;115:1734–1740.
4. Dornhoffer JL. Retrograde mastoidectomy with canal wall reconstruction: a follow-up report. Otol Neurotol 2004;25:653–666.
5. Hu J, Fleck TR, Xu J, et al. Contemporary changes with the use of facial nerve monitoring in chronic ear surgery. Otolaryngol Head Neck Surg 2014;15(3):473–477.
6. Hohman M, Bhama PK, Hadlock TA. Epidemiology of iatrogenic facial nerve injury: a decade of experience. Laryngoscope 2014; 124:260–265.
7. Ryu N-G, Kim J. How to avoid facial nerve injury in mastoidectomy. J Audiol Otol 2016;20(2):68–72.

REVIEW QUESTIONS

1. All of the following are common reasons for failed CWD mastoidectomy *except*:
   a. Residual disease left in the epitympanum
   b. Tympanic membrane perforation
   c. High facial ridge
   d. Inadequate meatoplasty

2. All of the following statements are accurate regarding a Bondy-modified radical mastoidectomy except;
   a. The posterior ear canal wall is left intact
   b. The epitympanum is cleared with a postauricular approach
   c. It involves reconstruction of the ossicular chain
   d. The cholesteatoma matrix is left in place as the epithelial lining of the exteriorized epitympanum

3. What is the relationship of the second genu of the facial nerve to the HSC?
   a. CN VII is lateral and posterior to the HSC
   b. CN VII is medial and posterior to the HSC
   c. CN VII is medial and anterior to the HSC
   d. CN VII is lateral and anterior to the HSC
   e. CN VII is medial and inferior to the HSC

ADDITIONAL SOURCES

Bento RF, Carolina A, Fonseca O. A brief history of mastoidectomy. Int Arch Otorhinolaryngol 2013;17(2):168–178.

Gluth MB, Metrailer AM, Dornhoffer JL, et al. Patterns of failure in canal wall down mastoidectomy cavity instability. Otol Neurotol 2012;33(6):998–1001.

Thiel G, Rutka JA. Pothier DD: The behavior of mastoidectomy cavities following modified radical mastoidectomy. Laryngoscope 2014;124:2380–2385.

135 Bone-Anchored Hearing Devices

Yael Raz, Douglas M. Hildrew

INTRODUCTION

- Bone-anchored devices conduct sound through bone vibration, bypassing the external and middle ear conductive apparatus
- Useful in patients with conductive or mixed hearing loss who cannot benefit from conventional amplification and are not candidates for surgical correction of their hearing loss
- Also useful in patients with single-sided deafness, as the sound coming to the deafened side can be transmitted by bone vibration to the intact contralateral cochlea with little cross-cranial attenuation
  - Does not provide sound localization but reduces the head shadow effect
- Two general types of devices
  - Percutaneous: sound processor delivers acoustic signal to the osseointegrated implant via direct coupling to an abutment that projects through the skin
    - Consists of three parts: a titanium implant that is osseointegrated into the skull, an abutment that couples the implant to the sound processor, and the sound processor
    - Baha Connect (Cochlear):
      - Baha DermaLock: 6, 8, 10, 12, and 14 mm abutments
        - Cochlear's DermaLock surface technology covers the abutment surface with a hydroxyapatite layer
          - Designed to allow use without thinning of the surrounding soft tissue
      - Cochlear also makes a titanium abutment without a hydroxyapatite covering, offered in 6-, 9-, and 12-mm lengths
    - Ponto (Oticon)
      - Ponto BHX Implant: 6-, 9-, 12-, and 14-mm abutments
  - Transcutaneous—skin remains intact. Connection established via magnet
    - Alpha2 MPO (Sophono/Medtronic)
    - Baha Attract (Cochlear)
- Percutaneous strategies have the advantage of direct coupling and therefore better sound transmission.
  - It is estimated that transmission through the skin (transcutaneous) accounts for 10- to 12-dB sound attenuation.[1]
- Percutaneous devices carry a significant risk of soft tissue reaction at the skin–device interface, reportedly as high as 38% to 56%.[2,3]

KEY OPERATIVE LEARNING POINTS

- Successful implantation of a bone-anchored hearing device relies on osseointegration of the implant.
  - Disposable drill bits ensure a sharp bit for each step.
  - Irrigation prevents thermal damage.
  - The implant is inserted with a high-torque drill at slow speed to avoid thermal damage to the surrounding osteocytes.
- Electrocautery to the skin surrounding the percutaneous abutment is minimized to help ensure formation of a healthy skin–abutment interface.
- The deep dermis should be sutured to the periosteum surrounding the abutment to ensure a healthy skin–abutment interface.

PREOPERATIVE PERIOD

History

- Radiation, severe osteoporosis, and Paget disease can affect the quality of the bone.
  - Torque applied when the fixture is tightened may have to be adjusted accordingly
- Previous surgical history (mastoidectomy, craniotomy), presence of a ventriculoperitoneal (VP) shunt, or history of a temporal bone fracture will influence device type/location/incision.
- If the patient has ipsilateral intracranial/extracranial pathology that will require magnetic resonance imaging (MRI) for surveillance, the patient and corresponding treatment team should be adequately informed before implantation.
  - MRI performed with an implant magnet in place results in significant artifact that can adversely affect visualization of nearby pathology.
    - Artifact may extend over 11 cm.
  - Baha Attract—internal magnet approved for 1.5 Tesla
  - Alpha 2 (Sophono)—internal magnet approved for 3 Tesla
- Patients who form keloids are particularly prone to develop adverse soft tissue reactions.

Physical Examination

- Check for the presence of scars and/or VP shunt tubing that may impact the placement of the incision or the device.
- In patients with microtia/atresia, if auricular reconstruction is planned, a decision regarding the placement of the device should be made with the planned reconstruction flaps in mind.
  - The device may have to be placed more posteriorly to avoid contacting the anticipated rim of the reconstructed auricle.
    - This prevents disruption of the vascular supply to the temporoparietal skin flap used for its coverage.

Imaging

- Generally not indicated for preoperative planning
  - It should be confirmed that patients undergoing a procedure for the indication of single-sided deafness have been appropriately evaluated for internal auditory canal (IAC)/cerebellar pontine angle (CPA) pathology prior to surgery
- In certain patients where there is concern about the thickness of the bone, CT can be useful.
  - Children with craniofacial anomalies, such as Treacher Collins syndrome or microcephaly, are more likely to have thin cortical bone or a low-hanging middle fossa tegmen.

Indications

- There are two indications for bone-anchored devices:
  - Unilateral profound hearing loss
    - Patient must have excellent hearing in the contralateral ear (air conduction pure tone average [PTA]) ≤ 20 dB).
  - Mixed or conductive hearing loss and patients who are not candidates for conventional amplification/ossiculoplasty (i.e., because of atresia with unfavorable middle ear anatomy, chronic otorrhea after a canal wall down mastoidectomy, history of canal closure as part of lateral temporal bone resection, and/or allergy to ear mold material)
    - Patients with a mixed loss must have a bone line PTA equal to or less than 45 dB to be fitted with the Baha 5 processor, equal to or less than 55 dB for the larger Baha 5 Power processor, and equal to or less than 65 dB sensorineural hearing loss (SNHL) with the SuperPower, which has a behind the ear (BTE) component.
    - Patients with a mixed loss must have a bone line PTA equal to or less than 45 dB to be fitted with the Ponto, Ponto Plus, or Ponto Pro processors and equal to or less than 55 dB for the Ponto Power Plus and Ponto Pro Power processors.
- Patients should experience a benefit with the demonstration device in the office.
  - If the patient is a candidate for a transcutaneous (magnet-based) coupling, the demonstration device should be attached to a soft band during the trial.
    - A soft band more closely approximates the benefit of a transcutaneous device.
  - If the patient is a candidate for a percutaneous (direct-coupling) device, the demonstration device should be attached to a more rigid over-the-head metallic tension band.
    - A tighter metallic headband more closely approximates the benefit of a percutaneous device.
    - Advantages of the percutaneous devices include
      - No dampening of signal at the skin
        - Better sound transmission
      - Less artifact on MRI
        - The large magnets of the transcutaneous devices cause significant scatter and are not well suited for patients who need serial imaging for pathology located near the device.
      - Better retention of the processor
      - Preferable in patients with very thin/frail skin
        - A transcutaneous device may risk skin dehiscence and/or erosion.
    - Advantages of the transcutaneous devices include
      - Good cosmesis
      - No requirements for abutment care
      - Significantly lower rates of skin complications compared with the percutaneous device (infections, skin overgrowth)
      - Easier handling for patients with manual dexterity issues
      - Ability to be converted to a percutaneous device if hearing deteriorates
        - If implantation is started with the a percutaneous device, the skin overlying the device would be compromised and it would be difficult to convert to a transcutaneous system.

Contraindications

- Patients who have lived with unilateral profound SNHL may not report much of a benefit compared with those who have recently become deafened.
- Bone-anchored hearing devices are US Food and Drug Administration (FDA)–approved for children 5 years of age or older.
  - Children less than 5 years of age can be fitted with a processor attached to a soft band.
- Caution is advised in patients with reduced hearing and a bone line greater than 55 dB in considering a bone-anchored hearing device.
  - Although the higher-power devices can allow patients with bone lines up to 55 to 65 dB to get benefit, it is helpful to get a sense of the rate of deterioration in hearing.
  - If the hearing is deteriorating rapidly, the patient may quickly lose benefit from the bone-anchored hearing device and a cochlear implant may be more advisable.
- Relative contraindications
  - Radiation, severe osteoporosis, Paget disease, presence of a VP shunt, and patients prone to keloid formation.
  - If the patient has pathology close to the ear that requires monitoring with MRI, a percutaneous device is preferable to a transcutaneous device.
  - Some patients with developmental delay, psychiatric issues, and/or autism spectrum disorders may not be able to perform the hygiene necessary to keep an abutment site healthy.
    - If possible, consider a transcutaneous device.

Preoperative Preparation

- Until approximately age 9, it is recommended that a two-stage approach be used.
  - At the first stage, the implant (fixture) is placed but the abutment or magnet is not attached. Instead, a cover screw is used to maintain patency of the inner threads of the implant.
    - In children, consideration should also be given to insertion of a "sleeper" implant.
      - This is maintained under the skin with a cover screw and serves as a backup in case of failure of osseointegration or secondary trauma with loss of the initial fixture.
  - After allowing for a 3- to 6-month time period for osseointegration, at the second stage the cover screw is removed and the abutment and/or magnet is attached.
- Two-stage surgery should also be considered for adults in the setting of abnormal (irradiated) bone or when insertion of a bone-anchored hearing device is being performed in conjunction with another surgery such as excision of an acoustic neuroma.
- Although in most adults the skull is thick enough to accommodate a 4-mm implant, it is good practice to have a 3-mm countersink and a 3-mm implant available for every case.
- An appointment with an audiologist is typically scheduled prior to surgery so that information regarding the use of the processor and warrantees can be reviewed.
  - The color of the sound processor should also be selected ahead of surgery, since the internal and external components are typically ordered simultaneously

OPERATIVE PERIOD

Anesthesia

Usually general, although this can be performed under local anesthesia in adults.

Positioning

Supine, head turned toward the contralateral side

Perioperative Antibiotic Prophylaxis

First-generation cephalosporin IV prior to incision

Monitoring

None necessary

Instruments and Equipment to Have Available

- Surgical instruments
  - Depending on which company and/or system is used, the needs may include a dummy device, raspatorium, dissector, drill, drill indicator, torque wrenches, screwdrivers, and abutment inserter.
  - For the transcutaneous devices, additional instruments that may be needed include the dummy device, soft tissue gauge, bone bed indicator, and implant magnet template.
- Company-specific drill console
- Drilling disposables: ¾-mm conical guide drill, 3- and 4-mm widening (countersink) drill.
  - Additional disposables for the percutaneous devices include a healing cap and a 5-mm biopsy punch.
- Implants (Baha, Ponto) come in multiple variations.
  - Fixture length can be either 3 or 4 mm.
    - This will depend on skull thickness as determined with the guide drill.
  - The implant can come separate, or preattached to the abutment.
    - Steps vary depending on the surgeon's choice of a single-stage procedure (preattached) or two-stage procedure.
      - For a two-stage procedure, the implant is covered with a cover screw before skin closure instead of the placing the abutment or magnet.
        - The abutment or magnet may then be placed during a second procedure after full osseointegration has taken place.
- In addition to the company-specific drill console, a conventional otologic drill should be available for the transcutaneous devices.
  - It may be necessary to drill down bone surrounding the implant site so that the magnet lies flush with bone around its entire perimeter.

Key Anatomic Landmarks

- For the percutaneous device, the implant site is typically 50 to 55 mm from the EAC. For the transcutaneous device, the implant site is typically 50 to 70 mm from external auditory canal (EAC).
  - In using the dummy device to mark out the planned implant site, the top of the dummy should line up with the superior aspect of the helix.
  - The procedure may have to be modified depending on patient anatomy—presence of scars, craniotomies/plates/mesh.
  - Particular caution is called for with microtia patients who will be undergoing reconstruction in the future so as not to interfere with vascular supply for planned reconstruction.

Prerequisite Skills

- Experience in otologic surgery.
- The surgeon should be aware that the drills/burrs and other instruments used are specific to each company and to this procedure.

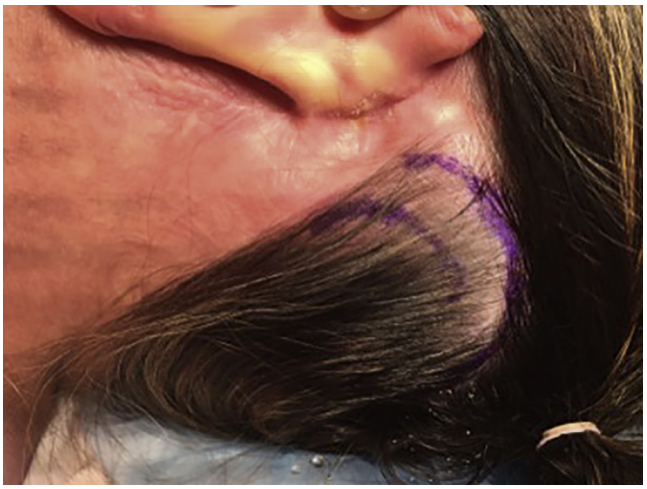

Fig. 135.1. When the Baha transcutaneous device is being implanted, typically a C-shaped incision is made with a posteriorly based flap.

- Trainees will have to familiarize themselves with the company-specific equipment ahead of time, ideally in a Temporal Bone Laboratory.

Operative Risks

- Failure of osseointegration
- Bone, epidural, or sigmoid sinus bleeding
- Cerebrospinal fluid leak
- Percutaneous: adverse soft tissue reaction including overgrowth of skin surrounding the abutment and infection at skin–abutment interface.[3]
- Transcutaneous: numbness of scalp, thinning of skin overlying magnet or exposure of the magnet, discomfort at the site from pressure between the external and internal magnets, higher risk of hematoma since a flap is elevated.

Surgical Technique

- This chapter focuses on technique for the transcutaneous Baha Attract and the percutaneous Baha Connect using a preattached abutment (Baha FAST).
- Baha Attract (transcutaneous).
  - Mark the optimal location of the dummy device.
    - Align the superior aspect of the dummy with the superior aspect of the auricle, 50 to 70 mm from the EAC.
    - The incision should be greater than or equal to 15 mm from the planned magnet location.
    - Typically a C-shaped incision is used with a posteriorly based flap (Fig. 135.1).
      - This allows room for the incision to be extended further posteriorly if the bone at the planned drilling site proves inadequate.
    - An incision that makes a 180-degree arc around the implant site will allow the drilling to be performed in a perpendicular fashion.
    - The incision may have to be modified in patients with previous incisions.
      - Previous postauricular incision can be incorporated as the anterior aspect of the Attract incision, with superior and inferior limbs extending posteriorly at 90-degree angles to the old incision to create a posteriorly based flap.
      - Alternatively, an inferiorly pedicled C-shaped flap can be used to avoid the previous scar.

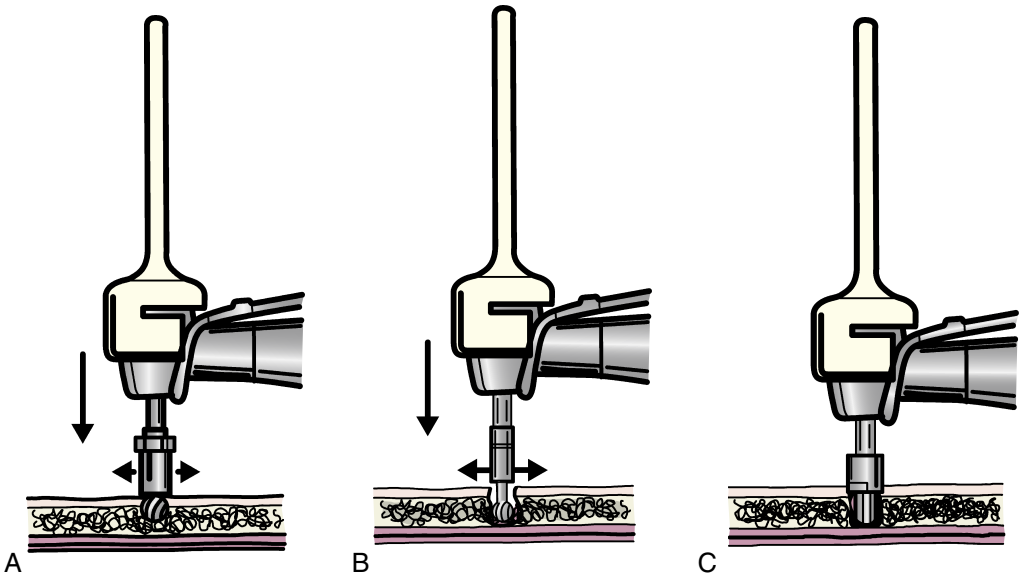

Fig. 135.2. A, Drilling begins with the use of the guide drill and a plastic spacer to ensure a depth no greater than 3 mm. **B,** The spacer is then removed and, if cortical bone thickness is sufficient, the guide hole is drilled to a depth of 4 mm. **C,** The appropriately sized countersink is then used.

- It is helpful to mark the bone at the intended implant location with methylene blue.
  - Use a 25-gauge needle on a 1-mL syringe and carefully remove all of the bubbles, making sure that the dye fills the tip of the needle.
    - Keeping the needle tip firmly against the bone, the syringe is then rotated back and forth and a few gentle taps are applied to the plunger.
      - The goal is to mark the bone without coating the soft tissue overlying the bone with excess dye.
- Lidocaine 1% with 1:100,000 epinephrine is injected along the planned C-shaped incision
- The postauricular region is then prepped and draped.
- Incision is carried down to the periosteum, leaving the periosteum intact.
  - Elevation is continued in the plane overlying the periosteum until the planned drilling site is identified (methylene blue is seen).
  - Further elevation is necessary in the central region to allow the posterior aspect of the magnet to fit under the skin flap.
    - The implant magnet's template can be used to make sure that the flap has been adequately elevated.
- A cruciate incision is made in the periosteum at the planned drilling site and the periosteal flaps are elevated with a raspatorium.
- The bony contours surrounding the drill site should be carefully inspected at this point.
  - The implant site can be moved a few millimeters if the bone surface is irregular/depressed.
    - Within the topography of the squamosa, it is preferable to place the fixture on a "mountain" rather than in a "valley."
      - The magnet must vibrate freely without contacting surrounding bone.
    - Optimizing placement of the device will save time in later steps of the procedure by maximizing chances that the bone bed indicator will not hit adjacent bone.
- The ¾-mm guide drill is used with the plastic spacer in position under copious irrigation at a drill speed of 2000 rpm (Fig. 135.2).
  - It is vitally important to make sure that this initial drilling is performed perpendicular to the bone. An angled approach at this juncture will affect all the subsequent steps and result in a "tilted" implant.
    - This will require the use of the otologic drill to take down surrounding bone in order to allow the magnet to sit properly without abutting adjacent bone.
  - A drill indicator attachment can be used to facilitate visualization of the drill's trajectory.
  - After use of the guide drill, the dissector is used to determine whether there is bone or dura at the depth of the drill site.
    - Osseointegration may be impaired by the absence of bone at the deep surface of the implant.
    - In most adults, the bone thickness is sufficient to accept a 4-mm device. This longer fixture is preferable when possible.
- If sufficient bone is encountered with the 3-mm guide drill, the plastic spacer is taken off and drilling is resumed to allow the conical guide drill to reach a 4-mm depth at 2000 rpm under irrigation.
  - If the initial drill site does not have sufficient bone depth, alternate sites can be attempted.
    - If multiple attempts do not reveal bone depth sufficient to handle a 4-mm device, a 3-mm countersink is used and followed by a 3-mm implant.
  - If there is sufficient bone depth, a 4-mm countersink is used under copious irrigation at a drill speed of 2000 rpm.
    - The countersink drill widens the guide hole to an appropriate diameter and creates an even surface for the small flange at the lateral aspect of the implant.
    - If the initial angle of drilling was successfully performed in a trajectory perpendicular to the bone, a 360-degree shallow countersink ring should be apparent at the margin of the drill site.
      - This ensures there is not a step-off when the implant is affixed.
- The appropriate length fixture is opened (3 or 4 mm).
- Very important: the fixture should not be handled directly but rather maintained within the plastic ampule, which is stabilized within the Baha tray.

- While still seated within the plastic ampoule, the fixture is loaded onto the drill using the implant inserter.
  - Visually aligning the triangular aspect of the inserter with the respective triangle in the head of the implant facilitates this step.
  - A click should be felt when the fixture engages.
- Before the fixture is engaged with bone, the site should be copiously irrigated to eliminate bone dust and remove all bone fragments.
- The fixture is then inserted using a drill speed of 20 to 30 Ncm for soft bone or 40 to 50 Ncm for hard bone.
  - No irrigation should be used until the first threads of the implant have engaged (two rotations) to avoid trapping fluid between the bone and the screw.
  - Essentially no pressure is necessary at this stage. The drill will stop automatically when the appropriate torque has been reached; it can then be disengaged from the inserted implant.
- The bone bed indicator is then screwed onto the fixture and rotated in a clockwise direction to ensure that there is no adjacent bony prominence that will make contact with the magnet.
  - If the gauge cannot be freely rotated, a conventional otologic drill is used to remove the surrounding prominent bone until the bone bed indicator can be rotated freely and completely.
- The bone bed indicator is then removed and the magnet is screwed into position using the gold-tipped (Unigrip) screwdriver.
  - The magnet is marked with an "up" arrow, which should be pointed superiorly.
  - The magnet should be tightened to a final torque of 25 Ncm using the multiwrench with ISO adapter
- The soft tissue gauge is then used to determine whether the skin flap is appropriate.
  - If over 6 mm thick, it will have to be thinned in order to allow the processor and internal magnet to interact sufficiently.
    - The skin flap should be uniformly thinned to 6 mm, not just overlying the internal magnet.
- Three "tacking" sutures placed midway between the magnet and the incision (at the inferior, anterior, and superior locations) are helpful in closing the dead space between the skin and the periosteum surrounding the magnet (Fig. 135.3).
  - Avoid suturing directly over the magnet.
- The incision is closed with 4-0 Vicryl for the deep layer of the skin followed by a running 5-0 fast-absorbing plain gut.
- Tincture of benzoin, Steri-Strips, a nonadherent gauze dressing, and a compressive dressing (such as a Glasscock cup) are then applied.

- Baha Connect (percutaneous) using DermaLock abutments
  - The technique for the Baha Connect has evolved considerably over the past 15 years.
    - The initial recommendation was to aggressively thin the tissue surrounding the abutment in order to minimize any movement at the device–skin interface and remove the hair follicles surrounding the abutment.
      - This can be performed by hand or using a dermatome attached to the Baha drill.
    - Over time the technique has shifted toward preservation of the tissue surrounding the abutment.
    - Cochlear Corporation has recently discontinued the dermatome attachment, indicating the degree to which the initial approach has been abandoned.
    - Current techniques favor preservation of the surrounding skin.

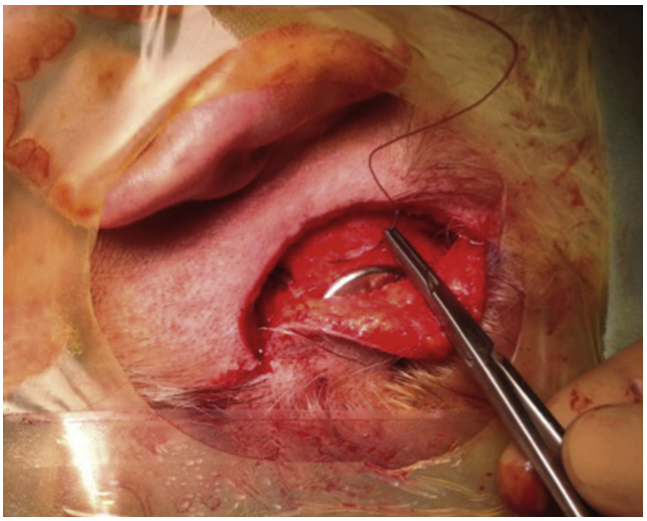

Fig. 135.3. Several "tacking" sutures are placed between the magnet and the incision to close the dead space between the skin and the periosteum surrounding the magnet.

      - This has led to the development of the Baha DermaLock, in which abutments of varying length with a thin hydroxyapatite collar are available and the surgeon determines the appropriate abutment length depending on the thickness of the individual patient's skin.
    - This is achieved through a linear incision that is in line with the implant site or offset by 1 cm.
      - More recently, some surgeons have eliminated the incision altogether and performed the drilling steps through a biopsy punch method.[4]
  - A dummy device is used to mark the planned drilling site, which is 55 mm from the ear canal and in line with the top of the auricle.
  - The incision can be placed "in line" (having the abutment emerge through the primary skin incision) or may be "off line" (staggered, so that the abutment emerges through a 5-mm skin biopsy punch posterior to the incision).
    - If the implant is placed off-line (staggered) from the incision, at least 1 cm should separate the two so that a healthy bridge of skin is maintained.
    - The incision should be 2 to 3 cm in length (Fig. 135.4).
  - Prior to infiltration with local anesthetic, a needle, hemostat, and ruler are used to gauge the skin thickness in order to choose the appropriate abutment length.
    - For a single-stage procedure, the abutment comes preattached to a 4-mm implant.
    - If there is insufficient bone thickness and the 3-mm implant is used, the abutment must be attached separately if a single-stage procedure is still planned.
    - A 6-mm abutment is used for skin thickness of 3 mm or less, 8-mm abutment for skin thickness of 4 to 5 mm, 10-mm abutment for skin thickness of 6 to 7 mm, 12-mm abutment for skin thickness of 8 to 9 mm, and 14-mm abutment for skin thickness in excess of 11 mm.
      - Skin that is over 11 mm thick will likely need to be thinned.
  - Local anesthetic is infiltrated into the planned incision site.
  - Methylene blue can be used to mark the planned device site by way of the technique described earlier for the Baha Attract.
  - The incision is then made with a knife and carried down to the plane of the periosteum.



Fig. 135.4. A 2- to 3-cm skin incision is used to identify the underlying periosteum. The periosteum is then elevated and drilling proceeds first with the guide drill, then with the countersink drill.



Fig. 135.5. Folded iodine-impregnated gauze is placed between the skin and the healing cap to apply gentle pressure on the skin surrounding the abutment.

- A cruciate incision is made in the periosteum.
- The periosteum is elevated with a raspatorium and drilling proceeds perpendicular to the bone with the 3-mm guide drill; then, if appropriate, the 4-mm guide drill and the appropriate countersink drill as described for the Baha Attract are used (see Fig. 135.4).
- For insertion of the implant, the abutment inserter bit is used to insert the combined abutment/implant (FAST system).
  - Again, it is important not to touch the fixture. It is retrieved from the plastic ampule using the abutment inserter.
  - A click should be felt when the castellated drill bit engages properly with the fixture.
  - Before the fixture is engaged with bone, the site should be copiously irrigated so that all bone fragments are removed.
  - The fixture is then inserted using a drill speed of 20 to 30 Ncm for soft bone or 40 to 50 Ncm for hard bone.
    - No irrigation should be used until the first threads of the implant have engaged (two rotations) to avoid trapping fluid between the bone and the screw.
    - Essentially no pressure is necessary at this stage. The drill will automatically stop when the appropriate torque has been reached and then can be disengaged from the inserted implant.
    - The drill will stop automatically when the appropriate torque has been reached.
- If the drilling has been performed off line from the incision, a 5-mm biopsy punch can be used to remove skin overlying the abutment. The 5-mm skin opening is then simply advanced over the abutment.
- Wound closure is achieved with a 4-0 Vicryl for the deep layers of the skin, securing it to the periosteum, followed by a running 5-0 fast-absorbing plain gut.
  - Tincture of benzoin followed by Steri-Strips placed for a final layer of protection.
- The dressing is then placed over the abutment.
  - A piece of folded iodine-impregnated gauze is positioned over the abutment.
  - A central hole is created within the impregnated gauze so that it surrounds the post of the abutment.
  - Sufficient folds of the gauze are utilized to apply gentle pressure when the healing cap is applied over the gauze. (Fig. 135.5).

Common Errors in Technique

- Failure to drill perpendicular to the bone.
  - This becomes apparent when the countersink step does not yield a 360-degree impression on the bone.
  - This error carries through to all the subsequent steps and can result in a sound processor contacting skin rather than vibrating freely (in percutaneous implants) or the need to use the otologic drill to remove some temporal squamosal tissue in order to avoid having the magnet contact bone (in the Baha Attract).
    - If a Ponto device (Oticon) is used, it can be placed as an angled abutment (angled at 10 degrees) to correct this issue.

POSTOPERATIVE PERIOD

Postoperative Management

- A gentle compressive dressing (Glasscock cup) is applied for 24 hours.
- Pain medication is provided as needed.
- Wound is kept dry for 48 hours.

- Baha Attract: a wound check is performed about a week after surgery.
  - A second visit is often coordinated with the processor fitting, which occurs 1 month out from the surgery.
- Baha Connect (DermaLock): The first postoperative appointment is typically 1 week after surgery. The healing cap is removed and the patient initiates daily hygiene for the abutment using an alcohol-free wet wipe.
  - A second visit several weeks later is helpful in making sure that the skin–device interface appears to be healthy.
  - The sound processor is typically fitted after allowing 3 months for osseointegration.

Complications

- Immediate
  - Pain, bleeding/hematoma, infection, anesthetic complications
  - Exposure or injury to the dura/sigmoid sinus—bone wax can be used to seal the leak and the drilling performed at a new site.
    - If there is good bone thickness, some advocate placement of the device, which will seal/stop the leak or bleeding.
      - Note: A cerebral abscess has been reported with the Baha system, so caution is advised.[5]
  - Implant becomes stuck/drill stops before complete insertion has been achieved.
    - If the implant is almost completely engaged, the drill can be reversed to back the implant out by one rotation and then the torque increased slightly (5 Ncm).
    - If the implant is barely engaged and appears to have entered at an inappropriate angle, the drill should be reversed to remove the implant from the site.
      - Check the site to make sure that there is no bone debris in the defect preventing the implant from seating properly.
      - Make sure that the alignment is optimal and attempt reinsertion once.
      - If this is not successful, an alternate site should be chosen.
- Delayed
  - Percutaneous device
    - Adverse skin reaction (overgrowth of skin at the abutment, inflammation/granulation tissue at the skin–device interface).[2,3]
      - The Holger classification system is useful in grading the severity of skin reactions and facilitating comparisons across different manufacturers and techniques.[6]
      - Local wound care is implemented with topical antibiotic ointments, occasional oral antibiotics, silver nitrate chemical cautery of granulation tissue, steroid injection (Triamcinolone), topical steroid application (clobetasol), and rarely surgical revision.[3]
    - Switching to a longer abutment can also help in cases of skin overgrowth.
    - If none of these measures is effective, the abutment can be removed, a cover screw placed, and a new abutment placed once the infection has been controlled.
  - Baha Attract
    - Discomfort, thinning of skin overlying the magnet, or magnet exposure
    - Persistent pain may be secondary to a loose implant or loose magnet
  - Failure of osseointegration—can occur due to poor bone quality or poor surgical technique.
    - Implant loss can also occur with trauma or infection.

Alternative Management Plan

- Conventional amplification
- Contralateral routing of Signal (CROS) aids (for single-sided deafness)
- Cochlear implantation, if criteria are met
- Alternative bone-anchored devices—Ponto (Oticon), and Alpha2 (Sophono/Medtronic)

DISCUSSION

Evidence-Based Medicine Question

- If surrounding skin and soft tissue begins to overgrow the abutment site, what can be done to help reverse this process?
  - Although the incidence of soft tissue skin reactions has been dramatically reduced with the advent of modified surgical techniques and proprietary technology from each of the vendors, these complications do still occur. This topic is not widely discussed within the current literature.
  - A defined treatment algorithm has been proposed to manage soft tissue reactions of progressive severity.[3]
    - The first step of the treatment algorithm is that of local wound care. This includes topical antibiotic ointment (Bacitracin, Mupirocen), oral antibiotics (based on wound cultures), application of topical silver nitrate chemical cautery and/or Clobetasol cream (0.5%).
    - The second step of the treatment algorithm consists of an intralesional triamcinolone acetonide injection (roughly 40 mg per injection).
    - The final step of the treatment algorithm, used only for pronounced overgrowth of skin around the abutment that proves resistant to prior intervention, calls for surgical revision therapy.

Editorial Comment

Bone-anchored hearing devices have been available for over 30 years. The initial product was based on work by Brånemark, implanting titanium into the bone. Tjellström, in 1983, developed a procedure to affix a titanium implant into the mastoid bone. An internally fixed magnet with an external device was the basis for the Xomed Audiant Bone Conductor transcutaneous system, which was withdrawn from the market in the mid-1990s because of limited performance and wound issues. Contemporary percutaneous devices and techniques have been developed that provide excellent hearing results. The indications have included hearing impairment from single-sided deafness as well as conductive and mixed hearing loss. The percutaneous (protruding through the skin) configuration is being supplanted by a transcutaneous (across the skin) connection using magnetic attraction. The impetus for this has been to minimize the wound complications and address cosmetic concerns where the abutment comes through the skin. Soft tissue skin problems include irritation of the skin surrounding the implant, overgrowth of skin over the device, granulation tissue reaction, infection, and, rarely, persistent pain. There have been ongoing successful modifications of the soft tissue approaches to reduce the incidence of these wound complications. This has evolved from creating a split-thickness skin flap with a dermatome for subcutaneous debridement to a C-shaped flap, also with subcutaneous debridement, to placement of the unit 1 cm behind a short vertical incision and, more recently, directly through a 5-mm skin punch without any soft tissue dissection. Nonetheless, ongoing care of the implant site remains a challenge for some recipients. Current

technology now allows for transcutaneous devices to provide sufficient power to offer a real benefit for the appropriate candidates. All three transcutaneous (magnetic attraction) devices (BAHA Attract, Sophono Alpha 2, and BONEBRIDGE) are MRI-compatible, but the field of distortion may interfere with discerning pathology of the ipsilateral temporal lobe.

Another advantage of the transcutaneous devices is the shorter time recommended to load (attach) the processor to the patient. This can be a month, as there is no significant torque applied for attaching or removing the external magnet and processor. The current recommendations for the percutaneous devices remain at 3 months in the United States, although experience in Europe has demonstrated that this can be as short as 2 weeks.

Owing to constraints of space and the desire for brevity, this chapter does not address all of the available products and the specific technical points needed to successfully complete the surgery. The authors have focused on the devices they currently use. Surgeons should be very familiar with the principles and instruments associated with the products they will implant.

Barry Hirsch


Access the review questions and additional sources list online at http://www.expertconsult.com

REFERENCES

1. RK Gurgel AT. Bone-anchored cochlea stimulators. In: Brackmann DE, Shelton C, Arriaga MA, editors. Otologic Surgery. 4th ed Philadelphia: Elsevier; 2015. p 360.
2. Gluth MB, Eager KM, Eikelboom RH, et al. Long-term benefit perception, complications, and device malfunction rate of bone-anchored hearing aid implantation for profound unilateral sensorineural hearing loss. Otol Neurotol 2010;31(9):1427–1434. http://dx.doi.org/10.1097/MAO.0b013e3181f0c53e. PubMed PMID: 20729779.
3. Hildrew DM, Guittard JA, Carter JM, et al. Clobetasol's influence on the management and cost of skin overgrowth associated with the bone anchored hearing aid. Ochsner J 2015;15(3):277–283. PubMed PMID 26413004.
4. Gordon SA, Coelho DH. Minimally invasive surgery for osseointegrated auditory implants: A comparison of linear versus punch techniques. Otolaryngol Head Neck Surg 2015;152(6):1089–1093. http://dx.doi.org/10.1177/0194599815571532. PubMed PMID: 25715352.
5. Scholz M, Eufinger H, Anders A, et al. Intracerebral abscess after abutment change of a bone anchored hearing aid (BAHA). Otol Neurotol 2003;24(6):896–899. PubMed PMID: 14600471.
6. Holgers KM, Tjellstrom A, Bjursten LM, et al. Soft tissue reactions around percutaneous implants: A clinical study of soft tissue conditions around skin-penetrating titanium implants for bone-anchored hearing aids. Am J Otol 1988;9(1):56–59. PubMed PMID: 3364537.

REVIEW QUESTIONS

1. In placing the fixture into the bony well, no irrigation should be used until the first threads of the implant have engaged (two rotations) to avoid trapping fluid between the bone and the screw.
   a. True
   b. False

2. Which of the following is a true statement?
   a. The MRI artifact is less for a transcutaneous device than a percutaneous device.
   b. MRI is contraindicated in patients with transcutaneous bone-anchored hearing devices.
   c. The MRI scatter associated with a transcutaneous device may extend up to 11 cm.
   d. All of the transcutaneous bone-anchored hearing devices are FDA-approved for imaging with a 3 Tesla MRI.

3. Which of the following is NOT an indication for a bone-anchored hearing device?
   a. Unilateral profound SNHL
   b. Bilateral profound SNHL
   c. Mixed loss and not a candidate for conventional hearing aids
   d. Maximal conductive loss and not a candidate for conventional hearing aids

4. Which of the following is a relative contraindication for placing a bone-anchored hearing device?
   a. Severe osteoporosis
   b. Patients prone to keloid formation
   c. Implanting a percutaneous device in a patient with pathology close to an ear that will require monitoring with MRI
   d. Inability of patient perform routine cleaning of abutment site
   e. All of the above

5. The FDA has approved bone-anchored hearing devices for children 5 years of age and older.
   a. True
   b. False

ADDITIONAL SOURCES

None necessary

136 Implantable Middle Ear Devices

Elizabeth Toh, Jack A. Shohet

INTRODUCTION

This chapter is devoted to a review of active middle ear implants that are currently approved by the US food and drug administration (FDA) and are available locally as a surgical rehabilitation option for select hearing impaired individuals. These include the Esteem Implant (Envoy Medical Corporation, Minnesota), the Vibrant Soundbridge Implant System (MED-EL Corporation, Innsbruck, Austria), and the Maxum System (Ototronix, Texas). In the United States, all implantable middle ear devices are currently only approved for sensorineural hearing loss in adults. Each of the above implant systems will be reviewed separately.

All active middle ear implants directly drive the ossicular chain using piezoelectric or electromagnetic transduction. This eliminates the concern for acoustic feedback inherent to conventional acoustic hearing aid technology. With the Esteem and Vibrant Soundbridge systems, there is no concern for ear canal occlusion. The Maxum integrated processor and coil (IPC) worn in the ear canal transmits electromagnetic energy instead of sound, which therefore mitigates the occlusion effect.

Conventional hearing aid technology remains the mainstay for the rehabilitation of hearing loss in patients with favorable external ear anatomy. The primary motivators for the selection of implantable middle ear devices for patients with sensorineural hearing loss include lifestyle considerations (water exposure, convenience, 24/7 continuous use, cosmesis) and limited benefit with conventional amplification in the presence of aidable hearing. Indications also include compromised function or discomfort due to acoustic feedback, sound distortion, occlusion effect, ear canal irritation, abundant cerumen production, or poor fit.

ESTEEM IMPLANT (ENVOY MEDICAL CORPORATION)

The Esteem Implant is a totally implantable hearing system consisting of three implanted components: a sound processor (SP)/lithium iodine battery placed under the temporoparietal scalp and two piezoelectric transducers (driver and sensor), which are implanted in the mastoid and projected into the middle ear (Fig. 136.1). The Esteem system is activated and adjusted via radio frequency telemetry using an external remote control (Personal Programmer) programmed to customized specifications based on the patient's audiogram.

Mechanical sound vibrations transmitted from the tympanic membrane, malleus, and incus are detected by the sensor, which is coupled to the incus, and converted to electrical signals, which are then transferred to the SP. Amplified and filtered electrical signals are relayed from the SP to the driver, which is attached to the stapes capitulum. The driver converts the electrical signals back to mechanical vibrations, which are delivered through the stapes to the oval window (Fig. 136.2).

KEY OPERATIVE LEARNING POINTS

1. Esteem surgery is technically challenging and demands precise sensor and driver placement for successful hearing outcomes.
2. A well-developed mastoid, normal tympanic membrane, and normal middle ear anatomy are critical for successful placement and function of the Esteem Implant system.
3. The ossicular chain must be permanently disarticulated for Esteem driver placement.

PREOPERATIVE PERIOD

History

1. History of present illness
   a. Etiology, duration, and stability of hearing loss
   b. Hearing aid experience: The patient's reported experience with hearing aids provides good insight into their motivation for pursuing surgery and a starting point for discussing reasonable hearing expectations with the Esteem Implant.
   c. Other symptoms suggestive of underlying ear disease, which may contraindicate Esteem surgery, such as dizziness, tinnitus, aural fullness, otalgia, or otorrhea should be identified.
   d. Hearing status of the contralateral ear: The patient will not be able to hear in the operated ear for approximately 2 months postoperatively; therefore, it is important to optimize hearing in the nonoperative ear before surgery.
2. Past medical history
   a. Prior otologic procedures: Prior myringotomy with or without tube placement, tympanoplasty, ossiculoplasty, or stapes surgery may be contraindications for this procedure.
   b. Medical illness: Comorbidities that would impact wound healing, Eustachian tube function, or the need for future magnetic resonance imaging (MRI) scans. History of bleeding disorders is a relative contraindication since extensive soft tissue dissection is required for SP placement, and adherence of the mastoid cement may be challenging.
   c. Other surgery: Prior soft tissue surgery in close proximity to the ear to be implanted, ventriculoperitoneal (VP) shunt, or craniotomy surgery may impact the design of the incision and the SP placement.
   d. Medications: Anticoagulants, vitamins, and herbal products should be discontinued 1 week prior to surgery.

Physical Examination

1. Ears
   Look for a normal ear canal and tympanic membrane and the absence of any obvious tympanic membrane retractions or limited movement, middle ear lesions, or effusions. Inspect the postauricular scalp to ensure the absence of any skin pathology.

Audiogram

1. Pure tone audiogram: air and bone conduction thresholds
2. Speech audiogram: speech reception thresholds (SRTs), unaided word recognition scores



Fig. 136.1. The Esteem Implant.

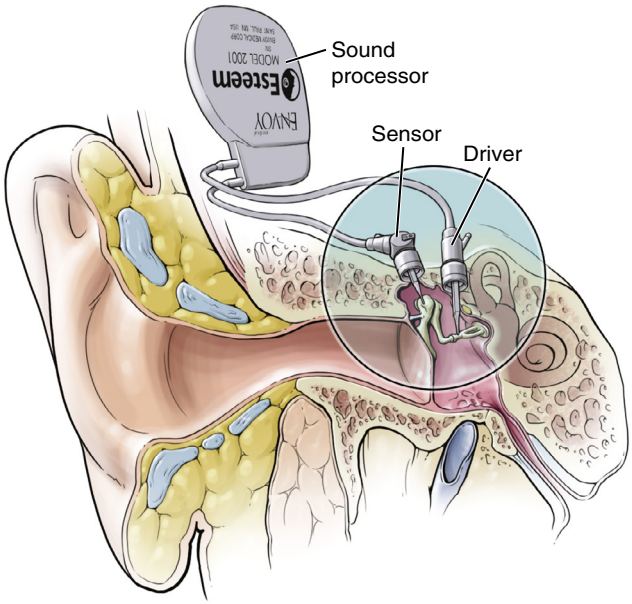

Fig. 136.2. Placement and function of the Esteem Implant.

3. Sound field testing: aided thresholds, word recognition at 50 dB HL and at comfortable suprathreshold levels
4. Tympanograms

Imaging

1. Temporal bone computed tomography (CT) scan
   This is obtained preoperatively to ensure adequate space for the placement of transducers (minimum of 22 mm between sigmoid sinus and stapes capitulum and 2.5 mm between incudomalleal joint and tegmen tympani). If hearing is symmetric, the mastoid with larger dimensions is preferable for ease of implantation.
2. MRI brain with gadolinium*
   Not routinely required. This is obtained preoperatively to screen for retrocochlear pathology ONLY if hearing loss is asymmetric.

Indications

1. Adults 18 years or older with stable bilateral moderate to severe sensorineural hearing loss (PTA 40 to 90 dB)
2. Unaided word recognition scores greater than or equal to 40%
3. Normal Eustachian tube function
4. Normal tympanic membrane
5. Normal middle ear anatomy
6. Adequate mastoid and middle ear space for implant placement determined on temporal bone CT scan
7. Minimum of 30 days' experience with appropriately fitted hearing aids
8. Realistic hearing expectations
   In general, *experienced hearing aid users* meeting indications 1 to 6 who desire the Esteem device for lifestyle, comfort, convenience, or cosmetic reasons and who have realistic expectations for comparable or more natural hearing relative to conventional hearing aids are ideal candidates.

Contraindications

1. History of significant Eustachian tube dysfunction, active chronic middle ear disease, or cholesteatoma
2. Prior ossiculoplasty or stapes surgery
3. Meniere disease or other inner ear diseases associated with fluctuating hearing loss
4. Retrocochlear pathology
5. Disabling tinnitus
6. Anticipated need for MRI in the future

Preoperative Preparation

1. Choice of ear to be implanted:
   a. Poorer hearing ear
   b. Larger mastoid dimensions
   c. Poorer hearing aid fit
2. Discontinue any anticoagulants 10 to 14 days prior to surgery.

OPERATIVE PERIOD

Anesthesia

General: Esteem surgery is always performed under general anesthesia.

Positioning

Supine: Patient is positioned supine with the body firmly secured to the operating table and the head turned away from the surgeon. The operating room table is turned 180 degrees.

Perioperative Antibiotic Prophylaxis

First-generation cephalosporin for patients who are not allergic to penicillin or cephalosporin
Clindamycin for penicillin-allergic patients

Monitoring

Facial nerve monitoring
Intraoperative system analyzer (ISA) testing is performed by field clinical engineer (FCE).

Instruments and Equipment to Have Available

1. Standard mastoid set
2. Additional middle ear instrumentation*: includes TABB double-edged flap knives, curved Rosen needle
3. SP and transducer templates*
4. High-speed drill for mastoid surgery

The current Esteem Implant is not MRI compatible.

*Indicates equipment/materials provided by the manufacturer at the time of surgery.

5. Bipolar electrocautery: to be used for hemostasis after the implant is placed
6. Diode,* argon, CO_2, or KTP laser
7. Laser Doppler vibrometer and reflective tape*
8. Sterile ear microphone*
9. Esteem ISA*: used to test Esteem Implant function intraoperatively. Both equipment and engineer are provided by the manufacturer.
10. Second microscope fitted with laser Doppler vibrometer*
11. Hydroxyapatite cement and glass ionomer cement*
12. Deionized water

An FCE is provided by Envoy Medical for every initial and revision Esteem surgery to perform intraoperative functional and device testing.

Key Anatomic Landmarks

1. Incus: identified in the epitympanum anterolateral to the lateral semicircular canal. This provides an indicator for the approximate level of the facial recess along the posterior ear canal.
2. Facial nerve: The mastoid segment is the medial boundary of the facial recess.
3. Chorda tympani nerve: This is the lateral boundary of the facial recess and is often sacrificed in Esteem surgery for driver placement. The fibrous annulus of the tympanic membrane lies lateral to the chorda.
4. Tegmen tympani and mastoideum: the floor of the middle fossa and superior boundary of the mastoid and epitympanic dissection

Prerequisite Skills

1. Mastoidectomy and facial recess exposure
2. Ossiculoplasty surgery
3. Otologic laser certification
4. Otologic cement application

Operative Risks

Risks of mastoidectomy surgery, including injury to the sigmoid sinus, tegmen, dura, posterior ear canal, lateral semicircular canal, facial nerve, and ossicular chain are discussed elsewhere in this book. Those listed below highlight the additional risks incurred for placement of the Esteem Implant.

1. Injury to the facial nerve
   The facial nerve may be injured while opening the facial recess as a result of direct trauma or heat injury. The facial nerve also may be injured when using the diode laser to section the long process of the incus. The vertical segment of the nerve should be protected by placing a finger in the mastoid cavity while screwing the stabilizer bars to prevent inadvertent slipping of the screwdriver into the mastoid. The tympanic segment of the nerve should be well covered with moist Gelfoam while using the diode laser.
2. Trauma to the ossicles
   Drill trauma to the malleus and incus may occur as the epitympanum is being opened to expose the incudomalleal joint. The stapes is at risk for dislocation and fracture when separating the incudostapedial joint and removing mucosa from the capitulum. The incus is at risk for dislocation when creating a neojoint between the sensor and incus body. Trauma to the ossicles is best avoided with gentle manipulation of the mobile ossicular chain during surgery and gentle stabilization of the ossicle with a suction or other atraumatic micro-instrumentation.

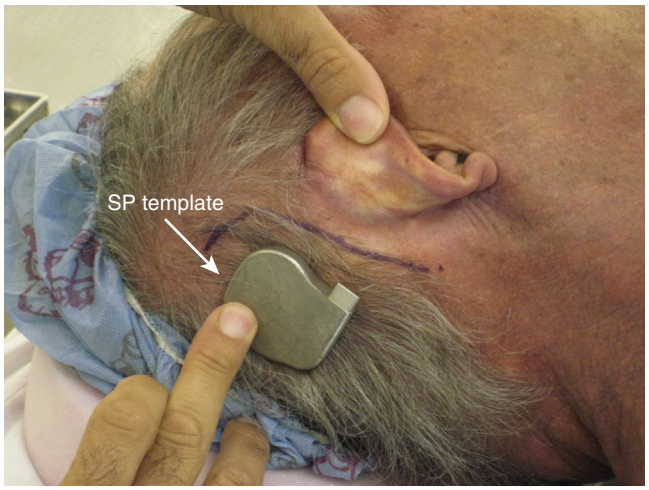

Fig. 136.3. The recommended Esteem sound processor (SP) placement and surgical incision.

3. Injury to or transection of the chorda tympani nerve
   Transection of the chorda tympani nerve is necessary in most cases to provide adequate surgical exposure for driver placement and cement application between the driver tip and stapes capitulum.
4. Tympanic membrane perforation
   This may occur when widening the facial recess after the chorda tympani nerve has been sacrificed. Once the fibrous annulus is identified, no further drilling should be performed on the lateral aspect of the facial recess. The tympanic membrane is also at risk with the use of the diode laser. Care should be taken to direct the laser away from the tympanic membrane and pause to allow heat dissipation between laser exposures.

Surgical Technique

- Mark position for SP placement (Fig. 136.3) on a relatively flat part of the skull posterosuperior to the anticipated mastoid cavity. Mark a lazy S incision behind ear to accommodate placement of the SP at least 1.5 cm away from the anterior border of the SP. Perform small strip shave and inject incision site with local anesthetic containing 1:100,000 epinephrine solution.
- Place facial nerve monitoring electrodes in ipsilateral orbicularis oculi and orbicularis oris muscles and appropriate ground and stimulating electrodes. A separate ground electrode for the intraoperative implant testing is placed in the midline forehead.
- Prepare and drape the ear in usual sterile fashion.
- Insert the microphone into the sterile ear canal and secure the pinna forward with watertight adhesive dressing once the functionality of the microphone has been confirmed by the FCE.
- Make a postauricular incision down to the avascular plane superficial to the temporalis fascia layer and elevate the anterior and posterior skin flaps.
- Incise the temporalis fascial layer and periosteum in a vertical, stepped fashion anterior to the skin incision. Elevate the periosteum anteriorly and posteriorly. The spine of Henle and posterior-superior bony ear canal should be exposed anteriorly. Posterior exposure permits SP placement.
- Drill an SP bed in the previously identified SP location behind the anticipated mastoid cavity and a shallow electrode trough to accommodate the SP header and electrodes. Suture tying down of the holes on either side of the SP bed may be considered to secure the SP.[1]

- Perform a cortical mastoidectomy with skeletonization of the mastoid tip, sigmoid sinus, posterior fossa plate, tegmen, and posterior ear canal. Open the epitympanic recess for clear exposure of the body of the incus and incudomalleal joint. This wide exposure is necessary for placement and visualization of the driver and the sensor, as well as the application of cement.
- Place a small saline-soaked Gelfoam pledget over the proximal body of the incus (sensor neojoint location) to keep the mucosa moistened through the remainder of the procedure until the placement of the sensor.
- Open the facial recess, keeping the incus buttress intact and skeletonizing the facial nerve. Unless the facial recess is unusually wide, the chorda tympani nerve is sacrificed, and the fibrous annulus of the tympanic membrane forms the lateral boundary of surgical exposure in these cases.
- Sharply remove any visible ossicular chain adhesions. Place small strips of reflective tape on the stapes and incus body (remove the Gelfoam for this purpose). Obtain intact chain measurements using the laser Doppler vibrometry (FCE). If the ossicular chain is hypomobile, do not proceed with Esteem implantation.[2]
- If ossicular chain mobility is within the normal range, proceed to incise the mucosa of the incudostapedial joint with a #59 beaver blade, and elevate the stapes capitulum mucosa medially toward crura, then separate the incudostapedial joint.
- Place the saline-soaked Gelfoam medial and lateral to the incus in the middle ear to protect the tympanic facial nerve and tympanic membrane.
- Amputate the distal 3 to 4 mm of the long process of the incus long using a laser (for diode laser, use 5 to 8 watts, single pulse mode, pulse duration 100 to 200 ms). Then remove the Gelfoam from the middle ear.
- Paint the stapes capitulum with methylene blue-soaked Gelfoam.
- Remove any methylene blue-stained mucosa over the stapes capitulum and dry the capitulum with the laser (for diode laser use 2 watts, single pulse mode, 100 to 200 ms pulse duration). This is a critical step for reliable bonding of the ionomeric cement used to couple the Esteem driver tip to the stapes capitulum.
- Precoat the stapes capitulum with ionomeric cement and allow to cure for 10 minutes.
- Screw on the Glasscock stabilizer bars to the posterior cortical margin of the mastoid cavity, and attach the driver and the sensor.
- Test capacitance of the driver and sensor with the provided cables (FCE).
- Position the sensor in the mastoid with the tip over incus body adjacent to incudomalleal joint. Then place the driver in the mastoid with the tip over the cement-coated stapes capitulum, bellows parallel to the footplate, avoiding bony contact within the facial recess (Fig. 136.4).
- Carefully place small saline-soaked Gelfoam pledgets in the mastoid cavity medial and adjacent to the sensor and driver transducer bellows, creating a physical barrier to prevent anterior migration of the hydroxyapatite cement.
- Rotate the patient toward the surgeon, and apply hydroxyapatite cement completely around transducer bodies proximal to their silicone shields. After 3 minutes, inspect the driver and sensor tips for migration as the cement cures. This can be controlled early in the cement curing process by applying gentle pressure on the stabilizer bars or bellows using micro-instrumentation. Allow the cement to cure for 15 to 20 minutes. Ensure there is no undo pressure on the transducer leads, which can displace the transducer tips.

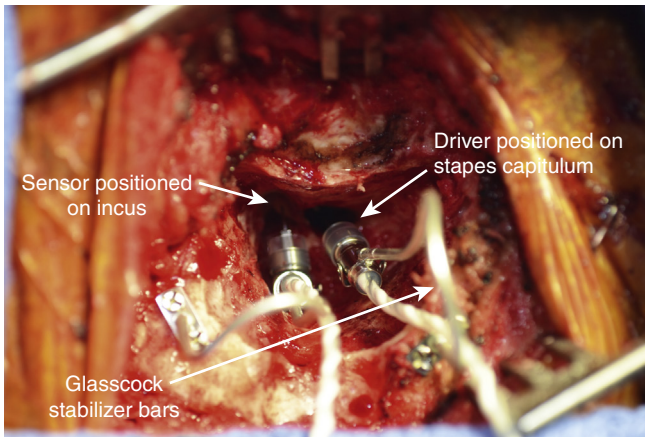

Fig. 136.4. The positioning of Esteem driver and sensor.

- The Gelfoam is carefully removed from the mastoid 5 to 10 minutes after the application of cement.
- Apply ionomeric cement around the driver tip onto the stapes capitulum cement precoat, and allow it to cure for 10 minutes.
- Apply ionomeric cement to the sensor tip, and allow it to cure for 5 minutes. Then create a neojoint by incising the incus mucosa around cement-ossicle interface, separating the cement cap with the sensor tip from the incus. A sharp, gently curved pick and TABB knife are useful for this step.
- Irrigate the mastoid and middle ear with antibiotic solution.
- Test the sensor and driver placement and function using laser Doppler vibrometry (FCE). If either one is not functioning within the parameters defined by prior intact chain measurement, transducer placement must be revised and the testing repeated until acceptable measures are obtained.
- Clean the proximal sensor and driver leads with deionized water and dry.
- Insert the sensor and driver leads into the SP header, and secure the SP in the bony seat. Perform system testing (FCE).
- Remove stabilizer bars.
- Perform layered wound closure (2-0 Vicryl muscle/periosteum, 3-0 Vicryl subcutaneous, and 4-0 Vicryl subcuticular, and apply Steri-Strips).
- Remove the microphone, and inspect the ear canal and tympanic membrane.
- Place a pressure dressing over the ear for 24 hours.[1]

COMMON ERRORS IN TECHNIQUE

1. Inadequate mastoid and middle ear exposure
   Wide mastoid cavity saucerization and a wide facial recess with attention to removing the superior-lateral corner at the root of the zygoma are all helpful to maximize visualization and cement application around the driver tip.
2. SP placement too far posterior
   Ideal location for the SP is the posterosuperior to the mastoid cavity (behind superior limb of lazy S incision) for easy access during surgery for future battery changes.
3. Driver misalignment
   The driver bellow should be positioned parallel to the plane of the stapes footplate and must not be in contact with the facial nerve in the facial recess.
4. Incomplete cement coverage over the driver tip
   This is deficient most commonly along the anterior interface. It is best to draw cement over the anterior joint interface early in the cement application process for ease of visualization and access. Care should be taken to ensure that cement does not contact the incus remnant or tympanic membrane.

5. Driver and sensor migration
   Expect marginal volume expansion of the hydroxyapatite cement during the curing process. This may cause slight shifts in positioning of the sensor and driver tips. Monitor the position of the sensor and driver tips during the first 5 minutes after cement application, and control tip migration with direct pressure on the bellows.
6. Hydroxyapatite cement desiccation and fracture
   This can be avoided by placing moist Gelfoam over the cement as it cures. Any fracture lines through the cement must be reinforced with additional cement.

Battery Change Technique

- Average battery life of the Esteem Implant is 5 years.
- Since the Esteem battery is integral to the SP unit, battery changes afford the patient any interval technology updates for the implant system.
- Battery change is usually performed under local anesthesia unless otherwise indicated by patient preference/tolerance.
- Only bipolar electrocautery should be used for battery change, and avoidance of any electrocautery is preferred.
- Prior to the procedure, the new SP is programmed using the patient's existing SP parameters, and the Personal Programmer is linked to the new SP.
- Tape the surgical ear forward.
- After sterile preparation and draping, the original postauricular incision anterior to the SP component is infiltrated with local anesthetic with 1:100,000 epinephrine solution buffered with sodium bicarbonate solution.
- The initial skin incision is made with a scalpel. Thereafter, blunt and sharp dissection are used to isolate the proximal driver and sensor leads adjacent to the SP header and expose the fibrous capsule encasing the SP.
- Incise fibrous capsule, and remove SP from soft tissue pocket. Remove the driver and sensor leads from the SP header.
- Perform capacitance testing with the cable provided by the FCE.
- Inspect leads for surgical trauma. If the electrical component of either lead is violated during the procedure, the wound should be closed and the patient returned to the OR electively for a formal revision to replace the damaged transducer.
- Irrigate the SP pocket with bacitracin or other antibiotic solution.
- Clean the leads with sterile deionized water, and dry with instrument wipes.
- Insert the driver and sensor leads fully into appropriate header slots in the new SP.
- Confirm hearing restoration, and perform volume testing to confirm functionality of the new SP. The implant is active from the time of surgery.
- Close the wound in layers.
- Apply a pressure dressing over the ear for 24 hours.

POSTOPERATIVE PERIOD

Postoperative Management

1. Wound care: Expect mild soft tissue edema around the incision and implant. Keep a light pressure dressing over the ear for 24 hours.
2. Activate and program the SP 8 weeks after surgery. This allows adequate time for the resolution of retained blood within the middle ear, thus avoiding the possibility of mechanical feedback.
3. One or two additional programming visits may be helpful to optimize hearing outcomes within the first year.

Complications

1. Wound infection
   All wound infections should be treated aggressively with broad-spectrum skin flora coverage.
2. Wound dehiscence
   If primary wound closure without tension is not possible, a local soft tissue flap with or without skin grafting may be required to cover the SP. Prophylactic antibiotic coverage for skin flora should be prescribed.
3. Mastoid and/or middle ear scar tissue/adhesion formation
   Adhesions restricting mobility of the sensor or driver may limit gain and cause feedback. Functional testing with or without temporal bone CT imaging may help to localize involvement to the sensor or driver. A transmastoid approach for revision surgery is generally recommended unless functional testing localizes scar tissue formation between the driver tip and incus remnant or tympanic membrane.
4. Driver detachment
   This can be diagnosed on functional testing of the implant. A transcanal approach may be used to replace or augment ionomeric cement over the driver tip.
5. Poor functional gain with implant
   If hearing benefit with the Esteem Implant remains poor (significantly worse than the preoperative aided condition), revision surgery and transducer repositioning may improve function. Alternatively, the implant may be removed and hearing reconstructed with a partial ossicular replacement prosthesis, a Kraus K-Helix Crown prosthesis (Grace Medical), or ionomeric cement.
6. Facial paralysis
   Treat with 7- to 10-day oral steroid taper.
7. Dysgeusia
   Long-term dysgeusia is expected in 5% to 7% when the chorda tympani nerve is sacrificed.

Alternative Management Plan

For patients desiring the benefits afforded by the Esteem Implant System (24/7 function, limited water exposure, cosmesis, convenience) at a lesser cost or risk, deep insert extended-wear hearing aids (Lyric) may be considered. The average battery life on the Lyric hearing aid is 2 to 3 months.

DISCUSSION

Evidence-Based Medicine Question

Besides advantages in lifestyle with a totally implanted hearing system, are there any audiometric advantages with the Esteem Implant compared to conventional hearing aids?

A prospective, nonrandomized, multicenter, subject-as-own-control, FDA clinical trial demonstrated an improvement in SRT from 41.2 dB with the hearing aid to 29.4 dB with the Esteem Implant. Word recognition score at 50 dB HL (WRS50) improved from 46.3% with the subjects' hearing aids to 68.9% with the Esteem. A pure tone average (PTA) improvement of 27 ± 1 dB was seen.[1]

Editorial Comment

The Esteem Totally Implantable Hearing System
Eric M. Kraus, Douglas A. Chen

Overview: Postmarket approval experience has been gained during the last 7 years. Careful patient selection is paramount. Patients report improved sound fidelity and clarity as compared to hearing aids secondary to low distortion system characteristics and an unobstructed ear canal. Long-term results have

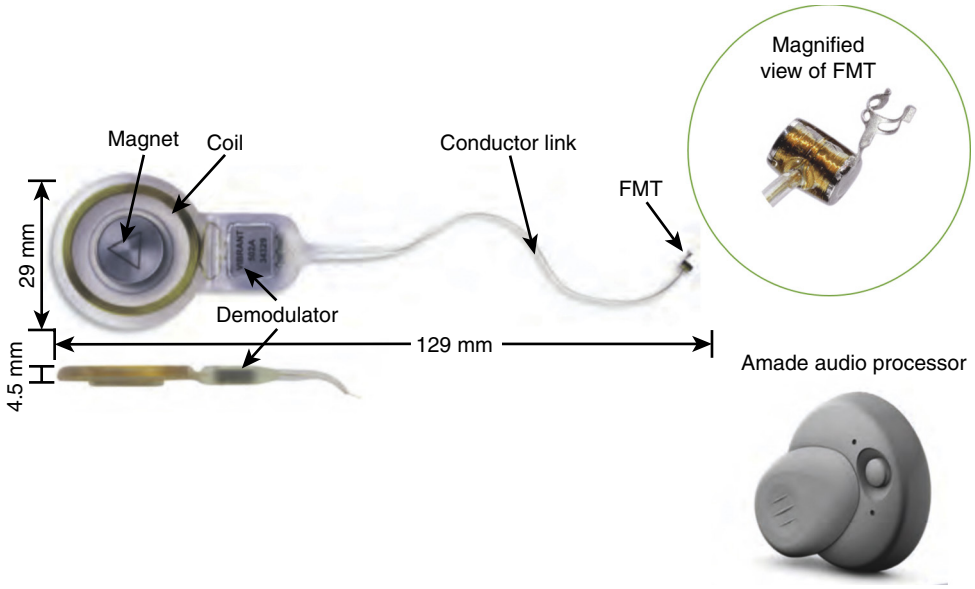

Fig. 136.5. Vibrant Soundbridge implant with external audio processor and internal vibrating ossicular prosthesis with magnified view of floating mass transducer (FMT).

shown stable hearing without deterioration in bone conduction thresholds compared to the contralateral ear. Better audiometric tests to quantitate fidelity are needed. The system is capable of 55 dB of acoustic gain, which is better in low than high frequencies. Such gain levels are capable of creating temporal bone vibrations that can be detected by the sensor and may result in mechanical feedback. Expert programming is essential. However, patients enjoy the freedom of not having to wear external hardware. The necessity to replace the battery every 3 to 5 years remains problematic secondary to skin thinning, compromised blood supply, and fibrosis. A rechargeable option would markedly decrease potential surgical risks, time, and cost.

Surgical considerations: The operative procedure is challenging due to three-dimensional considerations during implantation of the transducers. The surgical learning curve requires approximately 20 procedures to acquire the necessary skill set. The facial recess must be opened widely to its anatomic limits. The chorda tympani nerve is sacrificed in approximately 70% of cases. Stable fixation of the SP is critical to prevent anterior migration. After 13 years of follow-up, some patients have required explantation and ossicular reconstruction due to late effect fibrosis, bone bridging, or the inability to achieve enough gain without mechanical feedback. Explantation and effective ossicular reconstruction are possible with hearing restoration back to baseline levels.

Eric M. Kraus

VIBRANT SOUNDBRIDGE DEVICE (MED-EL CORPORATION)

Vibrant Soundbridge is a partially implantable active middle ear device that uses electromagnetic energy to mechanically drive the ossicular chain. The system has two components (Fig. 136.5):

1. An externally worn audio processor secured magnetically to the scalp
2. A surgically implanted vibrating ossicular prosthesis (VORP) attached to a floating mass transducer (FMT). The FMT is coupled to the ossicular chain with an attachment clip to serve as an electromagnet transducer. It comprises a miniature magnet encased in a hermetically sealed titanium casing wrapped with electromagnetic coils.

Sound detected by the audio processor microphone is processed and relayed across the skin to the internal receiver of the VORP. Electrical signals are then relayed from the VORP to the FMT, which in turn generates vibrations from the oscillating magnet within an electromagnetic field to drive the ossicular chain (Fig. 136.6). The use of Vibrant Soundbridge for surgical rehabilitation of conductive and mixed hearing loss by placing the FMT directly on the round window membrane remains investigational in the United States at the time of this publication. The current Vibrant Soundbridge implant system available in the United States is not MRI compatible.

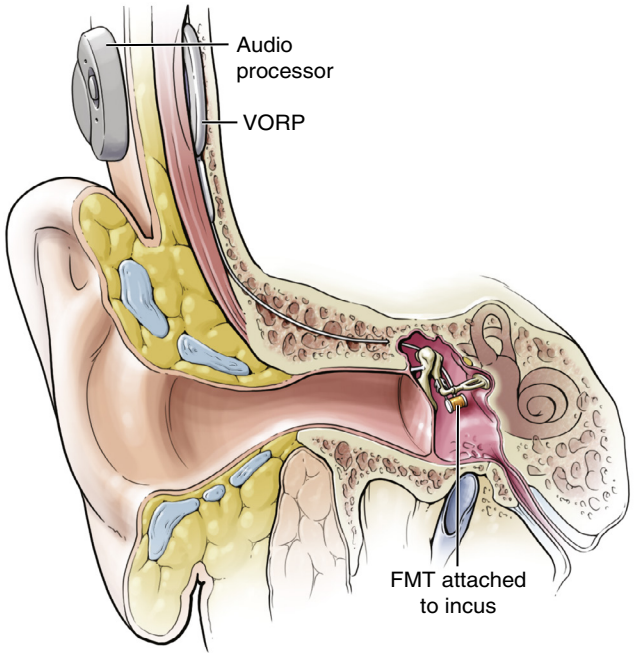

Fig. 136.6. Placement of Vibrant Soundbridge implant. *VORP*, Vibrating ossicular prosthesis; *FMT*, floating mass transducer.

KEY OPERATIVE LEARNING POINTS

1. The ossicular chain integrity is maintained during placement of this direct drive active middle ear implant.
2. A wide facial recess is necessary for placement of the FMT.
3. Adequate crimping of the attachment clip is necessary to ensure the function of this implant.

PREOPERATIVE PERIOD

History and Physical Examination

As for the previously described Esteem Implant

Audiogram

1. Pure tone audiogram: air and bone conduction thresholds
2. Speech audiogram: SRTs, unaided word recognition scores
3. Sound field testing: aided thresholds, aided word recognition with headphones at the most comfortable level and with hearing aids at 65 dB SPL
4. Tympanograms
5. Acoustic reflex thresholds

Imaging

1. Temporal bone CT scan
   This is generally recommended for the preoperative mapping of the mastoid and facial nerve anatomy.
2. MRI brain with gadolinium*
   Not routinely required. This is obtained preoperatively to screen for retrocochlear pathology if the hearing loss is asymmetric.

Indications

1. Adults 18 years or older with stable moderate to severe sensorineural hearing loss who desire an alternative to a conventional acoustic hearing aid
2. Word recognition scores of 50% or better at most comfortable level using headphones or with hearing aids at 65 dB SPL
3. Intact tympanic membrane and ossicular chain with normal middle ear function
4. Prior hearing aid experience is strongly recommended
5. Realistic hearing expectations

Contraindications

As for the Esteem Implant

Preoperative Preparation

As for the Esteem Implant

OPERATIVE PERIOD

Anesthesia

General

Positioning

Supine: The patient is positioned supine with the body firmly secured to the operating table and the head turned away from the surgeon. The operating room table is turned 180 degrees.

Perioperative Antibiotic Prophylaxis

First-generation cephalosporin for patients without allergy to penicillin or cephalosporin
Clindamycin for penicillin-allergic patients

Monitoring

Facial nerve monitoring

Instruments and Equipment to Have Available

1. Standard mastoid set
2. High-speed drill for mastoid surgery
3. MED-EL Surgical Accessory Kit*: includes three VORP templates, forming forceps, and a skin flap 7 mm gauge
4. Bipolar electrocautery: to be used for hemostasis after the implant is placed

Key Anatomic Landmarks

1. Incus: identified in the epitympanum anterolateral to the lateral semicircular canal. This provides an indicator for the approximate level of the facial recess along the posterior ear canal.
2. Facial nerve: The mastoid segment is the medial boundary of the facial recess.
3. Chorda tympani nerve: This is the lateral boundary of the facial recess and may need to be sacrificed if the facial recess is too narrow to accommodate the FMT. If the chorda tympani nerve is sacrificed, the fibrous annulus of the tympanic membrane forms the lateral boundary of the facial recess.

Prerequisite Skills

1. Mastoidectomy and facial recess exposure
2. Middle ear/ossiculoplasty surgery

Operative Risks

In addition to the standard risks of mastoidectomy and facial recess surgery, the following are risks incurred for Vibrant Soundbridge Implant surgery.

1. Injury to the facial nerve/chorda tympani
   A very wide facial recess is necessary to pass the FMT and forming forceps into the middle ear. Heat trauma to the facial nerve can be avoided by ensuring continuous irrigation while skeletonizing the facial nerve in this location. If the chorda tympani nerve must be sacrificed for access, it should be sharply divided at its take-off from the mastoid segment of the facial nerve.
2. Trauma to the ossicles
   This may be incurred to the incus or stapes while positioning and crimping the FMT attachment clip onto the incus. This is best avoided using an atraumatic surgical technique. If the attachment clip cannot be tightened safely through the facial recess, this may be accomplished in the middle ear through a transcanal approach.

Surgical Technique[3]

- Mark the position of the VORP posterosuperior to the intended mastoidectomy cavity, then mark out a lazy S incision with the superior limb at least 1.5 cm anterior to the VORP. Perform a small strip shave, and inject the incision site using local anesthetic with 1:100,000 epinephrine solution.
- Place facial nerve monitoring electrodes, and confirm the functionality of the monitor.
- Prepare and drape the ear in the usual sterile fashion.

**The current Vibrant Soundbridge implant is not MRI compatible.*

*Indicates equipment provided by manufacturer.

- Make the postauricular incision down to the avascular plane above the temporalis fascia, and elevate the anterior and posterior skin flaps.
- Elevate an anteriorly based pericranial flap to expose the mastoid cortex. If a bony recess for the VORP demodulator is planned, the pericranial flap should extend posterosuperior to the intended mastoid cavity for bony access.
- Mark the outline of the VORP demodulator position with the VORP template, and drill a shallow bony recess. Place drill tie-down holes on either side of the bony recess to secure the VORP.
- *The slim profile of the current VORP offers the option for temporalis pocket placement without drilling a bony recess or placing tie-down sutures. This can be done by incising the periosteum along linea temporalis and bluntly dissecting a pericranial pocket between the temporoparietal suture line anteriorly and the lambdoid suture posteriorly. Size the pocket with the VORP template.*
- Drill a bony electrode trough extending from the bony recess or temporalis pocket to the posterior margin of the mastoid cavity.
- Ensure that the skin flap over the receiver coil and magnet is 7 mm or less using a skin flap gauge.
- Perform a mastoidectomy, leaving cortical bone overhanging the cavity along the superior and posterior margins to secure the conductor link. Identify and expose the incus body in the epitympanum.
- Open the facial recess within the boundaries of the chorda tympani nerve and facial nerve. The recess must be able to accommodate a 2.5- to 3-mm diamond bur in order to provide adequate access for the FMT and forming forceps. The chorda tympani nerve may need to be sacrificed if the recess is narrow. Preserve the incus buttress to maintain the integrity of the ligament that secures the short process of the incus.
- Place and secure the VORP in the bony recess or within the temporalis pocket.
- Prebend the distal conductor link a few millimeters from the FMT so that once the FMT is secured to the ossicular chain, the conductor link does not contact the walls of the facial recess.
- Advance the FMT through the facial recess, and position it parallel to the axis of motion of the stapes, with the FMT up against the incudostapedial joint and the clip as far superior on the incus long process as possible (Fig. 136.7).
- Tighten the clip around the incus long process using the forming forceps.
- Tuck the excess conductor link under the superior or posterior mastoid cortical overhang.

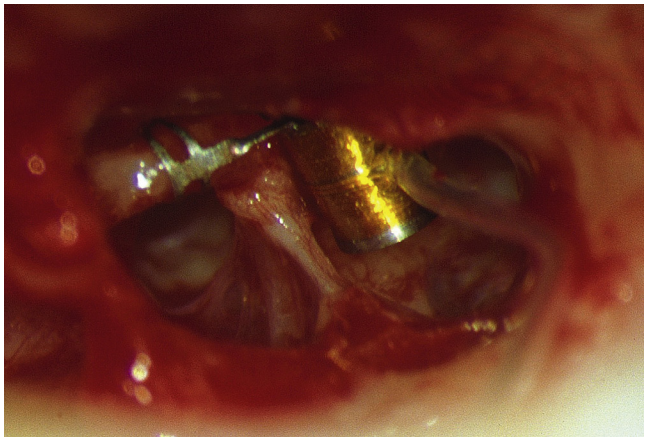

Fig. 136.7. Floating mass transducer attached to incus.

- Reapproximate the pericranial flap, and close the wound in the usual layered fashion. Any wound hemostasis after placement of the VORP should be performed using bipolar electrocautery only.
- Place a pressure dressing over the ear for 24 hours.

Common Errors in Technique

1. Thick skin flap
   Impairs magnetization of the audio processor and proper implant function postoperatively. Use the skin gauge to ensure that the skin flap over the VORP magnet is less than 7 mm thick.
2. VORP placement
   If the patient wears eyeglasses or head gear, the VORP should be positioned such that the external SP location does not interfere with use of either.
3. Conductor link contact with facial recess walls
   This will impede movement of the FMT and can be avoided by creating a pre-bend in the conductor link before placement of the FMT.
4. FMT contact with surrounding structures
   FMT contact with the promontory, pyramidal eminence, or tympanic membrane will impede movement of the FMT and should be avoided during placement.
5. FMT damage
   Avoid repeated manipulation of the FMT attachment clip, and avoid grasping the FMT at its junction with the conductor link.
6. Suboptimal attachment clip fixation
   If the facial recess is narrow, an additional transcanal exposure may be needed to securely crimp the attachment clip in place.

POSTOPERATIVE PERIOD

Postoperative Management

As for the Esteem Implant. The audio processor is activated 8 weeks after implant placement. A baseline hearing test is also obtained for the implanted ear.

Complications

1. Wound infection
   All wound infections should be treated aggressively with broad spectrum skin flora coverage
2. Facial paralysis
   Related to facial recess drilling. Treat with 7- to 10-day oral steroid taper
3. Dysgeusia
   May occur if the chorda tympani nerve sacrificed
4. Hearing degradation
   May result from incus long process erosion at the attachment clip site, clip detachment, or scar tissue formation and may necessitate revision surgery

Alternative Management Plan

As for the Esteem Implant

DISCUSSION

Evidence-Based Medicine Question

Does mass loading of the ossicular chain with the FMT have any measurable impact on air-conduction thresholds in implanted ears?

Several studies have reported the absence of any change in air-conduction thresholds in implanted ears. However, bone conduction thresholds at 0.5 and 1 kHz improved, suggesting improved hearing via bone conduction due to an additional mass on the middle ear structures.[4]

Editorial Comment

Surgery for the Vibrant Soundbridge requires extensive facial recess exposure to ensure adequate access for positioning and crimping of the clip. Glass ionomer cement has been used to further facilitate fixation of the clip, but it must be used conservatively to not fixate the FMT.

Douglas A. Chen

MAXUM HEARING IMPLANT SYSTEM (OTOTRONIX, TEXAS)

The Maxum is a semi-implantable electromagnetic hearing system comprised of:

1. Internally implanted component: titanium-encased magnet with a nitinol (nickel/titanium alloy) split attachment coil used to couple the implant to the ossicular chain at the incudostapedial joint
2. Externally worn component: This is deeply inserted in-the-canal digital sound processer with an integrated electromagnetic induction coil (IPC; Fig. 136.8).

The fundamental technology of the Maxum system was developed from the SOUNDTEC Direct Drive Hearing System, which required the use of a behind-the-ear IPC. Sound detected by the IPC microphone is amplified, processed, and delivered as electrical signals to the electromagnetic coil. The latter generates an electromagnetic field, within which the implanted magnet coupled to the ossicular chain vibrates. These vibrations are transferred from the stapes to the inner ear.

KEY OPERATIVE LEARNING POINTS

1. The ossicular chain does not need to be disarticulated for placement of the implant magnet.
2. Precise alignment of the implant magnet with the external ear canal is critical for optimal implant function and hearing benefit.

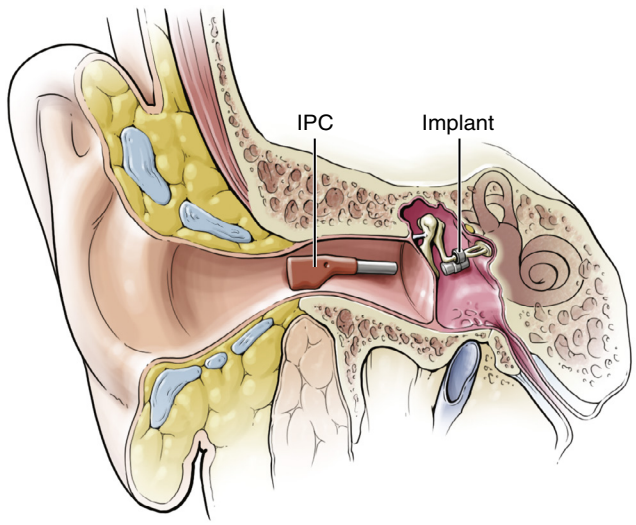

Fig. 136.8. Placement of Maxum deep insert sound processor with integrated electromagnetic induction coil and implant. *IPC*, Integrated processor and coil.

PREOPERATIVE PERIOD

History

As for the Esteem Implant with the exception of 2c, since a transcanal approach is used

Physical Examination

1. Ears
   Assess the ear canal dimensions. Minimum anatomic dimensions for IPC fitting include a canal length 20 mm from the meatus to the tympanic membrane and a width of 4 mm at the meatus and 3 mm from the second bend to the tympanic membrane.[1] Look for normal tympanic membranes and the absence of any obvious middle ear lesions or effusions. A deep earmold impression of the entire external ear canal to the tympanic membrane is made and then analyzed by the manufacturer to ensure an IPC can be constructed to accommodate the anatomy.

Audiogram

1. Pure tone and speech audiogram
2. Tympanograms

Imaging

1. Temporal bone CT scan
   Not routinely required. This is indicated only if the ear exam or audiogram is suggestive of middle ear pathology.
2. MRI brain with gadolinium*
   Not routinely required. This is indicated only for retrocochlear screening if sensorineural hearing loss is asymmetric.

Indications

1. Adults 18 years or older with stable moderate to severe sensorineural hearing loss who desire an alternative to a conventional acoustic hearing aid
2. Unaided word recognition score of 60% or better in implanted ear
3. Intact tympanic membrane and ossicular chain with normal middle ear function
4. Prior hearing aid experience is strongly recommended
5. Realistic hearing expectations

Contraindications

1. All contraindications for the Esteem Implant apply to the Maxum implant
2. A narrow ear canal
3. Any other external ear canal condition that would preclude or interfere with wearing a completely-in-the-canal IPC

Preoperative Preparation

1. Choice of ear to be implanted:
   a. Poorer hearing ear
   b. Non-telephone ear
2. Discontinue any anticoagulants 10 to 14 days prior to surgery.

**The current Maxum implant is not MRI compatible.*

OPERATIVE PERIOD

Anesthesia

Local with or without intravenous sedation: This is recommended for most patients. The procedure may be performed under general anesthesia if the patient prefers.

Positioning

Supine: The patient is positioned supine with the head turned away from the surgeon.

Perioperative Antibiotic Prophylaxis

None necessary

Monitoring

None necessary

Instruments and Equipment to Have Available

1. Nonmagnetic cylinder-holding forceps*
2. Diode, KTP, argon, or CO_2 laser
3. Glass ionomer cement*
4. Image capture capability on surgical microscope

Key Anatomic Landmarks

1. Incudostapedial joint

Prerequisite Skills

1. Middle ear/ossiculoplasty surgery
2. Otologic laser certification
3. Otologic cement application

Operative Risks

1. Tympanic membrane perforation
   This may occur when elevating the tympanomeatal flap and attempting to enter the middle ear without visualizing and elevating the fibrous annulus.
2. Injury to chorda tympani nerve
   This can be avoided by careful dissection when elevating tympanic membrane to expose the posterior mesotympanum. Care must be taken to avoid the chorda during laser crimping.
3. Ossicular trauma
   The positioning of the magnet cylinder may be modified by adjusting the attachment clip angle. This should be done before crimping the attachment coil to minimize ossicular trauma. Manual crimping is avoided for the same reason.

Surgical Technique

- The patient's ear is prepped and draped in the usual sterile fashion.[5]
- The ear canal is injected circumferentially with local anesthetic containing 1:100,000 epinephrine solution, including the posterior vascular strip.
- A tympanomeatal flap is elevated, and the middle ear is entered posteroinferiorly while carefully separating the chorda tympani nerve from the tympanic membrane.

*Indicates equipment/materials provided by the manufacturer at the time of surgery.

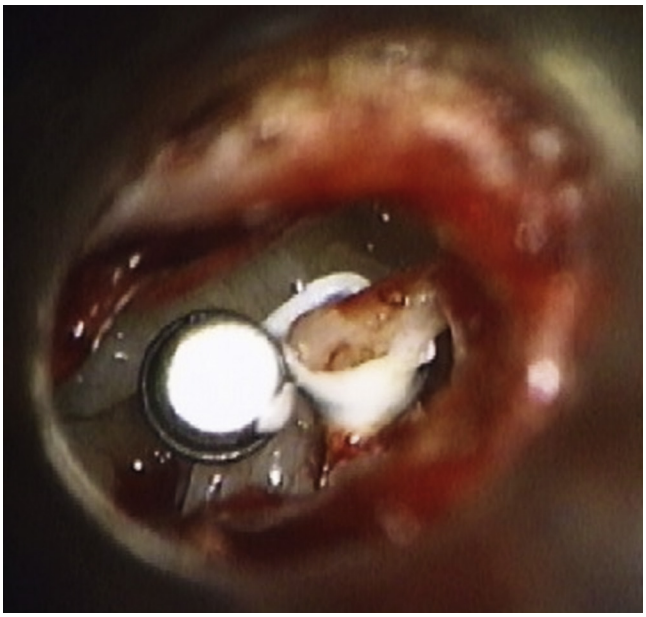

Fig. 136.9. Ideal positioning of Maxum implant cylinder eliciting "full moon" pattern of light reflection.

- The posterosuperior ear canal is curetted until the incudostapedial joint, pyramidal eminence, and tympanic facial nerve are all visible.
- The integrity and mobility of the ossicular chain are then confirmed.
- A moist piece of Gelfoam is positioned over the promontory as a cushion for the implant and to facilitate manipulation and positioning.
- The implant cylinder is picked up with a nonferromagnetic grasper and positioned inferior to the incudostapedial joint with the C-clip around the incudostapedial joint.
- The implant is positioned using the Gelfoam and nonferromagnetic instruments so that the lateral portion of the magnet is perpendicular to the axis of the ear canal. This will elicit a "full moon" pattern of light reflection from the microscope's light (Fig. 136.9).
- The C-shaped clip should be visualized almost circumferentially around the incudostapedial joint before heating with the laser at the lowest power setting.
- A glass ionomeric cement is reconstituted and applied to the C-clip around the incudostapedial joint to further fixate it and prevent movement.
- A photo of the implant cylinder in place is taken and given to the manufacturer to facilitate IPC manufacturing.
- Return the tympanomeatal flap to its native position, and pack the ear canal with antibiotic-soaked Gelfoam.

Common Errors in Technique

1. Suboptimal alignment of implant cylinder
   A "full moon" pattern must be seen from the lateral surface of the magnet prior to fixing it in place. The magnet must also be clear of the promontory or tympanic membrane to ensure proper vibratory freedom.
2. Inadequate or inadvertent cement placement
   Only a very small amount of cement is required to fixate the magnet. Excess can cause fixation to other structures and impair implant mobility. If not completely fixated with cement, the magnet can move when the IPC is not being worn, which causes a disturbing rattling sensation in the ear.

POSTOPERATIVE PERIOD

Postoperative Management

1. Avoid water exposure to the implanted ear for 3 to 4 weeks.
2. An ototopical solution may be used daily for 3 weeks.
3. Remove any residual ear canal packing 3 weeks after surgery.
4. Activate the implant 3 to 4 weeks after surgery.
5. Two or more additional fitting/programming visits may be necessary to optimize the fit and function of the IPC after activation.

Complications

1. Tympanic membrane perforation/trauma
   Persistent perforations incurred from surgery may require myringoplasty if spontaneous closure does not occur 3 to 6 months after surgery. Tympanic membrane trauma from the IPC coil early in the fitting process can occur, but it is rare.
2. Dysgeusia
   This may occur even without obvious trauma to the chorda tympani nerve. This should be managed expectantly.
3. Sensorineural hearing loss
   Excessive or aggressive manipulation of the ossicular chain when securing the attachment clip may cause sensorineural hearing loss.
4. Loose implant magnet
   This usually manifests as reduced hearing benefit or audible rattling with implant magnet vibration when not wearing the IPC. Revision surgery may be required to further fixate the implant.

Alternative Management Plan

As for the Esteem Implant

DISCUSSION

Evidence-Based Medicine Question

Does the Maxum offer any hearing benefit over and above optimally fitted conventional hearing aids?

Several comparative outcomes studies using the SOUNDTEC device have demonstrated average functional gains of up to 10 dB over preoperative best aided conditions, and up to 5% average improvement in speech discrimination scores.[6,7]

Editorial Comment

The Maxum Implant

Overview: As with all hearing implants, careful patient selection is important. Specifically, the patient's ear canal must be straight enough to accommodate the deep insertion tip of the electromagnetic SP (IPC). If the canal is stenotic or angled, a staged, pre-implant canalplasty may be required prior to performing an ear canal mold impression, which is used to create a custom IPC. The implant is capable of up to 60 dB of functional gain from 125 to 12,000 Hz. It is particularly good at amplifying high frequencies. Patients whose PB Max word recognition scores are better than their word recognition scores when tested at 40 dB above SRTs, or at maximum comfort levels, have been found to be good candidates. Direct stapedial and cochlear vibration lead to increased fidelity due to low distortion characteristics of the implant. IPC adjustments may require some trial and error. Most patients adapt to the deep insertion IPC within 3 weeks. Bilateral implants are possible. Scratching sounds sometimes reported with first-generation implants have been eliminated by second-generation design enhancements.

Surgical considerations: The operative procedure is performed through a straightforward, outpatient, transcanal tympanotomy under local or general anesthesia. Adequate visualization of the incus and stapedius tendon is necessary. The Nitinol split ring connector is right- or left-ear specific. During implantation, nonmagnetic, Maxum middle ear instruments are used to prevent the implant from attracting to the standard surgical instruments. Carefully placing the split ring around the lenticular process and heat shrinking the ring requires a gentle learning curve. Once heat crimped, the stapedius tendon stabilizes the ring during fine adjustments prior to applying cement. Intraoperative photographs are taken to help facilitate the postoperative IPC tip adjustment.

Eric M. Kraus

Access the review questions and additional sources list online at http://www.expertconsult.com

REFERENCES

1. Glasscock ME, Shohet JA. Implantable middle ear hearing devices: Esteem and Maxum. In: Kirtane M, de Souza CE, Sanna M, Devaiah AK, editors. Otology and Neurotology. Stuttgart, New York, Delhi: Rio, Thieme Verlagsgruppe; 2013. p. 233–240.
2. Seidman MD, Standring RT, Ahsan S, et al. Normative data of incus and stapes displacement during middle ear surgery using laser Doppler vibrometry. Otol Neurotol 2013;34(9):1719–1724.
3. Vibrant Soundbridge: The Implantable Hearing System Surgical Guide, MED-EL. http://www.medel.com/data/pdf/28031.pdf.
4. Snik FM, Cremers WR. First audiometric results with the Vibrant Soundbridge, a semi-implantable hearing device for sensorineural hearing loss. Int J Audiol 1999;38(6):335–338.
5. Hough JV, Dyer RK, Glasscock ME. Surgeon's Manual, Maxum System. Houston, Ototronix: LLC; 2012.
6. Roland PS, Shoup AG, Shea MC, et al. Verification of improved patient outcomes with a partially implantable hearing aid, the SOUNDTEC direct hearing system. Laryngoscope 2001;111:1682–1686.
7. Silverstein H, Atkins J, Thompson Jr HJ, et al. Experience with the SOUNDTEC implantable hearing aid. Otol Neurotol 2005;26:211–217.

REVIEW QUESTIONS

1. In patients with the Esteem Implant, development of acute eustachian tube dysfunction can result in all of the following, except
   a. Decreased hearing
   b. Ear pain
   c. Feedback
   d. Vertigo

2. Which of the following is a contraindication for hearing rehabilitation with an Esteem Implant?
   a. Meniere disease
   b. Prior history of herpes zoster oticus
   c. External canal exostoses
   d. Tinnitus

3. Hearing benefit with the Vibrant Soundbridge implant may be impacted by all of the following, except
   a. Cementing the FMT attachment clip to the incus
   b. Thick scalp flap
   c. Marginal contact between the FMT and the promontory
   d. Mild eustachian tube dysfunction

4. Risks of Vibrant Soundbridge implant surgery include:
   a. Alopecia
   b. Dysgeusia
   c. Facial hypoesthesia
   d. Tympanic membrane perforation

5. What is the most likely cause of rattling in an ear implanted with the Maxum device?
   a. Incorrect placement of the implant magnet
   b. Contact between the magnet cylinder and the promontory
   c. Contact between the magnet cylinder and the tympanic membrane
   d. Inadequate fixation of implant magnet on the ossicular chain

6. When implanting the Maxum, the chorda tympani nerve is at risk for injury except when:
   a. Elevating the tympanomeatal flap
   b. Curetting the posterosuperior ear canal
   c. Palpating the ossicular chain
   d. Laser crimping the attachment clip

ADDITIONAL SOURCES

Hunter JB, Carlson ML, Glasscock III ME. The Ototronix MAXUM middle ear implant for high-frequency sensorineural hearing loss: preliminary results. Laryngoscope 2016;126(9):2124–2127.

Comparative results between MAXUM middle ear implant and conventional hearing aids for patients with severe high frequency sensorineural hearing loss.

Kraus EM, Shohet JA, Catalano PJ. Hearing results with the ESTEEM Totally Implantable middle ear device: phase II trial-1year results. Otol Head Neck Surgery 2011;145(1):100–109.

This publication discusses hearing outcomes and adverse events related to 57 Esteem patients implanted across three US clinical sites during the Phase II FDA trial.

Luetje CM, Brackman D, Balkany T, et al. Phase III clinical trial results with the Vibrant Soundbridge implantable middle ear hearing device: a prospective controlled multicenter study. Otolaryngol Head Neck Surg 2002;126(2):97–107.

Short-term hearing outcomes and adverse events for 53 patients implanted with Vibrant Soundbridge during the US Phase III clinical trials.

Maurer J, Savvas E. The Esteem System: a totally implantable hearing device. Adv Otorhinolaryngol 2010;69:59–71.

Comprehensive review of the Esteem technology and surgical technique.

Mosnier I, Sterkers O, Bouccara D, et al. Benefit of Vibrant Soundbridge device in patients implanted for 5 to 8 years. Ear Hear 2008;29(2):281–284.

A European multicenter retrospective analysis of objective and subjective long-term hearing results for 77 patients implanted with Vibrant Soundbridge for sensorineural hearing loss.

Sziklai I, Szilvassy J. Functional gain and speech understanding obtained by Vibrant Soundbridge or open-fit hearing aid. Acta Otolaryngol 2011;131(4):428–433.

Comparison of hearing outcomes between open fit hearing aids and Vibrant Soundbridge for sloping high frequency sensorineural hearing loss.

137 Cochlear Implantation in Adults

Jonathan L. McJunkin, Craig Buchman

INTRODUCTION

A cochlear implant is an implanted medical device that restores the ability to perceive sound. The two patient populations that have benefited most from cochlear implants are children with congenital or early-onset profound hearing loss and postlingual adults who no longer benefit from amplification.

KEY OPERATIVE LEARNING POINTS

- The middle ear is accessed via mastoidectomy through a facial recess approach between the facial and chorda tympani nerves.
- The round window is located inferior to the incudostapedial joint and is the key landmark for insertion of the electrode array.
- The receiver-stimulator portion of the cochlear implant is positioned 2 cm posterior to the mastoidectomy cavity.
- Slow insertion of the electrode is thought to minimize trauma to the inner ear and potentially preserve hearing.

PREOPERATIVE PERIOD

History

History of Present Illness

- Details of hearing loss: When did the hearing loss begin? Has its progression been gradual, rapid, or sudden? Is there a known cause for the hearing loss—hereditary, noise-related, ototoxic medications, meningitis? Which ear is the better-hearing ear?
- Amplification history: How long has the patient used amplification in each ear? If/when did the patient stop wearing a hearing aid on either side?
- Current communication ability: How much lip-reading ability does the patient have? Which environments are problematic? Is the patient socially isolated?

Past Medical History

- Prior treatment: Sudden hearing loss, chronic ear disease, previous ear infections, radiation therapy
- Medical illness: Any conditions precluding 3 hours of general anesthesia? Cardiac, pulmonary status?
- Surgery: Prior implants? Stapes surgery? Chronic ear surgery? Craniotomy?
- Medications: Surgery on patients using anticoagulants: nonsteroidal anti-inflammatory drugs (NSAIDs), warfarin, rivaroxaban. Inquire about oral narcotic with acetaminophen abuse.

Physical Examination

- General appearance: Ability to communicate in office setting? Eye contact? Syndromic features?
- Ear: Postauricular skin characteristics? Previous surgical scars? Ear canal and tympanic membrane intact, free of infection? Otorrhea?
- Vestibular: Nystagmus? Gait?
- Cranial nerves: Facial nerve function? Weber and Rinne tests?

Imaging

- Standard preoperative computed tomography (CT) imaging to assess temporal bone anatomy. Check for abnormal cochlear morphology (ossification in setting of meningitis); enlarged vestibular aqueduct; and characteristics of the facial nerve, sigmoid sinus, and tegmen.
- Magnetic resonance imaging (MRI) may be used in patients where there is concern for cochlear nerve aplasia in order to visualize the nerve within the internal auditory canal. It may also help in assessing the patency of the cochlea.

Indications

- Children with prelingual deafness
  - Children 1 to 2 years of age: Pure tone average (PTA) >90 dB in bilateral condition
  - Children above 2 years of age: Pure tone average (PTA) >0 dB in bilateral condition or failure to progress with auditory amplification
- Adults with postlingual deafness
  - Bilateral moderate to profound sensorineural hearing loss no longer benefiting from amplification
  - Open set sentence bilateral testing less than 60% in best-aided condition, less than 50% in the better ear (non-Medicare)
  - Hybrid cochlear implant
    - Normal to moderate hearing loss in low frequencies and severe to profound loss in the middle to high frequencies
    - Consonant-nucleus-consonant (CNC) word score between 10% and 60% in the ear to be implanted in the preoperative aided condition and the other ear equal or better but not above 80%
    - Previous suitable hearing aid trial if not already using amplification

Contraindications

- Cochlear nerve aplasia
- Cochlear aplasia
- Active middle ear infection

Preoperative Preparation

- Chlorhexidine scrub in the 24-hour period before surgery
- Pneumococcal vaccinations (Pneumovax 23 and Prevnar 13)
- Cessation of anticoagulants

OPERATIVE PERIOD

Anesthesia

- General

Positioning

- Supine with the head turned away from the operative side

Preoperative Antibiotic Prophylaxis

- First-generation cephalosporin

Monitoring

- Facial nerve monitor

Instruments and Equipment to Have Available

- Operating microscope
- Standard mastoidectomy equipment
- Cochlear implant insertion instruments set
- Smooth jeweler's forceps
- 5910 Beaver ophthalmic blade for round window incision

Key Anatomic Landmarks

- Incudostapedial joint/oval window: The stapedial tendon is often the first landmark visualized upon entering the middle ear through a facial recess approach. The tendon originates from the pyramidal process and attaches to the stapes, which is located in the oval window. The round window niche can be identified directly inferior to the oval window.
- Round window: The round window overlies the scala tympani of the basal turn of the cochlea.
- Facial nerve: The middle ear space is accessed from the mastoid by posterior tympanotomy (facial recess) between the facial nerve and chorda tympani nerve.

Prerequisite Skills

- Complete mastoidectomy
- Fine motor skills are necessary to insert the electrode

Operative Risks

- Improper insertion of the cochlear implant:
  The electrode array can be placed into a hypotympanic air cell, missing the cochlea entirely. This risk can be minimized by obtaining adequate exposure through the facial recess approach and carefully removing the lip of bone overlying the round window. There is frequently a layer of fibrous tissue that obscures the round window; this should be removed as well.
- Injury to the facial nerve
- Injury to the chorda tympani nerve
- Violation of the annulus, entry into the medial external auditory canal
- Injury to a low-lying mastoid tegmen, leak of cerebrospinal fluid (CSF)

Surgical Technique

- Timeout to confirm that the correct side is being performed
- The operative ear is prepped and draped.
- The skin incision is marked 1 cm posterior to the postauricular crease superior to the mastoid tip to the level of the superior temporal line (Fig. 137.1).
- The postauricular incision site is injected with 1% lidocaine with 1:100,000 epinephrine.
- Soft tissue dissection is carried down to the level of the periosteum. The edges of the incision are undercut to gain exposure toward the mastoid tip and zygomatic root.
- The periosteum of the mastoid is incised to create an anteriorly based periosteal flap that is elevated anteriorly to the level of the spine of Henle. The posterior aspect of the external auditory canal is identified without elevating the soft tissue medially along the canal.



Fig. 137.1. Skin incision marked for cochlear implant on the right side.

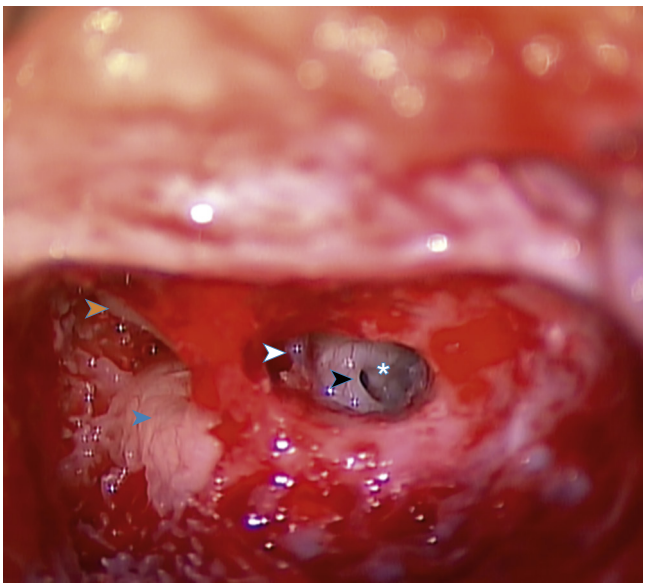

Fig. 137.2. Facial recess approach view of right ear. *Orange arrow:* Lateral process of incus. *Blue arrow:* Lateral semicircular canal. *White arrow:* Incudostapedial joint. *Black arrow:* Round window niche. *Asterisk:* Cochleostomy site located anteroinferior to round window.

- Complete mastoidectomy is performed. The bony posterior canal wall is thinned. A facial recess approach is performed.
- The incudostapedial (IS) joint in the middle ear space is identified.
- The round window niche 2 mm inferior to the IS joint is identified (Fig.137.2).
- Carefully remove the lip of bone superior to the round window using the drill. Remove any fibrous tissue that obscures a clear view of the round window membrane (Fig. 137.3).
- Cochleostomy can be performed anteroinferior to the round window by drilling the bone until it is eggshell thin. The last layer is ideally removed with either a pick or rasp to minimize damage to intracochlear structures.

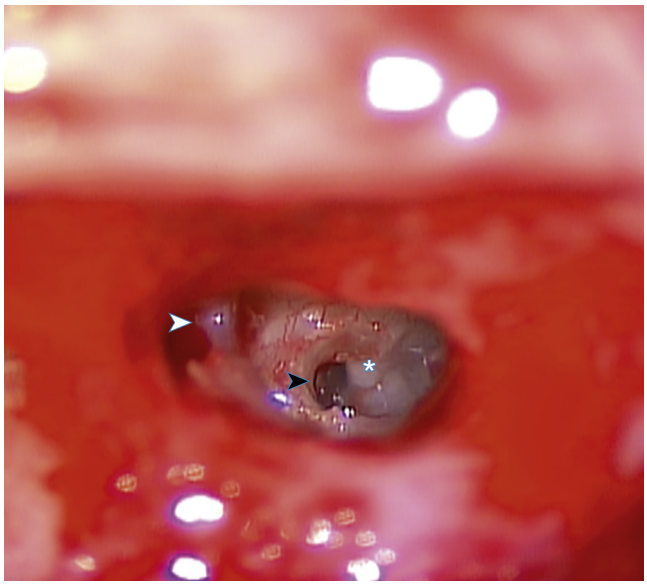

Fig. 137.3. Magnified view of right ear facial recess. *White arrow:* incudostapedial joint. *Black arrow:* Round window after niche has been opened. *Asterisk:* Cochleostomy site anteroinferior to round window.

- Sodium hyaluronate or another lubricating solution may be applied over the cochleostomy site.
- Once the approach to the cochlea is complete, the site for the receiver-stimulator is prepared.
- A subperiosteal pocket is developed posterosuperior to the edge of the mastoidectomy.
- The implant mockups are used to determine when an adequate pocket has been elevated. The device is typically placed at a 30- to 45-degree angle superiorly from the temporal line.
- The well for the implant is drilled at a minimum of 2 cm posterior to the mastoidectomy site to make sure that the anterior edge of the receiver-stimulator will not abut the external portion of the processor.
- A channel is drilled from the well to the mastoidectomy for the electrode array. The silicone mockup is used to check that the device can easily be placed into the prepared site.
- The wound is copiously irrigated to remove any bone dust. The monopolar cautery is taken off the field.
- The implant is placed into the subperiosteal pocket and drilled well with the Weitlaner retractor, which is already in place, to avoid damaging the implant.
- The orientation of the stimulating electrodes is visualized with the microscope. The electrodes should be oriented superiorly to face the cochlear modiolus upon insertion (Fig. 137.4).
- The electrode array is inserted into the cochlea slowly, using smooth forceps to grasp the array just proximal to the contacts.
- The insertion technique will vary depending on the design of the electrode array. Certain arrays are placed with the advanced off-stylet technique: The array is initially inserted partially with a stylet in place. It is then advanced slowly and smoothly into the cochlea while the stylet is held steady. Once the array has been fully inserted, the stylet is removed while the array is held in place. If there is initial difficulty with insertion, the array can be gently rotated or backed out slightly before attempting to readvance it. The array is inserted to the marker rings as indicated by the manufacturer.

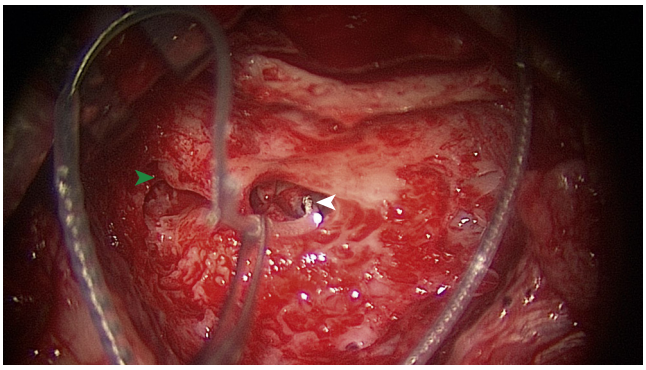

Fig. 137.4. Cochlear Implant electrode array insertion in a right ear. Note that the contacts of the electrode array are oriented superiorly toward the modiolus. *White arrow:* Electrode array at round window with contacts oriented superiorly. *Green arrow:* Incus.

- A small piece of soft tissue (fascia or periosteum) is placed at the cochleostomy adjacent to the array to seal the site. Another piece of fascia can be placed in the facial recess.
- If there is excess length to the electrode array, it is carefully coiled in the mastoid cavity to avoid pulling the array from the cochlea.
- The grounding electrode (if present) is placed under the temporalis muscle superiorly.
- The periosteum is closed to cover the electrode array. The soft tissue is closed in three layers. A mastoid dressing is applied.

Common Errors in Technique

- Inadequate facial recess:
  A narrow facial recess makes identification of the round window more difficult. Insertion of the electrode array is also more challenging if there is inadequate anteroposterior space to release the array from the inserting forceps.
- Anterior placement of receiver stimulator:
  While minimizing the length of the postauricular incision is cosmetically appealing, the implant must be placed an adequate distance posteriorly to allow space for the external portion of the device. Smaller incisions make it more difficult to visualize tissue elevation posteriorly while also controlling bleeding.
- Rapid insertion of the electrode array:
  Slower insertion of the electrode array minimizes damage to intracochlear structures.[1]

POSTOPERATIVE PERIOD

Postoperative Management

- The mastoid dressing should be worn for 24 hours. The patient can shower without scrubbing the wound after 48 hours.
- Pain medication: Mild pain is expected after cochlear implant surgery.
- Anticoagulants can be restarted on postoperative day 1.

Complications

- Hematoma: The patient should be counseled to monitor for unusual swelling or color change of the incision site. Any significant edema or bleeding from the incision is atypical and requires evaluation. If a hematoma develops,

the patient should be taken back to the operating room for evacuation of the hematoma and control of bleeding.
- Infection: Any purulent drainage from the wound or overlying skin edema and erythema are concerning for infection. Antibiotics should be started promptly. If infectious signs do not improve rapidly, limited incision and drainage without device removal is often effective.[2]
- Injury to the chorda tympani nerve: The patient may report taste dysfunction (metallic sensation) on the affected side if the chorda tympani nerve is injured. This can last for months before gradually resolving.
- Injury to the facial nerve: Facial paralysis in the immediate postoperative period warrants careful reflection by the surgeon on the mechanism and site of injury. Possibilities include heat transfer from the drill shaft while exposing the round window through the facial recess approach or direct injury to the mastoid segment. If there is concern for direct injury, the patient should be returned to the operating room for exploration. Delayed or partial facial weakness should be managed conservatively.
- Meningitis: The overall risk of meningitis is slightly higher in cochlear implant recipients compared with the general population.[3]

Alternative Management Plan

- Auditory amplification
- Sign language and lip reading

DISCUSSION

Evidence-Based Medicine Question

Do cochlear implant recipients achieve better open set word recognition than in the best-aided preoperative condition?

Yes. One study demonstrated an average improvement from 16% preoperative HINT score to 61% CNC score in the implanted ear.[4]

Editorial Comment

Cochlear implant technology has evolved over the past 30 years. The properly screened patient can be offered an implant with the assurance that he or she will achieve significant benefit not experienced with a hearing aid. The indications for candidacy have been lifted from people only with profound hearing loss to those with normal hearing in the low frequencies and severe to profound loss in the high frequencies. If low-frequency hearing is not preserved with a hybrid device (electric acoustic stimulation), the outcome has still been shown to be better than with the use of a hearing aid alone.

Bilateral implants should enhance sound localization and the ability to understand conversations in the presence of background noise. Most third-party providers support implantation of a second device. It is thought that central processing is augmented with input from both ears. In our experience, most adult patients are satisfied with one cochlear implant and use of a hearing aid in the opposite ear.

Testing for candidacy has been modified to allow people with less severe hearing loss to become candidates. Previous tests were done using hearing in noise test (HINT) tests without competing sound. AzBio sentence testing adds a more difficult dimension to the method of testing. Currently, background sound can be instilled into the testing paradigm to create an environment similar to that of the real world. Presentation levels with a signal-to-noise level of +5dB make it harder for people with hearing aids to function. A cochlear implant can be offered with the assurance that it can reliably improve the ability to hear speech.

For many recipients a cochlear implant is a life-changing event. They are no longer isolated from employment, family, and friends. This is a remarkable technology that brings back one of the critical special senses: the hearing of sound and speech.

Barry Hirsch

Access the review questions and additional sources list online at http://www.expertconsult.com

REFERENCES

1. Kontorinis G, Lenarz T, Stöver T, et al. Impact of the insertion speed of cochlear implant electrodes on the insertion forces. Otol-Neurotol 2011;32(4):565–570.
2. Yu KC, Hegarty JL, Gantz BJ, et al. Conservative management of infections in cochlear implant recipients. Otolaryngol Head Neck Surg 2001;125(1):66–70.
3. Reefhuis J, Honein MA, Whitney CG, et al. Risk of bacterial meningitis in children with cochlear implants. N Engl J Med 2003;349:435–445.
4. Holden LK, Finley CC, Firszt JB, et al. Factors affecting open-set word recognition in adults with cochlear implants. Ear Hear 2013;34(3):342–360.

REVIEW QUESTIONS

1. Where in the cochlea is the electrode array placed?
   a. Scala tympani
   b. Scala media
   c. Scala vestibuli
   d. Scala olympi

2. Cochlear implants are contraindicated for patients with profound sensorineural hearing loss and
   a. Mondini malformation
   b. History of meningitis
   c. Age above 85 years
   d. Active middle ear infection

3. The most frequently used landmarks in the middle ear to identify the round window niche include the following, except the
   a. Stapes tendon
   b. Oval window
   c. Facial nerve
   d. Eustachian tube

4. What is the key landmark for positioning the cochleostomy?
   a. Oval window
   b. Cochleariform process
   c. Pyramidal process
   d. Round window

ADDITIONAL SOURCES

Bigger RC, Black FO. Auditory prostheses in perspective. Ann Otol Rhinol Laryngal 1977;86(Suppl 38):3–10.
This was a landmark study requested by the NIH to study the efficacy of cochlear implants. Researchers found improved lip reading and sound awareness amongst recipients and validated the concept of cochlear implantation.

Cohen NL, Waltzman SB, Fisher SG. A prospective, randomized study of cochlear implant patients. The Department of Veteran Affairs Cochlear Implant Study Group. N Engl J Med 1993;328(4):233–237.
This is a prospective study that demonstrated improved cochlear implant performance in patients with multichannel electrode arrays over single channel arrays.

138 Facial Nerve Decompression

J. Seth McAfee

INTRODUCTION

The facial nerve is afflicted by paralysis more frequently than any other nerve in the body, most commonly in its peripheral segment as it courses through the temporal bone. The functional and cosmetic implications of facial paralysis carry the potential to significantly impact a patient's life, with resulting psychologic damage. There are many sources of otologic facial paralysis (Table 138.1), and managing facial paralysis is inevitable in the career of physicians managing otologic pathology. This chapter focuses on the role of facial nerve decompression in managing facial paralysis.

The facial nerve is composed of an estimated 10,000 fibers.[1] Seventy percent are myelinated motor axons innervating the muscles of facial expression, and the remaining 3000 fibers are spread amongst general visceral efferents (salivation and lacrimation), general sensory afferents (cutaneous sensation), and special visceral afferents (taste). The extent to which facial animation is compromised is directly correlated to the fraction of injured motor fibers. The anatomy of the facial nerve is organized by distinct layers, including the endoneurium, perineurium, and epineurium (Fig. 138.1). The endoneurium surrounds each nerve fiber, closely adherent to the Schwann cell layer of each axon. Individual fibers are then grouped into fascicles, and each fascicle is surrounded by perineurium. The epineurium is the outermost layer, where the vasa vasorum and lymphatics deliver oxygen and nutrients to the nerve. Sunderland[2] described a classification system for stratifying the severity of seventh nerve injury, as outlined in Fig. 138.2. First-degree injury is termed neuropraxia, describing a physiologic conduction block due to intraneural edema, with intact neural structure. Relief of compressive forces facilitates resolution of injury and return of function. Second-degree injury results from failure to relieve compressive forces, termed axonotmesis, resulting in injury to axons without violation of the endoneurial sheath. With relief of the pathologic process, complete recovery is anticipated. Third-degree injury indicates disruption of the endoneural tubules. Disruption of endoneurial tubules allows disorganized axonal regeneration, as each axon can enter any open endoneurial tube. This pattern of disorganized, faulty regeneration accounts for synkinesis, and recovery is anticipated to be incomplete. Fourth-degree injury is characterized by violation of the perineurium in addition to axons, myelin sheaths, and endoneurium. Attempts at regeneration are even more disorganized, with axons aberrantly entering the wrong fascicles. Fifth-degree injury is characterized by complete laceration or transection of the nerve, to include the epineurium. Recovery after fourth- and fifth-degree injury is uniformly poor. Neurotmesis includes third through fifth degree injuries.

KEY OPERATIVE LEARNING POINTS

1. The decision as to whether facial decompression is advantageous is based upon the etiology of paralysis, duration of paralysis, and outcome of electrodiagnostic testing.
2. Electrodiagnostic testing is necessary only in cases of complete paralysis, as the prognosis for cases of incomplete paralysis is uniformly good.
3. Evoked electromyography (EEMG) may underestimate the extent of recovery in a regenerating nerve and should be followed by electromyography (EMG) to survey for voluntary motor unit action potentials (VUMAPs), prior to consideration of decompression.
4. There is no consensus in the literature to support facial decompression in acute otitis media (AOM).
5. Facial paralysis in context of chronic otitis media (COM) with cholesteatoma should be addressed operatively without delay, with goals of exploring the facial nerve and eliminating disease.
6. Surgical decompression for Bell's palsy must address the meatal foramen. This can be accomplished by middle fossa or translabyrinthine approaches.

PREOPERATIVE PERIOD

History

1. History of present illness
   a. How long has the paralysis been present?
   b. Was the paralysis abrupt or gradual in onset?
   c. Has this occurred previously (ipsilateral or contralateral)?
   d. Does the patient have hearing loss?
   e. Does the patient have ear pain or drainage?
   f. Is the patient dizzy?
   g. Was there associated trauma to the head?
2. Past medical history
   a. Does the patient have a history of chronic ear disease?
   b. Has the patient been previously diagnosed with Bell's palsy?
3. Surgical history
   a. Has the patient had prior otologic surgery?
4. Medications
   a. Is the patient anticoagulated?

Physical Examination

1. Facial examination
   a. Which branches of the facial nerve are affected?
   b. What is the extent of the weakness?
   c. What is the House-Brackmann score? (Table 138.2)
   d. Is there involvement of other cranial nerves?
   e. Is there or has there been a vesicular rash?

2. Otologic examination
   a. Is there suppurative drainage or cholesteatoma?
   b. Is there trauma to the ear canal or tympanic membrane?

Imaging

The decision as to whether imaging is necessary is guided by the etiology of the paralysis. A radiographic evaluation generally provides little information for a diagnosis of Bell's palsy. However, a surgeon considering middle fossa decompression may obtain computed tomography (CT) to assist in identifying surgical landmarks or to facilitate intraoperative image guidance. Facial paralysis in combination with suppurative ear disease warrants imaging to evaluate the course of the facial nerve, survey for additional intratemporal or intracranial complications, and to facilitate preoperative planning and counseling.

Paralysis exceeding 6 months duration, facial twitching, slow progression of weakness over a period of weeks to months, and recurrent episodes should prompt a radiographic evaluation for neoplastic disease.

1. Electrodiagnostic testing
   Electrodiagnostic testing represents the primary diagnostic modality by which the severity of neural injury is assessed, facilitating estimations of prognosis. A finding of facial paralysis is not specific with respect to the extent of injury, as a patient with neuropraxia may demonstrate paralysis of similar severity to the patient with a transected nerve. In turn, the goal of electrodiagnostic testing is to identify the

TABLE 138.1 Differential Diagnosis for Facial Paralysis

Birth	**Neoplastic**
Traumatic vaginal delivery	Facial nerve neuroma
Myotonic dystrophy	Facial nerve hemangioma
Mobius' syndrome (facial diplegia associated with other cranial nerve deficits)	Vestibular schwannoma
	Glomus jugulare tumor
	Meningioma
	Von Recklinghausen's disease
	Cholesterol granuloma
	Carcinoma (invasive or metastatic from the breast, kidney lung, stomach, larynx, prostate, or thyroid)
Traumatic	**Toxic**
Cortical injuries	Thalidomide (Miehlke's syndrome: involvement of cranial nerves VI and VII with atretic external ears)
Basilar skull fractures	Tetanus
Brainstem injuries	Diphtheria
Penetrating injury to the middle ear	Carbon monoxide
Facial injuries	Lead intoxication
Barotrauma	
Neurologic	**Iatrogenic**
Opercular syndrome (cortical lesion in the facial motor area)	Mandibular block anesthesia
Millard-Gubler syndrome (abducens palsy with contralateral hemiplegia because of a lesion in the base of the pons involving the corticospinal tract)	Anti-tetanus serum
	Vaccine treatment of rabies
	Otologic, skull base, and parotid surgery
	Embolization
Infectious	**Idiopathic**
Malignant otitis externa	Bell's palsy
Acute or chronic otitis media	Melkersson-Rosenthal syndrome (recurrent facial palsy, furrowed tongue, fascial labial edema)
Cholesteatoma	Hereditary hypertrophic neuropathy (Charcot-Marie-Tooth disease, Dejerine-Sottas disease)
Meningitis	
Parotitis	Autoimmune syndromes of temporal arteritis, periarteritis nodosa, and other vasculitides
Chickenpox	
Herpes zoster oticus (Ramsay Hunt syndrome)	Guillain-Barre syndrome (ascending paralysis)
Encephalitis	Multiple sclerosis
Poliomyelitis (type I)	Myasthenia gravis
Mumps	Sarcoidosis (Heerfordt's syndrome, uveparotid fever)
Mononucleosis	Wegener's granulomatosis
Leprosy	Eosinophilic granuloma
Human immunodeficiency virus and acquired immunodeficiency syndrome	Amyloidosis
	Hyperostoses (e.g., Paget's disease, osteopetrosis)
Influenza	Kawasaki disease (infantile acute febrile mucocutaneous lymph node syndrome)
Coxsackievirus	
Malaria	
Syphilis	
Tuberculosis	
Botulism	
Mucormycosis	
Lyme disease	
Genetic and Metabolic	**Vascular**
Diabetes mellitus	Benign intracranial hypertension
Hyperthyroidism	Intratemporal aneurysm of the internal carotid artery
Pregnancy	
Alcoholic neuropathy	
Bulbopontine paralysis	
Oculopharyngeal muscular dystrophy	

Data modified from Mary M: Differential diagnosis by history, physical findings and laboratory results. In May M (ed): The Facial Nerve. New York, Thieme-Stratton, 1986.

patient population sustaining injury of such severity that the chance of satisfactory, spontaneous recovery is low. This information is gathered by way of facial EMG and EEMG. Electrodiagnostic testing is necessary only in cases of complete paralysis, as the prognosis for cases of incomplete paralysis is uniformly favorable.

a. Evoked electromyography

EEMG assesses the functional capacity of the nerve by measuring the amplitude and latency of a compound muscle action potential (CMAP) after neural stimulation. This is accomplished with the use of surface electrodes placed at the stylomastoid foramen for stimulation and the nasolabial fold for measurement. The CMAP of the injured side is comparatively expressed as a percentage of the normal side, that percentage representing the number of electrically excitable fibers. Because the applied stimulus cannot propagate through degenerated axons, the CMAP represents the collective stimulus of intact (neuropraxic) fibers. It should be noted that a transected facial nerve may generate a CMAP of normal amplitude until Wallerian degeneration and sufficient axonal loss have progressed beyond the intratemporal segment, past the point of the applied stimulus. This process occurs over a period of 48 to 72 hours, during which EEMG provides limited useful information. EEMG should then be performed on an every other day basis to survey for progressive axonal degeneration (Fig. 138.3). Reliability of EEMG fades after a period of 2 to 3 weeks, as regenerating fibers and fibers recovering from neuropraxia fire asynchronously, yielding a disorganized, diminished response.

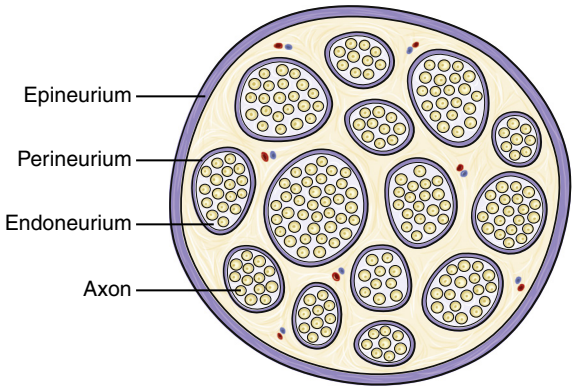

Fig. 138.1. Cross-section schematic of nerve demonstrating endoneurium, perineurium, and epineurium.

b. Facial nerve electromyography

In contrast to EEMG, EMG measures responses that are volitional in nature. Needle electrodes are inserted into facial musculature for analysis of resulting electrical activity during insertion, rest, and volitional movement. EMG is capable of detecting VUMAPs when no facial mobility is visually evident.[3] This feature renders EMG helpful in the setting of postoperative paralysis. If the nerve is transected, EMG will immediately show loss of VMUAP. However, loss of VMUAP is not specific to nerve transection, as neuropraxia may generate identical findings.[4] Therefore, demonstration of VMUAP is helpful to the surgeon in that it indicates the nerve is intact. Loss of VMUAP in this setting is less helpful, given the lack of specificity in regards to severity of injury. While EMG is capable of identifying a nerve as intact in the acute period, it is incapable of confirming degeneration in this time frame. Contrarily, EMG does provide utility in detecting muscle denervation 2 to 3 weeks out from injury, as destabilized resting potentials of the muscle membrane appear graphically as fibrillation potentials. This 2- to 3-week period represents the time in which Wallerian degeneration ensues. Polyphasic action potentials n this time frame indicate muscle re-innervation. Finally, when

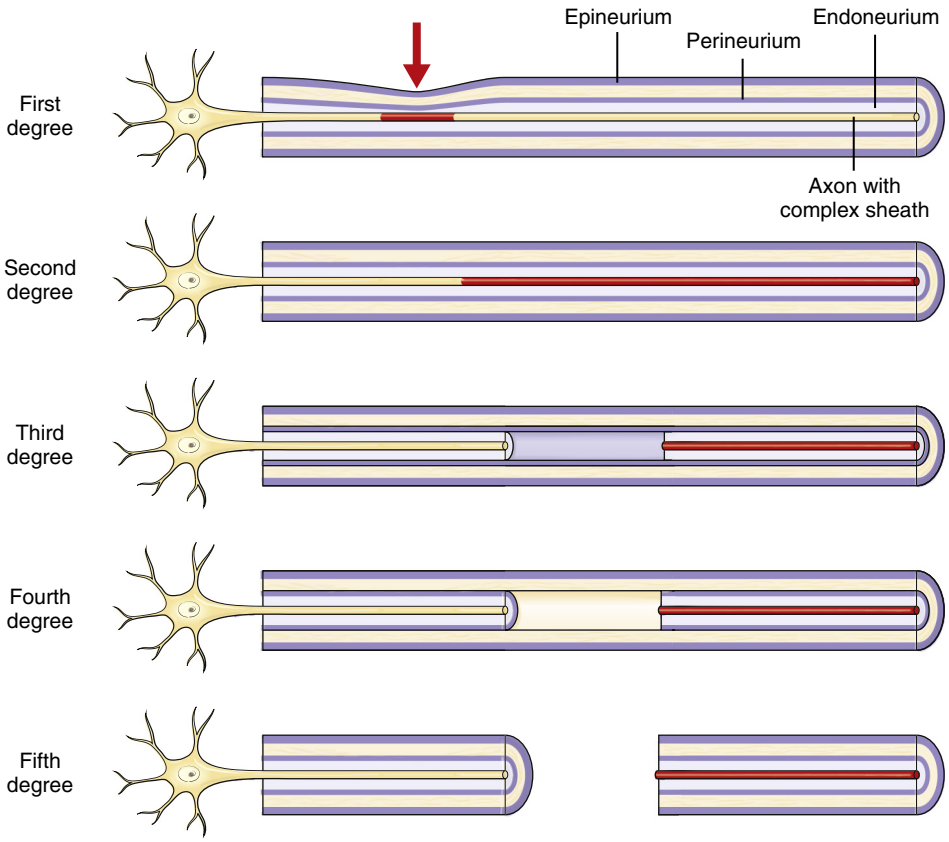

Fig. 138.2. Classification of Degrees of Neural Injury (From Sunderland): First degree—Compression (arrow) without loss of structure; recovery is normal. Second degree—Axon degeneration: regeneration is appropriate, and recovery is satisfactory. Third degree—Loss of endoneural tubes; recovery is incomplete with synkinesis. Fourth degree—Disruption of perineurium; recovery is very poor. Fifth degree—Complete disruption; no recovery.

TABLE 138.2 House-Brackmann Facial Nerve Grading System

Grade 1	Normal	Normal function in all areas
Grade 2	Mild dysfunction	Slight weakness noticeable on close inspection
Grade 3	Moderate dysfunction	Noticeable but not disfiguring weakness. Complete eye closure with effort. Mild synkinesis
Grade 4	Moderately severe dysfunction	Obvious weakness and/or disfiguring asymmetry. Incomplete eye closure. Normal symmetry/tone at rest
Grade 5	Severe dysfunction	Barely perceptible motion. Disfiguring asymmetry at rest
Grade 6	Total Paralysis	No movement

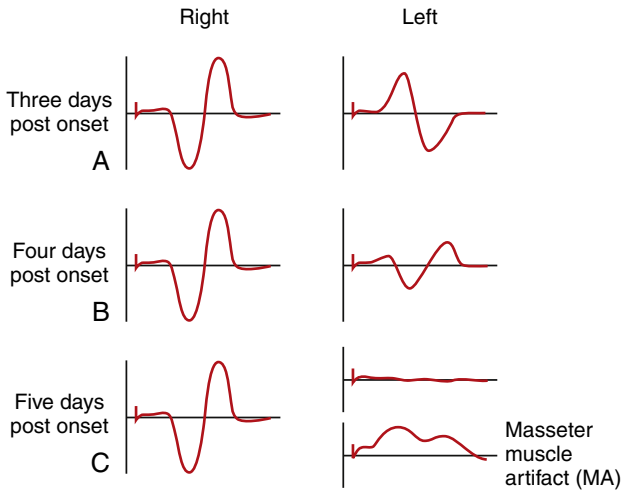

Fig. 138.3. Compound muscle action potential comparison of evoked electromyography. Progressive loss of response on the left as a result of axonal degeneration. **A,** Three days post onset. **B,** Four days post onset. **C,** Five days post onset. Masseter muscle artifact may be confused with a small evoked potential. The masseter is stimulated when high voltages are used. It can be best identified by its very short latency.

EEMG results have progressed to thresholds indicating need for decompression, EMG should be performed to survey for early VMUAPs, which project a favorable prognosis in absence of surgical intervention. This is necessary because with early reversal of a conduction blockade, dys-synchrony of nerve firing may result in failure to generate a CMAP, yielding a false-positive result on EEMG.

2. Audiogram
Defining auditory function will assist in reaching a diagnosis. For those patients requiring facial nerve decompression, the status of hearing is a key consideration in choosing a surgical approach.

Indications

1. Bell's palsy
Bell's palsy is a diagnosis of exclusion, presenting as an acute hemifacial weakness in the absence of further symptomatology. Weakness is global in distribution, and sparing of the forehead suggests a central etiology. Bell's palsy is by far the most common of the acute facial palsies, accounting for 75% of cases, at an estimated incidence of 30 to 40 cases per 100,000 people annually. Reviews of the natural history demonstrate satisfactory recovery in greater than 80%, and 85% of patients will demonstrate improvement within 3 weeks of onset.[5] Timing to onset of recovery and completeness of the palsy are the two most significant prognostic indicators.

Electrodiagnostic studies have localized the conduction blockade in Bell's palsy to the meatal foramen,[6] which is the entry location of the facial nerve into the temporal bone, forming the labyrinthine segment. This is the narrowest segment of the canal, estimated at 0.68 mm in diameter. The anatomy of the meatal foramen is characterized by a confluence of Bill's Bar and the falciform (transverse) crest with dense periotic bone laterally in the internal auditory canal (IAC). The nerve is devoid of epineurium, and is instead ensheathed by a band of periosteum that seals the entry site into the fallopian canal, resulting in potential for entrapment in situations of neurogenic edema (Fig. 138.4).

The mainstay of the patient's evaluation in Bell's palsy is electrodiagnostic testing. Audiometry demonstrates symmetric function, with the exception of an absent acoustic reflex on the involved side, and routine use of imaging is unnecessary. Facial nerve decompression is indicated for patients demonstrating CMAP reduction of 90% or greater, with confirmed lack of motor activity on voluntary facial EMG.[7,8] These criteria are based upon the observation that approximately one half of this patient population will sustain permanent, unsatisfactory recovery in the absence of decompression. If 90% degeneration is not documented within 2 weeks of onset, further electrodiagnostic testing is unnecessary, and prognosis for recovery is good.

Review of the literature demonstrates that pharmacologic treatment of Bell's palsy is a subject of considerable debate. However, guidelines support the use of combined systemic steroid (prednisone 1 mg/kg per day + taper) and antiviral therapy (valacyclovir 500 mg tid × 10 days) in patients presenting within 3 days of onset of paralysis,[9] and common practice supports initiation of therapy in patients presenting within 7 days.

2. Chronic otitis media
Paralysis of the facial nerve due to COM is a known complication of advanced disease, generally related to the effects of chronic suppuration and cholesteatoma. Authors have proposed various mechanisms, including chronic osteitis, bone erosion, nerve edema and inflammation, neural compression, and ischemia. Disruption of the nerve is most common in its horizontal course. Onset of facial palsy in COM may be abrupt or gradual. A palsy of abrupt onset is commonly due to acute infection superimposed on the presence of cholesteatoma. Such an occurrence should serve as a reminder that not all paralysis of acute onset is due to Bell's palsy. There is little controversy regarding treatment for facial paralysis associated with COM. Careful management with early surgical intervention has proven its efficacy in supporting neural recovery, and antibiotics and steroids are considered important adjunctive measures. The timing of surgery in relation to the onset of facial palsy is paramount. Patients should be taken to the operating room without delay, regardless of the extent of paralysis or the duration of time since onset. The goals of surgery are to eradicate all cholesteatoma and infection and to explore the facial nerve, which may require facial decompression. No consensus has been reached regarding the necessary extent of decompression at the time of surgery. Regardless of the specifics of surgical methodology, complete eradication of disease in a single procedure should be the operative goal for patients with facial paralysis due to COM.

3. Iatrogenic facial nerve injury
Factors which predispose a patient to iatrogenic injury can challenge even the most accomplished of surgeons, include variable landmarks and distorted tissue planes in revision surgery, inflammatory disease altering the course of the nerve, congenital structural anomalies, and errors in microsurgical

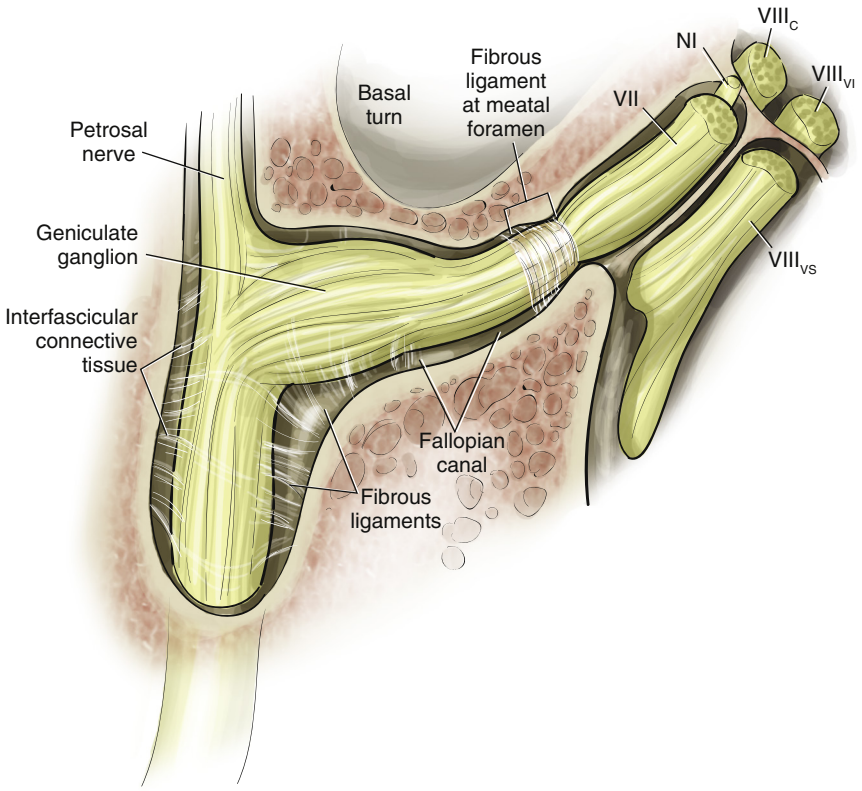

Fig. 138.4. Surgical anatomy of the lateral internal auditory canal, meatal foramen, and first genu of the facial nerve. Left ear, superior view.

technique. Second to hearing loss, facial paralysis is the most common reason for malpractice lawsuits in otologic surgery today.[10] If upon the patient's waking the surgeon is confronted with an immediate, complete paralysis, several issues deserve consideration. Use of a local anesthetic is a known source of temporary paralysis. If the surgeon identified the nerve and is confident of its integrity, patience should be all that is necessary for return of facial function. Similarly, use of packing material may inflict undue stress and compression of the facial nerve. Consideration of more invasive management options begins when palsy persists despite removal of packing, and the waning effects of local anesthesia have passed. If the status of the facial nerve is unknown or if it was aggressively instrumented, one should proceed with exploration. However, if the surgeon is confident the nerve is intact despite gentle manipulation, observation may be appropriate.

As previously discussed, EMG may serve as a diagnostic adjunct in the acute setting for aiding in the decision to explore or observe. Demonstration of VMUAP indicates that the nerve is intact, eliminating the immediate need for exploration. Loss of VMUAP in this setting is less helpful, as this may indicate injury as mild as neuropraxia or as advanced as transection. If palsy is complete and early exploration is deferred, serial electrodiagnostic testing with EEMG is indicated after 48 to 72 hours have passed. Reduction in the EEMG response to less than 10% of the normal side within 5 days of injury is indicative of severe injury and potentially transection. EMG should then be utilized to survey for VMUAP's. If no volitional activity is noted on EMG, the patient should be taken for re-exploration. The quality of the outcome declines dramatically when surgery is delayed beyond 30 days post injury, and when repair is delayed past 1 year, results are uniformly poor. Patients with delayed onset facial palsy, even when it progresses to a complete palsy, generally achieve satisfactory recovery.

Facial paralysis associated with noniatrogenic trauma may merit decompression, which is discussed in Chapter 145.

Contraindications

1. Herpes zoster oticus/Ramsay Hunt
   The symptomatic combination of otalgia and a herpetic, vesicular eruption of the ear and face is known as herpes zoster oticus. The addition of facial paralysis is referred to as Ramsay Hunt syndrome. Symptoms result from reactivation of varicella zoster virus, previously quiescent in the geniculate ganglion. The frequency of complete paralysis is significantly higher, and the likelihood of satisfactory recovery is substantially reduced. Symptoms are generally more severe, and the patient may demonstrate involvement of multiple cranial nerves. Accompanying auditory and vestibular symptoms confer an even worse prognosis. Radiographic workup is of limited utility, and in contrast to Bell's palsy, electrodiagnostic testing has proven unreliable. Early administration of combined systemic steroid and antiviral therapy is paramount, and the role of surgical decompression is limited.
2. Facial paralysis associated with acute otitis media
   The advent of antibiotics has dramatically reduced rates of peripheral facial palsy complicating AOM. Facial paralysis in this setting is a phenomenon observed nearly exclusively in children. The care of these patients should be considered urgent, and include myringotomy and aggressive use of topical and systemic antimicrobials. Tympanostomy tube placement permits ongoing egress of inflammatory fluid as well as established access to the middle ear for administration of topical medication. Mastoidectomy is indicated in the case of associated coalescing mastoiditis or intracranial extension, but facial nerve decompression cannot be recommended for facial paralysis due to AOM.
3. Facial paralysis in the only hearing ear
4. Unfit for general anesthesia due to overall health status.

Preoperative Preparation

1. Review the history and assumed source of facial paralysis.
2. Review the audiogram to assess the hearing status of the ipsilateral and contralateral ears.
3. Review imaging, if obtained.
4. In cases where electric diagnostic testing was performed review the EEMG and EMG.

OPERATIVE PERIOD, MIDDLE FOSSA DECOMPRESSION

Anesthesia

General

Positioning

The patient is placed supine with head turned and the operative ear facing upward. For a middle fossa approach, the surgeon is positioned at the head of the bed. If the surgeon elects to use an image guidance system, a Mayfield clamp should be used to secure the head.

Preoperative Antibiotic Prophylaxis

1. First-generation cephalosporin
   a. Additional medications
      1) Dexamethasone
      2) Mannitol (0.5 mg/kg) administered at the time of skin incision for brain relaxation, easing temporal lobe retraction
      3) Hyperventilation to CO_2 partial pressure of 25 mm Hg

Monitoring

Somatosensory evoked potentials as well as the seventh and eighth nerves are monitored intraoperatively. Request should be made of anesthesia to avoid muscle relaxants beyond what is necessary for induction

Instruments and Equipment to Have Available

1. Operative microscope
2. Otologic drill
3. Assortment of otologic burrs
4. Surgeon's preferred, fine otologic instrumentation
5. Craniotomy set
6. Middle fossa retractor
7. Facial nerve monitor and stimulator

Key Anatomic Landmarks

1. Arcuate eminence/superior semicircular canal (SSCC)
   The arcuate eminence is commonly the first landmark identified on the floor of the middle fossa to assist the surgeon in locating the facial nerve. The labyrinthine segment courses just anterior to the ampullated end of the superior semicircular canal.
2. Greater superficial petrosal nerve
   The greater superficial petrosal nerve (GSPN) courses anteriorly across the floor of the middle cranial fossa. It location can be confirmed by retrograde stimulation of the facial nerve by passing current with the facial nerve stimulator. The angle between the GSPN and the superior semicircular canal is approximately 120 degrees, bisected by the IAC.

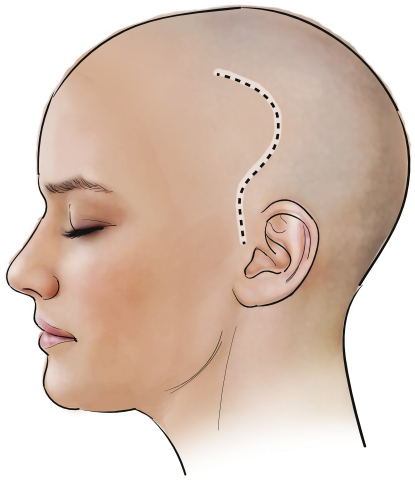

Fig. 138.5. The incision for middle fossa exposure of the facial nerve begins slightly anterior to the tragus and extends superiorly approximately 10 to 12 cm.

3. Middle ear
   Structures of the middle ear, including the head of the malleus and body of the incus, are additional landmarks by which the facial nerve can be identified. Identification of the tympanic segment of the facial nerve proximal to the second genu facilitates retrograde dissection of the geniculate ganglion and identification of the labyrinthine segment.

Prerequisite Skills

1. Knowledge of the anatomy of the middle fossa
2. Fine microscopic surgical techniques
3. Knowledge and experience with intracranial surgery

Operative Risks

1. Sensorineural hearing loss
2. Cerebrospinal fluid (CSF) leak
3. Dizziness
4. Persisting facial weakness
5. Temporal lobe injury
6. Epidural hematoma
7. Cerebrovascular accident

Middle Fossa Surgical Technique

1. Skin incision/soft tissue dissection
   The skin incision is placed in the pretragal area, extending superiorly past the helical root before gently curving posteriorly and then anteriorly (Fig. 138.5). An anteriorly based U-shaped muscle flap is designed such that innervation and blood supply are preserved. Skin and muscle flaps are covered with hydrating sponges and mobilized out of the field with a self-retaining retractor.
2. Craniotomy
   Otologic burrs or a craniotome is used to create a craniotomy measuring 5 cm from anterior to posterior and 4 cm from superior to inferior (Fig. 138.6). Given the anterior angulation of the petrous pyramid, it should be designed such that ⅔ of the craniotomy opening is anterior to the external auditory canal. The root of the zygomatic serves as a reliable landmark for the floor of the middle fossa, and flush positioning of the craniotomy in this regard minimizes the extent of temporal lobe retraction. Special

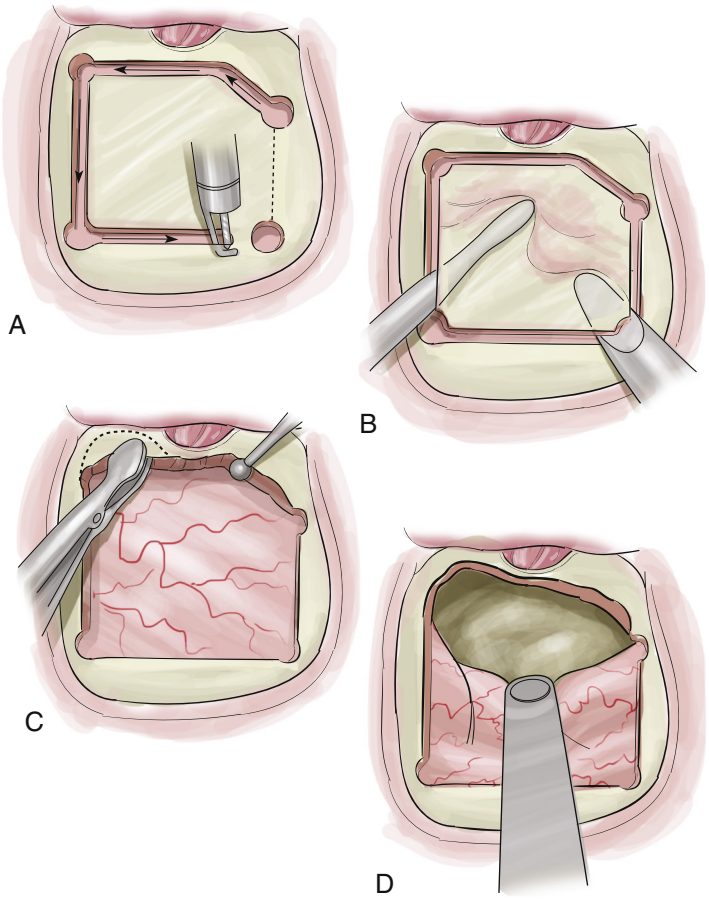

Fig. 138.6. Anatomic drawings courtesy of Jackler's Atlas of Skull Base Surgery. **A,** Use of craniotome or otologic burrs to create the craniotomy opening. **B,** Separation of the bony flap from underlying dura. **C,** Lowering of the inferior margin of the craniotomy to the middle flossa floor to optimize exposure and reduce temporal lobe retraction. **D,** Posterior to anterior dural elevation.

care should be taken when designing the craniotomy so that the vertical incisions are parallel, providing a precise fit for the middle fossa retractor. Too wide a craniotomy may exceed the reach of the retractor, precluding its use and severely compromising exposure. Dura is carefully elevated away from the bone flap, which is removed and placed on the back table for later use. Branches of the middle meningeal artery may be positioned on the surface of the dura or medial side of the bone flap, and bleeding can be controlled with judicious use of an irrigating bipolar cautery. A sized Kerrison or surgical drill is used to lower the inferior margin of the craniotomy if necessary.

3. Elevation of the dura
   The dura is elevated in a posterior to anterior direction. This technique protects against elevation of the GSPN and subsequent violation of a potentially dehiscent geniculate ganglion. Identification of the middle meningeal artery marks the anterior extent of the dissection. This area commonly bleeds from the pterygoid plexus and is controlled with oxidized cellulose or Surgifoam. Care is taken to identify the superior petrosal sinus along the petrous ridge, such that retractor placement is atraumatic.
4. Identification of the arcuate eminence
   Evaluation of the floor of the middle fossa is commonly unyielding of clear anatomic landmarks. However, the perpendicular trajectory of the superior semicircular canal to the petrous ridge is a reliable anatomic relationship. The arcuate eminence marks the position of the superior semicircular canal, which discloses the position of the IAC. However, the arcuate eminence commonly is not readily identifiable, and an elevation of bone may not represent the true location of the underlying superior canal. This situation requires methodical removal of bone with a larger diamond burr and copious irrigation, layer by layer, in the anticipated region of the superior canal. Appreciation of the dense, yellow bone that is characteristic of the otic capsule further directs drilling to uncover the blue-lined SCC. The position of the IAC can be estimated 60 degrees anterior to the position of the superior canal (Fig. 138.7A).
5. Facial nerve identification and decompression
   The facial nerve can be identified by one of several methods. Drilling medially near the porous allows for safe blue-lining of the IAC (Fig. 138.7A). This area is free of the anatomic hazards common to the ampullated end, where the cochlea and labyrinth are positioned. Once the position of the IAC is confirmed, bone is removed laterally to identify Bill's bar. The labyrinthine segment is identified anterior to Bill's bar. Alternatively, the labyrinthine segment can be identified by opening the tegmen tympani, identifying the facial nerve at the first genu, and following it to the geniculate ganglion (Fig. 138.7B). Once identified, attention is directed at relieving the constriction imposed by the meatal foramen (Fig. 138.7B). The nerve is decompressed using a 1-mm diamond burr. Copious irrigation should be used to avoid transfer of thermal energy, which may further injure the nerve. Special care should be taken while thinning bone over the labyrinthine segment in identifying a potential blue line anterior or posterior to the nerve, as the cochlea and superior semicircular canal are positioned in these locations respectively. Fine picks are used to remove the final layer of bone overlying the labyrinthine segment and geniculate ganglion. Removal of the bone and sharp opening of the periosteal sheath in this location is done in an effort to relieve the constriction imposed by the meatal foramen.

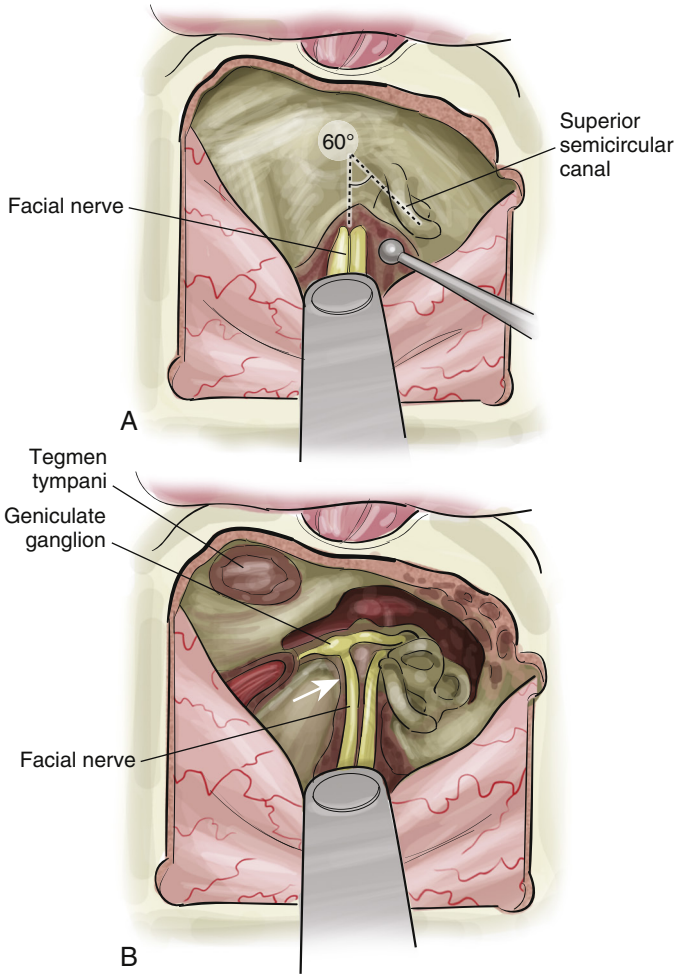

Fig. 138.7. Anatomic illustrations courtesy of Jackler's Atlas of Skull Base Surgery. **A,** Identification of the facial nerve at the porus acousticus of the internal auditory canal (IAC), estimated at 60 degrees anterior to the position of the superior semicircular canal. **B,** Alternative method of identifying the facial nerve by opening tegmen tympani, identifying the horizontal segment, and dissecting it retrograde to the geniculate ganglion and labyrinthine segment. Arrow marks the position of the meatal foramen as the nerve exits the fundus of the IAC.

6. Closure
   After completing the decompression, opened air cells of the petrous apex are waxed, a graft of temporalis muscle is placed over the IAC, and temporalis fascia is positioned over the middle fossa floor. The retractor is removed, the temporalis flap is closed, and the temporal bone flap is replaced and secured. A multilayer, watertight skin closure is performed with deep absorbable suture and nylon superficially in the skin.

Common Errors in Technique

1. Malposition or inadequate size of the craniotomy approach
2. Failure to lower the inferior aspect of the craniotomy to the floor of the middle fossa
3. Injury to the GSPN and geniculate ganglion if they are uncovered and exposed
4. Violation of the cochlea or superior semicircular canal
5. Unrecognized injury to the integrity of the dura
6. Development of a hematoma if adequate hemostasis is not obtained

POSTOPERATIVE PERIOD

Decompression by the middle fossa approach requires observation of the patient in the ICU overnight. Narcotic analgesics are initially used judiciously, given their propensity to mask intracranial complications. The following day the patient is transferred to the floor, where he or she is encouraged to ambulate and resume a normal diet. The drain is removed when collection is less than 20 cc. Discharge routinely occurs 3 to 6 days following surgery.

Complications

1. Hearing loss
   Inadvertent fenestration of the cochlea or labyrinth may result in sensorineural hearing loss and vertigo. Should fenestration occur, the site should be immediately occluded with bone wax. Contact of the drill with the ossicular chain may also generate sensory neural hearing loss.
2. Cerebrospinal fluid leak
   Trauma to middle fossa dura may result in a CSF leak. It is important to use the proper sized burr, watch all edges of the burr while drilling, and use diamond burrs when in tight areas or around exposed dura. If the dura is violated, repair with fascia, muscle, or homograft dura/pericardium is necessary.
3. Temporal lobe edema/contusion
   Temporal lobe injury may occur during the craniotomy or due to temporal lobe retraction. If injury to the temporal lobe is suspected, a CT scan of the head should be performed, and a neurosurgeon should be consulted.
4. Epidural hematoma
   While uncommon, epidural hematoma can occur following middle fossa craniotomy. Treatment involves urgent craniotomy for evacuation of the hematoma.

Alternative Management Plan

1. Transmastoid decompression: Indicated when facial nerve injury is limited to the tympanic and mastoid segments of the facial nerve
2. Translabyrinthine decompression: Affords access to the entire course of the facial nerve. This approach should be reserved for cases when hearing preservation is not a priority.

DISCUSSION

Evidence-Based Medicine Question

For patients with Bell's palsy who exhibit electrophysiologic features associated with poor outcomes, does facial nerve decompression result in improved outcomes compared to nonsurgical treatment?

1. Gantz et al.[7] reported a prospective study in which results of surgical decompression were compared to nonsurgical controls treated with steroids. Surgical decompression was offered to patients exhibiting 90% degeneration on ENoG (EEMG) and a lack of voluntary motor unit action potential on EMG within 14 days of onset. Nineteen patients underwent surgical decompression compared to 11 nonsurgical controls. Of those undergoing decompression, 18 (95%) had a good outcome (defined as return to HB 1 or 2), half of which recovered to normal function. One patient (5%) recovered to a HB 3 and none to a HB 4 or 5. Among nonsurgical controls, 66% demonstrated a poor outcome. Among the 33% with a good outcome, none recovered to normal function. Among patients decompressed after 14 days of onset, results were similar to nonsurgical controls.
2. Patients exhibiting 90% degeneration on ENoG and a lack of voluntary motor unit action potential on EMG within 14 days of onset can expect to have at least a 50% chance of poor recovery of facial nerve function.[7]

Editorial Comment

There is evidence supporting timely surgical intervention for specific indications in facial paralysis can improve outcomes compared to medical therapy alone. There are challenges that must be met by the surgeon and his/her team who offer management of acute facial paralysis. They can be considered to be independent. The first is knowing the appropriate electrical tests that can provide pertinent information as to the inferred status of the facial nerve. One must know the indications for each test, when they should be obtained, and interpretation of the results. This information allows the physician to decide whether surgical exploration or decompression is a reasonable option. The next challenge is having the ability to surgically intervene. In particular, decompression of the labyrinthine segment of the facial nerve via a middle fossa approach requires knowledge and experience beyond that necessary for routine otologic procedures.

Hearing is unaffected in Bell's palsy yet the cochlea and superior semicircular canal are in immediate danger should the dissection stray from the exact location of the nerve.

Transmastoid surgery of the facial nerve is also indicated in patients with acute paralysis secondary to COM with cholesteatoma. CT imaging often identifies the site of pathology and the route in which intervention should be directed. Electrical testing is not necessary given the immediate urgency needed for intervention.

Traumatic injury to the facial nerve also requires electrical testing to help determine the status of the integrity of the nerve. This is addressed in Chapter 145, Temporal Bone Trauma.

Barry Hirsch

Access the review questions online at http://www.expertconsult.com

REFERENCES

1. Van Buskirk C. The seventh nerve complex. J Comp Neurol 1945;82:303–333.
2. Sunderland S. Nerve and Nerve Injuries. 2nd ed. London: Churchill Livingstone; 1978. p. 88–89, 96–97, 133.
3. May M, Schaitkin BM, Wiet RJ, et al. Trauma to the facial nerve: external, surgical, and iatrogenic. In: May M, Schaitkin BM, editors. The Facial Nerve. New York: Thieme; 2000. p. 367–382.
4. Schaitkin BM, May M, Klein SR. Topognostic, otovestibular, and electrical testing: diagnosis and prognosis. In: May M, Schaitkin BM, editors. The Facial Nerve. New York: Thieme; 2000. p. 213–230.
5. Peitersen E. The natural history of Bell's palsy. Am J Otol 1982;4:107–111.
6. Gantz BJ, Gmur A, Fisch U. Intraoperative evoked elecromyography in Bell's palsy. Am J Otolaryngol 1982;3:273–278.
7. Gantz BJ, Rubinstein JT, Gidley P, et al. Surgical management of Bell's palsy. Laryngoscope 1999;109(8):1177–1188.
8. Fisch U, Esslen E. Total intratemporal exposure of the facial neve: pathologic findings in Bell's palsy. ArchOtolaryngol 1972;95:335–341.
9. Baugh RF, Basura GJ, Ishii LE, et al. Clinical practice guideline: Bell's palsy. Otolaryngol Head and Neck Surg 2013;149 (Suppl. 3):S1–27.
10. Blake DM, Svider PF, Carniol ET, et al. Malpractice in otology. Otolaryngol Head Neck Surg 2013;149:554–561.

REVIEW QUESTIONS

1. Which of the following is true regarding facial electromyography (EMG)?
   a. Facial EMG is effective in identifying muscle denervation in the acute period by demonstration of fibrillation potentials.
   b. The lack of volitional motor unit action potentials in the immediate postoperative setting indicates neuropraxia of the facial nerve.
   c. The presence of volitional motor unit action potentials in the immediate postoperative setting indicates neuropraxia of the facial nerve.
   d. Facial EMG has no application in the immediate postoperative period but is more effectively implemented to identify denervation after Wallerian degeneration occurs.

2. For which of the following etiologies of facial paralysis is decompression generally not indicated?
   a. Chronic otitis media (COM) with cholesteatoma
   b. Bell's palsy
   c. Latrogenic injury
   d. Acute otitis media
   e. Ramsay Hunt
   f. a and c
   g. d and e

3. Which of the below statements is not true of the meatal foramen?
   a. The meatal foramen represents the site of entry of the facial nerve into the fallopian canal.
   b. The meatal foramen is formed by a confluence of bony partitions and dense periotic bone at the fundus of the internal auditory canal (IAC).
   c. The facial nerve is devoid of epineurium at the meatal foramen, instead ensheathed by dense periosteum that seals the entrance into the fallopian canal.
   d. Facial paralysis in context of Bell's palsy requires decompression at the meatal foramen and second genu.

139 Tumors of the Facial Nerve

Howard S. Moskowitz

INTRODUCTION

Disorders of the facial nerve most commonly develop because of a variety of infectious and inflammatory processes. Involvement of the facial nerve can occur anywhere along its course ranging from the posterior fossa, temporal bone, to parotid gland either by primary or secondary involvement of the facial nerve. Tumors of the facial nerve represent a much less common etiology in patients presenting with facial nerve dysfunction. Consideration for neoplastic involvement of the facial nerve should be routinely considered, particularly in circumstances of slow progressive loss of motor function of the facial nerve or recurrent episodes of paresis or paralysis. The most common tumor involving the facial nerve is the schwannoma. Many other neoplastic processes that can involve the facial nerve have been reported including hemangiomas, paragangliomas, and granular cell tumors. Furthermore, many types of cancer have the capability to metastasize to the temporal bone and may involve the facial nerve.

Schwannomas of the facial nerve arise from Schwann cells that are the myelin-producing cells peripheral to the axon. The histologic appearance of Antoni A (dense array of cells), Antoni B (areas of loose stroma), or combined patterns is identified on histologic examination. A schwannoma can arise anywhere along the course of the facial nerve (Fig. 139.1). These tumors can also exhibit multiple discrete intraneural connections between distant portions of the facial nerve.[1] Hemangiomas of the facial nerve typically occur at the geniculate ganglion, generally believed to arise from the extensive capillary plexus that surrounds the facial nerve at this location. The facial nerve can also become involved with a glomus jugulare or tympanicum, and there have been reports of paragangliomas developing primarily from the Fallopian canal and invading the facial nerve.

Patients with tumors of the facial nerve commonly present with a facial nerve paresis or paralysis that fails to improve with medication, therapy, or time. However, up to 50% of patients with a primary schwannoma of the facial nerve do not present with signs or symptoms of facial nerve dysfunction. Other common symptoms at presentation include hearing loss, tinnitus, or vestibular dysfunction. The diagnosis is typically made after radiologic studies are obtained.

A fundamental consideration regarding management concerns the extent of facial nerve weakness and the prospects for recovery, as the risk of facial nerve injury can be high with surgical management of these tumors.[2] In some patients, consideration for stereotactic radiosurgery (SRS) may play a role in the treatment paradigm.

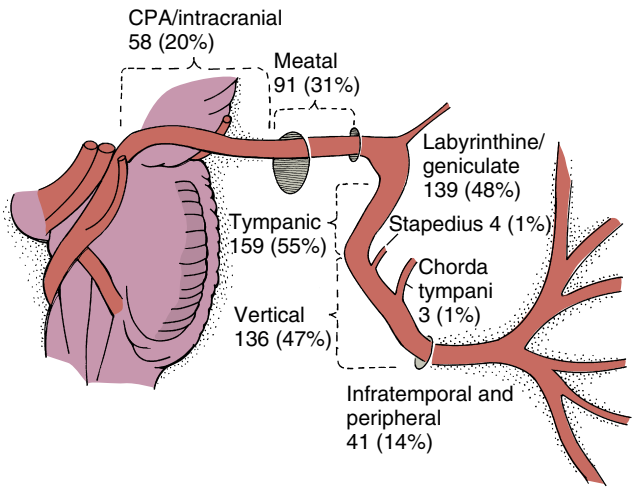

Fig. 139.1. Segmental distribution and frequency of facial schwannomas. These tumors may involve multiple segments of the facial nerve.

KEY OPERATIVE LEARNING POINTS

1. Consideration for facial nerve function should play a key role in the decision as to whether or not to proceed with surgery.
   - The fundamental goal is to preserve facial nerve function for the longest duration possible.
2. Surgical management of tumors that are intimately associated with the nerve will often result in complete facial nerve paralysis.
   - Need to compare current facial nerve function with the best conceivable surgical result with optimal reconstruction
3. It is essential to consider the hearing status in the affected ear and the contralateral ear.
4. Schwannomas of the facial nerve exhibit a tendency to involve portions of the facial nerve beyond the extent of the visible tumor.
   - Intraoperative frozen section should be obtained to ensure clear surgical margins.
   - Prepare to use different surgical approaches if additional exposure is required for tumor resection and repair.
5. SRS may be an effective treatment option for control of tumors of the facial nerve and should be considered in patients with higher surgical risks, good facial function, or only one hearing ear.

PREOPERATIVE PERIOD

History

The history should include comprehensive details regarding facial nerve function. Patients commonly present with a progressive facial nerve weakness. A patient who exhibits slowly progressive facial weakness over several months suggests a tumor. The paralysis may also be "recurrent," although it may never recover completely between episodes. A significant number of patients may have no weakness on initial presentation. The patient may complain of facial twitching or fasciculations and may complain of eye symptoms due to inability to blink or close the eye.

Patients may present with normal hearing or some degree of hearing loss. In some cases, patients may not report significant hearing loss but may only complain of tinnitus. Sensorineural hearing loss may result from tumors that compress the cochlear nerve or invade the otic capsule. Patients may also have conductive hearing loss if the tumor involves the tympanic portion of

the facial nerve and impacts the ossicular chain. Patients may report vestibular dysfunction owing to compression of the vestibular nerve or possible erosion into the labyrinth. Patients do not typically complain of pain, but when present, the pain may be indicative of a malignant tumor.

The past medical and surgical history should be thoroughly reviewed. A determination of the patients' medical status and comorbidities will play a key role in determining which of the potential treatment options would be most suitable for the patient.

Physical Examination

1. Neurologic examination
   a. Facial nerve examination
      1) Assess extent of weakness of gross and fine motor function.
      2) Attention to signs of synkinesis and mass motion
      3) Categorize the extent of facial nerve function using the House-Brackmann scale (Table 139.1).
      4) Keep photographs and video documentation to illustrate any progression of facial weakness over time.
   b. Hearing examination
      1) Weber and Rinne tuning fork testing to ascertain the type of hearing loss
         - Negative Rinne may result when ossicular chain movement is impeded by the tumor.
      2) Formal audiogram
         - Acoustic reflexes—This can give insight into compromise of facial nerve function with ipsilateral and contralateral stimulation.
   c. Full cranial nerve examination
      1) Trigeminal nerve
         - Dysfunction can be evaluated by testing of the corneal reflex.
      2) Lower cranial nerves
         - Close attention to voice, cough, swallow, and vocal cord function

TABLE 139.1 House-Brackmann Facial Nerve Grading System

Grade	Description	Characteristics
I	Normal	Normal facial function in all areas
II	Mild dysfunction	*Gross:* Slight weakness noticeable on close inspection; may have very slight synkinesis *At rest:* Normal symmetry and tone *Motion:* Forehead—moderate to good function; eye—complete closure with minimal effort; mouth—slight asymmetry
III	Moderate dysfunction	*Gross:* Obvious but not disfiguring difference between the two sides; noticeable but not severe synkinesis, contracture, or hemifacial spasm *At rest:* Normal symmetry and tone *Motion:* Forehead—slight to moderate movement; eye—complete closure with effort; mouth—slightly weak with maximal effort
IV	Moderately severe dysfunction	*Gross:* Obvious weakness and/or disfiguring asymmetry *At rest:* Normal symmetry and tone *Motion:* Forehead—none; eye—incomplete closure; mouth—asymmetrical with maximal effort
V	Severe dysfunction	*Gross:* Only barely perceptible motion *At rest:* Asymmetry *Motion:* Forehead—none; eye—incomplete closure; mouth—slight movement
VI	Total paralysis	No movement

   d. Clinical examination of the vestibular system to ascertain underlying balance disorders
      1) Electronystagmography or videonystagmography may be useful in determining the extent of vestibular dysfunction.
      2) Fistula testing in cases in which the integrity of the labyrinth is suspect
2. Otoscopic examination
   a. Essential, but generally normal
   b. If the tumor involves the tympanic segment of the facial nerve, then a retrotympanic mass may be visualized.
   c. May present as a swelling in the external auditory canal if the descending or mastoid segment of the facial nerve is involved
3. Head and neck examination
   a. The parotid gland and neck should be examined to search for evidence of tumor or cervical lymphadenopathy.
4. Ophthalmologic examination
   a. Essential to assess corneal protection
   b. If the patient demonstrates a poor Bell's phenomenon and is unable to adequately protect the cornea, then the patient may need a gold or platinum eyelid weight.
   c. If ectropion is present the patient may need a lower lid-tightening procedure.
5. Electrophysiologic facial nerve tests
   a. May be useful in some cases
   b. Electroneuronography may show a reduction in amplitude that supports the compromise of neural integrity.
   c. Facial electromyography prototypically shows simultaneous denervation (fibrillation potentials) and re-innervation (polyphasic voluntary motor unit potentials).
      - This combination of potentials is more commonly encountered in slowly progressive pathologic processes.

Imaging

1. High-resolution computed tomography (CT) and magnetic resonance imaging (MRI) should be used to demonstrate the presence and extent of a facial nerve tumor.
2. Imaging characteristics of selected tumor types:
   a. Facial nerve schwannomas
      1) MRI
         - Typically enhance with administration of contrast
         - Solitary lesions or may have skip lesions with intervening segments of normal appearing facial nerve ("beads on a string")[3]
      2) CT
         - May exhibit widening of the Fallopian canal
   b. Hemangiomas
      1) Found predominantly at the geniculate ganglion[4]
      2) MRI
         - Heterogeneous hyperintensity on T2-weighted sequences with punctate foci of hypointense signal
      3) CT
         - Irregular borders with remodeling of surrounding bone or evidence of intratumor bony spicules
   c. Paragangliomas
      1) MRI
         - Salt and pepper appearance on T1-weighted sequences with contrast as well as hyperintensity on T2-weighted sequences

Indications

Treatment is typically reserved for patients who exhibit evidence of progressive tumor size and/or neurologic sequelae. Some tumors may appear stable from a radiologic perspective, but they can result in worsening facial function, hearing loss,

vestibular dysfunction, or other neurologic changes. Before undertaking surgery, it is essential to consider the site and the extent of the lesion and the hearing status of both ears. It is generally difficult to recommend treatment if the patient exhibits normal facial movement or only subtle weakness. However, patients may require active management in cases of hearing loss, unrelenting pain, pulsatile tinnitus, or atypical vestibular complaints.

1. Facial nerve weakness
   a. Surgery is typically not undertaken until facial nerve function has worsened to greater than House-Brackmann grade 3.
      - If resection of the facial nerve tumor results in loss of facial nerve continuity, the best facial nerve result attainable with reconstruction is a House-Brackmann grade 3.
   b. Residual facial nerve function
      - Patients with long-standing facial nerve paralysis may have worse results after facial nerve repair.
2. Hearing status
   a. Good contralateral hearing
      - Full complement of surgical options is available
   b. Poor contralateral hearing
      1) In patients with normal hearing, attempted removal of tumor should generally be avoided if injury to the ipsilateral cochlear nerve or otic capsule is likely.
      2) Tumor decompression should be considered unless the size or location of the tumor presents no other options.

Contraindications

1. Surgery should not be performed in patients with severe underlying medical conditions that preclude their ability to undergo a surgical procedure. SRS may be an option for these patients.
2. Patients with small tumors or with little or no neurologic sequelae should be strongly considered for watchful waiting with serial clinical and radiologic examinations.
3. Surgical intervention should be avoided in patients with facial nerve tumors in an only hearing ear.

Preoperative Preparation

1. Medical clearance should be obtained prior to surgery. Standard avoidance of medications or supplements that may promote bleeding and inhibit coagulation should be stressed to the patient.
2. Coordination with electrophysiology monitoring services should be arranged in advance of the procedure date.
3. Review the diagnostic imaging studies and audiometric findings of both ears.
4. If facial nerve repair is to be performed by another service, reconfirm their planned participation.

OPERATIVE PERIOD

Anesthesia

1. All standard surgical techniques require general anesthesia.
2. Careful coordination and discussion with the anesthesia service regarding the extent of usage of paralytic medications.

Positioning

1. Most surgical procedures for treatment of tumors of the facial nerve can be performed with supine positioning with the head turned to the contralateral side.
2. Patient position should be made to permit access to the abdomen if abdominal adipose tissue is needed for reconstruction as well to the neck (greater auricular nerve) or leg (sural nerve) if a nerve graft is required to repair the facial nerve.

Perioperative Antibiotic Prophylaxis

1. A first-generation cephalosporin is generally sufficient for cases of exclusive transmastoid surgery.
   - In cases of documented allergy to penicillins, clindamycin can be used.
2. For more extensive surgical cases where the antibiotic is desired to penetrate the central nervous system, ceftriaxone may be a better option.
   - In cases of documented allergy vancomycin can be used.
3. A dose of antibiotics is given prior to the incision and then maintained for a total of 24 hours.

Monitoring

1. Routine anesthesia monitoring
2. Electrophysiologic monitoring
   a. Facial nerve function should be monitored with real-time monitoring with the opportunity for direct stimulation of the facial nerve.
   b. Auditory brainstem responses, direct cochlear nerve recordings, somatosensory evoked potentials, and other testing modalities may serve a role in the surgical management based on surgeon preference.

Instruments and Equipment to Have Available

1. Standard mastoidectomy and middle ear dissection set
2. Soft tissue set for harvesting abdominal adipose tissue or nerve graft
3. Microsurgical set for facial nerve grafting
4. Facial nerve stimulating probe compatible with facial nerve monitoring system
5. Middle fossa retractor
6. Retractor system for sigmoid sinus and posterior fossa dura
7. Operating microscope

Key Anatomic Landmarks

Course of intratemporal facial nerve

1. After leaving the brainstem, the facial nerve enters the internal auditory canal (IAC). The course of the facial nerve is divided into several segments:
   a. Meatal segment—within the IAC
   b. Labyrinthine segment—fundus of IAC to facial hiatus and geniculate ganglion
   c. Tympanic segment—geniculate ganglion to pyramidal eminence (second genu)
   d. Mastoid segment—pyramidal eminence to stylomastoid foramen
2. There are several key anatomic associations:
   a. Within the IAC, the facial nerve courses anteriorly and superiorly as it approaches the geniculate ganglion and middle ear.
      1) The facial nerve passes superior to the falciform (transverse) crest in the lateral aspect of the canal.
      2) The facial nerve passes anterior to the vertical crest of bone known as Bill's bar.
   b. As the facial nerve courses posteriorly through the middle ear, it is usually well covered in the bone of the

fallopian canal and courses superior to the cochleariform process and the oval window.
c. The facial nerve gives off the chorda tympani nerve branch as it descends through the mastoid segment.

Prerequisite Skills

1. Extensive expertise with all approaches for lateral skull base surgery and middle ear surgery including reconstruction of the ossicular chain.
2. Must be prepared for the possibility that tumor has infiltrated the facial nerve and will require resection with re-anastomosis or nerve grafting

Operative Risks

1. Facial nerve paralysis
2. Hearing loss
3. Vestibular dysfunction
4. Vascular injury
5. Intracranial complications

Surgical Technique

There are a variety of surgical options for the management of tumors of the facial nerve including decompression, debulking, and resection with possible primary re-anastomosis or interposition graft if the integrity of the facial nerve is lost. Radiographic size, location, degree of hearing loss, and involvement of adjacent structures will dictate the most advantageous surgical approach. The surgeon should individualize these criteria to the needs of the patient.

1. Decompression
   a. Involves removal of the bone overlying the Fallopian canal, which allows room for more tumor growth
      - May reduce potential effects of nerve compression and should permit axonal flow for neuronal transmission
   b. Tumor will likely continue to grow, but decompression may provide a longer period before a final decision must be made regarding potential facial nerve sacrifice
2. Debulking
   a. More controversial approach that has been used for management of facial nerve schwannomas
   b. Several reports from different centers have used this approach to manage tumors while preserving facial function.
   c. Given that there can be histologic evidence of normal nerve fibers running through the tumor, there is often concern for potential complete damage to facial nerve function.
3. Resection with possible primary re-anastomosis or interposition graft if the integrity of the facial nerve is compromised

Techniques

1. Transmastoid approach
   - Tumors confined to the horizontal or vertical fallopian canal
2. Middle fossa approach
   - Tumors of the IAC, labyrinthine segment, and geniculate ganglion region if hearing preservation is attempted
   - Patients older than 65 do not typically tolerate this approach due to fragility of the dura and effects of temporal lobe retraction.
3. Middle fossa and transmastoid approaches can be combined.
   - Larger tumors centered at the geniculate ganglion
   - There is a need for access to proximal and distal nerve stumps for repair in cases where hearing is attempted to be preserved.
4. Translabyrinthine approach
   - If hearing is worse than the 50/50 rule (pure tone average greater than 50 dB and speech discrimination less than 50%), hearing conservation surgery should not be attempted.
   - Permits direct access to the tumor and facilitates repair
5. Retrosigmoid approach
   - Uncommon approach for facial nerve tumors (not covered in this chapter)

Transmastoid Approach

1. Standard postauricular approach 1 cm posterior to postauricular sulcus through skin, subcutaneous tissue, and fibroperiosteal layer over mastoid cortex
2. Wide cortical mastoidectomy with identification of horizontal semicircular canal, delineation of sinodural angle, and appropriate thinning of the bone of the posterior ear canal
3. Identify the short process of the incus, and, depending on tumor location, open the facial recess widely.
4. Progressively thin the bone overlying the facial nerve until translucent.
5. The incus will need to be removed for access to the tympanic segment (Fig. 139.2).
6. Removal of the head of the malleus will permit exposure of the proximal tympanic segment.
7. May need to sacrifice the chorda tympani nerve with extension of facial recess inferiorly if tumor extends toward the distal aspect of the vertical segment
8. If the tumor cannot be separated from the nerve, sharply transect the nerve, remove the tumor, and evaluate the margins with frozen sections.
9. Repair the nerve with an interposition graft from the greater auricular nerve.
   - Position without tension between remaining segments of the facial nerve.
   - May use fascia or fibrin glue to minimize mobility
10. Ossicular reconstruction if ossicular chain has been disrupted

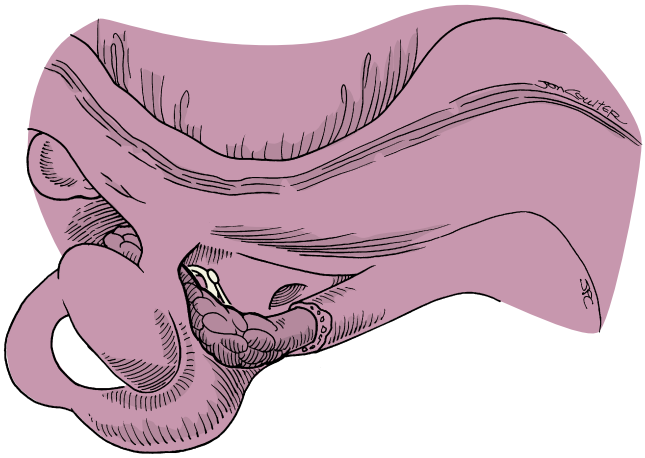

Fig. 139.2. A complete mastoidectomy via a facial recess approach provides exposure of the epitympanum and the vertical segment of the facial nerve. The incus has been removed to reveal the tumor. The head of the malleus is intact.

Middle Fossa Approach

1. Consider the use of intraoperative mannitol, furosemide, and a single dose of corticosteroid.
2. Incision in the pretragal area is extended superiorly with a gentle curve
3. Inferiorly based U-shaped flap of temporalis muscle and fascia is retracted inferiorly
4. A 5 × 5-cm craniotomy should be made 2/3 anterior and 1/3 posterior to the external auditory canal.
   a. Based on root of zygoma as close to floor of middle fossa as possible
   b. Perform with high-speed drill either by outlining entire flap or by exposing four corners (burr holes) and delineate with footplate drill
   c. Bone flap is set aside for later replacement
5. Elevate the dura from the floor of the middle fossa.
   a. Identify the middle meningeal artery (anterior limit).
   b. Elevate posterior to anterior to avoid injury to dehiscent geniculate ganglion.
   c. Identify the greater superficial petrosal nerve and arcuate eminence.
   d. Middle fossa retractor should be placed to support the temporal lobe
6. Identify the superior semicircular canal with a high-speed drill and copious irrigation.
7. Remove bone from the medial aspect of the petrous ridge at the bisection of angle formed by the greater superficial petrosal nerve and superior semicircular canal
   a. IAC is identified in the medial aspect of the meatal plane and traced laterally
   b. Circumference of the porus acusticus is exposed 270 degrees
   c. Dissection proceeds from medial to lateral
   d. Need to narrow exposure laterally to 90 degrees to avoid injury to the cochlea and superior semicircular canal
8. Dura of the IAC is divided along its posterior aspect
9. Tumors that arise eccentrically from the nerve may be excised while maintaining continuity of the nerve, but if the facial nerve integrity is lost, a graft is required (Figs. 139.3 and 139.4).
10. May use a small piece of temporalis fascia or adipose tissue to fill the defect in the IAC
11. Retractor is removed, and the temporal lobe can re-expand
12. Replace the craniotomy flap and secure with miniplates.

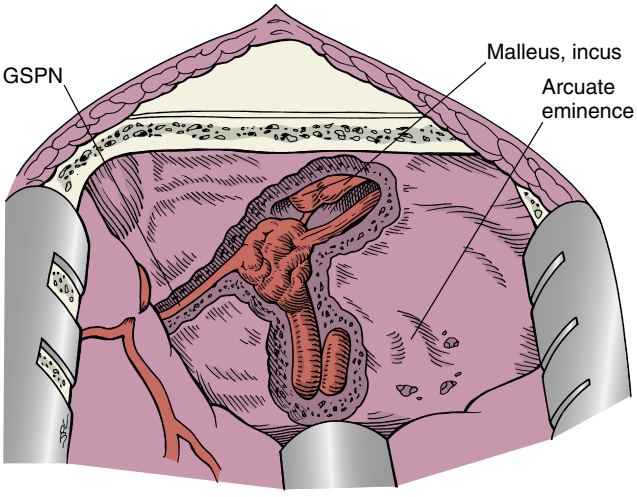

Fig. 139.3. Middle fossa approach to a tumor of the facial nerve located at the geniculate ganglion. The labyrinthine and proximal horizontal segments are exposed. *GSPN*, Greater superficial petrosal nerve.

Combined Middle Fossa and Transmastoid Approach

1. Enables full dissection of the intratemporal course of the facial nerve
2. Particularly useful for lesions at the geniculate ganglion with extension proximally and distally
3. May permit preservation of inner ear function
4. Uses the same postauricular incision
   a. Superior limb extends beyond the root of the helix to the preauricular area, parallel to the hairline toward the temporal area
   b. The incision courses superiorly and curves posteriorly parallel to the superior temporal line (Fig. 139.5).

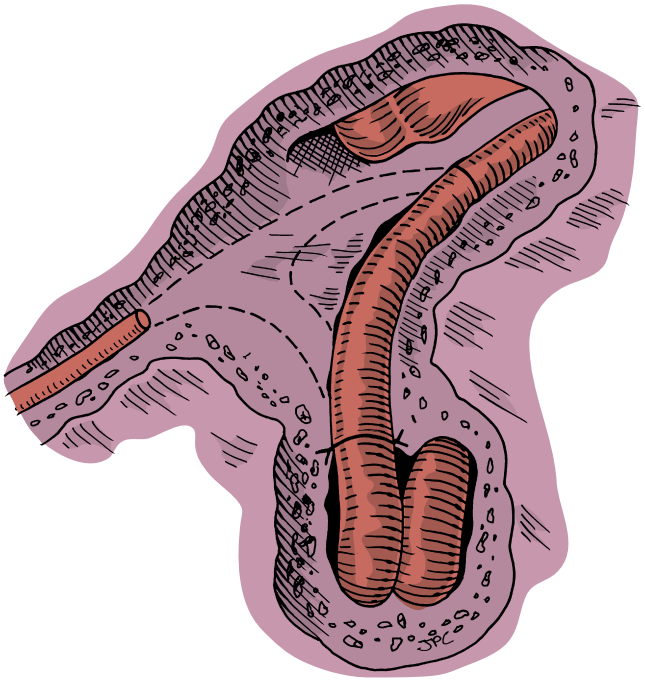

Fig. 139.4. Interposition cable graft repair from the facial nerve in the distal internal auditory canal to the horizontal segment.

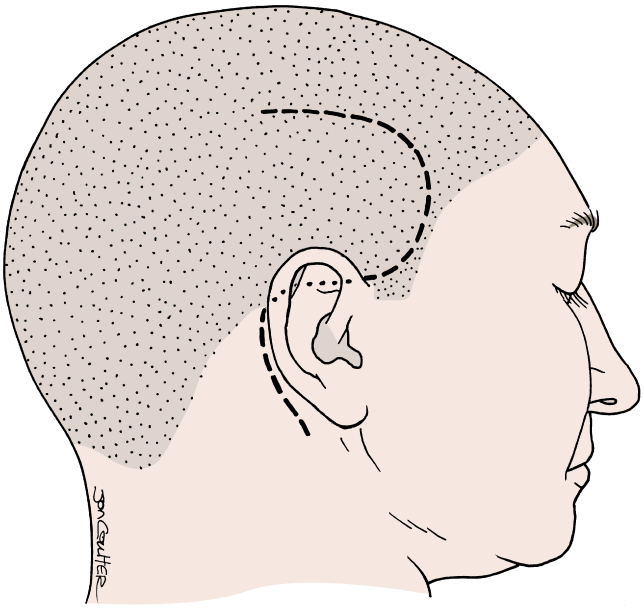

Fig. 139.5. Incision for a combined middle fossa–transmastoid approach.

5. Tegmen tympani is removed to expose the tumor and course of facial nerve that can be repaired with bone taken from the middle fossa craniotomy plate

Translabyrinthine Approach

1. Standard postauricular curvilinear approach 3 to 4 cm posterior to postauricular sulcus
   - The superior and inferior limbs are extended to allow anterior retraction of the pinna.
2. Create the initial skin incision superficial to the temporalis fascia and mastoid periosteum.
   - Stagger the offset medial incision in the deeper layer anterior to the skin incision to assist with the watertight closure.
3. Perform a complete mastoidectomy (Video 139.1).
   - Remove bone 2 cm posterior to the sigmoid sinus to expose the dura of the posterior cranial fossa.
4. Identify the facial nerve in its descending portion and skeletonize it just proximal to the stylomastoid foramen.
5. Remove the tegmen bone over the middle fossa dura adjacent to the sinodural angle and over the posterior fossa dura.
6. Perform a standard labyrinthectomy.
7. The bone posterior to the IAC is removed.
8. Bone remains at an eggshell thickness over the dura of the IAC until all bony dissection is completed.
9. Bone is removed around the IAC superiorly and inferiorly to provide 270 degrees of exposure.
10. Once the facial nerve is identified, the dura of the posterior fossa and midportion of the IAC are opened sharply.
11. The tumor is removed using microsurgical technique (Fig. 139.6) (Video 139.2).
12. Nerve repair depends on length resected
    a. Small—requires primary repair by mobilizing residual nerve segments from the fallopian canal, supporting nerve segments with Gelfoam, and may also re-approximate with one 9-0 or 10-0 nylon suture if possible (Fig. 139.7)
    b. Large—requires interposition nerve graft (Fig. 139.8) (Videos 139.3 and 139.4)
13. Harvest abdominal adipose tissue.
    a. Use separate instruments and change gloves.
    b. Adipose tissue should soak in bacitracin solution and the wound copiously irrigated with bacitracin solution.
14. Fill the cavity with adipose tissue and provide support to the nerve anastomosis.

Greater Auricular Nerve Graft

1. Supplies sensation to the pinna and preauricular area
   - Sacrifice of nerve generally leaves only a small area of anesthesia

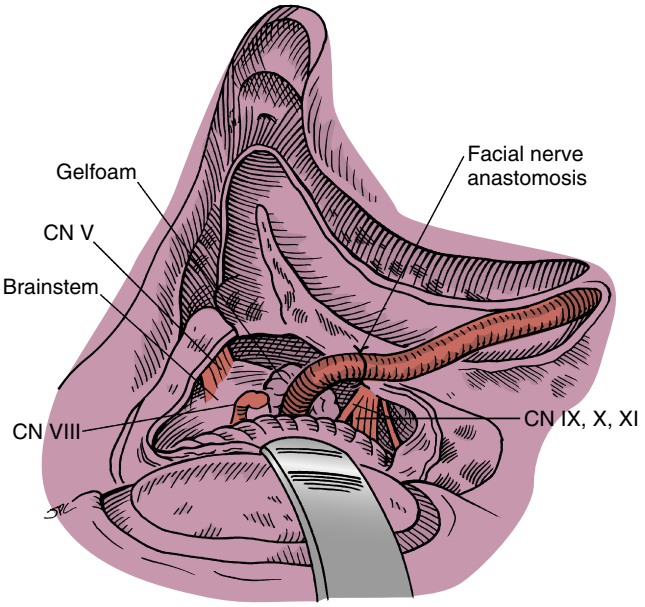

Fig. 139.7. Horizontal and vertical segments of the facial nerve mobilized to permit primary repair of the facial nerve (cranial nerve [CN] VII). The brainstem, trigeminal nerve (CN V), cochleovestibular nerves (CN VIII), and lower cranial nerves (CN IX, X, XI) are demonstrated. Gelfoam supports the proximal nerve for suturing.

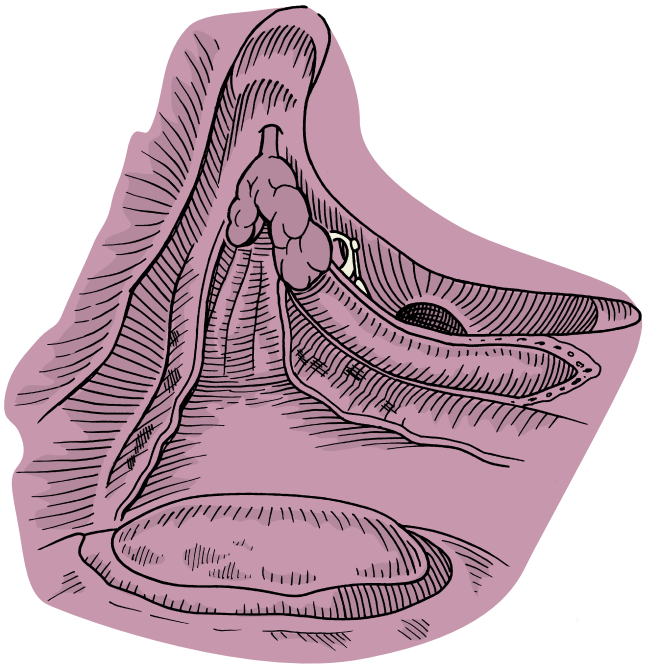

Fig. 139.6. Translabyrinthine approach to a tumor of the facial nerve proximal to the geniculate ganglion. An island of bone remains over the sigmoid sinus. The dura of the internal auditory canal is intact. The tumor extends from the fundus to the second genu.

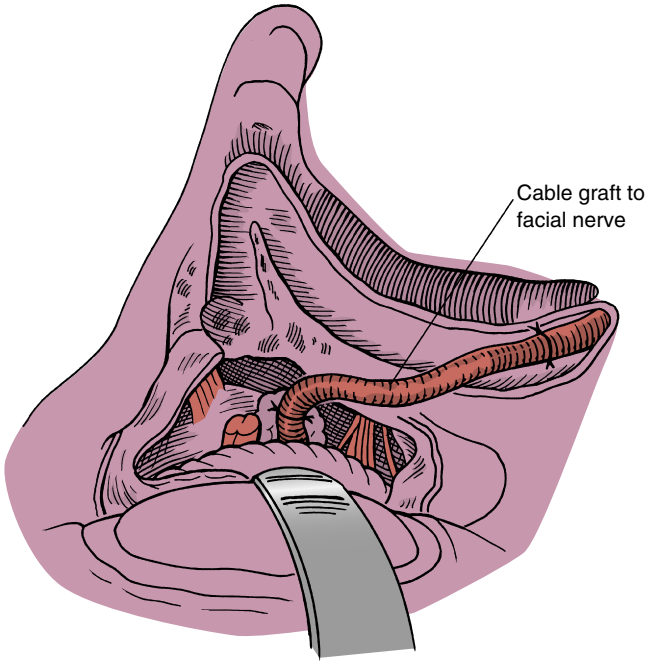

Fig. 139.8. Greater auricular nerve interposition cable graft to the facial nerve from the porus to the distal vertical segment.

2. Anatomy of nerve is relatively constant
3. Two methods to localize (Fig. 139.9)
   a. Divide the sternocleidomastoid (SCM) muscle into thirds and identify at posterior border of SCM between upper and middle thirds.
   b. The nerve is located midway along a line connecting the mastoid tip and the angle of the mandible.
4. Incision in skin crease taken through subcutaneous tissue
   - Retrograde dissection along the nerve by retracting the SCM anteriorly permits more proximal harvesting of the nerve from its origin in the cervical plexus.

Common Errors in Technique

1. Essential to weigh the risks and benefits of complete tumor extirpation versus the potential development of facial nerve paralysis
2. Need to ensure that surgical margins at both ends of the resected tumor are clear of microscopic tumor
   - Frozen sections should be taken to confirm that the margins are clear of tumor since visual inspection is not sufficient for this purpose.

POSTOPERATIVE PERIOD

Postoperative Management

1. The patient should be admitted to the intensive care unit for the first day following more extensive surgical procedures.
2. Patients should be placed on strict eye precautions.
   - Lubricating ointment, artificial tears, moisture chamber

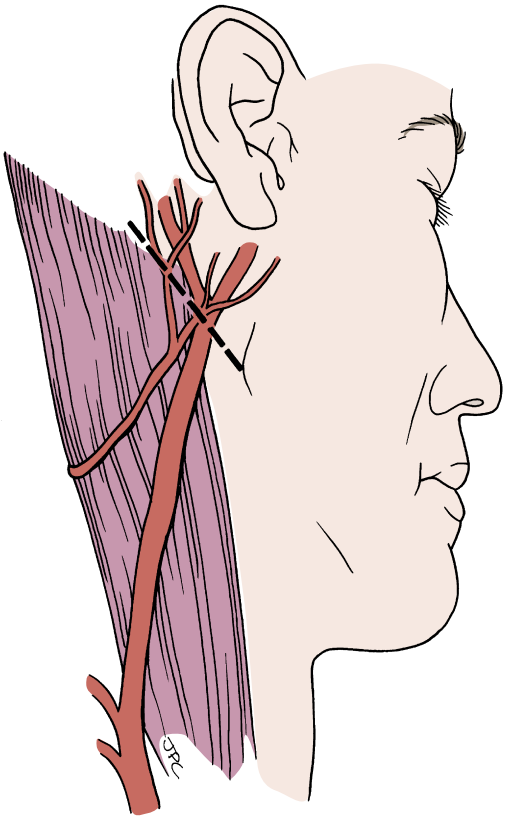

Fig. 139.9. Methods for identifying the greater auricular nerve with pertinent anatomic landmarks. The greater auricular nerve exits posterior to the sternocleidomastoid muscle at the junction of its upper and middle thirds. The greater auricular nerve can also be found midway between the angle of the mandible and the mastoid tip.

3. Neurologic symptoms are closely monitored for the first 24 hours.
4. Compression dressing over the surgical site should remain in place for 3 to 5 days.
5. Consultation for physical therapy should be made, and the use of a walker may be helpful for early rehabilitation should vestibular function be compromised.
6. Sutures or staples should be removed 7 to 10 days after surgery.

Complications

1. Facial nerve paresis or paralysis
   a. Frequently present preoperatively but may worsen postoperatively even if facial nerve integrity is maintained
   b. Critical attention to protect cornea
      - If corneal protection is compromised a gold or platinum weight can be inserted into the upper eyelid.
2. Cerebrospinal fluid leak
   a. Look for clear otorrhea, rhinorrhea, or skin fistula
   b. Patients should avoid straining or sneezing with closed mouth.
   c. If a cerebrospinal fluid (CSF) leak develops, treatment should be started to prevent meningitis.
      1) Consider bed rest with lumbar drain
      2) Re-explore wound with possible obliteration of the Eustachian tube
3. Hearing loss and loss of balance function
   a. Surgery may disrupt cochlear nerve function or violate the cochlea, particularly with surgical procedures that involve the IAC (excludes translabyrinthine procedures).
   b. Essential to be aware that these tumors can erode into the adjacent otic capsule to produce a fistula to the cochlea or the labyrinth
      - Fistulas can be asymptomatic and may not be evident on preoperative imaging.
   c. Patients should undergo a formal postoperative audiogram.
4. Vascular injury
   a. Intraoperative venous bleeding generally responds to local compression.
   b. Injury of the carotid is not usually an issue unless eroded by tumor.
   c. Posterior fossa approaches should include identification and protection of the anterior inferior cerebellar artery.

Alternative Management Plan

Based on aspects of tumor size, location, and associated signs and symptoms, there are other options for facial nerve tumors:

1. Watchful waiting with serial clinical examinations and imaging
2. SRS

If facial nerve function is insufficient after surgery despite apparent maintenance of facial nerve continuity or seemingly appropriate facial nerve repair, other facial nerve re-animation procedures should be utilized to enhance the functional and cosmetic result.

DISCUSSION

Evidence-Based Medicine Question

Can facial nerve tumors be effectively treated with SRS?

There are a variety of techniques of SRS including frame-based linear accelerator, gamma knife, or mobile linear accelerator. Potential advantages of SRS treatment include avoidance of surgery, potential arrest of tumor growth, and

possible preservation of facial nerve function. SRS aims to minimize the risks of long-term complications associated with conventional external beam radiation therapy such as osteonecrosis, skin breakdown, potential development of a malignant tumor, and acute cranial nerve dysfunction. SRS has been most commonly described for treatment of tumors that are presumed to be facial nerve schwannoma. Most reported cases of SRS treatment of facial nerve schwannomas indicate no worsening in facial nerve function after treatment. Recent studies have indicated that these approaches afford excellent tumor control and a low rate of new cranial nerve deficits.[5] However, studies with longer term follow-up are required to provide a true comparison between treatment modalities.

Editorial Comment

The management of facial nerve schwannoma has become more conservative over time, and the ideal treatment algorithm continues to develop. The underlying challenge is trying to predict the natural history and progression of a lesion where a presumptive histopathologic diagnosis is based on the combination of the patient's signs and symptoms and the interpretation of radiologic imaging. The skull base team, consisting of neurotology, neurosurgery, and head and neck surgeons, collaborates in the decision regarding recommended intervention and execution. This undertaking requires the surgical skills needed in optimizing the surgical approach, decompressing or resecting the tumor, and reconstructing with the goal of preserving or restoring facial nerve function while achieving a watertight closure and minimizing postoperative dysfunction. The role of SRS is in evolution for primary management and adjuvant care.

Barry Hirsch

Access the review questions online at http://www.expertconsult.com

REFERENCES

1. Wilkinson EP, Hoa M, Slattery 3rd WH, et al. Evolution in the management of facial nerve schwannoma. Laryngoscope 2011;121(10):2065–2074.
2. McRackan TR, Rivas A, Wanna GB, et al. Facial nerve outcomes in facial nerve schwannomas. Otol Neurotol 2011;33(1):78–82.
3. Mowry S, Hansen M, Gantz B. Surgical management of internal auditory canal and cerebellopontine angle facial nerve schwannoma. Otol Neurotol 2012;33(6):1071–1076.
4. Semaan MT, Slattery WH, Brackmann DE. Geniculate ganglion hemangiomas: clinical results and long-term follow-up. Otol Neurotol 2010;31(4):665–670.
5. McRackan TR, Wilkinson EP, Brackmann DE, et al. Stereotactic radiosurgery for facial nerve schwannomas: meta-analysis and clinical review. Otol Neurotol 2015;36(3):393–398.

REVIEW QUESTIONS

1. Which approach provides access to the full length of the intratemporal facial nerve?
   a. Transcanal
   b. Transmastoid
   c. Middle fossa
   d. Translabyrinthine
   e. Retrosigmoid

2. What is the ideal manner for surgical repair of the facial nerve?
   a. Removal of excess facial nerve to keep anastomosis taut
   b. Approximation of nerve ends without tension
   c. Application of tissue glue
   d. Imbrication of epineurium
   e. Utilization of nerve graft

3. Preoperative CT scan indicates a tumor centered on the geniculate ganglion with evidence of bony remodeling and intratumoral bone spicules. This finding is most consistent with which tumor type?
   a. Schwannoma
   b. Hemangioma
   c. Paraganglioma
   d. Granular cell tumor
   e. Metastatic thyroid carcinoma

4. After surgical re-anastomosis of the facial nerve, what is the ultimate expected functional result of facial nerve function?
   a. I–II
   b. II–III
   c. III–IV
   d. IV–V
   e. V–VI

140 Acoustic Neuroma

Moises A. Arriaga, Joshua M. Sappington

INTRODUCTION

Acoustic neuroma (AN) and vestibular schwannoma (VS) are the most common lesions arising within the posterior cranial fossa. They are well-circumscribed, benign, encapsulated tumors that arise from Schwann cells of the vestibular nerve and usually originate in the internal auditory canal (IAC). Typically the tumors are slow growing (1 to 2 mm per year); some do not grow at all after discovery and others expand to life-threatening dimensions.

The three modern strategies for managing AN are **observation** with serial imaging, **stereotactic radiation (**SR**),** and **surgical removal.** Surgical removal is the only curative strategy and will be the focus of this chapter.

KEY OPERATIVE LEARNING POINTS

1. AN management is based on tumor size, location, the patient's hearing and health status, and patient/surgeon preference.
2. The translabyrinthine (TL) approach allows for a direct route to the cerebellopontine angle (CPA) and for identification of the facial nerve within its vertical segment as well as its course through the IAC.
3. The retrosigmoid (RS) and middle fossa (MF) are the two approaches that allow removal of the tumor and potential preservation of hearing for appropriately selected patients. With both approaches, tumor resection and facial nerve function are of primary importance, with hearing preservation being a secondary though very important objective.

PREOPERATIVE PERIOD

History

1. History of present illness
   a. Gradual hearing loss
   b. Five percent of AN patients present with sudden hearing loss.
   c. Asymmetric hearing loss should be assumed to be an AN until proven otherwise.
   d. Vestibular symptoms are usually motion intolerance rather than acute vertigo.
   e. Facial nerve dysfunction is rarely a presenting symptom in AN.
   f. Patients with a large AN may have cranial nerve dysfunction leading to hypoesthesia (CN V), diplopia (VI), dysphagia (CN IX, X), hoarseness, and aspiration. Such tumors can cause increased intracranial pressure leading to headaches and papilledema.
2. Past medical history
   a. Previous schwannoma or meningioma: Neurofibromatosis-2 (NF-2) is an autosomal dominant but a previous AN on the contralateral side or meningioma or a family history of NF-2 requires thorough evaluation. NF-2 management is different from sporadic AN management, which is the subject of this chapter.
   b. Medical illness
   c. Surgery
   d. Family history
   e. Medications, vitamins, and supplements

Physical Examination

In addition to a complete head and neck examination,

1. Microscopic otoscopy: A tympanic membrane perforation raises the risk of postoperative cerebrospinal fluid (CSF) otorrhea and the possibility of an inflamed mastoid, which would affect the selection of a transtemporal approach.
2. Cranial nerve: A systematic examination of all nerves (especially VII)
3. Nystagmus: Bruns' nystagmus in large tumors with brainstem compression reveals coarse, slow-beating nystagmus on ipsilateral gaze (brainstem induced) and fine beating nystagmus on contralateral gaze (vestibular induced).
4. Vestibular examination: Gait testing, Fukuda stepping test and head thrust tests identify vestibulopathy.

Relevant Testing

1. Audiogram: Air, bone, and speech audiometry objectively document hearing levels. Fifty decibels Speech Response Threshold (SRT) (or Pure Tone Average (PTA)) and 50% speech discrimination are the lower limit in considering hearing preservation surgery.
2. Vestibular: AN patients undergo a complete vestibular testing battery that includes ROTO (rotational chair), VEMP (vestibular evoked myogenic potentials), and VNG (videonystagmography). Documentation of pretreatment vestibular function is a baseline for future comparison and patient education about postoperative symptoms and a guide for perioperative vestibular physical therapy.
3. Facial: A preoperative electroneuronography (ENoG) abnormality identifies preoperative facial nerve compromise.
4. ABR (audiometric brainstem response) is used in large lesions as a baseline for intraoperative contralateral brainstem monitoring during surgery and to assess the preoperative status of the cochlear nerve if hearing preservation surgery is being considered.

Imaging

1. MRI with gadolinium of the IAC is the gold standard for diagnosing AN. The sensitivity approaches 100%; however, false positive results are possible.[1]
2. T2 sequences can identify the nerve of origin of the tumor and whether there is a cap of CSF at the fundus that may facilitate preservation of hearing in an MF or RS approach.
3. CT with contrast is not as sensitive as MRI. Currently MRI with contrast can identify lesions as small as 1 to 2 mm.
4. CT combined with ABR: A recent meta-analysis found that pooled sensitivity for ABR was 82.0% for all tumors, and for tumors greater than 1 cm this rose to 95.6%.[2] For patients that cannot complete MRI, ABR with CT may offer an alternative means of diagnosis.
5. CT without contrast is used for surgical planning in all three surgical approaches. For TL surgery, the mastoid pneumatization, distance between the sigmoid and the IAC, and the height of the jugular bulb relative to the IAC are the important features. For the MF approach, the relationship between the

arcuate eminence and superior canal (SSC) and the pneumatization over the IAC are important. In RS surgery, the pneumatization of the petrous bone, position of the sigmoid sinus, jugular bulb, and vertical height of the IAC are important features.

Indications

1. Treatment strategy: Patients with AN are offered three management options: observation, SR, and microsurgical resection. The surgeon individualizes recommendations in every case.
2. Observation ("watch and scan") is increasingly used as initial tumor management for AN. A central tenant of skull base surgery is to avoid any additional morbidity with treatment, which is greater than what would be expected with the natural course of the disease.[3] The Denmark experience reveals that within the first 5 years, 17% of intrameatal tumors and 28.9% of extrameatal tumors grew, while 45% lost class A hearing after 5 years regardless of tumor growth.[4] The critical issue with observation is that it this strategy requires close follow-up, as we are not currently able to predict which tumors will grow.
3. SR for AN includes stereotactic radiosurgery, which is a one-time treatment, and hypofractionated SR (radiotherapy) in which the treatment is divided into three to five doses. Based on Lars Leksell's innovations, the goal of SR is prevention of tumor growth to preserve neurologic function. The initial high-dose treatment plans (16 Gy marginal) have been replaced with lower dose 12 Gy single dose or 18 Gy fractionated with similar tumor control rates as previous regimens but with less risk of cranial neuropathy or brainstem complications.[5,6] Since no pathologic specimen is obtained, SR risks radiating a malignant lesion with inadequate dosage; close follow-up is essential. Special considerations in radiation include the following:
   a. Control rates: Control in growing tumors is approximately 80% to 85% versus 90% to 95% when all lesions are included.
   b. Radiation-induced malignancy: There have been eight cases of radiation-induced malignancy confirmed with microsurgical resection following stereotactic radiotherapy documented in the literature.[7]
   c. Hearing preservation: Initial hearing preservation deteriorates over time—only 20% retain useful hearing after five years in the Mayo series.[8]
   d. Type of radiation: Gamma Knife versus CyberKnife versus other LINAC systems:

   In our practice, only tumors with documented growth are radiated, and younger patients are typically not radiated. We use CyberKnife or Gamma Knife Icon because it is a frameless stereotactic system that permits fractionation with high precision.
4. Microsurgical resection: The only curative treatment for AN is microsurgical resection. Patients who undergo gross total resection (GRT) benefit from excellent tumor control, management of mass effect, pathologic diagnosis of benign schwannoma, and less intense imaging regiment postoperatively. The best results are obtained at skull base centers that treat a high volume of AN.[9] Tumors may be managed by one of three lateral skull base approaches: TL, MF, and RS craniotomy. Age, hearing status, tumor size, and location all play a role in determining the approach for each patient.
   a. TL: Popularized by the pioneering work of Drs. William House and William Hitselberger, TL is the prototypical neurotologic, collaborative skull base surgical approach.
      1) TL sacrifices hearing as a part of the approach.
      2) TL is recommended for patients without serviceable hearing and in cases where hearing preservation is unlikely.
      3) The primary advantages of TL are little to no brain retraction, reliable identification of the facial nerve at the meatal foramen, and no intradural drilling, thus reducing the risk of postoperative headache.
   b. RS
      1) Hearing preservation: The modern RS is a versatile approach allowing for a wide view of the posterior fossa with hearing preservation for tumors with limited lateral extension into the IAC. MRI T2 sequence imaging can determine the extent of tumor penetration into the IAC.
      2) Hearing preservation with posterior fossa extension: One advantage of RS over MF is that RS allows for hearing preservation in instances where tumors extend more than 0.5 cm into the CPA.
      3) When hearing preservation is not an option, the decision between RS and TL for medium and larger tumors is the surgeon's preference. The authors usually select TL due to less brain manipulation than with the RS approach.
   c. MF approach:
      1) Hearing preservation: MF is an extradural subtemporal technique to access the IAC and is used for hearing preservation with small laterally based lesions.
      2) Limitation: The major limitations to MF are that it provides poor access to the posterior fossa and requires temporal lobe retraction. The addition of temporal lobe retraction adds a minimal risk of seizure, aphasia, and stroke specifically to this approach, and caution should be used in elderly patients due to age-related changes in the dura. Depending on the nerve of origin of the tumor, the risk of facial paresis may be slightly greater in the short term with the MF when compared to other approaches; however, by 1 year the difference is not significant.[10]
5. Treatment selection
   a. Patient education: Detailed information is presented regarding all treatment strategies.
   b. Risks:
      1) Observation: Patients are educated that their tumor may grow, and there is no good means of determining which tumors grow prior to observation, that hearing may deteriorate, and that they may still require either microsurgical resection or stereotactic radiotherapy.
      2) Surgery: Specific risks include bleeding, infection, facial paralysis, hearing loss, balance disturbance, CSF leak, stroke, prolonged headache, need for tracheostomy, gastrostomy, and locked-in syndrome or death.
      3) Informational materials: Patients are provided with a booklet, recommendations for web-based link(s), and a book chapter on CPA tumor management as reliable resources for them to refer to after their appointment.
      4) Radiation: Patients are advised that the risks are similar to surgery but may take years to manifest. Risks specific to radiation include radiation-induced hydrocephalus, hearing loss, facial nerve dysfunction, and the risk of radiation-induced malignancy.

Contraindications

1. Contraindications to microsurgery are mainly related to medical issues. If a patient cannot tolerate general anesthesia, then the tumor is observed; and if it demonstrates growth, stereotactic radiotherapy is offered with possible CSF diversion for hydrocephalus.

2. For patients with tumors that reach or compress the brainstem, microsurgical resection is offered in place of stereotactic radiotherapy or observation. Tumor swelling is common for 18 months following SR. Accordingly any brainstem or cerebellar compression identified prior to treatment contraindicates radiation.

Preoperative Preparation

1. See "Relevant Test" section for audiologic and imaging requirements.
2. Cessation of anticoagulants
3. Preoperative consultation for medical clearance

Operative Period

Anesthesia

1. General

Positioning

1. TL: Supine with the head in a foam donut
2. MF: Supine in neurosurgical pins. The flexible MF retractor could damage the brainstem if it is affixed to the bed and the patient were to move from lightening of anesthesia. By attaching the retractor to head pins, the retractor and the patient's head move as a unit, and inadvertent patient movement does not pose a danger related to retractor damage.
3. RS: Both lateral recumbent position and, more recently, prone positioning in neurosurgical head pins are used, depending on surgeon preference.

Preoperative Medication

1. Antibiotics:
   a. Systemic: A first-generation cephalosporin intravenously prior to incision (unless the patient is allergic to penicillin)
   b. Drill irrigation fluid with antibiotics (cefazolin in patients who are not allergic—otherwise plain saline)
   c. Wound irrigation fluid with antibiotics
2. Steroids: Dexamethasone 10 mg prior to incision
3. Antivirals: Preoperative famciclovir 500 mg three times daily for 3 days preoperative and 4 days postoperatively to minimize the chance of viral reactivation and delayed facial palsy from Bell's palsy (see Evidence-Based Medicine section)

Monitoring

1. Facial nerve monitoring
2. For hearing preservation: Ipsilateral ABR
3. For large AN: Contralateral ABR and CN X via EMG endotracheal tube

Instruments and Equipment to Have Available

1. Middle ear and skull base microsurgical instrument sets
2. Operative microscope with capability for face-to-face orientation for four-handed tumor resection technique
3. High-speed otologic drill
4. MF retractor for procedures using this approach

Key Surgical Landmarks

1. Facial nerve: In all approaches, the facial nerve is an important landmark that needs to be preserved in its intratemporal and intracranial potions.

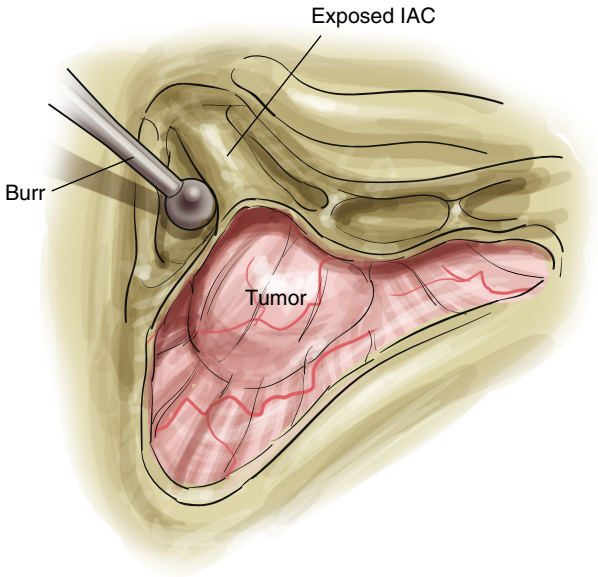

Fig. 140.1. The IAC is skeletonized and bone is removed to expose 180 to 270 degrees of the canal. The facial nerve is identified as it exits the IAC at Bill's bar. *IAC*, Internal auditory canal. *(With permission from Brackmann D, Shelton C, Arriaga MAA: Otologic Surgery, 4th ed. Philadelphia, PA: Elsevier; 2015 [Fig. 49.12 in source].)*

2. Labyrinth: The lateral canal for TL and SSC for MF approach are important for orientation.
3. Orientation of cranial nerves within the IAC

Prerequisite Skills

1. Knowledge of the temporal bone
2. Knowledge of posterior fossa anatomy
3. Microsurgical technique
4. Experience in interpreting auditory feedback from the facial nerve monitoring system

Operative Risks

1. Bleeding: Intracranial bleeding during or after surgery
2. Facial nerve injury: Even with an intact nerve, an immediate or delayed facial nerve paralysis is possible.
3. CSF leak: The use of hydroxyapatite cement during closure of TL and RS approaches has helped decrease postoperative CSF leak rates dramatically. Inadequate sealing of opened petrous air cells around the IAC may also result in CSF rhinorrhea.
4. Stroke
5. Infection: Meningitis and wound infection

Surgical Technique

Translabyrinthine Approach (Figs. 140.1 to 140.3)

1. C-shaped postauricular incision with staggered periosteal incisions permit elevation of soft tissue to expose temporal bone.
2. A complete mastoidectomy includes uncovering the MF and posterior fossa dura and the sigmoid sinus.
3. Labyrinthectomy
4. Identification of the facial nerve in the mastoid segment

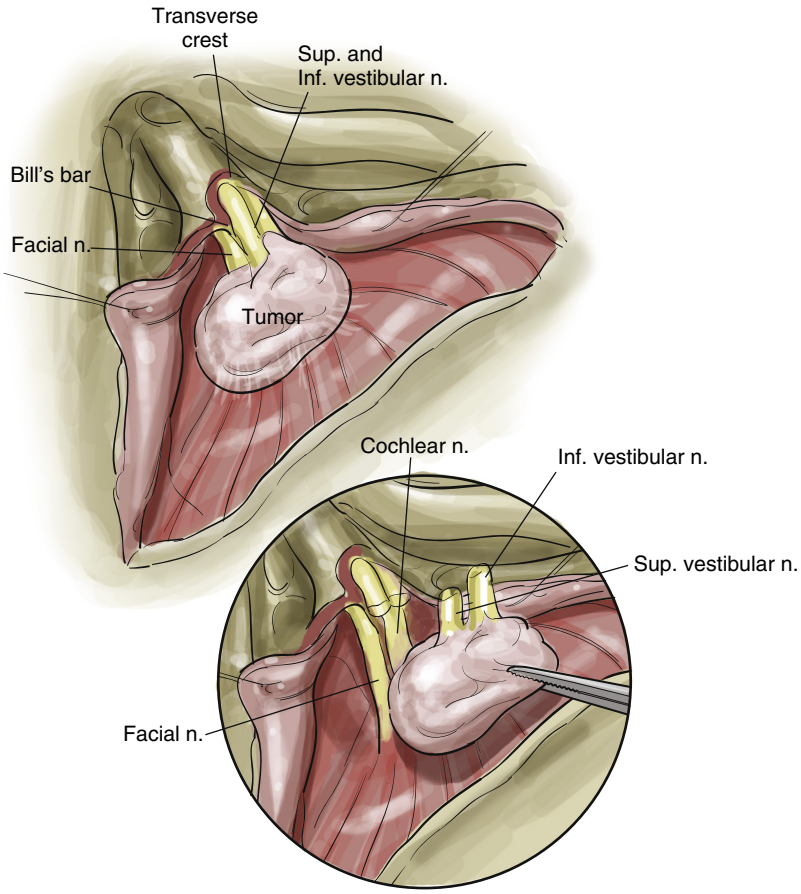

Fig. 140.2. The vestibular nerve and tumor are separated from the facial nerve in the internal auditory canal and dissected to the porous acousticus and cerebellopontine angle. *Inf.*, Inferior; *n.*, nerve; *Sup.*, superior. *(With permission from Brackmann D, Shelton C, Arriaga MAA: Otologic Surgery, 4th ed. Philadelphia, PA: Elsevier; 2015 [Fig. 49.14 in source].)*



Fig. 140.3. With the two-surgeon, four-hands technique, the surgeons can sit or stand opposite each other and assist each other in the same manner as open surgery with both sets of instruments in the surgical field by retracting, suctioning, stimulating, or exposing tissue and advancing the operation as a team.

5. An inferior trough is drilled between the IAC and the jugular bulb, with the cochlear aqueduct as the anterior-inferior limit.
6. A superior trough is created between the MF dura and the IAC; 270-degree exposure of the IAC dura is adequate exposure.
7. At the IAC fundus, the transverse crest separates the inferior vestibular nerve (IVN) and superior vestibular nerve (SVN).
8. Obliteration of the Eustachian tube includes removing the incus, transecting the tensor tendon and packing the Eustachian tube with alternating pieces of temporalis muscle and Fibrillar Surgicel.
9. IAC facial nerve identification requires transecting the SVN at the vertical crest (Bill's bar). Dissection of the tumor along the facial nerve continues medially until the plane of dissection is obscured at the porous acousticus. The two-surgeon, four-handed technique permits rapid debulking of a large AN in the CPA.
10. The final remnants of the tumor and capsule are removed using continuous facial nerve monitoring as the tumor capsule is removed. When gross total removal is not possible, some tumor may be left on the facial nerve for its preservation. Such "near-total" removal results in a low risk of recurrence; however, continuing prospective studies of this strategy are under way.
11. Adipose tissue harvested from the left lower quadrant or acellular dermal substitute is placed in the dural defect. Hydroxyapatite cement is then used to reconstruct the craniotomy defect, forming a watertight reconstruction.
12. The musculoperiosteal flaps are closed and the skin reapproximated with 2-0 Vicryl suture. The skin is closed with a running locked 3-0 Vicryl rapide suture, which provides a second discrete layer of closure diminishing a potential CSF leak. Sterile Steri-Strips are applied and a plastic cup fastened with elastic straps is placed.

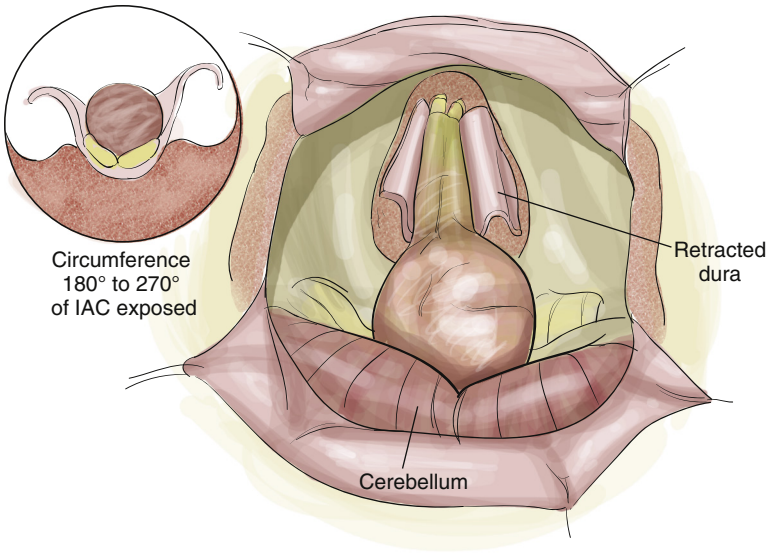

Fig. 140.4. After incising the overlying dura, the internal auditory canal is exposed approximately 180 degrees by drilling troughs on either side. *IAC,* Internal auditory canal. *(With permission from Brackmann D, Shelton C, Arriaga MAA: Otologic Surgery, 4th ed. Philadelphia, PA: Elsevier; 2015 [Fig. 50.6 in source].)*

Retrosigmoid Approach (Fig. 140.4)

1. An incision is made in the retromastoid area through skin to nuchal musculature. Musculoperiosteal flaps are raised exposing RS bone.
2. An RS craniotomy is performed using the sigmoid and transverse sinus as landmarks. The craniotomy is carried anteriorly to the sigmoid and superiorly to the transverse sinuses.
3. Mastoid air cells are occluded with bone wax.
4. A dural incision exposes the cerebellum.
5. CSF release: Gently supporting the cerebellum with a Telfa strip and suction tip allows opening the cisterna magna. Patiently releasing CSF avoids injury to the cerebellum.
6. With the cerebellum relaxed and tumor exposed, the IAC can be drilled. If the CPA component of the tumor inhibits drilling of the IAC, tumor debulking exposes the petrous bone for IAC drilling.
7. If the AN extends into the IAC, the dura is reflected inferiorly as a semicircular flap. The IAC is drilled 270 degrees in circumference. In hearing preservation cases, the medial two-thirds of the IAC can be exposed. Further lateral exposure risks entrance into the inner ear.
8. Tumor resection techniques are the same as in TL.
9. Air cells of the IAC are occluded with bone wax and a small muscle plug is placed in the IAC.
10. The subarachnoid space is filled with saline, and the dura is closed primarily or with a graft.
11. Hydroxyapatite cement is used to reconstruct the craniotomy site.
12. Wound closure is the same as TL.

Middle Fossa Approach (Fig. 140.5)

1. A preauricular vertical incision is made through skin to the temporalis muscle. The temporalis muscle is then divided, exposing the lateral aspect of the skull and squamous portion of the temporal bone.
2. Care is taken to identify the level of the zygomatic root as a landmark for the level of the floor of the MF.
3. A 5 cm by 5 cm craniotomy bone flap is centered on the root of the zygoma.
4. The craniotomy is refined so that it is flush with the level of the floor of the MF. The dura is then raised in a posterior-to-anterior fashion off of the floor of the MF to protect the geniculate ganglion and facial nerve, which are dehiscent in up to 15% of cases.
5. The dura is elevated anteriorly up to the foramen spinosum (middle meningeal artery) and medially to the superior petrosal sinus and the crest of the petrous bone. A MF retractor is used. While many types are available, we use two retractor spatulas supporting the dura attached to adjustable "goose-neck" arms, which are connected to the Mayfield head frame.
6. Antidromic greater superficial petrosal nerve (GSPN) stimulation identifies the geniculate ganglion.
7. The SSC is identified directly, or if necessary, the mastoid air cells are opened from the tegmen to reveal it. The SSC is "blue lined" and can be occluded with bone wax, SSC occlusion widens the exposure by using the hearing-preservation labyrinthine occlusion techniques from vestibular surgery.
8. Drilling proceeds from medial to lateral to expose the IAC. Exposure is limited anteriorly by the close relationship of the cochlea to the lateral third of the canal anteriorly.
9. The dura of the IAC is opened, and the intracanalicular tumor is removed by first separating the anteriorly placed facial nerve from the tumor. To maximize hearing preservation, a medial to lateral dissection helps protect the cochlear nerve fibers at the habenula perforata. The bony IAC defect is covered with adipose tissue or acellular dermal substitute.
10. Temporal lobe retractors are removed, and the bone flap is replaced with plates and screws.
11. The temporalis fascia is closed with Vicryl.
12. The skin closure is the same as TL and RS.

Common Errors in Technique

1. Inadequate bone removal in TL surgery
2. Poor placement of craniotomy in MF and RS will create difficulties with medial exposure and tumor resection.
3. Attempts at facial nerve stimulation and dissection are not advisable when the nerve is firing and indicating irritation. It is better to stop and wait to proceed, as nerve changes cannot be monitored while it is firing.

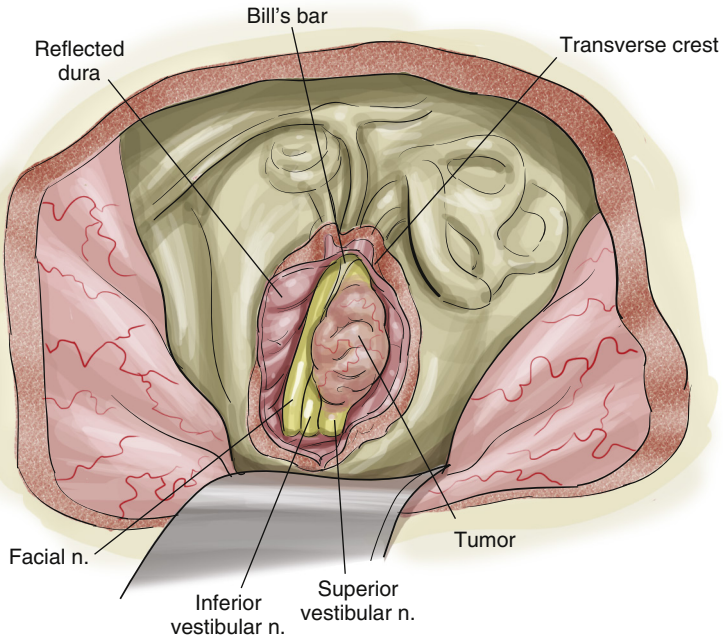

Fig. 140.5. An intracanalicular acoustic tumor is dissected from the facial and cochlear nerves. *(With permission from Brackmann D, Shelton C, Arriaga MAA: Otologic Surgery, 4th ed. Philadelphia, PA: Elsevier; 2015 [Fig. 48.8 in source].)*

POSTOPERATIVE PERIOD

Postoperative Management

1. ICU for the first 1 to 2 days
2. Head CT and temporal bone CT are obtained on the first postoperative morning. If CT does not demonstrate intracranial bleeding, SQ heparin is used for venous thrombosis prophylaxis.
3. Complete blood count (CBC) and metabolic bloodwork
4. Patients are encouraged to ambulate. Early postoperative vestibular physical therapy has lowered our average postoperative stay for AN to 3.5 days by hastening vestibular compensation.

COMPLICATIONS

1. Facial paralysis:
   a. Intact nerve: If the nerve stimulates with low current at the end of the case, a favorable outcome is likely. If the patient has a delayed facial nerve paralysis, the prognosis also has a favorable outcome.
   b. Incomplete eye closure: Use lubricating drops, lubricating ointment at night, and a moisture chamber to protect the eye. In cases with poor intraoperative facial stimulation or paralysis longer than a month, insertion of a platinum eyelid weight protects the eye until facial function recovers.
   c. Nerve transection: Immediate direct repair is best; when necessary, nerve substitution (V to VII or XII to VII) provides facial function.
2. CSF leak:
   a. Incision: Additional sutures with a tight mastoid dressing usually resolve the drainage. If leakage persists, a lumbar drain is placed.
   b. Rhinorrhea: A lumbar drain is the initial treatment. If a lumbar drain fails to stop the CSF leak, then the leak is repaired surgically. The approach to close the CSF leak is dependent on the approach and patient hearing status. If the approach was a MF or RS, then the wound is opened, explored, and any open air cells are occluded. If the patient did not retain hearing, then the eustachian tube can be obliterated with muscle and Surgicel or hydroxyapatite cement. Some surgeons report transection and closure of the ear canal and mastoid obliteration.
   c. Recalcitrant leaks: Allow for closure of the ear canal with removal of all squamous epithelium of the ear canal and tympanic membrane and obliteration of the Eustachian tube, middle ear, and mastoid.
3. Hemorrhage: Intracranial bleeding is managed based upon the location and size of the bleeding.
4. Hearing loss: Despite attempts to preserve hearing and even with good ABR waveforms at the end of the case, hearing can be lost. Numerous techniques for hearing rehabilitation for unilateral sensorineural loss include CROS hearing aids and implantable bone vibration devices (e.g., BAHA, PONTO, and Sophono).
5. Headache: Moderate postoperative pain can be controlled with temporary analgesics. To limit headaches, special attention is placed on limiting intradural spread of bone dust or avoiding direct adhesion of muscle to dura with cranioplasty techniques. While prolonged headache with TL and MF is unusual, RS patients can suffer from severe discomfort, requiring long-term use of narcotics.

ALTERNATIVE MANAGEMENT

For every patient with an AN observation, stereotactic radiotherapy and microsurgery are the available options of management.

DISCUSSION

Evidence-Based Medicine Questions

Which is preferred—complete resection versus subtotal or near-total resection?

If small remnants of the tumor do not cause clinical problems for operated patients, then leaving the tumor on critical structures may limit surgical morbidity. While preliminary indications are encouraging, a prospective longitudinal trial is under way to understand the long-term implications of this strategy.

Can treatments for viral reactivation prevent delayed facial weakness after acoustic tumor surgery?

A provocative retrospective report from the House Ear Clinic suggests that pretreatment with steroids and antivirals

(similar to protocols for Bell's palsy) are effective at preventing delayed paralysis.

What are the trends in AN management?

A recent retrospective review of the surveillance, epidemiology, and end results program (SEER) database reviewed the management of 8330 patients from 2004 to 2011. The review found that approximately 48% of patients underwent microsurgical resection, 24% radiation alone, and 29% observation. Interestingly, within the cohort that had surgery, 18% underwent subtotal resection, and of that subcohort, 13.4% received postoperative radiation therapy. Multivariable regression demonstrated that younger patients and patients with larger tumors underwent surgery. Overall rates of surgery decreased, observation increased, and radiation stayed constant.[3]

The senior author's (Arriaga's) experience mirrors the SEER database trends. Between 1991 and 2015, in a series of 1709 AN, 50% were treated with microsurgery. In our series, the specific management strategy was observation 47%, TL 32%, RS 7%, MF 11%, and SR 3%.

Editorial Comment

The authors have had early experience with using a prone position for the RS approach. They anticipate sharing this experience in the pending literature. The lateral decubitus or park bench position with Mayfield head pins is currently the more common position.

The preoperative battery of auditory, vestibular, and facial nerve testing can provide information regarding the functional status of both the ipsilateral and contralateral seventh and eighth nerves. This can help guide the process of planning preoperative counseling and intervention. It could be predictive of comprised hearing and facial nerve outcomes. Vestibular physical therapy can be initiated prior to surgery to facilitate postoperative rehabilitation. Each surgical team should decide the degree of testing they think is warranted in managing their patients undergoing surgery or even radiation therapy.

Barry Hirsch

Access the review questions and additional sources list online at http://www.expertconsult.com



REFERENCES

1. Arriaga MA, Carrier D, Houston GD. False-positive magnetic resonance imaging of small internal auditory canal tumors: a clinical, radiologic, and pathologic correlation study. Otolaryngol Head Neck Surg 1995;113(1):61–70.
2. Koors PD, Thacker LR, Celho DH. ABR in the diagnosis of vestibular schwannomas: a meta-analysis. Am J Otolaryngol 2013;34:195–204.
3. Carlson ML, Habermann EB, Wagie AE, et al. The changing landscape of vestibular schwannoma management in the United States—a shift toward conservatism. Otolaryngol Head Neck Surg 2015;153:440–446.
4. Stangerup S-E, Caye-Thomasen P. Epidemiology and natural history of vestibular schwannomas. Otolaryngol Clin N Am 2012;45:257–268.
5. Lunsford LD, Niranjan A, Flickinger JC, et al. Radiosurgery of vestibular schwannomas: summary of experience in 829 cases. J Neurosurg 2013;119:195–199.
6. Yang I, Sughrue ME, Han SJ, et al. Comprehensive analysis of hearing preservation radiosurgery for vestibular schwannoma. J Neurosurg 2010;112:851–859.
7. Maducdoc MM, Ghavami Y, Linskey ME, et al. Evaluation of reported malignant transformation of vestibular schwannoma: de novo and after stereotactic radiosurgery or surgery. Otol Neurotol 2015;36:1301–1308.
8. Carlson ML, Link MJ, Wanna GB, et al. Management of sporadic vestibular schwannoma. Otolaryngol Clin N Am 2015;48:407–422.
9. Wackym PA. Stereotactic radiosurgery, microsurgery, and expectant management of acoustic neuroma: basis for informed consent. Otolaryngol Clin N Am 2005;38:653–670.
10. Ansari SF, Terry C, Cohen-Gadol AA. Surgery for vestibular schwannomas: a systematic review of complications by approach. Neurosurg Focus 2012;33(3):E14.

REVIEW QUESTIONS

1. A patient presents with a 2.8-cm CPA lesion with less than 50% SDS and greater than 50 dB SRT. Which of the following is the worst approach?
   a. Middle fossa
   b. Retrosigmoid
   c. Transcochlear
   d. Translabyrinthine

2. A 24-year-old patient presents with a 2.5-cm CPA lesion that enhances on T1 with gadolinium. The MR demonstrates considerable brainstem compression. What is the management option for the patient?
   a. Microsurgical resection
   b. Observation and follow with repeat imaging
   c. Stereotactic radiotherapy
   d. Discharge from clinic

3. A 65-year-old man presents with a complaint of hearing loss. An audiogram demonstrates asymmetric sensorineural hearing loss and poor speech discrimination on the affected side. He has no other complaints. What is the next step in his evaluation?
   a. CT head
   b. CT temporal bone
   c. MR IAC with and without contrast
   d. CT temporal bone with contrast

4. The previous patient presents as described in question 3 but recently had a pacemaker placed. What is the best next step?
   a. CT head with contrast and obtain an ABR
   b. MR IAC with and without contrast
   c. CT temporal bone with contrast and obtain an ABR
   d. CT temporal bone with contrast

5. A 55-year-old female presents with a 1.9-cm IAC lesion that enhances with gadolinium on T1 imaging. The tumor is confined primarily to the CPA with minimal if any IAC extension. Her audiogram demonstrates an SRT of 25 dB and SDS of 83%. What is the best surgical approach if she wishes to preserve hearing?
   a. Retrosigmoid
   b. Transcochlear
   c. Translabyrinthine
   d. Middle fossa

ADDITIONAL SOURCES

Arriaga MA, Scrantz K. Four-handed, two surgeon microsurgery in neurotology. Laryngoscope 2011;121:1483–1485.

Arriaga MA, Haid R, Masel D. Antidromic stimulation of the greater superficial petrosal nerve in middle fossa surgery. Laryngoscope 1995;105:102–105.

Brackmann DE, Fisher LM, Hansen M, et al. The effect of famciclovir on delayed facial paralysis after acoustic tumor resection. Laryngoscope 2008;118(9):1617–1620.

Gurgel RK, Dogru S, Amdur RL, et al. Facial nerve outcomes after surgery for large vestibular schwannomas: do surgical approach and extent of surgery matter? Neurosurg Focus 2012;33(3):E16.

Volosky PG, Hillman TA, Stromberg KJ, Buchinsky FJ, Chen DA, Jackson NM, Arriaga MA. Hydroxyapatite cement cranioplasty following translabyrinthine approach: Long-term study of 369 cases. Laryngoscope. 2017 Jan 6. doi: 10.1002/lary.26403. (Epub ahead of print).

141 Resection of the Temporal Bone

Stephanie Moody Antonio

INTRODUCTION

Resection of the temporal bone may be indicated as a component of management for advanced cancers of the parotid gland, periauricular skin, and neck, as well as primary lesions of the external auditory canal (EAC), middle ear, and mastoid. The anatomy of the temporal bone is complex with implications for the spread of cancer from one anatomical region through pathways that expand the need for more encompassing extirpative surgery. Partial or complete resection of the temporal bone introduces cosmetic and functional consequences that must be considered and weighed against the risks of leaving residual cancer, which is the primary risk factor for recurrence and subsequent mortality. Although radiotherapy plays an important role in the management of carcinoma in the temporal bone region, it has significant limitations; therefore, only surgical treatment is curative. Complete resection with wide margins is the only viable option; therefore, it is important to have a thorough knowledge of the anatomy of the entire region and an excellent surgical technique.

KEY OPERATIVE LEARNING POINTS

1. Primary malignancy of the temporal bone is rare, but resection of the temporal bone also may be required for periauricular skin cancer, parotid, metastatic disease, or other soft tissue cancers with secondary spread to the temporal bone. An appropriate margin may require resection of adjacent functional structures, such as the bony ear canal, tympanic membrane, facial nerve, or dura.
2. The diagnosis of cancer of the temporal bone should be considered for a patient with long-standing otorrhea, otalgia, facial nerve paralysis, or a mass or ulcer of the EAC.
3. The modified Pittsburgh staging system for primary lesions of the temporal bone is predictive of the outcome.
4. Partial resection and mastoidectomy for biopsy should be avoided.
5. The primary goal of surgery is complete resection with clear margins, which is the best predictor of a good outcome.

PREOPERATIVE PERIOD

History

- Squamous cell carcinoma of the EAC has a reported incidence of approximately 1 per 1 million per year. Other pathologies may involve the temporal bone, including basal cell carcinoma, adenocarcinoma, and adenocystic carcinoma.
- Primary malignancies of the temporal bone may also arise in the EAC, middle ear, mastoid and, rarely, in the jugular foramen and petrous apex.
- Secondary tumors may involve the temporal bone as a result of spread from adjacent structures, such as the concha, pinna, parotid gland, and dura.
- Metastasis to the temporal bone from distant sites can also occur, often at the petrous apex.
- Carcinoma of the ear canal may be difficult to distinguish from chronic otitis externa, malignant otitis externa, cholesteatoma of the ear canal, temporal bone osteonecrosis, and otitis media.
- Symptoms include:
  - Persistent, deep-seated, unrelenting pain
  - Bloody otorrhea
  - Hearing loss
  - Weakness of the facial nerve
  - Deficits of other cranial nerves
  - Diffuse edema or stenosis of the ear canal
- Maintain a high index of suspicion for any condition of the EAC that does not respond to topical or systemic antibiotic treatment.
- Cancer of the temporal bone may occur in younger people who are more likely to have aggressive disease.

Physical Examination

- Findings include a friable, necrotic, bloody broad-based mass, polyp or ulceration, or diffuse thickening or stenosis of the EAC.
- Define the involvement of cartilaginous and bony canal with microscope examination of the ear.
- Evaluate the function of the facial nerve and other cranial nerves.
- Determine whether the cancer appears to involve the tympanic annulus or the tympanic membrane, middle ear (middle ear mass or effusion), neck (masses or tenderness), and temporomandibular joint (TMJ) (trismus).
- Perform an audiogram.

Imaging

- Determine the extent of disease for staging using examination and imaging.
- Usually, both magnetic resonance imaging (MRI) and computed tomography (CT) will be required to adequately stage the disease process.
  - High-resolution thin cut CT of the temporal bone
  - MRI of the skull base with and without contrast
  - CT or MRI of the neck with contrast
- Encroachment of cancer in the region of the internal carotid artery (ICA) should be investigated with CT angiography or angiography with the balloon occlusion test if resection of the ICA is considered. Venography is helpful for evaluation of the dural sinuses.
- Screen for additional pathology with chest radiography and liver function testing.
- In malignant tumors with a high predilection for systemic spread, such as melanoma, CT scanning of the chest, abdomen, and pelvis, as well as whole-body bone scanning, should be performed.
- Positron emission tomography (PET) may be considered for the evaluation of local involvement and distant metastasis.
- While a survey of the extent of disease with combined imaging modalities is generally predictive of intraoperative findings, the extent of the cancer may be underestimated, especially with respect to spread posteriorly, superiorly, and medially.[1]

TABLE 141.1 Modified Pittsburgh Staging System for Primary Cancers of the Temporal Bone

T1	Tumor limited to the EAC; no bone erosion or soft tissue extension
T2	Tumor with limited bone erosion to the EAC or <0.5 cm of soft tissue involvement
T3	Tumor with full-thickness EAC bone erosion, <0.5-cm soft tissue involvement, or tumor in the middle ear or mastoid
T4	Tumor eroding the cochlea, petrous apex, medial wall of the middle ear, carotid canal, jugular foramen, or dura; or >0.5 cm soft tissue involvement; or facial nerve paresis

EAC, External auditory canal.

Indications

- Primary cancer of the EAC can be staged according the modified Pittsburgh system[2] as T1 through T4, depending on the degree of bone, cartilage, and soft tissue involvement (Table 141.1).
- Sleeve resection of skin of EAC for very limited lesions of the external auditory meatus and lateral EAC
- Lateral temporal bone resection for lesions limited to the EAC (T1, T2)
- Subtotal temporal bone resection for cancer invading the middle ear and mastoid (T3, T4)
- Total temporal bone resection for cancer extending to the petrous apex
- Cancer extending to the TMJ, neck, dura, or infratemporal fossa (ITF) will require resection including these regions

Contraindications

- Extension into the cavernous sinus and brain parenchyma makes total extirpation of the cancer nearly impossible, and the possibility of cure becomes unlikely, even with the addition of aggressive adjuvant radiation therapy and chemotherapy.
- Involvement of the internal carotid canal is also problematic, but it is not an absolute contraindication to surgical resection.
- Compromised medical status precluding a prolonged general anesthetic and recovery.

Preoperative Preparation

- Biopsy is performed by direct incision; a staging mastoidectomy is not appropriate because it reduces the reliability of staging radiography and it may compromise the surgical margins of resection.
- A team approach is often necessary for advanced cancer, including the cooperation of a Neurotologist, Head and Neck Surgeon, Reconstructive Surgeon, Neurosurgeon, Pathologist, Radiation Oncologist, and Intensivist, as well as experienced nursing teams.
- Consider whether a simultaneous osseointegrated implant for hearing device or prosthetic ear is indicated, or discuss with the patient that these options may be considered after primary surgical management of the cancer has been completed.
- The patient's medical status should be optimized before surgery. Significant conditions, such as coronary artery disease, chronic obstructive pulmonary disease, diabetes mellitus, bleeding disorders, and malnutrition should be identified and treated preoperatively.

OPERATIVE PERIOD

Anesthesia

- General oral endotracheal anesthesia
- Arterial line for surgery involving more than a lateral temporal bone resection
- Urinary catheter
- Avoid neuromuscular blocking agents
- Furosemide and mannitol, 0.25 to 0.5 g/kg, 30 minutes before intracranial dissection

Positioning

- Place the patient supine with appropriate padding, head turned with the affected ear up.
- If intracranial or more extensive dissection is planned, a Mayfield clamp may be used.
- Secure the patient to the table with 4-inch tape across the shoulders, hips, and thighs.
- Use sequential compression stockings on the patient.
- Prep the primary surgical site, neck, and planned graft sites.

Perioperative Antibiotic Prophylaxis

- A third-generation cephalosporin with cerebrospinal fluid (CSF) penetration, such as ceftriaxone, is administered perioperatively.

Monitoring

- Facial nerve monitoring from the orbicularis oris and orbicularis oculi
- Cranial nerves IX and X are monitored in some cases

Instruments and Equipment to Have Available

- Otologic microscope
- Plastics microscope if a free flap is anticipated
- Otologic drill
- Otologic mastoid and middle ear dissection set
- Head and neck instrument set
- Monopolar and bipolar electrocautery for both otologic and head and neck teams
- Prass or Kartush probe for direct facial nerve stimulation
- Fine straight and gently curved osteotome and mallet
- Osseointegrated implants for bone-conduction hearing device and/or prosthetic auricle (Vistafix)

Key Anatomic Landmarks

- The cartilaginous portion of the EAC is a poor barrier to the spread of neoplasm. Cancers in this area can erode through skin, cartilage, and soft tissue to invade the parotid gland anteriorly or the concha and postauricular sulcus posteriorly (Fig. 141.1A and B).
- The fissures of Santorini are vertical fissures in the cartilaginous EAC that allow direct access of cancer from the skin of the EAC to the periparotid tissues.
- The bony ear canal provides a more resistant barrier to direct invasion. Cancer in this area tends to track medially through the tympanic membrane into the middle ear and mastoid spaces.
- The foramen of Huschke is a defect in the anterior inferior tympanic ring that usually closes by 5 years of age, which provides a potential pathway between the bony EAC and the soft tissues of the parotid area and TMJ.
- Cancer may invade from the middle ear along the Eustachian tube to the ICA, Meckel's cave, and the cavernous sinus.
- Superior extension through the tegmen tympani and tegmen mastoideum may result in involvement of the middle fossa dura and the temporal lobe.
- Medially, the otic capsule provides a barrier to the spread of cancer, but the round and oval windows can be penetrated allowing for invasion through the vestibule and into the internal auditory canal (IAC) and posterior fossa.

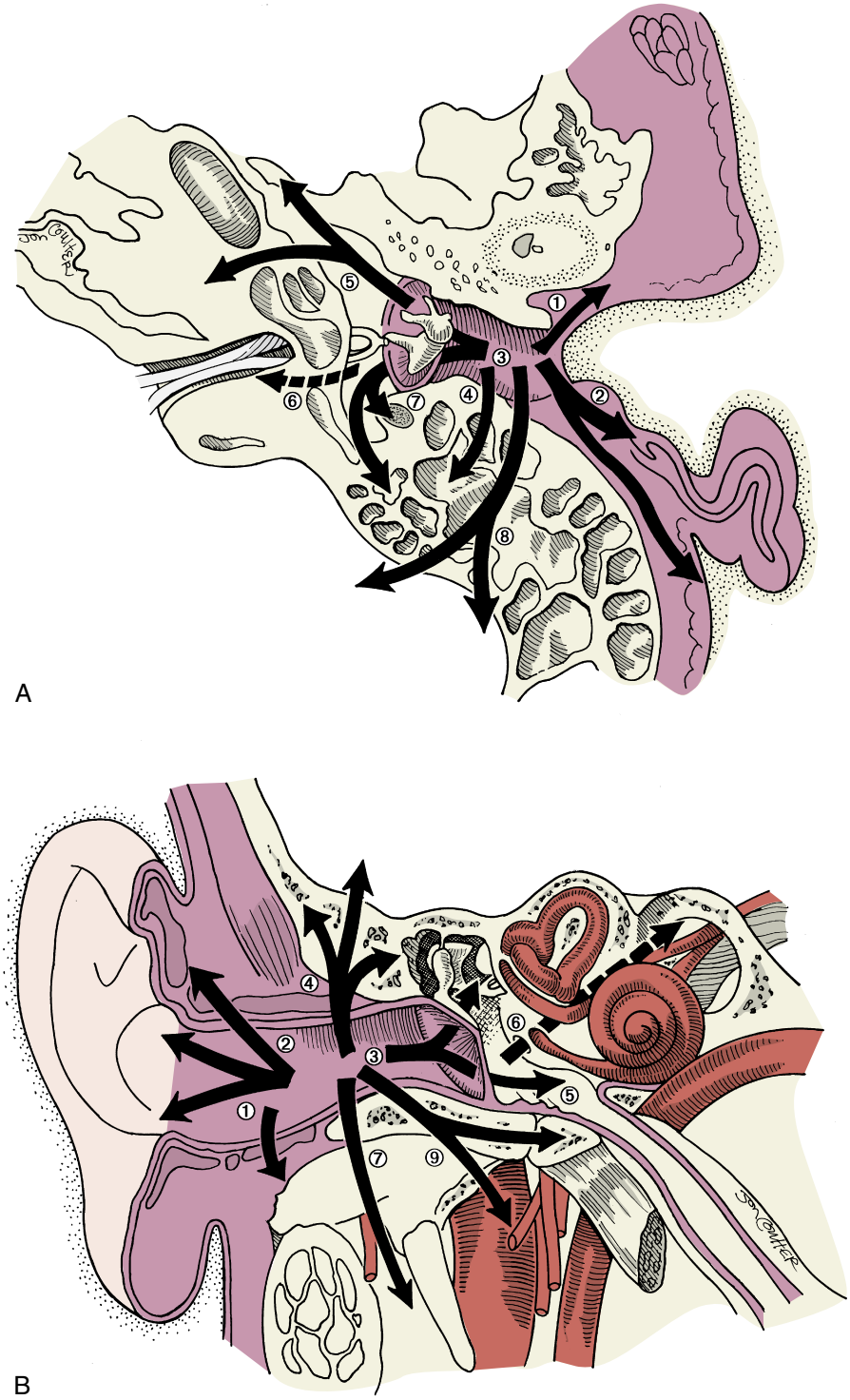

Fig. 141.1. Axial **(A)** and coronal **(B)** temporal bone anatomy showing pathways of spread of cancer *(1)* anteriorly through the cartilaginous canal into the parotid, *(2)* through the concha into the postauricular soft tissues, *(3)* through the tympanic membrane, *(4)* posteriorly into the mastoid, *(5)* medially to the carotid artery and Eustachian tube, *(6)* medially to the otic capsule through the round and oval windows, *(7)* along the facial nerve either inferiorly to the infratemporal fossa or medially to the internal auditory canal, *(8)* through the mastoid, posterior fossa tegmen, and sigmoid sinus, and *(9)* inferiorly to the jugular foramen, carotid artery, and lower cranial nerves.

- The facial nerve provides a pathway for the spread of cancer intracranially, into the neck through the stylomastoid foramen, or into the ITF via the greater superficial petrosal nerve.
- Posteriorly, cancer can invade the posterior fossa plate, dura, and sigmoid sinus.
- Extension inferiorly leads to involvement of the jugular foramen and neck.
- Lymphatic drainage of the EAC extends anteriorly to the parotid and periparotid lymph nodes, inferiorly to the internal jugular lymph nodes, and posteriorly to the mastoid lymph nodes. The lymphatic drainage pathways from the

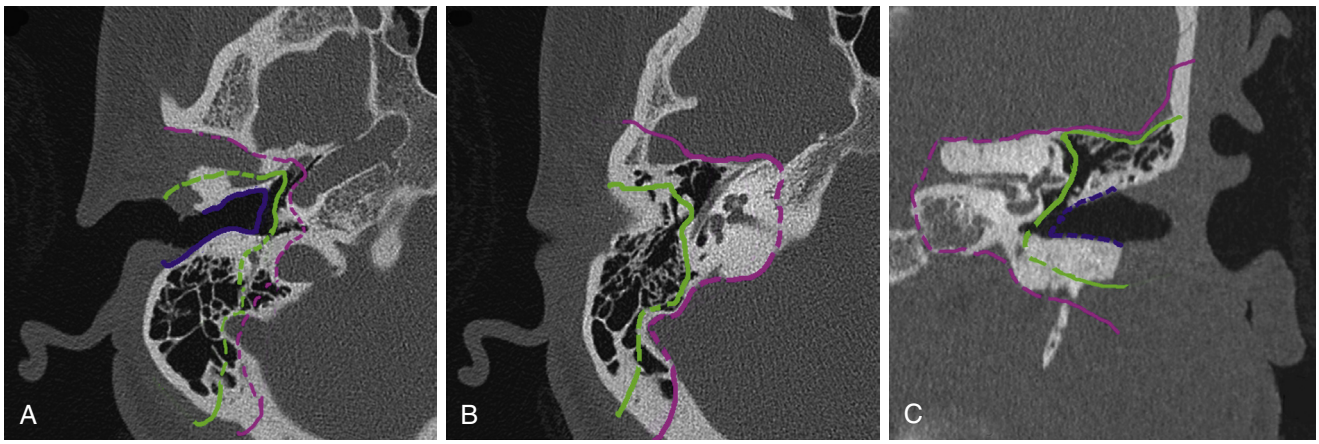

Fig. 141.2. Three types of temporal bone resections: sleeve resection *(blue line)*, lateral temporal bone resection *(green line)*, and total temporal bone resection *(pink line)*. Dotted lines indicate where the extension of resection may take place depending on the extent of the disease. **A**, Axial CT at the level of the EAC showing jugular bulb, carotid, and vertical portion of facial nerve. **B**, Axial CT at the level of the cochlea, the horizontal segment of the facial nerve, and the petrous apex. **C**, Coronal CT at the level of the EAC and IAC.

middle ear and mastoid have not been well defined, but they are believed to be of only minor importance, because nodal metastasis from a malignancy limited to the middle ear and mastoid is rare.

Prerequisite Skills

- Advanced mastoidectomy
- Closure of external auditory meatus
- Auriculectomy
- Neck dissection
- Parotidectomy
- Facial nerve decompression/resection
- Microvascular anastomosis
- Osseointegrated implantation
- Craniotomy
- Dural resection and reconstruction
- Dissection of ITF
- Dissection of jugular bulb
- Local myofascial rotation flap
- Split-thickness skin graft
- Microvascular reconstruction

Operative Risks

- Deformity
- Loss of ability to wear glasses
- Hearing loss
- Vertigo
- Facial nerve paralysis
- Blood loss
- Infection
- Wound complications
- Paralysis of cranial nerves IX, X, XI, XII
- CSF leak
- Meningitis
- Temporal lobe edema or infarction
- Generalized cerebral ischemia

Surgical Technique

Lateral Temporal Bone Resection

1. This is appropriate for cancer limited to the EAC without penetration medially through the tympanic membrane.
2. The anatomic unit removed en bloc is the EAC, the tympanic membrane, and the malleus (Fig. 141.2A to C).
3. The boundaries of resection include the middle ear cavity medially, the TMJ capsule anteriorly, the zygomatic root superiorly, the mastoid cavity posteriorly, and the ITF inferiorly. Laterally, the resection can include the concha, as well as portions of the pinna, depending on the extent of the cancer.
4. Inject the proposed incision sites with 2% lidocaine with 1:100,000 epinephrine for hemostasis.
5. Make a circumferential incision around the concha for cancer involving only the EAC and extend as needed for a wide skin margin. If the upper one-third of the pinna can be preserved, it offers some advantage for patients who wear glasses; but otherwise, there is minimal advantage to saving small portions of the pinna.
6. Make a wide incision 3 cm behind the postauricular sulcus extending into the neck if neck dissection is anticipated (Fig. 141.3).
7. After elevating the skin a short distance anteriorly, the dissection is directed medially through the fibroperiosteal layer to the mastoid cortex.
8. Elevate the subperiosteal flap and connect the conchal incision circumferentially with the postauricular wound lateral to the temporalis fascia and parotid fascia, and continue elevation anteriorly until the masseter muscle is identified.
9. Send the skin margin for frozen section.
10. Oversew the lateral margin of the EAC to prevent tumor spillage.
11. Perform a complete mastoidectomy. Avoid over-thinning the bony ear canal to the point of exposing the cancer.
12. Open the facial recess and extend it by sacrificing the chordae tympani nerve.
13. Inspect the middle ear through the facial recess to verify the absence or presence, of penetration of the cancer through the tympanic membrane.
14. Identify the facial nerve and dissect it to the stylomastoid foramen.
15. Separate the incudostapedial joint and remove the incus.
16. Cut the tensor tympani tendon.
17. Inferiorly, drill between the facial nerve and the annulus of the tympanic membrane toward the anterior wall of the EAC until the capsule of the TMJ and the periosteum of the anterior tympanic ring are reached.



Fig. 141.3. A typical incision for a primary lesion of the external auditory canal including a circumferential incision through the cartilaginous canal and a wide postauricular incision.

18. Superiorly, drill through the air cells of the zygomatic root between the tegmen tympani and the epitympanum to expose the endosteum of the glenoid fossa.
19. Once this bony dissection has been completed, the EAC is attached anteriorly by the thin tympanic plate.
20. The spread of cancer anteriorly or inferiorly into the TMJ or ITF can be treated by extension of the surgical resection into these areas.
21. An osteotome is inserted through the extended facial recess to the bone just lateral to the Eustachian tube orifice. A few gentle taps on the osteotome will complete the osteotomy, and the EAC can be dissected from the TMJ capsule.
22. Pack the Eustachian tube.
23. Perform a superficial parotidectomy with facial nerve dissection.
24. Remove the EAC with the parotid tissue.
25. Orient the specimen for the pathologist.
26. The neck dissection, if done, is usually performed as a separate specimen.
27. Use an inferiorly based temporalis muscle flap to fill the defect. This is facilitated by the removal of the root of the zygoma.
28. Close the skin defect at the concha primarily or with a split-thickness skin graft.

Subtotal Temporal Bone Dissection

1. This is appropriate for cancer that extends medially to the tympanic membrane and invades the middle ear, hypotympanum, otic capsule, facial nerve, or mastoid.
2. The main specimen typically includes the EAC, tympanic membrane, superficial or total parotid, mandibular condyle, and facial nerve. In most cases, additional bone is removed piecemeal, by drilling the otic capsule, tegmen, bony plate of posterior fossa, and jugular bulb, although this portion of the temporal bone may be removed en bloc. The resection may include dura, temporal lobe, and contents of the ITF.
3. Margins are the middle fossa dura superiorly, the posterior fossa dura and sigmoid sinus posteriorly, the IAC anteriomedially, the base of the skull and jugular bulb inferiorly, and the petrous apex medially.
4. Perform a lateral temporal bone dissection.
5. Expose and control the critical neurovascular structures of the neck and perform a neck dissection based on the degree of nodal involvement.
6. Disconnect the sternocleidomastoid muscle from the mastoid tip to expose the digastric muscle and transverse process of the atlas exposing the jugular vein, carotid artery, and lower cranial nerves at the skull base.
7. Thin and resect the tegmen mastoideum and posterior fossa plate, exposing the jugular bulb.
8. If facial nerve preservation is planned, decompress the entire nerve.
9. Perform the translabyrinthine approach to the IAC or expose the IAC through a middle fossa crainiotomy. Open the IAC and transect the cochlear and vestibular nerves and mobilize or transect the facial nerve.
10. If cancer has infiltrated the protympanum, the dissection will include resection of the mandibular condyle and dissection of the ITF with total parotidectomy, transposition of the carotid artery, resection of the Eustachian tube, cranial nerve V3, and the adjacent skull base as needed.
11. Drill out the remainder of the otic capsule containing the cochlea and the vaginal process between the jugular bulb and the ICA leaving only the anterior petrous apex. Expose the ICA in its vertical and horizontal segments.
12. If cancer involves the lateral wall of the sigmoid sinus or jugular bulb, ligate the internal jugular vein and sigmoid sinus. Open and pack the jugular bulb to control the bleeding from the inferior petrosal sinus.
13. If cancer is present on the medial wall of the jugular bulb, the resection must be extended into the pars nervosa. If the decision is made to do this, remove the medial wall of the jugular bulb and the contents of the par nervosa, including cranial nerves IX, X, and XI.
14. Resect the involved dura with margins and repair with a fascial or pericranial graft. If there is limited invasion of the temporal lobe, it may be resected, albeit with a small potential for cure.
15. Cover the IAC with fascia and fibrin glue.
16. Reconstruct the soft tissue defect with a microvascular free flap.

Total Temporal Bone Resection

1. This is indicated for a tumor invading the Eustachian tube or extending into the petrous apex.
2. Remove the remaining anterior petrous apex after a subtotal temporal bone resection.
3. Gain proximal and distal control of the intrapetrous ICA.
4. Mobilize the ICA from the skull base.
5. Drill the remaining petrous apex and resect or obliterate the Eustachian tube.
6. Reconstruction is similar to the subtotal temporal bone resection with dural repair and free flap.

Common Errors in Technique

- Although it may be tempting to try to employ less extensive resections for limited cancers of the lateral ear canal or bony canal, procedures such as sleeve resections, resection limited to the cartilaginous canal, or radical mastoidectomy often lead to long-term management problems with poor healing, collapse of the canal, cholesteatoma, and cerumen impaction. Therefore, a lateral temporal bone resection is the minimal procedure for cancers of the cartilaginous or bony EAC.
- For cancers limited to the EAC, avoid violation of the bony EAC and annulus during lateral temporal bone resection, which would potentially expose the surgical field to the cancer.
- Remain oriented to the location of the Eustachian tube orifice during osteotomy to avoid injury to the carotid artery.

- Careful pathologic evaluation is critical to understand long-term prognosis and prescribe adjuvant therapy. It is helpful to send multiple frozen sections during dissection, making sure the identity of each specimen is clearly defined and communicated to the nursing and pathology team. Ideally, the surgeon will personally orient the specimen for the pathologist in the operating room so that they can identify margins that are potentially close and should be examined by frozen section.
- Since the extent of disease is sometimes difficult to appreciate preoperatively, especially in the case of soft tissue tumors, such as adenocarcinomas or adenocystic carcinoma, the surgical team and patient must be prepared to extend the dissection as necessary.
- If a laceration of the ICA occurs, it is managed by primary repair, patch, bypass grafting using the saphenous vein, or sacrifice without reconstruction. Be prepared to know whether the patient can tolerate sacrifice of the vessel by obtaining a preoperative balloon occlusion test.
- Damage to the vein of Labbé can lead to significant temporal lobe infarction with aphasia if on the dominant side as well as seizures. When packing or ligating the sigmoid or transverse sinus it is important to stay far anterior to the insertion of the vein of Labbé into the transverse sinus.
- Assure complete closure of the Eustachian tube as it offers a potential route for contamination of the surgical wound from the nasopharynx and route for CSF leakage.
- Although pedicled flaps are sometime adequate, free microvascular flaps offer the most flexible options for closure of large defects after subtotal and total temporal bone dissections.
- Dural closures should be watertight. Avoid active suction drains close to or communicating with the site of dural repair. Obliterate dead spaces with reconstruction and perform a watertight closure of the skin.
- If a tracheostomy is performed, avoid communication between the tracheostomy and the neck dissection. When drainage of the neck wound is needed, the potential for CSF leak into the neck is high. A pathway for CSF flow from the neck to the tracheostomy wound would carry a great potential for contamination and serious infection.

POSTOPERATIVE PERIOD

Routine Postoperative Management

- If the intracranial cavity was opened, the patient should be admitted to the neurointensive care unit, frequent neurologic monitoring should be ordered and a CT scan should be performed in the morning.
- Monitor pulmonary and cardiovascular status, and record fluid input and output.
- Keep the head of the bed elevated, use stool softeners, and ask the patient to avoid straining.
- Advance the diet as tolerated.
- Prescribe perioperative antibiotics for 24 hours.
- The patient must wear compression stockings.
- Continue the mastoid dressing for 3 to 5 days; remove and replace to check the wound on days 1 to 2.
- Remove any skin bolsters at day 5.
- If a flap was used, avoid pressure dressings and keep the flap exposed so the viability can be readily monitored.
- Monitor for CSF leak.
- Monitor for venous congestion of any remaining pinna and microvascular flaps.
- Prevent exposure keratitis and corneal ulceration with routine eye care for patients with facial paralysis. Apply saline eye drops every 1 to 2 hours during the day and ophthalmic lubricant at night. At night, apply lubricant and tape the eye closed with a Steri-Strip or thin paper tape. Taping may also be helpful to reduce ectropion and enhance eye blink during the day by fashioning a sling along the lower eyelid and a tape "weight" along the upper eye lid. A plastic eye shield (moisture chamber) is also useful. If facial nerve function is expected to return within a few months, as occurs after facial nerve transposition, the patient usually requires no further treatment. If recovery from facial nerve dysfunction is expected to take longer or if the dysfunction will be permanent, a gold or platinum weight is placed in the upper eyelid and a lateral tarsal strip is performed in a separate setting.
- If the lower cranial nerves were functional preoperatively and required transection intraoperatively, perform a tracheostomy and consider a type I thyroplasty with or without vocal cord medialization.
- Patients with more extensive dissections may benefit from physical therapy to initiate gait training and vestibular therapy.
- Radiation treatment is begun approximately 6 weeks after surgery, or when adequate wound healing has occurred.
- Postoperative surveillance with imaging is performed at 3 months and every 6 months thereafter.
- A prosthetic ear may be applied either with adhesive or by osseointegrated implants. A prosthesis is pursued after adequate time for radiation treatments and wound healing.
- Hearing loss may be alleviated with a bone conduction device or CROS hearing aid if the pinna is present.

Acute Postoperative Complications

- Aspiration pneumonia
- Meningitis
- CSF leak
  - If the leakage occurs through an incision, the area of dehiscence is reinforced with horizontal mattress sutures (sterile technique) and a pressure dressing.
  - CSF leaks that persist for more than 24 hours should be managed with a lumbar drain.
  - The use of antibiotics prophylactically in the presence of a CSF leak is controversial.
  - If the CSF leak persists after 3 to 5 days of lumbar drainage, exploration is indicated.
- Acute intracranial hemorrhage
  - The signs of acute intracranial hemorrhage are altered sensorium or loss of consciousness. Focal neurologic deficits, including fixed and dilated pupils, bradycardia, and hypertension can also occur.
  - A CT scan without contrast enhancement is performed. The patient's condition is temporized by the administration of mannitol, 0.25 to 0.5 g/kg intravenously, and hyperventilation if intubated. If the patient's vital signs are unstable or there is evidence of brain stem herniation, emergent exploration is warranted. A ventriculostomy can be performed to rapidly decompress the increased intracranial pressure. The craniectomy or craniotomy is reopened, and the blood clot is evacuated. The source of bleeding is sought and controlled.
- Wound complications
  - Careful clinical evaluation (pinprick test) and/or routine Doppler ultrasound is performed to detect any impending compromise of pedicled and free flaps. If vascular compromise does occur, the patient is taken back to the operating room for an alternative flap or revision of the vascular anastomosis.
  - Wound dehiscence occurs most frequently at the distal edge of a pedicled flap.

Alternative Management Plan

1. Postoperative radiotherapy is indicated for T3 and T4 lesions and should be strongly considered for a T2 lesion. Surgery alone is curative for T1 lesions, assuming adequate margins are obtained. Radiotherapy is also considered for aggressive pathologic features, such as perineural invasion, close margins, nodal involvement, and extracapsular spread.[3]
2. Radiotherapy alone offers a poor survival rate.
3. The role of preoperative or postoperative chemotherapy is unclear, but has been shown to have some promise for advanced disease.[4]

DISCUSSION

Evidence-Based Medicine Question

Unanswered questions plague the clarification of the optimal management of tumors in the region of the temporal bone. The role of elective neck dissection, parotidectomy, primary radiotherapy, and chemotherapy need further clarification. The outer limits of surgically resectable cancer and the role of total temporal bone resection and piecemeal resection for advanced or recurrent cancer, especially with involvement of the dura or brain, remain controversial.[3,5] Emerging reports of the use of chemotherapy are promising, but yet unproven.[4] The applicability of any of the treatment protocols and prognostic indicators to control secondary spread to the ear canal, mastoid, and temporal bone is unclear.[6] Addressing these controversies with high quality evidence remains a significant challenge. The world literature is replete with case series and a few systematic reviews, most of which are marred by small samples, heterogeneity of the histology, clinical settings, non-standardized staging and treatment protocols, and inadequate clinical details. Meta-analysis and systematic reviews are difficult to produce due to the rarity of the disease, the variability in surgical approaches and definitions, the challenges in determining the extent of the disease, the variances in reporting clinical details, and the lack of an AJCC-endorsed internationally accepted standardized staging system.

Editorial Comment

Dr. Moody has comprehensively organized a complex topic into the contemporaneous format of this textbook. This chapter covers the diagnosis, evaluation, staging, treatment options, and surgical procedures necessary to manage this potentially aggressive disease. As with most diagnoses of cancer, early recognition and intervention offers the best opportunity for cure. This relatively rare diagnosis makes it difficult to devise treatment strategies or protocols for trials among oncology teams.

The Department of Otolaryngology at the University of Pittsburgh created a recognized staging system for carcinoma of the temporal bone. Others are also available. It is important to have a unifying staging system in order to provide meaningful comparisons of outcomes across contributing institutions.

Much planning is needed in surgically addressing this disease. The participation of other disciplines is needed to optimize the surgical resection and achieve safe, functional, and cosmetically appealing reconstruction. Clinical and radiologic long-term monitoring is mandatory for tumor surveillance. Along with MR imaging, PET scanning offers another means of assessing the resected area deep to flap reconstruction.

Barry Hirsch

Access the review questions online at http://www.expertconsult.com

REFERENCES

1. Leonetti JP, Smith PG, Kletzker GR, et al. Invasion patterns of advanced temporal bone malignancies. Am J Otol 1996;17(3):438–442.
2. Moody SA, Hirsch BE, Myers EN. Squamous cell carcinoma of the external auditory canal: An evaluation of a staging system. Am J Otol 2000;21(4):582–588.
3. Zanoletti E, Lovato A, Stritoni P, et al. A critical look at persistent problems in the diagnosis, staging and treatment of temporal bone carcinoma. Cancer Treat Rev 2015;41(10):821–826.
4. Takenaka Y, Cho H, Nakahara S, et al. Chemoradiation therapy for squamous cell carcinoma of the external auditory canal: A meta-analysis. Head Neck 2015;37(7):1073–1080.
5. Moffat DA, Wagstaff SA, Hardy DG. The outcome of radical surgery and postoperative radiotherapy for squamous carcinoma of the temporal bone. Laryngoscope 2005;115(2):341–347.
6. Essig GF, Kitipornchai L, Adams F, et al. Lateral temporal bone resection in advanced cutaneous squamous cell carcinoma: Report of 35 patients. J Laryngol Otol 2013;74(1):54–59.

REVIEW QUESTIONS

1. Based on the Pittsburgh staging system for cancers of the temporal bone, how would a cancer that erodes the bony canal wall, but does not involve the middle ear, soft tissue, or facial paralysis be staged?
   a. T1
   b. T2
   c. T3
   d. T4

2. Radiotherapy is indicated for which cancers?
   a. Cancer staged T2, 3, or 4
   b. Cancer with perineural invasion
   c. Cancer with positive margins
   d. All of the above

3. Routine preoperative evaluation for cancer of the ear canal should include:
   a. High resolution CT of the temporal bone
   b. MRI of the skull base and neck with contrast
   c. PET scan
   d. a and b

4. Treatment of stage T1N0 cancer of the external auditory canal requires:
   a. Lateral temporal bone resection alone
   b. Lateral temporal bone resection, parotidectomy, and neck dissection
   c. Postoperative radiotherapy
   d. Sleeve resection

5. The most important prognostic indicator for long-term survival is:
   a. Age
   b. Positive margins
   c. Lymph node metastasis
   d. Postoperative radiotherapy

142 Glomus Tumors

C. Y. Joseph Chang

INTRODUCTION

Paraganglioma or glomus tumor is a tumor of the neuroendocrine system derived from neural crest cells and chemoreceptor cells. Although most tumors are sporadic, familial glomus tumors may occur in 20% of patients with glomus tumors. Some of the tumors are multicentric and bilateral at the time of presentation, which typically occur at an earlier age in successive generations in families harboring genetic mutations. Glomus tumors are slow-growing, invasive, highly vascular neoplasms that are in proximity to the important temporal bone structures that can include the facial nerve, internal carotid artery (ICA), and lower cranial nerves. Glomus tympanicum tumors typically arise in the middle ear space and may involve the middle ear with or without extension to the hypotympanum, attic, and mastoid, and rarely, the ICA and petrous apex or intracranial areas. These tumors typically do not involve the lower cranial nerves, so the cranial nerve morbidity from treatments is usually limited to the facial nerve and hearing/vestibular apparatus. In contrast, glomus jugulare tumors arise in the jugular foramen and typically involve the superior and lateral wall of the jugular bulb. In addition to the cranial nerves at risk for glomus tympanicum tumors, the lower cranial nerves, IX, X, XI, and sometimes XII, may be involved and place the patient at significant risk for dysphagia, dysphonia, and shoulder dysfunction that may be extremely debilitating.

Two classification systems have been offered for nomenclature and staging. Fisch described and modified a classification system based on the size and extent of the tumor (Box 142.1). The other classification system was devised by Glasscock and Jackson (Box 142.2). Both classifications address the pertinent issues of tumor size, petrous apex or carotid artery involvement, and intracranial extension. This provides critical information necessary to design an operative approach and plan.

Treatment options for glomus tumors of the temporal bone include observation with serial scanning to monitor for growth, microsurgical excision, and radiation therapy (XRT). For advanced tumors that approximate or involve the lower cranial nerves, the standard practice in the past consisted of aggressive surgical removal with possible adjuvant radiation in some cases. Complete surgical resection of these tumors minimizes the chance for recurrence but may result in significant morbidity. This treatment may incur lower cranial dysfunction, requiring the need for a tracheotomy, nasogastric tube placement, or percutaneous gastrostomy feeding tube, along with complications of aspiration, pneumonia, malnutrition, and weakness of the shoulder and tongue. In addition, sacrifice of the ICA is avoided as much as possible to prevent the morbidity of ischemic cerebral damage.

Radiation therapy does not eliminate the tumor but is intended to halt tumor progression. Proponents for surgery have suggested that radiation is indicated for palliation, following incomplete tumor excision or for patients who are medically infirm or elderly. However, there is strong evidence indicating that radiotherapy could also be considered the definitive treatment strategy for skull base glomus tumors. Glomus jugulare tumors have traditionally been treated by fractionated XRT. Newer techniques using a frame-based linear accelerator, gamma radiation from cobalt delivered through the Gamma Knife, or photon beam from a robot-mounted mini-linear accelerator such as the CyberKnife are available for single or multiple focused treatments (fractions), providing submillimeter accuracy in treatment delivery.

Based on the apparent success of varied radiation procedures, the management recommendations have evolved recently to treatment options that preserve function as much as possible. This approach may entail observation, primary radiation, or subtotal function preserving tumor resection followed by observation or radiation of the residual tumor.

KEY OPERATIVE LEARNING POINTS

- Surgical treatments for glomus tympanicum tumors are typically limited to tympanoplasty and mastoidectomy dissections.
- Surgical treatments for glomus jugulare tumors are more extensive and, in addition to those noted previously, include various degrees of infratemporal fossa dissection, exposure of the skull base from the upper neck, possible petrous apex, and intracranial exposures.
- If the lower cranial nerves of the jugular foramen are to be preserved, the medial wall of the jugular bulb must be left intact, and care should be taken not to compress the contents of the pars nervosa.
- For jugulare tumors, the facial nerve may be managed by the fallopian bridge technique in most cases and facial nerve transposition for very extensive tumors.
- The prevention of cerebrospinal fluid (CSF) leak in cases of dural penetration can be managed with various techniques, from adipose tissue graft packing of a more isolated posterior temporal bone CSF leak with preservation of the hearing mechanism to eustachian tube (ET) and external auditory canal (EAC) closure and possible use of a temporalis muscle rotation flap.

PREOPERATIVE PERIOD

History

1. History of present illness
   a. Pulsatile tinnitus
   b. Hearing loss
   c. Dizziness: Vertigo and/or imbalance
   d. Otalgia
   e. Facial weakness or twitching
   f. Dysphagia
   g. Hoarseness
   h. Shoulder weakness and/or pain
   i. Dysarthria, tongue dysfunction
   j. Labile hypertension, tachycardia, headache, perspiration, pallor, and nausea—may indicate a significant catecholamine release from the tumor requiring medical management
2. Past medical history
   a. Prior treatment with surgery or radiation
   b. Medical illness such as coronary artery disease, lung disease, bleeding disorders
   c. Family history of vascular or endocrine tumors

BOX 142.1 Glomus Tumor Classification: Fisch

Type	Description
A	Tumor limited to middle ear cleft (promontory)
B	Tumor confined to middle ear, hypotympanum, and mastoid
C_1	Tumor eroding jugular bulb and carotid foramen; not invading carotid artery
C_2	Tumor involving infralabyrinthine and apical temporal bone; erosion of vertical carotid artery
C_3	Tumor involving infralabyrinthine and apical temporal bone; erosion of horizontal carotid artery
C_4	Tumor involving infralabyrinthine and apical temporal bone; tumor grows to foramen lacerum and cavernous sinus
D_1	Intracranial tumor <2 cm
D_2	Intracranial tumor >2 cm; e, extradural; i, intradural
Di_3	Unresectable intracranial extension

Data from Fisch U: Infratemporal fossa approach for glomus tumors of the temporal bone. Ann Otol Rhinol Laryngol 91:474-479, 1982, and Fisch U, Mattox D: Classification of glomus temporal tumors. In Fisch U, Mattox D (eds): Microsurgery of the Skull Base. Stuttgart and New York: Georg Thieme; 1988, pp 149-153.

BOX 142.2 Glomus Tumor Classification: Glasscock-Jackson

Type	Description
GLOMUS TYMPANICUM	
I	Small mass limited to promontory
II	Tumor completely filling middle ear space
III	Tumor filling middle ear and extending into mastoid
IV	Tumor filling middle ear, extending into mastoid or through tympanic membrane to fill external auditory canal; may extend anterior to carotid
GLOMUS JUGULARE	
I	Small tumor involving jugular bulb, middle ear, and mastoid
II	Tumor extending under internal auditory canal; may have intracranial extension
III	Tumor extending into petrous apex; may have intracranial extension
IV	Tumor extending beyond petrous apex into clivus or infratemporal fossa; may have intracranial extension

Data from Jackson CG, Glasscock ME, Harris PF: Glomus tumors: diagnosis, classification, and management of large lesions. Arch Otolaryngol 108:401-410, 1982.

Physical Examination

1. Otologic evaluation: Ear microscopy or endoscopy
   a. Vascular middle ear lesion
   b. Tympanic membrane involvement
   c. Extension into the ear canal
   d. Brown's sign: Tumor blanching with ear insufflation
   e. Tuning fork
2. Balance evaluation
   a. Gait
   b. Tandem gait
   c. Romberg test
3. Cranial nerve evaluation
   a. Facial nerve
   b. Cranial nerves IX, X, XI, XII
4. Neck: Mass in the upper neck
5. Audiologic evaluation
   a. Pure tones
   b. Speech discrimination scores
   c. Tympanogram

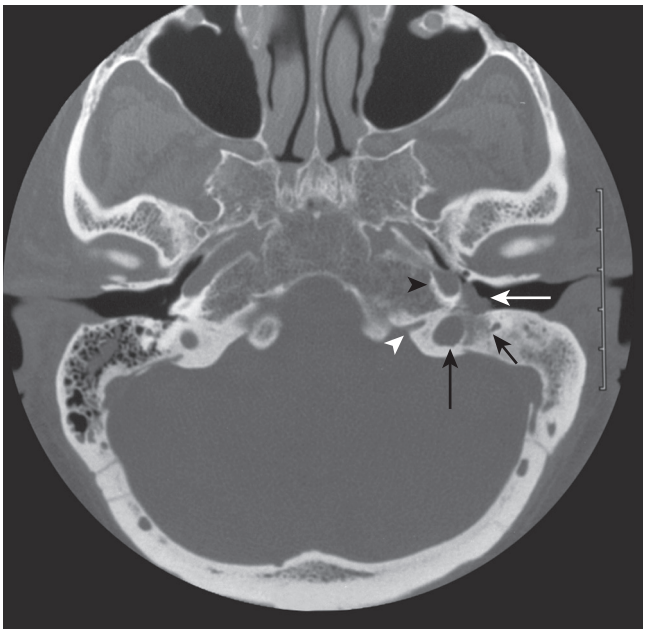

Fig. 142.1. Bone-windowed CT scan demonstrating the left middle ear and a hypotympanic mass *(white arrow)* infiltrating and eroding bone between the carotid artery *(black arrowhead)*, the jugular vein *(large black arrow)*, and the medial aspect of the facial nerve *(small black arrow)*. The pars nervosa is not affected *(white arrowhead)*.

Imaging

1. Computed tomography (CT) of the temporal bone with 0.6 mm axial and coronal cuts (Fig. 142.1)
   a. Opacification or soft tissue masses of the middle ear, attic, or mastoid
   b. Bony erosion along the jugular bulb and jugular foramen
   c. Involvement of the ICA
   d. Erosion of bone along the posterior petrous bone that could indicate extension of the tumor into the posterior fossa
   e. Bony erosion into the otic capsule
2. Magnetic resonance imaging (MRI) with gadolinium of the brain, internal auditory canal, and neck
   a. Enhancing lesion involving the middle ear, attic, mastoid, hypotympanum, jugular foramen, petrous apex, internal carotid artery, or intracranial areas
   b. Flow void within the sigmoid sinus, jugular bulb, and jugular vein
   c. Identification of any synchronous tumors of the head and neck or skull base

3. Angiography: Four-vessel cerebral arteriogram may be done during preoperative tumor embolization if embolization is planned.
   a. Tumor blush
   b. Identification of feeder vessels
   c. Identification of any synchronous vascular tumors of the head and neck or skull base
4. Magnetic resonance angiography (MRA) or CT angiography (CTA) may be done as a noninvasive alternative to angiography, although it is not as sensitive as formal angiography.

Indications

1. The main goal of intervention is to prevent and/or halt the progression of bothersome symptoms and to avoid incurring additional symptoms.
   a. Pulsatile tinnitus
   b. Hearing loss
   c. Dizziness
   d. Dysphagia
   e. Hoarseness
   f. Shoulder dysfunction
   g. Symptoms related to catecholamine release
2. Most symptomatic glomus tympanicum tumors can be surgically removed with limited risk of significant morbidity.
3. Many glomus jugulare tumors can be removed completely with mild risk of increased morbidity, unless there is involvement of the jugular foramen pars nervosa, significant ICA involvement, or intracranial extension.
4. Tumors that involve structures that will incur significant patient morbidity associated with total resection may be considered for alternative treatments.
   a. Observation with serial MRI
   b. Subtotal resection (STR), leaving tumors in sensitive areas, followed by options of observation or radiation
   c. Primary radiation options
5. Most small to medium tumors can also be considered for observation with serial MRI versus primary radiation.

Contraindications

1. Advanced age and medical comorbidities with increased risk for general anesthesia may make any surgical option too risky for some patients.
2. Patients with pre-existing dysphagia related to prior cerebrospinal accident (CVA) or other diseases not related to the tumor may not tolerate treatment related injury to the lower cranial nerves.

Preoperative Preparation

1. Medical treatment of any tumor-associated elevation of circulating catecholamines—alpha and beta blockade
2. Angiographic embolization of tumor, in most cases of glomus jugulare tumors, typically 1 to 2 days prior to surgery
3. If there is significant involvement of the ICA that may be at risk for vascular injury, the patient typically undergoes balloon test occlusion with xenon perfusion to see if sacrifice of the carotid will be tolerated. Alternatively, a protective ICA stent may be placed.[1]
4. Type and cross 2 to 4 units of red blood cells when operating on glomus jugulare tumors.

OPERATIVE PERIOD

Anesthesia

General

Positioning

Supine: The patient's head is turned away from the surgeon.

Perioperative Antibiotic Prophylaxis

- First-generation cephalosporin. The antibiotic regimen is the standard protocol for prophylactic antibiotic coverage. Administer clindamycin if patient is allergic to penicillin.

Monitoring

- Facial nerve monitoring
- Cranial nerve IX to XII monitoring for extensive skull base glomus jugulare tumor
- Somatosensory monitoring for potential carotid artery involvement

Instruments and Equipment to Have Available

1. Operating microscope
2. Standard ear surgery set
3. Otologic drill
4. Standard neurosurgical set, including retractors, for intracranial extension
5. Variety of hemostatic agents (Surgicel, Avitene, Surgifoam)

Key Anatomic Landmarks

1. Facial nerve along the vertical and horizontal segments, identified by the oval window niche, horizontal semicircular canal, and stylomastoid foramen
2. Lower cranial nerves as they exit the jugular foramen. Cranial nerve IX remains medial to the jugular vein. Cranial nerve X tracks between the jugular vein and carotid artery. Cranial nerve XI crosses lateral to the jugular vein as it extends to the posterior neck. Cranial nerve XII tracks lateral to the carotid artery as it extends anteriorly deep to the anterior belly of the digastric muscle.
3. The petrous ICA lies medial to the eustachian tube, foramen ovale, and foramen spinosum.

Prerequisite Skills

1. Tympanoplasty with mastoidectomy; facial recess
2. Infratemporal fossa skull base dissection
3. Muscle rotation flaps for reconstruction

Operative Risks

1. Inability to control hemorrhage
2. Injury to the facial nerve
3. Injury to the lower cranial nerves
4. Cochleovestibular damage
5. CSF leak
6. ICA injury
7. Arterial or venous CVA

Surgical Technique

Glomus Tympanicum Tumors

The surgical approach for glomus tympanicum tumors is dictated by the size of the tumor. Small tumors limited to the mesotympanum and hypotympanum without involvement of the jugular bulb are removed through a transcanal approach. This is predicated on favorable anatomy of the bony ear canal.

Larger lesions usually require a postauricular approach to provide greater exposure, including possible mastoidectomy and opening of the facial recess. A canaloplasty is also necessary when the inferior annulus is not adequately visualized through the external auditory meatus due to tortuosity of the ear canal or significant tumor extension into the hypotympanum.

- Adequate injection of the ear canal and postauricular sulcus with 1% lidocaine with 1:100,000 epinephrine
- For a postauricular approach, a lateral and posterior ear canal skin flap is created with superior, inferior, and connecting incisions halfway into the bony ear canal.
- The postauricular incision is made 3 mm posterior to the sulcus, and the incision is connected with the ear canal incision. The meatal flap is retracted with a half-inch Penrose drain, and the pinna is reflected anteriorly with a Weitlaner retractor.
- The previously made vertical meatal flap incision defines the lateral margin of the tympanomeatal flap.
- The tympanomeatal flap is created after the inferior to anterior canal wall incision is made. The anterior incision is carried further superiorly, depending on the extent of tympanic annulus elevation needed.
- The middle ear is entered medial to the fibrous annulus, which is elevated as far anteriorly as needed to access the entire tumor. Care is taken not to incise the tumor in order to prevent hemorrhage (Fig. 142.2).
- For small tumors of the middle ear, the vascular pedicle is typically located on the promontory. The tumor can be gently manipulated until the pedicle is visualized. The pedicle may be transected, and the hemorrhage may be controlled with the application of bone wax or Surgicel.
- Microbipolar cautery may also be used, but due to the risk of injury to the cochlea, excessive use of bipolar cautery should be avoided.
- For larger tumors involving the hypotympanum and protympanum, there may also be vascular pedicles in both areas that cannot be accessed without debulking the tumor.
- The tumor may need to be debulked first after shrinking the tumor with the bipolar cautery. Once the vascular pedicles are found and transected, the hemorrhage may be controlled with the application of bone wax or Surgicel. Cotton pledgets soaked in epinephrine (adrenalin) also provide hemostasis.
- For tumors extending to the epitympanum or mastoid, a canal wall up (CWU) mastoidectomy may also be needed. This exposure is typical for that required for removal of cholesteatoma (see Chapter 134).
- If feasible, the middle ear, hypotympanic, and protympanic areas of the tumor should be removed with control of the tumor vascular supply first to reduce the hemorrhage related to dissection of the remaining tumor. Bipolar cautery may still be needed for the attic and mastoid tumor removal.
- The ossicular chain may require disarticulation with removal of the incus and malleus head for complete removal of the tumor. In this case, the ossicular chain reconstruction may be performed after tumor removal (see Chapter 132). In some cases, only a temporary separation of the incudostapedial joint is necessary, with replacement of the lenticular process of the incus to the stapes capitulum after removal of the tumor.
- If there is tumor infiltration to the stapes obturator foramen and footplate, complete tumor removal may be difficult with mechanical techniques. The Diode or argon laser with 0.2-mm fiberoptic probe may be used at a setting of 1 to 2 watts, 0.2-second single shot duration to vaporize the tumor in this area, taking care not to injure the stapes footplate of horizontal facial nerve. The CO_2 laser may also be used, but it typically requires a higher power setting of 2 to 5 watts for optimal results.
- In rare cases, the tumor has invaded the area inferior to the hypotympanum toward the jugular bulb. In tympanicum tumors, there is typically no tumor invasion into the wall of the jugular bulb, so opening of the sigmoid sinus will not be needed. The infratympanic facial recess approach is extended (Fig. 142.3). It may also be necessary to create a "fallopian bridge" by skeletonizing the distal vertical portion of the facial nerve in order to remove the entire tumor (see Fig. 142.3).
- If a tympanic membrane (TM) perforation has been made during tumor removal, it can be repaired using the standard medial graft technique (see Chapter 131).
- The middle ear is packed with Gelfoam or Surgicel, depending on the degree of hemostasis needed. The ear canal is packed with Gelfoam.
- The postauricular wound is closed in layers.
- A mastoid dressing is applied if a postauricular approach is used.

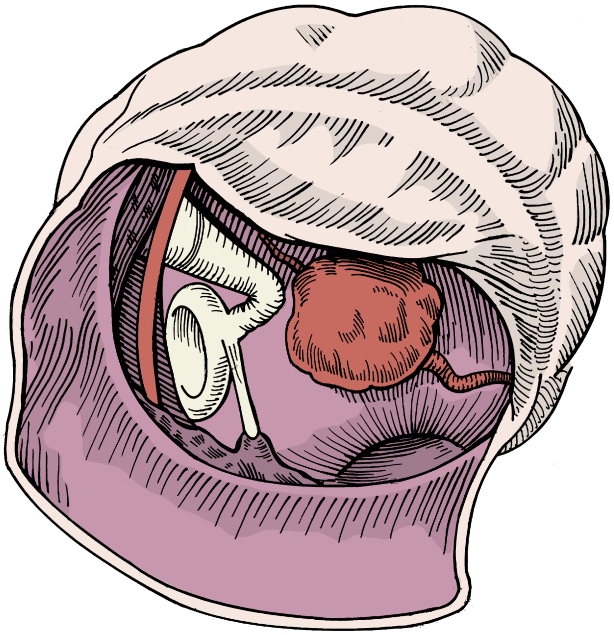

Fig. 142.2. Transtympanic approach to a glomus tumor isolated within the middle ear.

Glomus Jugulare Tumors

Most glomus jugulare tumors involve the middle ear, jugular bulb, and hypotympanic air cells without intracranial involvement. The tumor may erode bone near the vertical carotid artery and/or jugular foramen pars nervosa (Fisch type C_1 and C_2, Glasscock-Jackson jugulare type I and 2).

- A postauricular mastoidectomy incision located 3 cm posterior to the pinna extends over the lower border of the mastoid tip, through an upper neck skin crease, toward the greater cornu of the hyoid bone. The incision in the neck is carried through the subcutaneous tissue and platysma muscle, with preservation of the greater auricular nerve (Fig. 142.4).
- If the there is no cervical extension of tumor, the main reason for the cervical incision is to obtain inferior control of the jugular vein. In this case, the cervical dissection can be kept separate from the postauricular dissection to minimize

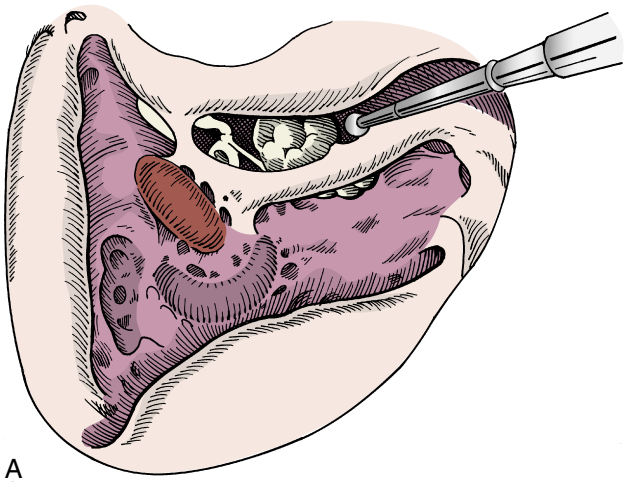

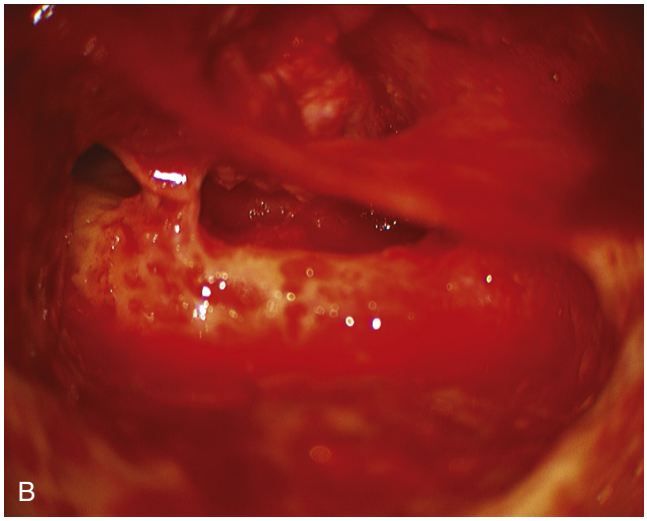

Fig. 142.3. A, Access to the glomus tumor in the middle ear and hypotympanic space is achieved by extending the facial recess approach. Opening the retrofacial infralabyrinthine air cells provides exposure of the posterior margins of the tumor. **B,** Surgical photo of extended facial recess approach providing access to the hypotympanum.

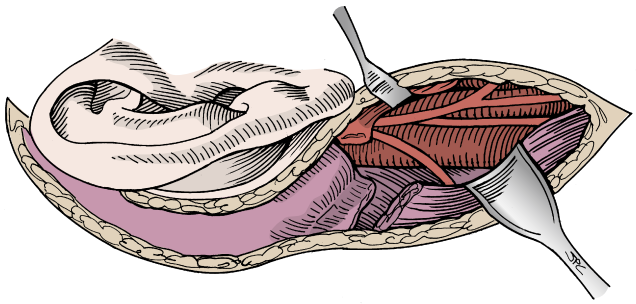

Fig. 142.4. The postauricular incision is carried into the neck. The carotid artery, jugular vein, and lower cranial nerves are isolated. The sternocleidomastoid and digastric muscles are retracted.

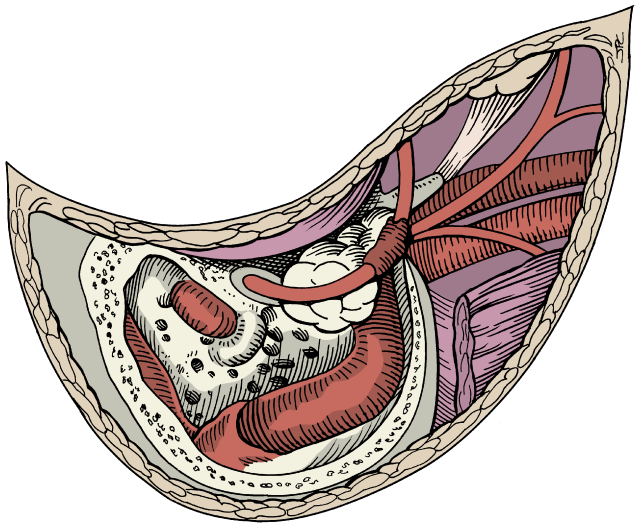

Fig. 142.5. Canal wall down transmastoid tumor dissection isolating the sigmoid sinus, vertical facial nerve along the extended facial recess, digastric ridge, neck vessels, and lower cranial nerves.

the risk of CSF leak into the neck if there is dural penetration related to tumor removal.

- The temporal bone dissection described for the transmastoid glomus tympanicum tumor is performed.
- The facial recess is opened, and the chorda tympanic nerve is sacrificed to form an extended facial recess approach. Retrofacial and infralabyrinthine air cells and bone are removed to the stylomastoid foramen. The facial nerve is skeletonized, leaving eggshell-thin coverage, creating a "fallopian bridge" (see Fig. 142.3).
- The digastric ridge is delineated within the mastoid cavity. Dissection is continued anteriorly toward the stylomastoid foramen. The mastoid tip may have to be removed. It is sometimes necessary to expose the posterior fossa dura both posterior and anterior to the sigmoid sinus. The sigmoid sinus is also decompressed. Some bone is left over the proximal sigmoid sinus near the sinodural angle (above Donaldson's line). The sigmoid sinus is carefully dissected free from the overlying roof of bone. This exposure provides access to extraluminal packing or suture ligation of the sinus. Dissection is continued along the sigmoid sinus toward the jugular bulb. All bone must be removed from this area (Fig 142.5).
- Prior to opening the sigmoid sinus to expose the intraluminal portion of the tumor, proximal and distal control of the sigmoid sinus must be achieved. The superior portion of the sigmoid sinus may be occluded by either extraluminal packing or ligation. Extraluminal occlusion is performed with oxidized cellulose that is packed under a retained shelf of bone covering the proximal sigmoid sinus. If this is not successful or feasible, ligation of the sinus is performed by making small openings in the dura anterior and posterior to the sigmoid sinus. An aneurysm needle is passed from posterior to anterior deep to the sigmoid sinus. The needle is blindly passed medial to, but hugging, the sigmoid sinus, avoiding injury to the intracranial contents (cerebellum). A long 2-0 silk ligature is passed through the aneurysm needle up to its midlength, and the aneurysm needle is withdrawn. The suture is then cut in half, so as to leave two separate ligatures (Fig. 142.6). A small piece of muscle is harvested and placed over the sigmoid sinus, and the first suture is tied and secured. The second suture is similarly tied, thus providing double ligation and occlusion of the proximal sigmoid sinus.
- The jugular vein in the neck is then doubly ligated. If the tumor extends into the cervical portion of the jugular vein, the proximal stump of the jugular vein in the neck

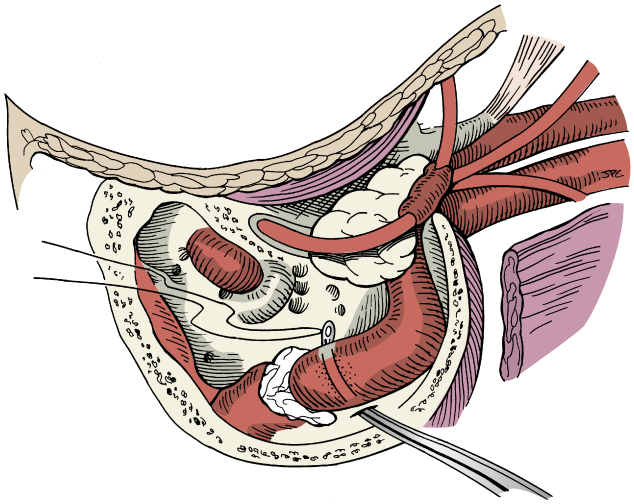

Fig. 142.6. The extended facial recess approach exposes the tumor in the hypotympanum. The vertical portion of the facial nerve remains in place. The proximal sigmoid sinus can be isolated by extraluminal packing or suture ligation.

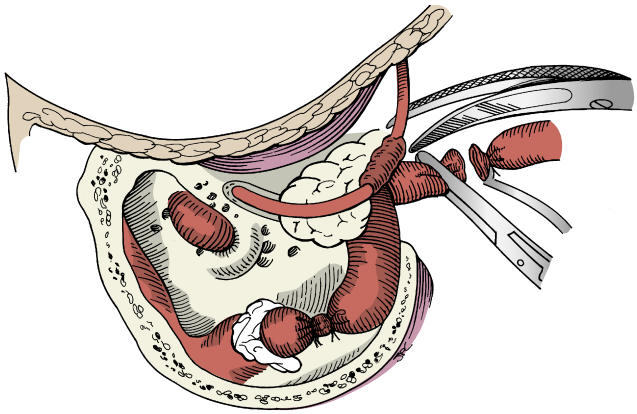

Fig. 142.7. Proximal control of the sigmoid sinus is achieved. Surgicel packing can also be used to occlude the proximal sigmoid sinus. The jugular vein is divided, and the proximal segment is dissected into the jugular fossa. The anterior plane of dissection is along the carotid artery, which is shown in Fig. 142.6.

is dissected superiorly toward the jugular bulb and fossa (Fig. 142.7). Care is taken to preserve the spinal accessory nerve. It is usually necessary to pass the proximal stump of the jugular vein medial to the spinal accessory nerve in order to facilitate the superior dissection. If the tumor does not extend into the cervical area, the tied off jugular vein may be left in situ. The distal extratemporal ICA should be in direct view as the jugular vein is dissected toward the jugular bulb. The styloid process and its muscular attachments may need to be removed in order to gain access to the skull base.

- The tumor may now be removed in a piecemeal fashion to the remnant around the sigmoid sinus and jugular bulb. In addition to bipolar cautery, small cotton balls or cottonoid patties soaked with 1:1000 epinephrine may be used to compress sites of bleeding during removal of the tumor.
- The sigmoid sinus is opened distal to the ligatures in order to inspect the intraluminal contents. Usually, the medial wall of the sigmoid sinus is not invaded by a tumor unless there is intracranial extension. The inferior aspect of the sigmoid sinus is incised in a longitudinal direction toward the jugular bulb. The tumor is sequentially isolated from a posterior-to-anterior direction, dissecting the superior, lateral, and inferior walls of the sigmoid sinus from the medial wall. Bipolar coagulation is usually needed to obtain hemostasis and shrink the tumor. The lateral and superior aspect of the jugular bulb are dissected toward the superior extent of the tumor.
- The tumor often occludes the jugular bulb. However, once the tumor is removed from this area, brisk bleeding may be encountered from the multiple orifices of the inferior petrosal sinus and condylar vein. The medial jugular bulb is packed with oxidized cellulose. This dissection is performed medial (deep) to the vertical portion of facial nerve and stylomastoid area. Care must be taken to avoid trauma or pressure to the medial (deep) surface of the facial nerve. The tumor often remains in the hypotympanum and middle ear. This is removed by working both medial and lateral to the facial nerve.
- Dissection medial to the medial wall of the jugular bulb will entail dissection of the lower cranial nerves. The recent trend is not to remove this portion of the tumor unless absolutely necessary, in order to reduce the risk of postoperative dysphagia and other lower cranial nerve morbidities. The remaining tumor may be observed or treated with radiation.
- Certain intraoperative findings may necessitate a canal-wall-down procedure. The first is the need for increased exposure of tumor invading the carotid artery. Also, limited space in the retrofacial and infralabyrinthine areas may require transposition of the facial nerve in order to provide adequate exposure of the tumor. Reconstruction of the tympanic membrane and ossicular chain can still be performed as needed.
- Unless the medial wall of the jugular bulb, sigmoid sinus, or posterior fossa dura is penetrated, CSF is not encountered. The dead space created by the removal of bone and tumor may be partially obliterated with abdominal adipose tissue if CSF leak is a concern. Otherwise, the defect may be left aerated. Packing of the ear canal is identical to that described previously. A Penrose drain is placed deep to the cervical skin flaps if there has been a significant neck dissection. A Hemovac drain can also be used, but suction is turned off after 1 day, as it will tend to suck air through the eustachian tube. The postauricular wound is closed in three layers, reapproximating the musculoperiosteum, subcutaneous tissue, and skin.

Large Glomus Jugulare Tumors (Fisch Type C_2 or Greater)

Glomus tumors that invade the petrous apex, horizontal portion of the ICA, and/or cavernous sinus require a postauricular infratemporal exposure (see Chapter 121) in addition to the temporal bone portion of the dissection described in the previous section. Typically, the ear canal will need to be removed and the meatal opening closed. If there has been a significant dural resection, eustachian tube closure and abdominal fat obliteration of the skull base defect will be needed (see Chapter 144 and Chapter 121).

The vertical segment of the facial nerve may interfere with access to large tumors filling the jugular fossa and invading the carotid artery. Facial nerve transposition is sometimes necessary to achieve optimal exposure.

- The facial nerve is decompressed from the geniculate ganglion to the stylomastoid foramen with cutting and then

diamond burrs. Favorable anatomy may permit more limited mobilization of the facial nerve from its second genu.

- Precise dissection and isolation of the facial nerve in the stylomastoid foramen is difficult. The transposition is facilitated by cutting the remaining tendon and posterior belly of the digastric muscle within the mastoid proximal to the stylomastoid foramen.
- The muscle, along with the contents of the stylomastoid foramen, is elevated from the underlying bone in a posterior-to-anterior direction. The facial nerve is then dissected away from the fallopian canal. The cuff of fibrous tissue surrounding the facial nerve is sutured anteriorly to the periparotid fascia, providing retraction of the vertical and horizontal facial nerve (Fig. 142.8).

Common Errors in Technique

1. Inadequate exposure of the infratemporal fossa based on incomplete surgical planning may lead to less than expected degree of tumor removal.
2. The surgeon must be prepared to control a CSF leak if the dura is entered. Not anticipating this event may lead to serious wound and infectious complications.
3. Overaggressive dissection of the jugular foramen pars nervosa will lead to significant dysfunction of the lower cranial nerves postoperatively.
4. Inadequate planning for ICA management may result in catastrophic hemorrhage or cerebrovascular accident (CVA).

POSTOPERATIVE PERIOD

Postoperative Management

1. Check hematocrit if there was significant blood loss.
2. Monitor for CSF leak—rhinorrhea or otorrhea or wound leak
3. Evaluate lower cranial nerve function.
   a. Dysphagia
   b. Hoarseness/aspiration: Vocal cord function
   c. Dysfunction of the shoulder
   d. Dysfunction of the tongue

Complications

1. CSF leak (see Chapter 144 and Chapter 124)
   a. Lumbar drainage for 3 to 5 days
   b. Pressure mastoid dressing and pressure dressing to the neck as tolerated
   c. Surgical repair if needed
2. Dysphagia and hoarseness (see Chapter 46)
   a. Standard barium swallow study versus flexible endoscopic evaluation of swallowing with sensory testing (FEEST)
   b. Appropriate diet based on degree of dysphagia
   c. Nasogastric or gastric tube while non per oris
   d. Vocal cord medialization laryngoplasty with or without cricopharyngeal myotomy as needed (see Chapter 5)
3. Shoulder dysfunction
   a. Physical therapy as needed

Alternative Management Plan

1. Observation with serial imaging
2. Radiation therapy
   a. Stereotactic radiosurgery (SRS, single fraction)
   b. Stereotactic radiotherapy (multiple fractions)
   c. External beam radiation
   d. Stereotactic radiosurgery or radiotherapy may provide effective control of tumor when given as the primary modality of treatment, following recurrence of tumor, or as part of the planned strategy for subtotal resection.

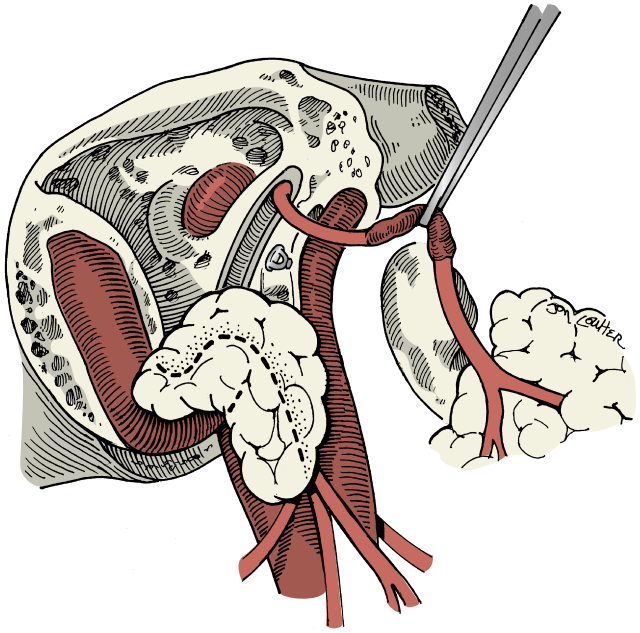

Fig. 142.8. The facial nerve has been mobilized anteriorly, exposing the tumor in the mastoid, middle ear, and jugular bulb areas. The tendons attached to the styloid process have been divided. Retraction of the mandible permits isolation of the carotid artery.

DISCUSSION

Evidence-Based Medicine Questions

What is the long-term tumor control rate with surgical resection and/or radiation?

In patients who undergo gross total tumor resection, the long-term recurrence rate is very low, especially for glomus tympanicum tumors.[2] For glomus jugulare tumors, the data are difficult to interpret due to the heterogeneity of tumor parameters and treatments. A recent meta-analysis[3] revealed that patients treated with subtotal resection were observed for 72 ± 7.9 months and had a tumor control rate of 69%. Those who underwent gross total resection (GTR) had a follow-up of 88 ± 5.0 months and a tumor control rate of 86%. Those treated with STR and SRS were observed for 96 ± 4.4 months and had a tumor control rate of 71%. Patients undergoing SRS alone had a follow-up of 71 ± 4.9 months and a tumor control rate of 95%. The difference in outcomes could be due to a combination of treatment effects versus differences in tumor parameters or other differences between groups.

What is the long-term lower cranial nerve dysfunction associated with treatment of glomus jugulare tumors?

The lower cranial nerve function is typically very good if the tumor does not involve the pars nervosa of the jugular foramen. If the pars nervosa requires dissection, there is a high incidence of persistent lower cranial nerve dysfunction. A significant number of patients who had pre-existing dysfunction or developed new dysfunction postoperatively will likely require adjuvant treatments.[4]

Radiation options provide a treatment alternative with improved lower cranial nerve dysfunction. Martin et al.[5]

reported that pre-existing cranial neuropathies improved in 20% and remained stable in 77% after radiosurgery. One patient had worsened lower cranial nerve function. The function of all previous intact nerves was preserved after radiosurgery. The 5- and 10-year actuarial control rates were 97% and 94%, respectively.

Editorial Comment

The diagnosis and management of paraganglioma (glomus tumors) of the head and neck have become more sophisticated and challenging. Approximately 20% of patients with glomus tumors have a genetic familial predisposition, with these patients being more likely to have multicentric and bilateral tumors, often presenting at a younger age. There are four paraganglioma loci (paraganglioma [PGL] 1, 2, 3, and 4) on two chromosomes responsible for inheritance. Mutations of the succinate-dehydrogenase (SDH) genes are linked to familial autosomal dominant patterns of inheritance. Identification of a patient carrying the mutation prompts full investigation of other tumor foci and the need to screen family members.

The pendulum is swinging in terms of management strategies for glomus jugulare tumors. The advancements in surgical resection and reconstruction techniques fostered aggressive interventions in removing these vascular tumors. Decades ago, the method for treatment was full course external beam radiation. Improvement in methods of embolization, intraoperative stabilization of blood pressure by skilled anesthetists, and reliable, effective methods of wound closure promoted multidisciplinary surgical teams to address these tumors. The significant morbidity experience by patients when the lower cranial nerves were sacrificed forces reconsideration as to the most appropriate intervention. Today, patients with large jugular paraganglioma and normal lower cranial nerve function are steered away from aggressive surgery alone. Subtotal resection is advocated with planned postoperative stereotactic radiation to the remainder of the tumor. It remains to be seen in the next 10 to 20 years if radiation both minimizes harm and offers long-term tumor control.

This chapter provides an excellent overview of the surgical management of jugulotympanic paraganglioma. The appropriate preoperative preparation and surgical planning can be tailored to safely offer resection based on the factors outlined previously. Familiarity with the skull base anatomy, surgical techniques, and the potential collaboration with colleagues from interventional radiology, plastics, neurosurgery, and radiation oncology provide strategies for optimal management.

Barry Hirsch

Access the review questions and additional sources list online at http://www.expertconsult.com

REFERENCES

1. Piazza P, Di Lella F, Bacciu A, et al. Preoperative protective stenting of the internal carotid artery in the management of complex head and neck paragangliomas: long-term results. Audiol Neurootol 2013;18(6):345–352.
2. Carlson ML, Sweeney AD, Pelosi S, et al. Glomus tympanicum: a review of 115 cases over 4 decades. Otolaryngol Head Neck Surg 2015;152(1):136–142.
3. Ivan ME, Sughrue ME, Clark AJ, et al. A meta-analysis of tumor control rates and treatment-related morbidity for patients with glomus jugulare tumors. J Neurosurg 2011;114(5):1299–1305.
4. Oestreicher-Kedem Y, Agrawal S, Jackler RK, et al. Surgical rehabilitation of voice and swallowing after jugular foramen surgery. Ann Otol Rhinol Laryngol 2010;119(3):192–198.
5. Martin JJ, Kondziolka D, Flickinger JC, et al. Cranial nerve preservation and outcomes after stereotactic radiosurgery for jugular foramen schwannomas. Neurosurgery 2007;61(1):76–81.

REVIEW QUESTIONS

1. Which modality is the best to evaluate for intracranial extension of glomus tumor?
   a. CT
   b. Arteriogram
   c. MRI
   d. Nuclear medicine scan
   e. a and b

2. Complications related to dissection of the jugular foremen pars nervosa do not include
   a. Dysfunction of the tongue
   b. Dysfunction of the vocal cord
   c. Dysfunction of the shoulder
   d. Pharyngeal dysphagia
   e. c and d

3. In order to preserve lower cranial nerve function, the following structure must be preserved
   a. Fallopian canal
   b. Medial wall of the jugular bulb
   c. Lateral wall of the jugular bulb
   d. Anterior belly of the digastric
   e. Posterior canal wall

ADDITIONAL SOURCES

Carlson ML, Sweeney AD, Wanna GB, et al. Natural history of glomus jugulare: a review of 16 tumors managed with primary observation. Otolaryngol Head Neck Surg 2015;152(1):98–105 (Results of primary observation).

Guss ZD, Batra S, Limb CJ, et al. Radiosurgery of glomus jugulare tumors: a meta-analysis. Int J Radiat Oncol Biol Phys 2011;81(4): e497–502 (A metanalysis of radiosurgery results).

Krych AJ, Foote RL, Brown PD, et al. Long-term results of irradiation for paraganglioma. Int J Radiat Oncol Biol Phys 2006;65(4):1063–1066 (Results of a large series of observation, surgery, external-beam radiotherapy, and stereotactic radiosurgery cases).

Künzel J, Iro H, Hornung J, et al. Function-preserving therapy for jugulotympanic paragangliomas: a retrospective analysis from 2000 to 2010. Laryngoscope 2012;122(7):1545–1551 (Results of a large series of cases undergoing primary function-preserving surgery with or without adjuvant radiotherapy, or primary radiosurgery).

Pollock BE. Stereotactic radiosurgery in patients with glomus jugulare tumors. Neurosurg Focus 2004;17(2):E10.

143 Cholesterol Granulomas and Congenital Epidermoid Tumors of the Temporal Bone

Julie P. Adelman, Pamela Roehm

INTRODUCTION

Benign lesions of the temporal bone present treatment challenges due to their central location among critical neurovascular structures. These lesions may remain undetected for years due to their insidious growth pattern and are often diagnosed incidentally by radiologic imaging. Larger lesions can encroach upon adjacent neurovascular structures, presenting with hearing loss, tinnitus, vertigo, cranial neuropathies, or headaches. Accurate diagnosis of petrous apex lesions is made possible by computed tomography (CT) and magnetic resonance imaging (MRI) characteristics. The surgical approach to lesions of the petrous apex varies based on the type and location of the lesion (Fig. 143.1).

The petrous apex is a pyramidal bony structure at the most medial aspect of the temporal bone (Fig. 143.2). At its base is the otic capsule, the canal of the tensor tympani muscle, and the petrous carotid artery. The superior boundary is the floor of the middle cranial fossa, extending from the arcuate eminence of the superior semicircular canal to the Meckel cave. The jugular bulb, vertical petrous carotid canal, and inferior petrosal sinus make up the inferior border. Posteriorly, the petrous apex is bounded by the posterior cranial fossa, extending from the posterior semicircular canal and endolymphatic sac to the petroclinoid ligament. Anteriorly, the petrous bone articulates with the greater wing of the sphenoid bone, extending medially to the foramen lacerum. The petrous bone articulates with the squamous portion of the temporal bone at its lateral edge.

The petrous apex may be divided into anterior and posterior portions by a vertical line drawn in the coronal plane through the internal auditory canal. Use of this plane as a dividing line can help determine the appropriate approach to lesions of the petrous apex.[1] Most petrous bones are filled with bone marrow or alternatively comprised of dense bone. However, 30% of petrous apices are pneumatized.[2] Pneumatization of the petrous apex may be highly variable and can differ from side to side in the same patient.

Although rare, there are a wide variety of lesions of the petrous apex. Asymmetric fatty marrow and unilateral opacification of the petrous apex air cells are the most commonly identified radiologic "abnormalities" of the petrous apex. It is important to correctly diagnose these entities, as they may be confused with dangerous pathologies, resulting in misdiagnosis and unnecessary evaluation or intervention. These lesions typically do not require surgical intervention and can be managed effectively by observation alone.[3] Unilateral effusions may be noted in pneumatized petrous apexes. These almost uniformly cause consternation in radiologists, who often describe these as "petrous apicitis" or as tumors of the petrous

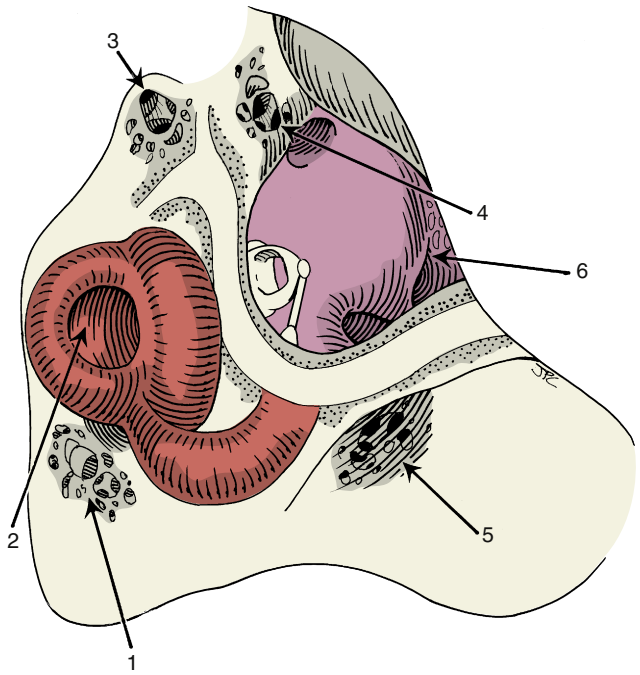

Fig. 143.1. Approaches for petrous apex cholesterol granuloma drainage. *1*, Supralabyrinthine tract inferior to the middle fossa dura; *2*, subarcuate tract through the superior semicircular canal; *3*, air cells of the root of the zygoma; *4*, small triangular region of bone between the genu of the carotid artery and the cochlea; *5*, retrofacial infralabyrinthine tract; *6*, infracochlear air cell tract.

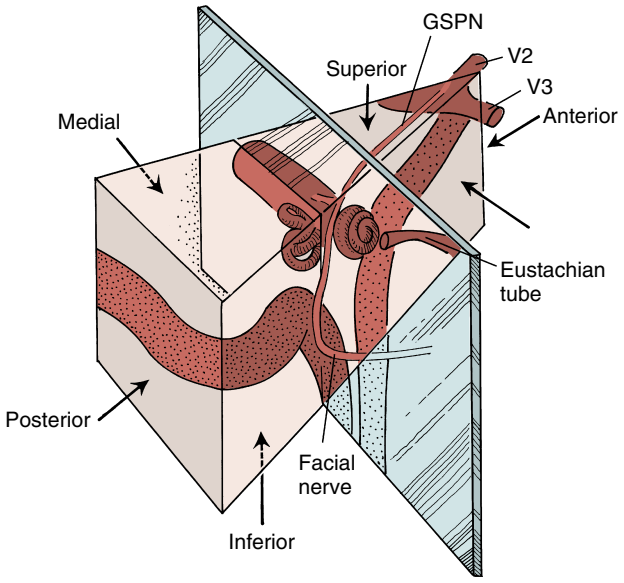

Fig. 143.2. Petrous portion of the temporal bone. A coronal plane through the internal auditory canal separates the posterior and anterior petrous apex. The greater superficial petrosal nerve (GSPN) runs along the superior surface of the petrous bone. The gasserian ganglion and the mandibular division of the trigeminal nerve are located in the apex. *V2*, second branch of trigeminal nerve, *V3*, third branch of trigeminal nerve.

apex. If asymptomatic, these do not require further treatment. If effusions cause troublesome symptoms, initial treatment includes a trial of antibiotic and steroids, with surgical drainage reserved for recalcitrant cases.[4]

True lesions of the petrous apex can be categorized as cystic or solid. Cystic lesions include cholesterol granulomas, congenital epidermoid tumors (cholesteatomas), and mucoceles. Solid lesions of the petrous apex include chondromas, chondrosarcomas, and metastatic carcinomas. All of these pathologies can be more rarely identified within the other portions of the temporal bone. Lesions of the temporal bone are often asymptomatic and increasingly identified serendipitously on imaging for other complaints. When symptomatic, these lesions cause complaints of headaches or signs due to impingement on neurovascular structures. Within the petrous apex, hearing loss is the most common presenting symptom (64%), followed by dizziness (49%), headache (43%), tinnitus (40%), and facial twitching (14%). Trigeminal paresthesia may also occur.[5] Symptoms more rarely reported include cranial neuropathies, facial paralysis, and diplopia. Eustachian tube involvement may present as recurrent otitis media or otorrhea.[6]

Cholesterol granulomas are the most common cystic lesion of the petrous apex (0.6 cases per million per year), occurring 10 times more frequently than cholesteatomas and 40 times more frequently than mucoceles.[4] A cholesterol granuloma is an intraosseous cyst with a fibrous lining, filled with a brown-yellow fluid composed of cholesterol crystals and inflammatory cells (Fig. 143.3). Cholesterol granulomas form as a result of anaerobic catabolism of blood and blood products. The blood products incite a foreign-body giant cell inflammatory response. They can form anywhere within pneumatized spaces of the temporal bone. Cholesterol granulomas lack a true epithelial lining and therefore do not require complete excision.

Congenital epidermoid tumors and acquired cholesteatomas are the second-most common lesions of the petrous apex. These slow-growing tumors comprise 4% to 9% of petrous apex lesions.[7,8] Epidermoids and cholesteatomas are sac-like cysts, lined by stratified squamous epithelium that contains keratin debris. The microscopic appearance of congenital epidermoids and acquired cholesteatomas is identical.[9] These lesions behave aggressively with the potential for progressive expansion and destruction of surrounding structures. Congenital epidermoid tumors are thought to arise from epithelial rests deposited within the temporal bone in early embryonic development. Acquired cholesteatoma occurs from medial spread of cholesteatoma originating within the middle ear or mastoid. These patients are more likely to present with symptoms of chronic otitis media.

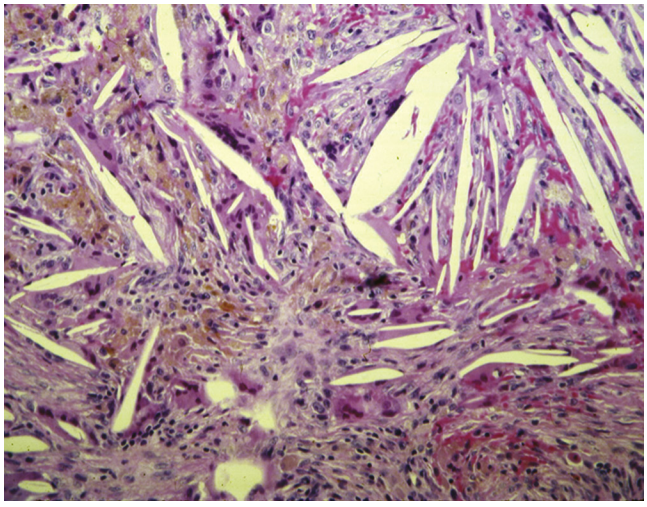

Fig. 143.3. Histopathology of cholesterol granuloma. Note the large cholesterol crystal surrounded by giant cells, macrophages, and fibrous connective tissue.

Like most lesions of the petrous apex, epidermoids often present when they become large. They produce symptoms by compression of the Eustachian tube, internal auditory canal, and cranial nerves or by putting tension on the surrounding dura; by the time most epidermoids are detected, cranial neuropathies are present (85%). In a series of 25 patients with cholesteatomas of the petrous apex, hearing loss was the most common presenting symptom (64%), followed by facial weakness (56%), dizziness (44%), otorrhea (32%), trigeminal paresthesia/neuralgia (12%), and cranial nerve VI palsy (4%).[10] These tumors often involve vascular structures as well, including the carotid artery. For these reasons, complete surgical resection of epidermoid tumors in this location can be difficult and recurrence can occur even with adequate exposure due to inability to remove all of the epidermoid from critical structures. The most common site for recurrent petrous epidermoids is in the region of the carotid artery.[10]

The common benign lesions of the petrous apex, cholesterol granulomas and petrous apex epidermoids, are often indistinguishable by history and physical examination alone, but typically can be diagnosed definitively by appropriate imaging (Table 143.1). Increasingly, benign lesions of the petrous apex are detected serendipitously on imaging ordered for other indications. If this occurs, appropriate imaging must still be performed to determine the type of lesion and its extent. Accurate diagnosis is required prior to surgical management, because the approach for these lesions differs radically.

High-resolution temporal bone CT is valuable in both diagnosis and treatment planning. Cholesterol granulomas and petrous apex epidermoids are nonenhancing iso- or hypodense masses on brain-weighted algorithms. Irregularities and erosion of the temporal bone around the mass on CT indicates a more aggressive lesion (tumor or cholesteatoma; Fig. 143.4A), whereas smooth, thickened borders around the mass indicate benign, less-aggressive lesions (cholesterol granulomas) that have slowly increased in size over time (see Fig. 143.4B). High-resolution temporal bone CT is invaluable in delineating the precise anatomic relationship of the lesion to structures including the otic capsule, middle ear, carotid artery, and middle and posterior fossa. This detail is essential in determining the feasibility of different surgical approaches.

MRI of the brain and temporal bones is also a critical component of preoperative imaging. T1 signal hyperintensity indicates the presence of adipose tissue, blood, or proteinaceous fluid. T2 signal hyperintensity indicates the presence of water. Cholesterol granulomas have a very distinct appearance on MRI imaging (Fig. 143.5). Because cholesterol granulomas are composed of the breakdown product of blood and inflammatory products, they produce hyperintensity on both T1- and T2-weighted MRIs. In addition, cholesterol granulomas do not enhance with gadolinium. Other lesions of the petrous apex, including epidermoids, mucoceles, unilateral benign effusions, arachnoid cysts, and neoplastic lesions, tend to be iso- or hypointense compared with brain on T1 imaging. Epidermoids and acquired cholesteatomas are characteristically hyperintense on T2-weighted MRI and often do not enhance with gadolinium (if they do, the pattern of enhancement is irregular; Fig. 143.6A). On diffusion-weighted imaging (DWI), cholesteatomas are hyperintense (see Fig. 143.6B), whereas

TABLE 143.1 Imaging Characteristics of Petrous Apex Lesions

	High-Resolution CT			MRI of Brain and Brainstem/Internal Auditory Canals			
Lesion	**Bone Windows**	**Brain Windows**	**With Contrast**	**T1**	**T2**	**T1 with Contrast**	**DWI**
Cholesterol granuloma	Smooth, thickened borders	Hypodense	No enhancement	Hyperintense	Hyperintense	No enhancement	Low intensity
Cholesteatoma or epidermoid	Irregular borders	Iso- or hypodense	No enhancement	Isointense	Hyperintense	No or irregular enhancement of borders	High intensity
Petrous apicitis	Irregular borders	Iso- or hypodense	Enhances	Hypointense	Hyperintense	Rim enhancement	Low intensity
Effusion	Fluid density with intact trabeculae and smooth ± thickened borders	Hypodense	No enhancement	Hypointense	Hyperintense	No enhancement	Low intensity
Mucocele	Smooth borders ± thickening, absent trabeculae	Hypodense	No enhancement	Hypointense	Hyperintense	No enhancement	Low intensity
Bone marrow	Nonexpansile area with small bone trabeculae present	Iso- or hypodense	No enhancement	Hyperintense (suppresses with fat suppression)	Isointense	No enhancement	Low intensity
Encephalocele	Smooth borders	Iso- or hypodense	No or mild enhancement	Isointense	Isointense	No or mild enhancement	Low intensity
Arachnoid cyst	Smooth borders ± thickening	Hypodense	No enhancement	Hypointense	Hyperintense	No enhancement	Low intensity

CT, Computed tomography; *DWI,* diffusion weighted imaging; *MRI,* magnetic resonance imaging.

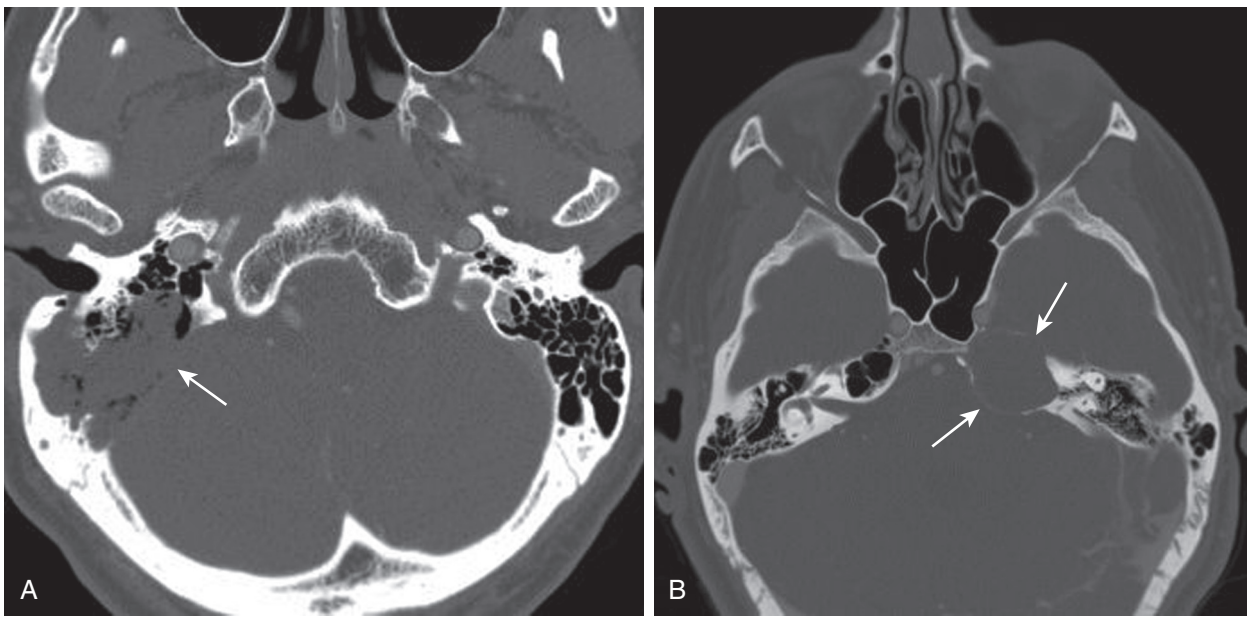

Fig. 143.4. A, Bone-windowed computed tomography (CT) demonstrating an erosive right petrous apex lesion *(white arrow)*, consistent with cholesteatoma. **B,** Bone-windowed CT demonstrating an expansile left petrous apex lesion with smooth margins, which is isointense with brain *(white arrows)*, consistent with cholesterol granuloma. *(courtesy of Barton Branstetter, MD.)*

mucoceles, effusions, and arachnoid cysts are hypointense. Neoplasms are isointense on DWI. MRI also provides soft tissue detail and information about intracranial extension or involvement of neurovascular structures.

Postoperative imaging is a crucial component of the care of lesions of the petrous apex. Following drainage of a cholesterol granuloma, the drained cavity may fill with fluid and thus make detection of a recurrence by CT difficult. However, serous fluid and recurrent cholesterol granuloma will have different appearances on T1-weighted images. Serous fluid-filled cavities will have decreased signal intensity, whereas recurrence will remain hyperintense on T1-weighted imaging.[6] After resection of a petrous apex epidermoid, either MRI or CT can be used to monitor for recurrence.

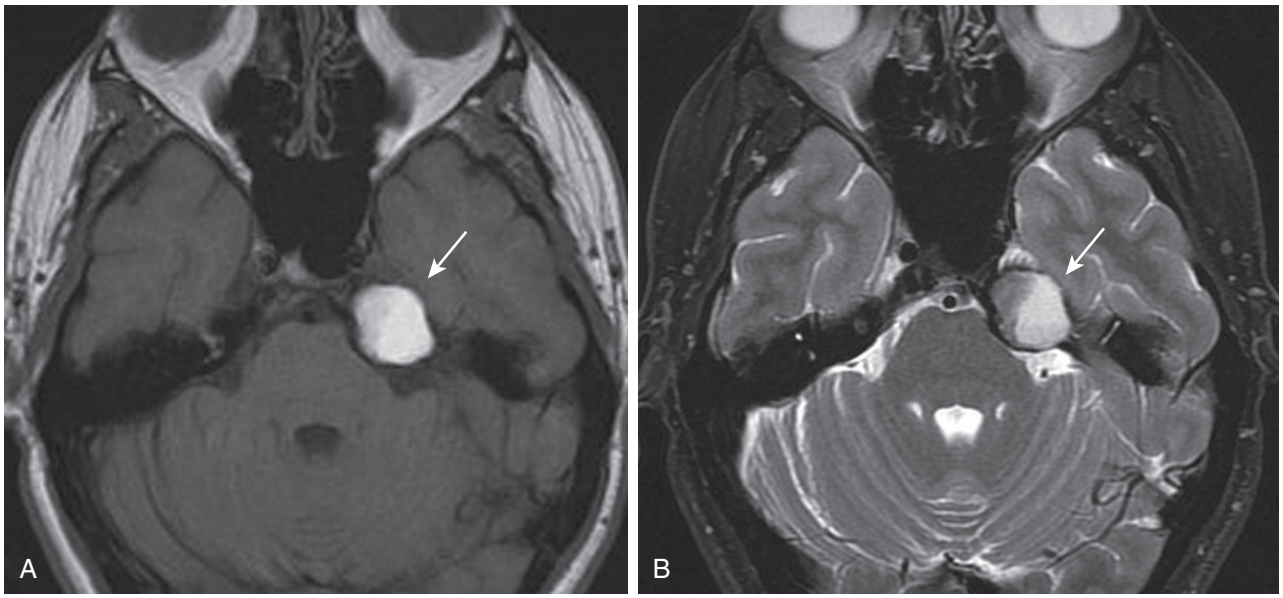

Fig. 143.5. Petrous apex cholesterol granuloma, preoperative views. **A,** T1-weighted magnetic resonance imaging (MRI) without contrast demonstrating a hyperintense (compared to brain) left petrous apex lesion *(arrow)* that is isointense with adipose tissue. **B,** T2-weighted MRI showing a hyperintense (to brain) left petrous apex lesion *(arrow)* that is isointense with cerebrospinal fluid and perilymph. *(Images provided through the courtesy of Barton Branstetter, MD.)*

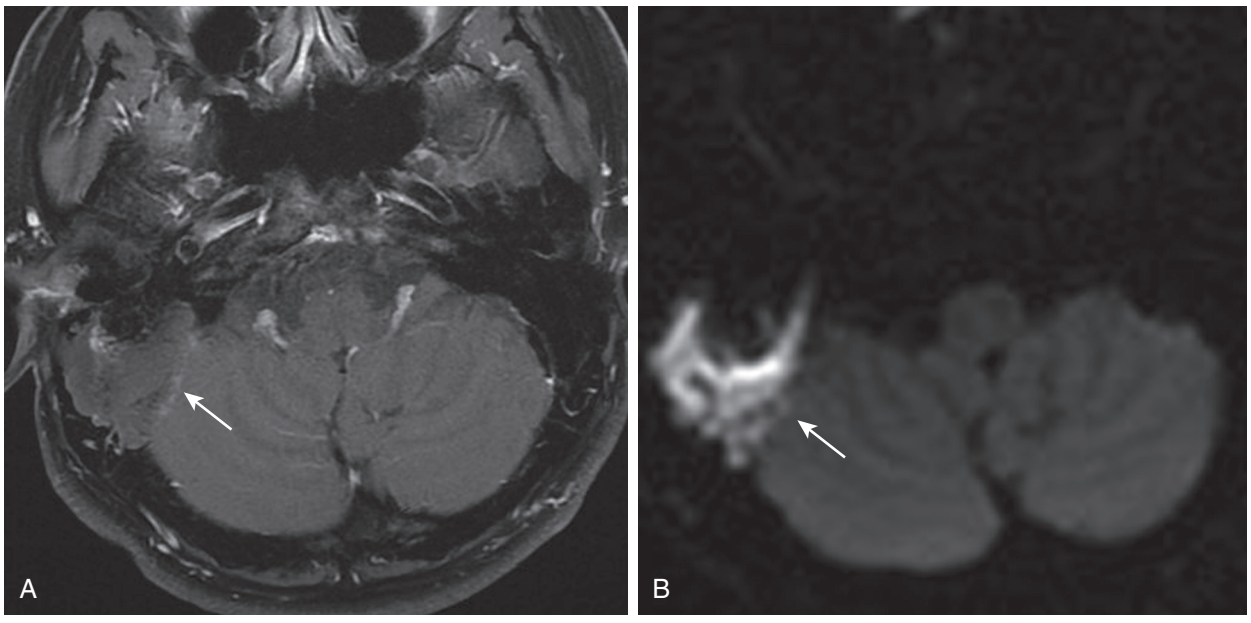

Fig. 143.6. Magnetic resonance imaging of right petrous epidermoid tumor. **A,** T1-weighted image with gadolinium showing slight border enhancement of a brain-isodense lesion of the right petrous and lateral temporal bone, consistent with epidermoid *(arrow)*. **B,** Diffusion-weighted image showing a bright signal in the same location consistent with a cholesteatoma or epidermoid tumor *(arrow)*. *(Courtesy of Barton Branstetter, MD.)*

PREOPERATIVE PERIOD

History

1. History of present illness
   a. Hearing loss
   b. Headache or retro-orbital pain
   c. Tinnitus
   d. Vertigo
   e. Facial weakness
   f. Facial twitching
2. Past medical history
   a. Previous otologic disease
   b. History of hearing loss
   c. History of recurrent ear infections
   d. Medical illness (history of cardiac disease, pulmonary status)
   e. Medications (anticoagulants, antiplatelet agents, aspirin, nonsteroidal anti-inflammatory agents)
3. Past surgical history
   a. History of otologic surgery

4. Family history
   a. Family history of otologic disease
   b. Family history of hearing loss
5. Social History

Physical Examination

1. Vital signs.
2. Examination of the head and neck including laryngoscopy.
   a. General appearance.
   b. Pneumatic otoscopy (assess external auditory canal, tympanic membrane, and middle ear).
   c. Cranial nerve examination

Audiometry

1. Pure-tone audiogram
2. Speech thresholds using spondees
3. Word recognition
4. Tympanometry
5. Additional testing, such as auditory brainstem responses (ABRs) and caloric testing of vestibular function may also be indicated.

Imaging

1. High-resolution temporal bone CT
   a. Important in delineating bony structures and precise anatomic relationships
   b. Provides information about the behavior of the lesion with respect to involvement of the bone.
   c. Enables the surgeon to evaluate appropriate surgical approaches based on anatomy.
2. MRI
   a. Can differentiate between many lesions by characteristics of T1- and T2-weighted imaging.
   b. Some lesions enhance with gadolinium, whereas others do not.
   c. DWI helps to distinguish epidermoids from other lesions.
   d. MRI can be valuable for determining recurrence of cholesterol granuloma.

Indications

1. Cholesterol granuloma
   a. Large lesions causing hydrocephalus or other complications related to brain and brainstem compression
   b. Lesions causing cranial neuropathies
   c. Pathology causing severe or uncontrollable pain
   d. Cholesterol granulomas can be treated effectively by drainage into the mastoid cavity, middle ear, sphenoid sinus, or middle fossa. The goal of surgical drainage for cholesterol granulomas is to maintain permanent drainage of the cavity to prevent recurrence.
2. Epidermoids and acquired cholesteatomas should always be removed in their entirety if possible.

Contraindications

1. Small, asymptomatic cholesterol granuloma
2. Medical comorbidities with increased risks from general anesthesia

Preoperative Preparation

1. Discontinue antiplatelet drugs and warfarin prior to neurosurgical approaches.
2. Obtain image guidance scans if intraoperative guidance will be used.

OPERATIVE PERIOD

Anesthesia

1. The procedure is performed under general anesthesia with orotracheal intubation.
2. Paralytic agents should not be used.

Positioning

1. The patient is positioned supine with the head extended for intranasal approaches.
2. The patient should be placed supine with the head turned toward the contralateral ear for middle fossa or lateral transtemporal procedures.

Perioperative Antibiotic Prophylaxis

1. First-generation cephalosporin
2. Clindamycin in the patient who is allergic to penicillin

Monitoring

1. Facial nerve monitoring is indicated for all mastoid and skull base approaches and strongly recommended for transnasal approaches for larger lesions.
2. Facial, lower cranial nerve, and somatosensory monitoring are used, especially if the surgical approach is in proximity to those nerves and the carotid artery.
3. Additional ipsilateral cranial nerve monitoring as indicated by the size of the lesion.
4. ABR monitoring for middle fossa approaches.

Instruments and Equipment to Have Available

1. Transmastoid and middle ear approaches
   a. Middle ear and mastoid set
   b. High-speed otologic drill and burs
   c. Binocular operating microscope
   d. 3-mm diameter 0- and 30-degree otoendoscopes.
   e. Silastic stent or drainage catheter
2. Middle fossa approaches
   a. Neurosurgical instruments including malleable retractors and adjustable brain retractors
   b. Basic middle ear and mastoid sets
   c. High-speed otologic drill and burs
   d. Silastic stent or drainage catheter
   e. Binocular operating microscope
3. Transsphenoidal approaches
   a. 0-, 30- or 45-, and 60-degree endoscopes
   b. Endoscope cleaning device
   c. Transsphenoidal endoscopic instrument set
   d. Suction bipolar
   e. Endoscopic bipolar
   f. Silastic stent or drainage catheter

Prerequisite Skills

1. Middle ear and mastoid approaches
   a. Tympanoplasty
   b. Canaloplasty
   c. Mastoidectomy
   d. Canal wall down (CWD) mastoidectomy
2. Middle fossa approaches
   a. Craniotomy
   b. Knowledge of the anatomy of the middle fossa
3. Transsphenoidal approaches
   a. Endoscopic sphenoidotomy
   b. Transsphenoidal pituitary approach

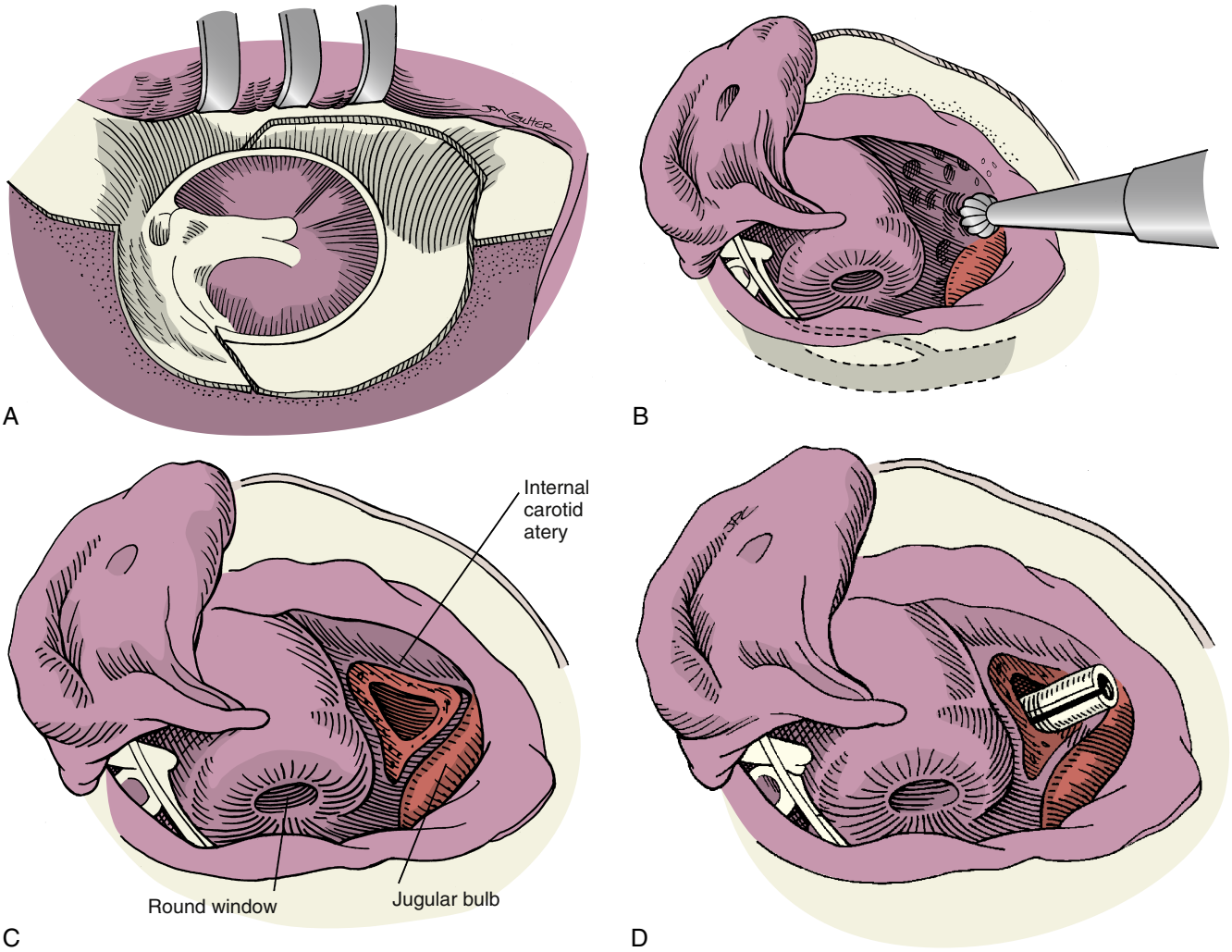

Fig. 143.7. Infracochlear approach. **A,** The superiorly based tympanomeatal flap is incised. The prominent anteroinferior bony canal wall will be removed. **B,** The superiorly based tympanomeatal flap is elevated to expose the mesotympanum and hypotympanum. A cutting burr is used to remove the prominence of the anterior canal wall and the inferior tympanic ring for further exposure of the hypotympanum. Care is taken posteriorly to avoid the vertical portion of the facial nerve. **C,** A diamond burr is used to remove the hypotympanic air cells. The limits of dissection are the internal carotid artery anteriorly, the jugular vein posteroinferiorly, and the basal turn of the cochlea superiorly. **D,** A rolled Silastic sheet is placed in the opening of the fistula from the cystic cavity to the hypotympanum.

Operative Risks

1. For all approaches
   a. Facial nerve paresis/paralysis
   b. Hearing loss
   c. Wound infection
2. For middle ear and mastoid approaches, additional risks include the following:
   a. Bleeding from the internal carotid artery and jugular bulb
   b. Tympanic membrane perforation
3. For middle fossa approaches, additional risks include the following:
   a. Cerebrospinal fluid leak
   b. Bleeding from the middle meningeal artery
   c. Bleeding from the internal carotid artery
   d. Cerebrovascular accident
4. For transsphenoidal approaches, additional risks include the following:
   a. Cerebrospinal fluid leak
   b. Bleeding from the carotid
   c. Blindness
   d. Diplopia

Surgical Technique

The selection of the appropriate surgical approach for a given petrous apex lesion is based primarily on the patient's preoperative hearing and balance status and the location of the lesion relative to the surrounding neurovascular structures. Approaches may be divided into hearing-preservation and non-hearing-preservation techniques.

Infracochlear Approach

The infracochlear approach was initially described by Ghorayeb and Jahrsdoerfer. This hearing-preservation approach has the advantage of providing a dependent drainage pathway from the cyst into the middle ear space (Fig. 143.7A–D). Although the window of exposure is narrower than that achieved using the infralabyrinthine approach, the approach is more direct. This technique has the added benefit of increased safety in patients with a high jugular bulb. This approach is infrequently used for cholesteatomas, but occasionally may be indicated in patients with small cholesteatomas in this area who have intact hearing. For patients with cholesteatoma, no stent is required.

1. A post auricular incision is made through the skin.
2. A Palva flap is elevated, exposing the bony external auditory canal.
3. A superiorly based tympanomeatal flap is created by incising the canal skin at the bony-cartilaginous junction.
4. The hypotympanum is exposed by removing anterior and inferior tympanic bone using an otologic drill.
5. The chorda tympani nerve is followed posteroinferiorly to find the facial nerve.
6. The jugular bulb and petrous carotid artery are identified.
7. Dissection anteromedially between the jugular bulb and carotid artery is performed using diamond burrs and curettes.
   a. The round window is the superior boundary of dissection.
8. The cyst is entered medially and its contents removed.
   a. Visualization of the cavity can be aided by intraoperative otoendoscopy.
   b. For cholesterol granulomas, the cyst cavity is irrigated copiously with sterile saline.
9. Silastic tubing is inserted to stent the drainage pathway.
   a. The lateral end of the tubing should extend into the middle ear.
10. The bony canal defect can be repaired using bone pate collected during drilling of inferior tympanic ring.
11. The tympanomeatal flap is placed back into position.
12. The external auditory canal is packed with Gelfoam.
13. The post auricular incision is closed.

Retrofacial Infralabyrinthine Approach

The infralabyrinthine approach provides a direct route to most petrous apex cholesterol granulomas (Fig. 143.8). This approach should be used with caution in patients with high-riding jugular bulbs, because adequate visualization of this structure is not afforded by this approach.

1. A post auricular incision is made, and the auricle is reflected anteriorly.
2. A Palva flap is elevated, and the bony external auditory canal is exposed.
3. A complete mastoidectomy is performed.
4. The sigmoid sinus is skeletonized and may be decompressed as needed.
5. The facial nerve, posterior semicircular canal, and jugular bulb are identified.
6. Using diamond burrs and curettes, the infralabyrinthine air cell tracts are followed anteromedially until the lesion is encountered.
7. The cyst contents are removed and the cavity irrigated.
8. A Silastic stent is placed in the cyst cavity, extending into the mastoid.
9. The musculoperiosteal flap and skin incisions are closed, and a mastoid dressing is placed.

Middle Cranial Fossa Approach

This hearing-preservation approach provides access to the petrous apex from above the auricle (Fig. 143.9). The middle fossa approach has fallen out of favor for drainage of cholesterol granulomas, because it does not often allow long-term drainage of the cyst. The cyst must be removed in its entirety to successfully treat a cholesterol granuloma using this approach. It retains its usefulness for epidermoids and benign and malignant tumors within the area.

1. A question-mark-shaped incision (reverse question mark on the right) is made through the skin and subcutaneous tissue above the auricle, extending 1 cm within the crease just anterior to the pinna to the superior edge of the tragus.
2. A stepped incision is made through the temporalis muscle and fascia and they are elevated anteriorly, exposing the root of the zygoma.
3. A middle fossa craniotomy is performed just superior to the pinna.
4. The bone flap is removed, and the dura is dissected off the floor of the middle cranial fossa from posterior to anterior.
5. A self-retaining temporal lobe retractor is placed.
6. The middle meningeal artery, arcuate eminence, and geniculate ganglion are identified.
7. Further dissection is directed by location of the lesion.

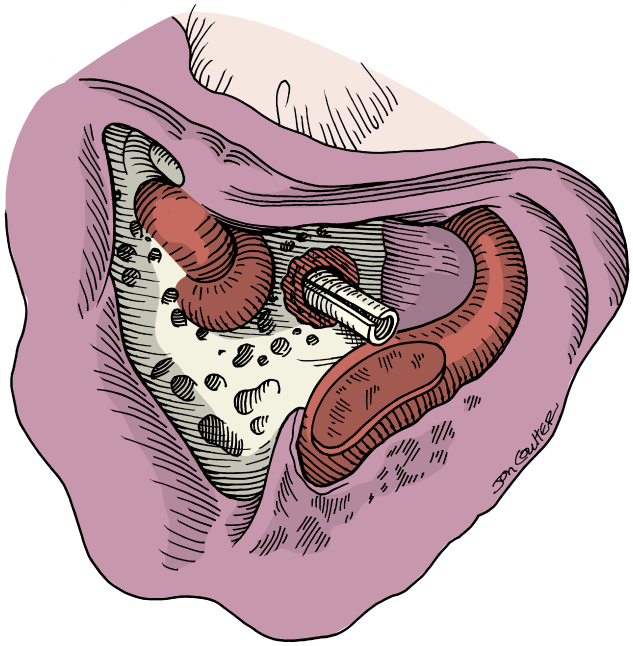

Fig. 143.8. Retrofacial infralabyrinthine approach. A transcortical mastoidectomy is performed to identify the antrum, posterior semicircular canal, facial nerve, digastric ridge, and jugular bulb. A Silastic tube from the mastoid into the cyst provides drainage and aeration.

Endoscopic Transsphenoidal Approach

With the development of minimally invasive, endoscopic techniques and intraoperative image guidance, endonasal transsphenoidal approaches to appropriately selected lesions of the petrous apex can be performed. This approach leaves both hearing and balance intact.

Endoscopically, the petrous apex may be entered by a medial approach with lateralization of the internal carotid artery, or by a transpterygoid infrapetrous approach. For benign lesions of the petrous apex, the risks associated with carotid manipulation are considered too great; this approach will not be discussed.

1. For medial transsphenoidal approaches, the patient is placed supine on the operating table and the nasal mucosa is decongested with both topical and injected agents.
   a. Image guidance is used during these surgeries. The images (sinus CT ± MRI) are registered prior to beginning the procedure.
2. The middle turbinates are outfractured or trimmed to allow visualization of the sphenoid ostia.
3. The mucosa overlying the sphenoid and posterior nasal septum is cauterized.

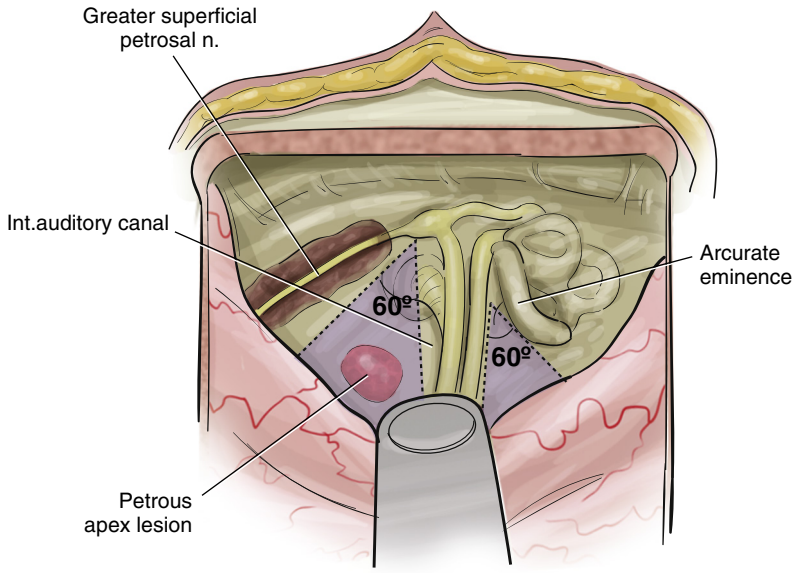

Fig. 143.9. Middle cranial fossa approach to the petrous apex, with typical site of lesion shown.

4. The posterior nasal septum is transected at the bony-cartilaginous junction and detached from the sphenoid rostrum.
5. 1.0 to 1.5 cm of the posterior septum is removed to facilitate visualization and manipulation of surgical instruments.
6. Bilateral sphenoidotomies are performed.
7. The operative landmarks including the planum sphenoidale, sella, clivus, optic canal, and carotid canal are identified.
8. The mucosa of the sphenoid sinus is removed.
9. A diamond burr may be used to thin the bony posterior wall of the sphenoid sinus at the medial wall of the lesion.
10. When the bone is thin enough, a Kerrison ronguer is used to unroof the cyst.
11. The contents of the cyst are then drained, and the region should be irrigated copiously.
12. A Silastic stent is placed through the opening into the cyst.
13. Doyle splints and nasal packing are placed in the nares bilaterally and removed on the third postoperative day.
14. The patient can be discharged on the day of surgery.

A more extensive approach may be necessary if the sphenoid sinus is poorly pneumatized or the cyst is located in a more posterolateral position. In such circumstances, the medial approach may be used. This modified technique involves decompression of the internal carotid artery and creation of a larger medial approach. The internal carotid artery is located by identifying the Vidian artery and nerve. The Vidian nerve can be identified by entering the pterygopalatine fossa and dissecting laterally until the nerve is seen exiting from the pterygoid canal. By removing bone medial and inferior to the canal, the operative field is widened by several millimeters and the internal carotid artery can be identified at its second genu. (See Chapter 120)

The most significant complication of this approach is recurrence due to stenosis of the drainage pathway, even with the use of a stent.

Tympanomastoidectomy with Exteriorization

Lesions of the petrous apex can be marsupialized and drained externally, often into a CWD mastoidectomy cavity (Fig. 143.10). Although cochlear hearing can be preserved by this approach, the patient will experience a maximum conductive hearing loss following the procedure.

1. A postauricular skin incision is made and the pinna retracted anteriorly.
2. A large, anteriorly based postauricular musculoperiosteal flap is elevated.
3. The mastoid antrum, incus, and horizontal semicircular canal are identified and are used as landmarks.
4. A tympanomeatal flap is elevated, and the middle ear is entered
5. The incudostapedial and incudomalleolar joints are disarticulated, and the incus is removed.
6. The posterior canal wall is taken down, and the facial ridge is lowered to the level of the external auditory canal.
7. The skin of the external auditory canal and tympanic membrane are completely removed.
8. Drilling continues anteriorly through the zygomatic root until the geniculate ganglion is identified, and dissection is carried out along the greater superficial petrosal nerve.
9. Dissection along this nerve opens the petrous apex through the air cells of the zygomatic root.
10. The contents of the cholesterol granuloma are removed, and the cavity is irrigated.
11. The external auditory meatus is then closed.
12. The postauricular incision is closed, and a mastoid dressing is applied.

Translabyrinthine Approach

This approach accesses lesions located in both the anterior and posterior petrous apices (Fig. 143.11). One disadvantage of this procedure is that residual ipsilateral hearing and vestibular function are sacrificed. Patients with preoperative residual vestibular function will require hospitalization for supportive therapy during the acute phase of their vestibular compensation. Patients who had no preoperative ipsilateral vestibular function and in whom the cerebrospinal space is not entered can be discharged on the day of surgery.

1. A C-shaped postauricular incision is made and the auricle is reflected anteriorly.
2. An incision is made in the periosteum along the temporal line superiorly and carried inferiorly to the mastoid tip.

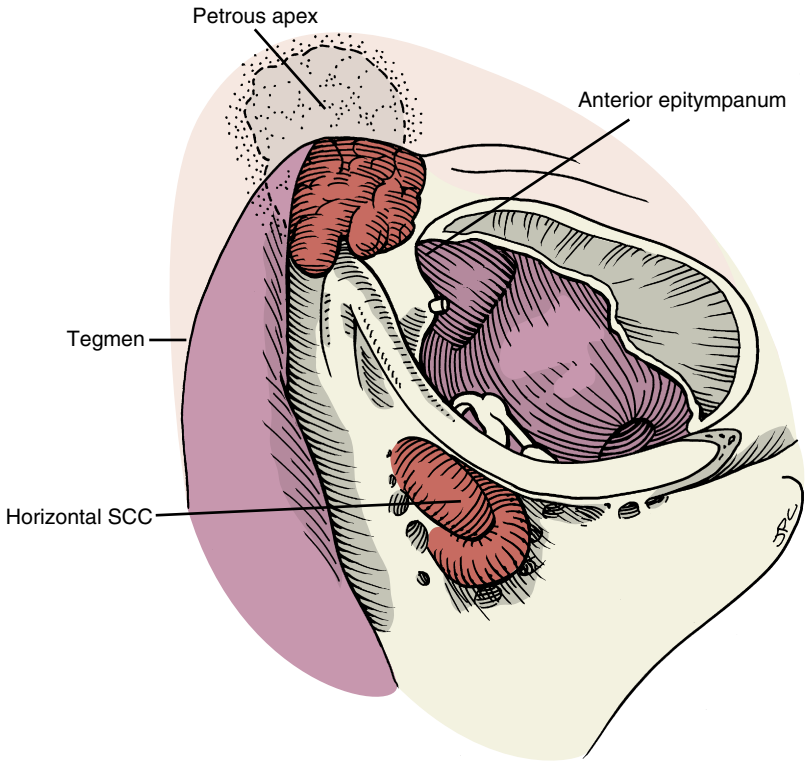

Fig. 143.10. Tympanomastoid exteriorization. A canal wall down (CWD) mastoidectomy is used to expose the anterior epitympanum and the cholesteatoma in the petrous apex *(shown in gray)*. Dissection along the greater superficial petrosal nerve opens the petrous apex through the air cells of the zygomatic route. *SCC,* semicircular canal.

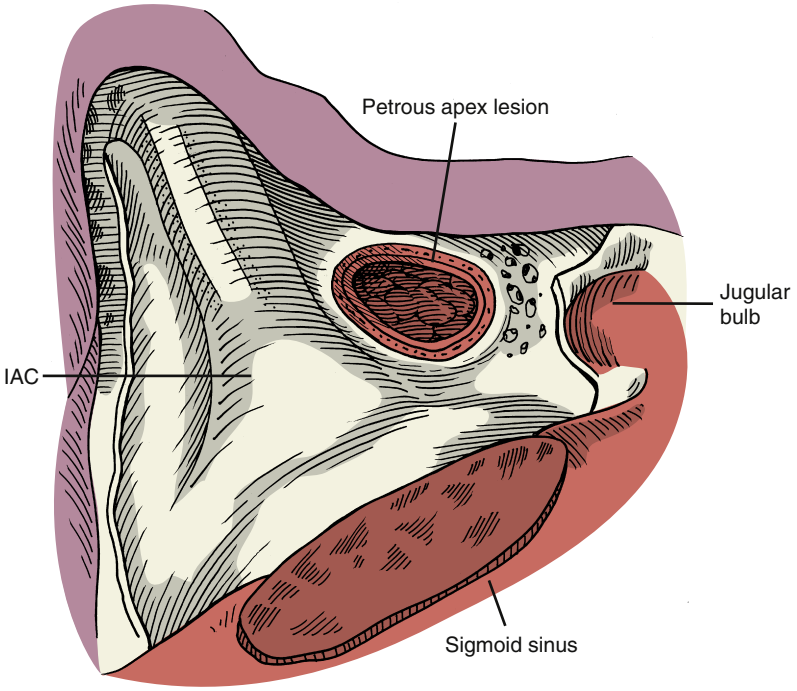

Fig. 143.11. Translabyrinthine approach to the petrous apex. The internal auditory canal (IAC) is skeletonized to create an inferior and superior trough around the porus acousticus. Care is taken to avoid the cochlear aqueduct and jugular bulb.

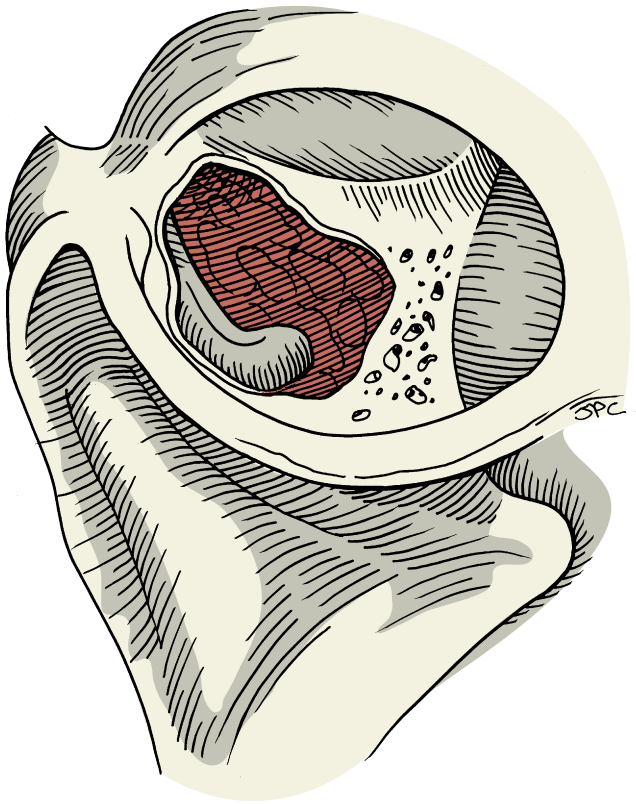

Fig. 143.12. Transcochlear approach to the petrous apex. The contents of the epidermoid tumor are removed while leaving the matrix lining intact.

3. The musculoperiosteal flap is elevated, exposing the external auditory canal.
4. A complete mastoidectomy is performed.
5. The mastoid antrum is entered, and the lateral semicircular canal is identified.
6. After identification of the posterior and superior semicircular canals, a labyrinthectomy is performed.
7. The internal auditory canal is identified but not entered.
8. The cyst is entered, and the contents of the cyst are drained.
9. The cavity is irrigated, and a drain is placed.
10. The musculoperiosteal flap is closed with absorbable sutures.
11. The skin incision is closed in layers, and a mastoid dressing is placed.

Transcochlear/Transotic Approaches

The transcochlear approach is an extension of the translabyrinthine approach that involves removal of the otic capsule in its entirety and can be useful when access to the anterior petrous apex is necessary (Fig. 143.12). This approach would not necessarily require rerouting of the facial nerve, depending on the angle of approach to the petrous apex. In these approaches, a blind-sac closure of the external auditory canal is performed. Both approaches result in loss of ipsilateral hearing and vestibular function.

1. A postauricular incision is made, and the auricle is reflected anteriorly.
2. A Koerner flap is elevated.
3. A CWD mastoidectomy is performed.
4. The tympanic membrane and ossicles are removed.
5. The chorda tympani nerve is cut, the tympanic bone is removed, and the facial ridge is lowered.
6. A labyrinthectomy may be performed if required.
7. The internal auditory canal is identified, and the facial nerve is either skeletonized leaving a thin bridge of bone or decompressed and dissected free.
8. The greater superficial petrosal nerve is identified and transected.
9. The bone of the cochlea is removed
10. Drilling is carried out anteriorly to expose the vertical and horizontal portions of the internal carotid artery.
11. The lesion is encountered and completely excised.
12. The Eustachian tube is plugged with muscle.
13. The cavity is obliterated with adipose tissue to contain a cerebrospinal fluid (CSF) leak if created.
14. The external auditory meatus is closed.

COMMON ERRORS IN TECHNIQUE

Cholesterol Granuloma

1. Failure to place an adequate drain.
   a. Recurrence occurs in 83% of patients without drain placement.
   b. The most common cause of recurrence in patients following drain placement is obstruction of the drainage pathway by fibrous tissue (18%).

Cholesteatoma

1. Failure to remove the cholesteatoma completely.[7]
2. Late recurrence (13%).[7]

POSTOPERATIVE PERIOD

Postoperative care after surgical treatment of a petrous apex lesion is highly dependent on the approach used. The extent of the operative procedure and the ease with which the procedure was performed should be taken into account when determining postoperative management (Fig. 143.13).

1. Following transmastoid, infracochlear, or infralabyrinthine procedures:
   a. The patient may be discharged the same day or after 23-hour observation. The mastoid dressing is removed on the first postoperative day following transcanal/transmastoid approaches.
   b. Start topical antibiotic drops postoperatively for 1 week following infracochlear or infralabyrinthine approaches or after transmastoid procedures where dissolvable packing is left in the ear canal.
   c. See patients 1 week postoperatively for check of the postauricular incision.
   d. See patients at 1 and 3 months postoperatively.
   e. Postoperative audiogram and CT or MRI 2 to 3 months following surgery.
2. Following translabyrinthine, transotic, and transcochlear approaches:
   a. Hospitalization for 3 to 7 days for supportive therapy (IV hydration, antiemetics, and vestibular suppressants) during the immediate postoperative vestibular compensation period, depending on the amount of preoperative vestibular function present in the ipsilateral ear.
      1) Patients with preoperative loss of vestibular function will not require extensive hospitalization postoperatively.
   b. Vestibular suppressants should be discontinued 2 to 3 days after surgery to allow central vestibular compensation to occur.
   c. Obtain MRI or CT imaging to monitor the surgical site at 2 to 3 months.

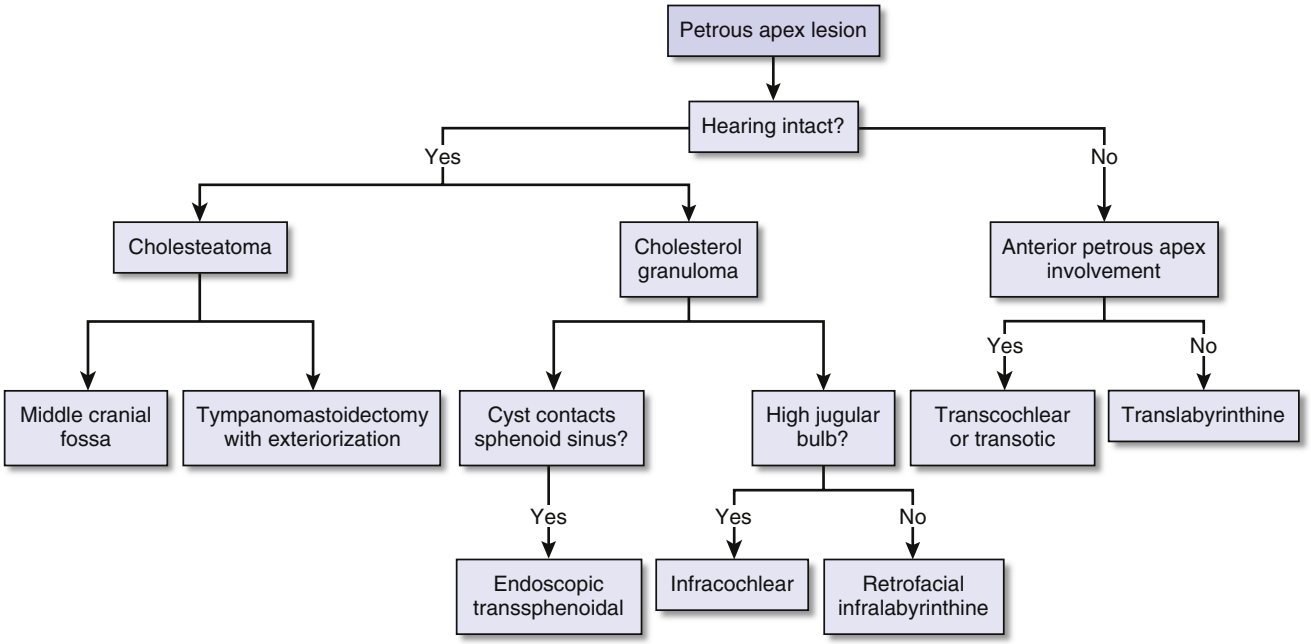

Fig. 143.13. Algorithm for management of benign lesions of the petrous apex.

3. Following middle fossa craniotomy, translabyrinthine, transcochlear, transotic, and other approaches that enter the cerebrospinal fluid space:
   a. Patients should be monitored in a neurosurgical intensive care unit for 2 to 5 days for signs of CSF leak, meningitis, mental status changes, neurovascular injury, diabetes insipidus, cerebral salt-wasting syndrome, and other neurosurgical complications.
   b. Obtain MRI or CT imaging postoperatively to assess and monitor the surgical site.

Complications

Complications are highly dependent on the surgical approach used and the extent of resection needed to treat the lesion effectively.

1. Recurrence/residual disease
   a. Cholesterol granuloma
      1) Observe if asymptomatic.
      2) Revision surgery by the same or an alternative approach.
   b. Cholesteatoma or epidermoid
      1) Revision surgery by the same or an alternative approach.
2. Tympanic membrane perforation
   a. Myringoplasty.
   b. Tympanoplasty.
3. Hearing loss
   a. Hearing aids. Conventional hearing aids can be used for conductive, mixed, or sensorineural hearing losses ranging from mild to severe.
   b. Contralateral routing of signals (CROS)/Bi-CROS aids or a bone-anchored hearing device can be used to remediate a unilateral profound hearing loss.
   c. Ossiculoplasty can be used to repair conductive hearing loss due to ossicular discontinuity.
4. Vertigo
   a. Losses due to approaches through the peripheral vestibular system can be treated with short-term use of vestibular suppressants with subsequent vestibular physical therapy.
   b. Dizziness due to benign paroxysmal positional vertigo can be treated with the Epley maneuver.
5. Cranial nerve deficits
   a. Facial nerve
      1) Facial nerve deficits due to intraoperative facial overstimulation improve spontaneously.
      2) If the facial nerve is transected intraoperatively, it should be repaired by end-to-end anastomosis or cable graft.
      3) If the facial nerve is injured intraoperatively but not completely transected, it can be observed and tested postoperatively. If postoperative electroneurography (ENOG) shows a decrease of greater than 90% to 95% function within the first 2 weeks after surgery, operative exploration and decompression should be performed.
      4) Long-term facial nerve deficits may require gold or platinum eyelid weight placement and/or lower lid tightening to protect the cornea.
      5) Long-term facial nerve deficits may be treated with a number of techniques, including hypoglossal-to-facial anastomosis, temporalis muscle or fascia graft, facelift, brow lift, gracilis muscle transfer, or cross-facial grafting (see Chapter 180).
   b. Cranial nerve (CN) IV and VI injury
      1) Many deficits may be short term.
      2) Deficits can be treated with prisms.
      3) Long-term deficits can be treated with strabismus surgery or long-term use of prisms.
   c. Lower cranial nerve injury
      1) Deficits in the lower cranial nerves are rare. Primary treatment should focus on swallowing function, including use of vocal fold medialization techniques to improve function.
6. CSF leak
   a. Lumbar drain
   b. Operative CSF leak repair
7. Vascular injury or bleeding
   a. Should be controlled intraoperatively.
   b. Bleeding from the carotid artery or other vessels occurring postoperatively can be treated with endovascular stent placement or revision surgery.
8. Wound infection
   a. Typically respond to oral or IV antibiotic therapy.
   b. Abscesses require operative incision and drainage.

Alternative Management Plan

These benign lesions of the petrous apex do not respond to chemotherapy or radiation. If asymptomatic, cholesterol granulomas of the petrous apex can be observed with serial imaging. Cholesteatomas of the petrous apex should always be removed unless the patient's medical status is too poor to undergo surgery.

DISCUSSION

Evidenced-Based Medicine Question

Question: Does placement of a drain or stent improve longer-term successful drainage of petrous apex cholesterol granulomas?

Answer: Placement of a drain into the cholesterol granuloma significantly lowers the rates of both reaccumulation (18% reaccumulate with a drain vs. 83% without) of the cholesterol granuloma and the need for reoperation. If a drain cannot be placed, full removal of the cyst wall with obliteration of the potential space using an adipose tissue graft or temporalis rotation flap is recommended.

Editorial Comment

The petrous apex approaches the midline of the skull base making safe access a potential challenge. The authors have pointed out that understanding the pathology helps to determine whether a cyst or granuloma should be drained or a tumor, such as an epidermoid, should be resected or exteriorized. Large epidermoid tumors have a higher incidence of persistence or recurrence due to difficulty in completely removing the entire tumor. Epidermoids have a tendency to line vessels and dura and insinuate between nerve fibers.

MRI and CT scans are complementary in the information they provide. They not only reveal the nature of the pathology, but provide a surgical strategy for accessing the tumor. Advances in expanded endoscopic transnasal surgery have significantly enhanced access options and control of the pathology. This is an enhanced skill set that is needed, especially if the carotid artery is to be mobilized. Procedures can connect the cyst cavity with the nasopharynx with a drainage tube emptying into a region that can be monitored endoscopically. This may not be as readily apparent with transmastoid procedures, because the catheter is medial to the tympanic membrane or in the mastoid cavity. The role of postoperative imaging remains critical in monitoring the status of the operative site. New imaging techniques using diffusion weighted sequences augment the sensitivity for differentiating recurrence of epidermoid tumor.

A close working relationship among the disciplines of radiology, otolaryngology, neurosurgery, anesthesiology and neurophysiology monitoring provide the resources to render a working diagnosis and surgical strategy for safely dealing with the pathology.

Barry Hirsch

Access the review questions and additional sources list online at http://www.expertconsult.com

REFERENCES

1. Chole RA. Petrous apicitis: surgical anatomy. Ann Otol Rhinol Laryngol 1985;94:251–257.
2. Myerson MC, Rubin H, Gilbert JG. Anatomic studies of the petrous portion of the temporal bone. Arch Otolaryngol Head Neck Surg 1934;20:192–210.
3. Moore KR, Harnsberger HR, Shelton C, et al. "Leave me alone" lesions of the petrous apex. Am J Neuroradiol 1998;19:733–738.
4. Arriaga MA, Brackmann DE. Differential diagnosis of primary petrous apex lesions. Am J Otol 1991;12:470–474.
5. Muckle RP, De la Cruz A, Lo WM. Petrous apex lesions. Am J Otol 1998;19:219–225.
6. Mosnier I, Cyna-Gorse F, Grayeli AB, et al. Management of cholesterol granulomas of the petrous apex based on clinical and radiologic evaluation. Otol Neurotol 2002;23:522–528.
7. de Souza CE, Sperling NM, da Costa SS, et al. Congenital cholesteatomas of the cerebellopontine angle. Am J Otol 1989;10:358–363.
8. King TT, Benjamin JC, Morrison AW. Epidermoid and cholesterol cysts in the apex of the petrous bone. Br J Neurosurg 1989;3:451–461.
9. Glasscock 3rd ME, Woods 3rd CI, Poe DS, et al. Petrous apex cholesteatoma. Otolaryngol Clin North Am 1989;22:981–1002.
10. Axon PR, Fergie N, Saeed SR, et al. Petrosal cholesteatoma: management considerations for minimizing morbidity. Am J Otol 1999;20:505–510.

REVIEW QUESTIONS

1. A cholesterol granuloma will have which characteristic features on MRI?
   a. Hyperintense on T1, hypointense on T2
   b. Hyperintense on T2, hypointense on T1
   c. Hyperintense on both T1 and T2
   d. Hypointense on both T1 and T2

2. Which approach is unsuitable for patients with high-riding jugular bulbs?
   a. Infracochlear approach
   b. Infralabyrinthine approach
   c. Middle fossa approach
   d. Transsphenoidal approach

3. Which of the following approaches will preserve hearing?
   a. Translabyrinthine
   b. Transcochlear
   c. Infracochlear
   d. Transotic

ADDITIONAL SOURCES

Chang P, Fagan PA, Atlas MD, et al. Imaging destructive lesions of the petrous apex. Laryngoscope 1998;108:599–604.

Ghorayeb BY, Jahrsdoerfer RA. Subcochlear approach for cholesterol granulomas of the inferior petrous apex. Otolaryngol Head Neck Surg 1990;103:60–65.

Glasscock 3rd ME. Middle fossa approach to the temporal bone. An otologic frontier. Arch Otolaryngol 1969;90:15–27.

Haberkamp TJ. Surgical anatomy of the transtemporal approaches to the petrous apex. Am J Otol 1997;18:501–506.

Hoa M, House JW, Linthicum Jr FH. Petrous apex cholesterol granuloma: maintenance of drainage pathway, the histopathology of surgical management and histopathologic evidence for the exposed marrow theory. Otol Neurotol 2012;33:1059–1065.

Hoa M, House JW, Linthicum FH, et al. Petrous apex cholesterol granuloma: pictorial review of radiological considerations in diagnosis and surgical histopathology. J Laryngol Otol 2013;127:339–348.

Lo WW, Solti-Bohman LG, Brackmann DE, et al. Cholesterol granuloma of the petrous apex: CT diagnosis. Radiology 1984;153:705–711.

Mattox DE. Endoscopy-assisted surgery of the petrous apex. Otolaryngol Head Neck Surg 2004;130:229–241.

Presutti L, Villari D, Marchioni D. Petrous apex cholesterol granuloma: transsphenoid endoscopic approach. J Laryngol Otol 2006;120:e20.

Sanna M, Dispenza F, Mathur N, et al. Otoneurological management of petrous apex cholesterol granuloma. Am J Otolaryngol 2009; 30:407–414.

Zanation AM, Snyderman CH, Carrau RL, et al. Endoscopic endonasal surgery for petrous apex lesions. Laryngoscope 2009;119:19–25.

144 Cerebrospinal Fluid, Otorrhea and Encephalocele

Esther X. Vivas

INTRODUCTION

Cerebrospinal fluid (CSF) leak of the temporal bone results from having a connection between the air-containing spaces of the temporal bone and the intracranial subarachnoid space. The connection is by way of defect(s) in the tegmen mastoideum or tegmen tympani with or without the presence of a concurrent encephalocele (Fig. 144.1) or meningoencephalocele. CSF collects in the middle ear and mastoid, and the egress of fluid is by way of a defect in the tympanic membrane or bony ear canal resulting in CSF otorrhea. With an intact tympanic membrane, fluid can drain down the Eustachian tube causing CSF rhinorrhea. The most common etiology of CSF otorrhea is a head injury with a fracture of the temporal bone, followed by iatrogenic injury or erosive changes from chronic otomastoiditis. Spontaneous or idiopathic CSF otorrhea is rare. In the pediatric population, CSF leaks are commonly associated with congenital malformations of the temporal bone. Congenital temporal bone CSF fistulas are rare and categorized as perilabyrinthine or translabyrinthine depending on the route of CSF transmission. These patients are more likely to present with meningitis or sensorineural hearing loss. Adults with spontaneous CSF otorrhea typically present with common otologic complaints of unilateral aural fullness or hearing loss, and typically have normal inner ear anatomy. As a result, the diagnosis can be elusive. A common initial diagnosis is chronic serous otitis media (CSOM). In this situation, a CSF leak becomes highly suspicious following myringotomy or placement of a tympanostomy tube. This often results in clear, watery otorrhea that is persistent and frequently pulsatile. Confirmation of the fluid as CSF can be achieved by obtaining an assay for beta-2 transferrin, which is highly sensitive and specific for detection of CSF, though vitreous and perilymph also contain the protein.[1] Meningitis with concurrent middle ear effusion is a rare and more serious presentation. Chronic intracranial hypertension, such as that seen with benign or idiopathic intracranial hypertension (IIH), is known to predispose to CSF leaks, including CSF otorrhea.[2] This syndrome is particularly prominent in obese, middle-aged women, and may be associated with headache, pulsatile tinnitus, and visual changes. There has been much investigation in trying to understand the mechanism for elevated ICP, and linking this process to the underlying pathophysiology seen in patients with IIH. Numerous reports have established an association between elevated intracranial pressure (ICP) and spontaneous CSF otorrhea.[3-7] Aberrant arachnoid granulations overlying the posterior fossa plate and the floor of the middle fossa potentially leading to bony erosion and CSF leak have also been reported in the literature. Unfortunately, due to the rare incidence of this disease, an established pathophysiology for spontaneous or idiopathic CSF leak is lacking. Patients with a history of chronic otitis can develop cholesteatoma that may erode into the otic capsule as well as through the middle or posterior fossa plates. Primary or metastatic malignant tumors to the temporal bone may also lead to bone erosion and CSF leak. In adults, the most common tumors are epithelial tumors and paragangliomas. In children, it is rhabdomyosarcoma.

Once the diagnosis is made, surgical repair is warranted because of the increased risk for developing central nervous system complications and infections, such as meningitis. An exception is CSF leak secondary to fractures of the temporal bone. Bed rest and elevation of the head results in spontaneous resolution in up to 90% of these patients; however, a lumbar drain (LD) may also be required with recalcitrant high volume leaks. Iatrogenic injury during mastoid or middle fossa surgery is typically recognized at the time, and immediate repair obviates subsequent management. The options for surgical repair vary according to the size and site(s) of the leak.[8,9]

KEY OPERATIVE LEARNING POINTS

1. CSF otorrhea may be acquired or spontaneous.
2. Imaging is essential in determining the size and location of a defect(s).
3. Regardless of the etiology, surgical repair is recommended, and the surgical technique is dictated by the site of the leak. An exception is CSF leak secondary to trauma, which typically resolves spontaneously.
4. All surgical repairs should employ a multilayer reconstructive technique, preferably with autologous tissue to minimize the chances of postoperative infection and foreign body reactions. The sources of anatomic materials include bone, free tissue grafts, or vascularized flaps
5. Surgical repair can be performed via transmastoid or middle fossa approaches or a combination of these. Obliteration of the middle ear may be required in particular circumstances.
6. Synthetic materials, such as bone cement substitutes also may be used in conjunction with autologous material.
7. CSF diversion via LD is often employed in the immediate postoperative period, especially in the repair of spontaneous middle fossa defects.
8. Intraoperative measurement of intracranial pressures may reveal elevated ICP in patients with spontaneous leaks, particularly in middle-aged obese women. However, pressures may be deceivingly normal as the result of active CSF egress through the defect.

PREOPERATIVE PERIOD

History

1. History of present illness
   a. Duration of symptoms; specifically ask about the duration of the hearing loss, aural fullness, or otorrhea.
   b. If otorrhea is present, has it responded to medical management such as topical drops or oral antibiotics?
   c. Is there concurrent rhinorrhea?
   d. Are the symptoms unilateral or bilateral?
   e. Determine if symptoms were spontaneous, insidious, or temporally related to trauma or surgery.
   f. Ask about the presence of headaches, particularly about morning headaches, stiff neck, or visual changes.
   g. Are there vestibular symptoms?
   h. Specifically ask about sound or Valsalva-induced vertigo.
   i. Is there pulsatile tinnitus?
2. Past medical history
   a. Ask about prior surgical interventions.
   b. Specifically ask about prior otologic or neurologic surgery.
   c. Is there a history of head trauma?

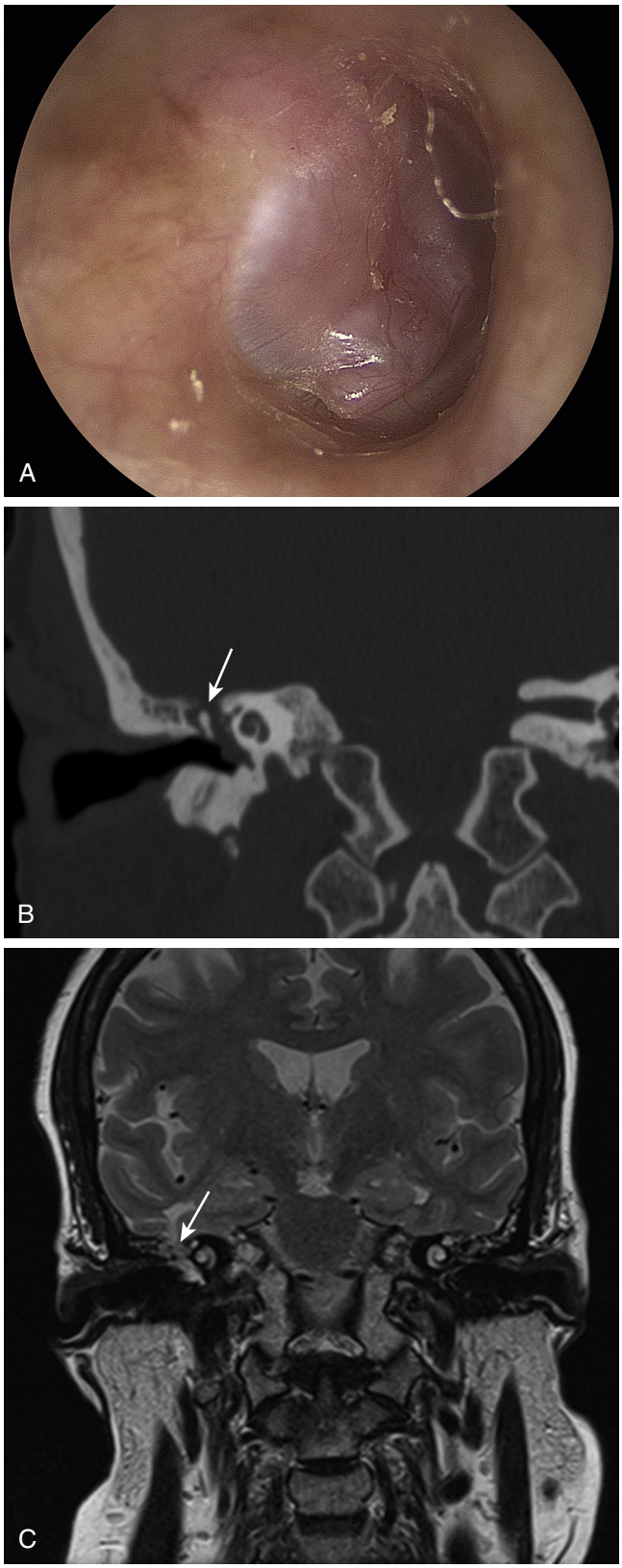

Fig. 144.1. A, Photo of a right ear canal. The tympanic membrane is bulging and pulsating due to the presence of an encephalocele. **B,** Coronal cut of a T2 weighted MRI image from the same patient, illustrating a right temporal lobe encephalocele into the middle ear. **C,** Coronal image of a CT of the temporal bones from the same patient. Image illustrates a tegmen tympani bony defect with right temporal lobe encephalocele into the middle ear.

d. Evaluate for history of chronic or recurrent otitis media.
e. Specifically elicit a history of meningitis.
f. Assess for history of malignancy.
g. Is the patient on anticoagulation therapy?

Physical Examination

1. Vital signs and body mass index (BMI) should be obtained.
2. A comprehensive examination of the head and neck should be performed, including thorough evaluation of cranial nerve function.
3. A tuning fork examination for the initial evaluation of hearing followed by comprehensive audiometry is essential.
4. Otomicroscopy is required to fully evaluate the tympanic membrane and middle ear.
5. The middle ear should be carefully inspected for the presence of fluid or mass lesions, such as encephaloceles (Fig. 144.1A).
6. Transmitted pulsations are often present.
7. CSF fluid is clear and at times difficult to see on examination; pneumatic otoscopy is helpful and may stimulate the formation of bubbles unmasking underlying fluid.
8. Diagnosis may be elusive, but usually becomes evident following a myringotomy, and manifests as clear watery otorrhea that is persistent and frequently pulsatile.
9. Assess for Tullio phenomenon in patients with vestibular complaints as there may be a concurrent superior semicircular canal (SSC) dehiscence.
10. If there is a tympanic membrane perforation or a pressure equalizer (PE) tube present, the most typical finding is pulsatile clear otorrhea. However, concurrent otitis media also may be present, making the initial diagnosis more difficult.
11. The fluid should be collected and sent off for B-2 transferrin assay.
12. Have the patient bend forward and place the head between their knees for several minutes as this may elicit CSF rhinorrhea.
13. If the tympanic membrane is intact and rhinorrhea cannot be elicited, consider aspirating middle ear fluid with a long 25G needle to obtain a specimen for B-2 assay.
14. Look for clear drainage in the posterior pharynx when performing the examination of the oral cavity.
15. A comprehensive eye examination for papilledema should be performed in patients with spontaneous CSF leak and risk factors for IIH.
16. A lumbar puncture can be performed pre- and postoperatively to identify elevated ICP in patients with spontaneous CSF leaks.

Imaging

Computed tomography (CT) of the temporal bones requesting thin axial and coronal reconstruction should be the initial imaging study obtained (see Fig. 144.1B).

Magnetic resonance imaging (MRI) w/wo contrast with T1 and T2 axial and coronal reconstructions through the temporal bones evaluates for cephalocele, and are complementary to CT images. Coronal FIESTA or constructive interface in steady state (CISS) sequences can depict CSF extrusion and brain herniation (see Fig. 144.1C).

Cisternography is no longer a routinely used imaging modality in the evaluation of these patients.

Indications

1. Nontraumatic CSF leaks should be addressed surgically unless the patient is deemed too frail and a high surgical risk.

2. Small defects of the tegmen mastoideum can typically be addressed with transmastoid approaches.
3. Multiple or large defects can be addressed with a middle fossa approach.
4. Tegmen tympani defects are best accessed with a middle fossa approach.
5. Defects in the otic capsule or tegmen mastoideum associated with chronic middle ear disease are approached in the standard tympanomastoid fashion.
6. In the absence of useful hearing, the middle ear may be obliterated and the ear canal closed.

Contraindications

1. Medical comorbidities with an unacceptable risk for general anesthesia.
2. Metastatic malignancy to the temporal bone.
3. Patients who cannot tolerate discontinuing anticoagulation therapy due to high cardiovascular risk.
4. CSF leaks secondary to temporal bone trauma should initially be managed conservatively.

Preoperative Preparation

1. Confirmation of CSF by way of a positive B-2 transferrin assay.
2. Preoperative comprehensive audiometry.
3. Preoperative videonystagmography (VNG) in patients with vestibular complaints.
4. Preoperative imaging is essential with CT *and* MRI as these are complimentary.
5. Ophthalmology evaluation for patients with risk factors for IIH.
6. Neurosurgical involvement is encouraged for a joint surgical team approach; particularly in the presence of large or multiple defects with an encephalocele(s) that will require a middle fossa approach.
7. Standard preoperative bloodwork including a coagulation profile.
8. Discontinue anti-platelet and anti-coagulant therapy in consultation with the patient's Primary care physician (PCP) or cardiologist.
9. Consult the neurophysiology service for intraoperative monitoring.

OPERATIVE PERIOD

Anesthesia

General: endotracheal intubation required, with nonparalyzing agents to allow for intraoperative cranial nerve monitoring.

Positioning

Transmastoid: supine with the head turned toward the contralateral ear.

Middle fossa: lateral decubitus or supine with a shoulder and hip bump, and Mayfield head holder (Fig. 144.2).

Perioperative Antibiotic Prophylaxis

Cephalosporin with adequate blood-brain barrier penetration; clindamycin and vancomycin are alternatives in patients who are allergic to penicillin.

Monitoring

Somatosensory evoked potentials (SSEP): this may be employed as per preference of the Neurosurgeon.

Electromyography (EMG): this is recommended with middle fossa or combined approaches, preferably administered by an electrophysiology service that is independent of the operating surgeon.

Facial nerve: this is recommended.

Auditory brainstem response (ABR): ipsi- and contralateral monitoring. This is recommended for complex or revision surgery, preferably administered by an electrophysiology service that is independent of the operating surgeon. If CSF is actively leaking through the ear, ipsilateral monitoring cannot be performed.

Instruments and Equipment to Have Available

1. Microscope
2. Otologic drill with irrigation system
3. Middle ear and mastoidectomy set
4. Middle fossa dura retractor
5. Electrophysiology monitoring device, such as nerve integrity monitoring system (NIMS) monitor with a Prass or Kartush probe or similar stimulator
6. Synthetic bone cement
7. Dural tissue homograft substitute
8. Fibrin glue
9. Titanium plating system to close the craniotomy defect
10. Surgical navigation device (helpful but is not essential)

Key Anatomic Landmarks

1. Temporal bone anatomy:
   a. Tegmen tympani and tegmen mastoideum
   b. Sinodural angle
   c. Semicircular canals
   d. Ossicular chain
   e. Tympanic and mastoid segment of the intratemporal facial nerve
2. Middle fossa floor anatomy:
   a. Arcuate eminence
   b. Greater superficial petrosal nerve (GSPN)
   c. Meatal plane over the internal auditory canal
   d. Middle meningeal artery
   e. Vein of Labbé
   f. Root of the zygoma noting the floor of the middle fossa.

Prerequisite Skills

1. Proficiency in temporal bone anatomy and tympanomastoidectomy
2. Proficiency in middle fossa anatomy, surgical approach, and techniques of repair.

Operative Risks

1. Intraoperative injury to the facial nerve
2. Intraoperative injury to the GSPN
3. Sensorineural hearing loss or deafness
4. Vertigo or disequilibrium
5. Conductive hearing loss from ossicular disruption or compression
6. Iatrogenic injury to the semicircular canals
7. Epidural or subdural hemorrhage
8. Iatrogenic CSF leak
9. Meningitis
10. Stroke

Surgical Technique

- Transmastoid approach is preferred for small lateral tegmen mastoideum defects:

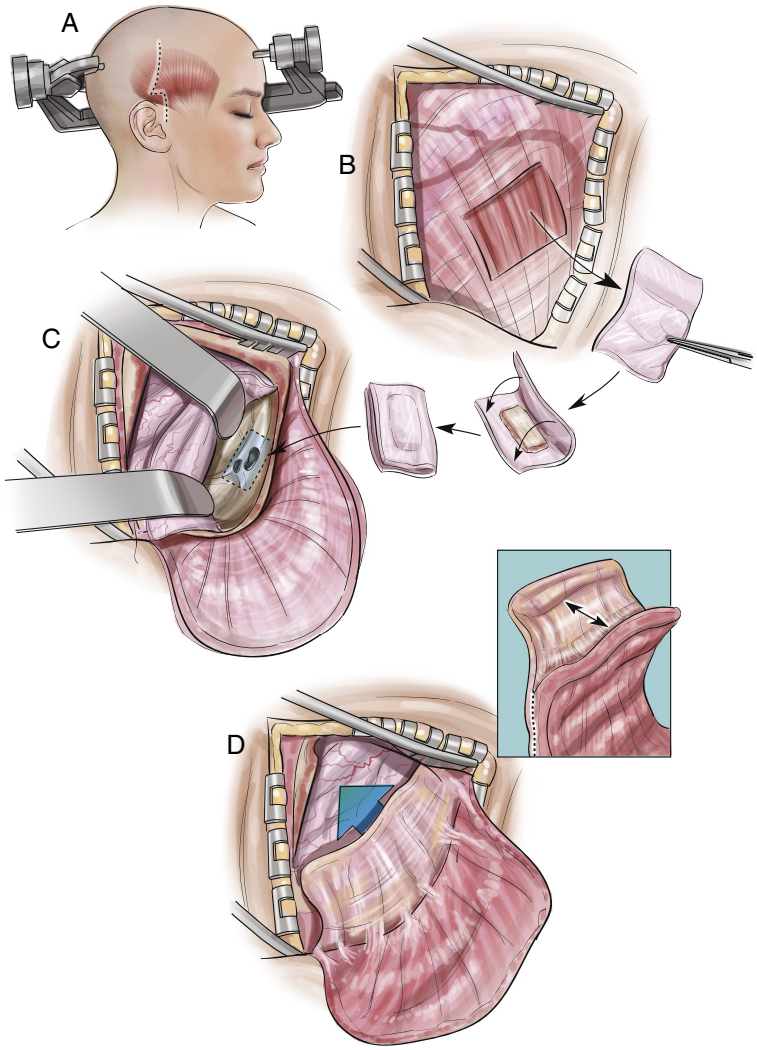

Fig. 144.2. Middle fossa surgical technique. Middle fossa craniotomy approach for reconstruction of tegmen defects with CSF otorrhea, including vascularized deep temporalis fascia-periosteal flap for multilayer closure. Once skin incisions **(A)** are made and the galea transected, a large piece of superficial temporalis fascia is harvested **(B)**. The temporalis muscle is carefully dissected in a subperiosteal fashion from an anterior to posterior direction, disconnecting it from the skull as far as possible posteriorly and superiorly. This maneuver preserves the temporalis muscle fibers and the blood supply to the periosteal layer of the deep temporal fascia. The temporalis muscle is then retracted inferiorly and anteriorly out of the field for later use. A middle fossa craniotomy and the dura of the inferior temporal lobe is dissected away from the middle fossa floor until the tegmen defect(s) are identified. Dissection is routinely done posterior to anterior along the tegmen floor, taking caution to preserve the greater superficial petrosal nerve, thereby avoiding traction on the geniculate ganglion. The locations of the defects are identified based on the preoperative studies and examination of the field, and are confirmed with image guidance, if available. Primary repair of the dura is dictated by the size, location, and integrity of the surrounding tissue. A thin piece of calvarial bone is harvested from the inner table of the craniotomy bone flap, wrapped in the superficial temporalis fascia, and draped directly over the bony defect(s) **(C)**. The final layer involves onlay of the vascularized deep temporalis fascia-periosteal flap. The flap is tucked medially as far as possible, and is splayed out over the surface area of the middle fossa bony floor covering the free superficial temporalis fascia and the bone graft **(D)**. The flap is sandwiched between the dura (and dural repair) of the temporal lobe and the bony repair. Finally, the craniotomy bone flap is replaced and secured, allowing adequate room anteroinferiorly to accommodate the vascular pedicle of the deep temporalis fascial flap. *(With permission from Vivas EX, McCall A, Raz Y, et al: ICP, BMI, surgical repair, and CSF diversion in patients presenting with spontaneous CSF otorrhea. Otol Neurotol, 2014 35:344-347.*

- Prep and drape the patient for a standard postauricular approach.
- Inject the postauricular region, incisura, and tragus with xylocaine and epinephrine.
- Harvest the fascia of the temporalis muscle and allow it to air dry.
- Perform a complete mastoidectomy.
- Identify the tegmen mastoideum, sinodural angle, sigmoid sinus, incus, and horizontal semicircular canal.
- Identify and preserve the facial nerve.
- Completely expose the tegmen defect(s).
- Perform a multilayer repair using a combination of autologous tissue, such as bone graft or bone pate, cartilage, and temporalis fascia.
- Surgicel can be placed over the completed repair.
- Fibrin glue can be used for reinforcement.

- Middle fossa approach is preferred when there are large or multiple defects along the tegmen mastoideum or if the tegmen tympani is involved. Large meningoencephaloceles are best managed through the middle fossa. It is

also used in the presence of canal wall down cavities. This should be a team effort in conjunction with neurosurgical colleagues:
  - An LD should be placed and ICP measured in patients with spontaneous leaks.
  - Prep and drape the patient for a middle fossa craniotomy.
  - Preserve the temporalis muscle and underlying fibroperiosteal layer.
  - Dissect the muscle off of the bone and retract anteriorly making sure to preserve the vascular pedicle.
  - Perform a craniotomy saving the bone for replacement with rigid plate fixation.
  - Expose the floor of the middle fossa with careful dissection using a posterior to anterior technique when elevating the dura.
  - Identify anatomic landmarks, such as GSPN and arcuate eminence.
  - The arcuate eminence/superior semicircular canal (SSC) is typically oriented perpendicular to the petrous ridge and 60 degrees from the internal auditory canal.
  - Maintain a high level of suspicion for SSC dehiscence in patients with numerous osseous defects and avoid direct suction over the area of the arcuate eminence.
  - Completely expose all osseous defects.
  - Reduce existing encephalocele(s) and perform appropriate repair of the dura.
  - Perform a multilayer repair of the tegmen plate using a combination of autologous tissue, such as bone graft or bone pate, cartilage, and temporalis fascia.
  - Vascularized tissue also can be used to create a pedicled deep temporalis fibroperiosteal flap.
  - Synthetic materials, such as bone cement, can be an adjunct to the repair, but should not be used independently.
  - Fibrin glue can be used for reinforcement.
  - A J-P drain under the temporalis muscle informs of a seroma or hematoma.
- Combined approaches may be required for complex defects and will require all or a combination of the techniques described above.
- Obliteration of the middle ear requires plugging of the Eustachian tube, removal of the middle ear contents, tympanic membrane, and ear canal skin. The meatus is oversewn and the middle ear cavity is filled with an abdominal adipose tissue graft.

Common Errors in Technique

1. Inadequate exposure of all osseous defects resulting in a persistent CSF leak.
2. Inadequate repair of defect(s), such as when performed with a single layer closure.
3. Lack of CSF diversion in the perioperative period in patients with spontaneous leaks and elevated ICP.
4. Aggressive elevation of dura resulting in iatrogenic tears, GSPN/facial nerve injury, trauma to the temporal lobe, or vascular injury.

POSTOPERATIVE PERIOD

Postoperative Management

1. Patients who undergo transmastoid approaches may be discharged the same day of surgery or after a night of observation, depending on medical comorbidities and the extent of the procedure.
2. Patients who undergo a middle fossa or combined approach should be observed in a monitored postoperative setting.
3. Neuro-checks should be performed routinely the first 24 hours and weaned as appropriate.
4. Postoperative CT of the head should be obtained to evaluate for subdural or epidural hemorrhage after middle fossa, or combined approaches if intraoperative bleeding was encountered or if an altered mental status develops.
5. If an LD was placed, it should remain open for 48 to 72 hours.
6. Bed rest while the LD is open.
7. The collection system of the LD should be maintained at shoulder level.
8. Patients should be instructed to avoid Valsalva maneuvers for 2 weeks after surgery.
9. Stool softeners may be used to help reduce Valsalva forces when needed.
10. Once the LD is clamped, the patient should be assessed for the presence of a persistent leak.
11. Transient aphasia may be present in patients who undergo the left middle fossa approach.
12. A high suspicion for seizures should be maintained after temporal lobe manipulation.
13. Seizure prophylaxis may be required.
14. Postoperative headache is common while the LD is open.
15. Following successful repair, consider repeating the lumbar puncture in a few weeks to assess for the return of increased intracranial pressure in those patients with spontaneous CSF leaks.

Complications

1. Persistent CSF leak
   a. This may develop from inadequate repair of the primary leak site, or alternatively from an unrecognized secondary defect. Wide exposure of the osseous defect(s) with multi-layer repair is the best way to prevent persistent leaks. Revision surgery may be required if an LD does not stop CSF egress.
   b. Persistent leaks raise suspicion for elevated intracranial pressures and may ultimately require CSF diversion.
2. Hearing loss
   a. Conductive hearing loss may occur from postoperative hemotympanum and undergo spontaneous resolution within weeks. Inadvertent dislocation of the ossicles can occur during surgical dissection and would require ossicular reconstruction. Ossicular fixation can occur if bone cement migrates into the middle ear and will require revision surgery. A hearing aid is a nonsurgical option for hearing rehabilitation of conductive hearing loss. A bone anchored hearing device (BAHA) is another option to address a conductive hearing loss. sensorineural hearing loss (SNHL) can result from iatrogenic injury to the SSC. This can be prevented by maintaining a high level of suspicion for a dehiscent SSC during dissection of the floor of the middle fossa and avoidance of direct suctioning over the area of the arcuate eminence. SNHL can also be sequelae of excessive manipulation or drilling of the ossicular chain. SNHL should be initially treated with an oral steroid taper for 7 to 10 days. Persistent hearing loss may be amenable to standard amplification.
3. Facial paresis/paralysis
   a. This may be secondary to inflammation, traction, or thermal injury. During middle fossa exploration, gentle dissection over the GSPN can reduce traction injury to the nerve. Thermal injury may also occur when using high-powered drills. Copious irrigation is the best prevention. Treat with 7 to 10 days of high dose oral steroids. Nerve transection requires immediate surgical

repair. Invasive facial reanimation procedures should be postponed for 12 months in the context of an anatomically intact nerve in order to wait for spontaneous recovery. Facial rehabilitation therapy is beneficial in the presence of synkinesis and hypertonicity.

4. Epidural or subdural hemorrhage; this may require evacuation
   a. Postoperative neurological checks in the immediate postoperative period is the best way to diagnose an evolving hemorrhage. Meticulous hemostasis during surgery is essential. Anticoagulants and aspirin products should be discontinued in the immediate pre- and postoperative period. Neurosurgical management is required if this complication occurs.
5. Meningitis
   a. Perioperative antibiotics and sterile techniques are the best preventative measures. If an active otitis is encountered the day of surgery, consider postponing the procedure. Keep the patient on antibiotic therapy postoperatively for 10 days if an active otitis is inadvertently encountered and the procedure cannot be aborted. If meningitis develops in the postoperative period, CSF culture should be obtained and broad spectrum antibiotics started until culture results are available. Neurological management is required if this complication occurs.
6. Brain abscess
   a. Perioperative antibiotics and sterile techniques are the best preventative measures. Immediate evacuation of the brain abscess is necessary. Fluid should be sent for culture and sensitivities, and broad-spectrum antibiotics started until the results are available. Neurosurgical management is required.
7. Stroke and aphasia
   a. Gentle manipulation with minimal traction of the temporal lobe is essential in preventing a stroke and aphasia. Neurological management is required if this complication occurs.
8. Seizures
   a. These may result from manipulation of the temporal lobe. Anticonvulsant therapy is required with slow taper. Neurological management is required if this complication occurs.

Alternative Management Plan

1. Patients who cannot undergo surgical repair should be treated with a diuretic, such as acetazolamide. Long-term management in this manner may not be successful.
2. Patients with persistent, recurrent, or new CSF leaks need to be evaluated for the presence of elevated ICP. If present, there may be a need for permanent CSF diversion with a shunt.
3. Recurrent temporal bone CSF leak following repair may require obliteration of the middle ear and mastoid.
4. Repair of a temporal bone CSF leak may unmask a CSF leak in the anterior or contralateral skull base, which will require a separate procedure.

DISCUSSION

The etiology of CSF leaks from the temporal bone differs between the pediatric and adult populations. In children, CSF leaks are more likely to be secondary to congenital malformations of the temporal bone, whereas adults are more likely to have suffered traumatic head injuries or the sequelae of chronic otitis or iatrogenic injury. Spontaneous CSF leaks from the temporal bone are rare in both populations. In adults they are associated with elevated BMI and benign intracranial hypertension. The treatment algorithm for CSF leaks involves surgical management, except for traumatic injuries because of the high rate of spontaneous resolution. Surgical management should be undertaken by those with proficient knowledge of temporal bone anatomy and who are comfortable with transtemporal and middle cranial fossa approaches. Optimal repairs include multilayer closure preferably with autologous tissue. Patients who are diagnosed with concurrent elevated intracranial pressures need to have the hypertension treated medically or with CSF diversion. Persistent intracranial hypertension poses a risk for recurrent leak or the development of a new leak at another site. Recent reports in the adult literature have highlighted an overall lower incidence of meningitis with spontaneous CSF temporal bone leak than previously thought.

Evidence-Based Medicine Question

Do adult patients with a spontaneous CSF leak have a higher incidence of developing meningitis? The authors cited below performed a retrospective review of patients who presented with spontaneous CSF leak or encephalocele over an 11-year period. They identified 12 adult patients (15 ears) with a documented duration of CSF leak ranging from 4 months to 11 years. None of the patients presented with meningitis during this time, except for one patient who developed meningitis secondary to a subarachnoid hemorrhage. This report is in contrast to the incidence of meningitis in the pediatric population, where spontaneous CSF leaks are likely from congenital malformations of the inner ear and present as recurrent episodes of meningitis. *Rao N, Redleaf M: Spontaneous middle cranial fossa cerebrospinal fluid otorrhea in adults.* Laryngoscope ***126(2):464-468, 2016.***[10]

Editorial Comment

Recognition of CSF otorrhea or rhinorrhea sets the otolaryngologist on a path to identify the source of the leak and to plan an efficacious and safe means of repair. The most common etiology of CSF otorrhea is temporal bone trauma. Fortunately, we rarely see iatrogenic cases of CSF leak following mastoid surgery. Spontaneous leaks are often identified following myringotomy tube placement for presumed serous otitis media. Once this has occurred, efforts are made to quickly evaluate patients and ideally obtain fluid for beta-2 transferrin assay. The relatively low incidence of subsequent infection (suppurative otitis media or meningitis) allows time for obtaining optimal imaging, consulting with other services (neurosurgery, ophthalmology), and planning for elective repair.

The author emphasized that the surgical technique should be comprised of a multilayer closure. Defects in the floor of the middle fossa can be reinforced with a bone graft taken from the temporal squamosal craniotomy and secured with temporalis fascia. If possible, a pedicled flap of fibro periosteum from the medial aspect of the temporalis muscle can be rotated into the defect to provide a vascularized covering of the compromised dura covering the temporal lobe.

Patients found to have increased intracranial pressure identified by a lumbar puncture obtained weeks after surgery require close surveillance. Acetazolamide may control borderline elevated pressures. A ventriculoperitoneal shunt may be necessary to avoid sequela of increased ICP, such as headaches, papilledema, and the development of a CSF leak from another location.

Barry Hirsch



REFERENCES

1. Skedros DG, Cass SP, Hirsch BE, et al. Beta-2 transferrin assay in clinical management of cerebral spinal fluid and perilymphatic fluid leaks. J Otolaryngol 1993;22:341–344.
2. Wang EW, Vandergrift 3rd WA, Schlosser RJ. Spontaneous CSF Leaks. Otolaryngol Clin North Am 2011;44:845–856, vii.
3. Prichard CN, Isaacson B, Oghalai JS, et al. Adult spontaneous CSF otorrhea: Correlation with radiographic empty sella. Otolaryngol Head Neck Surg 2006;134:767–771.
4. Brainard L, Chen DA, Aziz KM, et al. Association of benign intracranial hypertension and spontaneous encephalocele with cerebrospinal fluid leak. Otol Neurotol 2012;33:1621–1624.
5. Vivas EX, McCall A, Raz Y, et al. ICP, BMI, surgical repair, and CSF diversion in patients presenting with spontaneous CSF otorrhea. Otol Neurotol 2014;35:344–347.
6. Kari E, Mattox DE. Transtemporal management of temporal bone encephaloceles and CSF leaks: review of 56 consecutive patients. Acta Otolaryngol 2011;131:391–394.
7. Kenning TJ, Willcox TO, Artz GJ, et al. Surgical management of temporal meningoencephaloceles, cerebrospinal fluid leaks, and intracranial hypertension: treatment paradigm and outcomes. Neurosurg Focus 2012;32:E6.
8. Sanna M, Fois P, Russo A, et al. Management of meningoencephalic herniation of the temporal bone: Personal experience and literature review. Laryngoscope 2009;119:1579–1585.
9. Pelosi S, Bederson JB, Smouha EE. Cerebrospinal fluid leaks of temporal bone origin: selection of surgical approach. Skull Base 2010;20:253–259.
10. Rao N, Redleaf M. Spontaneous middle cranial fossa cerebrospinal fluid otorrhea in adults. Laryngoscope 2016;126(2):464–468.

REVIEW QUESTIONS

1. Surgical landmarks for the middle fossa approach include all of the following *except*:
   a. Meckel's cave
   b. Middle meningeal artery
   c. Vein of Labbé
   d. Arcuate eminence
   e. GSPN
   f. IAC

2. Complications from transmastoid CSF otorrhea repair include all *except*:
   a. Sensorineural hearing loss
   b. Conductive hearing loss
   c. Facial paralysis
   d. Persistent CSF leak
   e. Aphasia
   f. Meningitis
   g. Sigmoid sinus thrombosis

3. Spontaneous CSF leaks are:
   a. Most commonly seen in children
   b. Likely secondary to congenital malformations of the temporal bone in adults
   c. Resolve with conservative management
   d. Most commonly diagnosed in obese middle-aged women
   e. Most likely to present with meningitis in adults

4. Large or multiple osseous defects of the tegmen plate are best addressed with:
   a. Middle ear and mastoid obliteration
   b. Middle fossa approach with multilayer repair
   c. Transmastoid approach with multilayer repair
   d. Fibrin glue alone

5. Dehiscence(s) of the tegmen plate should always be repaired regardless of the presence of encephalocele or CSF leak:
   a. True
   b. False

145 Temporal Bone Trauma

C.Y. Joseph Chang

INTRODUCTION

Major head injuries can cause a variety of craniofacial fractures. Temporal bone trauma may occur as a result of blunt or nonpenetrating injury or a penetrating injury, such as gunshot wounds. The temporal bone contains several important structures, including the facial nerve, cochleovestibular nerve, labyrinth, ossicles, tympanic membrane, and internal carotid artery, that may be injured as a result of temporal bone trauma. If the force of trauma is strong enough, a fracture of the temporal bone may occur, which can injure these important structures, resulting in various functional deficits, including facial nerve dysfunction, hearing loss, dizziness, and cerebrovascular ischemic injury. Other associated sequelae include intracranial injuries such as hematoma, brain contusion, injury to the abducens nerve, and violation of the dura resulting in cerebrospinal fluid (CSF) leakage with increased risk of bacterial meningitis.

The management of trauma to the temporal bone typically occurs after initiation of trauma resuscitation for acute associated injuries, such as intracranial injury, vascular injury, thoracoabdominal injury, hemorrhage, shock, and other morbid events that require immediate medical or surgical attention. Injuries to the ossicular chain may require surgical management but are typically re-evaluated after several months using techniques described in Chapter 132 (Ossicular Chain Reconstruction). Sensorineural hearing loss and dizziness do not require acute surgical intervention unless there is a significant perilymphatic fistula. Lacerations of the ear canal usually heal spontaneously, but there is a risk of stenosis of the ear canal when severe damage is present in the skin of the ear canal. These cases are typically treated with placement of a wick or stent and steroid/antibiotic ear drops. The few cases that may result in stenosis or atresia of the ear canal can be managed surgically as described in Chapter on Ear Canal Stenosis Repair. The surgical management of CSF leak is described in Chapter 144 (Cerebrospinal Fluid Otorrhea and Encephalocele Repair).

This chapter will discuss in further detail the medical and surgical management of facial nerve injury. The management considerations will be based on a theory of disease based on limited data available at this time.

KEY OPERATIVE LEARNING POINTS

1. The bone overlying the facial nerve should be thinned and then gently fractured to remove the loosened bony fragments for atraumatic decompression of the facial nerve.
2. The labyrinthine segment of the facial nerve is located at the anterior-superior portion of the fundus of the internal auditory canal, which bisects the angle between the greater superficial petrosal nerve (GSPN) and superior semicircular canal (SSCC).
3. Granulation tissue along the facial nerve fracture site should not be dissected aggressively in order to avoid iatrogenic injury to the facial nerve.

PREOPERATIVE PERIOD

History

1. History of present illness
   a. Penetrating versus nonpenetrating injury
   b. Onset and status of facial nerve dysfunction: This information helps in the stratification of patients' prognosis for recovery and helps determine who may benefit from surgical intervention.
      1) Normal after injury with delayed palsy or paralysis
      2) Immediate onset palsy or paralysis
      3) Progression of palsy or paralysis over time
   c. Presence of other craniofacial and intracranial injuries
2. Past medical history
   a. Prior facial nerve dysfunction such as Bell's palsy. There may be fewer neurons functioning, even if the facial function returned to normal and lead to poorer prognosis for recovery after the current injury.
   b. Prior ear or mastoid surgeries
   c. Prior intracranial procedures
   d. Diabetes

Physical Examination

1. Facial nerve evaluation: House-Brackmann grading scale is typically used
2. Otologic evaluation
   a. Tympanic membrane
      1) Perforation
      2) Hemotympanum
      3) CSF otorrhea
   b. Ear canal
      1) Laceration
      2) Hemorrhage
   c. Surrounding soft tissue
      1) Battle's sign—Postauricular ecchymosis
   d. Tuning fork
   e. Balance evaluation
      1) Gait
      2) Tandem gait
      3) Romberg test
3. Rhinologic evaluation
   a. CSF rhinorrhea
4. Audiologic evaluation
   a. Pure tones
   b. Speech discrimination scores
   c. Tympanogram
5. Electrophysiological studies
   a. Electroneuronography (ENoG)
   b. Electromyography (EMG)

Imaging

Computed tomography (CT) temporal bone—The presence of temporal bone fracture can be confirmed. The locations of probable Fallopian canal fracture sites can also be determined.

Indications for Decompression Surgery

1. Patients with a poor prognosis for good facial nerve functional recovery. This includes patients with the clinical findings of immediate onset facial paralysis, immediate onset facial palsy with progression to paralysis, or those with unclear facial function at onset with progression to paralysis, in addition to ENoG showing greater than 95% denervation and EMG showing no voluntary motor potentials.
2. Timing—As early as possible, within 12 to 14 days of injury
3. Patient has no contraindication to surgery based on medical status and coexisting injuries.
4. Some physicians may consider CT findings regarding indication for surgery, but the main indication for surgery remains prognosis for facial nerve recovery based on clinical course and electrical testing.
5. Patients who remain unconscious after injury during the 12- to 14-day window for possible facial nerve decompression surgery represent a significant dilemma, as the degree of facial nerve injury cannot be adequately determined. It may be that most of these patients are not good candidates for facial nerve surgery due to the severity of their intracranial injuries. As there are no data correlating the CT findings to the probability of spontaneous facial nerve recovery, it may be prudent not to consider facial nerve surgery in these patients during the acute postinjury period.

Indications for Decompression Surgery

1. Evidence of facial nerve transection based on poor facial nerve recovery over 6 to 8 months or high likelihood of facial nerve transection based on clinical presentation
2. Timing—Facial nerve repair may be contemplated as early as the traumatic acute inflammatory changes have subsided, typically 4 weeks after injury, if the presence of facial nerve transection has been established.

Contraindications

1. Medical comorbidities and/or injuries with increased risk for general anesthesia

Preoperative Preparation

1. Ensure that any brain injury has not progressed.
2. Confirm status of hearing.
3. Obtain and review facial nerve electrical tests to confirm that there is no volitional movement.

OPERATIVE PERIOD

Anesthesia

- General: This procedure requires general anesthesia; no paralytic agents if direct facial nerve stimulation is anticipated

Positioning

- Supine: The patient is positioned the same as for any otologic procedure, with the head turned away from the surgeon. If a middle fossa craniotomy is performed, the vertex of the head will also need to be accessed. A shoulder roll and hip bump may be necessary if neck rotation is limited.

Perioperative Antibiotic Prophylaxis

- First-generation cephalosporin: The antibiotic regimen is the standard perioperative regimen for clean, noncontaminated surgery.
- Clindamycin or vancomycin if patient is allergic to penicillin

Monitoring

- Auditory brainstem response (ABR)—For intracranial procedure
- Somatosensory evoked potential (SSEP)—For intracranial procedure
- A lumbar drain can be placed at the time of middle fossa surgery to relax the temporal lobe prior to retracting it. The drain is removed at the end of surgery.
- An alternative or supplement is to administer mannitol 1 g/kg and furosemide 40 mg given 30 minutes prior to temporal lobe retraction.
- Dexamethasone 12 mg is given for nausea prophylaxis and reduction of intracranial edema.

Instruments and Equipment to Have Available

1. Standard otologic surgery set
2. Otologic drill
3. Standard craniotomy set with standard retractors for middle fossa cases
4. Operating microscope

Key Anatomic Landmarks

1. Standard mastoidectomy landmarks
   a. Horizontal semicircular canal (HSCC)
   b. Tegmen tympani
   c. Facial recess
   d. Stylomastoid foramen
   e. Cochleariform process
   f. Oval window niche
2. Standard middle fossa landmarks
   a. SSCC
   b. GSPN
   c. Meatal plane leading to the internal auditory canal

Prerequisite Skills

1. Tympanoplasty with mastoidectomy, facial recess
2. Middle fossa craniotomy
3. Knowledge of the anatomy of the floor of the middle fossa

Operative Risks

1. Intracranial and extradural hemorrhage
2. Dysphasia related to temporal lobe retraction
3. Seizures related to retraction of the temporal lobe
4. Injury to the inner ear related to unplanned fenestration or ossicular injury
   a. Conductive hearing loss
   b. Sensorineural hearing loss
   c. Dizziness
5. CSF leak due to injury of the dura

Surgical Technique

Total facial nerve decompression can be performed using one of two approaches: the combined middle fossa craniotomy and transmastoid approach and the translabyrinthine approach. The middle fossa craniotomy typically results in

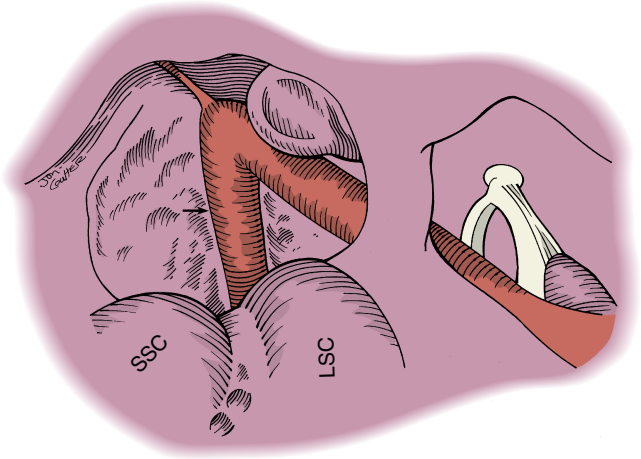

Fig. 145.1. Transmastoid approach for total facial nerve decompression, right side. The incus has been removed in this case. *SSC,* Superior semicircular canal; *LSC,* lateral semicircular canal.

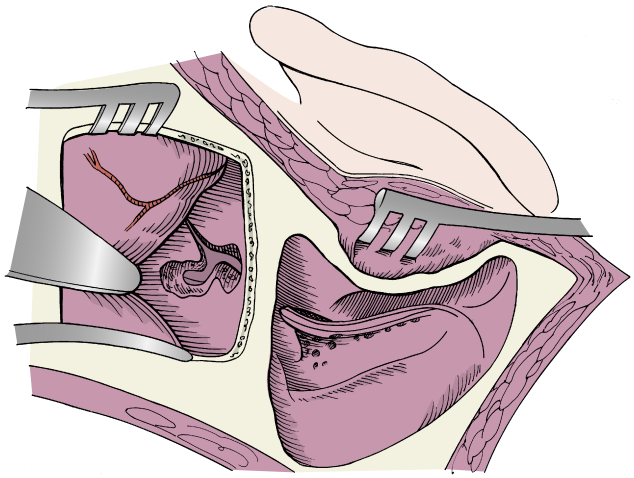

Fig. 145.2. Combined middle fossa and transmastoid approaches for total facial nerve decompression, right side.

preserved hearing, so it is indicated for patients who have usable sensorineural hearing function and those who are medically fit to undergo middle fossa craniotomy. The translabyrinthine approach violates the otic capsule, which results in complete deafness on the ipsilateral side. Therefore this approach is appropriate for patients with no usable ipsilateral hearing function and adequate contralateral vestibular function. The advantage of this approach is that it avoids any intracranial brain retraction.

Transmastoid, Middle Fossa Craniotomy Approach—Hearing Preservation

- Standard mastoidectomy with facial recess dissection is performed (Chapter 134: Mastoid Surgery). The incus may need to be dislocated temporarily after separation of the incudostapedial joint, or the incus may have to be removed for access. The incus buttress may be left intact in most cases (Fig. 145.1).
- The facial nerve is skeletonized from the second genu to the stylomastoid foramen. Care is taken to leave a very thin "eggshell" layer of bone over the facial nerve.
- The thin bone overlying the nerve is gently fractured using a curved pick (Rosen needle), and the bone fragments are removed.
- The epineurium of the nerve is not disturbed.
- Standard middle fossa craniotomy approach (Chapter on Acoustic Neuroma). A cranial flap is turned to expose the middle fossa dura (Fig. 145.2).
- The middle fossa dura is elevated to the level of the meatal plane over the internal auditory canal (IAC). Care is taken to dissect from posterior to anterior to prevent injury to the geniculate portion of the facial nerve. Anterior to posterior dissection could result in inadvertent elevation of the GSPN with the dura to the geniculate resulting in a traction injury to the facial nerve.
- The SSCC and GSPN are identified. The SSCC may be blue-lined to confirm location of the canal lumen.
- The area medial to the SSCC and GSPN is drilled to the IAC dura, which is skeletonized using a diamond burr toward the meatal foramen and labyrinthine segments of the facial nerve.
- The labyrinthine segment and meatal foramen are skeletonized with the diamond bur using copious irrigation. It is technically challenging to leave a thin bone lining that can be fractured with a pick in this area.

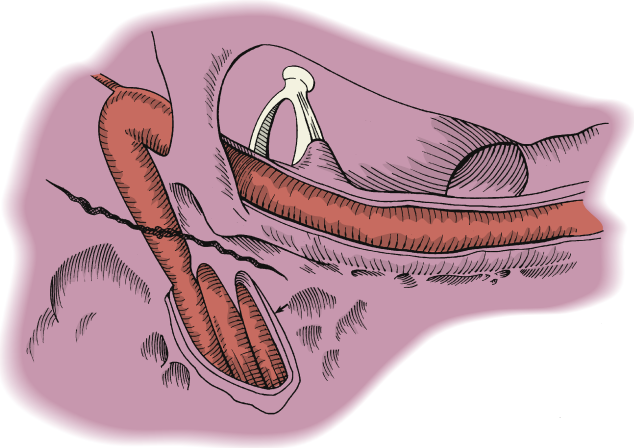

Fig. 145.3. Transmastoid translabyrinthine approach for total facial nerve decompression, right side.

- The basal turn of the cochlea is just medial to the labyrinthine and geniculate segments of the facial nerve, so care is taken to avoid drilling into this area.
- The tegmen tympani is drilled open with the diamond bur and the malleus head, incus body, horizontal facial nerve, and anterior portion of the HSCC are identified.
- The geniculate and horizontal segments of the facial nerve are decompressed from this approach.
- If the incudostapedial joint was separated, the incus is replaced back in position with application of Gelfoam to stabilize its position as needed.
- The cranial bone flap is replaced and fixated with a cranial plate and screw system.
- Standard closure of the mastoid and craniotomy incisions

Translabyrinthine Approach—No Useful Hearing

- The standard translabyrinthine bony dissection is performed (Fig. 145.3; see Chapter 140).
- After skeletonizing the vertical segment of the facial nerve and drilling through the labyrinth, the labyrinthine segment of the facial nerve can be found just medial to the ampullated end of the superior semicircular canal.

- The meatal segment to the lateral IAC and the geniculate can be decompressed at this stage.
- The horizontal segment can be decompressed from the medial and superior side to the second genu and then down along the vertical segment in the standard fashion. Care should be taken to avoid CSF leak through the IAC dura.
- The closure is performed with application of a muscle plug in the aditus ad antrum, waxing of all exposed mastoid air cells, and placement of an adipose tissue graft into the mastoid.

Facial Nerve Grafting

- The surgical approach is similar to those used for the facial nerve decompression.
- The facial nerve repair typically requires use of a nerve graft, since a significant segment of the injured facial nerve may be fibrosed and require resection. The greater auricular nerve is typically used. A sural nerve may also be used, but its diameter may be too large for use in the labyrinthine segment.
- A tension-free repair is critical for maximal axonal regrowth across the anastomoses. In most cases, the medial portion of the bony Fallopian canal can be preserved to allow for a suture-free repair by laying the nerve graft into the fallopian canal trough and stabilizing the repair with Gelfoam packing or tissue glue. The nerve graft should be made slightly longer than the length of the nerve defect to reduce the risk of separation at the anastomosis during the healing process.
- A standard suture repair may also be used to augment the repair, typically using 8-0 or 9-0 nylon or other monofilament suture for an epineurial anastomosis.
- An anastomosis of the facial nerve in the IAC is technically challenging. Usually only a single suture through the center of the nerve end is feasible.

Common Errors in Technique

1. If there are areas of inflammation and granulation along the course of the facial nerve where the fallopian canal has been disrupted, aggressive dissection in these areas should be avoided in order to minimize iatrogenic injury to the facial nerve. Visualization is very difficult in these areas so an iatrogenic facial nerve transection can occur.
2. Inadequate decompression of the labyrinthine segment and meatal foramen portions of the facial nerve if a middle fossa craniotomy is not performed
3. Failure to separate the incudostapedial joint in cases where the horizontal facial nerve cannot be decompressed without trauma to the incus
4. In facial nerve repair, the use of an inadequate length nerve graft or technical failure of repair may cause failure of the repair due to tension at the anastomosis.
5. Fenestration of the cochlea or superior semicircular canal during facial nerve decompression through the middle fossa approach
6. Injury to the middle fossa or IAC dura with CSF leak

POSTOPERATIVE PERIOD

Postoperative Management

1. Standard neurosurgery intensive care monitoring overnight
2. Monitor for intracranial complications and CSF leak.
3. Apply eye lubricating drops and ointments for patients with lagophthalmos.
4. Audiogram at 1 month postoperatively
5. Oral steroids may be given for 2 weeks: prednisone 60 mg per day for 10 to 14 days; then a 6-day taper.
6. Monitor facial nerve function over the next year.

Complications

1. Intracranial hemorrhage: The patient requires an immediate CT with possible placement of ventricular drain and return to the operating room for evacuation of hematoma if necessary.
2. CSF leak: Lumbar drainage for 3 days. If there is persistent leak, the patient will need a surgical repair as described in Chapter 144 (CSF Otorrhea).
3. Dizziness: Most patients will recover without treatment, but some may need vestibular physical therapy for prolonged imbalance. Acute vertigo may be managed with vestibular suppression with benzodiazepines or meclizine and antiemetic medications.
4. Persistent conductive hearing loss may be managed with ossicular reconstruction or a hearing aid.
5. Persistent sensorineural hearing loss may be managed with a hearing aid.
6. Severe to profound hearing loss may be managed with contralateral routing of signals (CROS) aid or osseointegrated implant (bone anchored hearing aid (BAHA) or Ponto).

Alternative Management Plan

1. Observation: Some patients have medical contraindications for surgery or decline surgery. Some patients are not evaluated for surgical facial nerve decompression until after the time window for decompression has passed. The efficacy of the facial nerve decompression is not fully understood, as discussed in a later section.
2. Delayed facial nerve decompression has been done, but its true efficacy and theoretical efficacy remain in doubt, as discussed in a later section.
3. Steroid treatment: High-dose treatment with steroids typically causes generalized reduction in inflammation and edema, so it could be considered as a noninvasive treatment option, although there are no data regarding efficacy.

DISCUSSION

Temporal Bone Fracture Classification

There has been an evolution in the classification of temporal bone fractures. In the past, the fractures were classified as either longitudinal or transverse. In practice, many fractures are comminuted and cannot often be classified well into one or the other category. A more modern classification divides fractures into otic capsule sparing and otic capsule penetrating injuries (Fig. 145.4A and B).[4] Most fractures can be classified as one or the other. In addition, there is a higher risk of sensorineural hearing loss, facial nerve injury, and CSF leak with otic capsule penetrating injuries, so there is some clinical utility to the use of this classification system. Penetrating fractures can also be classified using this classification, although the risk of facial nerve injury is high regardless of the classification of these injuries.

Evidence-Based Medicine Question

How effective is the combination of ENoG and EMG in predicting facial nerve recovery in patients with facial nerve paralysis due to temporal bone trauma?

The data regarding the prognostic value of ENoG for temporal bone trauma are extremely limited and are mostly extrapolated from data regarding Bell's palsy. Limited data

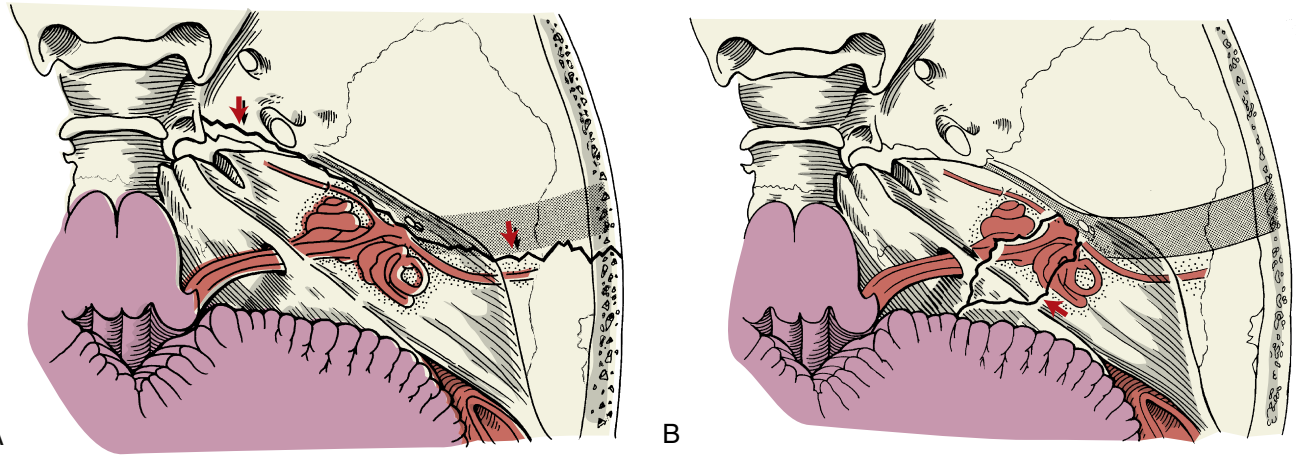

Fig. 145.4. A, Figure showing otic capsule sparing temporal bone fracture. *Red arrows* point to fracture line. **B,** Figure showing otic capsule penetrating temporal bone fracture. *Red arrow* points to fracture line.

suggest that less than half of patients with poor ENoG findings within 14 days of injury will have poor recovery of facial nerve functions.[5] The addition of poor EMG findings could increase the odds of poor facial nerve outcome, but the degree to which this is true remains unknown.

What is the efficacy of surgical facial nerve decompression?

The data regarding outcomes after facial nerve decompression surgery are difficult to determine, but roughly 50% or slightly more have a good outcome with HB 1 to 2 function.[1] It is unclear how much better these results would be if a similar cohort underwent non-surgical treatment.

What is the efficacy of steroid treatment?

There are no substantial published data regarding the effect of steroid treatment for traumatic facial nerve injury.

Editorial Comment

The evaluation and management of temporal bone trauma encompasses signs and symptoms related to hearing, balance and facial nerve function and assessing the integrity of the dura. CT imaging of the temporal bone should be obtained to assess the status of the otic capsule, pneumatized regions of the middle ear and mastoid, intracranial space and carotid artery. Identification of conductive hearing loss is managed expectantly since the loss from blood or other secretions in the middle ear typically resorb resulting in resolution. Immediate onset sensorineural hearing loss is often permanent. Imaging may show penetrating fracture going through the otic capsule or, rarely, air in the vestibule. Acute vestibular insult often improves within a few weeks due to central compensation. Persistent clear otorrhea raises suspicion of a cerebrospinal fluid leak which can be confirmed by testing for the beta-2 transferrin protein. Most traumatic leaks stop within a week suggesting conservative observation initially be followed.

This chapter focuses on the controversial management of injury to the facial nerve. There is limited substantiated scientific basis for the definitive medical or surgical intervention. In the presence of complete paralysis the electrical status of the facial nerve is assessed by electroneuronography and electromyography. The interpretation of the electrical test results have been correlated with management recommendations in place for idiopathic facial paralysis (Bell's palsy). The indications for facial nerve intervention in temporal bone trauma have been extrapolated from those ascribed for management of the facial nerve in surgical decompression in Bell's palsy. Experience over time has demonstrated that delayed onset facial paralysis following temporal bone trauma typically results in good to excellent recovery. Patients with unknown timing or immediate onset facial paralysis, if neurologically and medically stable, should undergo temporal bone imaging and electrical testing to identify the possible site of trauma and the electrical status of the degree of injury. This electrical test may need to be done serially to identify possible deterioration of neural function raising consideration for exploration and repair or decompression. At minimum, the results of electrical testing should provide prognosis for anticipated recovery.

Barry Hirsch

General Considerations

The facial nerve can be injured as a result of penetrating or nonpenetrating temporal bone trauma. Penetrating temporal bone trauma with facial nerve paralysis, such as those due to gunshot wounds, has a high incidence of facial nerve transection. In these patients, surgical intervention to repair the facial nerve is typically performed soon after the injury. Facial nerve injury due to nonpenetrating temporal bone trauma is typically due to edema of the facial nerve in response to the trauma. As the nerve becomes edematous within the Fallopian canal, ischemic nerve injury occurs. In theory, surgical decompression and removal of the bone of the Fallopian canal overlying the facial nerve should be helpful in reducing the level of injury. Based upon limited human histopathology data in temporal bone trauma cases, the edema and ischemia of the facial nerve extend throughout the fallopian canal and appear to be most severe at the narrowest areas of the canal, specifically the labyrinthine segment and meatal foramen, regardless of the site of the fracture. If this is indeed the case, facial nerve decompression must include not only the primary site of injury but also the entire length of the fallopian canal.[1]

The goal then becomes reduction of the progressive ischemic injury to minimize facial nerve fibrosis and allow the injured facial nerve axons to regenerate. If facial nerve decompression is contemplated, it must be done over in a timely fashion. Based on limited data from surgical decompression performed for the treatment of Bell's palsy and limited data on temporal bone trauma,[2] the time window may be as short as 12 days, after which the injury becomes irreversible and refractory to further treatments. One must also keep in mind that there are no definitive studies that show that facial nerve decompression has any efficacy in these cases for temporal bone trauma.[3]

Access the review questions and additional sources list online at http://www.expertconsult.com

REFERENCES

1. Chang CYJ, Cass SP. Management of facial nerve injury due to temporal bone trauma. Am J Otolaryngol 1999;20:96–111.
2. Hato N, Nota J, Hakuba N, et al. Facial nerve decompression surgery in patients with temporal bone trauma: analysis of 66 cases. J Trauma 2011;71(6):1789–1792.
3. Nash JJ, Friedland DR, Boorsma KJ, et al. Management and outcomes of facial paralysis from intratemporal blunt trauma: a systematic review. Laryngoscope 2010;120(7):1397–1404.
4. Little SC, Kesser BW. Radiographic classification of temporal bone fractures: clinical predictability using a new system. Arch Otolaryngol Head Neck Surg 2006;132(12):1300–1304.

REVIEW QUESTIONS

1. Possible sequelae of temporal bone trauma do not include
   a. Facial nerve injury
   b. Hearing loss
   c. Dizziness
   d. Cerebrospinal fluid
   e. Hypoglossal nerve injury

2. Evaluation of facial nerve injury does not include
   a. Facial nerve grading
   b. ENoG
   c. EMG
   d. CT
   e. Magnetic resonance imaging (MRI)

3. The area of the facial nerve at most risk of ischemic injury is
   a. Labyrinthine
   b. Geniculate
   c. Horizontal
   d. Vertical
   e. Extratemporal

4. Which of the following surgical approaches can preserve the ossicular chain?
   a. Transmastoid approach
   b. Transmastoid transfacial recess approach with temporary packing of the middle ear and eustachian tube
   c. Temporal bone obliteration with closure of the ear canal and eustachian tube
   d. a and b
   e. a and c

ADDITIONAL SOURCES

Brodie HA, Thompson TC. Management of complications from 820 temporal bone fractures. Am J Otolaryngol 1997;18(2):188–197.

McCutcheon BA, Orosco RK, Chang DC, et al. Outcomes of isolated basilar skull fracture: readmission, meningitis, and cerebrospinal fluid leak. Otolaryngol Head Neck Surg 2013;149(6):931–939.

146 Surgery for Vertigo

Peter Weber, Elizabeth Toh

INTRODUCTION

Surgery for vertigo is typically a treatment of last resort, whether due to a peripheral or central etiology. The vast majority of patients may be managed conservatively with medical treatment and/or vestibular rehabilitation therapy. Critical to the management of patients with vertigo is the correct diagnosis of the underlying pathology. The small percentage of patients who fail maximal medical management may benefit from surgery. It is imperative that the correct side is also identified. Surgical options include those that address the specific pathology of the disease, as well as those that ablate the peripheral vestibule or organ. This chapter describes operative techniques for posterior semicircular canal (PSC) occlusion; endolymphatic sac decompression, with or without shunting; labyrinthectomy; vestibular nerve section; and vascular loop decompression. Repair of superior canal dehiscence (SSCD) and treatment for acoustic neuroma are discussed in Chapters 149 and 142, respectively.

KEY OPERATIVE LEARNING POINTS

1. Surgery is indicated only for control of disabling vestibular symptoms in patients with peripheral or central vestibulopathy with failed maximal medical treatment and vestibular rehabilitation.
2. Vestibular ablation is typically contraindicated in those patients with bilateral peripheral or central vestibulopathy.
3. The retro sigmoid and retromastoid are the preferred approaches for vestibular nerve section in patients with aidable hearing in the affected ear.
4. The PSC should be fenestrated midway between the ampulla and the common crus for PSC occlusion to minimize the risk of violating the vestibule and causing sensorineural hearing loss (Fig. 146.1).
5. Ablation of the vestibular inner ear in the presence of bilateral peripheral vestibulopathy may result in disabling oscillopsia.
6. Suctioning in the vicinity of a fenestrated or dehiscent semicircular canal may result in disruption of the membranous labyrinth and cause postoperative sensorineural hearing loss.
7. Incomplete removal of the sensorineural epithelium within the PSC ampulla is the most common cause of persistent vertigo following labyrinthectomy.

PREOPERATIVE PERIOD

History

- Determine the frequency, duration, sidedness, symptoms, and length of time affecting the patient to help make the diagnosis.
- History of migraines, motion intolerance, family history, and visual disturbances should be elicited.
- History of seizures should be asked as well as cardiovascular disease.
- History of trauma should be assessed.
- Current and past medications should be assessed.
- Tinnitus is non-specific unless characterized as being pulsatile. The evaluation should include glomus tumor, dural AV arteriovenous malformations, meningoceles, SSCD superior semicircular canal dehiscence, aneurysms, vascular loops, and dehiscent high riding jugular bulb.

Physical Examination

- Office vestibular testing can usually evaluate benign positional vertigo (BPPV), hypoactive systems, vestibular ocular reflex (VOR) pathology, perilymph fistula, and acute vertiginous attacks.
- Postural hypotension may be important to eliminate.
- Pneumotoscopy should not cause vertigo or nystagmus. If present, consider perilymphatic fistula (PLF) or possibly SSCD.

Audiogram

- Early Meniere syndrome typically manifests low-frequency sensorineural hearing loss on the affected side. Progression of disease results in a greater flat SNHL sensorineural hearing loss.
- SSCD may demonstrate a conductive loss due to the third window effect, and loud noise may cause "dizziness" (Tullio phenomenon).
- Labyrinthectomy may be offered to those with severe to profound SNHL. Caution and informed consent should be provided to patients with functional hearing who are offered intratympanic gentamicin therapy. Up to 30% of patients may experience further hearing loss following gentamicin injections.

Vestibular Testing

- Videonystagmography (VNG) can be useful in identifying the "weak" side or bilateral weakness. Identifying bilateral weakness is important as it may preclude vestibular ablation surgery.
- Vestibular evoked myogenic potential (VEMP) testing can be useful in identifying SSCD or indicate the side of the lesion.
- Dix-Hallpike maneuver is used to make the diagnosis of BPPV.

Imaging

- Magnetic resonance imaging (MRI) with gadolinium is important to assess for central lesions or inflammation of the vestibular nerve(s) or cranial nerves.
- Computed tomography (CT) of the temporal bone in the coronal plane best highlights the SSCD (see Chapter 149).

Consultation With

- Cardiology may be indicated to evaluate for arrhythmias (Holter monitoring), autonomic dysfunction (tilt table testing), or other abnormalities.
- Neurology may be indicated for evaluation for a central etiology including headaches, seizures, and TIAs transient ischemic attacks.

- Psychiatry may be especially beneficial as many of these patients may suffer from depression or anxiety.

Indications

BPPV–Posterior Canal Plugging

- Offer surgery only after particle repositioning maneuvers by trained therapists or MDs Meniere's disease fail to control symptoms that significantly affect the life of the patient. Less than 1% of patients require surgical intervention.[1]
- Surgical success rates are over 90%.
- Must ensure the proper canal has been identified prior to surgery

Contraindications

Surgery in the elderly carries the potential development of vestibulitis, which can incur the unintended consequence of severe disequilibrium. This more chronic disorder is worse than the BPPV. The elderly with dysfunction of the inner ear are more prone to repeated falls and fractures.

Do not operate if the affected ear is the only hearing ear.

Preoperative Preparation

Verify that the planned operative procedure is being done on the identified malfunctioning semicircular canal.
Document hearing levels.
Document that a VNG was performed and rotary chair testing, if available, is obtained.
Explain the risks and ensure realistic expectations, including that disequilibrium may occur after the surgery.
Review imaging to ensure that no other pathology is present as the source for unrelenting positional vertigo.

OPERATIVE PERIOD

Anesthesia

General anesthesia is preferred, and the patient should not be paralyzed during the operative procedure so that cranial nerve 7, as well as other cranial nerves, can be monitored if the need arises.

Positioning

- The patient is turned 180 degrees from anesthesia so that the surgeon is on the side of ear to be operated and the scrub nurse on the opposite side with the microscope at the head of the table.
- For the suboccipital or retrosigmoid approach the patient is typically put in neurosurgical pins and a Mayfield holder. Depending on the ability to turn the neck, an ipsilateral shoulder and hip bolster may help in providing access.

Perioperative Antibiotic Prophylaxis

IV cefazolin; clindamycin for patients who are allergic to penicillin

Steroids

Typically 10 mg IV of Decadron for adults is given, which helps reduce postoperative vertigo and nausea.

Monitoring

Neurophysiology monitoring usually includes the facial nerve. For hearing preservation procedures the cochlear nerve is monitored. Somatosensory potentials are observed for intracranial procedures.

Instruments and Equipment to Have Available

- Microscope
- Mastoidectomy instrument set
- Neurosurgical instruments for intracranial procedures
- Otologic drill
- Facial nerve dissector and stimulator

Key Anatomic Landmarks

The lateral semicircular canal (LSC) is key. It is also important to understand the relationship of the facial nerve to the PSC and the sigmoid sinus.

Prerequisite Skills

Knowledge of temporal bone anatomy and experience, not only operating in this area but managing the potential complications

Operative Risks

- Pain
- Bleeding (including the sigmoid sinus)
- Infection (including meningitis)
- Hearing loss in the operated ear that can be partial or total; sensorineural loss is more common but conductive loss could also occur
- Facial paresis and paralysis
- Loss of taste sensation on the tongue
- Tinnitus
- Vertigo or disequilibrium that can be temporary or permanent
- CSF (leak cerebrospinal fluid leak)
- Seizure, stroke, death

Surgical Technique

BPPV—Posterior Canal Plugging

- The patient is prepped and draped as for standard mastoid surgery.
- A cortical mastoidectomy using a postauricular incision is done followed by identifying the LSC, incus, tegmen, and, typically, the sigmoid sinus.
- Saline-soaked Gelfoam pledget can be placed in the antrum to reduce the amount of blood and bone dust entering the middle ear space.
- The PSC lies directly posterior and perpendicular to the LSC.
- A diamond bur is used to skeletonize and blue-line the PSC so that a 1 × 3-mm oval window of bone over the mid-portion of the PSC is opened to expose, but not violate, the membranous labyrinth within the opened SCC (Fig. 146.1).
- The opened semicircular canal can be plugged with bone wax, bone dust, or connective tissue and then covered with fascia.
- If the membrane is violated, the canal is still packed.
- Suction should be avoided.
- Closure is per surgeon's choice.

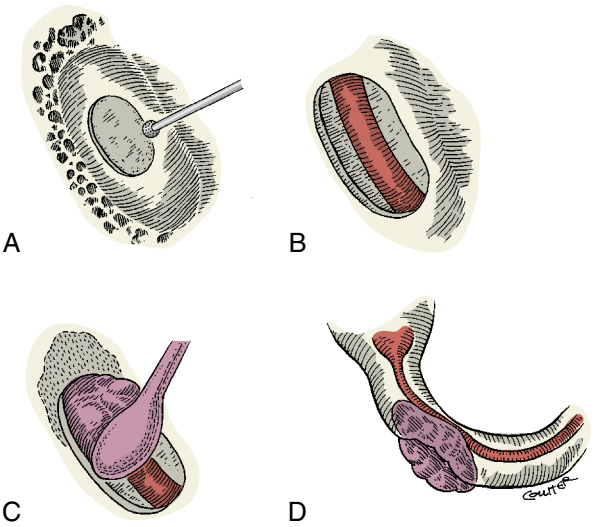

Fig. 146.1. Technique for posterior semicircular canal. A, Skeletonization of mid-portion of posterior semicircular canal (PSC) using small diamond bur. **B,** PSC fenestrated without violating membranous labyrinth. **C,** Bone wax, bone paste, or soft tissue is applied to the fenestrated portion of the PSC using a duckbill elevator. **D,** The membranous labyrinth within the PSC is compressed and occluded.

SURGERY: MENIERE

Endolymphatic Sac Decompression Shunt

- Offered only when the patient fails maximal medical therapy, including intratympanic steroid injections
- Maximal medical therapy includes treatment of identified vertiginous triggers such as migraine, allergy, stress, and diet.
- This remains an excellent choice of surgical options since it spares the vestibular system (important to many who have jobs or hobbies that require good balance), typically spares hearing, and postoperative recovery time is often brief.
- Vertigo symptoms are typically relieved in approximately 60% of patients.[2-4]
- As with all surgery for Meniere disease, fluctuating and progressive hearing loss, aural fullness, and tinnitus may persist.
- The patient is prepped and draped as for standard mastoid surgery.
- A standard postauricular incision is made followed by a cortical mastoidectomy, identifying the LSC, incus, tegmen, and sigmoid sinus.
- Saline-soaked Gelfoam pledgets can be placed in the aditus ad antrum to reduce the amount of blood and bone dust entering the middle ear space.
- The endolymphatic sac lies on the dura between the PSC and the sigmoid sinus and is consistently inferior to "Donaldson's Line"—an imaginary line extending posteriorly from the parallel plane along the LSC.
- The facial nerve is identified in the vertical segment.
- The sigmoid sinus is skeletonized and decompressed as necessary.
- The posterior fossa dural plate between the PSC and sigmoid sinus is removed and then followed up to and medial to the facial nerve as necessary (Fig. 146.2).
- The endolymphatic sac appears as thickened dura in a fan shape and can be followed anteriorly under the PSC to identify the operculum and endolymphatic duct.
- Decompression is now complete.

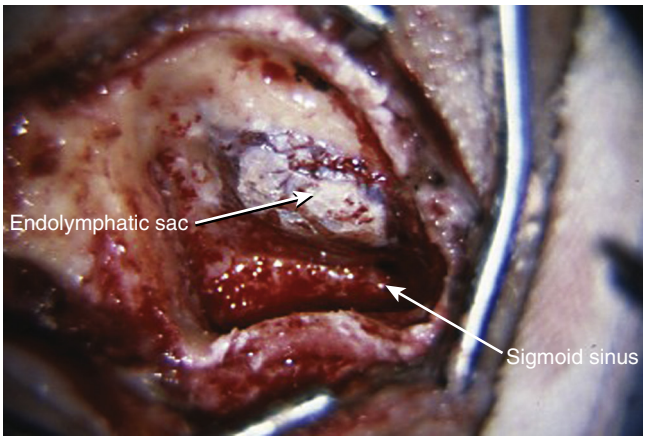

Fig. 146.2. The dura of the posterior fossa is widely exposed. The endolymphatic sac is visible as a thickening of the dura fanning out from the posterior semicircular canal to the sigmoid sinus.

- The dura can be elevated and the sac remain tented away from the bone of the posterior fossa by placement of Surgicel superior and inferior to the sac.
- To place a shunt, a small narrow piece of 0.005 inch-Silastic sheeting is cut to size. The sac is opened with a Beaver blade of choice, and the lateral walls are separated and the shunt is positioned.
- Closure is per surgeon's choice.

Labyrinthectomy

- Reliably controls the vertigo associated with Meniere greater than 95% of time[5]
- Destroys all the hearing, thus not recommended for patients with functional aided hearing
- Can be combined with a cochlear implant if indicated
- Patients require vestibular rehabilitation postoperative to aid in balance compensation.
- Patients should know that this may preclude them from functioning at heights, climbing ladders, or other activities that require critical balance.
- Elderly patients typically have a more difficult time compensating.
- All five sensory epithelia end organs have to be removed to achieve success.
- The patient is prepped and draped per standard mastoidectomy protocol.
- The LSC, incus, tegmen, and sigmoid sinus are identified.
- Perilabyrinthine air cells are removed to further expose the PSC and SSC.
- Identify the horizontal and vertical portions of the facial nerve.
- The LSC is first opened from superiorly to inferiorly in order to protect the facial nerve. It is opened posteriorly to the PSC (Fig. 146.3).
- The PSC is then opened and followed anteriorly and inferiorly taking care to protect the medial portion of the vertical segment of the facial nerve.
- Keeping the inferior wall of the PSC intact can protect a high riding jugular bulb.
- The PSC is followed superiorly to the common crus where it joins the non-ampullated end of the SSC.
- The SSC is then followed superiorly and anteriorly taking care to leave the superior wall intact to protect the tegmen.
- The vestibule is then opened, exposing the neurosensory epithelium of the superior and lateral ampullae.

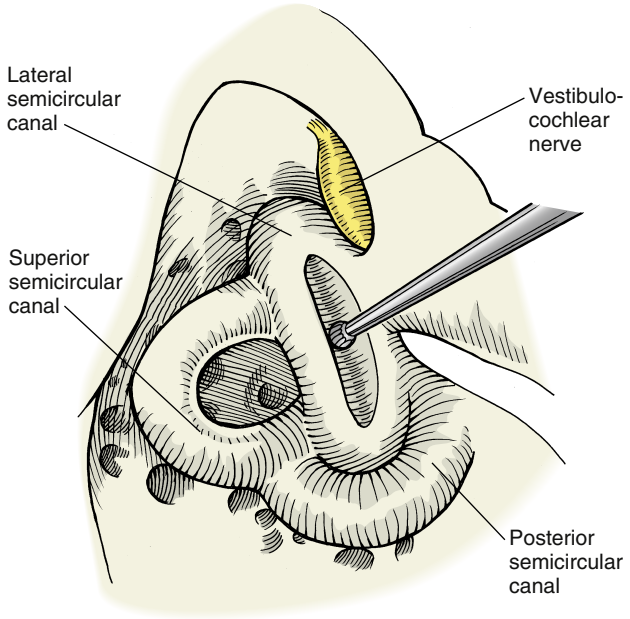

Fig. 146.3. The superior wall of the lateral semicircular canal is removed. The inferior wall is left intact to protect the facial nerve.

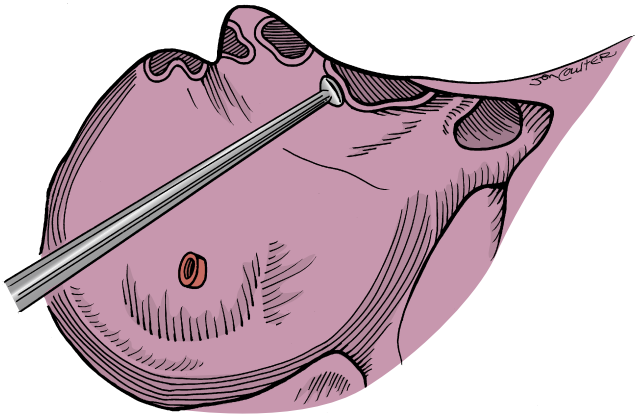

Fig. 146.4. The five areas of neurosensory epithelium are exposed and removed systematically using a round knife or microcurette.

- The neuroepithelium of the ampulla of the PSC lies medial to the vertical (mastoid) segment of the facial nerve. Specific efforts are needed to ensure removal. The medial wall of the vestibule is left intact to protect the internal auditory canal (IAC) and prevent CSF leaks.
- The neuroepithelium is removed from all five vestibular end organs (Fig. 146.4).
- Closure is per surgeon's choice.

Vestibular Nerve Section—Retrolabyrinthine

- Patients should know that this may preclude them from functioning at heights, climbing ladders, or other activities that require critical balance. Elderly patients typically have a more difficult time with vestibular compensation.
- Vestibular nerve section reliably controls the vertigo associated with Meniere greater than 95% of time.[5,6]
- Patients require vestibular rehabilitation postoperatively to aid in central compensation.

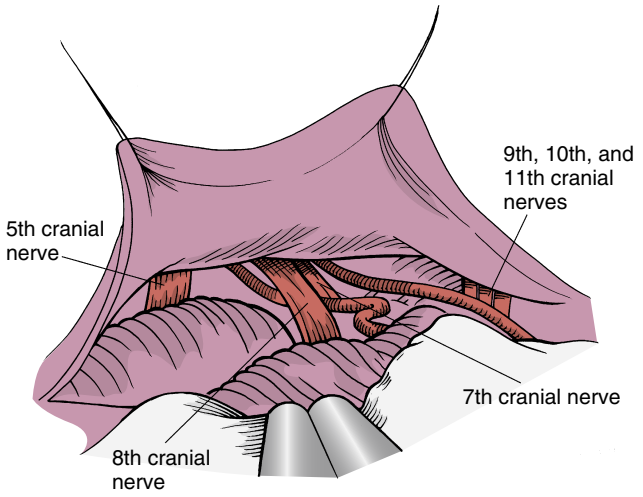

Fig. 146.5. Retrolabyrinthine exposure of the posterior fossa.

- The hearing preservation rate is greater than 95%.[6]
- The patient is prepped and draped for the standard mastoidectomy surgery.
- The incision is placed 2 to 3 cm posterior to the ear crease from the area above the temporal line to the mastoid tip.
- An anterior skin flap is elevated, and then a large Palva flap or T-based flap is elevated.
- A complete mastoidectomy is performed exposing the LSC, incus, tegmen, sigmoid sinus, PSC, and SSC.
- A Gelfoam-soaked pledget can be placed in the antrum.
- Bone over the posterior cerebellar dura, sinodural angle, and tegmen is removed with drill and/or bony elevators and bone biting forceps.
- The endolymphatic sac is preserved.
- The dura is then opened, anterior to the sigmoid sinus and posterior to the PSC via a C- or U-shaped flap.
- The cerebellum is protected with a ½ by 3-cm neuropatty, and the cerebellopontine cistern is opened to drain CSF.
- As the cerebellum falls away, the CP cerebellarpontine angle is opened, exposing the seventh and eighth cranial nerve complex (Fig. 146.5).
- The location of CN VII is confirmed with electrical stimulation.
- The cleavage plane between the auditory and vestibular portions of CN cranial nerve VIII is identified, typically demarcated by a small vessel and a subtle difference in color (the auditory portion is whiter) (Fig. 146.6).
- The vestibular portion is also superior to the auditory portion in the CP angle and then rotates within the IAC such that the auditory portion is anterior to the vestibular nerve and inferior to the facial nerve. The inferior and superior vestibular nerves lie posterior to the facial and auditory nerves in the IAC.
- Using a blunt dissector like a ball dissector or Rhoton the two portions are separated (Fig. 146.7).
- Typically a curved bayonet microscissors or nerve knife is used to cut the vestibular nerve, exposing the nervus intermedius (Fig. 146.8).
- Finally, a small portion of the nerve is removed so that the ends do not reapproximate and lead to recurrence of vertigo/disequilibrium.
- Hemostasis is assured, the neuropatty removed, and the dura reapproximated and covered with Tisseal to prevent CSF leak. If the dura cannot be closed, homograft substitution dura can be used as well.
- Fascia can be used to seal off the antrum, and the mastoid can be packed with abdominal adipose tissue.

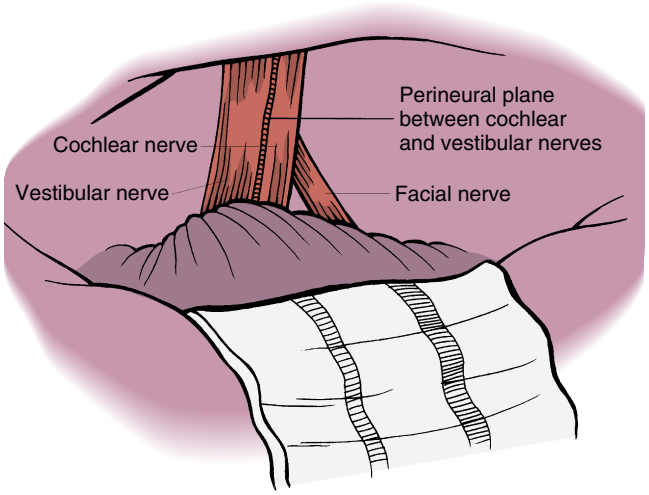

Fig. 146.6. A perineural plane between the cochlear and vestibular nerves is frequently demonstrated by a small vessel or a slight depression in the nerve running longitudinally on the dorsal surface of the nerve.

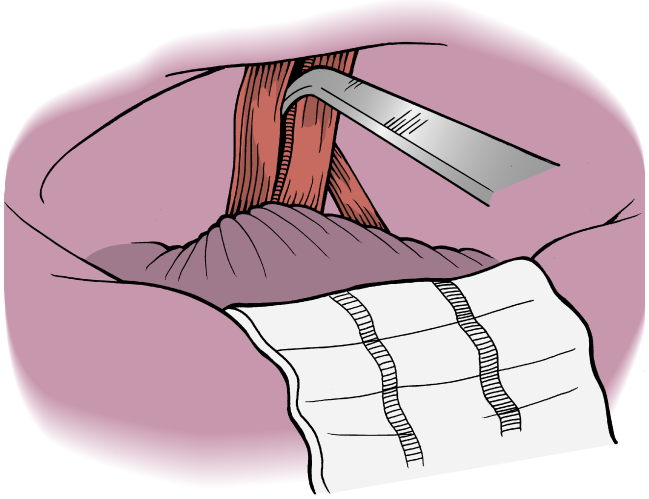

Fig. 146.7. Separation of the cochlear and vestibular nerves.

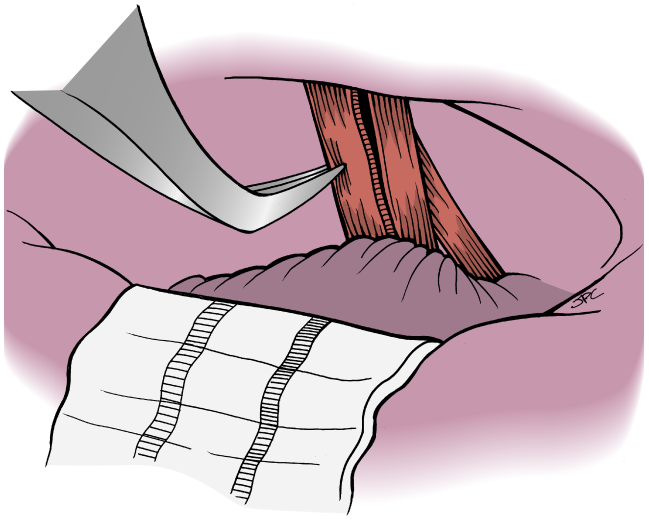

Fig. 146.8. The vestibular nerve is divided, starting from the superior-dorsal surface of the eighth cranial nerve.

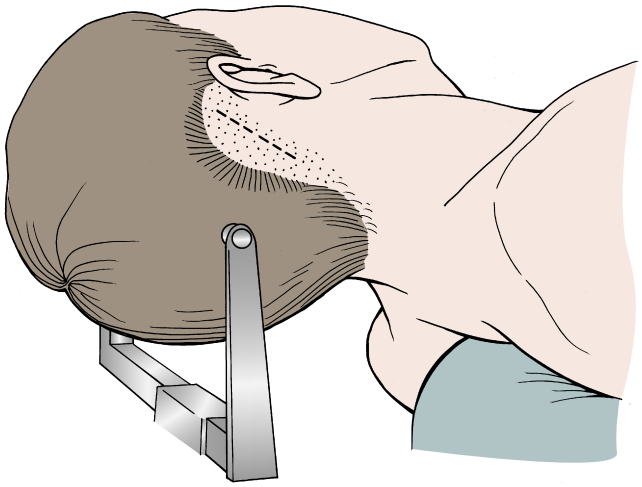

Fig. 146.9. The skin incision for a retrosigmoid vestibular nerve section.

- Closure is per surgeon's choice.
- Patients typically are hospitalized until the severe vertigo subsides.

Retrosigmoid Vestibular Nerve Section

- Patients should know that this may preclude them from functioning at heights, climbing ladders, or other activities that require critical balance. Elderly patients typically have a more difficult time with vestibular compensation.
- Nerve section reliably controls the vertigo associated with Meniere greater than 95% of time.[5]
- Patients require vestibular rehabilitation postoperatively to aid in compensation.
- The hearing preservation rate is greater than 95%.[6]
- The patient is typically placed in the supine position with the head secured with pins and a Mayfield head holder.
- A soft roll may be placed under the shoulder to help position the head flexed about 45 degrees down and rotated away to expose the surgical site.
- Some neurosurgeons may infuse mannitol to lower intracranial pressure.
- The incision is made obliquely from the posterior superior position toward the mastoid tip. The site of the incision is planned over the location of the sigmoid sinus, which can be determined by neural navigation systems (Fig. 146.9).
- These incisions and subsequent craniotomies have decreased in size over time.
- The incision is carried down to the periosteum, and the anterior and posterior flaps are elevated making sure to occlude the mastoid emissary vein if encountered.
- The courses of the sigmoid and transverse sinuses are either estimated or marked out with the use of neural navigation systems (Fig. 146.10).
- The small craniotomy is then made (1.5 to 2 cm), sometimes exposing the posterior portion of the sigmoid sinus.
- Hemostasis is obtained. Exposed mastoid air cells are occluded with bone wax. The C- or U-shaped flap in the dura is opened.
- From this point, the steps are the same as outlined in the retrolabyrinthine approach.
- To minimize postoperative headaches, the small craniotomy can be filled with a plug of bone dust and chips wrapped in Surgicel or by replacing the craniotomy bone flap.

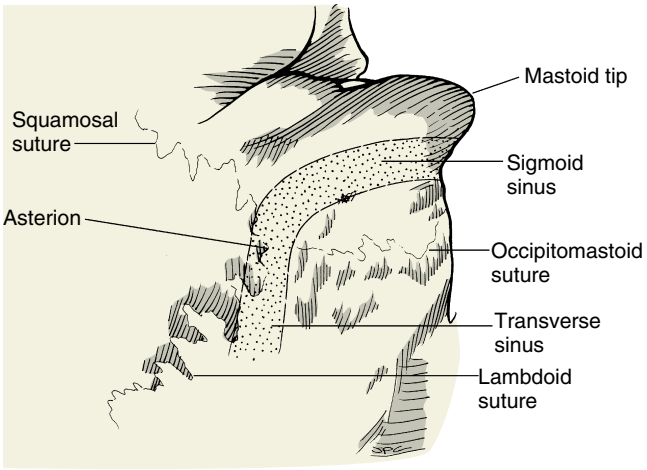

Fig. 146.10. The surface anatomy of the mastoid and retrosigmoid cranium and the estimated course of the transverse and sigmoid sinuses.

- Some surgeons use surgical plates or hydroxyapatite cement.
- The incision is closed per surgeon's choice.
- The patient is admitted until the severe vertigo subsides.

Middle Fossa Approach for Vestibular Nerve Section

- Patients should know that this may preclude them from functioning at heights, climbing ladders, or other activities that require critical balance. Elderly patients typically have a more difficult time with vestibular compensation.
- Reliably controls the vertigo associated with Meniere greater than 95% of time
- Patients require vestibular rehabilitation postoperatively to aid in compensation.
- The hearing preservation rate is greater than 95%.
- The reported advantage of this approach is that the superior, inferior, and singular portions of the nerve can be identified to increase complete nerve section.
- The disadvantages of this approach include significant temporal lobe retraction and increased risk to auditory and facial nerves, as well as headaches, compared to the other two approaches.
- The patient is supine with the head turned to expose the side to be operated on.
- Mannitol may be used to decrease intracranial pressure.
- Many incisions can be used to expose the needed cranium. I prefer an anteriorly based skin flap and a posteriorly based temporalis flap. However, the most common incision is a vertical incision extending superiorly from a pretragal skin crease inferior to the zygoma to the temporal line. Once the cranium is exposed, the craniotomy is marked out to be 4 × 5 cm such that two-thirds of the opening is anterior to the EAC and one-third is posterior (Fig. 146.11).
- The craniotomy is accomplished with a ball bur on a surgical drill or with craniotomy bur holes connected with a straight bit used with a footplate attachment.
- The bone flap is removed and saved in antibiotic solution to be replaced when closing the surgical exposure.
- Bipolar cautery is used to control bleeding.
- The dura is then elevated off of the floor of the middle fossa (Fig. 146.12), such that the middle meningeal artery is seen anteriorly, the tip of the petrous ridge medially, and the arcuate eminence posteriorly.

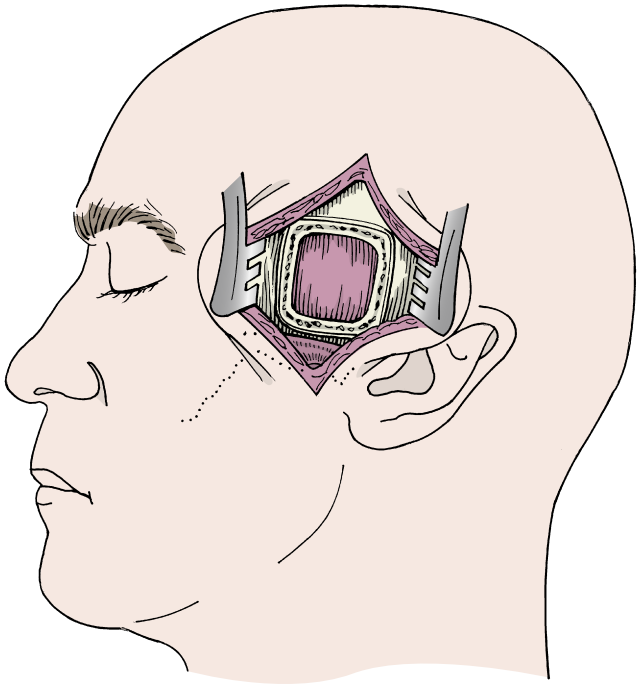

Fig. 146.11. Middle fossa craniotomy.

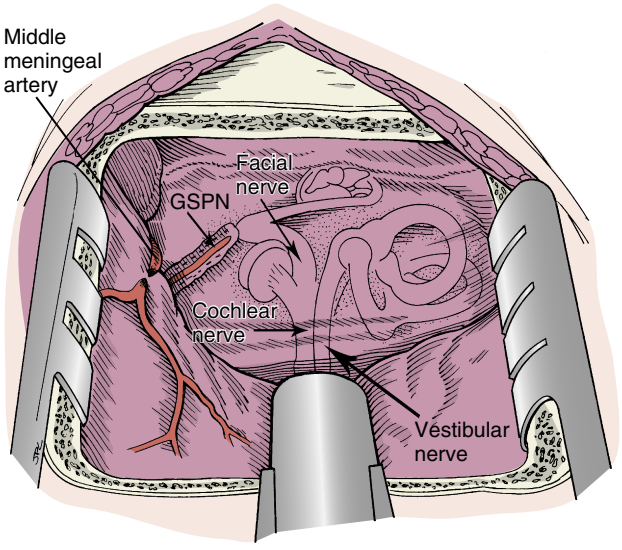

Fig. 146.12. Anatomy of the middle fossa floor. *GSPN*, Greater superficial petrosal nerve.

- Care is taken not to stretch or traumatize the greater superior petrosal nerve (GSPN) during elevation as this is the most common way to injure the facial nerve.
- A self-retaining middle fossa retractor is placed, and the location of the IAC is estimated by bisecting the angle formed by the GSPN and the arcuate eminence. In addition, neural navigation can readily pinpoint the IAC.
- The IAC is then exposed by drilling off the surrounding bone starting medially and working laterally, taking care not to injure the basal turn of the cochlea (Fig. 146.13).
- Bill's bar, which separates the facial nerve anteriorly from the superior vestibular nerve posteriorly, is exposed at the fundus.
- The dura of the IAC is opened, exposing the nerves within the IAC. The superior nerve is sectioned and reflected me-

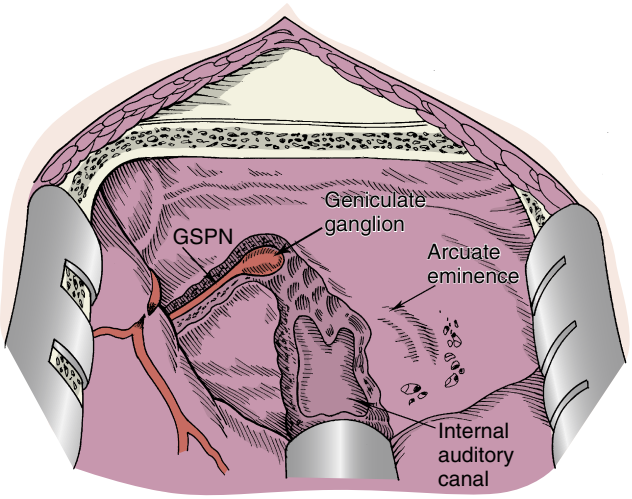

Fig. 146.13. Exposure of the internal auditory canal. *GSPN*, Greater superficial petrosal nerve.

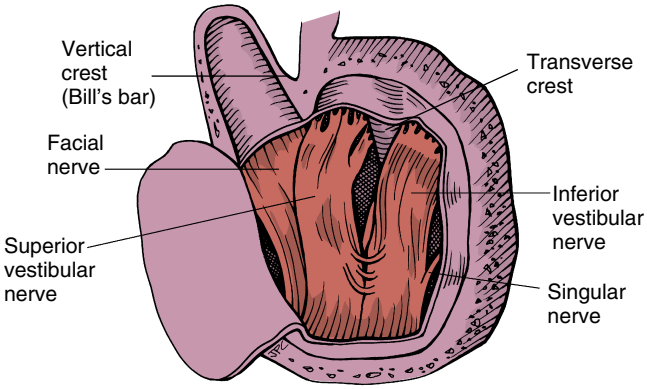

Fig. 146.14. The transverse crest and Bill's bar are exposed at the fundus of the internal auditory canal. The dura of the internal auditory canal is opened. The facial, superior vestibular, inferior vestibular, and singular nerves are identified.

dially to expose the inferior vestibular nerve, which is sectioned along with the singular nerve.
- Scarpa's ganglion is also removed.
- The dural flaps are reapproximated, and a free muscle plug is placed, the temporal lobe is allowed to re-expand, and the craniotomy bone flap is plated into place.
- Closure per surgeon's choice

Translabyrinthine Vestibular Nerve Section

- This is a very rare approach and only considered if a traditional labyrinthectomy fails.
- The goal is to remove Scarpa's ganglion, which could also be done via a middle cranial fossa approach.
- This additional entry into the IAC carries an increased risk of facial nerve injury and CSF leak.
- The initial surgery is the same as with labyrinthectomy as that provides the surgical approach. The lateral portion of the IAC is then exposed by drilling the bone covering the IAC away in a 270-degree fashion.
- The superior limit is the ampulla of the SSC. The transverse crest separating the superior and inferior vestibular nerves is identified.
- The dura is opened, and the nerves exposed (Fig. 146.14).
- The superior nerve is separated from the facial nerve in a lateral to medial fashion and a small section removed. The same is done with the inferior and singular nerves.
- The dura is reapproximated, and the incus is removed. A large fascia graft is placed to isolate the epitympanum from the antrum, and the mastoid cavity is packed with an abdominal adipose tissue graft.
- Closure per surgeon's choice

SURGERY FOR UNCOMPENSATED PERIPHERAL VESTIBULOPATHY

- These are patients who typically have an uncompensated unilateral hypofunctioning vestibular system.
- They have failed extensive vestibular rehabilitation and medical management.
- Treatment options include chemical ablation with gentamicin with the possibility of hearing loss, vestibular nerve section, or labyrinthectomy.

POSTOPERATIVE PERIOD

Postoperative Management

- For non-intracranial and cranial procedures, the patient is discharged when he or she is no longer vertiginous and is able to safely ambulate and maintain nutrition.
- Patients undergoing intracranial procedures are monitored in a neurosurgical ICU until medically stable to transfer to a surgical floor.
- Vertigo is typically managed with medications such as Phenergan, Valium, Ativan—interestingly, Zofran and meclizine do not seem to be as effective.
- Postoperative antibiotics are usually given for 7 days, although some surgeons elect to only administer perioperative antibiotics.
- Vestibular rehabilitation is important in any ablative vestibular procedure.

Complications

These mirror those of the operative risks:

CSF Leak

Early leaks may respond to lumbar drain and pressure dressings. For those that do not respond, reoperation may be required to seal the defect causing the leak.

Vertigo/Disequilibrium

This is not uncommon in the immediate postoperative period. However, vestibular rehabilitation is invaluable in assisting with disequilibrium and positional vertigo. Medications such as Ativan do have a role for acute vertigo management.

Meningitis

Intravenous antibiotics are essential for treating this bacterially induced disease. However, steroids may be useful if the disease is not bacterial.

Partial/Total Hearing Loss

This may be treated with hearing aids, osseointegrated implants, or cochlear implants.

Dysguesia/Loss of Taste

May occur if the chorda tympani is stretched or sacrificed. The taste typically compensates over a 1- to 9-month window, but about 2% of the time patients may continue to experience a metallic-like taste on half the tongue.

Facial Nerve Paralysis

Usually due to stretching of the nerve, however direct injury or cutting of the nerve can occur. High-dose steroids for 7 to 10 days is indicated, and repair of the nerve is done at time of injury if noticed. If the nerve does not recover, facial reanimation surgery may provide some benefit.

Intracranial Bleeding

Neurosurgery is consulted, and evacuation of clot and/or control of bleeding vessel may be indicated.

Pneumocephalus

May cause headaches or other intracranial complaints. Consult with neurosurgery to determine whether to observe, since air will resolve over time, or if evacuation is indicated.

Headache

This is not uncommon, depending on the surgery. Typical analgesics such as ibuprofen and acetaminophen normally help. For more chronic or complex cases, pain management or neurology may be consulted.

Alternative Management Plan

There are limited options for those patients who have failed optimal medical and physical therapy interventions. A transcanal labyrinthectomy is a quicker means of removing the neuroepithelium, allowing the patient a brief time under anesthesia if deemed safe by the patient's PCP or medical specialist.

Patients may opt not to consider perceived invasive procedures or are medically not safe to undergo general anesthesia and the ablative procedures described. Efforts should again be directed to use of vestibular suppressants and the possibility of intratympanic steroids or gentamicin. Physical therapy to ensure safety with ambulation should be revisited.

DISCUSSION

Evidence-Based Medicine Question

Is there a reliable surgical treatment algorithm for Meniere disease?

This is a difficult question to answer since so many variables play a role; however, the one overlying variable is "do no harm." Thus, the procedure that has the most chance of success while having minimal chance of complications wins out. A new study from England demonstrates 90% success 1 year following steroid injections, just a little bit better than gentamicin, which has the side effect of possible sensorineural hearing loss.[6] All the other procedures require anesthesia. When steroid injections fail, then one has to weigh the risks of using anesthesia with no significant risk to hearing and the vestibular system and a 65% success rate of endolymphatic sac surgery versus the office procedure of gentamicin with up to 30% hearing loss rates.[4] If the endolymphatic sac surgery is not successful and the goal is still to preserve hearing, then a vestibular nerve section may be a better treatment option (less than 5% chance of significant hearing loss) than gentamicin; however, the risk of an intracranial procedure must be factored in. The labyrinthectomy is typically the last option of surgical choice since it destroys hearing and balance.

Editorial Comment

Treatment of vestibular disorders is one of the more difficult challenges facing Otolaryngologists. It is critical to define the side of the pathology. Equally important is to understand the status of vestibular function on the contralateral side. BPPV of the PSC can be readily diagnosed. It is rare that the Epley repositioning maneuver fails to achieve satisfactory control. In the past, sectioning of the singular nerve was the recommended surgical approach for medical failure. Occlusion of the posterior canal is safer toward hearing preservation and more directed at the involved end organ.

Intratympanic gentamicin therapy is also very successful when delivered in the appropriate patient. This technique should be avoided in people with chronic ongoing vestibulopathy as it may aggravate the underlying symptom complex. It does incur the risk of sensorineural hearing loss. It should be used cautiously and with informed consent in patients with good hearing.

It is important to have an excellent understanding of the anatomy of the contents in the internal auditory canal. The seventh and eighth cranial nerves have a specific orientation that must be critically recognized in order to safely ablate vestibular dysfunction and preserve hearing and facial motor function. This pertains to the three approaches to vestibular nerve section.

The decision for labyrinthectomy is based on verification of the side of disease that is strengthened by the presence of unilateral hearing loss. As mentioned, the contralateral side should have good residual vestibular function in anticipation of rehabilitation from central compensation.

The use of postoperative vestibular rehabilitation therapy is strongly recommended to promote quicker recovery from any ablative procedure. The patient may require short-term disability as he or she regains the ability and confidence to function normally.

Barry Hirsch

Access the review questions online at http://www.expertconsult.com



REFERENCES

1. Shaia WT, Zappia JJ, Bojrab DI, et al. Success of posterior semicircular canal occlusion and application of the dizziness handicap inventory. Oto Head Neck Surg 2006;134:424–430.
2. Minor LB, Schessel DA, Carey JP. Meniere's disease. Curr Opin Neurol 2004;17:8–16.
3. Welling DB, Nagaraja HN. Endolympatic mastoid shunt: a reevaluation of efficacy. Otolaryngol Head Neck Surg 2000;122:340–345.
4. Sood AJ, Lambert PR, Nguyen SA, et al. Endolymphatic sac surgery for Meniere's disease: a systematic review and meta-analysis. Otol Neurotol 2014;35:1035–1045.
5. Teufert KB, Doherty J. Endolymphatic sac shunt, labyrinthectomy and vestibular nerve section in Meniere's disease. Otolaryngol Clin North Am 2010;43:1091–1101.
6. Hillman TA, Chen DA, Arriaga MA. Vestibular nerve section versus intratympanic gentamicin for Meniere's disease. Laryngoscope 2004;114:216–222.

REVIEW QUESTIONS

1. To surgically treat BPPV of the PSC it is important to:
   a. Suction out the offending otolith from the canal to prevent recurrence.
   b. Open the membranous labyrinth to plug the canal, thus providing the best seal to prevent recurrence.
   c. Drill through the canal in order to plug both ends to ensure no recurrence.
   d. Keep the membrane intact when plugging the canal.

2. When performing a vestibular nerve section from the retrosigmoid approach and visualizing the four nerves in the CPA, the inferior and superior vestibular nerve bundles are located:
   a. Directly posterior to the facial and cochlear nerve
   b. Directly inferior to the facial and cochlear nerve
   c. Directly anterior to the facial and cochlear nerve
   d. Directly superior to the facial and cochlear nerve

3. In a middle fossa craniotomy for vestibular nerve section, the superior and inferior vestibular nerves in the IAC are located:
   a. Directly posterior to the facial and cochlear nerve
   b. Directly inferior to the facial and cochlear nerve
   c. Directly anterior to the facial and cochlear nerve
   d. Directly superior to the facial and cochlear nerve

147 Superior Semicircular Canal Dehiscence

Andrew A. McCall

INTRODUCTION

Superior semicircular canal dehiscence (SCD) syndrome was first described by Minor et al. in 1998; it consists of anatomic dehiscence of the superior semicircular canal accompanied by symptoms including dizziness, autophony, and hearing loss.[1] The prototypical dizziness symptoms associated with SCD syndrome include sound- and/or pressure-induced vertigo. Autophony indicates the hearing of internal body sounds, such as hearing the heartbeat or hearing the eyes move. Hearing loss due to SCD typically presents as a low-frequency conductive hearing loss with an air-bone gap that commonly closes in the high frequencies.[2] The treatment of SCD syndrome consists of plugging the affected superior semicircular canal.

KEY OPERATIVE LEARNING POINTS

1. Dehiscence of the superior semicircular canal in SCD usually involves the floor of the middle cranial fossa.
2. Plugging the superior semicircular canal is the most efficacious treatment for SCD syndrome.
3. SCD is commonly associated with other bony defects in the floor of the middle fossa, which are usually addressed in the same setting.

PREOPERATIVE PERIOD

History

1. History of present illness
   a. Does the patient experience dizziness?
      Two types of elicited dizziness are commonly associated with SCD syndrome: sound- and pressure-induced dizziness. Sound-induced dizziness occurs in response to exposure of the affected ear to loud noise, such as that from loud machinery, music, or crowd noise. Pressure-induced dizziness in SCD syndrome occurs in response to the transient elevation of intracranial pressure, as occurs with heavy lifting or bearing down. The dizziness that occurs in response to these inciting events is usually transient. Dizziness may be elicited by positive pressure in the external meatus, as with finger manipulation. Some patients with SCD syndrome have nonspecific chronic dizziness with or without elicited dizziness.
   b. Does the patient have autophony?
      Autophony is the hearing of internal body sounds. Examples of common sounds heard by patients with SCD syndrome include hearing one's eyes move, the sound of one's heels hitting the floor, hearing one's heartbeat, the sound of chewing, or hearing one's voice reverberate within one's head. Note that autophony of breathing is not expected in SCD; if this is present, alternative diagnoses such as patulous Eustachian tube should be considered.[3]
   c. Does the patient have hearing loss?
      Hearing loss is common in SCD syndrome. The dehiscence of the superior canal results in a third mobile window (the oval and round windows being the first and second) into the inner ear. This third mobile window allows for the shunting of air-conducted sound energy away from the cochlea and leads to hearing loss.[4]
   d. Is the patient asymptomatic?
      Superior canal dehiscence can present as an incidental finding discovered on imaging performed for another reason. Patients with asymptomatic SCD do not require surgery and should be observed.
2. Past medical history
   a. Prior treatment: Has the patient had prior treatment for SCD syndrome or for dizziness thought to be from another etiology?
   b. Medical illness
      1) What is the hearing status in the contralateral ear?
      2) What is the vestibular function of the contralateral ear?
      3) Is there a history of migraine? Migraine may interfere with or prolong compensation following a vestibular insult, such as that which occurs following plugging of the semicircular canal.
      4) Is the patient's overall medical health sufficient to tolerate a craniotomy?
   c. Surgery
   d. Family history
      1) Some cases of familial SCD syndrome have been described. Most cases, however, appear to be sporadic.
   e. Medications
      1) Is the patient currently on anticoagulation therapy that would interfere with the performance of a craniotomy?
      2) Is the patient currently taking vestibular suppressant medication? Vestibular suppressants can interfere with vestibular compensation following surgery.

Physical Examination

1. Otoscopy
   a. Otoscopic examination in SCD syndrome is normal.
2. Tuning fork examination
   a. Weber lateralizes to the affected ear and Rinne can be negative (bone conduction perceived louder than air conduction). (Note: Not all patients with SCD have demonstrable hearing loss or an air-bone gap. Therefore the findings of tuning fork examination are variable in SCD and are often in line with audiometric findings.)
   b. When the vibrating tuning fork is placed on the lateral malleolus of the ankle, it can often be perceived in the affected ear.
3. Tullio phenomenon
   a. Presentation of a loud sound (as with a Barany noise box or delivered with an audiometer) to the affected ear results in dizziness.
4. Hennebert sign
   a. Pneumatic otoscopy or tragal pressure to the affected ear results in a vertical-torsional nystagmus with associated dizziness. Note that this nystagmus is likely to be difficult to perceive without the assistance of Frenzel lenses.

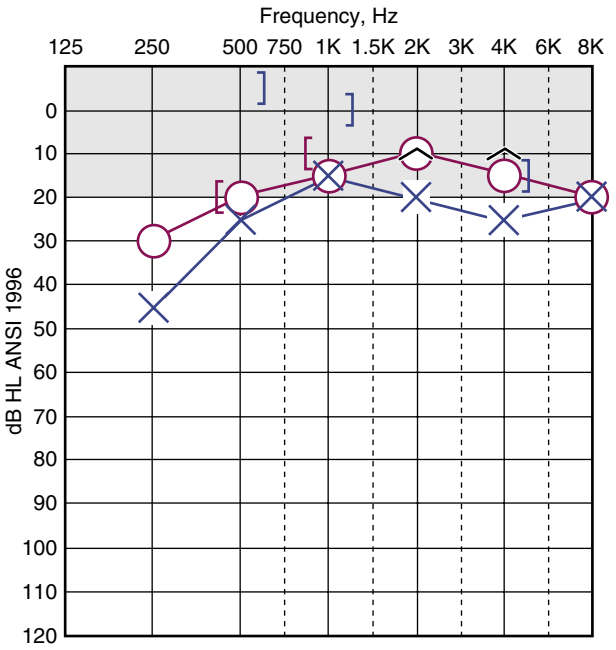

Fig. 147.1. Audiometric findings in dehiscence of the semicircular canal. This audiogram, from a patient with left superior semicircular canal dehiscence syndrome, demonstrates a supranormal bone conduction threshold at 500 Hz and an air-bone gap that is larger in the low frequencies.

Audiometric Findings and Other Testing

1. Audiogram
   a. The characteristic audiometric findings of SCD include supranormal bone conduction thresholds and a predominantly low-frequency air-bone gap (Fig. 147.1).
2. Acoustic reflex testing
   a. The audiometric findings in SCD may mimic those seen in otosclerosis. Acoustic reflex testing can be used to distinguish between these diagnoses. In SCD, acoustic reflexes are present. In contrast, in otosclerosis, acoustic reflexes are absent because the stapes is immobilized.
3. Vestibular evoked myogenic potential (VEMP)
   a. Presentation of a loud tone (or click) to the ear and evaluating for an inhibitory response in the ipsilateral sternocleidomastoid muscle is the cervical VEMP test. Reduced thresholds or increased amplitude on the test is consistent with SCD.
   b. The ocular VEMP test (excitatory response measured in the contralateral inferior rectus muscle) has been suggested to be a more sensitive and specific test for SCD than the cervical VEMP test.[5]

Imaging

Computed tomography (CT) of the temporal bone with fine cuts should be obtained when SCD syndrome is suspected. Multiple planes should be evaluated to confirm the diagnosis (Fig. 147.2). An image guidance study should be performed if the use of image guidance is planned for surgery.

Indications

1. SCD syndrome—Patients should make the final decision as to when they want to intervene based on their perceived severity and disability.

Contraindications

1. Anatomic SCD without symptomatology
2. An active coplanar semicircular canal problem (e.g., contralateral posterior semicircular canal benign paroxysmal positional vertigo [BPPV]) should be treated prior to proceeding with surgery.
3. SCD syndrome in an only one hearing ear: Very strong consideration should be given to alternatives to surgery owing to the risk of hearing loss in the operative ear.
4. Medical conditions that would preclude a craniotomy

Preoperative Preparation

1. Obtain preoperative medical clearance for craniotomy surgery.
2. Stop anticoagulation therapy (Note: this should be done with the guidance of the patient's medical provider).

OPERATIVE PERIOD

Anesthesia: General

Positioning

The patient is placed supine with the head turned and the ear to be operated facing upward. If image guidance is to be employed, the patient's head is fixed within a Mayfield head holder to fix it in position and permit placement of the image guidance system. The operating surgeon works at the head of the operating table; therefore the table must be positioned to accommodate the surgeon, the microscope, and the image guidance setup.

Perioperative Antibiotic Prophylaxis and Administration of Medication

First-generation cephalosporin

Steroids are given pre- and perioperatively to lessen the chances of sensorineural hearing loss (SNHL).

Mannitol is given near the time of craniotomy to provide brain relaxation.

Monitoring

Facial nerve electromyography (EMG), brainstem auditory evoked responses, somatosensory evoked potentials (SSEPs)

The anesthesia team should be notified that facial nerve monitoring will take place during the surgical procedure and that therefore long-acting neuromuscular blockade should be avoided.

Instruments and Equipment to Have Available

1. Binocular microscope
2. Craniotomy set and drill/craniotome
3. Brackmann-tipped suction irrigation setup
4. Facial nerve stimulator
5. Bone wax: Bone wax is placed in a warming bath to make it malleable and thus easy to mold into the contour of the dehiscence.
6. Image guidance: Image guidance can be a useful adjunct for locating and confirming the site of dehiscence of the superior canal or for orientation along the floor of the middle fossa. Its use may be particularly helpful in cases where there are numerous focal tegmental dehiscences that may be confused with the site of the SCD.
7. Middle fossa retractor

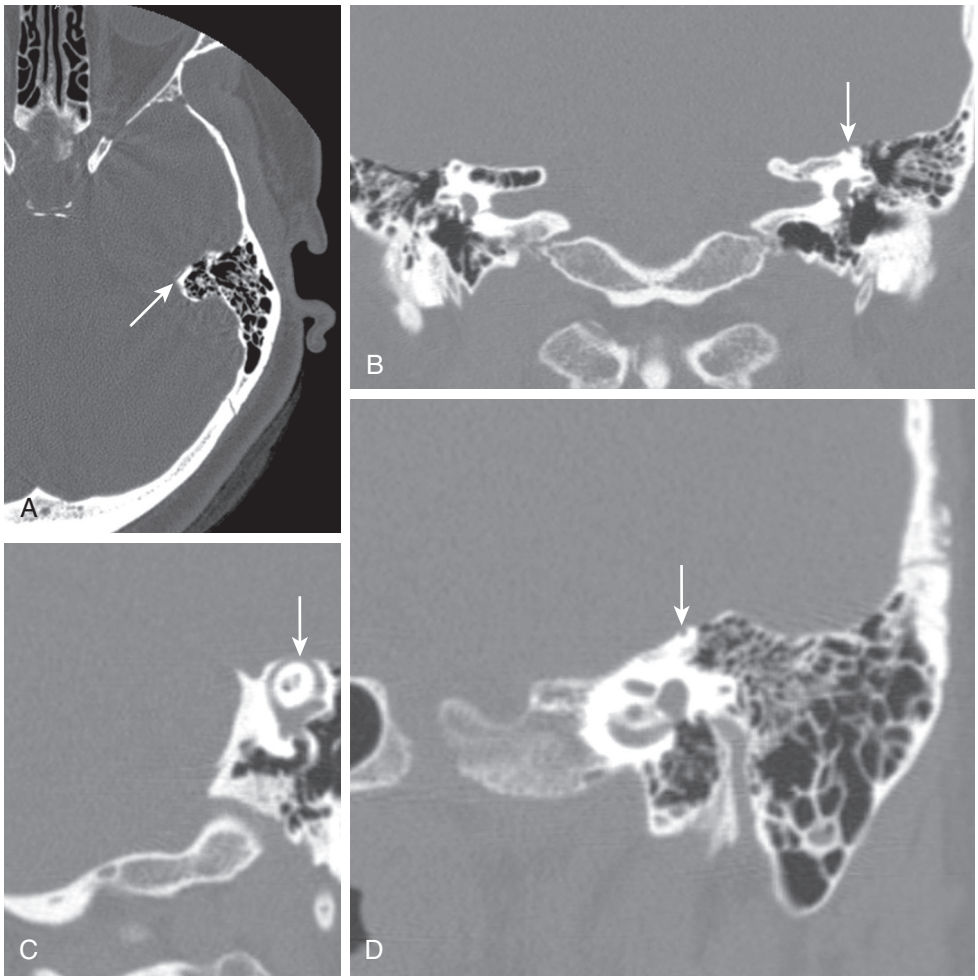

Fig. 147.2. Computed tomography findings in semicircular canal dehiscence. **A**, Axial, **B**, coronal, **C**, Pöschl, and **D**, Stenvers projections show dehiscence of bone overlying the left superior semicircular canal *(arrows)*.

Key Anatomic Landmarks

1. External auditory canal (EAC): The EAC and root of the zygoma are the surface landmarks useful for approximating the expected location of the internal auditory canal (IAC). The superior semicircular canal is located immediately posterior to the IAC near the petrous ridge.
2. Arcuate eminence/labyrinthine bone: The arcuate eminence is often distinguishable along the floor of the middle cranial fossa because the surrounding labyrinthine bone is denser and yellower in color than the surrounding tegmental bone. Furthermore, the arcuate eminence is typically raised in comparison with the surrounding tegmental bone. In SCD, a linear slit representing the dehiscence is centered within the arcuate eminence.
3. Greater superficial petrosal nerve (GSPN): The GSPN courses anteriorly across the floor of the middle cranial fossa. Its location can be confirmed by retrograde stimulation of the facial nerve by passing current with the facial nerve stimulator. The angle between the GSPN and the superior semicircular canal is approximately 120 degrees, bisected by the internal auditory canal.
4. Since the landmarks along the floor of the middle cranial fossa can be variable in their prominence, image guidance can sometimes be useful for purposes of orientation.

Prerequisite Skills

1. Knowledge of the anatomy of the floor of the middle fossa
2. Experience with image guidance if it is to be employed
3. Otomicrosurgical skills

Operative Risks

1. Sensorineural hearing loss
   SNHL can occur as a result of an intraoperative injury to the membranous labyrinth, from removal of too much perilymph, or from serous labyrinthitis following surgery. Great care should be taken in operating in the vicinity of the SCD to avoid suctioning perilymph and risking damage to the endolymphatic membrane.
2. Facial nerve injury
   The facial nerve may be dehiscent at the site of the geniculate ganglion and manipulation or traction of the facial nerve during elevation of the dura can result in facial paresis or paralysis. Although dehiscence of the facial nerve at the geniculate ganglion is more common in SCD patients than in the general population,[6] facial paresis/paralysis is rare following SCD surgery when proper operative technique is employed.
3. Inadequate plugging of the dehiscence resulting in persistent symptoms postoperatively
4. Epidural hematoma
5. Dural tear/cerebrospinal fluid (CSF) leak

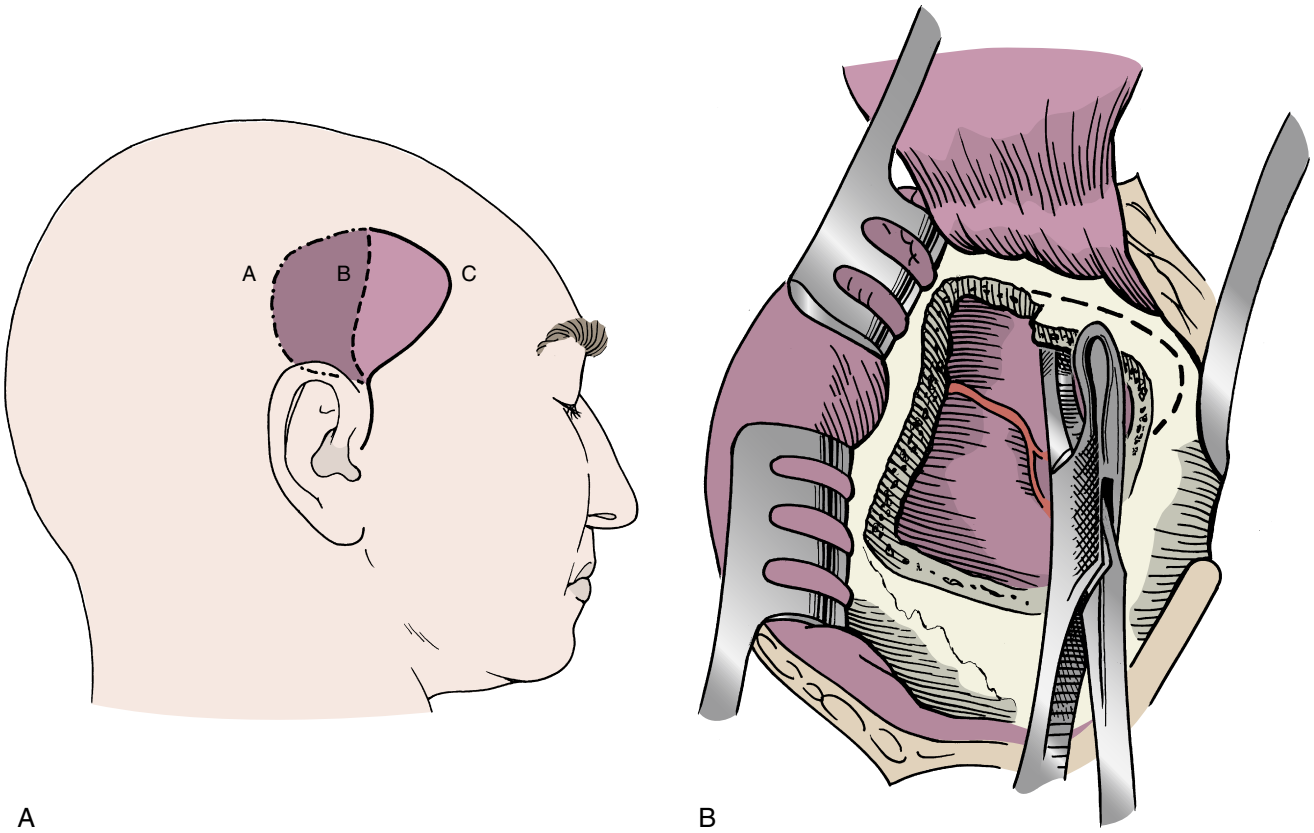

Fig. 147.3. A, Skin incisions for middle fossa approach to SCD. Our preference is that marked by line B. **B**,The craniotomy is taken down to the floor of the middle cranial fossa .

Surgical Technique

1. Skin incision and elevation of the soft tissues
   There are several types of skin incisions that can be used to approach the middle cranial fossa; the incision we most commonly employ extends from the preauricular crease to the temporal region (Fig. 147.3A). The temporalis muscle is then rotated anteroinferiorly toward the zygoma to allow for exposure of the bony cranium. A cuff of fascia is left posteriorly to facilitate reapproximation of this muscle during closure.
2. Craniotomy of the middle fossa
   Craniotomy of the middle fossa (see Fig. 147.3B) can be performed by either making burr holes and using a craniotome or using a standard otologic drill. With the otologic drill, a diamond burr is used to remove the inner cortex and avoid a dural tear. The craniotomy should be centered over or biased slightly anterior to the EAC and be approximately 4 by 5 cm. Rongeurs or a drill can be used to remove excess bone and make the inferior extent of the craniotomy flush with the floor of the middle fossa. If the middle fossa retractor is to be used, it is especially important to ensure that the vertical bony cuts parallel each other to permit retention of the retractor. Care must be taken, regardless of the instruments used, to keep the underlying dura intact for maintaining an extradural plane of dissection. In removing the bone flap, blunt dissection should be used to ensure that the dura is elevated off of the inner bony cortex (and thus does not tear). The bone flap should be set aside in a marked container for replacement during closure.
3. Dural elevation and identification of dehiscence of the superior canal
   The dura underlying the temporal lobe is then elevated off the floor of the middle cranial fossa. Instruments should be directed in a sweeping motion from posterior to anterior to avoid subluxing a dehiscent facial nerve at the geniculate ganglion. Venous oozing is commonly encountered during dural elevation anteriorly and can readily be controlled using hemostatic agents (such as Surgifoam or Surgicel packing). Dissection continues medially until the SCD is identified within the arcuate eminence near the petrous ridge. Identifying the GSPN anteriorly in the operative field (visually and augmented with facial nerve stimulation) can sometimes be helpful with orientation, especially in cases where identification of the SCD is challenging. Bipolar electrocautery can be used on the dura of the elevated temporal lobe to render it taut and thus help to lessen the need for manual retraction. Once the dehiscence is located (Fig. 147.4A), great care should be taken with the use of suction because of the risk of inducing sensorineural hearing loss with inadvertent suctioning of the perilymph or membranous labyrinth. A useful instrument to employ during exposure of the dehiscence is a small Brackmann-tipped suction irrigator; the continuous irrigation is useful for sweeping blood out of the field and keeping the field moist, while the small suction ports make it less likely that perilymph will be suctioned or inadvertent damage done to the endolymphatic membrane.
4. Plugging dehiscence of the superior canal
   Once the dehiscence has been adequately exposed, the canal is plugged. Placement of a middle fossa retractor can be used for exposure during plugging, but that is often unnecessary. Rather, the side of the suction irrigator can be broadly applied to the temporal lobe dura to provide retraction during plugging. Bone wax is placed directly onto the dehiscence and a small neurosurgical

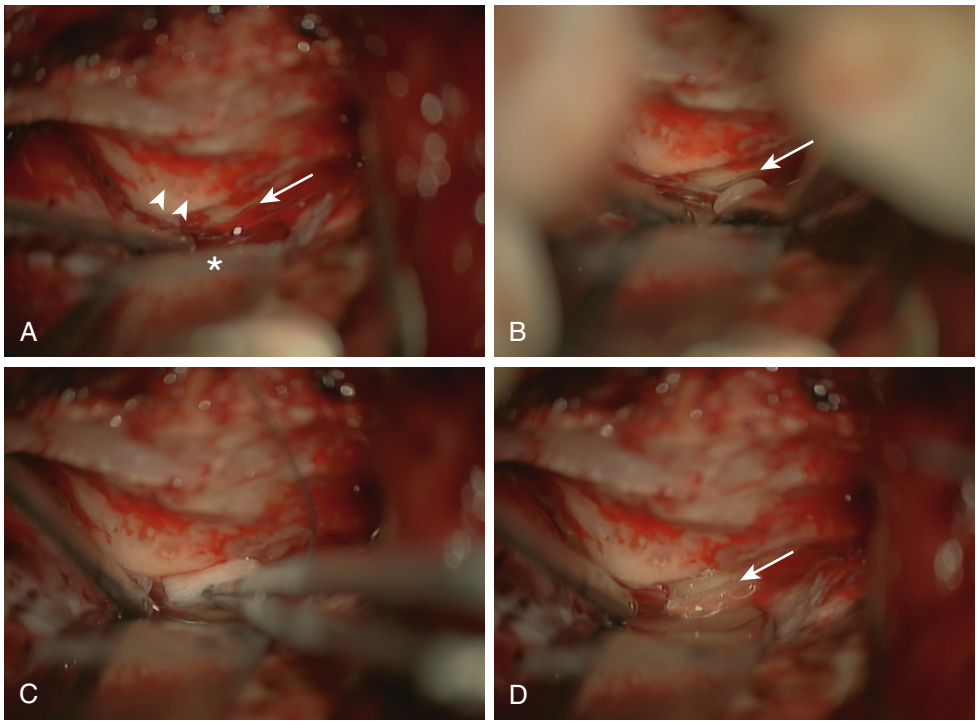

Fig. 147.4. Plugging of semicircular canal dehiscence. These panels show intraoperative photographs of the plugging of a left superior semicircular canal dehiscence (corresponding computed tomography shown in Fig. 147.2). In **A**, a middle fossa retractor is in position (*asterisk*), elevating the temporal lobe dura for visualization of the left semicircular canal dehiscence *(arrow)*. Also note the thin bone of the tegmen mastoideum overlying mastoid air cells *(arrowheads)* and contrast that bone with the dense labyrinthine bone of the arcuate eminence surrounding the site of superior semicircular canal dehiscence (best shown in panel **B**. Bone wax is placed onto the area of dehiscence, **B,** and a neurosurgical patty is used, **C,** to put inferior pressure on the wax such that it occludes the dehiscence, **D**.

patty is used to gently force bone wax into the site of the dehiscence, thus plugging the canal (see Fig. 147.4B-D). Pressure is directed inferiorly (toward the floor of the middle fossa and into the dehiscence) while the neurosurgical patty is removed to leave the bone wax in the site of dehiscence rather than allowing the wax to stick to the patty and be removed, risking damage to the endolymphatic membrane. Alternative materials that can be used for plugging include a mixture of bone wax and bone dust harvested during the craniotomy or a plug made up of fascia and bone chips. Care should be taken to make sure that both the ampullated and nonampullated ends of the canal are plugged. If additional skull base defects are identified, those should also be addressed (see Chapter 144).

5. Closure
   Hemostasis before closure is imperative. The craniotomy bone flap is secured with a plating system and a Jackson-Pratt (JP) drain is placed if there is concern for accumulation of blood. The temporalis muscle is sutured into position and the skin is closed.

Common Errors in Technique

1. Craniotomy not properly executed
   Missteps during the craniotomy can result in inadequate exposure. Particular attention should be paid to centering the craniotomy on the EAC or biasing it slightly anterior to the EAC and to ensure that it is made to come flush with the floor of the middle fossa. Furthermore, the procedure is designed to take place in the extradural plane. If a dural tear occurs, the dural defect should be repaired. Failure to recognize or properly repair a dural defect places the patient at risk for CSF leak and intracranial infection.
2. Adequate intracranial hemostasis is not maintained
   Venous oozing from the anterior aspect of the operative field in the vicinity of the GSPN is common during middle fossa craniotomy. Failure to control this bleeding will cause blood to obscure the operative field, thus placing the dehiscence at risk for accidental manipulation. The use of suction is of particular concern because suctioning to remove blood, if performed directly on the site of the dehiscence, risks rupturing the endolymphatic membrane or removing excessive perilymph, leading to sensorineural hearing loss.
3. Failure to fully occlude the superior semicircular canal
   Irrespective of the material used to plug the dehiscence, the surgeon must ensure that both ends of the superior semicircular canal are plugged. If the surgeon fails to fully plug the canal, a third window will remain and symptoms may persist following surgery.

POSTOPERATIVE PERIOD

Postoperative Management

1. Patients are admitted to the intensive care unit (ICU) or a monitored ward following surgery and their neurologic status is monitored.
2. Pain management: Oral or parenteral opiate analgesia is commonly required for several days following surgery.
3. Physical activity: Patients should be expected to experience a lack of normal balance following surgery, since the plugged canal is rendered nonfunctional and central compensation takes time to develop. Patients should be assessed by physical therapy while they are in the hospital; outpatient vestibular rehabilitation should be recommended.

Complications

1. Hearing loss
   Profound deafness is a risk with SCD surgery. Standard treatments for unilateral sensorineural hearing loss can be considered if this complication were to occur (see Chapter 135). Transient sensorineural hearing loss is detected in some patients in the postoperative period but usually recovers when mild. If there is a significant change in hearing, steroid therapy should be considered.
2. Facial paralysis

Facial paralysis is possible if a dehiscent geniculate ganglion is not recognized and is injured or the GSPN is accidentally stretched during dural elevation. This complication is rare. In cases where preoperative imaging is suggestive of a dehiscent geniculate ganglion, extra care should be taken to avoid this complication. Treatment is as with other causes of acute facial paralysis (see Chapter 138).

3. Epidural hematoma
   Although uncommon, an epidural hematoma can appear following middle fossa craniotomy. Treatment involves urgent craniotomy for evacuation of the hematoma.

Alternative Management Plan

1. Observation
   Observation is chosen by some patients with symptoms related to SCD syndrome—that is, those patients whose symptoms are not particularly bothersome and do not undermine their quality of life. Furthermore, observation is all that is necessary for asymptomatic patients with anatomic SCD.
2. Transmastoid SCD plugging
   As an alternative to middle fossa craniotomy, the superior semicircular canal can be plugged through a transmastoid route.[7,8]

DISCUSSION

Evidence-Based Medicine Questions

Is canal resurfacing an efficacious alternative to canal plugging for SCD syndrome?

1. Resurfacing of a dehiscent superior semicircular is associated with a higher rate of symptom recurrence than plugging of the affected canal. Dr. Minor, in reporting a series of patients (2005), found that four of 11 patients who underwent canal resurfacing without plugging developed recurrent symptoms within 3 to 6 months after surgery. On the other hand, of nine patient who underwent plugging, eight had complete resolution of symptoms and the ninth was "90% better."[9]
2. In cases of "near dehiscence," where a patient presents with findings consistent with SCD syndrome but the affected superior semicircular canal is found, at surgery, to have a very thin layer of bone overlying it, both plugging and resurfacing have been used with benefit.[10] Additional data are needed to determine which method is better for cases of "near dehiscence."

EDITORIAL COMMENT

Superior semicircular canal dehiscence (SSCD) is a relatively new radiographic diagnosis that encompasses a host of unusual signs and symptoms that can now be explained by the third window effect of a defect in the otic capsule covering the canal. In the past, hearing a patient indicate they hear themselves breathe, their eyes move or their heels hit a hard surface when walking were thought to carry a functional diagnosis. Patients would report symptoms of Tullio's phenomenon or show Hennebert's sign were evaluated for syphilis or thought to have a perilymphatic fistula. It is now recognized these and many other symptoms are consistent with SCD. Failed stapes surgery for otosclerosis was deemed to be from an inner ear conductive disorder attributed to stiffness of the basilar membrane. It is now recognized that the third window effect provides a tangible explanation for this other source of conductive hearing loss.

A thin cut bone algorithm CT scan in the coronal plane is needed to demonstrate the dehiscent semicircular canal. This imaging is necessary to demonstrate the presence and location of the bony defect and the surrounding anatomy of the temporal bone. Cervical or ocular vestibular evoked myogenic potential (VEMP) show the reflex arc from auditory stimulation to muscle responses in the neck or inferior rectus muscles. The threshold for eliciting these responses is lower in SSCD pathology.

The next controversy which is still debated is how best to repair the defect. The two schools of thought are capping (covering over the defect) and plugging (filling the defect with soft tissue, bone dust or bone wax). The approach for repair has also evolved. Initially a middle fossa approach was recommended to provide direct visualization of the dehiscence. Currently, if the amount of aeration in the antrum and tegmen are sufficient, a transmastoid approach can be executed. This usually entails covering of the bony defect with cartilage placed between the overlying dura and above the arcuate eminence. The canal can also be plugged isolating and unroofing its proximal and distal ends and occluding the membranous canal with soft tissue or bone wax. These repairs can be offered for signs and symptoms related to hearing loss and/or vertigo.

Patients should be counseled about the risks of benefits of the procedure. People may experience low grade vestibulopathy problems related to motion intolerance. Partial or complete sensorineural hearing loss can occur due to manipulation of part of the inner ear. It is the disabling nature of the disorder that promotes patients toward having it repaired. Successful elimination of these life changing symptoms can be most rewarding to both the patient and surgeon.

Barry Hirsch

Access the review questions list online at http://www.expertconsult.com



REFERENCES

1. Minor LB, Solomon D, Zinreich JS, et al. Sound- and/or pressure-induced vertigo due to bone dehiscence of the superior semicircular canal. Arch Otolaryngol Head Neck Surg 1998;124(3):249–258.
2. Merchant SN, Rosowski JJ, McKenna MJ. Superior semicircular canal dehiscence mimicking otosclerotic hearing loss. Adv Otorhinolaryngol 2007;65:137–145.
3. Poe DS. Diagnosis and management of the patulous eustachian tube. Otol Neurotol 2007;28(5):668–677.
4. Merchant SN, Rosowski JJ. Conductive hearing loss caused by third-window lesions of the inner ear. Otol Neurotol 2008;29(3):282–289.
5. Zuniga MG, Janky KL, Nguyen KD, et al. Ocular versus cervical VEMPs in the diagnosis of superior semicircular canal dehiscence syndrome. Otol Neurotol 2013;34(1):121–126.
6. Isaacson B, Vrabec JT. The radiographic prevalence of geniculate ganglion dehiscence in normal and congenitally thin temporal bones. Otol Neurotol 2007;28(1):107–110.
7. Beyea JA, Agrawal SK, Parnes LS. Transmastoid semicircular canal occlusion: a safe and highly effective treatment for benign paroxysmal positional vertigo and superior canal dehiscence. Laryngoscope 2012;122(8):1862–1866.
8. McCall AA, McKenna MJ, Merchant SN, et al. Superior canal dehiscence syndrome associated with the superior petrosal sinus in pediatric and adult patients. Otol Neurotol 2011;32(8):1312–1319.
9. Minor LB. Clinical manifestations of superior semicircular canal dehiscence. Laryngoscope 2005;115(10):1717–1727.
10. Ward BK, Wenzel A, Ritzl EK, et al. Near-dehiscence: clinical findings in patients with thin bone over the superior semicircular canal. Otol Neurotol 2013;34(8):1421–1428.

REVIEW QUESTIONS

1. When the dura is elevated off the floor of the middle cranial fossa to expose a dehiscent superior semicircular canal, which of the following techniques should be used?
   a. Bipolar electrocautery along the floor of the middle fossa
   b. Posterior-to-anterior dissection along the floor of the middle fossa
   c. Incision of the dura to gain exposure
   d. Identifying the middle meningeal artery and then dissecting in a posterior direction until the dehiscence is located

2. Complications of superior semicircular canal plugging include all of the following except
   a. Hearing loss
   b. Facial paresis/paralysis
   c. Epidural hematoma
   d. Jugular bulb injury

3. All of the following structures are useful for identifying the location of a dehiscent superior semicircular canal except the
   a. Cochleariform process
   b. External auditory canal
   c. Arcuate eminence
   d. Greater superficial petrosal nerve

148 Stereotactic Radiosurgery

C.Y. Joseph Chang, Stephen Cass

INTRODUCTION

Acoustic neuroma, also known as vestibular schwannoma, is a benign neoplasm arising from the vestibular portion of the cochleovestibular nerve. This tumor can cause a variety of sequelae, most common among which are hearing loss, tinnitus, and dizziness/imbalance. The tumor can grow to a large size and cause additional symptoms related to brain-stem compression, hydrocephalus, and effects on other cranial nerves (CNs). Extremely large tumors can be life threatening. Advances in magnetic resonance imaging (MRI) and audiologic evaluation have led more of these tumors to be detected even when there are few symptoms and the tumors are typically small. This has created a greater need for the management of these tumors over time. The main goal in this endeavor is to prevent the tumor from growing to a large size, thus decreasing the likelihood of morbidity, while also minimizing the deleterious effects of treatment. Secondary goals include the prevention of progressive CN dysfunction due to the tumor, such as loss of hearing and facial nerve dysfunction.

In order to determine the optimal treatment for a particular patient, it is necessary to understand the natural history of acoustic neuroma (growth rate and hearing changes over time) as well as the outcomes following intervention, whether that is surgery or stereotactic radiosurgery (SRS). Observation (watch and scan) has become more prevalent, adding another dimension to the decision making involved in treatment. What is the chance that a particular tumor will grow to a life-threatening size during the patient's natural life span and require treatment? On average these tumors grow slowly (2 mm per year), but the growth rate varies widely, with about 50% showing no growth during observation and others that grow an average of 2 to 4 mm per year (up to 18 mm). Moreover, the growth rate is nonlinear over time, since some growing tumors can stop growing while other tumors that showed no growth for years may start growing again.

The advent of radiosurgery for the treatment of acoustic neuromas more than 40 years ago has significantly changed the contemporary management of acoustic neuroma. To date more than 100,000 patients with acoustic neuroma have been treated with radiosurgery, and the rate of radiosurgery treatment is growing. Currently about 50% of acoustic neuromas are treated with surgery, and the remainder are split between observation and radiosurgery. In addition to primary treatment for tumors, radiation offers a noninvasive treatment of residual tumor after microsurgery.

Stereotactic radiation treatments are available in two types. Single-fraction stereotaxy (SRS) is one and stereotactic radiotherapy, used for multifraction treatment, is the other. Both types use precise stereotactic localization of the lesion as well as conformal treatment plans that focus the radiation beam on the target tissue. The use of the Gamma Knife to treat acoustic neuroma was first reported in 1971 and, over time, this technology has been refined through several generations of devices to its current utilization of MRI for target localization and automated radiation delivery. The Gamma Knife uses numerous fixed Cobalt 60 sources and collimators (the Perfexion Unit has 192 sources and collimators) to send a focused radiation beam to the target (Fig. 148.1). Several linear accelerator (LINAC)–based radiosurgery delivery systems are also available. These use advanced robotic technology, multileaf collimators, and radiographic verification of positioning, all of which are highly accurate and flexible.

This chapter discusses in further detail the management of acoustic neuroma with stereotactic radiosurgery. The management considerations are based on the limited data available at the time of writing.

KEY OPERATIVE LEARNING POINTS

1. Patient selection is complex owing to the lack of reliable information on long-term tumor control rates after radiotherapy.
2. The planning of tumor treatment must produce a highly conformal radiation field comprising the volume of the tumor and minimizing radiation to areas that are sensitive to radiation damage, including the cochlea and brainstem.

PREOPERATIVE PERIOD

History

1. History of present illness
   a. Age and family history of longevity. The length of time during which tumor control will be needed is important.
   b. Hearing loss. The presence of usable hearing will be important in patient counseling.
   c. Dizziness. The patient may have imbalance, a floating sensation, and vertigo; all of these may be affected by treatment.
   d. Facial numbness—Large tumors may cause trigeminal nerve dysfunction.
   e. Headache
   f. Facial nerve weakness or facial spasms. These may indicate a possible facial nerve schwannoma or a vascular tumor involving the facial nerve.
   g. The presence and nature of tinnitus
2. Past medical history
   a. History or family history of neurofibromatosis II (NF2)
   b. History of prior intracranial surgery or radiation to the area
   c. Chronic serious medical conditions including coronary artery disease, chronic lung disease, chronic anticoagulation, or other conditions that may make the patient a poor surgical candidate

Physical Examination

1. Otologic evaluation
   a. Tympanic membrane
   b. Tuning fork
2. Neurologic evaluation
   a. Facial nerve evaluation—The House-Brackmann grading scale is typically used.
   b. Other CNs
      1) Trigeminal nerve
         a) Facial sensation
         b) Corneal reflexes
   c. Cerebellar evaluation—dysmetria

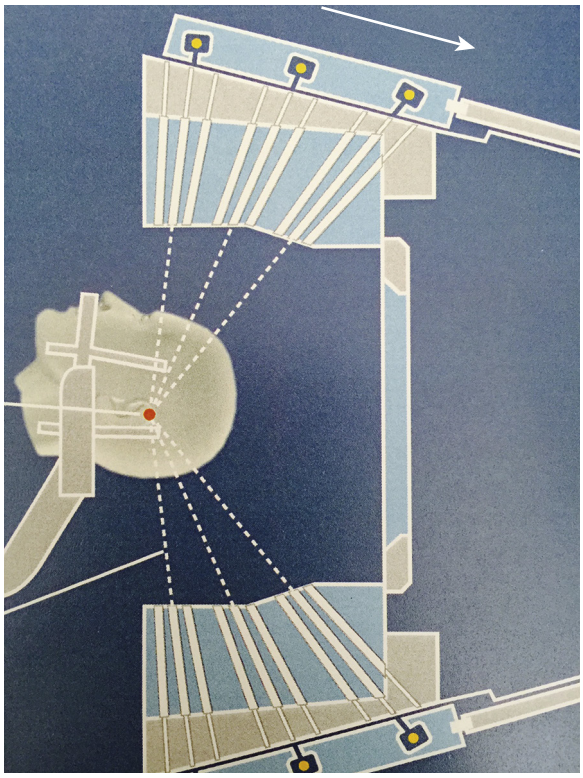

Fig. 148.1. Conceptual diagram of focused beam radiation.

   d. Balance evaluation
      1) Gait and tandem gait
      2) Romberg test
3. Audiologic evaluation
   a. Pure tones
   b. Speech discrimination scores
   c. Tympanogram
4. Vestibular evaluation
   a. Search for pathologic nystagmus
   b. Bedside testing of the vestibuloocular reflex (VOR)—head impulse test
   c. Videonystagmogram—This test may be performed if there are concerns regarding the status of contralateral vestibular function or the presence of other vestibular disorders.

Imaging

- MRI with gadolinium including high-resolution images through the internal auditory canals (IACs). Alternatively, MRI without gadolinium with high-resolution submillimeter images through the IAC (fast imaging employing steady-state acquisition (FIESTA)/constructive interference steady state (CISS) sequences) can image the IACs and cerebellopontine angle adequately but may miss other intracranial lesions.
- Computed tomography (CT) of the brain with contrast may be used if MRI cannot be performed due to metal implants or other issues, but its sensitivity is much lower than that of MRI.

Indications for Radiation

1. The considerations regarding the need to provide treatment for acoustic neuroma with radiation or surgery include tumor size, tumor growth rate, patient's symptoms, patient's age, and medical comorbidities. Because there is considerable uncertainty as to the optimal treatment for any given situation, the patient's and the treating physician's preferences and biases may play a major role in determining whether to treat and how.
2. Most tumors that have been determined to need active treatment
   a. SRS is ideally suited for small to medium-size tumors.
   b. Surgery is generally preferred in younger patients, since the rate of long-term (20 to 30 years) tumor control following SRS is not established and the chance of developing a radiation-induced complication is theoretically greater in a young versus an older person.
3. Patients who are medically unfit for surgery
4. Patients who are fit for surgery but choose stereotactic radiation
5. Tumors that have recurred after prior surgery
6. Some tumors that have recurred after prior stereotactic radiation have been retreated with stereotactic radiation.
7. Patients with bilateral acoustic neuromas associated with NF2 may also choose the radiation option, although tumor recurrence rates are higher and hearing preservation rates lower than those associated with sporadic tumors.



Fig. 148.2. Leksell head frame.

Contraindications

1. Many centers may consider tumors with an axial dimension larger than 3 cm as too large for radiation, but there are reports of a few centers treating such large tumors.
2. The presence of significant symptomatic brainstem compression usually requires surgical decompression with various degrees of tumor removal.
3. Patients in their thirties or younger will have to consider the issue of very long term tumor control with radiotherapy and long-term radiation-induced complications.

Preoperative Preparation

1. The head frame (fixator) must be applied.
   a. Gamma Knife system—The Leksell head frame is put in place via head stabilization pins applied under local anesthesia (Fig. 148.2). This technique is characterized by high-resolution targeting and registration of the lesion and very stable head/target positioning (1-mm accuracy).
   b. LINAC system—The face mask is custom-made for the patient (Fig. 148.3). In LINAC, the head is registered to the frame through a mask/frame system imaged



Fig. 148.3. Linear accelerator face mask with reference frame.

together with a CT scan (2-mm cuts) followed by fusion of an MRI to the CT to target the lesion. During treatment the head is stabilized by the mask and radiographs are taken after each table and gantry movement to adjust for any movement of the head within the mask system.

c. The Gamma Knife system is the most accurate, and is preferred when the greatest accuracy is required (i.e., high dose to a small target). For most other lesions, there is no practical difference between these approaches.

2. The MRI or CT is performed with the head frame or mask in position to allow the image to be referenced to the fixator.
   a. The imaging data are imported into the targeting system for use in treatment planning.

OPERATIVE PERIOD

Anesthesia

- None

Positioning

- Supine: The patient is positioned in the radiotherapy bay and the head frame or face mask is fixed to the system.

Perioperative Antibiotic Prophylaxis

- None

Monitoring

- Video and audio systems to communicate with patient.

Instruments and Equipment to Have Available

See "Preoperative Preparation," above.

Key Anatomic Landmarks

Tumor targeting takes into consideration the tumor's volume, shape, and location as well as important surrounding structures.

1. The structures that should receive as little radiation as possible include the following:
   a. The inner ear, including the modiolus
   b. The brainstem.
   c. CN 5
   d. Lower CN

Prerequisite Skills

1. Radiation biology
2. Radiation targeting

Operative Risks

1. Anxiety episode. If necessary, the patient may be sedated.

Surgical Technique

Source of Radiation

The Gamma Knife uses decaying Cobalt 60, which releases gamma radiation with an average energy of 1.25 meV. LINAC creates high-energy photons with various levels of energy; a maximum of 6 meV is most commonly used in SRS. The energy of the radiation affects the relationship of dose versus depth of tissue penetration. For 1.25 meV, the maximum dose is at 0.5 cm. For 6 meV, the maximum dose is 1.5 cm. These differences are taken into account by the treatment planning software associated with each type of device.

The main task of the treatment team is to formulate the radiation planning.

- The essential features of tumor targeting are similar among the various platforms. Conceptually, a device providing targeted treatment directs radiation from an external source at various angles to focus the dose on a central target. This geometry results in a radiation field with the highest dose at the center (isocenter) and a dose that decreases as a function of distance away from the isocenter (see Fig. 148.1).
- The percent isodose is the reduced dose that occurs at any circumferential distance away from the isocenter. The lower the isodose line used, the greater the decline in dosage at the margin but also the greater the difference between the minimum and maximum doses to the tumor. For example, when treatment is directed to the 50% isodose line, the maximum dose will be double the marginal dose, creating a "hot spot" at the center of the tumor.
- With a single shot of focal radiation, the shape of the isodose distribution field is spherical or elliptical, depending on the configuration of the treatment device.
- If multiple shots are targeted at different locations, the shape of the isodose distribution field can be made in a diversity of 3-dimensional shapes. An irregularly shaped isodose field can be created that conforms to the shape of the tumor to be treated.
- The prescription isodose is the radiation field created for the treatment of a particular tumor, and the prescription isodose line is the border of the treatment volume (Figs. 148.4 and 148.5).

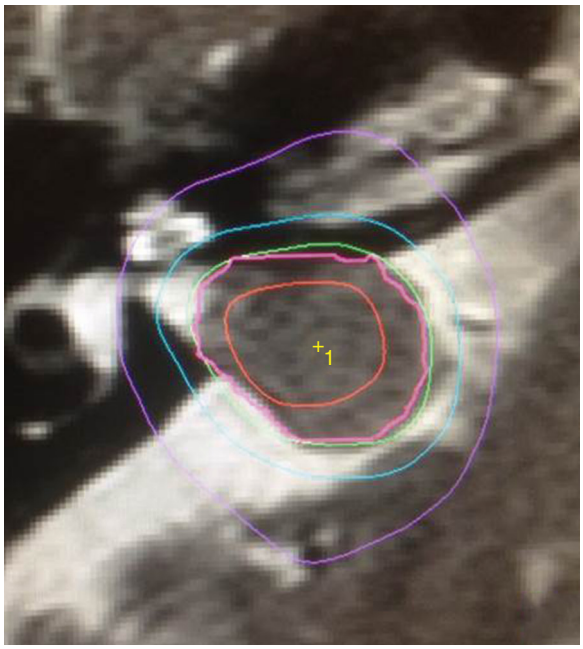

Fig. 148.4. Gamma Knife prescription isodose plan. +1 - Isocenter.

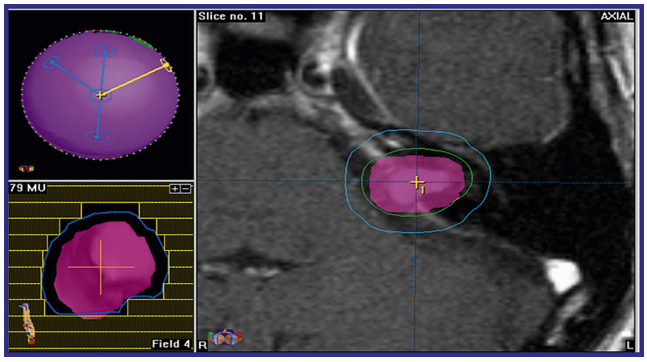

Fig. 148.5. Linear accelerator prescription isodose plan. +1 - Isocenter.

- The degree to which this prescription isodose covers the tumor volume is termed *conformity*. There are various indices indicating how good this conformity is, such as the conformity index, which is the ratio of the prescription isodose volume divided by the tumor volume.
- Targeting with the Gamma Knife is achieved by the use of 192 collimators (each with a single radiation source) at the same time. Fixed-diameter collimators are able to deliver very precise radiation beams with a very narrow penumbra to a single isocenter. The use of a single isocenter is ideal for creating a very precise, very small lesion in the trigeminal nerve for trigeminal neuralgia or a small eighth-nerve schwannoma near the cochlea.
- Target conformity is achieved in larger tumors using overlapping isocenters (multiple shots). Sector blocking can be used to further shape the radiation and shield critical structures. In LINAC, target conformity is achieved through the use of cones or multiple-leaf collimators and static beams or dynamic arcs created via table and gantry movements aimed at a single isocenter. The ability to create conformal treatment plans is likely no different between the two types of systems.
- Gamma Knife has been most commonly prescribed in the range of the 50% isodose line (an apparent trade-off between dose fall-off and creation of hot spots). For any given isodose reference, LINAC systems will generally create a more homogeneous dose of radiation compared with the Gamma Knife. The importance of differences in dose heterogeneity and isodose reference is not known.
- In both Gamma Knife and LINAC SRS, the radiation dose is referenced to an isodose line, which is a way of specifying the target dose. There is no difference in the ability to set this parameter.
- The radiation dose to the tumor is typically reported as the marginal dose applied at the 50% isodose line. The commonly used dose at this time is typically around 12 to 13 Gy at the 50% isodose line for Gamma Knife and 50% to 90% for LINAC systems. In the past, marginal doses of 25 to 50 Gy were used and resulted in significant rates of facial nerve dysfunction, trigeminal nerve dysfunction, edema of the brainstem, and hydrocephalus. These side effects have been reduced to very low levels with the currently used low doses.
- In addition to targeting the tumor adequately, structures outside the tumor that are sensitive to radiation damage must also be considered. There is still a radiation dose field outside the prescription isodose volume that extends to the radiation source. The radiation dose to structures such as the inner ear and brainstem should be minimized in designing the prescription isodose volume and is termed *blocking the area*.
- Hearing loss after targeted radiation has been associated with a higher dose to the cochlea in some studies, but this is likely not the only factor in hearing preservation. A high dose to the cochlear nucleus may also contribute to increased hearing loss, so this area as well should also be identified in targeting.

Common Errors in Technique

1. Poor conformity of treatment planning
2. Inadequate blocking of structures that are sensitive to radiation effects

POSTOPERATIVE PERIOD

Postoperative Management

1. Patients are discharged the same day and resume regular activities and diet.
2. Patients with very good hearing are treated with oral steroids for 10 days after treatment.
3. A small percentage of patients may develop headache, nausea, and swelling at the pin sites. These issues may be treated conservatively with medical management.
   a. Acetaminophen, nonsteroidal anti-inflammatory drugs (NSAIDs), and narcotics may be prescribed for headache.
   b. Vestibular suppressants may be given for vertigo.
   c. Topical wound care may be offered for pin-site issues.
4. Rarely, acute CN dysfunction can occur; this should be treated with corticosteroids and supportive care as necessary.

Complications

1. There is a very low rate of hydrocephalus after treatment that may require ventriculoperitoneal (VP) shunting.
2. Facial nerve dysfunction. Most cases of facial nerve dysfunction are delayed in onset, partial, and transient and

should be treated with oral steroids. If there is severe facial dysfunction, various treatment options for lagophthalmos and facial reanimation are available (see Chapters 179 and 180).
3. Trigeminal nerve dysfunction. It can be permanent but is transient in most instances. This complication is typically treated with oral steroids.
4. Hearing loss and tinnitus. There may be progressive hearing loss.
   a. A hearing aid may be required to ensure usable hearing.
   b. Contralateral routing of signals (CROS) device or an osseointegrated implant may be needed to correct unusable hearing (see Chapter 135).
5. Dizziness. In most patients, this will improve with vestibular physical therapy.

Alternative Management Plan

1. Observation with serial MRI. A significant percentage of tumors may not grow after initial diagnosis.
2. Microsurgical removal (see Chapter 140)

DISCUSSION

Outcomes, Prognosis, Complications

Tumor Control

It is critically important to understand the long-term outcome after stereotactic radiation because the treatment leaves tumor cells in place; control of tumor growth depends on damaging these cells and supporting vascular cells sufficiently that the tumor will fail to grow over a span of many years. Evaluation of the literature is hampered by the variable definitions of tumor control used in various studies. In the short term, over the first year after treatment, a significant number of tumors will enlarge temporarily, possibly due to inflammatory changes and edema, followed by involution to a baseline size or less.

A number of studies offer retrospective evidence that the treatment does significantly decrease the rate of tumor growth over 10 years versus observation without treatment. There is currently good observational evidence that, with current dosing strategies, tumor control rates over 10 years are greater than 80%.[1] The main factors that portend poor tumor control include failure of treatment conformity,[2] decreased radiation dose, large tumor size, and tumors that show active growth just prior to treatment.[3] Tumor control rates with any treatment modality should also be considered in view of the finding that about 50% of acoustic neuromas may not grow over a 5-year period of observation.

The tumor control rate after radiosurgery is established in the short term (90%). However, tumor control beyond 10 years is not definitively understood. The tumor control rate after surgical resection beyond 10 years is also poorly documented.

Facial Nerve Results

Rates of House-Brackmann I and II results after treatment are approximately 95% to 99%.[1,4] The facial nerve dysfunction typically occurs 6 to 9 months after treatment, is partial, and recovers. Facial nerve dysfunction is correlated with a higher dose at the treatment isodose line and target volume.

Hearing Loss

Diagnosis of a small acoustic neuroma when hearing is normal or near normal presents a special dilemma, since it is not clear whether early radiation treatment changes the natural history of hearing preservation seen in observed (untreated) patients. Hearing preservation is also possible with microsurgery (50% to 70%) in the case of small tumors, but the remaining patients will incur total loss of hearing. Additionally, the rate of serviceable hearing preservation over time may not differ from that following stereotactic radiation. The hearing loss related to radiation typically occurs slowly over time; therefore it is rare to have a patient experience sudden hearing loss after radiation.

On average, hearing function decreases over time, whether or not the tumor is observed or treated with stereotactic radiation. There are centers that advocate for the early treatment of tumors in patients with serviceable hearing because some data point to good hearing preservation for at least a few years. However, on long-term follow-up there may not be a significant advantage to radiation, as actuarial rates of long-term serviceable hearing in patients with serviceable hearing prior to treatment may be less than 30%.[5] Hearing preservation rates appear to correlate best with better pretreatment hearing function. Other issues may include radiation dose to the cochlea, marginal dose, and tumor size. There are conflicting reports as to whether the results of radiation are superior, similar, or worse as compared with hearing monitored simply by observation.

Vestibular Function

There is a significant incidence of vestibular dysfunction in patients with acoustic neuromas prior to any treatment, and there is a significant rate of imbalance after treatment of any type. Long-term dizziness may be seen in some 50% of patients after radiotherapy, microsurgery, and observation. It is not clear whether management of the tumor has, on average, a long-term effect on dizziness. The radiation dose to the vestibule does not appear to correlate with the degree of dizziness.

Neurofibromatosis 2

The tumor control rate in tumors associated with NF2 is known to be significantly poorer than that in sporadic tumors. Based on various studies from 2013 and 2014, these tumor control rates ranged from 84% at a median follow-up of 109 months, 93% at a median follow-up of 36 months, and 87.5% at 2 years. In a study from 2008, based on actuarial methods, the tumor control rate was 80.2% at 5 years and 80% at 3 years.

Hearing preservation rates are also poorer for tumors associated with NF. One study from 2014 reported actuarial hearing preservation rates of 44% at 5 years and 17% at 10 years. Another study from 2008 reported a usable hearing rate of 80% at 3 years.

Other Outcomes

Hydrocephalus requiring a VP shunt may occur in 0.8% to 6% of patients. The rate of trigeminal nerve dysfunction may vary between 0.2% and 21% depending on tumor size and radiation dose. Chronic headache may occur in some 50% of patients with acoustic neuromas and may not be affected by the treatment modality, including observation, microsurgery, or radiation. Radiation-induced malignancy is possible, but its true incidence following radiosurgery is not known. The available data suggest that the rate is low: 0.04% at 15 years in a study from 2014 (which included no acoustic neuroma neoplasms) and, in another study from 2013, 0.05% in 5000 patients treated with SRS. The corresponding rate in another study including only acoustic neuromas was 0.3% at 12.5 years.

Editorial Comment

The role of stereotactic radiation therapy has evolved over the past 30 years to become an accepted alternative means for treatment of acoustic neuroma. The initial controversy regarding its use centered on the long term control of tumor growth. Despite reduction in the prescribed dose the rate of tumor control has remained very good while the incidence of complications has significantly diminished. Microsurgery has a long term track record for efficacy. The outcomes following radiation, including the rare risk of development of malignancy, has been reported only for the past few decades. Greater confidence in relying on this modality stems from the consistent results demonstrating control over prolonged intervals.

The prevalence of radiation energy sources are delivered by either gamma radiation or linear accelerator. The literature is replete with studies lauding the beneficial outcomes of that particular method of treatment. It is challenging to both physicians and patients to decipher if one form of treatment is better than the other. At present, the success achieved with both techniques of radiation treatment is reassuring there is no one correct modality.

Experience over time has demonstrated that radiated tumors can and do show expansion over the first one to two years following treatment. When it occurs, the increase in size should stabilize or diminish due to contraction. Continued enlargement is deemed treatment failure and further intervention is warranted.

As is detailed in this chapter, the decision for initial intervention is based on numerous factors including tumor size, location in the IAC, the patient's symptoms, chronological age, hearing status, and medical comorbidities. The physician's bias may influence what treatment should occur but the final decision rests with the patient's preference. As with many relatively new management options, reported outcomes over longer periods of time will help determine how to prioritize where stereotactic radiation fits into the treatment paradigm.

Barry Hirsch

Access the review questions and additional sources list online at http://www.expertconsult.com

REFERENCES

1. Klijn S, Verheul JB, Beute GN, et al. Gamma Knife radiosurgery for vestibular schwannomas: evaluation of tumor control and its predictors in a large patient cohort in The Netherlands. J Neurosurg 2016;124(6):1619–1626.
2. Pollock BE, Link MJ, Foote RL. Failure rate of contemporary low-dose radiosurgical technique for vestibular schwannoma. J Neurosurg 2013;119(Suppl):840–844.
3. Niu NN, Niemierko A, Larvie M, et al. Pretreatment growth rate predicts radiation response in vestibular schwannomas. Int J Radiat Oncol Biol Phys 2014;1:89(1):113–119.
4. Flickinger JC, Kondziolka D, Niranjan A, et al. Results of acoustic neuroma radiosurgery: an analysis of 5 years' experience using current methods. J Neurosurg 2013;119(Suppl):1–6.
5. Tveiten OV, Carlson ML, Goplen F, et al. Long-term auditory symptoms in patients with sporadic vestibular schwannoma: an international cross-sectional study. Neurosurgery 2015;77(2):218–227.

REVIEW QUESTIONS

1. Obtaining adequate conformity of treatment planning does not include
   a. Creating a prescription isodose line that incorporates the entire tumor
   b. Setting the percent isodose at the isodose line
   c. Blocking nontarget structures that are radiosensitive
   d. a and b
   e. a, b, and c

2. Adverse sequelae of stereotactic radiotherapy may be reduced by
   a. Blocking radiosensitive structures
   b. Avoiding high radiation doses at the prescription isodose line
   c. Reducing the number of isocenters
   d. a and b
   e. b and c

3. Tumor control after stereotactic radiotherapy is not associated with
   a. Tumor size
   b. Tumor growth rate
   c. Hearing level
   d. a and b
   e. b and c

ADDITIONAL SOURCES

Chang CYJ, Kamerer DB. Stereotactic radiosurgery for acoustic neuromas. In: House WF, Luetje C, Doyle KJ, editors. Acoustic Tumors: Diagnosis and Management. 2nd ed. San Diego, CA: Singular Publishing Group Inc.; 1997. pp. 309–346.

Kondziolka D, Mousavi SH, Kano H, et al. The newly diagnosed vestibular schwannoma: radiosurgery, resection or observation? Neurosurg Focus 2012;33(3):E8 (Literature review of the natural history of hearing loss over time in acoustic neuroma cases).

Maniakas A, Saliba I. Microsurgery versus stereotactic radiation for small vestibular schwannomas: a meta-analysis of patients with more than 5 year's follow-up. Otol Neurotol 2012;33:1611–1620 (Meta-analysis of hearing results using microsurgery vs. SRS).

Stangerup SE, Thonsen J, Tos M, et al. Long-term hearing preservation in vestibular schwannoma. Otol Neurotol 2010;31:271–275 (Long term hearing results of watch and wait strategy).

149 Dacryocystorhinostomy

Tonya Stefko

INTRODUCTION

- External dacryocystorhinostomy (DCR) was first described by Toti in the early 20th century. The technique is applicable to patients complaining of tearing and demonstrating obstruction of the lacrimal outflow system. The procedure consists of creating a fistula for egress of tears directly from the lacrimal sac into the nose and bypassing the nasolacrimal duct (Fig. 149.1). Description of endonasal DCR took place even before a report of external DCR.

KEY OPERATIVE LEARNING POINTS

- For external DCR, the skin incision should be made in one stroke to the bone to minimize damage to the tissue planes.
- Silicon intubation of the lacrimal system must be performed gently and is used in this procedure both to minimize any scarring of the delicate canaliculi from postoperative inflammation and to help with identification and marsupialization of the lacrimal sac.
- It may be necessary to perform a septoplasty in cases where the septum is deviated toward the side of obstruction.

PREOPERATIVE PERIOD

History

- Congenital or within the first few months of life?
  - In newborns and infants, the most common site of obstruction is distally at the valve of Hasner, where canalization is often incomplete at the time of birth. In most patients, congenital nasolacrimal duct obstruction will resolve by the age of 6 to 12 months, so probing of the lacrimal system should be delayed until the end of the first year of life. Probing of the lacrimal system is most often curative at this age.[1]
- Complete medical history
  - Bleeding/clotting disorders
  - Hypertension-related pathology
  - If the patient will be under general anesthesia, evaluation by the primary physician is frequently necessary.
- In 8% to 14% of DCR surgeries, dacryoliths composed of precipitated organic material will be found.[2,3]
  - Affected patients may complain of intermittent tearing and pain and demonstrate a distended, tender lacrimal sacs but minimal or no inflammation.
  - Alternatively, the dacryolith may mimic complete obstruction and occasionally cause acute dacryocystitis.

Physical Examination

- Patients may complain of tearing for one of three reasons:
  - Hypersecretion of tears
    - Primary hypersecretion of tears is uncommon.
    - Secondary hypersecretion is a frequent cause of tearing.
      - May be due to a variety of ocular surface disorders, some as benign in nature as seasonal allergy. Associated symptoms and signs will help in making these diagnoses, and their proper treatment should proceed before surgical repair.
  - Reflex hypersecretion in patients with ocular surface dryness (as in those with Graves disease) must be addressed by referral to an Ophthalmologist.
    - Abnormal eyelid position can cause reflex tearing by rubbing of lashes against the cornea or by desiccation of the cornea as a result of inadequate blinking or closure.
      - Patients' complaints will assist in making the diagnosis inasmuch as those with surface disorders causing reflex hypersecretion will complain of burning and a foreign body sensation.
      - Fluorescein drops instilled into the conjunctival cul-de-sac will highlight defects in the corneal epithelium when viewed with a cobalt blue filter on a penlight in patients with dry eye.
  - Impaired drainage of tears
    - In adults, tearing secondary to insufficient lacrimal drainage is common.
      - Functional obstruction includes poor function of the medial canthal lacrimal pump, usually secondary to eyelid malposition or aberrant anatomy.
      - Physical obstruction may occur at the level of the punctum, canaliculus, common canaliculus, lacrimal sac, or nasolacrimal duct. The latter two account for about 74% of lacrimal outflow obstructions and are treated with greater than 90% success by external DCR surgery.[4]
  - Combination of both hypersecretion and underdrainage
    - Most patients referred to an Otolaryngologist with complaints of tearing will already have been evaluated by an Ophthalmologist and treated for ocular surface disorders causing hypersecretion. If not, ophthalmologic evaluation should proceed before any consideration of lacrimal surgery for correction of tearing.
- Complete endonasal examination, with particular attention paid to the distal end of the nasolacrimal duct beneath the inferior turbinate, should be performed in the office.
  - Occasionally, physical obstruction of the ostium is visible and readily treated.
  - Significant rhinitis should also be treated before surgical correction because it also rarely causes functional obstruction.
  - Note of any septal defects or deviation is important, particularly if an endonasal approach is selected.

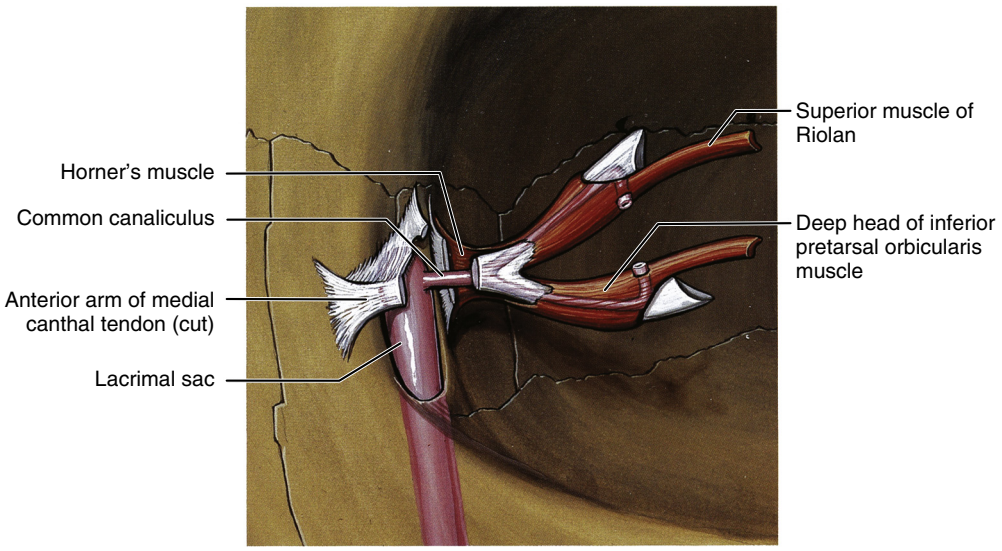

Fig. 149.1. Lacrimal drainage system, superficial anatomy. *(From Dutton JJ. Atlas of Clinical and Surgical Orbital Anatomy. Philadelphia: WB Saunders; 1994.)*

- Dilation and irrigation of the lacrimal system in the office can be used to localize the outflow blockage.
  - Probing of the lacrimal system, however, has no place in adult patients. This procedure is rarely if ever curative and will cause significant patient discomfort. In addition, there is a risk of trauma to the delicate mucosa-lined canalicular system, which is a considerably more difficult problem to treat than nasolacrimal duct obstruction.
  - Quick, easy passage of saline into the nasopharynx after topical anesthesia and gentle injection into the canaliculus may call into question the diagnosis of lacrimal obstruction.
    - However, this will often occur in the setting of a dacryolith because the liquid will drain around the object.
    - It is also sometimes possible to open the nasolacrimal duct with forceful injection, but resistance will be palpable and indicates that the system is probably functionally obstructed (i.e., not functioning under the normal very low physiologic generation of negative pressure).
  - The physician should note the speed and volume of flow, in addition to the presence of resistance or frank reflux of fluid.
    - Reflux in the presence of resistance to flow indicates obstruction.
    - If reflux occurs from the canaliculus being injected or if resistance to easy passage of a 22-gauge or smaller cannula is felt, canalicular obstruction is present, and DCR may not be appropriate.
    - Reflux of fluid from the opposite lid suggests obstruction distal to the common canaliculus, and DCR is likely to be curative.

Imaging

- May not be necessary in straightforward cases of lacrimal outflow obstruction
- Mandatory in children who develop tearing at some point after birth (i.e., acquired not congenital nasolacrimal duct obstruction) in the presence of normal eyelids; this suggests development of a mass
  - Magnetic resonance imaging (MRI) of the face with gadolinium
- Computed tomography (CT) of the orbits and sinuses may be ordered in some situations to evaluate sinus and nasal anatomy and whenever a mass is suspected. It is particularly helpful where there is a history of previous facial trauma.
  - CT of the face with or without intravenous (IV) contrast
- Dacryoscintigraphy may be useful to pinpoint the area of obstruction, but irrigation in the office can usually localize the point of obstruction.

Indications

- Acquired obstruction of the nasolacrimal duct
- Acute dacryocystitis with an abscess unresponsive to antibiotic therapy
  - Patients complain of tearing, discharge, swelling, and pain over the lacrimal sac.
  - Some cases proceed to periorbital cellulitis before diagnosis, so a high index of suspicion in this setting must be maintained.
  - Pressure over the sac produces purulent reflux from the punctum, which is often quite painful for the patient.
  - Probing or irrigation at this time is useless and may complicate the situation.
  - About two-thirds of acute infections grow gram-positive organisms in culture, and about 7% are anaerobic.[5] Treatment of acute infection consists of at least 3 weeks of oral antibiotic, antibiotic-steroid drops, and warm compresses.
  - An abscess in the area requires prompt percutaneous drainage, often possible in the office under local anesthesia. The sac may then be irrigated with antibiotic solution. Occasionally, poor response to oral therapy will require intravenous antibiotic treatment and prompt surgery.
    - This may, however, lead to a lacrimal fistula draining to the skin.
- Endonasal DCR has enjoyed renewed interest since the 1980s but is less preferred because of lagging success rates and expense. Recent reports suggest that the technique is becoming more successful.[6]
- In the presence of any suspicion of a mass in the lacrimal system, external DCR with biopsy is mandatory.

- The symptom of bloody tears is particularly worrisome for the presence of a tumor.
- Palpation of a mass superior to the medial canthal tendon also suggests a lacrimal sac abnormality.

Contraindications

- If a mass is suspected or found at surgery, it may be possible to complete the DCR if the sections are benign, if intraoperative frozen sections are available. If malignancy is found, however, dacryocystectomy with appropriate margins should be performed and creation of an ostium into the nose avoided.
- Successful DCR requires a functional upper outflow system.
  - Treatment of upper system (punctum, canaliculus, and common canaliculus) obstruction must be undertaken either separately or in the setting of surgical DCR.
    - Punctal stenosis may be treated by various punctoplasty techniques.
    - Canalicular stenosis may be treated with silicon intubation, generally only in the setting of incomplete obstruction.
    - Common canalicular stenosis may sometimes be treated in the setting of DCR by silicon intubation.
    - If intractable upper system obstruction is present, primary conjunctivodacryocystorhinostomy with placement of a Jones tube is necessary.

PREOPERATIVE PREPARATION

- Patients should discontinue anticoagulant medication if at all possible.
- Acute dacryocystitis should be treated medically as well as possible.

OPERATIVE PERIOD

Anesthesia

- Local anesthesia with sedation
  - Cocaine is an excellent nasal decongestant and topical anesthetic.
- General endotracheal anesthesia is my preference for patient comfort and protection of the airway.
- The patient may be administered nasal decongestant before anesthesia, or cottonoids soaked in decongestant may be placed.

Positioning

- Supine on operating table

Perioperative Antibiotic Prophylaxis

- 2 G of cephalexin IV
- 600 mg of clindamycin IV if cephalosporin-allergic

Monitoring

- As per anesthesia

Instruments and Equipment to Have Available

- Suction (8 Frasier or similar)
- 0.5 × 3 neurosurgical cottonoids
- Nasal decongestant
- Small skin rakes
- Scalpel (#15 blade)
- Cottle elevator

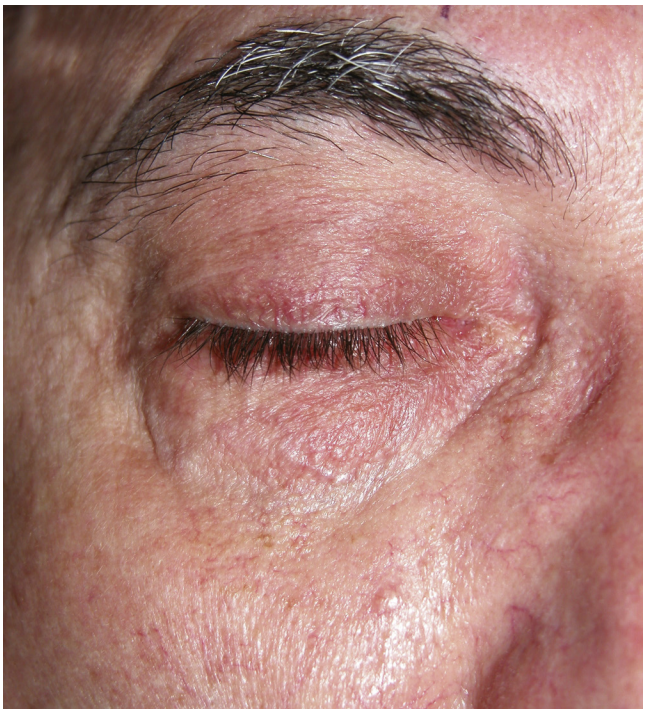

Fig. 149.2. Anterior lacrimal crest (arrow). The incision will be hidden in the lower eyelid crease.

- Small and medium up-biting Kerrison bone punches
- Silicon intubation system (i.e., Crawford or Reitling style)
- Bipolar cautery
- Small Castroviejo needle drivers
- 6.0 Vicryl suture
- 6.0 Silk suture
- 7.0 or 8.0 absorbable or nonabsorbable suture for skin
- 12-French silicon straight catheter

Key Anatomic Landmarks

- The anterior lacrimal crest is the anteriormost border of the orbit and is part of the ascending process of the maxilla (Fig. 149.2).
- The nasal ostium should be made just anterior to the tip of the middle turbinate.
- Bone removal should not proceed more than 2 mm above the medial canthal tendon to ensure no violation of the skull base.

Prerequisite Skills

- Basic surgical tissue handling skills
- Intubation of the nasolacrimal system

Operative Risks

- Failure of surgery to alleviate epiphora
- Infection
- Bleeding
- External scar
- Compromised blink due to violation of some fibers of the zygomatic branch of the facial nerve

Surgical Technique

- A number 15 scalpel blade is used to create an approximately 1.5-cm skin incision over the anterior lacrimal crest by cutting in one stroke down to the periosteum (Fig. 149.3).

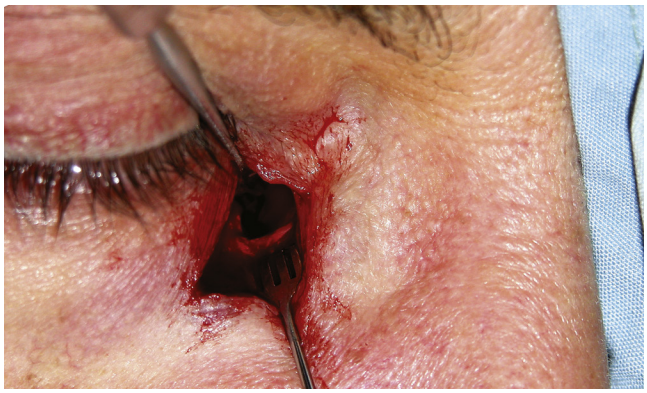

Fig. 149.3. Lacrimal sac elevated from the fossa (medial).



Fig. 149.4. Lacrimal sac reflected and bone partially removed from the fossa.

- A Cottle or similar instrument is used to elevate the periosteum over the maxillary bone. Elevation proceeds posteriorly and superiorly and includes the lacrimal sac fused to the periosteum (see Fig. 149.3).
- A small dehiscence of bone is often encountered at the junction of the maxillary and lacrimal bones and is useful for insertion of a Kerrison punch to begin bone removal.
  - If this dehiscence is not present, the bone may often be cut with a small osteotome.
  - Only rarely is it necessary to drill to gain access to the nose, although drilling is more frequent in patients with duct obstruction when dealing with inflammatory diseases such as sarcoid or Wegener granulomatosis.
  - If the anterior lacrimal crest obstructs visualization, it may be partially resected with the bone punch.
  - A wide area of bone removal facilitates working in the nose (Fig. 149.4).
- The patient's upper punctum is gently dilated, and a 0 or 00 Bowman or similar probe is inserted.
  - The probe is immediately turned medially, and gentle lateral traction is placed on the lid to straighten the canaliculus.
  - When the probe is in the sac, it is rotated up over the medial aspect of the brow and visualized through the wound to be distending the sac.
  - The sac is opened over the probe, and the incision is extended as completely superiorly and inferiorly as possible (Fig. 149.5).

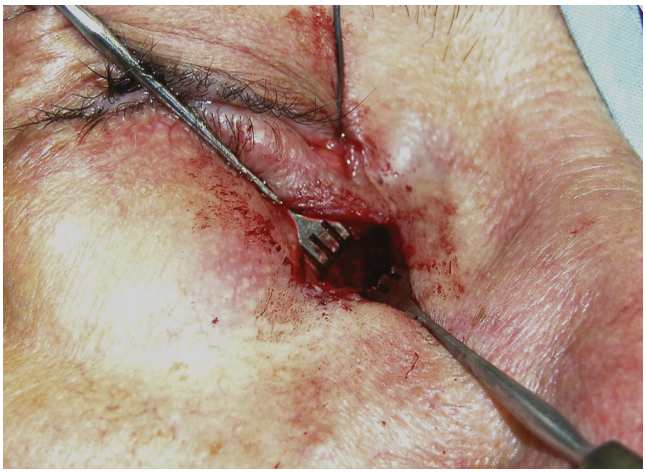

Fig. 149.5. Probe in the lacrimal punctum visible in the wound from the opened lacrimal sac.

  - The sac may be incised with an angled crescent blade, an angled needle-tipped cautery, or a radiofrequency dissector.
  - Extension of the incision in the sac anteriorly at its upper and lower limits is helpful for inspection of the interior of the sac.
  - Any foreign bodies should be removed.
  - A low threshold for biopsy should be maintained.
  - The probe is removed from the lacrimal punctum.
- The nasal packing is now removed.
- A vertical straight or oval opening into the nasal mucosa is created with a needle-tipped cutting/cautery device.
- One probe of a silicon intubation system (such as a Guibor tube) is passed through the upper canaliculus, into the sac, and through the fistula and retrieved in the nose with the appropriate device (such as a grooved director).
- The second probe is passed through the lower canaliculus and retrieved in the same manner. Both tubes are then elevated from the lacrimal sac (through the skin incision) with a small blunt hook, and 6-0 silk suture is tied around both at about the level of the skin incision.
  - The suture should be tied in a single square knot to facilitate later removal via the punctum.
  - The hook should then be used to check tension of the tubes at the medial canthal angle: The loop should prolapse no farther than the medial limbus (Fig. 149.6). The ends of the suture are trimmed to 3 mm.
- Approximately 4 cm of a 12F straight catheter is cut. One end may be beveled with drape scissors if desired.
- It is passed, beveled end first, over both wire probes, into the nasal cavity, and up into the wound. The catheter is retrieved in the wound with sturdy forceps, such as Adson's.
- Double-armed 7-0 chromic gut suture is passed across the lumen of the tube approximately 4 mm from its end while taking care to not cut the silicone stents with the needle (Fig. 149.7).
- The tube is retracted into the nose, and both ends of the suture are passed through the anterior wall of the lacrimal sac. The tube is pulled up into the sac, the sutures are tied in a series of five or six overhand knots, and the ends are cut (Fig. 149.8).
- The lacrimal sac area is now irrigated with an antibiotic solution.
- The three tubes are cut together approximately 1 cm proximal to the naris.
- A 5-0 nylon loose stitch is fashioned to secure the catheter to the nasal mucosa.



Fig. 149.6. Silicon stents should be loose enough to prolapse only as far as the medial corneal limbus.

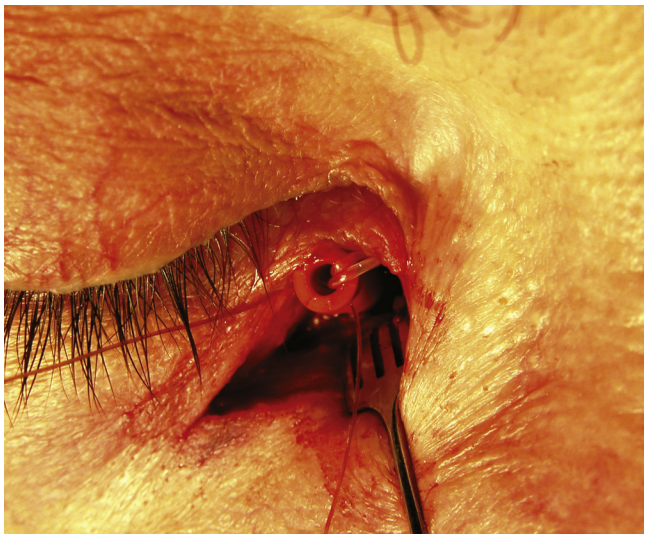

Fig. 149.7. Rubber catheter around the silicone stents and gut suture passed across the lumen (for fixation into the sac remnant).

- The ends are cut short and rotated into the lumen of the tube so that they do not irritate the patient.
- An alternative to the use of the silicon straight catheter is suturing of at least a posterior flap of the lacrimal sac to a posterior flap of nasal mucosa and, if possible, the two anterior flaps over the silicon lacrimal tube, using 6.0 Vicryl.
- Skin is closed with running 8-0 nylon suture or interrupted 7-0 chromic suture, and antibiotic-steroid ointment is applied (Fig. 149.9). This may be followed by a pressure bandage if significant hematoma is expected.

Common Errors in Technique

- Twisting the bone punch when it is directed superiorly may propagate a fracture to the skull base and cause a cerebrospinal fluid (CSF) leak.
- A functional upper lacrimal drainage system must be present for dacryocystorhinostomy to be effective.
- The rubber catheter stent must be sewn securely up into the body of the lacrimal sac.
- Gentle handling of the puncta and canaliculi is essential to avoid injury.

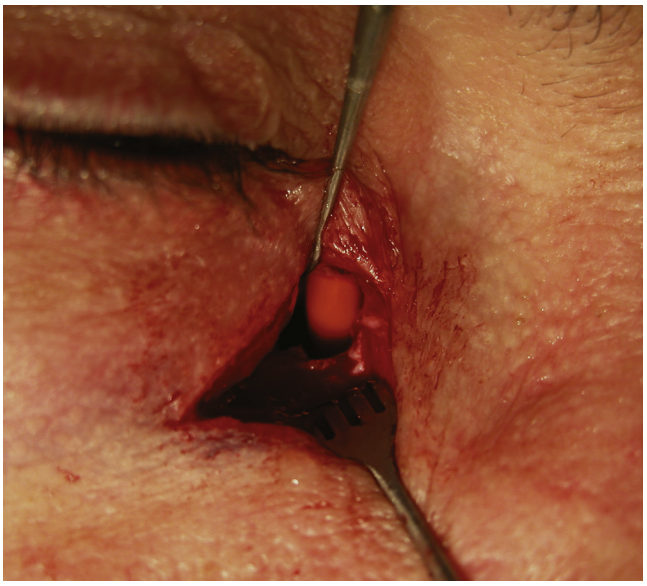

Fig. 149.8. Rubber catheter sewn into the anterior of the sac remnant and tied to rest in the fistula.

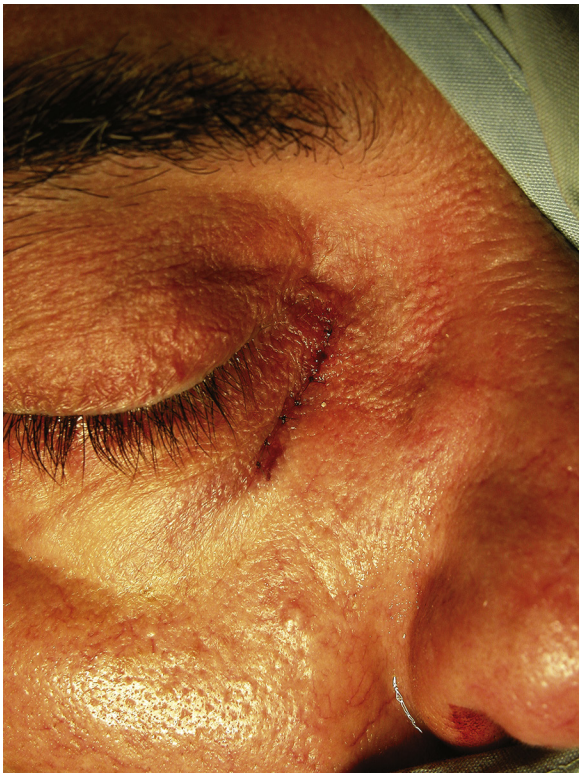

Fig. 149.9. The closed incision will be hidden in the lower eyelid crease.

POSTOPERATIVE PERIOD

Postoperative Management

- Oral antibiotic (as long as the silicon straight catheter will be in place, if used, or if infection was present)
- Topical antibiotic-steroid drops
- Nasal steroid spray
- Topical antibiotic-steroid ointment is applied to the sutures until they are removed in 5 to 7 days.

- Patients are instructed to not blow or pick their noses for 3 weeks. The first three medications are maintained until removal of the silicon straight catheter 10 days to 3 weeks postoperatively.
  - At this time the drops are tapered from 4 times a day to twice a day and then discontinued 1 week later.
  - The nasal steroid is continued until removal of the silicon stents, 2 months postoperatively.
- The patient is seen in the office 1 week postoperatively for removal of the skin sutures.
- One week after this visit (10 days to 2 weeks after surgery) the nylon suture in the nasal cavity is cut, and the catheter is withdrawn from the nostril in the office.
- The chromic gut suture holding the proximal end will have dissolved by this time.
- Two months postoperatively, the silicon tubes are removed either from the naris after cutting at the medial canthal angle or from the punctum by rotating the tube until the silk suture emerges from one punctum, cutting between them, and pulling the end with three lengths of tubing from the punctum.

Complications

- Too much tension on the silicone stent (placing the silk suture too deep) will cause erosion of the lacrimal puncta.
- Failure to put lateral traction on the eyelid (i.e., straightening the canaliculus) while passing a lacrimal probe will cause damage to the canalicular mucosa.

Alternative Management Plan

- Cases of upper system obstruction should be treated with respective appropriate procedures.
- In cases of recurrent infection or discharge in a patient with a dry eye, it may be preferable to do a dacryocystectomy.
- In some cases of inflammatory disease (granulomatous polyangiitis is most notable) a dacryocystectomy is likely more appropriate.
- In cases without severe infection

DISCUSSION

Evidence-Based Medicine Question

What is the success rate of DCR, external and endoscopic?

An analysis of 100 consecutive failed DCRs, about ¾ of them external and the remainder endoscopic, showed that the most common reasons for anatomic failure were inadequate bony ostium, incorrect marsupialization of the lacrimal sac, and closure of the mucosal fistula.[7] These reasons were not different between the two approaches. A recent report of more than 1000 consecutive cases of endoscopic DCR by one surgeon (employing silicon lacrimal stents) showed a success rate of 92.7%.[8] A meta-analysis of more than 2000 cases showed the same success rate for external and endoscopic DCR, 87%.[9] A report of four recently published studies examining the efficacy of both approaches found that when the previous study was removed, the reported success of external DCR was between 91% and 100% and that of endoscopic procedures ranged from 91% to 97%.[10]

Editorial Comment

The external approach to dacryocystorhinostomy is necessary to understand even though in the age of excellent instrumentation many people prefer an endoscopic procedure. In cases of acute infection, suspected mass, suspected dacryolith, and diverticulum of the sac, an external approach will be required. In children, endoscopic DCR has been reported with varying success, as has external DCR. When possible, it is preferable to work with the child's anatomy, by probing first, sometimes more than once, and then placement of silicon stents into the nasolacrimal duct, rather than bypassing normal anatomy entirely.

Tonya Stefko

Access the review questions and additional sources list online at http://www.expertconsult.com



REFERENCES

1. Kashkouli MB, Kassaee A, Tabatabaee Z. Initial nasolacrimal duct probing in children under age 5: cure rate and factors affecting success. J AAPOS 2002;6(6):360–363.
2. Hawes MJ. The dacryolithiasis syndrome. Ophthal Plast Reconstruct Surg 1988;4(2):87–90.
3. Iliadelis E, Karabatakis V, Sofoniou M. Dacryoliths in chronic dacryocystitis and their composition (spectrophotometric analysis). Eur J Ophthalmol 1999;9(4):266–268.
4. Kashkouli MB, Parvaresh M, Modarreszadeh M, et al. Factors affecting the success of external dacryocystorhinostomy. Orbit 2003;22(4):247–255.
5. Coden DJ, Hornblass A, Haas BD. Clinical bacteriology of dacryocystitis in adults. Ophthal Plast Reconstruct Surg 1993;9(2):125–131.
6. Ben Simon GJ, Joseph J, Lee S, et al. External versus endoscopic dacryocystorhinostomy for acquired nasolacrimal duct obstruction in a tertiary referral center. Ophthalmology 2005;112(8):1463–1468.
7. Dave TV, Mohammed FA, Ali MJ, Naik MN. Etiologic analysis of 100 anatomically failed dacryocystorhinostomies. Clin Ophthalmol 2016;10:1419–1422.
8. Jung SK, Kim YC, Cho WK, et al. Surgical outcomes of endoscopic dacryocystorhinostomy: analysis of 1083 consecutive cases. Can J Ophthalmol 2015;50(6):466–470.
9. Huang J, Malek J, Chin D, et al. Systematic review and meta-analysis on outcomes for endoscopic versus external dacryocystorhinostomy. Orbit 2014;33(2):81–90.
10. Marcet MM, Kuk AK, Phelps PO. Evidence-based review of surgical practices in endoscopic endonasal dacryocystorhinostomy for primary acquired nasolacrimal duct obstruction and other new indications. Curr Opin Ophthalmol 2014;25(5):443–448.

REVIEW QUESTIONS

1. A patient with intractable tearing undergoes irrigation of the lacrimal system, with resulting reflux from the canaliculus of the opposite lid. Possible sites of obstruction are
   a. Common canaliculus
   b. Punctum
   c. Opposite canaliculus
   d. Nasolacrimal duct

2. A possible reason for inability to retrieve the probe of the silicon lacrimal stent in the nose is (choose all that apply)
   a. Deviated septum
   b. Punctal obstruction
   c. Eustachian tube dysfunction
   d. Ethmoid air cell medial to the lacrimal fossa

3. Tearing in neonates should be treated with prompt DCR.
   a. True
   b. False

ADDITIONAL SOURCES

Caldwell G. Two new operations for obstruction of the nasal duct with preservation of the canaliculi. Am J Ophthalmol 1893;10:189–192.
Toti A. Nuovo metodo conservatore di cura radicale delle suppurazioni croniche del sacco lacrimale (dacriocistorinostomia). Clin Mod Firenze 1904;10:385–387.

150 Optic Nerve Decompression

Eric W. Wang, Timothy DeKlotz

INTRODUCTION

1. Visual compromise due to injury or compression of the optic nerve can be debilitating and lead to significant impairment in a patient's quality of life.
2. Transcranial and transfacial access for optic nerve decompression have been the classical approaches for surgical intervention, although endoscopic/transnasal approaches are playing a more common role in the management of pathology affecting the optic canal.
   a. Improvements in endoscopic instrumentation, understanding of the anatomy, and increased experience have enabled these advances.
3. Causes of optic nerve injury can be classified as traumatic or nontraumatic optic neuropathy (ON).
   a. Most early endoscopic experience was concerned with treatment of traumatic causes of ON; however, conflicting reports have failed to demonstrate a definite benefit of surgical intervention, which has led to this indication falling out of favor.
   b. Endoscopic decompression is now becoming a more common role in nontraumatic ON secondary to compressive lesions or fibro-osseous disease.

KEY OPERATIVE LEARNING POINTS

1. The optic canal is typically identifiable as a prominence in the superior-lateral wall of the sphenoid sinus.
2. At least 180 degrees of bone must be removed circumferentially from the canalicular segment of the optic nerve after carefully thinning the bone with a high-speed drill.

PREOPERATIVE PERIOD

History

1. History of present illness
   a. Visual complaints: Decreased acuity or color vision, diplopia, periorbital pain, unilateral versus bilateral symptoms
      1) Time course is important to document: Although chronic compression is frequently believed to have a decreased response to decompression, studies fail to correlate the length of time from the onset of the disease and the likelihood of visual improvement.[1]
   b. Additional neurologic symptoms: These symptoms may provide insight into the extent of the disease.
   c. Any recent interventions
2. Past medical history
   a. Prior interventions
      1) Surgical decompressions: Verify type of approach (transnasal endoscopic, transcranial) and outcomes.
      2) Nonsurgical treatment of underlying pathology: This might include radiation for a tumor or high-dose steroids.
   b. Other medical problems, surgeries: Determine if underlying health status may preclude surgical intervention.

Physical Examination

1. Ophthalmologic examination (formal ophthalmology consultation is highly recommended)
   a. Visual acuity (VA)
   b. Afferent pupillary defect: This can be seen prior to any decline in VA.
   c. Color vision testing: Decline in red color vision is seen first and may be present prior to a decline in VA.
   d. Extra-ocular motility
   e. Visual fields testing
   f. Optical coherence tomography: Noninvasive testing can determine the nerve fiber thickness of the retina (long-standing lesions with evidence of nerve atrophy may be less likely to recover function after decompression).[2]
2. Cranial nerves: Concurrent cranial neuropathies can help define the extent of lesions as well as other nerves that may require decompression.
3. Nasal endoscopy: Identify any barriers to an endoscopic approach that may need to be addressed preoperatively or intraoperatively (i.e., septal deviation requiring septoplasty, acute sinusitis requiring antibiotic therapy).

Imaging

1. Computed tomography (CT) with contrast of the sinus
   a. Navigational protocol: 1-mm slice width
   b. Contrast is important for defining the location of the internal carotid artery (ICA) in relation to the optic nerve.
2. ± Magnetic resonance imaging (MRI)
   a. Depends on specific indications of optic nerve decompression (i.e., critical for evaluating extension of the tumor into the optic canal but less important for defining fibro-osseous disease)

Indications

1. Compression due to an extrinsic mass
   a. Tuberculum and planum meningiomas with extension into the optic canal
   b. Mucocele
   c. Fibro-osseous lesion (Fig. 150.1)
   d. Primary sinonasal malignancy (in the absence of nerve invasion)
   e. Fungal ball
   f. Primary tumors of the skull base: chordoma, chondrosarcoma
2. Primary tumor of optic nerve: glioma, meningioma, hemangioma
3. ±– Trauma: Controversial
   a. International Optic Nerve Trauma Study[3]: There is no clear benefit of high-dose steroid therapy versus canal decompression versus observation alone.
   b. Select patients may benefit and be determined on a case-by-case basis.

Contraindications

1. Medical comorbidities precluding safe administration of general anesthesia: May require further optimization of the patient's medical condition if possible versus alternative treatment methods (i.e., radiation, steroids)

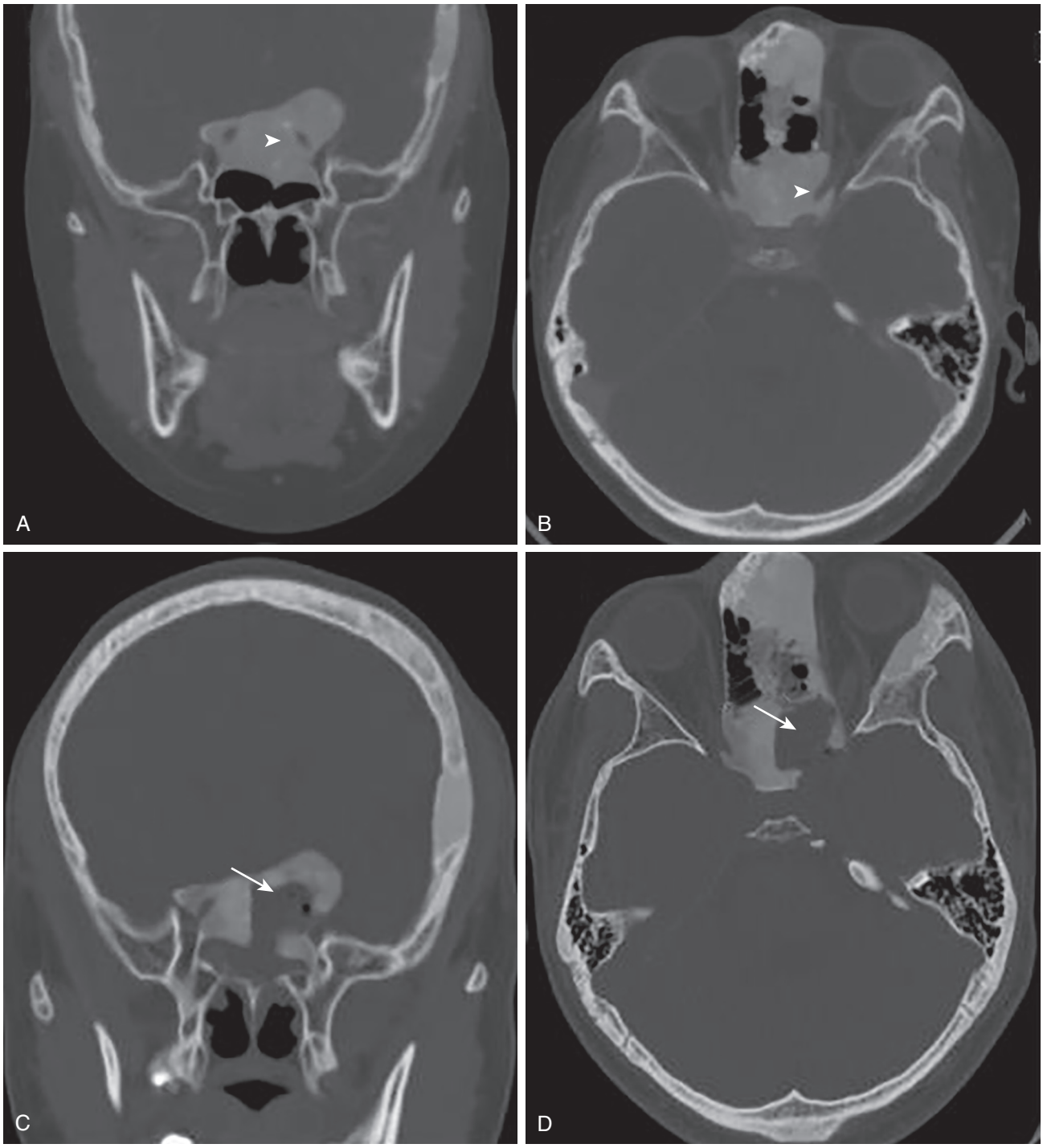

Fig. 150.1. Preoperative, **A, B,** and postoperative, **C, D,** computed tomography scans of a representative patient following endoscopic endonasal optic nerve decompression. Note symptomatic encasement of the left optic nerve *(arrowheads)* by fibrous dysplasia and wide bony decompression *(arrows)*. Right optic nerve with asymptomatic encasement (no prophylactic intervention performed).

2. Technical inexperience: Safe surgery requires significant experience in sinonasal surgery and should not be undertaken by a novice endoscopic sinus surgeon. Team surgery incorporating the skill set of an experienced otolaryngologist and neurosurgeon can be beneficial.
3. Trauma: See *Indications* above. Controversial indication and more recently has fallen out of favor
4. Optic nerve encasement, fibrous dysplasia: Surgical decompression of nerve encasement without visual compromise
   a. Surgery in asymptomatic patients is associated with visual deterioration.[4]

Preoperative Preparation

1. Documented formal ophthalmologic examination
2. Correct coagulopathy if present
3. Evaluate preoperative imaging for any variations in sphenoid pneumatization (i.e., an Onodi cell).

OPERATIVE PERIOD

Anesthesia

1. General endotracheal anesthesia

Positioning

1. Head position: Mild extension and rotation toward surgeon
2. Rigid fixation with head pins (i.e., Mayfield head clamp): Ensures no accidental movements during dissection and drilling around critical neurovascular structures
3. Body position: Supine, reverse Trendelenburg decreases intraoperative bleeding.

Perioperative Antibiotic Prophylaxis

1. First-generation cephalosporin, although consider ceftriaxone given the potential risk for cerebrospinal fluid (CSF) leak

Monitoring

1. None
2. Somatosensory evoked potentials: Can be considered if ICA is at particular risk
3. Electromyogram (EMG): Monitoring of other cranial nerves is dependent upon the risk based on the extent of the tumor.

Instruments and Equipment to Have Available

1. Endoscopic sinus surgery instrument set
2. Endoscopic bipolar cautery
3. High-speed elongated drill with diamond bur
   a. Recommend having 4- and 2-mm burs available
   b. Self-irrigating system

Key Anatomic Landmarks

1. Sphenoid sinus
   a. Most posterior paranasal sinus, located immediately posterior to the posterior ethmoid sinuses
   b. Paired: Separated by an intersinus septation
   c. Natural sphenoid os is medial to the superior turbinate, approximately ⅓ to ½ of the height from its lower border.
   d. Multiple important landmarks within the sinus will guide safe surgery (Fig. 150.2).
      1) Lateral opticocarotid recess: Pneumatization of the optic strut, bordered by the optic nerve and ICA posteromedially
         a) Defines the extent of the osseous canalicular segment of the optic nerve
      2) ICA prominence: Be constantly aware of this critical landmark to prevent potential catastrophic complication; it may be dehiscent.
      3) Optic nerve prominence: Key area of planned decompression
2. Optic nerve
   a. Travels in an anterolateral-to-posteromedial direction until reaching the chiasm
   b. Divided into four segments[5]
      1) Intraocular
      2) Orbital
      3) Canalicular
         a) True canalicular: Complete osseous canal
         b) Preforaminal: Under the falciform ligament
      4) Intracranial
   c. CSF extends into the canal proximally and may lead to a CSF leak if the optic nerve sheath is injured or opened.
   d. Ophthalmic artery (OA)
      1) Compromise can lead to visual loss.
      2) Typically arises from the ICA (although in a few patients, the OA can arise from a branch of the ICA or even the external carotid artery)[6,7]
      3) Within the canalicular segment, the OA lies inferior or inferomedial to the nerve.
         a) Travels laterally: At the intraorbital os, it lies inferolaterally.
      4) Runs within the optic canal sheath
         a) In a small subset of patients, it may travel in a separate bony canal inferiorly.
3. Onodi cell: Posterior superior pneumatization of a posterior ethmoid cell
   a. The previously discussed landmarks may be present within an Onodi cell instead of the sphenoid sinus depending on the extent of the cell.

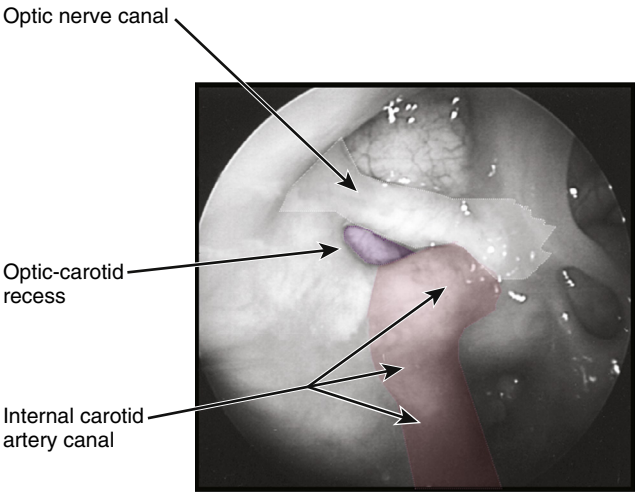

Fig. 150.2. Endoscopic view within the right sphenoid sinus demonstrating key anatomic landmarks; lateral opticocarotid recess, optic nerve prominence, internal carotid artery prominence. Pneumatization can vary and landmarks may be less visible in under-pneumatized sinuses.

Prerequisite Skills

1. Endoscopic ethmoidectomy (see Chapter 108, 3rd ed.)
2. Endoscopic sphenoidotomy (see Chapter 110, 3rd ed.)

Operative Risks

1. Optic nerve injury
   a. Thermal injury from high-speed drill
   b. Direct trauma during dissection
2. Hemorrhage
   a. Most commonly from cut mucosal edges
   b. Posterior septal branch of sphenopalatine artery can lead to brisk arterial bleeding.
   c. Catastrophic hemorrhage is possible if there is injury to the ICA.
3. Orbital injury
   a. Violation of the periorbita exposes the intraorbital contents to possible harm.

4. CSF leak
   a. Violation of the optic nerve sheath or anterior clinoid dura can lead to a CSF leak.

Surgical Technique (Video 150.1)

1. Nasal cavity decongestion: Topical oxymetazoline (0.05%) or epinephrine (1:1000) per surgeon preference
2. Uninarial approach
   a. Exceptions include (1) bilateral decompressions or (2) increased access required for tumor resection
3. Ipsilateral middle turbinate: Medialized or resected for access
   a. Preserve if possible, but do not hesitate to remove if limiting visualization.
4. Total ethmoidectomy
   a. Important to take down all septations, especially along the medial orbit and skull base to maximize visualization
5. ± Maxillary antrostomy
   a. May be performed for further delineation of the orbit if required
6. Wide sphenoidotomy
   a. The ipsilateral sphenoid sinus is maximally opened from planum sphenoidale to the floor of the sinus.
   b. Laterally, bone is removed flush with the orbital apex.
   c. The wide opening provides access for improved visualization and adequate freedom of mobility for dissection.
7. Identify key surface landmarks within the sphenoid sinus (see Fig. 150.2).
   a. In the absence of clear landmarks (i.e., fibrous dysplasia), stereotactic navigation can be helpful.
   b. Clear delineation of the medial orbit is imperative.
8. Posterior medial orbital decompression
   a. Thin posterior orbital bone can be dissected free after gently fracturing with a Cottle elevator.
   b. Thicker bone of the orbital apex will need to be thinned with a high-speed drill prior to dissecting free.
   c. Keep periorbita intact, otherwise orbital fat will herniate into the operative field and obstruct the surgeon's view.
      1) If a small amount of adipose tissue is obstructing an adequate view, judicious use of bipolar cautery can shrink the tissue. Do not attempt to resect this tissue.
9. Drilling and thinning of the orbital apex and optic canal (Fig. 150.3)
   a. A self-irrigating drill or copious handheld irrigation is used to prevent thermal injury to the underlying nerve.
   b. Bone is dissected free up to the tuberculum, optic strut, and paraclinoidal ICA (Figs. 150.4 and 150.5).
   c. At least 180 degrees of decompression is required to be considered adequate.
      1) Frequently up to 270 degrees of decompression can be achieved, especially if the anterior clinoid is well pneumatized.
   d. A 2-mm drill bit may be required when drilling the anterior clinoid, optic strut, and superior surface of the optic canal.
10. The optic nerve sheath is usually not opened.
11. The decompressed optic nerve can be covered with fibrin glue.
    a. Nasal packing is generally not employed given the potential for nerve compression and injury.
       1) The exception is following more complex cases requiring intradural dissection of the tumor and skull base reconstruction (in which optic nerve decompression is only a component of the overall procedure).
          a) Only gentle pressure with nasal tampon sponges is used to reinforce the reconstruction.

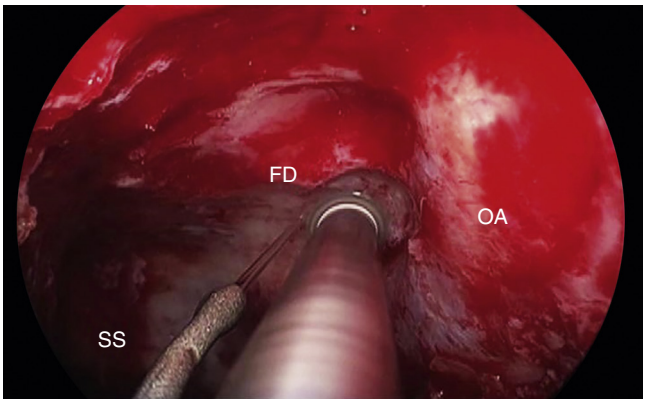

Fig. 150.3. Endoscopic view of the left sphenoid sinus and orbital apex. Abnormal bone overlying the orbital apex and optic nerve is drilled using a self-irrigating drill to prevent thermal injury. *FD,* Fibrous dysplasia; *OA,* orbital apex; *SS,* sphenoid sinus.

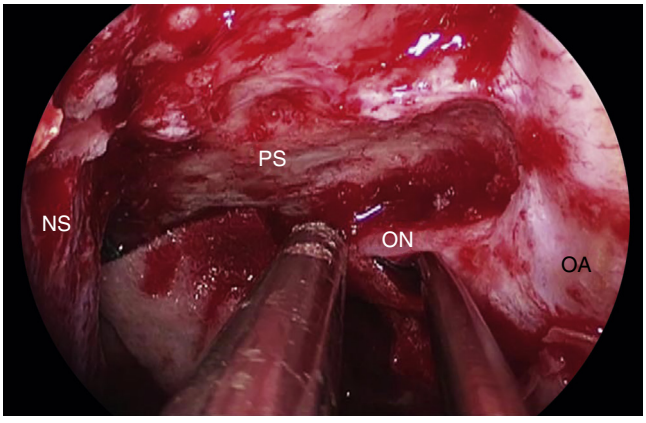

Fig. 150.4. Decompressed left orbital apex. Thinned bone overlying the left optic nerve is dissected free with a fine dissector. *NS,* Nasal septum; *OA,* orbital apex; *ON,* optic nerve; *PS,* planum sphenoidale.

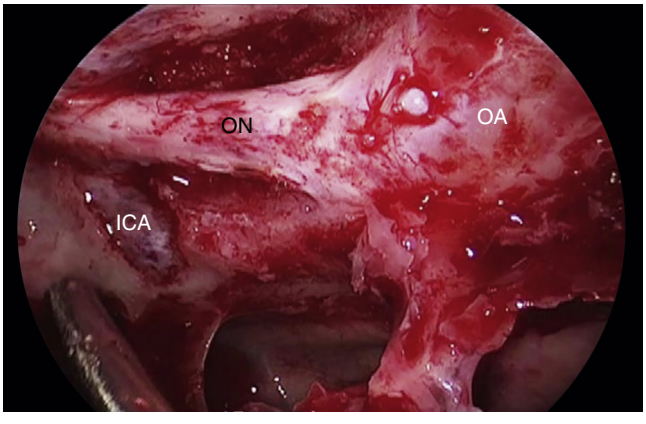

Fig. 150.5. Final decompression viewed with 45-degree endoscope demonstrating greater than 180 degrees of bony decompression of the optic nerve. The left internal carotid artery has been exposed without injury. *ICA,* Internal carotid artery; *OA,* orbital apex; *ON,* optic nerve.

Common Errors in Technique

1. Violation of periorbita can lead to an obstructed view.
2. Failure to use adequate irrigation can cause thermal injury of the optic nerve.
3. Placement of compressive nasal packing postoperatively can lead to nerve injury.

POSTOPERATIVE PERIOD

Postoperative Management

1. Nasal saline irrigation is started on postoperative day 1.
   a. Large-volume irrigations can be used immediately if an isolated nerve decompression procedure is performed.
   b. If part of a larger tumor resection procedure with intradural dissection (and requiring temporary packing for bolstering of a skull base reconstruction), then only nasal saline spray is used 4 times per day
2. Overnight admission is warranted to ensure no postoperative complications and for regular vision checks.
3. Antibiotics are generally not warranted postoperatively unless nasal packing is used.
4. Patient instructions are similar to those following standard sinus surgery.
   a. No nose blowing
   b. Avoid heavy lifting (<15 lbs) or strenuous activity for 1 to 2 weeks.
   c. Sneeze with an open mouth.

Complications

1. Epistaxis
   a. Minor oozing is common postoperatively and can typically be controlled with topical decongestant sprays.
   b. More significant bleeding is uncommon and the patient should be taken back to the operating room for exploration and control. The posterior septal branch of the sphenopalatine artery (as it crosses the anterior face of the sphenoid sinus) is the usual source of bleeding.
2. CSF leak
   a. Small risk during ethmoidectomy
   b. Superior decompression of the nerve may place the patient at particular risk of leak, notably if the corridor is narrow due to poor pneumatization of the anterior clinoid.
   c. Postoperative rhinorrhea can be collected and sent for confirmatory beta-2 transferrin testing if there is a high level of suspicion of a CSF leak.
   d. Head CT with any intracranial air is consistent with a dural defect.
   e. Immediate surgical repair is recommended rather than attempting conservative measures (i.e., lumbar drainage).
      1) A free graft (mucosal, adipose tissue) is likely all that would be required for repair.
3. Visual deterioration
   a. Inadequate irrigation while drilling over the nerve can lead to thermal injury.
   b. Vascular injury to the OA is possible.
   c. Compressive nasal packing can lead to neuropraxic injury and should be removed completely if possible or partially (if bolstering of skull base reconstruction is required).

Alternative Management Plan

1. Steroids
   a. Although steroids may temporize edema of the optic nerve, this is not a long-term solution to compressive pathology.
2. Radiation
   a. Can be used for select tumors, though use in close proximity to the optic nerve places vision at significant risk
3. Transcranial approach for optic nerve decompression

DISCUSSION

Evidence-Based Medicine Question

Is transnasal endoscopic optic nerve decompression more effective than traditional open approaches for treatment of nontraumatic ON?

1. Current literature for endoscopic optic nerve decompression is limited to small retrospective case series with no direct comparison trials reported.
   a. Although results are promising for the endoscopic approach, this procedure cannot be considered the standard of care for compressive pathology given the relatively limited amount of outcomes data available.[8]
   b. Further research is required to support the regular use of the endoscopic approach over other approaches.
2. The favorable safety profile of the procedure has been demonstrated through larger case series performed for traumatic ON.[9]

Editorial Comment

Endoscopic optic nerve decompression can be a challenging procedure and should not be approached by a novice endoscopic sinus surgeon. Stereotactic navigation can be a useful aid in surgery, but anatomic landmarks are more reliable. Bony decompression of at least 180 degrees is necessary to be considered adequate. Avoid nasal packing unless absolutely necessary to prevent possible compression injury to the optic nerve.

Tonya Stefko

Access the review questions online at http://www.expertconsult.com

REFERENCES

1. Bulters DO, Shenouda E, Evans BT, et al. Visual recovery following optic nerve decompression for chronic compressive neuropathy. Acta Neurochir (Wien) 2009;151(4):325–334.
2. Jacob M, Raverot G, Jouanneau E, et al. Predicting visual outcome after treatment of pituitary adenomas with optical coherence tomography. Am J Ophthalmol 2009;147(1):64. e2-70.e2.
3. Levin LA, Beck RW, Joseph MP, et al. The treatment of traumatic optic neuropathy: the International Optic Nerve Trauma Study. Ophthalmology 1999;106(7):1268–1277.
4. Amit M, Collins MT, FitzGibbon EJ, et al. Surgery versus watchful waiting in patients with craniofacial fibrous dysplasia—a meta-analysis. PloS One 2011;6(9):e25179.
5. Abhinav K, Acosta Y, Wang W-H, et al. Endoscopic endonasal approach to the optic canal: anatomic considerations and surgical relevance. Neurosurgery 2015;11(Suppl 3):431–445. discussion 445-446.
6. Locatelli M, Caroli M, Pluderi M, et al. Endoscopic transsphenoidal optic nerve decompression: an anatomical study. Surg Radiol Anat 2011;33(3):257–262.
7. Li J, Wang J, Jing X, et al. Transsphenoidal optic nerve decompression: an endoscopic anatomic study. J Craniofac Surg 2008;19(6):1670–1674.
8. Berhouma M, Jacquesson T, Abouaf L, et al. Endoscopic endonasal optic nerve and orbital apex decompression for nontraumatic optic neuropathy: surgical nuances and review of the literature. Neurosurg Focus 2014;37(4):E19.
9. Li H, Zhou B, Shi J, et al. Treatment of traumatic optic neuropathy: our experience of endoscopic optic nerve decompression. J Laryngol Otol 2008;122(12):1325–1329.

REVIEW QUESTIONS

1. At least _____ degrees of bony decompression must be accomplished to be considered an adequate optic nerve decompression.
   a. 90
   b. 120
   c. 180
   d. 270

2. What segment of the optic nerve is particularly at risk due to circumferential bony encasement of the nerve?
   a. Intraocular
   b. Orbital
   c. Canalicular
   d. Intracranial

3. What is *not* an indication of optic nerve decompression?
   a. Tumor extension into the optic canal
   b. Optic nerve glioma
   c. Fibrous dysplasia encasing the optic nerve without impaired nerve function
   d. Fibrous dysplasia encasing the optic nerve with impaired nerve function

4. The _____ defines the extent of the osseous canalicular segment of the optic nerve.
   a. Lateral opticocarotid recess
   b. Orbital apex
   c. Internal carotid artery
   d. Sella

5. Which option is *not* a potential cause of visual impairment following surgery?
   a. Thermal injury due to inadequate use of irrigation
   b. Injury to the ophthalmic artery
   c. Compression from nasal packing
   d. Failure to perform a maxillary antrostomy

151 Orbital Decompression

Tonya Stefko, Carl H. Snyderman

INTRODUCTION

- Decompression of the orbit may be considered for the treatment of space-occupying lesions causing compromise of function as a result of expansion of the orbital contents or a decrease in the rigid orbital confines. The volume of the orbit averages about 30 mL, and it is only anteriorly that it is not bound by bone. By far, the most common indication for decompression is Graves orbitopathy, but similar surgical techniques are applied to infectious, traumatic, neoplastic, and iatrogenic etiologies (e.g., orbital hematoma after sinus surgery) (Figs. 151.1 and 151.2).
- The incidence of Graves disease in the general population is about 1% to 3%. Females are affected about 5 times as often as men, but older men who experience orbitopathy often have a more fulminant course. About one-third of patients with Graves disease will have orbitopathy, often asymmetrical and usually mild or moderate. Approximately 85% of patients evaluated primarily for orbitopathy will be found to have a dysthyroid state. In adults, Graves disease is the most common cause of unilateral and bilateral proptosis. The first report of decompression for this condition occurred in 1911.[1]
- The pathogenesis of Graves orbitopathy remains only partially understood. Serum levels of antibodies to the thyroid-stimulating hormone (TSH) receptor and collagen XIII seem to correlate with orbital disease activity.[2] TSH receptors are found on orbital fibroblasts, which may differentiate into adipocytes, and are more sensitive to TSH receptor antibodies than dermal fibrocytes. The proptosis is due to an increase in retrobulbar glycosaminoglycan deposition and edema and to a later increase in retrobulbar adipose tissue. Smoking is thought to affect this by creating increased oxygen-reactive species or by causing local tissue hypoxia, both of which lead to increased chemokines recruiting T cells from the bloodstream. TH2 cells are the predominant type involved in the orbital disease.[3]
- The acute phase of the disease, which consists of orbital congestion, inflammatory cell infiltrate, and forward movement of the globe, generally lasts between 6 and 24 months. After this phase, the disease is characterized pathologically by increased fibrosis of the tissues. A second acute phase may occasionally affect the patient later in life. Asymmetrical involvement of the orbits occurs frequently.
- The only external factor proven to affect Graves orbitopathy is cigarette smoking. Current smoking outweighs previous smoking as a predictor of disease severity. Patients in whom orbital disease develops are 4 times as likely to smoke, and discontinuation of smoking appears to lessen the severity and protect patients from the development of further symptoms.[4] Pretibial myxedema, thyroid acropachy (swelling of digits and toes), and female sex are also associated with more severe orbital disease.[5]
- Symptoms of Graves orbitopathy include eyelid retraction, proptosis, diplopia, dryness of the eyes, a sensation of pressure behind one or both eyes, and swelling of the eyelids and conjunctiva (chemosis). Signs consist of eyelid retraction more than 1 mm from the limbus, eyelid lag on downward gaze (failure of the upper eyelid to descend properly when the patient looks down), unilateral or bilateral proptosis, restriction of extraocular movements (particularly upward gaze and abduction), hyperemia over the insertions of the horizontal rectus muscles, and corneal staining with fluorescein observed with a cobalt filter (Figs. 151.3 and 151.4).
- The courses of the orbital disease and any associated thyroid disease in Graves disease are independent. Euthyroid patients may have severe orbitopathy causing optic neuropathy or corneal perforation, whereas severely hyperthyroid patients may have no orbital signs or symptoms. Treating the thyroid abnormalities is essential to the patient's general health, but it is unlikely to help the eye disease. Exceptions are removal of a large goiter, which may lessen the orbital symptoms, and treatment with radioactive iodine, which sometimes acutely worsens the condition of the orbits (ameliorated by concurrent treatment with oral steroids).[6]
- Orbital decompression is sometimes undertaken for other causes of proptosis: infection with abscess, tumor, trauma to the optic nerve, or hematoma (such as might occur after endoscopic sinus surgery). Abscesses located along the lamina papyracea in the orbit or medially along the roof or floor are most amenable to endoscopic drainage. Occasionally, an orbital apex tumor causing compressive optic neuropathy (CON) may be successfully treated by decompression when resection of the tumor is inadvisable.[7]

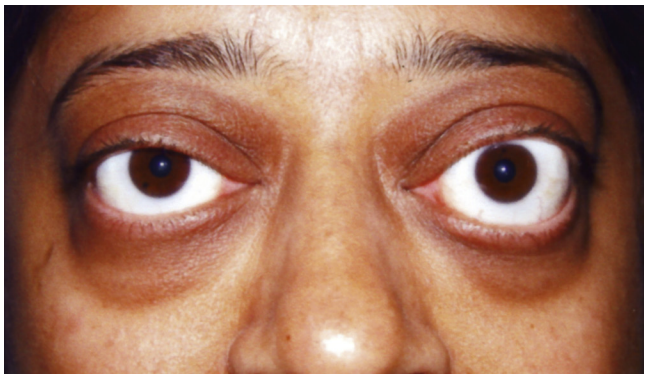

Fig. 151.1. Patient with Graves orbitopathy preoperatively.

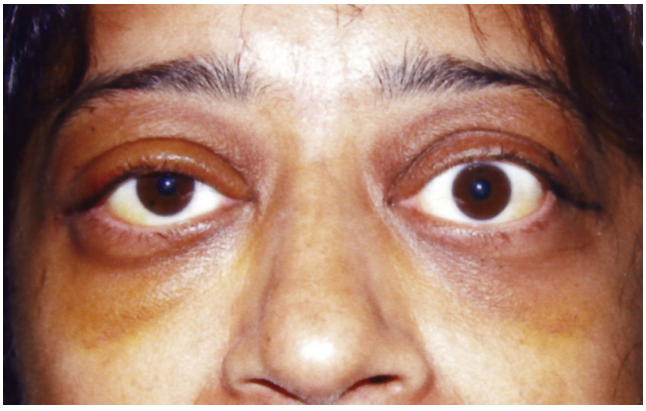

Fig. 151.2. Patient with Graves orbitopathy 6 days after balanced decompression of both eyes.

Key Operative Learning Points

- Whenever possible, defer orbital decompression in Graves patients until the disease has been treated medically and is no longer active.
- In cases of poorly responding optic neuropathy or impending corneal perforation, it may be necessary to operate during the active phase of the disease.
- The number of walls decompressed correlates directly with the reduction in proptosis. The most reasonable approach appears to be the balanced decompression:[8] removal of the medial and lateral walls of the orbit. A recent meta-analysis suggests that the average reduction in proptosis is 4.5 mm regardless of the method used.[9] The roof is rarely decompressed, and decompressing the orbital floor gives a higher likelihood of new postoperative diplopia.[10]



Fig. 151.3. Patient with Graves orbitopathy, optic neuropathy in the right eye, visual acuity of 20/50 in the right eye, and Ishihara color vision of 1.5 of 11 plates. Note the apical crowding *(arrow)*.

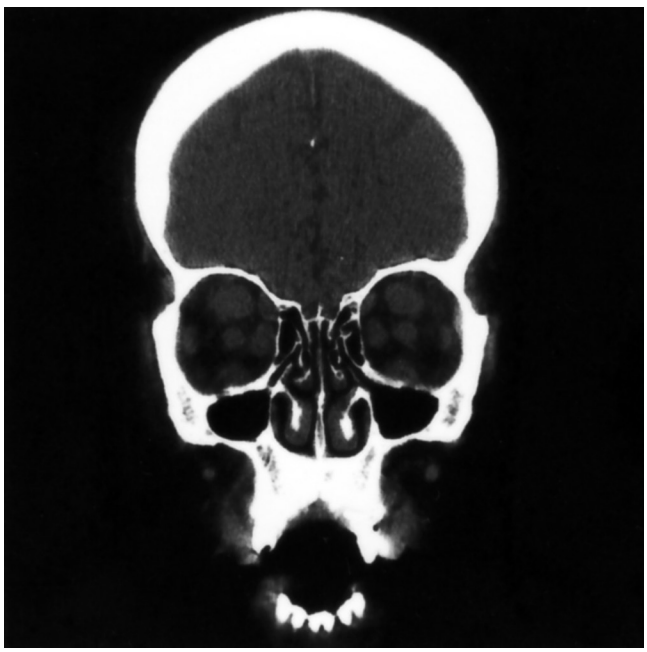

Fig. 151.4. Coronal view of the patient in Fig. 151.3.

PREOPERATIVE PERIOD

History

- Smoking
- Thyroid status (euthyroid; previous treatments to render the patient euthyroid)
- Previous eye surgery
- Diplopia
  - In primary gaze
  - In other positions of gaze
- Previous sinus problems/surgeries

Physical Examination

- Complete eye examination by an Ophthalmologist
  - Best corrected visual acuity
  - Color vision
  - Extraocular movements
  - Pupillary responses
  - Intraocular pressure
  - Biomicroscopic examination of ocular surface and posterior segment
  - Hertel exophthalmometry (measures projection of each globe beyond the orbital rim)
- Nasal endoscopy. Endoscopic examination of the nasal cavity is performed to identify structural abnormalities that may interfere with surgery (septal deviation), coexistent disease that needs to be addressed at the time of surgery (nasal polyposis), and conditions that need to be treated prior to surgery (acute or chronic rhinosinusitis).

Imaging

- Computed tomography (CT) (no contrast) of maxillofacial structures to determine whether there is sinus disease or septal deviation and assess the relative size of the extraocular muscles and orbital adipose tissue compartments. Other anatomic variations that may pose a problem during surgery include a low cribriform plate, Onodi cells, Haller cells, or non-pneumatization of sinuses.
- Magnetic resonance imaging (MRI; particularly T2 sequence) of orbits if there is any question whether the disease is active (inflammatory phase)

Indications

- Urgent decompression during active phase of inflammation (for Graves):
  - Compressive optic neuropathy
  - Corneal ulceration
- Elective decompression after the disease is quiescent (for Graves):
  - Proptosis
  - Sensation of pressure or pain
  - Dryness of the eyes
  - Subluxation of the globe

Contraindications

- Active sinus infection. Adequate medical or surgical management of sinus infection is necessary before orbital surgery due to the risk of infection spreading to the orbital tissues.
- Coagulopathy
- Unacceptable anesthesia risk

Preoperative Preparation

- CT scan
- Image-based navigation is optional and is not necessary unless there are anatomic variations or changes from prior surgery that obscure anatomic landmarks. If an optic nerve decompression is planned at the same time, navigation is helpful to identify the course of the optic canal and internal carotid artery.
- Preoperative counseling is particularly important so that the patient understands that this procedure, when performed for Graves disease, is likely to be the first in a series of surgeries. Strabismus surgery may be performed for unresolved diplopia, and eyelid surgery (either correction of retraction or blepharoplasty) may be required after that.
- Decide whether septoplasty or additional sinus surgery is necessary.
- Bilateral orbital decompression
  - Only rarely does it makes sense to stage this operation in a case of bilateral disease; however, there are a few patients in whom the orbitopathy is very asymmetrical and one orbit only may be decompressed.

OPERATIVE PERIOD

Anesthesia

- General endotracheal anesthesia

Positioning

- Patient supine with head elevated >15 degrees to decrease bleeding

Perioperative Antibiotic Prophylaxis

- Two grams cephalexin IV

Monitoring

- As per anesthesia

Instruments and Equipment to Have Available

- Medial wall decompression
  - High-definition monitor
  - Zero- and 45-degree nasal endoscopes
  - Extended-tip bipolar cautery
  - Separate suction setup
  - Monopolar suction electrocautery
  - Standard endoscopic sinus surgery set
  - Kerrison bone punches
  - Cottle elevator
  - Ball probe
  - Extended disposable sickle knife (Beaver blade)
  - Endoscopic drill with 3- or 4-mm coarse diamond bit is optional.
  - Doyle silastic splints
- Lateral wall decompression
  - Needle-tip monopolar electrocautery
  - Curved blunt tenotomy scissors (such as Stevens)
  - Selection of brain ribbon retractors
  - Desmarres retractors, medium size
  - Reciprocating bone saw
  - Bone wax
  - Small bone rongeurs
  - High-speed drill with cutting burr
  - Toothed forceps
  - Blunt Westcott scissors
  - Fine-needle drivers
  - Penrose drain
  - 6.0 Vicryl and 7.0 absorbable or nonabsorbable sutures

Key Anatomic Landmarks

- Superiorly, bone is removed to within 2 mm of the skull base while being careful to not fracture the skull base.
- The anterior ethmoidal artery crosses the roof of the ethmoid sinus between the second and third lamellae, just posterior to the nasofrontal recess, and is susceptible to injury.
- Examination of the maxillary sinus with an angled endoscope usually reveals the neurovascular bundle of the infraorbital nerve running across the roof of the maxilla. This is the lateral limit of bone removal from the orbital floor.
- Landmarks within the sphenoid sinus are identified: the carotid canal, optic canal, and lateral optic-carotid recess. Drilling of bone should be along the axis of the optic canal to avoid injury to the carotid artery.
- In patients with compressive optic neuropathy, it is vital to perform posterior medial wall decompression to relieve pressure on the optic nerve in the orbital apex.

Prerequisite Skills

- Endoscopic maxillary antrostomy, ethmoidectomy, and sphenoidotomy
- Nasal septoplasty
- Lateral orbitotomy

Operative Risks

- Violation of the skull base with cerebrospinal fluid (CSF) leak
- Bleeding from the anterior ethmoidal artery with orbital hematoma
- Traumatic injury of the optic nerve or internal carotid artery
- Hypesthesia from injury of the infraorbital nerve or descending palatine nerve
- Laceration of the medial rectus muscle

Surgical Technique

It does not matter whether the medial wall or lateral wall decompression is performed first. A relative advantage of performing the medial wall decompression first is that the orbital contents are under greater pressure and herniation of orbital adipose tissue into the sinus cavity is facilitated with external orbital massage.

Medial Wall Decompression

- A skin prep is optional.
- The nose is decongested with cottonoid pledgets soaked in 0.05% oxymetazoline.
- If a septoplasty is necessary for access, it is performed first.
- The inferior aspect of the middle turbinate is resected with curved sinus scissors to provide greater access and room for the orbital tissues to expand.
- The uncinate process is removed, and the antrostomy is maximally enlarged posteriorly and superiorly so that the junction of the medial and inferior walls of the orbit is exposed.
- The bulla ethmoidalis is opened for removal of ethmoid air cells in an anterior-to-posterior direction.

- The sphenoid sinus is opened, and the sphenoidotomy is maximally enlarged with Kerrison rongeurs. Residual septations are then removed in a posterior-to-anterior direction along the skull base. The nasofrontal recess is exposed, but further dissection of the frontal sinus is unnecessary and may predispose to stenosis.
- Bleeding from either the anterior ethmoidal artery or sphenopalatine artery is controlled with monopolar or bipolar electrocautery.
- The medial wall of the orbit is palpated and the thin bone of the lamina papyracea is fractured anteriorly with a Cottle elevator. Bone fragments are carefully elevated from the underlying periorbita with a Cottle elevator or ball-tipped probe.
- Removal of bone continues posteriorly to the anterior face of the sphenoid sinus, superiorly to the skull base, and inferiorly to the junction of the medial and inferior orbital walls.
- The floor of the orbit is then removed with angled Kerrison rongeurs to the medial aspect of the neurovascular bundle. The bone at the junction of the medial and inferior walls can be very thick and may require drilling. Removal of additional bone does not contribute to decompression and risks injury to the nerve and hypoglobus (vertical descent of the globe).
- If the decompression is being done for proptosis, decompression of the orbital apex beyond the anterior wall of the sphenoid sinus is not necessary. If the patient is undergoing decompression for visual loss, additional bone is removed posterior to the entrance of the optic canal.
- A sickle blade is used to incise the periorbita of the medial orbit, starting posteriorly and superiorly and proceeding anteriorly. A disposable Beaver blade is preferred because it is sharper than reusable knives. The blade can be bent 30 degrees toward the orbit approximately 1 to 2 cm from the tip to provide a greater reach. The metal is brittle, however, and may snap if overbent. Multiple parallel horizontal incisions (at least three) are made from the ethmoid roof to the floor of the orbit. Each incision is superficial and parallel to the course of the medial rectus muscle so that the fibers of an enlarged muscle are not inadvertently transected. Intervening strands of periorbita are cut to allow complete herniation of the orbital contents. Gentle external pressure on the eyelids with the hand highlights remaining strands of periorbita and facilitates herniation of orbital adipose tissue into the ethmoid defect (Video 151.1).
- Hemostasis is obtained with warm saline irrigation.
- Silastic nasal splints are placed to prevent intranasal synechiae. Care must be taken not to catch the orbital tissues with the edge of the splint. Nasal packing is not used due to the risk of orbital hematoma.

Lateral Wall Decompression

- The skin is prepped with ophthalmic Betadine solution.
- The eyes are administered ointment and left unsutured during the procedure.
  - In patients with poor closure, it may be useful to temporarily suture the contralateral eye to protect it.
- The lateral wall of the orbit is approached through a lateral canthotomy incision. The incision is approximately 2 cm in length and extends posteriorly from the lateral canthal angle in a crow's foot crease. Stevens or similar scissors are used to cut the lateral canthal ligament and deepen the incision to bone. Bleeding is controlled with electrocautery. The periosteum is incised vertically along the apex of the rim with a scalpel or needle-tipped electrocautery. A Cottle elevator is then used to elevate the periosteum from the lateral orbital wall while keeping the periorbita intact as much as possible. The periosteum must be elevated from both the interior and exterior surfaces of the lateral wall of the orbit. The bone should be identified as far superiorly as the fossa of the lacrimal gland and inferiorly to just above the level of the zygomatic arch. Careful elevation along the exterior surface proceeds in a posterior direction and then turns medially in the temporal fossa.
- Once the periosteum has been elevated from the bone, a wide ribbon retractor is inserted between the periorbita and bone by an assistant. A Desmarres retractor is placed over the cut surface of the skin. A reciprocating bone saw is used to cut through the lateral wall, parallel to the zygomatic arch; the tip of the saw blade is placed in the inferior orbital fissure, and the ostectomy is made from medial to lateral. Frequent pauses to assess the position and adequacy of protection of the orbital contents are essential. The second osteotomy is made just superior to the zygomaticofrontal suture with the tip of the saw blade inside the orbit. It is important to have good exposure of the lateral wall externally to gauge the depth of the saw blade and avoid cutting into the anterior or middle cranial fossa.
- A rongeur is now used to grasp the vertical strut, which is gently outfractured. It will be necessary to elevate the remainder of the temporalis muscle from the posterolateral surface of the bone with electrocautery. Bone wax is applied as needed, and any remaining small fragments of bone are removed with the same instrument. The sharp surfaces of the remaining zygomatic and frontal bones are smoothed with a burr or rongeur. Further bone may be removed superiorly and inferiorly and posteriorly until the sphenoid bone begins to widen.
- A short-bladed knife, such as a sickle knife, is now applied to the periorbita in a very superficial manner, directed posteriorly to anteriorly, to slit the fibrous septa and allow the orbital contents to prolapse into the temporal fossa. Care is taken to place no traction on the orbital adipose tissue and to remain superficial so that the lacrimal gland and lateral rectus muscle are not damaged. Bipolar cautery is used to obtain hemostasis.
- Careful closure of the wound is accomplished by precise realignment of the upper and lower gray lines of the eyelid with a single horizontal stitch of 6-0 absorbable material, such as polyglactin, buried laterally. The deep tissues are reapproximated with inverted 6-0 suture and the skin closed carefully with running 7-0 nylon or interrupted chromic gut suture. Before complete closure, a longitudinal strip of 0.25-inch Penrose drain is placed into the wound to emerge between sutures. A patch is placed loosely over the eye to absorb drainage. The patient is admitted for observation overnight, both for pain control and to monitor for any hemorrhage (Figs. 151.5 and 151.6).

Common Errors in Technique

- Preservation of the middle turbinate limits expansion of the orbital contents and predisposes to synechiae.
- Injury to the ethmoidal arteries can result in a retro-orbital hematoma. Posteriorly, the optic nerve and carotid artery are at risk for injury.
- A small antrostomy or sphenoidotomy is prone to scarring and obstruction.
- Removal of additional bone lateral to the infraorbital canal does not contribute to decompression and risks injury to the infraorbital nerve.
- Excessive decompression of the orbital tissues near the nasofrontal recess can result in obstruction of the frontal sinus.

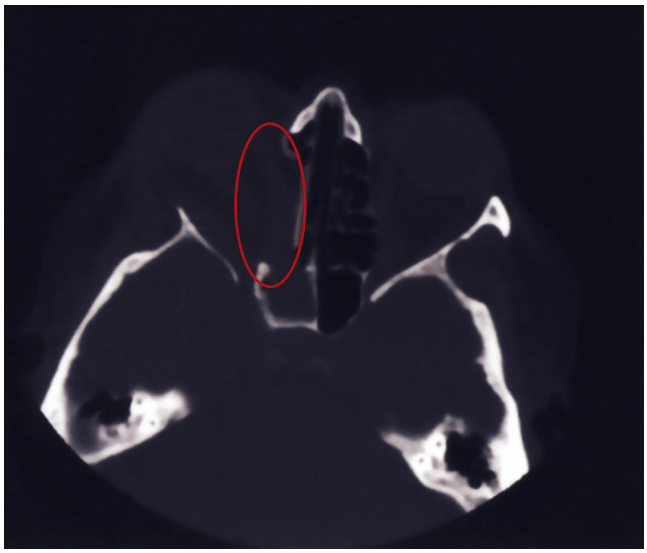

Fig. 151.5. Postoperative axial view of the patient from Fig. 151.3 with right optic neuropathy secondary to Graves orbitopathy. One week after balanced decompression, visual acuity in the right eye was 20/25 and Ishihara color vision was normal (17/18 plates). Note the herniation of the enlarged medial rectus into the bony defect *(circle)*.



Fig. 151.6. Postoperative coronal view of the patient from Fig. 151.3. Note the bony defects with herniation of the orbital contents *(circles)*.

- Excessive or aggressive removal of the medial wall superiorly can fracture the skull base and cause a CSF leak. Placing the saw blade too deep can injure the dura and brain with the superior lateral wall osteotomy.
- Injury to the infraorbital nerve can lead to loss of sensation of the midface.
- The medial rectus muscle, and to a lesser extent, the lateral rectus, are often infiltrated and enlarged and are susceptible to injury if the incisions in the periorbita are too deep.
- If the medial periorbita is incised first, herniation of orbital adipose tissue will hinder visualization for the superior incisions.
- The lateral rectus muscle is susceptible to injury during decompression of the lateral orbital wall.
- Ecchymosis of the periorbital tissues is common but may be associated with a hematoma.
- Unbalanced decompression of the orbit can result in significant diplopia. The diplopia is often transient but may require corrective surgery if it persists beyond 6 months.
- Careful realignment of the lateral commissure of the eyelids is necessary for an optimal cosmetic result.
- Bony decompression without adequate division of the periorbital septa is ineffective in decompressing the orbit.
- Any removal of intraconal adipose tissue must be done with a minimum of traction and from the inferotemporal quadrant (between the lateral and inferior rectus muscles) to decrease the risk of retrobulbar hematoma and injury to orbital structures.
- Monopolar cautery should be avoided near the apex of the orbit.

POSTOPERATIVE PERIOD

Postoperative Management

- Patients are administered a steroid pulse intravenously while undergoing observation overnight (4 to 8 mg every 8 hours thereafter while in the hospital). A rapid taper of oral steroid medication is adequate for most patients; those decompressed in an acute setting require a much more aggressive regimen and longer taper.
- Patients are instructed to not blow their nose for 2 weeks after the procedure, and a steroid/antibiotic ointment is applied to the sutures twice a day for a week.
- Nonabsorbable sutures are removed in 5 to 7 days.
- Intranasal splints are removed at 1 week, and a saline spray is used as necessary to minimize crusting. Mucosalization of the orbital tissues is usually complete by 2 months.
- Patients are counseled to expect some initial diplopia and that the final appearance is often not reached for at least 3 months.
  - Patients are observed for at least 6 months after surgery before consideration of extraocular muscle or eyelid surgery.

Complications

- The risks associated with endoscopic medial and inferior orbital decompression are similar to those after any endoscopic sinus surgery.
- New-onset or worsened postoperative diplopia will occur in about one-third of patients undergoing decompression of three walls,[10] but it has been observed in retrospective series; a "balanced decompression" consisting of only the medial and lateral walls is associated with only about a 10% incidence of new-onset diplopia.[8]
- If a CSF leak occurs intraoperatively, it should be assessed by a skull base surgeon and repaired intraoperatively. This may require removal of additional bone. If CSF rhinorrhea is confirmed postoperatively, it should be urgently repaired surgically.
- Manipulation of the infraorbital nerve can cause hypesthesia of the midface; it is usually transient if the nerve is not transected. Excessive removal of bone at the posterior margin of the maxillary antrostomy can injure the descending palatine nerve, resulting in numbness of the palate.
- Transection of the anterior ethmoidal artery can allow the end to retract into the orbital tissues resulting in a retrobulbar hematoma. This needs to be recognized and managed expeditiously based on intraorbital pressures. It may be necessary to further detach the lateral canthal ligament and delay closure of the lid incision.
- Epistaxis should be managed without nasal packing because this may result in an orbital hematoma.
- Orbital emphysema is the result of nose blowing and will resolve spontaneously. Monitor vision and observe for signs of orbital cellulitis.

Alternative Management Plan

- Irradiation of orbital tissues
- Some patients with shallow orbits and/or mostly proliferation of orbital adipose tissue (more so than muscle) may benefit from adipose tissue–only decompression of the orbits.
- In some patients with mild proptosis but lid retraction, eyelid surgery may camouflage some proptosis and allow for better protection of the cornea, and orbital decompression may not be necessary.

DISCUSSION

Evidence-Based Medicine Question

Which procedure provides optimal decompression of the orbit in patients with Graves exophthalmopathy?

Endoscopic decompression of the orbital apex gives excellent relief of CON. A small randomized trial of patients with CON showed that 45% of the patients treated with steroid required decompression surgery (three-wall coronal decompression) but that 82% of those treated initially with surgery still required pulse IV steroid, suggesting that IV steroid should be tried first. A small series of patients with CON were reported after treatment with a selective endoscopic orbital decompression (only the posterior medial orbital wall); all had stabilization or improvement of vision, and none developed new diplopia. These patients had reduction of proptosis averaging 3 mm. A long-term (median follow-up 5.2 years) review of transantral and transnasal decompressions (medial wall and floor only) showed a persistent decrease in proptosis of about 4.5 mm. A large meta-analysis of studies since 1990 showed a decrease in proptosis of up to 6 mm, with a form of balanced decompression (lateral and medial walls), with a 9% complication rate. Decompression of only the lateral wall decreased the effectiveness of the decompression by 50% (about 3 mm).

Editorial Comment

When considering an orbital decompression, the ENT surgeon must have the appropriate team with oculoplastics and endoscopic endonasal skull base experience. Additionally, the goals of the surgery and the underlying pathophysiology must be fully understood. Most orbital decompressions are carried out for Graves orbitopathy, although they can be for tumors, trauma, or infections. When considering an orbital decompression, the underlying pathology must also be fully medically treated. This is especially important in Graves orbitopathy, and one should operate on patients with nonactive inflammatory disease who are optimally managed by endocrinology. Preoperative planning with a CT and MRI is warranted; orbital position and volumes can be compared from side to side. Surgically, the number of decompressed walls correlates directly with the reduction in proptosis, and with a balanced medial and lateral wall decompression, the average reduction in proptosis is between 4 and 5 mm. When there is optic nerve compression present, concomitant optic nerve decompression, usually from the endonasal approach, should be considered.

Errors in technique are usually related to incomplete and nonmaximal removal of the orbital bone, injury to the ethmoid arteries, or incomplete openings of the sphenoid or frontal sinuses that can become obstructed from the prolapsing orbital contents.

Tonya Stefko

Access the review questions and additional sources list online at http://www.expertconsult.com

REFERENCES

1. Dollinger J. Die Druckentlastung der Augenhöhle durch Entfernung der äußeren Orbitalwand bei hochgradigen Exophthalmus (Morbus Basedowii) and konsekutiver Horn hauterkrankung. Dtsch Med Wochenschr 1911;37:1888–1890.
2. El-Kaissi S, Frauman AG, Wall JR. Thyroid-associated ophthalmopathy: a practical guide to classification, natural history and management. Intern Med J 2004;34:482–491.
3. Ludgate M, Baker G. Unlocking the immunological mechanisms of orbital inflammation in thyroid eye disease. Clin Exp Immunol 2002;127:193–198.
4. Cawood T, Moriarty P, O'Shea D. Recent developments in thyroid eye disease. BMJ 2004;329:385–390.
5. Fatourechi V, Bartley GB, Eghbali-Fatourechi GZ, et al. Graves' dermopathy and acropachy are markers of severe Graves' ophthalmopathy. Thyroid 2003;13:1141–1144.
6. Bartalena L, Marcocci C, Bogazzi F, et al. Relation between therapy for hyperthyroidism and the course of Graves' ophthalmopathy. N Engl J Med 1998;338:73–78.
7. Kloek CE, Bilyk JR, Pribitkin EA, et al. Orbital decompression as an alternative management strategy for patients with benign tumors located at the orbital apex. Ophthalmology 2006;113:1214–1219.
8. Graham SM, Brown CL, Carter KD, et al. Medial and lateral orbital wall surgery for balanced decompression in thyroid eye disease. Laryngoscope 2003;113:1206–1209.
9. European Group on Graves O, Mourits MP, Bijl H, et al. Outcome of orbital decompression for disfiguring proptosis in patients with Graves' orbitopathy using various surgical procedures. Br J Ophthalmol 2009;93:1518–1523.
10. Russo V, Querques G, Primavera V. Delle Noci N: Incidence and treatment of diplopia after three-wall orbital decompression in Graves' ophthalmopathy. J Pediatr Ophthalmol Strabismus 2004;41:219–225.

REVIEW QUESTIONS

1. Orbital decompression for Graves ophthalmopathy is best performed during the acute inflammatory phase.
   a. True
   b. False

2. The superior limit of a medial wall decompression is
   a. The frontal-ethmoidal suture line
   b. 2 mm below the junction of the ethmoid roof and orbital roof
   c. The superior margin of the medial rectus muscle
   d. The trochlea

3. The incisions in the periorbita should be parallel to the extraocular muscles to avoid injury to the muscle.
   a. True
   b. False

4. Which of the following are possible complications of orbital decompression surgery?
   a. CSF leak
   b. Orbital hematoma
   c. Orbital emphysema
   d. Hypesthesia of the mandibular nerve

ADDITIONAL SOURCES

Chu EA, Miller NR, Lane AP. Selective endoscopic decompression of the orbital apex for dysthyroid optic neuropathy. Laryngoscope 2009;119:1236–1240.

Jernfors M, Valimaki MJ, Setala K, et al. Efficacy and safety of orbital decompression in treatment of thyroid-associated ophthalmopathy: Long-term follow-up of 78 patients. Clin Endocrinol 2007;67: 101–107.

Leong SC, Karkos PD, Macewen CJ, et al. A systematic review of outcomes following surgical decompression for dysthyroid orbitopathy. Laryngoscope 2009;119:1106–1115.

Muller-Forell W, Kahaly GJ. Neuroimaging of Graves' orbitopathy. Best Prac Res Clin Endocrinol Metab 2012;26:259–271.

Wakelkamp IM, Baldeschi L, Saeed P. Surgical or medical decompression as a first-line treatment of optic neuropathy in Graves' ophthalmopathy? A randomized controlled trial. Clin Endocrinol 2005;63:323–328.

152 Orbital Abscess

Nikisha Q. Richards

INTRODUCTION

Subperiosteal orbital abscess (SPOA) is a well-defined complication of bacterial ethmoid sinusitis with potential vision and life-threatening sequelae. In fact, the most common cause of orbital cellulitis is sinusitis, especially of the ethmoid sinuses.[1] The severity of these potential outcomes emphasizes the importance of rapid clinical identification, risk stratification, and treatment. During the second half of the 20th century, these sequelae prompted surgical drainage of the orbit and sinuses in nearly all patients with this diagnosis. There have since been retrospective analyses showing bacteriology and response to antibiotic treatment correlating with the patient's age.[2] It has been speculated that age-related anatomic and physiologic differences in the sinuses may account for this correlation. The sinus cavities markedly enlarge from the neonate to the adult, but the ostia remain constant.[3] The rapid growth of the sinuses leads to a relative overwhelming volume to be drained by the unchanged size of the ostia. Bacteria can easily access the subperiosteal space through foramina and direct extension through thin bones such as the lamina papyracea.

KEY OPERATIVE LEARNING POINTS

- After the patient is under general anesthesia, forced ductions are always performed in all directions of all SPOA patients before and after drainage of the abscess. This helps differentiate a paretic from a restrictive ophthalmoplegia, thereby allowing for clinical correlation when there is suspected cavernous sinus involvement. The contralateral eye can be used for comparison if uncertain.
- Ensure that the cornea is protected at all times.
- When using a sub-eyebrow approach, bevel the scalpel blade in the direction of cilia growth to help prevent the destruction of the hair follicles.
- When using an inferior approach:
  - Take care to follow the curvature of the apex of the orbital rim to help prevent premature entry into the orbit and thusly unwanted presentation of orbital adipose tissue.
  - Use a circumspect approach to the periosteum to help prevent dissection into the eyelid or even transection of the origin of the inferior oblique muscle (IOM).
- When using a medial approach:
  - Be cognizant of the origin of the IOM.
  - The caruncle is an easily identifiable and reliable external landmark for prediction of the IOM origin.[4] The origin of the IOM is just anterior to a small depression just below and lateral to the lacrimal sac fossa.[5]
  - "The rule of twelves"—The anterior-to-posterior length from the anterior lacrimal crest to the anterior ethmoidal foramen is approximately 24 millimeters. From the anterior ethmoidal foramen to the posterior ethmoidal foramen is approximately 12 millimeters, and from the posterior ethmoidal foramen to the optic canal is about six millimeters (Fig. 152.1).
  - Being cavalier in the approach to the medial periosteum can result in fracture of the ethmoid bone or even transection of the origin of the IOM.
- Take care not to use the globe as a fulcrum.
- Always obtain cultures/Gram stain of the abscess contents.

PREOPERATIVE PERIOD

History

1. History of present illness
   a. Potential source of the abscess can be elicited by asking about recent sinus infections, preceding trauma compromising the integrity of the skin, or recent insect bites
   b. Onset of eye pain, headache, decreased vision, pain with movement of the eye
   c. Antibiotic or other treatment prior to presentation
2. Past medical history
   a. Previous episodes of orbital cellulitis or orbital abscess. How were they treated?
   b. Existing renal disease, integumentary or hematologic methicillin-resistant *Staphylococcus aureus* (MRSA) infection, chronic sinus infection
   c. Surgery including organ transplantation and previous sinus surgery
   d. Otherwise immunocompromised state
3. Medications
   a. Anticoagulants
   b. Allergies to antibiotics

Physical Examination

Every patient with orbital cellulitis, irrespective of the presence of a SPOA (Fig. 152.2), should have an ophthalmologic examination at least twice daily to include the following:

1. Assessment of periorbital/eyelid edema and erythema
2. Visual acuity
3. Color vision
4. Measurement of intraocular pressure
5. Evaluation of pupils for the presence of an afferent pupillary defect
6. Assessment of chemosis
7. An undilated evaluation of the posterior pole
8. Exophthalmometry
9. Extraocular motility
10. Associated pain with extraocular motility

Imaging

Computer tomography (CT) scan of the orbits with and without contrast or CT maxillofacial with and without contrast (Figs. 152.3 to 152.5)

Indications

- The following patients should undergo immediate surgical intervention:
  - Those less than 9 years of age with any of the following age-superseding criteria:
    - Decreased vision
    - Signs of optic neuropathy
    - Large SPOAs
    - An SPOA that is located anywhere except medially
    - Frontal sinusitis

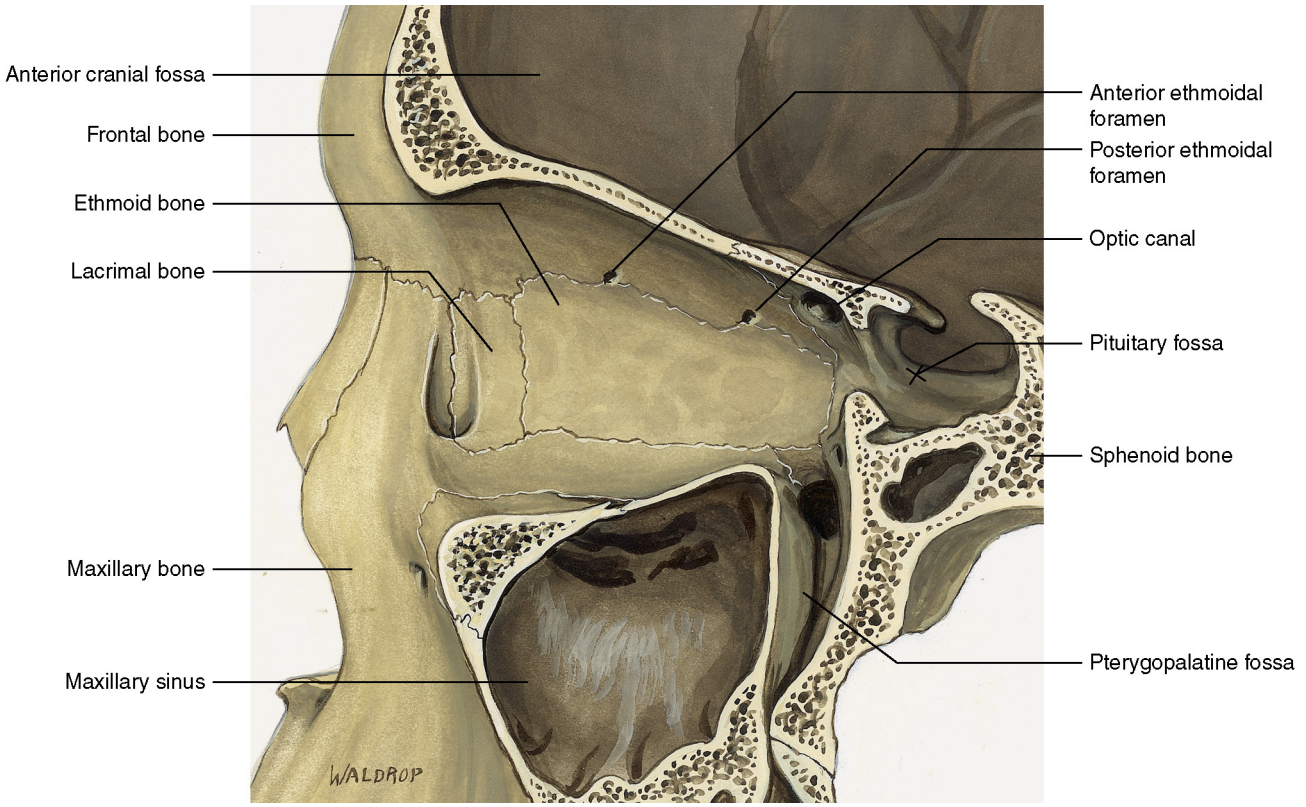

Fig. 152.1. Anterior lacrimal crest, posterior lacrimal crest, lacrimal sac fossa, anterior ethmoidal foramen, posterior ethmoidal foramen, fronto-ethmoidal suture, optic foramen. *(Dutton JJ. Atlas of Clinical and Surgical Orbital Anatomy. 2nd ed. Philadelphia: Saunders Elsevier; 2011, p 24, Fig. 2–5.)*



Fig. 152.2. Clinical appearance of subperiosteal orbital abscess.

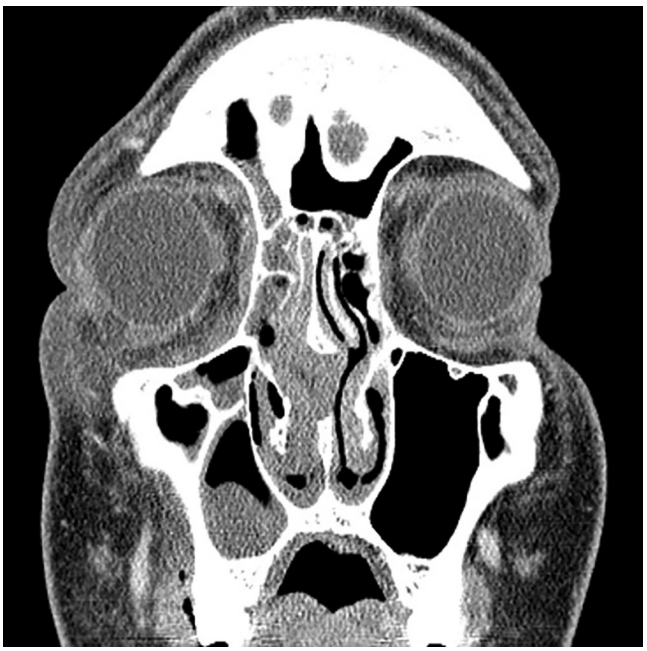

Fig. 152.3. Contrast-enhanced computer tomography displaying coronal view of right subperiosteal orbital abscess.

- Intracranial involvement
- Risk factors for anaerobic involvement[1,6]

- The following patients should undergo surgical intervention within 8 to 24 hours:
  - All patients ≥9 years of age
  - Always consider:
    - Decrease in visual function (acuity and color vision)
    - SPOA size
    - SPOA location
    - Frontal sinus involvement



Fig. 152.4. Contrast-enhanced computer tomography displaying more posterior coronal view of right subperiosteal orbital abscess.



Fig. 152.5. Contrast-enhanced computer tomography displaying axial view of right subperiosteal orbital abscess.

  - Intracranial extension
  - Factors predicting anaerobic infection such as:
    - Age ≥9 years
    - Chronic sinusitis
    - Odontogenic origin
- Patients failing prompt response to intravenous antibiotics proceed to surgical drainage[2,6]
  - No clinical improvement after 72 hours
  - Clinical deterioration despite 48 hours of treatment
  - Lack of fever abatement after 36 hours of appropriate antibiotic treatment

Contraindications

1. Surgical factors
   a. Inadequate expertise of the surgeon

Preoperative Preparation

1. Evaluations by:
   a. Ophthalmologist
   b. Otolaryngologist well versed in endoscopic sinus surgery
   c. Internist/pediatrician
   d. Anesthesiologist
2. Keep patients on nothing by mouth (NPO).
3. Broad-spectrum intravenous antibiotics (e.g., third-generation cephalosporin or ampicillin/sulbactam + vancomycin or clindamycin) to include anaerobic coverage especially in those with signs of or suspected chronic sinusitis or an SPOA of odontogenic origin
4. A lateral canthotomy and cantholysis may be indicated to help relieve an orbital compartment syndrome.

OPERATIVE PERIOD

Anesthesia

- General

Positioning

- Supine, positioning the patient on an eye stretcher may be helpful

Perioperative Antibiotic Prophylaxis

- Continue scheduled preoperative broad-spectrum intravenous antibiotics, but try to wait for perioperative administration until after culture samples are obtained.
- Choices:
  - Third-generation cephalosporin or ampicillin/sulbactam + vancomycin or clindamycin
  - Clindamycin or vancomycin only if the patient is allergic to penicillin

Monitoring

- Routine anesthesia monitoring

Instruments and Equipment to Have Available

1. 0.5 or Adson toothed forcep
2. Corneal protector
3. Ophthalmic ointment
4. Malleable and Desmarres retractors
5. Monopolar electrocautery with Colorado needle tip
6. Bipolar electrocautery
7. #15 Bard-Parker scalpel blade
8. Cottle elevator
9. Quarter inch Penrose drain
10. Curved Steven's tenotomy scissors
11. Westcott scissors
12. Cotton-tipped applicators
13. Jameson muscle hook

Key Anatomic Landmarks

See Figs. 152.1 and 152.6.

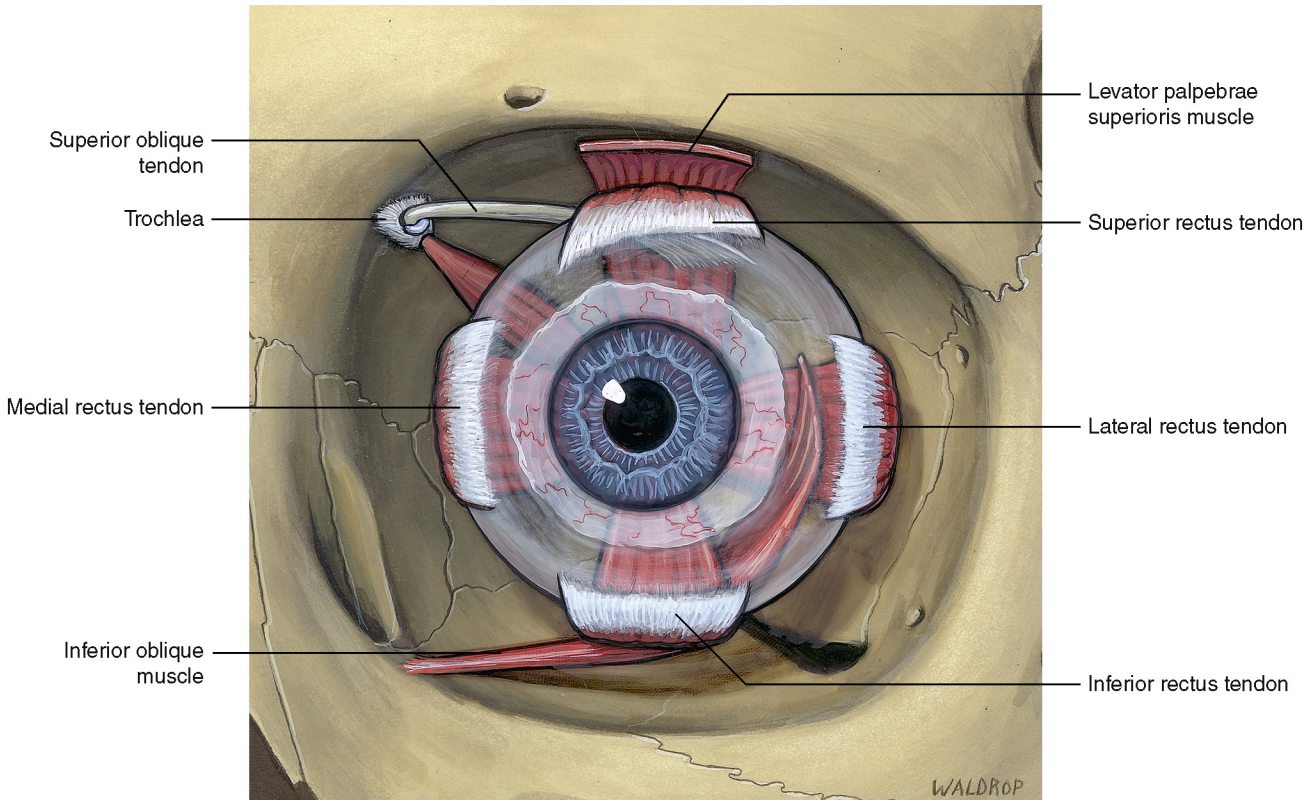

Fig. 152.6. Supraorbital notch/foramen and origin of the IOM (periosteum of the maxillary bone just posterior to the anterior lacrimal crest and inferior to the orifice of the lacrimal sac fossa). *(Dutton JJ. Atlas of Clinical and Surgical Orbital Anatomy. 2nd ed. Philadelphia: Saunders Elsevier; 2011, p 40, Fig. 3–4.)*

Prerequisite Skills

- Lateral canthotomy and cantholysis

Operative Risks

1. Penetration of the globe
2. Retrobulbar hemorrhage
3. Fracture of the ethmoid bone
4. Transection of the IOM
5. Scarring leading to lid malposition or strabismus
6. Loss of vision
7. Cerebrospinal fluid (CSF) leak

Surgical Technique

- Intraoperative evaluation after patient has been intubated
  - Forced ductions with 0.5 forcep in all directions
  - If patient was unable to comply with examination prior to intubation, this is an opportune time to perform the pupillary examination.

Subperiosteal Abscesses

Superior Orbit

- The superior orbit can be approached thru a sub-eyebrow or upper eyelid crease incision.
  - Sub-eyebrow approach (Fig. 152.7):
    - Consider a temporary tarsorrhaphy by passing a 5-0 or 6-0 monofilament suture partial thickness through the tarsal plate through or just adjacent to the eyelash line of the upper and lower eyelids in a horizontal mattress fashion.



Fig. 152.7. Sub-eyebrow incision for approach to superior orbit.

    - Prior to the incision, note and mark the location of the supraorbital notch in order not to violate the neurovascular bundle.
    - Inject local anesthetic with epinephrine subcutaneously.
    - #15 Bard-Parker scalpel blade is used to incise the skin from the mid to lateral brow
    - Maintain hemostasis at all times with bipolar electrocautery, but avoid cautery of the skin edge.
    - Bluntly dissect through the orbital orbicularis muscle until the orbital rim is reached (Fig. 152.8).
    - Incise the periosteum along the rim with monopolar electrocautery, and gently separate it from the bone with a Cottle elevator and then a malleable retractor while retracting the superior lip of the incision with a

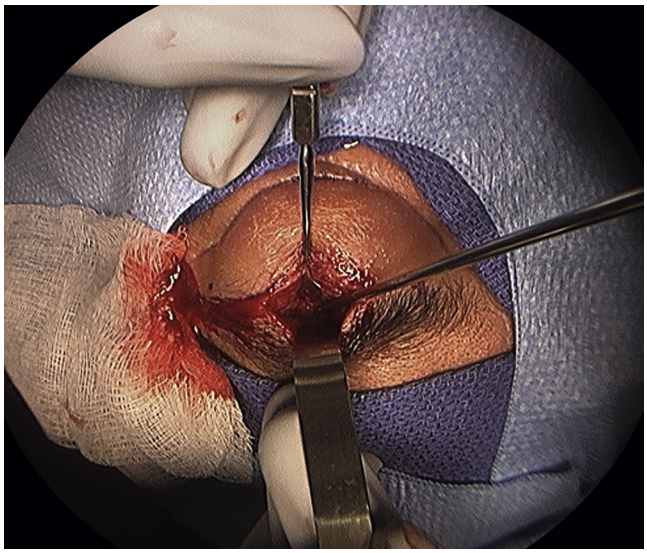

Fig. 152.8. Sub-eyebrow approach to superior orbit isolating frontal bone.

Desmarres retractor to expose and drain the abscess. A specimen of the abscess contents should be sent for culture and sensitivities.
- Close the deep tissues with an absorbable suture such as 4-0 Vicryl in a buried knot fashion sometimes in two layers.
- Close the skin with a monofilament suture such as 6-0 nylon in a simple interrupted or running fashion to be removed 5 to 7 days later.

- Eyelid crease approach:
  - Consider a tarsorrhaphy as described in the sub-eyebrow approach.
  - Mark the upper eyelid crease with a sterile marking pen.
  - Inject local anesthetic with epinephrine subcutaneously.
  - Incise the skin with a #15 Bard-Parker blade.
  - Spring iris or Westcott scissors are used to dissect superiorly in the plane between the orbicularis and orbital septum until the orbital rim is reached.
  - Maintain hemostasis at all times with bipolar electrocautery.
  - Incise the periosteum along the rim with monopolar electrocautery and gently separate it from the bone with a Cottle elevator while retracting the lips of the wound with Desmarres retractors to expose and drain the abscess. A specimen of the abscess contents should be sent for culture and sensitivities.
  - Consider placement of an orbital drain.
  - Close the skin in a simple running fashion with 7-0 or 8-0 absorbable or nonabsorbable suture. Nonabsorbable suture to be removed 7 to 10 days later.

Medial Orbit

- A combined endoscopic and external approach is most likely indicated.
  - Endoscopic ethmoidectomy by an Otolaryngologist should be undertaken, though decompression of the orbit may need to be performed first in cases where visual function is compromised (see Chapter 108).
  - Inject local anesthetic with epinephrine transconjunctivally in the area of the plica semilunaris taking care not to penetrate the globe.
  - Place a corneal protector lubricated with ophthalmic ointment over the globe.
  - The assistant should retract the medial eyelids with Desmarres retractors.
  - While tenting the caruncle anteriorly in a coronal orientation with a fine-toothed forcep, incise the conjunctiva between the plica and caruncle either with needle-tip cautery on low power or sharp Westcott scissors.
  - Bluntly dissect by spreading curved Steven's tenotomy scissors posteromedially in a 45-degree angle until the posterior lacrimal crest is reached.
  - Open the periosteum under direct observation, always protecting the globe with a malleable retractor.
  - Gently elevate the periosteum posteriorly until the abscess is identified and drained; a specimen of the abscess contents should be sent for culture and sensitivities.
  - Consider placement of a drain (rubber band, Penrose).
  - No suture closure is required.

Inferior Orbit

  - Place a corneal shield lubricated with ophthalmic ointment over the eye.
  - Expose and stretch the inferior forniceal conjunctiva over the inferior orbital rim with a malleable holding back orbital tissue and Desmarres retractor retracting the lower lid.
  - Incise the forniceal conjunctiva with a Colorado microdissection needle on low power.
  - Incise the periosteum at the inferior orbital rim in likewise fashion, and gently lift it from the orbital floor with a Cottle elevator to expose and drain the abscess; a specimen of the abscess contents should be sent for culture and sensitivities.
  - No suture closure is required.
- Consider placement of a drain.
- Consider a superior traction stitch through the tarsus of the lower eyelid if placing a drain.

Lateral Orbit

- Although this is the least common site of an SPOA, a lateral approach can be used to access the lateral aspect of the superior and inferior orbit as well.[7]
- A cosmetically pleasing approach to the lateral orbit involves performing a canthotomy in the natural skin crease followed by an inferior cantholysis (see Chapter 153).
  - The periosteum of interest is incised and lifted to access the abscess.
- When attempting to access the lateral aspect of the superior and inferior orbit, a lateral bony orbitotomy may be performed as described in Chapter 151.

Intraconal Abscesses

Addressed similarly as the previously described subperiosteal approaches as they often stem from the same origin as SPOAs. In certain situations, it is necessary to enter the intraconal space directly. This can be accomplished with either a medial or lateral approach. This requires surgeons familiar with ophthalmic and orbital techniques and will not be described here.

Common Errors in Technique

- Inadequate lubrication/protection of both the operative and fellow cornea intraoperatively
- Using the globe as a fulcrum
- Inducing corneal abrasions
- Premature removal of drain
- Not draining the abscess

- Medial orbit
  - Careless approach to the medial periosteum resulting in fracture of the ethmoid bone or even transection of the origin of the IOM
- Inferior orbit
  - Imprecise approach to the inferior periosteum resulting in dissection into the eyelid or even transection of the origin of the IOM
  - Not following the curvature of the apex of the rim to help prevent premature entry into the orbit and thusly unwanted presentation of orbital adipose tissue
- Superior orbit
  - Not beveling the scalpel blade in the direction of cilia growth to help prevent hair follicle destruction

POSTOPERATIVE PERIOD

Duration and method of delivery of antibiotics are determined by clinical presentation, culture results, immune system status, and the ability of the patient and family to follow up and administer antibiotics. At times, it is necessary to arrange for in-home nursing visits especially if the patient has a peripherally inserted central catheter. All patients should continue to have twice daily ophthalmic examinations until clinical improvement is evident. Frequency of examinations is tailored according to clinical response.

Postoperative Management

1. Monitor vital signs.
2. Monitor leukocytes.
3. Remove drain when no longer expressing exudate (usually 24 to 48 hours after surgery).
4. Avoid nonsteroidal anti-inflammatory drugs for pain due to risk of bleeding into already tight orbit.
5. Oxymetazoline nasal spray/drops
6. Tailor antibiotic regimen based on Gram stain and culture results.
7. Convert to oral antibiotics after 24 to 36 hours of persistent clinical improvement.
8. Do not discharge patient until there is persistent clinical improvement for 24 to 36 hours while on oral antibiotics.

Complications

1. Penetration of globe—Place a foxshield over the eye and consult ophthalmology emergently for repair.
2. Retrobulbar hemorrhage—Perform canthotomy and cantholysis of eyelids, obtain hemostasis, and consult ophthalmology emergently.
3. Transection of the extraocular muscles (EOM)—Consult ophthalmology urgently for examination and possible repair.
4. Scarring—Refer to oculoplastics if inducing an eyelid malposition.
5. Loss of vision—Consult ophthalmology emergently.

Alternative Management Plan

Nonsurgical cases are managed with an average of 4 days of intravenous antibiotics and typically followed by three weeks of oral antibiotics along with oxymetazoline nasal drops or spray.[8] The antibiotic regimen and duration of surgical cases are dictated by clinical response and culture results. A knowledgeable infectious disease specialist colleague is an invaluable resource as well.

DISCUSSION

Evidence-Based Medicine Question

When should an orbital abscess be drained?

A widely accepted management protocol was developed in 1994 from a series of patients from 1977 to 1992 that determined triage to medical or medical-surgical treatment and medical patients failing prompt response proceeding to surgical drainage.[2,6] Failure to promptly respond is defined as: no clinical improvement after 72 hours, clinical deterioration despite 48 hours of treatment, or lack of fever abatement after 36 hours of appropriate antibiotic treatment.[6,8] The following factors should always be taken into account: visual function (acuity and color vision), SPOA size, SPOA location, frontal sinus involvement, intracranial extension and factors predicting anaerobic infection such as age ≥9 years, chronic sinusitis, or odontogenic origin. Of course, the use of clinical judgment is always imperative, but essentially, all patients ≥9 years of age along with those less than 9 years of age with any of the accompanying age-superseding criteria including decreased vision, signs of an optic neuropathy, large SPOAs, an SPOA that is located anywhere except medially, frontal sinusitis, intracranial involvement, or risk factors for anaerobic involvement should undergo immediate medical-surgical treatment.[1,6] The nonsurgical approach in those patients less than 9 years of age has been validated longitudinally through 2012.[6,8]

Editorial Comment

This is a well-presented review of considerations for surgical drainage of orbital abscess. Almost never is this undertaken without concurrent drainage of adjacent sinus disease, the most common cause of subperiosteal and orbital abscess. In the presence of abscess pockets located in other than the subperiosteal space, the involvement of an orbital surgeon is strongly suggested.

Given the clinical circumstances an ethmoidectomy may also be required (see Chapter 108).

Tonya Stefko

Access the review questions online at http://www.expertconsult.com



REFERENCES

1. Smith JM, Bratton EM, Dewitt P, et al. Predicting the need for surgical intervention in pediatric orbital cellulitis. Am J Ophthalmol 2014;158(2):387–394.
2. Harris GJ. Subperiosteal abscess of the orbit: age as a factor in the bacteriology and response to treatment. Ophthalmology 1994;101(3):585–595.
3. Arey LB. Developmental Anatomy: A Textbook and Laboratory Manual of Embryology. 7th ed. Philadelphia: Saunders; 1974. p. 528.
4. Shin HJ, Shin KJ, Lee SH, et al. Location of the inferior oblique muscle origin with reference to the lacrimal caruncle and its significance in oculofacial surgery. Br J Ophthalmol 2016;100(2):179–183.
5. Yanoff M, Duker JS. Orbit and Oculoplastics. Ophthalmology. 4th ed. Philadelphia: Saunders Elsevier; 2013. p. 1260.
6. Liao JC, Harris GJ. Subperiosteal abscess of the orbit: evolving pathogens and the therapeutic protocol. Ophthalmology 2015;122(3):639–647.
7. Paluzzi A, Gardner PA, Fenandez-Miranda JC, et al. "Round-the-Clock" surgical access to the orbit. J Neurol Surg B 2015;76(1):12–24.
8. Emmett Hurley P, Harris GJ. Subperiosteal abscess of the orbit: duration of intravenous antibiotic therapy in nonsurgical cases. Ophthal Plast Reconstr Surg 2012;28(1):22–26.

REVIEW QUESTIONS

1. Which of the following is not an indication to drain an orbital abscess?
   a. Signs of an optic neuropathy
   b. Severe erythema of the eyelids
   c. An SPOA involving the inferior orbit
   d. Clinical suspicion of anaerobic bacteria involvement

2. Which of the following statements is true?
   a. All orbital abscesses should be drained.
   b. Presence of a fever is an indication for immediate surgical intervention.
   c. SPOAs can cause loss of vision and even death.
   d. A lateral canthotomy and cantholysis are never indicated preoperatively.

3. Which of the following muscles is at risk for transection during approach to the medial or inferior orbit?
   a. Inferior oblique
   b. Superior oblique
   c. Inferior rectus
   d. Lateral rectus

153 Lateral Canthotomy

Roxana Fu

INTRODUCTION

The lateral canthotomy coupled with an inferior cantholysis is often the first step in many eyelid and orbital procedures. The detachment of the inferior crus of the lateral canthal tendon allows for greater horizontal laxity of the lower eyelid.[1] It is commonly used in lower eyelid reconstruction techniques[2] (i.e., semicircular advancement flap), inferior or lateral orbitotomies for greater exposure,[3] or in eyelid tightening procedures such as a lateral tarsal strip.[4] It is used as the sole procedure to emergently decompress the orbit in the setting of an "orbital compartment syndrome," a condition characterized by multiple cranial neuropathies within the orbit due to an acute increase in intraorbital pressure.

Aside from airway compromise, an orbital compartment syndrome is one of the few true emergencies for the head and neck surgeon. Immediate intervention should be performed at the time of diagnosis to prevent permanent loss of vision.[5-7]

KEY OPERATIVE LEARNING POINTS

- Recognition of the potential for an orbital compartment syndrome in the setting of trauma, the postoperative period, or secondary to acute orbital or sinus pathology is required for a prompt diagnosis.
- Diagnosis of an orbital compartment syndrome is based on the clinical findings alone. Imaging is not sufficient to determine if a space-occupying lesion requires emergent treatment.
- Clinical presentation of etiologies varies; it is the *acute severity* and *loss of function* that are the hallmarks of an orbital compartment syndrome.
- Lateral canthotomy combined with an inferior cantholysis is essential to gain horizontal eyelid laxity and therefore greater orbital capacity.
- Repeat intraocular pressure measurements are required to demonstrate adequate orbital decompression.
- Adjunctive medical management should not delay necessary surgical intervention.

PREOPERATIVE PERIOD

Orbital compartment syndrome is a rare condition which, if unrecognized or untreated, can lead to blindness.[8] The most common causes are traumatic or iatrogenic etiologies[9] and can range from a rapidly progressing space-occupying lesion to severe acute orbital vascular congestion. Several potential causes of an orbital compartment syndrome, such as mild retrobulbar hemorrhage, may be managed conservatively with serial ophthalmic examinations.[10] It is the *loss of function* that is the hallmark of the development of an orbital compartment syndrome that requires immediate intervention.[7]

Regardless of the etiology, the presenting symptoms of pain or pressure in the eye, decreasing vision, and diplopia should prompt further examination for objective signs of an orbital compartment syndrome. These include proptosis, afferent pupillary defect, increased intraocular pressure, and decreased eye movement. While there are no large published case series guiding when treatment should be initiated, the loss of vision when accompanied by the aforementioned signs and symptoms should prompt emergent intervention.[7]

The orbit is enclosed by bone on all sides except anteriorly, and any forward displacement is limited by the eyelid apparatus and the tethering of the optic nerve to the globe. As intraorbital pressure rises, ocular perfusion decreases, leading to ischemia. Multiple cranial nerves within the orbit may be compromised, including the optic nerve and the nerves controlling eye movement.

Once the diagnosis is made, emergent orbital decompression is warranted by performing a lateral canthotomy and inferior cantholysis.[7] The objective of the procedure is to allow for additional forward movement of the orbital contents, not actual drainage of the hematoma. Decreasing the intraorbital pressure restores normal circulation and prevents further loss of vision. Visual recovery is possible if this procedure is performed in a timely manner.[7]

Orbital compartment syndrome after endoscopic sinus surgery is rare.[9] If signs are present intraoperatively (sudden proptosis, afferent pupillary defect, globe firm to palpation compared to the contralateral side), a lateral canthotomy and inferior cantholysis is indicated, followed by conversion to an external approach. If diagnosed postoperatively, nasal packing is removed and the head is elevated to allow for drainage, followed immediately by lateral canthotomy and inferior cantholysis prior to re-exploration of the operative site in the operating room.

History

1. History of present illness
   a. Progressively decreased vision and pain in the eye on the affected side
   b. Binocular diplopia (double vision present with both eyes open, resolves with closure of either eye)
   c. Trauma
      1) Retrobulbar hemorrhage
      2) Orbital emphysema
   d. Recent surgery in the face
      1) Retrobulbar anesthesia for ocular surgery
      2) Periorbital surgery that violates the orbital septum (i.e., lower eyelid blepharoplasty)
      3) Endoscopic sinus surgery
   e. Severe orbital congestion
      1) Orbital cellulitis with or without abscess formation
      2) Idiopathic orbital inflammation (rare)
   f. Contributing maneuvers that increase intraorbital pressure (Valsalva, vomiting, coughing, sneezing)
2. Past medical history
   a. Predisposing factors
      1) Orbital lesions that may spontaneously hemorrhage, such as vascular abnormalities (orbital varix, lymphangioma, arteriovenous malformations)
      2) Inherited or acquired coagulopathies
      3) Uncontrolled hypertension
      4) Rarely: connective tissue disorders (vitamin C deficiency, Elher-Danlos type IV)
3. Medications
   a. Anticoagulants

Physical Examination

1. Proptosis
   a. Forward displacement of the globe may be difficult to assess in the setting of periorbital edema. It may be helpful to compare one eye to the other.
2. Decreased extraocular motility
   a. Usually diffuse
   b. Assessment may be made difficult secondary to periorbital edema. Make use of the corneal light reflex to check for any disconjugate eye movement.
3. Elevated intraocular pressure
   a. In the acute setting, a handheld tonometer is preferred for its portability and ease of use.
   b. In the awake patient
      1) Use topical anesthesia with ophthalmic drops such as proparacaine or tetracaine.
      2) Have the patient focus on a distant target to facilitate cooperation (for sustained fixation and eyelid opening).
      3) If the patient is unable to keep his or her eyelids open, manually retract the upper eyelid to the superior orbital rim, with care not to place pressure upon the globe.
   c. Difficulty opening the eyelids secondary to eyelid edema
      1) Roll the eyelid margin tangentially away from the globe with a cotton-tip applicator, again with care not to place pressure upon the globe.
      2) To gain further access to the globe, a Desmarres retractor can be used to retract the lower eyelid inferiorly. This may further elevate the intraocular pressure transiently but can be helpful in attempting to examine extraocular motility and to check for an afferent pupillary defect.
   d. Check the contralateral intraocular pressure as an in vivo control.
   e. Note: Accurate assessment of intraocular pressure is ideal but may not be readily available in the emergent setting. In the setting of additional signs and symptoms of orbital compartment syndrome, in lieu of delays related to finding a tonometer, manual palpation of the globe may be sufficient. The affected eye will be firmer compared to the contralateral eye if the elevated intraocular pressure is severe enough. Increased resistance to retropulsion of the globe compared to the contralateral eye may also be elicited.
4. Afferent pupillary defect
   a. Check in a darkened room.
   b. Have the patient fixate on a distant target.
   c. A bright, but concentrated, light source is repeatedly swung from the unaffected eye to the affected eye.
      1) An afferent pupillary defect is present if initial dilation, instead of constriction, is seen in the affected eye in response to a direct light stimulus.
      2) An absolute afferent pupillary defect is seen when direct light stimulus over the affected eye elicits no pupillary constriction in the affected eye, and there is no consensual constriction of the unaffected eye.
   d. Note: While an afferent pupillary defect is the most objective finding of optic nerve compromise, the finding alone does not diagnose an orbital compartment syndrome. It is this finding in conjunction with the additional findings that helps secure this diagnosis.

Imaging

1. Computed tomography (CT) scan
   a. Is not required for diagnosis of orbital compartment syndrome,[7] but it is helpful in discovering the definitive etiology.
   b. Concerning signs include the following:
      1) Proptosis—forward displacement of the equator of the globe beyond the orbital rim
      2) Straightening of the optic nerve
      3) Tenting of the posterior globe
      4) Lack of these features does not rule out an orbital compartment syndrome, as it is an evolving process that may not be captured on initial imaging.
   c. Large floor and medial wall defects do not preclude the development of an orbital compartment syndrome.

Indications

- Emergent—orbital compartment syndrome
- Initial steps for the following:
  - Lateral or inferior orbitotomy
  - Advancing tissue for reconstruction of the lower eyelid
  - Horizontal eyelid tightening

Contraindications

- None—This procedure is considered a low-risk intervention, especially in the setting of permanent loss of vision without surgical treatment. The onus on the surgeon is early suspicion, evaluation, and an urgent canthotomy and cantholysis.

Preoperative Preparation

1. Evaluation with by an Ophthalmologist—if available
2. Intravenous sedation if the patient is uncooperative and it can be provided in a timely manner

OPERATIVE PERIOD

Anesthesia

- Inject local anesthetic with epinephrine into the lateral canthus, down to the periosteum of the lateral orbital rim and lateral 1/3 of the lower eyelid.
- Topical ophthalmic drops such as proparacaine or tetracaine are necessary to provide anesthesia for the awake patient prior to Betadine application.

Positioning

- The procedure is done with the patient in a supine position with the iris plane parallel to the floor.

Instruments and Equipment to Have Available

- Toothed forceps (such as Adson)
- Straight blunt-tipped scissors

Key Anatomic Landmarks

- Lateral canthal tendon
  - The eyelids are fixated to the lateral orbital rim by the lateral canthal tendon.
- Inferior canthal crus (Fig. 153.1)
  - The lateral canthal tendon divides into a superior crus attached to the upper eyelid and the inferior crus to the lower eyelid.
  - The inferior portion of the lateral canthal tendon is palpable as a distinct corded entity along the inferolateral orbital rim between the eyelid skin anteriorly and the palpebral conjunctiva posteriorly.

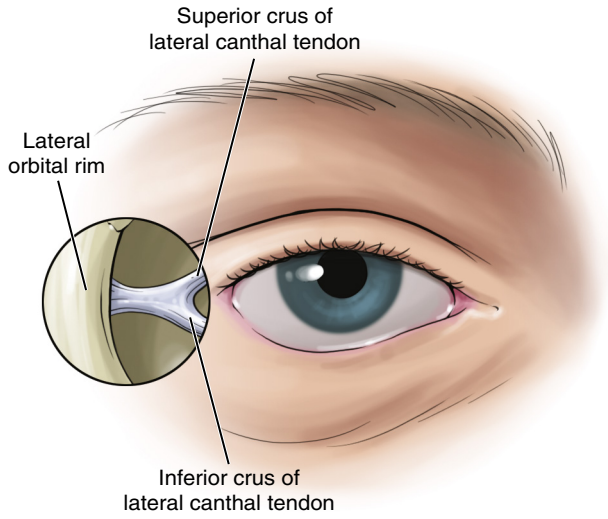

Fig. 153.1. The lateral orbital rim, the superior crus of the lateral canthal tendon, the inferior crus of the lateral canthal tendon.

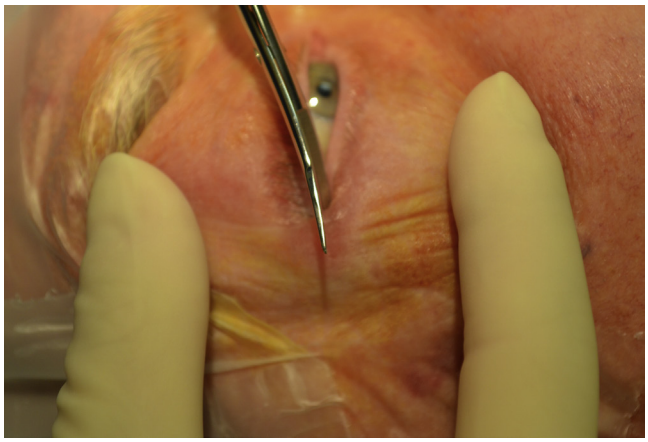

Fig. 153.2. Scissors placed to perform a lateral canthotomy.

Prerequisite Skills

- Familiarity with the anatomy of the eye and eyelids

Surgical Technique

- Surgical approach
  - Sharp instruments should always be pointed away from the globe.
  - Resting one's hands upon the patient while operating may prevent inadvertent injury should the patient move during the procedure.
- Lateral canthotomy
  - The lateral canthus is incised for approximately one centimeter down to the lateral orbital rim. One blade of the scissors is inserted just inside the lateral canthal angle; one is placed on the skin. The tip of the internal blade should rest on bone (Figs. 153.2 and 153.3).
- Inferior cantholysis
  - Hold the lower eyelid anteriorly with toothed forceps (Fig. 153.4).
  - Retraction of the upper eyelid away from the lateral canthus is helpful but not always necessary.

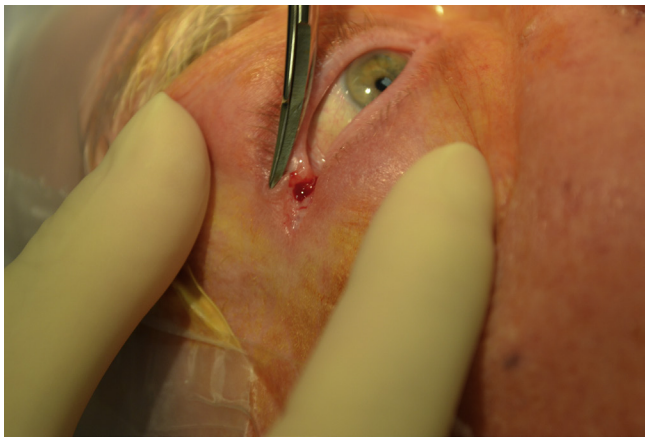

Fig. 153.3. Lateral canthotomy incision.

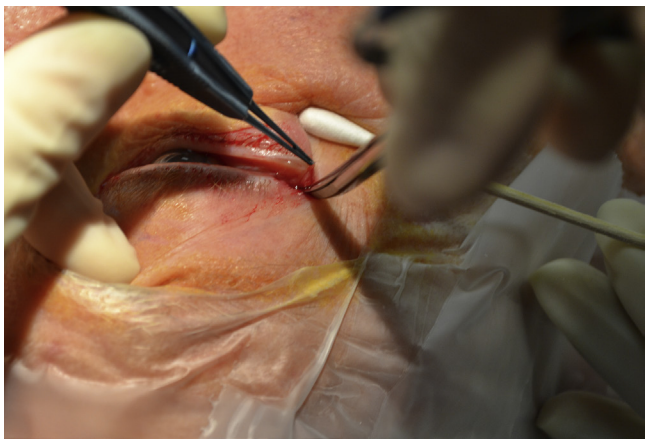

Fig. 153.4. Toothed forceps holding the lower eyelid anteriorly, strumming the scissors along the inferior orbital rim between the skin and conjunctiva to find the tendon.

  - Between the lower eyelid skin and inferior palpebral conjunctiva, palpate the inferior crus by strumming the scissors along the inferolateral orbital rim to find the tendon (see Fig. 153.4).
  - After palpation of the tendon with the scissors, the distinct corded entity is incised. Several incisions may be necessary to completely release the lower eyelid.
  - A superior cantholysis may be performed in a similar fashion with care to avoid the lacrimal gland given its propensity to bleed.
  - These incisions proceed parallel to the orbital rim.
  - Control any hemorrhage with pressure or bipolar cautery.

Common Errors in Technique

- Insufficient inferior cantholysis: The lower eyelid should be easily distracted from its attachment to the lateral canthus at the conclusion of the procedure (Fig. 153.5).
- Failure to use countertraction of the lower eyelid: Adequate and constant countertraction of the lower eyelid anteriorly with toothed forceps will place the inferior crus on traction, and the lower eyelid release will be felt in a graded fashion as each incision severs portions of the inferior crus of the lateral canthal tendon.
- Anticipating visual identification of the inferior crus: The inferior cantholysis is performed by palpation and of knowledge of eyelid anatomy.

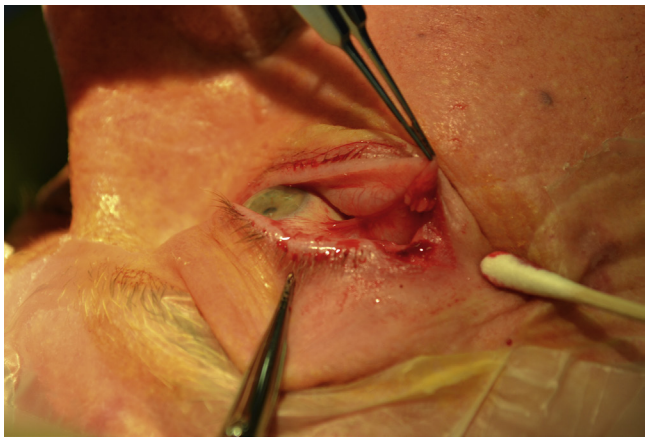

Fig. 153.5. Laxity of the lower eyelid following lateral canthotomy and inferior cantholysis.

POSTOPERATIVE PERIOD

Postoperative Management

- Topical antibiotic ointment to the lateral canthotomy site for 1 week
- Serial examinations including measuring best corrected visual acuity, pupils, and intraocular pressure
  - Eye pressure should be rechecked 30 minutes after the procedure.
  - Failure to decrease the intraocular pressure below 30 mm Hg should prompt a superior cantholysis and possible intraoperative exploration for definitive treatment.
- Discontinuation of anticoagulants, reversal of coagulopathies, and treatment of uncontrolled hypertension if possible
- Patients with spontaneous, non-traumatic/non-iatrogenic, orbital hemorrhage without an orbital lesion/cause should undergo a systemic evaluation to rule out inherited or acquired etiologies of coagulopathies.

Complications

- Failure to completely sever the inferior canthal tendon
- Eyelid malposition, such as ectropion, can be corrected on an outpatient basis in the future.
- Injuries to the globe are rare and should be immediately recognized to prompt an ophthalmic evaluation and management.

Alternative Management Plan

While a multitude of adjunctive medical therapies have been described, such as systemic and topical intraocular pressure lowering agents and high-dose corticosteroids,[10] these measures are not immediate and should not delay surgical intervention. Patients at risk, but have yet to develop orbital compartment syndrome, may be conservatively managed with serial examinations, but these should be limited to cases with close collaboration with ophthalmology. Further decompression of the orbit in the operating room may be needed if these surgical and medical therapies fail to decrease the patient's intraocular pressure.

DISCUSSION

Evidence-Based Medicine Question

What is evidence for performing a superior cantholysis after an inferior cantholysis?

While there are no large case series reporting the efficacy and need for a superior cantholysis after a lateral canthotomy and adequate inferior cantholysis is performed, Haubner et al. (2015) reported the intraocular pressure lowering effects of the procedures in a fresh-frozen cadaveric study. Eight orbits were injected with viscous material to simulate an orbital compartment syndrome. The range of intraocular pressures was from 30s to 80s after intraorbital injection. Seven orbits achieved a final pressure of less than 20 mm Hg with a lateral canthotomy and inferior cantholysis alone. The two orbits required an additional superior cantholysis to achieve a complete decompression, as described by the authors as a final intraocular pressure of less than 10 mm Hg.

Haubner F, Jägle H, Nunes DP, et al: Orbital compartment: effects of emergent canthotomy and cantholysis. Eur Arch Otorhinolaryngol 2015;272(2):479–483.

Editorial Comment

The "orbital compartment syndrome" is defined as an uncommon ophthalmologic surgical emergency characterized by an acute rise in intraorbital pressure, which may result in blindness. It is typically the result of facial trauma or a surgical procedure.

Lateral canthotomy is a brief but critical procedure for every otolaryngologist to be familiar with. Its use in emergency situations (increasing proptosis of any kind) and its place as the first step of other surgical procedures require careful rote memorization of the steps in this procedure and practice on a cadaver if possible.

Susan Stefko

Access the review questions online at http://www.expertconsult.com

REFERENCES

1. Gioia VM, Linberg JV, McCormick SA. Anatomy of the lateral canthal tendon. Arch Ophthalmol 1987;105:529–532.
2. Jordan DR, Anderson RL, Holds JB. Modifications to the semicircular technique in eyelid reconstruction. Can J Ophthalmol 1992;27(3):130–136.
3. Waite PD, Carr DD. The transconjunctival approach for treating orbital trauma. J Oral Maxillofac Surg 1991;49(5):499–503.
4. Riedel KG, Beyer-Machule CK. Temporal tarsal strip-plasty for correction of malposition of the lower eyelid. Fortscr Ophthalmol 1991;88(5):569–573.
5. Walsh FB, Hoyte WF. 3rd ed. Clinical Neuro-Ophthalmology, vol. 3. Baltimore, MD: Williams & Wilkins; 1969. p. 2380.
6. Hislop WS, Dutton GN, Duglas PS. Treatment of retrobulbar haemorrage in accident and emergency departments. Br J Oral Maxillofac Surg 1996;34:289–292.
7. Goodall KL, Brahma A, Bates A, et al. Lateral canthotomy and inferior cantholysis: an effective method of urgent orbital decompression for sight threatening acute retrobulbar haemorrhage. Injury 1999;30(7):485–490.
8. Hislop WS, Dutton GN. Retrobulbar haemorrhage: can blindness be prevented? Injury 1994;25:663–665.
9. Popat H, Doyle PT, Davies SJ. Blindness following retrobulbar haemorrhage—it can be prevented. Br J Oral Maxillofac Surg 2007;45:163–164.
10. Wood CM. The medical management of retrobulbar haemorrhage complicating facial fractures: a case report. Br J Oral Maxillofac Surg 1989;27:291–295.

REVIEW QUESTIONS

1. Which of the following statements is false? Orbital compartment syndrome
   a. Can lead to permanent vision loss if untreated
   b. Necessitates a prompt diagnosis to prevent delays in treatment
   c. Is an indication for an emergent lateral canthotomy and inferior cantholysis
   d. Can be medically managed without the need for a lateral canthotomy/cantholysis

2. Which of the following is not a potential cause for orbital compartment syndrome?
   a. Fulminant sinusitis without signs of orbital inflammation on CT scan
   b. Cataract surgery with topical anesthesia only
   c. Thrombosis of an orbital varix
   d. Sneezing after sustaining an orbital floor fracture

3. Which of the following signs should raise the suspicion of orbital compartment syndrome developing?
   a. Symptoms of seeing flashing lights
   b. Sudden proptosis
   c. Monocular diplopia (double vision only present with the unaffected eye is closed)
   d. Discharge from the eye

154 Orbital Exenteration

Tonya Stefko

INTRODUCTION

- The radical surgery of orbital exenteration is occasionally necessary in the management of cancer of the head and neck. For the Otolaryngologist, it will most frequently be due to the spread of a malignant tumor from the adjacent paranasal sinuses or the skull base. Some cancers arising in the skin will also require total or subtotal removal of the orbital contents. Invasive fungal infections are indications for aggressive débridement, sometimes including orbital exenteration. Rarely, a benign but locally aggressive tumor or intractable pain will be an indication.
- The most clear-cut indications for orbital exenteration are those involving malignant tumors with no hope of salvaging vision in the affected eye (Fig. 154.1). These situations most often include squamous cell carcinoma and other epithelial malignancies. In the largest reported series of orbital exenteration, squamous cell carcinoma (originating in the sinus, skin, or conjunctiva) accounted for one-third of exenterations.[1] A more recent series found basal cell carcinoma to be the most frequent diagnosis, followed by melanoma and sebaceous cell carcinoma.[2] Conversely, a review of 70 consecutive cases of maxillectomy found that 40% of these patients required concurrent orbital exenteration.[3] Imaging is likely to underestimate the extent of tumor invasion into the orbit, and the decision to proceed may need to be made in the operating room. The recent trend, particularly with squamous cell carcinoma, has been preservation of the orbit except in instances of proven invasion of the periorbita (by frozen section at the time of surgery). In several retrospective series there has been no difference in disease-free survival between patients treated with orbit-sparing procedures and those whose surgery included orbital exenteration.[4]
- Malignant tumors of the orbit or eyelids, although not strictly invading the eye or periorbita itself, may require removal of the orbital contents because of insufficiency of the remaining tissue for protection of the globe (Figs. 154.2 and 154.3).
- Surgical decision making in the setting of aggressive infection is difficult. Most fungal infections of the orbit spread from adjacent sinuses, and two main types occur. Aspergillus affects both immunocompromised and immunocompetent



Fig. 154.1. Patient with malignant melanoma destroying the globe, adnexa, and orbital contents.

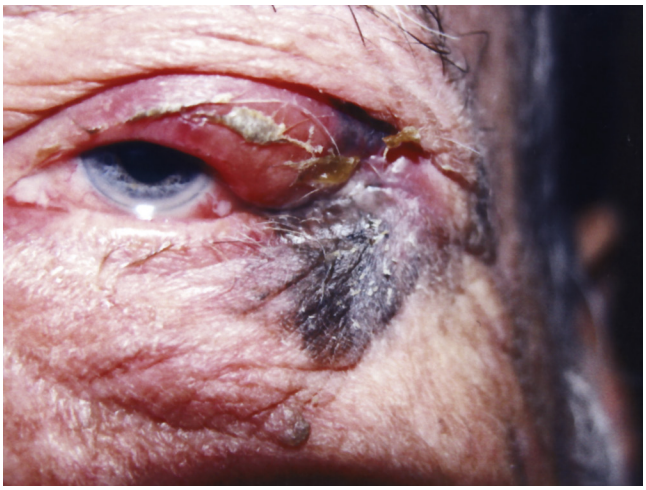

Fig. 154.2. Advanced cutaneous melanoma of the eyelid with orbital extension.

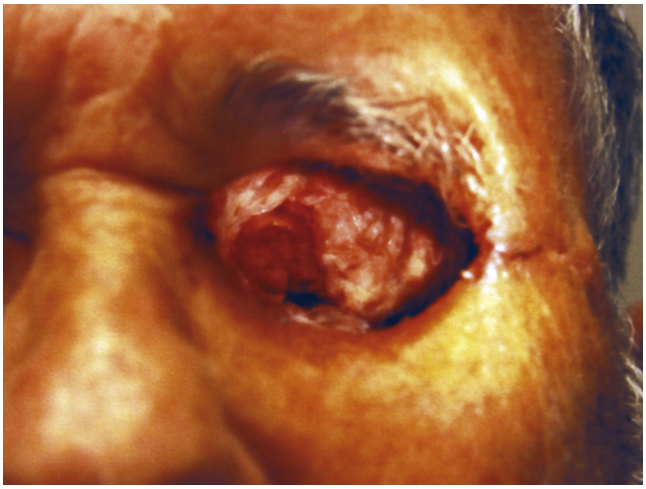

Fig. 154.3. Patient from Fig. 154.2, 12 days after exenteration with a split-thickness skin graft in the orbit.

hosts. In the former patients, the prognosis is extremely poor if the immune status cannot be improved and if intracranial involvement is present.[5] In the latter setting, exenteration is likely to be necessary in cases of apical involvement but not when the infection is confined to the anterior, inferomedial orbit,[6] where limited débridement may suffice.

- Rhino-orbital-cerebral mucormycosis is a rare but serious infection caused by *Rhizopus* species (occasionally *Mucor* or *Absidia*). It affects immunocompromised patients, most often those with a concurrent metabolic acidosis. These patients require aggressive surgical débridement to the level of bleeding tissue, with correction of the underlying medical abnormality. This has frequently included orbital exenteration in the presence of orbital signs, but one series revealed no difference in survival between patients with orbital involvement who underwent exenteration and those who did not.[7] However, the overall mortality in patients with orbital involvement was higher (33% vs. 14%). The operation may be followed by hyperbaric oxygen therapy, which improves survival.[8] A recent review showed 12/14 patients with orbital involvement died of the disease, and the only two who survived had undergone orbital exenteration.[5]
- Three to 17% of patients requiring exenteration have benign orbital disease.[9] The various associated diagnoses include inflammatory disease, Stevens-Johnson syndrome, lymphangioma, meningioma, and others. These diseases are either painful, inadequately controlled medically, and "grossly disfiguring" or, although histologically benign, tend to invade adjacent tissue.[10] The pain associated with the disease most often resolves immediately after surgery.

KEY OPERATIVE LEARNING POINTS

- In the practice of most Otolaryngologists, exenteration will be undertaken in conjunction with maxillectomy or during aggressive sinus débridement (e.g., for invasive fungal infection). During the informed consent process, if the decision whether to exenterate the orbit will be made at surgery, it must be made very clear to the patient and family that although every effort will be made to preserve the orbit and eye, this goal will not preclude complete eradication of disease.
- Total or subtotal exenteration should be planned. Subtotal exenteration most often means a partially lid-sparing technique (Fig. 154.4A), which is appropriate in most cases of benign disease and with tumors that primarily affect the posterior or deep portions of the orbit. It is inappropriate in any tumors affecting the skin, conjunctiva, or lacrimal gland. Lid-sparing exenteration gives an excellent color match to surrounding skin and heals relatively quickly.

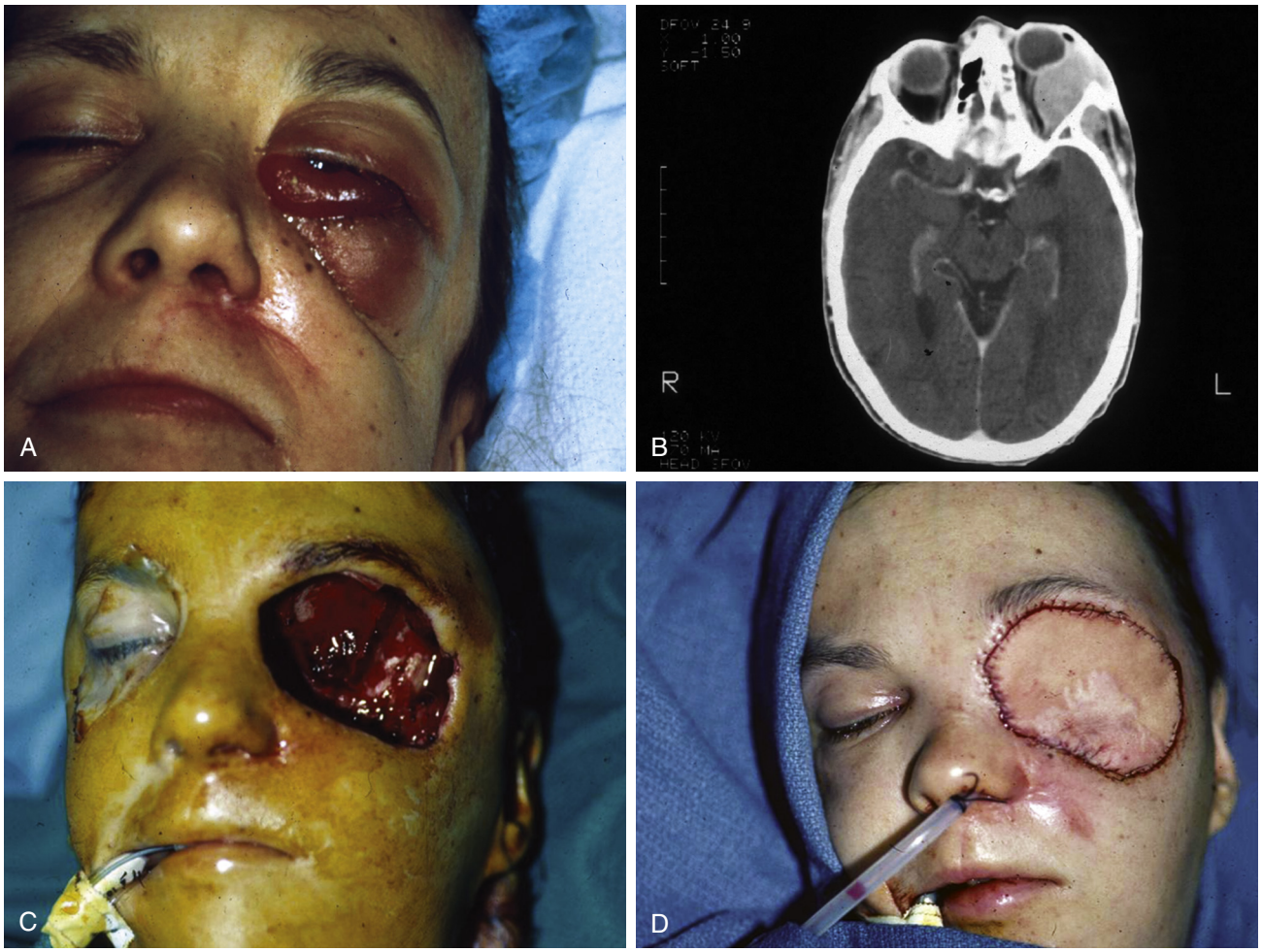

Fig. 154.4. A, Patient with a sarcoma of the maxilla treated by maxillectomy. Recurrence in the orbit was treated with radiation therapy. The tumor recurred once again and destroyed the orbital contents. **B,** Computed tomography scan demonstrating invasion of the orbit and destruction of the bony orbital wall. **C,** Defect after orbital exenteration. **D,** Reconstruction with a rectus abdominis free tissue transfer.

Globe-sparing exenteration has been described, with purported advantages of easier prosthetic fitting later.

PREOPERATIVE PERIOD

History

- Complete medical history, with attention to:
  - Previous malignancy
  - Tobacco use
  - Infectious disease (human immunodeficiency virus [HIV], human papilloma virus [HPV])
  - Bleeding disorders

Physical Examination

- Complete examination of the head and neck focusing on:
  - Examination of the cervical lymph nodes
  - Nasal/sinus endoscopy, if indicated
- Before scheduling surgery, a complete ophthalmologic examination of the remaining eye is indicated both to guide surgical decision making and to maximize the remaining vision.

Imaging

- Patients who may be candidates for orbital exenteration should, at the very least, be evaluated by computed tomography (CT) or magnetic resonance imaging (MRI) (or both) of the orbits, sinuses (see Fig. 154.4), and brain. In the majority of cases that involve malignancy, positron emission tomography (PET-CT) is also indicated.
  - Patients with invasive fungal sinusitis may have minimal findings on imaging.
- When a neck dissection is anticipated, preoperative imaging of the neck and scintigraphy should be considered. The choice of imaging will be guided by the patient's diagnosis. In patients with malignancies contiguous with the orbit, it is likely that imaging will underestimate the extent of disease, and intraoperative histopathologic monitoring will be necessary.

Indications

- Malignant tumor of the lacrimal gland
- Patients with tumor invasion of the periorbita proven by frozen section examination
- Resection of most of the orbital floor frequently leads to loss of integrity of the eye because of dystopia, diplopia, or ocular surface problems. This may be compounded by postoperative radiation effects on the eye.
- Invasive fungal sinusitis with orbital invasion

Contraindications

- Patients with invasion of orbital bones only will probably have comparable survival if the orbital contents are spared.

Preoperative Preparation

- Before the operation, coagulation studies, a complete blood count with platelets, and typing and crossmatching of two units of packed red blood cells should be performed.
- In many instances, given the radical nature of the surgery, the pathology of the lesion should be independently confirmed by pathologists experienced in the field of head and neck or orbital disease.
- Reconstructive options should be considered before surgery.



Fig. 154.5. Patient 1 year after left orbital exenteration for adenoid cystic carcinoma arising in left maxilla, reconstructed with an anterolateral thigh free flap.

  - The simplest option is healing by secondary intention, or granulation. The advantages of such healing are shorter operating time, good color match to surrounding tissue, excellent visibility for monitoring of possible recurrence of disease, and a tendency to produce a shallow socket (easier for eventual patient care). Disadvantages include a long healing time and the necessity for several painful dressing changes.
  - Split-thickness skin grafts, usually taken from the thigh, are frequently used to line the orbital cavity when total exenteration with removal of periosteum is performed (see Fig. 154.3). Although this leads to shorter recovery time and excellent visual monitoring for recurrence, a deeper cavity is formed, for which care and prosthetic fitting are somewhat more difficult. The pain encountered after this reconstructive option is generally from the donor site.
  - Local or free tissue flaps are most commonly performed at our institution, particularly for defects resulting from concurrent partial or complete maxillectomy. Temporalis muscle, with or without cervicofacial, radial forearm, and rectus abdominis flaps (see Fig. 154.4), are most frequently mentioned. These flaps have the advantage of ample tissue and good vascularity, which is desirable in a field likely to require radiation therapy (Fig. 154.5). Disadvantages of longer operating time, donor site morbidity/disfigurement, and a requirement for highly specialized microsurgical techniques (in the case of free flaps) discourage their use in very sick patients. These options also render monitoring for local recurrence of disease more difficult.

OPERATIVE PERIOD

Anesthesia

- General endotracheal anesthesia

Positioning

- Supine with vertex even with head of bed

Perioperative Antibiotic Prophylaxis

- cerebrospinal fluid (CSF) prophylactic dose (e.g., 2 g of cephalexin IV)

Monitoring

- Per anesthesia team

Instruments and Equipment to Have Available

- Suction
- Scalpels
- Monopolar cautery
- Bipolar cautery
- Curved enucleation scissors
- Snare
- Hemostatic agent
- Cottle elevator
- Dermatome if a split-thickness skin graft is planned

Key Anatomic Landmarks

- The frontoethmoidal suture is the level of the anterior and posterior ethmoid arteries and marks the level of the cribiform plate in most patients.
- The medial canthal tendon will be an area of dense adherence of tissue to bone and surrounds the lacrimal drainage system.

Prerequisite Skills

- Familiarity with orbital surgery

Operative Risks

- Bleeding requiring transfusion
- Postoperative infection
- Failure to control malignancy or infection
- Sino-orbital fistula
- CSF leak

Surgical Technique

- In the case of concurrent maxillectomy, that procedure is performed first.
- Surgical margins are marked (Fig. 154.6).
  - A suture tarsorrhaphy is usually helpful.
  - If the exenteration is to be a lid-sparing technique, an incision line several millimeters proximal to the eyelid margins and parallel to them is marked.
    - A scalpel is used to cut through skin and orbicularis muscle, and blunt dissection in the pretarsal/preseptal plane is then carried out to the level of the orbital rim.
    - The periosteum is incised, and the surgery proceeds as described in the following text.
- If the skin is to be included in the resection, the excision margins are drawn at the orbital rim and at least 1 to 2 cm from the cutaneous lesion (see Fig. 154.6).
- The marked areas may be infiltrated with local anesthetic with epinephrine to help with hemostasis.
- A no. 15 blade is used to make an incision through skin down to the periosteum. Bleeding from the supraorbital vessels should be expected.
- The periosteum is elevated with a Cottle or Freer elevator, beginning at the superotemporal portion of the orbit where the bone is thickest.

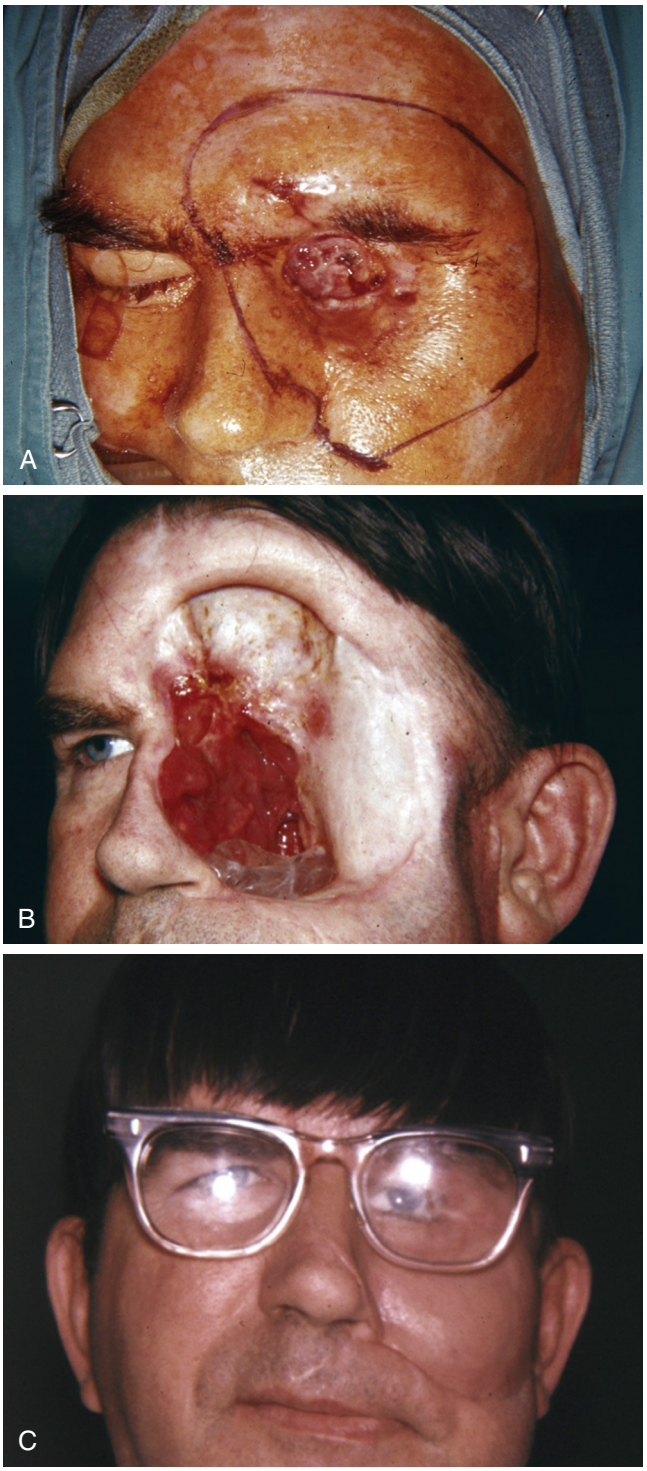

Fig. 154.6. A, Patient with recurrent basal cell carcinoma in a previously exenterated orbit. **B,** Postoperative defect lined with a split-thickness skin graft. **C,** Postoperative appearance with a prosthesis and glasses.

  - Dissection in this plane continues circumferentially and posteriorly, with cautery of the zygomaticofacial and zygomaticotemporal vessels encountered in the lateral wall.
  - Resistance will occur in the area of the trochlea (superomedially) and at the canthal ligaments and may require sharp dissection in these areas.

  - The posterior limb of the medial canthal tendon should be elevated off the bone, and the lacrimal sac should be divided at its junction with the nasolacrimal canal.
  - The inferior oblique muscle originates just lateral to the sac and should be elevated with the periosteum.
- Dissection proceeds posteriorly toward the apex of the orbit.
- Special care should be directed to the following areas:
  - Elevation of the periosteum over the lamina papyracea must be carried out very gently so that no dehiscences are created in the bone.
  - The ethmoidal vessels must be divided and the bleeding controlled with bipolar cautery and bone wax.
  - Areas of the roof, particularly posteromedially, are often quite thin or contain frank dehiscences.
- The contents of the superior and inferior orbital fissures and the apical stump must now be divided, which may be accomplished with a curved knife, curved enucleation scissors, or a snare. The latter is tightened to a soft stop and tightened sequentially over a period of several minutes to assist with hemostasis. The snare may then be tightened completely to transect the apical stump, or curved scissors may be used to cut just anterior to it.
- The orbit should immediately be packed with gauze and pressure applied for 5 to 10 minutes.
- The apex should then be explored cautiously with suction and bipolar cautery to localize and control any bleeding.
- If the orbit is to heal by granulation, it should be lined with a nonadherent dressing such as Telfa followed by Xeroform gauze, packed with fluffed gauze, and bandaged tightly. A small pledget of cellulose (Surgicel) or other hemostatic agent may be placed over the apical stump.
- It may be possible in some patients to preserve the eyelids. After a skin graft has been placed in the orbit, the margins of the eyelid are sewn together to provide a good appearance or at least a better appearance than if the orbit were open to view.
- If the skin of the lid has been spared, it is draped over the rim and spread posteriorly as far as possible. The remainder of the orbit may be left to granulate or may be covered with a split-thickness skin graft. If a split-thickness graft is used, it is harvested from a non–hair-bearing area of the inner surface of the thigh or the abdomen, and the donor site is covered with an adherent dressing. Dimensions of the graft are approximately 5 × 10 cm before meshing. The graft is carefully draped into the orbital cavity, with care taken to ensure that the epithelial side remains exterior. The graft is sutured in place at the rim with interrupted 7-0 chromic gut or silk suture. The wound is then dressed as discussed earlier.
- If a local or free flap is to be used for reconstruction, it is prepared and placed as dictated by the specific procedure. Fig. 154.5 shows a young patient one year after maxillectomy, radiation, and orbital reconstruction with lateral thigh free flap (he has declined further contouring of the tissue). The patient in Fig. 154.4A underwent a maxillectomy for sarcoma of the maxilla. A recurrence was treated with radiation therapy. The tumor recurred once again and destroyed the orbital contents and the orbital wall. The orbital defect was reconstructed with a rectus abdominis free tissue transfer.
- When flap reconstruction is not used, the pressure dressing remains undisturbed for 3 to 5 days. During this time the patient should have antibiotic coverage. After this time, the pressure dressing is gently removed, and the area is soaked with saline. After 5 to 10 minutes, the lining layer (nonadherent dressing such as Telfa or Xeroform) may be gently loosened from the underlying tissue. Minimal débridement should occur at this stage because areas of skin that appear devitalized may heal surprisingly well. The area is coated lightly with antibiotic ointment, and the patient and family are instructed to repeat the application of ointment twice daily. Ointment should also be applied to the light dressing placed over the orbit to prevent adherence. Vigorous cleaning of the area should be avoided.
- Rotation of a temporalis muscle flap (or its anterior half) through a defect created in the lateral orbital wall (either by removing the rim or drilling through the wall) can be used to create a shallower cavity. If the anterior half is used, the posterior half may be moved forward to prevent temporal hollowing.
  - The muscle is draped into the defect, sutured loosely in place with interrupted absorbable sutures, and either left to granulate, or the remaining lids are draped over it anteriorly.

Common Errors in Technique

- It is posteromedially that an iatrogenic cerebrospinal fluid leak may be created, either by direct trauma or by the use of monopolar cautery, which may travel through emissary foramina or dehiscences. Monopolar cautery should be avoided except in the anterior-most portion of the orbit.
- Sino-orbital fistulae most commonly occur in the area of the lamina papyracea.

POSTOPERATIVE PERIOD

Postoperative Management

- The patient is examined in the office 1 week postoperatively and then at regular intervals afterward as dictated by the healing process and the disease. Weekly or biweekly visits are appropriate in the first 4 to 6 weeks for cleaning of the socket and monitoring for infection. In most cases in which radiation therapy is not necessary, the patient is ready for prosthesis fitting in 3 months (see Fig. 154.6).
- Aggressive débridement of skin grafts early in the postoperative period is to be avoided.
- It has been reported that most patients are likely to wear an occlusive eye patch regardless of attempts at reconstruction. Prostheses may be fashioned by a prosthodontist and may be affixed by topical adhesive. Alternatively, prostheses may be fixed with magnets to osseointegrated implants.

Complications

- Intraoperative bleeding
  - Packing and pressure
  - Prothrombotic agents applied to the orbital apex
  - Transfusion of packed red blood cells if necessary
- Postoperative hematoma
  - Postoperative hematoma requires therapy if it occurs under a skin graft or in a free flap. The former may be drained by making a small incision in the graft, gently evacuating the hematoma, and then replacing the pressure dressing for 2 to 5 days. If this compromises perfusion of a free flap, the patient should be taken to the OR urgently for exploration.
- Postoperative infection
  - Must be vigorously treated with intravenous and then oral antibiotics, with judicious surgical débridement of devitalized tissue or drainage of purulent collections as needed
- Dehiscence of the surgical wound

- Dehiscence of the surgical wound should raise suspicion of infection, which must be treated aggressively before considering secondary repair.
- Free flaps must be monitored carefully by Doppler ultrasound to ensure patency of the artery and vein, and a pressure dressing is contraindicated.
- Fistulas resulting from orbital exenteration may communicate with either the sinuses or dura.
  - If a bone or dural defect is noted intraoperatively, it should be repaired.
  - If the orbit is to heal by granulation or a skin graft is used, a small flap of extraocular muscle and adipose tissue may be spared and used to cover either the bone window or the dural repair.

Alternative Management Plan

- When tumor involves both orbital apices, other palliative options should be sought.

DISCUSSION

Evidence-Based Medicine Question

Does orbital exenteration increase survival in patients with orbital malignancy?

A recent meta-analysis of the available literature assessing survival in patients with sinonasal malignancies involving the orbit suggests that patients in whom the orbit was not exenterated have a very slight increase in 5-year survival. However, their 95% confidence intervals evenly straddled an effect of 1 (i.e., no difference between the groups). The experience of one group with orbital exenteration for ethmoid malignancies finds it is mandatory to exenterate the orbit in cases where the invasion goes beyond periorbita, both for local control and for survival. The authors distinguish three grades of orbital invasion: invasion of the lamina papyracea, invasion of periorbita beyond the lamina, and invasion of the medial rectus, optic nerve, globe, or skin. In cases of maxillary SCC, a retrospective report of 139 patients showed that those with orbital invasion who were treated with orbit-preserving surgery had no difference in survival from those treated with radical surgery. All of their patients had undergone preoperative radiotherapy. Another more recent analysis seems to agree that sparing the orbit is indicated in those cases where invasion only involves the bony walls of the orbit or is confined to the periorbita (periorbita may be sampled by frozen section at surgery but adipose tissue cannot). They caution, however, that with massive invasion of the orbit (beyond orbital adipose tissue), it is not appropriate to spare the orbital contents and that in cases involving orbital adipose tissue, the limited resection should be undertaken only by experienced surgeons.

Editorial Comment

This chapter provides a comprehensive review of the use of orbital exenteration for infectious and neoplastic pathologies. An orbital exenteration has profound implications for the patient's quality of life especially in the psychologic and psychosocial domains. Therefore, it deserves careful consideration and surgical confirmation of imaging findings. Despite multiple attempts to clarify and better define its oncologic indications, controversy abounds. Nonetheless, as pointed out in this chapter, the current literature supports some important conclusions. Patients with tumors invading the bony orbit but sparing its soft tissues do not require an exenteration, as their oncologic outcome seems unaffected by the orbital preservation. However, it is important to recognize that anatomic preservation does not equate a functioning eye. Orbital function in these patients ultimately depends upon the adequacy of the reconstruction, need for postoperative adjunctive radiation or chemoradiation therapy (type of radiation, fractionation, and total dosage and extent of the field of treatment are important considerations), and the presence of concurrent cranial nerve VI or VII deficits. Performing an orbital exenteration to avoid a potential future complication is a complex and arguable decision that requires a very extensive and candid discussion between the patient and surgeon.

Conversely, patients with tumors that invade the orbital soft tissues may benefit from an orbital exenteration as long as the tumor can be cleared completely at all other locations. Its association with poorer outcomes is likely the result of tumors that are more aggressive. Periorbita is a formidable barrier; thus, a tumor rarely transgresses it. Nonetheless, to which degree the soft tissue must be invaded to constitute an absolute indication for an orbital exenteration is a highly contentious issue and varies according to the histopathology as well as the aforementioned functional issues. Correspondingly, an orbital exenteration for benign tumors must have a clear palliative value such as control of intractable pain.

Ricardo Carrau

Access the review questions and additional sources list online at http://www.expertconsult.com

REFERENCES

1. Levin PS, Dutton JJ. A 20-year series of orbital exenteration. Am J Ophthalmol 1991;112(5):496–501.
2. Rahman I, Cook AE, Leatherbarrow B. Orbital exenteration: a 13 year Manchester experience. Br J Ophthalmol 2005;89(10):1335–1340.
3. Yucel A, Cinar C, Aydin Y, et al. Malignant tumors requiring maxillectomy. J Craniofac Surg 2000;11(5):418–29.
4. Carrau RL, Segas J, Nuss DW, et al. Squamous cell carcinoma of the sinonasal tract invading the orbit. Laryngoscope 1999;109(2 Pt 1):230–235.
5. Thurtell MJ, Chiu AL, Goold LA, et al. Neuro-ophthalmology of invasive fungal sinusitis: 14 consecutive patients and a review of the literature. Clin Experiment Ophthalmol 2013;41(6):567–576.
6. Dhiwakar M, Thakar A, Bahadur S. Invasive sino-orbital aspergillosis: surgical decisions and dilemmas. J Laryngol Otol 2003;117(4):280–285.
7. Peterson KL, Wang M, Canalis RF, Abemayor E. Rhinocerebral mucormycosis: evolution of the disease and treatment options. Laryngoscope 1997;107(7):855–862.
8. Yohai RA, Bullock JD, Aziz AA, Markert RJ. Survival factors in rhino-orbital-cerebral mucormycosis. Survey Ophthalmol 1994;39(1):3–22.
9. Bartley GB, Garrity JA, Waller RR, et al. Orbital exenteration at the Mayo Clinic. 1967–1986. Ophthalmology 1989;96(4):468–473.
10. Rose GE, Wright JE. Exenteration for benign orbital disease. Br J Ophthalmol 1994;78(1):14–18.

REVIEW QUESTIONS

1. Orbital exenteration is not indicated in which of the following situations?
   a. Rhinocerebral mucormycosis
   b. Invasion of the orbital floor by squamous cell cancer of the maxillary sinus
   c. Capillary hemangioma involving both lids and the extraconal space
   d. Imaging evidence of frank invasion of the medial rectus muscle in the setting of an ethmoid tumor

2. The safest way to establish hemostasis of the apical stump in an orbital exenteration is by using monopolar cautery to divide the optic nerve at the annulus of Zinn.
   a. True
   b. False

3. Areas of greatest adherence of periorbita to bone include
   a. The lacrimal gland fossa
   b. The trochlea
   c. The orbital floor
   d. The zygomaticofacial neurovascular bundle

ADDITIONAL SOURCES

Bartley GB, Kasperbauer JL. Use of a flap of extraocular muscle and fat during subtotal exenteration to repair bony orbital defects. Am J Ophthalmol 2002;134(5):787–788.

Ben Simon GJ, Schwarcz RM, Douglas R, et al. Orbital exenteration: one size does not fit all. Am J Ophthalmol 2005;139(1):11–17.

Cuesta-Gil M, Concejo C, Acero J, et al. Repair of large orbito-cutaneous defects by combining two classical flaps. J Craniomaxillofac Surg 2004;32(1):21–27.

Iannetti G, Valentini V, Rinna C, et al. Ethmoido-orbital tumors: our experience. J Craniofac Surg 2005;16(6):1085–1091. 16327559.

Konstantinidis L, Scolozzi P, Hamedani M. Rehabilitation of orbital cavity after total orbital exenteration using oculofacial prostheses anchored by osseointegrated dental implants posed as a one-step surgical procedure. Klinische Monatsblatter fur Augenheilkunde 2006;223(5):400–404.

Menon NG, Girotto JA, Goldberg NH, et al. Orbital reconstruction after exenteration: use of a transorbital temporal muscle flap. Ann Plast Surg 2003;50(1):38–42.

Mohr C, Esser J. Orbital exenteration: surgical and reconstructive strategies. Graefe's Arch Clin Exp Ophthalmol 1997;235(5):288–295.

Muscatello L, Fortunato S, Seccia V, et al. The implications of orbital invasion in sinonasal tract malignancies. Orbit 2016;35(5):278–284.

Reyes C, Mason E, Solares CA, et al. To preserve or not to preserve the orbit in paranasal sinus neoplasms: a meta-analysis. J Neurolog Surg Part B, Skull base 2015;76(2):122–128.

Stern SJ, Goepfert H, Clayman G, et al. Orbital preservation in maxillectomy. Otolaryngology—Head Neck 1993;109(1):111–5.

Tahara S, Susuki T. Eye socket reconstruction with free radial forearm flap. Ann Plast Surg 1989;23(2):112–116.

Wu X, Tang P, Qi Y. Management of the orbital contents in radical surgery for squamous cell carcinoma of the maxillary sinus. Chin Med J 1995;108(2):123–125.

Wulc AE, Adams JL, Dryden RM. Cerebrospinal fluid leakage complicating orbital exenteration. Arch Ophthalmol 1989;107(6):827–830.

155 Rhinoplasty and Surgery of the Nasal Valve

Summit Kundaria, Paul Leong, Benjamin W. Light

INTRODUCTION

Rhinoplasty includes functional, cosmetic, and reconstructive surgery to address the function and appearance of the nose. Functionally, the airway begins at the nostril, and issues such as static or dynamic collapse (collapse on inspiration) may present at the level of the external or internal nasal valve.[1,2] The nose is the central facial aesthetic unit that is divided into nine subunits, and its structure has a great impact on an individual's overall appearance. The anterior projection of the nose on the face makes nasal reconstruction an art that combines the functional and aesthetic aspects of rhinoplasty. True mastery of rhinoplasty, with all its aesthetic and functional nuances, requires a long learning curve and the dedicated focus of a developing surgeon.

KEY OPERATIVE LEARNING POINTS

- For cosmetic rhinoplasty, the patient's motivations and expectations from surgery must be carefully explored. A realistic patient with sensible expectations is the foundation for a positive outcome.
- Patients with functional complaints may be best managed with concurrent septoplasty and inferior turbinate reduction.
- Altering the relative lengths of the medial crura and lateral crura will have predictable effects on nasal rotation and projection.
- All rhinoplasty should be performed with careful consideration of the aesthetic and functional consequences of the surgical manipulations being carried out.

PREOPERATIVE PERIOD

Careful evaluation of patient motivations for surgery is critical to surgical success, as unrealistic goals or aesthetic alterations that are not surgically feasible should be discussed beforehand. Managing patient expectations is critical to the preoperative and postoperative course. A detailed anatomic evaluation of the patient's nasal anatomy including a full facial evaluation must be carried out.

History

History of Present Illness and Past Medical History

- Motivations for surgery
- History of prior nasal surgery or trauma
- Presence of nasal obstruction and, if it is present, at rest or with inhalation (static vs. dynamic collapse)
- Presence of anosmia
- History of easy bleeding or bruising
- Patients should be screened for psychiatric disorders at the surgeon's discretion.

Medications

- Antiplatelet and anticoagulants should be discontinued for 2 weeks preoperatively, as medically indicated.
- Patients should all be screened for over-the-counter and herbal medications that may increase bleeding risk, such as high-dose fish oil.

Physical Examination

- A complete examination of the head and neck should be carried out, with particular attention to the external nasal anatomy.
  - The height of the nasion and rhinion should be noted, as well as the relative lengths of the nasal bones to the cartilaginous midvault.
  - The nasal bones should be palpated for irregularity and signs of prior trauma.
  - The thickness of the skin should be noted.
  - The shape of the medial crura and lateral crura should be noted, as well as their relative support.
  - The nasal-columellar relationship should be noted, as should the nasal projection.
  - The tip should be evaluated for bulbousness, and the cause of this should be investigated (thick skin vs. shape of cartilaginous skeleton).
  - The base of the nose should be evaluated for the shape and symmetry of the nostrils.
- Patients with nasal obstruction should have an endoscopic nasal examination to visualize the anatomic cause of obstruction, as the entire septum and inferior turbinates should be evaluated for deviation and hypertrophy, respectively.
- Examination of the patient during nasal inhalation (at a normal inhalation excursion and at a slightly elevated excursion) to evaluate for static and dynamic collapse of the internal and external nasal valves

Imaging

Any imaging that the patient had prior to consultation should be reviewed for bony anatomy and evidence of trauma, but imaging is not typically ordered when considering rhinoplasty alone. A full panel of rhinoplasty photographs should be taken, including frontal, oblique, basal, lateral, and lateral smiling.

Indications

- Improving the appearance of the nose
- Improving nasal obstruction from static or dynamic collapse of the internal or external nasal valve[3]
- Reconstruction after trauma or resection of cancer

Contraindications

- Medical comorbidities that would increase the risk of anesthesia or postoperative bleeding
- Unrealistic patient expectations or psychologic disorders that would place the patient at higher risk of postoperative dissatisfaction
- Active chronic nasal vasoconstrictor (rhinitis medicamentosa) use can increase the risk of intraoperative bleeding and interfere with the ability to use vasoconstrictors intraoperatively for hemostasis.

Preoperative Preparation

- Patients should be counseled about the postoperative care, including activity limitations, nasal rinses, and care of the nasal splints, if used.
- Expectations of improved appearance and function should be discussed, as well as the likely presence of palpable asymmetries and irregularities that may not be visually perceptible.
- General health clearance if necessary

Medication restriction list, including anticoagulants, should be reviewed with the patient 2 weeks prior to the procedure.

OPERATIVE PERIOD

Anesthesia

- Although rhinoplasty may be done with local anesthesia, sedation, or general anesthesia, the latter is the preferred method because of patient comfort and control of the airway in the case of severe epistaxis.

Positioning

- The patient is positioned supine with both arms tucked to allow the surgeon and assistant easy access to the facial area.

Perioperative Antibiotic Prophylaxis

- A single dose of IV antibiotic that covers skin flora (usually weight-dosed cephazolin if the patient is not allergic to penicillin) is given prior to the first incision.

Monitoring

- No special intraoperative monitoring is necessary for rhinoplasty alone.

Instruments and Equipment to Have Available

- Septorhinoplasty set
- Osteotomes (straight and curved, guarded)
- Rasps
- Freer elevator
- Converse scissors

Key Anatomic Landmarks

- Glabella
- Nasion/radix
- Rhinion
- Supratip
- Tip
- Infratip lobule
- Anterior septal angle
- Posterior septal angle
- Head of inferior turbinate
- Septum (cartilaginous and bony)
- Nasal bones
- Upper lateral cartilages
- Lower lateral cartilages
- Maxillary spine
- Nasal-columellar angle

Prerequisite Skills

- Septoplasty

Operative Risks

- Patient dissatisfaction with aesthetic result
- Nasal valvular collapse due to interrupted support mechanisms
- Scarring leading to airway blockage or unacceptable appearance
- Postoperative epistaxis
- Septal perforation
- Anosmia
- CSF leak

Surgical Technique

- Anesthesia
  - After the induction of general endotracheal anesthesia, the patient is positioned with the head of the bed turned 90 degrees and with both arms tucked so that the surgeon and assistant can both be at the patient's side without being limited by the patient's arms.
  - It is important to secure the patient's endotracheal tube in a way that does not distort the anatomy of the upper face and lip, as these landmarks are used throughout surgery to assess the patient's nose.
  - The patient's entire face is cleaned with ophthalmic betadine, and the patient is draped so that the entire face is visible.
- Local anesthesia
  - Open rhinoplasty begins with injection of local anesthesia into the planned incision sites and areas to be undermined.
  - A 1:1 mixture of 1% lidocaine and 0.5% Marcaine 1:100,000 with epinephrine is typically used. In the case of open rhinoplasty, this includes the transcolumellar incision, marginal incisions, and in the subcutaneous plane throughout the skin-soft tissue envelope and osteotomy sites.
  - If septoplasty is to be done concomitantly, then injection of the local anesthetic into the mucosa of the septum is also carried out.
- "Opening" the nose
  - The skin overlying the caudal margins of the lateral crura are first incised, followed by sharp dissection with converse scissors over the superficial aspects of these lateral crura to create pockets medial to the incisions, toward the nasal tip, as illustrated in Fig. 155.1.
  - The transcolumellar incision, usually designed as a "gull-wing" configuration as seen in Fig. 155.2A, is carried out with a scalpel through skin only, ensuring that the medial crura are not injured. This incision is extended horizontally past the flare of the medial crura and then vertically toward the dome as seen in Fig. 155.2B, paralleling the course of the caudal margin of the lower lateral cartilages.

- The skin is elevated over the medial crura with converse scissors inserted at the vertical aspect of one incision and aimed in a subcutaneous plane toward the contralateral vertical incision as seen in Fig. 155.3.
- Once this tunnel is finished, the deep aspect of the transcolumellar incision can be completed. The columellar artery often needs to be cauterized at this point, and then sharp dissection with scissors resumes to follow the caudal margins of the medial crura, as seen in Fig. 155.4A, to the nasal tip and to connect this flap to the previously dissected tunnels overlying the lateral crura.
- Sharp dissection is used to continue to elevate the soft tissue flap toward the nasion as seen in Fig. 155.4B, identifying the upper lateral cartilages and ensuring that dissection is carried out superficial to these as well as the nasal bones.
- Once the nasal bones are identified, sharp dissection is continued in the subperiosteal plane to the nasion. Hemostasis can be achieved by bipolar cautery or pressure but is usually not necessary unless dissection was carried out laterally into branches of the angular artery anastomosis.



Fig. 155.1. The marginal incision is made just caudal to the lateral crus and dissection followed on the superficial surface.

- The medial crura are retracted laterally, and the plane between them is sharply dissected to identify the caudal septum. Subperichondrial planes are identified on each side of this, and these flaps are raised bilaterally past the bony-cartilaginous junction. This approach can be used for the septoplasty and is especially useful in cases of severe deviations of the caudal septum causing nasal vestibular stenosis.
- In cases of lesser deviation of the septum, lack of caudal septal deviation, and when extra-corporal septoplasty is not indicated, a simple hemitransfixion incision may be more appropriate for a septoplasty.
- The attachments of the upper lateral cartilages to the septum are identified in a submucosal plane and are transected sharply, taking care to not injure the nasal mucosal lining.
- The nasal skeleton is now opened, and the septal cartilage is available for harvesting grafts, and the previously identified goal of surgery is addressed. We will now divide the nasal skeleton into thirds from superior to inferior and outline manipulations that can affect the appearance and function of the nose.

- Upper third
  - The bony upper third of the nose consists primarily of the nasal bony pyramid. In cases of a deficient projection of bony pyramid, grafting can be carried out with autologous cartilage with or without muscle fascia or perichondrium to augment the nasion.
  - Such maneuvers move the nasion superiorly, which can add balance to a nose that appears too short because of a low nasion.
  - More commonly, the nasal bones need to decrease in projection, in the case of dorsal hump removal. The hump typically has cartilaginous and bony components, with the cartilaginous hump resected sharply as shown in Fig. 155.5 and the bony aspect commonly addressed with osteotomies.
  - The osteotomies commonly used are shown in Fig. 155.6.
  - A dorsal osteotomy is carried out with care taken to have the plane of the osteotome in a path that leaves the remaining nasal bones of equal height as shown in Fig. 155.7.
  - Once the bony hump is removed, the patient is left with an "open roof," that is, lateral nasal bones with a flat, open

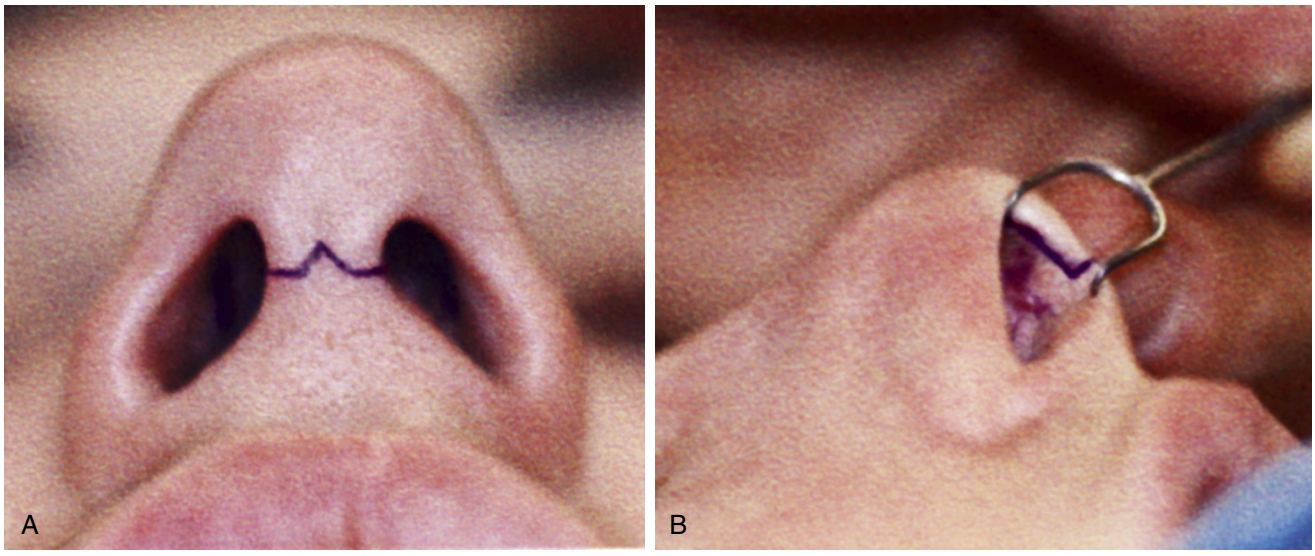

Fig. 155.2. A, Design of a transcolumellar incision. A five pointed "gull-wing" design is used. **B,** View of the lateral aspect of the transcolumellar incision.

dorsum without bony covering. Unless the nasal bones are medialized with lateral osteotomies, the patient can be left with an open roof deformity.

- The lateral osteotomies are carried out by engaging an osteotome to the pyriform aperture, usually on the ascending process of the maxilla at the level of the lateral attachment of the inferior turbinate. It helps to mark the patient's path of the osteotomy on the skin for an inexperienced surgeon so that both sides can be done symmetrically.
- Fig. 155.8 demonstrates the technique often followed for an appropriate lateral osteotomy. The High-Low-High technique is followed in the execution of this maneuver. The terminology "High-Low-High" can be confusing and merits more detailed discussion.
  - Starting "High" on the pyramidal aperture above the root of the inferior turbinate allows for the preservation of a triangular segment of maxillary bone that respects the ligamentous lateral suspensory attachment extending from the distal lateral crura.
  - Preserving this relationship avoids potential medialization of the lateral confine of the nasal valve. Preceding "Low" or posterior on the ascending process of the maxillary bone allows for the majority of the length of the bone incision to approximate the nasofacial junction under relatively thick lateral nasal skin.
  - More anterior osteotomies proceed through thinner bone (less structurally viable) and may be more easily palpable through thinner medial nasal skin.
  - The "High" end point of the osteotomy follows an anterior apex curvature. This allows the more predictable set point of the "back fracture" (illustrated with a perforated line in Fig. 155.8) required to allow medial mobilization of the nasal sidewall segment.
  - The apex of the osteotomy is terminated at the level of the medial canthus so as to prevent a "rocker" deformity protrusion of anterior margin of the bone at the superior fracture sight.
- Most often this osteotomy is performed through the endonasal approach to avoid potential external visible puncture trauma/scar potentially associated with percutaneous osteotomy techniques. The percutaneous osteotomy technique has advantages when dealing with severe upper third nasal deformities where extensive dorsal osteotomy work is necessary to mobilize old fractures.
- Once the bones are medialized adequately, gentle contouring can be carried out with a fine rasp in order to smooth any bony irregularities, as the skin in this region is thin and patients tend to notice bony asymmetries for this reason. A patient who underwent a dorsal hump removal is shown in Fig. 155.9.

- Middle third
  - The middle third of the nose consists primarily of the upper lateral cartilages and their attachment to the septum.
  - During open rhinoplasty, the cartilaginous septum is readily accessible to contour to the patient's desired look. This maneuver should be done with care, as overresection of the dorsal septum can lead to functional and cosmetic issues. If there is any twisting or deviation of the dorsal septum in this area, it should be addressed.
  - A common intervention in the middle third of the nose is grafting, namely, spreader grafts. These long, flat grafts typically made out of septal or auricular cartilage provide dorsal support to the middle vault and prevent or treat middle vault collapse. They serve a functional goal of preventing or treating collapse of the internal nasal valve, as well as a cosmetic goal of preventing an inverted "V"

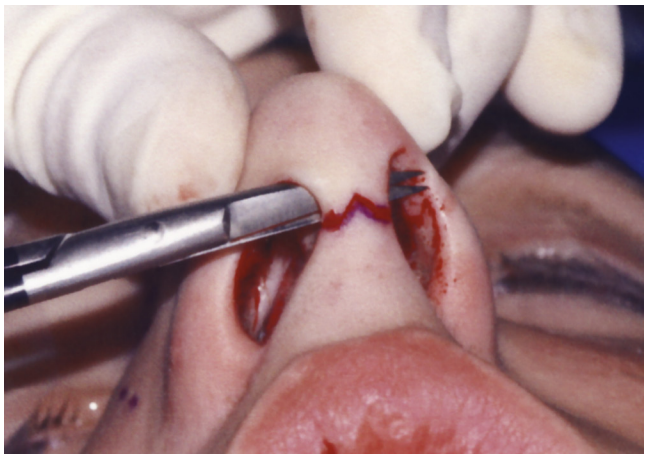

Fig. 155.3. The transcolumellar incision is completed sharply with the tissue scissors, making sure to stay superficial to the medial crura.

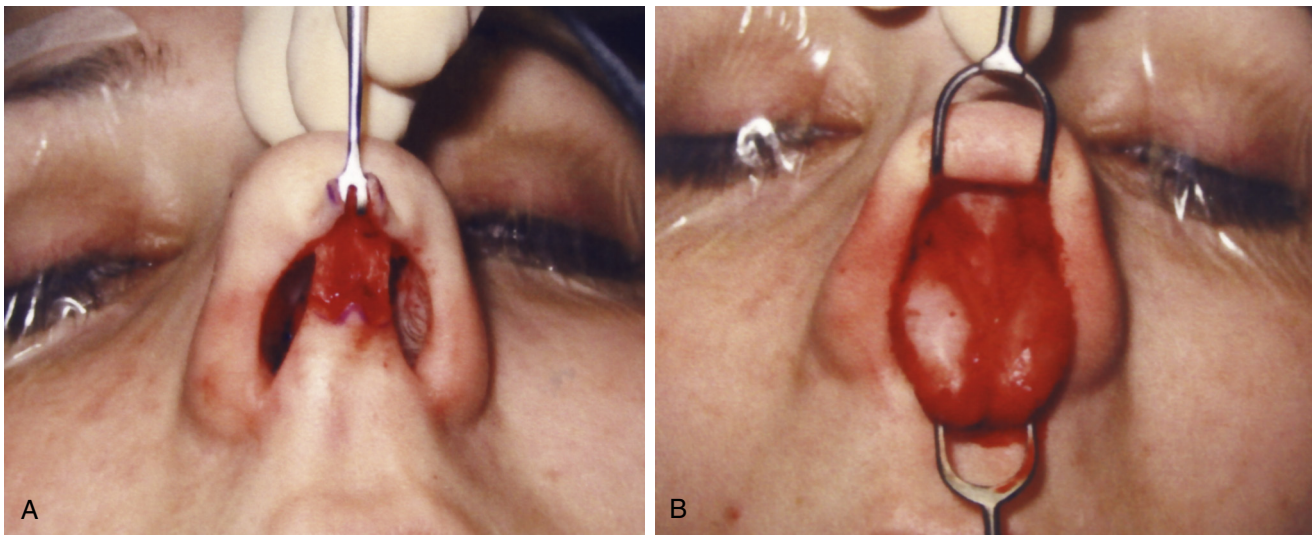

Fig. 155.4. A, The skin envelope is retracted while sharp dissection is used to elevate the skin envelope from the tip cartilages. **B,** Inferior retraction of the nasal tip cartilages aids in dissection toward the nasion.

deformity, which is a mismatch of width between the bony and cartilaginous dorsum.
- Spreader grafts are versatile, as they can be carried out symmetrically for the reasons above or asymmetrically to treat a deviated dorsal septum. They are typically secured in place using three separate interrupted horizontal mattress sutures to prevent any shifting or twisting of the grafts, as any movement would be visible or palpable to the patient.

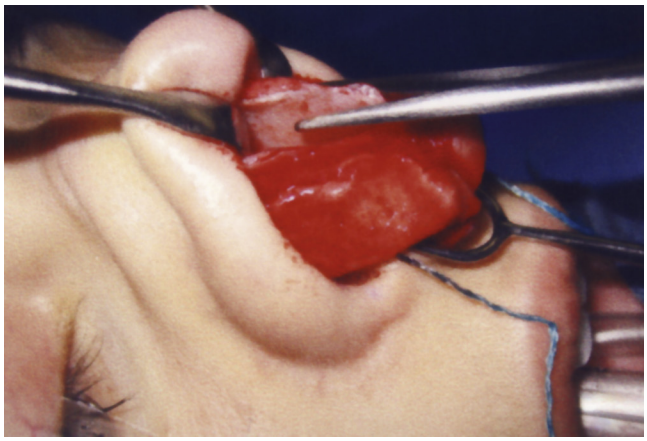

Fig. 155.5. Once the skin envelope has been elevated, a dorsal resection can be carried out with the scalpel or scissors, based on surgeon preference. Shown is the technique with the angled Foman scissors.

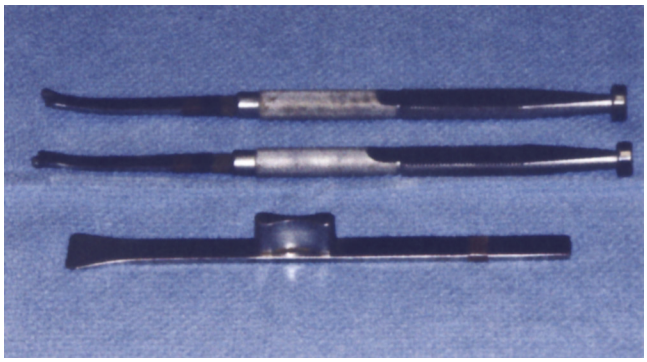

Fig. 155.6. Shown are the curved left and right osteotomes *(above)* and the straight Rubin osteotome.

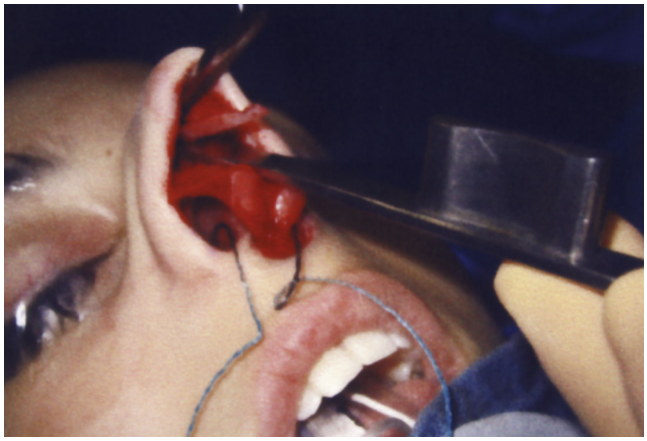

Fig. 155.7. A Rubin osteotome is used to carry out the dorsal osteotomy.

  - After spreader grafts are placed, the upper lateral cartilages are typically secured to them in their native position, using interrupted horizontal mattress sutures.
  - A variation of spreader grafts using cartilage harvested from elsewhere is to perform turn-in flaps using native upper lateral cartilage. In this case the portion of the upper lateral cartilage that otherwise would be resected to reduce the height of the cartilaginous dorsum is scored and "turned-in" before reattachment to the dorsal aspect of the septum.
  - This approach can provide a stable reinforcement of the midvault of the nose, without requiring cartilage from elsewhere in the nose or ears.
- Lower third
  - The lower third of the nose is a complex structure that includes the nasal tip and caudal portion of the septum. It is typically seen as a tripod with the paired medial crura as the inferior leg and two superolateral legs consisting of each lateral crura.
  - Any manipulation of the length of any leg of the tripod will have a predictable effect, such as increasing rotation (shortening the lateral crura) or decreasing tip rotation (shortening the medial crura). One must keep in mind that the lower lateral cartilages can have a high degree of asymmetry, irregular curvatures in the areas of the domes, and variable orientation, despite a somewhat symmetric appearing external nose.
  - This is mentioned because manipulations of the lower lateral cartilages can give a wide variety of effects that must be taken with care as to not give an undesirable aesthetic or functional effect, with the most common functional issue being static or dynamic collapse of the external nasal valve due to removal of its support.
  - Manipulation of the nasal tip can disrupt the major and minor tip support mechanisms.
  - Major tip support mechanisms

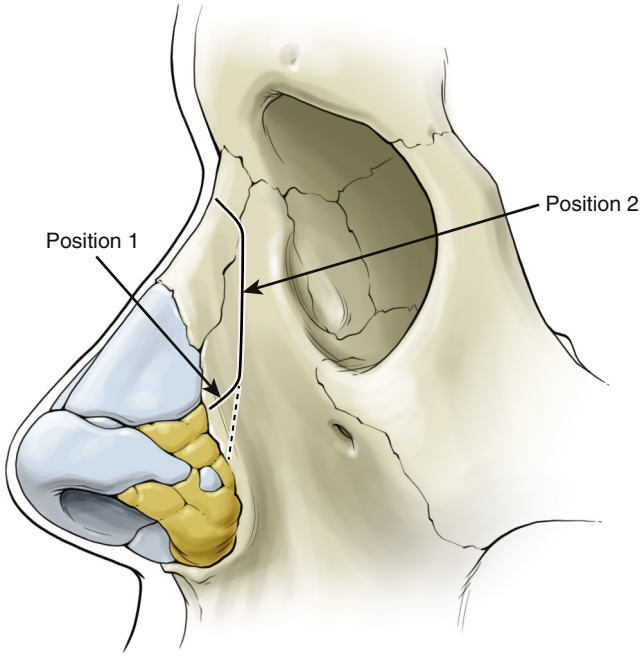

Fig. 155.8. Demonstration of the High-Low-High lateral osteotomy technique. The angle of approach for the first segment of the osteotomy is demonstrated at position 1. The incision is then angled superiorly along the nasofacial junction as noted in position 2. *(Adapted from Larrabee WF Jr. Open rhinoplasty and the upper third of the nose. Facial Plast Surg Clin North Am 1993;1:23–38.)*



Fig. 155.9. Shown are preoperative *(left)* and postoperative *(right)* pictures of the lateral view, **A,** and base view, **B,** of a patient after rhinoplasty consisting of a dorsal reduction and deprojection.

  - Strength of the lower lateral cartilage
  - Attachment of the medial crura to the septum
  - Attachment of the upper lateral cartilage to the lower lateral cartilage
- Minor tip support mechanism
  - Dorsal septum
  - Intermodal ligaments
  - Membranous septum
  - Nasal spine
  - Surrounding skin and soft tissues
  - Alar sidewalls
- A cartilage-sparing set of manipulations to first consider is altering the relative lengths of the lateral crura and medial crura.
- Lateral crural steal is when the lateral crura are recruited into the tip with horizontal mattress sutures, making the medial crura relatively longer and lateral crura relatively shorter, which increases tip projection. Similarly, the medial crura can be recruited to the lateral crura for the opposite effect.
- The manipulations of the nasal tip are numerous due to its anatomic complexity, with some of the more common maneuvers described below.
  - The lateral crura can be trimmed at the cephalic margins to decrease the bulbousness of the nasal tip as shown in Fig. 155.10. In addition to shaping the tip, the cephalic trim maneuver can increase rotation. Calipers are used to measure the amount of native cartilage left to prevent over-resection.

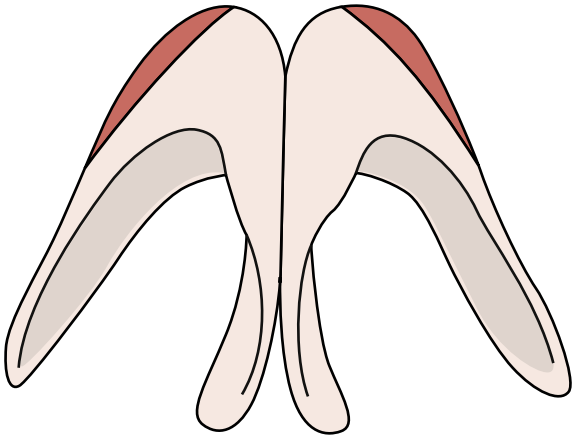

Fig. 155.10. The red areas show the resected portion of the lateral crura in a conservative cephalic trim. This can help refine the appearance of the nasal tip.

  - The tip can also be refined by domal suturing, using horizontal mattress sutures in each dome to change its contour as shown in Fig. 155.11.
  - The domes can also be divided and reapproximated in a configuration that gives the surgeon an intended look, with an example of this illustrated in Fig. 155.12.

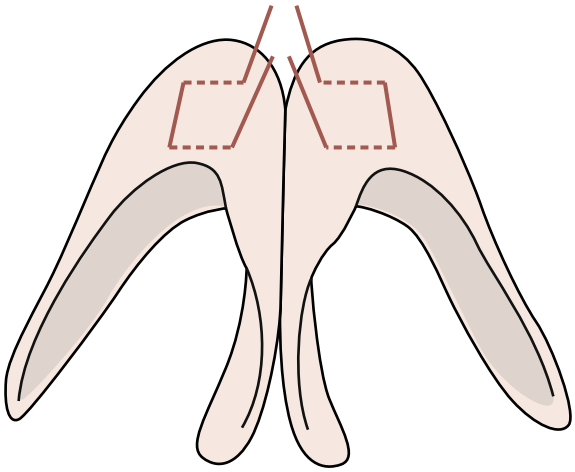

Fig. 155.11. Depicted are horizontal mattress transdomal sutures to narrow the nasal tip.

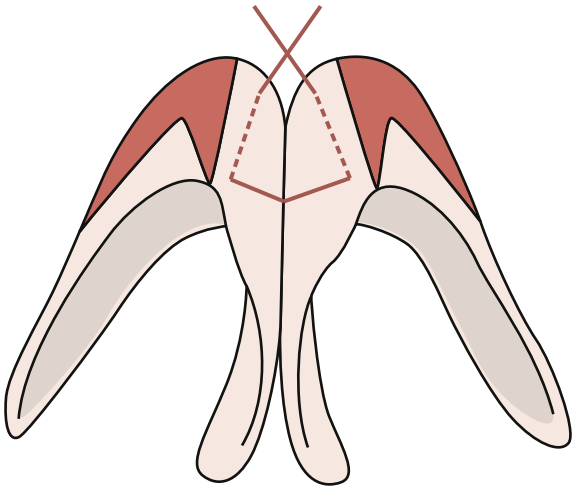

Fig. 155.12. A vertical dome division is carried out with a cephalic trim and reconstructed with interdomal sutures and reapproximating the lateral crura to the tip cartilages. This serves to narrow a "boxy" tip.

- The lateral crura can also be divided overlapped, and sutured in place as a cartilage-sparing maneuver that decreases the length of the lateral crura as depicted in Fig. 155.13.
- A similar overlapping technique can be used with the medial crura. By combining the overlapping technique of the medial and lateral crura, the surgeon can exercise control over both the degree of rotation and projection simultaneously. Care must be taken to not excessively destabilize the tip with more extensive maneuvers.[4]
- The lateral crural strut graft is a technique for reshaping and repositioning the lateral crura. This graft is composed of a strip of autogenous cartilage sutured to the under surface of the lateral crura. Lateral crural struts can be used to improve a boxy nasal tip, malpositioned or excessive cephalic lateral crura, rim retraction, and concave lateral crura.
- If external nasal valve collapse is compromising the patency of the nasal airway, lateral crural strut grafts can be a useful approach to rehabilitate this area.
- Lastly, cartilage grafting can be used between the tip and the soft tissue envelope to sculpt the tip and infratip while helping mask irregularities in the cartilaginous skeleton.

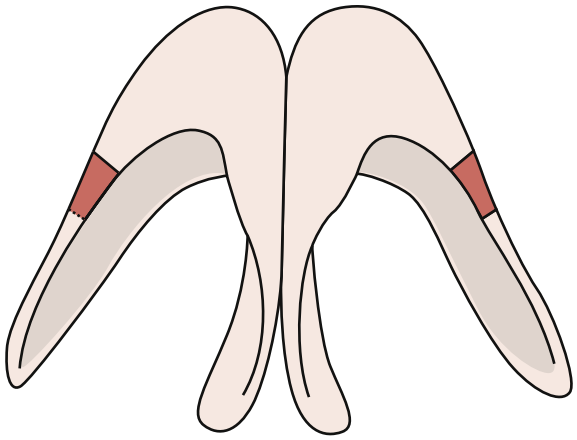

Fig. 155.13. The lateral crural overlay is depicted here with the red areas showing the area of overlap.

- Another powerful tool at the surgeon's hands is septal extension grafting, which is a cartilage graft that overlies the caudal septum and extends between the medial crura.[5]
- By affixing the lower lateral cartilage to the septal extension graft, the surgeon can alter the projection and rotation in virtually any fashion desired.
- This can be done to move a deviated septum toward the midline (placing a left-sided graft on a right-deviated caudal deviation) and serves the purpose of supporting the tip with cartilage.
- Several tip support mechanisms are interrupted during the approach to open rhinoplasty, and the process of scarring is progressive over time, usually leading to de-projection of the nasal tip over time. Septal extension grafting provides a way to secure the medial crura to the septum to support the tip using a septo-columellar suture.
- If the graft does not overlay the septum but is an end-to-end extension of the caudal septum, then it is called a caudal strut graft. These provide less thickness to the septal cartilage in the area of overlap of the septal extension graft with the septum but also lack the stability that this overlap provides.
- Caudal strut grafts are useful in straightening irregularly shaped medial crura.

- Closure
  - Once all of the cosmetic and functional aspects of surgery are completed, the skin envelope needs to be reapproximated to its native position.
  - This is done by first suturing the midline of the transcolumellar incision, followed by the apices of the "gull-wing" incision with 6-0 permanent monofilament suture.
  - After the apices, additional interrupted sutures are used between them, and then 6-0 fast-absorbing plain gut can be used to reapproximate the marginal incisions. Silastic splints can be placed, particularly if there is concern of synchecia formation. The nasopharynx is suctioned, and an orogastric tube is passed to decompress the stomach and esophagus prior to reversal of anesthesia.

Common Errors in Technique

- Inadequate exposure
- Inadequate hemostasis
- Elevating tissues in the wrong plane
- Over-resection of cartilaginous support of dorsum or tip
- Uneven or incomplete osteotomies
- Failure to restore tip support after interrupting it



Fig. 155.14. Inverted V deformity.

POSTOPERATIVE PERIOD

Postoperative Management

- Patients typically have external nasal splints which remain for 1 week postoperatively.
- Silicone nasal splints to support the septum and prevent adhesions between the septum and lateral nasal wall stay in place for 1 week and require the frequent use of saline spray (every 2 to 4 hours) to prevent crusting. This is started the day of surgery and continued while the splints remain in place.
- Pain control with acetaminophen and opioids is usually only necessary for the first few days postoperatively.
- Patients are asked to avoid nose blowing for 2 weeks postoperatively and to use intranasal saline spray instead.
- Splints and tape are removed at the 1-week visit, and a nasal examination is carried out; crusts are removed to improve the nasal airway.
- Postoperative epistaxis can be managed with topical vasoconstrictors (such as oxymetazoline spray) and infrequently requires intervention such as packing or placement of absorbable hemostatic agents.

Complications

- Polybeak deformity—appears as dorsal fullness and can result from over-resection of the nasal bones, under-resection of the cartilaginous septum, or scarring of the supratip region and is treated with steroid injection in the case of scarring or secondary rhinoplasty to address the anatomic cause
- Open roof deformity—manifests as a widened and frequently asymmetric bony nasal dorsum. This complication can be caused by:
  - Greenstick lateral osteotomies, which will frequently return to their preoperative position
  - Failure to appropriately mobilize the nasal bones medially
  - Overly aggressive nasal packing
  - Failure to appropriately correct a deviated perpendicular plate of the ethmoid
- Inverted V deformity—is collapse of the nasal midvault and internal nasal valve, resulting in a cosmetic and functional problem. It is the result of a dorsal resection without providing support to the midvault and is treated with providing this support, often by using spreader grafts to the cartilaginous dorsum (Fig. 155.14).
- Bossae—are the result of irregularities in the tip cartilages, which can be symmetric or asymmetric and visible. These are treated with secondary rhinoplasty to address the specific cause of the bossae.

Alternative Management Plan

- Hyaluronic acid-based injectable fillers are used as a "nonsurgical rhinoplasty" by some practitioners to treat asymmetries and augment the nasal dorsum. This is controversial due to reports of vascular complications (embolization of filler material) but is an increasingly common procedure.

Evidence-Based Medicine Question

Do objective measurements of nasal proportions correlate with facial attractiveness?

There have been many ideals of nasal proportions described. One example is the numerous methods described to assess nasal tip projection. A study of 300 lateral facial views showed no correlation among these measurements (as described by Goode, Simons Baum, Powell, and Crumley) with each other or with facial attractiveness as assessed by 78 viewers. This is just one of many illustrations that should make readers skeptical about relying on any single objective measurement too much without assessing the patient as a whole.

Editorial Comment

There are a variety of methods to measure nasal tip projection. Probably, the most common method is the one developed by Dr. Richard Goode, which measures the patient's tip projection and compares it to the length of the nasal bridge (normal ratio: 0.55 to 0.60). In practice, most experienced rhinoplasty surgeons do not actually measure tip projection but rather use a visual gestalt to determine if a nasal tip is over or under projected.

Frederic W.B. Deleyiannis

Access the review questions and additional source list online at http://www.expertconsult.com

REFERENCES

1. Lee MK, Most SP. Evidence-based medicine: rhinoplasty. Facial Plast Surg Clin N Am 2015;23:303–312.
2. Cannon DE, Rhee JS. Evidence-based practice: functional rhinoplasty. Otolaryngol Clin North Am 2012;45:1033–1034.
3. Ghosh A, Friedman O. Surgical treatment of nasal obstruction in rhinoplasty. Clin Plast Surg 2016;43:29–40.
4. Apaydin F. Projection and deprojection techniques in rhinoplasty. Clin Plast Surg 2016;43:151–168.
5. Kim MH, Choi JH, Kim MS, et al. An introduction to the septal extension graft. Arch Plast Surg 2014;41:29–34.
6. Devcic Z, Rayikanti BA, Hevia JP, et al. Nasal tip projection and facial attractiveness. Laryngoscope 2011;121:1388–1394.

REVIEW QUESTIONS

1. Which of the following structures does NOT contribute to the internal nasal valve?
   a. Septum
   b. Lower lateral cartilage
   c. Upper lateral cartilage
   d. Inferior turbinate

2. Lateral crural steal (recruitment of lateral crural cartilage to the midline) would have which effect on tip rotation and nasal projection?
   a. Increase rotation, increase projection
   b. Increase rotation, decrease projection
   c. Decrease rotation, increase projection
   d. Decrease rotation, decrease projection

3. Indications for an open approach to the septum, rather than an approach via a hemitransfixion incision, do not include
   a. Caudal septal deviation
   b. A preoperative plan that might require an extra-corporal septoplasty
   c. Very severe septal deviation
   d. Deviation of the bony nasal septum

ADDITIONAL SOURCE

Papel ID, Frodel JL, Holt GR, et al. Functional and aesthetic surgery of the nose in facial plastic and reconstructive surgery. 3rd ed. New York: Thieme; 2009.

156 Blepharoplasty

Grant S. Gillman

INTRODUCTION

As our population continues to grow older, society's emphasis on a more youthful appearance continues to increase and has led to rising interest in reversing the visible signs of aging. The periorbital region is one of the first areas of the face to show signs of aging. Correction of this imperfection can significantly "turn back the clock" of aging and has thus led to the popularity of aesthetic surgery on the eyelids. Owing to the critical role that the upper and lower eyelids serve in protecting the globe, the surgeon must be very attentive to the delicate balance between form and function when performing blepharoplasty. To that end, the surgeon must be intimately familiar with the anatomy of the upper and lower eyelids and periorbital area[1,2] to make the best preoperative decisions in order to facilitate well-executed surgery.

KEY OPERATIVE LEARNING POINTS

1. Be conservative with eyelid surgery. One can always do more, but complications resulting from overaggressive eyelid surgery can be very difficult to correct.
2. For upper eyelid surgery, preoperative skin markings should be checked and rechecked to avoid excessive excision of skin.
3. Opening the orbital septum low toward the tarsal plate in the upper eyelid increases the risk of injury to the levator aponeurosis and iatrogenic ptosis.
4. Patients with a very prominent, protrusive globe ("pseudoproptosis") in which the corneal plane lies anterior to the inferior orbital rim on lateral view—the so-called negative vector—are at high risk for postoperative eyelid malposition with lower lid transcutaneous approaches.
5. Absolute hemostasis is necessary to minimize the possibility of postoperative retrobulbar hematoma.
6. Overaggressive removal of skin or adipose tissue from the upper or lower eyelids can create a hollowed, gaunt appearance, in addition to functional complications such as lagophthalmos and eyelid malposition.

PREOPERATIVE PERIOD

History

1. History of present illness
   a. Prior periorbital surgery, previous blepharoplasty, visual difficulties, glaucoma, or dry eye symptoms. Concerns regarding other ophthalmic conditions (e.g., dry eyes, glaucoma, ptosis) merit preoperative evaluation by an ophthalmologist.
2. Past medical history
   a. Prior periorbital surgery: Cosmetic (blepharoplasty and/or brow lift) or reconstructive (skin cancer)
   b. Medical illness: Hypertension, diabetes, thyroid disease, facial muscle weakness, cardiovascular disorders
   c. Medications:
      1) Antiplatelet drugs
      2) Herbal products
      3) Alcohol

Physical Examination

1. General
   a. Visual acuity (eye chart)
   b. Size, shape, configuration, and symmetry of the bony orbit and palpebral aperture. Patients should be made aware of asymmetries preoperatively.
2. Upper eyelid
   a. Brow position: Determine the extent to which brow ptosis might be contributing to the apparent upper eyelid skin excess. In men, a youthful brow position rests at the level of the superior orbital rim; in women, ideal brow position is about 1 cm above the orbital rim. Significant brow ptosis should prompt a conversation with the patient about the merits of a brow-lift or combination brow-lift and blepharoplasty.
   b. Eye closure: Pre-existing lagophthalmos is an absolute contraindication to upper eyelid blepharoplasty. Lagophthalmos will be exacerbated if upper lid surgery is performed.
   c. Eyelid ptosis: Blepharoplasty alone will not correct eyelid ptosis and can make it more apparent. Depending on the experience of the surgeon, ptosis repair might require the expertise of an oculoplastic surgeon.
   d. Position and symmetry of the upper lid folds and supratarsal creases
   e. Record the degree of excess skin in each eyelid and adipose tissue in each adipose tissue compartment (medial and central compartments).
3. Lower eyelid
   a. The presence of scleral show, and the position of the globe in the orbit. Asymmetries should be pointed out to the patient preoperatively.
   b. Lower eyelid tone: If lid tone is poor, there is increased risk of lower lid malposition postoperatively. Consider alternative techniques to standard skin-muscle lower lid blepharoplasty or a concomitant canthoplasty or canthopexy.
      1) "Snap test" (the lid distraction test): The lower lid is drawn anteriorly outward from the globe with the thumb and forefinger. More than 10 mm movement of the lid margin is considered abnormally lax. In addition, note how long it takes for the lower lid to return to its pretest position. A normal, youthful lid will snap back immediately.
      2) "Lid retraction test": The lower lid is drawn inferiorly toward the orbital rim, and once again one observes for abnormally slow return of the lid to its normal position.
   c. Record the degree of excess skin in each eyelid and adipose tissue in each adipose tissue compartment (medial, central, and lateral compartments). Excess adipose tissue in the lower lid compartments is accentuated by upward gaze. Applying pressure to the patient's globe with the eyelids closed helps delineate the location of excess adipose tissue in both upper and lower eyelid compartments. Orbicularis oculi muscle hypertrophy is also recorded.

4. Preoperative photographs
   a. Full facial view and close-up frontal (eyes open, closed, and gazing upward), oblique, and lateral views of the eyes

Imaging

None

Indications

1. Upper eyelid blepharoplasty
   a. Dermatochalasis (upper eyelids): Cosmetic or functional (visual field restriction), depending on the degree of skin excess and hooding of the upper eyelids. A functional upper eyelid blepharoplasty will require documentation with automated visual field testing.
2. Lower eyelid blepharoplasty
   a. Pseudoherniation of adipose tissue ("bags"), with or without a vertical excess of skin

Contraindications

1. Medical comorbidities with increased risk for general anesthesia
2. Pre-existing ophthalmologic concerns: Severe dry eyes; pre-existing lagophthalmos or minimal tissue excess (risk of hollow-looking orbit postoperatively) in particular should be considered as contraindications to eyelid surgery.
3. Unrealistic expectations or difficult patient

Preoperative Preparation

1. Discontinue all potential anticoagulant/blood-thinning medications.
2. Ophthalmologic evaluation/clearance when indicated by any concerns in ophthalmologic history

OPERATIVE PERIOD

Anesthesia

Local anesthesia supplemented by intravenous sedation is generally adequate for aesthetic surgical procedures on the eyelids. Patients needing resection of skin only of the upper eyelids may tolerate local anesthesia alone. Occasionally the patient or anesthesiologist may feel more comfortable with general anesthesia, particularly if eyelid surgery is combined with other procedures. Patient comfort is a requisite for maximal surgical safety.

Positioning

Supine

Perioperative Antibiotic Prophylaxis

First-generation cephalosporin intravenously given before the skin incision
Clindamycin or gentamicin if allergic to penicillin

Monitoring

None

Instruments and Equipment to Have Available

1. Basic plastics/oculoplastics set

Key Anatomic Landmarks

1. Upper border of the tarsal plate in the upper eyelid lies level with the tarsal crease. Incisions or dissection should not be below this level.
2. The levator aponeurosis fuses with the orbital septum and attaches to the upper tarsal plate. For removal of adipose tissue in the upper eyelid, opening the orbital septum 5 mm or more above the tarsal plate minimizes the risk of iatrogenic ptosis.
3. The medial adipose tissue pad in both the upper and lower eyelids is distinguished from central or lateral adipose tissue pads by a paler, whiter color.
4. The inferior oblique muscle sits between the medial and central adipose tissue pads of the lower eyelid.

Prerequisite Skills

1. Familiarity with the surgical anatomy
2. Experience with oculoplastic surgery

Operative Risks

1. Upper eyelid blepharoplasty
   a. Excess skin excision: Avoidable with assiduous preoperative skin markings and measured excision (see operative technique)
   b. Retrobulbar hemorrhage: Patiently cauterizing (bipolar) or clamping and cauterizing the pedicle of the adipose tissue pad being removed will minimize the risk or traction or avulsion of orbital vessels.
2. Lower eyelid blepharoplasty
   a. Retrobulbar hemorrhage (discussed previously)
   b. Inferior oblique injury with secondary diplopia: A heightened awareness of the muscle position between the medial and central adipose tissue pads of the lower eyelid is necessary to identify and avoid inadvertent muscle trauma.
   c. Lower eyelid malposition (scleral show, ectropion)

Surgical Technique: Upper Eyelid Blepharoplasty[3,4]

1. Skin markings: Incisions are marked preoperatively with the patient sitting upright and the brow held in proper position. The curvilinear inferior incision is marked along the patient's natural upper eyelid crease, which lies at the upper edge of the tarsal plate. This is typically 8 to 12 mm above the lash line in the midpupillary line and 5 to 6 mm above the medial and lateral canthi. If the crease is less than 8 mm from the lash line centrally, measure the marking centrally to lie 8 to 10 mm above the lashes. At the lateral canthus, the marking sweeps laterally and upward toward the tail of the brow, as much as needed to excise the skin that accounts for any lateral hooding. The incision rarely needs to extend beyond the lateral orbital rim. Medially, the incision marking should not extend more than 1 to 2 mm beyond the punctum of the eyelid. Extending the incision into the concavity at the medial orbit risks creating a webbed scar across this area. To mark the upper incision, hold the patient's brow in its correct anatomic position when determining the amount of skin to be resected. A "skin pinch" technique is used to determine the amount of excess skin. Centrally the excess skin is gently grasped with fine forceps and lifted until slight eversion of the lashes occurs. The upper incision is marked at the point where the lower incision meets the upper limit of the excess skin. This is done in at least four positions across the upper eyelid. The marks are then connected to outline the upper inci-

sion line (Fig. 156.1). Test the planned excision at multiple levels by pinching the upper and lower incision markings together (before injecting the local anesthetic) and checking to avoid excess eversion of the lid margin and risk of lagopthalmos postoperatively. Conservatism is always recommended.

2. Infiltrate the local anesthetic: Inject with a 30-gauge, 1.5-inch needle between skin and the underlying orbicularis oculi (1 to 1.5 mL per eyelid).
3. Skin excision: The skin is incised (15 blade) along the markings and excised with a 15-blade scalpel, a needle-tip cautery, or sharp scissors. Hemostasis is obtained with a needle-tip electrocautery (Fig. 156.2).
4. To accentuate the supratarsal crease, excise a 3-mm strip of orbicularis muscle using fine forceps and curved scissors in the midportion of the wound.
5. Removal of orbital adipose tissue (if indicated): With finger pressure on the globe, the bulging excess adipose tissue in the orbital compartments is seen through the orbital septum. A small opening is made in the orbital septum over the adipose tissue compartment to be addressed. Excess adipose tissue is teased through the opening in the septum with fine forceps and a cotton swab (Fig. 156.3). Only adipose tissue that is easily delivered through the orbital septum is resected. A small amount of local anesthetic is injected into the base of the adipose tissue pedicle for hemostasis and comfort. A small hemostat is then placed across the base of the adipose tissue pedicle. Small scissors are used to excise the adipose tissue, leaving a small cuff above the hemostat to be cauterized before releasing the hemostat. Alternatively, one can slowly cauterize across the base of the adipose tissue (bipolar cautery) without clamping the pedicle, thereby minimizing the risk of excess traction on the posterior orbital vessels from manipulating a hemostat.
6. Skin closure: Simple interrupted sutures can be placed in the incision lateral to the lateral canthus to reduce tension along the closure line. The remainder of the incision is closed with running a 6-0 monofilament subcuticular suture (Fig. 156.4), a running locking suture, or simple interrupted sutures (surgeon preference). Mastisol and small Steri-Strips are used to anchor the medial and lateral ends of the suture.

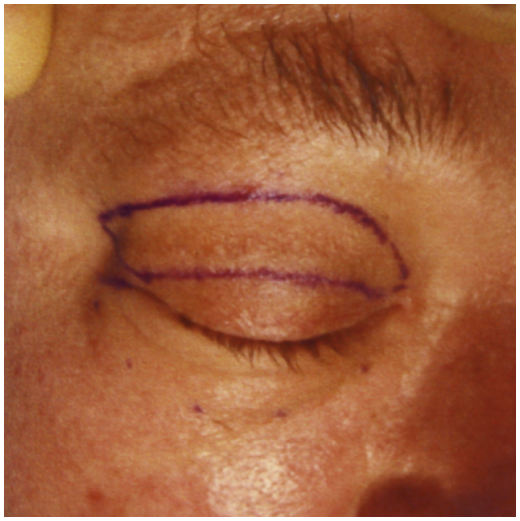

Fig. 156.1. Outline of an upper eyelid blepharoplasty incision.

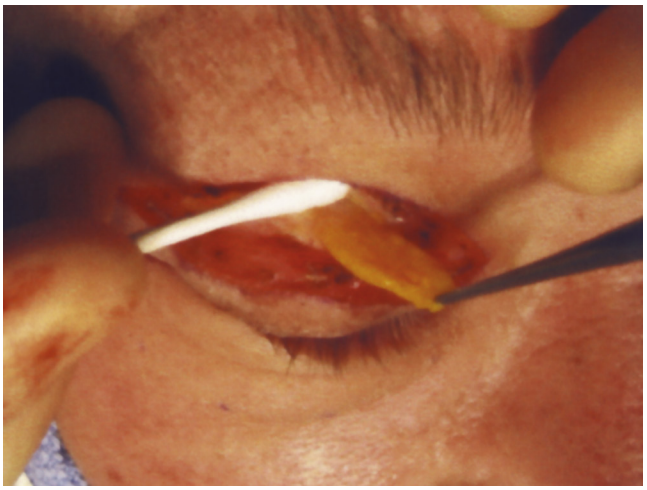

Fig. 156.3. Orbital adipose tissue is teased through the opening made in the orbital septum (upper eyelid lateral compartment).

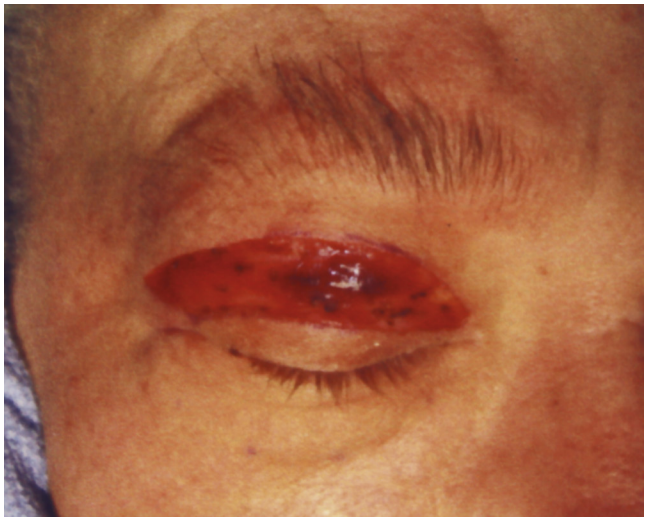

Fig. 156.2. Hemostasis achieved after skin excision. Orbicularis oculi visible within the wound.

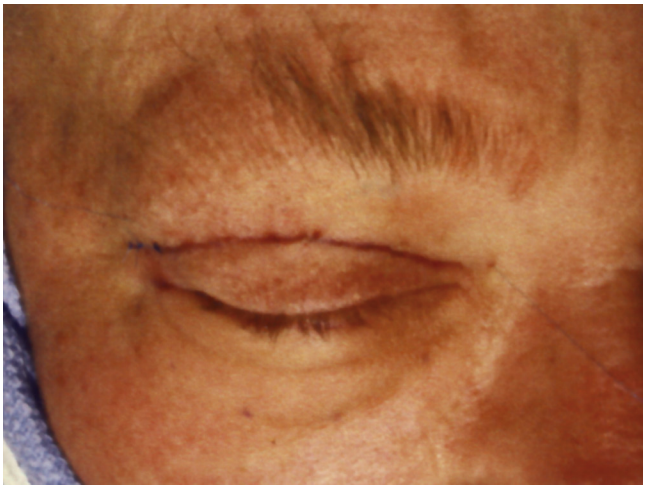

Fig. 156.4. Interrupted stitches approximate the wound edge lateral to the lateral canthus. Closure of the remaining incision with a subcuticular stitch.

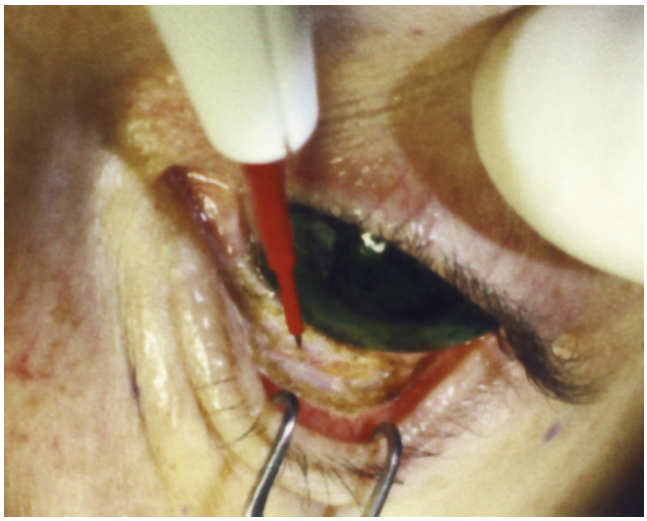

Fig. 156.5. Lower eyelid everted with a blunt double hook to expose the conjunctiva (right eye). Conjunctival incision (with needle-tip electrocautery) just below the inferior edge of the tarsal plate (left eye). Note the corneal protector in place.

Surgical Technique: Lower Eyelid Transconjunctival (Preseptal) Blepharoplasty

In patients with a minimal excess of skin, a transconjunctival approach[5] to the lower lids is preferred. As compared to a transcutaneous approach, the transconjunctival approach minimizes the risk of developing lower eyelid retraction (scleral show or frank ectropion) in patients with poor lid tone. In patients with significant excess skin of the lower lid or those who already have lower lid laxity for which correction (canthoplasty, canthopexy) is planned, a transcutaneous (subciliary) approach[6] is used with elevation of a skin-muscle flap.

1. Infiltration of local anesthesia: Once the patient is sedated, the conjunctivae are topically anesthetized with 0.5% ophthalmic tetracaine or proparacaine hydrochloride solution, and corneal shields lubricated with ophthalmic ointment are used for corneal protection. Lidocaine (1%) with 1:100,000 epinephrine is injected with a 27- or 30-gauge needle in the conjunctiva along the planned incision and percutaneously deep to the orbicularis of the lower lid to anesthetize and hydrodissect the plane of dissection.
2. Conjunctival incision: Retract the lower lid margin with a wide double prong hook. A conjunctival incision is made with a needle-tipped cautery 1 to 2 mm below the tarsal plate (Fig. 156.5) and deepened to divide the attachment of the lower lid retractors to the inferior tarsus. Medially, the incision stops short of the punctum of the lacrimal duct to avoid injury to the lacrimal canaliculi, and laterally the incision is carried as far as necessary to provide adequate exposure of the adipose tissue compartments.
3. Traction suture: A 5-0 silk or nylon bridle suture is placed through the inferior conjunctival incision margin, with a hemostat on the free ends of the suture. The hemostat is passed over the patient's forehead, retracting the conjunctiva and inferior retractors up over the cornea. This provides countertraction for the dissection and protects the underlying cornea.
4. Preseptal dissection: An assistant retracts the eyelid margin with a wide double hook or a Desmarres retractor. Preseptal dissection (Fig. 156.6)—between the overlying skin and muscle and the underlying orbital septum—is carried down to the orbital rim with a combination of sharp and blunt dissection. The orbicularis is separated from the septum by pushing the muscle anteriorly and inferiorly with a cotton swab. Orbital adipose tissue is seen behind the orbital septum (Fig. 156.7).
5. Incise orbital septum: Pressure on the globe will cause the orbital adipose tissue to bulge forward; a small opening is made in the septum overlying the adipose tissue compartments to be addressed. The adipose tissue from each compartment is addressed separately. Adipose tissue is teased from the surrounding fascia and attachments with fine forceps in one hand and a cotton-tipped swab in the other (Fig. 156.8). Only adipose tissue that can be easily delivered without excess traction should be removed. A small amount of local anesthetic should be injected into the base of the adipose tissue pedicle before excision.
6. Adipose tissue removal: A fine hemostat is placed across the base of the mobilized adipose tissue. Fine scissors are used for sharp resection, leaving a small cuff of adipose tissue above the hemostat, which is then cauterized. Alternatively, one can use bipolar cautery slowly and incrementally across the base of the adipose tissue (without a hemostat) and fine scissors to incise the cauterized stump and excise the adipose tissue. Only adipose tissue that extends above the plane of the inferior orbital rim without traction is excised. Staying at this level minimizes the risk of injuring the inferior oblique muscle, which lies between the medial and central adipose tissue compartments. Each adipose tissue compartment is addressed individually. The medial adipose tissue pad is distinguished from central or lateral adipose tissue by its paler color. Once adequate resection has been performed, replace the lower lid in its anatomic position. Examine the lower lid with and without pressure on the globe. Re-explore any area that looks prominent, and be attentive to bilateral symmetry. With the patient in the supine position, a slight concavity of the overall contour of the lid will generally ensure a good result.
7. Closure: It is not necessary to close the conjunctival incision. It will heal uneventfully, even if left unsutured. Alternatively, a single fast-absorbing 6-0 catgut suture (with an inverted buried knot) can be placed to align the conjunctival wound, positioning it lateral or medial to the corneal limbus (corneal-scleral junction) to avoid corneal irritation from the suture. A small amount of excess skin can be removed by subciliary "pinch" excision at the same time if only a minor amount of skin resection is needed.

Preoperative and postoperative photos of a lower eyelid transconjunctival blepharoplasty patient are seen in Fig. 156.9.

Surgical Technique: Lower Eyelid Transcutaneous (Skin-Muscle Flap) Blepharoplasty

Transcutaneous lower lid blepharoplasty is reserved for patients with excess skin or hypertrophy of the orbicularis muscle as well as those with lower lid laxity that would benefit from a planned suspension procedure. In patients with a significant disparity in the amount of excess skin and muscle, separate skin and muscle flaps are raised to the level of the infraorbital rims, and the appropriate excesses are dealt with individually. This is much less commonly done and likely accounts for no more than 1% to 2% of all blepharoplasty procedures. All other transcutaneous blepharoplasty patients are treated with the standard skin-muscle flap technique described herein.

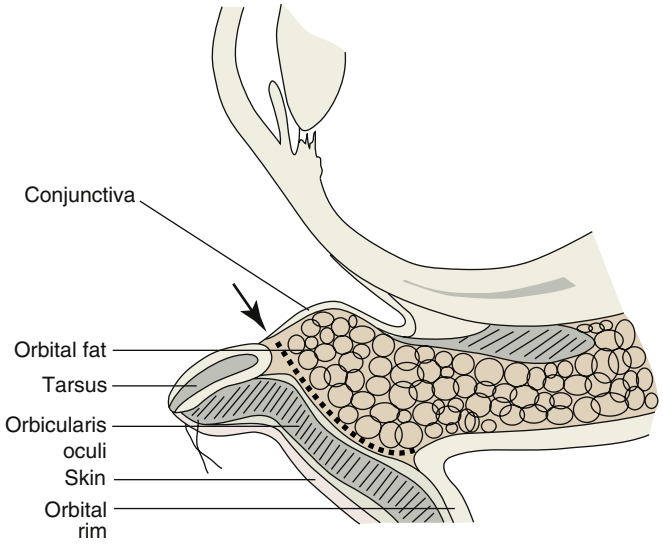

Fig. 156.6. Sagittal schematic view of the plane of dissection for preseptal transconjunctival blepharoplasty. The *arrow* indicates the level of the conjunctival incision, just below the inferior edge of the tarsal plate. The dissection then proceeds *(dashed line)* toward the inferior orbital rim in the plane between the orbicularis oculi and the orbital septum overlying the orbital adipose tissue compartments.

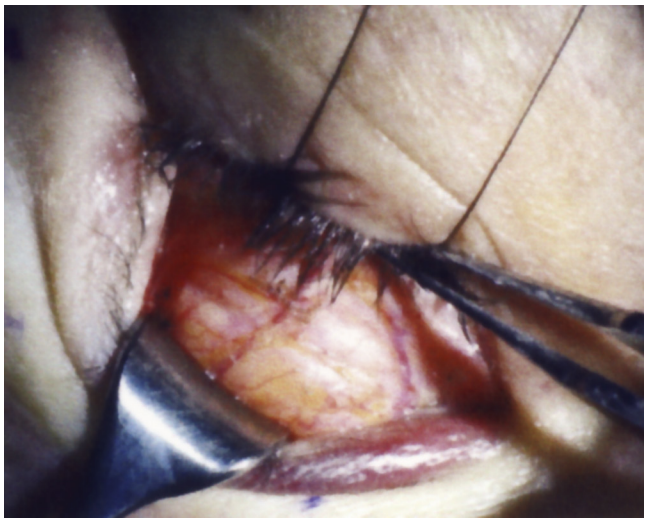

Fig. 156.7. After preseptal dissection in the plane between the orbicularis oculi and the orbital septum, a Desmarres retractor placed deep to the muscle exposes the orbital septum, through which one can see the underlying orbital adipose tissue compartments (right eye). A bridle suture is in place to retract the conjunctiva superiorly for corneal protection.

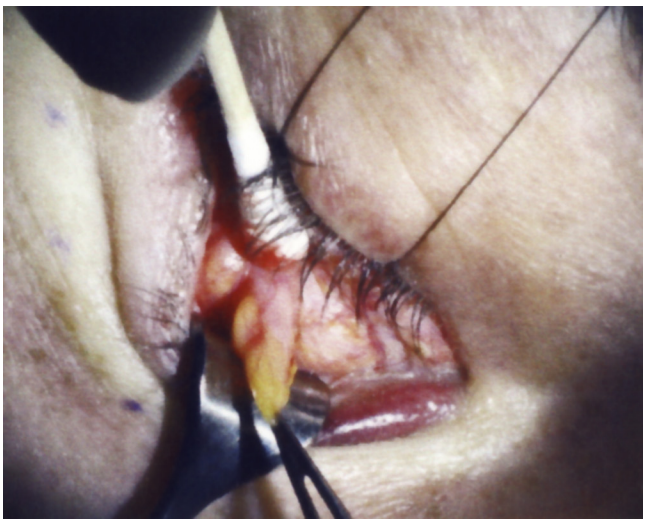

Fig. 156.8. Central compartment adipose tissue being teased though an opening in the orbital septum with the aid of a cotton-tipped applicator (right eye).

1. Incision marking: The lower eyelid incision is marked parallel and 1.5 to 2 mm below the lash line (Fig. 156.10). Adequate access can often be achieved with an incision extending medially only as far as the medial limbus of the cornea, lengthening the incision further if need be. Beyond the lateral canthus, the incision angles slightly downward and lateral, extending 5 to 7 mm parallel to or in a lateral periorbital skin crease (crow's foot). This extension should be only as long as needed to remove the redundant skin. The vertical separation between the lateral extents of the upper and lower eyelid incisions should be at least 5 to 7 mm.
2. Local anesthesia: Lidocaine (1%) with 1:100,000 epinephrine is injected along the incision and deep to the preseptal orbicularis oculi, with a 27-gauge, 1.5-inch needle. The eyes are lubricated with ophthalmic ointment.
3. Skin incision, submuscular dissection: A 15 blade is used to incise the skin of the small extension beyond the lateral canthus or along the entire subciliary incision, through skin only. The incision lateral to the canthus is then deepened to a submuscular (preseptal) plane. Through it, using fine scissors with a blunt spreading motion, one can blindly predissect deep to the muscle inferiorly and medially down to the orbital rim to separate the muscle from the septum deep to it (Fig. 156.11). Small, sharp curved scissors are then tunneled medially under skin in the pretarsal area, superficial to the orbicularis oculi, and the subciliary incision is completed through skin only. To this point, the dissection has involved skin only in the pretarsal area, superficial to the pretarsal orbicularis muscle. The dissection in the preseptal area has been deep to the orbicularis.
4. Connect the pretarsal and preseptal dissections: The planes of the skin-only elevation (pretarsal) and the skin-muscle flap dissection (preseptal) are connected by incising the muscle below the tarsus, approximately 3

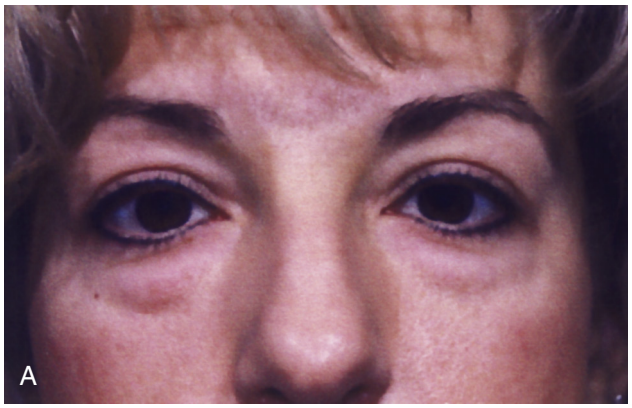

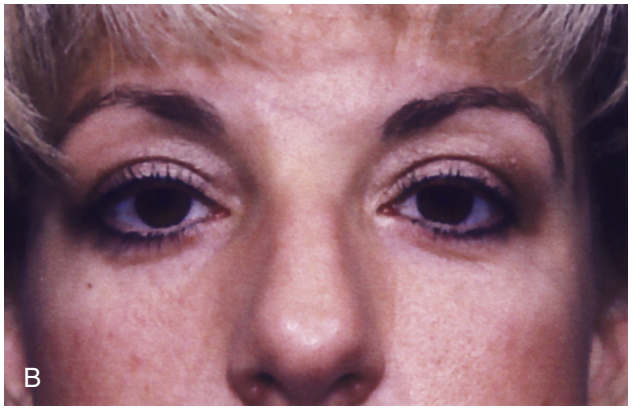

Fig. 156.9. Preoperative, **A,** and postoperative, **B,** views of a lower eyelid transconjunctival blepharoplasty patient.

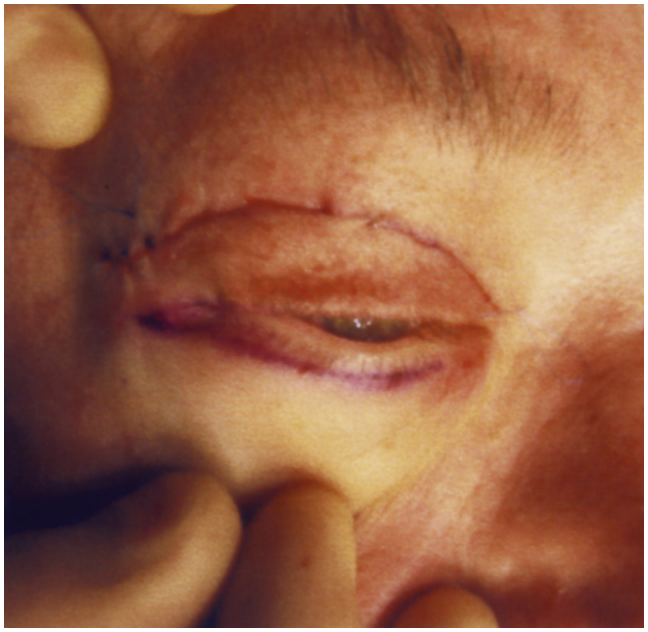

Fig. 156.10. The subciliary incision is marked approximately 2 mm below the lash margin and extends 5 to 7 mm beyond the lateral canthus.

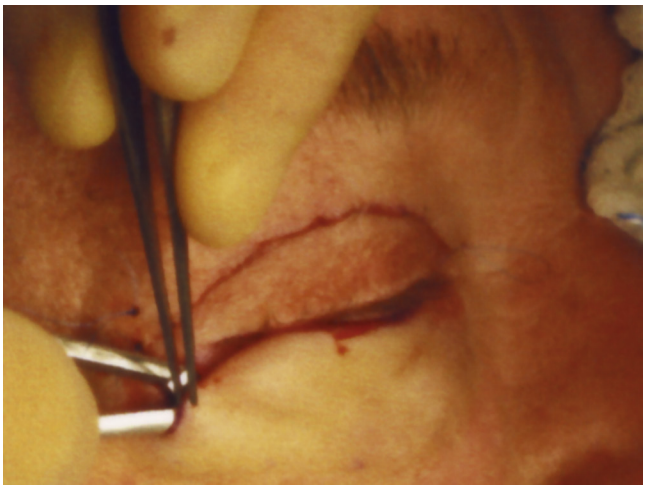

Fig. 156.11. The initial blind submuscular dissection should proceed easily without encountering any resistance through the relatively avascular plane between the orbicularis oculi and the orbital septum deep to it. The dissection is carried toward the inferior orbital rim.

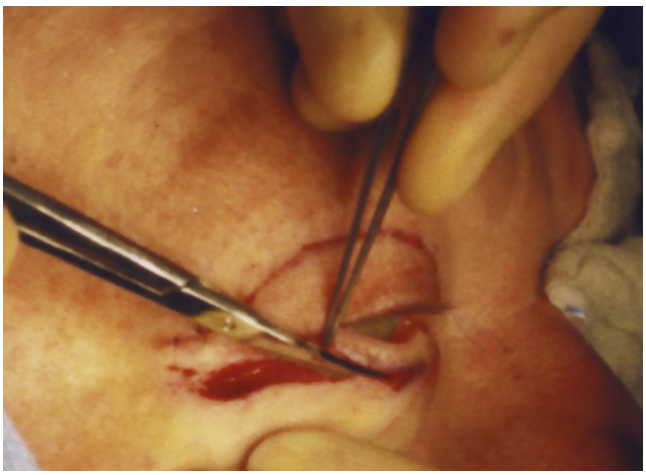

Fig. 156.12. The muscle is incised below the level of the subciliary incision with a "blade-in, blade-out" maneuver to connect the skin-only pretarsal dissection with the submuscular elevation below the tarsus.

to 5 mm from the lash line (Fig. 156.12). Leaving the pretarsal orbicularis muscle intact to act as a hammock helps support the lower lid, decreasing the likelihood of lid malposition.

5. Complete elevation of the skin-muscle flap: A bridle suture is placed through the superior incision margin or the gray line to retract the conjunctiva cephalically for corneal protection. The skin-muscle flap is retracted by an assistant with a wide blunt double-ball hook. The skin-muscle flap is elevated down to the level of the infraorbital rim, exposing the entire orbital septum (Fig. 156.13).
6. Adipose tissue removal: Small openings are made through the orbital septum to facilitate dissection of adipose tissue from each compartment (central, medial, and lateral) as needed. Adipose tissue removal proceeds as previously described for the preseptal transconjunctival approach.
7. Skin trim: The skin-muscle flap is redraped over the lower lid lashes in an upward and slightly lateral direction. An incision is made into the skin-muscle flap at the level of the lateral canthus to the point at which the overlapping skin



Fig. 156.13. A bridle suture retracts the tarsus and conjunctiva superiorly for corneal protection. The skin-muscle flap is elevated and retracted toward the inferior orbital rim to expose the orbital septum and the underlying orbital adipose tissue compartments.

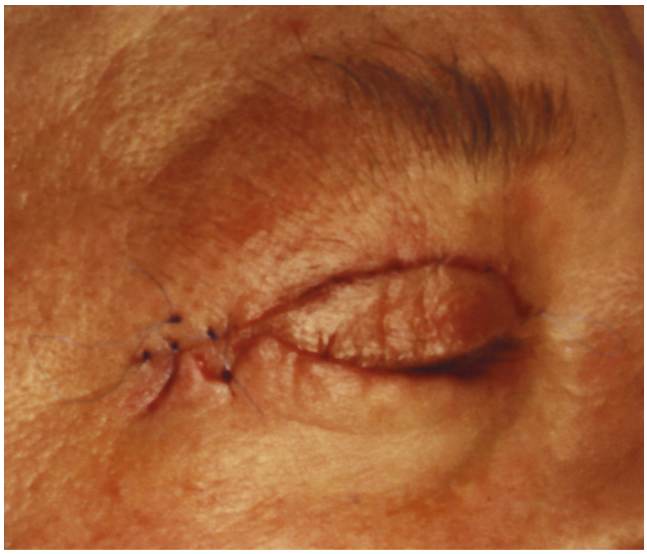

Fig. 156.14. The skin-muscle flap is redraped over the infraciliary incision. An incision is then made into the flap at the lateral canthus as far as the edge of the overlapped infraciliary incision. That point is secured with 6-0 Prolene suture, thereby effectively dividing the skin excess into two separate triangles—one medial and one lateral to the canthus.

meets the cut edge of the infraciliary margin. That point is sutured with 6-0 Prolene, and the excess skin is effectively divided into two triangles of excess skin—one medial and one lateral to the suture (Fig. 156.14). The extra skin is then judiciously excised—first the lateral triangle and then the medial triangle (Fig. 156.15), to allow for a tension-free skin closure. A conservative skin excision minimizes the risk of lid malposition. A thin strip of orbicularis is then excised from beneath the upper margin of the skin-muscle flap. Failure to do so would result in overlapping of this muscle over the pretarsal orbicularis that was not elevated.

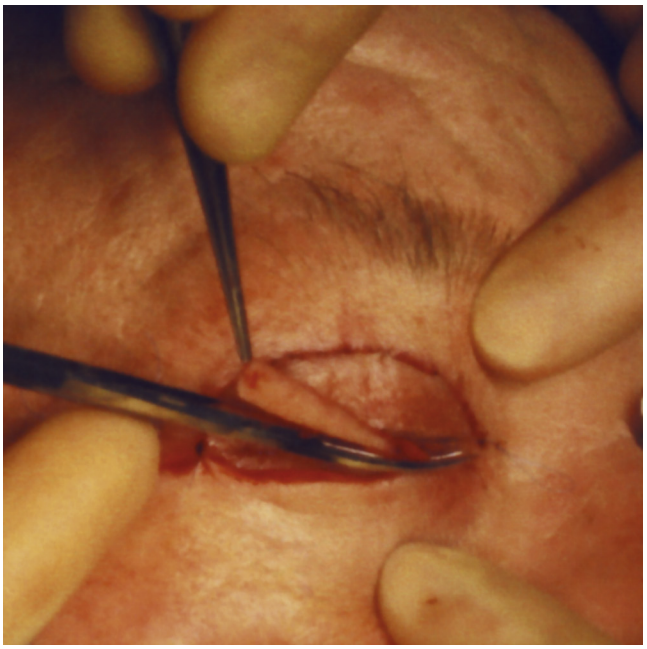

Fig. 156.15. Excision of the excess triangular skin medially. In a similar fashion, the excess skin is trimmed lateral to the suture (lateral to the lateral canthus).

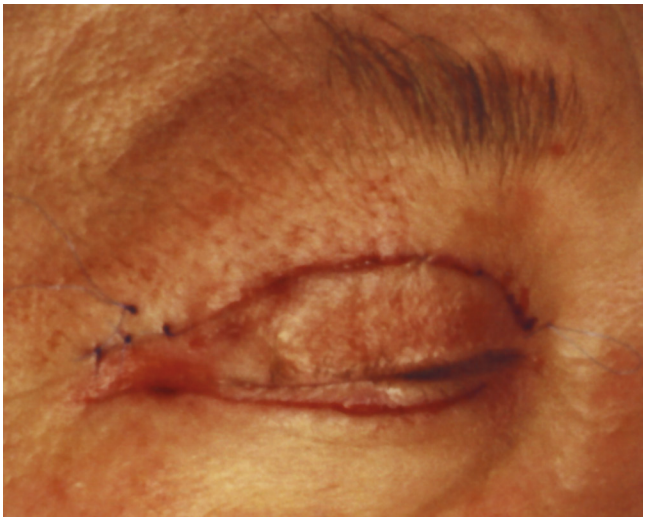

Fig. 156.16. Skin-muscle flap blepharoplasty, just before skin closure with easy tension-free approximation of skin edges.

8. Flap suspension, skin closure: Once hemostasis is verified, a flap suspension suture of 5-0 polyglactin is placed to support the lower lid through the healing period.[5] The orbicularis muscle under the skin-muscle flap is grasped medial to and below the lateral orbital tubercle (Whitnall's tubercle) and suspended with a buried inverted suture to the periosteum at the lateral orbital tubercle. It is important to get a good bite of periosteum and sufficient purchase on the muscle *without* dimpling the overlying skin. The skin edges should now lie gently approximated (Fig. 156.16) for easy tension-free closure. The incision is closed with interrupted 7-0 Prolene suture lateral to the canthal angle and interrupted or running 6-0 fast-absorbing gut suture along the subciliary portion.

Preoperative and 4-month postoperative photos of a patient who underwent both an upper eyelid as well as a lower eyelid skin-muscle flap blepharoplasty are seen in Fig. 156.17.

Common Errors in Technique

1. Asymmetric scar placement: This is easily avoidable with attention to preoperative markings.
2. Inadequate skin excision (upper eyelids): This is avoidable with attention to the preoperative markings. Conservative skin excision is always warranted to prevent lagophthalmos, but using a pinch technique as described will allow for an appropriate skin excision.
3. Failure to support lower eyelid with skin muscle flap lower blepharoplasty: Placement of the suspension suture as described is valuable for prevention of scleral show/lateral rounding of the lower lid.

POSTOPERATIVE PERIOD

Postoperative Management

1. Ice packs/cool compresses
2. Lubrication (if needed—artificial tears for daytime dryness; Lacri-Lube ointment for nighttime protection)
3. Wound care: The incision is gently cleaned with a cotton swab soaked in hydrogen peroxide 3 to 4 times daily, and ophthalmic antibiotic ointment is then applied.
4. If a transconjunctival approach is used for the lower lids, an ophthalmic antibiotic drop with steroid is used for the first 5 days postoperatively. Contact lenses should be avoided for at least 1 week after surgery.
5. Nondissolving sutures are removed at 5 to 7 days.

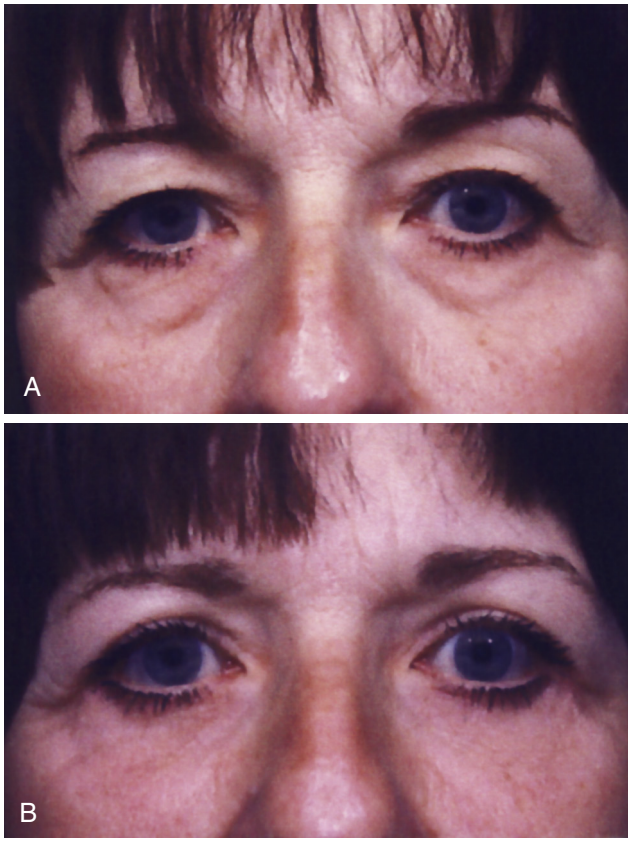

Fig. 156.17. Preoperative, **A,** and postoperative, **B,** views of a patient who had an upper eyelid blepharoplasty and a lower eyelid skin-muscle flap blepharoplasty.

Complications[7]

1. Corneal injury: Prevention involves corneal lubrication to prevent desiccation during surgery. Protective corneal shields can be placed during blepharoplasty. The surgeon should be cautious when using gauze near the cornea. Eye pain, tearing, and scleral injection suggest a corneal injury. This should prompt an evaluation by an ophthalmologist. Fluorescein staining can be used for diagnosis, and treatment includes ophthalmic antibiotic ointment and an occlusive dressing until healing is complete.
2. Wound separation: Infrequently the lateral aspect of the wound might separate slightly when sutures are removed. This is treated with Steri-Strips or the wound should be resutured if necessary.
3. Asymmetries: Postoperative asymmetries may reflect unrecognized preoperative asymmetries of excess lid skin or asymmetric preoperative brow position. Noting such asymmetries *preoperatively* and discussing them with the patient increases acceptance of minor postoperative asymmetries. If a brow procedure is not indicated or desired, asymmetric skin excision may be necessary to address differences between the two sides. Asymmetry in adipose tissue excision can also be apparent postoperatively. Attention to detail intraoperatively minimizes the risk of such problems. Asymmetry persisting several months postoperatively may require revision surgery.
4. Dry eyes: Postoperative edema is the most common cause and should settle over 1 to 3 weeks. The interim use of artificial tears and lubricating ointment helps prevent keratitis. Other causes of dry eyes include an unrecognized preoperative condition, injury to the lacrimal gland (uncommon), and excess skin resection. Excess skin resection will require repair with a full-thickness skin graft replacement.
5. Epiphora: Excess tearing is common during the first 48 hours postoperatively. It typically results from edema or temporary muscular atony, which impairs the function of the lacrimal drainage system and generally resolves as the swelling subsides. Other possible causes include eversion of the punctum (secondary to either edema or ectropion, discussed later) or, uncommonly, injury to the canaliculus.
6. Lagophthalmos: Most commonly, lagophthalmos is due to immediate postoperative edema. It is treated with lubricating ointments and time. Lagophthalmos due to overresection of upper lid skin can lead to desiccation and corneal injury. In such cases, release of the upper lid along with skin grafting must be considered. Prevention requires carefully measuring the amount of skin to be resected (via the aforementioned pinch technique) several times before any skin resection.
7. Ptosis: Temporary "pseudo-ptosis" secondary to swelling is not uncommon in the first postoperative week. Persistent ptosis suggests injury to the levator expansion when opening the orbital septum. The levator apparatus is at risk in the inferior portion of the wound close to the upper border of the tarsal plate, where the levator fuses with the orbital septum. Excising muscle or opening of the septum is safest if one stays away from the lower portion of the wound after excision of skin. Persistent ptosis should be corrected by reinsertion of the levator into the tarsus or dermis.

8. Extraocular muscle injury: The inferior oblique muscle lies between the medial and central adipose tissue compartments of the lower lid. It should be looked for in every case, although it is not always seen and injury is uncommon. Care must be taken to avoid clamp, cautery, or sharp injury to this vulnerable muscle during removal of adipose tissue. If immediately identified, the transected ends should be approximated. Diplopia on upward lateral gaze indicates injury to the muscle. Persistent postoperative diplopia lasting longer than 1 to 2 weeks should be evaluated by an oculoplastic surgeon.
9. Lower lid malposition: Excess "scleral show" in the immediate postoperative period may be due to edema and transient paresis of the orbicularis oculi muscle. It will often resolve as the edema diminishes and muscle functions returns. Massage of the lower lid in an upward and outward direction is beneficial. Tape support of the lower lid can lessen the degree of scleral show, decrease tearing, and improve comfort. Unappreciated preoperative lower lid laxity may also contribute to postoperative ectropion. To resupport the lid, a canthopexy or canthoplasty may be required. If the ectropion is due to overaggressive skin resection, correction will likely require complete scar release and full-thickness skin grafting after several months of observation and conservative management. The best means of treatment is prevention. A transconjunctival approach avoids the contraction associated with healing of the skin and muscle incisions used for the infraciliary approach. In addition, patients with any degree of laxity who require skin excision via an infraciliary approach should be considered for prophylactic lateral canthopexy.
10. Retrobulbar hematoma/visual loss: This is the most feared complication of blepharoplasty and develops as a result of vascular injury with retraction of the bleeding vessel into the retrobulbar space. The eye becomes firm, chemotic, and progressively more proptotic. The lids cannot close, as the globe continues to bulge outward. Increasing intraocular pressure can lead to ophthalmoplegia, ischemia of the optic nerve, and visual loss. A retrobulbar hematoma typically develops within the first 4 to 6 hours postoperatively. Prompt diagnosis and management are critical to prevent permanent visual loss. Initial treatment involves simultaneous opening of incisions; iced saline compresses; 20% mannitol (2 g/kg) as an osmotic agent to decrease intraocular pressure; acetazolamide (Diamox) 500 mg intravenously; dexamethasone (Decadron) 10 mg intravenously; control of hypertension (if present); head elevation; and correction of any coagulopathies. Visual acuity should be evaluated frequently. Any deterioration in visual acuity coupled with elevated intraocular pressure signifies impending optic nerve ischemia. In this situation, removal of all external sutures and lateral canthotomy/inferior cantholysis are indicated on an emergency basis for orbital decompression. Emergency ophthalmic consultation is necessary but should not delay performance of canthotomy and cantholysis.

DISCUSSION

Evidence-Based Medicine Question

What factors might contribute to postoperative dry eyes syndrome, and what steps might be taken preoperatively to better assess risk?

In a 10-year retrospective review of 892 patients undergoing blepharoplasty by a single surgeon, a self-reported dry eye questionnaire was administered to patients before and (minimum 3 weeks, mean follow-up 26 months) after surgery.[8]

Overall 26.5% of patients reported dry eyes syndrome (DES) at some time following surgery. DES was significantly more common in patients undergoing concurrent upper and lower lid blepharoplasty, with use of a skin-muscle flap blepharoplasty and in patients with temporary postoperative lagophthalmos. This highlights the need for all patients undergoing blepharoplasty to be assessed preoperatively for risks including scleral show, lagophthalmos, dryness, positive snap test result (lower lid laxity), prior surgery, and negative vector, all of which can further increase risk.

In summary, the incidence and reporting of DES may be underestimated, and appropriate preoperative assessment and counseling should be routine.

Editorial Comment

Abnormal tear film breakup and a Schirmer test are not good predictors of possible postblepheroplasty dry eye complications. A patient's anatomy (e.g., negative vector, lower lid laxity) and history are more important predictors of postoperative dry eye problems than ocular tests.

Frederic W.B. Deleyiannis

Access the review questions online at http://www.expertconsult.com

REFERENCES

1. Kontis TC, Papel ID, Larrabee WF. Surgical anatomy of the eyelids. Facial Plast Surg 1994;10:1–5.
2. Zide BM, Jelks GW. Surgical Anatomy Around the Orbit: the System of Zones. Philadelphia, PA: Lippincott Williams and Wilkins; 2006.
3. Pastorek N. Upper lid blepharoplasty. Facial Plast Surg Clin N Am. 1995;3:143–57.
4. Pastorek NJ. Blepharoplasty update. Facial Plast Surg Clin N Am. 2002;10:23–7.
5. Perkins SW. Transconjunctival lower lid blepharoplasty. Facial Plast Surg Clin N Am. 1995;3:175–87.
6. Smullen SM, Mangat DS. Cosmetic lower eyelid surgery: transcutaneous approach. Facial Plast Surg Clin N Am 1995;3:167–74.
7. Adamson PA, Constantinides MS. Complications of blepharoplasty. Facial Plast Surg Clin N Am 1995;3:211–21.
8. Prischmann JP, Sufyan A, Ting JY, et al. Dry eye symptoms and chemosis following blepharoplasty. JAMA Facial Plast Surg 2013;15(1):39–46.

REVIEW QUESTIONS

1. The inferior oblique muscle is at risk
   a. Between the medial and lateral adipose tissue pads of the lower eyelid
   b. Between the lid retractors and conjunctiva of the lower eyelid
   c. Between the central and lateral adipose tissue pads of the lower eyelid
   d. Between the punctum for the lacrimal duct and medial adipose tissue pad of the lower eyelid
   e. Between the medial and central adipose tissue pads of the lower eyelid

2. The benefit of a transconjunctival approach to the lower eyelid is
   a. Shorter incision
   b. Better exposure of orbital adipose tissue
   c. Better visualization of the inferior oblique muscle
   d. Better control of lower lid laxity
   e. Lower risk of postoperative lower lid malposition

3. The inferior incision for an upper lid blepharoplasty
   a. Should be placed at the upper border of the levator aponeurosis
   b. Is best made through skin and the underlying orbicularis to facilitate flap elevation in a submuscular plane
   c. Should be place just above the lash line
   d. Should be made at the upper border of the tarsal plate
   e. Should be made at the lower border of the tarsal plate

4. Management of retrobulbar hemorrhage might include (circle all that might apply)
   a. Lasix 60 mg as a stat intravenous (IV) dose
   b. Emergency lateral canthopexy
   c. Lateral canthotomy
   d. Activation of the overhead emergency response team
   e. Emergency inferior canthectomy

5. Possible causes of scleral show/lid malposition include all of the following except
   a. Overly aggressive upper eyelid blepharoplasty
   b. Scarring and retraction between the anterior and middle lamella of the lower eyelid
   c. Aggressive skin excision in lower eyelid blepharoplasty
   d. A subciliary approach to lower eyelid blepharoplasty
   e. Unrecognized preoperative lower lid laxity

157 Brow Lift

Benjamin W. Light, Paul Leong

INTRODUCTION

The brow lift procedure is a rewarding one to master. It allows for both functional and cosmetic concerns to be addressed, resulting in above average patient satisfaction. One of the earliest signs of aging is brow ptosis coupled with an accumulation of redundant tissues in the glabella region and forehead rhytids. A combination of sun exposure and time induced facial skin laxity allow brow tissue to migrate down past the superior orbital rim creating a "bunching" of glabella and eyelid anatomy. Patients frequently present with functional complaints of visual impairment; the often describe a weight or heaviness of their eyelids that limits their ability to remain attentive or focus due to impairment of vision and irritation of their eyelids weighing on their upper eyelid lashes. This downward migration of the upper face also leads friends and coworkers to perceive this brow heaviness as an outward appearance of tiredness, disgust, or angriness which can be very frustrating to the individual (Fig. 157.1A) As such, for either functional or cosmetic purposes, the brow lift can be a very beneficial procedure for the patient.[1]

In general, the closer the incision site of the brow lift approach to the actual brow region, the more control the surgeon may exert over the final position of the brow and its shape. Brow shape and position must be weighed against other variables such as patient acceptance, visibility of the scar, and risk of complications. Approaches to brow shaping, elevating, and stabilizing have changed a great deal over the past several decades with more recent advances allowing for a decrease in visible scars, healing time, and complications.

Often a brow lift is coupled with blepharoplasty (staged or synchronous) for optimal functional and cosmetic benefit. Performing the brow lift prior to a blepharoplasty is recommended to allow fixation of the brow position before determining if the blepharoplasty is even necessary. If eyelid surgery is performed, initial proper brow stabilization allows precise measurements for eyelid skin markings.

KEY OPERATIVE LEARNING POINTS

1. Proper selection of brow lift approach
2. Functional and cosmetic concerns in patient selection
3. Avoidance of pitfalls and complications associated with various brow lift approaches

PREOPERATIVE PERIOD

History

1. History of present illness:
   a. Note concerns that the patient has regarding brow appearance and symmetry.
   b. Discuss any history of visual disturbances.
2. Past medical history
   a. Prior treatment: Any use of neurotoxin in the frontalis or upper face within the 6 months prior to evaluation is important to note prior to surgery, as this can significantly alter the baseline relationship of scalp, brow, and eyelid position.
   b. Medical illness: History of facial nerve injury or palsy should be sought. Personal or family history of bleeding disorders or easy bruising is important to note. Past history of methicillin resistant staphylococcus aureus (MRSA) infections should be taken into consideration with respect to perioperative prophylaxis and hygiene. Patients using continuous positive airway pressure (CPAP) masks for treatment of obstructive sleep apnea (OSA) may need to forego the use of the mask for several weeks after a brow lift depending on the surgical approach and the type of mask used. Proper OSA treatment options may be discussed preoperatively for this eventuality. History of ophthalmologic surgery or treatment should be documented.
   c. Surgery: Previous surgeries of the upper face including excision of skin cancer (and repair techniques used to close the defect), blepharoplasty, forehead surgery, or traumatic injuries to the scalp/forehead are important to explore. Any history of postoperative nausea and vomiting should be explored in anticipation of preemptive perioperative pharmacologic intervention.
   d. Family history: Information on familial hairline recession and hair loss patterns in both male and female patients is important to consider when selecting the proper brow lift approach.
   e. Medication: The use of antiplatelet medications, alcohol, or herbal products
   f. Incidental: In anticipation of postoperative questions regarding swelling, routine inquiry as to the patients preferred sleeping position is needed. Preoperative discussion of the influence of sleep position on dependent edema can eliminate concerns when patients experience significant asymmetry of eyelid or brow swelling/bruising.

Physical Examination

1. Hairline position: The height of the forehead is an important variable in the selection of the proper brow lift approach. Each technique influences the hairline position and brow height in unique ways as described later.
2. Scalp: Hair thickness, color, and quality should be assessed to determine how visible a scar is likely to be when positioned around or behind the hairline.
3. Brow position: Note the position of the brow relative the orbital rim. Medial and lateral brow position is assessed. The quality of brow hair is noted. Thinning of lateral inferior brow due to plucking is noted and should be discussed with the patient (Fig. 157.2).
4. Eyelids: The presence of eyelid hooding due to dermatochalasis or eyelid ptosis should be noted.
5. Facial nerve: Baseline facial nerve function should be evaluated for strength and symmetry. Facial nerve dysfunction may often affect brow position and dynamics.
6. Trigeminal nerve: Preoperative function of the trigeminal nerve is important to note as the supraorbital and supratrochlear branches may be at risk during the procedure.



Fig. 157.1. Before **(A, C)** and after **(B, D)** photographs demonstrating typical results from a midforehead brow lift approach used in men. Other brow lift techniques are often not as much an option for men with high or no hairline to mask the incision sites.

7. Facial scars: The presence of facial scarring is important to note. Scarring of the forehead and scalp may result in disruption of natural dissection planes during surgery or asymmetric preoperative scar contracture that may need to be factored into the brow lift planning.

Imaging

A panel of preoperative photographs is necessary in cosmetic and functional brow lift patients. Frontal, oblique, and lateral photographs are recommended and required by insurance companies for preauthorization purposes. As patients with brow ptosis often have an unconsciously high baseline function or tone in the frontalis muscle to correct for longstanding visual deficit, they must be reminded at the time of photography to relax the forehead musculature to get an accurate image of their resting brow position.

Indications

1. Brow and forehead ptosis leading to secondary dermatochalasis with visual field defect greater than 25 degrees as measured by visual field testing. Ophthalmologists and optometrists regularly perform such testing as a screen to determine who may benefit from brow lift or blepharoplasty for functional visual improvement.
2. Facial nerve paralysis: Unilateral brow lift may be necessary to restore brow height for both functional and cosmetic purposes on the side of nerve dysfunction. The goal is to set the static brow height of the denervated side to somewhere between the lowest and highest positions of the opposite dynamic brow.
3. Forehead rhytids: Cosmetic concerns of aging of the upper face are more common after age 40. The brow lift procedure is often performed in conjunction with other facial

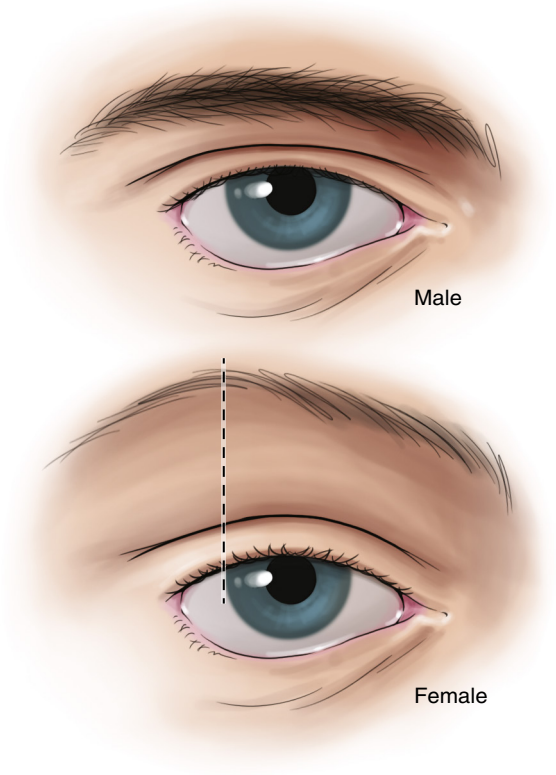

Fig. 157.2. Ideal brow position is relative. The male brow is typically more inferior in position, has fuller or thicker hair content and may be flatter when contrasted to the female brow. The female brow usually arches laterally and reaches its zenith somewhere around the junction of the medial two thirds and lateral third near a vertical line drawn vertically through the lateral limbus.

restoration procedures such as face-lift, mid-face lift, upper and/or lower blepharoplasty, or rhinoplasty. Facial resurfacing techniques should be avoided on the upper face if done concomitantly.
4. Horizontal and vertical static glabella "scowl" lines.

Contraindications

1. Patients with wound healing concerns (i.e., smoking or diabetes) generally do reasonably well healing scalp and forehead wounds due to the excellent blood supply to these tissues. Approaches to brow lift that avoid subcutaneous skin dissection should be chosen in this population.
2. General health concerns that may preclude anesthesia should be considered and investigated.

Preoperative Preparation

1. Hibicleanse scalp and hair wash the night prior to and morning of the operation.
2. Medication restriction list reviewed with the patient 2 weeks prior to the procedure. Anticoagulants are avoided.
3. Cardiac or general health clearance if deemed necessary.

OPERATIVE PERIOD

Anesthesia

General: Brow lift surgery may be done under awake sedation but for comfort, patients may prefer a general anesthetic.

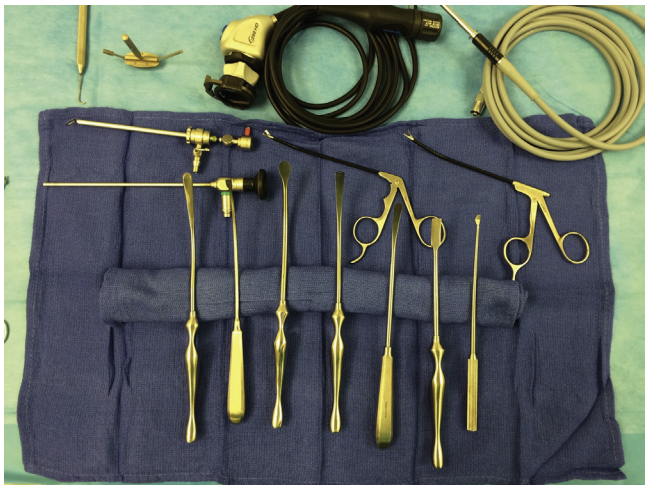

Fig. 157.3. Standard instruments used in an endoscopic brow lift procedure (clockwise from top left): bone bridge anchor system, endoscopic camera/light cord/30-degree endoscope with sheath, various straight and curved periosteal elevators, endoscopic insulated grasper and scissor.

Positioning

Supine: Positioning the patient so the cephalic scalp is as close to the upper edge of the operating table is important when performing the endoscopic approach to brow lift as much of the movement of the instruments may be hampered otherwise. Also, using a modified narrow headrest adapter for the operating table is advised for similar reasons.

Perioperative Antibiotic Prophylaxis

One to three grams Ancef is given IV preoperatively. Clindamycin 600 mg IV is given preoperatively when the patient is allergic to penicllin.

Monitoring

Facial nerve monitoring is not necessary.

Instruments and Equipment to have Available

1. For the endoscopic brow lift technique, specialized instrumentation includes (Fig. 157.3):
   a. Multiple straight and curved periosteal elevators with varying tip configurations
   b. Thirty-degree nasal endoscope with specialized sheath to facilitate endoscopic visualization using a standard OR camera/video system and monitor
   c. Specialized insulated curved endoscopic scissors and graspers to facilitate dissection and cautery
   d. Bone-tunnel or Endotine fixation system
2. Typical minor plastic instruments, retractors, and periosteal elevators are necessary for most other brow lift approaches.

Key Anatomic Landmarks

1. Frontal branch of the facial nerve
2. Trigeminal neurovascular bundle
3. Temporalis fascia divestment
4. Lateral orbital ligament
5. Sentinel vein
6. Corrugator supercilii and procerus muscles
7. Ideal brow position (see Fig. 157.2).

Prerequisite Skills

1. Facility with endoscopic technique is necessary to perform the endoscopic approach to brow lift.

Operative Risks

1. Improper plane of dissection: The surgeon needs to understand exactly which plane of dissection is necessary to achieve the desired results as each brow lift technique requires unique and often multiple levels of dissection.
2. Injury to the frontal branch of the facial nerve: Depending on the approach selected, careful anatomical dissection and conservative use of cautery or traction in the region of the nerve path is warranted to help avoid injury and resulting significant disfigurement.

Surgical Technique

With the patient seated in an upright position, manual elevation of the brow is useful to determine the extent of elevation necessary for best results. This can be done in front of a wall-mounted mirror with good lighting having the surgeon elevate the patient's brow from behind the patient.

Plucking of lateral caudal brow hair is a common cosmetic practice to create the appearance of lateral brow elevation. Proper brow elevation often requires lifting of the lateral brow region sufficient to elevate thick brow skin to or above the superior orbital rim. In those patients with severely thinned lateral brow hair the resultant brow may look "overly raised" when brow hair is used as the primary determinant of proper postop brow position. Identification and preoperative counseling of these patients are important to set expectations. The patient may be encouraged to allow resumption of hair growth in the lateral brow postoperatively.

The goals of any brow lift approach are to raise the brow position and to abrogate the depressing effect of the glabella musculature when possible. Using the approaches outlined below, one can achieve good results tailored to the patient's specific requirements.

Direct Brow Lift

Camouflaging the incision in the upper hair edge of the brow, the direct brow lift technique allows for excellent management of brow position (Fig. 157.4). It is less adequate in the treatment of glabella ptosis and lateral orbital hooding than other brow lift options as the shorter horizontal length of the incision site may limit medial and lateral elevation potential. It is a good choice for use in unilateral facial paralysis cases given its capacity for significant change in brow position using a unilateral well-concealed incision.

1. After marking the incision site with the patient in the upright position, 1% lidocaine with 1:100,000 epinephrine is injected to the operative area.
2. Half-strength betadine solution (betadine solution mixed 50:50 with balanced salt solution) is used to sterilize the brow and eyelid area. Full-strength betadine is used to sterilize the remaining field.
3. A fusiform horizontal incision is created inside the upper row of hairs in the brow hairline taking care to bevel the incision in the direction of the hair shafts. Cutting across upper brow hair shafts may result in loss of hair near the incision. The most superior incision should be beveled to help create an everted skin closure. The horizontal length of the incision should be limited and not extend past the superior brow hair-bearing margin.

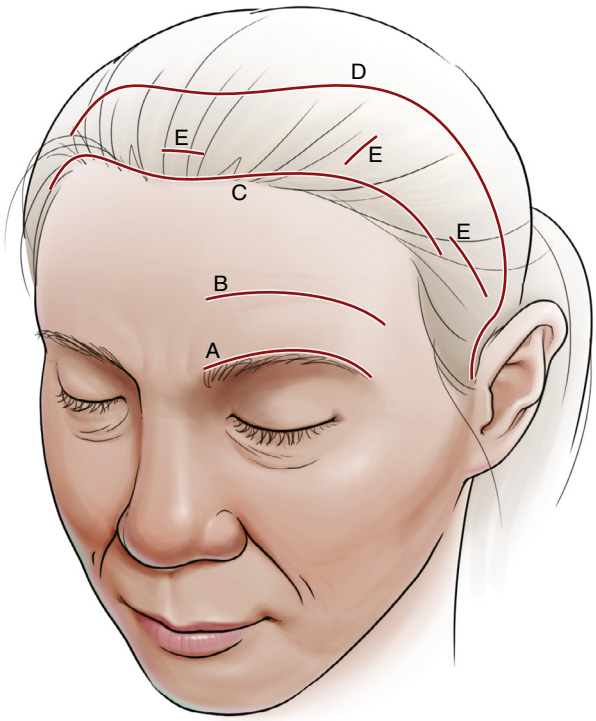

Fig. 157.4. This illustration demonstrates the incision sites used in various brow lift approaches: **(A)** Direct brow lift, **(B)** Midforehead brow lift, **(C)** Hairline incision brow lift, **(D)** Coronal incision brow lift, **(E)** Endoscopic brow lift.

4. Superior edge subcutaneous dissection can be performed to improve forehead rhytids in this region. Detachment of the affected skin from the forces exerted by deeper forehead muscle activity will allow improvement in static rhytids.
5. Medial sub-orbicularis muscle dissection may allow for sectioning of glabellar muscles if necessary.
6. After hemostasis is achieved with bipolar cautery, ptotic orbicularis and frontalis muscle may be sutured to the periosteum of the lower forehead using multiple well-positioned 4-0 prolene simple stitches to achieve adequate correction of lateral, central, and medial brow ptosis.
7. Wound closure using 5-0 pain dysfunction syndrome (PDS) simple subcutaneous sutures oriented to create eversion of the wound edges is necessary. 5-0 prolene subcuticular or 6-0 prolene superficial simple interrupted wound closure is then performed.

Midforehead Brow Lift

This approach to brow lift can be effective in men with unpredictable hairlines. The resulting scar is particularly well concealed when the technique is used in patients with deeper preexisting static forehead rhytids.[2] Given the incision placement proximity to the more mobile inferior forehead tissues, it affords excellent control of brow position along the entire width of the brow. Using a potentially broader horizontal incision than the direct brow lift, it is somewhat better at addressing medial brow/glabella ptosis than direct brow lift, but not as good as other approaches using superiorly based incisions (see Fig. 157.4). The obvious downside to using this technique is a potentially visible scar positioned in the midforehead (see Fig. 157.1).

1. After marking the incision site with the patient in the upright position, 1% lidocaine with 1:100,000 epinephrine is injected to the incision site and supraorbital rim area.

2. Half-strength betadine solution (betadine solution mixed 50:50 with balanced salt solution) is used to sterilize the brow and eyelid area. Full-strength betadine is used to sterilize the remaining field.
3. A fusiform horizontal incision is created in the midforehead taking care to bevel the incision to allow for eversion of the skin edges on closure. The contralateral brow lift incision site should be planned in an asymmetric fashion with each incision site centered on a horizontal rhytid of varying vertical position. This asymmetric scar placement will allow for greater concealment potential. The horizontal length of the incision can be extended to overlap at different heights medially for correction of medial forehead/glabella ptosis and may extend laterally past the lateral edge of the frontalis muscle.
4. Limited subcutaneous superior dissection is performed to allow some eversion of this skin margin upon closure. The inferior subcutaneous undermining may be carried inferiorly more extensively in the plane just above the frontalis muscle to the level of the brow if necessary. Great care must be taken in lateral dissection to avoid injury to the frontal branch of the facial nerve and in medial dissection to avoid the supraorbital neurovascular bundle.
5. The amount of skin removed is based on the lift required and takes some experience to judge adequately. Over excision of skin must be avoided. Fixation is achieved using 4-0 prolene to secure the soft tissues of the brow and orbicularis to superior periosteum.
6. Sharp dissection near the midline allows transition to a deeper subperiosteal plane of dissection giving access to the glabella musculature. Surgical sectioning of the corrugator and procerus muscles, if deemed necessary, is possible using this approach.
7. After meticulous hemostasis is achieved with bipolar electrocautery, the wound is approximated using 4-0 PDS simple interrupted subcutaneous sutures. 6-0 prolene simple interrupted or vertical mattress sutures allow surface closure with an emphasis on eversion of the wound edges.

Hairline Incision and Coronal Brow Lift

The hairline and coronal brow lift techniques are carried out in similar fashion but vary in design and placement of the incision. The coronal incision technique raises the position of the hairline, whereas the hairline incision technique lowers the hairline position and may result in a potentially more visible scar. Both techniques allow for: (1) excellent elevation of the full brow including lateral orbital hooding; (2) reduction in frontalis, corrugator and procerus induced rhytids; and if needed, (3) correction of glabellar skin ptosis.[3]

1. Incision sites and the entire forehead are infused with 1% lidocaine 1:100,000 epinephrine.
2. The curvilinear coronal incision (see Fig. 157.4) is placed in a position such that with intended removal of 1 to 2 cm of skin from the anterior leading edge of skin, the resultant incision will be located roughly 3 cm posterior to the hairline. The incision should be created parallel to the hair follicles if possible. The lateral extension of the incision may curve anteriorly downward to extend to the level of the helical root if necessary.
3. The hairline incision is created a few millimeters behind the hairline with the incision created in a beveled fashion to cut across the anterior hair follicles. This allows for growth of hair through the skin closure to aid in camouflaging the scar.
4. Medial exposure and dissection from the above approaches are facilitated anteriorly and inferiorly in the subgaleal plane to a point approximately 3 cm above the brow.
5. Sharp dissection to the subperiosteal plane is performed from this level inferiorly to the nasal bones taking care to preserve the supraorbital and supratrochlear neurovascular bundles.
6. The lateral incisions of each approach extend to the temple hair where dissection is carried down to the superficial layer of the deep temporal fascia. Anterior dissection and exposure to the orbital rim is carried out in the layer between this fascia and the temporoparietal fascia that contains the frontal branch of the facial nerve.[4]
7. The arcus marginalis is released at the level of the orbital rim allowing mobilization of the lateral brow.
8. In either technique, an adequate amount of skin is excised anterior to the incision and multilayer wound closure facilitates sufficient tension for brow fixation. Some surgeons suggest using tissue adhesives or bone-anchoring techniques for adjunct brow support during the healing phase.
9. For closure of the coronal incision wound, subcutaneous 4-0 vicryl deep sutures and superficial staples are used. This method is used for the hair-bearing lateral closure in the temples of the hairline incision technique. The medial forehead hairline closure is performed with 4-0 vicryl deep interrupted sutures and 5-0 or 6-0 prolene simple interrupted and/or vertical mattress sutures.

Endoscopic Brow Lift

This procedure offers some advantages over the options described above. It allows for smaller, well-concealed incisions behind the frontal and temporal hairlines (Fig. 157.5). It offers potential for less forehead and scalp numbness and the ability to apply multivector brow correction with central superior vector and lateral oblique vector lift forces. The approach may also allow for earlier resolution of tissue swelling and less blood loss than other brow lift options.[5]

The approach may not be useful in patients with a convex forehead and high hairline position as the endoscope may not be able to visualize inferior medial anatomy well. High hairlines may be elevated further using this technique and the relatively high point of fixation may limit control of brow shape in some patients. The use of the Endotine fixation system and preoperative neurotoxin adds expense to this approach.

1. One week prior to the procedure, neurotoxin is administered to the brow depressor muscles of the glabella and lateral orbicularis to assure less inferior pull on the forehead tissues after the procedure while the periosteum is healing back to the skull in the elevated position. While evidenced-based support for this practice may be lacking, we have noted that this measure can be helpful in our patient population.
2. Incision sites are marked and injected with 1% lidocaine, 1:100,000 epinephrine. Local anesthetic is infiltrated in the skin of the brow, across the forehead, and along the conjoint tendon bilaterally.
3. Medial dissection is facilitated using a central horizontal 1.5 cm incision and two vertical 2 cm incisions placed over the intended apex of the lateral brow bilaterally (Fig. 157.6).
4. Directed (nonendoscopic) subperiosteal dissection is widely carried out using a curved periosteal elevator downward to a level roughly 1.5 cm above the orbital rims and posteriorly to the vertex scalp and beyond as can be reached.



Fig. 157.5. Before **(A, C)** and after **(B, D)** photographs demonstrating typical results from endoscopic brow lift technique. (Patient A, C underwent lower blepharoplasty and rhinoplasty as well.)

5. Oblique temporal incisions are created for lateral dissection. Directly visualized dissection precisely on the surface of the superficial layer of the deep temporal fascia overlying the temporal muscle is performed using an elevator for wide field elevation of the flap to a point roughly 2 cm lateral to the orbital rim (see Fig. 157.6 shaded area).
6. Using a 30-degree endoscope in a protective sheath, dissection is visualized for dividing the conjoint tendon between the medial subperiosteal and lateral subgaleal planes at the superior temporal line (Fig. 157.7).
7. Endoscopic release of forehead tissue from bone and deep fascia are necessary to allow superior mobilization of the brow tissues. In the lateral dissection a confluence of fascia along the conjoint tendon makes dissection more difficult. In anterior dissection from this point toward the lateral canthus care should be taken to spare the sentinel vein so as not to predispose the patient to more prominent visible superficial periorbital/temple veins postoperatively. Also, a branch of the temporozygomatic sensory nerve often accompanies this vein. Damage to this nerve may cause unnecessary numbness in the zygomatic area. Release of the precanthal ligament and superior orbital ligament are necessary to maintain long-term results using this technique.
8. Endoscopic facilitation of medial dissection is performed to release periosteum at the level of the orbital rim, glabella, and superior temporal crest (see Fig. 157.6 shaded area). Taking great care to spare the supraorbital neurovascular structures, the glabella muscles (corrugator and procerus) are divided. Superficial to the corrugator the depressor supercilii are encountered and divided as well. Some surgeons suggest making a horizontal myotomy of the orbicularis oculi as well. Over resection of the corrugator muscle can lead to an unpleasing widened inter-brow distance postoperatively.
9. Lateral fixation is achieved using a 3-0 PDS suture securing the anterior temporal flap in an oblique vector posterosuperiorly to the temporalis fascia. Staples are used to close the wound.
10. Central fixation is achieved in the two paramedian vertical incision sites using one of many options. The Endotine system is an easy-to-use bone anchor that absorbs over time and provides for temporary firm superior fixation of brow, forehead, and scalp tissues. Alternatively, a cortical tunnel system can be used to allow suture fixation of forehead skin to a tunnel drilled into the outer cortex of the skull. Some advocate for tissue glue use as the sole fixative while others recommend using removable external screw fixation. Wounds are closed superficially with staples.

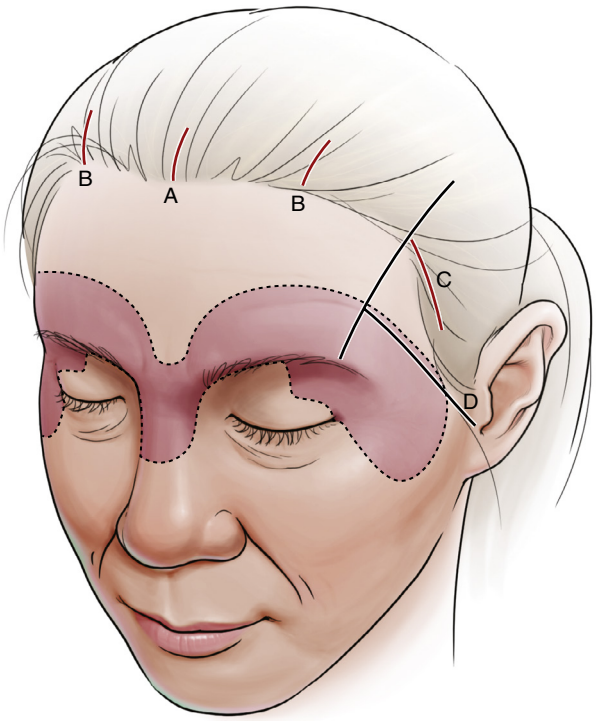

Fig. 157.6. Endoscopic brow lift dissection limits and incision site locations. **A,** midline central and **B,** Para median central cavity incisions. **C,** Temporal incision site. **D,** Frontal branch of facial nerve course predicted by a line drawn from the lower tragus to the temporal crest 1.5 cm superior to the tail of the brow.

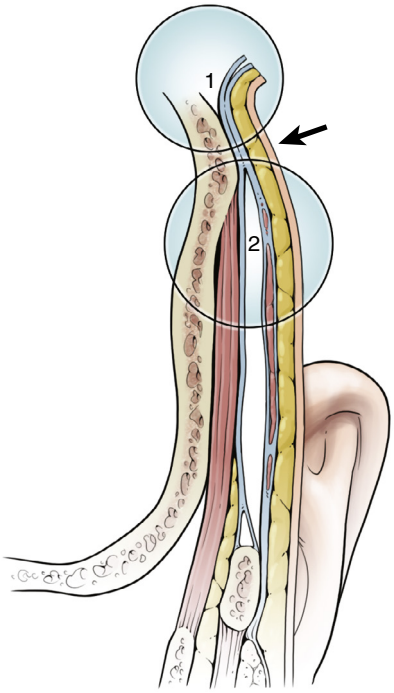

Fig. 157.7. Arrow marks the temporal crest and transition between (1) medial subperiosteal and (2) lateral subgaleal dissection planes.

Common Errors in Technique

1. Inadequate dissection and release of procerus and corrugator muscles.
2. Inadequate dissection and release of the arcus marginalis and lateral orbital tissues during endoscopic brow lift.
3. Improper wound closure techniques leading to visible and unsightly scars. Eversion of wound edges during closure and postoperative light dermabrasion will lead to less visible scars.
4. Inadequate correction of brow position can occur due to error in surgical judgment when performing either excisional brow lift or endoscopic techniques. Individual forehead skin laxity/tightness and forehead/scalp mobility vary greatly between individuals. This must be taken into consideration when assessing how much skin/muscle to remove/plicate, or how much superior vector tension to place during endoscopic procedures. Experience and deep consideration are necessary to determine the proper brow position for long-lasting functional and cosmetic results.
5. Extensive dissection of the forehead skin in the subcutaneous pre-frontalis plane should be avoided as this may result in skin necrosis.

POSTOPERATIVE PERIOD

Postoperative Management

1. Pain management: Though not necessarily an extremely painful recovery, pain management is necessary for the patient's comfort, but also for the prevention of undo blood pressure elevation due to pain. This is extremely important for prevention of excess bruising, swelling, and potential hematoma formation. It is a significant point of discussion emphasized in preoperative counseling of all patients. Certain patients have a preconceived notion that "pain medicines are bad to take." These individuals need to be reassured that when used properly they can facilitate recovery safely and not be addictive.
2. Blood pressure control: Thoughtful discussion of preoperative blood pressure status with treatment (if necessary) carried through the postoperative period is necessary to avoid excess risk of edema, bruising, and hematoma.
3. Swelling and bruising control: Elevating the head of the bed for several nights after the procedure is recommended for control of edema around the eyes and temple. Salt avoidance is recommended postoperatively. Timely pharmacologic intervention for postoperative nausea is necessary to avoid excess swelling and bruising secondary to the forceful retching that accompanies vomiting.
4. Anticoagulants are avoided for a two-week postoperative period if possible.
5. Forehead skin sutures are removed 5 to 7 days postoperatively depending on their location. Scalp staples located in hair-bearing regions are left in place for 10 days.
6. Skin closure sites are treated with mupirocin ointment twice daily. Scalp wound closures are cleansed with peroxide periodically to keep them clean, but no ointment is used as it seems unnecessary to prevent infection and may tangle and mat the hair significantly. Hair washing is allowed over the scalp wounds after 48 hours. Hair coloring is to be avoided for several weeks after surgery (in all seriousness, a discussion may be had with the patient to have hair colored just prior to the procedure to avoid consternation on their part after surgery).
7. Keflex 500 mg po ENM is prescribed for 7 days.
8. Preoperative discussion regarding restricted postoperative physical activity is strongly recommended. Patient expectations should be set to anticipate 10 days of limited activity to avoid straining or increased heart rate.

Complications

1. Hematoma: This is a rare complication if preoperative bleeding risks are properly evaluated and controlled. Meticulous

hemostasis is the most important feature in preventing hematoma formation. The use of postoperative pressure dressings or wound drains is not usually necessary.
2. Infection: This is rare, in part due to the high degree of blood flow to the scalp and forehead skin. Perioperative antibiotic prophylaxis is recommended.
3. Asymmetry of brow position: If the initial preoperative evaluation reveals resting asymmetry, this should be corrected if possible. Many preoperative asymmetries are noted to be functional in that an unconscious application of uneven frontalis muscle activity is to blame due to the urge to "unhood" the vision from the dominant eye visual field. Often this resolves if the procedure succeeds in resolving the superior visual deficit but this should be addressed with the patient preoperatively.
4. Injury to the frontal branch of facial nerve: This can be temporary or permanent and results in significant and disfiguring upper facial dramatic functional asymmetry. Great care should be taken in the elevation of tissues near the facial nerve. Proper technique used to help protect the facial nerve during each surgical approach is emphasized in the Surgical Technique section.
5. Paraesthesia or numbness of the forehead and frontal scalp in the distribution of the first branch of the trigeminal nerve: direct, midforehead, and hairline incision brow lift approaches may have numbness above the level of the incision. During manipulation of the neurovascular bundle using the endoscopic, coronal, or trichophytic approach, great care is taken to preserve the structures, but traction on the nerve often leads to some supraorbital or supratrochlear neural dysfunction. The nerve deficit may be temporary or prolonged but is not necessarily permanent as sensation may return even up to a year out from the procedure.
6. Visible scars: Meticulous wound closure technique must be applied to the closure of wounds during brow lift procedures of all types. Counseling the patient regarding the potential placement of visible scars is of paramount importance during the proper preoperative selection of the surgical approach.
7. Hair loss: Incisions created behind the hairline usually heal well and are very well concealed. Hair loss around incision sites is possible but this is often temporary. Judicious use of electrocautery and gentle tissue handling technique is warranted to avoid this outcome.
8. Overcorrection leading to a "Surprised" look: Fortunately, both cosmetic and functional brow lift patients are notably improved from the preoperative state using judicious technique and modest resection of glabella musculature; thus, obviating the need for extreme corrective forces to be applied to the surgical technique.

Alternative Management Plan

1. Chemical brow lift: Selective use of neurotoxin to relax brow depressor muscles.
2. Ultherapy: Directed use of transcutaneous ultrasound energy to create brow elevation.

DISCUSSION

Treatment of the upper face and forehead in the aging face patient remains an important component of overall facial rejuvenation. While in some surgeons' practices brow lift surgery has become less frequent over the last 10 years, this procedure retains a key role in optimizing outcomes.

As in all surgery, brow lift results are optimized when the patient is properly selected and the appropriate technique is applied. If brow lift surgery is used in the wrong patient (e.g., when the brows have not significantly descended with age) the result will be an appearance that does not seem natural to the patient. Alternatively, if the correct patient is selected, but overzealous techniques are used, results like the "surprised look" are possible. Neither of these errors should compel the surgeon to ignore the potential of brow lifting. The key is to recognize what the appropriate indications are to perform a brow lift, to select the optimal brow lift approach given the patient's particular anatomy, and then to apply this technique judiciously. Brow lift surgery remains a powerful tool to improve the cosmetic appearance and functional status of the patient.

Evidence Medicine Question

Is there evidence that endoscopic brow lift results can be expected to persist over the longer term?

Yes. Jones BM et al. reported that using objective measurements and validated subjective scoring systems that a brow lift produces a subtle elevation, with a natural eyebrow morphology close, with minimal long-term relapse.

Jones BM, Lo SJ: The impact of endoscopic brow lift on eyebrow morphology, aesthetics, and longevity: objective and subjective measurements over a 5-year period. Plast Reconstr Surg 132(2):226e–238e, 2013. http://dx.doi.org/10.1097/PRS.0b013e3182958b9f.

Editorial Comment

In the typical patient presenting with primarily lateral brow ptosis, a limited incision of 4 to 5 cm in length in the temporal scalp can elevate the temporal brow. This technique places the deep supraorbital nerve branches that innervate the frontoparietal scalp at minimal risk, does not require endoscopic instruments, and can be combined with transpalpebral resection of the corrugator supercilii muscles and procerus muscle.[6]

Frederic W.B. Deleyiannis

Access the review questions online at http://www.expertconsult.com

REFERENCES

1. Connell BF, Lambros VS, Neurohr GH. The forehead lift: techniques to avoid complications and produce optimal results. Aesthetic Plast Surg 1989;13(4):217–237.
2. Cook TA, Brownrigg PJ, Wang TD, et al. The versatile midforehead browlift. Arch Otolaryngol Head Neck Surg 1989;115(2):163–168.
3. Adamson PA, Johnson Jr CM, Anderson JR, et al. The forehead lift. A review. Arch Otolaryngol 1985;111(5):325–329.
4. Stuzin JM, Wagstrom L, Kawamoto HK, et al. Anatomy of the frontal branch of the facial nerve: the significance of the temporal fat pad. Plast Reconstr Surg 1989;83(2):265–271.
5. Isse NG. Endoscopic facial rejuvenation: endoforehead, the functional lift. Case reports. Aesthetic Plast Surg 1994;18(1):21–29.
6. Knize DM. Limited-incision forehead lift for eyebrow elevation to enhance upper blepharoplasty. Plast Reconstr Surg 1996;97(7):1334–1342.

REVIEW QUESTIONS

1. If a patient is felt to have a lower frontal hairline and the surgeon wishes to elevate the hairline as well as improve the brow position, what is the best brow lift approach?
   a. Endoscopic
   b. Direct
   c. Midforehead
   d. Coronal

2. If the surgeon is planning both an upper lid blepharoplasty and a brow lift procedure, which procedure should be done first?
   a. Upper lid blepharoplasty
   b. Brow Lift
   c. It does not matter

3. A forehead morphology that has a notably convex shape makes the endoscopic approach to brow lifting more challenging?
   a. True
   b. False

158 Face lift

Mark Mandell-Brown

INTRODUCTION

Much has been written about the aging face. The face lift procedure (rhytidectomy) is a critical component in addressing the issues of volume loss, sagging tissues, deep rhytids, jowling, and skin stretching. There are numerous trademarked names and even more nontrademarked names including "Vampire Lift," "Weekend Face lift," "Advanced Lift," "Quick Face lift," mid face lift, deep plane face lift, "Swift Lift," "Liquid Face lift," and composite lift.

While many of these are promoted for marketing in a highly competitive environment, the now defunct "LifeStyle Lift" with its multimillion dollar national marketing campaign brought face lift procedures to the attention of the general public and demonstrated the popularity and demand for rejuvenation procedures.

The public, in its thirst for noninvasive facial rejuvenation procedures, has embraced nonsurgical radiofrequency devices such as the Venus Legacy, Vanquish, and minimally invasive Thermi Lift as well as cryotherapy devices such as Cool Sculpting. Brief one time or repetitive nonsurgical treatments have caught the public's fancy.

The "Liquid" Face lifts in which hyaluronic acids such as Juvaderm, Voluma, Perlane or hydroxyapatite, (Radiesse) or poly-L-lactic acid (Sculptra) are used to fill out the volume loss with aging and heredity are increasingly popular. These products can "lift" the soft tissue and restore a more youthful appearance. Adipose tissue transfer has also gained in popularity to fill out the tear trough and add facial cheek volume. The "Vampire Lift" capitalizes on the public enchantment with vampires and uses platelet-rich plasma obtained from the patient's blood. This technique, when added with soft tissue fillers, supposedly improves facial rejuvenation by adding volume with healing blood factors.

Minimally invasive face lifts using barbed sutures have also been used, but many of these techniques have been removed by the Food and Drug Administration (FDA). However, the Silhouette Lift has recently gained popularity with an absorbable suture that suspends the sagging facial tissues.

Fortunately, there will always be demand for a well-performed face lift procedure. The key to obtaining a good result and avoiding complications requires knowledge, critical assessment, and surgical expertise.

KEY OPERATIVE LEARNING POINTS

- In-depth knowledge of facial and neck anatomy is essential for the successful rhytidectomy.
- Placement of incisions is critical to preserve the natural hairline in the temple and posterior neck.
- Careful planning is required to preserve the sideburn tuft of hair in a natural nonraised position.
- Preservation of the facial nerve is based on understanding the three key danger points. Injuring the temporal branch of the facial nerve can occur halfway between the lateral orbit and the temple hairline where the nerve is fairly superficial as it courses in the superficial temporalis fascia.
- The superficial muscle aponeurotic system (SMAS) was named by Mitz and Peyronie to describe the fascia system that is just deep to the facial skin and subcutaneous tissue. The SMAS is contiguous with the platysma in the neck.[1]
- Erb's point is located along the posterior border of the sternocleidomastoid muscle, midway between the mastoid and the clavicle. The greater auricular nerve emerges anteriorly to supply sensation to the ear and posterior cheek. The spinal accessory nerve courses along the posterior edge of the sternocleidomastoid muscle to supply motor function to the trapezius muscle.[1] (Fig. 158.1)
- With deep plane face lift techniques, Stensen's duct must be preserved, as it courses parallel to the buccal branch of the facial nerve. The duct travels in a line from the tragus to the corner of the mouth. What is deep plane? It is defined as the cleavage plane separating the SMAS from the deep cervical fascia.

PREOPERATIVE PERIOD

History

Consultation: As with all cosmetic surgeries, the consultation is critical for examining the patient and the patient's motivation, medical history, and performing a physical examination. A questionnaire can be helpful for determining the patient's area of interests, prior procedures, and a brief psychologic profile to determine whether any of the patient types to avoid are evident.

1. Areas of interest: Circle all that apply: sagging neck, face jowling, brow position, wrinkles, skin discolorations, wrinkles, smoker's lines.
2. Prior cosmetic procedures
3. Past medical history—medical history especially diabetes mellitus, coagulation defects, use of anticoagulants, herbal products, reactions to anesthesia, scarring
4. Past surgical history—cosmetic and noncosmetic
5. Social history—married, divorced, separated/work history
6. Psychologic history—psychologic counseling, life changes, holding grudges, suicide ideation, reasons for seeking face lift, sleep and eating habits to evaluate for depression
7. Smoking history—Some surgeons insist on a 2- to 3-week period of cessation of smoking prior to the face lift and 3 weeks after the surgery. Others refuse to operate on smokers with concern for skin flap viability. Some surgeons perform a urine nicotine test the morning of surgery and cancel the face lift if the test is positive. Others may have their patients sign a waiver that they have been informed that smoking may jeopardize their healing.
8. Computer imaging—There are 2D and 3D systems available. The photos can be used in the consultation to demonstrate the surgeon's anticipated but not promised goals of surgery. Incisions can also be demonstrated to the patient. The computer imaging enhances communication between the patient's goals and what the surgeon believes is an obtainable result.

Physical Examination

Assessing the degree of platysma banding, jawline jowling, submental fullness, nasolabial jowling, brow ptosis, masseter

hypertrophy, ptosis of submandibular glands, tear trough prominence, mid-cheek hallows, skin laxity, and Fitzpatrick skin type

Imaging

Photographs aid in evaluating the patient and recording for the medical record.

- Frontal view, lateral views, oblique views, animated views to evaluate the function of the facial nerve preoperatively. Consistent positioning of the patient for pre- and postoperative analysis is important. Using a solid blue or black background also aids by eliminating background distraction.

Indications

Determining the patient's motivation for a face lift procedure is as important as knowledge and skill in performing a face lift. Patients who have realistic goals and genuine interest in looking better but not perfect and understand the importance that guarantees cannot be provided are excellent candidates for the face lift.

Contraindications

Proper patient selection is critical to having a patient who is satisfied with his or her result and avoiding a malpractice suit. An excellent review of patient types shows to avoid the following[2]:

1. The overly narcissistic patient
2. The single immature male who is obsessive neurotic (SIMON) patient
3. The body dysmorphic patient
4. The unstable patient undergoing major lifestyle changes—for example, loss of job, divorce
5. The culturally estranged patient—desires major change to alter natural culture features
6. The exceptionalism patient—the patient who refuses to talk to staff, fill out paperwork, refuses to follow medical instructions, overly demanding
7. The unrealistic patient—brings photos of his or her youth—wedding photo, graduation photo—and expects to have the surgeon recreate
8. The multiply operated patient—lavishes praise on you and denigrates prior surgeons

Preoperative Preparation

Cessation of smoking at least 3 weeks prior to surgery is advocated by some physicians. Discontinuing aspirin, vitamin E, fish oil, and other platelet-inhibiting herbal products or medications is recommended 2 weeks prior to surgery. Arranging for transportation and an overnight caretaker following surgery is essential for procedures performed with Intravenous (IV) sedation or general anesthesia.

OPERATIVE PERIOD

Anesthesia

- The selection of the anesthesia technique is determined by the surgeon's preference, patient's preference, and the face lift technique selected. Some surgeons prefer general anesthesia, especially, for the more extensive face lift procedures.
- Other surgeons prefer IV sedation and an oral airway with oxygen cannula and carbon dioxide monitor.
- Sequential compression is recommended to prevent deep vein thrombosis.
- Public attention has been piqued with the ability to perform face lifts under local anesthesia. Surgeons often use oral anxiolytics or hypnotic medications. It is still important to monitor the patient's vital signs.
- Most surgeons use 1% xylocaine with 1,100,000 epinephrine along the incision line and in a field block.

Positioning

- The patient is placed supine typically with arms tucked comfortably by the side.
- The surgical table must allow convenient access to the patient's head.
- Some surgical chairs recline and also serve as a recovery chair.

Perioperative Antibiotic Prophylaxis

- A cephalosporin or other antibiotic is given 1 hour prior to surgery either intravenously or orally.
- Many surgeons prescribe continued oral antibiotic for a period of 5 to 7 days following surgery.
- With increased antibiotic resistance, there is a trend to give a one-time preoperative dose.

Monitoring

- Blood pressure, pulse oximetry, and Electrocardiogram (EKG) should be monitored for IV sedation or general anesthesia.
- It is important to monitor the patient's temperature when agents that trigger malignant hyperthermia are used.

Instruments and Equipment to Have Available

- Double skin hooks
- Senn retractors
- Army-Navy retractors
- Knife handles and blades
- Metzenbaum scissors
- Face lift scissors
- Needle holders
- Tissue forceps (Griffith-Brown, Castroviejo)
- Headlight
- Lighted retractor
- Iris scissors
- Suture scissors
- Liposuction cannulas
- Adipose transfer cannulas
- Monopolar and/or bipolar cautery

Key Anatomic Landmarks

Skin: laxity and rhytids

Muscles: zygomaticus major and minor, masseter, platysma, orbicularis oculi, frontalis, procerus, corrugator supercili, orbicularis oris, masseter, depressor anguli oris, sternocleidomastoid, temporalis

Distribution of adipose tissue

Nerves: facial nerve-temporalis, zygomaticus, buccal, marginal, cervical, greater auricular, trigeminal-supraorbital, infraorbital, supratroclear, mentalis

Vessels: facial artery and vein, superficial temporal artery and vein, jugular vein—external and internal, carotid artery

Salivary glands: submandibular gland, parotid gland, and Stensen duct
Skeletal: cervicomental angle, mandible, zygoma, mastoid, frontal bone, zygomatic arch
Retaining ligaments: zygomatic, masseter, mandibular, parotid

Prerequisite Skills

- Training in Otolaryngology, Oral Maxillofacial Surgery, or Plastic Surgery is important for a thorough understanding of the anatomy, proper handling of soft tissue, and nuances of the surgical procedure.
- Attending face lift courses, watching videos, and using fresh cadavers can aid the surgeon in developing the skills to perform face lift surgery.

Operative Risks

Controlled blood pressure, proper anesthesia with adequate level of sedation and monitoring, adequate preoperative screening for coagulopathies, and collagen vascular disorders can all decrease operative risks. Attention to detail to achieve meticulous hemostasis, preservation of the facial nerve, and avoiding excess wound tension on the skin flaps will decrease surgical risk. See "Postoperative Period: Complications."

Surgical Technique

Planning the Incision

1. The three critical areas for planning the incision involve the temple sideburn tuft, the tragus, and the postauricular hairline incision.
   - The incision can follow the temple sideburn beveled to protect the hair follicles. This protects the sideburn hair and preserves the sideburn in its natural position. However, the incision must be carefully closed to avoid a visible scar.
   - Alternatively, the incision can extend superiorly into the temple hair. The incision is hidden in the temple hair. However, the sideburn hair is elevated 1 to 2 cm with the flap elevation. Only if the patient has a very low sideburn is this option used. One of the telltales of a face lift or repeat face lift is that this option continuously elevates the sideburn hair in an unnatural more superior manner.
   - The incision can be made pretragal or posttragal. The pretragal incision requires less contouring to recreate a natural tragus. For men, the pretragal incision preserves the nonhair-bearing area anterior to the tragus. The hair bearing flap is advanced just to the anterior vertical incision, and no hair is brought to the tragus, which is posterior to the incision.
   - The posttragal incision is more hidden. However, careful reconstruction of the tragus must be undertaken to avoid amputating the tragal cartilage and producing a flattened appearance. In females, the posttragal incision is typically used. For men, the bearded skin will be brought into the tragus—necessitating shaving in this difficult area or having laser hair removal or other means to de-epilate the hair on the tragus.
   - The posterior neck incision can be planned to follow the neck skin/hair junction or proceed posteriorly into the occipital hair. Following the hair/neck skin junction makes it less likely to stair step the hairline, applies less traumatic shock to the hair follicles, and eases closure.
   - The advantage of planning the incision into the occipital hair is that the incision is hidden for those who wear their hair up or favor short hairstyles. However, shock to the hair follicles may cause iatrogenic alopecia and a stair-stepped pattern if the flaps are not properly aligned.
   - Patients are given the options for each of these designs so that they are involved in the planning and are properly informed as well as take ownership of the ultimate decision. Finally, a "time out" sheet indicating the placement of the incisions is reviewed the morning of surgery and signed off by both the patient and the surgeon on a facial diagram sheet.

Flap Design

There are a multitude of cheek/neck flaps and techniques. The more commonly used flaps include skin flap, treatment of SMAS with plication versus imbrication, high SMAS lift, "S" lift, and deep plane face lift.

1. For some patients with minimal jowling and only mild skin laxity or in patients who desire a tuck up lift after prior adequate treatment of the SMAS, a skin flap may suffice.
   The incisions are drawn preoperatively and demonstrated and agreed by the patient. The incision is made with the 15 blade on a Bard Parker handle. Nonpenetrating towel clamps are then used to provide traction and elevate the flap with face lift scissor dissection. Multiple tunnels are created by spreading the scissors in the superficial subcutaneous plane. Spreading is performed parallel to the facial nerve, and the multiple tunnels are connected with the face lift scissors beneath the skin flap. Hemostasis is achieved with the bipolar cautery in the area of the branches of the facial nerve or greater auricular nerve. Monopolar cautery may be used along the incision edges.
2. Skin flap
   - The skin flap may be undermined from 4 to 7 cm anteriorly in the cheek and/or neck area. The excess skin is then redraped posteriorly and superiorly applying traction with temporary regular width staples or penetrating towel clips at two key areas—superiorly near the anterior auricle and upper sideburn and posteriorly near the mastoid. The excess skin is then trimmed around the ear with the Metzenbaum scissors.
     Note: To avoid a pixie ear or pulling inferiorly in an unnatural position, absolutely no tension can be placed around the ear lobule. Undue tension will result in a "pixie" or scarred down ear lobe.
   - The postauricular skin can be tacked after making darts with the 15 blade and approximating the dart with a staple bringing the neck skin to the incision. Several Burow triangles are thus created, and the excess skin can be excised with the 15 blade.
     Note: Excess posterior skin of the neck can be treated by advancing the skin of the posterior neck skin toward the ear or by extending the incision posteriorly and creating a final Burow triangle to trim the excess skin.
3. Treatment of adipose tissue
   The second component to consider is the subcutaneous and deep subplatysmal adipose tissue. Various techniques to improve this layer include:
   - Once the skin flap is elevated, open tubing suction of the cheek and neck flap may be used. The sterile suction tubing can be connected to high wall suction, and the excess fatty subcutaneous tissue can be liposculptured.
     Note: Avoid suctioning directly on the subdermal adipose tissue just deep to the skin with either the open tubing method or the cannula method. This will create indentations on the skin surface or thin the skin to the point that a reticular capillary pattern occurs on

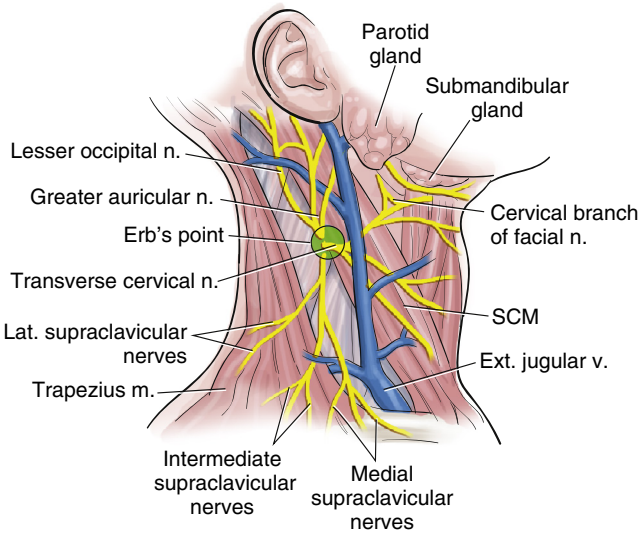

Fig. 158.1. Erb's point is an anatomic landmark where the greater auricular nerve and spinal accessory nerve are located along the posterior edge of the sternocleidomastoid muscle halfway between the mastoid process and the clavicle. When performing flap elevation, the greater auricular nerve courses very superficially over the sternocleidomastoid muscle. The spinal accessory is deeper and courses posteriorly, but it can be injured with posterior neck flap elevation.

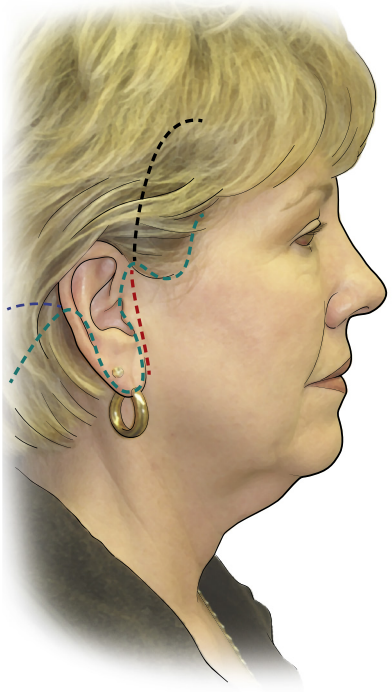

Fig. 158.2. Incision planning can be individualized for the patient's hairline and goals. The sideburn is preserved without further elevation *(green)*. If the incision is made superiorly into the temporal hair *(black)* the sideburn tuft is raised as the face lift flap is advanced superiorly. However, this incision is more hidden compared to the sideburn *(green)* incision. The incision then extends along the pre- or posttragal area. The posttragal *(green)* incision is more hidden. However, bearded skin will be advanced to this line, so shaving over the tragus may necessary for bearded skin. The pretragal *(red)* incision may be visible in some patients, but the bearded skin will be advanced only to this line and not further posterior onto the tragus. Posteriorly, the incision follows the postauricular sulcus and then curves either along the hairline *(green)* or into the hair *(blue line)*. For patients who have short hair, the hair incision is more camouflaged.

the skin. Direct subdermal suction may also compromise the skin vascular network and cause necrosis of the skin.

- Cannula method can also be used. There are numerous facial cannulas of all sizes that can be connected to high wall suction or an aspirator unit. The two options for cannula liposuction include using tumescent anesthesia along the cheek and neck. Then prior to flap elevation, perform liposuction (through 2-mm small openings along the planned incision) in the cheek, neck, and submental area. Then the skin flaps can be elevated as the skin is already undermined with the liposuction tunnels.
- Alternatively, once the skin flaps are partially elevated, under direct vision, the cannulas can be used to sculpt excess adipose tissue in the cheek and jawline as well as directly through a submental incision.

Note: Always keep the cannula parallel to the skin. Use caution in the neck around the external and internal jugular vessels.

4. Treatment of SMAS imbrication versus plication
   - *Imbrication* is overlapping the aponeurotic layer as in fish scales or roof tiles. ***Plication*** is folding and suturing the aponeurotic layer. No undermining is performed, and the SMAS is tacked over the parotid fascia. With imbrication, the SMAS is undermined and advanced posteriorly or superiorly and sutured to the underlying parotid-masseteric fascia in the cheek or the deep fascia in the temporalis (Fig. 158.2).
   - Plication may be the SMAS treatment of choice for the novice face lift surgeon or for some patients with minimal jowling. Permanent sutures such as a 2-0 Ethibond can be used to anchor the SMAS without undermining. Four or five sutures can be placed to overlap the SMAS in preauricular and neck deep fascia. This carries less risk of injury to the facial nerve or parotid duct since no undermining is performed.
   - Imbrication is the procedure of choice for more extensive jowling. The SMAS is undermined starting at a line drawn from the outer canthus to the angle of the mandibular angle. Metzenbaum scissors can be used to spread in a direction parallel to the facial nerves. Some surgeons prefer to identify the nerves while undermining, and some prefer to maintain a fascial layer over these essential motor nerve branches. When close to the facial nerves while using bipolar cautery for hemostasis, the assistant should be watching for facial muscle twitching to warn of the proximity to the facial nerve branches.
   - The SMAS is undermined for 3 to 5 cm in the cheek and neck area and then advanced posteriorly and superiorly to create a tighter sling that is anchored with 2-0 Ethibond or similar permanent sutures to the underlying deeper fascia. In some thin patients, the SMAS may be fairly attenuated, and creating a SMAS sling to plicate may be challenging (Fig. 158.3).
   - The high SMAS lift is useful for patients with deeper nasolabial furrows and midface jowling.[3] For these patients, the SMAS is undermined above the zygomatic arch. More extensive undermining is required to treat the perioral, infraorbital, and midface. However, less undermining is performed in the neck area, preserving playsmal/skin attachments. The parotidomasseteric and zygomatic ligaments are released. The SMAS is then secured in an oblique direction parallel to the zygomatic major muscle. The SMAS is anchored to the deep temporalis fascia (see Fig. 158.3). Thorough knowledge of the temporal branch of the facial nerve is required to avoid injury as it traverses over the zygomatic arch to innervate the fontalis muscle.

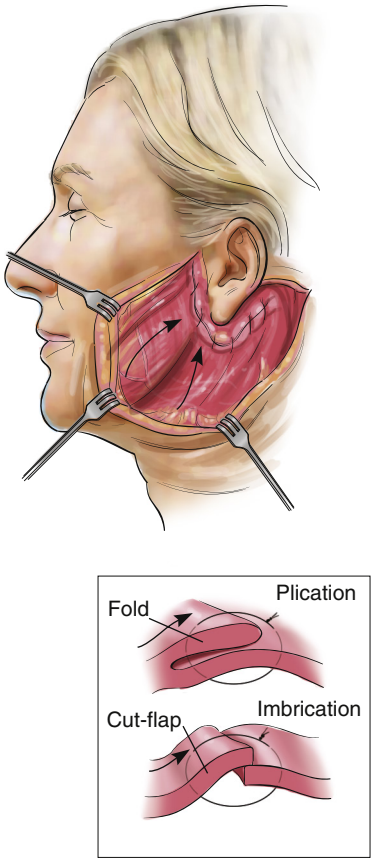

Fig. 158.3. Plication and imbrication are diagrammatically illustrated. Plication is folding tissue layers over and securing with sutures. Imbrication involves undermining and advancing the redundant tissues prior to suturing.

S Lift

- The original S lift is a short-flap face lift that utilizes a purse string suture "O" plicating the SMAS to the fascia of the zygomatic arch.[4] This "O" suture can be combined with "U" and "M" purse string sutures creating a longer flap with imbrication of the SMAS after vertical and lateral partial SMAS resection. The purse string sutures close the SMASectomy. To protect the temporal branch of the facial nerve, the zygomatic fascia is secured 1 cm anterior and inferior to the temporal nerve over the zygomatic arch.
- The "U" suture closes the vertical SMASectomy with a 2-0 Vicryl extending 2 cm anterior to the skin incision and extending from the zygoma arch fascia to a point 1 to 2 cm below the mandible with small purse string bites.
- The "O" suture closes the lateral SMASectomy with a 2-0 Vicryl in the direction of the nasolabial fold and 30 degrees anterior to the "U" suture anchoring the resected SMAS edge to the zygomatic arch periosteum with purse string bites.
- The "M" suture is used to elevate the malar pad by using a 3-0 Vicryl to secure the malar pad vertically to the lateral inferior orbicularis oculi muscle (Fig. 158.4).

Deep Plane Face lift

- Extends a cheek sub-SMAS dissection so that the SMAS, skin, subcutaneous tissue is elevated as one myocutaneous unit (Figs. 158.5 and 158.6)
- The entry point for the deep plane is in a line drawn from the lateral canthus to the angle of the mandible.
- The inferior cheek is elevated sub-SMAS and transitions to supra-SMAS in the upper cheek.
- The plane of dissection is superficial to the zygomaticus major and minor muscles.
- The zygomatic cutaneous ligaments are released at McGregor's patch. The flap extends medially to just beyond the nasolabial fold.
- The flap is elevated in a superolateral position.
- Sutures are used to anchor the entry point of the flap to the deep temporal fascia in the preauricular area.
- The inferior limit of the traditional deep plane face lift is the border of the mandible.

In the extended deep plane face lift, inferior dissection continues over the border of the mandible in the subplatysmal plane for 3 to 7 cm below the mandible. The cervical retaining ligaments are released between the platysma and the sternocleidomastoid muscle (see Fig. 158.5).[5,6]

Composite Face lift

- This combines the deep plane face lift and includes the orbicularis oculi muscle in the myocutaneous flap elevation.

Submentoplasty

- This can be combined with the face lift procedure or performed alone. A 3-cm horizontal incision is made in the submental crease. An inferior-based flap is undermined in the subcutaneous plane to the hyoid.
- Liposuction can be performed to remove the supraplatysmal adipose tissue. Subplatysmal adipose tissue can also be removed using liposuction through a midline opening in the platysma.

Various muscle plication procedures have been described, but a vertical approximation for support is a mainstay for tightening prominent platysma bands. The marginal branch of the facial nerve becomes more superficial as it enters the perioral muscles in the lateral chin area. Bipolar cautery may be useful in this area.

Platelet Rich Plasma

There has been increasing use of platelet-rich plasma mixed with thrombin in face lift surgery. This is sprayed under the flaps prior to closure. There is evidence that fibrin sealant has been shown to reduce the rate of hematoma in small studies. Other studies have shown no effectiveness.[7]

Common Errors in Technique

- Pixie ear
- Altered hairline
- Numbness resulting from injury to great auricular nerve
- Injury to stensen duct
- Injury to spinal accessory nerve
- Injury to the facial nerve
- Hematoma
- Button hole
- Skin slough
- Scarring
- Hair loss
- Cobra neck deformity

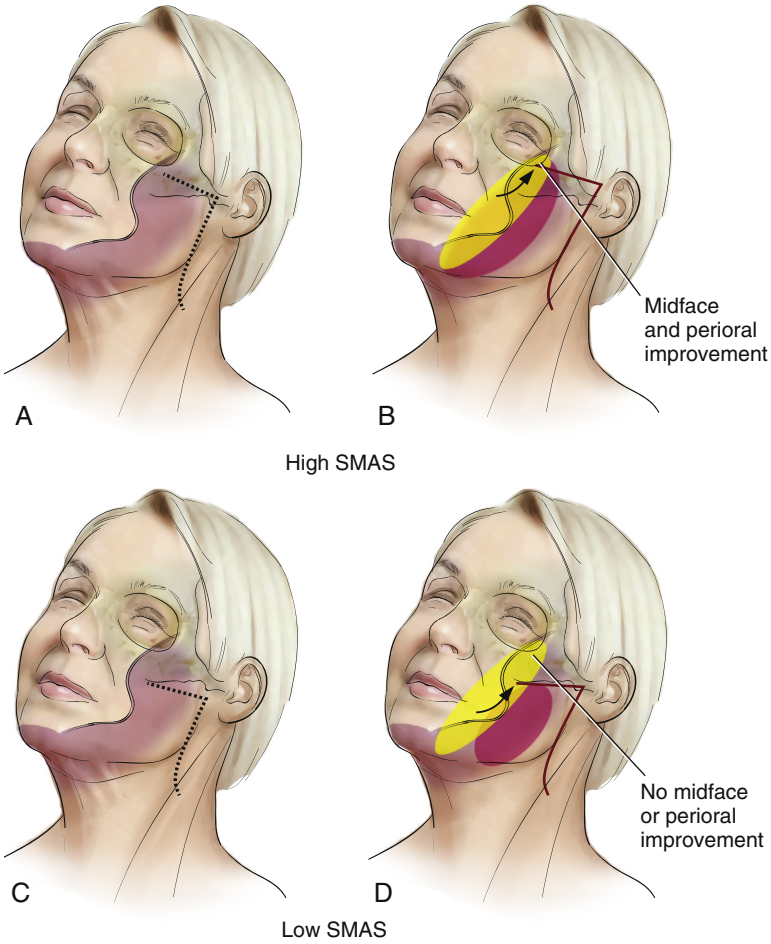

Fig. 158.4. (A) With the high SMAS lift, the SMAS is entered at the level of the zygomatic arch. (B) The suspension of the SMAS elevates not only the cheek and jawline jowling but also the anterior cheek and lower eyelid areas. (C) Care is required to preserve the temporal branch of the facial nerve. *SMAS*, Superficial muscle aponeurotic system. The low SMAS left does not have this good result (C/D).

Postoperative Management

- Patients have a head and neck wrap with gauze, Kerlex, and Coban wrapped circumferentially that is worn overnight. The patient returns the next day for removal of the dressing and to be evaluated for hematoma or motor nerve weakness. Some surgeons will place drains with more extensive face lifts.
- Incisions are cleaned with witch hazel, hydrogen peroxide, and topical antibiotic ointment.
- Smokers are requested to refrain from smoking for 3 weeks following surgery.
- Sutures and/or staples can be removed at 1 to 2 weeks after surgery.
- Patients are advised to avoid turning their neck for 2 weeks and to sleep elevated on their back for 6 weeks.

Complications

- Unrealistic patient demands—The consultation is important to convey realistic expectations to the patient. Pointing out and documenting facial asymmetries prior to surgery can alleviate postoperative patient complaints. Limitations of an anterior hyoid/larynx should also be emphasized.
- Pixie ear—This can occur when too much tension is placed at skin closure around the ear lobule (see (Fig. 158.7).
- Altered hairline—Planning and closing the incision are essential to maintaining a natural hairline.
- Numbness—Cutting branches of the greater auricular nerve will lead to numbness of the ear and cheek. This typically resolves over time.
- Injury to the parotid duct—If identified intraoperatively, the duct can be reapproximated with 6-0 or 7-0 sutures. If a sialocele develops, repeat aspiration or opening the flap and ligating the duct may be required.
- Injury to the spinal accessory nerve—The nerve exits near Erb's point in the posterior triangle posterior to the midsternocleidomastoid muscle. Injury would cause a weakness of the trapezius muscle and loss of shoulder elevation.
- Injury to the facial nerve—The marginal and temporal branches are most likely to be injured. The marginal branch can be injured during sub-SMAS elevation over the upper neck. The temporal nerve courses over the mid-zygomatic arch and is vulnerable with the high SMAS lift or deep plane face lift or the S lift. Injury to the facial nerve occurs in 0.7% to 2.5%.[6]
- Hematoma—Use of aspirin, anticoagulants herbal products that can promote bleeding, and vitamin E should be stopped 2 weeks before surgery. Control of intraoperative and postoperative blood pressure, establishing meticulous hemostasis, placing drains, applying tissue sealant, and placing a compression wrap are techniques to prevent hematoma formation. However, a review of tliterature does not support a particular technique to avoid a hematoma following face lift surgery.[7] Meticulous cautery, compression post operatively, and even drains may help prevent hematomas. Small hematomas can be evacuated with syringe aspiration. However, large hematomas with significant ecchymosis will require return to the operating room to elevate the flap, evacuate the hematoma, and inspect for bleeding sites. Failure to evacuate an expanding hematoma promptly may cause necrosis of the skin flap (Fig. 158.8).

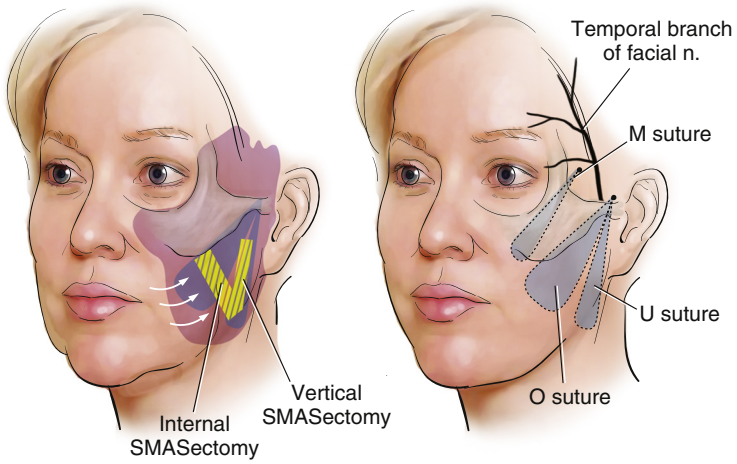

Fig. 158.5. The S lift modification is a short-flap technique using three purse string sutures to imbricate the SMAS. The "U" suture imbricates the SMAS vertically, and the "O" suture imbricates the SMAS laterally after a limited SMASectomy is performed. The "U" suture is anchored to the zygomatic arch periosteum and elevates the platysma at the angle of the mandible in a purse string "U" pattern. The "O" suture is placed at a 30-degree angle from the "U" suture and is anchored in the zygomatic arch periosteum. The "M" suture anchors the malar fat pad with a purse string suture secured to the lateral canthal area of the orbicularis oculi muscle.

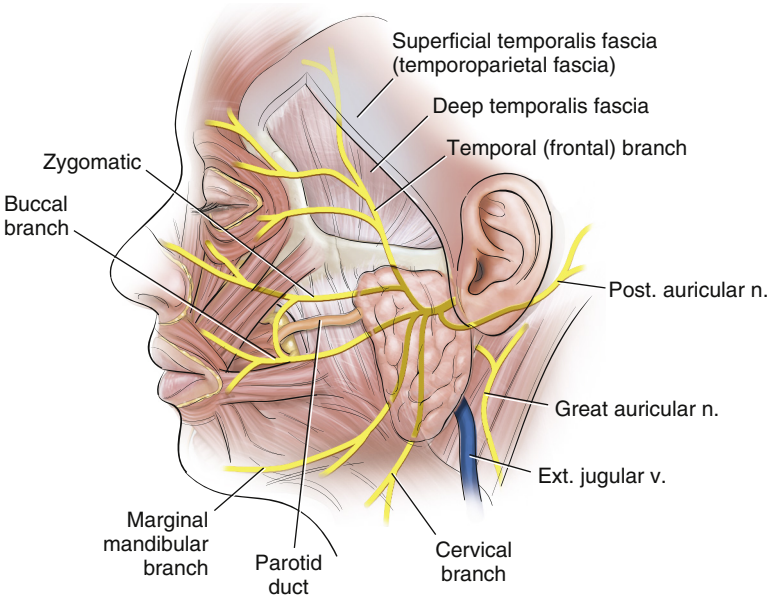

Fig. 158.6. Anatomy of the facial deep plane. The deep plane face lift uses a *sub*-SMAS dissection plane *in* the lower face combined with a supra-SMAS dissection plane in the upper cheek. The zygomatic cutaneous ligament McGregor patch and the mandibular ligament are released to improve suspension of the melolabial cheek.

- Button hole—Elevating the skin too superficial may create a button hole. This can occur when elevating the skin of the posterior neck over the sternocleidomastoid muscle in an effort to preserve the greater auricular nerve. It is best to suture the button hole immediately so that it does not expand. If the button hole occurs in an area where the skin will be resected, then it is not of a concern.
- Skin slough—This can occur from vascular compromise from smoking, creating a flap that is too thin, and too much tension on the skin. Typically when this demarcates, it will heal with conservative wound therapy.
- Scarring—An area of tension will result in hypertrophic or keloid scar. Some patients are prone to thickened scars. Straight head positioning when in bed for 4 to 6 weeks postoperative may help decrease tension on the scar. The widened scars may be treated with topical silicone products or injected with steroids such as Kenalog 10 mg/mL or 40 mg/mL several times about 6 weeks apart.
- Hair loss—Alopecia may result when the incision is carried into the hairline. Beveling the incision in the direction of the follicles and avoiding tension along the closure may reduce this risk. Allow time for the follicles to regenerate hair. Topical minoxidil may help, or follicular hair transplants may be required after adequate delay for healing (see Fig. 158.9).
- Systemic complications—Deep vein thrombosis and pulmonary embolism are extremely rare following face lift surgery. Use of sequential compression for lower extremities during surgery and early ambulation decrease this risk.
- Cobra neck deformity—This occurs when insufficient subdermal adipose tissue is maintained on the submental skin flap. Overzealous platysma resection or plication may result in prominent bands or ridges vertically oriented that appear similar to a "cobra" (Fig. 158.10).

Alternative Management Plan

For patients who have an interest in facial rejuvenation but who are not candidates for surgery because of lack of tissue laxity or have a medical history that contraindicates a face lift,



Fig. 158.7. Pixie ear is an unwanted stigma of face lift surgery. It is important to avoid any skin tension at the earlobe or a pulling down "pixie" ear web will result. A revision is required to release the ear lobule and advance skin closure without any tension.



Fig. 158.8. 1-Lematomas are a dreaded complication of face lift surgery. Despite meticulous cautery, control of intraoperative and postoperative blood pressure, avoidance of platelet-inhibiting medicines, and use of compression wraps, hematomas can still occur. It is paramount to identify the expanding hematoma as soon as possible to control the bleeding and preserve skin viability.

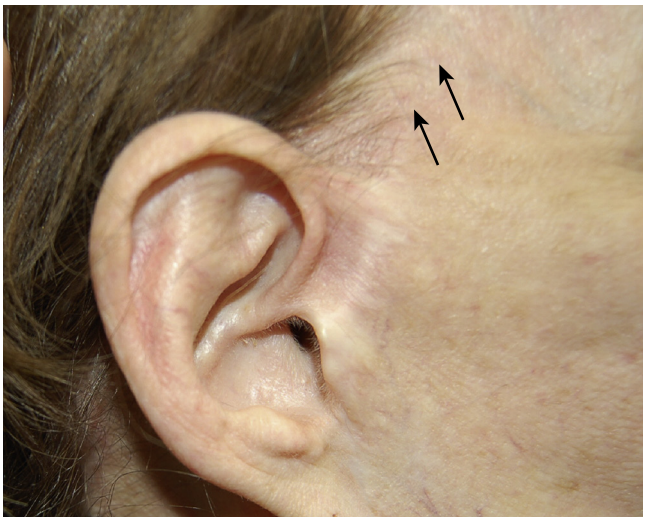

Fig. 158.9. Altered hairline results from poorly planned incisions, poor soft tissue handling, traumatic shock to the hair follicles with excess cautery, and excess tension on skin closure (arrows).



Fig. 158.10. Cobra neck deformity is depicted with the vertical band adherent to the skin. Excess liposuction of the subdermal neck skin and plication of the platysma can create the cobra neck. Treatment requires releasing the contracture from the overlying skin, a z-plasty, and/or adipose tissue grafting to the neck (arrows).

alternative options include soft tissue fillers, neurotoxin use in the forehead, glabella, or crow's feet area, facial peels, or laser resurfacing for rhytids. These options can also aid in improving the face lift results (A).

Evidence-Based Medicine Question

Has the subperiosteal lift fallen out of favor?[9]

The subperiosteal lift first advocated by Tessier and then Ramirez provides for undermining the periosteum of the lateral and superior orbital rim and midface. However, the procedure is technically difficult, has a higher risk of motor nerve injury, and has prolonged postoperative recovery.



Before After

Fig. 158.11.

Editorial Comment

Most current face lift techniques produce straight jawlines and good neck contours (Fig. 158.11). Proponents of extended SMAS and composite rhytidectomies stress that these techniques are needed to better correct midfacial ptosis and to improve the nasolabial folds. However, numerous clinical studies have also demonstrated that comparable clinical results are obtained up to 1 and 2 years when limited SMAS and standard SMAS procedures are compared with extended SMAS and composite rhytidectomies. For a smoothing effect of the nasolabial fold and a lift of the midface, other techniques should be considered, such as fillers and lifting the malar adipose tissue pad.

Frederic W.B. Deleyiannis

Access the review questions online at http://www.expertconsult.com

REFERENCES

1. Mitz V, Peyronie M. The superficial musculoaponeurotic system (SMAS) in the parotid and cheek area. Plast Reconstr Surg 1976;58:80–88.
2. Adamson PA, Chen T. The dangerous dozen—avoiding potential problem patients in cosmetic surgery. Facial Plast Surg Clin North Am 2008;16(2):195–202.
3. Marten TJ. High SMAS face lift: combined single flap lifting of the jawline, cheek, and midface. Clin Plast Surg 2008;35(4):569–603.
4. Hopping S, Janjanin S, Tannai N, et al. The S-Plus lift: a short-scar, long-flap rhytidectomy. Ann R Coll Surg Engl 2010;92:577–582.
5. Hamra S. The deep plane rhytidectomy. Plast Reconstr Surg 1990;86:53–59.
6. Baker SR. Deep plane rhytidectomy and variations. Facial Plast Surg Clin North Am 2009;17:557–573.
7. Mustec TA, Park E. Evidence-based medicine: face lift. Plast Reconstr Surg 2014;133(5):1206–1213.
8. Warren RJ, Aston SJ, Mendelson BC. Face lift. Plast Reconstr Surg 2011;128(6):747e–764e.
9. Kleinberger AJ, Spiegel JH. What is the best method for minimizing the risk of hematoma formation after rhytidectomy? Laryngoscope 2015;125(3):534–536.

REVIEW QUESTIONS

1. Erb's point is a convenient landmark for locating which nerve(s)?
   a. Marginal mandibular nerve
   b. Greater auricular nerve
   c. Spinal accessory nerve
   d. A and B
   e. B and C

2. The cervicomental angle should be
   a. 90 degrees
   b. 105 to 120 degrees
   c. 60 degrees
   d. 60 to 80 degrees

3. A patient calls the evening of her deep plane face lift surgery. She has throbbing pain, bleeding through her bandage wrap, and bruising intraorally. The pain medicine prescribed is not working. You advise her:
   a. Place ice on the cheek area and elevate the head of the bed.
   b. Have the caretaker release the dressing to determine if there is bleeding.
   c. Assume she has a hematoma and arrange to meet her for evaluation and treatment.
   d. Have her report to the local emergency room for evaluation and treatment by the Emergency room (ER) staff.

159 Facial Resurfacing: Peels and Lasers

Rebecca E. Fraioli

INTRODUCTION

Facial resurfacing with chemical peels and lasers is indicated for patients with photoaged skin. Photoaging is a term used to describe the changes that occur within the skin with aging and ultraviolet (UV) exposure, such as skin dullness due to loss of skin turnover and subsequent thickening of the stratum corneum, loss of elasticity due to breakdown of collagen and elastin, and pigmentary changes due to overactivity of melanocytes. Facial resurfacing is not appropriate for patients with deep rhytids or lax, sagging skin; patients with these characteristics will be better treated with surgery.

Facial resurfacing treatments work by damaging the skin and thereby triggering the wound healing process. Chemical peels cause exfoliation of damaged skin; the new skin that replaces it has better cellular organization, newly generated extracellular matrix, and a decrease in the number of cells with abnormal melanin deposits.[1]

Laser skin resurfacing may be ablative or nonablative. Ablative lasers damage and remove skin, similar to chemical peels. This is achieved by targeting water as a chromophore, resulting in heating and sloughing of skin. Traditional (nonfractional) ablative lasers affect all of the skin in the treatment area. Newer, fractional, ablative lasers treat only microcolumns of skin known as microthermal treatment zones (MTZs), sparing the skin between microcolumns. The spared adnexal structures allow faster skin regeneration, but with the compromise of less dramatic results.

Nonablative lasers used for skin resurfacing specifically target the water in the dermis and thus heat, coagulate, and stimulate collagen remodeling in the dermis while leaving the stratum corneum intact. This feature allows for a shorter recovery period, although at the cost of less noticeable results. Fractional nonablative lasers can be used to penetrate deeper into the dermis and provide improved results compared to nonfractional lasers.

KEY OPERATIVE LEARNING POINTS

- Chemical peeling agents are classified by the usual peel depth achieved.
- Very superficial peels are limited to the outermost layer of the epidermis, the stratum corneum.
- Superficial chemical peels are limited to the epidermis.
- Medium and deep peels penetrate the papillary and reticular dermis, respectively.
- In practice, many factors affect the depth of a chemical peel, and deeper than expected peeling can occur.
- Laser resurfacing can more precisely target the depth of the ablation.
- Lasers use an energy source to stimulate a lasing medium that then emits light waves of a single wavelength.
- Ablative lasers target water within the skin as a chromophore. Common ablative lasers are erbium:yttrium aluminum garnet (Er:YAG) with a wavelength of 2940 and carbon dioxide (CO_2) with a wavelength of 10,600. Common nonablative lasers are the 1320-nm neodymium:yttrium-aluminum-garnet (ND:YAG) laser and the 1064-nm ND:YAG laser.
- Ablative laser resurfacing removes the dermis and epidermis. Ablative lasers give the best result for wrinkle reduction but at the cost of a longer recovery period and increased risk of postprocedure complications.
- Fluence describes the energy per unit area of the laser beam. Higher fluence has more energy and penetrates deeper into the skin.
- Pulse width is essentially a measure of pulse duration.
- Spot size is the size of the laser beam. The larger the spot size, the higher the energy and the deeper the penetration of the laser beam.
- Melanin may also absorb some of the laser light; therefore patients with darker skin have a higher risk for laser burns. More conservative laser parameters should be used in patients with higher Fitzpatrick skin types (Table 159.1).[2,3]

PREOPERATIVE PERIOD

History

History of Present Illness

- What are the patient's specific concerns (e.g., acne, skin dullness, dilated pores, rhytids)?
- Prior surgeries and treatments
- History of sun or tanning exposure
- Current skin care regimen
- Patient's psychologic motivation for facial resurfacing
- Are treatment goals and expectations realistic?

Past Medical History

- Medical comorbidities
  - Diseases with impaired wound healing (e.g., collagen vascular diseases or poorly controlled diabetes mellitus)
  - Immunosuppression
  - Coagulation disorders
  - Phenol peels in particular have systemic risks and should be avoided in patients with pre-existing cardiac, renal, or hepatic disease.
  - If a phenol-based peel is planned, the patient should have a complete medical evaluation including cardiac, renal, and hepatic testing.
  - History of herpes simplex virus (HSV) outbreaks should be noted.

TABLE 159.1 Fitzpatrick Skin Types

Fitzpatrick Skin Type	Skin Color	Ability to Tan	Tendency to burn
I	Very white or freckled	Never tans	Always burns
II	White	Tans minimally	Usually burns
III	White to olive	Tans moderately	Sometimes burns
IV	Light brown	Tans readily	Rarely burns
V	Dark brown	Tans profusely	Very rarely burns
VI	Black	Tans profusely	Never burns

- Skin history
  - A history of keloid or hypertrophic scarring is a contraindication to facial resurfacing.
  - History of skin cancer
  - Prior external beam radiation or burns to the skin are contraindications because they damage the adnexal structures in the dermis responsible for skin regeneration following resurfacing.
- Medications (current and past)
  - Antiplatelet agents and anticoagulants
  - Isotretinoin (Accutane) is a contraindication to chemical peels for 6 to 12 months after the medication has been discontinued. Isotretinoin downregulates adnexal structures in the dermis that are necessary for skin renewal following facial resurfacing.
  - Corticosteroids can impair wound healing.
  - Exogenous estrogen found in hormone replacement therapy or oral contraceptives increases the risk of postinflammatory hyperpigmentation following facial resurfacing procedures.
- Allergies
  - Allergy to any of the peel ingredients is a contraindication to using that peel. In particular, allergy to aspirin is a contraindication to any peel containing salicylic acid.
  - Lidocaine allergy should be noted.
- Social history
  - Smoking is not an absolute contraindication to chemical peel or laser skin resurfacing. However, caution should be used in a heavy smoker especially for deeper peels or ablative lasers.
- Family history
  - A family history of skin cancer should be noted.

Physical Examination

- A full examination of the face and neck should be performed, and the skin should be carefully assessed for texture, rhytids, pigmentary changes, acne lesions, open wounds, and scars.
- Pigmented skin lesions must be examined, and suspicious lesions should be biopsied. Facial resurfacing is not a treatment for skin cancer.
- Photodamaged skin must be differentiated from skin or muscle laxity and loss or descent of adipose tissue. The former is an indication for facial resurfacing; the latter are indications for surgery or injectable fillers.
- The degree of photodamage should be assessed and classified according to the Glogau scale (Table 159.2).[1]
- The patient's baseline skin pigment and response to UV exposure should be assessed and classified according to the Fitzpatrick scale (Table 159.1).[3]
- A lower eyelid "snap test" should be performed to assess for lower eyelid skin elasticity and recoil. Pull the lower eyelid skin inferiorly and release. If the skin does not return to its starting position within 3 seconds, laser resurfacing should not be performed in the area of the lower eyelid due to risk of postprocedure ectropion.

Imaging

- Radiographic imaging is not indicated in patients desiring facial resurfacing. However, pre- and posttreatment photodocumentation are essential.
- Lighting and patient positioning should be standardized and consistent between pre- and posttreatment photos.
- The five standard views are frontal, right and left lateral, and right and left oblique. Close-up photos should also be obtained of lesions or areas to be specifically targeted.

TABLE 159.2 Glogau Skin Types

Glogau Type	Degree of Photoaging	Description of Changes	Patient Age	Makeup
I	Mild	• Mild pigmentary changes • No keratosis • Minimal or no wrinkles	20s	Minimal to none
II	Moderate	• Early solar lentigines • Rare keratosis, mainly palpable • Wrinkles seen only with facial expression	30–40s	Wears some foundation
III	Advanced	• Obvious dyschromia and telangiectasias • Moderate actinic keratoses • Wrinkles seen at rest	50s	Always wears heavy foundation
IV	Severe	• Sallow (yellow–gray color) • Keratoses, skin cancer, severe actinic changes • Wrinkles throughout, little normal skin	60–70s	Can't wear makeup due to cakes and cracks

Indications

- General indications for facial resurfacing are: photodamaged or thick, rough skin, hyperpigmentation, dilated pores, acne, and acne scarring.
- Factors influencing the choice of resurfacing agent include: degree of photoaging, skin Fitzpatrick type, comorbidities, and willingness for postprocedure downtime.
- Superficial chemical peels are appropriate for mild to moderate photoaging (Glogau types I and II). Patients with more severe photoaging (Glogau types III and IV) are unlikely to see significant benefit.
- Superficial peels may be used in all Fitzpatrick skin types.
- Medium and deep chemical peels may provide benefit to patients with advanced photoaging; however, recovery period and risks are higher than with superficial peels, and laser resurfacing may be a better option.
- Medium and deep chemical peels are contraindicated in patients with higher Fitzpatrick skin types due to the high risk of pigmentary complications.
- Nonablative laser resurfacing is appropriate for mild to moderate photoaging and rhytids (Glogau types I to III).
- Nonablative lasers have the advantage of limited postprocedure downtime, with the tradeoff of modest results. A series of treatments is usually necessary to see significant results.
- Fractionation increases depth of penetration and improves results; the tradeoff is increased healing time and increased risk of complications.
- Fractional nonablative lasers can be used in all skin types but should be used with caution in patients with darker skin types (Fitzpatrick IV to VI).
- Ablative laser resurfacing is indicated for patients with lower Fitzpatrick skin types (I to III) and more advanced photoaging, including static rhytids (Glogau IV). Patients must accept significant recovery downtime from this procedure.
- Fitzpatrick skin types IV to VI are not candidates for ablative laser resurfacing due to a high risk of pigmentary complications in these patients.

Contraindications

- Uncontrolled medical illness
- Bleeding disorder or anticoagulant use
- Active herpes simplex or other infection
- Open wound in the treatment area
- Damage to adnexal structures in the dermis that are responsible for regeneration of the epithelium, such as use of Isotretinoin (Accutane) within the preceding 6 to 12 months or a history of radiation treatment or burns to the face
- Medium to deep facial resurfacing in treatment area in the past 6 to 12 months
- Recent heavy sun exposure
- History of keloid or hypertrophic scarring
- Impaired wound healing
- Skin malignancy in the treatment area
- Pregnancy or nursing
- Body dysmorphic disorder or unrealistic patient expectations
- Allergy to chemical peel ingredients
- Ectropion is a contraindication to lower lid laser resurfacing.
- Tattoos in the treatment area are a contraindication to laser resurfacing, as a burn may occur in the skin under the tattoo.

Preoperative Preparation

- A standard skin preparation regimen should be initiated 6 weeks prior to skin resurfacing procedures
- Broad-spectrum sunscreen of SPF 30 and sun avoidance for 1 month prior to the treatment
- Topical retinoid should be started 6 weeks prior to chemical peeling. Preprocedure treatment with topical retinoids has been demonstrated to decrease time to reepithelialization following chemical peels.[4]
- Retinoid use also helps to modify the epithelium to a uniform thickness, which is helpful in achieving a standardized peeling depth. Retinoid use has not been shown to be beneficial prior to laser resurfacing.[5]
- Topical hydroquinone should be started 1 month prior to the procedure for patients with a history of hyperpigmentation or a high Fitzpatrick type.
- Antiviral prophylaxis should be started two days prior to the procedure and continued for 3 to 5 days following the procedure.
- Patch testing of chemical peels may be performed.
- All retinoid or AHA products should be stopped 2 weeks prior to the procedure to decrease skin irritation.
- Anticoagulant medications and supplements should be discontinued 2 weeks prior to the procedure. However, it is advisable to forgo facial resurfacing rather than to stop anticoagulant medications that are medically indicated.

OPERATIVE PERIOD

Anesthesia

- Superficial chemical peels do not require anesthesia during the procedure.
- Nonfractional nonablative lasers often have built-in skin cooling that is sufficient for pain control for these procedures.
- Fractional nonablative laser treatments usually require a topical anesthetic. Cold-air cooling may also be beneficial. Regional nerve blocks may be used if necessary.
- Deeper peels and ablative laser resurfacing will require increased pain control. Options include strong topical agents, nerve blocks, anxiolytics, and/or narcotics. In certain cases, IV sedation or general anesthesia may be necessary.



Fig. 159.1. This photo demonstrates the setup for performing a superficial peel. The peeling agents come premixed. A sterile specimen cup is used to decant a small amount of the peeling agent. Gauze sponges are folded up on sticks and used to apply the peeling agent to the face. Sterile saline is available to wash off the peeling agent if signs of undesirable clinical endpoints should occur.

Positioning

- For chemical peeling, the patient should be reclining with the head elevated 45 degrees. Head elevation helps to prevent pooling of the peel solution in dependent areas of the face.
- For laser treatments, the patient may be reclined in the treatment chair or lie flat in the supine position on the treatment table.

Perioperative Prophylaxis

- The risk of bacterial infection is low, and no antibacterial prophylaxis is indicated.
- Prophylaxis for HSV 1 and 2 should be given starting 2 days prior to the procedure.
- Because the rate of latent HSV infection is so high (up to 90% in some studies), many providers provide prophylaxis regardless of prior infection history.[6]

Monitoring

- Cardiac monitoring is necessary for phenol-based peels.

Instruments and Equipment to Have Available

Chemical Peels

- Patient eye protection (moist gauze or adhesive eye pads)
- Handheld fan
- Peel solution
- Gauze sponges for application and removal
- Saline
- Neutralizing solution (if applicable)
- An example of the materials necessary for a superficial chemical peel is shown in Fig. 159.1.

Nonablative Laser Resurfacing

- Laser
- Protective eyewear: lead goggles for patient and wavelength-specific goggles for providers

Key Anatomic Landmarks

- Chemical peels are applied to the entire face, sparing the periorbital areas and the lips.
- The peel should be feathered into the hairline and under the jawline.

Prerequisite Skills

- Superficial peels should be mastered before progressing to medium and deep peels.
- General laser safety training and specific training on the particular laser to be used are prerequisites to performing laser resurfacing. Laser guidelines are manufacturer-specific, and device-specific training from the manufacturer should be obtained prior to using the device.

Operative Risks

Chemical Peels

- Risks are rare following superficial peels. Peels extending deeper into the dermis have a higher risk for complications.
- Infection, including bacterial, fungal (candidiasis), and viral (herpes simplex outbreak)
- Hyper- and hypopigmentation
- Scarring
- Eye injury
- Allergic reaction to peel ingredients
- Systemic toxicity from peeling agents, particularly phenol toxicity and salicylate toxicity. This risk is checked by limiting the total area being peeled in a single setting and peeling one aesthetic unit at a time.

Laser Resurfacing

- Burns
- Fire. It is critically important to cover hair and remove flammable materials from the laser field.[7]
- Petechiae and purpura may occur when the laser settings are too intense.
- Bacterial infection is rare but may occur. HSV infection is possible despite prophylaxis.
- Atrophic, hypertrophic, and keloid scars. The risk of scarring is higher with ablative lasers.[7] Attention to proper laser technique during the procedure and meticulous wound care with prompt treatment of infection after the procedure are both critical to minimizing scarring.[8]
- Hyper- and hypopigmentation (temporary or permanent)
- Hair loss in or near treatment area
- Eye injury
- Ectropion is a risk when the lower eyelids are treated.

Surgical Technique

Chemical Peels

- The patient's hair and clothing are pulled away from the face and covered for protection from spills.
- Skin preparation is performed with a gentle cleanser and toner. Cleaning the skin allows for more even penetration of peeling agents and a more uniform depth of peel.
- Eye protection is placed.
- Rhytids and other depressed areas of skin are covered with petrolatum gel to prevent pooling of peel agents and increased depth of peeling.
- Cardiac monitoring is necessary for phenol-based peels.
- For medium and deep peels, the face should be divided by quadrants or aesthetic subunits, and the peel should be applied to one subunit at a time. Subunits with thicker skin (e.g., forehead) should be treated first and subunits with thinner skin (e.g., nose, chin, upper lip) should be treated last.[2]
- For peels with a risk of systemic toxicity, such as phenol-containing peels, a break of 10 to 15 minutes should be taken between each subunit. This spaces out the application of phenol and reduces the risk of toxicity. The full treatment time for a phenol-containing peel should be 60 to 90 minutes.[9]
- Facial peels should be feathered just past the hairline and just under the jaw, to allow the peeled area to blend in with unpeeled surrounding skin. The peeling agent is not applied to the periorbital areas or lips.
- Some peels are applied in layers (e.g., Jessner's and trichloroacetic acid [TCA] peels). The skin should be monitored for 5 minutes prior to applying a second layer. Another layer should be applied only if clinical signs of adequate or excessive peel depth have not occurred.
- The face should be monitored for signs of peel progression and excessive peel depth. Signs of excessive depth are agent-dependent and are discussed below.
- Many peels will show frosting, a whitening of the skin, as a peel endpoint. An example of mild frosting is shown in Fig. 159.2.
- Some peels require neutralization at the end of the procedure.

Glycolic Acid Peel

- An alpha-hydroxy acid that can be used as a very superficial (concentration of 20% to 35%) or superficial (concentration of 50% to 70%) peel
- A timed peel that requires neutralization after 3 minutes (or sooner, based on clinical signs)
- Peel neutralization is performed using either water or a 10% to 15% sodium bicarbonate solution applied to a gauze sponge and wiped across the face. Neutralization should be repeated 2 to 3 times to ensure termination of the peel.
- Desired endpoints for a glycolic acid peel are mild erythema or a 3-minute peel duration.
- Clinical triggers for peel termination prior to 3 minutes are severe discomfort or blanching or blistering of the skin.

Salicylic Acid Peel

- Contraindicated in patients with allergy to aspirin
- A beta-hydroxy acid used in concentrations of 20% to 30% for a superficial chemical peel. Increasing the concentration increases peel depth.
- Apply peel and set timer.
- A thin white precipitate will form on the skin a minute or two following the application of the peel. Wait 2 to 3 minutes more and wipe off precipitate with gauze. If there is no erythema of the skin or significant patient discomfort, another layer may be applied.
- Increasing the number of layers applied increases the depth of penetration of the peel. A maximum of three layers should be applied per peeling session.
- Treatment area must be limited to less than 25% of total body surface area to avoid salicylate toxicity.
- Self-neutralizing; neutralization is not necessary at the end of the peel
- Signs of overly deep peeling include moderate to severe pain or severe erythema or blistering of skin. If these signs are present, the peel should be wiped off immediately with moist gauze rather than waiting for the peel to self-neutralize.



Fig. 159.2. A, Demonstrates mild frosting that occurred following a combination of a single layer of glycolic acid 35% peel and a single layer of Jessner's peel. **B,** Thirty minutes following the peel application, the frosting has resolved.

Jessner Peel (Lactic Acid 14 g, Salicylic Acid 14 g, Resorcinol 14 g and Ethanol to 100 mL)

- Contraindicated in patients who are allergic to aspirin
- Application and monitoring are as for salicylic acid peels.
- Results in a very superficial peel if applied with 1 to 3 layers or a superficial peel if 4 to 7 layers of solution are applied
- Neutralization is not necessary.
- Most commonly used as a very superficial peel with 1 to 3 layers and an endpoint of mild skin erythema
- An attempt should be made to remove the peeling agent with saline-soaked gauze if signs of overly deep peel are noted, including moderate to severe pain or skin blistering.

Trichloroacetic Acid Peel

- TCA can be used for superficial (concentration 10% to 25%), medium (concentration of 30% to 40%), or deep (concentration above 40%) peels. TCA is rarely used for deep chemical peels.
- Apply peel in quadrants, then set timer. The peel takes 2 to 3 minutes to achieve full effect.
- Assess skin for response to peel. Minimal skin erythema corresponds to a very superficial peel. Mild skin whitening accompanied by erythema indicates a superficial peel. Complete white frosting without erythema represents a medium depth peel involving the papillary dermis.[2]
- If desired skin findings are not seen, another layer may be applied. Increasing peel layers leads to a greater depth of penetration.
- Self-neutralizing, but peeling agent should be washed off if signs of greater than desired peeling depth occur (e.g., severe pain, skin blistering)
- TCA peels have higher risk of pigmentary complications than glycolic or salicylic acid peels, and caution should be used in patients with darker skin types (Fitzpatrick IV to VI).

Fractional Nonablative Laser Resurfacing

- Each laser has device-specific guidelines set forth by the manufacturer. The laser operator must have training and familiarity with the specific device being used. The below steps should only serve as a general guideline for laser use.
- Clean the skin with a gentle cleanser and dry the skin.
- If necessary, topical anesthesia ointment is applied to the area to be treated and a waiting period should be observed for this to take effect.
- Cover tattoos with moist gauze. Less experienced operators should not perform laser resurfacing if there is a tattoo in the desired treatment area due to increased risk of burns.[2]
- Laser-specific eyewear must be given to everyone in the room to prevent eye injury. Fig. 159.3 demonstrates the array of safety goggles necessary, as each laser requires wavelength-specific goggles. The patient may wear lead goggles. The patient's contact lenses should be removed.
- Laser settings (spot size, fluence, density) should be chosen based on the Fitzpatrick skin type and patient history. Higher Fitzpatrick types require less aggressive settings.
- The handpiece is held perpendicular to and lightly touching the skin. An example of the technique is shown in Fig. 159.4.
- The skin should be treated in zones or facial units to ensure full coverage of skin.
- The handpiece is passed over the entire treatment area, with 20% to 50% overlap each time the handpiece is moved.
- Slow, continuous motion is preferred.
- Allow time for skin to cool between passes. Failure to do so may result in overheating and scar tissue formation.
- Assess skin after each pass of laser. Depending on the laser, multiple passes may be indicated if skin erythema has not occurred.
- Goals of treatment are mild to moderate erythema and darkening of skin. When these are achieved, no further passes should be performed.
- Signs of overly aggressive settings include petechiae, skin blistering, and development of a gray or white coloration of skin; these should trigger immediate termination of

treatment, and ice packs should be applied to limit thermal damage to the skin.
- Ice packs and hydrocortisone cream may be applied to areas of erythema following treatment.
- Sunblock SPF 30 or greater should be applied before the patient is discharged.



Fig. 159.3. An array of protective laser eyewear. Each laser requires its own wavelength-specific safety goggles.

Ablative Laser Resurfacing

- Each laser has device-specific guidelines set forth by the manufacturer. The laser operator must have training and familiarity with the specific device being used. The steps below should only serve as a general guideline for laser use.
- Anesthesia with topical cream, sedation, or nerve block.
- Remove patient's contact lenses, and apply lead goggles to patient and wavelength-specific protective eyewear to everyone in the treatment room.
- Providers in the room should wear a mask that can block aerosolized particles.
- A suction smoke evacuator should be held above the skin.
- A cool air blower may be positioned above the skin to aid with pain control.
- Laser settings (spot size, fluence, density) should be chosen based on the degree of facial aging.
- Perform trial pulses of laser at edge of area to be treated.
- Hold handpiece perpendicular to skin at distance recommended by manufacturer.
- Pass laser once over skin with no overlap between passes or as recommended by laser manufacturer. Lips and periorbital areas are not treated. Treatment should be feathered close to untreated areas and below the jaw.
- Skin should be assessed for response to treatment at all times. Erythema or slight skin whitening (seen as white dots for fractional lasers) are expected. Blistering or significant bleeding is a sign of overly aggressive treatment.
- Skin should be cooled at the end of the procedure with a cool air blower and ice packs.
- Apply occlusive ointment to skin following the procedure.
- Sunscreen should not be applied; however, patients must be counseled to wear a hat and avoid sun exposure.



Fig. 159.4. This photo demonstrates the positioning of the patient for an Erbium fractionated nonablative laser resurfacing procedure. The handpiece is at 90 degrees to the skin (A) and is gently touching the skin surface (B).

Common Errors in Technique

Chemical Peels

- Failure to standardize preparation and application steps may lead to deeper than expected peeling and a higher risk of complications.[9]
- Failure to feather the peel above the hairline and below the jawline may result in lines of demarcation between peeled and unpeeled skin.

Laser Resurfacing

- Laser resurfacing should not be performed over tattoos due to the risk of burns.
- Pigmented lesions that could represent malignancy should not be treated with laser resurfacing.
- Lower eyelid treatment is an advanced technique and should be performed only by providers with extensive laser resurfacing experience.
- Failure to feather laser adjacent to untreated areas may result in lines of demarcation between treated and untreated areas.

POSTOPERATIVE PERIOD

Postoperative Management

Superficial Chemical Peels

- The skin will begin to peel around day 3 to 5. A gentle skin cleanser and moisturizer should be used daily. Retinoids, hydroxy acids, and other products containing irritants should not be used.
- SPF 30 or greater sunscreen
- Topical hydrocortisone twice daily may be used if erythema is severe.
- The regular skin care routine may be resumed once the peeling has resolved, usually 2 weeks after the peel.

Nonablative Laser Resurfacing

- Ice packs may help with pain control.
- Gentle moisturizer may be used.
- Direct exposure to UV light should be avoided for 4 weeks.

Ablative Laser Resurfacing

- Cold compresses and occlusive (petroleum) moisturizer for the first 24 hours
- Days 2 to 5 clean skin with gentle cleanser
- Complete UV avoidance

Complications of Chemical Peel and Laser

- The appropriate choice of resurfacing agent based on Fitzpatrick and Glogau scales will minimize potential complications.
- Deeper than intended resurfacing may lead to pigmentary complications and scarring. Care must be taken to standardize peeling regimens, and close skin monitoring during treatment is essential.
- Severe postprocedure pain should prompt evaluation for infection.

Alternative Management Plan

- Microdermabrasion or dermabrasion
  - A mechanical skin exfoliation comparable to the chemical exfoliation achieved by chemical peels. A disadvantage is the potential for aerosolization of exfoliated skin, with associated risk for blood-borne pathogen exposure.
- Botulinum toxin and dermal fillers
  - Treat dynamic and static rhytids and volume loss, but do not rejuvenate photoaged skin.
- Surgical treatment of photoaging including brow lift, rhytidectomy, and platysmoplasty are complementary techniques but do not directly address the epidermal and dermal results of photoaging.

DISCUSSION

Evidence-Based Medicine Question

Are CO_2 lasers effective in the treatment of hypertrophic scars?

Multiple prospective studies have demonstrated that CO_2 lasers may improve scar pliability and contour. Different lasers can be used to target specific goals. The 585- and 595-nm pulse dye lasers (PDLs) are best suited for the treatment of pruritus and erythema, whereas the CO_2 may be used for the treatment of irregular scar contour.

Editorial Comment

When treating hypertrophic scars, the combination of CO_2 lasers and PDL may be superior to CO_2 laser alone. Because a PDL only penetrates about 1 mm, thick hypertrophic scars may not respond well to PDL. However, multiple split-scar randomized clinical trials have also shown that a PDL can improve scar height, pliability, and erythema, compared with untreated areas. PDL seems to be most effective treating immature hypertrophic scars, which are still hypervascular and erythematous, early in the remodeling phase.

Frederic W.B. Deleyiannis

Access the review questions and additional sources list online at http://www.expertconsult.com

REFERENCES

1. Glogau RG, Matarasso SL. Chemical face peeling: patient and peeling agent selection. Facial Plast Surg 1995;11:1–8.
2. Small R, Hoang D. A Practical Guide to Laser Procedures. Philadelphia: Wolters Kluwer; 2016.
3. Fitzpatrick TB. The validity and practicality of sun-reactive skin types I through VI. Arch Dermatol 1988;124:869–871.
4. Hevia O, Nemeth AJ, Taylor JR. Tretinoin accelerates healing after trichloroacetic acid chemical peel. Arch Dermatol 1991;127:678–682.
5. Hubbard BA, Unger JG, Rohrich RJ. Reversal of skin aging with topical retinoids. Plast Reconstr Surg 2014;133:481e–490e.
6. Wall SH, Ramey SJ, Wall F. Famciclovir as antiviral prophylaxis in laser resurfacing procedures. Plast Reconstr Surg 1999;104:1103–118.
7. Hirsch R. Iatrogenic laser complications. Clin Dermatol 2011;29:691–695.
8. Alster TS, Lupton JR. Prevention and treatment of side effects and complications of cutaneous laser resurfacing. Plast Reconstr Surg 2002;109:308–316.
9. Cortez EA, Fedok FG, Mangat DS. Chemical peels: panel discussion. Facial Plast Surg Clin N Am 2014;22:1–23.

REVIEW QUESTIONS

1. Which facial resurfacing agent is most likely to show improvement in patients with high Glogau score?
   a. Superficial chemical peel
   b. Deep chemical peel
   c. Nonfractional ablative laser resurfacing
   d. B and C
   e. None of the above

2. Superficial chemical peels
   a. Are contraindicated in patients with higher Fitzpatrick skin types
   b. Generally penetrate the epidermis but not the dermis
   c. Are most likely to show effect in patients with higher Glogau score
   d. All of the above
   e. None of the above

3. Risk factors for postprocedure pigmentary complications include
   a. Higher Fitzpatrick skin type
   b. Excessive tanning prior to procedure
   c. Use of oral contraceptive pills
   d. All of the above
   e. None of the above

4. Which of the following statements comparing fractional and nonfractional **ablative** laser resurfacing is true?
   a. Nonfractional ablative laser resurfacing can be used in all Fitzpatrick skin types.
   b. Nonfractional ablative laser resurfacing carries a higher risk of complications.
   c. Fractional ablative laser resurfacing can provide superior results.
   d. A and C
   e. All of the above

5. Which of the following statements comparing fractional and nonfractional **nonablative** laser resurfacing is true?
   a. Nonfractional nonablative laser resurfacing can be used in all Fitzpatrick skin types.
   b. Nonfractional nonablative laser resurfacing carries a higher risk of complications.
   c. Fractional nonablative laser resurfacing can provide superior results.
   d. A and C
   e. All of the above

ADDITIONAL SOURCES

Zide BM, Swift R. How to block and tackle the face. Plast Reconstr Surg 1998;101:840–851.
This review covers sensory nerve blocks that can be used for regional anesthesia of the face. These techniques may be useful when performing in-office facial resurfacing procedures.

160 Cosmetic Botox and Fillers

Robert J. Chiu

INTRODUCTION

Aesthetic procedures have gradually become more mainstream and popular over the past 15 years, largely led by the significant increase in minimally invasive procedures since the US Food and Drug Administration (FDA) approval of Botox Cosmetic treatment for glabellar rhytids in 2002.[1] In 2014, more than 15.6 million cosmetic procedures were performed, of which 13.9 million were minimally and noninvasive procedures (ASPS 2014 statistics). Of the minimally invasive procedures, more than 6.6 million botulinum toxin type-A (BoA) procedures were performed, representing a 748% increase since 2000. More than 2.3 million soft tissue filler injections were performed, representing a 253% increase since 2000.

A complete discussion of minimally and noninvasive cosmetic procedures would also include adipose tissue transfer/injections, chemical peels, laser skin resurfacing and other laser treatments, intense pulsed light (IPL), ultrasound and radiofrequency devices, sclerotherapy, microdermabrasion, and other procedures. This chapter will focus on the two most frequent noninvasive cosmetic procedures that prospective aesthetic patients seek: BoA neuromodulator injections and soft tissue filler injections. For simplicity, the BoA injections will be referred to as Botox (OnabotulinumtoxinA, Allergan), but it applies to other commercially available botulinum toxin-A products in the United States: Dysport (AbobotulinumtoxinA, Galderma) and Xeomin (IncobotulinumtoxinA, Merz; Table 160.1). The discussion of soft tissue filler injections will be limited to the hyaluronic acid (HA) product lines: Juvéderm (Allergan) injection procedure described can be applied to other HAs used in the United States: Restylane/Lyft/Silk (Galderma) and Belotero (Merz). The technique of Botox and filler injection procedures is summarized in FDA-approved anatomic locations, as well as in more advanced, off-label areas.

KEY OPERATIVE LEARNING POINTS

Preprocedure Period

Patient Selection

The importance of the doctor-patient relationship in aesthetic surgery and medicine should not be diminished, despite the increasing popularity of medi-spas, corporate aesthetic practices, Botox "parties," and the ease at which some minimally and noninvasive cosmetic procedures can be delivered. A patient who is interested in nonsurgical injectable procedures should have a consultation with a physician/surgeon specializing in aesthetic interventions/cosmetic procedures. During the consultation, the physician can ascertain the patient's concerns and goals and be able to offer appropriate recommendations and treatment options.

Patient Assessment

History of Present Illness/Chief Complaint (HPI/CC).

- Patient concerns and goals
  - Personal preferences
  - Gender, social, cultural, ethnic considerations
  - Work and/or family considerations
  - Downtime
  - Cost

History.

- General health
- Aesthetic treatment history
- Past medical history
- Systemic disease
  - Autoimmune/collagen vascular disease
  - Bleeding tendencies/hematologic conditions
  - Reaction to anesthesia
- Localized disease/condition
  - Ocular conditions
  - Herpes simplex virus (HSV)/cold sores
  - Facial nerve weakness/disorders
- History of allergic reactions
  - Severe allergies/anaphylaxis
  - Food allergies: milk and egg products
- Current medications
  - Steroids and other immunosuppressive agents, muscle relaxants, pain medications, anticoagulants (Coumadin or Plavix), psychiatric medications
- Over-the-counter medications and supplements
  - NSAIDs, other blood thinning products
- Females: Pregnancy and breast feeding
- Social history: Smoking and alcohol use
- Psychiatric history and conditions
  - Bipolar disorder
  - Body dysmorphic disorder (BDD)
- Family history: Cardiovascular, psychiatric, hematologic disorder
- Occupation/work history

Physical Examination.

- Skin quality and texture
- Facial sagging and laxity
- Loss of volume/contour deficiencies
- Dynamic and static rhytids
- Examination of face/neck at rest and with dynamic expression
- Scars and/or acne scars
- Pre-existing facial asymmetries/irregularities
- Eyebrow/upper eyelid complex ptosis
- Lower eyelid and cheek complex
- Facial nerve evaluation/facial weakness
- Cranial nerve examination
- Muscles of facial expression: Assess strength and size.
- Weight and height
- Fitzpatrick skin type
- Affect and psychologic presentation

Other.

- Photo documentation
- Informed consent process
- Answer patient concerns/questions
- Follow-up

TABLE 160.1 Injectable Neuromodulators in the United States—Listed by Dates of US Food and Drug Administration Approval

Year of FDA Approval	Product Trade Name (Manufacturer)
2002	Botox (OnabotulinumtoxinA) (Allergan)
2009	Dysport (AbobotulinumtoxinA) (Galderma)
2011	Xeomin (IncobotulinumtoxinA) (Merz)
Pending	PurTox (Mentor)
Pending	RT001 (Topical and Injectable) (Revance)

FDA, US Food and Drug Administration.

The Ideal Patient for Nonsurgical Injectable Treatments.

- Seeks nonsurgical options for rejuvenation
- Has aging changes mostly related to volume loss and/or dynamic rhytids
- Prefers minimal and/or no downtime
- Understands value of periodic ongoing treatments to maintain and achieve best results

Procedure/Treatment

Botox Cosmetic[2]

Indications.

- Dynamic rhytids
- Static rhytids: Mild to moderate rhytids/younger patients
- Brow shaping and sculpting
- Facial sculpting
- Wrinkle prevention

Contraindications.

Absolute Contraindications.

- Known hypersensitivity to any botulinum toxin preparation components
- Ongoing presence of infection at the proposed injection site(s)
- Pre-existing neuromuscular disorders, such as peripheral motor neuropathic diseases, amyotrophic lateral sclerosis, or neuromuscular junction disorders (e.g., myasthenia gravis or Lambert-Eaton syndrome)
- Pregnancy or lactation (category C)

Relative Contraindications.

- Generalized muscle weakness
- Uncontrolled systemic disease and/or patients in poor health
- Pre-existing dysphagia or dysphonia
- Breathing difficulties
- Pre-existing cardiovascular disease
- Presence of inflammation at the proposed injection site(s)
- Baseline eyelid ptosis
- Diplopia
- History of excessive weakness or atrophy in the targeted muscle(s) to be injected
- Unrealistic expectations
- Psychiatric disease
- Drug interactions: Aminoglycosides, calcium channel blockers
- Recent administration of a different botulinum toxin preparation

Pretreatment Planning.

- Selection of neuromodulator (patient and physician preference, clinical situation)
- Determine dose and volume to be injected
- Reconstitution and preparation
- Account for and/or limit other procedures performed at or around the time of injection (other nonsurgical injectable treatments, skin resurfacing procedures, surgical procedures).

Precautions Prior to Injection.

- Notification of any rash or infection near or at the planned injection site
- Avoid blood thinning agents such as aspirin/NSAIDs, fish oils, vitamin E, herbal supplements, and/or alcohol a few days prior to treatment.
- Continue prescribed medications, including medically necessary blood thinners.

Recommended Materials.

- Materials for mixing
  - 21- to 25-gauge needles
  - Preservative-free normal saline
- Digital camera
- Wipes
- Mirror
- Topical anesthetic (benzocaine/lidocaine/tetracaine [BLT] or lidocaine mixture)
- Gloves
- 30-gauge needle or tuberculin syringes
- 1-mL syringe
- Alcohol pads (or other disinfectant skin preparations)
- Bottle opener (to remove rubber stopper of vial)
- Marking pen/pencil
- Gauze pads (4 × 4 or 2 × 2)
- Ice pack
- Medical waste container

Preparation/Dilution/Storage.

- Vacuum-dried powder form in single-use 50-Unit or 100-Unit vials
- 2.5 mL of preservative-free 0.9% sodium chloride diluent to reconstitute each 100-Unit vial, yielding a concentration of 4 Units per 0.1 mL
- Common off-label preparation
  - Preservative containing saline
  - Adjusting diluent quantity (1.0 to 4.0 mL) to yield the desired dose per 0.1 mL
- Stored in refrigerator (2°C to 8°C) and administered less than 24 hours after reconstitution
- Off-label storage: Multiple studies showing preservation of drug potency up to 2 weeks

Botox Injection Technique.

General Considerations.

- Botox Cosmetic effect/timeline
  - Chemical denervation of the injected muscles within the first several days post injection
  - Clinical detectable relaxation of muscles from a few days to 14 days
  - Maximum clinical effect within the first 4 to 6 weeks
  - Duration of effect ranging from 3 to 4 months
- FDA-approved indication/sites: glabella (2002), crow's feet (CF)/lateral canthal lines (2013)
- Off-label use in all remaining upper face, lower face, and neck areas
- Potency units of different neuromodulators not interchangeable
- Use 1:2.5 or 1:3 Unit conversion for Dysport and 1:1 Unit conversion for Xeomin.

Positioning.

- Physician/injector preference
- Recumbent

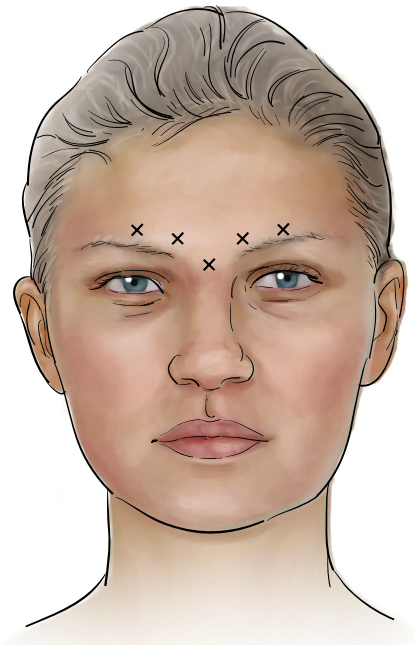

Fig. 160.1. Botox treatment for FDA-approved glabella indication: 4 Units/0.1 mL of reconstituted Botox Cosmetic is injected intramuscularly into each of five sites, two in each corrugator muscle at its inferomedial and superolateral aspect and one in the procerus muscle at the midline, for a total dose of 20 Units. *(Adapted from Botox package insert, Allergan, Inc.)*

- Semirecumbent
- Sitting up

Anesthesia.

- Topical anesthesia—lidocaine based
- Nerve/intraoral blocks
- Cooling devices—Zimmer

Monitoring.

- Possible vasovagal reaction

Key Anatomic Landmarks.

- Muscles of facial expression and neck
- Eyebrow position and shape
- Bony orbit
- Facial vessels

Upper Face Indications for Botox Cosmetic.

- Injections of glabella/frown lines/11's (corrugator/procerus muscles)[4]
  - On-label FDA-approved glabellar indication: 4 Units injected intramuscularly into each of five sites, 2 in each corrugator muscle and 1 in the procerus muscle for a total dose of 20 Units (Fig. 160.1)[2]
  - 10- to 40-Unit range for desired clinical effect/relaxation of the glabella
  - Higher doses needed for active muscles and male patients
- Injections of lateral canthal/CF lines (orbicularis oculi muscle):[3]
  - On-label FDA-approved CF indication: 4 Units are injected intramuscularly into each of six sites, 3 on each side, into the orbicularis oculi muscle for a total dose of 24 Units (Fig. 160.2).[2]
  - Two variant patterns of injecting lateral canthal lines are provided in the trial (see Fig. 160.2).
  - 10- to 30-Unit range for desired clinical effect/relaxation of the CF
  - Concurrent treatment of glabellar lines and lateral canthal lines can be performed with an on-label suggested dose of 44 Units.
- Injections of horizontal forehead rhytids/lines (frontalis muscle):
  - 5 to 20 Units injected intramuscularly into the frontalis muscle
  - Variable pattern and number of injection sites—individualize treatment
  - Counsel patients before injection regarding the possibility of brow position changes and brow ptosis.
  - Use in conjunction with treatment of orbicularis oculi to alter brow shape and position.
- Injections for chemical browlift (orbicularis oculi/corrugators/procerus muscle):
  - 5 to 20 Units total injected into the superolateral portion of the orbicularis oculi in the lateral third of the brow
  - Keep injections superior and lateral to the orbital rim to minimize ptosis.
  - May need to treat brow elevator to achieve desired brow height and shape
  - Can achieve a modest nonsurgical browlift of up to a few millimeters
- Treatment of bunny lines (overactive procerus muscle):
  - Indicated for patients with excessive horizontal nasal lines
  - Can be unmasked by Botox treatment and relaxation of glabellar rhytids
  - In addition to treating the procerus, use small doses (1 to 2 Units Botox or 3 to 5 Units Dysport per side) injected directly over the bunny lines.
  - Injecting too low and lateral can affect the levator labii superioris.
- Injections for "jelly rolls" in the lower eyelid (hypertrophied orbicularis oculi)
  - 1 to 2 Units injected into the lower eyelid pretarsal orbicularis muscle
  - Decreases hypertrophied orbicularis muscle and increases the palpebral aperture
  - Reduced blinking can lead to corneal exposure and related symptoms.
  - Other potential complications include epiphora and edema of the lower eyelid.

Lower Face Indications for Botox Cosmetic.

- Treatment of perioral lip lines (orbicularis oris), oral commissures (depressor anguli oris), and medial chin rhytids (mentalis muscles)
  - Can be used in conjunction with dermal fillers
  - Results are usually less dramatic and duration of effect shorter than those in the upper face.
  - Discuss the possibility of oral incompetence with your patient.
  - Contraindicated for patients who depend on use of muscles in perioral region (i.e., singers, musicians who play wind instruments)
- Injections of perioral (vertical) lip lines (orbicularis oris):
  - Inject the orbicularis oris muscle in small amounts, maximum 1 to 1.5 Units Botox or 3 Units Dysport per site, two to six sites in the upper lip and two to four sites in the lower lips.
  - Stay close (within 5 mm) to the vermilion border.
- Injections of oral commissures (depressor anguli oris muscles):
  - One to two injections (2 to 3 Units Botox or 6 to 9 Units Dysport) each side directly into the depressor anguli oris muscle overlying the mandibular body
  - Avoid injecting medial to the perpendicular line to the oral commissure.

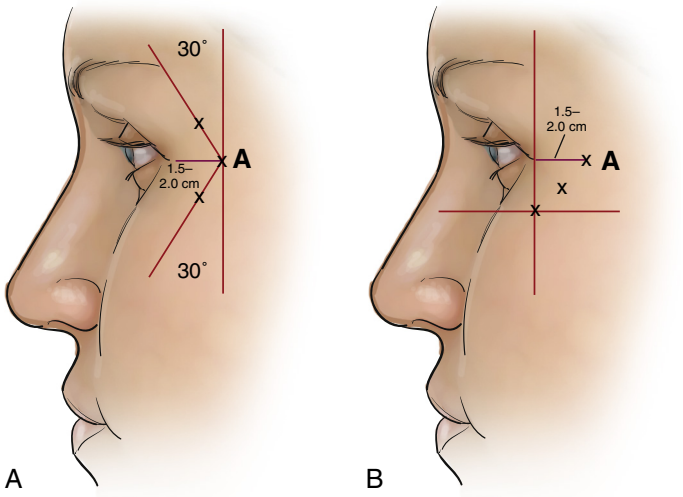

Fig. 160.2. Botox treatment for FDA-approved lateral canthal lines (crow's feet/CF) indication: 4 Units/0.1 mL of reconstituted Botox Cosmetic is injected into three sites per side (six total injection points) in the lateral orbicularis oculi muscle for a total of 24 Units/0.6 mL (12 Units per side). **A,** Standard CF injection pattern—the first injection *(A)* should be approximately 1.5 to 2.0 cm temporal to the lateral canthus and just temporal to the orbital rim, with the second and third injection *(X)* above and below the lateral canthus. **B,** Modified CF injection pattern—the first injection *(A)* should be approximately 1.5 to 2.0 cm temporal to the lateral canthus and just temporal to the orbital rim, with the second and third injection *(X)* below the lateral canthus. *(Adapted from Botox package insert, Allergan, Inc.)*

  - Avoid injecting close to the mouth to minimize complications related to oral incompetence and/or lower lip ptosis.
  - Improves marionette lines and lifts mouth corners (Fig. 160.3)
- Treatment of dimpled chin (mentalis muscle):
  - Two injection sites in a paramedian position near the inferior mandibular border: total of 2 to 8 Units Botox or 6 to 20 Units Dysport
  - Avoid injecting too far lateral or superiorly.

Other Lower Face and Neck Indications for Botox.

- Treatment of gummy smile (depressor septi muscle):
  - Indicated for patients with with "gummy smiles" gingival show upon smile
  - Use small doses (total 1 to 3 Units Botox or 3 to 9 Units Dysport) injected just below the nose into the lip elevator complex (one to two injections).
  - As a nonsurgical treatment option for dynamic ptotic noses
- Treatment of nasolabial folds (NLFs; levator labii superioris alaeque nasi muscle)
  - Patients with short upper lips and/or strong elevation of upper lip upon smile are potential candidates.
  - Use small doses (maximum 1 Unit Botox or 3 Units Dysport per side) injected just below the nose into the lip elevator complex and the levator labii superioris alaeque nasi muscle.
  - Advise patients that their smile pattern may be altered.
  - The area is best treated with dermal fillers.
- Treatment of neck bands (platysma muscle):
  - Consider in older patients who are not candidates for surgery
  - Younger patients who are not candidates yet for facelift surgery
  - Patients with good skin elasticity and minimal submental fullness
  - Botox has no effect on skin laxity or redundancy, laxity, or adipose tissue deposits
  - Requires higher dosages than the lower face
  - Use 10 Units Botox or 30 Units Dysport per platysmal band.
  - Can inject multiple sites per band from the mandible to the lower neck, or inject the band only at the cervicomental angle to recreate it
- Treatment of square jaw (masseter muscle):
  - Injected into the masseter muscle to alter shape of the jawline
  - Popular application in East Asian countries
  - 10 to 25 Units Botox or 30 to 75 Units Dysport used per side (two to four injections)
  - Treatment effect may require multiple sessions, and treatment onset is slower but effects tend to last longer.
  - Adverse effects include mastication difficulty, muscle pain, dysarthria, and awkwardness with smiling.
  - Patients with Temporomandibular Joint Disorders (TMJ) and/or grinding tendency may benefit.

Facial Sculpting Techniques Using Botox Cosmetic

Upper Face.

- Chemical brow lift/elevation
- Brow shaping
- Increase eye opening/aperture

Lower Face.

- Treatment of square jaw (masseter muscle)
- Lifting corners of mouth (depressor anguli orismuscle)
- Alteration of lip size and position (orbicularis oris muscle)

Postprocedure Period

Postprocedural Care

- Avoid lying flat or inversions for 4 hours following injection treatment.
- Avoid strenuous exercise or activity for 24 hours.
- Avoid alcoholic beverages and other blood thinning agents.
- No sun exposure for 7 days

Complications

Potential Risks/Adverse Effects[4]

General Information.

- Can occur within hours to weeks after injection with Botox Cosmetic



Fig. 160.3. Patient before and after Botox and HA filler treatment.

- Generalized reactions: malaise, headaches, Upper Respiratory Infection (URI) symptoms, nausea
  - 5% to 10% of first-time Botox Cosmetic users may experience reactions.
- Pregnancy category C and has not been studied in nursing mothers
- Safety and effectiveness not established in patients younger than 18 years or older than 65 years

Adverse Effects.

- Bruising
- Pain
- Upper eyelid ptosis
- Brow ptosis
- Hematoma (rare)
- Infection
- Loss of facial expression (overtreatment)
- Unsatisfactory reduction of rhytids (undertreatment)
- Unwanted muscle paralysis in distant sites ("distant spread")
- Neutralizing antibodies and loss of therapeutic effect
- Adverse neurologic effects
- Complaint of metallic taste after injections
- Adverse ophthalmic effects
  - Reduced blinking leading to corneal exposure, especially with injection to the medial part of the lower eyelid
  - Diplopia
- Interaction with aminoglycosides, agents interfering with neuromuscular transmission, and may exaggerate the effects of anticholinergic drugs and/or muscle relaxants
- Administering different botulinum neurotoxin products, which are not interchangeable with one another, in close proximity, should be performed with caution.
- Botox contains albumin and carries an extremely remote risk for transmission of viral diseases or Creutzfeldt-Jakob Disease (CJD).

Serious Adverse Effects.

- Rare serious adverse reactions, including some with fatal outcomes, include:
  - Excessive weakness, dysphagia, aspiration pneumonia, respiratory failure, arrhythmia, and myocardial infarction
- Serious hypersensitivity reactions including anaphylaxis

Eyelid Ptosis—Prevention
Glabellar Rhytids.

- Avoid injection near the levator palpebrae superioris, particularly in patients with larger brow depressor complexes.
- Lateral corrugator injections should be placed at least 1 cm above the central bony supraorbital ridge.
Crow's Feet/Lateral Canthal Rhytids.
- Injections should be placed 1 to 2 cm lateral to the bony orbit and directed laterally, not toward the eyeball.

- Injection volumes should be kept below 0.1 to 0.2 mL per injection point, with dose per injection less than 5 Units (Botox Cosmetic) or less than 12.5 Units (Dysport).

Eyelid Ptosis—Management.

- Reassure patient as to transient nature of condition.
- Regular follow-up to address patient's concerns
- Photo documentation
- Prescribe treatment of affected eye with eyedrops.[4]
  - Apraclonidine 0.5% (Iopidine)
  - Phenylephrine 2.5% (Neosynephrine)
  - Eyedrops work on the Müller muscle of the upper lid and can lift the lid up to 1.0 mm.

Eyebrow Ptosis—Prevention.

- Understand that forehead injections can have variable results and require experience.
- Consider injecting brow depressor muscles to offset possible brow ptosis from injecting frontalis muscle.
- Before forehead injections, counsel patients appropriately regarding the possibility of brow ptosis and/or the sensation of heavy brows.
- Consider injecting glabellar and forehead muscles at separate treatment settings.

Eyebrow Ptosis—Management.

- Limited treatment available
- Consider brow depressor muscle treatment.
- Reassurance and support
- Regular follow-up to address patient's concerns
- Photo documentation

Distant Spread of Botulinum Toxin Products.

- Postmarketing surveillance led to reports of events relating to spread of the products' effects beyond the area of injection to other areas of the body, causing symptoms similar to those of botulism.
  - Mostly reported in children with cerebral palsy being treated off-label
  - Some cases also reported in adults treated both for approved and unapproved uses
  - Symptoms can occur several hours to several weeks after treatment.
- In 2009, FDA mandated safety label changes.
  - Boxed warning to all botulinum toxin products alerting to possible distant spread
  - Designed to also highlight the difference in strength and potency of different botulinum toxin products
- Botox Cosmetic for approved indications at recommended doses has not been definitely associated with any serious and/or fatal outcome related to distant spread of toxin effect.

Fillers—Hyaluronic Acid

Overview.

- HA fillers have proven to be very safe and effective, as shown by postmarketing safety data and clinical experience.
- Classified as medical devices
- Designed to be implanted/injected into the mid to deep dermis, submucosa, subcutaneous layer, and/or deep (such as periosteum)
- Safe for use in all skin types
- Potentially reversible
- May stimulate collagenesis
- Restylane and Juvéderm, the two most used fillers in the United States, FDA approved in 2003 and 2006, respectively[5]
- Current marketed HA fillers, with FDA-approved indications (Table 160.2)

Indications.

- Improve moderate to severe rhytids (wrinkles) and folds (such as NLFs)
- Restoration of volume loss
- Facial sculpting and shaping
- Nonsurgical aesthetic rejuvenation

Contraindications and Adverse Reactions

Absolute Contraindications.

- Known hypersensitivity to gram-positive bacterial proteins
- Ongoing presence of infection at the proposed injection site(s)
- Pregnancy or lactation (category C)

Relative Contraindications.

- History of anaphylaxis or multiple severe allergies
- History of lidocaine allergy
- Uncontrolled systemic disease and/or patients in poor health
- Pre-existing cardiovascular disease
- Pre-existing collagen vascular/rheumatologic disease
- Patients on immunosuppressive therapy
- Presence of active inflammation at the proposed injection site(s)
- History of keloid formation, hypertrophic scarring, and/or pigmentation disorder
- Unrealistic expectations
- Psychiatric disease

Pretreatment Considerations

Planning.

- Selection of filler material
  - Patient preference (previous treatment, age, goals, cost, time)
  - Physician preference
  - Clinical indication/situation
  - Site of injection
- Determine amount/volume to be injected.
- Consider filler dilution and/or mixing with lidocaine/epinephrine (off-label).
- Selection of sharp needles versus blunt-tipped microcannulas (off-label)
- Assess for combination therapy (e.g., with Botox treatments) to enhance treatment result and longevity (Fig. 160.4).
- Account for and/or limit other procedures performed at or around the time of injection (other nonsurgical injectable treatments, skin resurfacing procedures, surgical procedures).

Patient Precautions Prior to Injection.

- Notification of any rash or infection near or at the planned injection site
- Avoid blood thinning agents such as aspirin/NSAIDs, fish oils, vitamin E, herbal supplements, and/or alcohol a few days prior to treatment.
- Continue prescribed medications, including medically necessary anticoagulants.
- Avoid smoking.

Recommended Materials.

- Materials for mixing (optional, off-label)
  - 21- to 25-gauge needles
  - 1% lidocaine or 1% lidocaine with 1:100,000 epinephrine
  - 3-mL syringes or 1-mL syringes
- Digital camera
- Wipes

TABLE 160.2 Injectable Fillers Listed by Dates of US Food and Drug Administration Approval

Year of FDA Approval	Product Trade Name (Manufacturer)	Duration of Action	Product Description
2003	Restylane (Galderma)	6–12 months	HA
2004	Sculptra (Galderma)	up to 2 years	PLLA
2006	Juvéderm Ultra (Allergan)	6–12 months	Nonanimal HA
—	Juvéderm Ultra Plus (Allergan)	6–12 months	Nonanimal HA
—	Belafill (formerly Artefill) (Suneva Medical)	up to 5 years	PMMA
—	Radiesse (Merz Aesthetics)	6–12 months	CaHA
2007	Restylane Lyft (formerly Perlane) (Galderma)	6–12 months	Nonanimal HA
—	Sculptra Aesthetic (Galderma)	up to 2 years	PLLA
2010	Juvéderm XC (Allergan)	6–12 months	Nonanimal HA with lidocaine
—	Restylane-L (Galderma)	6–12 months	Nonanimal HA with lidocaine
—	Restylane Lift-L (formerly Perlane-L) (Galderma)	6–12 months	Nonanimal HA with lidocaine
2011	Belotero (Merz Pharmaceuticals)	6 months	Nonanimal HA
—	LaViv (Fibrocell Technologies)	6 months	Autologous fibroblasts
—	Restylane-L for lips (Galderma)	6–12 months	Nonanimal HA with lidocaine
2013	Juvéderm Voluma (Allergan)	up to 2 years	Nonanimal HA
—	Juvéderm Voluma-XC (Allergan)	up to 2 years	Nonanimal HA with lidocaine
2015	Juvéderm XC for lips (Allergan)	6–12 months	Nonanimal HA with lidocaine
2016	Juvéderm Volbella XC for lips and perioral lines	up to 1 year	Nonanimal HA with lidocaine

CaHA, Calcium hydroxylapatite; *FDA,* US Food and Drug Administration; *HA,* hyaluronic acid; *PLLA,* poly-L-lactic acid; *PMMA,* poly(methyl methacrylate).



Fig. 160.4. Patient before and after Botox and HA filler treatment.

- Mirror
- Topical anesthetic (BLT or other lidocaine mixture)
- Gloves
- 25- to 30-gauge needle
- Microcannula
- Alcohol pads (or other disinfectant skin preparations)
- Marking pen/pencil
- Gauze pads (4 × 4 or 2 × 2)
- Ice pack
- Medical waste container
- Eyewash
- Hyaluronidase

Preparation/Dilution/Storage.

- HA filler supplied in individual sterilized packages and ready to use
- Most products today supplied with lidocaine
- Common dilution/mixing (off-label)
  - Diluents containing lidocaine and/or lidocaine with epinephrine
  - Increased comfort
  - Titration of filler viscosity: Allow for more superficial injection
- Off-label storage: Anecdotal

Filler Injection Technique

General Considerations.

- Vary injection depth, quantity, and technique/pattern strategies.
- Topical/injectable anesthesia and/or cold air treatment to minimize discomfort
- Aseptic technique

- Prime the needle/plunger.
- Correct with quantity sufficient to achieve desired volume effect.
- Following injection, gentle massage can be performed (depending on product).
- Mild to moderate injection-site responses, such as swelling and bruising, are to be expected and typically resolve within a few days to few weeks.
- Tailor treatment to individual needs and concerns.
- Proper patient counseling and informed consent process
- Subsequent follow-up to assess the results of the treatment and/or for further treatments

Injection Precautions.[6]

- The product should not be injected into blood vessels.
- Refrain from product use in vascular rich areas, such as the glabella and nose.
- Injector should be look for signs and symptoms of vascular occlusion and embolization: pain disproportionate to the procedure, immediate blanching, skin color changes that reflect ischemia.
- If blanching occurs, the injection should be stopped immediately with massage of area. Massage until it returns.
- Intravascular injection and embolization can lead to symptoms/signs consistent with vessel occlusion/compromise: infarction, ischemia, blindness.
- Dermal filler procedures carry a risk of infection, and standard precautions associated with injectable materials should be followed, not limited to skin disinfection.
- Superficial injections have higher risk of visible lumps and/or discoloration.

Filler Injection Pattern Strategies.[7]

- Serial puncture: Deposition of filler material in small boluses along closely spaced entry points along rhytids
- Linear threading: Filler injected gradually and evenly in the area of desired enhancement as needle is withdrawn (retrograde) and/or advanced (anterograde)
- Serial threading: Combination of serial puncture (small bolus depots) and linear threading techniques (retrograde and/or anterograde)
- Fanning: Linear threading but with needle direction change without needle withdrawal to form a fanlike pattern
- Cross-hatching: Linear threading technique applied in a series of threads that creates a injection pattern grid (at right angles) over the area of desired enhancement
- Depot: Deposition of filler material in medium to larger boluses

Filler Injection Techniques–Cannula/Microcannula.

- Common areas of use
  - Tear trough/infraorbital hollow
  - Cheek
  - NLFs
  - Temples
- Theoretic advantages
  - Decreased discomfort and sequelae versus sharp needle
  - Decreased risk of intravascular injection
- Deep threading and fanning techniques
- Deeper plane of injection (subdermal, subcutaneous, preperiosteal)

Filler Injection Techniques–Filler Dilution.

- Common off-label use
  - Mixing with saline, lidocaine, and/or epinephrine
  - Prior to introduction of lidocaine containing filler products
- Improved ability to inject more superficially
- Can vary dilution and viscosity

Positioning.

- Physician/injector preference
- Recumbent
- Semirecumbent
- Sitting up

Anesthesia.

- Topical lidocaine-based anesthesia
- Nerve/intraoral blocks
- Cooling devices—Zimmer

Monitoring.

- Possible vasovagal reaction

Key Anatomic Landmarks.

- Facial vessels
- Cheeks/midface
- Lips—pink and white lip
- Eyelid/cheek junction
- Eyebrow
- Jawline
- Temples

Hyaluronic Acid Fillers—On-Label Uses

Correction of Moderate to Severe Facial Wrinkles and Folds.

- Dermal implantation/injection
  - Juvéderm Ultra XC, Restylane Silk
  - Lip lines/perioral rhytids
- Mid to deep dermal implantation/injection
  - Restylane/Restylane-L, Juvéderm Ultra/Ultra XC, Juvéderm Ultra Plus/Ultra Plus XC, Belotero Balance
  - NLFs, marionette lines, mouth corners
- Deep dermal to superficial subcutaneous layer
  - Restylane Lyft/Restylane Lyft-L (formerly Perlane/Perlane-L)
  - NLFs, marionette lines, mouth corners
- Submucosal implantation/injection
  - Restylane/Restylane-L, Juvéderm Ultra XC, Restylane Silk
  - Lip augmentation

Correction Midface Contour Volume Loss.

- Deep dermal to superficial subcutaneous layer
  - Restylane Lyft/Restylane Lyft-L
  - Cheek/midface
- Subcutaneous to periosteal (deep) injection
  - Juvéderm Voluma XC
  - Cheek/midface

Anatomic Sites for Hyaluronic Acid Filler Injection/Correction (On-Label).

- NLFs (parenthesis/smile lines)
- Marionette lines
- Mouth corners
- Lip augmentation
- Lip lines/perioral rhytids
- Cheeks/midface contour

Anatomic Sites/Uses for Hyaluronic Acid Filler Injection/Correction (Off-Label).

- Forehead/glabellar rhytids
- Eyebrows
- Temples
- Periorbital
- Nasojugal grove/tear trough/infraorbital hollow (lid/cheek junction) (Fig. 160.5)



Fig. 160.5. Patient before and after Botox treatment to depressor anguli oris muscle.

- Malar smile lines
- Prejowl area
- Jaw shaping
- Earlobe
- Neck lines
- Nose (nonsurgical rhinoplasty)
- Chin (nonsurgical chin augmentation)
- Scars/acne scars

Facial Sculpting Techniques Using Hyaluronic Acid Filler.

- Cheek/midface contouring
- Brow augmentation/shaping
- Upper and lower lid contouring
- Jawline contouring
- Jaw shaping
- Nose reshaping
- Chin augmentation/contouring
- Earlobe shaping

Postprocedure Period

Postprocedural Care

- Within the first 24 hours, patients should avoid strenuous exercise or activity.
- Avoid blood thinners such as alcohol and NSAIDs to minimize ecchymosis.
- Minimize excessive sun or heat exposure to avoid irritation and swelling.
- Minimize manipulation or trauma to injected/filled areas.

Complications

Complications/Adverse Reactions.

- Local injection-site responses usually mild or moderate in intensity
- Most common immediate responses are redness, swelling, pain/tenderness, firmness, swelling, lumps, bruising, itching, and discoloration.
- Most symptoms resolve within 7 days.
- Delayed responses include persistent erythema, nodules/bumps, infection/biofilms, granulomas, telangiectasias and/or other skin discoloration/changes, and Tyndall effect (filler visibility).
- Dryness and peeling of skin
- Pivotal phase III trial of Juvéderm injectable gel (vs. Zyplast), multiple randomized studies, and postmarket safety surveillance of Juvéderm injectable gel showed a similar adverse event profile.

Serious Complications/Adverse Reactions.

- Serious allergic reactions (1:5000)
- Prolonged lumpiness/irregularities
- Prolonged swelling, commonly in the undereye/periorbital area
- Permanent discoloration
- Vascular occlusion/compromise leading to skin necrosis/tissue loss
- Vascular compromise leading to blindness and/or other visual compromise

Vascular Occlusion—Blindness and Visual Compromise

Overview.

- The most serious complication with filler injection procedures
- Vascular occlusion/embolism can lead to tissue compromise/necrosis and/or blindness.
- FDA recent 2015 communication released alerting to risk of intravascular injection with soft tissue fillers

Literature Review.[8]

- Ninety-eight cases of vision changes from filler identified, including one case of death, in association with blindness after 5 mL of autologous adipose tissue injected into the glabella
- Risk of devastating complication of blindness is exceedingly low, considering that more than 5.5 million filler procedures/treatments were performed worldwide in 2014
- Most large case series from South Korea
  - Available data collected from major medical centers with retinal specialists

- Cultural popularity of volumizing high-risk central portion of the face
- Virtually every anatomic location on the face at risk for blindness
- Highest risk sites
  - Glabella (38.8%)
  - Nasal region (25.5%)
  - NLF (13.3%)
  - Forehead (12.2%)
- Every filler type used
  - Autologous adipose tissue (47.9%) was the most common filler type to cause this complication, followed by HA (23.5%).
  - HA complications had better outcomes than autologous adipose tissue, but vision loss was still seen in 39.1% of cases.
- Most common symptoms: Immediate vision loss and pain
- Most cases of vision loss did not recover.
- Central Nervous System (CNS) complications seen in 23.5% of cases

Mechanism.

- Multiple mechanisms proposed for vascular compromise/occlusion
  - Intravascular occlusion
  - Embolization
  - Vessel compression/ischemia
- Intravascular injection mechanism
  - Filler material injected intravascularly can travel in retrograde fashion.
  - Injected bolus can move proximally or distally, in or against the direction of blood flow.
  - Ophthalmic artery has multiple branches and anastomoses to facial vessels in the nose and forehead
  - When filler reaches the ophthalmic artery, the bolus can travel to the retinal artery and cause partial or complete blindness.
  - Further retrograde transport to the internal carotid artery and possible cerebral vascular compromise

Prevention Strategies.

- Know the facial anatomy well.
- Track depth and plane of injection.
- Inject slowly and in small aliquots.
- Aspirate and look for flashback.
- May mix the filler with epinephrine
- Avoid injecting higher risk areas such as the glabella and nose.
- Consider using a cannula in the following anatomic areas: medial cheek, tear trough, and NLF.
- Use extreme caution when injecting in areas that have previously undergone previous surgical and/or nonsurgical procedures.

Management Strategies.

- If a patient complains of ocular pain or vision changes, stop the injection.
- Contact an ophthalmology or oculoplastics colleague and urgently transfer the patient directly.
- Consider treating the injected area and surrounding location with high-dose hyaluronidase.
  - Possible retrobulbar injection of high-dose hyaluronidase
- Monitor the patient's neurologic status and consider brain imaging.
- Other treatment options: warm compresses, digital massage, intraocular pressure-lowering agents (acetazolamide and mannitol), intravenous (IV) and/or oral steroids, aspirin, nitroglycerin paste, hyperbaric oxygen, antibiotics, mechanical and chemical thrombolysis, anterior chamber paracentesis, and/or anticoagulants

Hyaluronidase.

- Makes HA filler treatments theoretically reversible
- Can remove/reverse partial and/or total treatment
  - Bumps/irregularities
  - Prolonged swelling (e.g., lower lid puffiness)
- Variable effect
- Commercially available products
  - Vitrase (bovine)
  - Hylenex (recombinant)
- High-dose hyaluronidase most efficacious treatment for severe vascular complications

DISCUSSION

Evidence-Based Question

Is there a proven difference in the efficacy of different neuromodulators?

Review of existing literature on the three major botulinum toxin-A products (Botox, Dysport, and Xeomin) shows few head-to-head studies, with no definitive advantage of one product over the other. The generally accepted conversion factor between the products are 3:1 for Dysport:Botox and 1:1 for Xeomin:Botox, but consideration should be given to factors not limited to different diffusion properties, as well as modifying techniques to achieve consistent results.

Editorial Comment

Noninvasive rejuvenation procedures are too often promoted as alternatives and/or replacements of surgical rejuvenation, to the detriment of the patients' needs and reflecting misunderstanding of the central components of the aging process. Patients with aging changes predominantly involving descent, tissue laxity, and/or excess skin would benefit more from consultation focusing on surgical options.

Frederic W.B. Delayiannis

Access the review questions and additional sources list online at http://www.expertconsult.com



REFERENCES

1. Carruthers J, Lowe NJ, Menter MA, et al. A multicenter, double-blind, randomized, placebo-controlled study of the efficacy and safety of botulinum toxin type A in the treatment of glabellar lines. J Am Acad Dermatol 2002;46(6):840–849.
2. Botox [package insert]. Irvine, California: Allergan, Inc.
3. Carruthers A, Bruce S, de Coninck A, et al. Efficacy and safety of onabotulinumtoxinA for the treatment of crows feet lines: a multicenter, randomized, controlled trial. Dermatol Surg 2014;40(11):1181–1190.
4. Wollina U, Konrad H. Managing adverse events associated with botulinum toxin type A: a focus on cosmetic procedures. Am J Clin Dermatol 2005;6(3):141–150.
5. Baumann LS, Shamban AT, Lupo MP, et al. Comparison of smooth-gel hyaluronic acid dermal fillers with cross-linked bovine collagen: a multicenter, double-masked, randomized, within subject study. Dermatol Surg 2007;33(Suppl 2):S128–135.
6. JUVÉDERM Ultra Plus XC Directions for Use, JUVÉDERM Ultra XC Directions for Use, JUVEDERM VOLUMA XC DFU.
7. Dayan SH, Bassichis BA. Facial dermal fillers: selection of appropriate products and techniques. Aesthet Surg J 2008;28(3):335–347.
8. Beleznay K, Carruthers JDA, Humphrey S, et al. Avoiding and treating blindness from fillers: a review of the world literature. Dermatol Surg 2015;41(10):1097–1117.

REVIEW QUESTIONS

1. When injecting fillers, which of the following anatomic areas is at high risk for vascular compromise complications?
   a. NLFs
   b. Marionette lines
   c. Nose
   d. Lip

2. Which of the following is NOT a branch of the external carotid artery system?
   a. Labial artery
   b. Lateral nasal artery
   c. Angular artery
   d. Ophthalmic artery

3. Of the following, select the one statement that is true:
   a. Botox injections are contraindicated in the lower face.
   b. Filler injections are contraindicated in the upper face.
   c. Combination therapy with Botox and fillers in certain clinical situations can enhance therapy efficacy.
   d. None of the above

ADDITIONAL SOURCES

Jones D, Murphy DK. Volumizing hyaluronic acid filler for midface volume deficit: 2-year results from a pivotal single-blind randomized controlled study. Dermatol Surg 2013;39(11):1602–1612.

Moers-Carpi M, Carruthers J, Fagien S, et al. Efficacy and safety of onabotulinumtoxinA for treating crow's feet lines alone or in combination with glabellar lines: a multicenter randomized, controlled trial. Dermatol Surg 2015;41(1):102–112.

161 Management of Skin Cancer of the Head and Neck

John Zitelli, Amanda J. Tschetter

INTRODUCTION

Cancer of the skin is the most common form of cancer in humans. The incidence of skin cancer is greater than that of all other forms of cancer combined and is increasing more rapidly than any other, largely because of an aging population and an increased exposure to ultraviolet radiation. Skin cancer is most common in the 60- to 80-year-old age group, and as our life expectancy and this segment of the population have increased, the incidence of skin cancer has risen dramatically. In addition, since discovery of the health benefits of vitamins in the early 20th century, particularly the role of sunlight and production of vitamin D, sun exposure was advocated for its health benefits. As leisure time increased and convenient transportation offered warm and sunny vacations to those living in colder climates, the lifetime exposure to ultraviolet light increased as well. These and other epidemiologic factors such as the use of tanning beds and a deteriorating ozone layer have, together, resulted in a virtual epidemic of skin cancer affecting an expanded age range of patients. Because the majority of skin cancers arise on sun-exposed areas of the head and neck, it is an important part of operative Otolaryngology.

There are numerous forms of skin cancer as malignant neoplasms may arise from any cell type in the skin.

- Epidermis
  - Epidermal precursor cells → basal cell carcinoma (BCC)
  - Differentiated epidermal cells → squamous cell carcinoma (SCC)
- Melanocytes → melanoma
- Neuroendocrine cells → Merkel cell carcinoma (MCC)
- Adnexal skin cells
  - Sebaceous glands → sebaceous carcinoma
  - Eccrine glands → eccrine carcinoma and microcystic adnexal carcinoma
  - Apocrine glands → extramammary Paget's disease
- Fibroblasts → dermatofibrosarcoma protuberans (DFSP), atypical fibroxanthoma (AFX), and malignant fibrous histiocytoma (MFH)
- Endothelial cells → angiosarcoma
- Smooth muscle → leiomyosarcoma

KEY OPERATIVE LEARNING POINTS

1. Each type of skin cancer has a unique appearance, biologic behavior, prognosis, and response to treatment.
2. Knowledge of the biology of each type of cancer and the optimal operative approach are important prior to beginning treatment.

PREOPERATIVE PERIOD

History

1. History of present illness
   a. How long has the lesion been present? Lesions that have not undergone change for many years tend to be benign.
   b. Has the lesion changed in size? Increasing size or growth is a signal to consider malignancy and biopsy.
   c. Are there associated symptoms? Bleeding commonly indicates malignancy. Dysethesias, paresthesias, anesthesia, or loss of motor function (uncommon) may indicate perineural invasion.
   d. Has the lesion been treated previously? Previous treatment is a signal that the original treatment was inadequate, usually secondary to unrecognized positive margins. Routine pathologic examination only samples the surgical margins, therefore a report of clear margins is only an estimate. In the face of recurrence, retreatment with routine surgery is associated with much higher recurrence rates. Consider Mohs surgery.

2. Past medical history
   a. Medical illness
      Predisposing syndromes that influence management
      1) Basal cell nevus syndrome
         a) Features: multiple BCCs, palmoplantar pits, frontal bossing, hypertelorism, odontogenic keratocysts, skeletal abnormalities, and calcification of the falx cerebri
         b) Relevance: Tumors often appear before puberty and number in the hundreds over a lifetime. Patients typically become discouraged by the need for frequent treatment, are often lost to follow-up, and ultimately reappear with multiple difficult-to-treat lesions.
         c) Management: Counsel to prevent discouragement and lack of regular follow-up. Plan treatments to minimize loss of work/school and quality time. Select treatments with a high cure rate to prevent repeat treatments and minimize deformity.
         d) Adjunctive therapy: Chemoprophylactic treatment with retinoids (topical or systemic) has no long-term benefit. The smoothened receptor inhibitor, vismodegib, is food and drug administration (FDA) approved for advanced cases but is typically limited by intolerable side effects at standard dosing (dysgeusia, gastrointestinal disturbance, weight loss, myalgias, alopecia).
      2) Muir-Torre syndrome (Subset of Lynch syndrome)
         a) Features: at least one cutaneous sebaceous neoplasm (usually a sebaceous carcinoma/adenoma/epithelioma; sometimes a keratoacanthoma) and one visceral malignancy (most commonly colorectal or urogenital)
         b) Relevance: A single cutaneous sebaceous neoplasm warrants further investigation. Truncal lesions are most commonly associated with the syndrome; periocular are more likely sporadic. Testing the pathology specimen for defective mismatch repair proteins via immunohistochemistry is a sensitive screen (detects loss of protein expression of MLH1, MSH2, MSH6, or PMS2 within the tumor) and should be requested. If loss is noted, refer the patient for colonoscopy and genetic counseling.

c) Management: Most patients have only a few cutaneous cancers (curable if treated early) and should be screened regularly during their lifetime (professional and self-examination). Routine gastrointestinal and primary care appointments for visceral malignancy screening are key. Family members should also be tested.

3) Syndrome of multiple trichoepitheliomas
   a) Features: Trichoepitheliomas, benign neoplasms of the hair follicle, appear as small papules on the medial aspect of the cheeks, nose, and upper lip (also, ears and elsewhere); these lesions increase in number and size over the patient's lifetime. Cylindromas and spiradenomas may also be present.
   b) Relevance: Management difficulties arise.
      i) Trichoepitheliomas resemble BCC clinically and histologically; misdiagnosis may occur if an accurate clinical description is not given or if an expert pathologist is not available.
      ii) BCCs often develop within benign trichoepitheliomas and require adequate treatment.
      iii) Pathology examination is complex because of confusion between benign trichoepithelioma and malignant BCC at the margin.
   c) Management: A lesion that is enlarging, ulcerated, or looks different from the others should be biopsied and sent to a dermatopathologist.
4) Dysplastic nevus syndrome; atypical mole syndrome
   a) Arises spontaneously or as an autosomal dominant trait with incomplete penetrance
   b) Features: dozens of clinically atypical nevi, usually greater than 6 mm in diameter, and often with nonuniform pigmentation. Borders appear to diffuse into the surrounding skin (normal nevi have clearly distinct borders). Highest density of nevi on the trunk, head, neck and scalp. Biopsied lesions are labeled as dysplastic nevi (DN) based on pathologic architecture.
   c) Relevance: associated with an increased risk for melanoma
      i) 5% lifetime risk (1% for the average population)
      ii) A single DN may increase the risk.
      iii) Having multiple nevi and a family history of melanoma confers the highest risk, approaching 100%.
   d) Management: Controversy exists regarding diagnosis and treatment.
      i) DN resemble melanoma in some ways (clinically and histologically).
      ii) Biopsies are common because of the irregular clinical appearance.
      iii) Pathologists may have difficulty distinguishing the morphologic and cytologic atypia characteristic of DN from melanoma.
      iv) Margins are often positive.
      v) Ambiguous pathology reports leave management decisions to the clinician, who may be confused about the unresolved controversy.
      vi) DN with mild atypia are benign and do not require excision, regardless of biopsy margin status.
      vii) DN with moderate atypia are also benign. If removal was attempted on biopsy and pathology reports clear margins in the plane examined, we do not recommend re-excision. If biopsy margins are positive, the patient may be followed clinically or re-excision may be performed.
      viii) DN with severe atypia should be conservatively re-excised as one pathologist's DN with severe atypia may be another's melanoma or melanoma in situ (MIS).
   e) Importantly:
      i) DN may be found in patients with or without DN syndrome.
      ii) Melanomas may appear in pre-existing nevi but often develop in normal skin.
      iii) Elective removal of DN does not decrease the risk for melanoma.
      iv) A recurrent nevus may falsely resemble a melanoma on histopathology; a history of previous biopsy or lesion at the biopsy site should be noted in the pathology requisition.
      v) Counsel patients to minimize lifetime exposure to ultraviolet light, to perform regular skin self-examinations, to have yearly checkups by dermatologists, and to understand the genetics for children and close family members.

Diseases associated with skin cancer

5) Oral lichen planus
   a) Chronic inflammatory condition of skin and mucous membranes
   b) Whitening of the vermilion lip, ulceration, thickening of the epidermis, and induration caused by the inflammatory response can simulate SCC clinically and histologically.
   c) Predisposes to development of true invasive SCC
   d) Clinicopathologic correlation is imperative.
6) Solid organ transplant
   a) Skin cancer (majority are SCC) is a serious, nearly universal long-term sequela.
   b) Emphasizes the important role of immune surveillance in the prevention of skin cancer
   c) Patients often become discouraged with the overwhelming number of skin cancers, the need for frequent treatment, and the time and effort required to keep up with therapy.
   d) Neglected or recurrent disease may be life-threatening and is often the cause of death in transplant patients.
   e) Coordinating medical management with the transplant team to optimize the immunosuppressive drug regimen is often advisable.
   f) Early effective treatment, constant surveillance, follow-up, and patient education are imperative.
7) Chronic immunosuppression
   a) Human immunodeficiency virus–positive patients with low CD4 lymphocyte counts have a higher risk for SCC (and other skin cancers). Chronic human papillomavirus infection plays an important role.
   b) Compromises the prognosis of patients with known metastases or those at high risk for metastases

b. Surgery
c. Family history
d. Medications
   8) Many medications increase the risk of postoperative bleeding.

a) Antiplatelet drugs
b) Vitamin K antagonists
c) Direct thrombin inhibitors
d) Factor Xa inhibitors
e) High dose Vitamin E
f) Herbal products (garlic, gingko, feverfew, ginger, and saw palmetto)

9) The risk of postoperative bleeding or hematoma (<1%) is a minor concern in comparison to consequences of myocardial infarction or cerebral vascular accidents; therefore it is ill-advised to stop physician-prescribed anticoagulants for skin cancer surgery.
10) Self-prescribed supplements should be stopped 10 to 14 days prior to surgery.

e. Social history
1) Alcohol
a) Increases risk of postoperative bleeding
b) Advise abstinence for 24 hours leading up to and 48 hours postprocedure.
2) Tobacco
a) Increases risk of flap/graft failure
b) Adversely effects cosmesis
c) Patients should be counseled to quit (or decrease consumption as feasible).
3) Living situation/support system
a) One repair option may be favored over another based on postsurgical needs.
b) May determine ability to pursue adjuvant therapies

Physical Examination

1. Crucial to preoperative planning and decision making
2. Evaluating tumor size and margins
a. Nonmelanoma skin cancers:
1) Tightly stretch the skin under light-emitting diode (LED) examination or operating room lights.
2) Clues to tumor extension of BCC and SCC
a) Subtle pink color (vascular response induced by inflammation)
b) Scar-like white or yellow color (fibrosis and tumor infiltration)
c) Shiny or pearly appearance (underlying tumor lobules obscuring normal fine skin wrinkling)
d) Dermatitis-like appearance
i) Extension of superficial BCC or SCC in situ beyond invasive disease may simulate dermatitis, appearing totally different from the primary tumor (must distinguish from dermatitis due to bandaging).
3) Tumor depth
a) Difficult to estimate beyond simple palpation and movement over underlying structures (Mobile? Attached to bone?)
b. Melanoma of the head and neck
1) Margin assessment is more difficult compared to the trunk/extremities.
2) Lentigines, freckles, seborrheic keratoses, and actinic keratoses (AKs) may all camouflage the margin.
3) In situ extensions at the edge are often amelanotic, simulate dermatitis, or may be totally invisible.
3. Evaluating for local, regional, or metastatic cancer
a. Palpate the regional skin, soft tissues, and lymph nodes to determine the presence of satellite metastases, in transit metastases, or lymph node metastases.
b. Important in SCC, melanoma, MCC, undifferentiated pleomorphic sarcoma (UPS) (previously MFH), and sebaceous carcinoma

Imaging

1. Adjunctive testing to evaluate lymph nodes for metastatic cancer has limited value.
2. Imaging may be useful in obese patients in whom palpation of early clinical disease is difficult.
3. Preoperative imaging to determine the extent of invasion is minimally helpful.
a. Only estimates the likelihood of bone invasion, orbit invasion, or involvement of vital structures of the neck
b. Estimates the extent of gross tumor involvement but cannot detect microscopic extensions of skin cancer in soft tissue that often extend many millimeters from the main tumor mass

Indications

1. Most are surgical candidates.
2. Most skin cancers are small (<2 cm) and can be treated under local anesthesia in the office, ambulatory surgery center, or hospital outpatient setting with or without sedation.
3. Common contraindications to surgery often do not apply to smaller procedures.
a. Anticoagulants may be safely continued (see "Medications" above).
b. Age is generally not an issue.
1) Most tumors require simple, low-risk operative procedures.
2) A short, 1-day procedure is less disruptive to fragile, elderly patients than managing chronic, nonhealing ulcers from untreated skin cancer.

Contraindications

1. True contraindications to skin cancer surgery are rare.
2. *Life expectancy* is more important than age.
a. Consider the biologic behavior of the skin cancer and the patient's health and life expectancy.
1) BCC is a slowly growing cancer that may be asymptomatic for years. There may be no need to treat a small, nonulcerated BCC in a patient with other metastatic disease and a life expectancy of less than 1 year.
2) Treatment of nodular melanoma in an independent 95-year-old patient may be curative and allow the family to celebrate the potential 100-year mark.
3. Extent of disease and the impact of surgery
a. Very rarely, extensive or invasive cancers may require surgery that has a significant mortality rate, impacts quality of life after surgery, or is unlikely to achieve cure. The balance of risks and benefits must be weighed carefully.
1) Is it worthwhile to remove one eye because of a slowly growing BCC in an elderly patient who has little or no vision in the other eye?
2) Is temporal bone resection for management of a "close positive margin" after excision of SCC worth the mortality risk?
4. Informed consent must include the probability of results from treatment versus no treatment, alternative forms of therapy, and palliative treatment options.

Preoperative Preparation: Determining Surgical Margins by Histologic Tumor Type

Histopathology

1. Distinguishes tumor from benign diseases that may mimic cancer

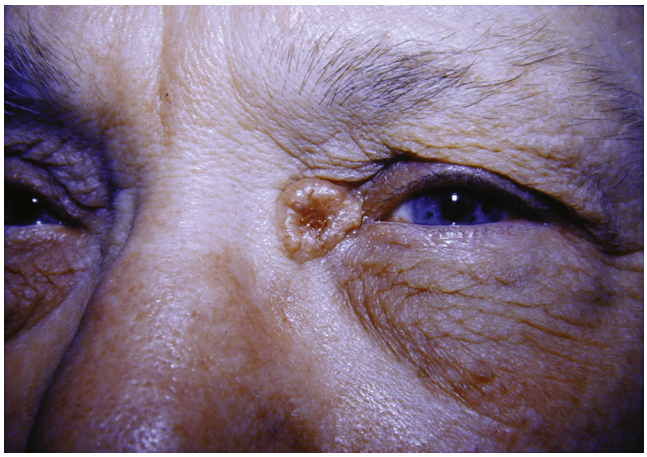

Fig. 161.1. Nodular basal cell carcinoma of the inner canthus.

2. Pathology results should correlate with the clinical picture.
   a. Biopsies are often small samples of a larger lesion and may not represent the entire tumor.
   b. Microscopic appearance of one skin cancer may simulate another (melanoma may be confused with a superficial BCC, and a MCC can be confused with cutaneous lymphoma).
   c. If the patient's history, tumor appearance, and histopathology results do not all correlate, another biopsy is indicated.
3. Histologic diagnosis of tumor type is essential to surgical planning.
   a. Determines the need for evaluation of metastases
   b. Determines width of the surgical margin

Complete removal of skin cancer is achieved through careful patient selection, surgical planning, and extensive examination of the margins by a pathologist. The approach differs according to tumor type. The best chance for cure is the first operation.

1. BCC (Fig. 161.1)
   a. Five-year cure rates of 90% to 95% are achievable by careful selection and planning.
   b. Primary BCC with a diameter ≤2 cm and clearly visible margins requires a 4-mm wide surgical margin.[1]
      1) 1 to 2-mm margins cure some BCCs, but 5-year cure rates are only 50% to 60% (inadequate).
   c. Margin depth is more difficult to estimate and depends more on the location of the tumor and clinical judgment.
   d. High-risk lesions and certain situations require margins wider than 4 mm or careful intraoperative frozen section control:
      1) Morpheaform/sclerosing/infiltrative
      2) Micronodular
      3) Superficial
      4) BCC greater than 2 cm in diameter
      5) Recurrent cancer
2. Cutaneous squamous cell carcinoma (cSCC) (Fig. 161.2)
   a. cSCCs are associated with a significant risk for metastases; however, extra wide margins, excised in the hope of including microscopic satellite metastases, do not improve survival or local control.
   b. Risk for tumor persistence is minimized to an acceptable level when histopathologic sampling confirms negative margins with the following clinical margin widths[2]:
      1) Low-risk cSCC → 4-mm margin
         a) Less than 1 cm in diameter
         b) Location: cheek, neck, and similar
         c) Not invading adipose tissue
         d) Histologic grade 1
      2) Moderate-risk cSCC → 6-mm margin achieves a clear surgical margin in 95% of cases
         a) 10 to 19 mm in diameter
         b) 2- to 6-mm Breslow thickness
      3) High-risk cSCC → 9-mm margin
         a) ≥2 cm in diameter
         b) Greater than 6-mm Breslow thickness
         c) Invasion of subcutaneous adipose tissue
         d) Perineural invasion of nerves with a diameter greater than 0.1 mm
         e) Location: temple, vermilion lip, scalp, ears
   c. Keratoacanthoma → 5-mm margin
      1) Variant of cSCC
      2) Often grows extremely rapidly
      3) May appear as a dome-shaped, crateriform nodule
      4) Spontaneous involution without treatment has been reported
      5) Can be aggressive, destructive, and indistinguishable from true cSCC, including the ability to metastasize
      6) Treatment of choice is complete removal
   d. Squamous cell carcinoma in situ (SCCIS)
      1) A small or large scaly macule or patch
      2) Malignant atypical cells are limited to the epidermis
      3) Squamous atypia extending down hair follicles into the dermis makes treatment more difficult. Deep destruction or full-thickness skin excision is required.
      4) In lesions with minimal or no follicular extension, superficial destruction (curettage, cryosurgery, or laser surgery) is quite effective.
      5) Untreated or inadequately treated SCCIS often progresses to true invasive cSCC with metastatic potential.



Fig. 161.2. Squamous cell carcinoma of the auricle.

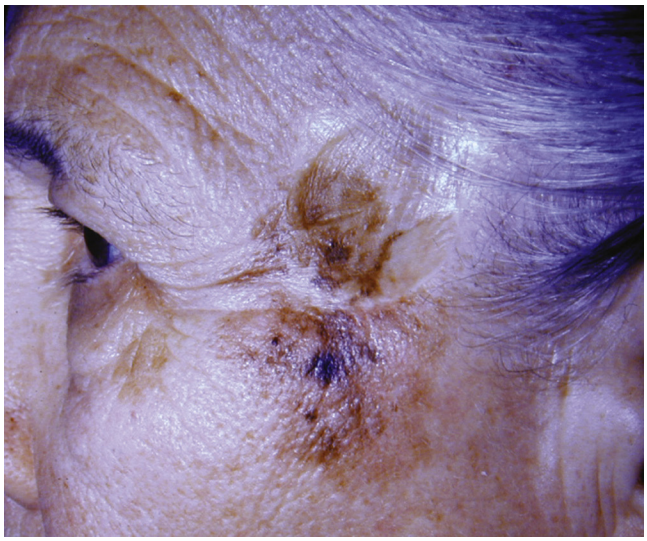

Fig. 161.3. Locally recurrent melanoma on the temple.

3. Melanoma (Fig. 161.3)
   a. Successful excision of melanoma on the head and neck is more difficult than excision on the trunk and extremities.
      1) Margins are more difficult to visualize.
      2) Amelanotic melanomas are more common.
      3) Surgical margins are often reduced for cosmetic or functional reasons.
      4) 9% to 18% of cases recur at the surgical margin because of inadequate excision.
   b. Surgical margins:
      1) A 5-mm margin (consensus statement[2i]) for MIS has no scientific basis and often results in inadequate excision and recurrence of both in situ and invasive melanoma.
      2) 1.2-cm margins cleared melanomas of all thicknesses on the head and neck in 97% of cases.[3]
      3) 1.5-cm margins cleared MIS on the head and neck in 97% of cases.[4]
      4) 5-mm margins clear more than half of MIS on the head and neck, but up to 2.4-cm margins are required to clear 100%.[3,4]
      5) Given that margin requirements may vary greatly from one tumor to the next (an MIS lesion may require 2.4-cm margins whereas an invasive melanoma with a Breslow depth greater than 4 mm may be cleared with a 6-mm margin in more than 50% of the cases), melanomas of the head and neck are best treated by Mohs surgery to confer the highest cure rates possible while preserving tissue to maximize both cosmetic and functional outcomes.
   c. Surgical technique
      1) There is high-level evidence for treating both invasive and in situ melanomas, especially those located on the head and neck, with Mohs surgery.
      2) Interdisciplinary care coordination is possible and effective.
         a) Excision of the primary melanoma by the Mohs surgeon followed by surgical nodal exploration by the head and neck surgeon prior to reconstruction can produce exceptional results with a local recurrence rate of less than 1%.[5]
   d. Recurrent melanoma
      1) Due to inadequate excision
         a) Occurs along the previously treated surgical margin
         b) Histopathology of the biopsy specimen generally shows an intraepidermal component.
         c) Much better prognosis than metastatic recurrence
         d) Prognosis still accurately related to tumor thickness
      2) Due to metastasis
         a) Histopathology of the biopsy specimen generally shows only dermal or subcutaneous components.
   e. Sentinel lymph node biopsy (SLNB)[6]
      1) Slight improvement in estimating a patient's prognosis in comparison with Breslow thickness alone for melanomas 2 to 4 mm thick
      2) Breslow thickness is more accurate than SLNB in melanomas less than 1 mm and greater than 4 mm thick.
      3) Early detection of microscopically positive lymph nodes with complete lymph node dissection may aid in improved regional control, which can be an important benefit in the head and neck, especially in patients who may otherwise neglect regular follow-up or self-palpation of lymph nodes and be seen instead with advanced regional lymph node metastases.
   f. Completion lymph node dissection (CLND)
      1) Value remains unproven
      2) Final results of the Multicenter Selective Lymphadenectomy Trial I (MSLT I) (no SLNB vs. SLNB ± completion lymphadenectomy) showed no survival benefit for SLNB and CLND in patients with microscopically positive disease.[7]
      3) Results of the MSLT-II trial (SLNB-positive patients received completion lymphadenectomy vs. observation with nodal ultrasound), expected in 2022, will hopefully provide further evidence to guide clinical decisions about SLNB and CLND.
   g. Gene expression profiling (GEP)
      1) Test performed on the original formalin-fixed, paraffin embedded tumor
      2) Tumor classified as class 1 (low risk) or 2 (high risk) for the 5-year risk of distant metastasis
      3) More accurately stratifies high- and low- risk patients compared to SLNB
      4) Assay combined with SLNB status can help identify SLNB(−) patients with high-risk disease as well as SLNB(+) patients who are unlikely to show disease progression.
   h. Radiation therapy (RT)
      1) Adjuvant regional RT may decrease local recurrence but does not improve overall survival.
   i. Systemic therapies
      1) Traditional chemotherapy such as dacarbazine showed durable response rates less than 2%.
      2) There has been a relative explosion in melanoma-specific drug therapies in recent years. Advanced therapies are prolonging survival in patients with stage IV melanoma. Numerous ongoing phase III trials are investigating the effects of immunotherapies and cell-signaling effectors in the adjuvant setting for stage III melanoma patients.
      3) Therapies to watch include the following:
         a) Immunotherapies: programmed cell death 1 (PD-1) and cytotoxic T-lymphocyte–associated antigen 4 (CTLA-4) immune checkpoint inhibitors
         b) Cell-signaling effectors: BRAF, MEK and cyclin-dependent kinase 4/6 (CDK4/6) inhibitors
         c) Intralesional therapies: Talimogene laherparepvec (T-VEC), Interleukin-12 (IL-12), and rose bengal (PV-10) intratumoral injections

j. Final points:
1) Primary management remains a surgical issue.
2) Early, complete removal of primary disease is the most important factor.
3) Teaching patients to palpate nodes and soft tissue is important.

4. Adnexal neoplasms
a. Sebaceous carcinoma
1) Malignant tumor of sebaceous glands
2) Commonly occurs on eyelids; also in other sites of the skin of the head and neck
3) Malignant potential similar to cSCC and should be treated as such
4) See section on Muir-Torre syndrome.
b. Microcystic adnexal carcinoma and eccrine carcinoma
1) Clinical appearance similar to BCC
2) Often show extensive subclinical invasion
3) Wider margins are more necessary than for BCC.
4) Complete margin examination or Mohs surgery will minimize the high rate of recurrence.
c. Trichoepithelioma
1) Benign tumor of the hair follicle (see syndrome of multiple trichoepitheliomas)

5. Merkel Cell Carcinoma (MCC)
a. Arises from neuroendocrine cells
b. Nondescript pink or red papule or nodule (rarely diagnosed clinically)
c. Biologic behavior is similar to melanoma
d. Very high risk of metastatic cancer
e. Microscopic extensions of MCC are much wider and deeper than clinical estimates.
f. Wide and deep margins (i.e., 2 cm) are recommended.
g. Careful histologic examination of the surgical margins is important to validate complete excision.
h. Mohs surgery can ensure total excision.
i. If negative margins are not possible or are in question, MCC is very radiosensitive, and RT may improve local control.
j. The role of SLNB and elective lymph node dissection may be similar to that in melanoma, although there is no proven survival benefit.

6. Dermatofibroma Sarcoma Protuberans (DFSP)
a. Tumor of fibroblast origin
b. Presents as a dermal subcutaneous, scar-like mass
c. Often a nodular tumor greater than 2 cm in diameter
d. Invades dermis and fibrous septa between lobules of adipose tissue so microscopic extent is much wider and deeper than is visible or palpable
e. Rarely metastasizes but has high local recurrence rates due to difficulty of clinically estimating microscopic tumor extension
f. Imaging studies are of limited value.
g. Wide lateral margins of 2 to 2.5 cm of normal-appearing skin may be adequate to clear the surgical margins.
h. The deep margins are often the most difficult to estimate.
i. Careful histologic margin control is important.
j. Mohs surgery is very effective and produces the lowest recurrence rates with the narrowest margins possible.

7. Angiosarcoma
a. Malignant tumor of blood vessels
b. Early on it is a purple papule or nodule but is most often detected as a large flat plaque resembling a bruise covering a wide area of the scalp and forehead.
c. Clipping the hair is necessary to see the full extent of disease in hair-bearing areas.
d. Surgical management is difficult:
1) Margins are difficult to evaluate histologically because growth of the malignant vessel is subtle.
2) Small lesions may be excised, but local recurrence and regional metastatic rates are high.
3) Large lesions are often not amenable to surgery because of their extreme size.
e. Radiation Therapy (RT):
1) It is a radiosensitive tumor so that treatment of small lesions improves local control.
2) Employed as the primary treatment for large lesions not amenable to surgery
f. Adjuvant chemotherapy has no proven value for the primary tumor.

8. Atypical Fibroxanthoma (AFX) and Undifferentiated Pleomorphic Sarcoma (UPS)
a. Often present as a pink papule or erosion in sun-exposed areas
b. Resemble SCC or BCC; usually diagnosed only after biopsy
c. AFX
1) Involves only the dermis and superficial adipose tissue
2) Rarely metastasizes
3) Excise with margins similar to those for cSCC
d. UPS
1) Previously "malignant fibrous histiocytoma"
2) Deeper than AFX; involves subcutaneous tissue or muscle
3) High risk of metastasis
4) Excise with a width and depth similar to that for MCC or melanoma
e. Elective regional lymph node dissection
1) Unnecessary for AFX
2) No proven value for UPS

9. Tumors of uncertain behavior
a. Surgeons are often faced with tumors on the head and neck with uncertain biologic behavior.
b. Ultimately, the clinician must process the information described by the pathologist along with the clinical picture to decide whether to manage it as a benign or malignant lesion.
c. Spitz nevi
1) Benign nevi
2) Usually enlarging, red papules in children or young adults
3) Resembles nodular amelanotic melanoma clinically and histologically
4) A classic lesion in a child 16 years or younger with a histologic diagnosis of Spitz nevus from a dermatopathologist does not require excision.
5) Uncertain lesions (lesions arising in adults, those showing cellular atypia or nonclassic histology) should be excised and treated as though they were melanoma (negative surgical margins documented by careful histologic examination).
d. DN
1) See "management" under dysplastic nevus syndrome section.
e. Many cutaneous lesions have overlapping features with their benign and malignant counterparts.
1) Desmoplastic trichoepithelioma can resemble morpheaform BCC clinically and histologically.
2) Other tumors of follicular origin may be difficult to distinguish from BCC with follicular differentiation.

OPERATIVE PERIOD

Anesthesia

General: rarely necessary
Conscious sedation: occasionally necessary (benzodiazepines ± opiates)
Local: preferred as it minimizes the risk to the patient

Positioning

Supine
Prone
Lateral recumbent

Perioperative Antibiotic Prophylaxis

First-generation cephalosporin
Second-generation cephalosporin
Clindamycin if allergic to penicillin

Instruments and Equipment to Have Available

1. 15-blade and blade handle
2. Forceps:
   a. Straight, serrated dressing (aid in margin-controlled excisions to decrease tissue damage)
   b. Adson, Brown-Adson (suturing)
3. Skin hooks (hemostasis, suturing, reconstruction planning)
4. Hemostats
5. Scissors:
   a. Straight iris (serrated or tungsten carbide)
   b. Suture cutting
6. Gauze
7. Cotton-tipped applicators
8. Desiccator or bipolar electrocautery
9. Needle driver
10. Suture
    a. Deep tissue and dermal approximation:
       1) Polyglactin 910/polyglecaprone 25/polydioxanone
    b. Epidermal approximation:
       1) Fast-absorbing surgical gut/polypropelene/polyglecaprone 25
    c. Tissue marking for pathology: any
    d. Securing a bolster:
       1) Silk or polyglactin 910
11. Special site considerations
    a. Eyelid:
       1) Anesthetic drops and eye shield (stainless steel or plastic)
       2) Beaver blade and handle
       3) Scissors
          a) Gradle
          b) Castroviejo curved iris
       4) Castroviejo needle driver
       5) Forceps
          a) Bishop-Harmon
          b) Paufique

Key Anatomic Considerations, Common Errors, and Surgical Repair Techniques by Tumor Location

1. Surgical approach to skin cancer must consider
   a. Tumor type
   b. Anatomic location
      1) Incidence and biologic behavior vary according to location.
   c. Margin verification
      1) Prior to repair there must be reasonable certainty that excision margins are tumor-free via:
         a) Use of evidence-based surgical margin width around a well-defined primary lesion
         b) Negative margins by extensive histopathologic frozen examination of all margins or Mohs surgery for large, deep, recurrent, or poorly defined tumors
            i) Alternatively, delay reconstruction until margins have been determined to be negative by permanent paraffin sections.
      2) Re-excision for positive margins becomes especially difficult after local flaps, complex reconstruction, or repair with extensive undermining of tissue.
   d. Reconstruction options
      1) Each defect is unique with its own challenges, but in most locations, reconstructive choices are predictable and yield reproducible results.
      2) The repair method depends on the likelihood of negative margins, laxity and availability of adjacent skin for closure, and patient's desire for a good cosmetic outcome.
2. Eyelids/periocular region
   a. BCC, SCC, melanoma, and sebaceous carcinoma are most common.
   b. *Anatomic considerations:*
      1) Inner canthus region
         a) BCC tends to invade deeply.
         b) A cancer that appears to be fixed to bone often involves the lacrimal drainage system or extends into the orbit.
         c) The reason for deep extension of small BCCs is not the "embryonic fusion plane" theory but rather that growth of BCCs is stromal dependent.
            i) Only invades tissue with appropriate stromal components
            ii) Show poor, slow growth in adipose tissue
            iii) Grow more quickly in fascia and muscle
            iv) With little protective adipose tissue in the periocular region, BCC quickly invades through the dermis into the deeper tissues of the medial and lateral canthus and orbital septum.
         d) Microscopic extensions are invisible, hard to predict, and not identifiable by MRI or CT.
   c. *Common errors:*
      1) Very difficult to achieve negative histologic margins with narrow surgical margins as clinical margins are often indistinct, especially in superficial BCC on thin eyelid skin and in tumors infiltrating into the lid margin and tarsal plate
      2) Mohs surgery or careful complete margin examination is important for successful management of periocular skin cancers.
   d. Surgical repair techniques
      1) Keys
         a) Protect the eyes, especially the cornea.
            i) Poorly planned repairs may result in ectropion with exposure-induced desiccation of the conjunctiva or keratitis from drying of the cornea.
         b) Suture must be placed in a manner that prevents irritation of the globe.
         c) After the key suture(s) is/are placed, have the patient open the eyes and mouth and look up (placing the eyelid under maximal tension) to check for distortion and to ensure apposition of the lid against the globe.
      2) Eyelid defects
         a) Defects crossing the eyelid margin are often best repaired by an oculoplastic surgeon.
         b) Primary closure
            i) Is easily performed on eyelid skin within the orbital rim
            ii) Care must be taken to move tissue horizontally, even when ellipse orientation is somewhat oblique.
         c) Inferiorly and laterally based rotation flap
            i) Is appropriate for larger defects of the lower lid
            ii) Extend the lateral incision superiorly so that during rotation, when the superior portion of the flap moves medially and inferiorly, the eyelid is not pulled down.

d) Full-thickness skin graft
i) Provides excellent cosmesis in the medial and lateral canthal regions
ii) Secondary choice for lower lid defects as the inevitable shrinkage of the graft increases the risk of ectropion
3) Brow defects
a) Must move hair-bearing skin to maintain brow continuity, even if brow length is shortened
b) Vertically oriented primary closures are appropriate for small defects.
c) V-to-Y flaps are good for larger defects.
d) Hair-bearing, full-thickness composite grafts, harvested from the temples, are rarely necessary.
i) Proper orientation of the hair follicles must be maintained (even to the point of a double graft).
1. Top graft of hair faces inferior and lateral.
2. Bottom graft of hair faces superior and lateral.

3. Ears
a. BCC, SCC, AFX, and melanoma are most common.
b. *Anatomic considerations:*
1) Tumors of the antihelix, conchal bowl, and the external auditory canal tend to invade through the thin skin quickly down to perichondrium and spread laterally with little visual surface change.
2) Sacrificing cartilage may be necessary to achieve negative surgical margins, but tumors rarely invade cartilage.
3) Lack of adipose tissue in the preauricular and postauricular sulcus allows for quick invasion, often making deep negative surgical margins difficult to achieve.
c. *Common errors*:
1) Margins are difficult to outline with certainty so recurrence rates are high.
2) Chondrodermatitis nodularis helicis (focal pressure dermatitis) of the ear can simulate malignancy (biopsy prior to excision).
d. Surgical repair techniques
1) Helical defects
a) Are typically the most challenging to reconstruct
b) Full-thickness skin graft
i) Useful when cartilage and perichondrium (vascular base) are preserved
ii) Donor site: postauricular skin
iii) Provides very good cosmesis
c) Helical rim advancement flap (Fig. 161.4)
i) For defects greater than 1 to 1.5 cm extending to or including cartilage
ii) Cut anteriorly through the skin and cartilage but not through the posterior skin.
1. Undermining/separating the posterior skin from cartilage leaves a large vascular base for the flap.
2. Cutting through anterior skin, cartilage, and posterior skin leaves only a small base of the helix to provide the vascular supply so the tip is often compromised.
d) Advancement flap from the postauricular surface through the postauricular sulcus
i) For large defects on the helical rim
ii) Can be performed as a one- or two-stage procedure
iii) Very reproducible repair
iv) May require cartilage replacement from the ipsilateral conchal bowl if cartilage from the helical rim is missing
2) Scapha defects
a) Split-thickness skin graft
i) For superficial defects
ii) Donor site: postauricular mastoid skin
b) Second intention healing
i) Defects inside the rim of the scapha heal nicely.
3) External canal defects
a) Should be grafted if more than half of the circumference is involved to prevent stenosis of the canal
4) Very large defects involving more than half the ear
a) A prosthesis is often better than reconstruction. Salvaging the tragus helps camouflage the prosthetic border.
b) Wedge resection often yields inferior cosmetic results compared with other reconstruction choices and should be avoided.

4. Lips
a. BCC (upper lip) and cSCC (lower lip) are most common.
b. *Anatomic considerations and common errors:*
1) cSCC is often associated with a dense inflammatory infiltrate making depth of invasion difficult to assess (tumor frequently feels deeper than is seen microscopically).
2) Invasive cSCC of the lower vermilion lip with extensive SCCIS along lateral portions of the vermilion is common (SCCIS often extends much wider laterally than appears clinically).
c. Surgical repair techniques
1) Please see Chapter 27.

5. Nose
a. BCC, SCC, melanoma, and MCC are often seen.
b. *Key anatomic considerations and common errors:*
1) Depth of tumor invasion is difficult to estimate, especially on the lower third of the nose.
a) Underlying cartilage makes it difficult to adequately palpate.
b) Lack of adipose tissue allows early invasion of muscle and fibrous tissue.
c) SCC of the nasal septum frequently invades into the bone of the nasal spine.
2) Recurrence rates for all skin cancers are high; careful margin examination or Mohs surgery is helpful.
c. Surgical repair techniques
1) Please see Chapter 163.

6. Cheeks
a. All forms of skin cancer are seen, including DFSP and angiosarcoma.
b. *Key anatomic considerations and common errors:*
1) Adipose tissue is often a barrier to invasion of deeper structures until the cancer becomes very large.
2) Tumor invasiveness is enhanced by superficially located muscle and aponeurotic layers along the medial portion of the cheek adjacent to the nose and the lateral preauricular cheek. Negative margins are most difficult to achieve at these sites.
c. Surgical repair techniques
1) Please see Chapter 171.

7. Forehead, temple, and scalp
a. All forms of skin cancer are seen.
b. cSCC tends to be aggressive; satellite metastases are common with large tumors.
1) Management of multiple satellite and in transit metastases
a) Surgical excision preferred when possible
b) Adjuvant wide-field radiation for widespread metastasis can be utilized for local/regional control.

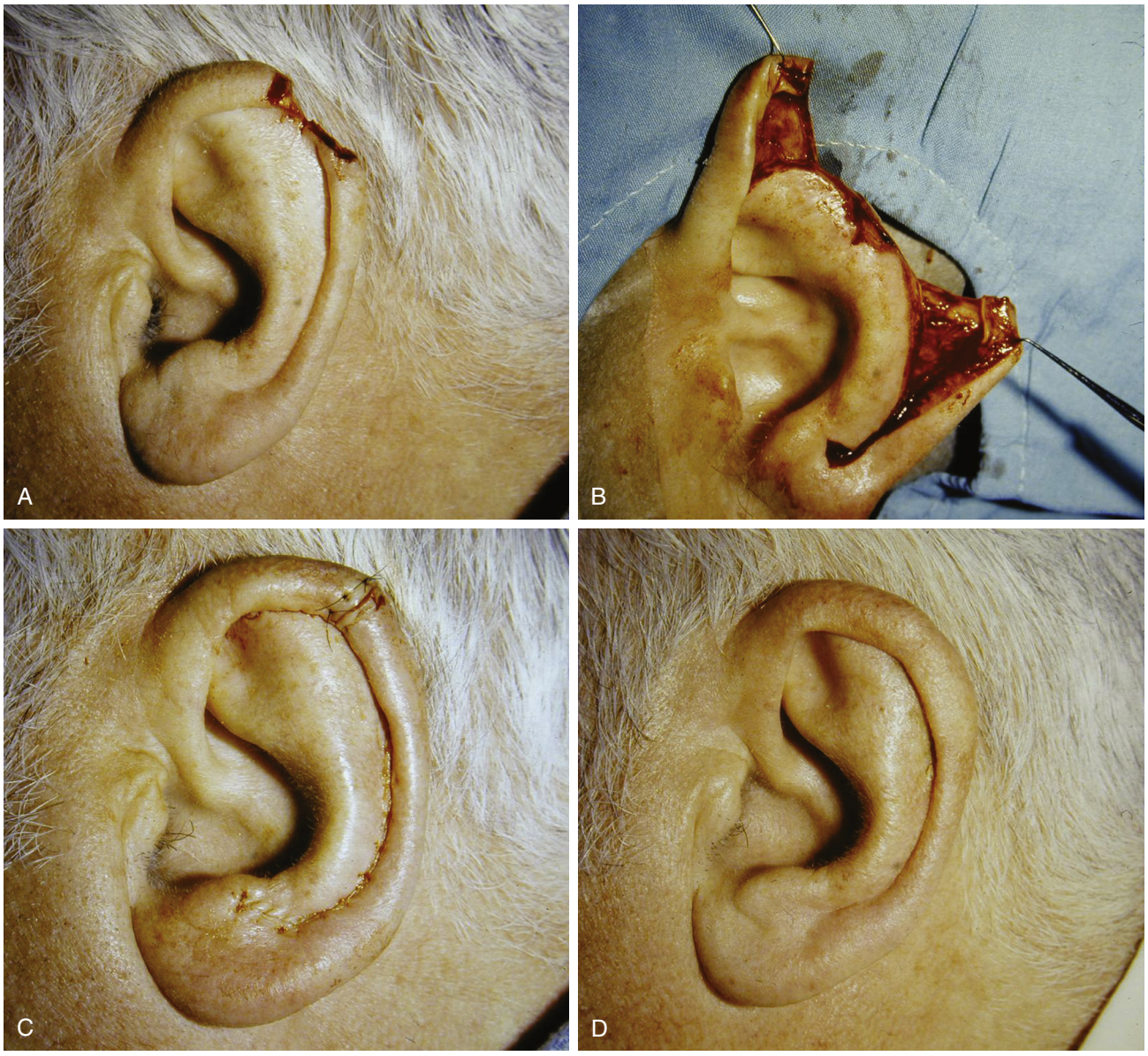

Fig. 161.4. Helical rim advancement flap. A, Defect after excision of basal cell carcinoma. **B,** Bilateral helical rim advancement flaps elevated with a broad posterior base. **C,** Immediate postoperative result. **D,** Cosmetic result after 6 months.

c. Key anatomic considerations
   1) Skull
      a) Acts as a strong barrier to invasion
      b) If bone appears pitted upon removal of periosteum it is assumed that early bone invasion has occurred, and the outer cortex should be removed (via osteotome, bur, or excision). Cover with a split-thickness skin graft.
      c) If bone is exposed but not involved, burring to improve survival of the reconstruction should be performed only as a last resort.
         i) Burring the outer cortex destroys its barrier function to tumor invasion.
         ii) The tumor can then easily invade the bone, making treatment of recurrences a high-risk operation.
   2) Temple
      a) Care should be taken to avoid the temporal branch of the facial nerve during excision and undermining.
d. Common errors:
   1) Early bone invasion is not easily seen with imaging studies and must be assessed intraoperatively.
e. Surgical repair techniques
   1) Please see Chapter 164.

Managing Open Wounds

1. Wounds best managed without reconstruction:
   a. Small biopsy wounds
   b. Wounds after excision of small cancers at the medial canthus, alar crease, ear, forehead, and scalp
   c. Large graft donor sites
2. Predictable events can inform decision making about which wounds can heal and which should be repaired.
   a. Wounds in concave areas heal with better cosmesis than do wounds on convex surfaces.
   b. Scars on pigmented skin or a red, ruddy complexion will be more noticeable than the same scar in pale, white skin.

c. Scars are better camouflaged in skin with other lesions like lentigines or keratoses than in flawless skin.
d. All wounds contract; distortion of nearby structures during healing (eclabion and ectropion) is possible.

Evaluation of Surgical Margins and Pathology Report Interpretation (Prerequisite Skills)

1. The major goal of treating skin cancer is to excise or destroy the tumor completely.
2. Destructive techniques, including RT, rely on a certain amount of guesswork in estimating the margin without the benefit of a tissue specimen to accurately evaluate the success of removal.
3. One advantage of surgical excision is the ability to evaluate the margins to assess completeness of removal.
4. If the goal of surgery is complete excision, and if the surgeon relies on the pathologist to measure the success of excision, the surgeon must understand the process of margin examination.
5. ***Routine tissue processing*** by pathologists:
   a. Involves only margin sampling
   b. Most "bread-loaf" specimens. This technique examines less than 0.1% of the margin.
   c. At best, only an estimate of surgical margin status is reported.[8]
   d. Biopsy of a malignant lesion that was not removed with the intent to include standard surgical margins may be reported by the pathologist to have negative margins, even when visible tumor remains.
   e. Surgeons must keep this in mind when interpreting pathology reports.
   f. It is critical to excise skin cancer with adequate margins of normal skin and only then use the pathologist's report to validate excision results.
6. Intraoperative frozen sections
   a. Give a quick estimate of margins.
   b. Are technically difficult to cut
   c. Intraoperative examination usually samples far less than the 0.1% examined by permanent sections.
   d. Results are followed by more accurate results from permanent sections (better quality for visualization), but these are typically only available days later.
7. ***Peripheral in-continuity tissue examination (en face tissue sectioning)***
   a. Some pathologists are willing to examine a greater portion of the margin.
   b. Strips of tissue from lateral and deep margins are processed from tangential cuts.
   c. Provides a more complete margin assessment
   d. Useful in evaluating a high-risk infiltrating skin cancer or those with clinically indistinct margins
8. ***Mohs surgery***
   a. Method of complete histologic control of the surgical margin[9]
   b. Literally examines 100% of the margin providing the most complete margin examination possible
   c. Excisional method performed under local anesthesia that differs from routine excision by surgical technique and tissue processing
   d. Tissue is excised in a way that allows the entire margin to be flattened into a two-dimensional, one-plane tissue "patty."
   e. This "patty" is cut into pieces for processing like a puzzle, the edges are dyed and numbered for individual identification, and a corresponding puzzle-like map of the specimens is drawn.
   f. Each specimen is processed so that the entire outer surface is examined microscopically.
   g. Results of the microscopic examination are marked on the map.
   h. Any remaining cancer at the margin can be located within the wound by using the map.
   i. The remaining cancer is re-excised in the positive area, reprocessed in the same fashion, and repeated if necessary until a true tumor-free plane is reached.
   j. The initial surgical margin is narrower than traditional margins (because complete margin examination is possible) and is often negative resulting in smaller wounds than those after traditional excision.
   k. Benefits:
      1) A negative margin is ensured with almost certainty.
      2) Recurrence rates are low.
      3) The rate of skin cancer cure is the highest of any method.
      4) Often preserves valuable normal skin for reconstruction by removing tumor with very narrow margins
   l. Mohs surgery as an alternative to routine excision becomes most useful in certain cases:
      1) Skin cancers that might be at higher risk for recurrence
      2) Those in the midface and ears (depth and lateral margins are difficult to estimate)
      3) Previously treated skin cancers (recurrent or those excised with positive margins)
      4) Cancer in areas where the smallest possible wound is important to achieve the best cosmetic or functional result
      5) Infiltrative tumors
      6) Tumors with poorly defined margins
      7) Tumors with high risk histopathologic characteristics that make negative margins difficult to achieve by routine excision
      8) Excisions requiring complex reconstruction
         a) Otherwise, routine surgery should be followed by delayed reconstruction until negative margins are confirmed by permanent paraffin pathology sections.
   m. Like routine excision, it usually requires a half- or full-day time commitment for patients.
   n. Requires special fellowship training because the surgeon also acts as the pathologist to better correlate the pathology results with the clinical tumor margin
   o. Mohs surgeons are an important part of the multispecialty team for the treatment of skin cancer.
      1) Often contribute by completely excising the cancer and working with colleagues for reconstruction after Mohs surgery
      2) Can clear soft tissue margins and identify any remaining tumor near vital structures of the head and neck, such as invasion of bone; perineural invasion extending into the infraorbital, supraorbital, or other important foramen; and invasion of the parotid gland close to the facial nerve
   p. Its costs compare favorably with other office procedures.
      1) In times of limited health care dollars, cost consideration is critical.
      2) Table 161.1 compares costs for the most common treatment options, including the cost from the time of initial evaluation up to and including 5 years of follow-up screening.[10]
9. Positive pathology report
   a. A pathology report with a final diagnosis of a positive margin should be taken seriously.
   b. Approximately 10% to 12% of excision specimens of head and neck cancer are positive for tumor at the margin.
   c. Without further treatment, at least a third will recur and may be difficult to cure after recurrence.

TABLE 161.1 Average Cost of Treating Skin Cancer by Different Methods

Method	Cost, $, Mean (Range)
Destruction (electrodessication and curettage)	392–652[a]
Office excision/permanent section	1,025.83 (438.22–13,459.09)
Mohs surgery	804.72 (544.67–8,397.67)
Office excision/frozen section	1,199.82 (693.49–13,702.18)
Ambulatory surgery/frozen section	2,507.10 (1,141.99–16,761.27)
Radiation therapy	2,559–4,558[a]

[a]Based on other reports referenced in this study.
(From Ravitskiy L, Brodland DG, Zitelli JA. Cost analysis: Mohs micrographic surgery. Dermatol Surg 2012, 38(4):585–594.)

d. When margins are positive, re-excision or Mohs surgery should be attempted.
e. When repeat surgery is not an option, RT may be considered, but the chance for cure is lower than with pathologically documented negative margins.

Operative Risks

1. Postoperative hemorrhage or hematoma
2. Pain
3. Sensory and motor nerve injury
   a. Temporal branch of facial nerve
   b. Marginal mandibular nerve
   c. Greater auricular nerve
   d. Spinal accessory nerve
   e. Branches of supratrochlear and supraorbital nerves
4. Skin and soft tissue infection

POSTOPERATIVE PERIOD

Postoperative Management

1. Immediate concerns
   a. Pain
      1) Most patients claim that the aching after skin cancer surgery is handled well by acetaminophen (smaller procedures) and minor narcotic pain relievers (larger procedures, especially wounds under tension or those involving muscle). Combination therapy with acetaminophen and ibuprofen may be more effective than narcotics.
   b. Bleeding
      1) Often occurs in the first 6 to 8 hours postoperatively
      2) Minimized by careful intraoperative hemostasis, a well-placed dressing that applies pressure over the wound and undermined areas, and instructions to the patient to minimize physical activity
      3) Patients should be instructed that if bleeding occurs, continuous pressure for 20 minutes will stop most bleeding.
2. Patient education
   a. Is an important part of postoperative management
   b. Inform of prognosis and risk for recurrence locally, regionally, and systemically. Differs according to tumor type, size, location, and treatment
   c. Advise about family risks as family members may require screening (see earlier sections on tumor types and syndromes).
   d. Instruct on self-palpation of skin and lymph nodes for patients at risk for recurrence by emphasizing:
      1) The method of palpation (for in transit, satellite, and nodal disease)
      2) That nodes are not usually painful
      3) That most regional recurrances is discovered first by the patient (possibly prior to regularly scheduled follow-up)
   e. Encourage sun protective measures.
      1) Most skin cancers are associated with ultraviolet light exposure.
      2) Minimize exposure by:
         a) Liberal application of a broad-spectrum (Ultraviolet A and B [UVA, UVB] protection) sunscreen
            i) Most people do not apply liberally enough to get the absorption indicated by the sun protective factor (SPF) value, so UVB protection ratings of SPF 30 or higher are better than a rating of 15.
         b) Use of protective clothing
3. Oncologic follow-up
   a. Patients with a history of skin cancer have at least a 40% risk of a second skin cancer within the first 5 years after surgery (higher risk if they have cSCC or a history of multiple skin cancers).
   b. Patients should be instructed in monthly skin self-examinations with a description of the appearance of the skin cancer.
   c. They should undergo full-body examination of the skin by a dermatologist at least yearly for early detection of new skin cancers.
   d. Follow-up schedules to observe for signs of local, regional, or distant disease depend on the tumor type and stage.
      1) High-risk tumors such as MCC, thick melanomas, or deep cSCCs may be monitored every 2 months.
      2) Patients with uncomplicated, low-risk BCC should be seen annually.
4. Cosmetic follow-up
   a. At 1 month:
      1) Tensile strength has developed so patients may massage their wounds to minimize swelling and scar firmness.
      2) Repairs at risk of contraction and distortion (lower eyelid, upper lip, etc.) may benefit from intralesional triamcinolone (40 mg/mL) injection.
   b. At 3 months: Dermabrasion of suture lines (or second intention sites) on thick sebaceous skin of the nose is beneficial.
   c. At 6 months: Re-evaluation for any other revisions can be considered.

Complications

1. Aside from pain and bleeding, most appear in the first few weeks.
2. Surgical site infections are:
   a. Detected as early as 48 hours
   b. Most commonly seen 5 to 7 days postoperatively
   c. Almost always *red* and *painful*
   d. Not always purulent
   e. Defined by the surgeon alone (clinical diagnosis)
      1) There is no absolute set of criteria for infection.
      2) Culture results do not define infection but serve as a guide for appropriate antibiotic therapy once a diagnosis is made.
3. Causes of "redness":
   a. Normal wound healing
   b. Wound infection
   c. Tight closure
   d. Excess intraoperative electrocoagulation
   e. Poor tissue handling or suturing technique
4. Hematomas at the surgical site should be drained if possible.
   a. Usually achievable through a 1- to 2-cm opening in the incision line
   b. Local anesthesia is necessary if the blood is coagulated, and pressure is necessary.

5. Interstitial hematomas:
   a. Occur when blood and fluid infiltrate the tissue without a pooled collection
   b. Cannot be drained
   c. Fortunately, these resolve quickly and completely.
6. Necrosis of flaps and grafts
   a. May begin to occur at 1 week and develop over the subsequent few weeks
   b. It is difficult to estimate the true extent of tissue loss at weeks 1 to 2.
      1) Delay any decision to débride tissue until the full extent of necrosis is evident by the appearance of a black eschar or autolysis and separation of fully necrotic skin.
   c. Dark or violaceous tissue often heals nicely without the need for débridement.
7. Open wounds that fail to heal are very frustrating.
   a. Often caused by one of three conditions:
      1) Overgrowth of *Candida albicans* (most commonly)
         a) Due to topical application of antibiotics and continuous use of occlusive dressings for 3 weeks or longer
         b) Clinical evidence of infection by yeast may be sparse.
         c) Simply adding or switching to a topical anti-yeast medication can promote healing.
      2) Erosive pustular dermatosis
         a) Suspected if the wound does not respond to anti-yeast medications
         b) Commonly occurs on the scalp and forehead (can be seen elsewhere) as superficial erosions with thick, yellow, greasy crusts
         c) Responds quickly to potent topical corticosteroids
      3) Exuberant granulation tissue
         a) If elevated over the wound edges, scraping it with a curette or scalpel may promote wound healing (local anesthesia with epinephrine plus a pressure dressing controls bleeding).
         b) Granulation tissue that is minimally elevated does not interfere with healing; no manipulation is necessary.
         c) Topical treatment with silver nitrate or other caustic agents delays wound healing and should be avoided.

Alternative Management Plan

1. Although surgery usually offers a simple treatment with little pain, delivers specimens for a pathologist to evaluate the success of removal, and is usually accompanied by an aesthetic reconstruction, there are significant reasons to consider alternative methods.
2. In properly selected patients, after considering variables such as tumor type, size, location, and patient expectations of cosmetic results, alternatives can offer cure rates similar to those of surgical excision.
3. *Curettage with electrodesiccation*
   a. Commonly used for small, noninvasive BCC less than 2 cm and very small cSCC or SCCIS
   b. Under local anesthesia, a circular knife 2 to 6 mm in diameter is used in a scraping motion to remove the majority of tumor (soft compared to the normal surrounding dermis).
   c. Scraping is followed by electrodessication of the wound, which destroys an additional 3 to 4 mm of skin and soft tissue.
   d. After removal of the tumor and wider destruction with electrodesiccation, the wound heals by second intention.
   e. A pale but acceptable scar is often left in carefully chosen locations.
   f. Not useful:
      1) If tumor involves adipose tissue, cartilage, or tissue for which one cannot feel the contrast between tumor and normal skin with the curette
      2) In scar tissue, recurrent skin cancers in scar tissue, or infiltrating tumors that cannot be separated from normal dermis
4. *Laser destruction*
   a. For superficial skin cancers confined largely to the epidermis and superficial dermis (superficial BCC, Bowen's disease, or microinvasive cSCC)
   b. Wounds are left to heal by second intention, and pale white scars often result.
   c. Advantages
      1) The ability to destroy very superficial layers of skin with less destruction than occurs with curettage and electrodesiccation
      2) The ability to detect focal invasive areas of tumor during vaporization by their unique "bubbling" reaction (normal dermis simply shrinks)
5. *Cryosurgical treatment*
   a. Liquid nitrogen (a coolant) freezes tumor and adjacent skin.
   b. Kills cells by dehydration or the formation of intracellular ice crystals that then burst the cell
   c. It is often claimed as a method to kill cancer cells and preserve a viable framework of collagen that heals with less scarring.
      1) In practice, the cosmetic result is similar to that achieved with other destructive techniques.
      2) Results are operator dependent (no way to accurately judge the depth of destruction without significant experience).
6. Radiation Therapy (RT)
   a. Was once a popular alternative to surgery that was used by dermatologists and radiation oncologists alike
   b. Operator dependent; experience is needed to estimate not only the width of the surgical margin but also, with more difficulty, the depth of tumor invasion
   c. Ten to thirty visits are required (inconvenient for most patients).
   d. The most expensive treatment option
   e. The advantage is that it provides a cure rate similar to that of surgery without most of the risks and complications of surgery.
   f. It is most useful as an adjunct to surgery:
      1) When surgical margins are positive but the tumor is inoperable
      2) If margins are questionable and there is high risk for recurrence
      3) To provide local control if there is a high risk for satellite metastases (applied around the surgical site)
7. Topical therapy
   a. Topical chemotherapy (5-fluorouracil) and a topical immunomodulator (imiquimod) have been tried with some success.
   b. Food and Drug Administration approval
      1) Both approved only for superficial skin cancers
      2) Imiquimod is not approved for use of skin cancers on the head (AKs only).
   c. Current studies show short-term success rates of 80%; long-term cure rates will likely be lower.
   d. Some consider topical therapy for widespread superficial disease that would otherwise be inoperable or for very superficial tumors that with excision might result in significant cosmetic deformity.
   e. Cost is high, results are interim, and use is limited.

8. Actinic Keratoses (AKs)
   a. Skin colored and erythematous macules with gritty yellow scale
   b. Detection on physical examination by inspection and palpation (often easier to "feel" than to see)
   c. Marker of chronic sun damage; indicates an increased risk of the formation of skin cancer
   d. Considered premalignant: Lesions may self-resolve, persist, or evolve to skin cancer (approximately 10% of lesions over a 10-year period). Treatment is recommended as the course cannot be predicted.
   e. Treatment includes destruction by liquid nitrogen cryotherapy, curettage, shave removal (if hypertrophic), or field therapy.
   f. Field therapy will reduce the number of precancerous lesions and, by this reduction, may prevent formation of invasive skin cancers.
      1) 5-fluoruracil (thymidylate synthase inhibitor; 5-FU) cream or solution
      2) Imiquimod (immune response modifier) cream
      3) Photodynamic therapy ("blue light treatments"; PDT)
         a) Aminolevulanic acid is applied to the skin causing an accumulation of photoactive porphyrins within AKs; upon exposure to blue light a cytotoxic reaction occurs causing the AKs to slough.
   g. Treatment selection
      1) Liquid nitrogen is best for isolated and hyperkeratotic AKs.
      2) PDT is most effective on flat and nonkeratotic AKs.
      3) 5-FU is most effective for widespread and mildly hyperkeratotic AKs.

DISCUSSION

Evidence-Based Medicine Question

What is the most important aspect of Mohs surgery?

Mohs surgery is a method of complete histologic control of the surgical margin; the technique literally examines 100% of the surgical margin. Traditional "bread-loaf" pathologic processing allows the pathologists to examine less than 0.1% of the surgical margin. Complete margin examination by Mohs surgery affords the highest cure rates and lowest tumor recurrence rates of any method (negative margin is ensured with near certainty) while allowing as much normal skin to be spared from the excision as possible. Mohs surgery as an alternative to routine excision becomes most useful in certain cases (see above *"Evaluation of Surgical Margins and Pathology Report Interpretation: Mohs Surgery*).

Editorial Comment

Although they are benign neoplasms, Spitz nevi sometimes have histopathologic features that overlap with those of melanoma. This has led to controversies regarding appropriate strategies for the diagnosis and treatment of this type of nevus. Children are much more likely to develop Spitz nevi than melanomas. Some dermatologists have endorsed the option of longitudinal follow-up for Spitz nevi with classic clinical and dermatoscopic features in children younger than 12 years of age, with subsequent routine evaluations. However, recently proposed guidelines also recommend that a biopsy be done for a Spitz nevus with atypical features such as large size (e.g., >8 to 10 mm), excessive growth, asymmetry, or ulceration in patients of any age.

Frederic W.B. Deleyiannis

Access the review questions online at http://www.expertconsult.com



REFERENCES

1. Wolf DJ, Zitelli JA. Surgical margins for basal cell carcinoma. Arch Dermatol 1987;123:213–215.
2. Brodland DG, Zitelli JA. Surgical margins for excision of primary cutaneous squamous cell carcinoma. J Am Acad Dermatol 1992;27:241–248.

2i. Diagnosis and treatment of early melanoma. NIH Consensus Development Conference. January 27–29, 1992. Consens Statement. 1992 Jan 27–29;10(1):1–25.

3. Bricca GM, Brodland DG, Ren D, et al. Cutaneous head and neck melanoma treated with Mohs micrographic surgery. J Am Acad Dermatol 2005;52:92–100.
4. Felton S, Taylor RS, Srivastava D. Excision margins for melanoma in situ on the head and neck. Dermatol Surg 2016;42:327–334.
5. Etzkorn JR, Sobanko JF, Elenitsas R, et al. Low recurrence rates for in situ and invasive melanomas using Mohs micrographic surgery with melanoma antigen recognized by T cells 1 (MART-1) immunostaining: tissue processing methodology to optimize pathologic staging and margin assessment. J Am Acad Dermatol 2015;72(5):840–850.
6. Bigby M, Popescu C. Sentinel lymph node biopsy in melanoma. BMJ 2015;351:h5940.
7. Morton DL, Thompson JF, Cochran AJ, et al. Final trial report of sentinel-node biopsy versus nodal observation in melanoma. N Engl J Med 2014;370(7):599–609.
8. Abide JM, Nahai F, Bennett RG. The meaning of surgical margins. Plast Reconstr Surg 1984;73:492–497.
9. Zitelli JA. Mohs surgery—concepts and misconceptions. Int J Dermatol 1985;24:541–548.
10. Ravitskiy L, Brodland DG, Zitelli JA. Cost analysis: Mohs micrographic surgery. Dermatol Surg 2012;38(4):585–594.

REVIEW QUESTIONS

1. What percent of the margins have been examined when a routine pathology report of a cancer excision reports "negative margins"?
   a. <0.1%
   b. <1%
   c. <10%
   d. 100%

2. What is the value of prophylactic neck dissection in cutaneous tumors as opposed to intraoral/mucosal tumors?
   a. Mixed value—improves disease-free survival, but adds significant morbidity
   b. Great value—improves disease-free and overall survival, outweighing any added morbidity
   c. No value—no survival benefit is conferred by prophylactic lymph node dissection in any solid tumor (including cutaneous tumors)

3. What is the appropriate management of a biopsy-proven dysplastic nevus with mild atypia?
   a. Excise with 1-mm margins to ensure complete removal.
   b. Excise with 5-mm margins to ensure complete removal.
   c. Excise with 1-cm margins to ensure complete removal.
   d. Clinical monitoring with a dermatologist; excision is not required for this benign lesion

162 Microvascular Reconstruction of the Head and Neck

Frederic W.B. Deleyiannis

INTRODUCTION

Free tissue transfer offers a well-accepted, superior ability to restore form and function to certain major defects of the head and neck. Microvascular surgery provides distinct advantages for reconstruction of osseous defects of the mandible, large glossectomy defects, total or near-total pharyngeal defects, and complex defects of the midface and skull base. Theoretically, any tissue with a defined vascular circuit (i.e., perforator) can be transferred as a free flap, but for reconstruction of defects in the head and neck, there are six free flaps which are particularly useful: the radial forearm free flap (RFFF), the anterolateral thigh (ALT) flap, parascapular and scapular free flaps, rectus abdominis and deep inferior epigastric perforator (DIEP) flap, fibula free flap (FFF), and jejunal free flaps.

KEY OPERATIVE LEARNING POINTS

1. When possible, resected tissue should be reconstructed with tissue that duplicates both the appearance and the function of the resected tissue. Epithelium can be used to resurface mucosal or skin defects. Muscle can be used to restore bulk and motion, and palatal and mandibular skeletal defects can be reconstructed with bone.
2. The ALT free flap, the flap most commonly used for reconstruction of defects in the head and neck, is routinely designed from perforators from the descending branch of the lateral circumflex artery/vein.
3. Multiple options (i.e., medial thigh free flap, tensor fascia lata free flap) from the thigh are available for soft tissue reconstruction, in addition or instead of an ALT free flap.
4. The fibula will provide up to 26 cm of bone vascularized by the peroneal artery and its two venae comitantes.

PREOPERATIVE PERIOD

History

1. History of present illness
   a. Successful reconstruction begins with planning the extirpation of the tumor based on Tumor Node Metastasis (TNM) stage and anticipating the impact of both the extirpation and reconstruction on the patient's quality of life.
   b. Prognosis, dental rehabilitation goals, the need for postoperative radiation therapy, and the type of neck dissection may impact surgical choices (i.e., recipient vessels, type of free flap).
2. Past medical history
   a. Cardiac, vascular, and pulmonary disease, as well as alcoholism, are common in patients with cancer of the head and neck and may independently impact survival and limit reconstructive options.
   b. Radiation induces soft tissue fibrosis, in particular perivascular fibrosis. Therefore, a history of prior radiation and the anticipated decreased vascularity may guide reconstructive options toward using a pedicled or free flap instead of a skin graft.
   c. Previous surgery, such as open abdominal surgery or open reduction and internal fixation of a radius fracture or a tibial fracture, may limit the choice of an extremity or of the abdomen as a donor site.

Physical Examination

1. An Allen test should be performed prior to harvesting an RFFF to ensure the postoperative viability of the hand.
2. Determine whether a patient has a pre-existing hernia of the abdominal wall before harvesting a rectus abdominis, iliac crest free flap, or jejunal free flap.
3. Confirm the presence of a palpable dorsalis pedis and posterior tibialis pulse prior to harvesting a fibular free flap.
4. Palpate the thickness of the thigh to determine its suitability for tissue transfer as an ALT flap.

Imaging

1. Preoperative imaging with a computed tomography (CT) scan and/or magnetic resonance imaging (MRI) to determine the extent of the tumor
2. Pre-bent plates and CT-guided templates can be fabricated prior to surgery to assist in designing and insetting osseous flaps.
3. The need for preoperative vascular assessment prior to fibular transfer is controversial. Large series done without preoperative imaging have reported no adverse sequelae, yet given the prevalence of the risk factors for peripheral vascular disease in the cancer of the head and neck population, others have stressed the need for vascular evaluation. Ankle-arm index screening and color flow Doppler imaging may be more economical and efficient ways to evaluate the vasculature of the lower extremity than angiography or magnetic resonance angiography.

Indications

1. Mandibular defects

   The morbidity of mandibular resection upon function is highly variable.[1,2] The level of postoperative disability depends on (1) the preoperative condition of the oral cavity (including the presence or absence of viable teeth), (2) the extent of mandible to be included in the resection, (3) the site of the tumor (anterior vs. lateral), and (4) the soft tissues to be resected.
   a. When the mandible is resected with an accompanying large amount of soft tissue, the mandibular defect is

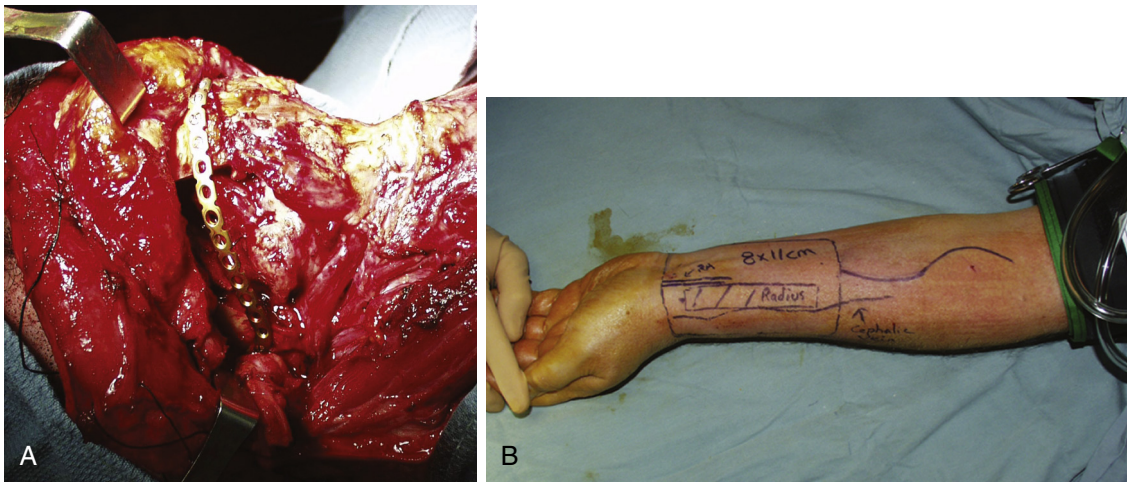

Fig. 162.1. Osteocutaneous radial forearm free flap for a lateral mandibular defect. A, Lateral mandibular and floor of mouth defect after resection of a T4 carcinoma. **B,** Flap design with radius, skin paddle, cephalic vein, and radial artery marked.

sometimes "incidental" to the rest of the wound. Closure of the soft tissue defect with restoration of function and coverage of the planned mandibular reconstruction become the primary goals.

b. Some patients following a segmental lateral mandibulectomy function well without restoration of mandibular continuity. However, a contour deformity of the lower third of the face will develop in patients who have not been reconstructed, and the pull of the contralateral muscles of mastication displaces the remaining mandible toward the side of the defect. In patients with dentition, this results in malocclusion. For these reasons, most surgeons offer patients primary reconstruction of lateral mandible defects with an osseous free flap (i.e., FFF or osteocutaneous RFFF; Fig. 162.1).

c. Numerous reports have supported the use of a reconstruction plate with soft tissue coverage to reconstruct pure lateral mandibular defects (Fig. 162.2). Soft tissue coverage has been generally provided by a pectoralis myocutaneous flap or a soft tissue free flap.

d. Delayed reconstructive failure secondary to external plate exposure or plate fracture has been generally reported to be between 7% and 30%, with soft tissue coverage provided only with a pectoralis flap. These rates of failure would likely be much higher if patients survived longer than 3 years. (Three-year survival of patients selected for reconstruction with a pectoralis flap is 11%.)[2]

e. Resection of the anterior mandible can leave a patient an oral cripple. When reconstruction is not attempted, the retained segments of the mandible tend to collapse toward the midline. This lack of support results in the Andy Gump deformity, with the associated oral incontinence and cosmetic deformity.

f. Free tissue transfer of a composite, osteocutaneous flap is the reconstructive method of choice for anterior defects (Fig. 162.3).

2. Glossectomy defects

a. It is unrealistic to expect a unidirectional, reinnervated muscle, such as the rectus abdominis, to mimic the complex, pattern of muscle contraction in the native tongue.

b. The attainable goals of tongue reconstruction are to preserve the mobility of the remaining tongue and to restore bulk so that the neotongue can contact with the palate to assist in articulation and swallowing.[3]

c. Because of the different functions of the two regions, the tongue is divided into the mobile anterior part and the base of the tongue. The mobility of the anterior tongue is critical for articulation, mastication, and the oral phase of swallowing. The base of the tongue is critical in completing the pharyngeal phase of swallowing.

d. The approach to reconstructing the mobile tongue should involve the use of thin, sensate, pliable tissues (i.e., RFFF or ALT free flap) that maintain maximum mobility and potentially restore sensation.

e. Defects of the base of the tongue present a separate problem. Volume of the base of the tongue must be restored so that the base of the tongue can contact the pharyngeal walls and generate a force to drive the food bolus through the pharynx.

f. Two flaps, in particular an ALT (or a RFFF, rectus abdominis free flap, or pectoralis flap) with a fibular flap, may be necessary for complex composite defects involving a segmental mandibulectomy defect with a glossectomy defect.

3. Pharyngectomy defect

a. The major goal of pharyngeal reconstruction is the restoration of swallowing. It is important to choose a flap that is not too bulky in order to avoid obstruction.

b. ALT (Fig. 162.4), RFF (Fig. 162.5), and jejunal free flaps are the primary options for pharyngeal reconstruction.

c. Laryngeal preservation in the setting of a major pharyngeal defect is especially challenging because aspiration is inevitable. In addition to the patient's preoperative function, designing a reconstruction that can minimize aspiration may be the critical issue that determines whether a patient will require a laryngectomy.

d. In most cases of advanced laryngopharyngeal or pharyngeal cancer, the larynx is resected.

e. If the cervical esophageal resection extends below the thoracic inlet, gastric pull-up continues to be the most reliable way to avoid a salivary leak in the chest.

4. Midface and maxillectomy defects

a. Defects in the midface occur after resection of tumors that arise from the paranasal sinuses, palate, overlying skin, nasal cavity, skull base, orbital contents, or oral mucosa. As a result, extensive reconstruction of the midface may require independently reconstructing the palate, orbit, cheek, and bony midface (maxilla and zygoma).

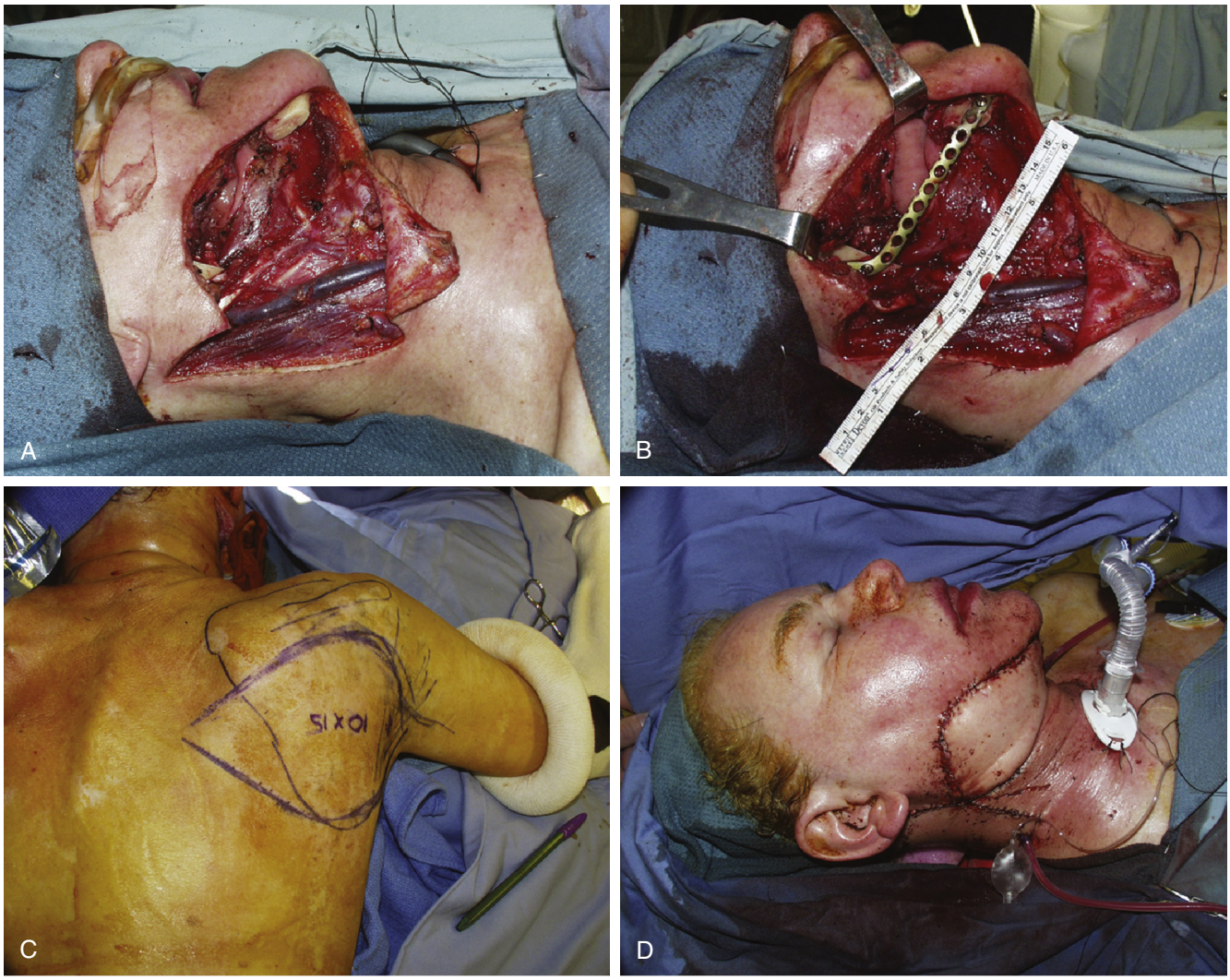

Fig. 162.2. Scapular fasciocutaneous flap. A, Composite resection of lateral mandible, floor of mouth, and cheek skin. **B,** Mandibular continuity restored with a reconstruction plate. **C,** Flap design. **D,** Flap inset with strip of skin de-epithelialized to allow for two skin paddles—one for cheek skin and one for floor of mouth reconstruction.

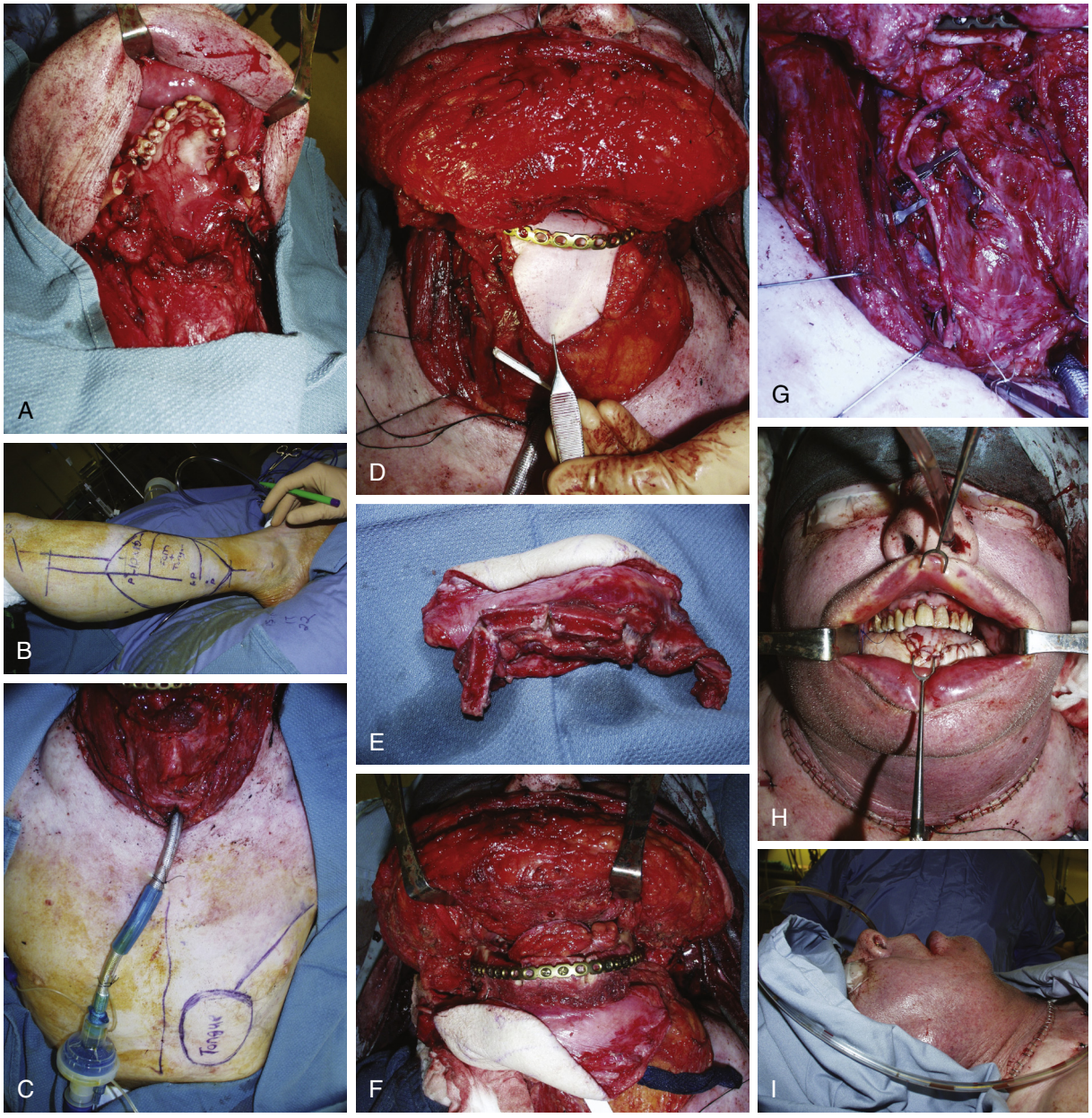

Fig. 162.3. Fibular osteocutaneous free flap and pectoralis major myocutaneous flap for near total mandibulectomy and total glossectomy. A, Near-total mandibulectomy and total glossectomy defect. **B,** Osteocutaneous fibular free flap design: skin perforators (*P*) marked. Skin paddle to be used for floor of mouth and anterior tongue reconstruction. **C,** Pectoralis flap for posterior tongue reconstruction. **D,** Inset of the pectoralis flap. **E,** Closing wedge osteotomies of the fibula. **F,** Inset of the fibular free flap with the skin paddle to be rotated over the plate and to be sewn to the pectoralis flap. **G,** Inset of greater saphenous vein graft into the proximal internal jugular vein stump. Both internal jugular veins had been ligated during the resection. **H,** Final inset—oral cavity. **I,** Final inset—lateral view.

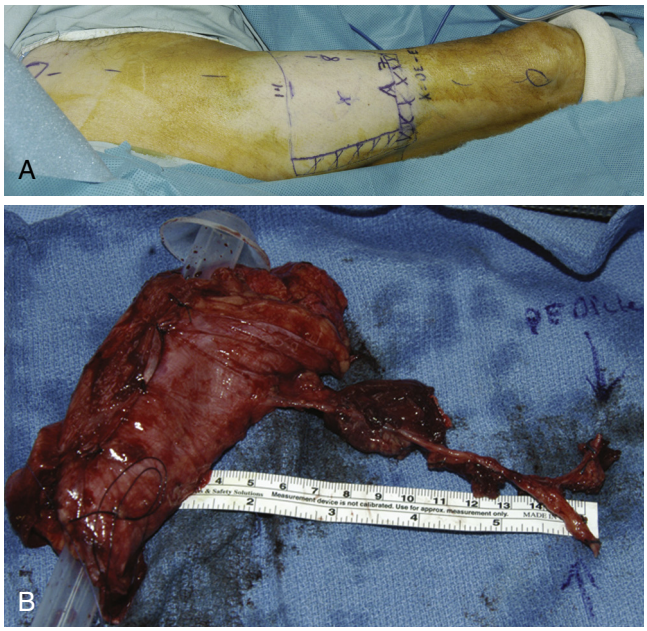

Fig. 162.4. Anterior lateral thigh flap. A, Flap design based on location of perforator. **B,** Total pharyngeal reconstruction using the anterior lateral thigh flap (ALTF). The fascia lata has been wrapped around the reconstruction for an additional layer of closure.



Fig. 162.5. Total pharyngeal reconstruction with a radial forearm free flap (RFFF) harvested with a monitor paddle. Flap design with monitor paddle.

   b. Cordeiro and Santamaria proposed a classification system and algorithm for reconstruction of maxillectomy and midfacial structures.[4] The temporalis muscle, soft tissue free flaps (rectus abdominis and radial forearm), nonvascularized bone (rib or calvarium), and vascularized bone flaps (osteocutaneous RFFF) were used to construct a variety of maxillectomy defects. Palatal defects were closed only with soft tissue. The nonvascularized and vascularized bone were used for the osseous reconstruction of the zygoma, maxilla, and orbital floor.
   c. The use of an FFF for midface reconstruction allows for the osteointegration of implants for dental rehabilitation.
   d. The ALT can be designed with multiple skin paddles, based on separate perforators, to reconstruct many midface/maxillectomy defects.
   e. In cases of combined midface and lip resection, oral competency can be restored by using local flaps, such as the Abbe lip-switch flap, in combination with free tissue transfer.
5. Skull base defects
   a. Although small defects can and should be reconstructed with local flaps, such as pericranial or temporoparietal fascial flaps, many defects in the expanding spectrum of extirpative endeavors will require free tissue transfer.
   b. The main reconstructive needs of skull base defects include separating the intracranial and extracranial spaces to avoid intracranial infections, obliterating the dead space with coverage of vital structures, preventing brain herniation, diminishing the risk of cerebrospinal fluid (CSF) leakage, and restoring cosmesis.
   c. The rectus abdominis, ALT, latissimus myocutaneous (or myofascial), and serratus free flaps are some of the flaps commonly chosen.

Contraindications

1. An expectation of a poor quality of life or of limited survival, regardless of the ability to successfully extirpate the tumor, may change the reconstructive recommendation.
2. Severe peripheral vascular disease and lack of recipient vessels in the neck following previous surgery may make the harvest and anastomosis of a free flap impossible.

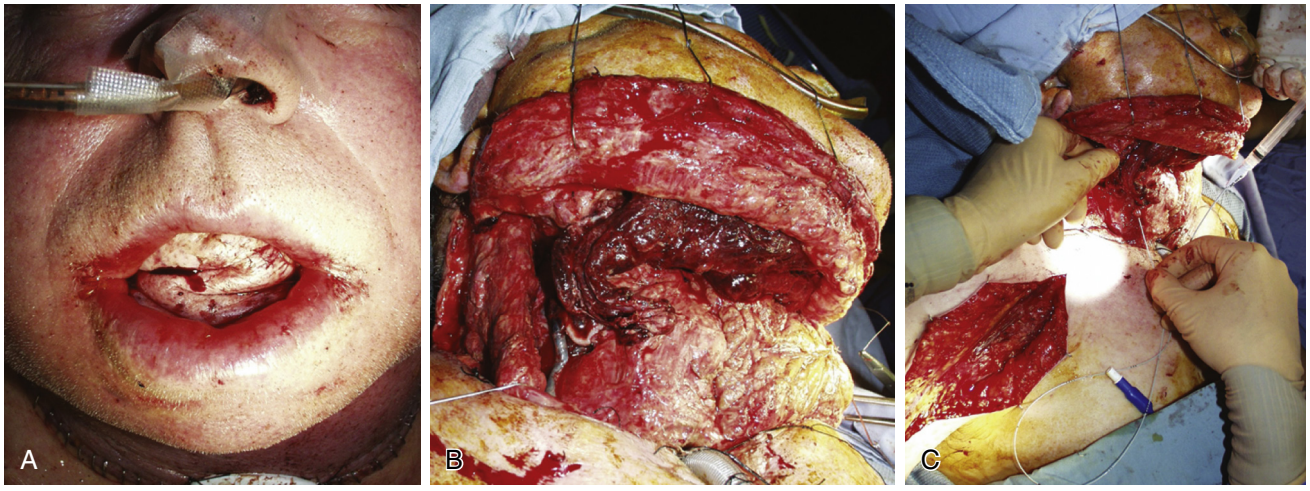

Fig. 162.6. Venous outflow obstruction and restoration (postoperative day #1, same patient as in Fig. 162.3). A, Venous congestion of fibular free flap: bluish blood with pinprick of flap skin paddle. **B,** Saphenous vein graft and internal jugular vein clotted. **C,** Clots in venae comitantes of fibular flap cleared with #3 Fogerty catheter.

Preoperative Preparation

1. Plan for the possible need for a second or backup free or pedicled flap. Protect an extremity so that no venipuncture is done in this extremity.
2. Be sure the tumor margins are clear before finalizing flap design.
3. Determine the recipient cervical vessels likely for anastomosis. If the neck is without recipient vessels, prepare for the possibility of vein grafts from the extremities.

OPERATIVE PERIOD

Anesthesia

General

Positioning

Supine: The bed is turned 180 degrees, allowing simultaneous access to the head and neck by the extirpative team and to the extremities by the reconstructive team. Sequential compression devices are placed on the contralateral leg if a fibula is being harvested and on both legs if an ALT is being harvested.

Lateral decubitus: Used for a scapular free flap and latissimus free flap

Perioperative Antibiotic Prophylaxis

First-generation cephalosporin: For cutaneous defects without communication to the oral cavity or pharynx

Unasyn or clindamycin (if allergic to penicillin): For defects of oral cavity and/or pharynx

Monitoring

None for flap harvest

Instruments and Equipment to Have Available

1. Basic microvascular instrument set and operating microscope
2. Doppler to detect and monitor perforators
3. Craniofacial and mandibular hardware for mandibular and midface bony reconstruction
4. Venous coupler system
5. Implantable Doppler (optional)

Key Anatomic Landmarks

1. Specific to each free flap (see "Surgical Technique")
2. For recipient vessels: Facial, superior thyroid, and transverse cervical arteries; external carotid artery
3. Veins include veins in zones I and V of the neck and the external jugular vein.

Prerequisite Skills

1. Advanced training in microvascular surgery (i.e., a head and neck fellowship and/or plastic surgery fellowship with an emphasis on microvascular reconstruction of the head and neck)

Operative Risks

1. Flap failure: This risk in experienced hands should be well less than 5%.
2. Deep neck infection; oral-cutaneous (or oral-pharyngeal) fistula
3. Pharyngeal stenosis
4. Donor site morbidity: Tendon exposure, failure of skin graft, hernia, extremity swelling, deep venous thrombosis (DVT), decreased ankle, or wrist flexion/extension
5. Harvest of a fibular free flap in patients with peripheral vascular disease (an ankle arm index <1.0) but with three-vessel runoff may still lead to delayed wound healing at the harvest site.

Surgical Technique

1. RFFF
   a. The RFFF is a fasciocutaneous flap deriving its blood supply from branches of the radial artery and venae comitantes that run in the intermuscular septum between the brachioradialis and flexor carpi radialis muscle.
   b. The major advantage of the RFFF is the large amount of thin forearm skin that can be harvested for reconstruction of any associated intraoral and/or external skin defect.
   c. A segment of radius vascularized by vessels passing from the radial artery through the lateral intermuscular septum and perforating vessels through the muscle belly of the flexor pollicus longus may be transferred with the radial forearm flap (see Fig. 162.1A and B).
   d. Approximately 10 cm of bone can be harvested between the insertion of the pronator teres and the insertion of the brachioradialis. A "boat-shaped" osteotomy in preference to right-angle bone cuts may help avoid the complication of a fracture. Only 30% of the cross-sectional area of the radius should be removed to avoid a fracture of the radius.
   e. Provided that the periosteum is carefully preserved on the volar and radial aspects of the segment of the radius, one or two osteotomies may be performed from the medullary aspect to allow reconstruction of anterior symphyseal and parasymphyseal defects.
   f. Whereas the anterior projection of the anterior mandible can be recreated using the osteotomized radial forearm osteocutaneous flap, the vertical height of the anterior mandible cannot be created, and the bony segment is usually too thin to allow placement of osseointegrated implants.
   g. The antebrachial cutaneous nerves of the forearm can be incorporated to create a sensate flap.
2. Anterolateral thigh free flap
   a. An ALT flap is a perforator flap, derived from the descending branch of the lateral circumflex femoral artery.
   b. Its advantages include a long pedicle (8 to 16 cm) with a suitable vessel diameter and the possibility of harvesting the flap with thigh musculature (the vastus lateralis muscle, rectus femoris muscle, and/or the tensor fasciae lata) or as a sensate flap (by incorporating the anterior branch of the lateral cutaneous nerve of the thigh).[5]
   c. To increase the width or length of the flap, an ALT may be harvested with multiple perforators or may be supercharged and/or venous augmented with separate pedicles from the medial, superior, and posterior-lateral thigh (i.e., perforators respectively from superficial femoral artery, ascending or transverse branch of the lateral circumflex artery, and the profundus femoral artery).
   d. Because of its distance to the head and neck, its harvest can be performed simultaneously with tumor extirpation.
   e. Flap elevation begins by mapping the cutaneous perforators with a pencil Doppler probe. These perforators are located by first marking the midpoint between the anterior superior iliac spine and superolateral corner of

the patella (see Fig. 162.4B and D). A circle centered at this midpoint is then drawn with a radius of 3 cm. The majority of the cutaneous perforators are located in the inferolateral quadrant of this circle. The flap is then harvested with its center over these perforators and its long axis parallel to that of the thigh.

f. The skin and subcutaneous tissue are raised until the perforator(s) to the skin is defined. Once the skin perforator is seen, it is dissected until the main pedicle is reached. If the skin vessel (or skin vessels) is a musculocutaneous perforator (the majority of patients), then the harvest includes an intramuscular dissection through the vastus lateralis muscle. If the skin vessel is a septocutaneous perforator, the dissection is simpler and proceeds between the vastus lateralis and rectus femoris muscles.

g. A skin defect less than 9 cm in width can be closed primarily without any reported evidence of compartment syndrome. Larger defects require skin grafting.

h. A distinct disadvantage is the thickness of the flap in overweight individuals. However, the flap can be trimmed to the subdermal adipose tissue level for use as a thinner flap (4 mm).

i. Although the vastus lateralis muscle is a major constituent of the quadriceps femoris, near-normal quadriceps function has been reported when it is taken for reconstruction.

3. Scapular and parascapular fasciocutaneous and osteocutaneous flaps
   a. The branching pattern of the circumflex scapular artery and vein permits the harvest of a number of fasciocutaneous and osteocutaneous flaps for reconstruction of the oral cavity.
   b. The scapular flap is based on the horizontal cutaneous branch of the circumflex scapular artery (see Fig. 162.2 A-D). The parascapular flap is based on the descending cutaneous branch of the circumflex scapular artery.
   c. Up to 14 cm of the lateral border of the scapula vascularized by periosteal branches from the circumflex scapular artery and vein can be isolated.
   d. Unlike other osteocutaneous flaps, the scapular bone and the two skin paddles can be orientated independently of one another for reconstruction of complex three-dimensional defects.
   e. In addition, the latissimus dorsi and serratus anterior muscles vascularized by the thoracodorsal artery and vein can be harvested with the scapular flaps based on the common vascular pedicle of the subscapular artery and vein.
   f. The disadvantages of these flaps are that they require harvesting in the lateral position; the lateral border of the scapula is quite thin and may preclude secondary osseointegrated implants, and the segmental periosteal blood supply may be compromised if multiple osteotomies are required to shape the scapula for anterior defects.
4. Rectus abdominis free musculocutaneous flap and DIEP flaps
   a. The rectus abdominis free musculocutaneous flap is based on periumbilical perforators from the deep inferior epigastric arteries. Incorporation of the periumbilical perforators permits an orientation of the skin paddle virtually in any direction from the midline.
   b. After the perforators are identified, the anterior rectus sheath is incised medial to the linea semilunaris and lateral to the linea alba. To preserve the strength of the abdominal wall, the anterior rectus sheath should not be harvested below the arcuate line. Inferiorly the anterior rectus sheath is incised vertically to completely expose the rectus muscle.
   c. The deep inferior epigastric pedicle is identified after the rectus muscle is bluntly dissected free from the posterior rectus sheath. The vascular pedicle, up to 15 cm in length, is exposed all the way to the origin of the vessels from the external iliac artery and vein.
   d. A DIEP flap is a perforator flap raised by dissecting a skin perforator (usually a dominant medial or lateral perforator) through the rectus abdominis muscle without harvesting the muscle itself. By not harvesting the rectus abdomnis muscle with the flap, one can preserve the strength of the abdominal wall.
   e. Closure of the abdominal wall can be accomplished with direct approximation of the residual anterior fascial margins.
   f. Harvest of a unilateral rectus muscle has little impact unless the patient is involved in vigorous physical activities.
5. Fibular free flap
   a. The FFF is the first-line choice for reconstruction of the mandible (Fig. 162.3A to I).
   b. The fibula can be transferred as a free osseous, free osteocutaneous, or osteomuscular flap.
   c. The skin of the lateral calf is supplied by septocutaneous perforators that traverse the posterior crural septum between the posterior compartment muscles, the gastrocnemius and the soleus, and the lateral anterior compartment muscles, the peroneus longus and brevis. Musculocutaneous perforators that run through the flexor hallucis and soleus may also supply the skin.
   d. The fibula will provide up to 26 cm of bone vascularized by the peroneal artery and its two venae comitantes. The peroneal artery provides both an endosteal and periosteal blood supply to the fibula, allowing multiple bony segments of the fibula to maintain their blood supply after multiple osteotomies of the fibula.
   e. The cross-sectional area of the fibula is ideally suited for placement of osseointegrated implants for dental rehabilitation.
   f. Criticisms of the use of the FFF include height discrepancy between the fibular bone and the native mandible and the inability to reconstruct associated large soft tissue defects (i.e., large glossectomy defects or through-and-through defects).
   g. A "double barrel" technique in which the fibula is folded on itself can effectively double the height of the neomandible.
   h. In conjunction with a FFF, large soft tissue defects can be reconstructed with a second flap, either an ALT or pectoralis myocutaneous flap.
   i. Following FFF harvest, most patients will have some slight decrease in range of motion of ankle plantar and dorsiflexion and a loss of ankle strength. If the flexor hallicus longus is also harvested with the flap, the patient will have loss of dorsiflexion of the great toe. These decreases are usually not severe enough to impact on the patient's daily activities.
6. Jejunal free flap
   a. The jejunal free flap was the first free tissue transfer in the literature in 1959. Over the past several years, the use of fasciocutaneous free flaps (RFFF, ALT) has replaced jejunal free flaps in the reconstruction of certain defects.
   b. This flap can be used as a mucosal tube or as a patch. Its advantages for pharyngeal reconstruction include

a diameter that matches that of the cervical esophagus, the potential for peristalsis, and an innate secretory ability.
c. Some of the relative disadvantages of this flap include abdominal complication rates as high as 5.8%. Tracheal esophageal puncture (TEP) speech can be less discernable versus other flaps due to the intrinsic moistness of the jejunum.
d. Flap harvest is usually performed by qualified general surgeons (possibly laproscopically) and may be done simultaneously with the extirpative procedure. Preoperative bowel preparation is not necessary.
e. The jejunal arteries arise from the superior mesenteric artery and form a series of vascular arcades that run in the mesentery. Large segments of jejunum can be harvested by dividing proximally a single jejunal vessel that feeds multiple arcades.
f. To limit ischemia to the jejunum, one should only divide the pedicle after the pharyngeal defect and recipient vessels have been prepared.
g. During the inset if there is a size mismatch at the level of the base of the tongue, the antimesenteric border may be divided to "open" up the proximal end. Any redundancy in the jejunum after inset may cause it to fold on itself and become a barrier to food transport. To prevent this redundancy, we perform the inset into the base of the tongue first and then the vascular microanastomosis. With perfusion reestablished, the jejunum expands, and after this expansion, we resect any redundant jejunum prior to completing the mucosal anastomosis to the cervical esophagus.

Common Errors in Technique

1. The length of the pedicle of a rectus abdominis flap may be insufficient to reach the neck, especially when the mandible is intact. Careful planning of the skin paddle and intramuscular dissection of the pedicle from the rectus muscle may be necessary to ensure adequate length.
2. Aggressive harvest (>40%) of the radial bone may lead to pathologic fracture. Prophylactic plating of the radius is advised to prevent a fracture.
3. Irreversible ischemic changes of the jejunum can occur within 2 hours. The jejunal vessels should only be divided and transferred from the abdomen once the recipient vessels have been isolated and prepared for microanastomosis.
4. Failure to recognize venous congestion will lead to total loss of the flap. Leeches should only be used as a treatment for venous congestion after problems with the microanastomosis and pedicle have been excluded by surgical exploration.

POSTOPERATIVE PERIOD

Postoperative Management

1. Free flap monitoring
   a. The most reliable way of assessing the viability of a free tissue transfer remains clinical examination. We prefer nursing assessment of all flaps (with Doppler of the pedicle) every hour for the first 72 hours, with a physician assessment every 6 hours.
   b. Color, turgor, temperature, evidence of edema, quantity and quality of blood extravasation after pinprick, and quality of the Doppler sound are all basic methods of assessment. The arterial signal should increase in strength during subsequent postoperative days. The venous signal should be augmentable.
   c. Signs of venous congestion include bluish discoloration, increased warmth and swelling, and quick and bluish blood return after pinprick (see Fig. 162.6).
   d. With arterial compromise, the flap appears pale, feels cool, and has a loss or delay of bright red blood with pinprick of the flap.
   e. If there is any concern about vascular inflow or outflow obstruction, the patient should be returned to the operating room immediately for surgical exploration.
   f. Most fasciocutaneous flaps that are buried, such as for pharyngeal defects, can allow for a small skin paddle to be separately incorporated into the cervical skin closure. This allows for clinical assessment and a pinprick examination. Later, as an outpatient under local anesthesia, this skin island can be removed, and the cervical skin suture line can be reapproximated.
   g. Implantable Doppler systems are also available for monitoring flaps.

Complications

1. Flap failure secondary to a thrombosis at a microvascular anastomosis, vessel kinking, or flap design exceeding the vascular territory of the flap pedicle/perforator (i.e., partial skin flap necrosis)
2. Donor site morbidity: Refer to specific flaps.

DISCUSSION

Evidence-Based Question

When a strip of hypopharyngeal mucosa remains after a total laryngopharyngectomy, should the remaining mucosa be resected to convert the defect into a circumferential defect?

The preservation of the remaining mucosa and the incorporation of this mucosa in the reconstruction may reduce the risk for stenosis. However, the additional suture lines may place the reconstruction at a greater risk for fistula compared to a tubed free flap. In the case of a circumferential defect, the jejunal free flap has been the most reliable flap. It requires no tubing and thus one less suture line. Most studies report that the jejunal free flap has stenosis and fistula rates that are lower or equal to those of tubed fasciocutaneous flaps. The major alternative to the jejunum is the tubed RFFF (see Fig. 162.5). Its advantages over the jejunum include the lack of an abdominal harvest, better TEP speech, and the ability to create separate skin paddles for cervical skin reconstruction. The use of a Montgomery stent may lower fistula and stenosis rates.

Editorial Comment

The anterolateral thigh free flap may also be used for pharyngeal reconstruction with the additional advantage that the fascia lata may be included to provide an additional layer of closure to the neopharynx (see Fig. 162.4B).

Eugene N. Myers

Access the review questions and additional sources list online at http://www.expertconsult.com



REFERENCES

1. Hidalgo DA, Rekow A. A review of 60 consecutive fibula free flap mandible reconstructions. Plast Reconstr Surg 1995;96:585–596; discussion 597–602.
2. Deleyiannis FWB, Carolyn C, Lee E, et al. Reconstruction of the lateral mandibulectomy defect: management based on prognosis and the location and volume of the soft tissue resection. Laryngoscope 2006;116(11):2071–2080.

3. Urken ML, Moscoso JF, Lawson W, et al. A systematic approach to functional reconstruction of the oral cavity following partial and total glossectomy. Arch Otolaryngol Head Neck Surg 1994;120:589–601.
4. Cordeiro PG, Santamaria E. A classification system and algorithm for reconstruction of maxillectomy and midfacial defects. Plast Reconstr Surg 2000;105:2331–2346; discussion 2347–2348.
5. Chana JS, Wei FC. A review of the advantages of the anterolateral thigh flap in head and neck reconstruction. Br J Plast Surg 2004;57:603–609.

REVIEW QUESTIONS

1. Which of the following flaps is a perforator flap?
   a. RFFF
   b. Fibular free flap
   c. Jejunal free flap
   d. An anterolateral thigh free flap

2. The septocutaneous perforators to the skin paddle of a fibular free flap traverse which septum of the leg?
   a. Anterolateral septum
   b. Posterolateral septum
   c. Interosseous septum
   d. Medial septum

3. To reduce the risk of fracture, what is the recommended limit of the cross-sectional area of the radius that should not be harvested in an osteocutaneous RFFF?
   a. No more than 10% of the radius should be harvested.
   b. No more than 20% of the radius should be harvested.
   c. No more than 30% of the radius should be harvested.
   d. No more than 40% of the radius should be harvested.

ADDITIONAL SOURCES

Deleyiannis FW-B, Badeau A, Leem T, et al. Supercharging and augmenting venous drainage of an anterolateral thigh free flap: anatomical options and clinical indications in head and neck reconstruction. Plast Reconstr Surg Glob Open 2014;2(4):e135.

Disa JJ, Pusic AL, Hidalgo DA, et al. Microvascular reconstruction of the hypopharynx: defect classification, treatment algorithm, and functional outcome based on 165 consecutive cases. Plast Reconstr Surg 2003;111:652–660; discussion 661–663.

Knott PD, Seth R, Waters HH, et al. Short-term donor site morbidity: a comparison of the anterolateral thigh and radial forearm fasciocutaneous free flaps. Head Neck 2016;38(Suppl. 1):E945–8.

Masia J, Sommario M, Cervelli D, et al. Extended deep inferior epigastric artery perforator flap for head and neck reconstruction: a clinical experience with 100 patients. Head Neck 2011;33(9):1328–1334.

Theile DR, Robinson DW, Theile DE, et al. Free jejunal interposition reconstruction after pharyngolaryngectomy: 201 consecutive cases. Head Neck 1995;17:83–88.

163 Nasal Reconstruction

Frederic W.B. Deleyiannis

INTRODUCTION

The nose is of critical aesthetic and functional significance. Mastery of nasal reconstruction requires not only a knowledge of flaps and grafts but also an appreciation of facial aesthetics and functional rhinoplasty. A skin graft or local flap will close most nasal defects, but without a comprehensive evaluation of the nasal defect and of anticipated reconstructive outcome, the reestablishment of facial balance and nasal breathing can be lost.

Nasal defects represent tissue loss, often the result of tumor resection or trauma. To reconstruct a nasal defect aesthetically and functionally, one must understand the layers and volumes missing from the defect, the nasal subunits involved, the cartilage support structures required, and the color and thickness of the proper skin replacement. This chapter describes the basic principles of nasal reconstruction as applied to acquired nasal defects.

KEY OPERATIVE LEARNING POINTS

1. Reconstruction of the nose begins with an analysis of the facial and nasal subunits involved and the nasal layers that are missing.
2. Cartilage grafts support skin flaps to prevent contraction. The septum, concha of the ear, and the ribs (sixth through ninth ribs) are the best donor sites for cartilage.
3. A forehead flap transfers skin of ideal quality to reconstruct the nasal skin defect in patients of all ages. A paramedian flap based on an ipsilateral supratrochlear vascular pedicle is located approximately 1.2 to 1.5 cm from the midline.
4. Reconstruction with a forehead flap should be done in three stages. Secondary cartilage grafting and flap thinning should be done at the second stage.

PREOPERATIVE PERIOD

History

1. History of present illness
   a. Most nasal reconstruction is done to repair defects created by the excision of basal cell or squamous cell carcinomas. These cancers usually present with a long history of a nodular or ulcerative lesion of the nose.
   b. It is critical to explain the significance and extent of an acquired nasal deformity to the patient. As in many aspects of plastic surgery, congruence between what is perceived by the patient and observed by the physician is essential.
   c. Because of the importance of the nose for body image, most nasal defects are reconstructed. The patient's age is generally not a contraindication for nasal reconstructive procedures.
2. Past medical history
   a. The surgeon should insist that smoking be stopped at least 3 weeks prior to reconstruction. Smoking will increase the risk of partial or total loss of a skin flap; this risk should be discussed with the patient and documented.
   b. The patient's general medical condition as well as the extent of the procedure may influence the decision for or against surgery. Sometimes a nasal prosthesis is a valuable and recommended option (Fig. 163.1).
   c. If the nasal defect is the result of a cancer resection, the pathology as well as the need and the timing of any adjuvant therapy (i.e., radiation therapy) should be discussed in the context of tumor surveillance, recurrence, wound healing, and overall prognosis.

Physical Examination

Analysis of the Defect—By Adjacent and Underlying Facial Structures

Extended nasal defects are those that extend beyond the nose and involve the cheek, upper lip, and/or underlying maxilla. Large cheek and lip defects may require free tissue transfer prior to nasal reconstruction (Fig. 163.2) to replace missing volume and skin. Small defects of the medial cheek and upper lip can be repaired with cheek advancement flaps or nasolabial flaps at the first stage. A foundation of skin and adipose tissue should exist or be reconstructed along the region of the piriform aperture (i.e., the nasal platform) to support the reconstructed alar bases and columella and to position the new nose anterior to the maxilla so that it does not extend beyond its normal borders and flow onto the cheek. Cheek advancement flaps can be used as a foundation for the nasal base before median forehead flap reconstruction and can be used for replacement of the nasal sidewall (Fig. 163.3). The nasal platform and base should be in harmony with the eyes (i.e., the alar base width should approximate the intercanthal distance).

Analysis of the Defect—By Nasal Subunits

The nose is often divided into subunits (Fig. 163.4), which define areas of dissimilar skin texture and depth.[1,2] Borders between these areas are sites of shadows and highlights. The convex subunits of the nose are the tip, dorsum, alae, and columella. Application of the subunit principle is mainly practical for reconstruction of the convex subunits with flaps, not for the concave subunits—the nasal sidewalls and soft triangles. As skin flaps heal, they contract in response to the collagen and myofibroblasts in the recipient bed. This contraction pulls the flap centripetally (i.e., trapdoors) into the convex shape of the unit it covers. The subunit principle is not suitable for repair with skin grafts because skin grafts do not undergo trapdoor contraction. These grafts lie flat and do not bulge with wound contraction, likely because they lack a layer of subcutaneous adipose tissue. If more than 50% of the subunit is missing, the entire subunit (in particular the tip or ala) should be replaced with a flap.

The nose in a young child is smaller, flatter, and less defined than that in an adult.[3] The subunit's borders are less distinct, but even in children the subunit principle can be used as a technique to hide scars and harness flap contraction.



Fig. 163.1. Nasal prosthesis. An 83-year-old male status post a total rhinectomy, before, **A,** and after, **B,** coverage with a nasal prosthesis.

Analysis of the Defect—By Nasal Layers (Skin, Cartilage, and Mucosa)

Accurate analysis of the defect with regard to the component layers of the nose is essential. In general, when only skin is missing, reconstruction can be done reliably with local flaps and, if the underlying framework has been resected, with cartilage grafts. The difficulty of the reconstruction increases as the amount of nasal lining diminishes.

The nose has three distinct zones of skin thickness with differing degrees of subcutaneous adipose tissue, sebaceous gland content, and mobility (Fig. 163.5).[4] The skin of zone 1 is nonsebaceous and mobile and covers the upper dorsum and sidewalls of the nose. Zone 2 contains thick, sebaceous, nonmobile skin and covers the supratip area, tip, and alar lobules. Zone 3 skin is thin, nonsebaceous, and fixed to the underlying alar cartilages or fibroadipose tissue structures of the alar margin, soft tissue triangles, infratip lobule, and columella.

Imaging

Imaging is generally not indicated for cutaneous carcinomas unless possible invasion of the underlying structures (i.e., bone destruction, perineural invasion) or regional metastasis is suspected. In these cases computed tomography (CT) or magnetic resonance imaging (MRI) may be indicated.

Indications

1. Nasal defects caused by cancer resection or trauma

Contraindications

1. Congruence between what is perceived by the patient and observed by the physician is essential. Discrepancies in form or function are best addressed before any consideration can be given to surgical intervention.
2. Preoperative counseling is also crucial to best define anticipated cosmetic results and limitations. This might include demonstrating certain procedures in a mirror for the patient and outlining schematic figures of the intended surgeries. If multiple staged surgeries are needed, their timing should be emphasized. If a patient is unwilling to proceed with a multistage plan, the surgical options/recommendations should change.
3. Medical comorbidities increase the risks of general anesthesia.

Preoperative Preparation

1. Be sure the surgical margins are clear before proceeding with reconstruction.
2. Discontinue antiplatelet drugs if possible.
3. In designing a flap to reconstruct the defect or subunit, one should use a template based on the contralateral, uninjured side. If the contralateral side is also injured, a plaster or clay model of an ideal nose can serve as the template.

OPERATIVE PERIOD

Anesthesia

- General: Although some skin flaps (i.e., bilobed, nasolabial, forehead) can be developed under local anesthesia or with sedation, general anesthesia is preferred for patient comfort, especially if cartilage grafts are being harvested.

Positioning

- Supine: The bed is turned 90 degrees, allowing access to both sides of the face (so that symmetry can be checked) and to the ears (so that cartilage grafts can be harvested if needed).

Perioperative Antibiotic Prophylaxis

- First-generation cephalosporin

Monitoring

- None

Instruments and Equipment to Have Available

1. Basic septoplasty and rhinoplasty surgery set
2. Needle-tip cautery
3. Plastic surgery soft tissue tray containing small double-pronged skin hooks, iris scissors, and 0.5 skin pickups



Fig. 163.2. Reconstruction of the cheek and nose with free tissue transfer. A, A 4-year-old girl with total loss of her left medial cheek (skin and underlying musculature) and heminose 1 year after an avulsion injury from a motor vehicle accident. **B,** Intraoperative plan: scar to be excised and reconstructed with a scapular flap. The stippled area is the area to be augmented with partial de-epitheliazation of the scapular flap. **C,** Cheek defect recreated. **D,** Design of the scapular flap. **E,** A year after reconstruction of the cheek with a scapular flap. **F,** First-stage nasal reconstruction 16 months after cheek reconstruction: Nasal defect recreated; nasal template designed from the contralateral side of the nose. **G,** First-stage nasal reconstruction: Nasal lining created with turnover flaps; conchal cartilage used for alar and tip grafting. **H,** Forehead flap for cutaneous covering. **I,** Second-stage nasal reconstruction, 4 weeks after the first stage. With the forehead flap bipedicled, the flap was thinned of frontalis muscle and subcutaneous tissue. **J,** Appearance after division and inset of the forehead flap (after the third stage).



Fig. 163.3. Reconstruction of the cheek and nose with a cheek advancement flap. A, Cheek and nasal defect (skin zone 1, lateral nasal sidewall). **B,** Cheek flap. **C,** Appearance 19 months after surgery.

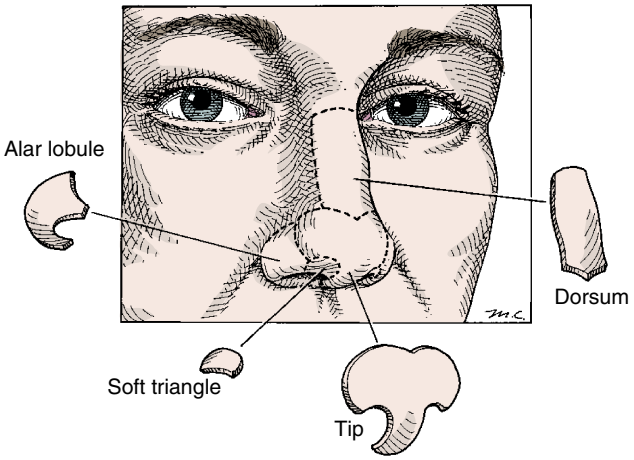

Fig. 163.4. Nasal subunits. The surface of the nose can be divided into distinct anatomic regions corresponding to sites of natural lines of shadow, curvature, and differing skin characteristics. The convex subunits of the nose are the tip, dorsum, alae, and columella. *(From Burget GC: Aesthetic restoration of the nose. Clin Plast Surg 12:463-480, 1985; with permission.)*

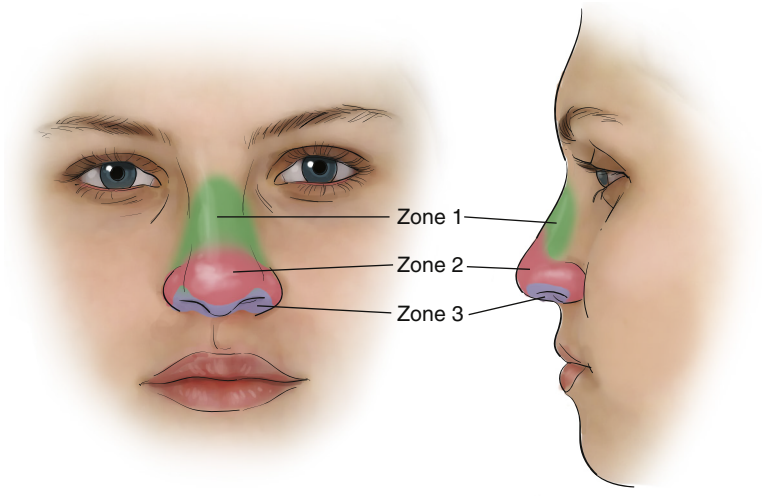

Fig. 163.5. Nasal skin zones. Depiction of the three zones of nasal skin types. *(Reprinted from Burget GC: Modification of the subunit principle for reconstruction of nasal tip and dorsum defects. Arch Facial Plast Surg 1:16-18, 1999; with permission.)*

Key Anatomic Landmarks

1. Medial canthi to determine the midline and the position of the nasal subunits on the middle third of the face
2. Inferior extent of the frontal hairline to try to avoid raising a forehead flap with hair

Prerequisite Skills

1. Septoplasty
2. Open rhinoplasty
3. Harvest of conchal cartilage graft

Operative Risks

1. Necrosis of a skin flap. Any skin flap can become necrotic if the blood supply of the flap is exceeded (i.e., a base width-to-length ratio of 1:3 in the face should not be exceeded for a random skin flap), if the flap is handled traumatically, or if the patient has other risk factors, such as smoking, which can affect perfusion.
2. Septal perforation or flattening of the concha if cartilage grafts are harvested with suboptimal technique

Surgical Technique

Reconstruction of the nose begins with an analysis of the defect. With a diagnosis of the facial and nasal subunits involved and the nasal layers missing, one can evaluate the various reconstructive options and plan the surgical approach.

Nasal Lining Options

A thin, vascular, and supple nasal lining remains the goal of reconstruction. Thick bulky flaps, such as a nasolabial flap, will block the nasal airway. Cartilage grafts placed on poorly perfused flaps will necrose and extrude. Lining flaps that are highly vascular and thin can be taken from multiple donor sites within the nose (Fig. 163.6).[5,6] Menick's technique of using a folded forehead flap in three stages offers a new, refined method of replacing nasal lining, and the transfer of free fasciocutaneous flaps enables the reconstruction of the total or near-total defect.[7]

Turnover Flaps. Turnover flaps are small flaps of the skin surrounding a defect that are turned over like the pages of a book into the nasal airway. Because they are based on scar, their blood supply can be tenuous and their length will be limited. If their blood supply appears inadequate at the time of reconstruction, cartilage grafting should be done secondarily.

Septal Mucoperichondrial Flaps: Ipsilateral and Contralateral. An ipsilateral septal flap, based anteriorly on the septal branch of the superior labial artery, has been described by Burget and Menick. The flap pivots on an anteroinferior point near the nasal spine and folds outward to provide lining for the nasal domes. The exposed septal cartilage is either harvested as a graft or left to remucosalize.

A contralateral septal flap can be harvested with or without septal cartilage. This technique involves harvesting the contralateral septal mucoperichondrium and swinging it like a trapdoor underneath the nasal dorsum through a dorsal perforation in the septum. The flap can reach the nasal sidewalls but not the alar margins.

Bipedicled Lining Flaps. The nasal lining of the alar margin can be successfully reconstructed with a bipedicled lining flap (Fig. 163.7). The flap is based medially on the septum and laterally on the vestibule and is pulled down to the alar margin. The secondary lining defect made above the alar margin can be covered with a contralateral (or ipsilateral) septal mucoperichondrial flap.

Menick´s Technique for Nasal Lining: The Folded Forehead Flap, Skin Grafts, and Three-Stage Nasal Reconstruction. To provide nasal lining, Menick has advocated folding the forehead flap on itself and setting it into the defect (Fig. 163.8). At a second operation, at 3 weeks, the covering portion of the flap is separated from its nasal lining portion and lifted entirely off the nose. The nasal lining flap is now thinned with removal of the frontalis muscle and excess subcutaneous tissue. Cartilage grafts are placed at this second stage. The covering portion of the forehead flap is also thinned and then reattached to the nose. The pedicle is divided at a third stage 3 weeks after the second stage. For large nasal defects, a full-thickness skin graft can be sewn to the edges of the mucosal defect and to the frontalis muscle layer of the forehead flap in the first stage. Wound healing and contracture are not initiated until the subcutaneous and frontalis planes are surgically injured. Therefore the reconstructed lining of the folded flap or skin graft remains supple and soft until it is supported by the delayed placement of cartilage grafts during the second stage.

Microvascular Free Tissue. For total or subtotal loss of the nose, free tissue transfer of a fasciocutaneous flap, usually a radial forearm free flap, can be done to reconstruct the nasal lining vault (Fig. 163.9).[8] However, a bulky free flap will obstruct the nasal airway unless it is supported on the nasal septum. When the anterior nasal septum is present, Burget and Walton advocate rotating it forward as a septal pivot flap (Fig. 163.10).[8,9] This septal flap has the ability to support the length and projection of the nose without obstructing the airway. The raw external surface of the free flap is skin-grafted. At a second stage 5 to 6 weeks later, the skin graft and subcutaneous adipose tissue of the free flap are removed and formal nasal reconstruction with cartilage grafting and a paramedian flap is carried out.

Without a septal pivot flap, a single paddle free flap will collapse against the piriform aperture. For correction of this problem, a double-paddle radial forearm free flap can be used to create a double-vaulted nasal lining and a columellar lining.

Skeletal Support

As the local flaps used for nasal reconstruction heal, the collagen and myofibroblasts within the flap and wound contract, pulling the flap toward a center of centripetal contraction. Grafts of cartilage and bone support the skin flaps, preventing contraction, and after a few months show through the covering flap to give the reconstructed nose a normal shape. Cartilage and bone from the septum, concha of the ear, or cartilage from the ribs (sixth through ninth rib) are the best donor sites. Because the septum is a possible growth center, the ear and costal cartilage are better options for sources of cartilage grafts in children. Grafts will survive only if placed on a well-vascularized bed, such as that provided by septal flaps. With the use of the folded forehead flap or microvascular free flaps, secondary placement of grafts is preferred.

To provide midline nasal support, there are several well-accepted options. A cantilevered bone graft can be harvested either from the outer calvarium of the skull or from rib as an osteochondral segment (Fig. 163.11). A sturdy longitudinal segment can then be crafted to extend from the nasion to the superior aspect of the nasal lobule as an onlay or cantilevered graft. This can be secured in place by suture to the underlying cartilaginous dorsum or plated/wired to the frontal bone

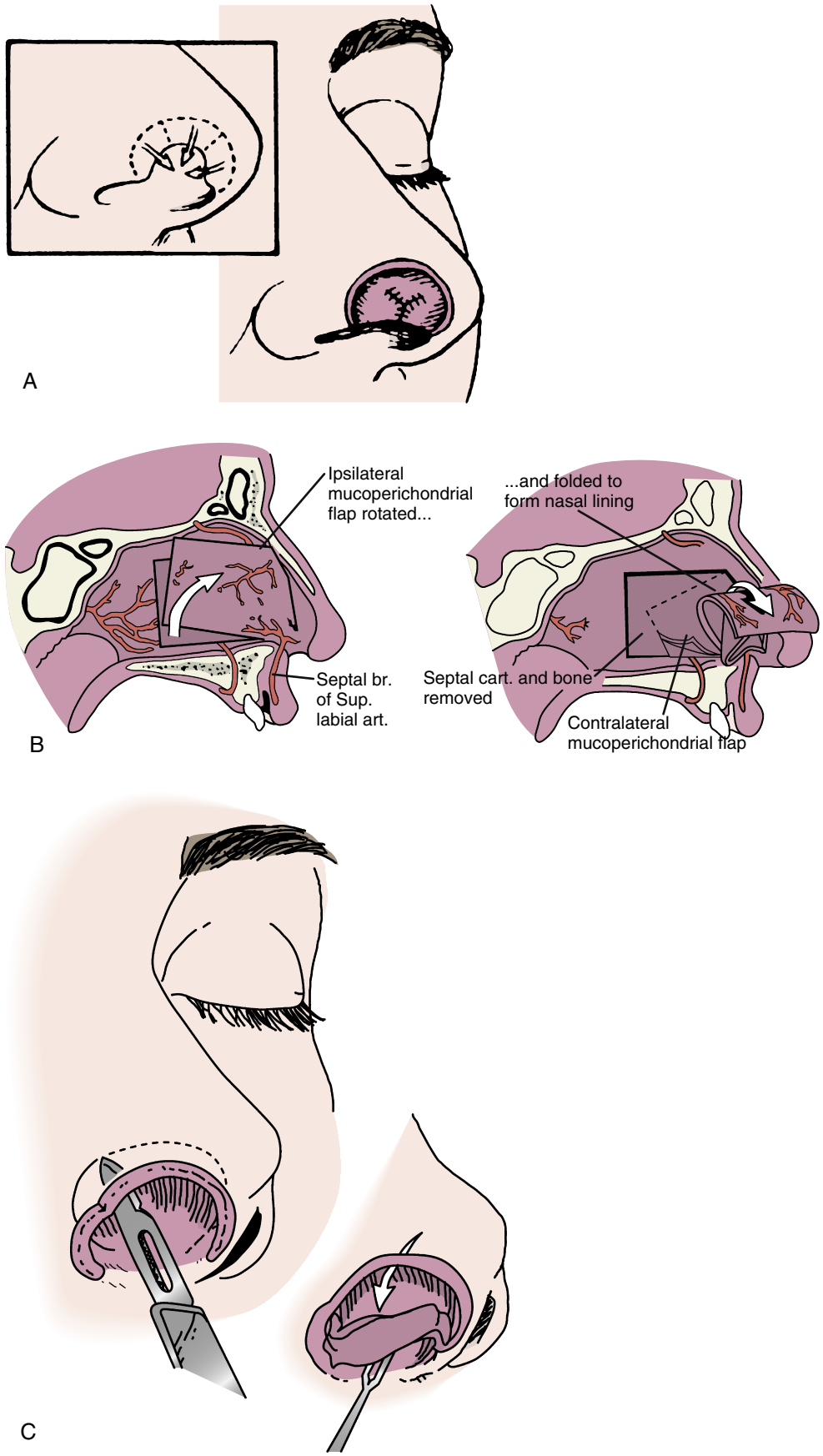

Fig. 163.6. Nasal Lining. Options for nasal lining include **A,** turnover flaps, **B,** septal mucoperichondrial flaps, and **C,** bipedicled lining flaps. *art.*, artery; *br.*, branch; *cart.*, cartilage; *Sup.*, superior. *(From Barton FE: Aesthetic aspects of partial nasal reconstruction. Clin Plast Surg 8(2):177-191, 1981; Burget GC, Menick FJ: Nasal support and lining: the marriage of beauty and blood supply. Plast Recon Surg 84(2):189-202, 1989; and Burget GC: Aesthetic restoration of the nose. Clin Plast Surg 12:463-480, 1985; with permission.)*



Fig. 163.7. Superiorly based, two-stage nasolabial flap. A, Defect of the soft tissue triangle, frontal view. **B,** Oblique view. **C,** First stage: Nasal lining reconstructed with a bipedicled lining flap, septal cartilage used to buttress the soft tissue triangle. **D,** Superiorly based nasolabial flap used for cutaneous coverage. **E,** Second stage: Nasolabial flap divided and inset, oblique view. **F,** Basal view. **G,** Appearance 1 week after second stage, frontal view.



Fig. 163.8. Three-stage nasal reconstruction with a forehead flap. A, Alar defect, frontal view. **B,** Oblique view. **C,** First stage: Design of the folded forehead flap for nasal lining and cutaneous covering. **D,** Immediate postoperative appearance. **E,** Second stage: Flap divided along the alar margin; nasal and cutaneous flaps thinned of frontalis muscle and subcutaneous tissue. **F,** Conchal cartilage harvested. **G,** Conchal cartilage graft to the ala. **H,** Third stage: Division of the forehead pedicle and flap inset. **I,** Appearance 4 months after pedicle division, frontal view. **J,** Oblique view.

and/or nasal bones as needed. Smaller segments of calvarial bone, rib, or septal cartilage can be carved into longitudinal struts for more limited reconstructions, as for the nasal sidewall.

For alar cartilage reconstruction, strips of cartilage 4 to 5 mm in width and 1.5 to 2.0 cm in length are harvested from the concha of the ear, septum, or rib (Fig. 163.12). To make an arch, one weakens or scores the cartilage in the area destined to be the lateral genu, and the cartilage is bent into a curve using one or two spanning mattress sutures. The intrinsic curves of conchal cartilage make it ideal for alar batten grafts, but conchal cartilage may be too weak to support a scarred nasal skin envelope. Septal and costal cartilage are stiffer than conchal cartilage and will better tolerate the compressive forces of a contracted skin envelope. A separate cartilage graft should be used to brace the soft tissue triangle.



Fig. 163.9. Radial forearm free flap (RFFF) for internal nasal lining. A, Near-total nasal defect, frontal view. **B,** Lateral view. **C,** Basal view. **D,** Template for the design of an RFFF for internal nasal lining. **E,** Harvest site and RFFF design. **F,** RFFF inset; forearm skin used for internal lining. **G,** Skin graft applied to the raw (i.e., external) surface of the RFFF. **H,** Postoperative appearance, frontal view. **I,** Lateral view. The patient will undergo removal of the skin graft, flap thinning, placement of a rib graft, and coverage with a forehead flap.

Nasal Skin Coverage

The size of the defect and the zone of nasal skin thickness can serve as useful guides for selecting the appropriate skin cover. Because the skin of zone 1 is mobile, local rotation-advancement flaps or primary closure can successfully reconstruct small defects (less than 1.5 cm). Zone 2 contains thick, sebaceous, nonmobile skin. The only donor skin that matches zone 2 is the remaining skin of zone 2 (i.e., transposed with a bilobed flap) or forehead skin with its dense subcutaneous adipose tissue. Zone 3 skin is thin, nonsebaceous, and fixed to the underlying alar cartilage or fibrofatty structures. Composite grafts from the ear (<1.5 cm) and preauricular full-thickness skin grafts can blend well in zone 3.

For large defects (>1.5 cm) a paramedian forehead flap is the preferred coverage for all zones. Columellar defects present a reconstructive challenge. A distal extension of the forehead

flap provides an optimal solution when the columellar defect is a missing element of a larger defect. Other options, in particular for isolated columellar defects, include superiorly or inferiorly based nasolabial flaps.

Full-Thickness Skin Grafts. Because the skin of the upper two-thirds of the nose (zone 1) is thin with few sebaceous units, full-thickness skin grafts blend well in this area. Possible sites of harvest include the preauricular area, postauricular area, nasolabial fold, and supraclavicular area. The forehead has also been found to be an excellent site of graft donor skin. Skin and a few millimeters of subcutaneous adipose tissue can be transferred from the forehead for superficial defects of the alae and tip (Fig. 163.13). A skin graft should not be harvested from an area that is a possible site for a forehead flap. Because of the temporary period of ischemia during wound healing, the melanocytes of a skin graft may be injured, causing the final graft to appear hypopigmented or hyperpigmented.

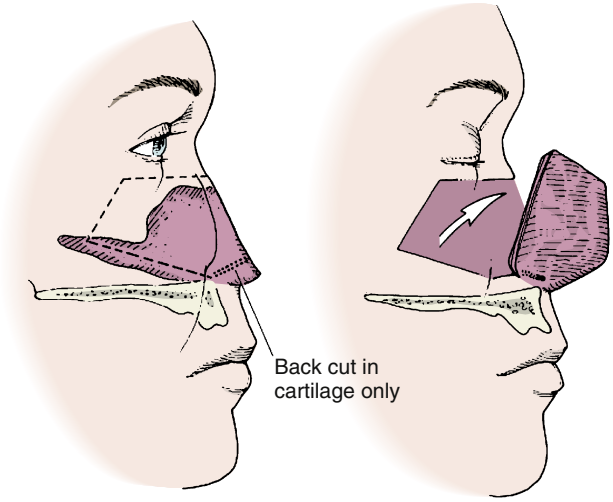

Fig. 163.10. Septal pivot flap. To provide dorsal and caudal support, the central cartilaginous/bony septum can be pivoted or swung anteriorly. The blood supply of the septal pivot flap is centered over the septal branches of the superior labial arteries.

Composite Chondrocutaneous Grafts. A composite chondrocutaneous graft can be an option for reconstructing the nasal skeleton with defects also including nasal skin and/or inner nasal lining. Composite grafts can be harvested from the root of the helix or from the conchal bowl (Figs. 163.14 and 163.15). The survival of the composite graft depends mainly on the size of the graft and on the vascularity of the recipient bed. Diffusion from the recipient bed is the only source of nutrients to the composite graft in the early postoperative period. Several authors have reported the complete healing of composite grafts after partial necrosis. In general, to minimize the possibility of necrosis, graft size should not exceed 1.5 cm; if possible, composite grafts should be placed under or on well-vascularized tissue. Grafts may be harvested as two layers (skin, cartilage) or as three layers (skin, cartilage, skin). Composite grafts are mainly used for reconstructing the alae and columella.

Bilobed Flaps. The bilobed flap as described by Zitelli (Fig. 163.16)[10] is the most suitable method to repair small (<1.5 cm) superficial defects of zone 2 (tip or ala, Fig. 163.17). It moves the nasal defect from the zone of thick immobile skin

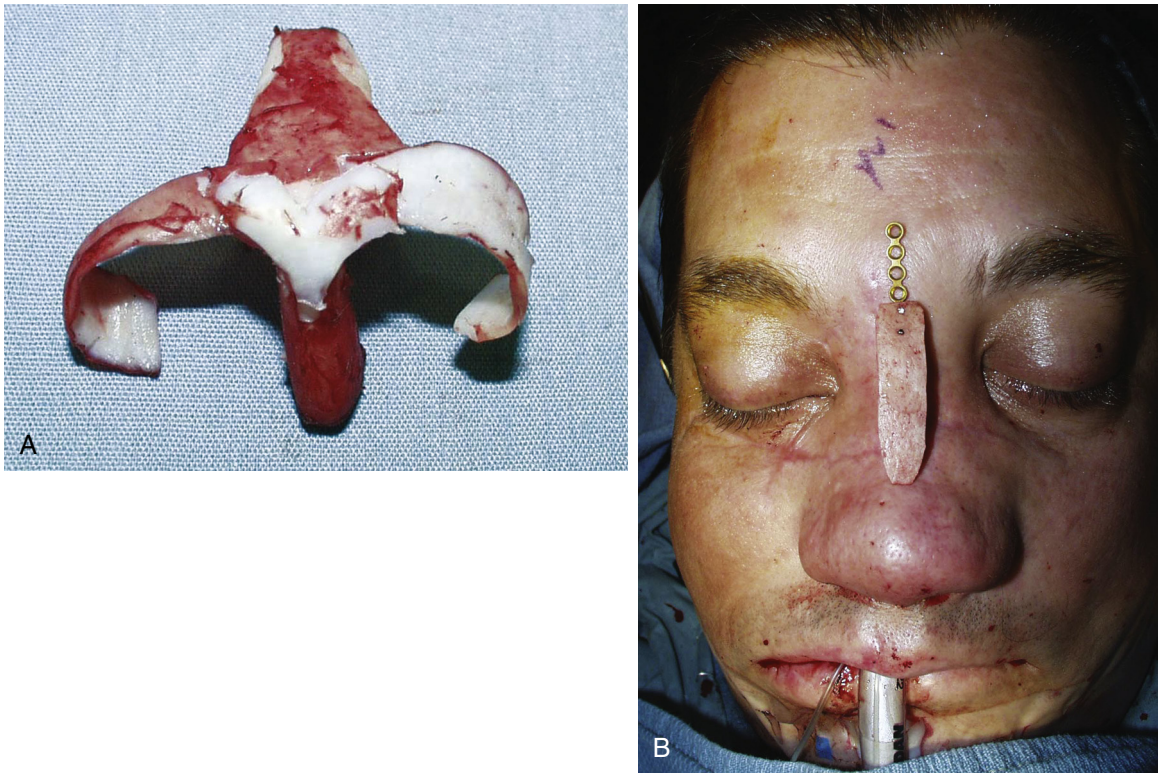

Fig. 163.11. Structural support of the nasal midline/dorsum. A, Costochondral graft carved into an "L" strut with alar battens. **B,** Cantilevered cranial bone graft to be fixed to the frontal skull with a miniplate.

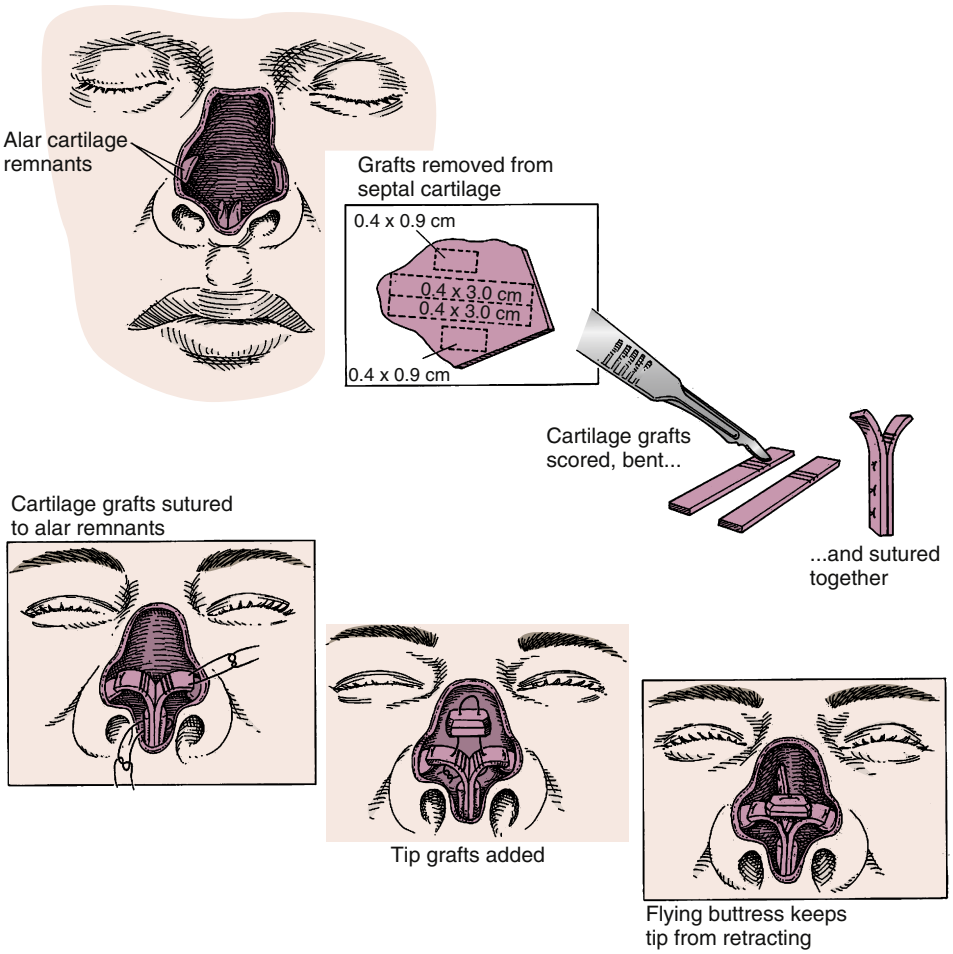

Fig. 163.12. Reconstruction of cartilage support. If lining is created or preserved, cartilage from numerous sources (in this case the septum) can be tailored to restore the nasal contour and curvature. A cap graft or tip graft can be used to promote lobule projection. *(From Burget GC, Menick FJ: Aesthetic restoration of one-half the upper lip. Plast Reconstr Surg 78(5):583-593, 1986; with permission.)*



Fig. 163.13. Forehead full-thickness skin graft with adipose tissue. A, Alar defect with skin graft harvested with 1 mm of adipose tissue on the dermis. **B,** Postoperative result at 1 year. Note the hypopigmentation. The contour has been well preserved without a depression.

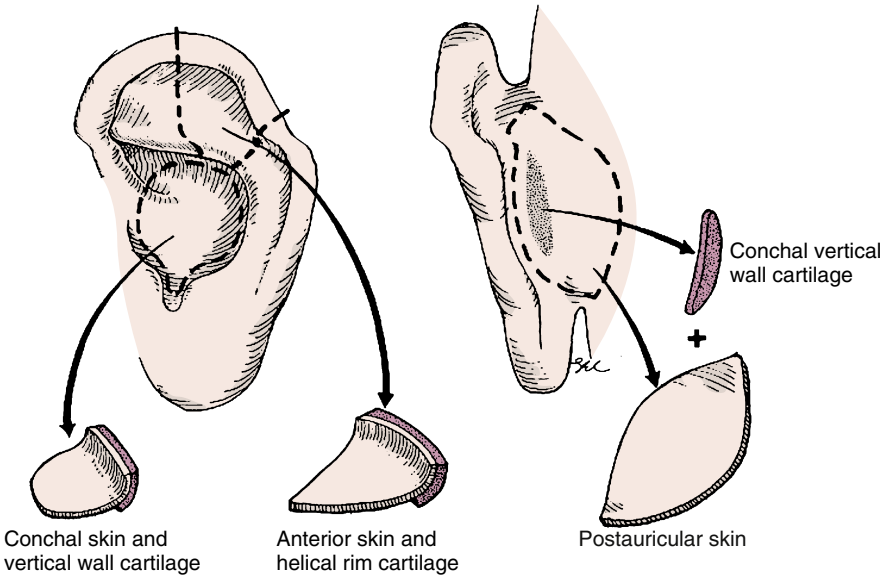

Fig. 163.14. Composite graft. The ear is an ideal donor site for nasal reconstruction, including full-thickness chondrocutaneous grafts. *(From Barton FE, Jr: Aesthetic aspects of partial nasal reconstruction. Clin Plast Surg 8(2):177-191, 1981; with permission.)*



Fig. 163.15. Composite chondrocutaneous graft for nasal stenosis. A, Bilateral nasal stenosis after necrosis of the nasal tip. **B,** Defect of the ala and tip recreated. **C,** Harvest of a composite auricular graft. **D,** Inset of the composite graft. **E,** Immediate postoperative appearance.

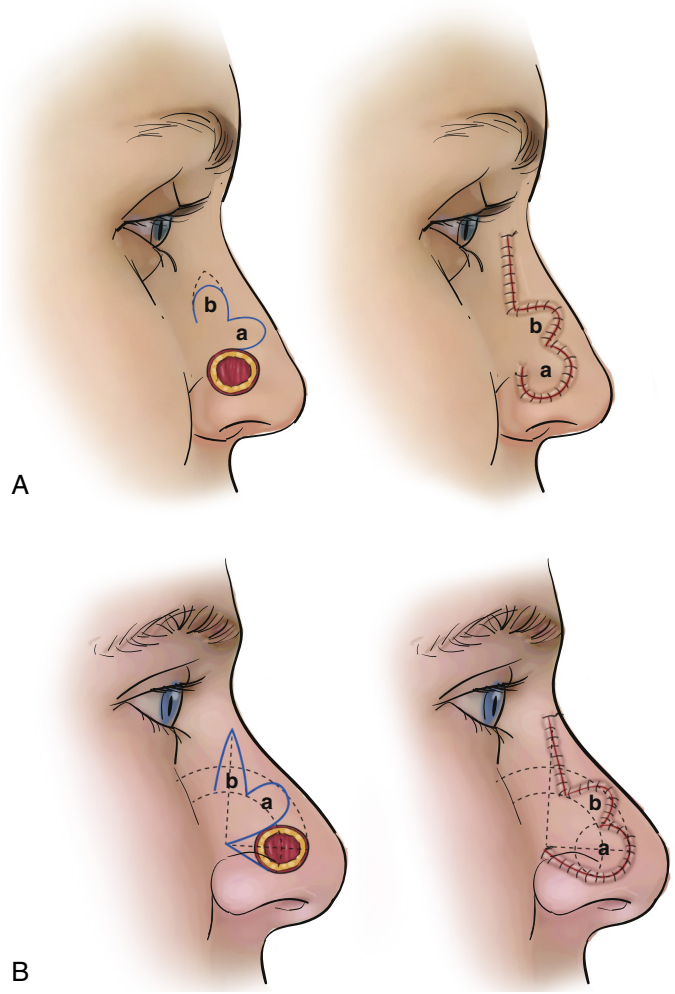

Fig. 163.16. Zitelli modification of the bilobed flap. Compared with the original design of a 180-degree arc of rotation, which typically produces a dog-ear deformity at the rotational point, **A,** the modified transposition flap creates a smaller defect by using a 90-degree arc of rotation and minimizing dog-ear and trapdoor formation, **B.** *(Adapted from Bhatia A, Rohrer TE. Flaps and Grafts in Dermatologic Surgery. Chapter 7, Transposition Flaps. 79-90. ©2007, Elsevier Inc.)*

(zone 2) to the zone of thin mobile skin (zone 1). The fundamentals of this transposition flap are as follows:

1. The arc of rotation can vary between 90 and 180 degrees but is generally designed to be between 90 and 100 degrees. The radius will usually approximate 1.5 diameters of the defect.
2. The first lobe should be the same size as the defect. The second lobe is smaller and just narrow enough to allow primary linear closure of the donor defect.
3. For medial defects, laterally based flaps can be designed.
4. Closure of the secondary defects should not distort normal landmarks, such as the lower eyelid.

Potential disadvantages of the bilobed flap are trapdooring (convex bulging) and obliteration of the alar groove.

Nasolabial Flaps. Based either superiorly or inferiorly, the nasolabial flap relies on a random blood supply derived from facial artery perforators and takes advantage of the abundance of mobile non-hair-bearing skin in the medial cheek. Primary closure of the defect within the nasolabial fold creates a minimal, postoperative deformity. Reconstruction involves first tracing an outline of the cutaneous defect on the donor site and then elevating the flap in a subcutaneous plane (Fig. 163.18; see also Fig. 163.7). The superiorly based nasolabial flap is good for reconstructing the entire alar subunit, the lower aspect of the nasal sidewall, and the nasal platform on which the alar base rests. The inferiorly based nasolabial flap is most useful for defects of the upper lip, floor of the nose, and columella. A nasolabial flap folded to create both internal and external lining creates a bulky alar rim that will require subsequent revision.

Forehead Flaps. A forehead flap transfers skin of ideal quality to reconstruct the nasal skin defect in patients of all ages. The forehead heals well with minimal scars even in donor sites left to heal secondarily. Midline or paramedian forehead flaps can be raised either on the supratrochlear or supraorbital vessels. Most surgeons elevate a paramedian flap based on an ipsilateral supratrochlear vascular pedicle that is located approximately 1.5 cm from the midline. A Doppler examination can be used to locate the pedicle, but even if no Doppler signal is found, a flap with a pedicle based almost anywhere along the midline of the forehead will likely survive. To avoid strangulation caused by the twisting of a wide pedicle, the pedicle width of a paramedian flap should be about 1.5 cm. To gain length for a paramedian flap, one can extend the flap into the hair-bearing scalp and/or extend the flap 1.5 cm below the orbital rim.

The pattern of the nasal defect should first be designed from the contralateral normal side of the patient's face as a model. Local anesthesia with epinephrine should not be injected into the forehead flap so as to allow intraoperative evaluation of the blood supply. The forehead flap is then



Fig. 163.17. Nasal tip defect reconstructed with a bilobed flap. **A,** Bilobed flap design. **B,** Closure. **C,** Early postoperative appearance.

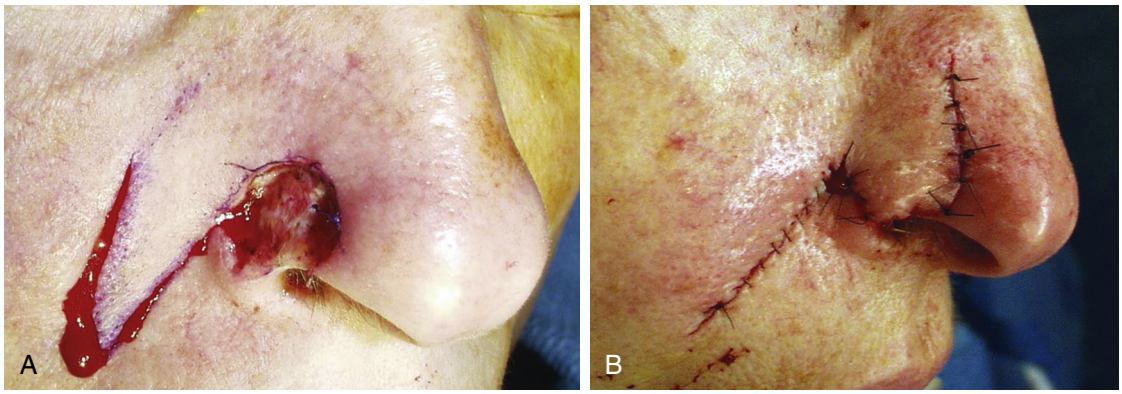

Fig. 163.18. Superiorly based, single-stage nasolabial flap. **A,** Alar defect. **B,** Nasolabial flap inset.

elevated from distal to proximal with all layers of the scalp (skin, subcutaneous tissue, and frontalis muscle) except periosteum. The forehead flap is then thinned only at the columellar inset and along the alar rim. Closure of the donor site should be done over the periosteum with subgaleal undermining of the forehead. Any gaps that cannot be closed should be kept moist with antibiotic ointment, covered with petroleum jelly gauze, and allowed to heal secondarily. The pedicle of the paramedian forehead flap in the glabellar region is typically covered with a split-thickness skin graft to decrease bleeding and oozing.

Menick advises the transfer of only pristine, unexpanded forehead skin. An expanded forehead flap can contract after the completion of nasal reconstruction, producing inferior aesthetic results. If necessary, tissue expansion can be done secondarily after nasal reconstruction to close the forehead donor site or to perform forehead scar revision.

Common Errors in Technique

1. If the first step in a nasal reconstruction is not recreation of the defect (i.e., excising old scar and contractions), the final result will be a reconstruction and flap design that is too small.
2. If the lip, cheek, and nose all require reconstruction, the lip-cheek platform (i.e., nasal platform) should be reconstructed in a first stage prior to nasal reconstruction. If nasal reconstruction is done at the same time, subsequent wound settling can shift the lip-cheek platform, causing a reciprocal shift in the position of the reconstructed nose.
3. Reconstruction of missing nasal lining with bulky flaps, such as a nasolabial flap or free flap, can lead to nasal obstruction.
4. When more than 50% of a nasal convex subunit is missing, patching the nasal defect with a local flap without replacing the entire nasal subunit may worsen the aesthetic outcome.

POSTOPERATIVE PERIOD

Postoperative Management

1. Patients undergoing first-stage nasal reconstruction with a forehead flap should stay in the hospital overnight.
2. Any blanching of the flap or signs of venous congestion can potentially be reversed with removal of sutures or reinsertion of the flap.
3. Doyle splints or intranasal packs are generally not used unless there is a risk of synechiae formation.
4. Because they may compromise the flap's circulation, external dressings are not placed on a flap used for nasal reconstruction.
5. Skin sutures, as well as any external bolster placed on a skin graft, are removed 5 to 7 days after surgery.
6. Postoperative parenteral antibiotics are not routinely prescribed.

Complications

1. Skin flap necrosis

If a forehead flap is to be used in a patient who is a smoker, delay the forehead flap by 3 weeks prior to transfer. This can be done by incising the perimeter of the flap without elevating it.

2. Nasal obstructive breathing
3. Alar retraction

Although a normal alar lobule contains little cartilage, a reconstructed ala should contain a cartilage graft (i.e., in a nonanatomic position) that spans the entire lobule to prevent soft tissue contraction. Reconstruction of the soft tissue triangle also requires a separate cartilage graft to withstand the forces of contraction.

4. Nonaesthetic scars

Consideration of the subunit principle is mainly useful only for reconstruction of the convex subunits of the nose (i.e., the tip, dorsum, alae, and columella) with local flaps. This is because as a local flap heals, it contracts centripetally, pulling the flap into a convex shape.

DISCUSSION

Evidence-Based Medicine Question

Should a pediatric nasal reconstruction be delayed until nasal growth is complete?

Psychosocial, functional, and aesthetic concerns should be addressed with early, definitive reconstruction. In children, reconstruction should be initiated and, if possible, completed before the child is of school age to avoid psychosocial repercussions. The reconstructed nose—with skin, lining, and support—will grow with the child. However, residual surgeries (to increase the nasal airway, to add cartilage grafts for the enhancement of projection or contour, and to revise scars) are expected.

Editorial Comment

Reconstruction in three stages with a folded forehead flap or forehead flap with a skin graft offers an excellent option for reconstructing the nasal defect with missing internal nasal lining.

Eugene N. Myers

Access the review questions online at http://www.expertconsult.com



REFERENCES

1. Burget GC, Menick FJ. The subunit principle in nasal reconstruction. Plast Recon Surg 1985;76:239–247.
2. Burget GC. Aesthetic restoration of the nose. Clin Plast Surg 1985;12:463–480.
3. Burget GC. Preliminary review of pediatric nasal reconstruction with detailed report of one case. Plast Reconstr Surg 2009;124(3):907–918.
4. Burget GC. Modification of the subunit principle for reconstruction of nasal tip and dorsum defects. Arch Facial Plast Surg 1999;1:16–18.
5. Barton Jr FE. Aesthetic aspects of partial nasal reconstruction. Clin Plast Surg 1981;8:177–191.
6. Burget GC, Menick FJ. Nasal support and lining: the marriage of beauty and blood supply. Plast Recon Surg 1989;84:189–202.
7. Menick FJ. A 10-year experience in nasal reconstruction with the three-stage forehead flap. Plast Reconstr Surg 2002;109:1839–55. discussion 1856-1861.
8. Burget GC, Walton RL. Optimal use of microvascular free flaps, cartilage grafts, and a paramedian forehead flap for aesthetic reconstruction of the nose and adjacent facial units. Plast Reconstr Surg 2007;120(5):1171–1207.
9. Burget GC, Menick FJ. Nasal reconstruction: seeking a fourth dimension. Plast Recon Surg 1986;78:145–157.
10. Zitelli JA. The bilobed flap for nasal reconstruction. Arch Dermatol 1989;125(7):957–959.

REVIEW QUESTIONS

1. The arc of rotation of a bilobed flap is generally designed with what angle?
   a. 45 degrees
   b. 90 degrees
   c. 135 degrees
   d. 180 degrees

2. Consideration of the subunit principle is mainly useful for reconstruction of the following subunits except which one?
   a. Tip
   b. Dorsum
   c. Alae
   d. Sidewall

3. The supratrochlear artery is located approximately how many centimeters from the midline?
   a. 0.5
   b. 1.5
   c. 2.0
   d. 2.5

164 Scalp Reconstruction: Role of Tissue Expansion and Flap Reconstruction

Stephanie E. Dreifuss, Mario G. Solari, Ernest K. Manders, Alex Senchenkov

INTRODUCTION

Scalp defects can occur secondary to trauma, tumor resection, infection, radiation, and congenital abnormalities. Strategies for scalp reconstruction must take into account the size of the defect, its characteristics, quality of surrounding tissue, donor site morbidity, timing of the adjuvant treatments, and patient-related variables. The reconstructive process may target skeletal and tissue defects. Staged revisional operations are commonly indicated in order to optimize aesthetic outcomes.

KEY OPERATIVE LEARNING POINTS

1. The scalp is a unique hair-bearing tissue and is best reconstructed using tissue expansion.
2. Full-thickness, composite, radiated, and very large defects require microvascular reconstruction that offers predictable and reliable results.
3. Secondary procedures such as flap debulking, cranioplasty with patient-specific implants, and tissue expansion are very useful in enhancing cosmetic and functional outcomes of the scalp reconstructive process.

PREOPERATIVE PERIOD

Preoperative Assessment

- Patient assessment is aimed to answer three questions:
  1. Is the tumor **resectable**?
  2. Is the resultant defect **reconstructible**?
  3. Is the patient **operable**, that is, able to withstand the proposed operation due to status of his or her general health?
- Resectability of the tumors is discussed in ablative chapters of the book.

History

- As in any preoperative assessment, it is critical to consider individual patient characteristics including **overall health** and **level of function** to establish their **operability.** Some patients may benefit from preoperative medical optimization to enable them to tolerate an operation and to optimize their healing potential.
- Patient **compliance** and **personal preference** should be taken into consideration prior to embarking on reconstruction that relies heavily on patient participation, such as frequent dressing changes or tissue expansions.
- Other specific patient and treatment characteristics, such as a plan for **adjuvant radiation** in oncologic patients or concomitant injuries in trauma or burn patients, must also be part of the patient assessment.

Physical Examination

- Characteristics of the defect:
  1. The most important factors that determine the reconstructive approach are defect **size**, **shape**, **location**, and **depth.**
  2. The condition of tissues surrounding the defect and the nature of **exposed structures** (soft tissue, periosteum, bone, or dura) may significantly influence the reconstructive plan to involve microvascular tissue transfer or calvarial reconstruction.
- **Surrounding tissue:** As with any defect, control of the wound is an important initial step in the reconstructive process.
  1. The optimal **quality** of surrounding tissues must be attained by either serial débridements or one-stage excisional preparation of the reconstructive site, whereby poor quality tissues such as **scars**, **chronic wounds**, **radiated or damaged scalp** are excised, and new wound edges consisting of healthy tissues capable of effective healing are established (Fig. 164.1A and B).
  2. In the cases of malignancies, **negative margins of resection** must be obtained. This issue becomes particularly relevant in the cases of aggressive tumors such as angiosarcoma of the scalp or poorly differentiated carcinomas. In such cases, scouting biopsies are performed first, and often several operations are necessary in order to achieve negative margins on permanent pathologic studies.
  3. Other important considerations unique to the scalp include the shape and symmetry of the **hairline, direction of hair growth, pattern of hair-bearing, or baldness** and **eyebrows**, all of which might be distorted by tissue rearrangement.
- **Flap**, **graft**, and **recipient vessel availability** are determined by the review of previous surgical history, available imaging, and, most importantly, physical examination.

Imaging

- **Computed tomography (CT) scan** is indicated in:
  - Patients undergoing oncologic reconstruction to ascertain depth of invasion or lymph node involvement
  - Trauma patients to determine the pattern or extent of concomitant injuries
- **Magnetic resonance imaging (MRI)** useful in
  - Assessment of tumor involvement of the skull
  - Intracranial invasion
- **Surgeon-performed duplex ultrasound** is the best in mapping out vasculature for free tissue transfer.

Indications

Primary indication for scalp reconstruction is a scalp defect with **exposed underlying structures** (galea, bone, dura, brain).

Reconstructive choices are largely dictated by the **size**, **condition,** and **extent of the defect**.

- Patients with radiation-related problems (i.e., osteoradionecrosis) or needing postoperative radiation, as well as the ones with large and composite defects, should be treated with microvascular tissue transfer if they can withstand surgical treatment.

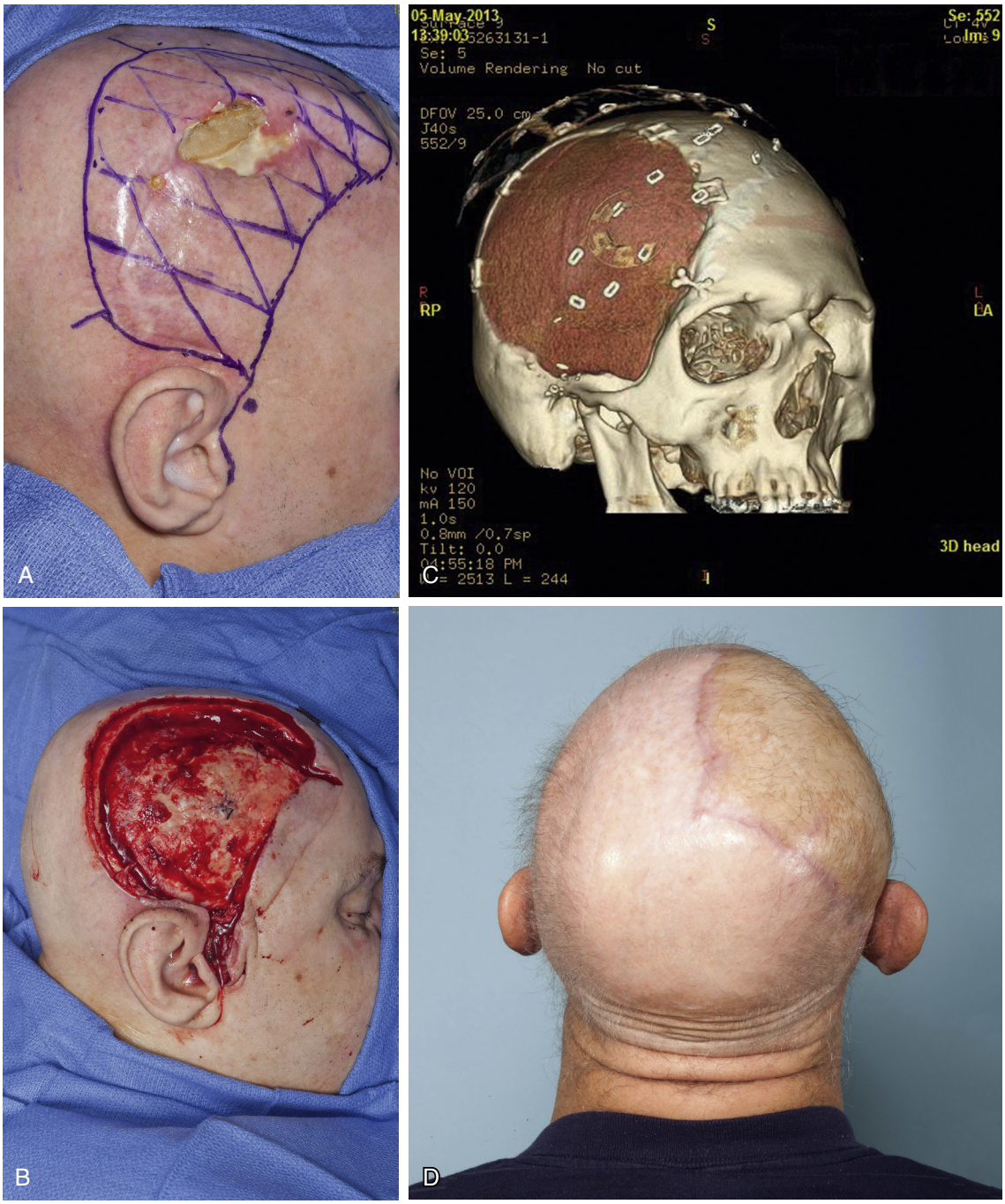

Fig. 164.1. A, The patient with a remote history of a radiated cranioplasty from combined treatment of the brain tumor, who developed infected osteoradionecrosis of the skull with an epidural abscess. **B,** Wide debridement and craniectomy, with immediate reconstruction using free latissimus dorsi muscle flap and temporary xenograft coverage were performed, which was followed by a staged full-thickness skin graft from the panniculectomy site and later a cranioplasty with the PEEK implant. Postoperative radiographic, **C,** and clinical, **D,** appearance of the patient-specific implant that was also designed to replace soft tissue deficit in the temporal fossa. (*Case of Giuseppe Lanzino, MD (Neurosurgery), and Alex Senchenkov, MD (Plastic Surgery), Mayo Clinic Foundation.)*

- Multiple reports support safety of microsurgery in the older but reasonably healthy patient, demonstrating that age should not be viewed as a contraindication to reconstruction and oncologically sound surgical care.
- In contrast, young and healthy individuals are the patients most likely to heal by secondary intention or with skin grafts. The healing area should be later revised with the help of serial excision and tissue expansion to minimize the sequelae of the scarring and loss of the hair-bearing scalp.

Contraindications

- Oncologic patients with **positive margins**, unless reconstruction is being performed for palliative purposes
- Defects that have been **inadequately débrided** and contain necrotic or nonviable tissue
- Wounds that contain **active infection**
- **Comorbidities** conferring an unacceptable surgical risk

Preoperative Preparations

- Consideration of patient preferences
- Preoperative evaluation may include cardiology evaluation or other assessment as indicated by the patient's past medical history.
  - **Cancer patients:** confirmation of negative margins and plan for adjuvant radiation
  - **Trauma patients:** management of concomitant injuries
  - **Infection:** Culture-specific antibiotic therapy is indicated if there is evidence osteomyelitis of the skull.
- **Imaging** as above
  - **Duplex ultrasound** to elucidate vasculature prior to free tissue transfer
- **Informed consent** should include discussion of risks, benefits, and alternatives of various reconstructive options. The patient needs to understand the need for various indicated procedures may arise intraoperatively.

OPERATIVE PERIOD

Anesthesia: General

Positioning: Supine unless the defect is posterior or the latissimus dorsi (LD) flap is used, which will require lateral decubitus positioning. Care must be taken to avoid pressure injuries, and the prolonged lateral decubitus position should be used with caution.

Perioperative antibiotics are administered according to the Surgical Care Improvement Project (SCIP) protocol.

Monitoring: Intraoperative monitoring depends on the reconstructive approach selected. Most techniques require standard anesthesia equipment and intraoperative monitoring. However, free tissue transfer may require arterial line placement for close blood pressure monitoring and blood draws throughout the procedure.

Instruments and Equipment to Have Available

Microsurgical and craniofacial instrumentation as dictated by the planned extent of the case

Key Anatomic Landmarks

- Scalp layer mnemonic: S.C.A.L.P.
  1. **Skin:** The skin of the scalp is thick and well vascularized.
  2. **Subcutaneous tissue:** Vessels, nerves, lymphatics, and hair follicles reside in the subcutaneous tissue of the scalp. Multiple connective tissue septations are present, providing additional mechanical rigidity. They secondarily prevent collapse of the transected vessels, hence the need for closure of the scalp lacerations to achieve hemostasis. The scalp also has a rich lymphatic network, which explains the aggressive lymphatic spread of some tumors in this location (e.g., malignant melanoma).
  3. **Aponeurosis** *(galea aponeurotica):* The galea (Latin: Roman leather helmet) is the layer of dense connective tissue continuous with the temporoparietal fascia, superficial muscular aponeurotic system (SMAS), frontalis, and occipitalis muscles; hence the term *aponeurosis.* The galea provides the strength of the scalp. Closure of this layer is critical in order to offload tension from the skin.
  4. **Loose areolar tissue:** The subgaleal layer is the mobile layer of the scalp. It is relatively avascular and is considered a safe dissection plane. Undermining in this plane allows for increased mobilization of the overlying scalp tissue. Similarly, this layer serves as a route of spread for hematoma, purulence, or excess fluid into the periorbital fat.
  5. **Pericranium:** This layer is the periosteum of the skull.
- Vasculature
  1. Arterial supply of the scalp comes from four territories with extensive collateralization:
     a. **Anterior:** The **supraorbital and supratrochlear arteries** arise from the internal carotid system and supply the lateral and medial forehead, respectively. Their territory extends to the anterior scalp.
     b. **Lateral:** The **superficial temporal artery**, a terminal branch of the external carotid system, supplies the largest territory of the scalp. These vessels should be considered in designing of the local flaps.
     c. **Posterior:** The **occipital arteries** supply the posterior scalp.
     d. **Posterolateral:** The **posterior auricular artery** supplies the smallest scalp territory.
  2. Vast anastomoses among arteries supplying these four territories allow for replantation of the scalp based on a single vessel.
  3. Venous drainage accompanies named arteries, and venous outflow may prove to be more problematic in scalp replantations and flap designs.
- Sensory innervation
  1. **Anterior:** The **supraorbital and supratrochlear nerves** arise from the ophthalmic branch of the trigeminal nerve and supply the anterior and anterolateral scalp.
  2. **Lateral:** The **zygomaticotemporal nerve** supplies the skin lateral to the temporal crest. It is a branch of the maxillary division of the trigeminal nerve.
  3. **Posterior:** The **greater and lesser occipital nerves** derive from spinal nerves and supply sensation to the posterior scalp.
  4. **Posterolateral:** The **auriculotemporal nerve** arises from the mandibular branch of the trigeminal nerve and supplies the lateral scalp.

Prerequisite Skills

Experience with the full spectrum of reconstructive techniques including both microvascular and craniofacial surgery will enable the surgeon to select the most effective reconstructive strategy.

Operative Risks

1. Morbidity and mortality related to patient's general medical condition. American Society of Anesthesiologists **(ASA) classification** has been adopted for preoperative risk stratification.
2. Nonmicrovascular reconstructive complications, e.g., graft failure, skeletal exposure, dehiscence of the closures, and healing delays, are common.
3. Microvascular complication related to high prevalence of thrombophilia in oncologic scalp patients may necessitate perioperative anticoagulation. Technical difficulty of the procedure is related to small diameter and anatomic variability of the recipient vessels; however, free flap losses are exceedingly rare, and reconstructive success is very high.

Surgical Techniques

- **Secondary intention:** Closure by secondary intention occurs by means of the buildup of granulation tissue and wound contracture.
  1. This process is enhanced by negative pressure wound therapy.
  2. In order for contracture to occur, a well-vascularized wound bed must be present at the base of the defect. Therefore, this method is appropriate for small defects without skeletal exposure.

3. Drawbacks to this technique include prolonged time to complete healing, the risk of displacing nearby structures secondary to wound contracture, and the resultant scar alopecia in the area of the wound.[1]
4. Historically, drilling openings in the outer table in order to gain access to a more vascularized diploic space was employed to enhance the growth of granulation tissue or incorporation of biologic matrix (Integra, Life Sciences, Plainsboro, New Jersey) with the goal of eventual skin graft. These techniques play a distant secondary role in the modern reconstructive practice because of prolonged healing times and suboptimal functional and cosmetic results. Lastly, a recurrence of the tumor in the setting of violated outer table will require full-thickness craniectomy.
5. Allograft, such as GammaGraft (Promethean Life-Sciences, Inc., Pittsburgh, Pennsylvania), or xenograft material can be applied to scalp wounds or exposed skull for a temporary coverage in preparation for reconstruction. Following tangential excision of the burns, allograft is used to "test-drive" the wound to ensure the future skin graft take. After one to three weeks, the allograft adherence is confirmed and a split-thickness skin graft can be performed. In tumor patients, delays in coverage are often related to pending pathologic confirmation of negative oncologic margins or confirmation of adequacy of tangential excision of burns.
6. A dermal regeneration template such as Integra (a bilaminar construct composed of a collagen layer covered with a silastic sheet) has a different purpose. Its main goal is to serve as a template for vascular and tissue ingrowth into the collagen layer to build a recipient tissue bed for a skin graft. The split-thickness skin grafts applied to either Integra or granulating skull are usually thin and fragile. They often result in prolonged healing times and long-term morbidity (Fig. 164.2).



Fig. 164.2. Long-term result of a reconstruction of the full-thickness scalp defect from angiosarcoma excision. The defect was initially covered with Integra applied to the pericranium (the periphery of the defect) and diploic matter of the skull in the central area, where the outer table was drilled out as a part of tumor resection. A split-thickness skin graft was used following incorporation of Integra. The patient has been suffering from dryness and continuous breakdowns of the fragile skin graft. *(Case of Ricky Cay, MD, Mayo Clinic Foundation.)*

- **Direct closure:** Given the mobility of the scalp in the subgaleal plane, primary closure of defects 3 cm or less may often be achieved with wide undermining of surrounding tissue, galeal scoring, and continuous external tissue expander application, e.g., DermaClose RC system (Wound Care Technologies, Inc., Chanhassen, Minnesota).[2]
  1. Attention must be paid to the resultant displacement of the hairline and eyebrows.
  2. To avoid scar widening and scar alopecia, layered closure with galeal approximation supports the overlying soft tissue closure.
  3. Primary closure of larger defects can be achieved in the parietal region where the tissue is more mobile; however, primary closure is more limited in the occipital region where less mobilization is possible.
  4. Additionally, a **coronal brow lift procedure** is useful in achieving direct closure of the small defects with a considerable secondary cosmetic benefit (Fig. 164.3A and B).
- **Skin graft:** Skin grafts require a healthy, granulating wound bed for optimal take and are usually inappropriate in radiated beds or wounds with skeletal exposure. Indications for skin grafting to the scalp are soft tissue wound with intact periosteum, well-excised burns, local flap donor site, and muscle free flap reconstruction.
  1. The drawbacks of the split-thickness skin graft to the scalp include contraction, color mismatch, alopecia, and long-term fragility (Fig. 164.2).
  2. Split-thickness skin grafts do not support hair transplantation or withstand adjuvant radiation well; hence they should generally be avoided in those settings.
  3. Full-thickness skin grafts fare better in either definitive reconstruction or in combination with muscle free flap (Fig. 164.1D).
  4. When coupled with tissue expansion, a split-thickness skin graft can later be excised to address these drawbacks (Fig. 164.4A and B).
- **Local flaps:** Local flaps, including transposition, advancement, and rotation flaps, are useful for reconstructing scalp defects.
  1. General principles for local flap reconstruction are inclusion of a named vessel when possible, flap delay procedures to provide reliable blood supply, design of a wider flap to augment perfusion, planning the resultant defect in the least cosmetically sensitive area possible, wide undermining and galeal scoring to increase flap advancement, and planning incisions parallel to hair follicles to avoid scar alopecia.[3]
  2. These flaps should be large in order to incorporate a sufficient number of vessels, accommodate the spherical shape of the skull, and allow for tension-free closure.
  3. The most common reason for local flap failure is venous insufficiency.
  4. Types of scalp flaps for small- and moderate-sized defects include advancement flaps, rotation advancement flaps, V-Y flaps, and bilobed flaps.[3]
  5. To close the resultant defect after local flap advancement or rotation, surrounding tissues can be widely undermined. If donor site primary closure cannot be achieved after this maneuver, skin grafting can be performed. Later, the skin graft can be excised and closed with the scalp skin gained by staged tissue expansion (Fig. 164.4A and B).
  6. For defects greater than 6 cm in diameter, multiple local flaps might be required.
  7. Ultimately, approach to closure with local flaps depends on the anatomic region of the scalp.
     a. Anterior defects can be closed using the Juri flap or temporo-parieto-occipital flap. This operation may involve a flap delay procedure, followed by elevation

of a flap based on the parietal branch of the superficial temporal artery, and transposition of this flap to the anterior hairline with primary closure of the parietal donor site.[4]

b. Large anterior or occipital defects are amenable to the Orticochea flap technique, which can reportedly close as much as 30% of the scalp. It employs bilateral flaps based on the superficial temporal arteries and a large posterior flap based on the occipital vessels.[5] This strategy imposes a large amount of scar on the scalp and may prove inadequate for larger defects, only moving an area of alopecia from one area to another, perhaps less obvious, area.

c. Vertex defects can be closed using pinwheel flaps, which recreate the natural whorl hair-bearing pattern of the vertex of the scalp.

- **Tissue expansion:** Tissue expansion is an invaluable and preferred tool for scalp reconstruction as it successfully replaces like with like, without leaving a donor site defect. Furthermore, as much as 50% of the scalp can be reconstructed with tissue expansion. Tissue expansion preserves normal sensation and hair growth orientation and results in a delay phenomenon, thereby increasing the vascularity of the expanded flap.

1. Requirements for tissue expansion include the absence of infection, the presence of healthy and well-vascularized tissue, no prior history of radiation, and a compliant patient willing to undergo the lengthy expansion process and resultant, temporary disfigurement.
2. Other disadvantages of tissue expansion include the risk of exposure, extrusion, device compromise, flap necrosis, and infection.
   a. A recent meta-analysis reported an overall 17.44% complication rate, with infection being the most common complication at a rate of 4.58%.



Fig. 164.3. A, Patient with full-thickness scalp loss from a burn that was reconstructed with a meshed split-thickness skin graft. **B,** A coronal browlift was performed for reconstruction of the defect from complete excision of the skin graft. (*Case of Alex Senchenkov, MD, Mayo Clinic Foundation.)*



Fig. 164.4. Staged reconstruction of the scalp defect from excision of the skin cancer: **A,** A rotational scalp flap and split-thickness skin graft of the donor site was performed, followed by the tissue expansion of the remaining scalp, and, **B,** complete excision of the skin graft. (*Case of Alex Senchenkov, MD.)*

b. Flap necrosis was found to occur at a rate of 3.65%, hematoma or seroma at a rate of 2.85%, exposure in 1.68%, and device malfunction in 1.54%.[6]
c. For these reasons, direct contact of a tissue expander with patient-specific cranioplasty implants and ventriculoperitoneal shunts should be avoided due to the risk of contamination.

3. It is a common practice to plan an incision for tissue expander placement either perpendicular to the axis of expansion or within an area that can be excised in the subsequent staged procedures. If remote incision is chosen, one should avoid compromising blood supply of any potential future flaps that will be used in subsequent stages of the reconstruction. The author's preference is to place an incision at the edge of the future defect or lesion.
   a. The expander is placed in the subgaleal plane and minimally filled intraoperatively with concentrated methylene blue dye to ease the postoperative identification. Gentle expansion can be started in a week as healing proceeds. Expansions are performed 1 to 2 times weekly.
   b. The endpoint for injection is when the patient reports the expansion is just beginning to feel uncomfortably tight. The expander may be overfilled to yield maximal tissue gain considering the curvature of the skull and the expected contraction following removal of the expander.
   c. It is important to measure the arc over the expander and subtract the base width to get an estimate of the tissue advancement possible.
   d. Upon final advancement of the expanded tissue, the expander capsule may be incised to allow for increased flap advancement to offset the planning imperfections. However, this maneuver does compromise the blood supply.

- **Free flaps:** A free flap is indicated for complex and composite defects with damage to surrounding tissues by radiation, burns, infection, osteoradionecrosis, or other insults or when vital structures such as dura or critical hardware are exposed. It provides immediate coverage for complex and composite scalp and cranial defects by providing healthy tissue with superior blood supply.
  1. Microvascular reconstruction plays a key role in oncologic cases that frequently require adjuvant radiation therapy that should be started within 6 weeks and completed within 100 days from the time of the resection for optimal oncologic outcome.
  2. The superficial temporal vessels are the preferred recipient vessels due to their proximity but not due to their quality. In fact, these are the most technically challenging recipient vessels in microsurgical practice. Particularly in women, they are frequently very small, spastic, and disproportionately afflicted with atherosclerosis. The surgeon may split the bifurcation to increase the diameter of these often sub-millimeter vessels or dissect the vessels to the level of the tragus as it dives under the parotid gland where the vessel caliber increases.
  3. Use of the facial, superior thyroid, and transverse cervical vessels as microvascular targets of free flap revascularization will require vein grafts to reach the defect (Fig. 164.5A) without compromising the aesthetic outcome of the operation (Fig. 164.5B).
  4. The surgeon must decide between the following microvascular reconstructive plans:
     a. Free muscle flap with skin graft vs. cutaneous free flap: Muscle with skin graft will not tolerate radiation as well as a cutaneous flap but is larger in size, better fills dead space, and enhances clearance of infection.

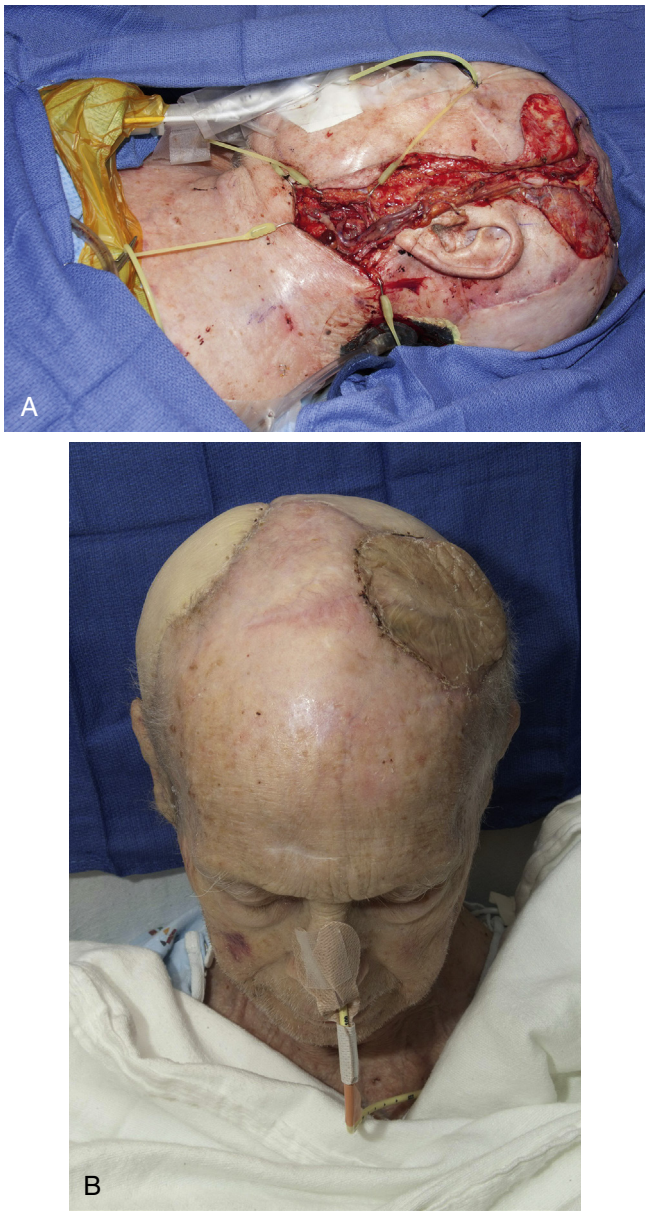

Fig. 164.5. Immunocompromised patient with recurrently recurrent squamous cell carcinoma of the scalp undergoing microvascular reconstruction of the Mohs defect with the third free flap. The left superficial temporal vessels had been used for revascularization of the previous free latissimus dorsi muscle flap for occipital defect reconstruction. The right superficial temporal vessels were used for free anterolateral thigh flap for right parietal defect reconstruction in the past. In the present case, the reversed greater saphenus vein graft connected the radial artery of the radial forearm flap to the facial artery and nonreversed vein graft and established venous outflow into the facial and external jugular veins, **A,** with successful reconstructive outcome, **B**. (*Case of Alex Senchenkov, MD, Mayo Clinic Foundation.*)

   b. Need and timing of staged cranioplasty
   c. Available donor sites and their morbidity: The transverse rectus abdominis musculocutaneous (TRAM) or deep inferior epigastric artery perforator (DIEP) donor sites are favored by most patients due to their positive cosmetic impact, while LD, if not used as a split muscle, may decrease strength in manual laborers and patients whose pectoralis major muscle was damaged.

   d. Defect size: small defects (radial forearm free flap or anterolateral flap [ALT]) versus large defects (TRAM or LD)
   e. Desire for hair restoration: Cutaneous free flaps can support hair transplantation whereas skin grafted muscle flaps cannot.
   f. Cosmetic expectations and willingness to undergo staged reconstructive procedures
5. An omental free flap with subsequent skin graft coverage was originally described for scalp reconstruction by Donald H. McLean and Harry J. Buncke in 1972, but its aesthetic outcome has been inferior.
6. In summary, microvascular tissue transfer effectively provides an immediate coverage solution in often desperate clinical situations.[7] Superb cosmetic and functional outcomes can be achieved by a combination of the reconstructive methods in the staged reconstructive process.

- **Calvarial reconstruction:** Indications for skeletal reconstruction associated with scalp defects include protection of underlying brain and restoration of normal contour.
  1. Options for reconstruction include autologous and alloplastic methods.
     a. Autologous techniques can involve banking and subsequent replacement of the original bone flap or split calvarial bone grafting from a remote area of the skull, ribs, or iliac crest. Parietal bone is preferred for split calvarial bone grafting due to its increased thickness.
     b. Alloplastic materials such as titanium mesh, polymethylmethacrylate, and hydroxyapatite have been historically used to rebuild full-thickness calvarial defects. Presently, superior computer-assisted design/computer-assisted manufacture (CAD/CAM) patient-specific implants of MEDPOR (Stryker, Kalamazoo, Michigan), PEEK (poly-ether-ether-ketone, KLS, Martin Group, Jacksonville, Florida), PEKK (poly-ether-ketone-ketone, Biomet, Jacksonville, Florida), and titanium (KLS, Martin Group, Jacksonville, Florida) are available. The advances in three-dimensional technology permit exact anatomic reconstruction of the missing skeletal and sometimes soft tissue elements (Fig. 164.1C).
  2. With any calvarial reconstruction, there is a risk of infection.
  3. Contour deformities are common in non-patient-specific reconstructions (Fig. 164.6).
  4. Autologous reconstructions carry the risk of graft resorption. One group reported infectious complications in 15.9% of cases.
  5. Infections did not appear to differ significantly between groups reconstructed with autogenous and alloplastic materials. Instead, infections were found to be related to preoperative radiation and infection history.[8] This information would indicate that the primary reason for cranioplasty complication was *insufficient soft tissue coverage*, which can be overcome with liberal use of microvascular tissue transfer or prior tissue expansion.
- **Replantation:** With the scalp being a specialized, unique tissue, complete or near complete scalp avulsions (Fig. 164.7A) are best managed with replantation or revascularization of the avulsed part (Fig. 164.7C). This technique is the ideal means of achieving a near-normal postoperative appearance.
  1. Avulsions are most likely to occur in the subgaleal plane (Fig. 164.7B). Due to the avulsion mechanism of injury, it is critical to assess the quality of the vessels, resect damaged vessels, and plan for vein grafting if necessary.



Fig. 164.6. The patient with composite excision of the locally advanced squamous cell carcinoma of the scalp and calvarium underwent reconstruction with an immediate off-the-shelf (non-patient-specific) titanium mesh and free latissimus dorsi muscle flap. A noticeable cranial asymmetry was the resultant complication. (*Case of Michelle Clarke, MD (Neurosurgery), and Alex Senchenkov, MD (Plastic Surgery), Mayo Clinic Foundation.*)

  2. The traditional teaching is that one arterial anastomosis is sufficient to sustain the entire scalp, but maximizing less-reliable venous outflow should also be emphasized.
  3. The only contraindications to scalp replantation are life-threatening conditions of the patient or a severely traumatized, lost, or improperly preserved avulsed part.

Common Errors in Technique

1. Failure to widely excise radiated tissues of poor quality to the extent of reconstructive capability
2. Underestimating tissue requirements and regenerative potential, and choosing reconstruction with local tissues instead of microvascular tissue transfer
3. Selecting noncustomized titanium mesh for reconstruction of a large calvarial defect that leads to poor symmetry and mesh show or exposure.

POSTOPERATIVE PERIOD

Postoperative Management

- **General principles:** Most scalp reconstructions that involve undermining or creation of dead space will require either drain placement or gentle head wrap to prevent postoperative seroma. Reston self-adhesive foam pads (3M, St. Paul, Minnesota) should be used carefully to avoid vascular compromise.
- **Specific considerations:** Other postoperative care is dependent upon the method of reconstruction.
  1. A patient undergoing closure by secondary intention should be educated in performing dressing changes, or there should be a compliant individual available to deliver wound care.

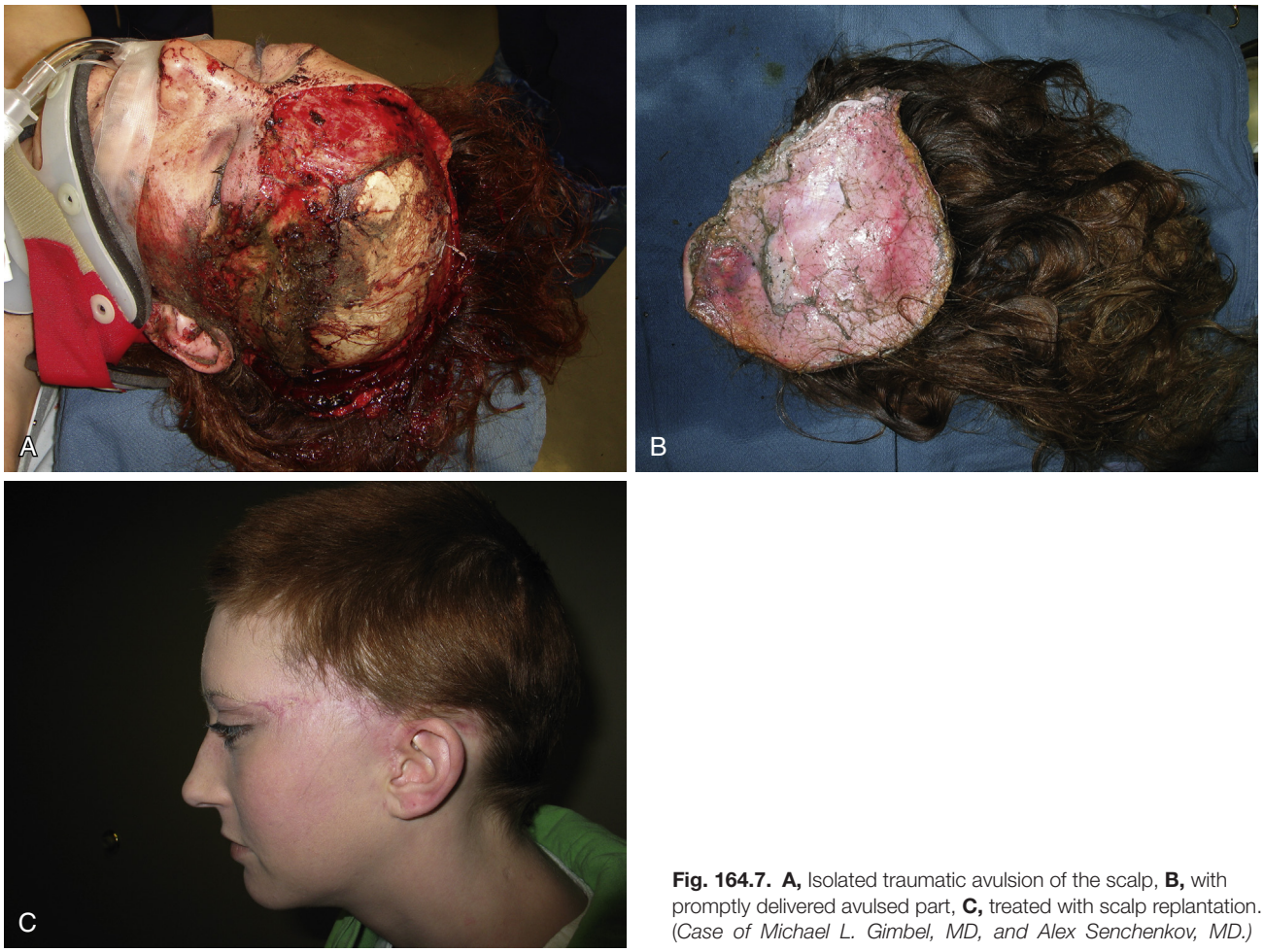

Fig. 164.7. A, Isolated traumatic avulsion of the scalp, **B,** with promptly delivered avulsed part, **C,** treated with scalp replantation. (*Case of Michael L. Gimbel, MD, and Alex Senchenkov, MD.*)

2. Skin grafts are best secured with a wound Vacuum-Assisted Closure (VAC) dressing (Kinetic Concents, Inc., San Antonio, TX). To optimize care of the skin graft, one layer of Xeroform is stapled or sutured to the skin and another layer to VAC sponge. The VAC dressing is applied for a period of 1 to 2 weeks. After its removal, the inner layer of Xeroform is left in place until the skin graft heals completely.
3. Free flaps and scalp replants require routine postoperative free flap monitoring. Flap color, capillary refill, temperature, and turgor should be assessed frequently, and arterial and venous signals should be monitored using handheld or implantable Doppler.
   a. For monitoring superficial temporal vessel-based free flaps, a Cook-Swartz monitor should be avoided because of the risk of the silicon cuff exposure due to the paucity of the overlying soft tissue.
   b. The ipsilateral temple also has to be removed from the patient's glasses for a period of 6 weeks to prevent pressure on the free flap pedicle.
   c. It is important to avoid pressure injuries to the fresh flaps. For occipital reconstructions the patient may need to be placed with his flap on a Clinitron portion of Rite Hite bed (**Hill-Rom, Inc.,** Batesville, Indiana) (upside down) or in a halo ring from PMT Halo Cervical Traction System (PMT Corporation, Chanhassen, Minnesota) to ensure protection of the flap.
4. In tissue expansion cases, expansions are initiated in approximately 1 to 6 weeks postoperatively and are continued 1 to 2 times weekly.
   a. Pain with expansions is an important consideration that often limits volume and frequency of expansion, and care should be taken to avoid pressure injuries to the fragile, expanding scalp.

Complications

- Unfavorable scarring, wound dehiscence, infection, and failure can occur with any reconstructive operation.
  - Complications specific to closure by secondary intention or skin grafting are unfavorable scarring, contraction distorting nearby structures, and graft failure.
  - Tissue expansion might be complicated by infection and exposure or extrusion of the prosthesis. Infection can be managed by removal of the expander, irrigation of the pocket, and delayed expander replacement in 3 to 6 months. Exposure can be managed with removal of the implant or dressing changes until closure is accomplished.
  - Local flaps can be complicated by seroma or hematoma, emphasizing the importance of meticulous surgical

technique and proper drain placement. Flap necrosis is often the result of inadequate flap design resulting from vascular, usually venous, insufficiency. Subsequent management of flap necrosis is usually conservative unless there is an exposure of the critical structures. Readvancing the flap that already has compromised circulation is ill advised. If a reconstructive procedure is still needed, an alternative, frequently microvascular approach, should be taken.

- Free flap cases have prolonged operative times with inherent risks of hypothermia, venous thromboembolism, and pressure injuries. Care should be taken to prevent these perioperative problems. Underbody warmers, warming blankets, and fluid warmers are standard practice. A prophylactic dose of subcutaneous heparin is administered prior to induction and repeated intraoperatively every 8 hours. Padding (e.g., full body silicone mattress and silicone shoulder and axillary rolls) is important.
- "Anesthesia mumps," an acute transient parotid swelling, has been observed in the patient in prolonged lateral decubitus position that was required for LD muscle flap reconstruction of the scalp. Padding and minimizing time in lateral decubitus position are useful.
- Prolonged scleral corneal protector causes corneal abrasion symptoms that are probably ischemic in nature. If possible, corneal protectors should be avoided.
- Microvascular complications are dealt with by early aggressive microvascular and pharmacologic methods.[9]

Revisional Reconstructive Procedures

- Given the many unique characteristics of the scalp and the aesthetic importance of this region, staged revisions are common.
- Deformities that may be addressed include alopecia, widened scars, standing cone deformities, displacement of mobile structures such as eyebrows, eyelids, or the hairline, color and texture mismatch of skin grafts, and contour deformities.
  - Alopecia can be managed with secondary local flaps, tissue expansion, serial excision, or hair transplantation.
  - Wide scars can be revised with re-excision and layered closure. In these situations, it is critical to close the galea to provide a strength layer and offload tension from the overlying skin.
  - Standing cones should be excised only after allowing sufficient time for resolution to pass, at least 6 weeks.
  - Should eyebrows or eyelids be displaced, full-thickness skin grafts, balancing direct and hairline browlifts, tissue expansion, or secondary local flaps should be performed to achieve improved symmetry.
  - Similar techniques can be used to restore a normal hairline pattern.
  - Skin grafts that cause a color or texture mismatch can also be managed with serial excision or tissue expansion.
  - Contour deformities may require secondary cranioplasty.

DISCUSSION

Evidence-Based Medicine Question

Controversy in reconstruction of the full-thickness scalp defects: to free flap or not to free flap and how "conservative" should we be?

Wide availability and superior outcomes of microsurgical reconstruction influenced the field of scalp reconstruction. Historically, scalp defects created a considerable problem in trauma and particularly in oncologic settings. The argument of what "conservative" reconstructive strategy is in management of scalp defect has been around ever since microvascular reconstruction of these defects gained momentum.

On one hand, reconstructive advantages of microvascular tissue transfer are difficult to overstate. Free tissue transfer supplies healthy, well-vascularized tissue to an area where the native tissue was compromised by trauma, malignancy, radiation, poor healing, or other insults. On the other hand, however, patients who require oncologic scalp reconstruction comprise a very challenging group with their advanced age, multiple comorbidities, and high prevalence of thrombophilia. The healing potential of these individuals is very poor. While there are not enough elderly patients with scalp defects to generate large studies, favorable observations have been made of the general safety of microvascular reconstruction in elderly patients with head and neck tumors (Ref A), renal failure Ref C and peripheral vascular disease Ref B. These patient groups have similar performance levels to patients with oncologic scalp defects. These parallels may support the trend toward more aggressive use of microsurgical reconstruction in managing patients with full-thickness scalp defects.

The technical reconstructive argument clearly favors microsurgical approach as opposed to drilling out the outer table and embarking on prolonged wound care. In a study by Upton et al., in a series of patients undergoing free flap scalp reconstruction, over half had undergone prior skin grafts or local flaps. In 95% of these patients, definitive reconstruction was achieved with free flaps. Microsurgical reconstruction compared favorably with nonmicrovascular management of the scalp defects. Using the microsurgical approach decreased the risk of complications, length of wound healing, and, thereby, the need for subsequent operations. Furthermore, microvascular tissue transfer allowed for a better cosmetic result by enabling the use of hair transplantation, liposuction, or other modalities to match the contour and other characteristics of the surrounding soft tissue.

The authors support the argument that perhaps a free flap is the most "conservative" treatment for the full-thickness defects of the scalp in the hands of proficient microsurgical and effective perioperative care teams.

Editorial Comment

The three most commonly used free flaps for scalp reconstruction are an ALT, RFFF, and latissimus free flap. A latissimus free flap covered with a skin graft often has an excellent aesthetic outcome after the latissimus muscle has atrophied. If a subsequent cranioplasty (i.e., with a PEEK implant or titanium) is needed, elevation and re-inset of free flap with a cutaneous paddle (i.e., ALT or RFFF) is likely to have less risk of wound breakdown than a latissimus flap covered with a skin graft.

Frederic W.B. Deleyiannis

Access the review questions and additional sources list online at http://www.expertconsult.com

REFERENCES

1. Angelos PC, Downs BW. Options for the management of forehead and scalp defects. Facial Plast Surg Clin North Am 2009;17:379–93.
2. O'Reilly AG, Schmitt WR, Roenigk RK, et al. Closure of scalp and forehead defects using external tissue expander. Arch Facial Plast Surg 2012;14:419–22.
3. Leedy JE, Janis JE, Rohrich RJ. Reconstruction of acquired scalp defects: an algorithmic approach. Plast Reconstr Surg 2005;116:54e–72e.
4. Juri J. Use of parieto-occipital flaps in the surgical treatment of baldness. Plast Reconstr Surg 1975;55:456–60.

5. Orticochea M. New three-flap reconstruction technique. Br J Plast Surg 1971;24:184–8.
6. Huang X, Qu X, Li Q. Risk factors for complications of tissue expansion: a 20-year systematic review and meta-analysis. Plast Reconstr Surg 2011;128:787–97.
7. Labow BI, Rosen H, Pap SA, et al. Microsurgical reconstruction: a more conservative method of managing large scalp defects? J Reconstr Microsurg 2009;25:465–74.
8. Reddy S, Khalifian S, Flores JM, et al. Clinical outcomes in cranioplasty: risk factors and choice of reconstructive material. Plast Reconstr Surg 2014;133:864–73.
9. Senchenkov A, Lemaine V, Tran NV. Management of perioperative microvascular thrombotic complications – the use of multiagent anticoagulation algorithm in 395 consecutive free flaps. J Plast Reconstr Aesthet Surg 2015;68:1293–303.
10. Manders EK, Graham WP III, Schenden MJ, Davis TS. Scalp expansion to eliminate large scalp defects. Ann Plast Surg 1984;12:305–12.

REVIEW QUESTIONS

1. In reconstruction of hair-bearing scalp, what reconstructive option produces the most natural result?
   a. Microvascular reconstruction with cutaneous free flap
   b. Local scalp flap
   c. Full-thickness skin graft over incorporated Integra bilayer
   d. Tissue expansion
   e. Healing by secondary intention

2. What scalp reconstruction technique is most likely to cause alopecia?
   a. Limiting tissue expansion to 25%
   b. Limiting tissue expansion to 50%
   c. Avoiding use of electrocautery
   d. Closing with staples
   e. Beveling skin incision

3. Which reconstructive technique delivers the most predictable reconstructive outcome in treatment of full-thickness scalp defects with cranial exposure?
   a. Drilling out of the cranium outer table and negative pressure wound therapy followed by skin graft
   b. Immediate application of Integra bilayer followed by skin graft
   c. Immediate or delayed scalp flap
   d. Microvascular tissue transfer
   e. Immediate placement of tissue expander and active expansion with temporarily covered wound

ADDITIONAL SOURCES

Shestak KC, Jones NF, Wu W, Johnson JT, Myers EN. Effect of advanced age and medical disease on the outcome of microvascular reconstruction for head and neck defects. Head Neck. Jan-Feb 1992;14(1):14–18.

Moran SL, Illig KA, Green RM, and Serletti JM. Free-Tissue Transfer in Patients with Peripheral Vascular Disease: A 10-Year Experience. Plast. Reconstr. Surg. 2002;109:999.

Moran SL, Salgado CJ, and Serletti JM. Free Tissue Transfer in Patients with Renal Disease Plast. Reconstr. Surg. 2004;113:2006.

165 Paramedian Forehead Flaps

Nathan Cass, Frederic W. B. Deleyiannis

INTRODUCTION

The origin of forehead flaps dates back thousands of years. Practitioners in ancient India were the first known to harvest skin from the forehead to repair facial defects, mainly of the nose. Due to nasal amputation as a common form of judicial and political punishment at the time, there was ample opportunity for the practice of reconstruction using forehead skin. Interestingly, the practitioners of the forehead flap surgical procedure belonged to the potter and tilemaker castes rather than that of the physicians. This method was kept as a closely guarded secret, passed down through oral tradition. The first written account of forehead flaps was a 1794 letter to the editor of the British periodical *Gentleman's Magazine*, likely written by Colly Lyon Lucas, the British chief surgeon of Madras, India. The first forehead flap performed in the West was in 1814 by Dr. Joseph Constantine Carpue of England. In the United States, John Mason Warren performed the first operation in 1834.

Further exploration and refinement of the forehead flap as a method of reconstruction followed throughout the 20th century. Forehead tissue is currently the gold standard for nasal reconstruction and is also used for many other facial defects. This chapter examines the use of the forehead flap in repairing defects of the head and neck.

KEY OPERATIVE LEARNING POINTS

- The size, shape, and location of the defect dictate the surgical planning of the forehead flap.
- As it courses superiorly, the supratrochlear artery passes superficial to the corrugator supercilii muscle and deep to the orbicularis oculi and frontalis muscles, piercing the frontalis to become subcutaneous 1 to 2.5 cm superior to the orbital rim.
- The base of an inferiorly based vertical forehead flap should be 1.0 to 1.5 cm wide, wide enough to allow for inclusion of the pedicle artery but narrow enough to permit easy rotation for preservation of length.
- The division and proximal inset of a forehead flap must be delayed until neovascularization of the flap has taken place.

PREOPERATIVE PERIOD

History

1. History of present illness
   a. Forehead flaps are most commonly used to reconstruct defects of the nose.
   b. The mechanism of tissue loss may be excision of a cancer, trauma, infection, or congenital defects.
2. Past medical and surgical history
   a. Previous soft tissue trauma to the forehead (i.e., old lacerations, excision of cancer) can potentially disrupt the blood supply to a forehead flap.
   b. Age and comorbid conditions should be ascertained, as they dictate the patient's American Society of Anesthesiologists (ASA) classification and risk of general anesthesia.
   c. Patients must be psychiatrically stable and emotionally prepared if they are to undergo a multiple-stage flap reconstruction.
3. Medications
   a. If a patient is taking anticoagulation medication, the necessity of the anticoagulation and the potential health risks of temporary cessation or bridging should be weighed.
4. Social history
   a. Smoking is associated with a higher risk of complications (i.e., ischemia of the flap and delayed donor site healing).

Physical Examination

1. Characteristics of the defect to be reconstructed (Fig. 165.1)
   a. Size: Though the majority of defects are successfully reconstructed with a paramedian forehead flap, a median forehead flap may provide a larger surface area for a near-total nasal reconstruction.
   b. Shape: Dictates the design of the forehead flap. For example, the three-dimensional contour of a large nasal defect requires precise planning (i.e., a template of the nose is designed on the forehead) to reconstruct the different subunits of the nose (Fig. 165.2).
   c. Location: To reach inferior defects, such as a columellar defect, the forehead flap may occasionally need to be extended into the frontal hairline. To avoid the hairline, the flap can be lengthened by extending the incisions inferiorly into the brow or by designing it slightly obliquely.
   d. Tissue missing: The skin of the forehead flap is routinely used for reconstructing the cutaneous component of a nasal defect. Other options must be included to reconstruct composite nasal defects (i.e., defects involving cartilage and nasal lining).

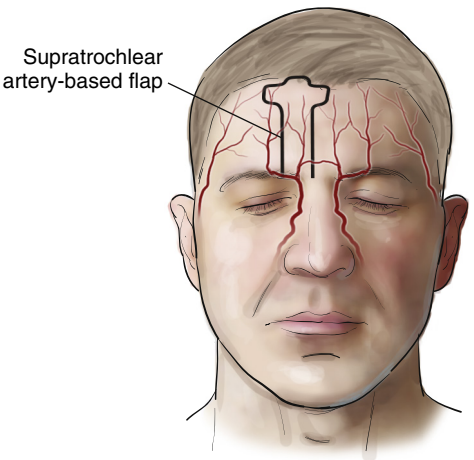

Fig. 165.1. Paramedian forehead flap based on right supratrochlear artery. (*With permission from Medscape article "Forehead Flaps" by Dr. Stephen Park*, http://emedicine.medscape.com/article/880171-overview#a10.)

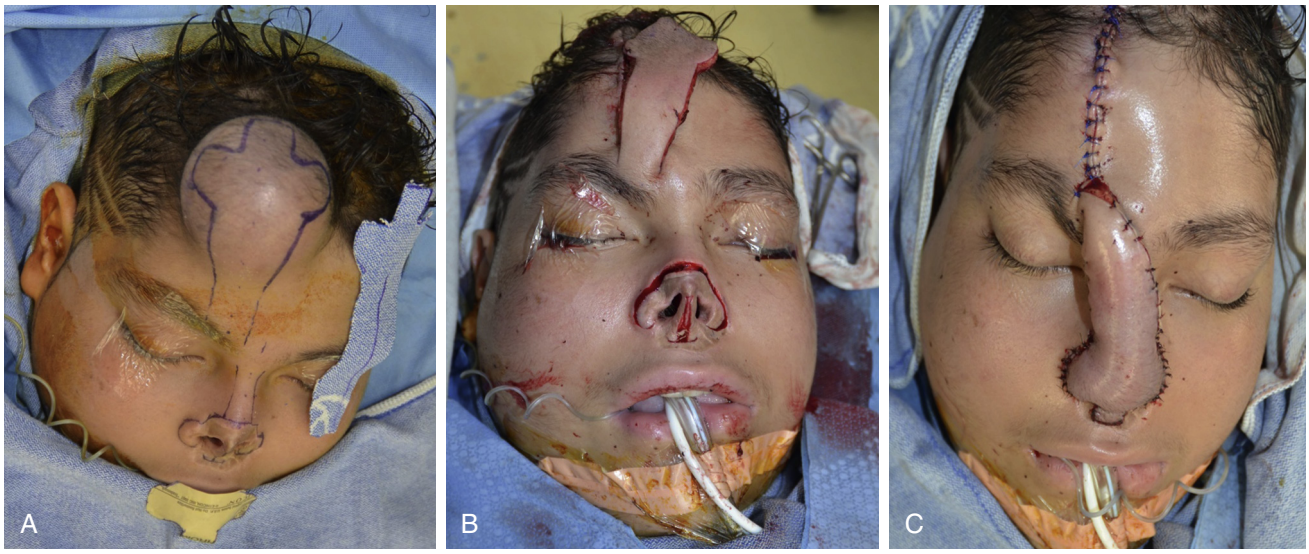

Fig. 165.2. Nasal tip, alae, and columella reconstruction with an expanded forehead flap. A, Tissue expansion complete, template of the nasal defect outlined on the expanded forehead flap. **B,** Expander removed, flap about to be rotated. **C,** Nasal defect reconstructed, forehead closed primarily.

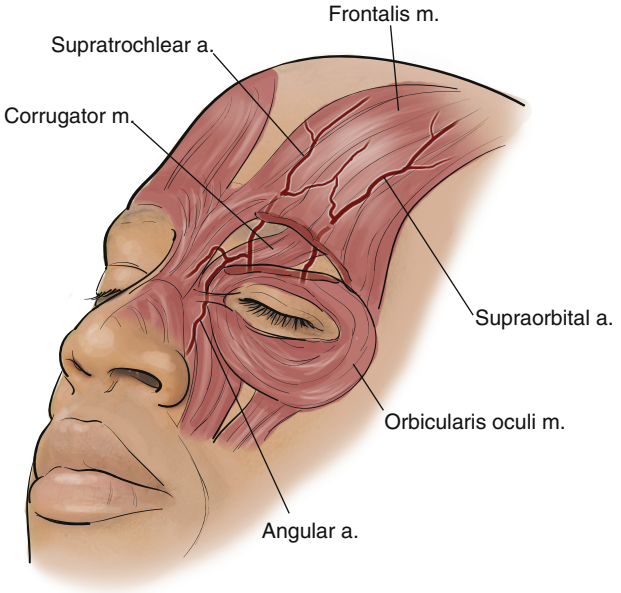

Fig. 165.3. Periorbital vessels and muscle relationships. (*Redrawn from Medscape article "Forehead Flaps" by Dr. Stephen Park,* http://emedicine.medscape.com/article/880171-overview#a10.)

2. Forehead examination
   a. Examine the forehead skin for any abnormality (i.e., scar, actinic changes) that could affect blood supply, the quality of the skin, or the ability to close the defect created by raising the forehead flap.
   b. Note the position of the frontal hairline.
   c. The distance from the base of the forehead flap to the defect must be meticulously measured to ensure adequate length once the flap is rotated.
   d. Consider the possibility of using tissue expanders (see Fig. 165.2) for excessively wide defects.[1]

Imaging

- Imaging is not necessary in the surgical planning of a forehead flap.
- Intraoperative Doppler may be used to mark the course of the supratrochlear artery.

Indications

- Nasal cutaneous defects[2-4]
- Periorbital and cheek defects when other local options (i.e., cheek advancement flaps) are not available

Contraindications

- Not medically stable to undergo local anesthesia with sedation
- Psychiatrically or emotionally unstable (especially for multistage procedures)
- Significant scarring, previous radiation therapy to the forehead, or other previous surgery (i.e., bicoronal incision for access the frontal skull), which may disrupt adequate blood flow and preclude its use as donor tissue
- Active smoking is not an absolute contraindication to surgery but should be approached with caution. Delayed procedures (e.g., incising the perimeter of the flap without initially raising it) may be advised.

Preoperative Preparation

- There are many options for the reconstruction of nasal defects. The surgeon and the patient should carefully decide which best fits the needs of the defect and the patient. Healing by secondary intention, primary closure, skin grafting, and other local flaps are alternative options (see Chapter 163).
- Timing of reconstruction
  - After creation of the defect (i.e., after Mohs surgery): The reconstruction may be more definitively planned preoperatively since the extent and location of the defect is known.
  - Concurrent with the creation of the defect (i.e., intraoperatively after tumor margins have been cleared with frozen sections): Preoperative counseling will likely include more reconstructive options since the extent of the defect is not precisely known before tumor excision. Delayed reconstruction pending final pathology margins is often desirable.

- Optimization
  - Medical conditions: Obtain medical clearance for general anesthesia if necessary.
  - Discontinuation of anticoagulation if possible
  - Cessation of smoking
- Photographs to document the defect, reconstructive options, and outcomes

OPERATIVE PERIOD

Anesthesia

1. General anesthesia is preferable for most forehead flaps for patient comfort and intraoperative planning.
2. For patients unable to tolerate this, performing the operation under local anesthesia with IV sedation is acceptable.
   a. Either lidocaine or a mixture of lidocaine and bupivacaine will work well for local anesthetic infiltration, and benzodiazepines given intravenously may provide adequate relaxation and sedation.

Positioning

- Supine: The bed is turned 90 degrees, allowing access to both sides of the face, forehead, frontal scalp, nose, ears, and neck so that symmetry can be checked and cartilage grafts can be harvested if necessary.

Perioperative Antibiotic Prophylaxis

1. First-generation cephalosporin
2. Clindamycin for cephalosporin allergy

Monitoring

- Standard intraoperative monitoring should be used: EKG, pulse oximetry, end-tidal CO_2, and temperature probe.

Instruments and Equipment to Have Available

- Plastic surgery soft tissue tray containing #15 C blades, small double-pronged skin hooks, iris scissors, and 0.5 toothed forceps
- Needle tip cautery and bipolar cautery
- Sterile Doppler
- Rhinoplasty set to evaluate the nasal airway

Key Anatomic Landmarks

Forehead Blood Supply

1. Internal carotid artery (ICA) supply
   a. Ophthalmic artery is the first branch of the ICA
      1) Supraorbital artery: Courses superior to the center of the globe; exits the skull at the supraorbital foramen or notch to give blood supply to the forehead region superior to the midorbits
      2) Dorsal nasal artery: One of the two terminal branches; it courses anteroinferomedially along the medial canthal region and down to the superior nasal sidewall. At the anastomosis with the angular artery, there is often a central artery that courses superiorly to supply the glabella and the inferior portion of the central forehead.
      3) Supratrochlear artery: One of the two terminal branches; it exits the skull at the superomedial aspect of the orbit above the medial canthus and courses in a superior direction to supply the forehead tissue above its origin.
2. External carotid artery (ECA) supply
   a. Facial artery: Travels superomedially over the mandible, giving off the inferior and superior labial arteries. The terminal branch is the angular artery, which gives off the lateral nasal branch before continuing a superomedial course past the medial canthus to anastomose with the dorsal nasal artery and occasionally with the supratrochlear artery. After this anastomosis, the angular artery contributes to a central artery, which courses in a superior direction near the midline of the forehead.
   b. Superficial temporal artery: One of the two terminal branches (the other is the internal maxillary artery); it arises between the superficial and deep lobes of the parotid gland, gives off the transverse facial artery—which courses anteriorly to supply the lateral face—then terminates in two branches. The parietal branch supplies the posterosuperior scalp, and the frontal branch courses anteriorly to supply the lateral forehead where it anastomoses with the supraorbital artery.

Prerequisite Skills

- Training and experience handling soft tissue, designing advancement–rotation cutaneous flaps, and raising pedicled flaps
- Training in functional rhinoplasty

Operative Risks

- Partial or complete flap loss
- Hematoma
- Infection
- Scalp numbness
- Brow and/or frontal hairline distortion or displacement
- Prolonged or poor wound healing at the forehead donor site

Surgical Technique

1. Flap design
   a. Inferiorly based: Most often used for nasal reconstruction
      1) Types (see Fig. 107.1)
         a) Paramedian[2-4]: Supratrochlear artery pedicle, skin flap centered over supratrochlear artery
         b) Midline[5]: Supratrochlear artery pedicle, skin flap centered in middle of forehead, nutrient artery on lateral edge of flap
            i) The central artery may also be used, which allows the flap to be based more inferomedially along the orbital rim and gives more length before reaching the hairline, which results in less hair-bearing skin transfer to the face.
         c) Median: Bilateral supratrochlear arteries; flap is more broad-based but with a decreased arc of rotation given the width of the base.
      2) Supratrochlear artery localization
         a) Doppler ultrasonography. However, landmarks may reliably be used to locate the supratrochlear artery instead of a Doppler.
         b) Multiple studies have confirmed that the supratrochlear artery is approximately 1.25 to 1.5 cm lateral to the midline at the orbital rim.
      3) Supratrochlear artery course (Fig. 107.3)
         a) Superficial to corrugator supercilii and deep to orbicularis oculi and frontalis muscles
         b) Pierces the frontalis muscle to become subcutaneous 1 to 2.5 cm superior to the orbital rim

4) Technique
   a) Outline the flap with a skin marker.
   b) The flap should be based above the medial canthus with its center approximately 1.25 to 1.50 cm lateral to midline.
   c) Design a flap width of 1.0 to 1.5 cm—wide enough to allow the supratrochlear artery to be encompassed within the flap with a margin on either side.
   d) The skin paddle at the superior end may be widened if the defect to be reconstructed requires a larger area of skin.
   e) Before making an incision, make a template of the flap (i.e., with a cut towel; see Fig. 107.2) and then rotate this template to the defect with the base of the flap (i.e., template) held in position. One can then check to see if the flap length and design are appropriate for the defect.
   f) In multistage procedures (i.e., three-stage nasal reconstruction[3]) include full-thickness frontalis muscle in the distal end of the flap in order to minimize contraction; the flap may be thinned at subsequent procedures.
   g) Try to design the forehead flap just below the hairline to avoid transfer of hair-bearing skin to the nose or face.
   h) The flap is inset into the nasal defect with 5.0 nylon sutures; a few deep dermal sutures may also be placed.
      i) To decrease the bleeding on the undersurface of the forehead flap (i.e., the bridge over the intact nasal skin), one can skin graft this area with a split thickness graft or apply Alloderm.

b. Laterally based: Best for reconstruction of defects of the orbit or cheek if other local flaps (i.e., cervicofacial advancement flaps) and the midline blood supply of the forehead are not available.
   1) Blood supply: Based on a superficial temporal artery (STA) or bilateral STAs. The donor site may be quite conspicuous when a large laterally based flap is used for midface defects.

2. Stages of reconstruction
   a. Multistage procedures
      1) First operation: Flap is initially sewn into the defect with the middle of the flap, forming a bridge over the intervening intact skin. Easy flap visualization allows ability to monitor for ischemia or venous congestion. If the pedicle is twisted, causing decreased perfusion, it may be detached from the defect and rotated back into its native position to reestablish blood flow. The flap would then be re-rotated back into the defect approximately 5 to 7 days after its initial harvest (i.e., increased perfusion based on the delay phenomenon).
      2) Second operation (optional): The flap is raised from the defect and is thinned to match the defect site. Cartilage grafts may be placed or thinned.
      3) Third operation: The flap pedicle is divided, and the proximal edge of the flap is inset into the defect for circumferential closure.
   b. Single-stage procedure—island flap: The pedicle may be de-epithelialized and the flap tunneled through the subcutaneous tissue. The disadvantages of a single-stage forehead flap include the possibility of increased pressure on the artery and vein of the pedicle from the tunneling, which could then result in ischemia or venous congestion.

3. Donor site closure
   a. Primary closure: Most preferable; may be accomplished if the flap is narrow or tissue expanders have been used (see Fig. 107.2)
   b. Secondary intention routinely yields a very acceptable scar. The donor site is kept moist with antibiotic ointment or Vaseline until it heals secondarily.
   c. Skin grafts are not routinely used.

Common Errors in Technique

- Insufficient flap length
  - Flap must be meticulously measured and re-measured to ensure adequate length.
  - Surgeon must account for loss of length that occurs with rotation of flap.
  - The inset of the forehead flap on the nasal defect must be tension-free.
- Inclusion of frontal hair in the forehead flap

POSTOPERATIVE PERIOD

Postoperative Management

1. Patients are often discharged the same day after a forehead flap. For patient comfort (i.e., oozing from the undersurface of the forehead flap or pain) or because of comorbid conditions, 23-hour or inpatient admission may be warranted.
2. If flap perfusion is in question or if the flap appears with excessive venous congestion, the patient should be brought back to the operating room and the flap rotated back into its native position.
3. Many forehead flaps will appear slightly congested (i.e., slightly blue) once rotated into the defect. This slight congestion resolves within 2 to 3 days.
4. The division of the forehead pedicle must be delayed until neovascularization of the flap has taken place. This can usually safely be done after 3 weeks.
5. Minor interventions, such as dermabrasion and additional debulking, may be advised after final healing has taken place (6 to 12 months) to smooth the transition areas between the flap and native nasal skin.

Complications

- Partial flap loss due to arterial insufficiency or venous congestion
- Poor cosmetic outcome: Scarring, notching, poor color matching, eyebrow malposition, transfer of hair-bearing skin to a non-hair-bearing area

DISCUSSION

Evidence-Based Medicine Question:

During a multistage reconstruction of a nasal defect with a forehead flap, what is the most appropriate length of time to delay the second stage?

The currently accepted standard is to delay the final stage for at least 3 weeks for most patients and longer in smokers or patients with other small vessel disease (hypertension, diabetes.). The delay allows time for neovascularization to occur to the skin flap from the tissue surrounding the defect. Based on intra- and postoperative angiography using laser-assisted indocyanine green imaging, some studies assert that neovascularization of the flap occurs at 1 to 2 weeks and advocate for earlier pedicle division and inset of the flap in order to reduce facial deformity. Gentle manual compression of the pedicle can also be done in

the clinic to ensure that the distal end of the flap has become vascularized (i.e., remains pink) from the recipient tissue. If the skin of distal forehead flap remains pink, the surgeon may then commence with the final stage of reconstruction. If the capillary refill is questionable, the division of the pedicle should be delayed.

Editorial Comment

Tissue expansion may be used to expand the width and length of a forehead flap, but expanded tissue may contract as it heals. Tissue expansion of the forehead may also be used after a forehead flap has been raised to decrease any wide scars of the forehead that are a result of secondary healing at the donor site.

Frederic W. B. Deleyiannis



Access the review questions and additional sources list online at http://www.expertconsult.com

REFERENCES

1. Wang Q, Song W, Hou D, et al. Expanded forehead flaps for reconstruction of different fasciocervical units: selection of flap types based on 143 cases. Plast Reconstr Surg 2015;135(5):1461–1471.
2. Shumrick KA, Smith TL. The anatomic basis for the design of forehead flaps in nasal reconstruction. Arch Otolaryngol Head Neck Surg 1992;118(4):373–379.
3. Menick FJ. A 10-year experience in nasal reconstruction with the three-stage forehead flap. Plast Reconstr Surg 2002;109(6):1839–1855.
4. Yu D, Weng R, Wang H, et al. Anatomical study of forehead flap with its pedicle based on cutaneous branch of supratrochlear artery and its application in nasal reconstruction. Ann Plast Surg 2010;65(2):183–187.
5. Faris C, van der Eerden P, Vuyk H. The midline central artery forehead flap. JAMA Facial Plast Surg 2015;17(1):16–22.

REVIEW QUESTIONS

1. What is the arterial blood supply to a paramedian forehead flap?
   a. Angular artery
   b. Dorsal nasal artery
   c. Superficial temporal artery
   d. Supraorbital artery
   e. Supratrochlear artery

2. What is the typical time for the division of the pedicle of a forehead flap in a smoker in a two-stage nasal reconstruction?
   a. 3 to 5 days after flap harvest and inset
   b. 1 week after flap harvest and inset
   c. 2 weeks after flap harvest and inset
   d. 3 weeks or greater after flap harvest and inset
   e. 6 months after flap harvest and inset

3. Which muscle is deep to the supratrochlear artery during its course superiorly over the forehead?
   a. Corrugator supercilii
   b. Frontalis
   c. Orbicularis oculi
   d. Nasalis
   e. procerus

ADDITIONAL SOURCES

Kleintjes WG. Forehead anatomy: arterial variations and venous link of the midline forehead flap. J Plast Reconstr Aesthet Surg 2007;60(6):593–606.

Surowitz JB, Most SP. Use of laser-assisted indocyanine green angiography for early division of the forehead flap pedicle. JAMA Facial Plast Surg 2015;17(3):209–214.

Xiang XF, Cheng B, Tang JB, et al. The scalping forehead flap for 1-stage reconstruction of large facial defects after tumor resection. J Craniofac Surg 2013;24(4):e346–e347.

Yalamanchili H, Sclafani AP, Schaefer SD, et al. The path of nasal reconstruction: from ancient India to the present. Facial Plast Surg 2008;24(1):3–10.

166 Pericranial Scalp Flap

Brian D. Thorp, Satyan B. Sreenath, Adam Zanation

INTRODUCTION

Surgical extirpation and reconstruction represent the shared common core goals in both open and endoscopic anterior skull base surgery. Successful operative intervention requires thoughtful planning in the context of the patient's anatomy, pathology, and comorbidities.

It is important to realize that the goals for the treatment of benign processes differ from those of malignant processes. Although gross total resection is always favored, surgical decompression with attempts at complete surgical excision without undue morbidity should always be the default with benign pathologies. In contrast, the treatment of malignant processes requires clear surgical margins.

Reconstructive efforts of the skull focus on the watertight separation of the cranial cavity from the upper aerodigestive/sinonasal tract. This separation is required to minimize the risk of postoperative cerebrospinal fluid (CSF) leak and associated sequelae such as meningitis and/or pneumocephalus. Reconstruction should also provide the obliteration of dead space, preservation of function, and restoration of cosmesis.

An array of skull base reconstruction options exists ranging from acellular grafts to vascularized flaps. This chapter will focus on the pericranial flap (PCF), a vascularized pedicled flap based on the supraorbital and supratrochlear arteries. This versatile flap has been used in a multitude of applications throughout the skull base and head and neck, and often represents the primary reconstructive choice in open anterior skull base procedures and the primary extranasal reconstructive choice in endoscopic anterior skull base procedures. It should be noted that the galeopericranial flap is also a vascularized pedicled flap based on the supraorbital and supratrochlear arteries. In addition to including the pericranium and immediately superficial loose areolar tissue, this flap includes the galea, thereby providing the reconstructive surgeon with a thicker pedicled flap.

KEY OPERATIVE LEARNING POINTS

1. The PCF is a vascularized pedicle flap based on the supraorbital and supratrochlear arteries and can be used in open and endoscopic anterior skull base reconstruction.
2. The pericranium includes the calvarial periosteum and associated areolar tissue lying deep to the galea. The flap can be elevated and used without risk to the remaining scalp.
3. The endoscopic-assisted PCF can be accessed and elevated using an array of incisions. We favor a trichophytic incision at our institution. When used in the setting of an endoscopic skull base resection, only half of the pericranium should be used, thereby maintaining an additional PCF option for future potential usage.
4. Although an extended PCF can be elevated via open or endoscopic techniques, with a length adequate to reach clival defects, it is most frequently used for defects in the anterior cranial fossa and sella.

PREOPERATIVE PERIOD

History

1. History of Present Illness
   Patients who present to the skull base surgeon often require a multidisciplinary approach to ensure accurate diagnosis and evaluation for optimal therapy. A detailed description of this critical portion of the evaluation is outside the scope of this chapter, but should focus on identifying clinical features that afford insight into the clinical progression, involved primary and adjacent structures, and the potential for regional or distant disease. This information should guide further investigations and frame patient counseling.
2. Past Medical History
   After identifying those patients who require anterior skull base surgery for which a PCF is considered, several factors must be taken into account.
   a. Prior interventions that may affect the viability, presence, or healing capacity of the PCF and/or scalp.
      1) Prior maxillofacial trauma that could have disrupted the vascular supply.
      2) Prior transcranial or endoscopic surgery for which a PCF was used or transgressed. At our institution in the setting of a previously used PCF where a contralateral flap is not available, consideration of other reconstructive options such as a tunneled temporoparietal fascia flap or free tissue transfer is required.
      3) Prior radiation therapy (including the scalp) that could affect wound healing or increase the difficulty of flap elevation must be considered. Of note, the report of a recent review indicated that there was no significant difference in the rates of CSF leak between those receiving radiation therapy (8.1%) and those not receiving radiation therapy (2.6%).[1]
   b. Medical Comorbidities
      1) Diabetes mellitus, hypercortisolism, poor nutritional status, and cigarette smoking are risk factors for delayed wound healing and should be taken into account by the surgical team.
   c. Medications
      1) All efforts should be made to hold antiplatelet and anticoagulants prior to surgical intervention to minimize the risk of excessive bleeding or the development of a hematoma in the donor site or surgical site.

Physical Examination

A comprehensive physical examination is of upmost importance when evaluating patients for skull base surgery. The physical examination should consider findings that indicate the degree of tumor extension including local mass effect and cranial nerve neuropathies. A thorough review of these features is outside the scope of this chapter, but a specific notation should be made regarding evaluation of the scalp for potential development of a PCF.

1. Evaluation of the scalp
   a. Prior incisions or scars should prompt directed questioning to ascertain the likelihood of a viable PCF. Suspected damage to the vascular supply or prior usage essentially eliminates its use in reconstruction of the skull base.
   b. Evaluation of the hair and hairline should also be noted, because this will help the reconstructive surgeon plan the incisions for flap access. Additionally, the facial skeleton and position of the calvarial convexity should be noted, because an incision placed anterior to or posterior to the convexity may make complete elevation of the flap challenging when using an endoscopic-assisted approach.
2. Nasal endoscopy
   a. Bilateral sinonasal endoscopy provides the reconstructive surgeon with critical information regarding the location of the tumor and helps to determine the availability of intranasal vascularized flap options (i.e., nasoseptal flap [NSF]), which are often unavailable in revision surgery or when malignant tumors involve the nasal septum.

Imaging

1. Anatomic imaging
   a. The evaluation of the primary site requires at least a computed tomography (CT) maxillofacial scan with image guidance protocol and a complementary contrasted magnetic resonance imaging (MRI) scan of the brain with image guidance protocol. These studies are critical in allowing the skull base team to assess the burden of disease, surrounding critical neurovascular structures, candidacy for resection, and the projected surgical defect.
   b. Such studies can also provide clues to the availability of intranasal vascularized flaps that may not be obvious on sinonasal endoscopy.
2. Imaging studies for staging should be sought in patients with malignant tumors to ensure appropriate treatment goals and treatment planning.

Indications

1. In open transcranial anterior skull base surgery, the PCF remains the most frequently used flap with its passage inferior to the supraorbital bone segment into the surgical defect with suturing and/or apposition to the resection margin.
2. Endoscopic anterior skull base surgery
   - Vascularized reconstruction produces lower rates of postoperative CSF leaks compared with free grafts in the presence of large dural defects.[2] It is preferable in repair of defects localized to the clivus and in patients with high-flow intraoperative CSF leaks.[3]
   - The PCF is the primary extranasal vascularized pedicle flap used at our institution when intranasal options are not available in the presence of large dural defects and/or high-flow CSF leaks localized to the anterior fossa/ethmoid roof and sella.[4]
   - Using radiological studies, the distance of the defect, locations, and size estimates of the PCF needed to fill defects were performed. Using a 3-cm correction factor accounting for flap transposition through the nasionectomy and retraction, the following flap length estimates were needed to reach the following defects: 11.31 to 12.44 cm for anterior fossa defects, 14.31 to 15.57 cm for sellar defects, and 18.3 to 20.42 for clival defects.[5]

Contraindications

1. Prior compromise of the vascular supply.
2. Prior flap usage without a contralateral option or flap transgression.
3. Defects localized to the posterior fossa/clivus; the defect generally lies at the distal-most aspect of an extended flap with the possibility of poor or inadequate coverage of the defect.

Preoperative Preparation

Prior incisions of the face/scalp should be evaluated to determine whether the blood supply (supratrochlear, supraorbital vessels) to the PCF is intact. Alternative flaps or materials should also be considered in reconstructing the skull base in the event of injury to the PCF's blood supply during harvest. The size of the expected defect/s will determine the length and design of the PCF.

OPERATIVE PERIOD

Anesthesia

General anesthesia is used, given the need for skull base dissection and/or reconstruction. Paralysis may or may not be used and is dictated by the need for neurophysiological monitoring during the resection portion of the operation.

Positioning

At the discretion of the surgeon, the patient may be placed in a supine position or in a modified "beach chair" position, with the head of the bed elevated and feet lowered. Occasionally, a mild degree of reverse Trendelenburg can also be used to optimize positioning and assist in visualization.[6] Mayfield pin immobilization may be used for open or combined approaches. For endoscopic procedures, pin immobilization is not required, and the head should be turned slightly toward the operating surgeon.

Perioperative Antibiotic Prophylaxis

1. Ceftriaxone, a third-general cephalosporin with good CSF penetrance, is used in patients without a documented allergy to penicillin.
2. Clindamycin is used in patients with a documented allergy to penicillin.

Monitoring

Intraoperative monitoring other than that for general anesthesia is generally not indicated in the harvest and inset of the PCF.

Instruments and Equipment to Have Available

1. Open/Combined
   a. Rainey clips with appropriate clip appliers.
   b. Transcranial instruments including a pneumatic drill with burs.
   c. High-speed drill with 3- and 4-mm course diamond burs.
   d. Microdissection instruments.
   e. Monopolar and bipolar cautery, hemostatic agents, and an array of pledgets.
   f. Commercially available dural substitutes for grafting.

2. Endoscopic
   a. Basic endoscopic sinus surgery set.
   b. High-speed drill with 3- and 4-mm course diamond burs.
   c. Endoscopic monopolar and bipolar cautery, endoscopic clip appliers with an array of hemostatic clips, hemostatic agents, and an array of pledgets.
   d. Commercially available dural substitutes for grafting needs.
   e. Absorbable and nonabsorbable packing materials.
3. Image guidance
   a. Line-of-sight image guidance is often favored in open procedures or those using pin immobilization.
   b. Electromagnetic image guidance may also be used when pin immobilization is not used. The choice between line-of-sight and electromagnetic image guidance is that of the operating surgeon, because both modalities provide comparable information.

Key Anatomic Landmarks

1. Thorough knowledge of the anatomy of the scalp is required to successfully elevate the PCF. The pericranium is the calvarial periosteum extending about the cranial convexity in the midline with the lateral boundaries delineated by the superior-most aspect of the temporalis muscles and their overlying fascia. Immediately superficial to the pericranium lies loose areolar tissue followed by the galea. At the discretion of the reconstructive surgeon, both of these layers can be incorporated into the flap to provide a thicker flap depending upon the reconstructive needs.
2. The supraorbital and supratrochlear arteries provide axial vascular supply to the flap. A unipedicled or bipedicled PCF flap can be designed based on the plan for reconstruction. We favor an unipedicled design for endoscopic-assisted PCF, because this leaves the contralateral flap for a later date if necessary. The position of the vascular supply can be identified using a Doppler probe or the supraorbital notch can be palpated and a flap pedicle width of 3 cm (1.5 cm on either side of the notch) can be designed.
3. The nasion is the most depressed portion of the nose on profile view and is generally at the intersection of the frontal process of the nasal bones and nasal process of the frontal bones. A surgical window created at this site, termed a nasionectomy, affords intranasal access just anterior to the anterior aspect of the frontal sinus outflow tract.

Prerequisite Skills

Head and neck oncologic and skull base training. Endoscopic skull base training is highly recommended due to the specific requirements of this procedure.

Operative Risks

1. Neurovascular structures
   a. A detailed understanding of the anatomy of the scalp and skull base, including the relative locations of neurovascular structures, is critical in the harvest and inset of the PCF. The prime neurovascular structures at risk are the supraorbital and supratrochlear vessels and the supraorbital nerve. With a thorough understanding of the trajectory of these structures, they may be successfully avoided and the sensory and motor functions of the scalp can be preserved.
2. Coronal approach versus endoscopic-assisted
   a. Depending on the harvest technique employed by the surgeon (standard open coronal incision versus minimally invasive endoscopic-assisted approach), there are distinct operative risks due to the length and location of the incision, the need for a craniotomy, and the effect on the frontal sinus outflow tract. Historically, the standard approach for the harvest of a PCF involved a coronal incision.[7] However, operative risks in this approach are higher with increased morbidity and involvement of other neurovascular structures including the superficial temporal artery and frontal and temporal branches of the facial nerve.[7]

The standard open harvest of the PCF is largely reserved for combined or large open craniofacial resections. The minimally invasive endoscopic-assisted approach has become the primary approach that we employ at our institution in the harvest of the PCF, which will be discussed in detail later.[6,8]

Surgical Technique

1. Coronal approach
   a. A standard coronal incision is made beginning in the preauricular region and traversing to the contralateral preauricular region. Once the incision is made, the plane between the subgaleal fascia and overlying galea is identified and the coronal flap is elevated anteriorly in this plane. Given the lateral extensions of the incision, the frontal branches of the facial nerve are identified and are elevated with the galea.[7]
   b. Next, the PCF is elevated off of the calvarium and brought anteriorly toward the supraorbital rims, taking care not to disrupt the supraorbital or supratrochlear vessels. If needed for tumor extirpation, a bifrontal craniotomy with removal of segments of the supraorbital rim is performed that allows for easy rotation and inset of the PCF, after which supraorbital bone is replaced superiorly over the flap for complete reconstruction.[7]
2. Endoscopic-assisted approach
   a. Once the tumor extirpation or other pathology has been addressed, attention is turned to the reconstruction portion of the procedure. Depending on the level of dural involvement and dissection, some form of synthetic dural substitute is often used for initial dural repair and placed in an underlay fashion to cover the defect.
   b. The scalp incision is planned as an ipsilateral hemicoronal incision, which is placed in a trichophytic fashion at the hairline near the midline and continued to the temporal hair tuft in standard hemicoronal fashion. The true skin incision is generally only approximately 3 to 4 cm in length and is often limited to the most superior aspect of the hemicoronal incision, but may be lengthened in either direction as necessary for flap exposure. Prior to the incision, a Doppler ultrasound probe can be used to identify the supraorbital and supratrochlear vessels, at which point a 3-cm-wide flap pedicle is outlined with the pedicle marked in the midline at the supraorbital rim.
   c. Following the incision, the dissection is carried out posteriorly in the subgaleal plane and then carried anteriorly to the orbital rims (Fig. 166.1). Subgaleal dissection may be aided with the use of 0- and 45-degree rigid endoscopes, which provide high-definition and magnified images of the dissection. Once an adequate posterior length is achieved, often approximately 15 cm posterior from the brow, a horizontal incision is made down to the pericranium at the posterior aspect of the flap with the use of extended needle tip cautery under direct endoscopic visualization.[6,8] Next, bilateral vertical incisions are made at the edge of the flap and carried forward from posterior to anterior, tapering toward

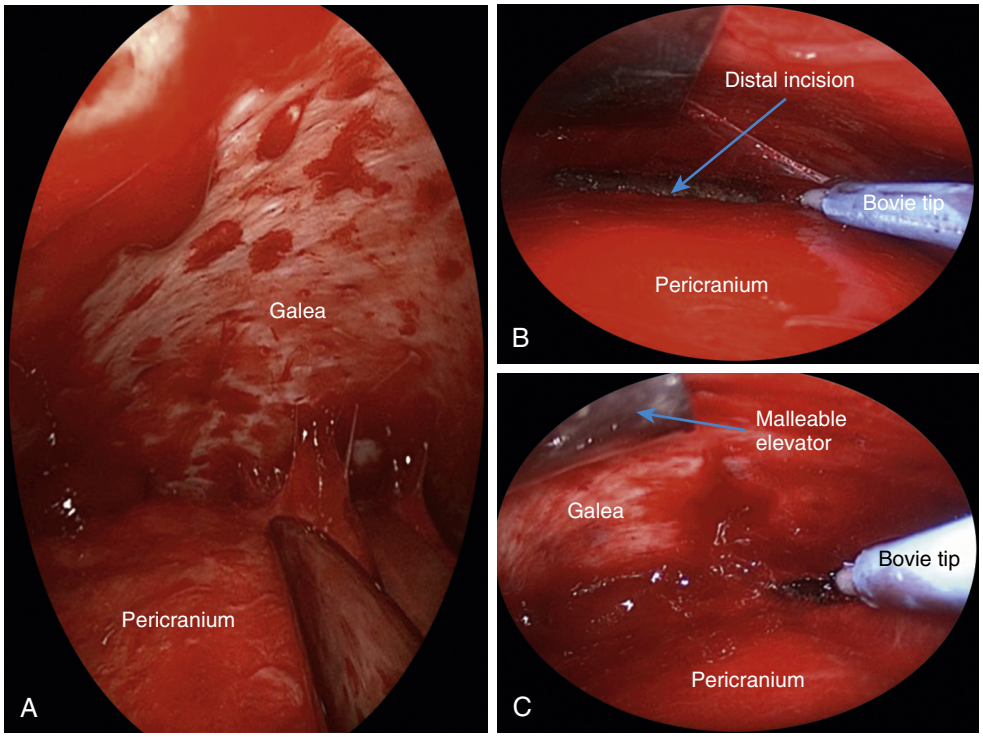

Fig. 166.1. A, Progressive elevation of the scalp within the subgaleal plane allowing for the isolation of the underlying pericranium. **B and C,** Following isolation of the pericranium, monopolar cautery is used to perform circumferential incisions about the pericranium with care taken to preserve a 3-cm-wide pedicle at the proximal aspect of the flap in the region of the superior orbital rim (arrow).

the pedicle and ensuring both adequate flap and pedicle width (see Fig. 166.1). The PCF is then meticulously elevated from the cranium and mobilized to the superior orbital rim under direct endoscopic visualization (Fig. 166.2).

d. Attention is then turned to the glabella, where an approximately 1-cm, horizontal skin incision is made in a natural skin crease and carried down to the periosteum at the level of the nasion. The subperiosteal plane at the level of the nasion is then dissected superiorly until it communicates with the subperiosteal plane of the PCF over the frontal bone.[8] Subsequently, a 3-mm coarse diamond burr is used to drill a 4 mm × 1.5 cm through-and-thorough bony defect, or ostectomy, at the level of the nasion (Fig. 166.3). Direct visualization of the ostectomy using the endoscope allows for safe drilling and minimizes potential injury to surrounding structures.

e. The PCF is then transposed in the subperiosteal plane into the region of the glabellar incision under endoscopic visualization to prevent torsion of the flap pedicle. Next, the PCF is passed and rotated through the nasionectomy and into the sinonasal cavity under direct visualization.[8]

f. In the sinonasal cavity, the PCF is extended to cover the skull base defect including the inlay graft, dural edges, and surrounding bony edges, where it acts as an extradural onlay.[8] During this interval, the flap is placed in a redundant position anteriorly to ensure that any potential space in this region is obliterated (Fig. 166.4). The edges of the flap are generally bolstered with a bioresorbable nasal dressing that assists in minimizing the formation of adhesions and provides mechanical compression. A layer of an absorbable hemostatic agent is then applied, followed by intranasal, expandable packing sponges, which help to support the reconstruction. Lastly, a 7-mm suction drain is placed under the scalp. The scalp and nasion incisions are then closed primarily in a multilayered fashion.

Common Errors in Technique

1. Flap length
   a. A common error in PCF reconstruction is underestimating the necessary length of the flap. According to Patel et al.,[5] who studied clinical outcomes and preoperative radiographic analysis in PCF reconstruction, preoperative analysis of CT scans can anticipate the necessary length of a PCF for an expected skull base defect. Additionally, it is important to be aware that some length will be lost with rotation and contracture of the flap. In an effort to overcome this, it was found that adding an additional 3 cm to the calculated length of the flap based on preoperative CT scans provided adequate length for closure.[5]
2. Flap inset
   a. Another critical element in the inset of the PCF is the location of the flap pedicle as it traverses the frontal sinus through the nasionectomy. Because there is potential risk for obstruction of the frontal sinus outflow tract, a large confluent frontal sinusotomy (Draf III) is performed and the flap is positioned to traverse this sinusotomy in the midline.[5] By doing so, the outflow tracts of the frontal sinus are maintained on each side of the pedicle, which minimizes the risk of mucocele formation.[5,9]
3. Sinonasal packing
   a. Flap failure secondary to its migration from the reconstruction site can sometimes be linked to inadequate sinonasal packing or removing the packing too early. It has been demonstrated that nasal packing left in place for 5 to 7 days postoperatively provides support for the repair and maximizes apposition of the flap to

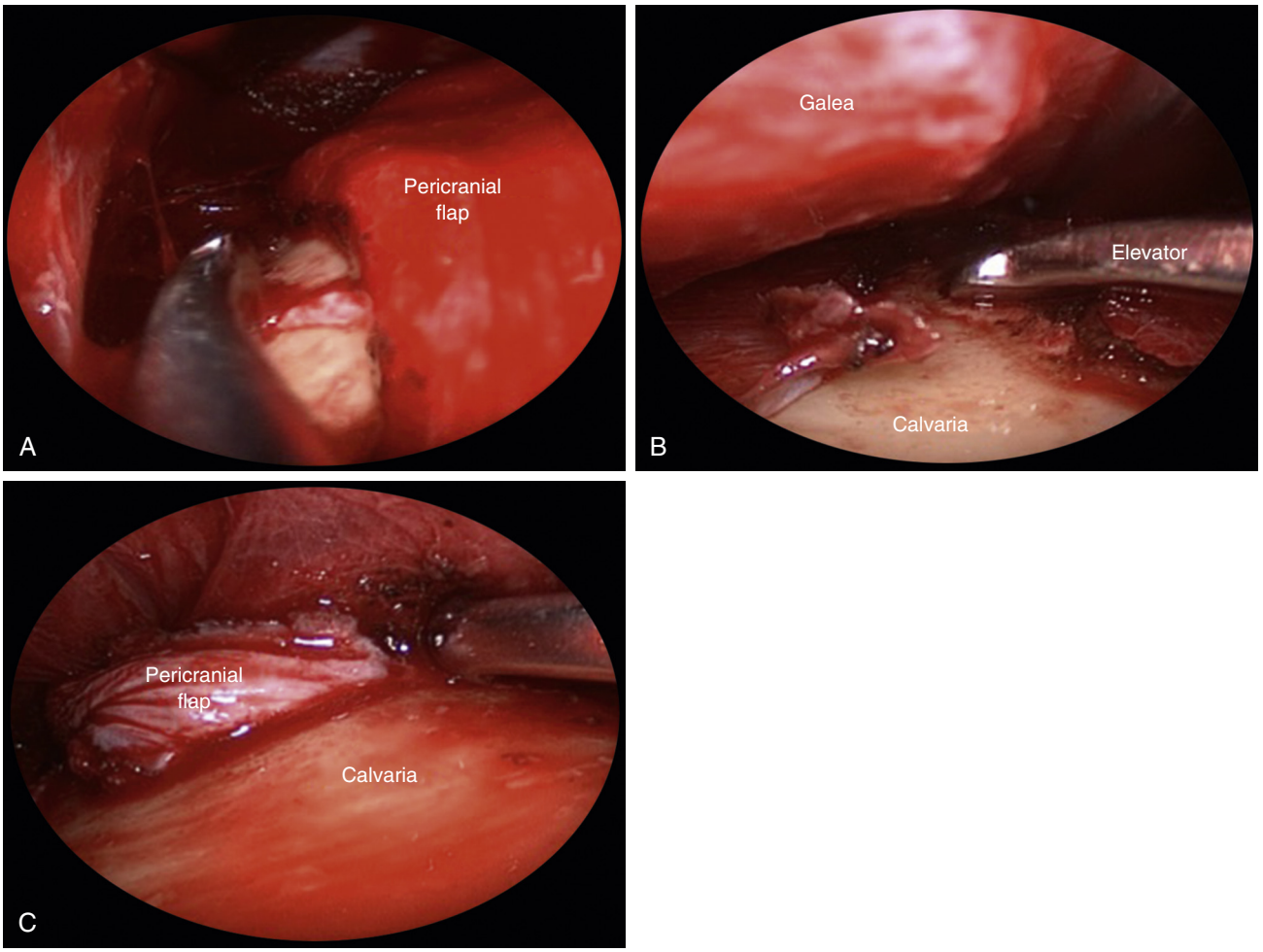

Fig. 166.2. A and B, Following circumferential incisions, a periosteal elevator is used to elevate the flap circumferentially. This is usually carried from the vertex/distal aspect of the flap toward the superior orbital rim. **C,** Care is taken to maintain the width of the pedicle while ensuring adequate elevation, thereby providing the appropriate degree of flexibility to allow the introduction of the flap into the nose.

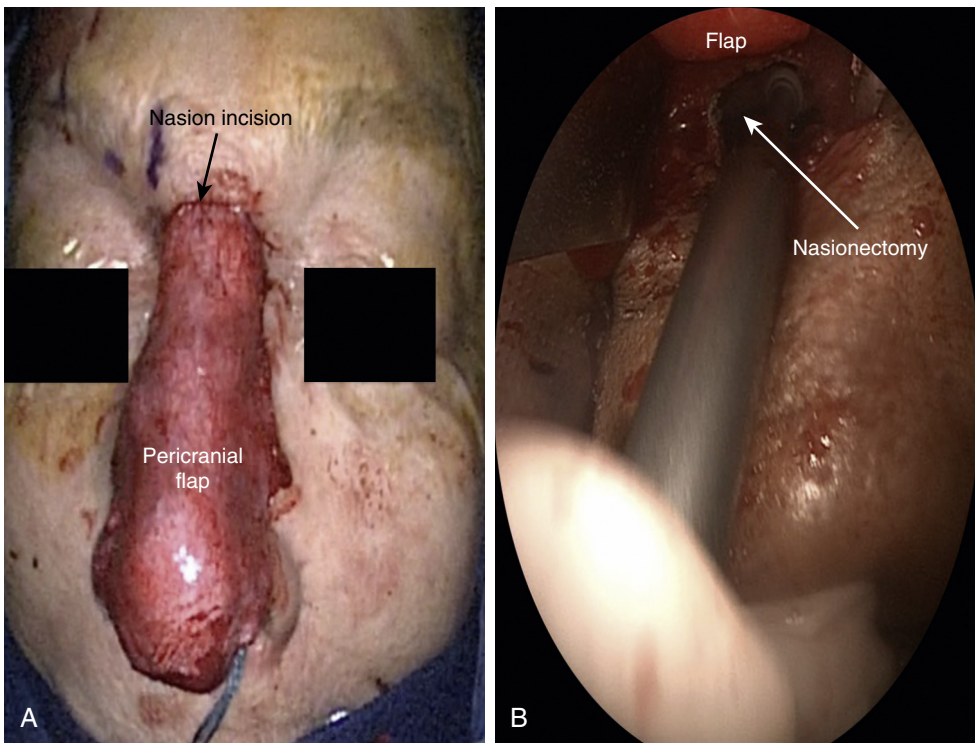

Fig. 166.3. A, After subperiosteal elevation, the flap is transposed through the incision in the nasion and temporarily reflected onto the nose. **B,** With the flap reflected inferiorly, a nasionectomy is performed with a high-speed drill via the nasion incision allowing access to the nasal cavity.

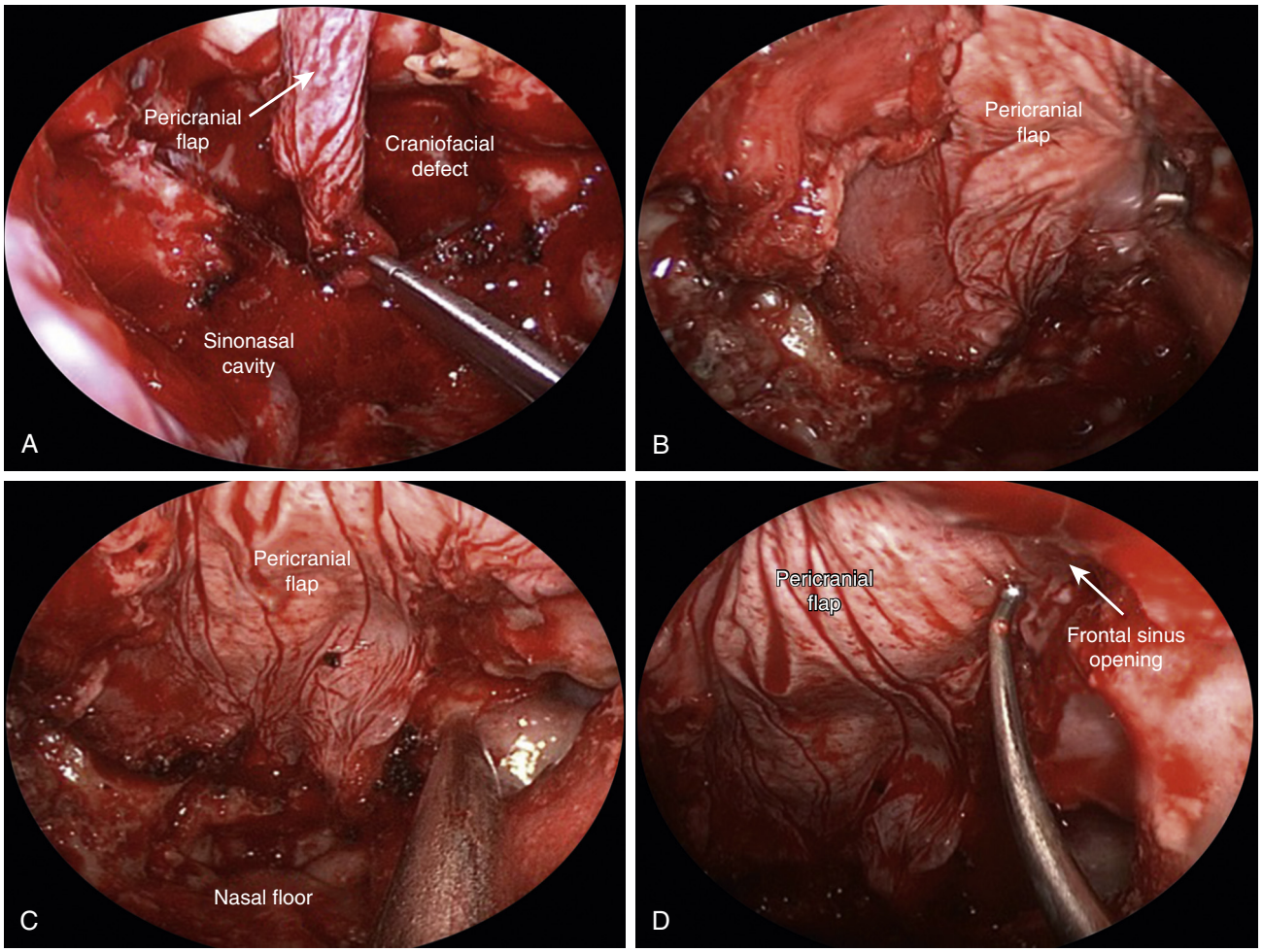

Fig. 166.4. A, Following nasionectomy, the flap is introduced through this bone window from an extranasal position to an intranasal position (arrow). **B and C,** The flap is then fully extended allowing complete coverage of the defect. **D,** Care is taken to ensure that the flap is placed into the confluent frontal sinus opening to ensure obliteration of any potential space in this region as the flap is spread across this portion of the skull base (arrow).

native nasal and skull base tissue.[1,5,8,9] With maximum apposition, rapid mucosalization of the tissue is facilitated in addition to minimizing the risk of a CSF leak postoperatively.

POSTOPERATIVE PERIOD

Postoperative Management

1. Given the intra- and extracranial components of the operative procedure, it is often recommended that patients undergoing PCF reconstruction be monitored in an intensive care unit (ICU), preferably a neurosurgical ICU.
2. In selected patients, including those with elevated intracranial pressure, morbid obesity, and/or those in whom significant dural defects with resulting high-flow CSF leaks are anticipated, consideration of preoperative placement of a lumbar drain is undertaken. It should be noted that the use of lumbar drains for CSF diversion is becoming less common and is often restricted to specific patient populations and/or surgical sites.
3. Nonabsorbable sinonasal packing is generally left in place for 5 to 7 days postoperatively, after which time it is removed. Absorbable packing material is usually left in position and allowed to be slowly washed away with postoperative sinonasal irrigations.
4. The patient is usually kept on antibiotics with coverage for staphylococcus while nonabsorbable packing material is in place. The antibiotics are often continued until the first postoperative outpatient visit.
5. In the postoperative period, the patient is kept on strict CSF leak precautions, which include: no nose blowing, no use of straws, no heavy straining, no use of continuous positive airway pressure (CPAP) machines, and keeping the head of the bed elevated at least 30 degrees.
6. Close postoperative follow-up is recommended for wound inspections, sinonasal debridement as indicated, and monitoring of the PCF via sinonasal endoscopy.
7. No smoking.

Complications

1. CSF leak

a. The predominant postoperative complication with the use of the PCF for skull base reconstruction is CSF leak. Importantly, the most common cause of CSF leak following vascularized skull base reconstruction repair is due to flap defect or displacement, and rarely flap death.[1,2,9] The diagnosis of a CSF leak after skull base repair should be

primarily clinical with the main signs being clear rhinorrhea, increasing headache, and possibly meningitis. Beta-2 transferrin is specific for CSF and can be tested for in the rhinorrhea fluid; however, we usually make the diagnosis of a postoperative CSF leak by clinical examinations. If a leak is suspected, a fine-cut head CT is obtained to evaluate for pneumocephalus and allows for revision surgical planning if needed. The management of a postoperative CSF leak depends on the quality of leakage. A low-flow CSF leak can be managed with conservative therapy with bed rest, stool softeners, and lumbar drainage. IV antibiotics with CSF penetration are continued if a leak is suspected. If the leak is a high-flow CSF leak, then revision surgery with bolstering of the defect with additional material (adipose tissue, dermal adipose tissue, acellular dermis, or collagen matrix) is needed. The bolstering can be done with an endoscopic endonasal approach from below or through revision craniotomy if necessary. Prevention of a CSF leak is mostly dependent on proper placement and bolstering of the vascular flap at the time of primary surgery.

2. Other major perioperative and postoperative complications
   a. Intracranial infection
   b. Pneumocephalus

Intracranial infection and pneumocephalus are additional complications that are concomitant with a CSF leak. These usually present in the early postoperative period (less than 3 weeks). Management is similar to CSF leak listed above. Pneumocephalus also requires 100% rebreather O_2 and elevation of the head of the bed, especially if any tension component is noted. At times, revision craniotomy is required for tension pneumocephalus or intracranial infections. Airway diversion with a tracheostomy may be required for persistent pneumocephalus in rare cases.

   c. Mucocele formation and prolonged skull base crusting

Both mucocele formation and prolonged crusting are due to disruption of the normal sinonasal mucosa. Radiation also has an impact on the risks of these complications. These are late complications usually occurring 6 months to 20 years after the primary surgery. The diagnosis of prolonged crusting is usually due to quality-of-life complaints from the patient and crusting noted on endoscopy. Treatment of crusting is through serial debridement, good nasal hygiene, and culture-directed antibiotics if an infection is noted. Mucoceles are usually incidentally found on serial imaging and are usually asymptomatic. Rarely, they can present with pain or infection. Treatment is usually endoscopic drainage.

   d. Donor site complications such as hematoma, superficial wound infections and scar hypertrophy are rare.

Alternative Management Plan

1. In situations that preclude the use of the PCF for reconstruction of skull base defects, other choices for vascularized skull base reconstruction include the NSF, tunneled temporoparietal fascial flap, palatal flap, and rarely, microvascular free flaps.[4,5]
2. Skull base defects may also be repaired with free-tissue grafts including mucoperichondrium, mucoperiosteum, and/or fascia. Noncellular grafting materials such as Alloderm may also be used for repair.[10]

DISCUSSION

Evidence-Based Medicine Question

Is the endoscopic-assisted PCF an option comparable to other vascularized flaps used in skull base reconstructions?

In the modern era of endoscopic endonasal skull base surgery, vascularized, reconstructive techniques have become a mainstay in the repair of large skull base defects.[2] Although the NSF remains the primary choice for vascularized skull base reconstruction, clinical and operative situations exist in which the viability of the NSF may be compromised or the defect may require a repair with a larger vascularized flap. Should the need arise, the endoscopic-assisted PCF serves as an excellent option in the repair of skull base defects.[2,5,8]

The PCF is very useful in reconstructing defects extending from the anterior skull base to the sella turcica. Minimal donor site morbidity considering the inherent size variability, lengthy flap pedicle, and reliable vascular supply provided multiple advantages to the reconstructive surgeon. Clinical outcomes in which the PCF was used for reconstruction of the skull base have revealed comparable outcomes to other types of vascularized skull base reconstruction.[9] In summary, the endoscopic-assisted PCF is a versatile option for the repair of a wide range of skull base defects.

Editorial Comment

Although the PCF is the most frequently used flap in the reconstruction of skull base defects, it is also used to reconstruct local defects in the head and face including the scalp and nose/nasal lining. It can be designed as a unilateral, bilateral, laterally based, or anteriorly based flap. It is easy to harvest, safe, and cost-effective.

Anna M. Pou

Access the review questions online at http://www.expertconsult.com



REFERENCES

1. Thorp BD, Sreenath SB, Ebert CS, et al. Endoscopic skull base reconstruction: a review and clinical case series of 152 vascularized flaps used for surgical skull base defects in the setting of intraoperative cerebrospinal fluid leak. Neurosurgical Focus 2014;37(4):E4.
2. Harvey RJ, Parmar P, Sacks R, et al. Endoscopic skull base reconstruction of large dural defects: a systematic review of published evidence. Laryngoscope 2012;122(2):452–459.
3. Soudry E, Turner JH, Nayak JV, et al. Endoscopic reconstruction of surgically created skull base defects: a systematic review. Otolaryngol Head Neck Surg 2014;150(5):730–738.
4. Patel MR, Stadler ME, Snyderman CH, et al. How to choose? Endoscopic skull base reconstructive options and limitations. Skull Base 2010;20(6):397–404.
5. Patel MR, Shah RN, Snyderman CH, et al. Pericranial flap for endoscopic anterior skull-base reconstruction: clinical outcomes and radioanatomic analysis of preoperative planning. Neurosurgery 2010;66(3):506–512. discussion 512.
6. Klatt-Cromwell CN, Thorp BD, Del Signore AG, et al. Reconstruction of skull base defects. Otolaryngol Clin North Am 2016;49(1):107–117.
7. Snyderman CH, Janecka IP, Sekhar LN, et al. Anterior cranial base reconstruction: role of galeal and pericranial flaps. Laryngoscope 1990;100(6):607–614.
8. Zanation AM, Snyderman CH, Carrau RL, et al. Minimally invasive endoscopic pericranial flap: a new method for endonasal skull base reconstruction. Laryngoscope 2009;119(1):13–18.
9. Patel MR, Taylor RJ, Hackman TG, et al. Beyond the nasoseptal flap: outcomes and pearls with secondary flaps in endoscopic endonasal skull base reconstruction. Laryngoscope 2014;124(4):846–852.
10. Hegazy HM, Carrau RL, Snyderman CH, et al. Transnasal endoscopic repair of cerebrospinal fluid rhinorrhea: a meta-analysis. Laryngoscope 2000;110(7):1166–1172.

REVIEW QUESTIONS

1. What is the vascular supply for the pericranial flap?
   a. Superficial temporal artery
   b. Supraorbital artery
   c. Supratrochlear artery
   d. b and c

2. What is the average length of the pericranial flap needed for repair of a sellar defect?
   a. 10 cm
   b. 12 cm
   c. 15 cm
   d. 20 cm

3. What is the average width of the pericranial flap pedicle?
   a. 2 cm
   b. 2.5 cm
   c. 3 cm
   d. 3.5 cm

167 Temporoparietal Fascial Flap

Peter D. Costantino, Margherita Bruni, Amir R. Dehdashti

INTRODUCTION

In general, the temporoparietal fascia is a poorly recognized, but highly useful, layer of tissue that invests the lateral scalp overlying and extending beyond the surface area of the underlying temporalis muscle. Skill in recognizing and elevating the temporoparietal fascia is important in both skull base exposures such as the infratemporal fossa approach and in reconstructive procedures that use the temporoparietal fascia as a pedicled flap based upon the superficial temporal artery and vein. Its successful preservation helps to ensure the continuity of the frontal branches of the facial nerve, and its elevation as a pedicled flap is valuable in the reconstruction of a wide array of defects. With a rich vascular supply, large area, thinness, pliability, and mobility, it allows for reconstruction of soft tissue, orbital, anterior or middle cranial fossa, nasopharyngeal, oropharyngeal, oral, maxillary, and palatal defects with ease.[1] The ability to accept a skin graft makes it an excellent choice for facial, auricular, scalp, or orbital defects.[2] In the oral cavity or pharynx, rapid mucosalization of the graft eliminates the need for further grafting over it. As a hardy graft it has utility in buttressing cranial defects with cerebrospinal fluid (CSF) leaks, permitting watertight exclusion of the intracranial contents from the upper aerodigestive tract. Bilateral flaps that remain connected across the sagittal suture may be harvested to reconstruct larger midline defects, that is, a "visor" flap. We have found temporoparietal fascial (TPF) flaps to be particularly useful in the management of palate defects, obviating the need for an obturator or free flap reconstruction in some cases. In pituitary or extended pituitary approaches, a flap can be tunneled through the maxillary sinus into the sphenoid sinus and draped along the dural defect. This permits vascularized closure in situations where a nasoseptal flap is unavailable or inadequate for closure.[3]

KEY OPERATIVE LEARNING POINTS

- The TPF flap is a robust vascularized tissue flap with myriad utility used in cranial base, facial, oral and pharyngeal reconstruction.
- The pedicle must be meticulously protected during the tedious dissection.

PREOPERATIVE PERIOD

History

- A thorough history is important to identify inappropriate candidates for this flap. Examples include patients who have had embolization or ligation of the external carotid artery and those in which previous surgery or trauma has transected the flap or its vascular supply.
- Previous parotidectomy is not necessarily a contraindication unless the superficial temporal vessels were sacrificed.

Physical Examination

- Thorough examination of the head and neck should be completed to gauge the extent of the tumor and anticipate the size of the defect.
- Examine the neck and scalp for evidence of previous surgery that could have compromised blood supply to the flap.
- The superficial temporal artery is generally 2 mm at the pretragal region and can be identified by Doppler to confirm adequate blood supply prior to deciding upon its use.

Imaging

- Careful preoperative review of computed tomography (CT) and magnetic resonance (MR) imaging is necessary to ensure that vasculature to the flap will not be compromised during the resection of the tumor.

Indications

- The TPF flap's area, thinness, pliability, and mobility make it a good choice for reconstruction of soft tissue, orbital, anterior or middle cranial fossa, nasopharyngeal, oropharyngeal, oral, maxillary, and palatal defects.

Contraindications

- The flap cannot be used if there has been previous disruption to its blood supply or when anticipated resection would disrupt the blood supply.
- Previous radiation therapy is a relative contraindication as it may result in poor wound healing and increased risk of flap necrosis.

Preoperative Preparation

- Patients should be counseled that there is a hemi-coronal incision with increased risk of alopecia along the donor area.
- A particular advantage to this flap is that there is no significant donor site defect since the flap is so thin.

OPERATIVE PERIOD

Anesthesia

- General

Positioning

- Supine
- Turn the bed 180 degrees.

Perioperative Antibiotic Prophylaxis

- First-generation cephalosporin
- If penicillin (PCN) allergic, give clindamycin

Monitoring

- No nerve monitoring is necessary.

Instruments and Equipment to Have Available

- Basic head and neck surgery set

- Double-hook retractors
- Bipolar cautery
- Hemostatic slurries or Gelfoam

Key Anatomic Landmarks

- Moving from superficial to deep, the layers of the scalp consist of skin, subcutaneous adipose tissue, the superficial temporoparietal fascia, loose areolar tissue, the temporalis fascia of the temporalis muscle, temporalis muscle itself, the pericranium, and then the calvarium.
- The temporoparietal fascia consists of a 2- to 4-mm thick layer of connective tissue that is continuous with the galea aponeurotica superiorly and the superficial musculoaponeurotic system (SMAS) inferiorly. Between the temporoparietal fascia and the deep temporalis fascia is a loose areolar tissue layer that permits the scalp to glide over the fixed temporalis fascia of the temporalis muscle. This avascular areolar layer facilitates dissection between these two fascial layers, that is, the temporoparietal fascia superficially and the more deeply located temporalis muscle fascia.
- The temporoparietal fascia is supplied by the superficial temporal artery, a terminal branch of the external carotid artery. The superficial temporal artery originates from the external carotid system and becomes superficial immediately behind the posterior limit of the parotid gland at the level of the tragus. It proceeds cephalad along this course, over the root of the zygoma, and into the tissues of the scalp within the temporoparietal fascia.
- The vessels typically divide into frontal and parietal branches approximately 3 cm above the zygomatic arch, with the frontal vessels arborizing with branches of the vessels that feed the frontal pericranium; that is, the temporoparietal fascia is contiguous with the same pericranium that is employed to create a pericranial flap. Hence, the temporoparietal blood supply anastomoses with the supraorbital and supratrochlear vessels in a rich axial pattern. Concurrently, the superficial temporal vessels also anastomose with the occipital vascular system posteriorly. The system is drained by typically paired veins that run superficial to the artery.
- From a surgical standpoint, it is important to recognize that the frontotemporal branches of the facial nerve run within the superficial temporalis fascia. Their course can be approximated by using the line of Pitanguy, described as a line drawn from 0.5 cm inferior to the tragus to a point 1.5 cm lateral to the brow. The branches control forehead mobility on that side; injury to these nerves results in inability to raise the ipsilateral brow or blepharoptosis.[4]

Prerequisite Skills

- Knowledge of head and neck anatomy, particularly the scalp
- Proficient in soft tissue techniques
- Head and neck or reconstructive fellowship

Operative Risks

- Injury to the vascular pedicle during harvest
- Flap necrosis if the pedicle is kinked during rotation
- Injury to the frontal branch of the facial nerve
- Secondary alopecia

Surgical Technique

- An incision is designed within the preauricular crease extending superiorly to create a hemi-coronal incision. The hair is not shaved but rather parted and braided with rubber bands to expose the incision site.
- A #15 blade is used to make the scalp incision at the midpoint of the temporal fossa, and this is carried down through the dermis and subcutaneous adipose tissue of the scalp, but not any deeper. The temporoparietal fascia is located immediately below the subcutaneous adipose tissue of the scalp, as are the superficial temporal vessels. Carrying the incision deeper than the subcutaneous scalp adipose tissue runs the risk of damaging the temporoparietal fascia and, more importantly, the superficial temporal vessels, thereby rendering the flap useless.
- Care must be taken in identifying the temporoparietal fascia as it can be densely adherent to the subcutaneous tissues of the scalp. In this regard, dissection of the superficial surface of the temporoparietal fascia is facilitated by staying immediately deep to the hair follicles while applying traction to the hair-bearing scalp with a double-hook retractor.
- Sharp dissection with tenotomy scissors is carried both anteriorly and posteriorly allowing a large flap to be exposed as defined by the reconstructive requirements of the defect.
- The superficial temporal system also supplies a rich subdermal plexus to the overlying scalp. As the hair-bearing scalp and subcutaneous adipose tissue are lifted off of the superficial surface of the temporoparietal tissues, these feeding vessels are transected, and bleeding should be controlled with bipolar cautery. Monopolar cautery can damage the underlying superficial temporal vessels or the flap itself and can contribute to postoperative alopecia of the overlying scalp.
- This dissection can be tedious but should be carried out meticulously so as to not disrupt the superficial temporal vessels. These vessels often can be seen within the superficial temporal fascia and should be protected.
- Limiting the dissection anteriorly at the temporal hairline protects the branches of the facial nerve; however, if the nerve is identified and carefully protected, further dissection can proceed. The flap can be extended to include galea superiorly and posteriorly if necessary (Fig. 167.1).
- Once the scalp flap has been elevated adequately, the superficial temporalis fascia is sharply incised and then dissected from the underlying deep temporal fascia. Between these is a layer of loose areolar fascia that is avascular and makes for an easy sharp or even blunt dissection. As the fascia is elevated inferiorly, care is taken to not disrupt the superficial temporal vessels, which should be kept under direct vision to reduce the possibility of injury.
- The flap is then rotated into position. Usually removing the zygomatic arch is not necessary with this thin flap, but it may increase length and decrease vascular congestion of the flap. Due to its rich blood supply the flap readily accepts a skin graft.
- When the flap is intended for repair of the anterior or middle cranial fossa, it is typically tunneled over the zygoma and through the maxillary sinus, which is opened to permit access. The flap then emerges through a large maxillary antrostomy into the nasal cavity and can be draped into position (Figs. 167.2 and 167.3).
- When used for palate repair, the flap is similarly tunneled through the maxillary sinus, then inferiorly to the palate defect. It is tacked into position transorally with absorbable sutures and allowed to mucosalize as it heals.

Common Errors in Technique

- Failure to identify the correct plane of dissection
- Disrupting the blood flow to the flap during dissection
- Not taking care to meticulously avoid hair follicles during dissection, which increases risk of alopecia

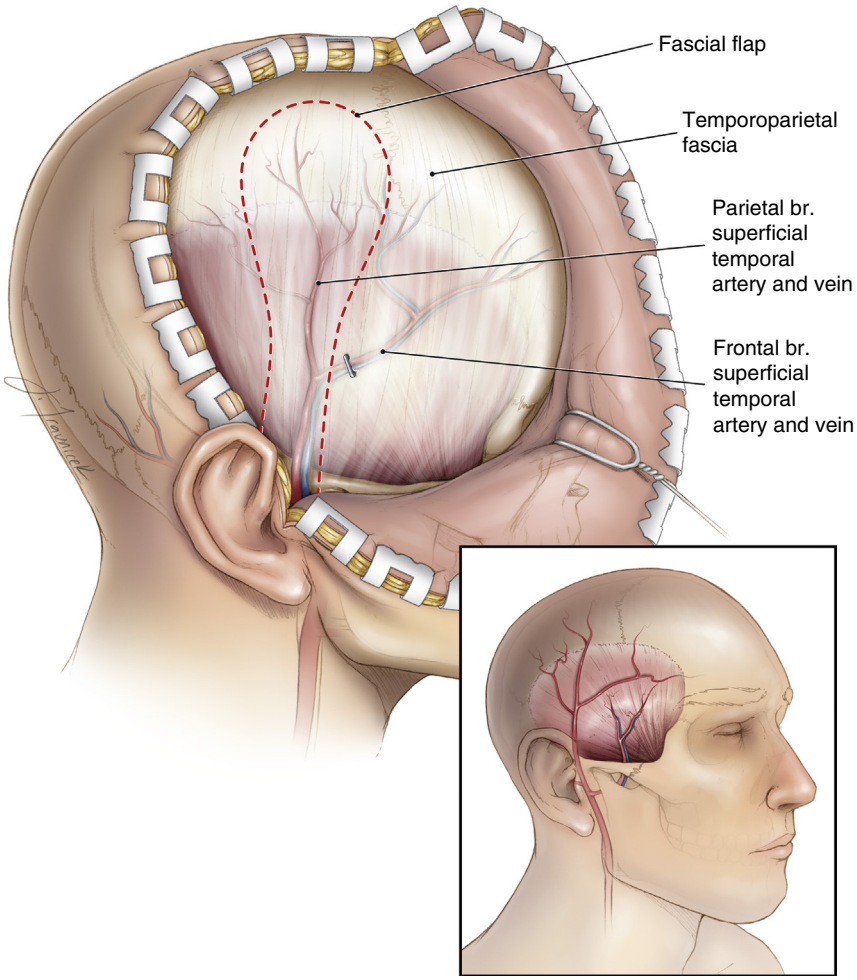

Fig. 167.1. The temporalis fascia is exposed, and the planned fascial flap with associated parietal branch of the superficial temporal artery is outlined with the dotted line. Note the frontal branches of the superficial temporal artery and vein have been clipped.

POSTOPERATIVE PERIOD

Postoperative Management

- Intraoperative steroids should be given and continued as a taper for several days after to prevent edema and venous congestion of the flap.
- Harvesting of a large TPF flap can compromise the scalp and lead to breakdown of the incision; therefore pressure dressings should not be placed postoperatively.
- A suction drain can be placed and removed when output is minimal.
- Routine postoperative antibiotics are used.

Complications

- The scalp receives its blood supply from the superficial temporal system, and necrosis of the flap or breakdown of the incision can be an issue, especially when harvesting large flaps. To reduce this risk, local anesthetic with vasoconstrictive agents is not injected, Raney hemostatic clips are not used, and pressure dressings are avoided.
- Alopecia can develop, although these areas can be excised in the future if desired.
- Donor site morbidity increases in the setting of previous radiation, and these patients should be counseled regarding these risks preoperatively.
- Injury to the frontal branches of the facial nerve is a potential risk, which can be avoided by not taking the flap anterior to the temporal hairline.
- Necrosis of the flap is a risk, in the event the pedicle is compromised during dissection or kinked during rotation. Because of the thin nature of this flap, there is no donor defect on the side of harvest.
- Alternatives to this flap include a pericranial flap or free tissue transfer.

DISCUSSION

Evidence-Based Question

In a literature review detailing major TPF flap uses as a tool in head and neck reconstruction, what were the distinct application categories that were defined?[1]

Answer: The TPF flap was found to be versatile and demonstrated utility in orbital reconstruction, auricular reconstruction, combined skin/tissue transfer, facial reconstruction, skin and mucosal defect repair, pharyngeal reconstruction after

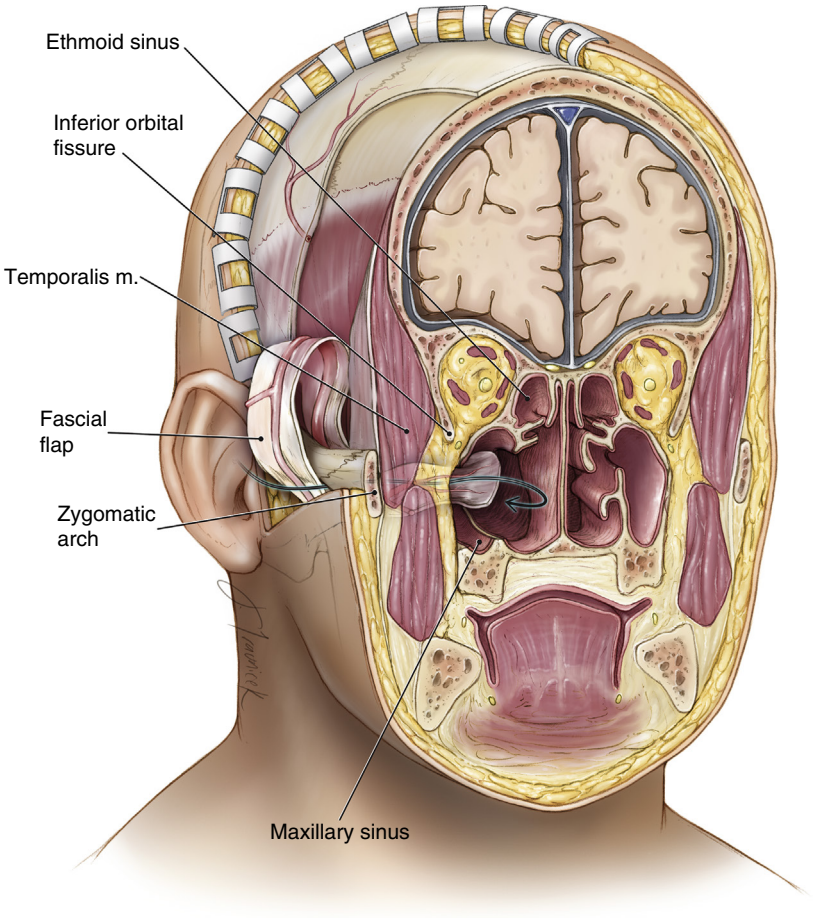

Fig. 167.2. The flap has been raised and is then tunneled anterior to the zygomatic arch and through the maxillary sinus in order to reach the sphenoidotomy.

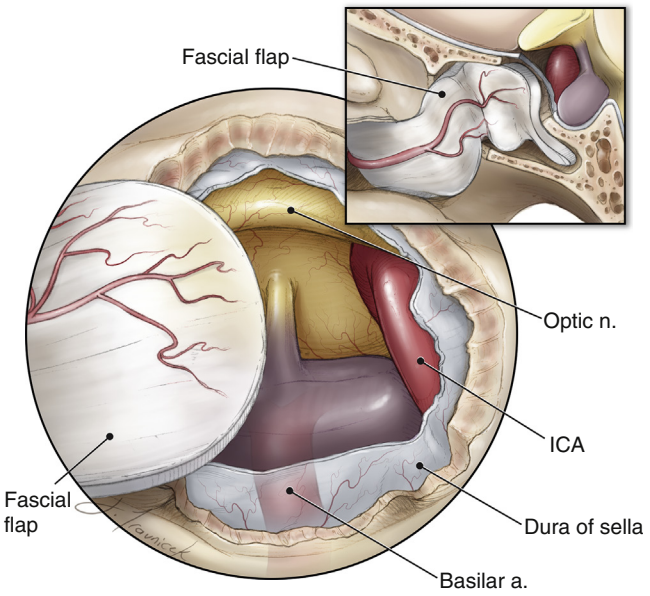

Fig. 167.3. The flap is brought into the sphenoid and used to repair the dural defect of the sella. *ICA*, Internal carotid artery.

salvage laryngectomy, and skull base reconstruction including CSF repair.

Editorial Comment

The TPF flap is a very versatile flap. It can be harvested as a pedicled flap, free flap, or composite flap with hair-bearing skin or parietal bone. Care must be taken during resection of the cancer in this area so as not to injure the superficial temporal vessels for immediate or future use.

Anna Pou

Access the review questions online at http://www.expertconsult.com

REFERENCES

1. Collar RM, Zopf D, Brown D, Fung K, Kim J. The versatility of the temporo-parietal fascia flap in head and neck reconstruction. J Plast Reconstr Aesthet Surg 2012;65(2):141–148.
2. Lai A, Cheney ML. Temporo-parietal fascial flap in orbital reconstruction. Arch Facial Plast Surg 2000;2(3):196–201.
3. Urken MI, Cheney ML. Temporo-parietal fascia. In: Urken MI, Cheney ML, editors. Atlas of Regional and Free Flaps for Head and Neck Reconstruction. Philadelphia, PA: Lippincott Williams & Wilkins; 2012. p. 219–231.
4. David SK, Cheney ML. An anatomic study of the temporo-parietal fascia flap. Arch Otolaryngol Head Neck Surg 1995;121:1153–1156.

REVIEW QUESTIONS

1. The frontal branches of the facial nerve run within which tissue layer?
   a. Subcutaneous adipose tissue
   b. Deep temporal fascia
   c. Superficial temporal fascia
   d. Within the temporal adipose tissue pad

2. The temporoparietal fascia flap can be used to reconstruct all of the following defects, except
   a. Orbital
   b. Palatal
   c. Middle cranial fossa
   d. Hypopharyngeal

3. All of the following are potential complications of a temporoparietal fascia flap, except
   a. Temporal hollowing
   b. Inability to raise forehead on ipsilateral side
   c. Alopecia
   d. Flap necrosis

168 Temporalis Muscle Transposition

Peter D. Costantino, Margherita Bruni, Amir R. Dehdashti

INTRODUCTION

The pedicled temporalis muscle flap is a very versatile, local, axial flap with many uses in craniofacial reconstruction (e.g., orbital cavity augmentation following exenteration, coverage of a temporal/subtemporal calvarial defect, maxillectomy augmentation, hemipalatectomy reconstruction, and mastoid/temporal defect reconstruction). As a moderately bulky flap with a good range of rotation, it allows for the reliable reconstruction of a variety of sites. In particular, it is the only local flap adequate in bulk and surface area for reconstruction following maxillectomy or unilateral palatomaxillectomy. It can be used to reconstruct the cranial base or to cover mesh or plates used to repair at the cranial base, temporal bone, or orbital rim. The flap has a sufficiently robust blood supply that it can be split into anterior and posterior paddles by bisecting the muscle along its fibers from its origin to the level of the zygomatic insertion. In this way, the muscle can actually be used as two separate flaps, connected to a common blood supply from the deep temporal artery. Bilateral flaps can be harvested to permit larger reconstructions that cross the midline.

KEY OPERATIVE LEARNING POINTS

- Vascularized flaps are the reconstruction modality of choice. Compared with free flaps, pedicled local flaps require less time, involve less morbidity of the donor site, and do not require microvascular expertise.
- Preoperative embolization or intraoperative oncologic resection can disrupt the blood supply to this flap and render it nonviable.
- Injury to the frontotemporal branch of the facial nerve is avoided by careful dissection at the level of the adipose tissue pad, taking care to leave the superficial layer of the deep temporalis fascia up with the skin flap.
- A superficial temporalis fascia flap may be raised along with the muscle for extended defects; if this is done, care should be taken to preserve the separate blood supply to the temporoparietal fascial flap.

PREOPERATIVE PERIOD

History

- Proper patient selection is imperative in deciding to use this flap. Although it is robust and applicable to many regional defects, this flap should not be used in cases where its internal maxillary or deep temporal blood supply has been compromised.
- A thorough history will often reveal patients who may not be appropriate candidates for the use of this flap. Examples include patients who have had embolization of the ipsilateral internal maxillary artery, those who have had extensive dissection along the medial surface of the muscle, cases where excision of the muscle was required, or those where the external carotid artery had to be sacrificed.

Physical Examination

- Thorough examination of the head and neck to gauge extent of tumor and size of anticipated defect
- Examine the neck and scalp for evidence of previous surgery that could compromise the blood supply to the flap.
- Examine the temporal region to evaluate the bulk of temporalis muscle.

Imaging

- Careful preoperative review of computed tomography (CT) and magnetic resonance imaging (MRI) is necessary to make sure that the vasculature to the flap will not be compromised during tumor resection.
- Special care must be taken with patients who have malignancies of the maxillary sinus, where the tumor may have penetrated the posterior confines of the maxillary sinus cavity. Tumor contamination of the infratemporal fossa in such cases can result in compromise of the deep temporal artery, precluding the use of this muscle as the reconstructive flap. This situation must be recognized preoperatively, as there are no local "backup" flaps for palatomaxillary repair when the deep temporal is resected and the temporal artery is not usable; that is, a free tissue transfer is the only other reconstructive option in such situations.

Indications

- For craniofacial reconstruction—that is, augmentation of the orbital cavity following exenteration, coverage of a temporal/subtemporal calvarial defect, maxillectomy augmentation, hemipalatectomy reconstruction, and reconstruction of a mastoid/temporal defect
- Secondary to its bulk and surface areas, this flap has particular utility for reconstruction following maxillectomy or unilateral palatomaxillectomy.
- It may be used to reconstruct the cranial base or to cover mesh or plates used for repair at the cranial base, temporal bone, or orbital rim.

Contraindications

- The temporalis muscle flap cannot be used if there has been previous disruption of its blood supply (e.g., preoperative embolization) or when anticipated resection would disrupt the blood supply.
- It should not be used if the patient is unwilling to accept a temporary cosmetic deformity due to repositioning of the muscle and subsequent temporal hollowing (patients are counseled that this defect can be repaired at a later stage).

Preoperative Preparation

- Patients should be counseled that the harvesting of this flap will result in a potentially significant concave deformity over the temporal fossa. This deformity can be augmented

in a secondary procedure whereby adipose tissue, hydroxyapatite cement, or silicone/polymeric implants are used to fill this potentially substantial deformity. Following augmentation, the aesthetic results are usually excellent.

OPERATIVE PERIOD

Anesthesia

- General

Positioning

- Supine

Perioperative Antibiotic Prophylaxis

- First-generation cephalosporin
- If the patient is allergic to penicillin, clindamycin can be used.

Monitoring

- No neurologic monitoring is necessary.

Instruments and Equipment to Have Available

1. Basic head and neck surgery set
2. Bipolar cautery for control of bleeding
3. Raney hemostatic clips for control of scalp bleeding
4. Hemostatic slurries or Gelfoam for control of venous oozing
5. Sagittal saw and midface plating set

Key Anatomic Landmarks

- The temporalis muscle is a fan-shaped structure lying within the temporal fossa of the skull; it originates from the lateral surface of the calvarium anterior to the coronal suture and inserts onto the coronoid process of the mandible. During its course from origin to insertion it passes underneath the zygomatic process, becoming infratemporal where it meets the mandible. The temporalis muscle is 12 to 16 cm long; its thickness varies from 0.5 to 1 cm. It becomes functionally much thicker following elevation (~2.0 cm), and the muscle pedicle can tolerate up to a 130-degree arc of rotation, which can be expanded to 180 degrees if the zygoma is resected or temporarily transposed.[1,2]
- The superficial surface of the muscle is covered with a smooth, shiny layer of temporalis fascia, which should not be confused with the temporoparietal fascia. The latter is superficial to the temporalis fascia and represents an entirely separate tissue layer. The temporalis fascia is part of the muscle itself and derives its blood supply from the muscle tissue, whereas the temporoparietal fascia envelops the superficial temporal vascular system and is continuous with the galea aponeurotica superiorly and the superficial musculoaponeurotic system (SMAS) inferiorly. Within the temporoparietal fascia are the frontotemporal branches of the facial nerve as well as the superficial temporal vessels. In contrast, there are no nerves or named vessels within the temporalis fascia.[1,2]
- As one proceeds anteroinferiorly from the origin of the muscle on the side of the skull toward the zygoma, the temporalis fascia splits into superficial and deep layers to envelop the temporal adipose tissue pad. Again, these superficial and deep layers of the temporalis fascia should not be confused with the superficial temporoparietal fascia, which is separate and distinct from the temporalis fascia in all of its layers. The superficial and deep layers of the temporalis fascia come back together below the temporal adipose tissue pad and commonly insert onto the deep surface of the zygomatic arch along its superior border.
- The blood supply to the temporalis muscle is from the anterior and posterior branches of the deep temporal artery, which arises from the second portion of the internal maxillary artery. These vessels enter the muscle at its deep (medial) surface superior to the coronoid process within the infratemporal fossa. There is also an accessory blood supply from the middle temporal artery arising from the superficial temporal artery. It is critical from a surgical standpoint to realize that only the deep temporal artery provides a sufficient blood supply to maintain muscle viability. The middle temporal artery alone is inadequate to maintain the muscle as a reconstructive flap.
- Last, the motor supply to the temporalis muscle is from the temporal branches of the mandibular nerve, a division of the trigeminal nerve. It enters the muscle along its anteromedial surface deep in the infratemporal fossa.

Prerequisite Skills

- Understanding of the complex anatomy of this region
- Standard dissection techniques and familiarity with bone work (osteotomies and replating at the conclusion of a procedure)

Operative Risks

1. Injury to the vascular pedicle
2. Flap necrosis/dehiscence
3. Injury to frontal branch of the facial nerve

Surgical Technique

- A hemicoronal incision is made down to the layer of the temporalis fascia. This fascia is thick and glistening white, distinguishing it from the wispier appearance of the superficial temporoparietal fascia. Between the superficial temporoparietal fascia and the temporalis fascia is a layer of very loose areolar tissue, creating a natural plane that facilitates separation of the two fascial layers with blunt dissection (e.g., using a periosteal elevator). If these layers do not separate easily, most likely the correct interfascial plane has not been identified and the dissection is either too superficial or unnecessarily deep to the desired plane of dissection. It is within this plane that the anterior scalp flap is elevated off the temporalis fascia to the level of the temporal adipose tissue pad.
- When the first signs of this yellow adipose tissue pad are identified as the scalp flap is elevated from posterior to anterior, the dissection plane must change to lift the adipose tissue pad with the scalp to protect the frontal branches of the facial nerve reliably. Hence the temporal adipose tissue pad is elevated with the scalp flap. This maneuver also serves to minimize temporal hollowing, which can result from damage to the adipose tissue pad.
- When the posterosuperior limit of the adipose tissue pad is identified, the temporalis fascia is incised with electrocautery. The adipose tissue pad is then lifted with its overlying superficial temporal fascia as well as the superficial temporoparietal fascia (the layer containing the frontal branches of the facial nerve). The adipose tissue pad is lifted off the deep temporal fascia down to the level of the zygoma. At this point the fascial layers converge and insert onto the zygomatic periosteum. This confluence of fascia and periosteum can then be lifted off the zygomatic arch bone with a periosteal elevator.

- A subzygomatic dissection is then performed, fully freeing the temporalis muscle fibers from the deep surface of the zygoma. The muscle is dissected to its insertion at the coronoid process. At this point the muscle is elevated from the temporal fossa using cautery, staying close to the bone as the muscle is elevated. Venous bleeding can be encountered as the muscle becomes infratemporal near the insertion of the deep temporal artery into the muscle itself. This venous bleeding is best controlled by hemostatic slurries or Gelfoam, as aggressive electrocautery can potentially compromise the blood supply to the muscle.
- With most skull base defects, zygomatic osteotomies are required to achieve the arc of rotation required for reconstruction. With a thin muscle and particularly for isolated orbital exenteration defects, a zygomatic osteotomy may not be needed. In contrast, all maxillary, palatal, and temporal bone defects are best served by including a zygomatic osteotomy. For maxillary and palatal defects, the zygoma is plated back into anatomic position after muscle transposition. In contrast, an osteotomy of the zygomatic root is usually required for tension-free reconstruction of the temporal bone defect. Additionally, the transfer of bulky temporalis muscles should routinely include osteotomies of the zygomatic arch and even the coronoid to maximize flap rotation and minimize the risk of strangulation of the blood supply.
- From a technical standpoint, zygomatic arch transposition is best achieved following temporalis flap elevation by freeing the masseter attachment to the zygoma inferiorly, thereby skeletonizing the zygoma with electrocautery. This is followed by osteotomy using a reciprocating saw. Holes can be predrilled in the zygoma; then anterior and posterior osteotomies are performed. The transposed bone is kept in moist saline gauze until it is replaced at the conclusion of the flap inset.
- The coronoid process is addressed with careful dissection of the muscle attachments, taking care not to disrupt the blood supply to the muscle. It can be removed by performing an osteotomy or by fracturing it off with a rongeur. Removal of the coronoid allows for increased length and mobility in positioning the flap.
- The flap is then inset and sewn into place with absorbable sutures. Any muscle exposed in the oral cavity is left bare (ungrafted), as it will reliably mucosalize within several weeks. Note that although initially bulky, the muscle flap will atrophy, fibrose, and thin with time.
- If removed, the zygomatic arch is then replaced with screws or plates. A suction drain is placed in the temporal fossa and the scalp is closed in the usual fashion.
- Figs. 168.1 to 168.6 show one of the author's cases demonstrating a maxillary defect after tumor resection followed by reconstruction with a temporalis muscle flap. The bulky muscle permits obliteration of the defect and functionally re-creates the palate. The facial contour is restored with titanium mesh.

Common Errors in Technique

- Failure to identify the correct plane of dissection
- Disruption of blood flow to the flap

POSTOPERATIVE PERIOD

Postoperative Management

- A drain is usually placed over the temporalis fossa and removed once output is minimal.
- A light pressure dressing is placed around the head.
- Intraoperative steroids should be given to decrease muscle swelling. These should be continued postoperatively for several days as a taper.
- The standard postoperative antibiotic regimen is implemented.

Complications

- Pedicled flaps have a robust vascular supply; however, previous radiation therapy can impair healing. Flap dehiscence can be managed conservatively, as these flaps frequently close by secondary intention/fibrosis without a requirement for further surgery.
- Flap necrosis should be suspected in nonhealing defects or when the muscle appears to be nonviable. It is common to have ecchymosis and a dark appearance to the muscle in the immediate postoperative period and lasting for several days to a week; however, a bedside needle prick can be used to confirm blood flow. If a necrotic flap is noted, it should be débrided to healthy bleeding muscle.
- An ipsilateral deformity with a temporal concavity is a known outcome with this procedure. We prefer not to reconstruct immediately owing to the risk of infection but to wait for healing and, if necessary, until after postoperative radiation. The defect can be corrected via a temporal incision and filled with hydroxyapatite cement or autologous adipose tissue graft at a later time.
- Injury to the frontal branch of the facial nerve can result in temporary or permanent ipsilateral paresis.

Alternative Management Plan

- Palatal defects can be allowed to heal and can be managed with an obturator.
- A temporoparietal fascial flap may be an option if less bulk is adequate for repair.
- Free tissue transfer if more bulk is needed

DISCUSSION

Evidence-Based Medicine Question

What kinds of outcomes have been reported when temporalis muscle is used as a primary reconstruction modality for palatomaxillary defects?

- Wang et al., in a retrospective chart review of their single-institution 15-year experience, concluded that the temporalis flap was a reliable reconstructive option with acceptable outcomes.[3]
  - Of a total of 69 flaps harvested, no flap was lost in its entirety, and there were only four cases of marginal or partial loss.
  - Transient paralysis of the temporal branch of the facial nerve was noted in five patients; this resolved without treatment within 3 months of surgery.
  - Based on self-evaluation of temporal aesthetic outcomes, 70.1% of patients judged their outcome as "good."
  - The size of the primary defect was significantly associated with diet status, mouth opening, and intelligibility of speech, while postoperative radiation correlated with restricted mouth opening and diet.

Editorial Comment

Golovine first reported the use of the temporalis flap for orbital reconstruction in 1898. Since that time the flap



Fig. 168.1. Coronal computed tomography (CT) image of a recurrent ameloblastoma in the right maxillary sinus.

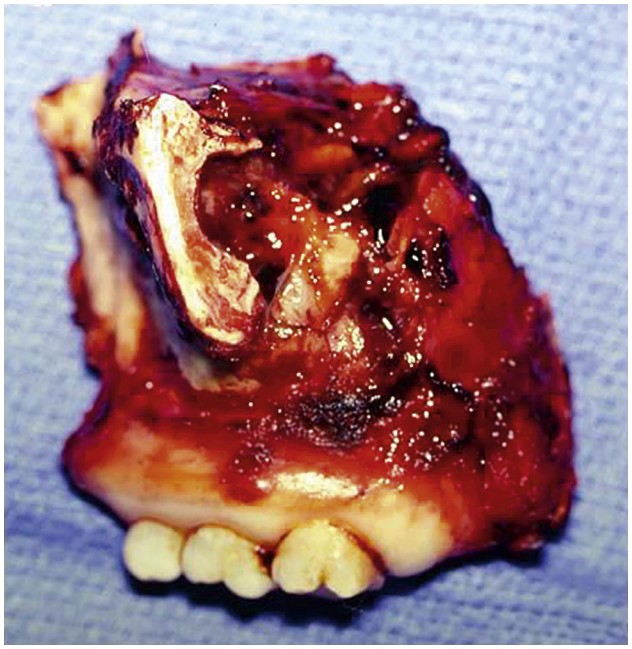

Fig. 168.2. The surgical specimen after total right maxillectomy.



Fig. 168.3. The maxillary defect after resection.

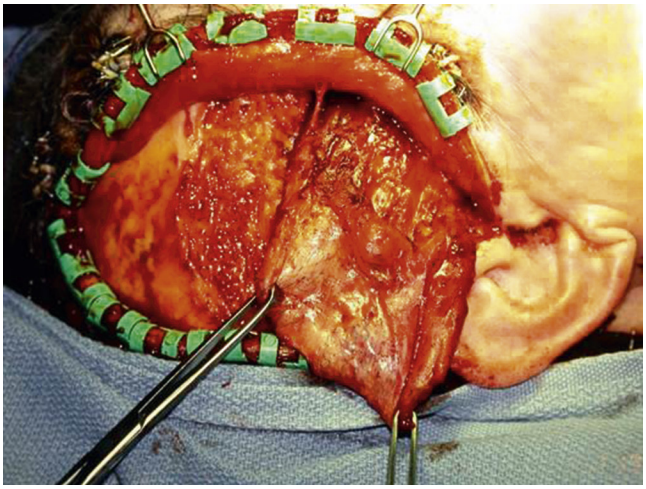

Fig. 168.4. Harvesting the right temporalis muscle flap. The muscle has been elevated off the cranium.

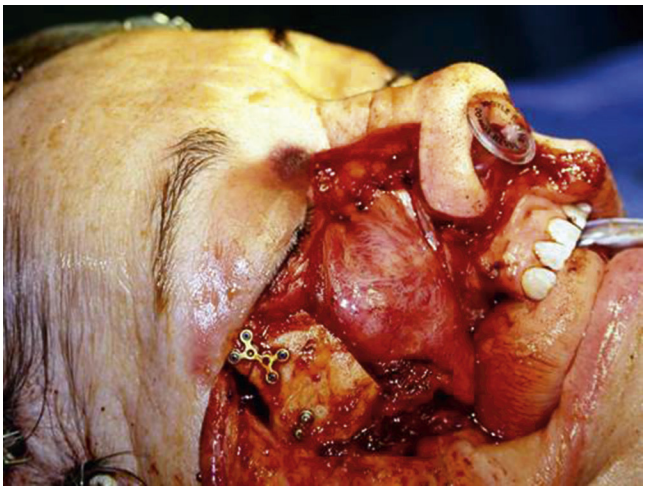

Fig. 168.5. The muscle has been rotated and set into the defect. Note that the zygomatic arch had been temporarily removed for tunneling of the muscle and now has been replaced with titanium miniplates.

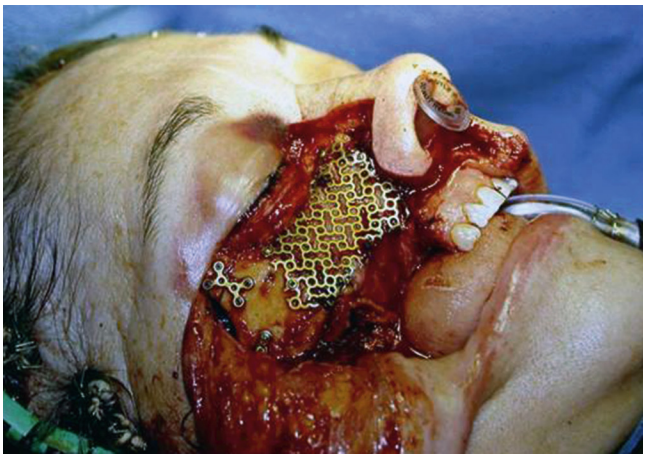

Fig. 168.6. Titanium mesh is placed to reconstruct the cheek contour. Note that inferiorly the flap re-creates the palate, obviating the need for an obturator.

has been used to reconstruct multiple maxillofacial and skull base defects because of its wide range of mobility, arc of rotation, and robust blood supply. The versatility of this flap, relative ease of its harvesting, and minor associated cosmetic defect make it invaluable in head and neck reconstruction.

Anna Pou


Access the review questions online at http://www.expertconsult.com

REFERENCES

1. Hanasono MM, Utley DS, Goode RL. The temporalis muscle flap for reconstruction after head and neck surgery. Laryngoscope 2001;111:1719–1725.
2. Fagen J. The open access atlas of otolaryngology, head and neck operative surgery. The temporalis muscle flap. Available at http://www.entdev.uct.ac.za/. Accessed October 15, 2015.
3. Wang Y, Cheng J, Yuan C, et al. Reconstruction of palatomaxillary defects following cancer ablation with temporalis muscle flap in medically compromised patients: a 15-year single institutional experience. Clin Oral Invest 2014;18:1663–1670.

REVIEW QUESTIONS

1. The frontal branches of the facial nerve run within which tissue layer?
   a. Subcutaneous adipose tissue
   b. Deep temporal fascia
   c. Superficial temporal fascia
   d. Within the temporal adipose tissue pad

2. What is the maximum arc of rotation of a temporalis muscle flap?
   a. 90 degrees
   b. 120 degrees
   c. 130 degrees
   d. 180 degrees

3. All of the following are potential complications of a temporalis muscle flap except
   a. Lower-lip weakness on ipsilateral side
   b. Inability to raise the forehead on ipsilateral side
   c. Temporal hollowing
   d. Flap necrosis

4. All of the following are true except
   a. The temporal adipose tissue pad is elevated with the scalp flap during the process of exposing a temporalis muscle flap.
   b. The blood supply to the temporalis muscle can be at risk during the elevation of the flap in the infratemporal fossa.
   c. The middle temporal artery is sufficient to support the viability of a temporalis muscle flap.
   d. Coronoid resection and zygomatic arc transposition can be used in patients with thick muscle or defects requiring a large arc of rotation to minimize tension upon closure.

169 Deltopectoral Flap

Jason I. Kass, Eugene N. Myers

INTRODUCTION

The deltopectoral flap (DP), introduced by Bakamjian in 1965,[1] dramatically changed how defects in the head and neck were reconstructed. For instance, reconstruction following total laryngopharyngectomy was accomplished using a combination of local skin flaps (Wookey procedure); delayed pedicle flaps from the back, chest, or abdomen; or split-thickness skin grafts fashioned over a stent.[2,3] These procedures frequently failed as a result of poor skin graft survival, severe strictures, fistulas, and infection. The delayed flaps took many months until inset, by which time the cancer had often recurred. The DP provides healthy, reliable, nonradiated skin to rebuild various defects and quickly became the most popular flap until the pectoralis major myocutaneous flap was introduced by Ariyan in 1979.[4]

The DP is a cutaneous flap based on the first four skin perforators from the internal mammary artery (IMA); (Fig. 169.1). These perforators vascularize a skin paddle that extends from the IMA, just lateral to the sternum, to the deltopectoral groove. Skin beyond the deltopectoral groove, overlying the deltoid, can be harvested, but the vascularity of this distal portion is supplied from deltoid perforators from the thoracoacromial trunk and the anterior circumflex artery and vein and is not completely reliable as a nondelayed flap. A flap 20 cm in length and 10 cm in width can reliably be raised and used with a high likelihood of success.[5]

Despite the evolution of regional and free-tissue options for reconstruction of defects in the head and neck over the last 50 years, the DP remains an important and versatile option for oral and pharyngeal reconstruction and for resurfacing the neck.

KEY OPERATIVE LEARNING POINTS

- The DP flap is based on the first to fourth perforators from the IMA.
- The DP flap is a fasciocutaneous rotational flap that can be used for external skin coverage, carotid coverage, reconstruction of the pharynx, and repair of pharyngocutaneous fistulas.
- The skin paddle is reliable when it is medial to the deltopectoral groove. The vascular supply beyond that point is based on a variable blood supply. For longer flaps, the distal portion should be raised in a delayed fashion.
- Although classically a two-stage reconstruction, an island DP flap can be completed in a single stage with primary closure of the skin of the chest wall.

PREOPERATIVE PERIOD

History

1. History of present illness
   a. Pharyngoesophageal defects following total laryngectomy
   b. Exposed skin defects of the neck requiring coverage with vascularized tissue
   c. Exposed vessels, particularly the carotid artery following surgical resection
   d. Coverage of a chronic wound
   e. Intraoral defects requiring reconstruction with a skin paddle
   f. Lack of recipient vessels in the neck for free tissue transfer
2. Past medical history
   a. Prior head and neck treatment:
      1) Prior history of radiation to the chest or neck
   b. Comorbid medical illnesses—cardiac, renal, pulmonary or neurologic (e.g., stroke)—that would significantly elevate perioperative risks
   c. Surgical history:
      1) Prior surgery of the upper chest
      2) Scars that suggest the IMA perforators may have been injured
      3) Prior cardiac surgery that may have sacrificed the IMA
      4) Prior pectoralis myocutaneous flap where the incision transected the IMA perforators
   d. Family history: Bleeding disorders are important to identify prior to operative intervention.
3. Medications
   a. Antiplatelet drugs
   b. Herbal products (increased risk of bleeding)
   c. Alcohol (consider risk of withdrawal)
   d. Allergies to antibiotics
4. Mental and social status
   a. Ability to give consent
   b. Social support structure
   c. Willingness and ability to undergo a two-stage operation should secondary division of the pedicle be required (staged DP)

Physical Examination

- Examination of the proposed donor site
  - Signs of prior surgery or injury to the IMA
  - Pacemaker/defibrillator
  - Central venous catheter port for chemotherapy
  - Radiation changes of the skin
  - Identify any cutaneous precancerous/malignant lesions on the planned skin paddle.
- Identification of potential alternative reconstructive donor sites using a cutaneous flap
  - Similar evaluation as above for pectoralis major myocutaneous flap
  - Allen test of both forearms for possible radial forearm free flap
  - Examination of thigh skin for possible anterolateral thigh free flap

Imaging

- No specific imaging is required prior to elevation of this flap.

Indications[6,7]

- Typical
  - Repair of cutaneous defects of the neck

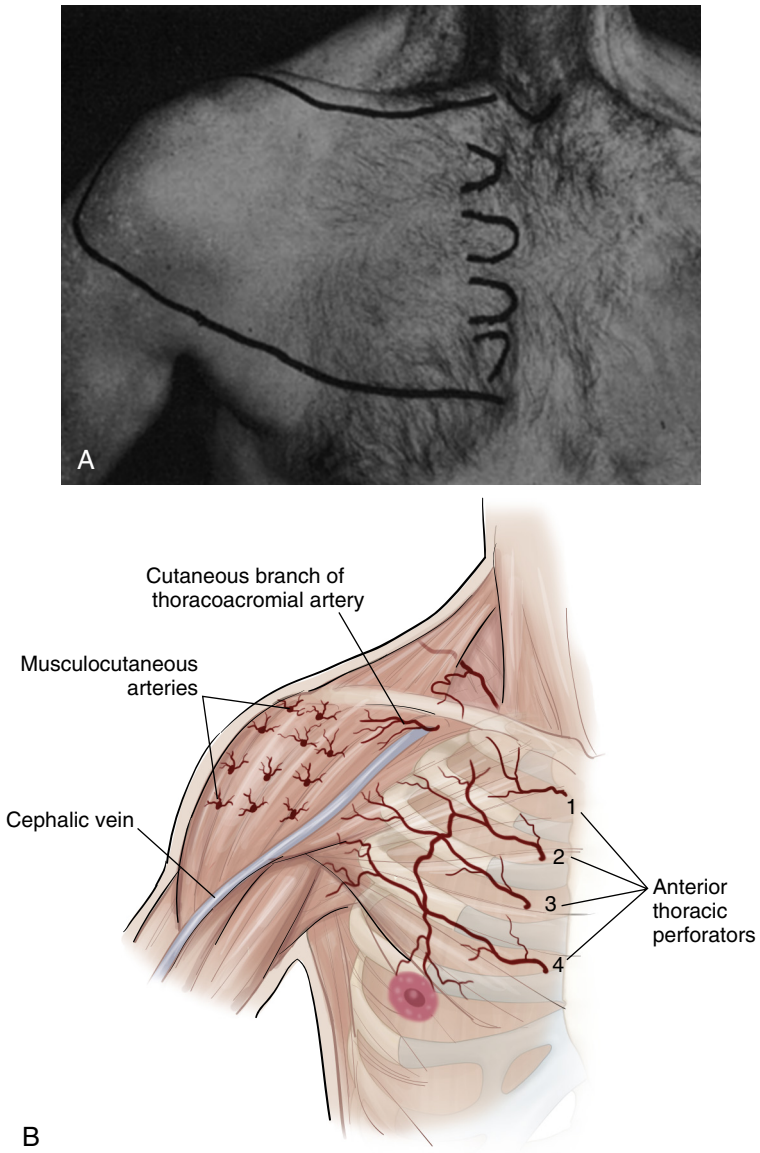

Fig. 169.1. A, Outline of incisions for the DP. IMAs are represented by semicircles. **B,** Drawing of the blood supply of the DP.

  - Coverage of exposed carotid artery or chronic wound infection
  - Coverage of other rotational or free tissue flaps[8]
  - Pharyngocutaneous fistula (prevention or treatment)
- Less common
  - Reconstruction of the soft palate
  - Reconstruction of the buccal mucosa
  - Closure of defects in the hard palate[9]
  - Reconstruction of the nasopharynx
  - Reconstruction of the pharynx (1 or 2 stages)

Contraindications

- Defects that are unable to be reached by the flap (anything rostral to the zygoma is generally very difficult to reach)[9]
- Patients with prior incisions that violate the IMA perforators
- History of cardiac surgery with ipsilateral harvest of the IMA

Preoperative Preparation

- No specific preoperative preparation is required beyond that used for surgical ablation.
- If the reconstruction is being performed secondarily, then the patient should have a routine preoperative evaluation to ensure that their condition is optimized for surgical intervention. This includes a cardiopulmonary examination and a complete blood count (CBC).

OPERATIVE PERIOD

Anesthesia

- This flap is typically used for anterior neck skin defects and pharyngeal or intraoral reconstruction, immediately following resection of a tumor of the head and neck, during which the patient is under general anesthesia. The DP flap can, in some situations, be elevated under local anesthesia. If the distal portion of the flap was raised and replaced as part of a delay procedure, it could also be performed under local anesthesia.

Positioning

- The patient is supine with the chest wall, neck, and upper arm in view. The arm can be tucked in at the patient's side.

Perioperative Antibiotic Prophylaxis

- Prophylaxis is dictated by the planned reconstruction. For clean cases, no antibiotic prophylaxis is required. For clean-contaminated intraoral reconstruction, cefazolin and metronidazole are recommended. Cefuroxime or clindamycin can be used if the patient is allergic to penicillins.

Monitoring

- There is no nerve monitoring required during flap elevation and inset.

Instruments and Equipment to Have Available

- Standard head and neck set
- For the classical DP flap, a dermatome is used to harvest a split-thickness skin graft to resurface the pectoralis muscle.

Key Anatomic Landmarks

- There are usually four perforators from the IMA that vascularize the skin lateral to the sternum.
- The deltopectoral groove is the typical lateral extent of the reliable portion of the skin paddle. Beyond this groove, the skin is vascularized by deltoid perforators. If this skin is included, the flap is less reliable because it relies on random subcutaneous vessels.
- The cephalic vein runs in the deltopectoral groove beneath the skin.

Prerequisite Skills

- Experience in reconstructive surgery is required. A comfort level with elevating pectoralis major, supraclavicular, or other rotational flaps is recommended.

Operative Risks

- Related to the duration of the procedure
  - Intraoperative cardiac events
- Related to flap elevation
  - Aspiration: Ensure that there is no significant air leak in the cuff and that the endotracheal tube is sufficiently inflated to protect the airway.
  - Airway fire: If the flap is being elevated near a tracheostomy or tracheostoma, maintain oxygen saturation below 30% when using electrocautery near the airway. Maintain good communication with the anesthesia team regarding fire risks.

Surgical Technique

- Classical medially based deltopectoral rotational flap (Fig.169.2)
  - The superior skin incision is placed along the superior edge of the clavicle.
  - The width of the base includes the first four interspaces between the clavicle and the fourth rib.
  - The lateral edge of the flap can reliably extend to the deltopectoral groove without concern for major tip necrosis. Beyond that, the flap can be extended to the lateral aspect of the upper arm. In those cases we recommend delaying elevation of the complete flap. When reconstructing the tongue, floor of the mouth, or pharynx, the flap has a typical width-to-length ratio of 2:1.

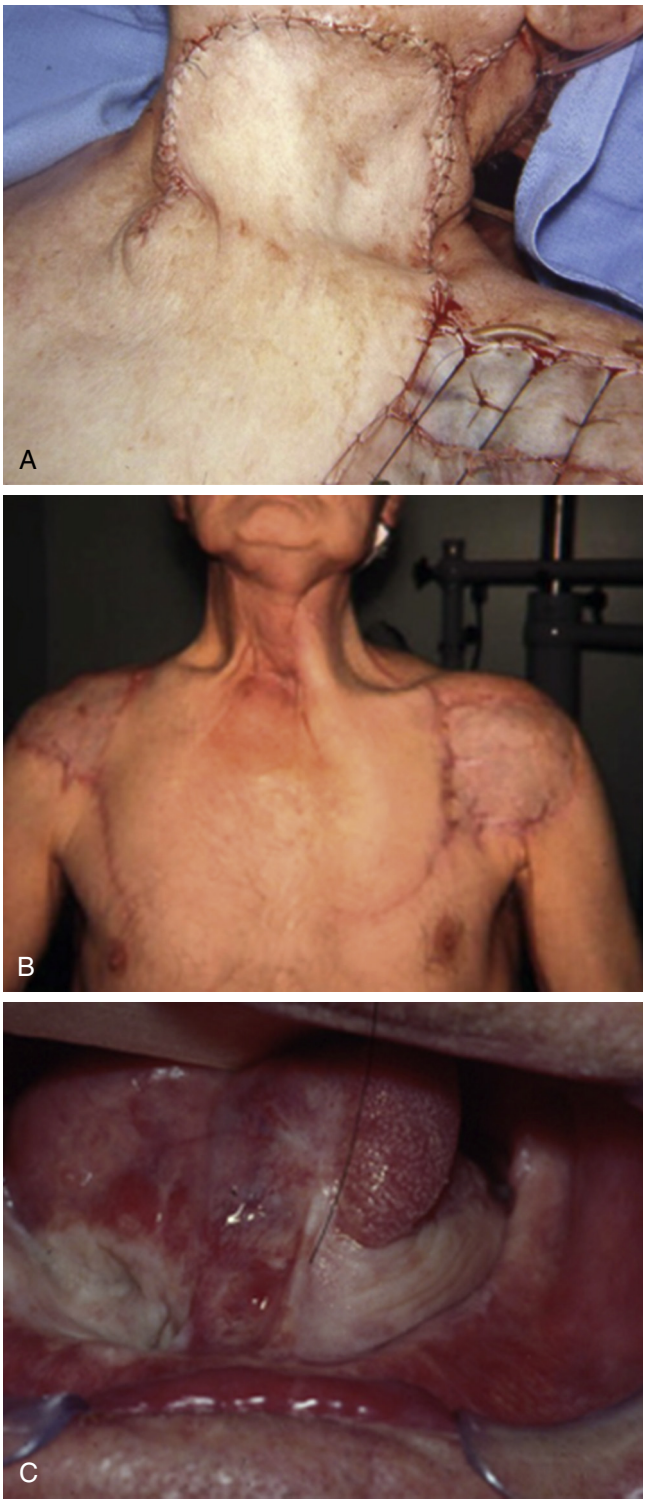

Fig. 169.2. A, DP inset into a defect produced by excision of the skin of the left neck. Also demonstrated are the tacking sutures in the skin graft and the catheters used to protect the skin from pressure necrosis from the black silk sutures used to reduce the size of the chest defect. **B,** A DP was used to resurface the left neck. **C,** A DP was used to resurface a defect in the left floor of the mouth. A skin graft was used to resurface a defect in the right floor of the mouth following excision of a squamous cell carcinoma 20 years following the resection of the lesion on the left.

- When delaying the flap, incise the skin margin and undermine only the portion of the skin supplied by the thoracoacromial artery perforators. Once these vessels have been ligated, the flap can be sutured back in place. We recommend delaying the final flap elevation for 2 to 3 weeks.
- The skin paddle is elevated deep to the fascia of the pectoralis muscle in a lateral-to-medial direction. Elevation should stop about 2 cm lateral to the sternum to prevent injury to the IMA perforators.
- The elevated skin paddle is then rotated into place and inset with care taken to ensure that there is no tension on the suture line. The flap may be passed over an intact bridge of skin or designed as an island flap (see below).
- If additional length is needed, an incision can be made through the skin and subcutaneous tissue overlying the sternum, inferior and medial to the most inferior perforator.
- The chest wall defect is typically covered with a split-thickness skin graft and a Penrose drain or suction drain is placed in the wound.
- Split-thickness skin grafts are harvested from the lateral aspect of the thigh. The skin grafts are sewn to the edges of the chest wall defect. Tacking sutures of 3-0 plain gut are used liberally to decrease the possibility of any shearing effect or large collection of blood or serum between the skin graft and the muscle (see Fig. 169.2A).
- Sutures of 0-silk on a Keith needle are placed with the first bite through the skin bordering the superior aspect of the donor site (Fig. 169.2A) and the second bite through the skin of the inferior border of the donor site. The needle is passed through a 1-cm piece of red rubber catheter to protect the skin from pressure necrosis from the suture. Then the suture is placed through the inferior edge of the donor site and back superior and placed through the skin of the superior edge of the donor site, then through another piece of red rubber catheter, and then tied with a surgeon's knot. Several such mattress sutures are usually required.
- Using a rolled up 4 × 4 gauze pad, any blood is pressed out from between the skin graft and the pectoralis muscle.
- Pieces of Xeroform gauze are tucked under the mattress sutures and spread out to cover the skin grafts.
- The flap is then left in place for 3 to 4 weeks. At that point, although not necessary, the pedicle can be divided with inset of the base of the flap into the donor site or the redundant flap may simply be excised.

- Island DP flap (see Fig. 169.3)[10]
  - A skin paddle is drawn at the lateral edge of the flap to ensure that, following elevation, the flap will reach the defect without tension. The pivot point for the base of the flap is generally 3 to 4 cm from the sternum.
  - A skin incision is made over the midportion of the pedicle and the skin is elevated, sharply, just deep to the dermis. This leaves all the subcutaneous adipose tissue undisturbed. Small vessels that bleed are cauterized using focal bipolar or needle-tip monopolar electrocautery.
  - With the skin overlying the flap pedicle elevated, the pedicle is elevated from the chest wall. An incision is made superiorly and inferiorly deep to the fascia of the pectoralis muscle.
  - A tunnel is created deep to the superior chest skin into the neck. It should also be large enough to allow the skin paddle to pass with minimal restriction.
  - The flap is elevated laterally off the chest wall and passed through the tunnel into the neck. Care should be taken not to shear the skin island off of the pedicle.
  - If the chest wall has considerable subcutaneous bulk, four tacking sutures can be placed in the corners of the skin paddle so that it will resist shearing forces during rotation.
  - Depending on the size of the island skin paddle, the skin can typically be closed primarily. A Penrose or suction drain is placed beneath the skin.
  - If the skin defect cannot be closed primarily, a split-thickness skin graft is used.

Common Errors in Technique

- The skin will become congested if the rotation at the base of the pedicle compresses the venous drainage (internal mammary vein [IMV]) vein. The flap should be elevated such that the skin paddle can be inset without twisting the proximal portion of the pedicle.
- For the island DP flap, the skin incision and elevation over the pedicle should be done sharply, just deep to the hair follicles. Elevating the flap within the subcutaneous adipose tissue will injure small superficial vessels that travel in the subdermal plexus.

POSTOPERATIVE PERIOD

Postoperative Management

The DP flap does not require any unique postoperative monitoring. A suction drain or Penrose drain is helpful to allow for routine drainage. Care must be taken to ensure that a hematoma does not accumulate beneath the flap. Primary focus should be on tip ischemia and necrosis. This will inevitably lead to wound dehiscence, fistula with pharyngeal/intraoral flaps, and infection. The Xeroform gauze and bolster sutures are removed from the chest wound in 2 weeks and any excess split-thickness skin graft is removed.

Complications[6]

The largest series of DP flaps (n = 678)[6] reported the following complications:

- Intraoperative loss (1%): rare and secondary to injury to the proximal main pedicle
- Tip necrosis (major, 17%; minor, 14%)
- Fistula (16%)
- Infection (11%)
- Flap separation (6%)
- Stricture (2%)
- Hematoma (1%)

Alternative Management Plan

Depending on the defect, there is a wide variety cutaneous, fasciocutaneous, and musculocutaneous flaps that can substitute for the DP flap. These include both regional and free tissue transfer. When time is of the essence, harvesting and insetting of the DP flap and resurfacing the donor site are much faster.

DISCUSSION

Evidence-Based Medicine Question

Where should the modern-day reconstructive surgeon place the DP among the many choices for pharyngoesophageal reconstruction?

There are no studies that directly compare outcomes between the DP and the varied regional and free tissue options.



Fig. 169.3. Closure of a pharyngeal defect using an island deltopectoral flap. A, Design of the skin paddle. The *solid line* represents the planned incision. The *dotted line* demonstrates the width of the subcutaneous pedicle. **B,** Following elevation of the flap. **C,** A subcutaneous tunnel was created and the skin paddle was used to close the pharyngocutaneous fistula. **D,** Primary closure of the skin defect is shown.

The reconstructive surgeon is left to make decisions based on expert opinion, experience, and comfort level between the many options. Of the recently published reports, all written by experienced microsurgeons, the DP flap has been used for vascularized skin coverage of the neck, carotid protection, creation of a controlled fistula, closure of a pharyngocutaneous fistula, and pharyngoesophageal reconstruction.[5] It continues to be useful when recipient vessel options are few or as a buttress to microvascular reconstruction for massive defects.[6]

Editorial Comment

Prior to 1965, when Dr. Bakamjian introduced the DP, reconstruction of defects in the head and neck region were primitive at best. Radiation using orthovoltage machines was given in large doses to attempt to cure advanced stage cancers. When the cancer recurred, as it often did, radical surgery resulted in the formation of tissue necrosis, bone exposure with osteoradionecrosis, and oropharyngocutaneous fistulas. To prevent exposure and blow out of the carotid artery, the wounds were closed incorporating an orostome or pharyngostome to prevent saliva from undermining the cervical flaps and exposing the carotid artery, which regularly led to rupture of the wall of the vessel, exsanguination, and death.

The introduction of the DP flap was a game changer because it allowed immediate reconstruction with a nondelayed regional flap from outside of the radiated field. This eliminated the stomas and promoted accelerated healing. As imaginative head and neck surgeons adapted this flap, they quickly found additional uses for it such as reconstruction of defects of the middle and lower thirds of the face, the oral cavity, the neck, and the esophagus. Dr. John Conley used an epithelial shave of the proximal portion of the tubed pedicle flap to do a one-stage reconstruction of a total laryngopharyngeal defect.

As often happens, the introduction of a new technique stimulated the imagination of the new generation of surgeons to find ways of improving closure of these challenging defects. In 1979 Dr. Steven Ariyan proved this point when he introduced the pectoralis major myocutaneous flap, which has become the most frequently used regional pedicle flap in head and neck reconstruction. For more than 30 years imaginative surgeons have introduced a wide variety of free flap transfer, often using a combination of tissues (e.g., osseocutaneous free flaps) and free flaps in conjunction with regional pedicle flaps. With intense research being carried out with 3-D imaging and stem cells, we can be sure that in the future immediate reconstruction of defects in the head and neck will change for the better yet again.

Eugene N. Myers

Access the review questions and additional sources list online at http://www.expertconsult.com

REFERENCES

1. Bakamjian V. A two-stage method for pharyngoesophageal reconstruction with a primary pectoral skin flap. Plast Reconstr Surg 1965;36:173–184.
2. Wookey H. The surgical treatment of carcinoma of the hypopharynx and the esophagus. Br J Surg 1948;35(139):249–266.
3. Sundaram K, Har-El G. The Wookey flap revisited. Head Neck 2002;24(4):395–400.
4. Ariyan S. The pectoralis major myocutaneous flap: a versatile flap for reconstruction in the head and neck. Plast Reconstr Surg 1979;63(1):73–81.
5. Manders E. Regional pedicle flaps—DP. Operative Otolaryngoscopy Head and Neck Surgery. 2nd ed. Philadelphia, PA: Saunders; 2008. p. 761.
6. Gilas T, Sako K, Razack MS, et al. Major head and neck reconstruction using the DP. A 20 year experience. Am J Surg 1986;152(4):430–434.
7. Andrews BT, McCulloch TM, Funk GF, et al. DP revisited in the microvascular era: a single-institution 10-year experience. Ann Otol Rhinol Laryngol 2006;115(1):35–40.
8. Blackwell KE, Buchbinder D, Biller HF, et al. Reconstruction of massive defects in the head and neck: the role of simultaneous distant and regional flaps. Head Neck 1997;19(7):620–628.
9. Bakamjian VY, Poole M. Maxillo-facial and palatal reconstructions with the DP. Br J Plast Surg 1977;30(1):17–37.
10. Portnoy WM, Arena S. Deltopectoral island flap. Otolaryngol Head Neck Surg 1994;111(1):63–69.

REVIEW QUESTIONS

1. What is the blood supply to the medially based DP?
   a. Pectoral branch to the thoracoacromial artery
   b. Thoracoacromial artery directly
   c. Perforators from the subclavian artery
   d. Perforators from the IMA

2. What is the most common contraindication to elevating and using a DP?
   a. Prior neck irradiation
   b. History of cardiac bypass surgery
   c. Prior pectoralis major reconstruction with a scar perpendicular to the DP pedicle
   d. Prior radical neck dissection on the ipsilateral neck

3. When designing a medially based DP, at what length does tip necrosis become likely and delayed elevation a prudent operative plan?
   a. Any distance lateral to the deltoid muscle
   b. Any distance lateral to the nipple
   c. Any distance lateral to deltopectoral groove
   d. All flaps should be delayed

ADDITIONAL SOURCES

Gingrass RP, Culf NK, Garrett WS, et al. Complications with the DP. Plast Reconstr Surg 1972;49(5):501–507.
Krizek TJ, Robson MC. Potential pitfalls in the use of the DP. Plast Reconstr Surg 1972;50(4):326–331.
Mortensen M, Genden EM. Role of the island DP in contemporary head and neck reconstruction. Ann Otol Rhinol Laryngol 2006;115(5):361–364.

170 Pectoralis Major Musculocutaneous Flaps in Head and Neck Surgery

Zoe M. Macisaac, Mario G. Solari, Ernest K. Manders, Alex Senchenkov

INTRODUCTION

Regional flaps play an important role in reconstructive surgery of the head and neck. Introduced in 1979,[1] the pectoralis major musculocutaneous flap was an important improvement over the deltopectoral flap and multistage tissue transfers that had dominated the reconstruction attempts previously. This flap allowed effective and more reliable single-stage tissue transfer for reconstruction of complex defects of the neck and face, upper aerodigestive tract, and skull base. This development enhanced resection capability and enabled patients with cancer of the head and neck to receive timely adjuvant radiation therapy, facilitating surgical treatment combined with curative intent. However, with advances in microvascular tissue transfer, the pectoralis major flap has been relegated to a secondary role in reconstruction.[2-4] Nevertheless, the pectoralis major flap remains an important reconstructive option for certain indications.

KEY OPERATIVE LEARNING POINTS

1. The role of the pectoralis major musculocutaneous flap in contemporary head and neck reconstruction lies in the salvage of patients who are not candidates for free flaps or for coverage of the neck when a free flap is deemed unwarranted.
2. The flap is based on the pectoral branch of the thoracoacromial trunk. The trunk originates from the subclavian vessels and emerges at the point projected on the skin just medial to the deltopectoral triangle bordered by the deltoid, pectoralis major, and clavicle (also known as the Mohrenheim fossa). The pectoral branch runs along a line drawn from that projected point to the xiphoid process (Fig. 170.1A). The pedicle runs on the undersurface of the pectoralis major muscle (Fig. 170.2B) in the clavipectoral fascia and must be visualized and protected during dissection.
3. Dissection of the flap should be performed with minimal muscle bulk (Fig. 170.3) and, when necessary, comprising the entire muscle. Complete denervation of the muscle included in the flap is important to prevent subsequent animation of the flap and to promote atrophy.
4. The skin paddle is often designed on the inferior border of the muscle or inframammary fold in women (see Fig. 170.3); its perimeter can be used as the exposure for flap dissection (see Fig. 170.1A). Distal location of the skin paddle improves the arc of rotation.
5. A minimal-access dissection of the flap through the perimeter of the skin paddle is best performed with the use of lighted retractors. Complete hemostasis and secure ligation of the deltoid and acromial branches of the thoracoacromial trunk are the key. A laparoscopic harmonic scalpel is an excellent adjunct in this dissection (see Fig. 170.1C).

PREOPERATIVE PERIOD

History

1. Previous procedures that may have compromised the anatomic integrity of the pectoralis major flap (subpectoral pacemaker placement or any operation in the area of the pedicle) and congenital absence of the pectoralis major muscle (e.g., Poland syndrome) will preclude its use as a reconstructive option.
2. Paralysis of the ipsilateral latissimus dorsi muscle will result in shoulder impairment.
3. All medical comorbidities—including those that relate to mortality risk (e.g., respiratory and cardiac disease, alcoholism) and those related to wound healing (e.g., diabetes, nutritional status, smoking, thyroid dysfunction)—should be assessed and mitigated preoperatively if possible.

Physical Examination

1. The functional and anatomic integrity of the pectoralis major flap and the ipsilateral latissimus dorsi muscle must be evaluated.
2. The amount of subcutaneous adipose/breast tissue overlying the muscle should be examined in order to determine whether the flap should be harvested as a myocutaneous or myofascial flap.

Imaging

1. Imaging is typically unwarranted for flap evaluation but if necessary the authors favor a surgeon-performed duplex ultrasound evaluation as the most versatile form of imaging.

Indications

1. Infection or radiation-related carotid artery exposure or blowout
2. Complications of carotid endarterectomy or stenting
3. Cervical skin defects with vascular exposure following neck dissection, pharyngeal or esophageal fistula, and/or failed free flaps
4. Reconstruction of the upper aerodigestive tract in patients with vessel-depleted, multiply operated necks
5. Medical comorbidities or poor physical status, precluding microvascular tissue transfer

Contraindications

1. Anatomic compromise of the pectoralis major muscle and/or its blood supply is an absolute contraindication.
2. In the case of the nonfunctional latissimus dorsi muscle, shoulder dysfunction should be balanced against a critical defect.

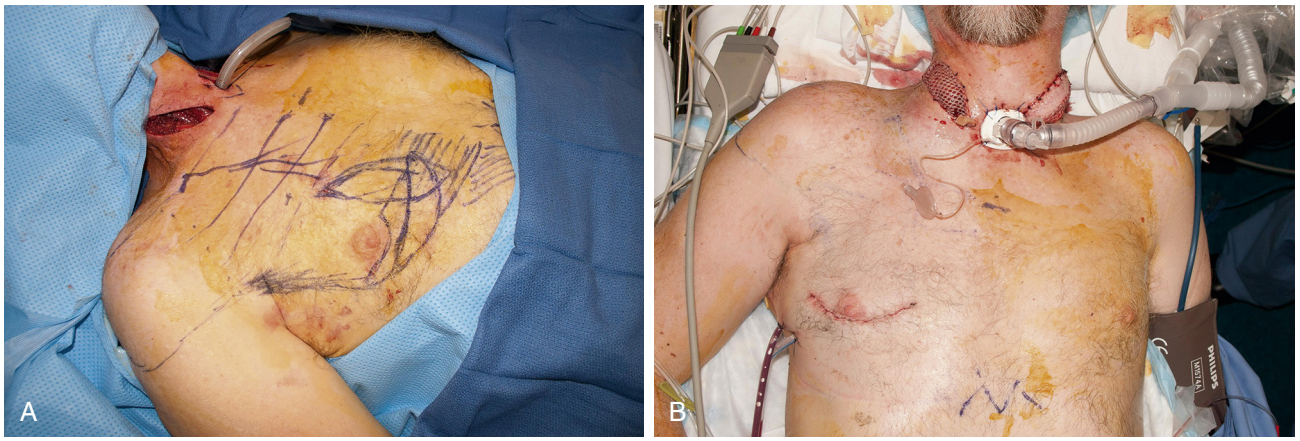

Fig. 170.1. A 68-year-old man with a history of carcinoma of the tonsil treated with chemoradiation developed exposure of the cervical spinal hardware through the posterior pharyngeal and cervical esophageal wall. A, The flap is harvested through the perimeter of the skin paddle and inset. A meshed 1.5:1 and stretched split-thickness skin graft is used to offset the tension of radiated skin on the flap. The flange of the tracheostomy tube is trimmed and sutured to prevent application of the tracheostomy ties postoperatively. **B,** Postoperatively, secondary contracture of the skin graft minimizes the deformity, the denervated muscle atrophies, and the skin paddle of the flap is excised in the office under local anesthetic. *(Case of Mark S. Allen, MD [thoracic surgery], and Alex Senchenkov, MD [plastic surgery], Mayo Clinic Foundation.)*

3. Cosmetic concerns in women and deformity in men should be taken into consideration and discussed preoperatively.
4. Insufficient arc of rotation and/or size of flap to cover defect. This can be determined at the time of flap design if not before.

Preoperative Preparation

1. Negative margins after excision of the tumor
2. Uninfected wound

OPERATIVE PERIOD

Anesthesia

1. General

Position

1. Supine
2. The bed is turned 90 or 180 degrees from the anesthesiologist.

Perioperative Antibiotic Prophylaxis

1. **Preoperative:** A first-generation cephalosporin may be administered; if the procedure is done in conjunction with cancer extirpation, no additional antibiotics are needed for harvesting of the flap.

Monitoring

1. Continuous monitoring of blood pressure, pulse, and oxygen content per anesthesia
2. Arterial blood gases when indicated
3. Hemoglobin and hematocrit when indicated

Instruments and Equipment to Have Available

1. Routine head and neck set with retractor set
2. Monopolar and bipolar electrocautery
3. Lighted retractors if minimal exposure is preferred

Key Anatomic Landmarks

1. The pectoralis major muscle is related superiorly to the clavicle and deltoid muscle and inferiorly to the rectus abdominis and external oblique.
2. Origin from the medial half of the clavicle, anterior surface of the sternum, cartilaginous portion of the upper seven ribs, and the aponeurosis of the external oblique muscle; insertion to the lateral lip of the bicipital groove of the humerus
3. Dominant pedicle: Pectoral branch of the thoracoacromial artery and venae comitantes (from the subclavian artery and veins: emerges through the clavipectoral [coracoclavicular] fascial bridge between the subclavius and pectoralis major muscles and runs on the deep surface of the muscle)
4. Care must be taken to ligate the acromial and deltoid branches during flap dissection. Failure to do so may result in unwanted postoperative bleeding.
5. Minor pedicle: Pectoral branch of the lateral thoracic artery and vein that emerges below the clavicle and enters the deep surface of the upper border of the muscle 3 to 4 cm lateral to the thoracoacromial branches; in a few patients this is the main blood supply to the flap
6. Minor segmental pedicle: Internal mammary perforating arterial branches through first to sixth intercostal spaces and venae passing through the intercostal spaces to enter the deep surface of the muscle within 1.5 to 2 cm of the sternal margin
7. Minor segmental pedicle: Perforating branches of the fifth, sixth, and seventh intercostal arteries, passing through the intercostal spaces to enter the deep surface of the muscle 4 to 6 cm from the sternal origin
8. Motor nerve supply: Lateral pectoral nerve (from the lateral cord of the brachial plexus, entering the muscle on its deep surface approximately at its midpoint)
9. Motor nerve supply: Medial pectoral nerve (from the medial cord of the brachial plexus, entering the muscle on its deep surface laterally after passing through the pectoralis minor)
10. Sensory nerve supply: Segmental innervation from the second through seventh intercostal nerves

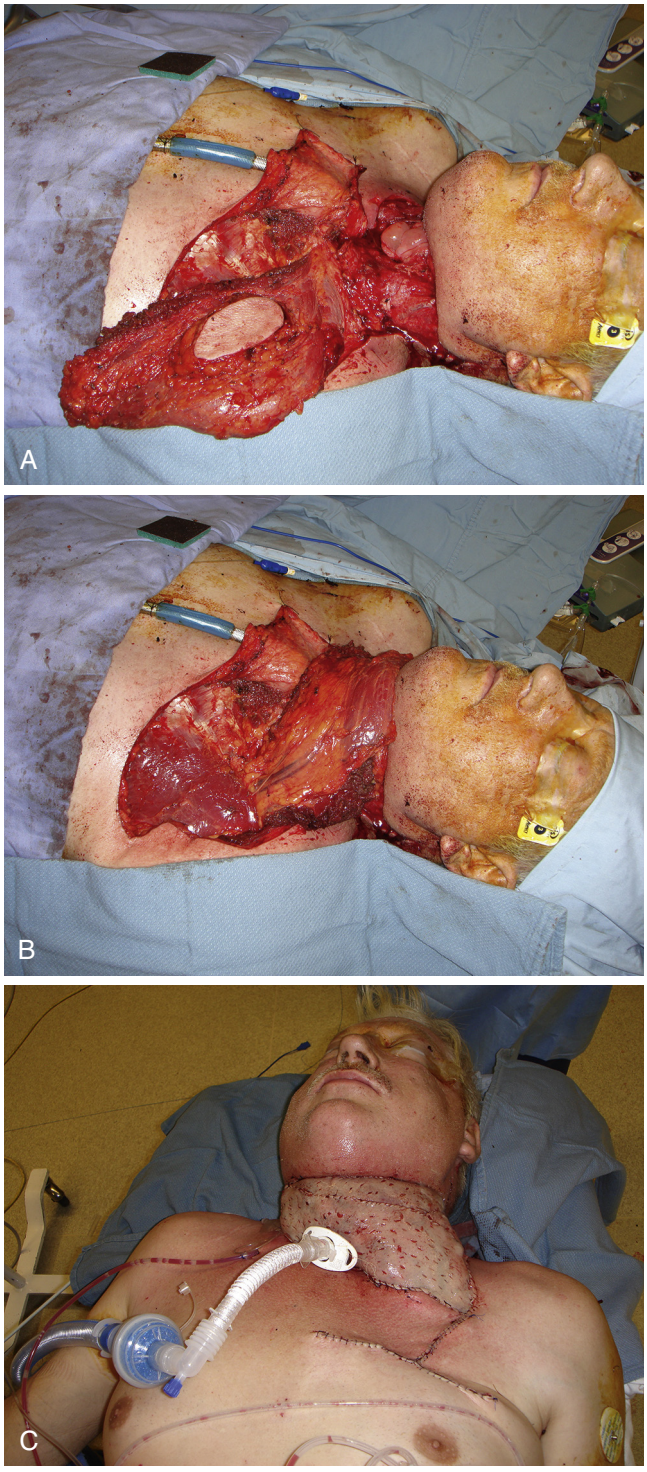

Fig. 170.2. Salvage laryngectomy with neck dissection for chemoradiation failure of squamous cell carcinoma of the larynx. Postoperatively the patient developed a pharyngeal leak. A pectoralis major musculocutaneous flap is used for reconstructive salvage. **A,** Beveling out dissection of the small paddle maximizes its viability. **B,** The entire muscle is used to ensure coverage of both the pharynx and neck. **C,** The radiated neck and skin of the upper chest are completely divided to prevent compression of the flap pedicle and exposed muscle surface if grafted with a sheet split-thickness skin graft. *(Case of Ernest K. Manders, MD, and Alex Senchenkov, MD.)*



Fig. 170.3. A pectoralis major musculocutaneous flap dissection in a female patient in the setting of surgical salvage. The skin paddle is harvested from the inframammary fold on the narrow denervated strip of muscle. *(Case of Alex Senchenkov, MD.)*

Prerequisite Skills

1. Knowledge of the anatomy of the chest wall
2. Proficiency in soft tissue surgery
3. Understanding of the defects amenable to this reconstruction

Operative Risks

1. Bleeding
2. Damage to the pedicle
3. Shearing of the cutaneous portion of the flap from the underlying muscle
4. Hemopneumothorax
5. Poor flap design

Surgical Technique: (Include Narrated Videos Online)

- Pectoralis major musculocutaneous flap:
  - Design the skin paddle adjacent to the inferior border of the muscle and outline the territory of the deltopectoral flap as well as the thoracoacromial vessels (see Fig. 170.1A). Duplex ultrasound is a useful adjunct study that confirms the vascular anatomy of the flap.
  - Dissection is started with the skin paddle, and the perimeter of this incision is often sufficient for the entire exposure. If the skin paddle has a random component (i.e., not directly overlying the muscle), care must be taken to recruit a deep fascial plane just above the intercostal muscles to preserve the blood supply of this random portion of the skin paddle.
  - A narrow central slip of muscle containing the vascular pedicle is dissected in the cephalad direction. This is best accomplished using lighted breast augmentation retractors or a head light. A laparoscopic harmonic scalpel is particularly useful to achieve secure hemostasis. The

preserved lateral remnant of the muscle will provide an anterior axillary fold postoperatively. In many cases the entire muscle is harvested, using the flap to cover vessels, a pharyngeal suture line, or other areas of defect.

- Careful visualization of the vascular pedicle on the deep surface of the muscle and palpation of the pulse are important to the safety of the dissection.
- Complete the dissection up to the clavicle and divide and ligate the deltoid and acromial branches of the thoracoacromial trunk, which will enhance the arc of rotation of the flap (see Fig. 170.2B).
- The pectoral nerves must be identified (see Fig. 170.2B) and divided to induce muscle atrophy and prevent animation of the flap.
- A tunnel is made between the chest and the neck in a subcutaneous plane to allow passage of the flap into the neck/defect. The tunnel should easily allow passage of four fingers. Detached from its clavicle insertion, the clavipectoral fascia forms a fascial band, which must be released to avoid compression of the pedicle.
- Radiated neck skin lacks compliance; therefore such tunnels should be released with skin grafting of the muscle if necessary (see Figs. 170.1B and 170.2C).
- Flap inset is done without twisting the pedicle. Deep aspects of the flap are secured to prevertebral fascia or other structures such as the mandible to avoid down pulling due to gravity, thus preventing dehiscence and leaks.
- Internal mammary perforators 2, 3, and 4 are preserved in order to maintain the blood supply for a future deltopectoral or internal mammary artery perforator (IMAP) flap.
- Most donor sites can be closed directly. For larger skin defects, vacuum-assisted closure (VAC) and DermaClose with staged closure have been employed. Skin grafts are rarely needed.
- Ties around the neck should not be used postoperatively. The authors' practice for patients with both free and pectoralis major flaps is to cut off the tie opening on the flange of the tracheotomy tube and suture it to the neck skin (see Fig. 170.1B). A sign saying *Nothing Around Neck* is posted over the patient's bed.

Common Errors in Technique

1. Excessive tissue bulk resulting in difficulty closing the neck or defect
2. Tight tunnel causing pedicle compression
3. Compression of the flap pedicle with the tracheostomy cannula tie
4. Limited pedicle length and arc of rotation
   - Preoperative flap design and measurements are critical. It should be recognized that body habitus may limit the reach of the flap.
5. Excessive traction on the thoracoacromial pedicle
   - Careful design, dissection, inset of the skin paddle, and suture stabilization of the muscle portion of the flap are preventive measures.
6. Skin paddle loss
   - The skin paddle should be designed to lie at least in part over the muscle territory (see Fig. 170.1B).
7. Dehiscence

Postoperative Management

1. Adequate pain control, warm room, and adequate hydration to avoid vasospasm
2. Tracheostomy care to prevent pedicle compression (see Fig. 170.1B)
3. Perioperative antibiotics
4. Referral to physical therapy

Complications

1. Dehiscence of flap and postoperative fistula due to its bulk and pedicle attachment. Immediate care for salivary leak is required (drainage of saliva, débridement). Additional flaps may be necessary and urgent if there is exposure of the carotid artery.
2. Partial flap necrosis typically due to inadequate blood supply to random portion of flap
3. Reduced shoulder and neck function

Alternative Management Plan

1. Free flap reconstruction
2. Other regional flap reconstruction

DISCUSSION

Evidence-Based Medicine Question

What are the benefits and disadvantages of using a pectoralis major flap for head and neck reconstruction compared with free flap reconstruction?

Introduced by Ariyan in 1979,[1] the pectoralis major regional flap became the standard and reliable method of reconstruction of large defects in the head and neck until microsurgical reconstructions became widely available.[2-4]

Despite its reliability and shorter operative time, the pectoralis major flap is associated with *longer hospital stays*[2-4] and *higher hospital costs* ($28,460 for free flap reconstruction compared with $40,992 for pectoralis major reconstruction).[2] Longer hospital stays associated with pectoralis major flap reconstruction may be related to the *increased rate of adverse events* (partial flap necrosis, salivary fistula, wound infection, and delays in healing). Flap physiology, flap bulk, pedicle tethering, and wound morbidity of the donor site—which communicates directly with the site of the reconstruction—may play deleterious roles.[2-4] Healing delays in patients treated with pectoralis flaps are not trivial: in the setting of multimodality oncologic treatment, these patients require adjuvant radiation therapy within 6 weeks and completion of all treatments within 100 days for the best oncologic outcomes.

There are important physiologic differences in the blood supply of pedicled flaps and free flaps that may pertain to the superiority of microvascular reconstructions. Frequently skin paddles lie at least one angiosome away from the pedicle vessel's vascular territory.[4] In the case of a pectoralis flap, the skin paddle is primarily supplied by the internal mammary perforators rather than the branches of thoracoacromial vessels, as demonstrated by the classic work of Taylor and Palmer.[5] In contrast, the blood supply of the free flap skin paddle corresponds to the very angiosome of its vascular pedicle. The reliability of such microvascular flaps and the power of their blood supply are truly superior to traditional regional flap reconstructive surgery.

Editorial Comment

As microsurgical techniques have become widely adopted and refined, free flap reconstruction has supplanted reconstruction with the pectoralis major flap. However, for patients who are not candidates for free flap reconstruction, the pectoralis major flap remains a viable option.

Alex Senchenkov

REFERENCES

1. Ariyan S. The pectoralis major myocutaneous flap. A versatile flap for reconstruction in the head and neck. Plast Reconstr Surg 1979;63(1):73–81.
2. Kroll SS, Evans GRD, Goldberg D, et al. A comparison of resource cost for head and neck reconstruction with free and pectoralis major flaps. Plast Reconstr Surg 1997;99(5):1282–1286.
3. Kroll SS, Reece GP, Miller MJ, et al. Comparison of the rectus abdomens free flap with the pectoralis major myocutaneous flap for reconstructions in the head and neck. Am J Surg 1992;164(6):615–618.
4. Blackwell KE. Unsurpassed reliability of free flaps for head and neck reconstruction. Arch Otolaryngol Head Neck Surg 1999;125(3):295–299.
5. Taylor GI, Palmer JH. The vascular territories (angiosomes) of the body: experimental study and clinical applications. Br J Plast Surg 1987;40(2):113–141.

REVIEW QUESTIONS

1. Which of the following is a relative contraindication to using a pectoralis major flap?
   a. Infection-related carotid artery exposure
   b. Neck defect with esophageal leaks
   c. Pharyngeal reconstruction in the patients with vessel-depleted multiply operated necks
   d. Severe thrombophilia
   e. A nonfunctional latissimus dorsi muscle

2. A 78-year-old moribund patient underwent a composite resection for treatment of locally advanced squamous cell carcinoma of the oral cavity; previous palliative radiation had failed. Because the patient could not tolerate the length of the microvascular reconstruction procedure owing to severe cardiovascular comorbidities, a pectoralis major musculocutaneous flap was used in the surgery. The entire procedure was performed on the basis of a weight-based heparin nomogram and aspirin in view of recently placed cardiac stents and symptomatic cerebrovascular disease. Four hours after arrival in the intensive care unit (ICU), the patient was hemodynamically labile and a small hematoma of the chest wall was noted at the flap donor site. The patient is returned to the operating room for re-exploration of the site. General "nonsurgical" oozing is noted in the lateral aspect of the most cephalad part of the dissection pocket. The next step should be which of the following?
   a. Decrease heparin drip to 500 U/h and return the patient to the ICU
   b. Transfuse single-donor platelets and, if improvement is noted, return the patient to the ICU
   c. Pack the site with a clotting agent (e.g., Surgicel) and return the patient to the ICU
   d. Extend the skin incision for close evaluation of the pedicle site
   e. Apply wound VAC to allow sponge compression to small bleeding sites

3. A 69-year-old edentulous man with squamous cell carcinoma of the oral cavity invading left mandibular parasymphysis (T4 N0) underwent composite resection with bilateral neck dissection and reconstruction with an osteocutaneous free fibula flap. On postoperative day 1, the patient was taken back to the operating room for venous congestion and underwent venous thrombectomy. Despite postoperative anticoagulation, necrosis of the intraoral skin paddle developed and salivary leak into freshly dissected neck ensued. The patient was again returned to the operating room where the free fibula was found to be completely necrotic. Following débridement, what will be the most appropriate course of action?
   a. Placement of radial forearm fasciocutaneous free flap over the existent mandibular plate
   b. Placement of pectoralis major/rib osteomusculocutaneous flap
   c. Use of iliac crest bone graft with pectoralis major musculocutaneous flap
   d. Placement of pectoralis major musculocutaneous flap to cover the existent reconstruction plate
   e. Removal of the plate and pectoralis major musculocutaneous flap (mandibular swing)

171 Cervicofacial Transposition Flaps

Brittany Howard, Trevor Hackman

INTRODUCTION

Historically, regional flaps from the cervicofacial region have played a key role in the reconstruction of defects in the head and neck. A regional flap is a vascularized tissue flap that is pedicled on an axial blood supply and is not immediately adjacent to the defect area that requires reconstruction. Since the introduction of this technique in the 1960s, the possibility of reliably transposing large volumes of vascularized tissue for reconstruction has revolutionized our ability to resect disease and safely reconstruct defects in the head and neck. Although significant focus was placed on the role of free flaps for reconstruction during the 1980s and 1990s, recent years have brought a rebirth of interest and enthusiasm for the use of regional flaps.

The advantage of regional flaps is that they can provide diverse tissue options for reconstruction (fasciocutaneous, myofascial, musculocutaneous, and osseomusculocutaneous) with low donor-site morbidity. Additionally, operative times are typically lower than with free flap reconstructions because most regional flaps are adjacent to the primary surgical field, do not require repositioning, can be harvested rapidly, and do not require microvascular techniques. In today's age of increasing concern over health care costs, the association of regional flap reconstruction with decreased operative time and a shorter length of hospitalization as compared with free tissue transfer is an added benefit.

KEY OPERATIVE LEARNING POINTS

1. An ideal reconstruction provides a patient with the best outcome (in both function and form) with the lowest donor-site and overall morbidity.
2. Flaps can be characterized by their pattern of vascularity. Flaps from the cervicofacial region include both random-pattern vascular flaps (cervicofacial flaps) and axial vascular pattern flaps (cervicopectoral, supraclavicular, deltopectoral, and submental flaps).
3. A comprehensive understanding of regional anatomy allows for the use of multiple regional flaps to reconstruct defects in the head and neck.
4. Planning for the vascular pedicle and its final geometry are of key importance for flap viability and success in reconstruction.

PREOPERATIVE PERIOD

History

1. History of present illness
   a. The extent and complexity of the defect requiring reconstruction must be determined.
      1) Ideally defects should be reconstructed with like tissue. If a defect involves a loss of cutaneous tissue, it is ideally reconstructed with cutaneous tissue of similar color, thickness, and texture.
      2) Similarly, if the defect includes multiple tissue types such as epithelium and muscle, a flap including tissue of similar thickness and tissue type is ideally used for reconstruction.
   b. Current function and future functional needs should be elicited.
      1) Preoperative swallowing and breathing should be evaluated.
      2) Possible need for postoperative airway protection (tracheostomy) and nutritional support (nasogastric feeding tube) should be considered.
2. Past medical history
   a. Prior treatment in the head and neck region
      1) Prior head or neck surgery may affect the viability of regional reconstructive options.
      2) Prior radiation may affect postoperative healing and flap viability.
   b. Medical illnesses that may affect flap viability and reconstructive outcomes
      1) Diabetes, especially if poorly controlled, can affect healing outcomes and flap viability.
      2) Peripheral vascular disease may affect flap viability.
      3) Coagulopathies may affect postoperative bleeding or coagulation.
      4) Tobacco abuse/nicotine exposure is associated with arterial constriction and vascular insufficiency. It should be avoided in the perioperative period.
   c. Family medical history
      1) Coagulopathies can promote postoperative bleeding or coagulation and thus flap viability.
   d. Medications
      1) Consideration of risks/benefits to discontinuing any drugs that would increase the risk of bleeding. Development of a hematoma can threaten flap viability.

Physical Examination

1. Examination of the face
   a. The face should be carefully evaluated for any scars or evidence of prior surgical intervention, as this could disrupt blood flow for a cervicofacial advancement flap. The size of the defect should be measured to make sure that the planned flap is large enough to cover the defect.
2. Examination of the neck
   a. The neck should be carefully evaluated for any scars or evidence of prior surgical intervention that may affect blood flow.
   b. In planning a submental island flap, the amount of submental skin redundancy must be measured via the "pinch test," with the patient in mild neck extension to ensure adequate flap volume while sparing enough tissue for closure of the primary donor site without restricting head elevation.
3. Doppler examination
   a. A preoperative Doppler exam ination is required for the supraclavicular artery flap to identify and trace the vascular pedicle from the supraclavicular fossa over the clavicle and onto the deltoid region of the shoulder. This can be done either in the office or on the day of surgery.
   b. The site of Doppler signals should be marked with a marking pen to facilitate future identification.

Imaging

1. Computed tomography (CT) scan with contrast: Although not required for flap planning, this may be useful to evaluate the vascular system within the neck if prior surgery has been performed. It can help in surgical planning to establish that the vessels of the flap pedicle are intact.
2. CT angiography (CTA) or formal angiography: Although rarely needed, an angiogram may be useful if there is concern regarding the presence of the flap's pedicle vessels.

OPERATIVE PERIOD

Anesthesia

1. General anesthesia
   a. This is the most commonly used anesthetic approach because the flap is often harvested concurrently with tumor resection.
   b. General anesthesia is helpful in procedures that require dissection of the vascular pedicle, since this calls for meticulous care.
   c. Use of a paralytic is at the discretion of the surgeon depending on the nerves at risk.

Positioning

1. The patient is positioned supine.
2. Placement of a shoulder roll or extension of the neck away from the side of operation may be beneficial during early flap elevation.
   a. At the end of the surgery, if the closure is under tension, consider removing all rolls and rotating the patient back to neutral position to reduce tension and aid in primary closure.

Antibiotics

1. Their use depends on the defect to be reconstructed and the associated risk factors.

Monitoring

1. Monitoring of the facial nerve is recommended when its branches are at risk.

Instruments and Equipment to Have Available

1. Standard head and neck set
2. Bipolar cautery
3. Sterile Doppler
4. Spy fluorescent angiography—allows for the prediction of flap viability after harvesting

Operative Risks

1. Flap viability: Because of the random pattern of the flap, it is at increased risk for vascular insufficiency, especially at its distal and peripheral edges.
2. Bleeding: The development of a hematoma in the wound can compromise the flap's viability owing to compression of the pedicle.
   a. Meticulous hemostasis should be established at the time of closure.
   b. Suction drains should be placed whenever possible owing to the significant dead space created during flap elevation and risk of hematoma formation.
3. Injury to the cranial nerves
   a. Branches of the facial nerve are at risk most noticeably in raising of the cervicofacial and submental island flaps. Nerves should be identified and protected during primary flap elevation.
   b. The accessory nerve is at risk during elevation and rotation of the sternocleidomastoid muscle flap. It should be identified, dissected free of the muscle, and preserved during flap elevation/rotation.

CERVICOFACIAL FLAP

The cervicofacial flap is unique among the flaps discussed in this chapter as it is the only flap with a random blood supply; as such it is better categorized as a local flap rather than a regional one. However, given its importance in cervicofacial reconstruction, it is included in this discussion. The cervicofacial flap is a fasciocutaneous flap based off of a random blood supply; it encompasses tissue from the facial and cervical regions. Although it is commonly referred to as an advancement flap, it is more correctly classified as an arc rotation flap, as its movement for closure of the defect includes both advancement and rotation vectors.

PREOPERATIVE PERIOD

Indications

1. Defects of the cheek and lateral face
   a. Unmatched in its ease of harvest, ability to resurface large defects, good color match, and esthetic result with minimal donor-site morbidity
   b. Ideal for thin superficial defects

Contraindications

1. Vascular insufficiency of the flap owing to its size, base, or other factors
   a. The primary limitation of the flap is that, because of its random blood supply, it requires a large base for maximal vessel recruitment and vascularity may be compromised at its distal edges.
   b. Patients with prior radiation therapy, surgery, or significant peripheral vascular disease are more vulnerable to ischemic loss of the flap.
   c. Given the dependence of the flap on a microcirculatory network, it is strongly recommended to have the patient forego nicotine for a minimum of 2 weeks prior to surgery.
2. A patient who is unable to tolerate revision procedures
   a. Advancement and rotation of the flap can result in a temporary standing-cone deformity.
   b. If there is concern regarding the vascularity of the distal flap, the standing cone should be left and a revision surgery planned to remove the deformity once neovascularization from the wound edges into the flap has occurred.

OPERATIVE PERIOD

Surgical Technique

Flap Design

- The flap is designed beginning from the posterior edge of the facial defect requiring reconstruction.
- The superior limb of the flap extends posteriorly from the facial defect to the area of the mastoid tip. The incision is then dropped down the neck approximately 2 cm posterior to the anterior edge of the trapezius muscle; it then turns anteriorly in a natural skin crease in the neck at the level of the clavicle (Fig. 171.1).



Fig. 171.1. Cervicofacial flap design (A to D): Patient with a defect in the anterior right cheek after resection of a skin cancer. A, The posterior limb is carried horizontally to the preauricular region and then continued around the lobule in the postauricular tissue to increase the potential arc of rotation. The incision is then carried inferiorly to the clavicle. Horizontal skin creases in the lower neck are marked and the level of horizontal transition depends on the arc of rotation needed. **B,** Skin incisions are made along the preplanned lines, including a postauricular limb to increase the arc of rotation. **C,** The flap is elevated in a subcutaneous plane to allow for rotation and to avoid risk to the facial nerve. **D,** Final operative result: Drain is in place. The postauricular limb is excised, as is the "dog ear" deformity that arose anteroinferiorly.

- The size of the flap to be elevated is based on the size of defect to be resurfaced, calling for ongoing intraoperative assessment of the flap size and freedom of rotation needed to achieve a tension-free closure.

Flap Elevation (see Fig. 171.1)

- The flap is elevated in a subplatysmal plane in the cervical region.
- Elevation occurs in a supra-*Superficial muscular aponeurotic system* (SMAS) plane in the facial region.

Rotation and Advancement of the Flap Into the Defect (see Fig. 171.1)

- During rotation a standing-cone deformity is created at the base of the flap. If there is any concern for flap viability, this standing cone is left intact, to be addressed at a future staged procedure, as its removal can compromise the vascular supply to the distal portion of the flap.

Drain Placement

- Drains should almost always be placed, as development of a hematoma under the flap can impair its viability and the surgical outcome.
- Placement of a light compressive dressing should be considered to maintain good contact between the flap and the underlying wound bed (especially if no drain is placed).
- Appropriate design, inset, and drain placement allow for very acceptable long-term results (Fig. 171.2).

SUPRACLAVICULAR FLAP

A regional flap that has received significant attention in recent years for its applicability to head and neck reconstruction is the supraclavicular flap. It is an attractive option for reconstruction of defects in the head and neck, given its excellent color and texture match, favorable arc of rotation, ease of harvesting, and minimal donor-site morbidity.

PREOPERATIVE PERIOD

Indications

1. The supraclavicular flap is a thin fasciocutaneous flap whose skin color closely matches that of the head and neck.
2. The supraclavicular flap is ideally suited to resurfacing soft tissue defects of the neck, lateral skull base, floor of mouth, and lower face.
3. Reconstructive surgeons have recently expanded the applications of the supraclavicular flap and have compared it to the regional equivalent of the radial forearm free flap.
   a. Both the supraclavicular and radial forearm free flap provide thin, pliable fasciocutaneous vascularized flaps for reconstruction.
   b. The supraclavicular flap has been described for reconstruction of pharyngectomy defects,[1] as with the radial forearm free flap.
   c. In terms of viability, this flap has been directly compared with free flaps for the reconstruction of hemiglossectomies[2] and lateral skull base defects.[3]

Contraindications

1. Caution must be exercised when the flap is being considered as a reconstruction option in patients who have previously undergone neck surgery, particularly level 4, and supraclavicular fossa neck dissection, as the supraclavicular perforator off the transverse cervical artery may be absent, resulting in a nonviable random flap.

OPERATIVE PERIOD

Key Anatomic Landmarks

- Supraclavicular triangle
  - The cutaneous perforator of the supraclavicular artery is identified within the supraclavicular triangle.
  - The supraclavicular triangle is defined posteriorly by the anterior border of the trapezius, the posterior border of the sternocleidomastoid muscle, and inferiorly by the clavicle.



Fig. 171.2. Final aesthetic outcome after reconstruction of a facial defect with a cervicofacial rotation advancement flap. Note excellent match of skin color and texture.

Surgical Technique

1. The supraclavicular flap is designed as an elongated ellipse over the supraclavicular region extending inferiorly to the deltoid tip. A flap width of 6 to 8 cm typically allows for primary closure of the donor site.
   a. Wider flaps (10 to 16 cm) can be harvested with reliable viability if needed for defect reconstruction, but primary closure cannot typically be achieved for these donor sites, so that secondary skin grafting will be necessary.
2. From its base at the supraclavicular triangle, the flap can be extended laterally over the shoulder for lengths up to 26 cm; when the flap is extended onto and beyond the deltoid tip, the vascular supply will have a random pattern.
   a. As a rule, the flap should not be extended more than 5 cm beyond the last audible Doppler signal (Fig. 171.3).
3. The cutaneous perforator of the supraclavicular artery is identified within the supraclavicular triangle and is the fulcrum around which the flap can be rotated.
4. The flap is elevated working distal to proximal along the flap in the subfascial plane. The flap can be designed so that it is maintained with a cutaneous base or as an island perforator flap to maximize the arc of rotation.
   a. Care should be taken to avoid injuring the cephalic vein on the flap's ventral surface.
   b. While cautery may be used to elevate the distal aspect of the flap, sharp dissection is recommended to release the flap off the fibrous attachments to the clavicle and trapezius muscle.
5. For the majority of supraclavicular flaps, the donor site can be closed primarily after appropriate undermining of the surrounding soft tissue.
6. Placement of a drain is recommended.

SUBMENTAL ISLAND FLAP

The submental flap is a versatile regional flap that can be designed as a fasciocutaneous, musculocutaneous, myofascial, or osseomusculocutaneous flap. Its utility for reconstructing defects in the head and neck has drawn significant interest in recent years. The submental island flap is a central perforator flap that can be based on either or both of the submental vessels.

PREOPERATIVE PERIOD

Indications

1. Because of its unparalleled color and texture match to facial skin, the submental island flap provides an excellent option for the reconstruction of facial defects.
   a. The ability to include a muscular component with the flap makes it superior to the cervicofacial flap in reconstructing facial defects where additional bulk is desired to correct potential deficiencies of contour.
2. Oral cavity, oropharynx and laryngectomy defects
3. Lateral skull base defects
4. Anterior skull base and orbital defects
5. This is a bipedicled flap that has a maximally robust vascular supply and may be appropriate for the reconstruction of midline defects (anterior floor of mouth, larynx, pharynx).
   a. However, its lateral reach is limited by the bilateral nature of its pedicle.
6. A unilateral pedicle is ideal for the reconstruction of lateral defects; the pedicle's average length is 8 cm, reliably allowing reach from the level of the zygoma superiorly to the level of the clavicle inferiorly.
   a. Based upon a unilateral vascular pedicle, a large flap paddle can be raised with reliable viability of the entire cutaneous component.
   b. The cutaneous component of the flap can extend from the ipsilateral angle of the mandible to the opposite mandibular angle and from the mandible superiorly to below the level of the hyoid (as large as 17 cm × 9 cm).

Contraindications

1. Prior neck surgery may have damaged the vascular supply to the flap and thus have impaired its viability. Submental artery and vein perforators to the overlying cutaneous component are typically divided in a standard neck dissection exposure.
2. Patients with bulky level 1b cervical metastasis and/or potential extracapsular extension as the submental vessels transverse this location

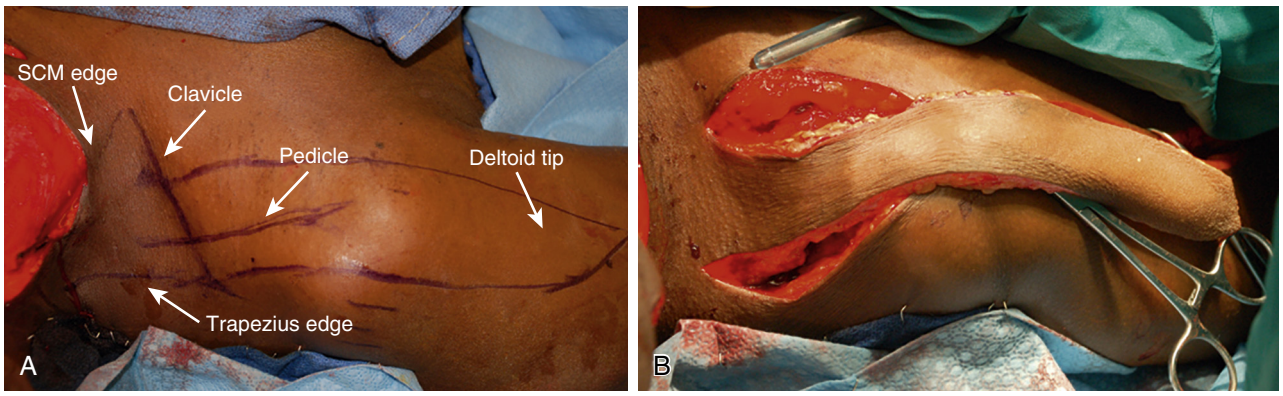

Fig. 171.3. Supraclavicular artery flap (A and B): Right supraclavicular flap raised to reconstruct a defect in the floor of the mouth. A, The vascular pedicle has been mapped with Doppler ultrasonography from the triangle created by the posterior edge of the sternocleidomastoid muscle (SCM), the clavicle, and the anterior edge of the trapezius muscle over the shoudler to the deltoid tip. The flap incisions are planned around this axial pedicle with the distal aspect of the flap overlying the deltoid tip. **B,** The flap has been raised fully and the remnant lateral skin edges of the arm have been approximated with piercing towel clamps in anticipation of primary closure.

OPERATIVE PERIOD

Key Anatomic Landmarks

1. The submental artery originates from the facial artery deep to or within the submandibular gland. It courses over the superior aspect of the submandibular gland anteriorly on the superficial surface of the mylohyoid muscle and sends up cutaneous perforator branches that traverse both medially and laterally to the anterior belly of the digastric muscle.
2. The submental vein or veins provide the venous drainage for the flap but have a notably more variable course. The submental vein may be a terminal branch of the facial vein or, less commonly, may originate from the external jugular system. This variable venous anatomy becomes highly important during flap harvesting and elevation, as the accidental loss of veins during initial exposure can compromise the vascular integrity of the final flap.

Surgical Technique

1. Surgery begins with planning of the flap design (Fig. 171.4).
   a. The size and complexity of the defect requiring reconstruction are then considered, as is the extent of inclusion of muscle within the flap.
   b. Although the flap can be raised as a fasciocutaneous flap, inclusion of the ipsilateral mylohyoid and the anterior belly of the digastric muscle simplifies the dissection and provides added protection of the vascular pedicle coursing along the superficial surface of the mylohyoid.
   c. If additional bulk is advantageous, the contralateral mylohyoid and anterior belly of the digastric muscle can also be included. An osseomusculocutaneous flap can be designed with inclusion of the inferior aspect of the mandibular mentum with the flap.
      1) This is based upon bony perforators near the midline of the flap and can be especially useful in the reconstruction of the maxilla where small bony defects exist.
2. The dominant cutaneous perforators are first identified with a Doppler near the insertion of the anterior digastric muscles on the mandible.
3. The superior incision is planned so that it overlies the inferior edge of the body of the mandible; placing this incision too far below the level of the mandible will put the perforating vessels at risk.
4. The superior incision is drawn laterally just below the level of the mandible to the desired lateral limit (can extend angle to angle).
5. A pinch test is used to determine the vertical height of the skin paddle that can be harvested and still allow primary closure; this inferior extent is then marked.
6. The medial superior incision is opened first, carrying the incision onto the mandible at the midline.
7. The flap is dissected away from the mandible with a Cottle elevator in a subperiosteal plane and the anterior belly (or both anterior bellies depending upon the defect) of the digastric muscle is/are released from the mandible.
8. The skin incision is then opened on the ipsilateral side of the vascular pedicle to the lateral extent of dissection and to the depth of the platysma muscle.
9. The posterior platysma muscle is then carefully divided to expose the submandibular gland.
10. The marginal mandibular nerve is identified overlying the facial vessels and the submandibular gland. With the operator maintaining a view of the marginal mandibular nerve at all times, the intervening platysma muscle is divided superiorly to connect the anterior and posterior portions of the dissection, protecting and preserving the underlying marginal mandibular nerve.
11. With the superior incision complete on the ipsilateral side, the marginal mandibular nerve is then mobilized off the underlying fascia of the submandibular gland and swept upward out of the field of dissection for the remainder of the procedure.
12. The vascular pedicle is next identified at the deep posterior aspect of the submandibular gland.
    a. The venous system is always superficial and lateral to the arterial supply, and venous drainage can be rapidly identified to be either coursing into a common facial vein or less commonly into the external jugular vein.
13. The venous and arterial pedicles are then traced through the gland, dividing the perforators going to the gland. Care is taken to preserve a broad fascial cuff from the pedicle to the skin, through which the skin perforators travel.
14. The submandibular gland may be preserved or removed. If it is removed, the gland is dissected free of its surrounding structures, including the hypoglossal nerve and the lingual nerve. The submandibular duct is identified and divided, and the submandibular gland is removed.
15. The vascular pedicle can now be traced over the superficial surface of the mylohyoid muscle; in cancer resections, all associated lymph nodes and adipose tissue are removed.
    a. If comprehensive dissection of level I lymph nodes is not required, the adipose tissue can be left surrounding the pedicle and dissection does not have to extend onto the superficial surface of the mylohyoid muscle.
    b. When the mylohyoid muscle is to be included in the flap for added bulk and pedicle protection, it is released off the mylohyoid line along the mandible superiorly and off the hyoid bone inferiorly.
16. The final inferior attachment of the anterior belly of the digastric muscle to the hyoid bone is then released.
17. Final flap elevation then proceeds by freeing the contralateral side.
18. If significant muscle bulk is not needed, the contralateral cutaneous flap can be elevated in a supraplatysmal plane.
    a. This protects all neurovascular structures on the contralateral side including the marginal mandibular nerve.
19. If greater muscle bulk is desired, the contralateral platysmal muscle can be included, as can the contralateral mylohyoid and anterior belly of the digastric muscle.
20. The flap is now fully free and can be inset for reconstruction (see Fig. 171.4).
    a. To increase perfusion pressure to the flap, the facial artery distal to the takeoff of the submental artery is ligated and divided.
21. Drains should be placed in the submental region owing to the high rate of seroma formation.

Common Errors in Technique

1. If a submental flap is desired for reconstruction when concurrent neck dissections are to be performed, the flap is raised first to make sure that the vascular supply to the flap is identified and preserved.
2. Thinning of the underlying fascia between the pedicle and the overlying skin will compromise the skin perforators, particularly those overlying the digastric muscle.

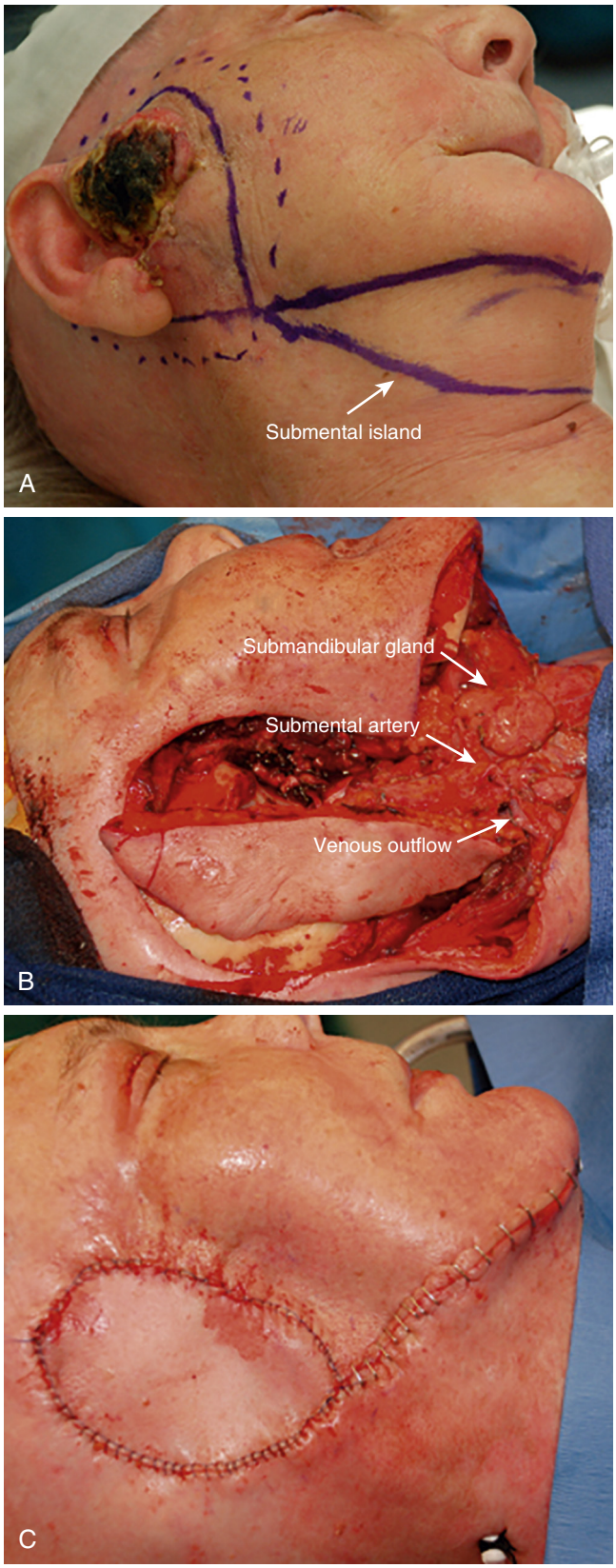

Fig. 171.4. Submental artery flap (A to C): A lateral temporal bone defect is slated for resection and submental island flap reconstruction. A, The patient's primary malignancy is drawn on the skin. An ipsilateral submental island flap is drawn, with the superior incision along the inferior border of the mandible. **B,** The elliptical skin paddle has been elevated on the posterior vascular pedicle of the facial system and has been rotated into the defect. **C,** The flap has been inset and the flap harvest site is closed primarily along the inferior border of the mandible.

POSTOPERATIVE PERIOD FOR FLAPS

Postoperative Management

1. Flap monitoring
   a. For pedicled flaps, the need for close flap monitoring is debatable, as pedicle compromise is unlikely.
   b. Frequency and need are at the surgeon's discretion.
      1) Typical flap monitoring can include monitoring with Doppler signal, capillary refill, color, and warmth.
2. Drains
   a. Drains should be remain in place until output has decreased significantly (<30 mL per 24 hours or less) and the content is clear.
3. No limitations on postoperative activity
4. Pain medication as needed

Complications

1. Flap viability can be compromised by multiple factors; therefore early identification is important to increase the chances of salvage.
   a. Arterial compromise
      1) Most commonly secondary to arterial compression from poor vessel geometry, pedicle stretch, or hematoma
      2) Typically requires return to the operating room for exploration of the vascular pedicle and to see whether arterial flow can be reestablished
   b. Venous compromise, more common than arterial compromise
      1) Most commonly secondary to venous kinking or compression from vascular pedicle geometry or hematoma
      2) Requires return to the operating room for exploration of the vascular pedicle and to see whether venous flow can be reestablished
      3) If venous flow cannot be reestablished, the flap may be salvaged by the use of leeches and heparin scrub to provide venous outflow from the flap.
   c. Infection
      1) Usually a delayed source of flap compromise (>5 days postoperatively). Typically secondary to salivary leak. "Nothing by mouth" (NPO) status and good oral care may help to prevent this complication.
   d. Poor microcirculation
      1) Patients who are obese and those with diabetes, peripheral vascular disease, or prior radiation therapy constitute the population most at risk.
2. Hematoma
   a. Rapid identification and evacuation are imperative to prevent compromise of the vascular pedicle secondary to compression. As part of the exploration of the hematoma, the establishment of hemostasis is imperative.
3. Seroma
   a. May occur postoperatively, especially in cases with significant dead space
   b. Can typically be managed in the office with repeat needle aspiration.
   c. Failure to identify and evacuate a seroma may lead to infection and potential flap loss.

Alternative Management Plan

1. Healing by secondary intention
2. Skin graft reconstruction
3. Alternative regional flap reconstructions (pectoralis major flap, latissimus dorsi flap, etc.)
   a. See Chapters 174 and 176A.

4. Free flap reconstruction
   a. May be associated with increased operative times
   b. May be an appropriate choice for larger and more complex defects
   c. Allows for more versatility in reconstruction

DISCUSSION

Evidence-Based Medicine Question

How does the use of the submental flap for the reconstruction of head and neck defects compare with the reconstruction of similar defects using free flaps?

Recent studies have compared the submental flap with radial forearm and anterolateral thigh free flaps for the reconstruction of glossectomy defects and lateral skull base defects.[4,5] Findings were that reconstruction with the regional submental flap resulted in reduced operative time and length of hospitalization compared with free flap reconstruction without any difference in functional outcomes or flap viability rates.

Editorial Comment

The cervicofacial flap, submental island flap, and supraclavicular flap are very versatile flaps for reconstructing defects of the face, oral cavity, pharynx, and lateral skull base. These flaps are relatively easy to harvest and are reliable. The color match is excellent for the face and neck. The flaps are very useful in patients whose necks are depleted of recipient vessels and whose comorbidities may not allow prolonged anesthesia; that is, they serve well when time is of the essence.

Anna Pou

Access the review questions online at http://www.expertconsult.com



REFERENCES

1. Sethi RK, Kozin ED, Lam AC, et al. Primary tracheoesophageal puncture with supraclavicular artery island flap after total laryngectomy or laryngopharyngectomy. *Otolaryngol Head Neck Surg* 2014;151(3):421–423.
2. Zhang S, Chen W, Cao G, et al. Pedicled supraclavicular artery island flap versus free radial forearm flap for tongue reconstruction following hemiglossectomy. *J Craniofac Surg* 2015;26:e527–e530.
3. Hunt JP, Buchmann LO. The supraclavicular artery flap for lateral skull and scalp defects: effective and efficient alternative to free tissue transfer. *J Neurol Surg Rep* 2014;75:e5–e10.
4. Paydarfar JA, Patel UA. Submental island pedicled flap vs radial forearm free flap for oral reconstruction: comparison of outcomes. *Arch Otolaryngol Head Neck Surg* 2011;137:82–87.
5. Howard BE, Hayden RE, Barrs DM, et al. Lateral skull base reconstruction: a comparison of the submental flap to free and regional flaps. *Otolaryngol Head Neck Surg* 2016 Jun;154(6):1014–1018.

REVIEW QUESTIONS

1. Landmarks for the supraclavicular triangle include all of the following except the
   a. Anterior border of the trapezius
   b. Posterior border of the sternocleidomastoid muscle
   c. Anterior border of the sternocleidomastoid muscle
   d. Superior edge of the clavicle

2. The vascular supply to the superiorly based sternocleidomastoid flap is the
   a. Branch of the occipital artery
   b. Branch of the superior thyroid artery
   c. Branch of the suprascapular artery
   d. Branch of the transverse cervical artery

3. The vascular pedicle to the submental flap courses deep to the mylohyoid muscle.
   a. True
   b. False

172 Trapezius and Latissimus Dorsi Regional Flaps

Brittany Howard, Trevor Hackman

INTRODUCTION

Regional pedicle flaps for reconstruction of the head and neck are most commonly harvested from ventral body surfaces due to the favorable patient positioning, location close to the primary defect, and familiar anatomy. Flaps from the dorsal body surface are advantageous because they can provide significant tissue bulk for reconstruction and a multitude of tissue types including cutaneous, muscular, and osseous options. Additionally, in patients who have undergone prior head and neck surgery, the vascularity of these flaps is often preserved compared to flaps from the ventral surface. The most common dorsal surface pedicled flaps used for head and neck reconstruction are the trapezius and latissimus dorsi flaps.

KEY OPERATIVE LEARNING POINTS

1. Regional flaps from the dorsal surface can provide excellent reconstructive options for the head and neck region because they can provide large volumes of soft tissue and a variety of tissue types.
2. The latissimus dorsi regional flap is a reconstructive option for patients who have undergone prior neck surgery because its blood supply is from the subscapular system not from the neck.
3. The main cause of regional flap vascular compromise is poor pedicle geometry. Thus, flap planning and final inset should take this into consideration and ensure that the vascular pedicle lies easily without kinking, compression, or tension.

PREOPERATIVE PERIOD

History

1. History of present illness:
   a. The cause of the defect should be determined because it can affect current and future reconstructive needs.
      1) In defects secondary to benign or malignant tumors, the risk of recurrence and possible need for future reconstruction should be considered. Donor sites that do not limit future reconstructive options are preferred (a supraclavicular flap may compromise future use of a lateral trapezius flap, because both are based on branches of the transverse cervical artery).
      2) In defects secondary to traumatic injury, the needs of immediate coverage must be weighed against goals of ultimate reconstruction. For example, a pedicled flap reconstruction may provide the most rapid/immediate solution for traumatic defect coverage. However, if a free flap would provide the best long-term results, a free flap may be the preferred reconstructive option despite the added time and complexity associated with this form of reconstruction.
   b. The extent and complexity of the defect requiring reconstruction should be determined.
      1) Reconstruction ideally replaces lost tissue with tissue of similar texture, thickness, and type. Thus, cutaneous tissue defects are ideally reconstructed with cutaneous tissue of similar color, thickness, and texture.
      2) A composite defect involving multiple tissue types is ideally reconstructed with equivalent tissue. Thus muscle is replaced with muscle, and bone is replaced with bone. Finding donor tissue matching the needs of the defect may guide a surgeon's decision when choosing between a regional flap and a free flap.
   c. Current function and future functional needs should be elicited.
      1) Preoperative swallowing and breathing should be evaluated.
      2) Possible need for postoperative airway protection (tracheostomy) and nutritional support (nasogastric or gastric feeding tube) should be considered.
2. Past medical history
   a. Prior treatment in the head and neck region:
      1) History of surgery in the neck, axilla, and back may affect viability of regional reconstructive options.
      2) Prior radiation may affect postoperative healing and flap viability.
   b. Medical illnesses may affect flap viability and reconstructive outcomes:
      1) Diabetes, especially if poorly controlled, can effect healing outcomes and flap viability.
      2) Peripheral vascular disease may affect flap viability.
      3) Coagulopathies may affect postoperative bleeding or coagulation.
      4) Tobacco abuse/nicotine exposure is associated with arterial constriction and vascular insufficiency. This should be avoided in the perioperative period.
   c. Family medical history:
      1) Coagulopathies may affect postoperative bleeding or coagulation and thus flap viability.
   d. Medications:
      1) Consider the risks and benefits of discontinuing any drugs that may increase the perioperative risk of bleeding. A hematoma in the postoperative period can affect flap viability.

Physical Examination

1. Neck examination
   a. The neck should be carefully evaluated for any scars or evidence of prior surgical intervention that the patient may have forgotten to mention during collection of the history of the present illness or past medical history.
2. Extremity examination
   a. The axilla and extremity on the side considered for flap harvest should be carefully inspected for any evidence of scars suggesting prior surgery.
   b. The range of motion and strength of the extremity on the side selected for flap harvest should be carefully evaluated and documented preoperatively.
3. Doppler examination
   a. A Doppler examination to identify and trace the vascular pedicle should be performed prior to proceeding with surgery. This can be done in the office or on the day of surgery.
   b. The site of Doppler signals should be marked with a marking pen to facilitate future identification.

Imaging

1. No dedicated imaging of the neck, axilla, or back is required prior to planning or harvesting trapezius or latissimus dorsi flaps.

Preoperative Preparation

1. The side to be used for flap harvest should have the upper extremity marked "No Lines and No IVs" in the preoperative area. This extremity will be prepped into the surgical field.
2. Discontinue any medications that increase the risk of bleeding if medically safe.

OPERATIVE PERIOD

Anesthesia

1. General anesthesia:
   a. Due to the extent of dissection and positioning needs of the surgery, general anesthesia is necessary for the procedure.
   b. Use of a paralytic agent is at the discretion of the surgeon. Some surgeons prefer paralysis during dissection because it relaxes muscles and makes manipulation easier. Others prefer no paralysis to aid in identification of motor nerves during dissection.

Positioning

1. Lateral decubitus
   a. Facilitates exposure of the back to the midline
   b. Requires placement of the axillary roll and careful positioning to prevent injury of the brachial plexus
2. Modified lateral decubitus
   a. Adequate exposure can be accomplished with placement of a bump or bean bag. There is less exposure of the back compared to a true lateral decubitus positioning.
   b. Does not require placement of an axillary roll
3. Prone
   a. Prone positioning may be preferred if trapezius or latissimus dorsi flaps are used to reconstruct the posterior neck or occipital defects.

Perioperative Antibiotic Prophylaxis

1. As indicated by the primary defect undergoing reconstruction

Monitoring

1. None necessary

Instruments and Equipment to Have Available

1. Handheld Doppler
2. Monopolar and bipolar cautery
3. Axillary roll
4. Bean bag

Operative Risks

1. Bleeding: Development of a hematoma must be carefully monitored because it can cause compression of the vascular pedicle and result in flap compromise.
2. Infection: Infection at the flap donor site is a relatively low risk, but the area may be contaminated by the defect undergoing reconstruction (especially in cases involving oral or oropharyngeal defects). Antibiotics should be chosen based on the primary site defect and associated risk of infection.
3. Scarring/cosmetic defect: It may be impossible to close donor sites primarily, and they may require split-thickness skin grafting. When split-thickness skin grafting is used, a less aesthetic donor site appearance will generally result, and a second donor site is created where the graft is harvested.
4. Flap loss: A significant risk in any flap reconstruction surgery is that of partial or total flap loss. In pedicled flaps, the most common cause of total flap loss is poor pedicle geometry with pedicle compression within a tunnel, kinking, or tension at time of inset. Care must be taken to avoid these situations. Partial flap loss may be due to numerous factors including the patient's peripheral vascular disease, perioperative hypo- or hypertension, rough handling of the tissue, and excess flap size resulting in random-pattern blood supply to distal flap tissues.
5. Damage to surrounding structures: During flap harvest and inset involving the trapezius flaps and latissimus dorsi flaps, there are multiple neurovascular structures at risk. The structures at risk include the brachial plexus and the accessory nerve. Damage to the brachial plexus can affect function of the shoulder and upper extremity. Damage to the accessory nerve or destabilization of key trapezius muscular insertions can result in shoulder droop and weakness.

TRAPEZIUS FLAPS

Introduction

The trapezius muscle is a triangular muscle that extends from the occipital skull base, along the spine, to the level of the 10th thoracic vertebrae. It has insertions onto the lateral third of the clavicle, the spine of the scapula, and the acromion. The trapezius muscle is associated with three separate musculocutaneous flaps based on three separate vascular pedicles. These include the superior trapezius flap, the lateral trapezius flap, and the inferior trapezius flap. Because each of these flaps is based upon a unique vascular pedicle, they are considered, designed, and surgically elevated separately.

Superior Trapezius Flap

The superior trapezius musculocutaneous flap is based upon vascular contributions from the paraspinous muscular perforators and from branches of the occipital artery.[1] This flap requires a broad superior base to provide sufficient vascular supply and as such has a limited arc of rotation.[1] Although its limited arc of rotation decreases its applicability, it has the most reliable vascular supply of the trapezius flaps.[1]

PREOPERATIVE PERIOD

Indications

1. Lateral neck defects. Due to the limited arc of rotation, this flap can only reach the lateral neck for defect reconstruction and hence has been supplanted by newer reconstructive options (i.e., supraclavicular flap).

Contraindications

1. Prior neck surgery that may have damaged the vascular supply from the occipital artery. However, the flap may be viable from paraspinous perforators.
2. Anticipated poor wound healing because the donor site often cannot be closed primarily and must be left to heal by secondary intention or with skin grafting

OPERATIVE PERIOD

Surgical Technique

1. The flap is designed by incorporating the skin overlying the trapezius muscle with a superior and medial base.
2. The superior/anterior incision is placed along the anterior edge of the trapezius muscle.
3. The inferior incision is designed parallel to the anterior incision at the level of the scapular spine.
4. The lateral extent of the flap is designed at or beyond the level of the acromion.
5. The incisions are opened and the flap is elevated in a lateral-to-medial direction.
6. Laterally the flap is elevated in a plane deep to the deltoid fascia.
7. Once the acromion is reached, the trapezius is elevated sharply off its bony insertions.
8. The flap is lifted off the supraspinatus muscle deep to the muscular fascia.
9. The flap can now be rotated and inset for reconstruction of the defect.
10. The donor site is closed primarily or skin grafted.
11. The transverse cervical vessels are commonly identified during this portion of the procedure and should be divided.

Common Errors in Technique

1. Division of the transverse cervical vascular pedicle aids in elevation of the flap and improves the arc of rotation.
2. A back-cut at the lower incision beyond the midline increases the arc of rotation of the flap.

Lateral Trapezius Flap

The lateral trapezius is based upon the transverse cervical artery. Similar to the superior trapezius flap, it is designed overlying the superior portion of the trapezius muscle. Compared to the superior trapezius flap, the lateral trapezius flap has improved applicability because it allows harvest of a larger musculocutaneous paddle, has a better arc of rotation for head and neck defects, and the donor site can often be closed primarily. Additionally, the lateral trapezius flap can be harvested as an osseomusculocutaneous flap with incorporation of vascularized spine of the scapula.

PREOPERATIVE PERIOD

Indications

1. Reconstruction of soft tissue defects of the lateral neck, lateral skull base, oral cavity, and oropharynx
2. Reconstruction of composite defects of the lateral mandible (as an osseomusculocutaneous flap)

Contraindications

1. Prior neck surgery that may have injured or divided the transverse cervical vascular pedicle

OPERATIVE PERIOD

Key Anatomic Landmarks

1. The origin of the transverse cervical artery is variable, and it can arise from the thyrocervical trunk, suprascapular artery, subclavian artery, or dorsal scapular artery.

Surgical Technique

1. The flap is centered on the transverse cervical artery. The long axis of the flap is designed between the vertebral column and the medial scapula edge. Typical flap size is 6 to 8 cm wide by 30 to 38 cm long. The inferior end of the flap can extend up to 13 cm distal to the trapezius muscle. A flap that extends past the trapezius muscle edge has a random-pattern blood supply.
2. Flap elevation begins with identification of the transverse cervical vascular pedicle in the neck. Once identified, the pedicle is traced to its entrance into the trapezius muscle. This ensures that the pedicle is preserved and not accidently divided during flap elevation.
3. The medial incision is then made down to the level of the trapezius muscle fibers. The trapezius muscle is then divided at the medial edge of the flap.
4. The muscle is elevated from medial to lateral identifying the previously preserved transverse cervical vascular pedicle on the undersurface of the muscle, deep to the fascia.
5. The lateral incision can then be opened through the muscular layer, again preserving the vascular pedicle.
6. The flap is elevated off of the deep tissues (latissimus and rhomboid muscles) working from inferior to superior. During this dissection, the dorsal scapular artery will be encountered as it pierces between the rhomboids and must be divided to allow flap elevation and rotation.
7. The flap can then be rotated and inset for reconstruction of the defect.
8. The donor site is closed primarily, and suction drains are placed.

Common Errors in Technique

1. If primary closure of the donor site is desired, the flap should not exceed 8 cm in width.
2. The spine of the scapula should be the superior extent of the dissection to preserve the lateral attachment of the trapezius to the scapular spine and acromion. Shoulder function is preserved by maintaining these attachments. Dissection superior to this line can result in shoulder droop and weakness.
3. Anatomic variations have been described in which the transverse cervical vascular pedicle passes through portions of the brachial plexus. Flap harvest should not be pursued in these cases.

Lower Trapezius Flap

The inferior or lower trapezius musculocutaneous flap is based upon the dorsal scapular vascular pedicle. This is commonly considered the most versatile of the trapezius flaps because its long vascular pedicle from the dorsal scapular artery allows for a wider arc of rotation and reach.[2-5] Additionally, the lower trapezius flap is advantageous because the distal skin paddle is thin and pliable when compared to the other trapezius flaps.

PREOPERATIVE PERIOD

Indications

1. Reconstruction of defects of the face, scalp, lateral skull base, neck, oral cavity, and oropharynx

Contraindications

1. Prior neck dissection resulting in disruption of the vascular supply to the dorsal scapular vascular pedicle (which can be a branch of the transverse cervical artery)

OPERATIVE PERIOD

Key Anatomic Landmarks

1. The dorsal scapular artery originates from the transverse cervical artery or as a separate branch from the subclavian artery.
2. The dorsal scapular artery courses deep to the levator scapulae muscle. Its main branch to the lower trapezius flap penetrates between the rhomboid muscles. The vascular pedicle then runs inferiorly along the deep surface of the trapezius to supply the lower third of the trapezius muscle and the overlying skin.
3. Anatomic landmarks that should be marked at the beginning of the case include the margins of the trapezius muscle, the medial border of the scapula, and the thoracic spine with demarcation of the 12th vertebrae.

Surgical Technique

1. The flap is designed such that at least one-third of the skin island overlies the trapezius muscle. There is a greater density of perforating vessels medially near the thoracic spine compared to laterally (Fig. 172.1A).
2. The inferior extent of the flap should not exceed 10 cm distal to the inferior edge of the scapula. The cutaneous flap component that is not centered over the muscle is perfused by a random-pattern blood supply and is at greater risk of vascular insufficiency.
3. The medial incision is made first to the level of the trapezius muscle. The trapezius muscle is then divided, being careful not to injure the underlying latissimus dorsi muscle.
4. The dissection plane between the trapezius muscle and the latissimus dorsi muscle is then developed working from inferior-medial to superior-lateral.
5. During this dissection the course of the dorsal scapular artery can be seen as it descends along the deep surface of the trapezius muscle within the fascia layer.
6. With the vascular pedicle protected, the lateral flap incisions can be made to free the island flap.
7. The superior apex of the flap incision is then extended superiorly, along the medial border of the scapula.
8. The vascular pedicle is traced, dividing the overlying trapezius muscle fibers to free the pedicle and increase its pedicle length.
9. The pedicle is traced until it is seen diving between the bellies of the rhomboid muscles.
10. At this point the flap can be rotated and inset for reconstruction of the defect, suction drains are placed and the donor site is closed primarily. (see Fig. 172.1B).

Common Errors in Technique

1. If the arc of rotation is insufficient to allow inset, the minor rhomboid muscle can be divided to improve the arc of rotation.

LATISSIMUS DORSI FLAP

Introduction

The latissimus dorsi flap was the first regional musculocutaneous flap described. The latissimus dorsi muscle is a long, broad, and flat muscle that originates from the aponeurosis joining the posterior layer of the thoracolumbar fascia from about the sixth thoracic vertebra to the posterior iliac crest. The muscle then inserts into the intertubercular groove of the humerus. The reconstructive strength of the latissimus dorsi flap lies in the fact that it provides the largest volume of soft tissue and the greatest arc of rotation of any regional flap available to the head and neck surgeon. This versatile and reliable flap can include the entire latissimus dorsi muscle and its overlying cutaneous component, based upon musculocutaneous perforators.[6-8] When designed for reconstruction of head and facial defects, the latissimus dorsi flap is based on the thoracodorsal artery. This flap can also be harvested as a free tissue transfer and combined with other flaps in the subscapular system (scapula tip, scapular and parascapular flaps) for chimeric designs.

PREOPERATIVE PERIOD

Indications

1. Reconstruction of lateral neck defects, oral defects, oropharyngeal defects, and lateral and posterior skull base or scalp defects

Contraindications

1. Inability to position in lateral or modified lateral decubitus position
2. Contralateral or midline defects (this limitation can be overcome by using the latissimus dorsi flap as a free flap)

OPERATIVE PERIOD

Key Anatomic Landmarks

1. The thoracodorsal artery and vein form the vascular pedicle to the latissimus dorsi flap

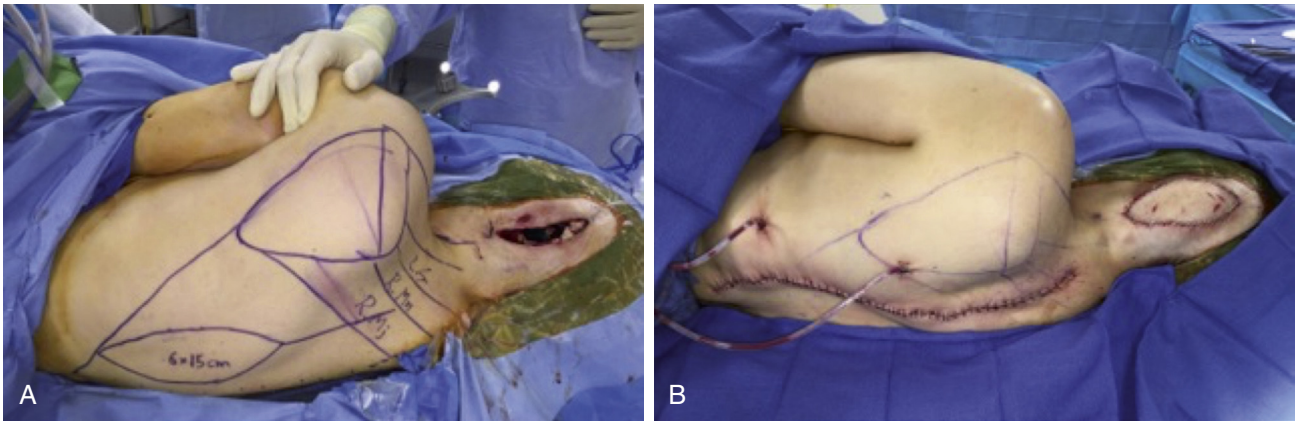

Fig. 172.1. Lower island trapezius flap; design and closure. ***A,*** Pre operative flap incision planning ***B,*** Donor site closure after flap harvest. *(Courtesy of Jason Rich.)*

   a. The thoracodorsal vessels typically originate from the subscapular vessels separate from the circumflex scapular vessels (Fig. 172.2A).
   b. The thoracodorsal pedicle enters the latissimus dorsi muscle 8 to 12 cm proximal to the humeral attachment of the muscle.
   c. After entering the muscle, the pedicle divides into two primary branches that parallel the superior and anterior edge of the muscle.
   d. The majority of cutaneous perforating vessels occur along the anterior edge of the muscle in the upper two-thirds.
2. The thoracodorsal nerve innervates the latissimus dorsi. Its course runs parallel to, and often intertwines with, the vascular pedicle.

Surgical Technique

1. Once positioned, the lateral edge of the latissimus is palpated and marked.
2. If a cutaneous component is to be harvested, it is designed as an ellipse or otter tail overlying the latissimus muscle. It is designed with its long axis parallel to the lateral muscle edge and located such that it captures the greatest density of perforators, which occur at the lateral, superior aspect of the muscle.
3. The arc of rotation is checked to ensure that the flap will reach the defect prior to placement of incisions.
4. Incisions are then made along the lateral edge and into the axilla. Dissection is carried down to the level of the latissimus muscle, and the anterior/lateral edge of the muscle is exposed along its full length.
5. The anterior skin flap is then elevated and undermined to expose the serratus muscle. This increases exposure and aids in future closure of the donor site.
6. With the lateral edge of the latissimus fully exposed, the thoracodorsal pedicle is identified by blunt dissection along the lateral edge of the latissimus muscle.
7. The pedicle is then traced to its origin from the subscapular system (see Fig. 172.2A). Vascular branches to the serratus and teres major muscle are identified and ligated. Dissection of the vascular pedicle is aided by manipulation of the upper extremity by the surgical assistant to aid in exposure.
   a. Various chimeric flaps can be created by incorporating the serratus anterior and fifth or sixth rib, the scapular system (skin and lateral bone border of the scapula) based on the circumflex scapula system, or the scapula tip (bone, muscle) based on the angular artery into the harvest.
8. The thoracodorsal nerve is identified and divided to aid in muscular atrophy and to prevent future accidental vascular compression by muscular activity.
9. The flap is then elevated in a distal-to-proximal direction. Distal division of the latissimus muscle is performed to allow adequate tissue to reach the defect to be reconstructed in a tension-free fashion.
10. Once the distal muscle is freed, the medial cutaneous incisions can be safely made, and the medial skin flap can be elevated to allow increased medial exposure.
11. Medial incisions through the latissimus muscle are made, and the flap is elevated off the underlying teres major muscle. Care is taken to divide and ligate any perforating vessels between the muscle bellies.

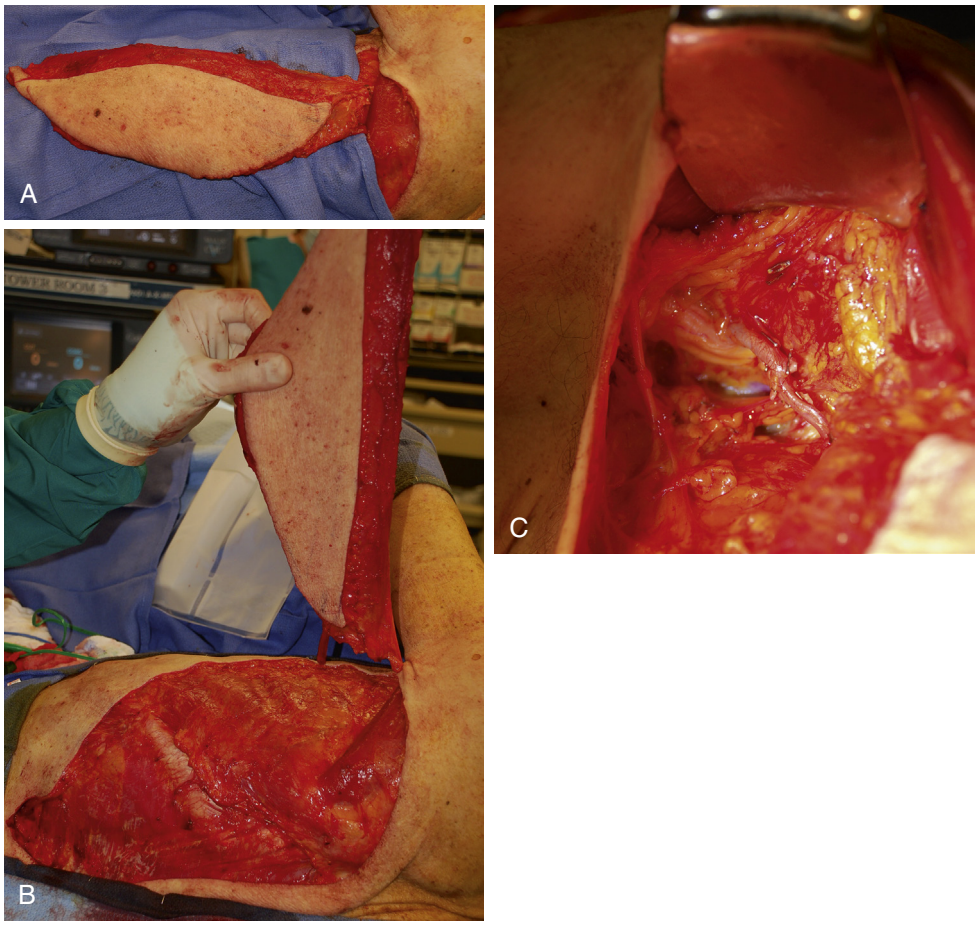

Fig. 172.2. Latissimus flap harvest. A, Subscapular arterial system. **B** and **C,** Fully elevated latissimus flap pedicled on the thoracodorsal system.



Fig. 172.3. Defect and inset. A, Left lateral skull base defect including craniectomy and neck dissection. **B,** Operative closure. **C,** Results 2 months after the procedure.

12. A tunnel is now created through the axilla to the neck.
    a. Working from the axilla, a tunnel is created between the pectoralis major and minor muscles.
    b. During this dissection, the thoracoacromial pedicle can be visualized and should be preserved to protect the pectoralis major flap for possible future use.
    c. Working now from both the cervical and axillary incisions, a section of the clavicular head of the pectoralis major muscle is divided while protecting the thoracoacromial pedicle.
    d. This sectioned muscle should be large enough to allow the operator's hand to easily pass between the neck and axilla. This ensures that the tunnel is large enough so that the latissimus muscle flap or pedicle will not be compressed.
13. Finally, the humeral tendon of the latissimus muscle is divided to finish freeing the flap (see Fig. 172.2B and C).
14. The flap is now rotated and passed through the tunnel into the neck. It can now be inset for reconstruction (Fig. 172.3).
15. Suction drains are placed and the incision on the back is closed primarily. When the width of the flap exceeds 10 cm, primary closure may not be feasible. In these cases, vacuum-assisted closure (VAC) devices can be placed within the closure line and serve as the suction drain for the site, obviating the need for drains, and assist with wound closure (Fig. 172.4).

Common Errors in Technique

1. Kinking of the vascular pedicle is common when it is rotated and passed through the tunnel. Care must be taken to ensure optimal pedicle geometry. Preservation of the circumflex scapular system may help anchor the vascular pedicle and allow a gentle curve without kinking.
2. Waiting until the final step to divide the latissimus dorsi humeral attachments decreases the chances of the flap applying unsupported force on the vascular pedicle.
3. Care must be taken to prevent hyperextension or hyperabduction of the upper extremity during dissection because either event can result in injury to the brachial plexus.

POSTOPERATIVE PERIOD

Postoperative Management

1. Flap monitoring
    a. For pedicled flaps, the need for close monitoring of the flap is debatable because the likelihood of pedicle compromise is low.
    b. Frequency and need are at the surgeon's discretion.
        - Typical flap monitoring by nursing can include monitoring for Doppler signal, capillary refill, color, and warmth.
        - We routinely perform flap checks every hour for 24 hours, then every 2 hours for 24 hours, then every 4 hours after that.
        - The patient may need to be in the ICU or on an intermediate-level nursing floor to allow for frequent flap checks.
2. Drains: Suction drains should be placed to help evacuate fluid from the donor site dead space. They can be removed when drainage is clear and less than 30 mL per 24 hours.

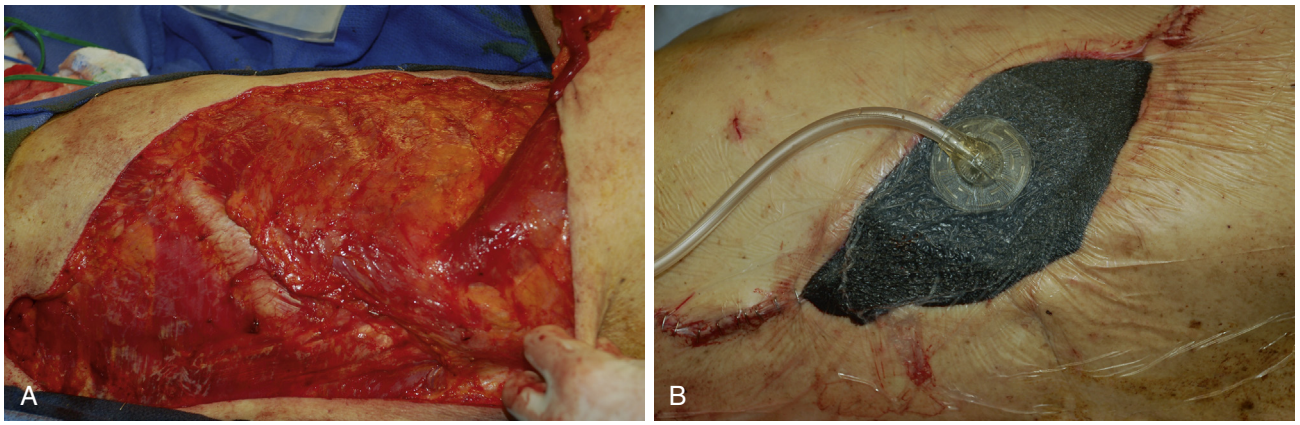

Fig. 172.4. Latissimus defect and closure. A, Donor site defect (too wide for primary closure). **B,** Vacuum-assisted closure of the defect.

3. Pain medication: Patients often experience significant discomfort following harvest of these flaps. Typically, they initially require IV and oral/enteral pain medication postoperatively. They should be transitioned to oral/enteral pain medication within the first 24 to 48 hours.
4. Physical therapy: Early aggressive physical therapy is important to ensure that the patient regains maximum function in the operated shoulder and upper extremity. We initiate therapy within 48 hours of completion of surgery.

Complications

1. Flap viability can be compromised by multiple factors, and early identification is important to maximize the likelihood of flap salvage.
   a. Arterial compromise
      - Most commonly secondary to arterial compression from vascular pedicle geometry or hematoma
      - Typically requires return to the operating room for exploration of the vascular pedicle and to see if arterial flow can be reestablished
   b. Venous compromise, which is more common than arterial compromise
      - Most commonly secondary to venous kinking or compression from vascular pedicle geometry or hematoma
      - Requires return to the operating room for exploration of vascular pedicle and to try to reestablish venous flow
      - If venous flow cannot be reestablished, the flap may be salvaged by the use of leeches and heparin scrub to provide venous outflow from the flap.
      - Failure to treat venous compromise will progress to arterial compromise as pressures within the venous system overcome the perfusion pressure from the feeding artery.
2. Hematoma
   a. Early identification and evacuation are key to preventing complications of infection or flap compromise. This should be done in an urgent and sterile manner.
3. Donor site dehiscence
   a. Treat with local wound care, and allow to heal by secondary intention if the vascular pedicle is not exposed.
   b. If the vascular pedicle is exposed or at risk, the patient should be returned to the OR for revision of the wound.
4. Upper extremity and/or shoulder weakness
   a. The most common cause is brachial plexus traction injury. Reassurance should be provided because the majority of these will resolve, although full return of function may take several months. Aggressive physical therapy is necessary to maximize recovery.
   b. In the case of nerve injury or division, the mainstay is physical therapy to maximize recovery.

DISCUSSION

Evidence-Based Medicine Question

What is the most appropriate nomenclature for describing the vascular pedicle supplying the lower trapezius flap? There are conflicting reports of it being based off the transverse cervical artery versus the dorsal scapula artery.

Historically, the lower trapezius flap has been described as receiving its blood supply from the transverse cervical artery and/or the dorsal scapula artery. This confusion stems, in part, from the fact that the dorsal scapula artery can be a branch of the transverse cervical artery (referred to in those cases as the deep branch of the transverse cervical artery). To address this, an extensive anatomic study of the vascular pattern supplying the lower trapezius flap in 124 cadavers was reported in 2004 by Haas et al.[2] The authors found that the vessel supplying the lower trapezius flap was a deep branch of the transverse cervical artery in 55% of cadavers; however, 45% of the vessels originated directly from the subclavian artery (41%) or the costocervical trunk (4%). Thus, the vessel supplying the lower trapezius flap is best referred to as the dorsal scapula artery because it is anticipated to originate separately from the transverse cervical artery in nearly half of all cases.

Editorial Comment

With the ongoing challenges in health care resources and reimbursement, the importance of pedicled flaps cannot be underestimated. The cost savings, in addition to good functional results, make these flaps appealing. The trapezius and latissimus dorsi flaps provide coverage for multiple defects. Expertise in harvesting and insetting these flaps should be in the armamentarium of every reconstructive surgeon.

Anna Pou

Access the review questions online at http://www.expertconsult.com



REFERENCES

1. Aviv JE, Urken ML, Lawson W, et al. The superior trapezius myocutaneous flap in head and neck reconstruction. Arch Otolaryngol Head Neck Surg 1992;118(7):702–706.
2. Haas F, Weiglein A, Schwarzl F, et al. The lower trapezius musculocutaneous flap from pedicled to free flap: anatomical basis and clinical applications based on the dorsal scapular artery. Plast Reconstr Surg 2004;113:1580–1590.
3. Yoon SK, Song SH, Kang N, et al. Reconstruction of the head and neck region using lower trapezius musculocutaneous flaps. Arch Plast Surg 2012;39(6):626–630.
4. Netterville JL, Wood DE. The lower trapezius flap. Vascular anatomy and surgical technique. Arch Otolaryngol Head Neck Surg 1991;117:73–76.

5. Urken ML, Naidu RK, Lawson W, et al. The lower trapezius island musculocutaneous flap revisited. Report of 45 cases and a unifying concept of the vascular supply. Arch Otolaryngol Head Neck Surg 1991;117:502–511.
6. Ong HS, Ji T, Zhang CP. The pedicled latissimus dorsi myocutaneous flap in head and neck reconstruction. Oral Maxillofac Surg Clin North Am 2014;26(3):427–434.
7. Wilkman T, Suominen S, Back L, et al. The pedicled latissimus dorsi flap in head and neck reconstruction: an old method revisited. J Reconstr Microsurg 2014;30(3):163–170.
8. Har-El G, Bhaya M, Sundaram K. Latissimus dorsi myocutaneous flap for secondary head and neck reconstruction. Am J Otolaryngol 1999;20(5):287–293.

REVIEW QUESTIONS

1. The latissimus dorsi musculocutaneous flap receives its arterial supply from which artery?
   a. Transverse cervical artery
   b. Thoracodorsal artery
   c. Dorsal scapula artery
   d. Circumflex scapular artery

2. The lateral trapezius flap receives its arterial supply from which artery?
   a. Transverse cervical artery
   b. Thoracodorsal artery
   c. Dorsal scapula artery
   d. Circumflex scapular artery

3. The lower trapezius flap receives its arterial supply from which artery?
   a. Transverse cervical artery
   b. Thoracodorsal artery
   c. Dorsal scapula artery
   d. Circumflex scapular artery

4. The lateral trapezius flap can be harvested as an osseomusculocutaneous flap by including a portion of which of the following?
   a. Lateral border of the scapula
   b. Medial border of the scapula
   c. Scapula spine
   d. Scapula tip

173 Skin Grafting

Adam Terella, John Song

INTRODUCTION

There are two basic types of skin grafts: full-thickness and split-thickness skin grafts (FTSGs and STSGs, respectively). Full-thickness grafts are composed of epidermis and full-thickness dermis, including adnexal structures, whereas split-thickness grafts are composed of epidermis and varying amounts of dermis without adnexal structures. Each type of graft has unique characteristics and indications for use in head and neck reconstruction. Although improved techniques with local or regional vascularized tissue transfer have resulted in the decreased use of skin grafts in reconstruction, there are circumstances in which skin grafts may still represent the best reconstructive option.

KEY OPERATIVE LEARNING POINTS

- Choosing the correct thickness for a skin graft is critical (full vs. split) to optimizing function and aesthetics.
- In general, FTSGs will approximate skin color and texture and limit contraction better than STSGs.
- STSGs have a higher rate of survival on wound beds with minimal vascularity due to decreased metabolic demand.
- Meticulous hemostasis of the wound bed and immobilization and prevention of shearing forces on the skin graft by proper suturing and bolstering techniques enhance graft take through apposition of the graft to the recipient bed.

PREOPERATIVE PERIOD

When considering using a skin graft for reconstruction, several factors must be considered in the preoperative period:

- Characteristics of the defect (certainty of margin status, location/surrounding anatomy, depth, vascularity of recipient bed)
- Characteristics intrinsic to the type of graft (full thickness vs. split thickness vs. allograft/xenograft)
- Characteristics of the patient (systemic illness, patient expectation, reconstructive goals)

With careful consideration of all of these factors, a well-developed reconstructive plan can be established.

Characteristics of the Defect

As with any reconstruction, facial aesthetic subunits must be considered when determining whether or not a skin graft is the most appropriate surgical repair. The face can be divided into aesthetic subunits, within which the skin will have similar characteristics. It is helpful in the preoperative period to mark the divisions of the facial subunits as they relate to the existing or proposed soft tissue defect. By doing so, scars can be placed along zones of transition between adjacent subunits, thus helping to camouflage a reconstruction. Occasionally, enlarging a defect to allow resurfacing an entire aesthetic subunit may be desirable.[1]

When using a skin graft, the surgical defect should not include a large portion of a free margin, such as the alar rim or vermillion border. If placed along a free margin, graft contraction during healing can result in distortion of the free margin, such as eclabium or ectropion.

The vascularity of the defect must be taken into account when considering a skin graft. To a large extent, the viability of a skin graft depends on acquiring a blood supply from the wound bed. Graft "take" requires an adequate vascularity of the recipient bed, direct contact between graft and recipient wound bed, avoiding hematoma or seroma formation, and preventing shearing forces. Hematoma, seroma, and shearing forces separate the graft from the bed and disrupt revascularization.

Characteristics of the defect unfavorable for skin graft "take" include radiated tissue, exposed cortical bone, cartilage, tendon, or actively bleeding tissue. In general, grafts placed over avascular defects are unlikely to survive. When attempting to skin graft over cortical bone, survival is enhanced if a thin layer of the outer cortex is taken down with a 6-mm cutting burr until punctate bleeding is noted.[1] If this is not possible, coverage of the avascular defect with a fascial or muscle flap can provide vascularity for a skin graft.

Characteristics of Full-Thickness Skin Grafts

FTSGs will resist contraction and have a texture and pigmentation more similar to normal skin than STSGs. However, the increased dermal thickness results in increased metabolic demand and thus a need for a well-vascularized wound bed for survival. This may result in decreased rates of graft survival and longer healing times.[1]

Appropriate donor sites for FTSGs largely depend on the location of the defect and the characteristics of the tissue being replaced. Replacing "like tissue with like tissue" should be the goal. Commonly used donor sites include supraclavicular fossa, postauricular, preauricular, or upper eyelid. The supraclavicular region is best for harvesting large FTSG, due to significant laxity in the region and ease of primary closure. Postauricular skin is an optimal donor site in males because it is usually hairless and allows for a camouflaged donor site scar. In females, a preauricular skin graft provides better skin color match and usually is not hair bearing. Contralateral upper eyelid skin provides a thin, full-thickness graft that is desirable for shallow perioccular defects.[2]

Characteristics of Split-Thickness Skin Grafts

STSGs are composed of epidermis and partial-thickness dermis without adnexal structures. STSGs tend to have more exposed capillaries on the undersurface than FTSGs and thus can revascularize more quickly. They also have less tissue and thus have a lower metabolic demand than FTSGs, improving graft survival when the wound bed has limited vascularity. In contrast to FTSGs, STSGs tend to contract and have a poor texture and color match with normal facial skin, resulting in a suboptimal cosmetic outcome.

For large defects, an STSG can be an expedient technique for providing wound coverage. In these situations, the STSG may be meshed at ratios of 1:1.5 or 1:3 to increase the area that can be covered, while improving take rates by preventing hematoma or seroma. However, depending upon the location of the defect the use of a meshed graft can give a suboptimal cosmetic result.

History

1. History of present illness
   a. Duration of wound (chronic vs. acute)
   b. Etiology of defect (basal cell carcinoma, squamous cell carcinoma, melanoma, traumatic)
   c. Margin status (if following resection of malignancy)
   d. Need for ongoing close tumor surveillance
   e. Cosmetic expectation of the patient
   f. Need for adjuvant treatment or radiation
   g. Evidence of active infection or inflammatory skin disease
2. Past medical history
   a. Prior malignancy
   b. Previous treatment or intervention of prior malignancy or defect
   c. Previous radiation to the head and neck
   d. Past surgery or trauma that may affect flap donor site or inability to use local or regional flaps
3. Medical illnesses: All of these negatively impact graft survival.[2]
   a. History of cardiopulmonary disease "Are you able to walk up a flight of stairs?"
   b. Diabetes
   c. Hematologic disorders
   d. Collagen vascular disease
   e. Malnutrition
   f. Immunosuppression (e.g., solid organ transplant, human immunodeficiency virus (HIV))
4. Medications
   a. Anticoagulation
   b. Immunosuppression
5. Social history[3]
   a. Tobacco use: cigarettes, smokeless tobacco, nicotine replacement

Physical Examination

1. Determine the need for FTSG versus STSG versus the placement of a skin substitute.
2. Look for evidence of infection in the wound bed.
3. Gain an understanding of the vascularity of the wound base (bone, fascia, adipose tissue, muscle, granulation).
4. Is saliva bathing the graft site?
5. Feasibility of skin graft immobilization to prevent shearing forces
6. Evaluate potential depth mismatch with surrounding tissue. Evaluate actinic change and potential color mismatch with skin from proposed donor site.
7. Does the defect or wound approximate the boundaries of an aesthetic facial subunit?
8. Does the defect or wound involve greater than 50% of an aesthetic facial subunit?
9. Is the involved facial subunit a concavity or convexity?
10. Is the defect in close proximity to structures that may be distorted by graft or wound contraction (lower eyelid, alar margin, oral commissure)?
11. Evaluate donor sites for desirable characteristics.

Imaging

None necessary

Indications

Although there is virtue in using the simplest solution to a given problem, at times more complex methods of reconstruction may be preferred and will result in significantly better outcomes. For this reason, one should use the most appropriate level of reconstruction. Skin grafting may be indicated for any defect that:

- Primary closure would result in a suboptimal functional or aesthetic outcome
- Local or regional flaps result in undesirable distortion of anatomy (e.g., ectropion) or donor site morbidity
- Complete closure of a defect with a local flap/regional results in excessive flap tension and thus vascular compromise
- Is associated with deeply invasive tumors or uncertain margins, where close surveillance of the area is necessary
- Requires temporary closure of a defect pending definitive or staged reconstruction
- In patients who cannot tolerate long periods of anesthesia

Contraindications

- Contraindications to skin grafting include wound characteristics unfavorable for graft "take." In general, grafts placed over avascular defects, such as radiated tissue, exposed cortical bone, cartilage, tendon, or actively bleeding tissue, are unlikely to survive.

Preoperative Preparation

- Identify potential donor sites with desirable characteristics. For large FTSGs, the supraclavicular region is often best due to significant laxity that enables primary closure. For facial defects in males, postauricular skin is appropriate because it is usually hairless. In females, a preauricular skin graft provides an appropriate skin color match and usually is not hair bearing. Contralateral upper eyelid skin is an appropriate FTSG donor site for perioccular defects.
- When a skin graft is used on a wound with abundant granulation tissue, a 10-day course of antistaphylococcal antibiotics may be started 3 days prior to grafting. Granulating wounds commonly have high bacterial levels, which can negatively affect the take of the graft.

OPERATIVE PERIOD

Anesthesia

- Some small skin grafts can be harvested under local anesthesia with or without conscious sedation. However, for larger grafts, general anesthesia is recommended, as it can be difficult to anesthetize a large donor site.

Positioning

- Patients are typically placed in a supine position or any position necessary to allow access to both the donor and recipient sites.

Perioperative Antibiotic Prophylaxis

- Appropriate antibiotic coverage for the primary site should be chosen and administered prior to resection.
- In general, amoxicillin-clavulanate, clindamycin, or cephalosporin and metronidazole all provide adequate antibiotic coverage. If drug-resistant skin flora exists, appropriate antibiotic coverage should be used in consultation with a specialist in infectious disease.

Monitoring

- Usual monitoring for general anesthesia

Instruments and Equipment to Have Available

- Powered dermatome (preferred for larger harvest sites):
  - Padgett, Davol, and Zimmer powered dermatomes all can be used. Zimmer dermatomes are most commonly used nowadays because they are more likely to harvest a graft of more uniform depth and width (Fig. 173.1).
- Nonpowered dermatome:
  - Weck knives, scalpels, and double blades can be used for small graft harvests. These instruments usually require practice and a higher level of technical skill to harvest grafts of uniform thickness.

Key Anatomic Landmarks

- Graft harvest sites should be designed as to minimize cosmetic and functional deficits.
- For split-thickness grafts harvested from the thigh, the graft site should be placed in the mid or lateral skin and at least four fingerbreadths from the patella, so as to not interfere with knee flexion and extension.
- FTSG harvested from the supraclavicular region should be harvested from the fossa, which avoids placing the resulting closure directly over the clavicle. Preauricular or upper eyelid harvests should be placed along the naturally occurring preauricular crease or supra tarsal crease, respectively.

Prerequisite Skills

- Basic soft tissue handling skills are required for harvest, transfer, inset, and bolster placement.

Surgical Technique

- STSG harvest with Zimmer dermatome
  - An appropriate-sized plate is selected so that the graft is approximately 10% to 15% wider than the size of the defect. The width of the graft should allow enough slack so that the graft can make full contact with the underlying recipient site and is not tented up (see Fig. 173.1A and B).
  - The thickness of the skin harvest is most commonly set for 0.012 inches. A thin graft will have a higher rate of take and be more resistant to infection (see Fig. 173.1C).
  - The donor site is lubricated with mineral oil. With an assistant providing constant countertraction, the Zimmer dermatome is engaged at a 30- to 45-degree angle. As the dermatome flattens along the harvest site, uniform pressure is applied, and the dermatome is continuously running until the predetermined end of the graft. The dermatome exits at the same 30- to 45-degree angle (Fig. 173.2A to C).
  - The surgeon can visualize the harvest as the landing and taking off of an airplane, using the same 30- to 45-degree angle.
  - It is critical that the dermatome is running throughout the entire harvest.
  - Lidocaine (1%) with epinephrine (1:100,000) is applied to the donor site and allowed to sit while the graft is inset into the recipient site. This technique allows for hemostasis as well as local anesthesia to minimize postoperative pain (see Fig. 173.2D and E).
  - A semiocclusive dressing for the donor site is placed. Adhesive is applied to the periphery of the donor site. Tegaderm is applied over the donor site and secured to the adhesive peripherally (see Fig. 173.2F). The transparent dressing allows for accumulation of serosanguineous fluid over the donor site and promotes more rapid epithelialization than either occlusive or nonocclusive dressings. Visual inspection of the fluid also allows for early detection of infection.
  - The skin graft can be meshed to increase its surface area, to create slits to allow fluid to escape from beneath the graft, and to allow for better adherence to an irregular recipient site (Fig. 173.3A to C). The graft is meshed at a 1:1.5 or 1:2 ratio, as the space between the meshes has to heal by secondary intention. Meshing at a higher ratio can result in significant contracture of the wound, as well as a checkered appearance of the wound and increased healing time. Smaller meshes ("pie crusting") can be created by hand using a scalpel blade and may be preferred in recipient areas where a checkered appearance would have significant cosmetic impact.
  - For graft inset, the graft is loosely draped over the recipient site with the dermal (lighter) side down. The graft should be loose enough to prevent tenting but not so loose as to create overlapping folds. 4-0 Vicryl sutures are used to secure the graft circumferentially to the edge of the recipient bed, as well as in between the meshes to increase its adherence to the bed (see Fig. 173.3C).
  - A bolster is used to provide uniform pressure over the graft. Immobilizing the graft with an occlusive material prevents shearing and the accumulation of fluid under the graft. The bolster is secured with 2-0 silk sutures in a "star-burst" pattern radially. Xeroform gauze wrapped around moistened cotton balls is often used (Fig. 173.3D and E), but other bolsters including foam, Adaptic, or a wound vacuum-assisted closure (VAC/negative pressure wound therapy) system can also be used.

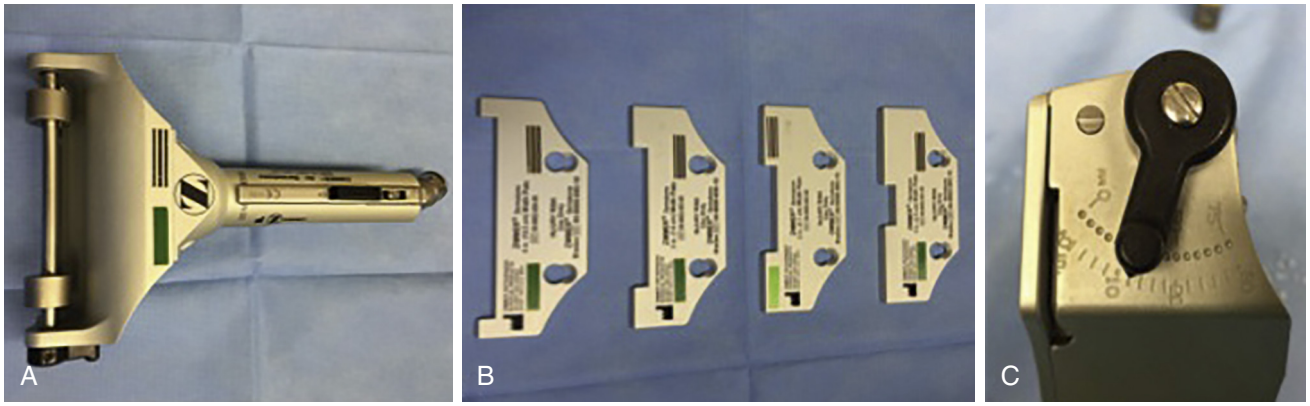

Fig. 173.1. A, Zimmer Air Dermatome. **B,** Serially sized harvest plates. **C,** Dermatome thickness is set at 0.012 inches.

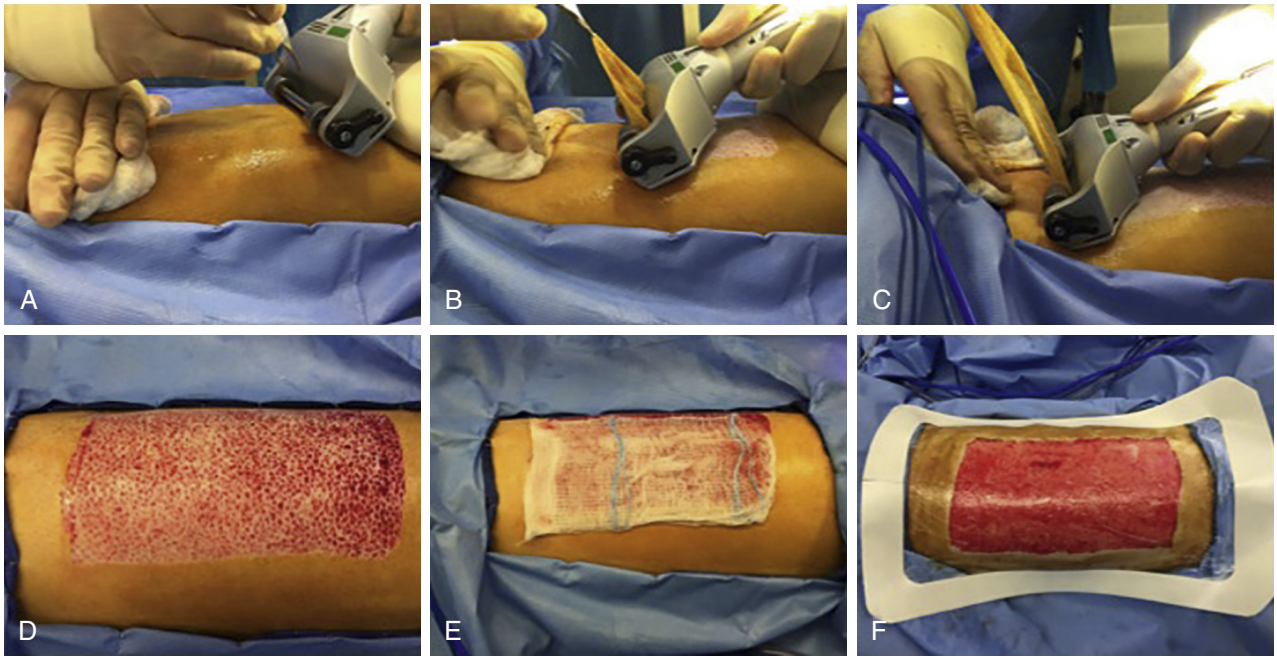

Fig. 173.2. A to **C,** The donor site has been lubricated with mineral oil. With an assistant providing constant traction, the dermatome is engaged at a 30- to 45-degree angle. Even pressure is applied, and the dermatome exits at the same 30- to 45-degree angle. The assistant retracts the graft as it is being harvested. **D,** Donor site appearance after harvest. **E,** Lidocaine (1%) with epinephrine (1:100,000)-soaked gauze is applied to the donor site for hemostasis and local anesthesia. **F,** A large Tegaderm dressing is applied after application of adhesive around the donor site.

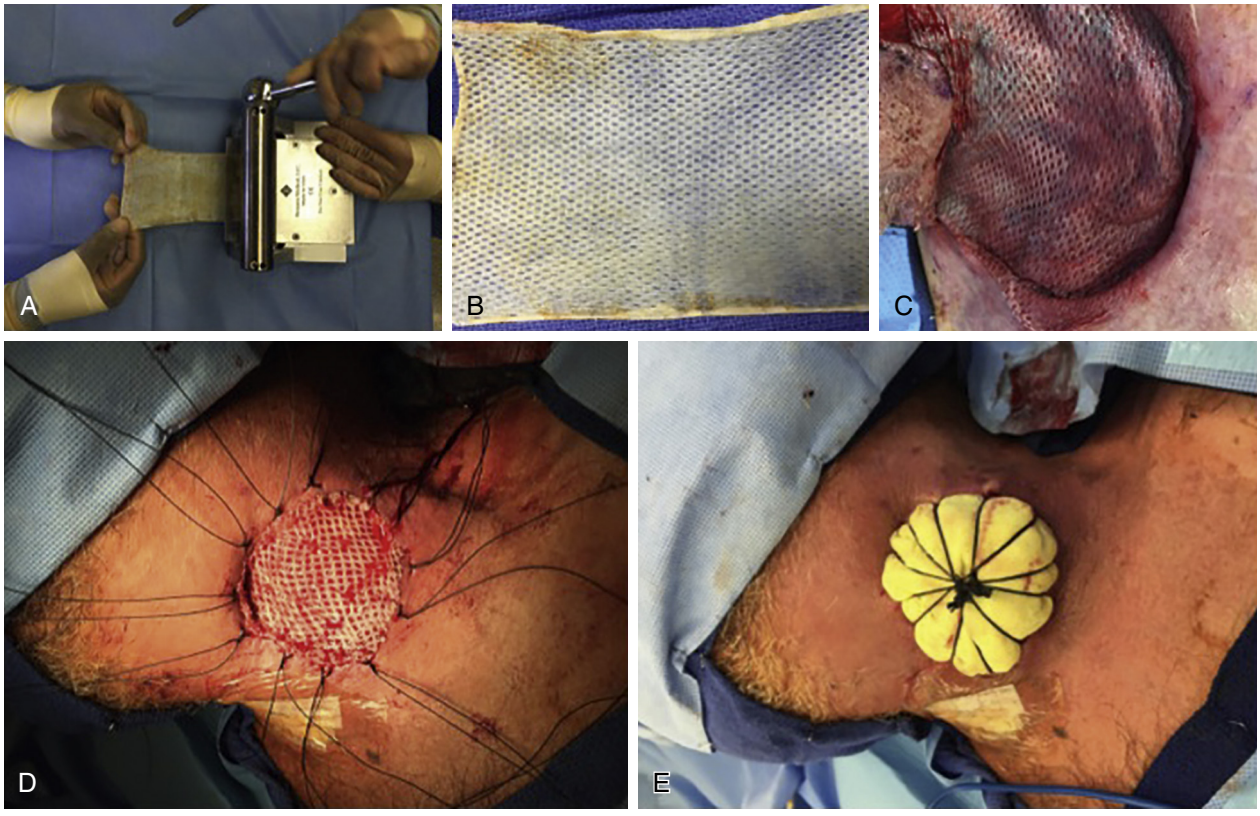

Fig. 173.3. A to **C,** Skin graft is meshed using a meshing device. This graft has been meshed to a 1:1.5 ratio. Meshing allows for better adherence to an irregular donor site surface and prevents fluid buildup under the graft. **D** and **E,** The graft is secured to the borders of the recipient bed with 4-0 Vicryl sutures. The same sutures are placed between the meshes to secure the graft to the recipient bed. A xeroform gauze is used as a bolster and is secured with circumferential 2-0 silk sutures in a star-burst pattern.

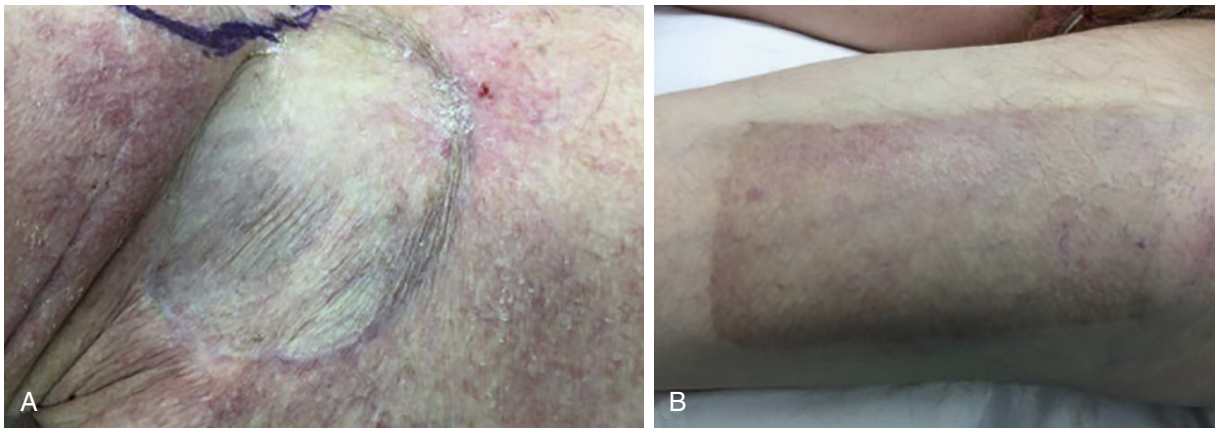

Fig. 173.4. A and **B,** Recipient and harvest sites at 4 weeks postoperative. The graft has 100% take, and the donor site has healed evenly and is smooth to the touch.

- FTSG harvest
  - A template is made of the surgical defect using Telfa and oversized by approximately 10% to account for graft contraction. If local anesthesia is being used at the donor site, the graft should be designed prior to injection in order to prevent distortion of measurement due to tissue expansion. The graft is harvested deep to the dermis, attempting to leave subcutaneous adipose tissue off the graft surface. After being excised from the donor site, a curved Iris scissor is used to thoroughly remove all remaining subcutaneous adipose tissue, revealing the white dermis of the graft.
  - Graft inset: The graft is placed onto the donor site so as to maximize contact between graft and wound bed. Interrupted circumferential tacking sutures are placed, using a 5-0 chromic suture. If the graft is large, sutures are placed through the midportion of the graft to prevent "trampolining" of the graft off of the wound bed.
  - A few slits are made in the center of the graft to prevent hematoma formation similar to that of an STSG.
  - Bolstering is then completed as outlined above for split-thickness grafting.

Common Errors in Technique

- Engaging the dermatome at an angle less than 30 to 45 degrees will create a thin, irregular graft that will shear off the donor site in strips. An angle greater than 45 degrees will create a gouge within the donor site.
- Failure to provide countertraction of the donor site and not providing uniform pressure on the dermatome will result in a graft thinner than planned. The dermatome should be running fully before engaging (landing the air plane) as well as exiting (takeoff) the donor site to prevent the graft from becoming enmeshed in the blades. Retraction of the graft by the assistant also prevents this error in technique.
- Ensure that the dermal side is in contact with the recipient bed. Epidermis-to-epidermis contact will not heal and will lead to graft loss.
- Meticulous insetting of the graft (both to the edge of the bed as well as tacking the graft onto the bed) creates the maximum contact of the graft to the recipient bed and is the most important step in achieving good cosmetic results (Fig. 173.4A and B).
- Harvesting too thick a graft can result in poor graft take. We prefer a graft thickness of 0.012 inches because the rate of healing is inversely proportional to the thickness of graft harvested.
- Bolsters should be placed so that there is an even distribution of pressure throughout the graft. Stay sutures should be placed such that no part of the bolster is looser than any other area.

POSTOPERATIVE PERIOD

Postoperative Management

- The routine use of postoperative antibiotics is not routinely recommended. Patients with diabetes, who are immunocompromised, or with infected recipient sites may benefit from oral antibiotics.
- Full revascularization of the graft results in 6 to 7 days postoperative. Most bolsters can be removed safely after this period. The bolsters are moistened prior to removal to prevent lifting the graft from the recipient site. Any accumulated blood or fluid under the graft may be expressed by making small incisions into the graft.
- Donor site management (split thickness): If significant fluid volume accumulates under the Tegaderm, it can be aspirated and the site reinforced with an additional dressing. If the fluid becomes cloudy and infected, the entire dressing should be removed, the donor site cleaned with hydrogen peroxide, and a new sterile Tegaderm reapplied.
- Donor site management (full thickness): Bacitracin or petrolatum ointment is applied three times daily for 10 days.
- Wound contraction is inversely related to the thickness of the graft, with an FTSG having the least amount of contraction and STSG the most contraction. In functional or cosmetically important areas, a compression device, such as a Jobst dressing or facial mask, can be used daily to minimize contraction.

Complications

- Graft failure can occur due to:
  - Technical error (failure to place the dermal side down in contact with the recipient bed; tenting the graft by stretching it too tightly and thus preventing apposition with the recipient bed)
  - Hematoma or seroma formation under the graft preventing adherence to the wound bed and neovascularization. Poor vascularization or infection of the wound bed

- Mobilization of the graft due to improper placement of the bolster or placement over tendons or joints
- Uninfected eschars can be maintained to act as a biologic dressing. Nonviable graft areas can be débrided but may risk damaging deeper viable graft tissue.

Alternative Management Plan

Using skin grafts with local flaps

- Using a skin graft as an adjunct to local flaps is an effective way to close large cutaneous defects of the head and neck. Local flaps may cause anatomic distortion by placing excessive tension on a free margin. Large flaps may also be under too much tension, resulting in vascular compromise of the flap. Rather than risking anatomic distortion or flap survival, a portion of the surgical defect can instead be closed with a skin graft. Grafts harvested from redundant tissue removed during flap closure (Burow grafts) can frequently be used, rather than creating a separate graft donor site.

Skin substitutes

- For large cutaneous defects with poor vascularity, the use of a skin graft may result in prolonged healing times, inadequate healing, or significant donor site morbidity.
- Skin substitutes are most concisely classified according to their origin—autologous, allogeneic, xenogeneic, or recombinant.

Allografts

- AlloDerm, an acellular human dermis, is an allograft commonly used in the reconstruction of soft tissue defects. It was shown to support fibroblast infiltration, neovascularization, and epithelialization.[4] Like split-thickness skin grafting, AlloDerm also has utility in the reconstruction of oral cavity mucosal defects, with an overall take rate of 90% with complete epithelialization noted within 4 weeks.[5]
- Allogenic skin substitutes are available as Apligraf (Organogenesis, Inc., Canton, Massachusetts). Apligraft contains living cells that produce growth factors that may aid in the recruitment of host cells. Apligraf is composed of type I bovine collagen, keratinocytes, and fibroblasts from neonatal foreskin. It is food and drug administration (FDA) approved for use in venous ulcers and diabetic foot ulcers but also has off-label applications in head and neck reconstruction.[6] Fig. 173.5A to C illustrates the wound-healing progression of a patient treated with a combination of a local flap and Apligraf.

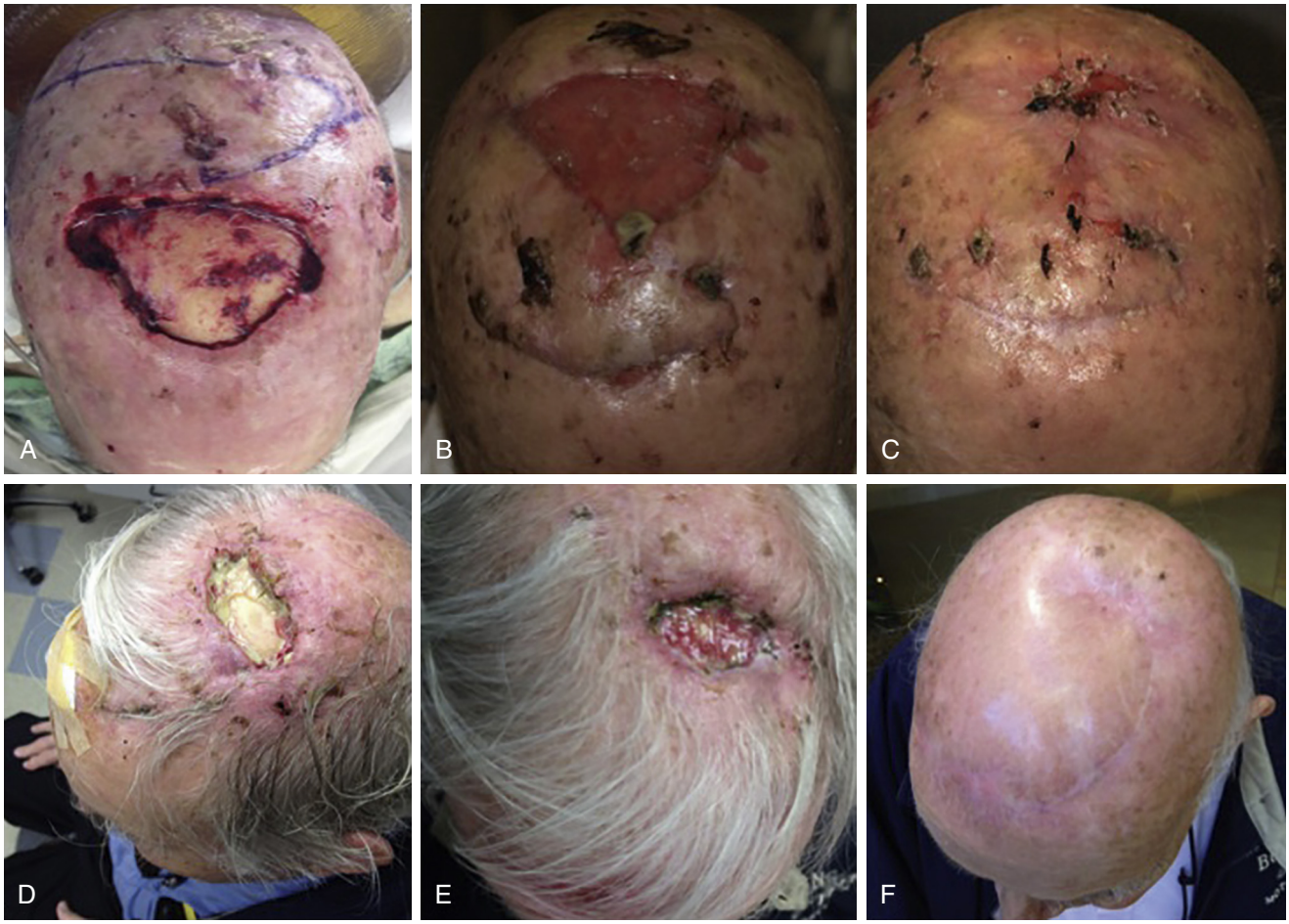

Fig. 173.5. A, An 87-year-old male status post (s/p) Mohs for squamous cell carcinoma (SCCa), very poor candidate for general anesthesia. **A,** No viable periosteum present to support grafting. Transposition flap to fill defect, resulting in a large donor site with viable pericranium. Apligraf used at the donor site. **B,** Three weeks after one application of Apligraf. **C,** Two months after one application of Apligraf. **D,** A 90-year-old male s/p Mohs surgery for squamous cell carcinoma of the scalp vertex resulting in 7 × 7 cm defect. The pathology report suggests perineural invasion. Adjuvant radiation is planned. Large rotation and advancement flaps completed. Postoperative course was complicated by infection and then partial dehiscence of the wound. **E,** 2.5 weeks following application of MatriStem powder and a wound sheet. **F,** Two months following completion of radiation therapy.

Xenografts

- Xenografts are biologic materials transplanted from one species to another. Integra Dermal Regeneration Template (Intregra LifeSciences Corporation, Plainsboro, New Jersey) is a xenograft/semisynthetic bilayer. It has an outer thin silicone film that covers an inner porous matrix of cross-linked collagen and glycosaminoglycan. This collagen and glycosaminoglycan layer serves as a scaffold for the regenerating dermis. Integra is approved by the FDA in patients with extensive loss of skin and those with reconstruction of a complex surgical wound. Use of the dermal regeneration template is usually then followed by a delayed STSG.[7] It should be noted that a multicenter investigation of patients managed with Integra following release of scar contracture noted a concerning 20% rate of infection.[8]
- MatriStem MicroMatrix and MatriStem Wound Matrix are other xenografts composed of acellular porcine urinary bladder. They are available as a powder or as a single or multilayered sheet. The wound sheets are composed of extracellular matrix with an intact basement membrane that remains after processing. Data supporting its use are largely limited to case series and level III evidence. We have found utility in this xenograft for difficult-to-heal scalp wounds (see Fig. 173.5D and E).

DISCUSSION

Evidence-Based Medicine Question

Skin graft failure due to infection is most commonly due to which causative agent?

a. *Pseudomonas* spp.
b. *Staphylococcus aureus*
c. *Enterobacteriaceae* spp.
d. *Acinetobacter* spp.

In a prospective, 3-year study[9] to evaluate skin-graft failure due to infection, *Pseudomonas* spp. was isolated as the most common causative agent (58.1%), followed by *S. aureus* (16.1%).

Editorial Comment

The use of skin grafts in reconstruction of the head and neck is often overlooked by the novice surgeon due to the wide use of fasciocutaneous free flaps. Skin grafts, particularly STSGs, have been successfully used in reconstruction of the oral cavity, preserving the floor of mouth sulcus for dentures and tongue mobility, the oropharynx and retromolar trigone to prevent trismus, and midface for lining of soft tissue for placement of an obturator. FTSGs and STSGs are very useful in reconstruction of the eyelids, for correction of ectropion, and for facial and nasal reconstruction of small Mohs defects. They are perhaps among the most versatile grafts in head and neck reconstruction and are useful in those who cannot undergo prolonged periods of general anesthesia due to medical comorbidities. In the past, there was a misconception that STSGs "did not work" for oral cavity reconstruction; this was typically due to improper surgical technique used by the surgeon.

Allografts are an excellent adjunct to STSGs and as replacement when there is a lack of skin available for grafting.

Anna Pou

Access the review questions online at http://www.expertconsult.com



REFERENCES

1. Jewett BS. Skin and composite grafts. In: Baker SR, editor. Local Flaps in Facial Reconstruction. 2nd edition St. Louis: Mosby; 2007. p. 337–365.
2. Mowlavi A, Andrews K, Milner S, et al. The effects of hyperglycemia on skin graft survival in the burn patient. Ann Plast Surg 2000;45(6):629–632.
3. Goldminz D, Bennett RG. Cigarette smoking and flap and full-thickness graft necrosis. Arch Dermatol 1991;127(7):1012–1015.
4. Wainwright DJ. Use of an acellular allograft dermal matrix (AlloDerm) in the management of full-thickness burns. Burns 1995;21(4):243–248.
5. Rhee PH, Friedman CD, Ridge JA, et al. The use of processed allograft dermal matrix for intraoral resurfacing: an alternative to split-thickness skin grafts. Arch Otolaryngol Head Neck Surg 1998;124(11):1201–1204.
6. Falanga VJ. Tissue engineering in wound repair. Adv Skin Wound Care 2000;13(2 Suppl):15–19.
7. Richardson MA, Lange JP, Jordan JR. Reconstruction of full-thickness scalp defects using a dermal regeneration template. JAMA Facial Plast Surg 2016;18(1):62–67.
8. Frame JD, Still J, Lakhel-LeCoadou A, et al. Use of dermal regeneration template in contracture release procedures: a multicenter evaluation. Plast Reconstr Surg 2004;113:1330–1338.
9. Unal S, Ersoz G, Demirkan F, et al. Analysis of skin-graft loss due to infection: infection-related graft loss. Ann Plast Surg 2005;55(1):102–106.

REVIEW QUESTIONS

1. A split-thickness skin graft consists of the following skin layers
   a. Epidermis and variable portions of the dermis
   b. Epidermis and full-thickness dermis
   c. Epidermis, dermis, and variable portions of subcutaneous adipose tissue
   d. Epidermis only

2. When contemplating the use of a full-thickness graft versus split thickness, increased dermal thickness results in
   a. Increased metabolic demand and thus a need for a well-vascularized wound bed for survival
   b. Increased rates of graft survival and shorter healing times
   c. Increased graft contraction
   d. Improved color match

3. Why is a bolster used in skin grafting?
   a. It helps to ensure immobilization of the graft.
   b. Prevents hematoma/seroma formation
   c. Maximizes graft contact with the wound bed
   d. All of the above

174 Autologous Fascial Grafts and Acellular Allografts

Brendan Alleyne, Brian Gastman

INTRODUCTION

Free fascial grafts and allogeneic options, such as acellular dermis like Alloderm, are available for use in various settings of head and neck reconstruction. There are many sources of these tissues including the fascia lata (FL), temporal fascia as well as those made from dermal sheets either autologous or "off the shelf" acellular versions. Not only are there many sources of these materials, but there are many uses. From soft tissue augmentation to supporting facial structures, surgeons have made many innovations using them to optimize function and form of the head and neck. In this chapter, we focus on a select few uses of these grafts. For instance, we describe the commonly used FL grafts in facial paralysis. We also demonstrates the use of Alloderm as a soft tissue augmentation material. The examples described are merely a sampling of the many uses of these tissues but highlight the potential of their use.

KEY OPERATIVE LEARNING POINTS

- Soft tissue and defect assessment—What's missing?
- Reconstructive goals
- Harvest and inset of FL graft
- Considerations for Alloderm placement

PREOPERATIVE PERIOD

Patient selection may prove to be even more vital to reconstructive success than the technical aspects. The patient's overall health and history may by default limit many surgical pathways. Additionally, the goals of care of the patient need to be verbalized, and both the surgeon and the patient should agree on the most reasonable reconstructive option in lieu of final treatment goals. Risks and benefits must be discussed in detail with consideration of the ultimate morbidity from reconstructive efforts such as the possibility of nonhealing wounds, increased donor sites and scarring, Alloderm-related infection or seroma, and future revision surgeries.

HISTORY

A history of wound healing issues, diabetes, and cardiopulmonary history should be obtained alongside our anesthesia colleagues to help be certain of adequate safety in proceeding with surgery. Nutrition should be assessed preoperatively as it bears direct consequences on wound healing. This is especially important when a second surgical site is created, as this is an additional wound, and this should be discussed at length with the patient.

1. History of present illness
   a. Risk factors for complication: smoking, diabetes mellitus, vasculopathy, vascular injury, radiation, chemotherapy
   b. Nutritional status
   c. Facial paralysis due to resection of facial nerve, trauma, or idiopathic, for example, Bell's palsy
2. Past medical history
   a. Diabetes mellitus
   b. Prior radiation to surgical field
   c. Vasculopathy
   d. Pulmonary disease
   e. Cardiac disease
   f. Immunosuppression
   g. Chronic pain syndrome
   h. Systemic vascular disease
3. Prior treatment of scalp, skull base, facial nerve, or parotid gland
   a. Prior known cancer of the head and neck
   b. Previous surgery of the head and neck
   c. Previous chemotherapy or radiation
4. Current medications
   a. Anticoagulants including antiplatelet agents and new generation coagulation cascade inhibitors
   b. Herbal products
   c. Allergies to antibiotics and pain medication
5. Social history
   a. Psychologic: patient understands and can accept new deficits and issues related to reconstruction
   b. Patient expectations
   c. Support system: case manager or social worker is consulted to assess patient's support system and needs
   d. Goals of employment
   e. Substance abuse, particularly narcotics

FASCIA LATA

When to Consider Fascia Lata

PHYSICAL EXAMINATION

1. Face
   a. Examination of the facial and trigeminal nerve and overall functional deficits
      1) Ptosis, facial nerve injury/paralysis
      2) Oral competence
      3) Signs and symptoms of dry eye
      4) Eye closure
   b. Baseline symmetry of soft tissue structures, eyebrows, lips, eyelids
   c. Location of rhytids, quality of skin, evidence of hypertrophic or keloid scarring
   d. Neurovascular involvement
      1) Facial nerve involvement/resection
2. Health status
   a. Nutrition/weight loss
   b. Cardiovascular health
   c. Pulmonary health
   d. Mental status and sources of emotional support
   e. Smoking status
   f. Alcohol or narcotic addiction

IMAGING

- Not usually necessary unless concern for recurrent disease

INDICATIONS (FASCIA LATA GRAFT)

- Fascial sling for facial soft tissue support for facial nerve palsy following trauma, neoplasm, congenital sequelae, or cerebrovascular accident[1–3]

- Can also be used as a sling for brow elevation, lip ptosis, and orbital support
- Autologous in nature, relatively infectious resistant, incorporates well
- Does not stretch such as seen in dermal grafts or Alloderm
- Minimal donor site morbidity
- Can be harvested endoscopically

CONTRAINDICATIONS

1. Patient factors
   a. Unstable health status
   b. Poor nutrition
   c. Inability to give informed consent
   d. Inability to accept postoperative morbidity
   e. Low Global Assessment of Functioning (GAF) or low social support
   f. Smoking
   g. Collagen-vascular disease
2. Surgical factors
   a. Prior harvest of fascia from the area
   b. Radiation to harvest area
   c. Prior surgery or trauma to the leg

PREOPERATIVE PREPARATION

1. Evaluations by
   a. Reconstructive surgeon
   b. Anesthesiology
   c. Physical medicine and rehabilitation

Operative Period

ANESTHESIA

- General

POSITIONING

- The entire face, neck, and selected donor site (lateral thigh and entire scalp and face) are sterilized and draped in the usual fashion.
- The surgery is done with the patient in a supine position or lateral to facilitate FL harvest but can also be repositioned for inset.

PERIOPERATIVE ANTIBIOTICS

- Ideally, they are administered during induction of anesthesia and continued for 24 hours.
- Choices
  - Cefazolin
  - Clindamycin
  - Vancomycin
  - Ciprofloxacin

MONITORING

- Routine anesthesia care
- Muscle paralysis can be beneficial during FL harvest.

INSTRUMENTS AND EQUIPMENT TO HAVE AVAILABLE

- Basic soft tissue set
- FL harvest set
  - Long thoracic scissors
  - Long narrow Deaver retractor
  - Right angle clamp
  - Long thoracic Rider needle holder

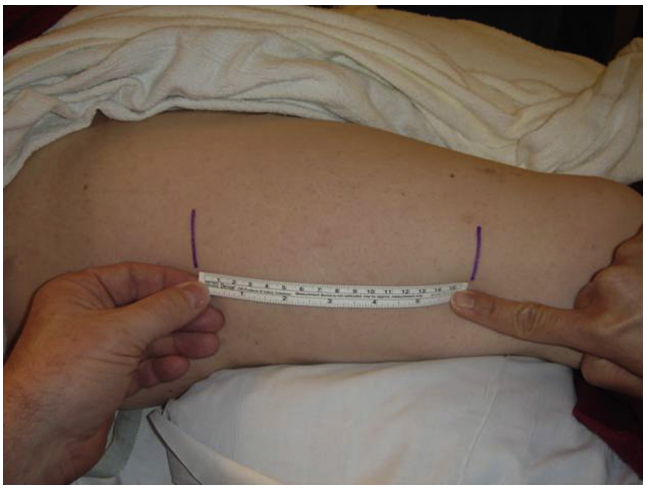

Fig. 174.1. Lateral thigh incision for fascia lata harvest.

  - Narrow hemostat (Jacobs)
  - 3-0 chromic and 4-0 prolene on tapered needles
  - FL stripper or long straight scissors

KEY ANATOMIC LANDMARKS

- FL
  - Midline lateral thigh below iliac crest (Fig. 174.1)
  - Middle ⅓ from iliac crest to lateral knee

PREREQUISITE SKILLS

- Basic head and neck surgical skills

OPERATIVE RISKS

1. Evaluations by:
   a. Anesthesiology and primary team
2. ASA guidelines
3. Typically FL harvest alone will carry a low postoperative risk of DVT and PE.

SURGICAL TECHNIQUE

- Intraoperative evaluation
  - Soft tissue evaluation of laxity
  - Asymmetry
- Surgical approach
  - Anatomic landmarks are marked at the FL donor site.
  - Lidocaine with epinephrine is administered prior to the skin incision for hemostasis.
- Surgical approach FL continued
  - Midline lateral thigh below iliac crest (see Fig. 174.1)
  - 4-cm transverse incision at superior aspect of middle ⅓ from iliac crest to lateral knee (Fig. 174.2)
  - Incision down through fascia with retractor placed in subfascial plane
  - Scissors used to split fascia in line with fibers
  - Two transverse incisions may be needed for larger patients/fascial strips.
  - Fascial strip harvested en bloc (Fig. 174.3) (fascial strip to be at least 1.5 cm wide and 17 cm long)
  - Long scissors can be used in parallel with the fibers, while a right angle creates tension proximally.
  - The scissors undermine subfascially prior to using them to make the parallel cut.
  - Otherwise, a fascial stripper can be used to harvest the graft en bloc.

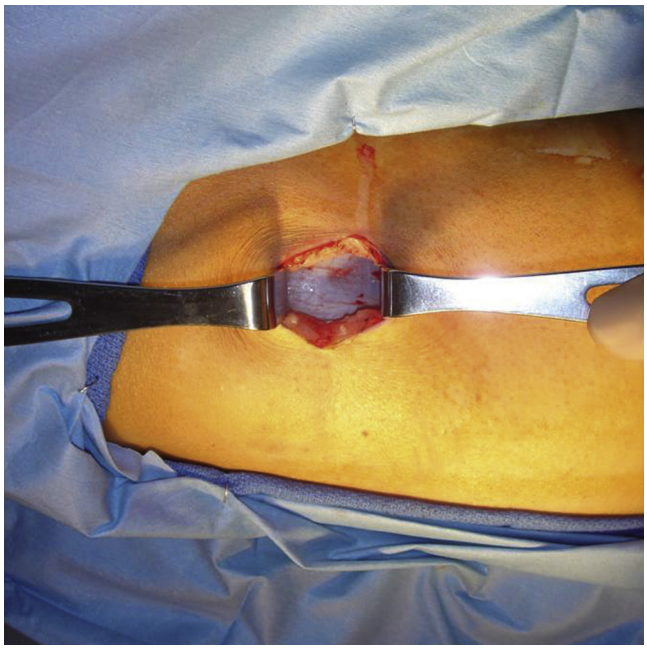

Fig. 174.2. View of fascial layer.



Fig. 174.3. Harvested fascial strip.

- FL reconstruction for facial paralysis-static sling
  - Use static fascial slings to restore facial symmetry in areas of neural weakness.
  - Fascial strips for anchoring soft tissues
  - Commonly employed for increasing oral competence
- Inset: FL for static fascial sling
  - 1.5- to 2-cm incisions within nasolabial fold (Fig. 174.4)
  - 1.5- to 2-cm incisions within hair-bearing scalp above lateral eyebrow (Fig. 174.5)
  - Fascia split to pass through lower lip wet vermillion incisions (Fig. 174.6)
  - Fascial strip encircling orbicularis and sutured on itself (Fig. 174.7)
  - Thoracic rider needle holder used to grasp fascial strip and pull toward temporal incision (Fig. 174.8)
  - Fascial strip, once anchored at orbicularis and modiolus, is directed through face toward temporal incision (Fig. 174.9)
  - Fascial strip pulled through temporalis fascia and then fixed to itself (Fig. 174.10)



Fig. 174.4. Labial and nasolabial markings.



Fig. 174.5. Lateral view showing nasolabial and temporal markings.

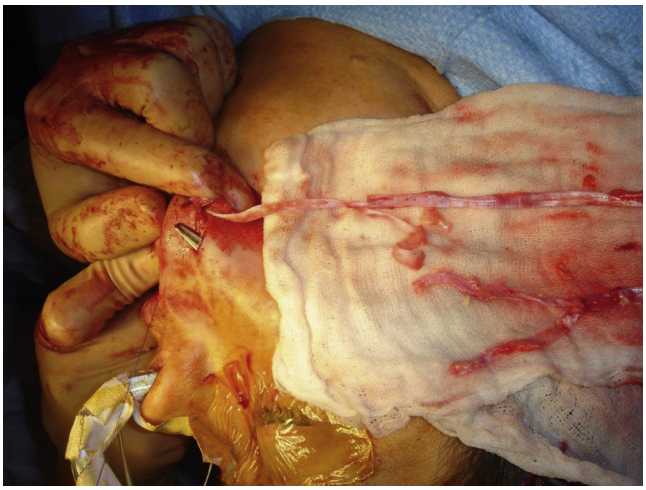

Fig. 174.6. Fascial strip passed into the lower lip incision.

  - Tightness of fascial sling is adjusted through lower lip incisions, deliberately overcorrected (Figs. 174.11 and 174.12)
- Closure
  - The FL harvest site can be closed primarily with or without subcutaneous drain placement.

COMMON ERRORS IN TECHNIQUE: FASCIA LATA

- Improper or inadequate anchoring of grafts leading to premature failure and loss of corrective support over time



Fig. 174.7. Preoperative lip and nasolabial fold markings fascial strip encircling the orbicularis and sutured on itself.



Fig. 174.8. Thoracic rider needle holder used to grasp the fascial strip and pull toward temporal incision.



Fig. 174.9. Fascial strip, once anchored at orbicularis and modiolus, is directed through face toward temporal incision.



Fig. 174.10. Fascial strip is pulled through temporalis fascia and then fixed to itself.

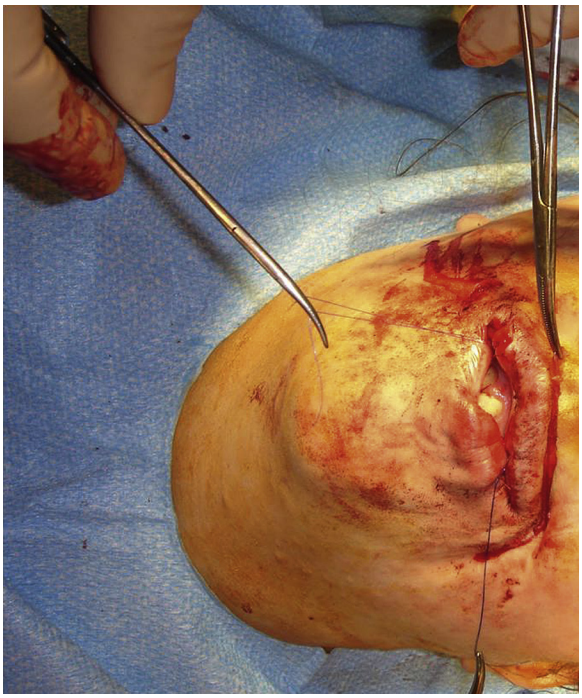

Fig. 174.11. Tightness is adjusted through lower lip incisions, deliberately overcorrected.

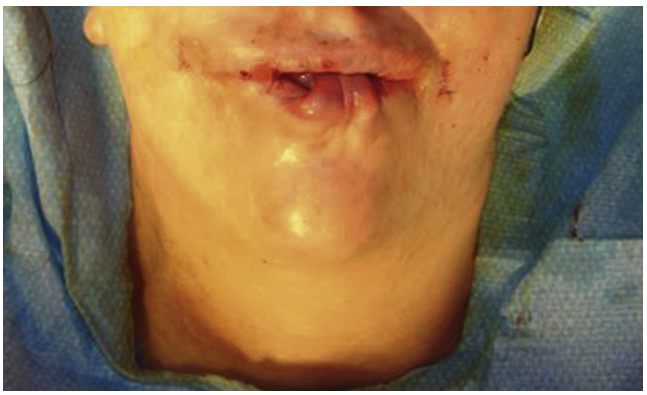

Fig. 174.12. Immediate postoperative view.

Postoperative Period

POSTOPERATIVE MANAGEMENT

- Perioperative antibiotics are continued for 24 to 48 hours.
- Drains are removed when the volume of output decreases to less than 30 mL over a 24-hour period.
- Typically drains are removed 7 days postoperatively.
- Immediate postoperative facial analysis (inset of FL with overcorrection of tightness of strips)
- Nutrition
  - Oral feeding with a soft diet typically begins on postoperative day 1 and advances as tolerated.

COMPLICATIONS

- Hematoma
  - Most likely combination of muscle belly injury during fascia harvest and lack of hemostasis prior to closure
  - Will require immediate evacuation of clot and identification of bleeding source with washout and hemostasis with cautery and or suture ties
- Pain
  - Injury to lateral femoral cutaneous nerve
  - Pain control
  - Postoperative physical therapy
- Premature graft failure
  - Improper anchoring such as when using fascial strip for oral competence
  - Suture failure such as "cheese-wiring"
  - Will require elective re-anchoring of areas involving fascial sling rupture

ALTERNATIVE MANAGEMENT PLAN

Patient wishes should be discussed along with all reconstructive options. At times, the less invasive option will be the best option for a particular patient. Patients unable to receive a fascial autograft could elect to undergo nongrafting techniques such as contralateral facial Botox or an ipsilateral facelift. For grafting techniques, a patient could undergo a palmaris longus tendon graft if available. Additional alternatives would include a free tissue dynamic reconstruction.

ALLODERM

When to Consider Alloderm

PHYSICAL EXAMINATION

1. Assessment of the defect and overall concerns of function
   a. Dimensions of the actual or planned defect
      1) Measured area of defect in centimeters
      2) What tissue types will be missing?
      3) Exposed hardware or vital structure?
   b. Neurovascular involvement
      1) Facial nerve involvement/resection
2. Neck
   a. Look for previous scars, wounds; assess quality, quantity, and mobility of neighboring skin
3. Scalp
   a. Palpate with attention to areas of deformity, wounds with exposure of previous hardware
   b. Examine for previous surgical scars, quality, thickness of tissues, temporal hollowing
4. Face
   a. Location of rhytids, quality of skin, evidence of hypertrophic or keloid scarring
   b. Soft tissue contour abnormality
5. Health status
   a. Nutrition/weight loss
   b. Cardiovascular health
   c. Pulmonary health
   d. Mental status and sources of emotional support
   e. Smoking status

IMAGING

- Not usually necessary unless there is a concern for recurrent disease

INDICATIONS (ALLODERM)[1–3]

- Augmentation of soft or hard tissue deficit
- Improvement in contour
- Mild to moderate soft tissue defects
- Patient's desire to not have a donor site for reconstructive tissues
- Cost:benefit versus surgical risk of donor site of autologous materials
- Post-parotidectomy
  - Prevention of Frey's syndrome
  - Elimination of dead space
  - Contour abrogating stigmata of the surgery
- Coverage of vital structures such as neck vasculature following parotidectomy or neck dissection or exposed cranioplasty
- For skull defects; impending cranioplasty exposure or craniofacial contour bony deformity improvement
- Commonly used for cosmetic augmentation such as in nasal dorsum

CONTRAINDICATIONS

1. Patient factors
   a. Unstable health status
   b. Poor nutrition
   c. Inability to give informed consent
   d. Inability to accept postoperative morbidity
   e. Low GAF or low social support
   f. Smoking
2. Tumor factors
   a. Unknown margins
   b. Goals of reconstruction may become palliative
3. Surgical factors
   a. Large defects involving bone may make Alloderm inadequate in isolation.
   b. Infection

PREOPERATIVE PREPARATION

1. Evaluations by
   a. Oncologic surgeon if necessary
   b. Oncologists (radiation, medical and dental oncology) if necessary
   c. Reconstructive surgeon
   d. Anesthesiology

Operative Period

ANESTHESIA

- General

POSITIONING

- The entire face and neck are sterilized and draped in the usual fashion.
- The surgery is done with the patient in a supine position.

PERIOPERATIVE ANTIBIOTICS

- Ideally, they are administered during induction of anesthesia and continued for 24 hours.
- Choices
  - Cefazolin
  - Clindamycin
  - Vancomycin
  - Ciprofloxacin

MONITORING

- Routine anesthesia care

INSTRUMENTS AND EQUIPMENT TO HAVE AVAILABLE

- Basic soft tissue set

PREREQUISITE SKILLS

- Basic head and neck surgical skills

OPERATIVE RISK

1. Evaluations by:
   a. Anesthesiology and primary team
2. ASA guidelines
3. Depending on other associated portions of the operation, Alloderm alone usually carries low postoperative risk of DVT, PE

SURGICAL TECHNIQUE

- Intraoperative evaluation
  - Soft tissue evaluation
  - Vital structures exposed
- Surgical approach
  - Anatomic landmarks are marked.
  - Defect dimensions are measured and templated when appropriate.
  - Lidocaine with epinephrine is administered prior to the skin incision for hemostasis.
- Reconstruction using Alloderm
  - Evaluate defect dimensions.
  - Can aid in adding several centimeters of soft tissue bulk
  - Alloderm can be used effectively for smaller volume defects.
  - Need to thaw the Alloderm prior to use
  - It can be kept in sterile saline 10 to 15 minutes prior to inset.
  - Alloderm, adipose tissue, and fascia can be used to add volume in otherwise low-risk coverage areas.
  - It can be used to cover vital structures such as:
    - Exposed neck vasculature post-parotidectomy (Figs. 174.13 and 174.14).
    - Impending cranioplasty exposure. Note areas of thinning dermis on underside of reflected scalp flap, seen in magnified view at upper right corner (Fig. 174.15).

COMMON ERRORS IN TECHNIQUE: ALLODERM

- Insufficient graft bulk leading to inadequate correction of contour
- Excess graft bulk that may require thinning either acutely or in a delayed fashion
- Use as an allograft sling can often lead to stretching over time and loss of corrective effect
- Closure
  - The Alloderm inset site can be closed primarily depending on with or without subcutaneous drain placement

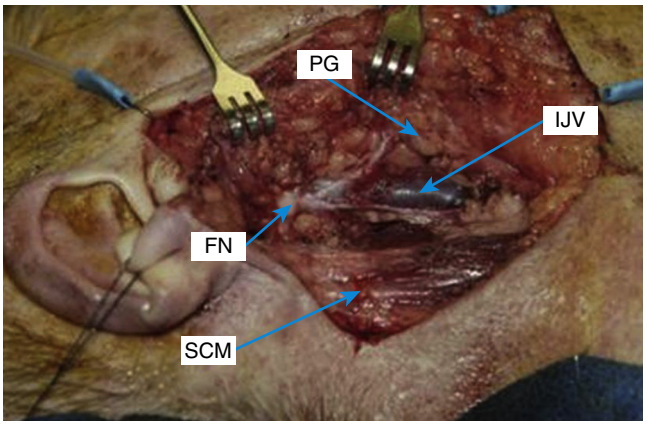

Fig. 174.13. Right soft tissue defect following parotidectomy with exposed neurovascular structures: internal jugular vein (IJV), marginal mandibular branch of facial nerve (FN), sternocleidomastoid (SCM), parotid gland (PG).



Fig. 174.14. Alloderm applied as soft tissue coverage of vital structures in the neck.

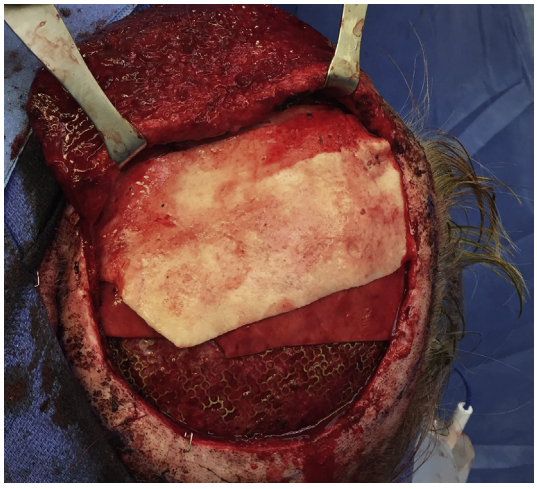

Fig. 174.15. Alloderm placed in subgaleal position to augment impending cranioplasty exposure through scalp. Note areas of thinning dermis seen in upper right magnified inset.

Postoperative Period

POSTOPERATIVE MANAGEMENT

- Typically, an outpatient procedure depending on the nature of concurrent surgeries necessitating allograft placement
- Drains are removed when the volume of output decreases to less than 30 mL over a 24-hour period.
- Perioperative antibiotics are continued for 24 to 48 hours.
- Typically drains are removed 7 days postoperatively.
- Immediate postoperative facial analysis (evaluate inset of FL with overcorrection of tightness of strips)
- Nutrition
  - Oral feeding is typically begun on postoperative day 0.

COMPLICATIONS

- Hematoma
  - Will require immediate evacuation of clot and identification of bleeding source with washout and hemostasis with cautery and or suture ties
- Pain
  - Pain control
  - Postoperative physical therapy
- Seroma
  - Common with using Alloderm and may require drainage and appropriate antibiotic therapy
- Premature graft failure
  - Premature Alloderm stretching when used as sling
  - Suture failure such as "cheese-wiring"
  - Will require outpatient operative exploration and correction

ALTERNATIVE MANAGEMENT PLAN

Patient wishes should be discussed along with all reconstructive options. At times, the less invasive option will be the best option for a patient. Many times, the use of an allograft such as Alloderm is an effective means of bridging the gap between patient reconstructive goals and risk-benefit of more invasive surgical procedures. In cases where this allograft cannot be used, autografts such as adipose tissue, dermatoadipose tissue grafts, or flaps can be used for soft tissue bulk. These modalities range in complexity and associated donor site morbidity.

DISCUSSION

Evidence-Based Medicine Question

Is Alloderm a viable option for soft tissue coverage of the head and neck?[4]

Acellular dermal matrix, or Alloderm, has several desirable properties which have made it useful in the following reconstructions: nasal; tympanic membrane; periorbital; extra and intraoral reconstruction; dura mater; and even soft tissue defects from parotidectomy, improving contour. Additionally, the FL graft and Alloderm are commonly used in the rehabilitation of facial nerve paralysis. They are static techniques used to suspend the soft tissues of the face and can be used alone or in combination with dynamic procedures. Alloderm has the advantage of no donor site morbidity. Both materials require overcorrection of facial symmetry at the time of procedure to account for postoperative stretching. However, in a small study by Boyette and Vural (2010), it was demonstrated that stretching the Alloderm graft prior to implantation required no overcorrection and decreased long-term elongation of the implant.

The following properties of Alloderm are desirable:

- There is no donor site.
- Processing limits immune response.
- It is helpful in augmenting soft tissue defects.
- Helpful in covering vital structures

Editorial Comment

Tensor fascia lata (TFL) and Alloderm are commonly used in the rehabilitation of facial nerve paralysis. They are static techniques used to suspend the soft tissues of the face and can be used alone or in combination with dynamic procedures. Alloderm has the advantage of no donor site morbidity. Both materials require overcorrection of facial symmetry at the time of the procedure to account for postoperative stretching. However, in a small study by Boyette and Vural (2010), it was demonstrated that stretching the Alloderm graft prior to implantation required no overcorrection and decreased long-term elongation of the implant.

Anna Pou

Access the review questions online at http://www.expertconsult.com



ACKNOWLEDGMENT

Case material kindly shared by Dr. Ernest K. Manders.

REFERENCES

1. Neligan PC. 3rd ed. Plastic Surgery, vol. 1. St. Louis, MO: Saunders; 2013. Principles. Edited by Peter C. Neligan Chapter 32.
2. Wei FC. Flaps and Reconstructive Microsurgery. 1st ed. St. Louis, MO: Saunders; 2009. Section One. Principles of Reconstructive Surgery. Edited by Geoff Greenwood et al.
3. Thorne CH. Grabb and Smith's Plastic Surgery. 7th ed. Philadelphia, PA: Lippincott Williams & Wilkins; 2014. Chapter 31. Reconstruction of the Scalp, Calvarium and Forehead. Edited by Charles Thorne.
4. Shridharani SM. A systematic review of acelluar dermal matrices in head and neck reconstruction. Plast Reconstr Surg 2012;130: 35–45.

REVIEW QUESTIONS

1. When employing fascia lata as a fascial sling, it is important to
   a. Overcorrect intraoperatively
   b. Undercorrect intraoperatively
   c. Use wide strips
   d. Double layer strips

2. Indication for the use of Alloderm in facial reconstruction is
   a. Soft tissue reinforcement
   b. Infected field
   c. Coverage of vital structures
   d. a and c
   e. All of the above

175 Split Calvarial Graft

Catharine B. Garland, Jesse Goldstein, Joseph Losee

INTRODUCTION

Calvarial graft may be the preferred bone graft for reconstruction of much of the craniofacial skeleton. Both cortical and cancellous bone can be harvested in relative abundance. Cortical calvarial bone graft is pliable, allowing for reconstruction of the complex three-dimensional contours of the facial skeleton. It is thin for orbital grafting and strong for recreation of the facial buttresses. These attributes make it ideal for both primary and secondary reconstruction after facial trauma and for reconstruction after tumor extirpation. Furthermore, when a coronal incision is already being used for exposure of the fracture or defect, using calvarial bone graft for reconstruction requires no additional donor site incisions.[1-3]

Calvarial bone graft may be harvested in several different fashions depending on the needs of the operation and the patient. We will review the standard harvest of a parietal bone graft through a coronal incision.[4] Other incisions may be used, such as a parasagittal incision in the hair-bearing frontoparietal scalp. We discuss harvesting cortical and cancellous graft as a split graft in situ, via an intracranial approach in which the graft is split ex vivo, and our preferred methods for harvesting particulate bone graft. A large quantity of particulate bone graft is available from the calvarium, which we have found particularly effective in reconstructing calvarial defects.

Using calvarial graft to reconstruct calvarial defects allows one to replace like with like. This is nearly always favorable to prosthetic reconstruction when possible, especially in the growing skeleton. Split calvarial bone graft can be used in older children and adults who have a well-developed diploic space. Using a template from the contralateral skull leads to a symmetric autologous reconstruction. In the infant and young child, full-thickness calvarial bone graft may be harvested to reconstruct a defect. Young infants may regenerate the donor site defect fully when there is an intact, healthy dura below. Although regenerative capacity is thought to diminish with age, we have been successful reconstructing full-thickness defects with particulate bone graft in all ages using protected bony regeneration.[5,6]

KEY OPERATIVE LEARNING POINTS

1. Parietal bone is usually thick with less curvature than other areas of the calvarium. Parietal bone is therefore the most common calvarial graft donor site.
2. Calvarial graft may be split in situ or ex vivo. When splitting calvarium ex vivo an intracranial approach is used and neurosurgical assistance is recommended.
3. Full-thickness calvarial bone graft may be used for reconstruction of the zygoma in trauma or in congenital anomalies.
4. Calvarium may also be used as particulate bone graft. Cortical bone may be harvested for particulate graft, or cancellous bone from the diploic space may be used when splitting the bone.

PREOPERATIVE PERIOD

History

1. Surgical history: Does the patient have a history of prior surgery on the scalp or skull?
2. Bleeding history: Bleeding from the scalp incision and bone graft harvest site can lead to moderate blood loss and possibly require blood transfusion. Screen all patients for a history of bleeding disorders and for the use of aspirin, nonsteroidal anti-inflammatories, and other antiplatelet agents.

Physical Examination

1. Evaluate the scalp for scars that may impact the vascularity of the scalp flaps.
2. Palpate the skull for any bony irregularities or defects.

Imaging

Computed tomography (CT) scan is recommended for preoperative planning. Bone windows with coronal, sagittal, and three-dimensional (3D) reconstructions are ideal. Carefully evaluate the coronal images for the thickness of the native parietal bone and the width of the diploic space where one intends to split the bone. This careful preoperative planning can help avoid injury to the dura or venous sinuses during the operation.

Indications

1. In situ split calvarial graft: This may be performed in the adult patient with thick calvarial bone and a well-formed diploic space.
2. *Intracranial* ex vivo split calvarial graft: This is a better option for pediatric patients in whom the diploic space may be thin or poorly formed. When preoperative CT scan demonstrates irregularity of the bone, splitting the graft ex vivo is also preferable. Performing this as a team approach with a neurosurgeon is recommended.
3. *Particulate* calvarial bone graft: This technique may harvest a large quantity of particulate bone that is useful for reconstructing calvarial defects or for filling other bony spaces. We mix the particulate bone with several milliliters of blood from the field prior to packing this bone into the defect.
4. Calvarial reconstruction: Calvarial defects may be reconstructed either with full-thickness or split cortical graft or with particulate bone graft harvested from the calvarium. Even large defects may be filled with particulate bone graft if the underlying dura is healthy and the regenerate is protected.

Contraindications

1. Age less than 10 years is a relative contraindication for split calvarial bone graft. In this age group, the diploic space may

not be well formed, and the bone may not be able to be split. High-resolution bone CT scan can inform preoperatively of when, or where, split calvarial bone grafting is possible.

Preoperative Preparation

Preoperative laboratory studies, including complete blood count, basic metabolic panel and coagulation studies
Type and cross for blood
Blood donation for donor-directed blood if desired

OPERATIVE PERIOD

Anesthesia

General

Positioning

Supine: The patient's head is usually placed on a gel donut for stabilization. Ensure that the endotracheal tube is secured well and that the sterile drapes are placed to allow the surgeon to move the head in the operating room as needed.

Perioperative Antibiotic Prophylaxis

First-generation cephalosporin

Monitoring

Two large-bore peripheral intravenous lines are placed, given the potential risk of blood loss.
An arterial line is commonly used for intraoperative monitoring.

Instruments and Equipment to Have Available

Raney clips
Wide Obwegeser periosteal elevators
Straight and curved osteotomes
Thin, sharp osteotomes for splitting the bone
Bone bending forceps
Bone holding forceps
Bone cutter
Power drill/burr/saw
Safescraper bone scraper (Osteogenics Biomedical)
Hemostatic agents of choice (e.g., thrombin, Gelfoam, Surgicel, Tisseel, Floseal).

For intracranial approach:
Craniotome
Penfield dural elevators
Malleable retractors
Cranial fixation system: wire, plates, mesh, screws

Key Anatomic Landmarks

1. The parietal bone is most commonly used as the donor site. The bone to harvest should be marked at least 1 cm posterior to the coronal suture and 1.5 cm lateral to the sagittal suture (Fig. 175.1). This ensures that the surgeon is harvesting bone of adequate thickness away from the dural venous sinuses and major perforating vessels.
   a. Parietal bone is an advantageous donor site for many reasons: It is thick, it has less acute curvature than occipital or fontal bones, and any irregularities in the parietal area are likely to be covered by hair.
   b. If frontal bone is being harvested, ensure that the donor site is cephalic to the level of the frontal sinus and behind the hairline. This avoids complications associated with the sinus and ensures that any bony irregularities are more likely to be hidden by the hair.
2. A coronal incision should typically be made at the level of the ear (Fig. 175.2) just posterior to the coronal suture. The incision should not be too far anterior so as to allow some distance between the incision and the hairline. In men with male pattern baldness or at risk for male pattern baldness, the incision should be made somewhat more posteriorly to reduce its visibility. It should contain zigzags so that the hair will be able to grow over it.

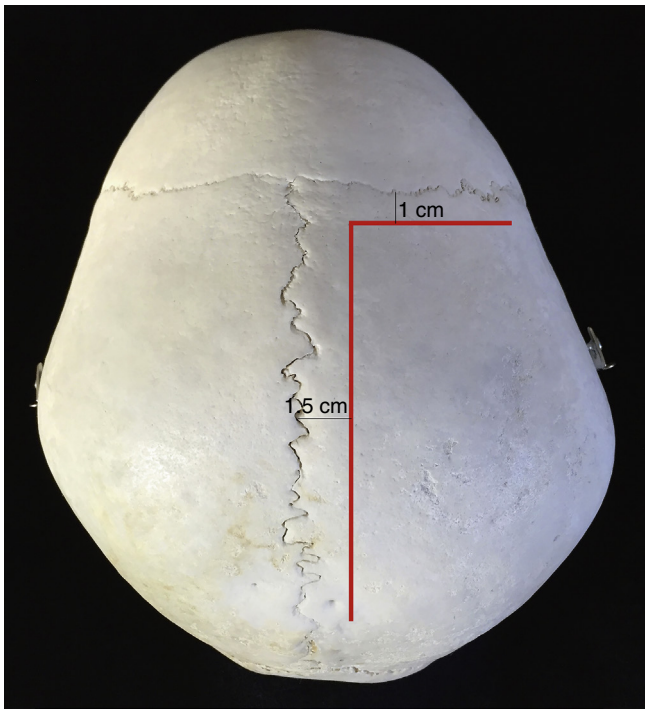

Fig. 175.1. Landmarks for marking a parietal bone graft. Bone should be harvested at least 1.5 cm lateral to the sagittal suture and 1 cm posterior to the coronal suture.

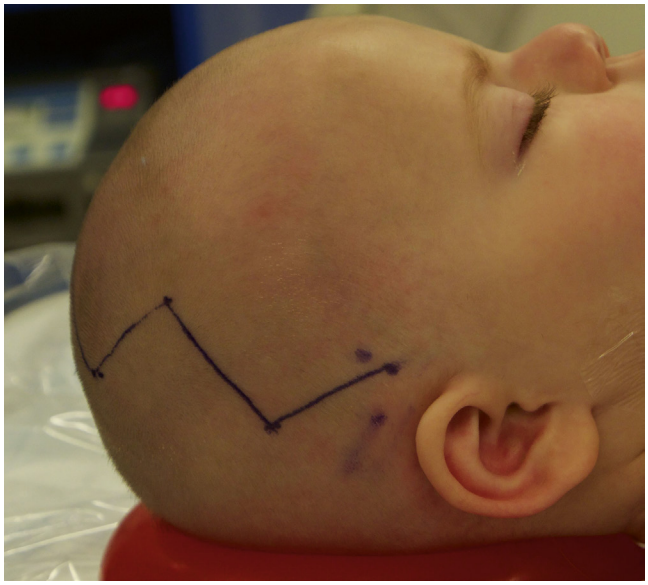

Fig. 175.2. Coronal zigzag incision for harvesting bone graft.

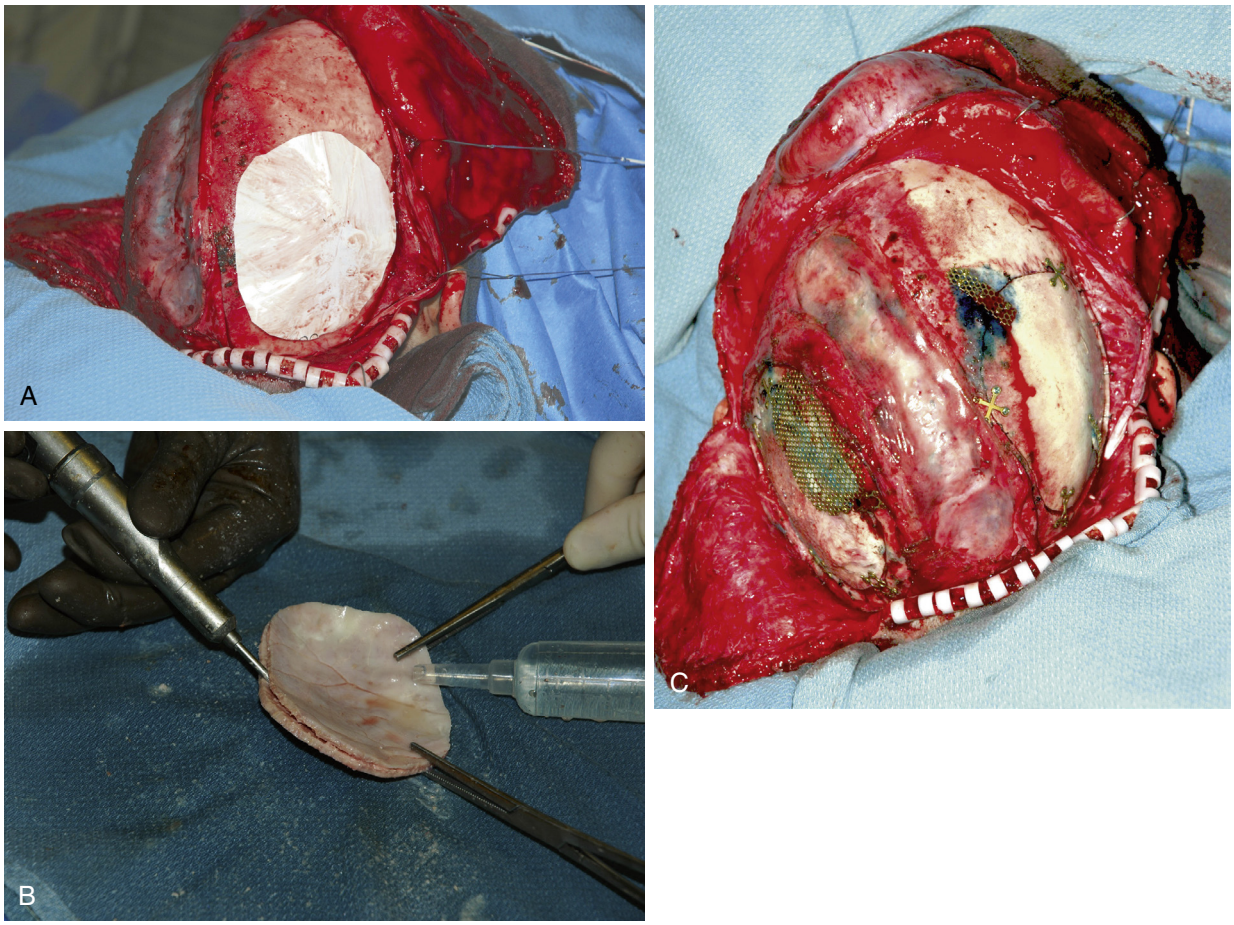

Fig. 175.3. Intracranial approach to split calvarial bone graft for reconstruction of a calvarial defect. A, Left parietal skull defect, with a template made for harvest of a right-sided parietal bone graft. **B,** After removing the right-sided parietal bone, it is split ex vivo using a sagittal saw and copious irrigation on the back table. **C,** Calvarial reconstruction with half of the split bone graft placed back into the right-sided donor defect and half reconstructing the left side of the skull.

Prerequisite Skills

Coronal exposure to the craniofacial skeleton
A team approach with a neurosurgeon is recommended for cases in which the intracranial approach is planned.

Operative Risks

1. Bleeding, blood transfusion: The scalp, bone, and dura are the primary sources of bleeding. These should be controlled before moving on to the next step. We often use a combination of electrocautery, bone wax, and hemostatic agents such as Surgicel, Gelfoam, thrombin, Tisseel fibrin sealant, and Floseal hemostatic matrix as indicated.
2. Dural tear, cerebrospinal fluid (CSF) leak: Dural tears can nearly always be repaired with sutures or a dural patch at the time of injury. It is imperative that a dural tear is recognized and repaired to prevent a CSF leak.

Surgical Technique

1. The zigzag coronal incision should be marked (see Fig. 175.2) and the hair shaved along the incision. The hair and scalp should be washed with chlorhexidine scrub, and the hair should be combed. Often sterile surgical lubricant or bacitracin ointment is helpful in keeping the hair away from the surgical incision. In women or with longer hair, the hair may need to be secured in multiple places with small rubber bands.
   a. An alternative approach for harvesting a smaller piece of bone graft is to use a short straight or curvilinear incision directly over the harvest site on the parietal skull. This is often in a parasagittal location.
2. Infiltrate the scalp incision with a dilute epinephrine-containing solution (5 to 10 mcg/mL) to reduce the risk of bleeding.
3. Use a blade to open the scalp through the galea. Cautery should be used judiciously to avoid injury to the hair follicles near the incision. Raney clips are a useful adjunct for bleeding from scalp edges.
4. The scalp should be elevated in the subgaleal plane, leaving the pericranium intact over the bone.
5. Incise the periosteum with knife or electrocautery. Using wide Obwegeser elevators, raise a pericranial flap. If you are harvesting a parietal bone graft, it may be easiest to raise a laterally and inferiorally based flap. In other circumstances you may wish to raise the pericranial flap based anteriorly along the frontal bone or posteriorly toward the occiput.
6. Mark the proposed graft and harvest the bone.
   a. Intracranial approach, splitting the bone ex vivo (Fig. 175.3):
      1) Neurosurgical assistance should be requested with this approach.

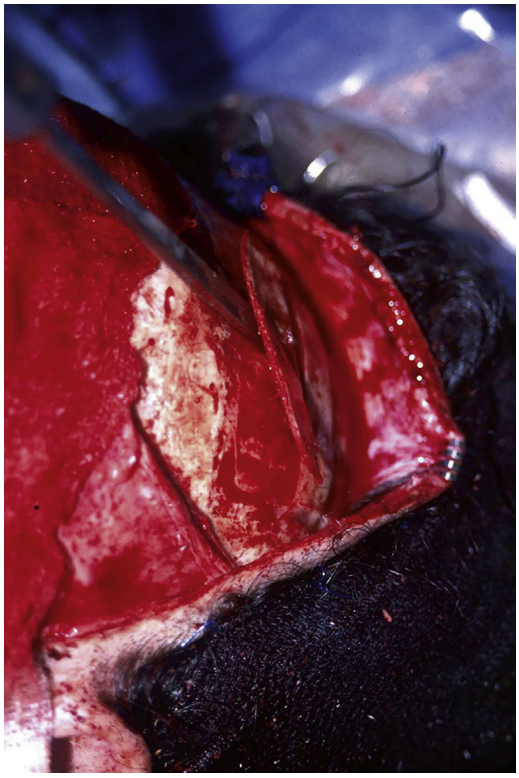

Fig. 175.4. Harvesting split calvarial graft in situ. The osteotome is placed tangent to the bone to split and remove a strip of graft. Subsequent strips are removed in the same manner.

2) Burr holes are made as needed for adequate exposure to free the dura along the planned craniotomy incisions.
3) Penfield elevators are used to free the dura from the inner table of the bone.
4) The craniotome is used to complete the craniotomy and the bone flap is carefully removed.
5) Irrigating bipolar cautery and hemostatic agents are used as needed to achieve hemostasis of the dura and bony edges.
6) On the back table, the parietal bone flap is then split. This is ideally performed using gradually increasing sizes of sharp straight and curved osteotomes.
   a) For thick bone, a reciprocating saw may be used to harvest cortical graft. The bone and saw are copiously irrigated throughout the process. When a power saw is used, understand that the cancellous diploic bone is likely to be injured.
7) Half of the split bone is placed back onto the dura to reconstruct the calvarial defect and is fixated either with wires or small plates. In children, we use Vicryl or polydioxanone suture instead of wire and a resorbable plate fixation system.
8) The burr hole defects may be filled with particulate bone graft or cancellous bone from the graft harvest.

b. In situ split-thickness bone graft (Fig. 175.4)
   1) A side-cutting burr or reciprocating saw is used to make this osteotomy through the outer table at the site of your proposed graft harvest. The diploe should be visible.
   2) A 5-mm narrow strip of bone is removed first. This allows placement of the osteotome tangent to the calvarium so that the bone can be split. Progressively larger sharp straight and curved osteotomes from 8 to 15 mm in width are used, to separate the outer table. Typically the parietal bone is harvested in strips of up to 20 mm in width.
   3) Cancellous bone from the diploic space may also be harvested, either as sheets using an osteotome or as particulate bone graft using curettes.
   4) The edges of the donor site may be burred down to create a smoother transition.
   5) Gelfoam or Surgicel is often placed over the donor site to decrease bleeding.

c. Particulate bone graft (Fig. 175.5)
   1) Cancellous bone may be harvested by curette in pieces or by osteotome in sheets during either of the previously discussed techniques when split cortical bone is used.
   2) The Hudson brace hand drill and bit (see Fig. 175.5A and B) are traditionally used to harvest particulate bone from either the ectocortex of the bone or the endocortex in the case of the intracranial approach. This bone may be collected in a specimen cup and mixed with blood from the field until needed to fill the defect.
   3) We have found the Safescraper device (see Fig. 175.5C) to be a less cumbersome way to capture particulate bone graft from the calvarium. This device is scraped along either the inner or outer cortical surface of the bone. It captures thin ribbons of bone in a 2.5-mL collection canister. This is then easily emptied into a larger specimen container on the field. When adequate bone has been harvested, it will be mixed with blood from the field until use.
   4) Particulate bone is used to fill any calvarial defects left from graft harvest. For larger defects, protected bone regeneration is performed by packing the particulate bone graft between the dura and a bioresorbable mesh or between two sheets of mesh, as the situation dictates (see Fig. 175.5D).

7. The pericranial flap that was created should be placed over the donor site, and absorbable suture may be used to tack it into place.
8. A closed suction drain placed under the scalp flap may be used to prevent blood and fluid accumulation. The galea and skin should then be closed precisely.

Common Errors in Technique

1. Making the coronal incision too anterior: It is more likely to become visible, particularly if baldness develops.
2. Burning the bone with power saws and not using enough irrigation.
3. Not having sharp enough osteotomes to make a clean split.

POSTOPERATIVE PERIOD

Postoperative Management

1. A CBC should be sent postoperatively if there is significant bleeding during the operation.
2. The head should be kept elevated to prevent edema.
3. We typically treat the incision with bacitracin ointment for 1 to 2 weeks postoperatively to optimize healing.
4. When a drain is used, it is typically removed in 2 to 3 days when output has decreased and is serous rather than sanguineous in nature.
5. Any change in mental status should be taken seriously. CT scan of the head is recommended to rule out hematoma or other intracranial complication. Although extremely rare, this serious complication has been reported in the literature.

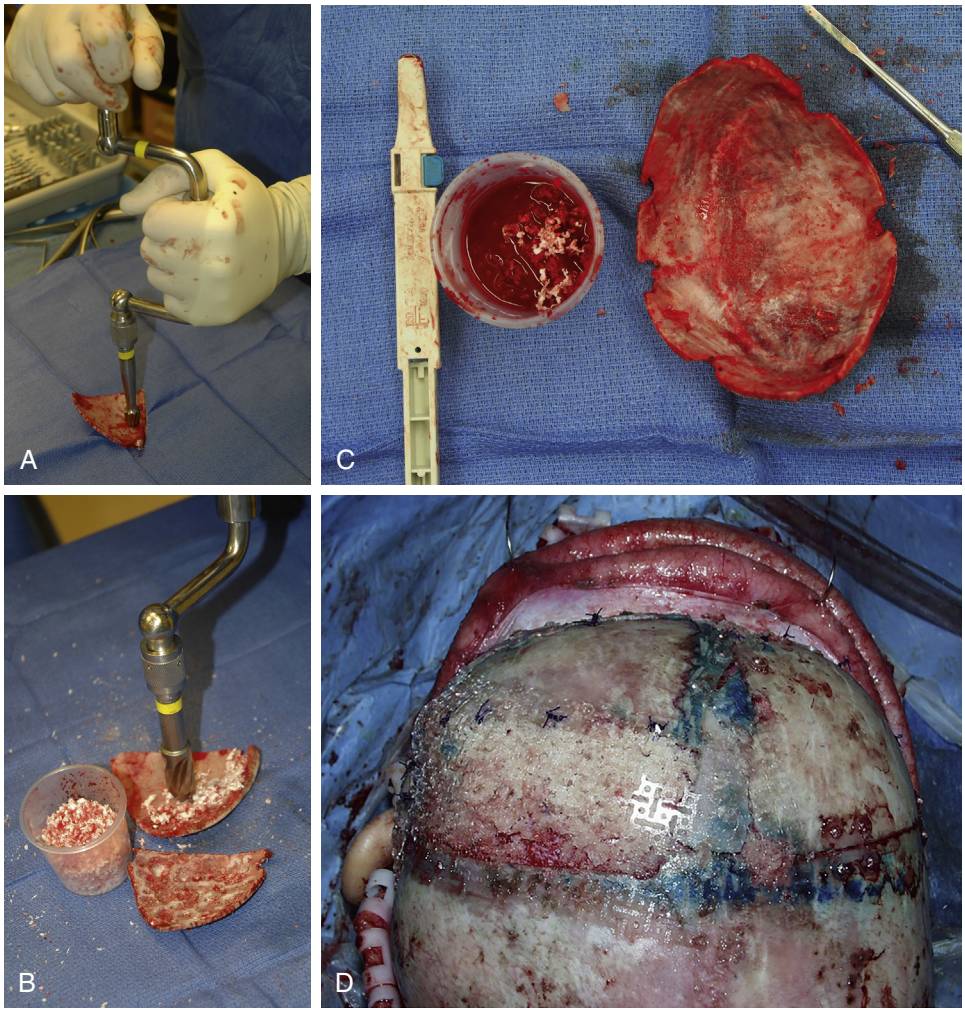

Fig. 175.5. Particulate bone graft. A and **B,** Harvesting particulate bone graft using a Hudson hand brace. **C,** Safescraper device used for harvesting particulate bone graft from the endocortex of a calvarial bone graft. **D,** Reconstruction of a calvarial defect with protected bone regeneration. Particulate bone graft is packed into the defect and protected with a bioresorbable mesh.

Complications

1. Hematoma/seroma: The incidence of hematoma/seroma is approximately 1%. Placement of a closed suction drain may reduce this risk.
2. Hypertrophic scarring/scar alopecia: This can be avoided by minimizing thermal injury along the incision line and meticulous closure of the galea and skin.
3. Calvarial irregularities: These are common in the in situ technique but are typically covered by hair.
4. Bone graft resorption

Alternative Management Plan

1. Alternative bone graft such as rib or iliac crest
2. Prosthetic reconstruction

DISCUSSION

Evidence-Based Medicine Question

What is the incidence of major complication with split calvarial bone graft?

Major complications associated with split calvarial bone grafting are quite rare overall. The most feared complication of operating on or around the calvarium is that of neurologic sequelae from intracranial hematoma or major bleeding from a dural sinus. In a review of 586 bone grafts performed by a single author (Kline et al.), there were no neurologic complications.[7] Furthermore, the authors performed a widespread survey of craniofacial surgeons, finding only three such complications in more than 12,000 calvarial graft harvests. An additional eight complications (four with permanent and four with temporary neurologic injury) were identified. These were all performed by surgeons with no or very limited training in calvarial bone grafting. Other smaller studies support these findings. Canella et al. report on a case in which a sagittal sinus laceration occurred with midline harvest.[8] However, other studies by Posnick et al. and Jackson et al. do not report any cases with neurologic disturbances or major bleeding.[9,10] Minor complications, such as hematoma, seroma, delayed wound healing, and wound infection, are also relatively infrequent occurrences, with the same literature suggesting a rate of 1% to 5%.

Editorial Comment

Calvarial bone grafts are widely used in reconstruction of the head and neck, including calvarial and midface defects. There are several types of bone grafts that may be taken: shaved

corticocancellous outer table graft with attached pericranium; bone paste; split-thickness outer table grafts; and full-thickness parietal bone grafts and inner table grafts taken from a full-thickness bone flap. These grafts can be used in those who will require radiation therapy. The complication rate is overall low as is resorption rate. Harvest is relatively simple, and head and neck surgeons should become familiar with its harvest.

Anna Pou


Access the review questions online at http://www.expertconsult.com

REFERENCES

1. Naran S, Menard RM. Bone grafting: physiology and techniques. In: Taub PJ, Patel PK, Buchman SR, Cohen MN, editors. Ferraro's Fundamentals of Maxillofacial Surgery. New York, Heidelberg: Springer; 2015.
2. Tessier P, Kawamoto H, Matthews D, et al. Taking calvarial grafts, either split in situ or splitting of the parietal bone flap ex vivo—tools and techniques: V. A 9650-case experience in craniofacial and maxillofacial surgery. Plast Reconstr Surg 2005;116(5):54S–71S.
3. Tessier P, Kawamoto H, Matthews D, et al. Taking calvarial grafts—tools and techniques: VI. The splitting of a parietal bone "flap." Plast Reconstr Surg 2005;116(5):74S–88S.
4. Cornelius C, Gellrich N, Hillerup S, et al: Coronal approach. In Ellis E, Shimozato K, Buchbinder D (eds): AO Surgery Reference. Davos, Switzerland: AO Foundation. Available at https://www2.aofoundation.org/wps/portal/surgery?showPage=approach&contentURL=srg/92/04-Approaches/A70_Coronal-approach.jsp&bone=CMF&segment=Midface&approach=Coronal%20approach&Language=en. accessed 31 January 2017..
5. Rogers GF, Greene AK, Mulliken JB, et al. Exchange cranioplasty using autologous calvarial particulate bone graft effectively repairs large cranial defects. Plast Reconstr Surg 2011;127(4):1631–1642.
6. Chao MT, Jiang S, Smith D, et al. Demineralized bone matrix and resorbable mesh bilaminate cranioplasty: a novel method for reconstruction of large-scale defects in the pediatric calvaria. Plast Reconstr Surg 2009;123(3):976–982.
7. Kline RM, Wolfe SA. Complications associated with the harvesting of cranial bone grafts. Plast Reconstr Surg 1995;95(1):5–13.
8. Canella DM, Hopkins LN. Superior saggital sinus laceration complicating an autogenous calvarial bone graft harvest: report of a case. J Oral Maxillofac Surg 1990;48(7):741–743.
9. Posnick JC, Seagle MB, Armstrong D. Nasal reconstruction with full-thickness cranial bone grafts and rigid internal skeletal fixation through a coronal incision. Plast Reconstr Surg 1990;86(5):894–902.
10. Jackson IT, Adham M, Bite U, et al. Update on cranial bone grafts in craniofacial surgery. Ann Plast Surg 1987;18(1):37–40.

REVIEW QUESTIONS

1. Split calvarial bone graft is harvested from the parietal bone. Significant bleeding is encountered. This is most likely because of which of the following?
   a. The osteotomy was made too anterior.
   b. The osteotomy was made too posterior.
   c. The osteotomy was made too medial.
   d. The osteotomy was made too lateral.

2. Which of the following patients is not a good candidate for reconstruction with split calvarial bone graft?
   a. A 21-year-old with bilateral Le Fort III fractures with comminution and bone loss
   b. A 2-year-old with a left frontal bone defect from trauma
   c. A 38-year-old with comminuted naso-orbito-ethmoid and nasal bone fractures
   d. A 46-year-old with a parietal scalp defect following previous craniotomy

3. A patient who had a coronal approach to bilateral Lefort III fractures, reconstructed with split calvarial bone graft, has alopecia at her incision site. This is most likely because:
   a. The incision was made too anterior
   b. The hair follicles were injured with electrocautery
   c. The galea was not reapproximated
   d. The skin was under excessive tension

176 Rib Graft

Catharine B. Garland, Jesse Goldstein, Joseph Losee

INTRODUCTION

Rib graft is a useful adjunct for the reconstruction of the craniofacial skeleton and can be harvested in multiple forms to fit different situations. Rib graft may be harvested as a long, pliable bone graft. This is commonly used for mandibular reconstruction. It may also be used to reconstruct the bony buttresses of the face after trauma or tumor resection. Rib bone can be split longitudinally through the thin medullary canal using an osteotome. Split rib graft is useful for reconstructing calvarial defects and defects of the midface, such as the orbital floor, where a thin autologous bone graft is ideal.[1,2]

The ribs are also a source of abundant cartilage for reconstruction of the nose, ears, and trachea. Costal cartilage from the ribs is the most common source of donor material for reconstructing the ear in cases of microtia. In secondary rhinoplasty, rib cartilage is often a necessary adjunct for recreating the support structures of the nose because septal cartilage may be weakened or absent in these cases.[3] Finally, ribs may be used as a composite costochondral graft containing both cartilage and bone for reconstruction of the mandibular condyle and for temporomandibular joint arthroplasty. The hyaline cartilage cap can act as a growth center in pediatric patients while withstanding the stresses of the temporomandibular joint.

KEY OPERATIVE LEARNING POINTS

1. Rib cartilage and bone are commonly harvested from the fifth, sixth, and seventh ribs.
2. To maintain thoracic stability, when more than one rib bone graft is required, harvest alternate ribs rather than two sequential ribs.
3. Rib bone cortex is thin and may not allow stable screw fixation. It is best fixated with wires.
4. Costal cartilage may be harvested as a large cartilage block from the synchondrosis of the ribs inferiorly if necessary.
5. After removal of the rib graft, evaluate for injury to the parietal pleura and the presence of a pneumothorax prior to closure.

PREOPERATIVE PERIOD

History

1. Does the patient have a history of prior surgeries or rib graft harvest? This is a common situation in secondary rhinoplasty and secondary bone reconstruction. Although bone and cartilage can regenerate within the periosteal or perichondrial sleeve, the bony regenerate is thin and not of equivalent quality. In addition, performing a secondary harvest from the same site is often more difficult due to the presence of scar tissue. This may lead to an increased risk of penetrating the parietal pleura during the dissection and causing a pneumothorax. We advocate using the alternate side in these instances.

Physical Examination

1. Evaluate for any prior scars on the thorax.
2. Evaluate the shape of the rib cage. Understand that the curvature and location of the rib may differ if the patient has a long and narrow thoracic cavity rather than a short and wide thorax.

Imaging

Imaging is not necessary for rib graft harvest. However, some authors have advocated the use of limited computed tomography (CT) scan of the sternum in older patients prior to cartilage harvest. CT scan can preoperatively estimate the quality of the graft by demonstrating the degree of calcification of the costal cartilages.

Indications

1. Bone (Fig. 176.1): Rib bone graft is useful for mandibular, orbital, and zygomatic reconstruction. It provides an abundant source of relatively pliable bone that also may be split. Split rib graft may be used for calvarial reconstruction.
2. Costal cartilage (Fig. 176.2):
   a. Costal cartilage can provide strong support grafts for cases of difficult primary or secondary rhinoplasty (see Fig. 176.2A and B). It is particularly useful for columellar struts, extended spreader grafts, and dorsal grafts. However, rib cartilage grafts have shown an incidence of warping ranging from 0% to 25% in studies. An alternative is to use rib cartilage for a diced cartilage-fascia graft.
   b. The synchondrosis of the sixth, seventh, and eighth ribs can be harvested as a cartilage block for microtia reconstruction (see Fig. 176.2C and D). A floating rib cartilage is also used to create the helix.
   c. Costal cartilage is also useful for laryngotracheal reconstruction in cases of laryngeal or tracheal stenosis.
3. Composite costochondral graft: This is most commonly used for reconstruction of the mandibular condyle and for temporomandibular joint arthroplasty.

Contraindications

1. Concomitant lung disease—Pain from rib graft harvest may lead to postoperative splinting or shallow breathing. This can increase the risk of atelectasis or pneumonia. Emphasize the importance of postoperative pulmonary toilet in all patients, and exercise caution in those with concomitant lung disease.

Preoperative Preparation

Routine

OPERATIVE PERIOD

Anesthesia

General

Positioning

Supine for the majority of cases

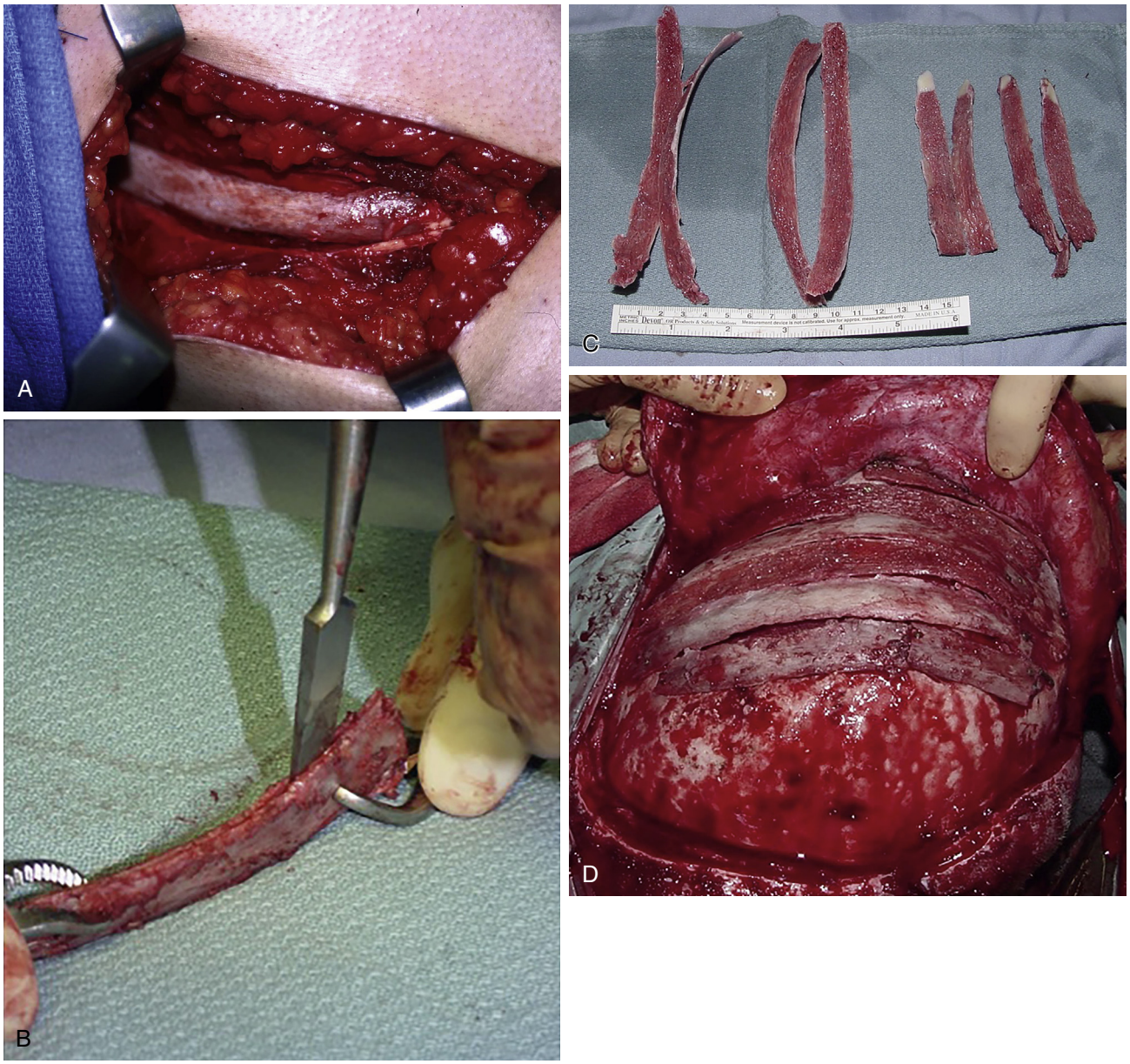

Fig. 176.1. Rib bone graft harvest. A, Rib bone exposed in situ. **B,** Rib bone graft ex vivo, being split with a sharp osteotome. **C,** Several split ribs. **D,** Calvarial defect reconstructed with several split rib bone grafts.

Lateral: When harvesting a longer rib bone graft, it may be helpful to rotate the patient onto the contralateral side to reach the posterolateral portion of the rib more easily.

Perioperative Antibiotic Prophylaxis

First-generation cephalosporin

Monitoring

None necessary

Instruments and Equipment to Have Available

1. Periosteal elevators:
   a. A Cottle elevator or Molt periosteal elevator can be useful early in the dissection. The Cottle elevator can sharply release perichondrium from costal cartilage.
   b. Angled Semb elevators are used as the dissection proceeds posteriorly to reduce the risk of penetrating through the posterior periosteum and producing a pneumothorax.
   c. Doyen elevators complete the dissection and strip the periosteum and perichondrium circumferentially in a continuous fashion.
2. Retractors:
   a. Self-retaining retractors are useful if operating alone.
   b. Long rib retractors, such as Tessier rib retractors or Langenbeck retractors, are helpful for exposure along the length of the rib.
3. Costotome for dividing the rib bone graft laterally
4. Bone holding forceps
5. Bone bending forceps
6. Curved osteotomes for splitting rib when desired
7. Silicone carving block for cartilage grafts

Key Anatomic Landmarks

1. The manubriosternal junction denotes the location of the second rib. This is also typically the first rib that can be

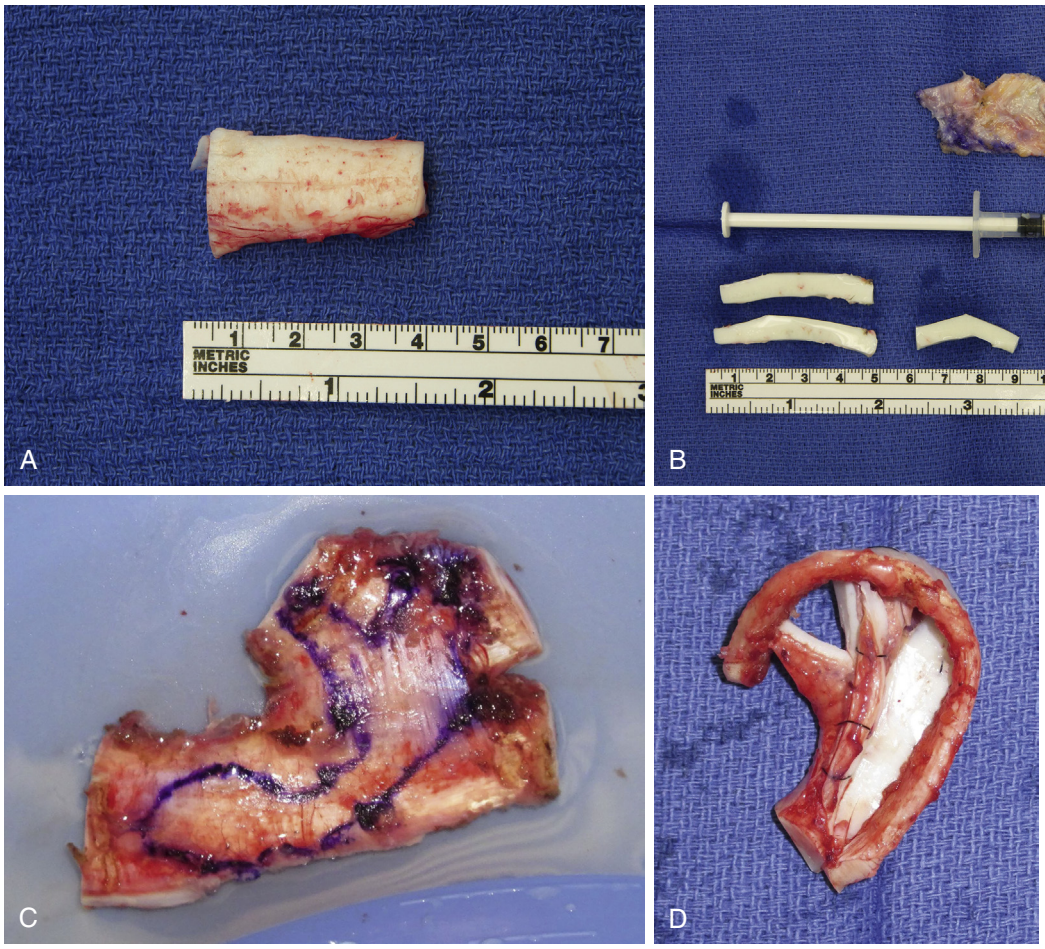

Fig. 176.2. Costal cartilage grafts for rhinoplasty and microtia reconstruction. A, Sixth rib harvested for rhinoplasty. **B,** Cartilage cut into spreader grafts, columellar strut graft, and diced for a dorsal graft. Diced cartilage is placed into a 1-mL syringe for easy filling of a fascial envelope. **C,** Synchondrosis of the ribs harvested for microtia reconstruction. **D,** Cartilage carved and sutured together to create the auricle.

palpated below the clavicle. From here you may count the ribs down along the sternal border to identify the fifth, sixth, and seventh ribs.
2. Identify the costal margin.
3. In female patients, mark the breast fold because you may hide your incision in this fold.

Prerequisite Skills

Gentle dissection technique including elevating periosteum and perichondrium
Manipulation of cartilage and bone
Identification and treatment of pneumothorax

Operative Risks

1. Pneumothorax
2. Injury to intercostal vessels and nerves: Recall that the intercostal neurovascular bundle travels in the costal groove, along the inferoposterior surface of the rib. Take particular caution in this region to avoid injury. Although the bleeding may be a nuisance, it rarely has any long-term effects if injured.

Surgical Technique

1. Mark anatomic landmarks as described previously.
2. Mark your incision (Fig. 176.3A): In women, use the inframammary fold. In men, your incision may be directly over the rib to be harvested. A short 3- to 4-cm incision may be used if it is positioned well. Use appropriate retractors to expose the rib as you work.
3. Incise through the superficial thoracic fascia and dissect directly down to the rib.
4. If harvesting cartilage graft, you will encounter the superior portion of the vertically oriented rectus abdominis muscle and fascia (see Fig. 176.3B). Incise the fascia and retract the muscle fibers laterally to access the costal cartilage below (see Fig. 176.3C). Try to avoid dividing the muscle fibers because this will reduce postoperative pain.
5. Incise the periosteum or perichondrium longitudinally over the central portion of the rib (see Fig. 176.3D). At each end of your planned rib harvest, make a perpendicular incision such that the final incision looks like an "H." Making these perpendicular extensions preserves the perichondrial and periosteal flaps and avoids tearing as you dissect around the posterior surface.
6. Using your elevators, carefully raise the periosteum off of the anterior rib. Over the soft costal cartilage, where it is easy to dissect into the cartilage itself, take care that you are elevating the perichondrium in the correct plane.
7. Use the Semb elevators to dissect out the superior and inferior borders of the rib, moving toward the posterior surface.

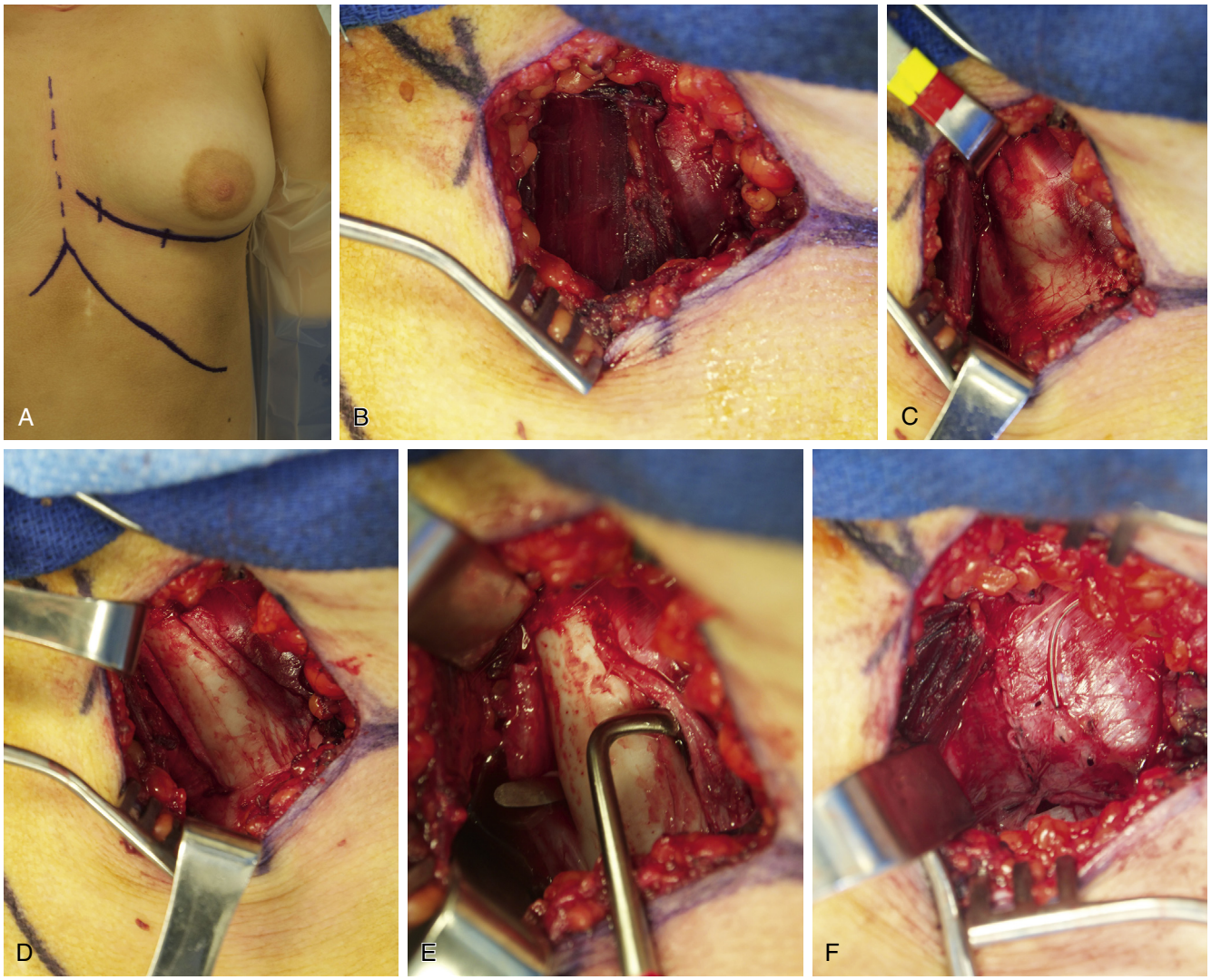

Fig. 176.3. Rib cartilage harvest. A, Landmarks are marked, including costal margin, midline, and inframammary fold. The incision is planned in the inframammary fold to make it less noticeable. **B,** Incise through skin and subcutaneous tissue to the level of the vertically oriented rectus abdominis muscle. Here, anterior rectus fascia was removed for use as a graft. **C,** Retract the muscle fibers laterally to fully expose the costal cartilage with its overlying perichondrium. **D,** Incise the perichondrium along the length of the rib and perpendicularly at each end. Elevate the periosteum fully across the anterior surface first, then continuing to the superior, inferior, and posterior aspects of the cartilage. **E,** The Doyen elevators are placed to complete the circumferential dissection. These are moved medially and laterally along the rib to fully strip the perichondrium from the posterior surface. **F,** After the graft is divided and removed, tightly close the perichondrium. Here we have also placed an indwelling pain catheter for postoperative analgesia.

8. After the dissection has proceeded circumferentially in one area, the Doyen elevators are used to complete the posterior periosteal dissection (see Fig. 176.3E).
9. Use a knife to cut cartilage or a bone cutter to cut the rib close to the costochondral junction.
10. Hold the free edge of bone with bone holding clamps. Complete the subperiosteal dissection laterally to the desired length. The costotome is used to divide the rib laterally.
11. Check for pleural tears by filling the wound with sterile saline and looking for bubbles while the anesthetist performs a Valsalva maneuver.
12. Close the perichondrium or periosteum tightly, and close the fascia and skin in layers (see Fig. 176.3F).
13. Placing a closed suction drain is optional but not usually necessary.
14. Placing a 0.2% ropivacaine pain pump in the wound through multiple fascial layers prior to wound closure reduces postoperative pain.

Common Errors in Technique

1. If harvesting more than one rib graft, do not take two contiguous ribs. Leaving a rib between them preserves the stability of the chest wall. Make the skin incision over the intervening rib. Using this single incision, you can then harvest a rib above and below it.
2. Do not dissect in the subcutaneous plane. All dissection should be down in the subfascial plane, on the rib to be harvested.
3. Failing to have the appropriate retractors prevents the necessary exposure as you dissect medially and laterally.

4. Dissecting too deeply on the posterior side of the rib increases the risk of pneumothorax.

POSTOPERATIVE PERIOD

Postoperative Management

1. Chest radiograph if there is any concern for pneumothorax
2. Continuous pulse oximetry overnight to monitor for desaturation
3. Incentive spirometry and pulmonary toilet. Ambulation as soon as able

Complications

1. Pneumothorax: This is relatively rare, with an incidence of less than 1%.
   a. If detected intraoperatively, place a red rubber catheter into the pleural space as you close the layers of the chest wall tightly. Have your anesthetist perform a Valsalva maneuver as you remove the catheter with your final suture.
   b. A small pneumothorax on postoperative chest radiograph may require no treatment if the patient is otherwise clinically stable. However, treating the patient with supplemental nasal cannula oxygen at a flow rate of 3 to 6 L/min increases the rate of pleural air absorption.
   c. If there is a larger pneumothorax or if the pneumothorax is clinically significant with increased work of breathing, chest pain, or hypoxemia, a pigtail catheter chest tube or small thoracostomy tube should placed to a chest tube suction system, such as a Pleur-evac. The chest tube may be removed when the pneumothorax has resolved in the first few postoperative days.
2. Bleeding: This is usually moderate and easily controlled intraoperatively. Bleeding most commonly occurs from the intercostal vessels. When dissecting cartilage medially, the internal mammary vessel may be encountered. However, harvesting from a more inferior rib reduces the risk of encountering these vessels.
3. Hypertrophic scarring: This is the most common negative outcome associated with rib graft harvest.
4. Chest wall deformity: This is more common when contiguous ribs are used. When harvesting the costal cartilage for microtia repair, the cartilage may regrow asymmetrically.

Alternative Management Plan

1. Alternative cartilage grafts include nasal septum and ear cartilage.
2. Alternative bone grafts such as split calvarial, iliac crest, or tibial bone may be used instead of rib graft.

DISCUSSION

Evidence-Based Medicine Question

What is the incidence of rib cartilage "warping" in rhinoplasty, and what are some strategies to prevent this?

Costal cartilage grafts for rhinoplasty are common; however, complications including warping occur with some frequency. Two reviews of the literature report an incidence of cartilage warping of 5.2%[4] and 3.0%.[4,5] However, individual studies report rates of warping ranging from 0% to as high as 26%. Authors report different strategies to reduce warping; however, the data to support one technique over another are limited at best. Some authors advocate delaying the insertion of the graft for at least 30 minutes after harvest, and others soak the graft in water to allow the cartilage to change prior to insertion. Many authors cut the cartilage such that the most central segment is used. This is devoid of perichondrium and may have some efficacy in reducing the rate of warping. Finally, for dorsal augmentation, rather than a straight piece of cartilage, many surgeons advocate the use of diced cartilage grafts to eliminate the risk of postoperative warping.

Editorial Comment

The use of rib grafts for mandibular reconstruction has largely been replaced with free tissue transfer; however, in those unable to undergo free tissue transfer or in developing countries where resources may not be available, rib grafts remain a viable and good option. Rib grafts can also be used for mandibular reconstruction in the pediatric population, depending on the defect. Extirpative head and neck surgeons should become familiar with this technique for mandibular reconstruction.

Anna Pou

Access the review questions and additional sources list online at http://www.expertconsult.com

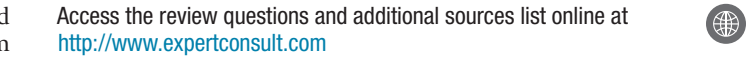

REFERENCES

1. Munro IR, Guyuron B. Split-rib cranioplasty. Ann Plast Surg 1981;7(5):341–346.
2. Tessier P, Kawamoto H, Matthews D, et al. Taking long rib grafts for facial reconstruction—tools and techniques: III. A 2900-case experience in maxillofacial and craniofacial surgery. Plast Reconstr Surg 2005;116(5):38S–46S.
3. Marin VP, Landecker A, Gunter JP. Harvesting rib cartilage grafts for secondary rhinoplasty. Plast Reconstr Surg 2008;121(4):1442–1448.
4. Varadharajan K, Sethukumar P, Anwar M, et al. Complications associated with the use of autologous costal cartilage in rhinoplasty: a systematic review. Aesthet Surg J 2015;35(6):644–652.
5. Wee JH, Park MH, Oh S, et al. Complications associated with autologous rib cartilage use in rhinoplasty: a meta-analysis. JAMA Facial Plast Surg 2015;17(1):49–55.

REVIEW QUESTIONS

1. The intercostal neurovascular bundle is located:
   a. Anterior and superior to the rib
   b. Anterior and inferior to the rib
   c. Posterior and superior to the rib
   d. Posterior and inferior to the rib

2. The most common complication of rib graft harvest is:
   a. Thoracic instability
   b. Hypertrophic scar
   c. Pneumothorax
   d. Bleeding

3. Autologous cartilage for microtia reconstruction may be harvested from:
   a. The second, third, and fourth ribs
   b. The fifth and sixth ribs
   c. The sixth, seventh, and eighth ribs
   d. The ninth floating rib

ADDITIONAL SOURCES

Daniel RK. The role of diced cartilage grafts in rhinoplasty. Aesth Surg J 2006;26(2):209–213.

Naran S, Menard RM. Bone grafting: physiology and techniques. In: Taub PJ, Patel PK, Buchman SR, Cohen MN, editors. Ferraro's Fundamentals of Maxillofacial Surgery. New York: Springer-Verlag; 2015.

177 Cranioplasty

Christian B. Ricks, Brian Jankowitz, Paul A. Gardner

INTRODUCTION

Cranioplasty is the main reconstructive procedure in neurosurgery. Cranial defects can vary widely in size and etiology; they include traumatic, infectious, tumor, vascular, and iatrogenic defects. The majority of large defects created in modern neurosurgery are a result of decompression to relieve uncontrolled intracranial pressure (ICP) following trauma, stroke, or hemorrhage. Although decompressive craniectomy has been shown to decrease ICP and improve survival, the indications, methods, and timing are still controversial.[1] Regardless of the cause, it is generally accepted that nearly all cranial defects should be corrected with bone, mesh, or other rigid material to protect the underlying brain. In addition, cranial defects can lead to pain, significant cosmetic deformity, changes in cerebral metabolism, and perturbations in cerebrospinal fluid (CSF) dynamics, which can impair optimal rehabilitation. Infection and wound breakdown are the primary complication following cranioplasty. Other more serious complications, such as hemorrhage/hematoma, stroke, malignant edema, or seizure, are rare.

KEY OPERATIVE LEARNING POINTS

1. The perioperative management of patients undergoing cranioplasty varies depending on the etiology of the cranial defect.
2. Wide exposure of the entire defect is critical for proper, safe, and cosmetically accurate reconstruction. This is generally best achieved through complete reopening of the prior incision but can present a challenge in the setting of trauma, by which bone may be lost beyond the confines of a standard craniectomy.
3. The entire surgery should remain extradural when possible to avoid further brain injury or complications such as stroke and seizure.
4. Dissection of the temporalis muscle from the underlying dura is frequently challenging, and leaving the deep periosteum adherent to the dura may be the only option in many cases.
5. Care should be taken to avoid transgressing or communication with the frontal (or rarely sphenoid or maxillary) sinuses during exposure for cranioplasty or opening a pneumatized zygoma that can communicate with the mastoid air cells.
6. Complete dissection of the epidural plane to expose the inner cortex of the native skull is critical for replacement of autologous bone or polyetheretherketone (PEEK) implants in contrast to titanium mesh implants, for which only the outer cortex has to be completely exposed.
7. Wide undermining or even rotation of surrounding scalp is occasionally necessary to allow for proper cranioplasty coverage without tension on scalp/skin edges; the latter can lead to wound breakdown and loss of implant.

PREOPERATIVE PERIOD

History

1. A thorough history is important to fully clarify the circumstances that led to the cranial defect. Patient factors that lead to wound healing problems or infection (e.g., diabetes, smoking, immunodeficiency, poor nutrition, ischemic necrosis from a helmet) should be corrected prior to cranioplasty to prevent a recurrent infection or wound dehiscence. Vascular compromise to the scalp flap can be a consequence of vasculopathy, trauma, or poor planning of the incisions. Other sources of potential contamination, such as the sinuses in cranial base defects, should be recognized in order to properly plan the cranioplasty. Finally, the need for further treatment of associated intracranial problems such as hydrocephalus must be understood prior to planning the cranioplasty, since this can affect the timing or complexity of reconstruction.
2. The underlying condition that has led to a cranial defect may require ongoing antiplatelet or anticoagulant therapy. The duration and extent of this issue must be thoroughly understood in planning the surgery. Often, cranioplasty must be performed with the patient on acetylsalicylic acid (ASA) to balance the risk of further vascular incident.
3. The overall condition of the patient and his or her wishes must be fully understood to provide the best result and determine the timing of the cranioplasty. In patients without coincident comorbidities who are recovering well, early cranioplasty can be considered to decrease the risk of infection and hasten recovery. Finally, a clear understanding of the patient's physical capabilities and available support will help to determine the best course of recovery.
4. Details of the course of neurologic or systemic recovery are critical to ensure the proper timing of the cranioplasty. Early cranioplasty can be key in the rare setting of the "syndrome of the trephined" (see further on) to ensure reversal of perfusion deficits or prevent further, delayed herniation.

Physical Examination

1. Patients should be examined for signs of systemic infection or indicators of poor wound healing, such as malnutrition.
2. Evaluation of the wound and the cranial defect is critical in planning for a cranioplasty. If the incision shows signs of ongoing infection or failure to heal, this must be resolved prior to surgery. In addition, any scalp retraction, though rare, should be noted in advance, as this can affect the surgical technique and even the type and size of the cranioplasty material.
3. If the bone has been placed in the subcutaneous tissue of the abdomen, it should be palpated to ensure that it has not resorbed. An anteroposterior abdominal radiograph can be used to evaluate further if there is concern for loss of volume.
4. A thorough neurologic examination is critical in understanding where the patient is in his or her expected recovery. The minor disruption of recovery caused by the repeated anesthesia required for cranioplasty must be balanced against improvements related to ease of mobilization, recreation of normal cranial vault conditions, and even reversal of the "syndrome of the trephined" (see further on).

Imaging

1. Updated imaging is important prior to planning a cranioplasty. Problems such as hydrocephalus, deep infection, and continued edema or hygroma/hematoma formation

must be identified preoperatively to ensure their proper management. Simple, noncontrast computed tomography (CT) is adequate in uncomplicated cases.
2. Vascular problems should be thoroughly understood or completely imaged to clarify their impact on remaining cerebral perfusion, scalp perfusion, the need for continued antiplatelet or anticoagulant therapy, or other treatment of associated conditions such as stenosis, dissection, or aneurysm/pseudoaneurysm. Often, CT angiography or MR angiography is adequate to assess associated vascular anomalies, but if follow-up digital subtraction angiography is warranted for full evaluation, it should be performed in advance of cranioplasty to ensure that further additional treatment is not necessary either prior or in concert with cranioplasty.
3. Any sign of superficial or deep infection should be further evaluated with either postcontrast CT, postcontrast magnetic resonance imaging (MRI) with diffusion-weighted imaging, or lumbar puncture to ensure that there is no contraindication to cranioplasty.

Indications

1. Stroke (Fig. 177.1). Three randomized controlled trials (DECIMAL, DESTINY, and HAMLET) have demonstrated reductions in mortality in decompressive hemicraniectomy (DHC) patients, with more favorable outcomes if performed within 48 hours of stroke onset.[2]
2. Trauma (Fig. 177.2). The controversial DECRA study showed that despite decreasing ICP, decompressive craniectomy (DC) was associated with a worse functional outcome in those managed surgically.[1] The recently released RESCUE ICP clarifies that surgical decompression for traumatic intracranial hypertension leads to lower mortality but higher vegetative states than medical management alone.[3]
3. Tumor or vascular malformations (Fig. 177.3). Defects associated with tumor resection are typically a result of local bone invasion by tumors such as meningiomas; therefore cranioplasty should be planned prior to tumor resection and performed at the same time (Fig. 177.4). This can even be done with planning software to create

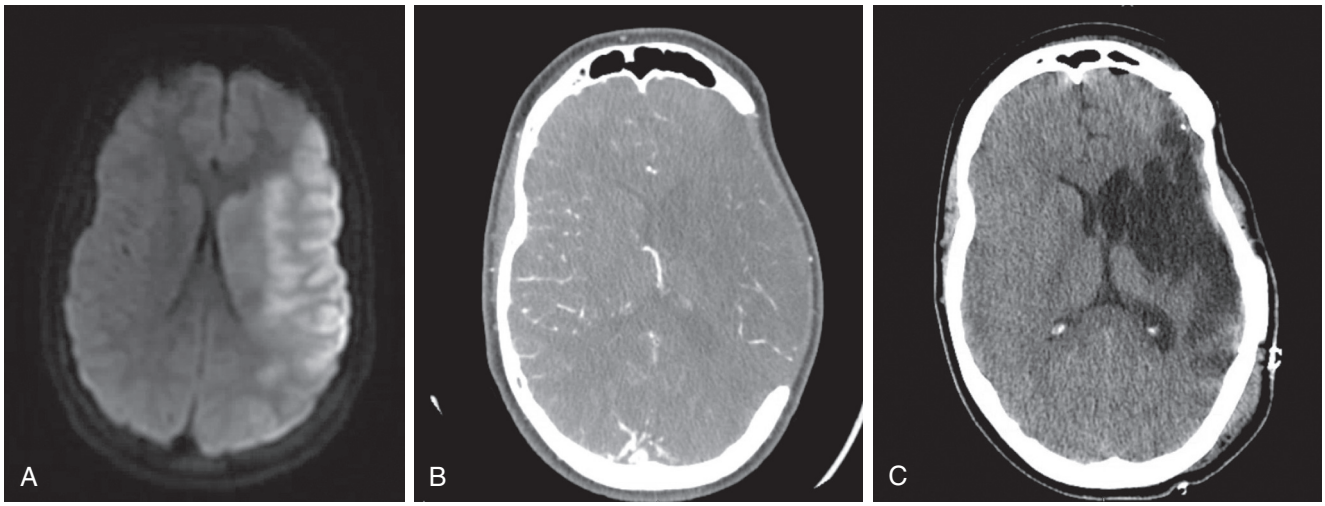

Fig. 177.1. Magnetic resonance imaging, computed tomography, and angiography scans showing, **A,** left middle cerebral artery (MCA) ischemic stroke, **B,** requiring left decompressive hemicraniectomy, **C,** followed by autologous cranioplasty.

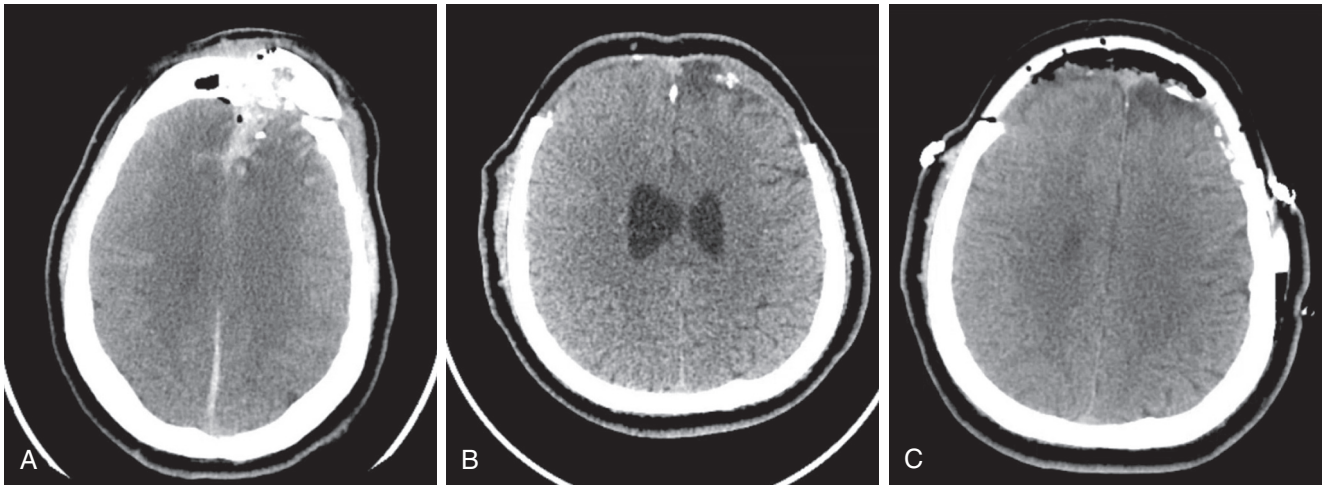

Fig. 177.2. Noncontrast computed tomography scans showing left frontal gunshot wound, **A,** requiring bifrontal decompressive craniectomy, **B,** and polyetheretherketone cranioplasty, **C.**

three-dimensional models and allograft plates in advance. More aggressive pathologies such as sarcomas or invasion of superficial tumors such as squamous cell carcinoma should be considered for delayed cranioplasty, allowing for completion of treatments such as adjunctive radiation without the introduction of nonvascularized cranioplasty materials.

4. Infection (Fig. 177.5). Includes meningoencephalitis, encephalitis, empyema, posttraumatic and iatrogenic or postoperative infection of the bone flap
5. Flap contamination (dropped flap). There is some evidence that sterile washing with antibiotic solution and betadine is adequate to prevent infection in the setting of a contaminated flap.[4] However, if this is not possible or if there is concern about this technique, then an allograft can be used as a replacement.
6. "Syndrome of the trephined" or "sinking flap syndrome" (Fig. 177.6). This occurs in 10% of DC patients.[5] The sinking flap can cause pressure on the underlying cortex affecting perfusion and CSF flow, which can lead to neurologic deterioration. Severe forms can cause "paradoxical herniation," usually exacerbated by CSF diversion.
7. Damage to unprotected cerebrum requiring use of a helmet[6]
8. CSF alterations. DHC can precipitate hydrocephalus, subdural hygromas, and CSF leaks or fistulas, which may improve once the cranioplasty is performed (see Fig. 177.6).
9. Dural sinus thrombosis. This is rarely treated with DHC but may have a prolonged course of increased ICP compared with an arterial infarct, potentially affecting the timing of the cranioplasty.

Contraindications

1. It is essential to rule out ongoing systemic or local infection before proceeding with the cranioplasty. The preoperative collection of seromarkers of infection—including complete blood count, C-reactive protein, and erythrocyte sedimentation rate—is strongly encouraged. A noncontrast head CT or lumbar puncture can also be helpful in screening for active infection. Residual/recurrent intracranial air

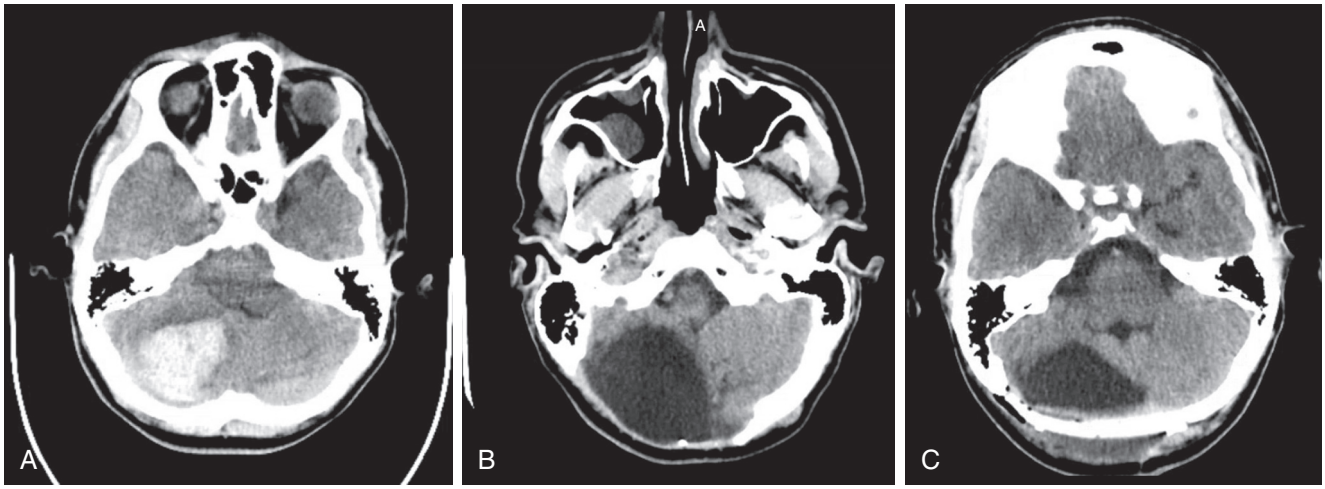

Fig. 177.3. Noncontrast computed tomography scans showing right cerebellar hemorrhage from an arteriovenous malformation, **A,** requiring suboccipital craniectomy, **B,** and polyetheretherketone cranioplasty, **C.**

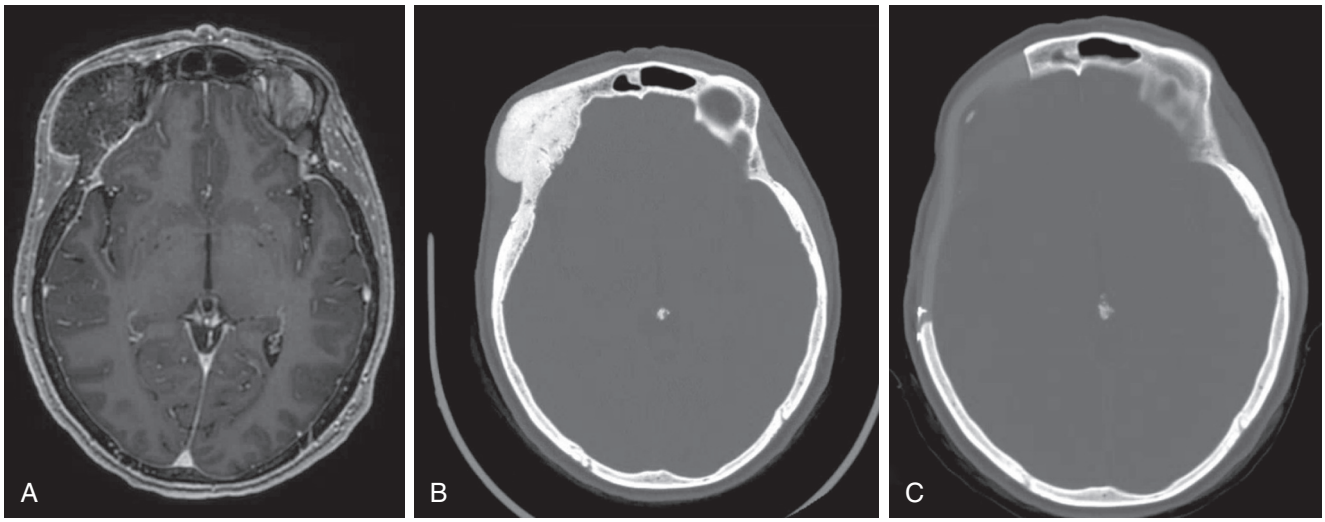

Fig. 177.4. A, Contrast magnetic resonance imaging showing intraosseous meningioma. **B,** Preoperative fine-cut computed tomography of the head, **C,** used to create an allograft polyetheretherketone implant using three-dimensional planning software at the time of surgery.

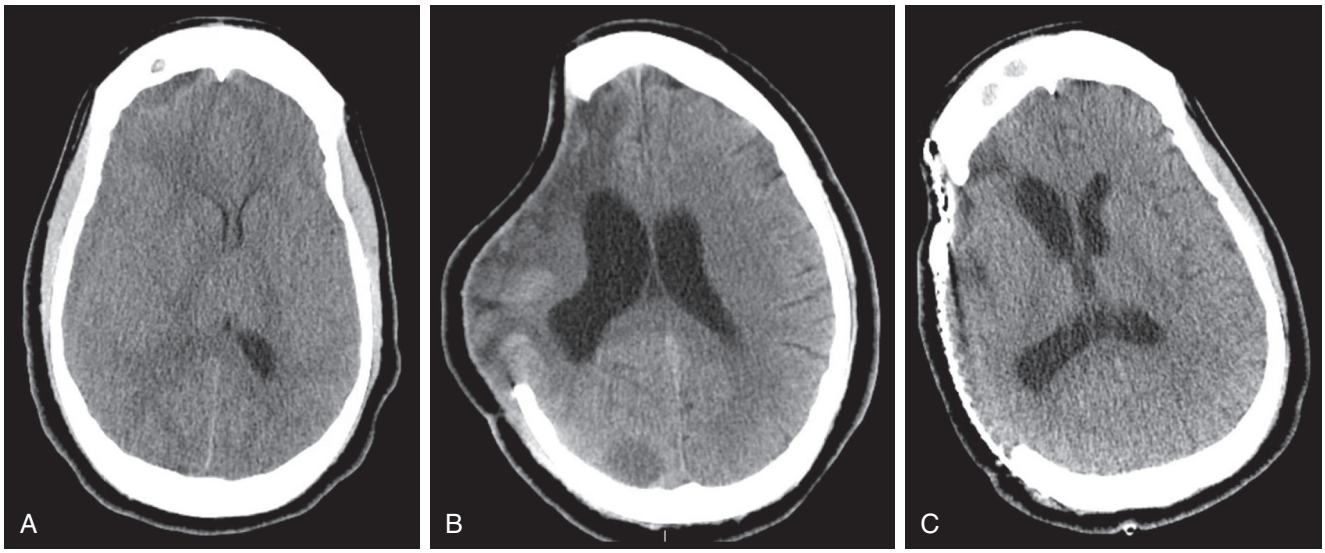

Fig. 177.5. Noncontrast computed tomography scans showing right subdural empyema, **A,** requiring decompressive craniectomy, **B,** and titanium mesh cranioplasty, **C.**

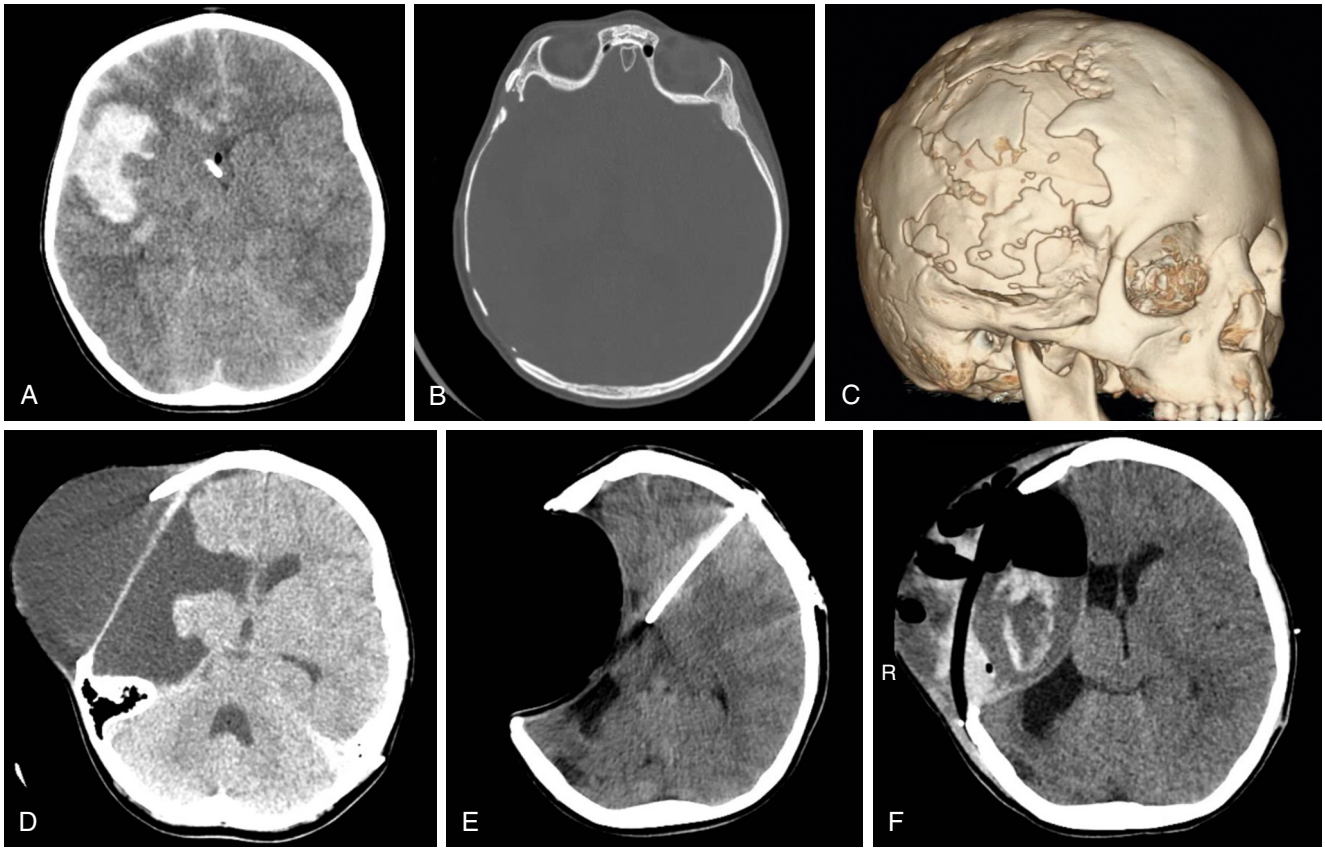

Fig. 177.6. Noncontrast computed tomography scans of a patient with a traumatic brain injury, **A,** requiring right hemicraniectomy. After cranioplasty, bone eventually reabsorbed, **B, C.** Accumulation of extra-axial fluid collection in epidural and subdural spaces as well as hydrocephalus requiring shunting, **D,** followed by sinking flap syndrome, **E,** and postcranioplasty hemorrhage, **F.**

or an elevated CSF white blood cell count is especially concerning.

2. Small areas of ischemia, decubitus ulcers, or suture abscesses causing skin necrosis can usually be addressed through intraoperative skin flap techniques or use of a dermal matrix.[7]
3. Continued symptomatic cerebral edema is an obvious contraindication to cranioplasty. The optimal timing for cranioplasty is typically more than 6 weeks to allow for the resolution of edema or evolution of encephalomalacia. If there is any doubt about the timing of cranioplasty, it should be delayed.
4. Adjuvant treatments such as chemotherapy or radiation should be completed and cranioplasty delayed until systemic or local effects have ceased or been minimized as much as possible. Animal studies suggest waiting at least several weeks after surgery to administer radiation to



Fig. 177.7. Positioning for a left decompressive craniectomy cranioplasty. **A,** Supine with a shoulder roll to allow for moderate head rotation to bring the craniotomy to the apex of the surgical field without impeding jugular outflow. **B,** Surgical site preparation including clipping the hair with area for exiting drain, washing with scrub brush, and wiping with chlorhexidine gluconate cloths prior to ChloraPrep sterilization.

prevent wound complications, but no consensus on the timing of surgery before or after adjuvant therapy exists.[8] A common minimal requirement is to schedule radiation and chemotherapy 2 weeks before and 2 weeks after surgery.

5. Systemic conditions such as diabetes mellitus or smoking must be properly addressed prior to cranioplasty. Evaluation of hemoglobin A1c levels and documentation of adequate glucose control are key for diabetics, and, in general, smoking should be stopped prior to any reconstructive procedure.
6. Multiple repeated intracranial infections, wound breakdown, or failed cranioplasties should be considered as a relative contraindication for further replacement. Indolent infections such as *Propionibacterium acnes* should be explored; these often require observing wound cultures at least 7 days. Rare cases require that patients live long periods of their lives without a bone flap, a condition that is usually but not always safe.
7. Patients who are at high risk for general anesthesia must be carefully assessed to determine their risk-benefit ratio for cranioplasty. Frailty indices such as the risk assessment index (RAI) can be used to help decide whether anesthesia can be performed safely.

Preoperative Preparation and Materials

1. Preoperative evaluation of the cranioplasty material is a necessity. The availability and suitability of the patient's bone flap (if removed and saved in a sterile fashion) or commercial implant are critical to confirm. If the bone flap is placed into the abdomen, a radiograph or CT of the abdomen should be obtained to ensure that the flap has not resorbed.
2. The ideal material for reconstruction in the absence of autologous bone should be biocompatible, inert, osteoconductive, and easy to manipulate yet mechanically resistant. The choice of materials depends on the patient's age, size of defect, underlying pathology, fullness of underlying brain, and surgeon preference.[9]
3. The patient's own bone is the first choice for calvarial reconstruction, given biocompatibility, fit, cost, and strength characteristics. The viability of harvested bone flaps can be preserved through freezing, gas sterilization, or implantation in an abdominal subcutaneous pocket. With the advent of improved sterilization techniques and the adoption of computer-aided allograft creation, autologous bone harvest for split-thickness graft creation is no longer a reasonable option.
4. Alternative materials are generally reserved for cases where autologous cranioplasty has failed (owing to infection or reabsorption), is unavailable, or bone is fractured beyond repair. These materials include synthetics such as PEEK, titanium, and polymethylmethacrylate (PMMA) as well as biomimetics like hydroxyapatite, which behaves like bone and can expand with growth. Preoperative, fine-cut, three-dimensional reconstructive CT scans can be used to create prefabricated custom prostheses,[10] albeit at a significant expense.
5. Larger defects (>25 cm^2) or those in cosmetically important locations should receive custom-made implants, with small defects in hair-covered areas reserved for hand-modeling.

OPERATIVE PERIOD

Anesthesia

1. Neuroanesthesia principles should be maintained and appropriate agents administered to avoid inducing intracranial hypertension. Systemic hypotension should be avoided as well, especially in patients with a history of a prior stroke, as there may be penumbral regions of ischemia or the patient may be at risk for watershed infarcts in the setting of vascular occlusion.

Positioning

1. Proper position depends on the type of cranioplasty being performed. In general, the craniectomy defect should be at the apex of the surgical field, which can usually be accomplished by positioning the patient supine with a horseshoe headrest (Fig. 177.7).

2. The neck should not be overly rotated, and a shoulder roll should be used to maximize rotation of the torso while preventing kinking of the internal jugular vein to maintain intracranial venous drainage.

Perioperative Prophylaxis

1. A single dose of weight-based preoperative cefazolin has been shown to reduce infections in craniotomies and is generally repeated postoperatively for 24 hours. Vancomycin and clindamycin are alternatives in patients with beta-lactam allergies.
2. Given the risk of postoperative seizures in supratentorial craniotomies, a single preoperative dose of an anticonvulsant (usually levitiracetam) is often administered, although there is no evidence to support antiepileptic drugs (AEDs) for a cranioplasty. If the dura is not abrogated and there is no evidence of a postoperative seizure, these medications should be stopped immediately or at hospital discharge.

Monitoring

1. Given the noninvasive nature of cranioplasty, intraoperative neurophysiologic monitoring is generally not required.

Instruments and Equipment to Have Available

A standard craniotomy set generally provides the necessary tools. Additional items to have include the following:

1. Raney scalp clips
2. Bovie
3. Bipolar electrocautery
4. Rubber bands
5. Titanium plating system
6. Hemostatic gelatin powder
7. Sponges
8. Jackson-Pratt drain
9. A dural substitute or dural suture should also be on hand in the advent of a large dural tear.

Key Anatomic Landmarks

1. The necessary landmarks depend on the location of the cranioplasty. For all types of bicortical bone, exposure to the epidural plane must be accomplished circumferentially to allow proper placement of the graft.
2. For hemicraniectomy defects, the circumferential exposure extends inferiorly to the root of the zygomatic arch and sphenoid wing and anteriorly to the superior margin of the frontal sinus. The superior sagittal sinus is sometimes exposed with a hemicraniectomy and always with a bifrontal craniectomy; it should be identified and protected.

Prerequisite Skills

Detailed knowledge of head and neck anatomy and training in head and neck or neurosurgery

Operative Risks

Intraoperative risks include blood loss, dural tears, brain contusion, sinus injury, parenchymal edema and swelling with difficulty placing graft, poor graft fitting or malpositioning, and inability to reapproximate skin from excess tension. See "Complications" further on for complete perioperative risks.

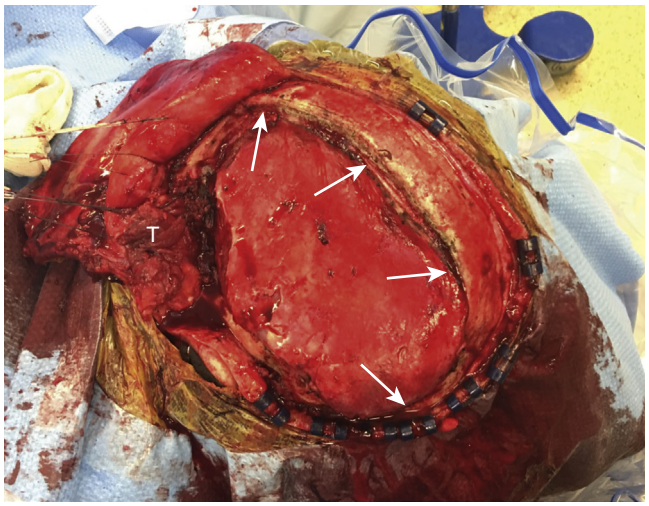

Fig. 177.8. Opening of entire incision, hemostasis with Raney clips, and blunt dissection staying in the epidural plane. Temporalis muscle *(T)* is identified inferiorly above the zygoma and reflected with a myocutaneous flap, followed by circumferential exposure of bicortical bone *(arrows)*.

Surgical Technique

Intraoperative

1. After positioning, the hair is clipped with an electric razor along the prior incision allowing for a small area posteriorly for a drain to be tunneled (see Fig. 177.7) and the surgical field sterilized with chlorhexidine gluconate cloths, followed by ChloraPrep. A complete head shave is not necessary.
2. The original incision is opened in its entirety; bovie electrocautery is used to expose the underlying bone, and Raney clips are placed for hemostasis (Fig. 177.8). Care must be taken in areas where the incision is not over bone so as to stay superficial to the dura.
3. Bicortical bone is exposed circumferentially around the defect. For a standard DHC, this will require extending the dissection inferiorly to the root of the zygomatic arch and anteriorly to the orbital bar and pterion.
4. The myocutaneous flap is gradually dissected from the underlying dura or dura substitute and brought forward to the superficial temporal line. The plane between dura and temporalis is best found inferiorly above the zygoma and is used to elevate the temporalis muscle with the myocutaneous flap. Dissection superficial to the periosteal temporalis layer is sometimes necessary to prevent durotomies, as this vascular layer is generally adherent to the underlying dura or parenchyma.
5. After careful hemostasis, the bone or implant is plated and advanced anteriorly to minimize bone gaps in the most cosmetic locations before securing it to the skull (Fig. 177.9). If a large gap exists in the inferior temporal region, a mesh plate can be added for cosmetic purposes, although small gaps are well tolerated due to the overlying temporalis muscle.
6. Hydrocephalus or persistent cerebral edema may disallow replacement of the flap, particularly if the graft is placed within the defect, as with an autologous or PEEK cranioplasty. In these circumstances, if hyperventilation, head elevation, and mannitol are not enough, then one may consider placement of a temporary external ventricular drain through the open defect in Kocher's point to allow enough CSF drainage to easily place the cranioplasty.

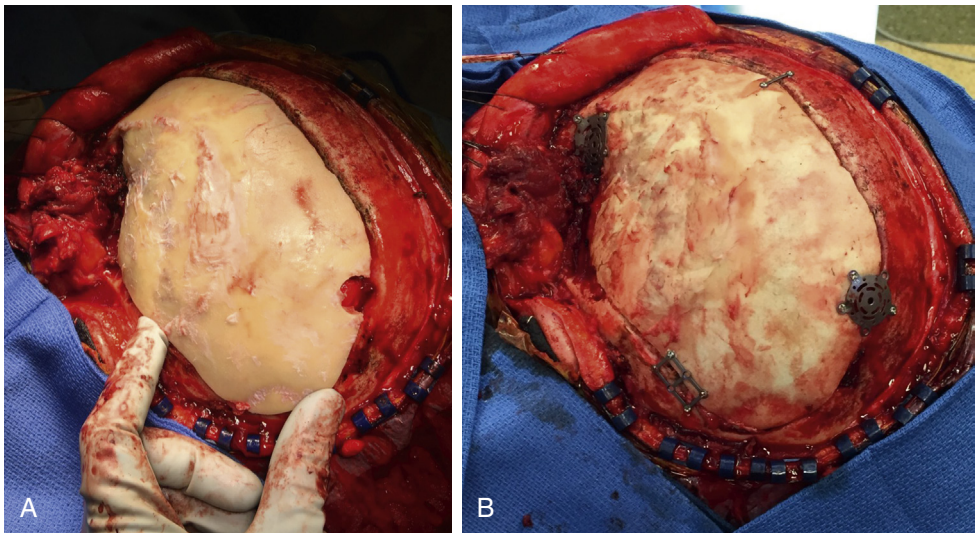

Fig. 177.9. Bone flap is advanced anteriorly, **A,** and plated, avoiding hardware placement under the forehead, **B.**

Closure

1. A 7 or 10 Jackson–Pratt drain is placed below the temporalis muscle for maximal efficacy and tunneled posteriorly. Copious irrigation is followed by closure of the temporalis with interrupted absorbable suture, followed by standard galea fascia approximation using buried interrupted absorbable suture and finally skin closure with either a running Vicryl suture or staples (Fig. 177.10).
2. Larger defects may experience progressive cutaneous retraction, leading to difficulty with closure. This is most commonly encountered along the inferior and posterior limbs of the incision, behind the ear. One should consider approximating this segment first. The incision should have minimal tension to prevent wound healing issues. If the tissue gap is small, parallel incisions in the subgaleal fascia are useful to greater scalp mobility. One may also perform a subperiosteal dissection posteriorly or across the midline to mobilize more scalp tissue for closure. Larger defects may require the use of tissue expanders or plastic surgery assistance. Vertical mattress sutures can be useful for tissue reapproximation and eversion in focal areas of difficulty.



Fig. 177.10. Jackson-Pratt drain tunneled posteriorly is placed beneath retracted temporalis muscle followed by tensionless closure of galea fascia and skin staples for optimized skin eversion.

Common Errors in Technique

1. Dissection superficial to the temporalis muscle is a common error. Leaving the muscle on the dura can create a significant residual mass below the cranioplasty. The loss of its scalp attachment can also precipitate temporalis dysfunction and atrophy.
2. To limit cosmetic deformity after cranioplasty, the graft should be advanced as far anteriorly as possible, titanium plates avoided underneath the forehead, and titanium mesh used for large temporal defects extending to the floor of the middle fossa.
3. Excessive tension of the skin closure can be avoided using subgaleal incisions, galeal fascia reapproximation, and vertical mattress sutures when needed

POSTOPERATIVE PERIOD

Postoperative Management

1. Although the use of preoperative antibiotics has been established to prevent infectious complications in craniotomies, meta-analyses evaluating postoperative duration have revealed no clear association. In general, antibiotics are continued for a total of 24 hours, with cefazolin the preferred agent unless a beta-lactam allergy exists, in which case vancomycin or clindamycin is used.
2. Approximately 14% of patients have postoperative seizures. Factors increasing this risk include male sex, increased age, and graft infection. Unfortunately meta-analysis has not shown a convincing impact on seizure frequency with the use of perioperative AEDs. In patients not already on AEDs, a preoperative single dose is commonly given, with the duration usually lasting until discharged from the hospital.
3. A noncontrast CT of the head is generally advised to ensure proper graft placement and to rule out a subdural hematoma or parenchymal contusion.
4. Restarting antiplatelet agents is generally avoided until outpatient follow-up; however, high-risk patients can

immediately resume such treatment; some studies have even shown no increase in hemorrhagic complications in patients taking acetylsalicylic acid.

Complications

1. Hemorrhage (see Fig. 177.6)—A new ipsilateral hematoma occurs in 3.6% of patients undergoing cranioplasty.[5]
2. Wound healing—The healing of a long flap based on a limited blood supply is exacerbated if the superficial temporal artery is sacrificed. Immobile patients can exert pressure on the wound; this occurs in up to 10% of patients and must be carefully avoided.[5]
3. Infection—3.8% of patients develop abscesses or epidural empyema. Meningitis has occurred in 4.5% and infection of a bone flap 5.4%. Synthetic dura and biomaterials are associated with higher rates of infection.
4. Hydrocephalus, or subdural effusions (see Fig. 177.6)—seen in 5.8% of patients compared with 25% of those following DC[5]
5. Bone resorption (see Fig. 177.6)—occurs in 9.5% of cases and may require reoperation.[5] Long storage time before implantation is a modifiable risk factor.
6. Cranioplasty dislocation—seen in 5.9%
7. Seizures—14% of patients have postoperative seizures, although a proportion of these already have a diagnosis of epilepsy.

Alternative Management Plan

1. Patients with small cranial defects should be considered for observation, since bone ingrowth or scar hyperplasia can eventually cover many small defects. Methylmethacrylate or calcium phosphate–based compounds, which start as a putty and harden within minutes, are another alternative to fill in small defects with an excellent cosmetic result.
2. Patients with very large defects and poor neurologic status, significant comorbid disease, or multiple infections should be considered for chronic helmeting to avoid the risks of additional surgery.

DISCUSSION

Evidence-Based Medicine Question

What factors contribute to periprocedural complications of cranioplasty?

1. Complications—including hydrocephalus, infections, hematomas, bone resorption, seizures, and wound breakdown—are common after cranioplasty, which has a 31% complication rate. One study examining patient variables in 348 cases found, through multivariate analysis, that predictors of complications included hypertension, hemorrhagic stroke, advanced age, diabetes mellitus, seizures, repeat surgery, and bifrontal cranioplasty.
2. Many of these variables are the same, having contributed to the initial pathology requiring craniectomy, and are nonmodifiable. Further investigation regarding the modification of these variables, such as improved glucose control, would be beneficial to alter management strategies.

Editorial Comment

Cranioplasty is a common neurosurgical reconstructive procedure that is best managed using a multidisciplinary approach. In addition to the indications mentioned in the text, cranioplasty can be used in the repair of craniosynostosis, lack of skull expansion, and birth defects. Depending on the situation, the bone may be removed, reshaped, or replaced.

Anna Pou

Access the review questions and additional sources list online at http://www.expertconsult.com

REFERENCES

1. Cooper DJ, Rosenfeld JV, Murray L, et al. Decompressive craniectomy in diffuse traumatic brain injury. N Engl J Med 2011;364(16):1493–1502.
2. Vahedi K, Hofmeijer J, Juettler E, et al. Early decompressive surgery in malignant infarction of the middle cerebral artery: a pooled analysis of three randomised controlled trials. Lancet Neurol 2007;6(3):215–222.
3. Hutchinson PJ, Kolias AG, Timofeev IS, et al. Trial of decompressive craniectomy for traumatic intracranial hypertension. N Engl J Med 2016;375(12):1119–1130.
4. Jankowitz BT, Kondziolka DS. When the bone flap hits the floor. Neurosurgery 2006;59(3):585–90. discussion 585–590.
5. Kurland DB, Khaladj-Ghom A, Stokum JA, et al. Complications associated with decompressive craniectomy: a systematic review. Neurocrit Care 2015;23(2):292–304.
6. Honeybul S. Decompressive craniectomy: a new complication. J Clin Neurosci 2009;16(5):727–729.
7. Cordaro ER, Calabrese S, Faini GP, et al. Method to thicken the scalp in calvarian reconstruction. J Craniofac Surg 2011;22(2):598–601.
8. Patel DM, Agarwal N, Tomei KL, et al. Optimal timing of whole-brain radiation therapy following craniotomy for cerebral malignancies. World Neurosurg 2015;84(2):412–419.
9. Neovius E, Engstrand T. Craniofacial reconstruction with bone and biomaterials: review over the last 11 years. J Plast Reconstr Aesthet Surg 2010;63(10):1615–1623.
10. Goh RC, Chang CN, Lin CL, et al. Customised fabricated implants after previous failed cranioplasty. J Plast Reconstr Aesthet Surg 2010;63(9):1479–1484.

REVIEW QUESTIONS

1. Which of the following statements is true? The optimal timing for a cranioplasty is
   a. 1 to 2 weeks
   b. 6 to 12 weeks
   c. 6 to 12 months
   d. At any time

2. Which of the following is NOT an appropriate cranioplasty graft in the setting of an infection?
   a. Titanium mesh
   b. Polyetheretherketone
   c. Autologous bone
   d. Methylmethacrylate

3. The most likely site of wound breakdown after a cranioplasty is
   a. Anteriormost aspect near the widow's peak
   b. Inferiormost aspect near the zygoma
   c. Superiormost aspect near the sagittal suture
   d. Posteroinferiormost aspect behind the ear

4. Which statement is true regarding perioperative antiepileptic drugs and antibiotics?
   a. Several studies show decreased postoperative complications with perioperative administration.
   b. Studies suggest that preoperative antibiotics but not antiepileptic drugs affect postoperative complications.
   c. Studies suggest that preoperative antiepileptic drugs but not antibiotics affect postoperative complications.
   d. There is no supporting literature for the perioperative administration of either.

ADDITIONAL SOURCES

Alotaibi AF, Hulou MM, Vestal M, et al. The efficacy of antibacterial prophylaxis against the development of meningitis after craniotomy: a meta-analysis. World Neurosurg 2016;90:597–603.

Brommeland T, Rydning PN, Pripp AH, et al. Cranioplasty complications and risk factors associated with bone flap resorption. Scand J Trauma Resusc Emerg Med 2015;23:75.

Cabraja M, Klein M, Lehmann TN. Long-term results following titanium cranioplasty of large skull defects. Neurosurg Focus 2009;26(6):E10.

De Bonis P, Frassanito P, Mangiola A, et al. Cranial repair: how complicated is filling a "hole"? J Neurotrauma 2012;29(6):1071–1076.

Korinek AM, Golmard JL, Elcheick A, et al. Risk factors for neurosurgical site infections after craniotomy: a critical reappraisal of antibiotic prophylaxis on 4578 patients. Br J Neurosurg 2005;19(2):155–162.

Rahman M, Donnangelo LL, Neal D, et al. Effects of perioperative acetyl salicylic acid on clinical outcomes in patients undergoing craniotomy for brain tumor. World Neurosurg 2015;84(1):41–47.

Weston J, Greenhalgh J, Marson AG. Antiepileptic drugs as prophylaxis for post-craniotomy seizures. Cochrane Database Syst Rev 2015;(3):CD007286.

Zanaty M, Chalouhi N, Starke RM, et al. Complications following cranioplasty: incidence and predictors in 348 cases. J Neurosurg 2015;123(1):182–188.

Zanotti B, Zingaretti N, Verlicchi A, et al. Cranioplasty: review of materials. J Craniofac Surg 2016;27:2061–2072.

178 Nerve Graft Techniques

Laura Hetzler, Anna Pou

INTRODUCTION

Neural injury, repair, and subsequent recovery are widely studied, since these topics relate to the entire human body. There are few other regions of the body where impaired nerve function can be more devastating than in the head and neck. Peripheral cranial nerves contribute to our most personal attributes, such as speech, facial expression, and the complex neural coordination of deglutition. The technical aspects of nerve repair have been refined; however, challenges persist in terms of the functional outcomes.

Any patient undergoing head and neck surgery faces risks to multiple cranial nerves. Often in our field, a nerve must be identified and dissected for preservation or resected as part of an oncologic procedure. Oncologic goals supersede the preservation of neural structures when there is curative intent; however, even when the nerve can be preserved, extensive dissection can cause functional issues that may not be entirely relieved.

The facial nerve (FN) is the most commonly reconstructed nerve in the head and neck. The FN is also the most studied in regard to outcomes. The loss of facial expression removes the visible thumbprint of our personalities in day-to-day interactions and can be devastating both emotionally and functionally. Unlike some of the other cranial nerves that are affected in oncologic surgery or even with the removal of benign tumors—such as cranial nerve VIII during acoustic neuroma surgery or the spinal accessory during radical neck procedures—a repair of the FN may be neither indicated nor performed.

KEY OPERATIVE LEARNING POINTS

1. Tension-free repair is imperative. Placing the nerve in a "lazy s" configuration within the wound is helpful to ensure that there is adequate laxity.
2. Preoperative assessment of the patient's smile on the normal side of the face should determine what facial motion and vector are needed to recreate a natural reanimation of the paralyzed side.
3. Success in cross-FN grafting for smile reanimation relies on choosing the appropriate donor nerve that is associated only with movement of the oral commissure and upper lip, that is, the nerve that mimics the preoperative smile of the normal side.

PREOPERATIVE PERIOD

History

Patient Selection

The severity and anatomic location of the injury are important predictors of how or when a repair should be performed.

- The viability of the proximal nerve, distal nerve, and musculature and motor end plates are key variables in the algorithm of neural repair.
- The time from injury to repair plays a key role in designing a reconstructive plan.
- Immediate repair will typically yield the best outcome, as Wallerian degeneration is complete after 3 days, after which the distal nerve segments can no longer be stimulated.
- The patient's goals and wishes must be discussed prior to intervention. Patient expectations must be managed to prepare for incomplete recovery, which can occur even with the best of reconstructive efforts.

Past Medical History

- History of diabetes mellitus and smoking may impair wound healing.
- Medical comorbidities may limit the use of general anesthesia and therefore also the reconstructive options.
- History of soft tissue loss in the face should be noted.
- Negative margins or absence of recurrent tumor must be confirmed.

Past Surgical History

- History of previous FN repairs
- History of previous facial surgeries, including skin cancers
- Surgery performed on potential donor sites

Physical Examination

- Extent of facial paralysis throughout the regions of the face—that is, paresis versus paralysis, upper versus lower division, individual nerve branches
- Presence of soft tissue loss
- Evaluation of donor sites (neck, leg, groin)

Imaging

None necessary

Indications

- Suspicion of injury to the FN with immediate loss of function
- Mechanism of injury consistent with FN disruption
- Resection of FN segment as part of en bloc cancer surgery
- Iatrogenic injury during surgery involving the tissues surrounding the FN

Contraindications

- Chronicity of facial paresis such that the motor end plates associated with the muscles of facial expression are no longer viable
- Resection of distal FN branches and facial musculature
- Comorbidities precluding general anesthesia
- Unrealistic patient expectations as to level of recovery with nerve repair and grafting

Preoperative Preparation

Considerations for Type of Procedure to Be Chosen

- All attempts should be made to do a primary neurorrhaphy when there has been traumatic or iatrogenic injury.
- In the traumatic or oncologic setting, there may be loss of tissue so that the surgeon will be unable to perform a tension-free coaptation. In this situation the patient should be asked for consent to the use of appropriate donor sites for nerve graft harvest.
- Donor nerves are selected based on the caliber, length, and branching pattern needed.
- The anticipated viability of proximal and distal nerve segments will dictate whether or not an interposition graft can be used versus an alternate neural input such as a nerve transposition. Preoperative photos should be taken in order to document a visible deficit.

Surgical Considerations

- Nerve composition may be variable even along the length of the same nerve, depending on the location.
- Presence or absence of a nerve sheath or epineurium may require alternative techniques for nerve repair—that is, FN repair.
- The proximal FN is devoid of a nerve sheath at the cerebellopontine angle. As the seventh cranial nerve travels through the temporal bone, it develops more of a covering. This nerve sheath offers some protection with surgical manipulation, thus allowing the extratemporal nerve to be more resilient to extensive dissection.
- Epineurial repair is the standard technique of neurorrhaphy. Perineurial and endoneurial or fascicular repairs have been discussed; however, they have yet to prove beneficial.

OPERATIVE PERIOD

Anesthesia

- In the situation of early nerve repair where distal branches can be stimulated, the anesthesia team must be advised that no long-lasting paralytics should be administered.
- Epinephrine 1:100,000 should be used without xylocaine if nerve stimulation will be necessary. Most operative suites will have 1:1000 epinephrine available. Dilution to 1:100,000 epinephrine is performed by mixing 0.1 mL 1:1000 epinephrine with 9.9 mL injectable saline for hemostasis without nerve inhibition.

Positioning

- Most of these operations are performed with the patient in the supine position with the donor site exposed.

Perioperative Antibiotic Prophylaxis

Antibiotic prophylaxis should be given according to established guidelines. In the case of a truly clean procedure with no entry into the middle ear or oral cavity, weight-appropriate antistaphylococcal antibiotics should be given preoperatively and discontinued 24 hours postoperatively.

Monitoring

- Handheld nerve stimulator
- Routine monitoring by anesthesia team

Instruments and Equipment to Have Available

- A microscope should be draped and optics arranged to allow appropriate assistance.
- Microinstruments should be used for the handling of neural tissues.
- Nylon suture 8-0 and 9-0
- A blue or green background should be available to allow for tissue discrimination.

Key Anatomic Landmarks

- FN(main trunk):
  - Posterior belly of the digastric muscle: (FN lies 1 cm deep to the medial attachment of the muscle to digastric groove)
  - Tragal pointer (FN lies approximately 1 cm deep and slightly anterior and inferior to pointer)
  - Tympanomastoid suture line (FN lies 6 to 8 mm deep)
- Sural nerve:
  - The nerve is located 2 cm posterior to the lateral malleolus running anterior to the small saphenous vein.
- Medial antebrachial cutaneous (MABC) nerve
  - The MABC nerve runs down the ulnar side of the arm medial to the brachial artery and pierces the deep fascia with the basilic vein.
- Great auricular nerve:
  - Midportion of sternocleidomastoid muscle (SCM) approximately 1 cm from the external jugular vein.

Prerequisite skills

- Proficiency in microsurgery
- Detailed knowledge of FN anatomy

Operative Risks

- Bleeding
- Inability to obtain adequate donor nerve/length
- Inability to locate cut ends of FN branches
- Associated donor site morbidity
  - MABC nerve: injury to median nerve

Surgical Technique

Primary Neurorrhaphy

The best possible outcome after neural injury follows primary neurorrhaphy.[1] Direct coaptation of proximal and distal nerve segments should be performed only if a tension-free neurorrhaphy can be achieved. Standard microsurgical techniques apply, and microscopic magnification should be used.

- Nerve ends should be carefully using microinstruments.
- The nerve ends should be trimmed of necrotic tissue with sharp microscissors or a 15-blade knife stabilized on a firm surface, such as a tongue blade.
- Trimming should proceed in such a fashion that the axons do not extend beyond the nerve sheath. This allows for gentle approximation of the axons end to end.
- A standard epineurial repair done under magnification with interrupted 8-0 or 9-0 monofilament sutures should be performed on a blue or green background, allowing for tissue discrimination and visualization.
- The number of sutures used depends on the location of the nerve as well as its caliber. We typically perform only the number needed to ensure that all fascicles are tucked nicely within the epineurium (Fig.178.1).

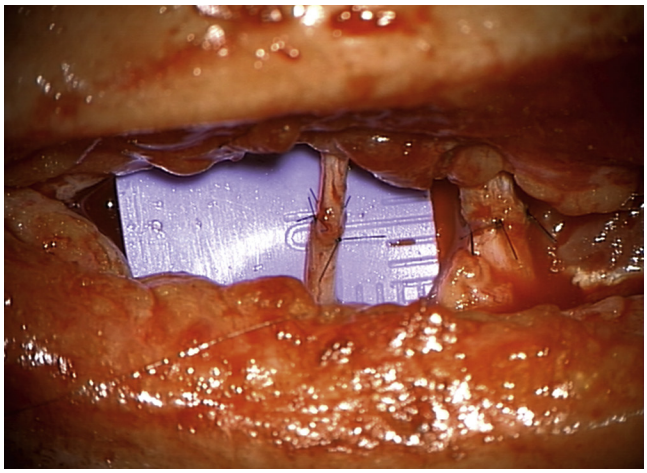

Fig. 178.1. Primary neurorrhaphy of a large buccal branch of the facial nerve following trauma *(left)*. The larger structure in the image *(right)* is a repaired parotid duct.

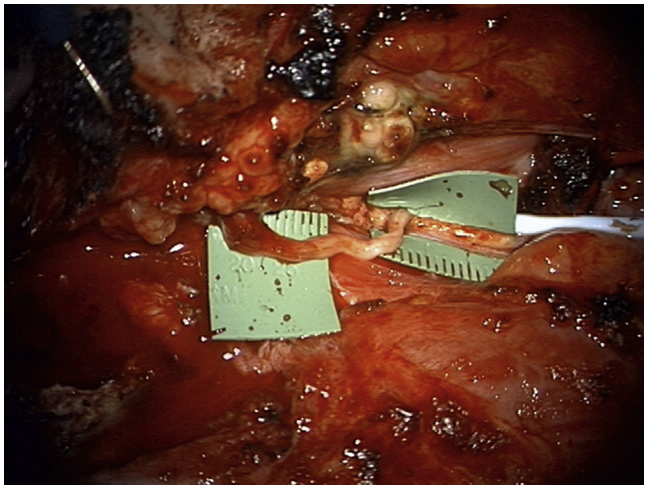

Fig. 178.2. Great auricular nerve cable interposition extending from the main trunk of the facial nerve to the hypoglossal nerve. The patient had a facial neuroma extending to the stylomastoid foramen; therefore a primary neurorrhaphy could not be performed, necessitating an interposition graft. Note the laxity in the bridging nerve.

Interposition Graft

If an intervening segment of nerve is lost and tension-free repair is not possible, an interposition graft is used. The identical microsurgical technique used in primary neurorrhaphy is employed; however, there are two coapted sites on either end of the nerve graft (Fig.178.2).

- The great auricular nerve is the most commonly used nerve graft in the head and neck. Other nerve graft options in these areas include the lesser occipital and transverse cervical nerves.
- If a longer nerve graft is needed, attention may be turned to the upper and lower extremities for donor sites.
  - The sural nerve in the lower extremity is an excellent resource when length is needed.
  - The medial anterior brachial cutaneous nerve in the upper extremity is useful because it has an excellent match to the FN diameter as well as an ideal branching pattern.



Fig. 178.3. Skin markings for locating the great auricular nerve. This nerve will be located at the bisection of a line between the angle of the mandible and the mastoid tip. Notice its proximity to the external jugular vein (prominence seen at the inferior neck).

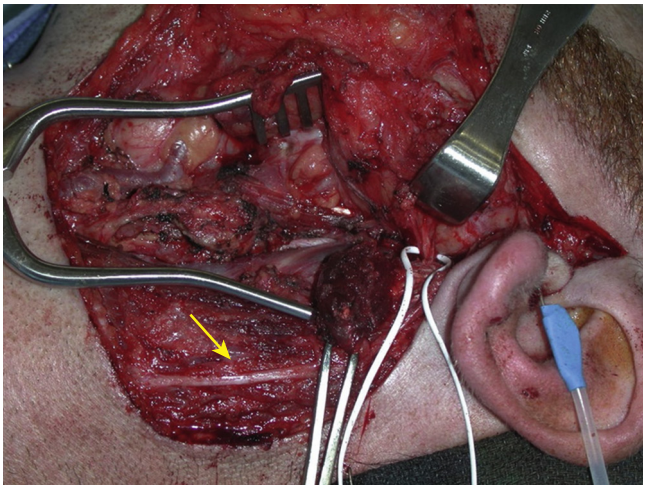

Fig. 178.4. The great auricular nerve seen running anterosuperiorly on top of the sternocleidomastoid muscle *(arrow)*.

Great Auricular Nerve Graft

The great auricular nerve (GAN) is a branch of the cervical plexus that passes reliably over the sternocleidomastoid muscle.

- The GAN passes 1 cm inferior to the external jugular vein.
- Lengths of up to 6 to 7 cm with a distal branching pattern can be harvested.
- The GAN can be located by drawing a line between the mastoid tip and the angle of the mandible. Bisecting this line with a perpendicular line marks the approximate location of the GAN (Fig. 178.3).
- In performing an ipsilateral surgery where a nerve graft may require the use of the GAN, care should be taken when the subplatysmal skin flaps are being raised so as not to damage the integrity of the nerve (Fig.178.4). Consideration must be given to using the contralateral great auricular nerve in the presence of malignancy, where perineural invasion could be present ipsilaterally.

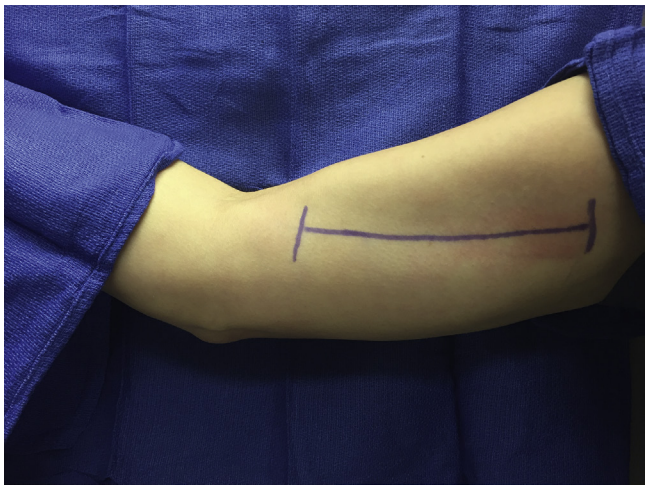

Fig. 178.5. Skin incision marking for harvesting the medial antebrachial cutaneous nerve along the bicipital groove in the upper right arm.

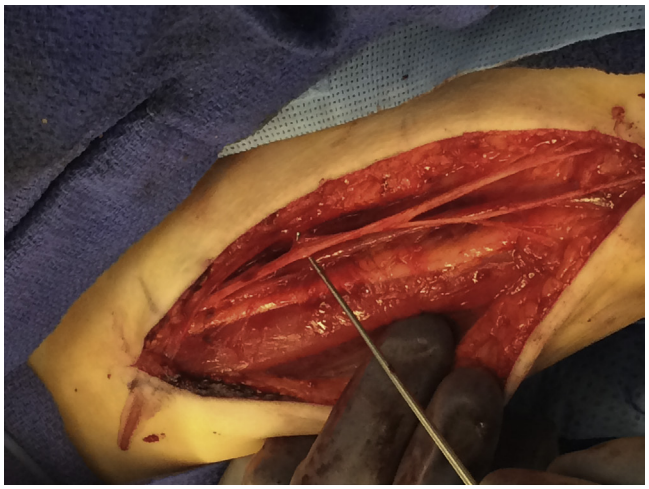

Fig. 178.6. Nerve hook underneath the medial antebrachial cutaneous nerve in the left upper arm. Note the distal branching and the basophilic vein and median nerve deep to the medial antebrachial cutaneous nerve.

Medial Antebrachial Cutaneous Nerve Graft

The MABC nerve is a sensory nerve of the forearm used extensively in the repair of peripheral nerves.

- The MABC nerve is located in the plane between the biceps and the triceps in the upper arm; it has a grafting length of 15 to 25 cm.
- The branching pattern and caliber are similar to those of the distal FN, and donor site morbidity is minimal.
- Recommendations have been made to use epinephrine only so that the median nerve can be stimulated; however, we do not find that imperative for this technique.
- The MABC nerve can be harvested from the elbow to the axilla, depending on the length needed.

Positioning

- A two-team approach is made possible by prepping the arm into the field of surgery at the time of ablation.
- The arm should be positioned in such a way that the surgeon can visualize the ventral surface.

Surgical Technique

- The bicipital groove is the primary landmark and should be marked and injected with local anesthetic (Fig.178.5).
- Incision through the skin with a #10 blade scalpel is performed.
- Electrocautery can be used to dissect through any dense subcutaneous adipose tissue.
- Once the two major muscle groups are visualized, the dissection can be carried into the fascial plane between them. The next major landmark to be seen is the basilic vein.
- The MABC nerve can be found just superior to the basilic vein.
- The median nerve is quite large and lies inferior and deep to the vein, with a smaller cutaneous nerve just anterior to the vein as well.
- The MABC is a single cable of nerve with a branching pattern near the elbow that can be seen passing more anteriorly into the cutaneous structures (Fig.178.6).
- Closure of the incision with 4-0 Monocryl followed by a 5-0 Monocryl running subcuticular suture is appropriate.
- Typically no drains are needed, but the arm may be wrapped with Kerlix and an Ace bandage.

Sural Nerve Graft

The sural nerve is frequently used for cranial nerve repair; its diameter is ideal for a variety of repairs. The sural nerve provides sensation to the lateral and dorsal aspects of the foot.

- A two-team approach is recommended and is quite feasible.
- A donor nerve length of up to 40 cm can be achieved with minimal donor site morbidity.
- Preoperatively, any history of trauma to the donor site must be ruled out.
- Caution must be used in diabetic patients as these wound care issues could be intensified in patients with diabetic neuropathy.

Positioning

- The entire lower leg should be prepped and draped with the lateral surface visible for ease of harvest.

Surgical Technique

- The most direct approach to harvesting this nerve uses a vertical incision running from its location at the lateral malleolus and extending superiorly along the lateral leg for the length needed. A preferred alternative to this is to perform horizontal stair-step incisions at intervals along the length of the nerve extending superiorly in the lateral leg (Fig.178.7).
- A fascia stripper can be used for minimally invasive nerve harvest. Most recently, endoscopic harvest has been popularized in many centers with emphasis on cross-FN grafting.
- The nerve will be located 2 cm posterior to the lateral malleolus running anterior to the small saphenous vein.
- The initial incision should be made approximately 2 cm above the lateral malleolus to make sure that the nerve has not yet branched.
- Blunt dissection should be performed once the incision is extended into the immediate subcutaneous tissue.
- Generally three superficial branches can be seen distal to the lateral malleolus; these should be preserved (Fig.178.8).

- Dissection along the length of the nerve can be performed for 3 to 4 cm using lighted retractors.
- A second stair-step incision can be made 6 to 8 cm superior to the initial incision, and dissection can be carried inferiorly to the initial dissection plane.
- Subsequent stair-step incisions can be created until the desired length of nerve has been harvested.
- Closure of each incision with 4-0 Monocryl, deep as well as running subcuticular suture, and overlying Steri-Strips is appropriate.
- The leg may be wrapped with Kerlix for compression.
- No drains are needed.

Cross-Facial Nerve Grafting

Cross-FN grafting is unique in regard to facial reanimation. The goal of all facial reanimation is to restore a mimetic spontaneous smile. Reanimation of the face using the contralateral FN is ideal in that it offers elegant coordination with the normal side of the face. In contrast to nerve transposition procedures, where movement of the tongue or jaw produces facial movement, cross-FN grafting on the paretic side is powered by the facial nucleus for the contralateral normal nerve, offering better symmetry of motion. The downside of cross-FN grafting is of course the risk to the function of the normal FN; however, this is rarely noticed. Other criticisms include less power given the smaller caliber of nerves.

Many techniques have been described, such as segmental end-to-end neurorrhaphy extending from the donor nerves to the paretic nerve end to side versus end-to-end coaptation. This procedure, just like any nerve graft, must be customized to the individual. Cross-FN grafting is also used to power free muscle transfer for facial reanimation in a two-stage operation.

One- or two-stage cross-FN grafting depends on the status of the contralateral face. Typical two-stage cross-FN grafts occur in the setting of free tissue transfer for reanimation of the smile. The first stage of a two-stage cross-FN grafts can also be performed at the same time as a "babysitter" procedure (typically nerve transposition) to allow for neural input into the facial musculature prior to coaptation of the distal end of the cross-FN graft during the second stage.



Fig. 178.7. Left lower extremity stair-step incisions for harvesting a sural nerve graft.



Fig. 178.8. Up to 40 cm of sural nerve can be harvested from each lower extremity.

Positioning

- A two-team approach for sural nerve harvest and facial wound prep can be used.
- The bed is typically turned 90 or 180 degrees depending on room orientation. If 90 degrees is turned, then the donor leg should be away from anesthesia for ease of harvest.

Anesthesia

- If the nerve graft is to be tunneled in the upper lip, an oral ring adair elwyn (RAE) tube secured to the lower lip in the midline is ideal, and the entire face should be prepped.
- The normal (not paralyzed) side of the face is injected with epinephrine 1:100,000 (no lidocaine) (Fig.178.9).

Technique

- A facelift incision can be made using a #15 blade, and a skin flap can be elevated over the parotideomasseteric fascia extending out to the anterior border of the parotid gland.
- The incision can be extended in a modified Blair fashion to allow for adequate exposure, but this is rarely needed.



Fig. 178.9. Skin markings for the left, previously reanimated side of the face (post-"babysitter" XII–VII) at the time of cross-facial nerve grafting. Note extension into the hairline rather than utilization of the full neck incision for this nerve transposition. Note: The babysitter nerve is defined in the section titled Cross-Facial Nerve Grafting.

- Extension into the temporal hair is often all that is required for adequate exposure.
- FN branches are then identified anterior to the parotid gland and isolated with vessel loops (Fig.178.10).
- When reanimation of the contralateral oral commissure and smile is the objective, the nerve selected should provide motion of the oral commissure with little effect on the surrounding musculature of the eye, nose, or neck.
- Typically four to five branches with cross-innervation can be located.
- The sural nerve is then coapted end to end to the donor facial branch in the standard epineurial fashion, as described earlier.

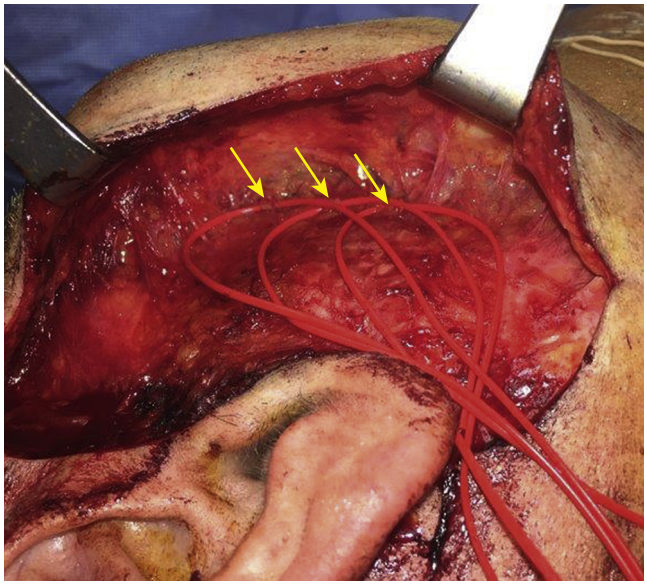

Fig. 178.10. *Right* (donor) side of cross-facial nerve graft with three large buccal branches identified at the anterior border of the parotid overlying the masseteric fascia *(arrows)*.

- The grafts, depending on the recipient branch, are tunneled above the supraorbital ridge and within the brow for the orbicularis oculi, or they are tunneled within the upper lip for the zygomatic and buccal branches.
- A Penrose drain may be placed and removed on postoperative day 1.
- The skin is closed with 4-0 Monocryl in a deep, buried fashion and 5-0/6-0 nylon on the skin.
- A pressure wrap may remain in place for 1 to 3 days.

Common Errors in Technique

- Tension on the suture line
- Failure to clean nerve ends prior to repair, which can lead to ingrowth of scar tissue and formation of a neuroma

Postoperative Care

- Incisions should be kept clean with shower, soap, and water after 36 hours.
- Nonreactive and nonmedicated emollients should be used on all incisions.
- Ocular care in the setting of FN paralysis is important to avoid permanent loss of vision.
- Reassurance and management of patient expectations are imperative, as the return of function will take months to occur. Nerves grow at a rate of 1 mm per day; thus, for a graft such as cross facial nerve grafting (CFNG), this may take more than 6 months.
- Facial physical therapy is recommended once facial motion is noted (Fig.178.11).

Complications

Complications: Common to All

- Bleeding: Bleeding is typically minor in nature; care is taken to adequately ligate named vessels, and bipolar cautery is used to control oozing or bleeding near the nerve endings. Scarring (particularly involving incisions on the face/neck and donor sites): Hypertrophic scarring or keloids may de-

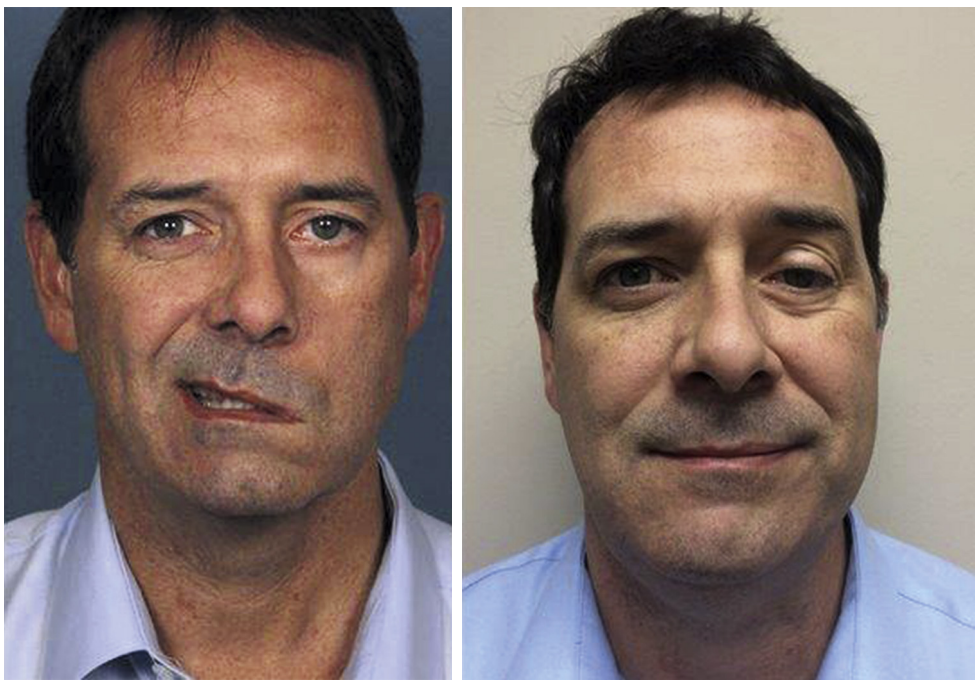

Fig. 178.11. Pre- and postoperative photograph of nerves XII–VII (3 years postsurgery) and CFNG (8 months postsurgery).

velop owing to tension on the suture line, infection, or skin type. Meticulous skin closures and the use of Kenalog injections to treat hypertrophic scarring/keloids will improve outcomes.
- Infection: This is uncommon in clean cases performed using sterile techniques. Infection may occur in "dirty wounds"—that is, contamination from traumatic injuries. This can be prevented by wound débridement, copious irrigation, and antibiotic therapy using current guidelines. Erythema, edema, and purulent drainage are signs of infection. Infection is treated with culture-directed antibiotic therapy and incision and drainage if necessary.
- Hematoma: Acute changes in the operative sites including fullness, ecchymosis of skin, pain, seepage of blood from suture lines, and rapid filling of drain reservoirs are signs of hematoma. If a hematoma forms over the trachea, it can lead to respiratory distress. Hematoma is treated with evacuation of the hematoma and control of bleeding sites. This can be prevented with meticulous hemostasis, control of blood pressure, and avoiding the use of nonsteroidal anti-inflammatory drugs (NSAIDs) and anticoagulants in the perioperative period. Failure to improve nerve function: Failure of the nerve repair is noted on physical examination. This can be prevented by using good surgical technique with attention to detail and meticulous handling of the tissues and nerve endings. If repair was that of the FN, static procedures can be employed to improve facial function/esthetics.
- Neuroma: Neuroma formation occurs particularly in the GAN. This typically presents as a trigger point on the lateral neck. Prevention and treatment of GAN neuromas are similar; the cut nerve ends are cauterized or ligated and buried in the SCM.

Harvesting of the Great Auricular Nerve

- Numbness of the outer cheek, occipital scalp, and earlobe may be present but often improves over time.
- Burn to affected areas due to lack of sensation. Patients, particularly women, should be advised to use caution with blow dryers and curling irons.

Harvesting of the Medial Antebrachial Cutaneous Nerve

- Donor-site morbidity is typically very limited.
- Injury to the basilic vein and median nerve may occur.
- A sensory deficit along the medial aspect of the mid-forearm is usually well tolerated.

Grafting of the Sural Nerve

- Intensification of diabetic neuropathy findings and pain may occur.
- Lateral and dorsal foot numbness can impair the ability to discern injury.
- Transient ankle or foot edema may be present.
- Minimal levels of pain, cold sensitivity, and scar discomfort are common.

Grafting of the Cross-Facial Nerve

- Weakness of the donor side of the face is typically not an issue. If it does occur it is usually not noticeable and, in fact, in some instances may improve symmetry. Any appreciated differences are often temporary, as cross innervation prevails.
- Overall graft failure

ALTERNATIVE MANAGEMENT PLAN

- Static reanimation using a facial sling (Alloderm, fascia lata) plus surgical treatment of the eye
- Treatment of the eye only: gold/platinum weight; lateral tarsal strip/canthopexy; brow lift

DISCUSSION

Evidence-Based Medicine Question

What salvage procedure can be used for failed cross-FN graft (CFNG) with free gracilis muscle transfer in facial paralysis?

Eisenhardt et al. reported a 14% (3/21) failure rate with use of a CFNG and gracilis free muscle transfer for FN paralysis. Although the failure rate of free gracilis muscle transfer in this situation is low, the transferred muscle requires sufficient neural input from the CFNG to be successful. The authors used direct recoaptation of the neural pedicle from the CFNG to the masseteric nerve, leaving the free muscle transplant in place if it was still viable. Because the involved structures are in the same vicinity, another nerve graft was unnecessary. If the procedure is not delayed, the gracilis muscle can be left in place. If the primary reconstructive procedure occurred more than 12 months earlier, a new muscle transfer should be performed. All patients showed muscle contraction after 3 months and a smile with open mouth after 6 months. Symmetrical excursions of the oral commissure and a satisfactory social smile were achieved; however, a spontaneous smile was not.[5]

Editorial Comment

Although this chapter deals mainly with FN reconstruction, the same principles and techniques apply to any nerve reconstruction. Meticulous detail must be paid to patient selection, reconstructive procedure, and technique in order to obtain the best functional result possible and best quality of life. Although primary neurorrhaphy done as soon as possible is the best option, this is not always possible. Following FN repair, weakness and synkinesis are inevitable; House-Brackman grade 3 is the best outcome. FN repair is often supplemented with static procedures such as a platinum (gold) weight for the upper eyelid.

Anna Pou

Access the review questions online at http://www.expertconsult.com

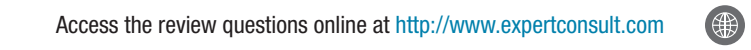

REFERENCES

1. Humphrey CD, Kriet JD. Nerve repair and cable grafting for facial paralysis. Facial Plast Surg 2008;24(2):170–176.
2. Anani R, El-Sadeck A. Fibrin glue versus microsurgical sutures in peripheral nerve repair: experimental and clinical study. Egypt J Plast ReconstrSurg 2009;33(1):69–74.
3. Brown PD, Eshleman JS, Foot RL, et al. An analysis of facial nerve function in irradiated and unirradiated facial nerve grafts. Int J Radiat Oncol Biol Phys 2000;48(3):737–743.
4. Nakatsuka H, Takamatsu K, Koshimune M, et al. Experimental study of polarity in reversing cable nerve grafts. J Reconstr Microsurg 2002;18(6):509–515.
5. Eisenhardt SU, Eisenhardt NA, Thiele JR, et al. Salvage procedures after failed facial reanimation surgery using the masseteric nerve as the motor nerve for free functional gracilis muscle transfer. JAMA Facial Plast Surg 2014;16(5):359–363.

REVIEW QUESTIONS

1. FN grafting is contraindicated in
   a. Patients undergoing postoperative radiation therapy
   b. Patients with insulin-dependent diabetes mellitus
   c. Patients above 90 years of age
   d. Patients whose facial muscles are absent

2. Sural nerve graft harvest
   a. Is relatively contraindicated in diabetics
   b. Is seldom used in facial reanimation
   c. Is most useful when a short graft is required
   d. Can potentially cause foot drop

3. Primary neurorrhaphy is done by suturing the
   a. Epineurium
   b. Perineurium
   c. Endoneuriurm
   d. Axons

4. The medial antebranchial cutaneous nerve
   a. Lies between the biceps and triceps of the upper arm
   b. Provides a grafting length of 15 to 25 cm
   c. Branching pattern and size are similar to the distal FN
   d. All of the above

5. In a 78-year-old male with skin cancer metastatic to the parotid gland requiring neck dissection, parotidectomy, and sacrifice of the FN, nerve grafting should be
   a. Delayed until radiation therapy is complete
   b. Performed immediately
   c. Abandoned due to advanced age
   d. Delayed pending final margins

179 Eyelid Reanimation in Patients With Facial Paralysis

Jason A. Liss, Morgan R. Godin

INTRODUCTION

Prompt attention to the ophthalmic manifestations of facial nerve paralysis is crucial to the care of affected patients. Loss of facial nerve function causes numerous functional and cosmetic deficits in the periocular region. These include poor eyelid closure with an increased palpebral fissure height, lower eyelid ectropion causing limited lacrimal pump function, decreased meibomian gland function and rapid evaporation of tears, decreased lacrimation from loss of parasympathetic tone, and descent of the brow with secondary hooding of the visual axis.[1,2]

Symptoms can range from mild discomfort to severe dryness with corneal ulceration and scarring to corneal perforation with loss of the involved eye. Greater degree and duration of facial nerve dysfunction is the most important risk factor for significant ocular damage, but other features such as concurrent trigeminal nerve involvement, poor Bell phenomenon, and increased age or greater tissue laxity worsen the prognosis for the eye.[2]

We have chosen to include two routinely performed staples of eyelid "reanimation" (upper eyelid weight and lower eyelid lateral tarsal strip) and one procedure that we have found to be of great value in the management of facial nerve paralysis (the tarsoconjunctival onlay flap). The latter can be viewed as a type of tarsorrhaphy, with greater cosmesis and reversibility, with potentially less limitation of peripheral vision.[3]

Other important procedures often performed on patients with facial paralysis, such as brow-lifting procedures, blepharoplasty, tarsorrhaphy, and lower eyelid spacer graft, are briefly mentioned in the discussion.

UPPER EYELID WEIGHT

Upper eyelid closure is more important than lower eyelid position in preserving corneal lubrication. Two common techniques that are employed to treat a paralyzed upper eyelid are the upper eyelid weight and the palpebral spring. Palpebral springs produce a more rapid closure than a weight, but they typically drop the upper lid margin and have problems with extrusion and migration as well as magnetic resonance imaging (MRI) incompatibility.[4] Therefore, placement of an upper eyelid weight, which allows the paralyzed lid to close with gravity, continues to be commonly performed due to its relative surgical simplicity, high success rate, low complication rate, and cosmetic acceptability. Gold is the most commonly placed weight material; but a cosmetically visible lump, extrusion, inflammation, capsule formation, and gold allergy have led to platinum chains being inserted in many cases.[5] The pretarsal weight implantation technique is described in detail in this chapter.

KEY OPERATIVE LEARNING POINTS

1. Placement of the weight should be as inferior and medial as possible and fixed to the tarsal plate to prevent migration.
2. Dissection through the orbicularis oculi muscle should be straight down from incision to superior tarsal border so that the muscle can be easily and anatomically closed over the implant.
3. Pretarsal placement of the weight will offer the best closure but might be more cosmetically noticeable than other placement techniques.

PREOPERATIVE PERIOD

History

Frequent irritation or foreign body sensation?
Prognosis for return of facial nerve function, if known?
Previous eyelid surgery?

Physical Examination

Degree of upper eyelid closure during reflex blink and with forced closure? How much lagophthalmos is present?
Corneal sensation impaired?
Conjunctiva injected?
Corneal surface examination: fluorescein uptake using cobalt blue light, especially inferiorly?
Areas of corneal thinning, stromal haze, neovascularization, or scarring?

Imaging

None necessary

Indications

1. Significant lagophthalmos with signs or symptoms of corneal desiccation
2. Expected duration of facial nerve paralysis of at least several weeks

Contraindications

1. Known gold allergy would indicate placement of an alternate implant material.
2. Restrictive or cicatricial cause of lagophthalmos

Preoperative Preparation

The appropriate weight is chosen by affixing a sizer weight, using double-sided tape or mastisol, to the pretarsal eyelid skin, waiting 10 minutes for the patient to get accustomed to the weight and then observing the eyelid position and movement. Good closure with minimal lagophthalmos and a maximum of 1 to 2 mm of ptosis indicates the appropriate weight selection.

OPERATIVE PERIOD

Anesthesia

Local anesthetic or monitored anesthesia care with local anesthetic

Positioning

Supine

Perioperative Antibiotic Prophylaxis

None

Monitoring

None unless under monitored anesthesia care (MAC)

Instruments and Equipment to Have Available

- Castroviejo needle drivers
- Westcott or spring-loaded iris scissors
- Small toothed forceps for gentle tissue handling
- Small double-skin hooks
- Appropriate suture
- Gold or platinum plate

Key Anatomic Landmarks

1. The superior border of the tarsus is indicated by a vascular arcade often visible beneath the levator fibers and on the surface of Muller muscle.
2. The lash follicles in the skin will indicate the approaching eyelid margin as dissection descends along the tarsus.
3. When dissecting in the pretarsal region of the eyelid, only the skin, orbicularis, and levator aponeurosis fibers are encountered before reaching the tarsal plate.

Prerequisite Skills

1. Basic tissue handling and dissection skills
2. Familiarity with the extraocular anatomy

Operative Risks

1. Dissection superior to the tarsal plate could result in recession of the levator tendon causing ptosis and bleeding from the peripheral eyelid vascular arcade.
2. Placing the implant-fixing sutures full thickness through the eyelid could cause significant corneal damage postoperatively; in addition, failure to lift the tarsal plate off the globe surface when placing these sutures risks entering the cornea with the suture needle.

Surgical Technique

1. The upper eyelid crease is marked across the central and medial upper eyelid. The placement of the weight will be centered over the medial limbus (border of the iris) (Fig. 179.1A). In a case of a concomitant sixth cranial nerve palsy, placement should be as far medial as possible.
2. The upper eyelid is injected with 1% lidocaine with 1:100,000 epinephrine.
3. A 2- to 2.5-cm incision is made with a number 15 blade in the marked crease of the upper eyelid. This incision line is generally 8 to 10 mm from the margin of the upper lid.
4. Sharp dissection is carried through the orbicularis oculi, straight down to the surface of the tarsal plate. The tarsal plate is contacted near its superior border (see Fig. 179.1B).
5. A pretarsal pocket is then created, which extends inferiorly to the beginning of the lash follicles, and as medial as the tarsus extends (see Figs. 179.1C and 179.2A).
6. The implanted weight is placed into the pocket, ideally centered over the medial limbus and as inferior as possible, with the two suture holes inferior and the single central suture hole superior. The implant is secured using 8-0 nylon sutures, placed partial thickness through the tarsal plate (see Fig. 179.2B). To place these partial-thickness sutures, the lid is elevated off the surface of the globe, and after placement, the underside of the upper eyelid is inspected to ensure that the needle has not been passed full thickness through the conjunctiva.
7. The orbicularis oculi muscle is then closed with buried interrupted 6-0 Vicryl sutures.
8. The skin layer is then closed using 7-0 chromic sutures or similar (see Fig. 179.1D and 179.2C).

Common Errors in Technique

1. Failure to place the weight centered over the medial limbus thereby sacrificing some eyelid closure
2. Failure to properly fix the weight to the tarsal plate
3. Failure to close the orbicularis layer over the weight to prevent extrusion
4. Suturing deeper tissue such as the septum or the levator in the attempt to close orbicularis, thereby shortening the eyelid and creating cicatricial lagophthalmos

POSTOPERATIVE PERIOD

Postoperative Management

1. Ophthalmic antibiotic ointment is applied 3 to 4 times per day to the suture line.
2. If removable sutures are used, they are removed in 7 to 10 days.
3. Even if dissolvable sutures are used, the patient should be seen within 2 weeks to monitor the condition of the corneal and eyelid closure.

Complications

1. Oversized or undersized weight
2. Implant migration and extrusion
3. Inflammatory reaction or allergy to the implant
4. Pressure-induced astigmatism

Alternative Management

1. In some cases with reasonably good eye closure, lubrication alone or lubrication and lower eyelid surgery might be sufficient.
2. Palpebral springs can be considered.

Lateral Tarsal Strip

Loss of tone in the orbicularis oculi muscle causes laxity and often ectropion in the lower eyelid, distracting the eyelid from the globe, allowing tears to pool in the inferior conjunctival cul de sac, blurring vision, worsening the lacrimal pump function, and allowing rapid evaporation of tears.

In many cases, a lateral tarsal strip procedure to shorten and tighten the lower eyelid can be extremely helpful in reducing lower eyelid laxity and improving lower eyelid apposition to the globe.[6,7] Importantly, this procedure *need not* be reversed in case of facial nerve recovery.

KEY OPERATIVE LEARNING POINTS

1. The structurally sound load-bearing tissues that must be sutured together to tighten the eyelid are the tarsus in the posterior lamella of the eyelid and the periosteum just inside the lateral orbital rim.
2. The eyelid should be shortened horizontally such that after suturing, it can be distracted from the surface of the globe by about 1 to 2 mm.

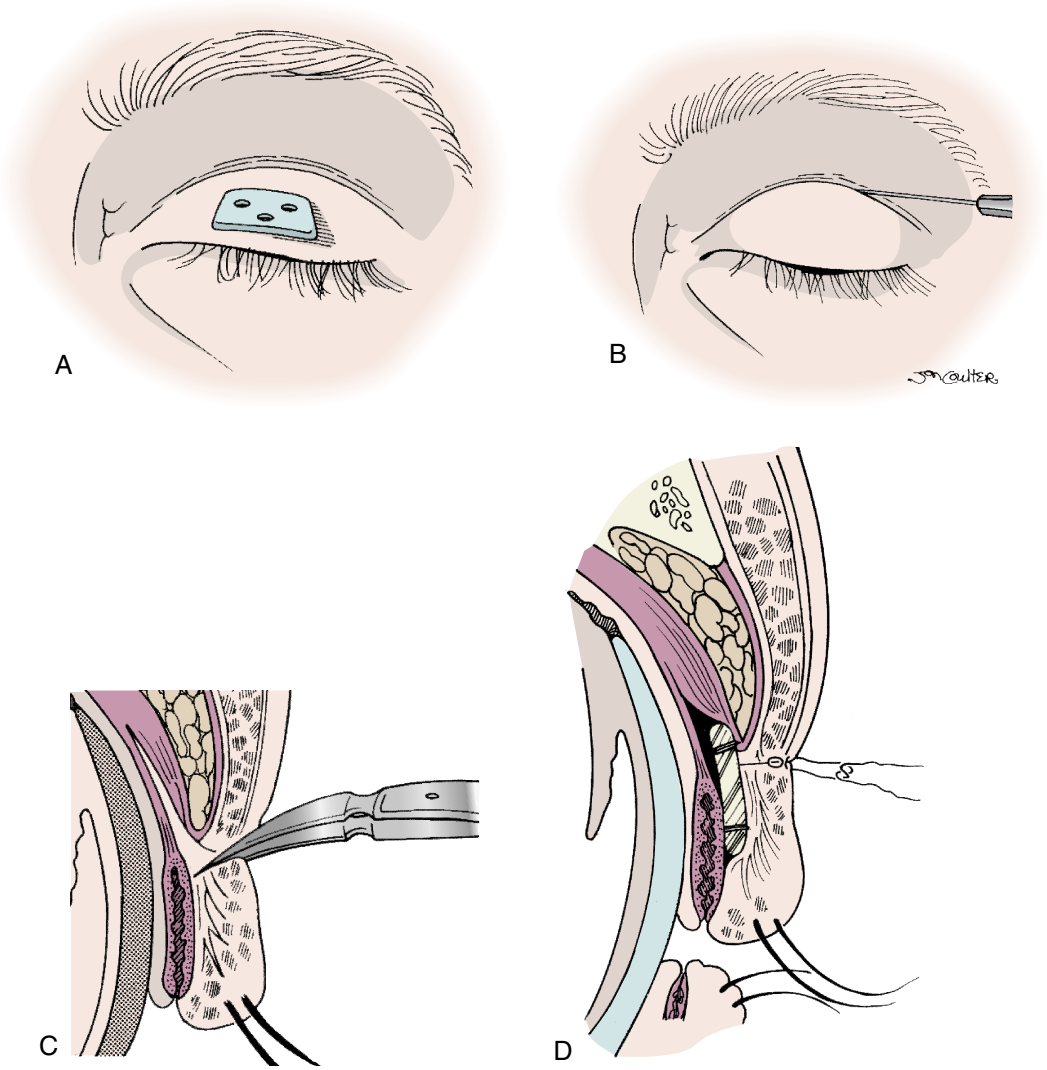

Fig. 179.1. A, Gold weights are tried as external lid loads preoperatively. **B,** Double-action scissors are used to sharply dissect a pocket to the tarsal plate noted as a white plane. **C,** Further dissection divides the orbicularis muscle and levator aponeurosis. The lowest point of dissection is 2 mm from the lash line, often noted surgically as the position of the vascular arcade. **D,** The gold weight is centered at the medial and central third of the lid to improve coverage medially. Three-point fixation is necessary to avoid extrusion, and the levator and orbicularis are closed with 6-0 absorbable suture.

PREOPERATIVE PERIOD

History

Frequent irritation or foreign body sensation?
Tears welling up in the cul de sac, intermittent blurred vision, frequent epiphora?
Prognosis for return of facial nerve function, if known? Lower eyelid drops or ectropion?
Previous lower eyelid surgery?

Physical Examination

Significant lower eyelid laxity or ectropion?
Prominent globe compared to the orbital rim? (Simulating a lateral tarsal strip might paradoxically slide the lower eyelid margin beneath the globe rather than anterior to it.)
Impaired corneal sensation?
Conjunctiva injected?
Corneal surface examination, fluorescein uptake, especially inferiorly?
Areas of corneal thinning, stromal haze, neovascularization, or scarring?

Imaging

None necessary

Indications

1. Lower eyelid laxity with a globe that is not very prominent compared to the orbital rim
2. Symptomatic dry eye, tearing, and/or an expected long-term facial nerve dysfunction

Contraindications

1. Prominent globe such that if the lid is tightened, the lid margin will slide under the globe rather than protecting it further

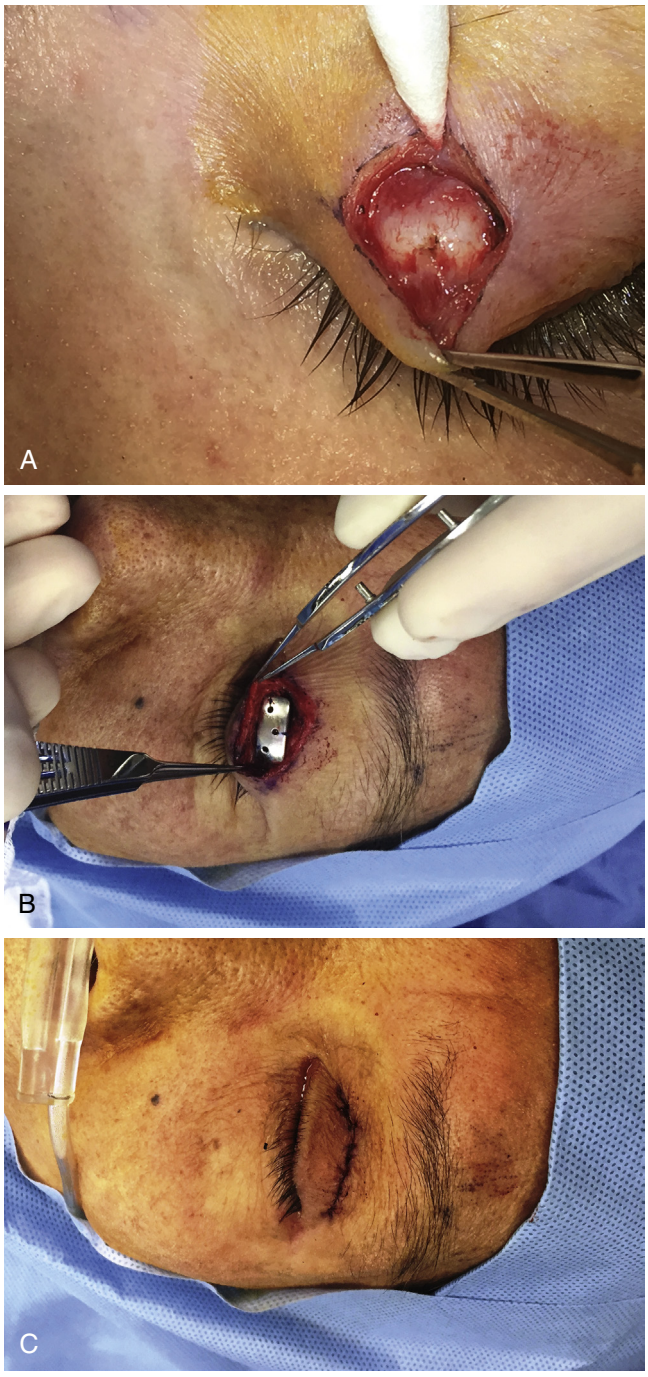

Fig. 179.2. A, Pretarsal pocket has been created, which extends inferiorly to the lash follicles and medially to the edge of the tarsus. **B,** Implant (in this case, platinum) is placed into the pretarsal pocket as inferiorly as possible, centered over the medial limbus and secured with 8-0 nylon sutures, partial-thickness through the tarsus. **C,** Skin closure using 7-0 chromic sutures, after closure of orbicularis over the implant with 6-0 Vicryl.

Preoperative Preparation

None

OPERATIVE PERIOD

Anesthesia

Local anesthetic or MAC with local anesthetic

Positioning

Supine

Perioperative Antibiotic Prophylaxis

None

Monitoring

None unless under MAC

Instruments and Equipment Have Available

Similar to gold weight procedure

Key Anatomic Landmarks

1. The tarsus lies in the posterior lamella of the eyelid, is about 3.5- to 4-mm tall in the lower eyelid, and is bordered posteriorly by conjunctiva, anteriorly by orbicularis, and superiorly by the eyelid margin.
2. The tarsal strip should be attached to the Whitnall tubercle, located 4 to 5 mm posterior to the orbital rim and about 11 mm inferior to the frontozygomatic suture (which is not seen in the surgery)—at about the level of the inferior pupillary margin or such that the lid rides just above the inferior limbus centrally.

Prerequisite Skills

Basic tissue-handling and dissection skills; familiarity with the extraocular anatomy

Operative Risks

1. Use caution not to puncture the globe with a curved suture needle when suturing the tarsal strip.
2. Bleeding can be encountered in the dissection of the lateral canthus or lateral eyelid.

Surgical Technique

1. The area of the lateral canthus and lateral lower and upper lid is injected with 1% lidocaine with 1:100,000 epinephrine.
2. A horizontal or slightly downward-angled lateral canthal incision is made through the lateral commissure and the canthal skin for about 1 cm (see canthotomy/cantholysis picture, Chapter 153).
3. Sharp scissors are used to cut through the orbicularis oculi down to the level of the periosteum of the lateral orbital rim, taking care not to disrupt the periosteum on the rim.
4. The lower eyelid is grasped just lateral to the epithelialized margin and pulled anteriorly and medially, stretching the canthal tendon. The canthal tendon is cut with Stevens tenotomy scissors until the lower eyelid falls freely away from the globe (inferior cantholysis) (Fig. 179.3A).
5. Traction on the lower eyelid toward the lateral orbital rim is used to determine the desired amount of shortening of the lid. The lid should be distractible by about 1 to 2 mm off the globe once it is shortened.
6. The orbicularis and skin layer are divided off the anterior face of the tarsus for the length of the desired tarsal strip, the marginal epithelium is excised from the margin, and the conjunctiva is scraped off the posterior tarsus with a number 15 blade or lightly cauterized with bipolar cautery (see Fig. 179.3A).



Fig. 179.3. A, Lateral tarsal strip (LTS) has been prepared by removing orbicularis and skin from the anterior tarsus, marginal epithelium from the superior tarsal edge, and conjunctiva off the posterior tarsus. **B,** LTS harnessed with double armed 4-0 Mersilene suture on an S2 needle from posterior to anterior through the strip; one arm is placed 1 mm below the lid margin then the second one 1 to 2 mm below the first. **C,** LTS secured with horizontal mattress suture to the periosteum inside the lateral orbital rim such that the lower eyelid is at the level of the inferior limbus centrally.

7. The lateral tarsal strip is harnessed at its medial-most extent with a double-armed 4-0 Mersilene suture on an S-2 needle, from posterior to anterior through the strip. One arm is placed 1 mm below the lid margin, and the second is placed about 2 mm below the first in the same fashion. These needles should not come through the skin anteriorly (see Fig. 179.3B).
8. The tarsal strip is then sutured to the periosteum over the Whitnall tubercle as follows: Each arm of the 4-0 Mersilene suture is placed through the medial-most extent of the tarsal strip from the posterior (conjunctival) side to the anterior side, and then each needle is sutured to the periosteum inside the lateral orbital rim, at about the height of the inferior pupil, or such that the lower eyelid hits just above the lower limbus centrally, in horizontal mattress fashion (see Fig. 179.3C).
9. Prior to tying the Mersilene, a 6-0 Vicryl suture is used in buried fashion to reestablish the lateral commissure by suturing the new lateral extent of the lower eyelid to the lateral extent of the upper eyelid. The Mersilene is then tied to tighten the eyelid.
10. The skin of the lateral canthus is then trimmed if needed and closed with an interrupted 6-0 plain gut or 7-0 chromic gut suture.

Common Errors in Technique

1. Over- or undertightening of the eyelid
2. Placing the canthus too high or too low
3. Failure to get a solid bite of periosteum at the orbital rim
4. Anterior placement of the lateral tarsal strip causing anterior distraction of the lower eyelid

POSTOPERATIVE PERIOD

Postoperative Management

Complications

1. Suture granuloma
2. Eyelid dehiscence
3. Recurrence of ectropion
4. Eyelid rides beneath the globe and fails to provide protection

Alternative Management

1. In some patients with a prominent globe or recessed malar eminence, an eyelid spacer or lower eyelid advancement might be indicated.
2. In more severe cases, a lateral tarsorrhaphy or, in our opinion, a lateral tarsoconjunctival flap from upper lid to lower lid might be very helpful in supporting the lower eyelid and giving good corneal coverage.

Lateral Tarsoconjunctival Onlay Flap Lower Eyelid Suspension

The lateral tarsoconjunctival onlay flap lower eyelid suspension surgery can be beneficial for many patients with facial nerve paralysis. This procedure provides numerous advantages over a tarsorrhaphy, with similar benefits. A tarsorrhaphy can be cosmetically unappealing, limit the peripheral vision, and reversal can cause trichiasis and margin keratinization. The onlay graft provides excellent lower eyelid suspension (and shortening if combined with a lateral tarsal strip), is more aesthetically pleasing than a tarsorrhaphy, provides some upward lower eyelid movement on lid closure, is less peripherally limiting due to the wider palpebral aperture, and is more cleanly reversible (Fig. 179.4).[3]

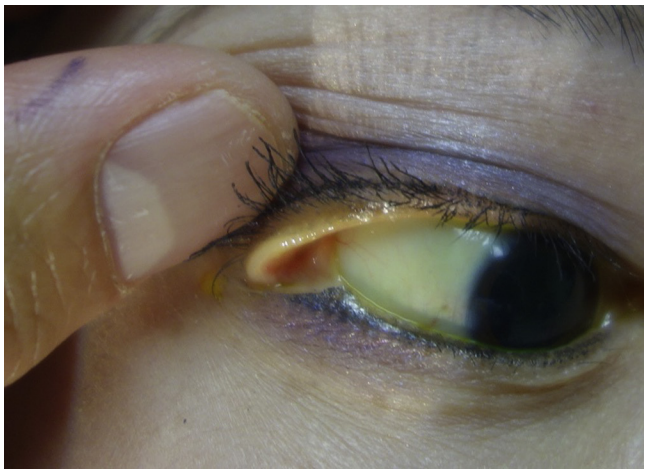

Fig. 179.4. Lateral tarsoconjunctival onlay flap with lower eyelid suspension; note relatively wide palpebral aperture compared to typical lateral tarsorrhaphy.

KEY OPERATIVE LEARNING POINTS

1. This flap technique is similar in concept to a Hughes tarsoconjunctival flap for eyelid reconstruction.
2. It is important not to extend the tarsoconjunctival flap too loosely from the upper lid, as doing this will sacrifice some of the lower eyelid suspension.

PREOPERATIVE PERIOD

History

Similar to the procedures described earlier

Physical Examination

- Significant lagophthalmos
- Poor upper eyelid closure
- Lower eyelid ectropion and laxity
- Corneal staining or more severe corneal dryness
- Loss of corneal sensation

Imaging

None necessary

Indications

Indicated in patients with poor eye closure, lower eyelid ectropion, and dryness, especially if the eyelid weight and lateral tarsal strip have not provided enough benefit. In more severe cases, it can be performed primarily, often along with an eyelid weight, lateral tarsal strip, and lower eyelid retractor recession.

Contraindications

Prior procedures compromising the tarsus of the upper lid or the margin of the lower lid, such as eyelid reconstructions after cancer excisions or significant eyelid trauma

Preoperative Preparation

None

OPERATIVE PERIOD

Anesthesia

Local anesthetic or MAC with local anesthetic

Positioning

Supine

Perioperative Antibiotic Prophylaxis

None

Monitoring

None unless under MAC

Instruments and Equipment to Have Available

Similar to the procedures described earlier

Key Anatomic Landmarks

1. The tarsus is located in the posterior lamella of the upper eyelid and measures about 8 to 10 mm in height centrally but tapers at its sides.
2. It is important to leave the inferior 4 mm of tarsus intact to preserve upper eyelid structural integrity.
3. The destination of the flap in this case is the posterior lamella (tarsus) of the lower eyelid margin.

Prerequisite Skills

Basic tissue handling and dissection skills; familiarity with extraocular anatomy

Operative Risks

Minimal

Surgical Technique

1. The lateral upper and lower eyelids are infiltrated with 1% lidocaine with 1:100,000 epinephrine.
2. A 5-0 silk traction suture is placed in the upper eyelid margin, and the eyelid is everted over a Desmarres retractor.
3. The posterior tarsal surface is dried, and a tarsal segment is marked in the lateral superior tarsus, leaving the marginal 4 mm intact and measuring about 6 mm horizontally.
4. The tarsus is incised along the marked lines with a number 15 blade, and the tarsoconjunctival flap is developed with scissors by dissection superiorly in the plane anterior to tarsus, that is, leaving the tarsus pedicled on the conjunctiva, taking care to advance the tarsal segment enough to reach its destination on the lower eyelid margin but not in excess (Fig. 179.5A).
5. The lateral lower eyelid margin is divided at the gray line for the distance corresponding to the developed tarsoconjunctival flap, and the epithelium of the posterior lamellar margin is excised (see Fig. 179.5B).
6. The tarsoconjunctival flap is sutured to the denuded tarsus of the lower eyelid with interrupted 6-0 Vicryl sutures, in mattress fashion (see Fig. 179.5C and D).
7. If lower eyelid laxity exists that needs to be addressed, a canthotomy/cantholysis and lateral tarsal strip may be performed **prior to** denuding the lower lid margin and suturing the upper lid flap.

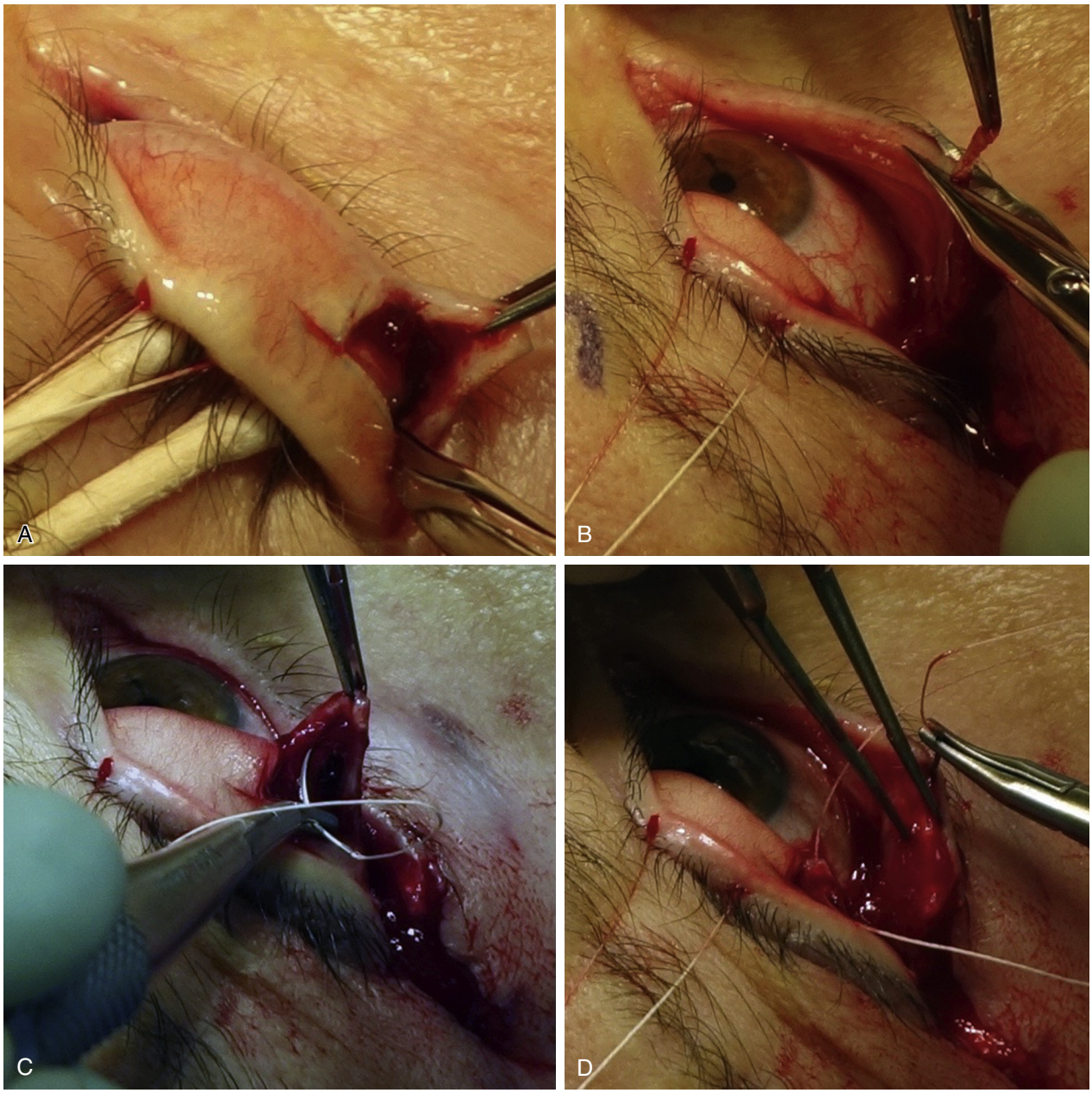

Fig. 179.5. A, With the upper eyelid everted, the marginal 4 mm of tarsus is left intact, and the lateral superior tarsus is incised with a number 15 blade, then bluntly recessed downward on a conjunctival pedicle. **B,** The lateral lower eyelid margin is divided into anterior and posterior lamellae, and the posterior marginal epithelium is excised for a distance corresponding to the tarsoconjunctival flap width. **C and D,** The tarsoconjunctival flap is sutured to the denuded tarsus of the lower eyelid with interrupted 6-0 Vicryl sutures.

Common Errors in Technique

1. Advancing the tarsoconjunctival flap too freely from the upper eyelid can reduce the lower eyelid suspension.

POSTOPERATIVE PERIOD

Postoperative Management

Antibiotic ointment or drops to the involved eye for about 1 week; follow-up within 2 weeks to check on the condition of the cornea

Complications

1. Dehiscence of the graft
2. Peripheral vision limitation
3. Suture granuloma

Alternative Management

To be considered as part of the armamentarium along with the other procedures in this chapter

DISCUSSION

There are many surgical options in the management of the ophthalmic manifestations of facial paralysis, and we have described several here. The majority of patients require a combination of these techniques, and the approach should be tailored for each patient.

Eyelid loading is a standard component in the care of most patients. The success rate is high in most studies, with excellent results for safely reducing lagophthalmos.[8,9] Drawbacks include the slow eye closure achieved by relying on gravity, and complications including weight extrusion, poor cosmesis, inflammation/allergy, and astigmatism. Using platinum chains reduces the incidence of all of these complications except for the slow closure.[5]

Lateral tarsal strip is a well-described and successful procedure for improving lower eyelid tension and position.[7,8] In patients with lower eyelid laxity and ectropion that do not have overly prominent globes, this is an excellent technique to consider.

In some cases, either because the globe is prominent compared to the orbital rim (Hertel measurement of about 20 mm or more), or there is a recessed malar eminence, or simply due to the tissue laxity and lack of muscle tone, a posterior lamellar eyelid spacer graft is needed to bolster the lower lid against gravity and help bring the lower eyelid margin up to the inferior limbus. This anatomic situation is often referred to as a "negative vector." A tarsal strip alone would potentially pull the eyelid beneath the globe, so the lid needs to be made taller.

Many materials have been used as a spacer graft through the years, with strengths and weaknesses of each material. Some of the choices are autografts (hard palate, ear cartilage, dermis fat graft),[10] cadaveric allografts (acellular human dermis (Alloderm, banked sclera), and xenografts (porcine acellular dermal matrix [Enduragen]; porcine intestinal submucosal collagen matrix [Tarsys]). Hard palate offers an excellent analogue to eyelid posterior lamella because it contains both collagen and mucosal lining, resists gravity well, and does not reabsorb over time. It does require a donor surgical site, though, so many of these procedures are now being done with acellular porcine dermal matrices. These are our favored materials; the technique is outside the scope of this chapter.

The lateral tarsoconjunctival onlay flap lower eyelid suspension surgery can be beneficial for many patients not responsive to eyelid loading and lower lid tightening alone. Advantages over tarsorrhaphy are greater cosmesis, less peripheral vision limitation, lower eyelid elevation on closure, and easy reversal.[3] In severe cases in which these techniques are not working, a lateral tarsorrhaphy must be considered.

Descent of the brow due to loss of frontalis muscle action can cause debilitating obstruction of the visual axis and great cosmetic asymmetry. Chemodenervation above the normal brow can provide improved symmetry. Brow lifting procedures such as pretrichial, endoscopic, mid-forehead and direct brow lifts, as well as transblepharoplasty browpexy procedures, are often a necessary component of care, especially in longer-term cases. In older patients especially, eyelid skin must also be reduced with a concurrent blepharoplasty. The blepharoplasty, however, should be done conservatively, and care should be taken not to excise descended brow skin rather than true excess eyelid skin. These techniques are outside the scope of this chapter.

Evidence-Based Medicine Question

Is surgical management generally successful in protecting the cornea and restoring comfort in patients with facial nerve paralysis?

Eyelid weights with or without concomitant lower eyelid procedures are very successful in restoring satisfactory closure to the eyelid. Foda,[8] in 1999, reported that 92.5% of patients had complete closure, and Snyder in 2001 showed 89% of patients had satisfactory closure. Jobe,[9] in 1974, had only a 3% extrusion rate for gold weights, although authors have found up to 50% extrusion in some studies. The platinum chains cause less allergy and tissue inflammation, with less extrusion and better cosmetic results.

The lateral tarsal strip is also quite successful, with Marzouk et al.[6] reporting 85% of patients having satisfactory correction of ectropion with similarly good aesthetic and functional results. Kam et al.[7] found 87% functional and 78% anatomic success.

Tao et al.[3] in his report on 110 patients treated with the tarsoconjunctival onlay procedure (with or without canthopexy) found improved lagophthalmos, exposure keratopathy, and eyelid position in all cases.

Golio et al.[1] reported on 72 patients with cancer-related facial paralysis, treated with combinations of gold weight (72 patients), lateral tarsorrhaphy (71), lateral tarsal strip (53), and brow lift (21). All patients reported less dependence on external lubricants, 30 of 39 reported improved foreign body sensation, and 36 of 52 reported less unwanted tearing. They summarize that outcomes in facial nerve paralysis are excellent in general but that most patients require several procedures, which can be performed together.

Editorial Comment

This chapter describes the basic procedures necessary to protect the eye in case of temporary or permanent facial nerve dysfunction. Whenever possible, it is preferable to start with surgical correction of the lower lid position, because this procedure will not need to be reversed in the event of nerve recovery. The chapter begins with a description of the placement of an upper eyelid load to assist with closure: This improves volitional blink but does not improve the more important reflex blink, so it may be less useful in patients who cannot be taught to intentionally close the eye. There is also a critical question of whether there is loss of corneal sensation, which severely impedes corneal healing. If this is present, tarsorrhaphy should be strongly considered.

Tonya Stefko

Access the review questions and additional sources list online at http://www.expertconsult.com

REFERENCES

1. Golio D, De Martelaere S, Anderson J, Esmaeli B. Outcomes of periocular reconstruction for facial nerve paralysis in cancer patients. Plast Reconstr Surg 2007;119(4):1233–1237.
2. Momeni A, Khosla RK. Current concepts for eyelid reanimation in facial palsy. Ann Plast Surg 2014;72(2):242–245.
3. Tao JP, Vemuri S, Patel AD, et al. Lateral tarsoconjunctival onlay flap lower eyelid suspension in facial nerve paresis. Ophthal Plast Reconstr Surg 2014;30(4):342–345.
4. Demirci H, Frueh BR. Palpebral spring in the management of lagophthalmos and exposure keratopathy secondary to facial nerve palsy. Ophthal Plast Reconstr Surg 2009;25(4):270–275.
5. Silver AL, Lindsay RW, Cheney ML, Hadlock TA. Thin-profile platinum eyelid weighting: a superior option in the paralyzed eye. Plast Reconstr Surg 2009;123(6):1697–1703.
6. Marzouk MA, Shouman AA, Elzakzouk ES, Elnaggar MTA. Lateral tarsal strip technique for correction of lower eyelid ectropion. J Am Sci 2011;7(5):394–405.
7. Kam KY, Cole CJ, Bunce C, et al. The lateral tarsal strip in ectropion surgery: is it effective when performed in isolation? Eye (Lond) 2012;26(6):827–832.
8. Foda HM. Surgical management of lagophthalmos in patients with facial palsy. Am J Otolaryngol 1999;20(6):391–395.
9. Jobe RP. A technique for lid loading in the management of the lagophthalmos of facial palsy. Plast Reconstr Surg 1974;53(1):29–32.
10. Sullivan SA, Dailey RA. Graft contraction: a comparison of acellular dermis versus hard palate mucosa in lower eyelid surgery. Ophthal Plast Reconstr Surg 2003;19(1):14–24.

REVIEW QUESTIONS

1. Where is the optimal pretarsal placement of a gold weight in the upper eyelid?
   a. Centered over mid-pupil
   b. Centered over medial limbus
   c. Centered over lateral limbus
   d. Centered over the orbital septum

2. Potential advantages of a platinum chain over a gold weight include all of the following, except
   a. Improved cosmesis
   b. Lower frequency of allergy
   c. Lower extrusion rate
   d. Improved speed of closure

3. The lateral tarsal strip is sutured to which anatomic landmark?
   a. Periosteum inside the lateral orbital rim
   b. The orbicularis oculi of the upper eyelid
   c. The inferior crus of the lateral canthal tendon
   d. Just outside the lateral orbital rim on the Whitnall ligament

4. A patient has suffered unilateral facial nerve paralysis with resulting lagophthalmos and unclear expected recovery time. What is the single best initial treatment?
   a. Antibiotic ointment
   b. Lateral tarsoconjunctival onlay flap
   c. Gold weight placement
   d. Artificial tears

5. All of the following are true regarding the lateral tarsoconjunctival onlay procedure, except
   a. It induces some lower lid elevation on eye closure.
   b. It is difficult to reverse without complication.
   c. It narrows the palpebral fissure.
   d. It may limit peripheral vision.

ADDITIONAL SOURCES

Becker FF. Lateral tarsal strip procedure for the correction of paralytic ectropion. Laryngoscope 1982;92(4):382–384.

Bladen JC, Norris JH, Malhotra R. Cosmetic comparison of gold weight and platinum chain insertion in primary upper eyelid loading for lagophthalmos. Ophthal Plast Reconstr Surg 2012;28(3):171–175.

Booth AJ, Murray A, Tyers AG. The direct brow lift: efficacy, complications, and patient satisfaction. Br J Ophthalmol 2004;88(5):688–691.

Cosar CB, Cohen EJ, Rapuano CJ, et al. Tarsorrhaphy: clinical experience from a cornea practice. Cornea 2001;20(8):787–791.

Gire A, Kwok A, Marx DP. PROSE treatment for lagophthalmos and exposure keratopathy. Ophthal Plast Reconstr Surg 2013;29(2):e38–40.

Henstrom DK, Lindsay RW, Cheney ML, Hadlock TA. Surgical treatment of the periocular complex and improvement of quality of life in patients with facial paralysis. Arch Facial Plast Surg 2011;13(2):125–128.

Ibrahim AM, Rabie AN, Kim PS, et al. Static treatment modalities in facial paralysis: a review. J Reconstr Microsurg 2013;29(4):223–232.

Kahana A, Lucarelli MJ. Adjunctive transcanthotomy lateral suborbicularis fat lift and orbitomalar ligament resuspension in lower eyelid ectropion repair. Ophthal Plast Reconstr Surg 2009;25(1):1–6.

Knize DM. Anatomic concepts for brow lift procedures. Plast Reconstr Surg 2009;124(6):2118–2126.

Korn BS, Kikkawa DO, Cohen SR, et al. Treatment of lower eyelid malposition with dermis fat grafting. Ophthalmology 2008;115(4):744–751.e2.

Lavy JA, East CA, Bamber A, Andrews PJ. Gold weight implants in the management of lagophthalmos in facial palsy. Clin Otolaryngol Allied Sci 2004;29(3):279–283.

Liao SL, Wei YH. Correction of lower lid retraction using tarsys bioengineered grafts for Graves ophthalmopathy. Am J Ophthalmol 2013;156(2):387–392.e1.

Martin-Oviedo C, Garcia I, Lowy A, et al. Hyaluronic acid gel weight: a nonsurgical option for the management of paralytic lagophthalmos. Laryngoscope 2013;123(12):E91–96.

Mavrikakis I, Malhotra R. Techniques for upper eyelid loading. Ophthal Plast Reconstr Surg 2006;22(5):325–330.

McCord C, Nahai FR, Codner MA, et al. Use of porcine acellular dermal matrix (Enduragen) grafts in eyelids: a review of 69 patients and 129 eyelids. Plast Reconstr Surg 2008;122(4):1206–1213.

Pascali M, Corsi A, Brinci L, et al. The tarsal belt procedure for the correction of ectropion: description and outcome in 42 cases. Br J Ophthalmol 2014;98(12):1691–1696.

Schrom T, Buchal A, Ganswindt S, Knipping S. Patient satisfaction after lid loading in facial palsy. Eur Arch Otorhinolaryngol 2009;266(11):1727–1731.

Seiff SR, Chang Jr JS. The staged management of ophthalmic complications of facial nerve palsy. Ophthal Plast Reconstr Surg 1993;9(4):241–249.

Snyder MC, Johnson PJ, Moore GF, Ogren FP. Early versus late gold weight implantation for rehabilitation of the paralyzed eyelid. Laryngoscope 2001;111(12):2109–2113.

Symbas J, McCord C, Nahai F. Acellular dermal matrix in eyelid surgery. Aesthet Surg J 2011;31(Suppl. 7):101s–107s.

Tan ST, Staiano JJ, Itinteang T, et al. Gold weight implantation and lateral tarsorrhaphy for upper eyelid paralysis. J Craniomaxillofac Surg 2013;41(3):e49–53.

Tanenbaum M, Gossman MD, Bergin DJ, et al. The tarsal pillar technique for narrowing and maintenance of the interpalpebral fissure. Ophthal Surg 1992;23(6):418–425.

Terzis JK, Karypidis D. Blink restoration in adult facial paralysis. Plast Reconstr Surg 2010;126(1):126–139.

Terzis JK, Kyere SA. Experience with the gold weight and palpebral spring in the management of paralytic lagophthalmos. Plast Reconstr Surg 2008;121(3):806–815.

Walrath JD, McCord CD. The open brow lift. Clin Plast Surg 2013;40(1):117–124.

Watts TL, Chard R, Weber SM, Wax MK. Immediate eye rehabilitation at the time of facial nerve sacrifice. Otolaryngol Head Neck Surg 2011;144(3):353–356.

Zwick OM, Seiff SR. Supportive care of facial nerve palsy with temporary external eyelid weights. Optometry (St. Louis, Mo) 2006;77(7):340–342.

180 Facial Reanimation

Barry Schaitkin, Courtney T. Chou

INTRODUCTION

- Rehabilitation of the patient with chronic facial paralysis must take into account the loss of form and function. When contemplating facial reanimation, the surgeon should consider all variables that might influence the choice of procedure, including the patient's age, prognosis, pathology, the extent of paralysis and functional deficit, the current status of the nerve and the likelihood of spontaneous recovery, other neural deficits, comorbidities, and patient expectations (Box 180.1).[1,2] Reanimation of the paralyzed eyelid is usually required in addition to the procedures described in this chapter (see Chapter 179).

KEY OPERATIVE LEARNING POINTS

- Surgical principles of nerve repair:
  - Nerve repair, whether by direct anastomosis or graft placement, must be tension-free.
  - The endoneurial surface of each end must match.
  - The ideal graft not only has the proper length but also a similar axon volume.
  - Nerve repair should always be performed using an operating microscope.

PREOPERATIVE PERIOD

History

- History of present illness
  - Cause of paralysis
    - One may think of the facial nerve nucleus as the proximal system and the facial nerve musculature as the distal system and classify patients based on which systems are surgically available. The procedures are then dictated by the integrity of those systems for use by the surgeon.
      - Proximal system intact and distal system intact
        - Patients with disruption of the facial nerve in the temporal bone are good examples of the proximal and distal system intact. These patients are ideally suited for having the facial nerve nucleus reconnected to the facial musculature by primary neurorrhaphy or by use of a nerve graft. Reconstituting the nerve should be performed as soon as possible to achieve the best results.
      - Proximal system intact and distal system not available
        - Patients with extensive invasion of the facial nerve by cancer can create a situation without a distal nerve graft site. Ideally, the viable proximal facial nerve can then be used to innervate a microvascular free flap, or alternatively, these patients without a distal system can be helped by muscle transposition.
      - Proximal system not available and distal system intact
        - Patients who have lost the facial nerve as part of acoustic tumor surgery should have the nerve reconstituted immediately, if possible, by a nerve graft. However, this frequently is not possible, and patients are often reluctant to have a craniotomy for reestablishing nerve continuity. These patients are dynamically innervated by nerve substitution with a masseteric nerve graft, hypoglossal jump graft, or by use of a cross-facial nerve graft.
      - Neither system available
        - For those lacking both systems, two dynamic options are available: the temporalis muscle transposition and the innervated free flap based on another cranial nerve (V, the contralateral cranial nerves VII, XI, and XII have been used). This situation is characteristic of the patient who has undergone radical surgery for cancer of the parotid gland and presents years later for reanimation.
  - Duration of paralysis
    - The sooner reinnervation is performed, the better the functional outcome. However, reinnervation should not be performed while recovery is still a possibility. Ideally, primary neurorrhaphy or grafting should be performed within 30 days of injury. If performed after 6 months, the results can be disappointing. Nerve substitution via transposition or jump grafting has been reported to be successful within the first 1 to 2 years after injury. If paralysis has been present for more than 2 years, reanimation methods other than nerve repair or grafting such as muscle transposition, microvascular free flap, or static procedures should be used.
  - Patient expectations
    - Facial reanimation requires excellent patient-surgeon communication and rapport. The patient must be educated about the etiology and natural course of his or her facial impairment. When considering a procedure, the risks, benefits, and expected postoperative course and outcome should be discussed.
- Past medical history
  - Age
    - Young patients have increased tissue turgor and elasticity that make muscle transposition more challenging as well as increased fibroblastic activity that can result in hypertrophic facial scars. However, reinnervation in young patients is often more successful due to the greater regenerative potential of their nerves.
  - Life expectancy
    - Life expectancy is an important consideration given the varied recovery times for different reanimation techniques. A patient with a limited life expectancy may benefit from a static procedure or muscle transposition with an immediate result as opposed to a dynamic procedure requiring reinnervation and a prolonged recovery.
  - General health
    - Patient comorbidities impact wound healing. Diabetes, malnutrition from chronic disease, and prior radiation increase the risk of delayed healing and wound dehiscence.

BOX 180.1 Facial Reanimation Procedures

STATIC PROCEDURES

1. Suspension of oral commissure with fascia lata graft
2. Nasal alar lateralization with fascia lata graft or use of Mitek anchor
3. Lower lip wedge resection

DYNAMIC PROCEDURES

1. Facial nerve repair by primary repair or interposition graft
   a. Primary repair of facial nerve
   b. Repair of facial nerve with great auricular nerve interposition graft
2. Nerve substitution by transposition or graft
   a. Hypoglossal-facial transposition
   b. Hypoglossal-facial graft with great auricular nerve
   c. Masseteric-facial transposition
   d. Cross-facial graft
3. Muscle transposition and free muscle neurovascular anastomosis
   a. Digastric muscle transposition
   b. Gracilis muscle free flap

Physical Examination

- Brow
  - Assess for brow droop and asymmetry.
- Eye
  - Assess for degree of eye closure, presence of Bell's phenomenon (upward movement of the globe with attempted lid closure), tear production, and corneal sensation.
- Nose
  - Assess for shift of ipsilateral upper lip philtrum and collapse of nasal ala, especially with inspiration.
- Mouth
  - Assess for asymmetric smile, inability to expose the lower teeth, and drooling.
- Cranial nerve examination
  - Assess for concomitant cranial nerve deficits, especially in patients who have had an acoustic tumor resected, because this will impact options for dynamic reanimation.
- Imaging
  - None. Although imaging may be required for the evaluation of facial paralysis, it is not required prior to facial reanimation.

OPERATIVE PERIOD
Static Procedures

Static procedures can be combined with dynamic procedures or be used independently. Common static procedures to consider when reanimating the middle and lower face are (1) suspension of the oral commissure, (2) nasal alar lateralization, and (3) lower lip wedge resection, which are discussed here (Fig. 180.1).[3]

Indications

- Patients with a poor prognosis, in whom dynamic reanimation is not a practical option, as an adjunct to residual function, or in those who have failed dynamic reanimation
- Nasal obstruction as an indication for nasal alar lateralization
  - It is important to perform a complete preoperative nasal analysis to differentiate between paralytic factors and pre-existing structural factors that may also be contributing to the patient's obstructive symptoms.
- Asymmetry of the mouth at rest and with smile as an indication for the suspension of the oral commissure or lower lip wedge resection
  - Major problems encountered around the paralyzed mouth are upper lip droop, corner of mouth droop, and lower lip asymmetry with associated functional deficits such as oral incompetence and speech impediment.

Contraindications

- Medical comorbidities with increased risk for general anesthesia or awake sedation
- Ongoing evaluation or treatment of facial paralysis

Preoperative Preparation

- If performing a static suspension procedure (i.e., suspension of oral commissure or nasal alar lateralization), decide on the material to be used for suspension.
  - Many materials have been used including permanent suture, alloplastic mediums such as Gore-Tex (W.L. Gore & Associates Inc., Flagstaff, Arizona) or AlloDerm (LifeCell Co., Bridgewater, New Jersey) and autologous grafts such as fascia lata and palmaris longus tendon.
  - Although autologous grafts have the disadvantage of donor site morbidity, they are still superior to alloplasts due to decreased risk of infection, rejection, and extrusion.

OPERATIVE PERIOD
Anesthesia

- General anesthesia. Although some reanimation procedures, mainly static procedures, can be performed with awake sedation, general anesthesia is preferred for patient comfort.

Positioning

- The patient is placed in the supine position with the head stabilized in a donut pillow for procedures involving the face only and with the addition of a shoulder roll for procedures requiring access to the neck.

Perioperative Antibiotic Prophylaxis

- First-generation cephalosporin

Monitoring

- None

Suspension of oral commissure with a fascia lata graft

OPERATIVE PERIOD
Instruments and Equipment to Have Available

- Facial plastics set
- Fascia stripper
- Miniplate set
- Closed suction drain
- Permanent monofilament suture

Key Anatomic Landmarks

- Nasolabial fold (NLF)
- Vermilion border

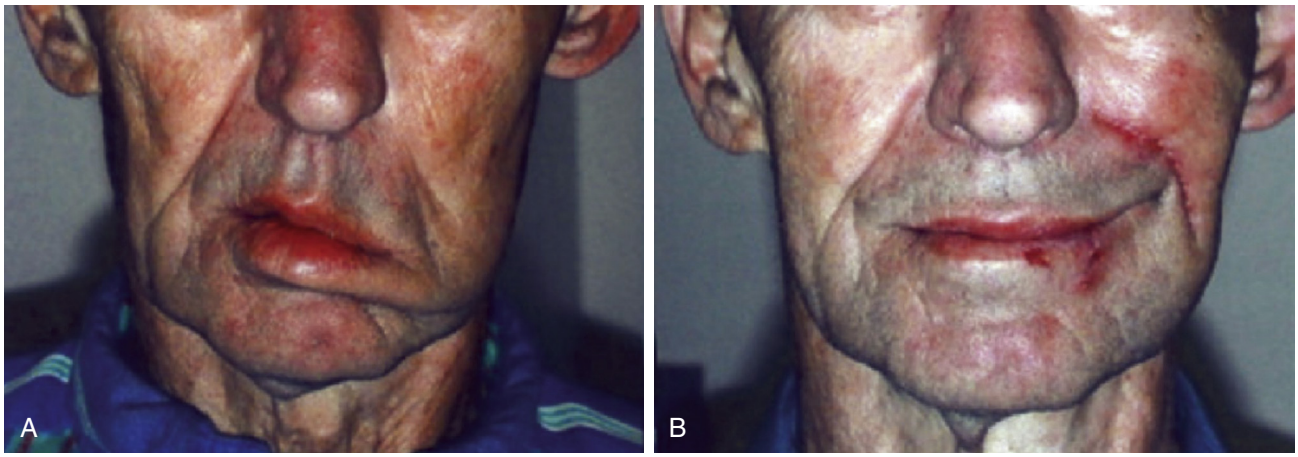

Fig. 180.1. Patient before, **A,** and after, **B,** static suspension of oral commissure and lower lip wedge resection.

- Superficial muscular aponeurotic system (SMAS)
- Modiolus
- Zygomatic arch

Prerequisite Skills

- Facelift
- Open reduction and internal fixation of midface fractures

Operative Risks

- Intraoperative bleeding

Surgical Technique

- Harvest fascia lata graft from lateral thigh.
  - The distance between the zygomatic arch and the modiolus is measured to approximate the required length of fascia lata. One half of the measured distance is used as the incision length on the lateral thigh. A 2.5-cm-wide strip of fascia lata is harvested through this incision. The distal end of the graft is bisected in preparation for placement superior and inferior to the upper and lower lip.
- Perform perioral and temporal incisions.
  - The perioral incision may be placed within the NLF or the vermilion border. Incisions in the NLF work best in older patients with deep folds on the normal side. The resultant scar will visually resemble an NLF.
  - The temporal incision is placed in the preauricular hairline.
- Develop a tunnel between the two incisions.
  - Blunt dissection is used to develop a plane between the subcutaneous tissue and the SMAS.
- Pass the graft through the tunnel from the perioral incision to the hairline incision using a long clamp.
- Secure the distal ends of the graft.
  - The bisected distal ends of the graft are passed into the upper and lower lip tunnels and secured to the submucosa with permanent monofilament suture. The graft is then secured a third time proximal to the bisected tails to the modiolus.
- Apply superolateral tension to create the desired smile and secure the proximal end of the graft.
  - A tunnel is dissected around the zygomatic arch, and the proximal end of the graft is passed deep to the arch. The graft is pulled superiorly and laterally to create a smile. Preoperative planning determines the vector of pull desired to mimic the contralateral side. Of note, the smile should then be overcorrected.
  - Alternative: The graft may be sutured to the temporalis fascia.
- Irrigate the wounds with antibiotic solution (because the tissue is adjacent to the oral cavity and contamination can occur), place drain, and close incisions.

Common Errors in Technique

- Smile is undercorrected
  - It is important to overcorrect the smile at the time of surgery as the graft will lose some tensile strength. Most changes occur within the first 3 to 6 weeks. The graft material itself, especially alloplastic material, should be stretched on the back table prior to inserting it in the patient to minimize the relaxation of the material over time.
- Circumferential placement of distal ends of the graft
  - This can severely limit the oral aperture and the patient's ability to open the mouth to its full extent.
- Graft placed in the wrong plane
  - If the graft is placed too superficially, it may be visible and result in a "saber sign," which mimics a dueling injury.
  - If the graft is placed too deep, augmented residual function could be lost.

POSTOPERATIVE PERIOD

Postoperative Management

- Patients require very little specific postoperative care after the majority of these procedures, and most are discharged on the day of surgery. However, there are a few precautions that the surgeon should take.
  - The patient with surgery that abuts the oral cavity should receive perioperative antibiotics.
  - Patients with muscular or facial attachments near the modiolus should be placed on a soft diet to avoid dehiscence.
  - No pressure dressings are used over nerve grafts or muscle flaps.

Complications

- Dehiscence of the suspension material
  - Most of these issues prove easier to remedy through revision surgery because the scar from the first procedure provides a better means of attachment.
- Granuloma, extrusion, or infection of foreign material used for suspension
  - These issues may affect both the alloplastic material itself as well as the material used to secure the graft (i.e., miniplates).

Alternative Management Plan

- Alternative suspension material may be used.
  - Instead of fascia lata, palmaris longus tendon may be harvested. Gore-Tex, AlloDerm, and suture suspension are also options.
- Dynamic reanimation with a gracilis microvascular free flap may be used if the patient is an appropriate candidate (see "Free muscle neurovascular anastomosis" section).

Nasal alar lateralization with fascia lata graft or use of Mitek anchor

OPERATIVE PERIOD

Instruments and Equipment to Have Available

- Facial plastics set
- If using fascia lata graft: fascia stripper and miniplate set
- If not using fascia lata graft: Mitek anchor (Mitek Products Inc., Westwood, Massachusetts)
- Permanent monofilament suture

Key Anatomic Landmarks

- Alar crease
- Lower lateral cartilage
- Anterior face of maxilla

Prerequisite Skills

- Facelift
- Open reduction and internal fixation of midface fractures

Operative Risks

- Intraoperative bleeding
- Injury to infraorbital nerve

Surgical Technique

- If using a fascia lata graft, harvest the graft from the lateral thigh.
- Perform alotomy (Fig. 180.2).
  - The incision at the alar crease may be extended into the NLF for wider exposure.
- Dissect laterally to expose the maxilla.
  - Elevate the periosteum to expose the anterior wall of the maxilla. Dissection should not proceed superior to 1 cm below the orbital rim, where the infraorbital nerve exits its foramen.
- If a fascia lata graft is used, secure the graft to the nasal ala, apply lateral tension, and secure the lateral graft to the anterior wall of the maxilla.
  - The medial aspect of the graft is secured to the fibrocartilage base of the lateral nasal ala with permanent monofilament suture.
  - The lateral aspect of the graft is secured to the maxilla with a miniplate.
- If using the Mitek anchor, drill the anchor into the front face of the maxilla. The device comes preloaded with a permanent suture that can be attached to the nasal ala and tightened.
- Irrigate the wound and close the incision.

Common Errors in Technique

- Alar base and supra-alar widening
  - Due to the oblique vector of suspension, the appearance of the nasal tip can change and become a source of dissatisfaction for patients.

POSTOPERATIVE PERIOD

Complications

- Dehiscence of suspension material
- Granuloma, extrusion, or infection of foreign material used for suspension

Alternative Management Plan

- Septorhinoplasty
  - Patients with a structural predisposition to valve collapse may benefit from a septorhinoplasty. For instance, alar batten grafting may help in cases of in-bowing during inspiration.
- Alternative suspension material may be used.
  - Gore-Tex, AlloDerm, and permanent suture are other options.

Lower lip wedge excision

Procedure provides horizontal shortening of the lip, improved oral competence and speech, and better symmetry from removal of the area that takes on a "fat lip" appearance.[4]

OPERATIVE PERIOD

Instruments and Equipment to Have Available

- Facial plastics set

Key Anatomic Landmarks

- Lateral commissure
- Horizontal chin crease
- Orbicularis oris
- Vermilion border

Prerequisite Skills

- Oral cavity resection for malignancy
  - Although not necessarily required, prior experience with oral cavity resection lends familiarity to handling tissues and identifying structures.

Operative Risks

- Intraoperative bleeding

Surgical Technique

- Outline borders of the wedge resection.
  - The lateral border should not reach the lateral commissure. The inferior border should be superior to the horizontal chin crease. The width of the resection should not exceed one-third of the distance between the junction of the normal and paralyzed side of the lower lip and the lateral commissure on the involved side.
  - A scalpel marking of the vermillion border for later approximation is helpful for accurate approximation of the lip.
- Excise full-thickness wedge.
- Close incision.

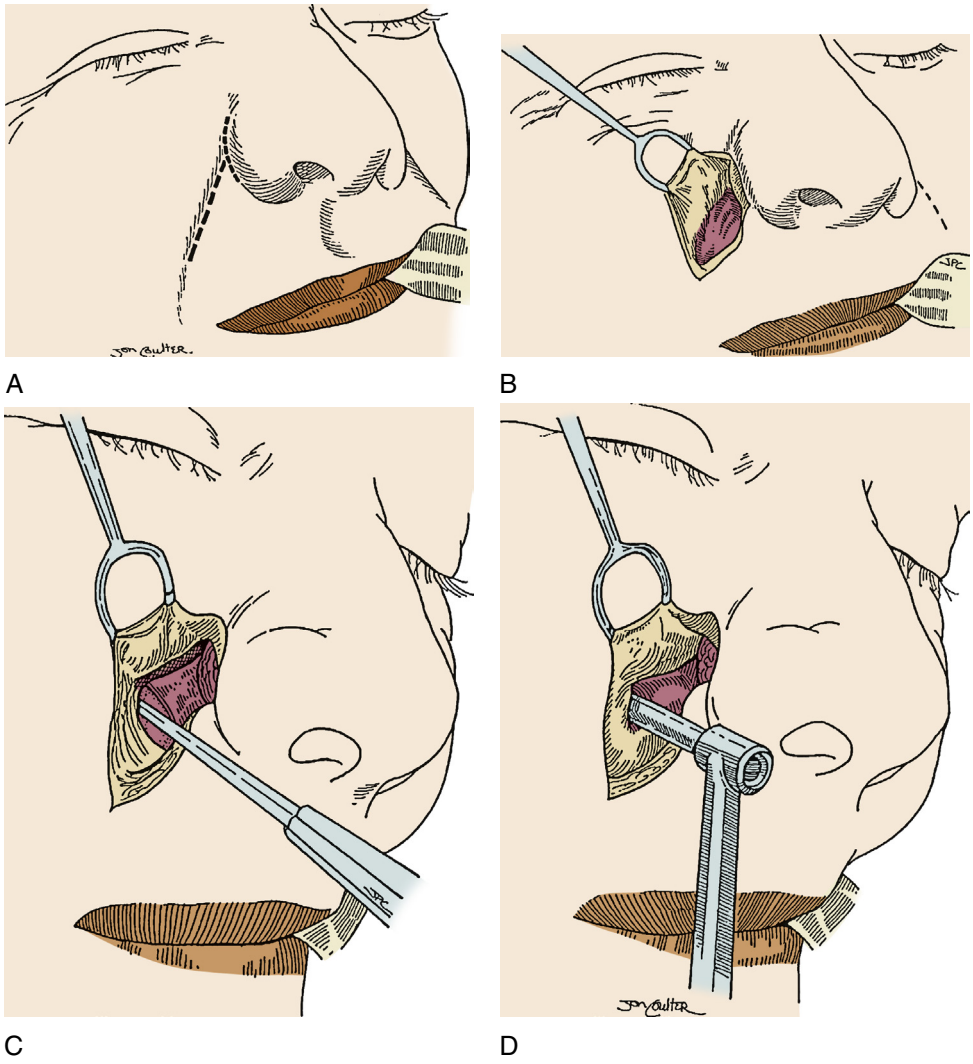

Fig. 180.2. Nasal alar lateralization with Mitek Mini Quick Anchor (Mitek Surgical Products, Inc., Norwood, Massachusetts). A, Incisions are made in the alar-facial and nasolabial creases. **B,** The deep aspect of the alar base is exposed. **C,** The periosteum is elevated to expose the lateral ascending buttress of the maxilla. **D,** A drill guide is placed perpendicular to the exposed area of maxilla to produce the proper direction and tension for securing fascia from the alar base. *(From May M: Regional reanimation: nose and mouth. In: May M, Schaitkin BM [eds]. Facial Paralysis: Rehabilitation Techniques. New York, NY: Thieme; 2003, pp 228 [see Fig.7.3], with permission.)*

- Realignment of the oral mucosa, orbicularis oris, and skin is performed in layers. The vermilion white roll must be realigned meticulously to avoid cosmetic deformity.

Common Errors in Technique

- Microstomia
  - Overresection is avoided by attending to the relative width of the resection as compared to the length of the lower lip.
  - Keep in mind that patients with large dentures will need a space adequate to put them in and take them out.

POSTOPERATIVE PERIOD

Complications

- Wound dehiscence
- Wound infection

Alternative Management Plan

- Contralateral lower lip weakening with chemodenervation with botulinum toxin or transection of fibers of the contralateral depressor labii inferioris
- Dynamic reanimation with digastric muscle transposition may be used if the patient is an appropriate candidate (see Chapter 168).

Dynamic Procedures

Dynamic procedures can be combined with other reanimation procedures or used independently. (1) Facial nerve repair by primary repair or interposition graft, (2) nerve substitution by transposition or graft, and (3) digastric muscle transposition and gracilis free flap are discussed here.[5,6] Reanimation of the upper and lower face, separately if possible, improves outcomes.

(1) Facial nerve repair by primary repair or interposition graft

PREOPERATIVE PERIOD

Indications

- Patients with available proximal and distal facial nerve systems
- Primary nerve repair is indicated when a tensionless closure can be accomplished between the free edges of the nerve.
- Repair with an interposition graft is indicated if a tensionless closure cannot be accomplished due to a gap between the free edges of the nerve.

Contraindications

- Unavailable proximal and/or distal facial systems
- Medical comorbidities with increased risk for general anesthesia
- Ongoing evaluation or treatment of facial paralysis

Preoperative preparation

- Counsel patient on the risks, benefits, and expectations of surgery.
- Determine timing of repair.
  - Ideally, nerve continuity should be reestablished at the time of the ablative operation or within the first 72 hours after injury. During this time period, the distal nerve branches still respond to electrical stimulation, allowing for easier intraoperative identification. However, repair performed up to 30 days after injury may still result in functional improvement.
- If performing an interposition graft, choose a graft nerve.
  - The nerve graft must be long enough to bridge the neural defect without tension and must provide a reasonable match to the endoneurial diameter of the free nerve edges.
  - The great auricular nerve is a good choice for short neural defects. The nerve can yield approximately 7 to 10 cm in length. The use of this nerve results in anesthesia of the ear lobe.
  - The sural nerve is a good choice for patients with neural defects greater than 10 cm. The nerve can yield up to 40 cm in length. The use of this nerve results in anesthesia of the lateral and dorsal aspects of the foot.
  - The medial antebrachial cutaneous nerve is a good choice for total nerve reconstruction as it has multiple branches. The nerve can yield approximately 10 to 15 cm in length. The use of this nerve results in anesthesia of the upper forearm.

OPERATIVE PERIOD

Instruments and Equipment to Have Available

- Operating microscope
- Nerve stimulator
- Bipolar Bovie cautery
- Microinstruments set
- Facial plastics set
- Fine permanent monofilament suture
- Closed suction drain

Key Anatomic Landmarks

- To identify the facial nerve (see Chapter 92).
  - Tragal pointer
  - Posterior belly of the digastric muscle
  - Tympanomastoid suture line
  - Styloid process
  - If necessary, the facial nerve may need to be identified proximally within the mastoid (see Chapter 134). The following landmarks are used.
- To identify the great auricular nerve
  - Sternocleidomastoid muscle (SCM)
  - Spinal accessory nerve (CN XI)
  - External jugular vein (EJV)

Prerequisite Skills

- Parotidectomy
- Prior experience with operative microscope and microinstruments

Operative Risks

- Further injury to distal facial nerve
- Intraoperative bleeding

Surgical Technique

Primary Repair of Facial Nerve

- Perform a modified Blair incision.
- Identify and prepare the ends of the injured facial nerve.
  - Ease of identification depends on the location of, mechanism of, and time since injury.
  - The facial nerve is identified as it exits the stylomastoid foramen using traditional surgical landmarks (see Chapter 92). The nerve is followed distally with gentle dissection and meticulous hemostasis until the site of injury is identified.
    - If attempting to identify the nerve in a previously operated and/or radiated bed, the surgery can be extremely difficult and may require retrograde dissection.
  - The free edges of the nerve are dissected several millimeters proximally and distally.
  - Methylene blue (1%) may be applied with a cotton-tipped applicator to the prepared ends to identify the epineurial (dark blue stain) and endoneurial (lighter blue stain) components of the nerve and to distinguish them from surrounding structures.
  - The epineurium is peeled and trimmed at the proximal and distal ends to expose the endoneurial surface, and the endoneurial surface is trimmed sharply.
  - A colored background may be placed under the nerve edges to create a work platform to stabilize the nerve and facilitate visualization.
- Perform suture repair.
  - The best method of nerve coaptation is the subject of controversy. Perineurial, epineurial, endoneurial, and intrafascicular repair have been described, but the data have not demonstrated a significant difference in outcome among these techniques.
  - The current standard is to perform a perineurial repair: Two to three fine (8-0 or 10-0) monofilament sutures are carefully placed through the perineurium, out the endoneurium, through the endoneurium, and out the perineurium to provide adequate approximation.
  - Irrigate the wound, place the drain, and close the incision.

Repair of Facial Nerve With Great Auricular Nerve Interposition Graft

- Perform a modified Blair incision.
- Identify and prepare the ends of the injured facial nerve.
- Harvest and prepare the graft.
  - Note: If using either the sural or medial antebrachial cutaneous nerves, the donor site must be prepped into the field at the beginning of the operation.
  - The great auricular nerve is found by drawing a line between the angle of the jaw and the mastoid. This line is bisected at a right angle by the great auricular nerve as it passes the posterior border of the SCM just posterior to the EJV.
  - The nerve is dissected off the SCM. Additional length may be obtained by dissecting the proximal end of the nerve (posterior and deep to the posterior border of the SCM) and the distal end (within the subcutaneous tissues superficial to the parotid).
    - When dissecting the proximal end of the great auricular nerve, care must be taken not to injure the CN XI as it courses from the deep surface of the SCM, parallel and approximately 1 cm superior to the great auricular nerve.

- The great auricular nerve is divided sharply proximally and distally. The length of the graft should be at least 1 to 2 cm longer than the gap to be bridged to allow for trimming of the graft ends.
- The epineurium is peeled and trimmed at the proximal and distal ends to expose the endoneurial surface, and the endoneurial surface may be further trimmed sharply.

- Match the endoneurial diameter of the graft ends to the facial nerve ends.
  - The endoneurial surface of the smaller nerve end may be cut on a bias to increase its surface area and yield a better match to the larger facial nerve end.
- Perform inset of the graft.
  - The graft is placed between the free edges of the facial nerve. The bridge created by the graft should form an S or C shape to ensure a tensionless closure.
    - Rotating the graft so that the distal end is sutured to the proximal end of the facial nerve has been described but has not been shown to result in superior outcomes.
  - Perineurial suture repair is performed as previously described at the two anastomotic sites.
- Irrigate the wound, place the drain, and close the incision.

Common Errors in Technique

- Traumatizing the facial or donor nerve by cutting through intact epineurium
  - Attempting to section a nerve with the epineurium intact may result in crush injury to its fascicular contents.
- Tension at the site of repair
  - Due to inadequate length of the facial nerve or interposition graft material. Tension is avoided by noting whether the facial nerve ends meet and hold together without need for suture.
- Mismatch of endoneurial surfaces
  - Mismatch is avoided by careful inspection under magnification and appropriate preparation of the nerve ends.

POSTOPERATIVE PERIOD

Complications

- Dehiscence of neural repair
- Injury to the CN XI while harvesting the great auricular nerve

Alternative Management Plan

- If patients fail facial nerve repair, either by primary repair or interposition graft, other dynamic reanimation techniques may be utilized (see "Nerve substitution by transposition or graft" and "Muscle transposition and free muscle neurovascular anastomosis" sections). Static procedures may also be considered (see "Static Procedures" section).
(2) Nerve substitution by transposition or graft (hypoglossal-facial transposition or graft, masseteric-facial transposition, cross-facial graft)

Hypoglossal-facial transposition

Hypoglossal-facial transposition and grafting procedures have demonstrated the most consistent results. Thus, they are presented here in the greatest detail, but their general surgical concepts can be applied to masseteric-facial and cross-facial nerve procedures (Fig. 180.3).

PREOPERATIVE PERIOD

Indications

- Patients with an unavailable proximal but intact distal facial nerve system
  - For example, patients who have undergone cerebellopontine angle tumor surgery where the nerve is injured but not grafted or have sustained severe temporal bone trauma

Contraindications

- Unavailable distal facial nerve system
  - For example, patients who have undergone a massive resection including extracranial nerves and muscles of expression or gunshot wounds or explosions
- Patients at risk for multiple or bilateral cranial nerve lesions
  - For example, patients with neurofibromatosis type II and adenoid cystic carcinoma
- Medical comorbidities with increased risk for general anesthesia
- Ongoing evaluation or treatment of facial paralysis

Preoperative Preparation

- Counsel the patient on the risks, benefits, and expectations of surgery.
  - Although mimetic movement is not possible, the majority of patients demonstrate voluntary facial movement with tone and symmetry at rest, with improvement seen predominantly in the midface.

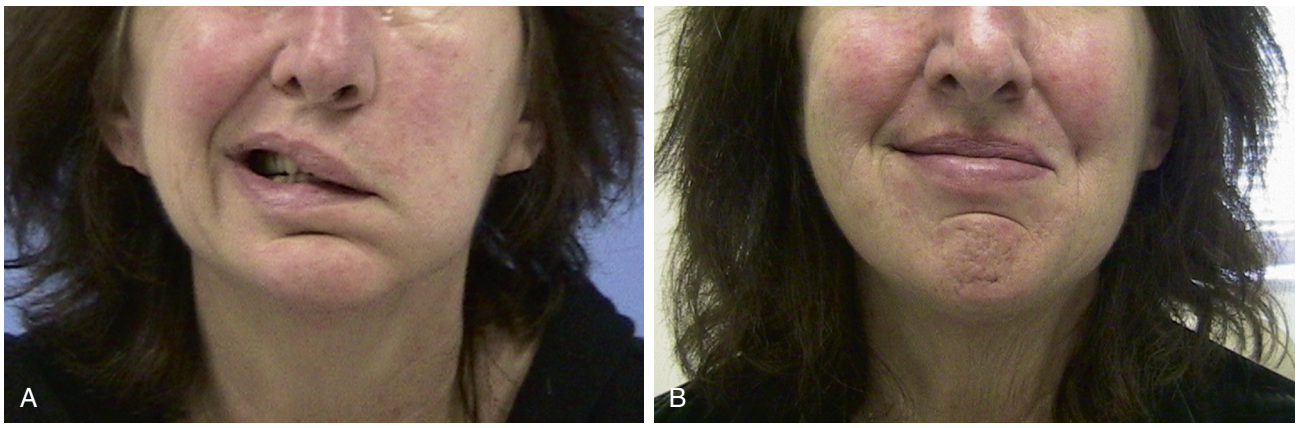

Fig. 180.3. Patient before, **A,** and after, **B,** hypoglossal-facial transposition.

- Defects due to donor nerve disruption with both nerve transposition and grafting should be described. Note: Grafting requires only partial disruption of the donor nerve and therefore results in less donor morbidity as compared to nerve transposition, which requires sacrifice of the entire donor nerve.
  - Disruption of the hypoglossal nerve results in hemitongue weakness.
  - Disruption of the masseteric nerve actually results in minimal functional morbidity.
- Determine the timing of the repair.
  - The hypoglossal-facial graft works best if performed in the first year of paralysis.
  - Traditional hypoglossal-facial transposition can be done as long as 2 years after injury with good results.
- Choose the donor nerve.
  - Ipsilateral hypoglossal nerve
  - Ipsilateral masseteric nerve
  - Contralateral facial nerve
- If performing a graft, choose a nerve graft.
  - The three most commonly used nerve grafts are the great auricular, sural, and medial antebrachial cutaneous nerves.

OPERATIVE PERIOD

Instruments and Equipment to Have Available

- Operating microscope
- Nerve stimulator
- Bipolar Bovie
- Microinstruments set
- Facial plastics set
- Fine permanent monofilament suture
- Closed suction drain

Key Anatomic Landmarks

- To identify the facial nerve (see Chapter 92).
  - Tragal pointer
  - Posterior belly of the digastric muscle
  - Tympanomastoid suture line
  - Styloid process
  - The facial nerve may need to be identified proximally within the mastoid (see Chapter 134)
- To identify the great auricular nerve
  - SCM
- To identify the hypoglossal nerve
  - Posterior digastric muscle
  - Internal jugular vein (IJV)
  - Internal carotid artery (ICA)
  - External carotid artery (ECA)
  - Occipital artery
- To identify the masseteric nerve
  - Zygomatic arch
  - Frontal branch of facial nerve
  - Temporomandibular joint (TMJ)

Prerequisite Skills

- Facial nerve repair by primary repair or interposition graft
- Prior experience with operative microscope and microinstruments

Operative Risks

- Further injury to distal facial nerve
- Intraoperative bleeding

Surgical Technique

Hypoglossal-Facial Transposition

- Perform a modified Blair incision.
- Identify and prepare the facial nerve.
  - The facial nerve is identified as it exits the stylomastoid foramen using traditional surgical landmarks (see Chapter 92). The nerve is followed distally with gentle dissection and meticulous hemostasis to just distal to the pes anserinus.
  - The nerve is divided just proximal to the pes anserinus. The epineurium of the deep/posterior aspect of the nerve is preserved to hold the facial nerve in position and prevent the nerve from retracting into the parotid gland.
- Identify and prepare the hypoglossal nerve.
  - The hypoglossal nerve is identified and isolated as it courses between the IJV and carotid vessels along the undersurface of the digastric muscle.
  - Just distal to the takeoff of the descendens hypoglossi, the epineurium is trimmed to expose the perineurium, and the nerve is sharply divided.
  - The proximal nerve ending is then brought medial to the digastric muscle to achieve additional length and allow for a tensionless closure.
- Match the endoneurial diameter of the hypoglossal nerve end to the facial nerve end.
- Perform suture anastomosis.
  - Perineurial suture repair is performed as described previously.
- Irrigate the wound, place the drain, and close the incision.

Hypoglossal-Facial Graft With Great Auricular Nerve

- Perform a modified Blair incision.
- Identify and prepare the facial nerve as described previously for hypoglossal-facial transposition.
- Harvest and prepare the graft.
  - The distance required is usually less than 8 cm, which is easily accomplished with the great auricular, sural, or medial brachial cutaneous nerves. The harvest technique for the great auricular nerve was described previously (see "Facial nerve repair by primary repair or interposition graft" section). The graft is placed in a moist, saline-soaked gauze sponge for later use.
- Identify and prepare the hypoglossal nerve.
  - Once the hypoglossal nerve is identified, it is exposed by placing a Penrose drain under the nerve (but over the descendens hypoglossi nerve) and gently stretching and elevating the Penrose drain with a self-retaining retractor.
  - A beveled incision is made not more than one-third of the way through the hypoglossal nerve, partially transecting the nerve and exposing a portion of the proximal endoneurial surface.
    - The diameter of the hypoglossal nerve is larger than that of the great auricular nerve, and only one-third of the nerve is used for grafting. Kartush has suggested passing an 8-0 monofilament suture through a point representing one-third of the neural diameter to allow the surgeon to know when this limit is reached.
    - Sectioning the nerve under visual confirmation of serial stimulation with an electric stimulator also allows the surgeon to work with decreased risk of permanent tongue weakness.
- Match the endoneurial diameter of the graft to the hypoglossal and facial nerves.

- Suture the proximal end of the graft to the proximal hypoglossal nerve.
  - Perineurial suture repair is performed as previously described. The Penrose drain is divided with scissors and gently removed without disrupting the graft.
- Suture the distal end of the graft to the distal facial nerve.
  - Perineurial suture repair is performed and tensionless closure ensured by S- or C-shaped graft placement as previously described.
- Irrigate the wound, place a drain, and close the incision.

Masseteric-Facial Transposition

- Masseteric-facial nerve transposition is performed with principles similar to those described for hypoglossal-facial transposition.
- The masseteric nerve is a branch of the mandibular branch of the trigeminal nerve (V3). When adequately dissected, it has sufficient length for tensionless, direct coaptation with the facial nerve.

The nerve may be identified within the "subzygomatic triangle."

Common Errors in Technique

- Traumatizing the facial or donor nerve by cutting through intact epineurium
- Tension at the site of repair
- Mismatch of endoneurial surfaces

POSTOPERATIVE PERIOD

Complications

- Dehiscence of neural repair
- Injury to the CN XI when harvesting the great auricular nerve

Alternative Management Plan

- If patients fail nerve substitution, either by primary transposition or graft, other dynamic reanimation techniques may be used (see "Muscle transposition and free muscle neurovascular anastomosis" section). Static procedures may also be considered (see "Static Procedures" section).
- When these procedures are successful, eye reanimation is often still insufficient and it may be necessary to employ eye reanimation procedures.

(3) Muscle transposition and free muscle neurovascular anastomosis

Digastric Muscle and Gracilis Muscle transposition

The digastric muscle transposition and gracilis muscle neurovascular free flap are discussed here (Fig. 180.4).[7] Use of the temporalis muscle for transposition is discussed elsewhere (see chapter 168).

PREOPERATIVE PERIOD

Indications

- Patients with neither proximal nor distal facial nerve system available
  - The digastric muscle works best in those with isolated lower lip paralysis. Combining this lip depressor with procedures on the lip elevators runs the risk of causing oral incompetence.
  - The gracilis muscle is harvested as a free flap from the thigh to allow for active re-creation of smile function.

Contraindications

- Lack of suitable motor input
  - The anterior belly of the digastric is innervated by the third division of the trigeminal nerve (V3).
  - The gracilis is usually innervated as a single-stage procedure with the masseteric branch of V3.
    - A single-stage jump graft from the hypoglossal nerve is a second option.
    - A two-stage cross-facial nerve graft is a third option.
- Medical comorbidities with increased risk for general anesthesia
- Ongoing evaluation or treatment of facial paralysis

Preoperative Preparation

- Counsel the patient on the risks, benefits, and expectations of surgery.
  - It is important to review the accomplishments of any previous reanimation procedures.
- Determine the duration and extent of current facial function.
- The patient is marked preoperatively with the vector and extent of movement desired.

OPERATIVE PERIOD

Instruments and Equipment to Have Available

- For digastric transposition:
  - Facial plastics set

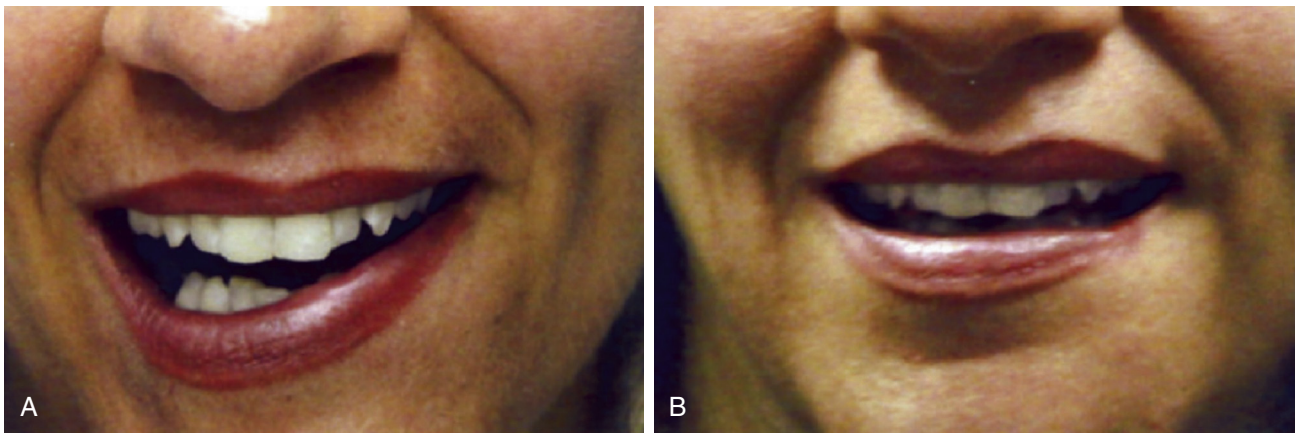

Fig. 180.4. Patient before, **A,** and after, **B,** digastric muscle transposition after ramus mandibularis paralysis during parotidectomy.

- Anchoring sutures of 4-0 Vicryl
- 6-0 nylon suture
- Closed suction drain

- For gracilis free flap:
  - Operating microscope
  - Nerve stimulator
  - Bipolar Bovie cautery
  - Microinstruments set
  - Anchoring sutures of 3-0 Ti-Cron (Syneture, US Surgical Covidien, Mansfield, Massachusetts)
  - Fine permanent monofilament suture
  - Closed suction drain

Key Anatomic Landmarks

- To identify the digastric muscle:
  - Vermilion border
  - Greater cornu of the hyoid
- To identify the gracilis muscle:
  - Temporalis fascia
  - SMAS
  - Modiolus

Prerequisite Skills

- Facelift
- Soft tissue techniques

Operative Risks

- Intraoperative bleeding
- Loss of any current facial function if dissection is deep to the SMAS

Surgical Technique

Digastric Muscle Transposition

- Select a horizontal neck crease for an incision at least 2 cm inferior to the mandibular border.
- Isolate the digastric muscle, and release the posterior tendon.
- Dissect and create a tunnel to the submental incision.
- Release the digastric muscle from the hyoid bone.
- Tunnel to the vermillion incision, preserving the nerve to the anterior belly of the digastric muscle.
  - In older patients, a lower-lip wedge resection to remove nonfunctional bulky lip can be performed (see "Static Procedures" section).
- Set tension on the rotated digastric to provide some initial static support.
- Attach the digastric with a 4-0 Vicryl suture to the orbicularis oris along its inferior ipsilateral border, and close the deep layer similarly.
- Irrigate the wounds, place the drains, and close the incisions.
  - Use 6-0 nylon suture for lip closure. Marking the vermillion border preoperatively assists in accurate reapproximation of the lip.

Gracilis Muscle Free Flap

- Mark the patient's smile based on the contralateral smile preoperatively.
- Harvest the gracilis muscle.
  - Measure the required length from the proposed new oral commissure to the temporalis fascia.
  - Anchoring sutures can be placed while the muscle is still in situ.
  - Preserve the neurovascular pedicle.
  - Less than one-half of the gracilis is required.
- Facelift incision dissected to the oral commissure or connected to the vermillion incision to pass muscle
- Anchoring sutures of 3-0 Ti-Cron set and tested for smile vector
- Microscopic repair of vein, artery, and then nerve
- Attach the adjusted length of the gracilis to the temporalis fascia.
- Irrigate the wounds with antibiotic irrigation because the tissue is adjacent to the oral cavity and contamination can occur, place the drain, and close the incisions.

Common Errors in Technique

- Anchor detachment
- Smile is undercorrected, overcorrected, or placed in an incorrect vector
- Thin skin flap reveals muscle
- Free flap vascular incident that results in loss of the flap
- Too much bulk

POSTOPERATIVE PERIOD

Complications

- Infection
- Hematoma
- Partial dehiscence
- Failure or underpowering of neural input

Alternative Management Plan

- If the reanimation procedures fail, static procedures may be considered (see section "Static Procedures").

DISCUSSION

Evidence-Based Medicine Question

When should facial nerve reinnervation, via primary neurorrhaphy or interposition grafting, be performed following nerve injury?

- Many studies have looked at this question and their results have been variable. In general, when the nerve is repaired within 30 days of injury, results have been excellent. Functional results decrease as the time from injury increases. Although there is evidence of recovery in patients grafted more than 1 year after injury, it is our opinion that repair after 1 year should not be performed given disappointing functional results. In these cases, nerve transpositions, muscle transpositions, or free flaps may be considered.

Editorial Comment

The degree of facial movement following gracilis muscle transfer depends on the donor motor nerve density. The masseter nerve provides a more robust innervation source than the cross-facial nerve. Reconstruction with either innervation source provides an improvement in oral commissure excursion. Patients with masseteric innervation will likely have an increased range of excursion, whereas patients with cross-facial innervation may be better able to generate a spontaneous smile.

Fred W.B. Deleyiannis

Access the review questions online at http://www.expertconsult.com

REFERENCES

1. Hohman MH, Hadlock TA. Etiology, diagnosis, and management of facial palsy: 2000 patients at a facial nerve center. Laryngoscope 2014;124:E283–293.
2. Robinson M, Baiung J, Hohman M, et al. Facial rehabilitation. Oper Tech Otolaryngol 2012;23:288–296.
3. May M. Regional reanimation: nose and mouth. In: May M, Schaitkin BM, editors. The Facial Nerve, May's. 2nd ed New York, NY: Thieme Medical; 2000. p. 775–796.
4. Glenn MG, Good RL. Surgical treatment of the "marginal mandibular lip" deformity. Otolaryngol Head Neck Surg 1987;97:462–468.
5. May M. Nerve substitution techniques. In: May M, Schaitkin BM, editors. The Facial Nerve, May's. 2nd ed New York, NY: Thieme Medical; 2000. p. 611–634.
6. Swartz WM. Free muscle transfers for facial paralysis. In: May M, Schaitkin BM, editors. The Facial Nerve, May's. 2nd ed New York, NY: Thieme Medical; 2000. p. 667–676.
7. Hohman MH, Hadlock TA. Microvascular free gracilis transfer for smile reanimation. Oper Tech Otolaryngol 2012;23:262–267.

REVIEW QUESTIONS

1. Patients with facial paralysis after acoustic tumor surgery are an example of:
   a. Proximal system intact and distal system intact
   b. Proximal system intact and distal system not available
   c. Proximal system not available and distal system intact
   d. Neither system available

2. Which of the following suspension materials has the lowest risk of extrusion?
   a. Permanent suture
   b. Gore-Tex
   c. AlloDerm
   d. Fascia lata

3. Although the best method of nerve coaptation is controversial, the current standard method is which of the following?
   a. Perineurial repair
   b. Epineurial repair
   c. Endoneurial repair
   d. Intrafascicular repair

181 Marginal Mandibulectomy

Melonie Nance

INTRODUCTION

1. The goal of surgical management of any cancer of the head and neck is to remove the cancer in its entirety and preserve form and function. Marginal mandibulectomy (MM) evolved as a surgical technique to obtain the margin around the tumor yet avoiding the cosmetic and functional complications of segmental mandibulectomy (SM). Crile first described the MM in 1923 as an incision that is "carried down to the underlying bone, and thence into the bone by a sharp chisel or saw, so that a slice of bone can be split off in one piece, bearing the undisturbed cancer off as on a bone platter."[1] The three most common locations of cancer of the oral cavity in which MM plays a role include the floor of the mouth, the gingival ridge, and the retromolar trigone, where carcinoma abuts the mandible.
2. It was once believed that the oral cancers invade the mandible by draining through the lymphatic channels in the mandibular periosteum on their way to the cervical lymphatics. Hence, segmental mandibulectomies and composite resections were performed for oncologic completeness. Reconstructive surgery was still in rudimentary stages so that resections resulted in suboptimal cosmetic and functional outcomes, including malocclusion, temporomandibular joint dysfunction, *Andy Gump* deformity, tracheostomy, and gastrostomy tube dependence. Marchetta et al. later demonstrated that mandibular involvement occurs predominantly via direct invasion of the periosteum.[2] This finding eliminated the mandate for SM. Furthermore, Barttelbort et al. proposed a theory of tumor invasion of the mandible. The cancer initially quickly invades the broad plane of the mandible superior to the mylohyoid muscle attachment. Involvement of the inferior lingual cortical plate occurs infrequently and late.[3] Because of this theory, MM became a feasible procedure for removal of the cancer without compromising the mandibular arch.
3. The local recurrence and survival rates after segmental and MM were shown to be comparable (though one must be aware of the patient selection bias: Patients with gross bone involvement require a more extensive procedure). MM became an oncologically sound procedure in the management of oral cavity cancers and securing the margin around the cancer. The adverse cosmetic and functional outcomes are limited by preservation of the architecture of the mandibular arch and native muscular attachments. In addition, dental rehabilitation is a viable option in the form of a removable dental plate or dental implants. A major and legitimate concern with this procedure is the inability to obtain reliable intraoperative bone margins. Hence, careful preoperative planning must be executed.

KEY OPERATIVE LEARNING POINTS

1. The goal of MM is to secure the margin around the cancer.
2. Proper patient selection is the key: Meticulous preoperative clinical and radiologic evaluation should be performed to rule out bone involvement.
3. Osteotomies must be planned before the surgery.
4. Osteotomies should be placed with assurance of preservation of healthy residual teeth and allowing for dental rehabilitation.
5. Most recurrences occur in the soft tissues, not the bone. Hence, careful intraoperative frozen section analysis should be used to avoid recurrence in the soft tissues.
6. Most MM defects can be successfully reconstructed with the split-thickness skin graft.

PREOPERATIVE PERIOD

History

Physical Examination

1. Despite invention and advancement of many sophisticated diagnostic imaging techniques, physical examination remains the mainstay in decision making. Invasion of the mandible should be suspected and assessed in any patient with an ulcerative lesion within the vicinity of oral or lingual cortices, as up to one-third of cases of histologically proven mandible invasion do not show clinical signs of bone invasion preoperatively.[4] Tsue et al. and Werning et al. independently observed that the location of the primary cancer was predictive of mandibular invasion: Bone invasion was more likely to be present in cancers of the floor of the mouth, retromolar trigone, and inferior alveolar ridge.[5,6] The presence of dentition was shown to influence perineural invasion. The inferior alveolar nerve was four times more likely to be involved by the cancer in the edentulous mandible than in the partially dentate mandible.[7] The resorption of the alveolar ridge appears to be greater in the edentulous mandible, which places the nerve in a more superficial position, making it more susceptible to invasion of the cancer. Bimanual palpation allows the surgeon to determine whether the tumor is fixed to the bone, signifying bone invasion. The examination may be limited by pain and might require topical or even a general anesthetic (Fig. 181.1).

Imaging

1. Werning et al. demonstrated that clinical evaluation of mandibular bone invasion was more sensitive than radiologic assessment (a mixture of Panorex, occlusal views, routine radiographs, and computed tomography [CT]) (sensitivity

of 73%), while radiologic evaluation was more specific (specificity of 82%) and had a higher reliability index (0.29 vs. 0.19). They concluded that the combination of clinical and radiologic evaluations is more accurate than either one alone.[6] A newer tomographic modality, single positron emission CT (SPECT), was shown to have 87% overall accuracy in predicting bone invasion, as compared to 71% for clinical examination, CT scanning, and Panorex.[8] SPECT sensitivity approached 95%, as compared to 55% for conventional CT and 50% for Panorex. Another tomographic evaluation named Dentascan was found useful in evaluation of the buccal and lingual mandibular cortices. The Dentascan images consist of panelliptical and parasaggital views derived from the reformatting of the regular axial CT images. Brockenbrough et al. demonstrated sensitivity of 95%, specificity of 79%, positive predictive value of 87%, and negative predictive value of 92% for Dentascan.[9] One of the immediately obvious limitations of CT scanning in the oral cavity is dental artifact. Magnetic resonance imaging (MRI) does not have this shortcoming and may be more useful in the evaluation of medullary bone. It also produced promising results: Sensitivity of MRI in detecting mandibular invasion was 93% with 93% accuracy.[10]

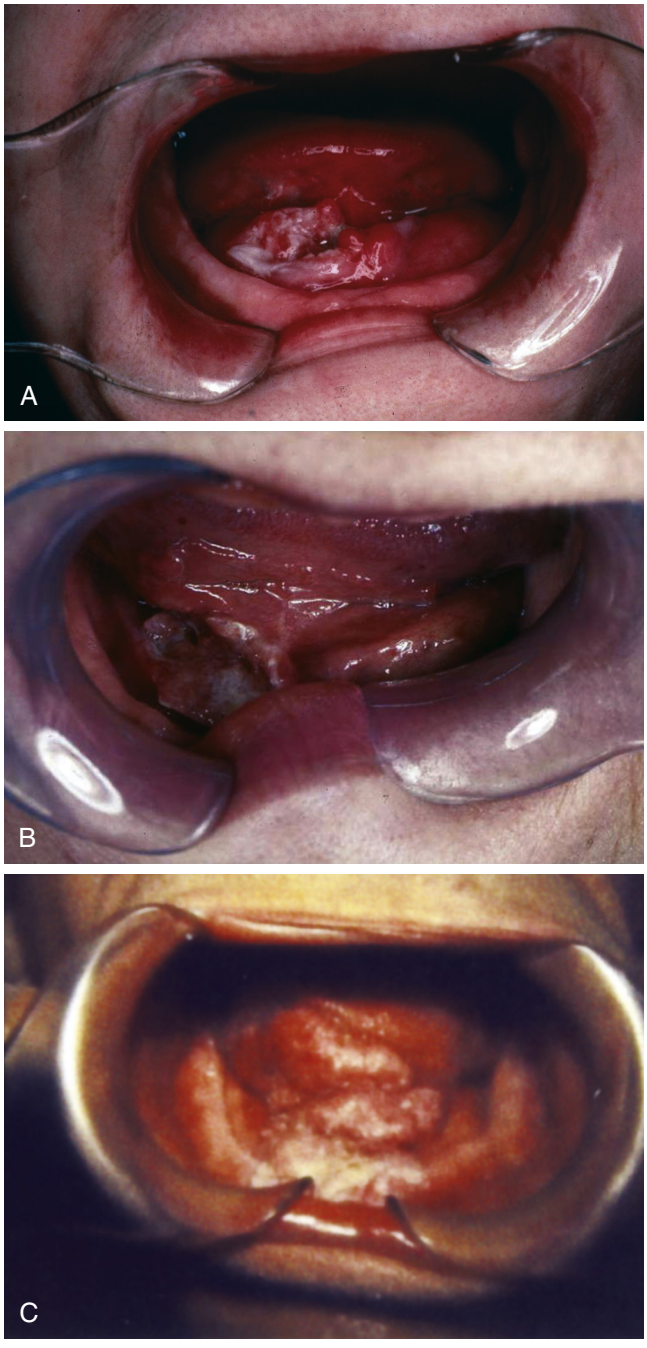

Fig. 181.1. A, Cancer of the floor of the mouth too close to the mandible to resect without marginal mandibulectomy. **B,** A tumor adherent to the mandibular periosteum. **C,** A tumor crossing but not invading the mandible.

Indications

1. Tumor so close to the mandible that it is not feasible to obtain an adequate margin of resection without removing the alveolar process of the mandible
2. Abutment of the lesion to the lingual aspect of the periosteum of the mandible
3. Tumor that crosses the alveolus and into the gingivobuccal sulcus

Contraindications

1. Absolute
   a. Gross destruction of the bone
   b. Invasion by cancer of the mandibular canal
2. Relative
   a. Edentulous mandible with reduced vertical height
      1) The concern in question is sacrifice of the endostial blood supply, placing the remaining bone at risk of avascular necrosis and a pathologic fracture.
   b. Previously radiated mandible
      1) While there is usually a single port of cancer entry into the bone in radiation-naïve mandible, histologic analysis of previously radiated bone demonstrates multiple tumor loci. This finding suggests that the radiation alters bone resistance to tumor spread, likely by impairing the periosteal blood supply and weakening it, making the pattern of spread less predictable and posing a real risk of leaving cancer behind by performing subtotal resection.[7]

Preoperative Preparation

1. While clinical assessment in combination with radiographic evaluation is of paramount importance, direct examination of the bone under the periosteum remains the gold standard for identifying mandibular invasion.
2. In addition to the informed consent, preoperative patient counseling must also encompass discussions of postoperative airway and nutrition management, which may include temporary tracheostomy and placement of a nasogastric tube. In addition, various reconstructive options should be reviewed.

OPERATIVE PERIOD

Anesthesia

1. General anesthesia
   a. Orotracheal intubation with endotracheal (ET) tube placed on contralateral side from tumor is sufficient.
   b. Nasotracheal intubation may be considered, since it provides greater exposure.
   c. If the patient is to have a tracheostomy, it should be done prior to the surgery and an endotracheal tube placed in the tracheostoma to deliver the anesthetic.

Positioning

1. The patient is placed in the supine position.
2. Shoulder roll is not necessary for tumor resection but may be placed preoperatively if a neck dissection is planned.

Perioperative Antibiotic Prophylaxis

1. Standard oral cavity perioperative antibiotics are recommended such as Unasyn or similar.

Monitoring

Usual monitoring for general anesthesia

Instruments and Equipment to Have Available

1. Standard head and neck and dental surgical instrument set
2. Multiple types of cheek and tongue retractors should be available.
3. Both a sagittal and reciprocating saw should be available. The surgeon must determine the most appropriate one depending on the position of the tumor, exposure, retraction, and degree of mouth opening.

Key Anatomic Landmarks

1. The mandible is a horseshoe-shaped facial bone of paramount importance for maintaining an aesthetically pleasing appearance and supporting the attachment of muscles critical for proper oral competence, speech, mastication, and swallowing. It is derived from the first branchial arch. It consists of medullary and cortical bone. The cortical bone is thinner at the occlusal surface. The inferior alveolar nerve, the third division of the trigeminal nerve, enters the mandibular canal at the mandibular foramen. It travels through the mandibular canal to exit the mental foramen to provide sensation to the lower teeth (incisive nerve) and lip (mental nerve). The blood supply to the mandible is derived through the periosteum via facial arteries. Important aspects to be considered in MM are as follows:
   a. Mandibular height—With atrophy of the edentulous mandible, the vertical height is reduced and (1) the alveolar canal may lie very close to the surface and (2) the remaining mandible may be too thin and therefore at risk of a pathologic fracture.
   b. Location of the mental foramina—Ideally, the osteotomies should be placed at least 7 mm away to protect the nerve bundle.
   c. Position of the mylohyoid line—It is the attachment of the mylohyoid muscles, which are considered the "deep margin" of the floor of mouth.

Prerequisite Skills

1. Familiarity with oral cavity structure
2. Familiarity with neck dissections
3. Experienced with skin grating techniques

Operative Risks

1. Cosmetic dissatisfaction
   a. This can be mitigated by properly managing expectations with the patient in an honest preoperative discussion.
2. Postoperative pathologic fracture
3. Dental malalignment
4. Injury to the inferior alveolar nerve

Surgical Technique

1. Surgical planning
   a. MM involves two vertical and one horizontal osteotomies in continuity with the excised cancer, preserving the inferior rim of the mandible.
      1) There are two variations on the technique:
         a) Rim mandibulectomy involves resection of the full thickness of the upper mandible.
         b) Sagittal mandibulectomy involves resection of the partial thickness of the lingual cortex of the mandible.
2. Technique
3. After achievement of adequate general anesthesia, perioperative antibiotics are administered intravenously, and the head and neck area and the appropriate reconstructive option donor site are prepped and draped. Direct laryngoscopy should be performed first to confirm preoperative evaluation findings. If the findings remain favorable for proceeding with the surgery, a tracheostomy is placed if needed. A bite block is used to prop the mouth open, and various cheek retractors are available to facilitate exposure. A silk suture is placed in the midline of the tongue approximately 1 cm posterior to the tip for traction purposes. The lesion is identified, the mucosa is dried with gauze, and the extent of the resection is marked with methylene blue, marking pen, or needle tip monopolar cautery (on cut mode). Following the oncologic principle of en bloc resection, the MM always remains in continuity with the soft-tissue specimen.
4. Incisions are made with the needle tip monopolar cautery (Fig. 181.2). A marking suture is placed on the known

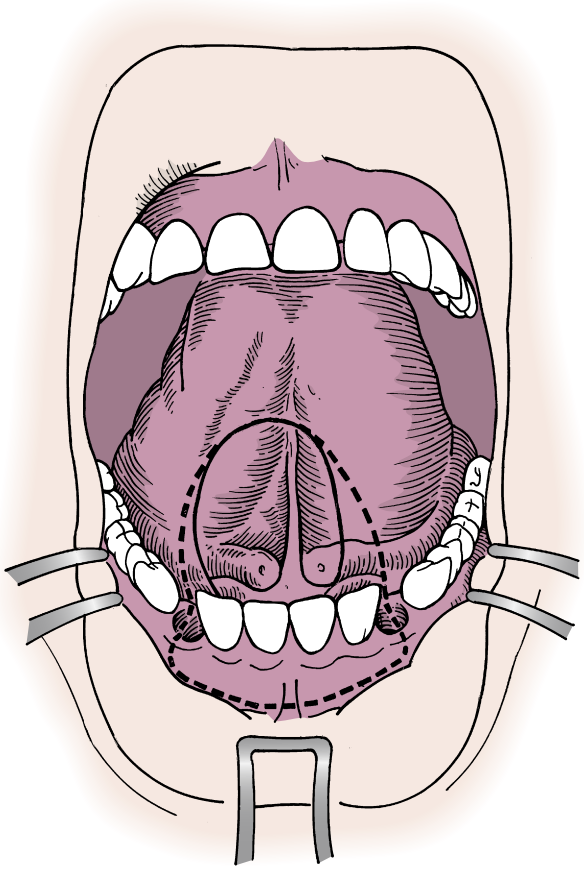

Fig. 181.2. An incision in soft tissue with dissection of the periosteum off the bone.

margin of the specimen before removing it to orient the pathologist who will be examining the specimen with frozen sections. Ideally, the pathologist should be present in the operating room for proper in situ orientation. The incision is carried through periosteum down to the bone. A broad, sharp periosteal elevator is used to elevate the mucoperiosteum off the mandible, thereby exposing the alveolar process. Dental extractions are performed if the tooth is within the planned osteotomy site. The osteotomy should be made in the middle of the tooth socket to preserve healthy bone adjacent to the remaining tooth.

5. Originally, it was thought that since there is a chance that the inferior alveolar nerve can be invaded by the cancer, it should be removed along with the mandibular canal en bloc with the MM. However, Brown and Brown et al. did not find evidence supporting the significant spread of the cancer along the nerve or through the medullary space. They concluded that the excision of the mental canal with the nerve within it is not a required part of the MM.
6. While the tumor size dictates the amount of bone to be excised, it is advised to leave at least 1 cm of the bone to reduce the chance of postoperative fracture. An oscillating saw is used for both vertical transverse osteotomies. It is important to perform complete osteotomies, as trying to remove the bone forcefully with a suboptimal osteotomy may lead to mandibular fracture. The osteotomies in rim mandibulectomy can be placed at 90-degree angles to each other (Fig. 181.3).
7. Once free of the mandible, the bone fragment is left attached to the soft tissue part of the tumor, and the specimen is delivered en bloc.
8. While the soft tissue margins are assessed by frozen section analysis, hemostasis is achieved with cautery and bone wax, and osteotomy sites are smoothed with a pineapple drill bit.
9. Closure/reconstruction
   a. The wound is closed primarily or with a split- or full-thickness skin graft in radiation-naïve patients. Free tissue transfer is employed when additional soft tissue coverage is needed (in cases of partial glossectomy or maxillectomy) or in radiation failure cases. The skin grafts heal well, because most of the cut bony surface is cancellous rather than cortical bone and provides adequate recipient bed vascularity for the graft survival. However, in the update by Deleyiannis et al., one-fifth of the patients reconstructed with split-thickness skin grafts that received adjuvant radiation developed osteoradionecrosis. Hence, free tissue transfer should be considered in cases of sizeable tumors, which may warrant postoperative radiation (Figs. 181.4 and 181.5).

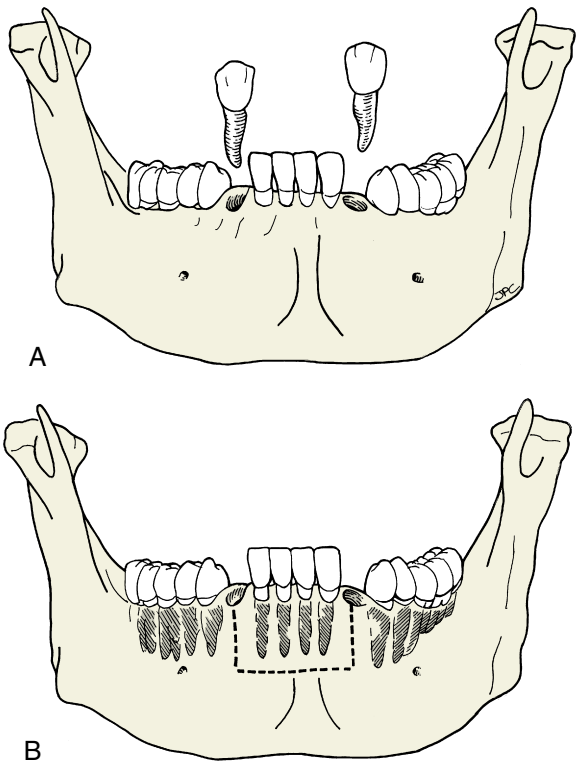

Fig. 181.3. A, Teeth are extracted and osteotomies are placed in the tooth sockets to avoid eventual loss of support to the remaining teeth. **B,** Vertical and horizontal osteotomies are made with an oscillating saw.

Common Errors in Technique

1. Invasion of bone may be underestimated in up to one-third of the cases.
2. Improperly placed or executed osteotomies may compromise dental health and future dental rehabilitation and mandibular strength.
3. Failure of the proper intraoperative frozen section analysis may lead to positive margin, compromising local control.

POSTOPERATIVE PERIOD

Postoperative Management

1. Postoperative care is similar to the patients with floor of mouth soft tissue cancer resection. Antibiotic prophylaxis is given for the length of time accustomed to a

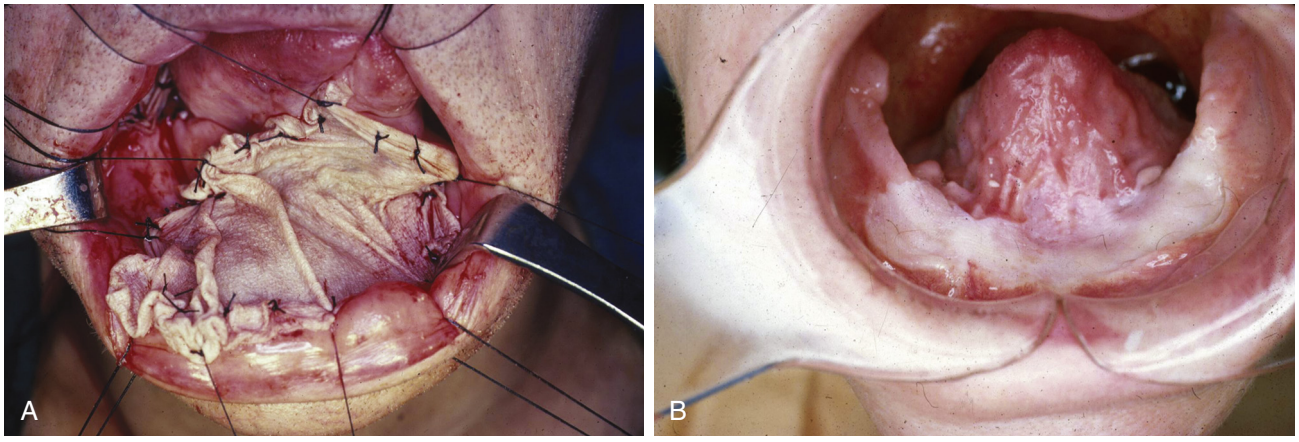

Fig. 181.4. A, A split-thickness skin graft is sewn into place over the defect. **B,** The healed skin graft overlying soft tissue and bone.

particular institution. Routine tracheostomy care is advised in cases where preoperative tracheostomy was placed. In patients whom split-thickness skin-graft reconstruction was employed, liquid diet is started as soon as cleared by speech and language pathology evaluation. The bolster holding the graft in place can be removed in 5 to 7 postoperative days. The patient does not need to remain in the hospital for that long and can be discharged once the calorie counts confirm adequate nutritional intake (exceptions are patients with newly placed tracheostomy—they need to remain in the hospital until the first tracheostomy change). In cases with free tissue transfer, postoperative protocols specific to that institution should be followed.

Complications

1. The major complication of MM is intraoperative or postoperative fracture of the mandible. Fracture can take place intraoperatively in two situations. First occurs when a vertical osteotomy is extended deeper than necessary. Mandibles with decreased vertical height (such as an edentulous mandible) are particularly vulnerable to this type of incident. Second happens when the osteotomies are not complete and the surgeon is trying to remove the bone forcefully by fracturing the alveolar process or the cortex of the bone. In both settings, the fracture must be repaired intraoperatively with a compression plate. The reported postoperative fracture rate ranges between 2% and 16%. The risks associated with this complication included concurrent osteoradionecrosis, prior radiation, facial artery ligation, and periosteal stripping.
2. In the review of 43 patients by Chen et al., the rate of osteoradionecrosis was 17.4% in patients who received adjuvant radiation after undergoing MM. It developed between 2 and 6 months after completion of radiation. All patients recovered without surgical interventions. Four of 137 (2.5%) MM patients presented by Pathak et al. developed osteoradionecrosis postoperatively. All four were managed with SM and free tissue transfer.

DISCUSSION

Evidence-Based Medicine Question

Does the use of an MM decrease the survival rate in cancer of the oral cavity?

1. Survival
   a. Several authors found that the type of mandibular resection (segmental vs. marginal) did not affect the 5-year survival, supporting the MM as the oncologically sound alternative to a more extensive segmental resection. Munoz et al. report a 5-year survival rate of 60.35% for patients who underwent marginal or SM. The type of resection did not affect the survival. It was the positive soft tissue margin and bone invasion that correlated with the poor 5-year survival (Figs. 181.6 and 181.7). O'Brien et al. similarly emphasized clear soft tissue margin status as the predictor of survival. In their 11-year experience with MM, Pathak et al. report 5-year disease-free survival of 62.9% and cause-specific survival of 72.2%. Cause-specific survival was significantly better in patients with gingival buccal than floor of mouth cancer. Age, tumor stage, margin status, bone involvement, and adjuvant radiation did not affect 5-year cause-specific survival. In their 13-year experience, Muscatello et al. reported similar 5-year disease-free survival of 77.3% and overall survival of 60.7%.
2. Recurrence
   a. The reported rates of recurrence in patients who underwent MM range between 4% and 20%. Most recurrences are reported to occur within the first year. Munoz Guerra et al. compared an MM group (50 patients) with an SM group (56 patients). They failed to show that bone invasion affected local recurrence in either group and identified tumor stage as the only factor predictive of local recurrence. Similar findings of no statistically significant correlation between the bone invasion and recurrence were reported by other groups. Several research groups demonstrated that the recurrences predominantly occur within the soft tissue. In the review of 43 MM patients by Chen et al., two-thirds of patients with local recurrence underwent salvage surgery, and 83.3% were controlled oncologically, bringing the total local control after salvage surgery to 90.7%. Similar numbers for salvage treatment and total local control were reported by Pathak et al.
3. Quality of life

Rogers et al. administered the university of Washington quality of life questionnaire (UQ-QOL) to 44 patients undergoing an MM and 57 patients undergoing SM preoperatively and postoperatively at 6, 12, and 18 months. The SM group had more pain, problems with chewing, and lower overall UW-QOL scores. The SM group also scored worse at all postoperative time points, specifically, in areas of appearance, swallowing, recreation, and chewing. The difference between groups diminished in patients with large tumors and those who underwent adjuvant radiation. Wolff et al. assessed quality of life by assigning the eastern cooperative oncology group (ECOG) performance status to their 82 SM and 54 MM patients. While there were no statistically significant differences in survival, number of recurrences, second primaries,

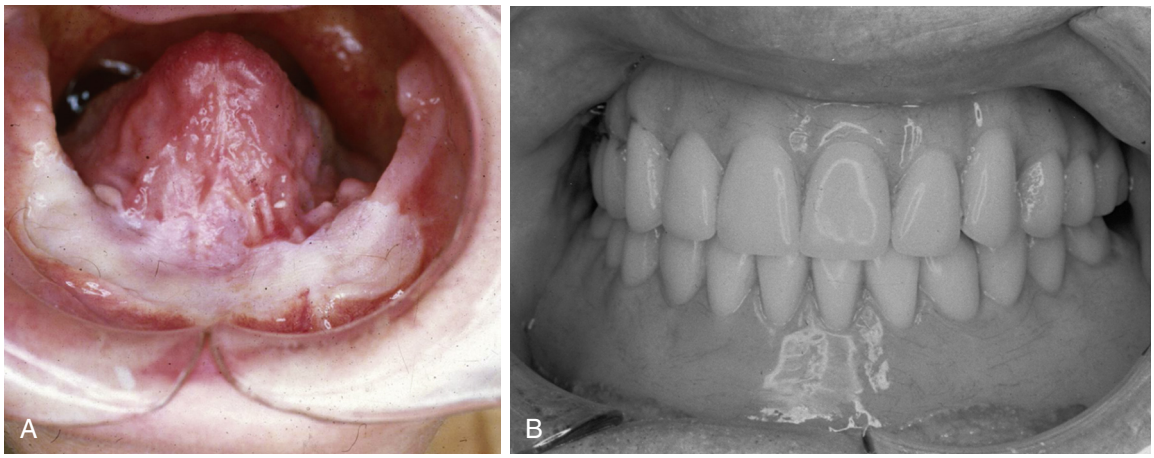

Fig. 181.5. A, a healed split-thickness skin graft and, **B,** Complete dentures in a patient following marginal mandibulectomy and excision of the cancer.

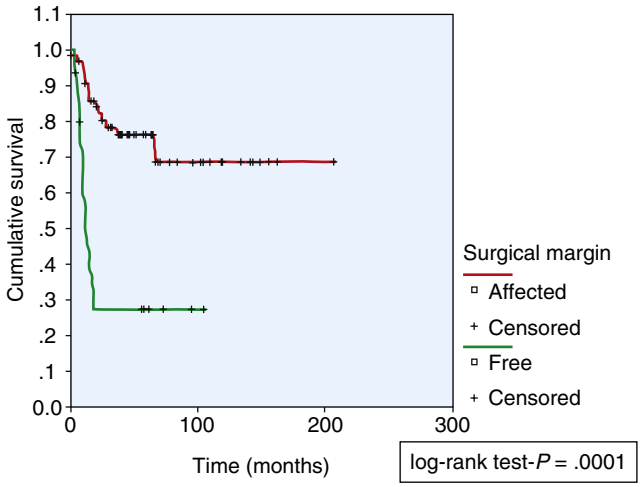

Fig. 181.6. Kaplan-Meier estimate of survival by surgical margin status. Tumor infiltration beyond the margin of resection had a negative effect on survival. *(Reprinted with permission from Muñoz Guerra MF, Naval Gías L, Rodríguez Campo F, Sastre Pérez J: Marginal and segmental mandibulectomy in patients with oral cancer: a statistical analysis of 106 cases. J Oral Maxillofac Surg 2003, 61:1293.)*

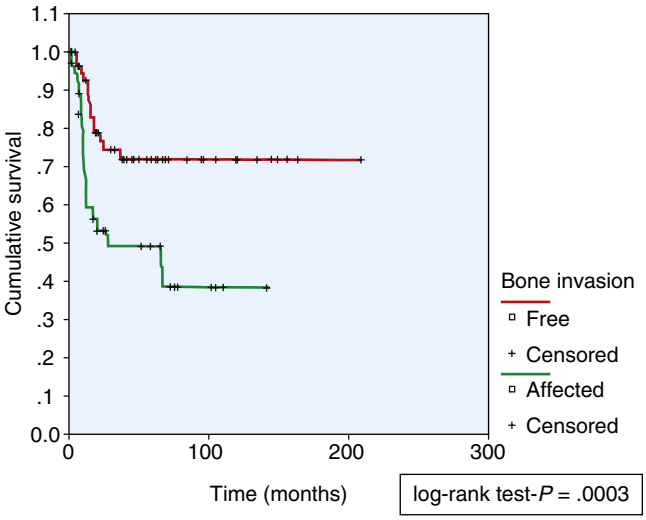

Fig. 181.7. Kaplan-Meier estimate of survival related to bone invasion. Tumor infiltration beyond the margin of resection had a negative effect on survival. *(Reprinted with permission from Muñoz Guerra MF, Naval Gías L, Rodríguez Campo F, Sastre Pérez J: Marginal and segmental mandibulectomy in patients with oral cancer: a statistical analysis of 106 cases. J Oral Maxillofac Surg 2003, 61:1293.)*

metastases, and postoperative complications between the groups, over 50% of MM group were able to carry normal unrestricted activity compared with preoperative status, where only 35% of SM group were able to achieve the same.

Editorial Comment

MM is one of the first and best examples of modifying a surgery (i.e., SM) to preserve function and cosmesis, while following sound oncologic principles to attain a complete resection of the tumor. This chapter presents a scholarly review of the procedure, including its historical background and addressing oncologic and surgical principles.

As for any organ-sparing surgery, adequate patient selection is a requisite to obtain superior outcomes. A high resolution CT scan with bone algorithm or Dentascan helps to identify the presence of bone erosion and estimate the height of the mandible in edentulous patients (an atrophic mandible will not tolerate an MM irrespective of oncologic feasibility). A dual-energy CT eliminates much of the dental amalgam artifact; thus, its need should be identified during the oral examination. Nonetheless, bimanual palpation and the ability to glide the lesion and surrounding soft tissues over the bone are superior to imaging in those patients without gross involvement by CT. Unfortunately, an adequate examination is often limited by pain, therefore requiring general anesthesia. In any case, these two techniques are complementary; thus, using them in combination is best.

Technically, MM has not changed significantly since its inception. However, the additional use of titanium reconstruction plates has extended the indications in patients with mild to moderate atrophy of the mandible and decreased the incidence of postoperative pathologic fractures. In addition, the use of thin and pliable flaps such as the platysma, submental, and radial forearm microvascular flaps can accelerate healing and preserve function.

Ricardo Carrau

Access the review questions and additional sources list online at http://www.expertconsult.com

REFERENCES

1. Crile GW. Carcinoma of the jaws, tongue, cheek, and lips. Surg Gynecol Obstet 1923;36:159–162.
2. Marchetta FC, Sako K, Murphy JB. The periosteum of the mandible and intraoral carcinoma. Am J Surg 1972;122:711–713.
3. Barttelbort SW, Ariyan S. Mandible preservation with oral cavity carcinoma: rim mandibulectomy versus sagittal mandibulectomy. Am J Surg 1993;166:411–415.
4. Weisman RA, Kimmelman CP. Bone scanning in the assessment of mandibular invasion by oral cavity carcinomas. Laryngoscope 1982;92:1–4.
5. Tsue TT, McCulloch TM, Girod DA, et al. Predictors of carcinomatous invasion of the mandible. Head Neck 1994;16:116–126.
6. Werning JW, Byers RM, Novas MA, et al. Preoperative assessment for and outcomes of mandibular conservation surgery. Head Neck 2001;23:1024–1030.
7. McGregor AD, MacDonald DG. Reactive changes in the mandible in the presence of squamous cell carcinoma. Head Neck Surg 1988;10:378–386.
8. Imola MJ, Gapany M, Grund F, et al. Technetium 99m single positron emission computed tomography scanning for assessing mandible invasion in oral cavity cancer. Laryngoscope 2001;111(3):373–381.
9. Brockenbrough JM, Petruzzelli GJ, Lomasney L. DentaScan as an accurate method of predicting mandibular invasion in patients with squamous cell carcinoma of the oral cavity. Arch Otolaryngol Head Neck Surg 2003;129:113–117.
10. Bolzoni A, Cappiello J, Piazza C, et al. Diagnostic accuracy of magnetic resonance imaging in the assessment of mandibular involvement in oral-oropharyngeal squamous cell carcinoma: a prospective study. Arch Otolaryngol Head Neck Surg 2004;130:837–843.

REVIEW QUESTIONS

1. Marginal mandibulectomy is appropriate for patients presenting with which symptoms?
   a. Erosion of the bony cortex of the mandible
   b. Involvement of the mandibular canal by cancer
   c. Abutment of the lesion onto the periosteum
   d. Circumferential encasement of the mandible without bone invasion

2. Complications of marginal mandibulectomy include all of the following except:
   a. Oral fistula
   b. Pathologic fracture of the mandible
   c. Malocclusion
   d. External cosmetic deformity

ADDITIONAL SOURCES

Brown J. Mechanisms of cancer invasion of the mandible. Curr Opin Otolaryngol Head Neck Surg 2003;11:96–102.

Brown JS, Lowe D, Kalavrezos N, et al. Patterns of invasion and routes of tumor entry into the mandible by oral squamous cell carcinoma. Head Neck 2002;24:370.

Chen YL, Shih-Wei K, Fang KH, et al. Prognostic impact of marginal mandibulectomy in the presence of superficial bone invasion and the nononcologic outcome. Head Neck 2011;33:708–713.

Deleyiannis FWB, Dunklebarger J, Lee E, et al. Reconstruction of the marginal mandibulectomy defect: an update. Am J Otolaryngol 2007;28:363–366.

Ertem SY, Uckan S, Ozden UA. The comparison of angular and curvilinear marginal mandibulectomy on force distribution with three dimensional finite element analysis. J Craniomaxillofac Surg 2013;41:e54–e58.

McGuirt Jr WF, Johnson JT, Myers EN, et al. Floor of mouth carcinoma: the management of the clinically negative neck. Arch Otolaryngol Head Neck Surg 1995;121:278–282.

Melugin MB, Oyen OJ, Indresano AT. The effect of rim mandibulectomy configuration and residual segment size on postoperative fracture risk: an in vitro study. J Oral Maxillofac Surg 2001;59:409–413.

Muñoz Guerra MF, Naval Gías L, Rodríguez Campo F, Sastre Pérez J. Marginal and segmental mandibulectomy in patients with oral cancer: a statistical analysis of 106 cases. J Oral Maxillofac Surg 2003;61:1289–1296.

Muscatello L, Lenzi R, Pellini R, et al. Marginal mandibulectomy in oral cancer surgery: a 13-year experience. Eur Arch Otorhinolaryngol 2010;267:759–764.

O'Brien CJ, Adams JR, McNeil EB, et al. Influence of bone invasion and extent of mandibular resection on local control of cancers of the oral cavity and oropharynx. Int J Oral Maxillofac Surg 2003;32:492–497.

Pathak KA, Shah BC. Marginal mandibulectomy: 11 years of institutional experience. J Oral Maxillofac Surg 2009;67:962–967.

Rogers SN, Devine J, Lowe D, et al. Longitudinal health-related quality of life after mandibular resection for oral cancer, a comparison between rim and segment. Head Neck 2004;26:54–62.

Song CS, Har-El G. Marginal mandibulectomy: oncologic and nononcologic outcome. Am J Otolaryngol 2003;24:61–63.

Totsuka Y, Usui Y, Tei K, et al. Mandibular involvement by squamous cell carcinoma of the lower alveolus: analysis and comparative study of histologic and radiologic features. Head Neck 1991;13:40–50.

Wolff D, Hassfeld S, Hofele C. Influence of marginal and segmental mandibular resection on the survival rate in patients with squamous cell carcinoma of the inferior parts of the oral cavity. J Craniomaxillofac Surg 2004;32:318–323.

182 Segmental Mandibulectomy

Steven Parnes, Kristina Piastro

INTRODUCTION

Segmental mandibulectomy involves the removal of a full-thickness segment of the mandible, often secondary to a malignant or benign tumor, trauma, or osteoradionecrosis. Segmental mandibulectomy may be performed in the setting of a *composite resection*, a term coined by Ward and Robben in 1951. It was thought that cancer of the oral cavity had a propensity to spread via periosteal lymphatics to the mandible; thus resection of a segment of mandible in continuity with a cancer of the oral cavity, oropharynx, or a primary cancer of the alveolar ridge was recommended regardless of whether the bone was actually invaded. Marchetta and colleagues disproved the theory of lymphatic invasion; thus mandibulectomy (Table 182.1) is reserved for those with advanced cancer of the oral cavity or oropharynx where invasion of the mandible is clinically evident or cannot be ruled out. Fundamental concepts of extirpation have not changed in the interval. However, methods of reconstruction continue to evolve with the development of microsurgical techniques and reliable free flaps.

KEY OPERATIVE LEARNING POINTS

- Most patients must undergo a tracheostomy, because postoperative oral disability could otherwise result in aspiration, and edema may lead to airway obstruction.
- Mandibulectomy results in significant cosmetic and functional compromise and should be undertaken only if the operating surgeon feels that negative margins can be obtained.
- The periosteum and mandible serve as barriers to invasion; however, patients who have undergone radiation, have had surgery that resulted in periosteal stripping/resection, or have poor peridontal health are at greater risk.
  - Cancers generally arise at the occlusal surfaces, but they can also invade at the muscular attachments or through invasion of the mental/inferior alveolar nerve.
- Defects after segmental resection of the mandible can be divided into anterior and lateral defects in reference to the mental foramen.
  - An anterior defect results in loss of function of the oral cavity, including mastication, oral competence, drooling, swallowing ability, and airway compromise.
  - A lateral defect results in less morbidity; however, they include imbalance of mastication forces and altered contour of the posterior lower third of the face. The mandible will deviate toward the resected side due to the pull of the suprahyoid muscles on the residual fragment, causing inferior displacement and rotation around the remaining condyle.
- Free flap reconstruction offers a high degree of reliability and good aesthetic outcomes.
- Decisions regarding reconstruction should be based on the patient's age, dentition, and expectations as well as on the anticipated soft tissue defect.
  - Plans for reconstruction of the mandible must be finalized before the mandibulectomy procedure. Various techniques are listed in Table 182.2.
  - A simulated virtual surgical plan may be helpful.

PREOPERATIVE PERIOD

History

- Comorbidities and lifestyle habits that would affect the healing process
- Postoperative swallow, speech, and dental rehabilitation
- Approximately 25% of all head and neck cancers and 60% of all oropharyngeal cancers are positive for human papillomavirus (HPV), a finding that may alter postoperative treatment.[1]
- We have found varying association of mandibular invasion with inferior alveolar nerve paresthesia, loose teeth, gender, age, habits (alcohol, tobacco chewing), clinical type of lesion, skin fixation by the tumor, dental status, and patients with recurrent cancers who have received prior radiotherapy.

Physical Examination

- Routine preoperative examination of the head and neck with attention to the relationship of the primary cancer to the mandible using bimanual palpation to evaluate for adherence of the cancer to the periosteum or bone invasion.
- Preoperative determination of the presence or extent of invasion of the mandible is challenging.
- Testing for numbness of the lower lip to ascertain whether the cancer has involved the mental nerve

TABLE 182.1 Definitions of Mandibulectomy

Mandibulotomy	Osteotomy of the mandible to permit exposure, no bone resected; bone is reapproximated at the completion of the procedure
Marginal mandibulectomy	A portion of the mandible, typically the alveolus or lingual plate, is resected while leaving the continuity of the mandible intact.
Segmental mandibulectomy	A portion of the mandible is resected, with disruption of condyle-to-condyle continuity. IE resection of the Ramus Angle Body Parasymphysis

TABLE 182.2 Methods of Restoring Mandibular Continuity

Soft tissue only
Regional pedicle flap
Skin graft
Reconstruction plate
Plate and screw with a regional pedicle flap
Plate and bone-anchored post with a titanium hollow screw reconstruction plate (THORP)
Microvascular free flaps with bone (preferred option)
Radius
Fibula
Scapula
Iliac crest

Imaging

- Clinical examination has been found to be a sensitive way to identify bone invasion; however, the best results can be obtained by combining it with a radiologic study.
- No imaging technique is 100% accurate in identifying invasion of the mandible.
- More than 60% to 70% of bone mineral must be lost before radiographic changes become evident.
- Computed tomography (CT) scans, magnetic resonance imaging (MRI), and bone scintigraphy have been reported to have sensitivity and specificity ranging from 85% to 95%.[1]
  - CT findings of osseous involvement include cortical erosion adjacent to the primary lesion (Fig.182.1A), aggressive periosteal reaction, abnormal attenuation in bone marrow, and pathologic fractures. Image quality around the alveolar crest may be hampered by severe dental artifacts and image noise.
  - MRI may be more sensitive for marrow and the inferior alveolar canal; however, it also results in more false positives and frequently overestimates the extent of tumor invasion. This is due to the high intensity of the edematous or inflammatory changes at the soft tissues adjacent to the tumor.
  - Positron-emission tomography (PET) with fluorine 18 fluorodeoxyglucose (FDG) is also expected to be useful for assessing bone invasion because FDG accumulates well at the malignant tumor.
- For patients undergoing free flap reconstruction, conventional angiography or MR angiography is recommended for patients over 50 years of age and those with comorbidities such as diabetes mellitus (DM), hypertension, trauma, arteriopathy, or equivocal pulses.
- Three-dimensional (3-D) imaging for reconstruction plans and 3-D modeling have greatly improved preoperative surgical planning (see Fig. 182.1).

Indications

- Malignant tumor invasion of the medullary space of the mandible by either a primary tumor of the alveolar ridge or from an adjacent site such as the floor of the mouth
- A hypoplastic, edentulous, or previously radiated mandible that precludes safe performance of a marginal mandibulectomy
- Benign tumor of the jaw, such that extirpation would result in instability and possible pathologic fracture
- Advanced osteonecrosis related to radiation or bisphosphonate use or osteomyelitis
- Severe mandibular trauma with unstable or devitalized bone

Contraindications

- Comorbidities for general anesthesia; cardiac, hemodynamic, nonreversible coagulopathic disorder
- Extensive tumor that precludes complete resection
- Distant metastases (a palliative mandibulectomy may be indicated in highly selected patients)

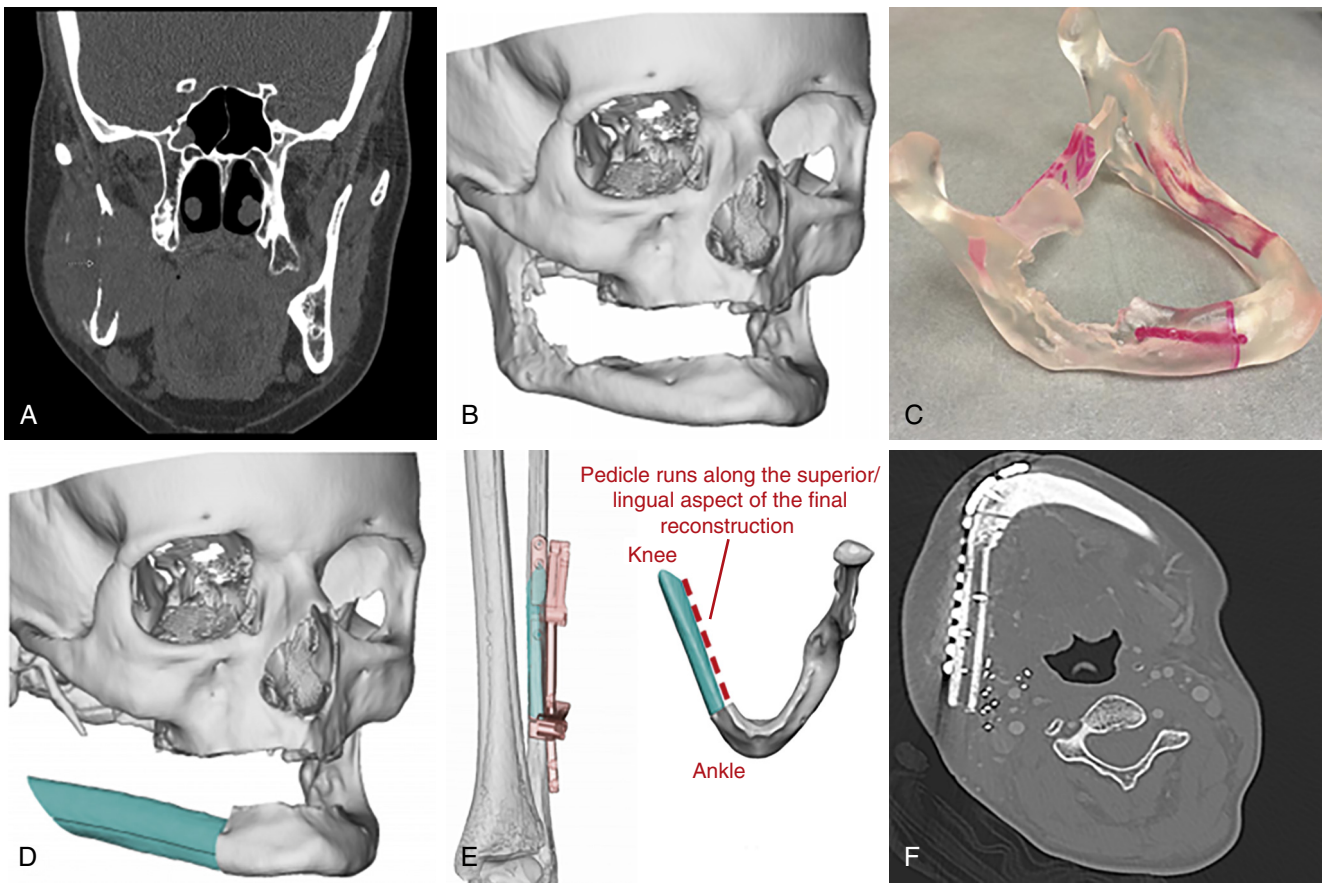

Fig. 182.1. A, A computed tomography (CT) scan of a patient demonstrating carcinoma that eroded the ramus of the mandible. **B,**Three-dimensional reconstruction for virtual surgical planning. **C,** Three-dimensional model of mandible preoperatively. **D,** Virtual plan with fibular reconstruction. **E,** Fibular resection planning. **F,** CT scan of postoperative view after osseocutaneous fibular free flap reconstruction.

Preoperative Preparation

- Discussion of patient expectations and possible outcomes, including expected sequelae and unexpected complications
  - Functional and cosmetic outcomes, especially in those patients who have had prior radiation therapy
  - Planned incision sites, tracheostomy for airway management, possible gastrostomy tube for alimentation
- Multispecialty approach, as patient will likely require postoperative therapy
  - Dental, radiation, and medical oncology, speech/swallow
- Coordination with teams involved
  - Reconstructive team: appropriate preparation, setup, instrument availability, reconstructive plan, and possible grafts or pedicle flaps
  - Dental/Oromaxillofacial Surgery: extractions, primary osseointegrated fixation devices
  - General surgery: gastrostomy tube placement for postoperative alimentation

OPERATIVE PERIOD

Anesthesia

- General, with oral endotracheal intubation and conversion to tracheostomy
  - Nasal intubation for lesions confined to the mandible that are not felt to warrant tracheostomy
- May initiate paralysis after identification of marginal branch of CN VII and XI

Positioning

- Head is positioned 180 degrees away from the anesthesia circuit.
  - Allows for multiteam approach if there is a free flap plan
  - Reverse Trendelenburg position (approximately 20 degrees)

Perioperative Antibiotic Prophylaxis

- A postoperative infection rate of 24% to 87% has been reported in clean-contaminated cases without the use of prophylactic antibiotics.[2]
- Higher risk with DM, advanced stage of disease/extent of surgery, tracheostomy, flap reconstruction, previous external radiation therapy (XRT).
- A variety of single and combination antibiotics have been evaluated and recommended for prophylaxis for major head and neck surgery.
  - Prophylactic perioperative antibiotics should be started prior to skin incision for maximal benefit.
    - Academy of health-systems pharmacists (ASHP) guidelines recommend administration of prophylactic antibiotics within 60 minutes of start of procedure and redosing after two half-lives of the drug.
    - Coverage should include skin flora as well as aerobic and anaerobic bacteria.
    - A variety of single and combination antibiotics have been evaluated and recommended for prophylaxis for major head and neck surgery involving the upper aerodigestive tract. Examples include
      - Clindamycin: 600 mg IV with 4 additional doses q6h
      - Ampicillin/sulbactam: 1.5 g (1 g ampicillin and 0.5 g sulbactam) or 3 g (2 g ampicillin and 1 g sulbactam) IV/IM every 6 hours
      - Cefazolin: 2.0 g IV with 3 postoperative doses q8h
  - Continuation of perioperative antibiotics beyond 24 to 48 hours postoperatively has not demonstrated decreased rates of infection.

Monitoring

- Standard general anesthetic monitoring
- Arterial line for free flap cases, hemodynamic and blood loss monitoring
- Communication with anesthesia team regarding fluid management and use of vasopressors, which may negatively affect free flap survival
- Acoustic Doppler ultrasonography postoperatively for free flap monitoring
  - A suture placed to mark the site of the pedicle to ensure that both the medical and nursing teams can properly assess free flap viability

Instruments and Equipment to Have Available

- Soft tissue and head and neck set
- Orthognathic/oral surgery/dental extraction set
- Nerve monitor if indicated, bipolar electrocautery, saw set with both wedge-shaped reciprocating and oscillating saw or Gigli manual saw if powered unavailable, drill to smooth bony free edges
- Reconstructive team: microscope, microvascular set, mandibular reconstruction plating set

Key Anatomic Landmarks

- The mandible contributes to the peripheral boundaries of the floor of mouth: the lower third of the facial form, speech, swallowing, mastication, and respiration.[4]
  - Disruption of the mandible can significantly affect any of these functions.
- Mandibulectomy is divided into lateral and anterior defects by the mental foramen.
  - When intraoral incisions are being extended to improve exposure, ensure dissection and preservation of the contralateral mental nerve.
- The farther anterior the defect, the more disfiguring and functionally debilitating the outcome. This is related to loss of key muscular attachments located anteriorly (genioglossus, geniohyoid) and loss of tongue mobility and control.
- Defects of the symphyseal region are most debilitating, and surgical reconstruction is mandatory for segmental stabilization.
- Lateral defects are more forgiving if muscular attachments are preserved; in these cases the result is often near normal appearance and function.
- Choice of incisions varies with the site of the cancer and planned reconstruction.
  - If tumor invades the mandible, an ipsilateral neck dissection is usually warranted and may be incorporated with a lip-splitting, half-H incision that is at least 2 cm below the angle of the mandible to avoid injury to the mental nerve (Fig. 182.2).
    - More than 30% of patients with squamous cell carcinoma of the oral cavity have lymph node metastases, and histologic confirmation of metastatic disease is the most important prognostic factor.
    - The neck dissection specimen may be kept in continuity with the tumor or dissected separately.
    - Cancers involving the base of the tongue, approaching midline, or major lymph adenopathy of the ipsilateral side should be treated with a bilateral neck dissection.
    - When a lip-splitting incision is used, it is important to ensure close realignment of the vermillion border prior to making the incision.
  - Degloving with a visor flap compromises the contralateral mental nerve.

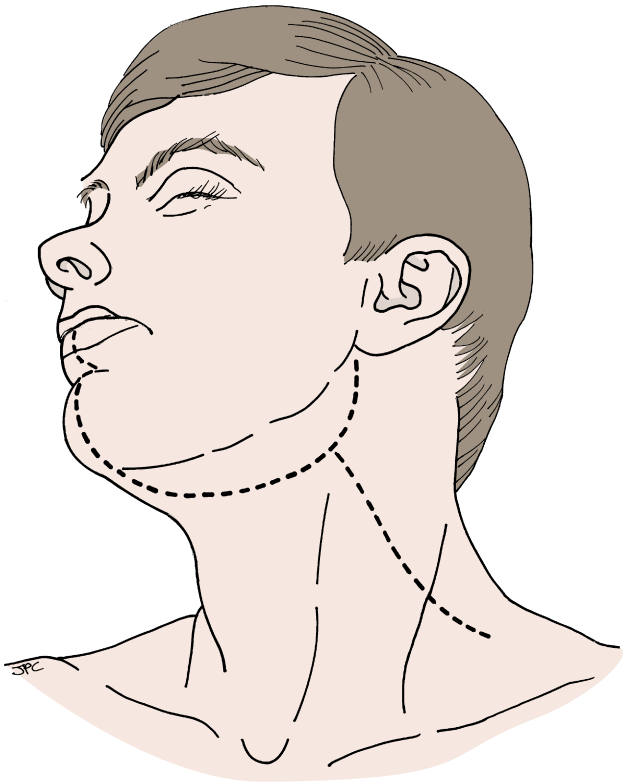

Fig. 182.2. Among the incisions used for composite resection is the lip-splitting modified half H. This incision provides excellent visibility of lesions in the posterior oral cavity. It can be used for bilateral neck dissection by the formation of a submental trifurcation.

Prerequisite Skills

- Soft tissue handling
- Neurovascular dissection, microvascular surgery team expertise
- Familiarity with surgical and Gigli saws
- Dental extraction technique and instruments

Operative Risks

- Risks associated with anesthesia
- Injury to lingual and hypoglossal nerves, resulting in dysphagia and dysarthria
- Significant blood loss from various branches of the external carotid and internal maxillary arteries
- Segmental mandibulectomy results in transection of the inferior alveolar nerve and will cause permanent anesthesia of the affected lower lip postoperatively.
  - There has been variable success with a segmental nerve graft using donor nerve (sural nerve or lateral femoral cutaneous nerve); preservation of the contralateral mental nerve is recommended.

Surgical Technique

- The technique of mandibulectomy has not changed significantly over the past several decades except that a nondiseased mandible is no longer removed, and a mandibulotomy is the preferred approach in these cases, as discussed in Chapter 181, "Marginal Mandibulectomy." What has changed are the methods of reconstruction, which range from primary closure; healing with secondary intention; reconstruction with split-thickness skin grafts, local, or regional flaps to microvascular reconstruction with free tissue transfer. These methods are beyond the scope of this chapter. Here we describe the method of segmental mandibulectomy and associated procedures as performed at our institution.
- Tracheostomy is generally indicated for maximal intraoperative exposure and postoperative airway management; however, for lesions requiring minimal soft tissue resection and reconstructive plans, a nasal intubation may be sufficient.
- Tumor is reexamined under general anesthesia and the resection and reconstructive plans are confirmed; margins are marked usually between 1 and 2 cm from the edge of the cancer.
- We prefer a lip-splitting incision, which is carried out inferiorly to about the level of the hyoid and posteriorly to the mastoid tip, providing excellent exposure of the mandible and neck while preserving the contralateral mental nerve (see Fig.182.2).
  - If the incision for neck dissection is incorporated, care must be taken to avoid communication with the tracheostomy incision and injury of the marginal nerve, with placement of the incision at least 2 fingerbreadths below the border of the mandible.
  - A visor flap may also be used with initial intraoral gingivobuccal incisions (Fig. 182.3C and D) and may be more cosmetically appealing; however, this tends to compromise the contralateral mental nerve and does not allow for visualization of tumors at the posterior to middle third of the tongue and retromolar trigone.
- The intraoral incisions along the antero-lateral gingivolabial and buccal sulcus allow mobilization of the lip (Fig. 182.4) as it is dissected the mental nerve is sacrificed, this does not add to morbidity as the inferior alveolar canal needs to be transected with the specimen (Fig. 182.5)
- Dissection is carried over the periosteum of the buccal plate of the mandible anterior to the masseter muscle. The marginal branch is identified and elevated with the skin flap. Should there be evidence of tumor invading lateral to the mandible, the facial artery and mandibular branch may have to be sacrificed (Fig. 182.6).
- When adequate exposure of planned mandibular and tumor resection has been identified, the reconstructive team may wish to preplate the mandible prior to resection. The reconstructive plate is prebent, and screw holes are placed at either end on the residual bone. The plate is then removed and sterilized prior to implantation.
- The position of the osteotomy is then marked; it should encompass a margin of at least 2 cm and extend anteriorly to include the mental foramen. Should there be teeth at the planned osteotomy sites, dental extractions are performed at this point.
- A reciprocating saw is used to perform the anterior osteotomy, with care taken not to injure the neurovascular structures at the floor of mouth; appropriate soft tissue retraction prevents excessive injury. Since postoperative extraction may prove difficult, additional extractions should be carried out if the patient has poor remaining dentition or not enough remnant mandible to support surrounding teeth.
- Posteriorly an oscillating saw may be used to section the ramus. Should the extent of disease require an osteotomy above the notch of the mandible, the coronoid will be removed with the specimen. This will require section of the tendon of the temporalis muscle (Fig. 182.7). The placement of this osteotomy will decrease bleeding risk from the inferior alveolar artery.
- Once both osteotomies have been performed, additional mucosal incisions can be carried out in the oral cavity and

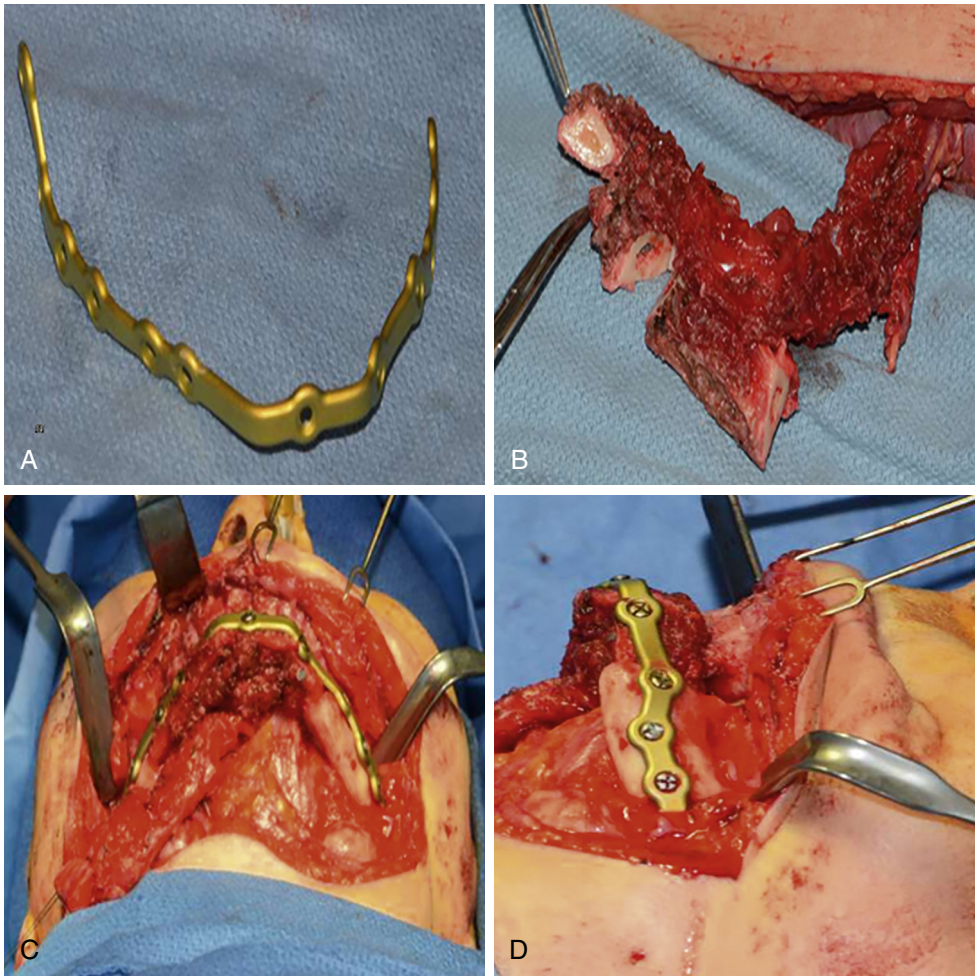

Fig. 182.3. A, Precontured mandibular reconstruction plate. **B,** Harvesting of the free fibular osseocutaneous graft. **C,** Visor incision with inset of the free fibular graft (FFG). **D,** Sagittal view of inset FFG with adequate projection.

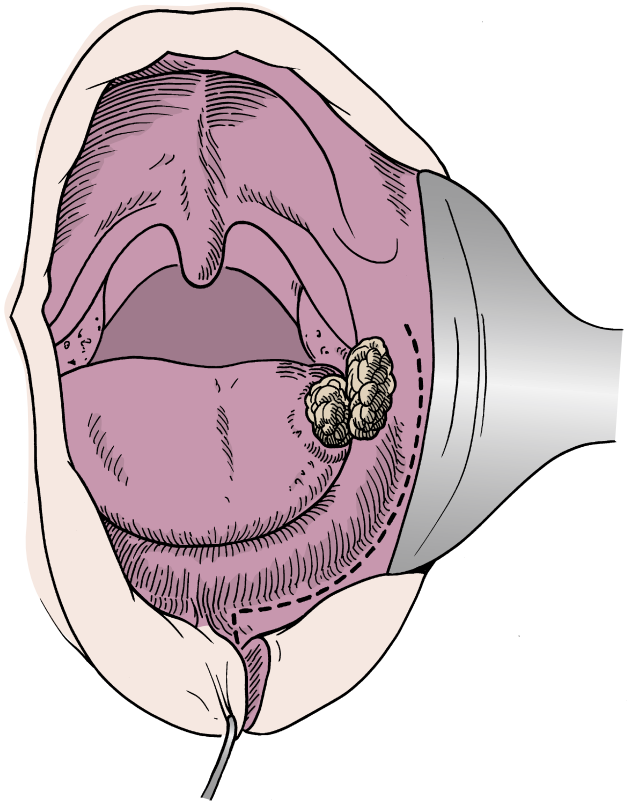

Fig. 182.4. A lip-splitting incision with extension along the buccogingival sulcus to permit retraction of the cheek flap. Care must be taken to avoid compromising the tumor margin of the resection laterally.

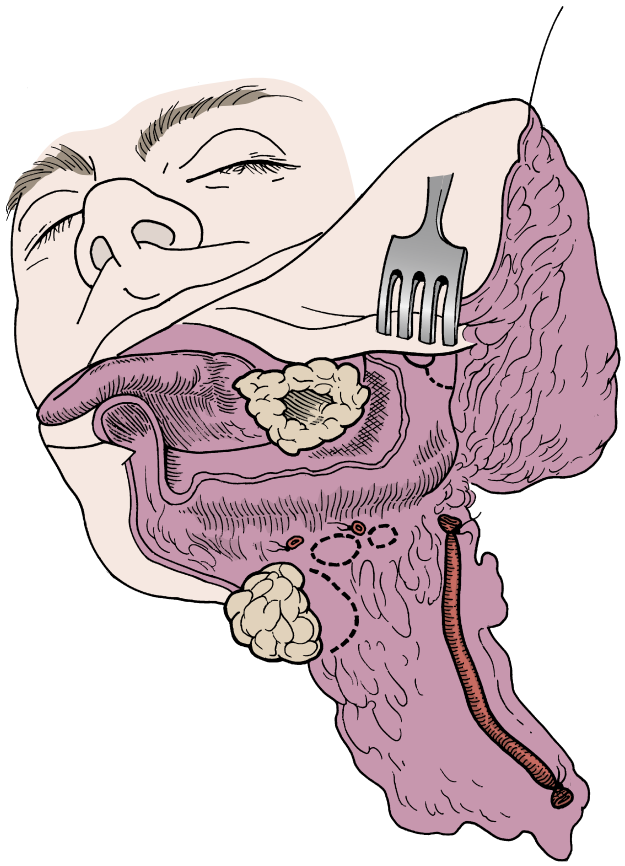

Fig. 182.5. Reflection of the cheek flap provides excellent visualization of the cancer.

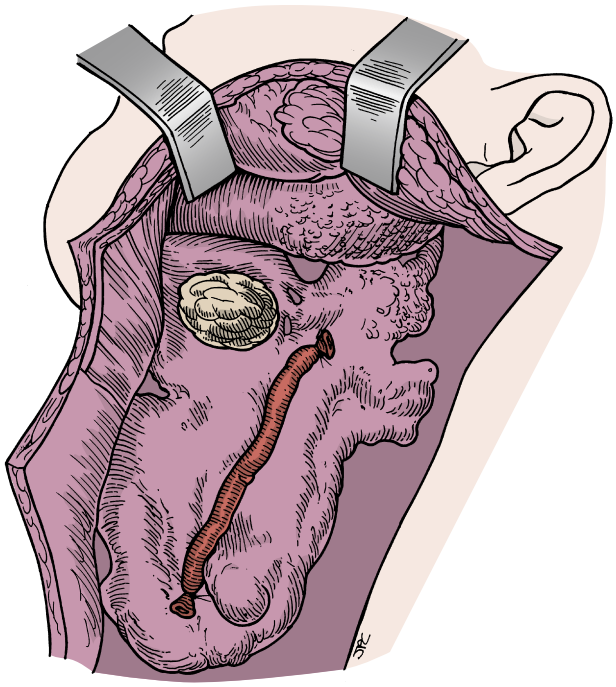

Fig. 182.6. Dissection of the mandibular periosteum and masseter muscle lateral to the mandible. Care must be taken to avoid exposing the cancer by excessive dissection superiorly.

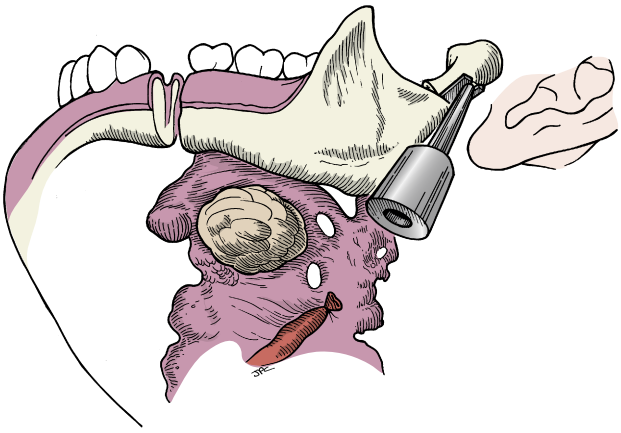

Fig. 182.7. An oscillating saw is used for osteotomy of the neck of the mandibular condyle. The osteotomy could also be made through the midramus. If oncologically feasible and reconstruction is planned, a vertical osteotomy will provide more bone, thereby improving fixation of the graft.

may be aided by suture traction on the tongue or soft palate (Fig. 182.8).

- Once the tumor is fully excised, hemostasis is achieved with cautery and/or a ligature, and the edges of the bone resection may be smoothed with a drill.
- The composite resection is sent for review of frozen sections to include the neurovascular pedicle of the mental/inferior alveolar nerve. Often we will obtain an intraoperative consult with the pathologist to discuss the case and the specimen, making sure that it is accurately labeled and assessed. Bone margins cannot be assessed as they require decalcification; therefore biopsy of the proximal and distal neurovascular structures may serve as the surrogate.
- We often choose to perform the neck dissection with a separate specimen if there is no frank lateral extension of the

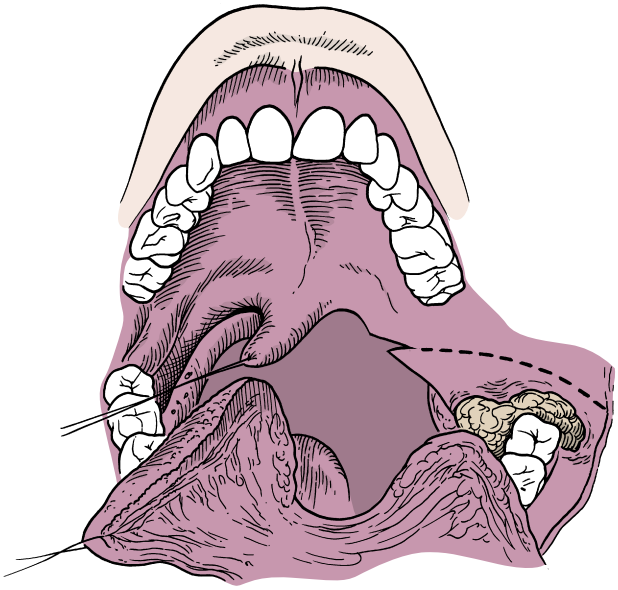

Fig. 182.8. Retraction of the soft palate with a suture placed in the uvula will help to make precise incisions through the mucosa of the soft palate. It is also advisable to place a suture through the specimen to facilitate orientation by the pathologist.

tumor to the basin of the pre-and postfacial nodes. The surgical steps are discussed in Chapter 181, "Neck Dissection."
  - A supraomohyoid (levels Ia, Ib, II, and III) is performed; elective removal of level IV is still under debate.
  - Bilateral neck dissection is carried out with advanced tumors of the oral tongue, floor of mouth, lip, and mandible that violate the midline of these regions.
- Reconstruction options for oral and mandibular defects are varied (see Table 182.2) and include primary closure, skin grafts, local and regional flaps, and free tissue transfer with microvascular anastomosis. The most frequently used flap at our institution is the fibula osteocutaneous free flap, which has demonstrated excellent survival and viability (see Fig. 182.3B).
- Goals of reconstruction:
  - Reestablish the contour of the lower third of the face.
  - Restore tongue volume and floor of mouth to preserve mobility and allow for optimal speech and swallow functions.
  - Restore mandibular continuity while maintaining appropriate occlusal surfaces, and provide a structure for future dental implantation.
- The reconstructive methods are beyond the scope of this chapter; they are discussed elsewhere in this text (see Chapters 161 to 169).

Common Errors in Technique

- Obtaining surgical access for mandibulectomy is one of the surgeon's greatest challenges; direct visualization of the osteotomy and protected tissues is vital.
- Misalignment of the reciprocating saw may cause damage to surrounding structures.
- The inferior alveolar and lingual nerves are put at risk because the cheek interferes with the saw and causes it to point posteriorly; this can be avoided by performing the posterior cut through an open approach.
- The submandibular duct is often put at risk; if the gland won't be excised, the duct should undergo a sialodochoplasty and be sutured to the floor of the mouth.

- Transection of the lingual, buccal, and facial vessels can result in significant bleeding; awareness of anatomy and preparation to encounter and control bleeds mitigates this concern.
  - If the neck dissection is performed in conjunction with a composite resection, the vessels should already be identified more proximally, with access to control should bleeding be encountered.

POSTOPERATIVE PERIOD

Postoperative Management

- Monitoring in the intensive care unit (ICU) for 24 to 48 hours
  - Flap assessment with acoustic Doppler ultrasonography, capillary refill, color, and turgor
  - Fluid balance and shifts
  - Tracheal suctioning, drain management
- If a bolster was placed, with antibiotic coverage while in place, it is removed approximately 1 week after surgery.
  - Oral care, oral rinses
  - Consideration of removal of the tracheostomy occurs after bolster removal.
- Nutrition/Gastrointestinal access: Usually via nasogastric tube, generally at least until bolster removal and decannulation
  - Gastroesophageal reflux precautions with a proton pump inhibitor

Complications

- Infection and fistula formation, the need to remove fixation hardware, and possible flap failure, osteomyelitis, temporomandibular joint (TMJ) pain, chronic pain
- Dental malocclusion in the dentate patient undergoing segmental resection
- Nonunion of the bony reconstruction
- Positive margins, necessitating a return to the operating room for additional resection
- Dysphagia, dysarthria
- Aspiration

Alternative Management Plan

- Definitive radiation therapy, concurrent chemoradiation, and induction therapy are alternative options for patients who are not candidates for surgery.
- Chemotherapy is given concurrently with radiation therapy; definitive radiation doses used are 66 to 74 Gy (2.0 Gy/fraction; daily Monday to Friday over 7 weeks).
- Chemotherapy may be given as an induction in order to decrease tumor size and make it amenable to either resection or radiation therapy.
- For recurrent or distant metastatic cancers, a platinum-based chemotherapy regimen is preferred.

DISCUSSION

Evidence-Based Medicine Question

Are radiation and chemotherapy indicated in the treatment of advanced cancer of the oral cavity that has invaded the mandible?

Cancer of the oral cavity that has invaded the mandible requires resection with segmental mandibulectomy with sufficient oncologic margins. Patients with bone involvement are staged T4, and many of these patients will be found to have cervical adenopathy on pathologic review of neck dissection specimens. Recent reports suggest that adjuvant chemotherapy and radiation are beneficial in this group.[4]

The updated meta-analysis by Bourhis et al. (2009) looked at chemotherapy in head and neck cancer (MACH-NC)using individual patient data from 93 randomized trials (level 1A evidence) and showed that concomitant chemoradiotherapy is the standard of care in locally advanced head and neck squamous cancer. At 5 years, these investigators found that, relative to radiotherapy alone, the addition of concomitant chemotherapy to radiotherapy was associated with an increase in survival of 6.5%—representing a 12% to 13% improvement in locoregional control and about a 3% decrease in distant metastases.

Editorial Comment

Segmental mandibulectomy has been a reliable procedure for the resection of advanced oral cancers for over a century. Despite its multiple sequelae, the extirpative technique has undergone only trivial changes. Reconstruction of the mandible, however, has leapt forward with the use of microvascular tissue transfer. This has proven to be a reliable reconstructive technique for both the soft tissue and bone, thus helping to restore cosmesis and function.

Steven Parnes

Access the review questions and additional sources list online at http://www.expertconsult.com

REFERENCES

1. Wiener E, Pautke C, Link TM, et al. Comparison of 16-slice MSCT and MRI in the assessment of squamous cell carcinoma of the oral cavity. Eur J Radio 2006;l58(1):113–118.
2. Brook I. Microbiology and principles of antimicrobial therapy for head and neck 236 infections. Infect Dis Clin North Am 2007;21:355–391.
3. Lewis A, Kang R, Levine A, et al. The new face of head and neck cancer: the HPV epidemic. Oncology 2015;29(9):616.
4. Ferris RL, Myers EN, Wax MK. Master Techniques in Otolaryngology: Head and Neck Surgery, vol 1(16). Philadelphia: Wolters Kluwer; 2013. p. 135–143.

REVIEW QUESTIONS

1. What is an indication for segmental mandibulectomy?
   a. Oral cavity tumor adjacent to mandible with evidence of invasion into superficial lingual cortex
   b. Access to resection of a malignant tumor of the oropharynx
   c. Malignant tumor invading the medullary space or neurovascular structures of the mandible, either a primary alveolar ridge tumor or from an adjacent site such as the floor of mouth
   d. All of the above

2. What is the difference between lateral and anterior segmental mandibulectomy?
   a. All lateral mandibulectomy defects require osteocutaneous reconstruction.
   b. Anterior defects result in significant functional and airway compromise and therefore require reconstruction and stabilization.
   c. The aesthetic and functional outcomes in lateral and anterior defects are similar.
   d. The more posterior a mandibular defect, the greater the functional and aesthetic deficits.

3. Which imaging modality has 100% accuracy in the detection of mandibular invasion?
   a. CT
   b. MRI
   c. PET-CT
   d. None of the above

ADDITIONAL SOURCES

Bernier J, Cooper JS, Pajak TF, et al. Defining risk levels in locally advanced head and neck cancers: a comparative analysis of concurrent postoperative radiation plus chemotherapy trials of the EORTC (# 22931) and RTOG (# 9501). Head Neck 2005;27(10):843–850.

Cooper JS, Pajak TF, Forastiere AA, et al. Postoperative concurrent radiotherapy and chemotherapy for high-risk squamous-cell carcinoma of the head and neck. N Engl J Med 2004;350(19):1937–1944.

Genden EM, Ferlito A, Silver CE, et al. Contemporary management of cancer of the oral cavity. Eur Arch Otorhinolaryngol 2010;267(7):1001–1017.

Genden EM, Rinaldo A, Jacobson A, et al. Management of mandibular invasion: when is a marginal mandibulectomy appropriate? Oral Oncol 2005;41(8):776–782.

Pignon JP, le Maitre A, Maillard E. Meta-analysis of chemotherapy in head and neck cancer (MACH-NC): an update on 93 randomised trials and 17,346 patients. Radiother Oncol 2009;92:4–14.

Shah J, Gil Z. Current concepts in management of oral cancer–surgery. Oral Oncol 2009;45(4):394–401.

183 Mandibular Osteotomy Approaches

Carlos D. Pinheiro-Neto, Lisa Galati

INTRODUCTION

The mandibulotomy approach was first described by Roux in 1836.[1] Dubner and Spiro, in 1959, developed the technique with paralingual extension, which is the origin of the modern mandibulotomy. Since then, several modifications to the technique have been described.[2] However, the basic principle of the mandibulotomy still remains, which is to provide exposure and a surgical corridor to the oral cavity and oropharynx. The approach may also be used to access the parapharyngeal space and skull base. The modifications are usually intended to minimize postoperative complications. The two principal types of anterior mandibulotomy are the median and the paramedian.

The median mandibulotomy is performed between the central incisors and may require the extraction of a tooth, owing to the narrow space, with the osteotomy placed in the middle of the tooth socket. This preserves the bone of the adjacent sockets, maintaining the stability of the adjacent teeth. The paramedian mandibulotomy is performed between the lateral incisor and canine and usually does not require tooth extraction.

KEY OPERATIVE LEARNING POINTS

1. The osteotomy is performed anterior to the mental foramen to maximize blood flow to the bone and facilitate postoperative healing.
2. Accurate reapproximation of the lip is the key to superior cosmesis. The lip should be closed in three layers: the mucosa, the orbicularis oris muscle, and the skin.
3. Bone realignment and fixation are enhanced by preplating (placing the plate and drill holes) before proceeding to the mandibulotomy. Use of a stair-step osteotomy facilitates fixation.
4. Postoperative application of a bulky supportive dressing tends to reduce facial edema and support immobilization, which enhances rapid healing and good cosmesis.
5. A tracheostomy is necessary to provide an airway during the early postoperative phase. The cannula can be removed as soon as edema resolves and oropharyngeal function has resumed.

PREOPERATIVE PERIOD

History

1. History of present illness
   a. Questions about the site of the tumor: tongue, tonsil, gingiva, soft palate
   b. Tumor size and growth: how long ago was the lesion noticed?
   c. Assessment of function: dysphagia, trismus, dyspnea, dysphonia, aspiration, and weight loss
   d. Has a mass in the neck been noted? When? The presence of metastasis of the neck is a major prognostic factor and also important for surgical planning. Often a mandibulotomy is performed in association with neck dissection.
2. Past medical history
   a. History of cancer
      Important to ask about cancer affecting other anatomic sites. Carcinomas of the oral cavity and oropharynx share similar risk factors with carcinomas of lung and esophagus.
   b. Dental disease
      Poor dentition increases the risk of wound infection and consequent malunion or nonunion of the mandible. Teeth in poor condition may require extraction prior to or at the time of the osteotomy. Consultation with an oral/maxillofacial surgeon is mandatory. Poor dentition and periodontal disease are important considerations for radiation therapy, as these are major risk factors for osteoradionecrosis (ORN) of the mandible; they should be treated prior to mandibulotomy.
   c. Craniofacial anomalies
   d. Prior radiation therapy to the head and neck area
   e. Diabetes mellitus
      It is well known that diabetes is a risk factor for poor and delayed healing as well as wound infection.
3. Past surgical history
   a. History of craniofacial trauma or orthognathic surgery
      The presence of plates and screws in the mandible can change the osteotomy plan.
   b. Facial lacerations, especially in the inferior lip, vermilion, and chin
      Any preoperative scars should be well documented in order to avoid confusion with cosmetic sequelae resulting from the surgical approach
   c. History of tracheostomy or tracheal surgery
      The surgeon should anticipate difficulties during the tracheostomy owing to scar from previous surgery. Was it an emergent tracheostomy or a planned one? Was it a percutaneous endoscopic or classical tracheostomy?
   d. History of any head and neck surgery
4. Social history
   a. Tobacco and alcohol use
      Both are well-established risk factors for oral cavity and oropharyngeal squamous cell carcinoma.

Physical Examination

1. Careful inspection of the head and neck is important to search for scars that might suggest previous facial trauma or surgery. Scar in the anterior neck may represent a prior tracheostomy. The skin should also be assessed, especially in patients with a history of radiation therapy.
2. Information about the size of the tumor, location, infiltration, and cranial nerve involvement can be assessed with a thorough physical examination, including inspection and palpation.
3. In case of severe trismus, intraoral palpation is compromised and further assessment of the lesion can be done with complementary examinations.
4. Flexible transnasal laryngoscopy is a good option to evaluate extension of the tumor to the hypopharynx and larynx, especially in patients with severe trismus.

5. Palpation of the neck is important for the diagnosis of metastasis to the cervicallymph nodes.
6. Careful inspection of the teeth and gingiva is important. Swelling and hyperemia of the gingiva in the presence of tenderness to palpation are suggestive of periodontal disease. A dental consultation should be ordered accordingly.

Imaging

1. Panoramic radiography: Important in order to study the site of the osteotomy. Information regarding the angulation and distance between the tooth roots can be obtained. If a stair-step osteotomy is planned, the distance between the apices of the teeth and the border of the mandible at the osteotomy site should be measured.
2. Computed tomography (CT): Important in order to detect bone involvement. Invasion of the mandibular cortex is often best studied with CT scans.[3] The presence of bone involvement is a contraindication to the mandibulotomy approach.
3. Magnetic resonance imaging (MRI): Possible spread through the medullary space may be better identified with MRI.

Unfortunately, imaging techniques may miss subtle involvement of bone by tumor. If there is a rim of normal tissue between the tumor and bone, the mandible may be spared. There is no substitute for good clinical judgment.

Indications

1. Tumors located in the posterior aspect of the oral cavity and oropharynx may be best suited for a mandible-sparing procedure if the periosteum of the mandible is not infiltrated by the cancer.
2. The mandibulotomy approach should be considered if the transoral approach fails to provide good enough exposure to ensure clear margins for lesions involving the soft palate, tonsil, base of the tongue, and/or retromolar trigone.
3. With the advent of transoral robotic surgery (TORS), the regions that can be resected transorally with clear margins have increased. Some cancers that previously would have required an osteotomy of the mandible for approach and resection are currently being successfully treated with TORS. (See Chapter 99, Transoral Robotic Surgery.)
4. Larger and more infiltrative cancers still require a mandibulotomy approach to provide enough exposure for complete resection. Additionally, reconstruction is greatly facilitated and healing enhanced if the repair is performed with a comfortable surgical exposure.
5. Intact dentition and severe trismus interfere with the transoral approach.
6. In resecting cancers involving the base of the tongue, tonsillar fossa, soft palate, and/or retromolar trigone, the choice between using the mandibulotomy approach and TORS usually depends on the surgeon's preference and/or experience. Both techniques have been effective in the treatment of oropharyngeal cancer.[4,5]
7. If the cancer is fixed to the periosteum but does not invade the cortex, a marginal mandibulectomy is preferred. (See Chapter 181).
8. A combination of marginal mandibulectomy and anterior mandibulotomy is to be avoided because it is frequently associated with a pathologic fracture postoperatively.
9. Exposure in patients requiring a marginal mandibulectomy may be improved by using a midline lip- and chin-splitting incision and elevation of the facial flap. This technique is appropriate in patients in whom the transoral approach would be inadequate for a marginal mandibulectomy and excision of the cancer.
10. If the mandible is grossly invaded, a segmental mandibulectomy is essential. The area of bone to be removed is determined preoperatively, and osteotomies are created during surgery to facilitate exposure and complete resection of the cancer.

Contraindications

1. If the cancer has invaded the mandible, mandibulotomy is not appropriate. Such patients require a segmental mandibulectomy to achieve clear margins.[6,7]
2. When the periosteum is involved but the cortex is intact, a marginal or rim mandibulectomy should be considered.
3. Segmental mandibulectomy is recommended if the cortex of the mandible or marrow space is involved by cancer. The space obtained after segmental mandibulectomy is used to gain access to the oral cavity and/or oropharynx for complete resection of the cancer. In this case the reconstruction is performed with free flaps; fibular free flaps are commonly used.

Preoperative Preparation

1. After the preoperative evaluation, the surgeon should be able to decide on the best surgical approach to the cancer: transoral, mandibulotomy, or mandibulectomy.
2. In some cases the preoperative plan can change, but that would be an exception. In challenging situations, any possibility of modification of the surgical plan should be anticipated by the team and explained to the patient.
3. Physical examination is critical to detect invasiveness of the cancer; when this is associated with radiologic findings, accuracy is increased.
4. The best clinical examination is performed with the patient under general anesthesia.
5. In the imaging studies, it is sometimes difficult to distinguish a subperiosteal reaction from invasion. These studies are also important to evaluate the cervical lymphatics. MRI enhances the soft tissue interfaces, whereas CT better delineates the interface between bone and soft tissue. Neither imaging technique, however, can detect subtle degrees of bone involvement.
6. Where tumor is in close proximity to the mandible, intraoperative frozen section pathology is important for evaluation of the periosteum.

OPERATIVE PERIOD

Anesthesia

- General anesthesia is established and—if there is no contraindication, such as severe trismus—orotracheal intubation is performed.
- Where orotracheal intubation is impossible, fiberoptic nasal intubation is performed. It is imperative for the surgeon to be in the room, helping the anesthesiologist, during the intubation of patients with oral cavity/oropharynx tumors.
- After the airway has been secured, a tracheostomy should be carried out and the endotracheal tube removed from the oral cavity, thereby improving the exposure.
- Primary awake tracheostomy is indicated in cases of severe compromise of the airway.

Positioning

The patient is placed in the supine position. A shoulder roll is used to extend the neck and improve exposure of the mandible.

Perioperative Antibiotic Prophylaxis

- A variety of single and combination antibiotics have been evaluated and recommended for prophylaxis in major head and neck surgery involving the upper aerodigestive tract. Examples include
  - Clindamycin: 600 mg IV with 4 additional doses q6h
  - Ampicillin/sulbactam: 1.5 g IV with 8 additional doses q6h
  - Cefazolin: 2.0 g IV with 3 postoperative doses q8h

Monitoring

None necessary

Instruments and Equipment to Have Available

- Standard head and neck set
- Extra-thin reciprocating and oscillating saw
- Mandible plate system
- Screws
- High-speed drill

Key Anatomic Landmarks

Profound anatomic knowledge and understanding of the mandibular mechanics and physiology are paramount for surgeons who intend to split a normal, functional anatomic structure to approach deeper areas in the neck. The lower lip is the first structure to be divided before osteotomy of the mandible. The lip is a composite tissue formed by skin, muscle, and mucosa. The vermilion is the most apparent feature of the lip and is a modified mucosa adapted to external exposure. To prevent deformities of the lip, the surgeon should be aware of two important vermilion lines for the inferior lip reconstruction. The anterior vermilion line or mucocutaneous junction is the transition between the vermilion and the skin. The posterior vermilion line (or "wet-dry" line) marks the boundary between the vermilion and the mucosa of the lip, the innermost line of contact between the upper and lower lips when the mouth is closed. The orbicularis oris muscle forms most of the body of the lip. The inferior labial artery, a branch of the facial artery, supplies the inferior lip. This artery crosses the lip horizontally in a plane between the muscle and the mucosa approximately at the level of the anterior vermilion line (Fig. 183.1).[8]

An important anatomic consideration for a mandibular osteotomy is the course of the inferior alveolar nerve, which enters the medial aspect of the ramus through the mandibular foramen and courses through the mandibular canal. The course of the nerve through the ramus is oblique downward and forward until it reaches the body of the mandible, where it runs horizontally and forward until it exits through the mental foramen, located at the external cortex of the mandible. A vertical line through the mental foramen usually crosses between the first and second premolars.[9] The inferior alveolar nerve provides the sensory supply to the lower teeth. After exiting the mental foramen, the nerve is called the mental nerve and gives sensory supply to the inferior lip and chin. The inferior alveolar artery is a branch of the maxillary artery and also runs through the mandibular canal until it exits as the mental artery through the mental foramen (Fig. 183.2).



Fig. 183.1. Cadaver dissection showing **A,** demarcation of the incisions in the lip and chin. **B,** Mandible split showing the normal anatomy of the floor of the mouth.

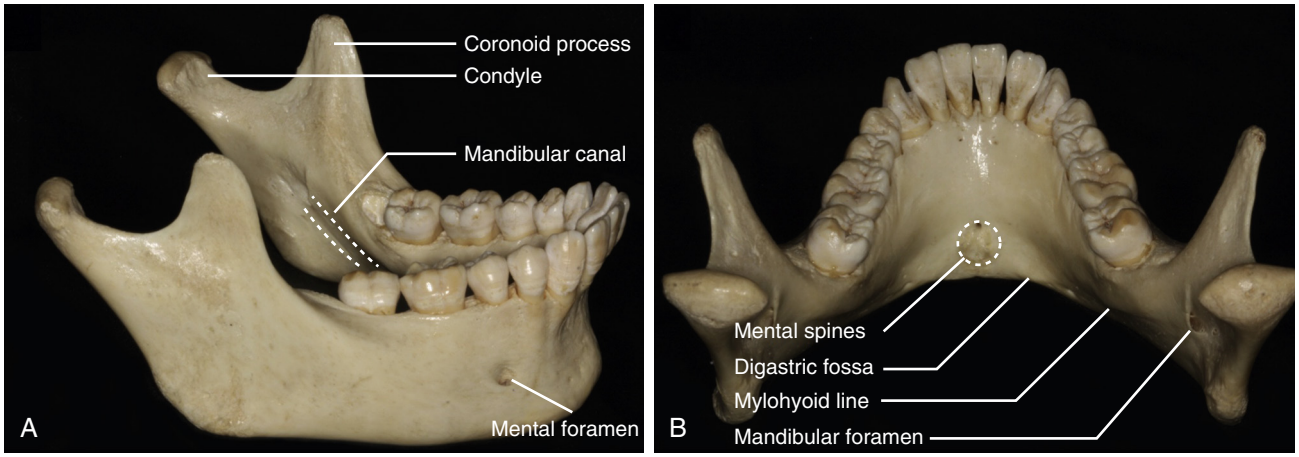

Fig. 183.2. Anatomy of the mandible. **A,** Lateral view. **B,** Posterior view.

Muscles originating in the mandible represent an additional functional consideration. The most superficial anterior belly of the digastric muscle arises from the inner lower border of the symphysis of the mandible. The mylohyoid muscle is the main muscle of the floor of the mouth and originates at the mylohyoid line, which extends from the symphysis of the mandible to the third molar. Deeper to the mylohyoid, the geniohyoid muscle arises from the inferior mental spine, also located at the inner cortex of the mandibular symphysis, and the genioglossus muscle originates at the superior mental spine. All these muscles play important roles in mastication, swallowing, and speech.

If no tooth extraction is planned for the mandibular osteotomy, the space between the teeth should also be considered. The interdental space between the lateral incisor and the canine (paramedian approach) is significantly larger than the distance between the central incisors (median approach).[10]

The ideal site for osteotomy of the mandible should combine maximum exposure of the operative site with maximum preservation of the uninvolved anatomic structures. The exact location of the osteotomy is tailored accordingly to the lesion; however, the anatomic foundations should be respected so as to minimize complications. Lateral mandibulotomy, performed through the body of the mandible, has largely been abandoned owing to the risk of injury to the inferior alveolar nerve. The mandibulotomy performed anterior to the mental foramen is preferable.

Prerequisite Skills

1. Lip reconstruction (See Chapter 25, Lip Surgery.)
2. Open reduction and internal fixation of mandible fractures (See Chapter 121, Facial Fractures.)
3. Oncologic principles for resection of cancers of the oral cavity and oropharynx (See Chapters 29 and 46, Oral Cavity and Oropharyngeal Tumors.)

Operative Risks

1. Injury to the dental roots: Preoperative panoramic radiography to study the angulation and length of the dental roots at the osteotomy site is important to avoid injury to the roots. A straight vertical osteotomy between the teeth is usually preferred.
2. Injury to the mental nerve: If exposure of the nerve is needed, careful dissection of the mental nerve and its release from the periosteal layer of the mandible are important to prevent injury of the nerve during the lateral elevation of the lip-chin flap.
3. Bleeding at the osteotomy site from branches of the inferior alveolar artery can be controlled using bone wax or cautery.
4. Bleeding from the lingual artery can be life threatening in the postoperative period; thus this artery should be dissected out and ligated.

Surgical Technique

Marking Lip and Chin Landmarks

- The cutaneous incision is marked in the midline and oriented vertically.
- The anterior vermilion line (mucocutaneous junction) and the posterior vermilion line (wet-dry line) are marked to facilitate reapproximation of the lip at the completion of the case.
- For the anterior vermilion line, the back of the tip of the surgical blade is used to mark the transition between the vermilion and the skin.
- A needle and methylene blue dye are used to temporarily tattoo the wet-dry line, and the marked line is preserved until the end of the procedure.

Lip and Chin Incisions

- The lip is split through the skin, orbicularis oris muscle, and mucosa.
- Terminal branches of the inferior labial artery are cauterized.
- The incision is extended vertically along the chin and submental area down to the level of the hyoid bone.
- An incision is made in the midline down to the periosteum of the mandible.
- Intraoral incisions are then carried laterally in the gingivobuccal sulcus, and a 5- to 8-mm cuff of vestibular mucosa is left attached to the bone to facilitate closure at the completion of the procedure.
- The periosteum is incised sharply, then carefully elevated for about 2 cm on both sides of the osteotomy site.
- The elevation of this cheek flap should be enough to provide good exposure of the anterior aspect of the mandible where the mandibulotomy will take place.
- The inferior border of the mandible is well exposed.
- The origin of the anterior belly of the digastric muscle is identified in the inferior border of the mandible.
- If possible, exposure of the mental foramen and nerve is avoided to decrease the risk of injury to the nerve and postoperative numbness. If the nerve is exposed, meticulous dissection around it should be performed using sharp instruments (surgical blade) to release the nerve from the periosteum of the mandible.

Osteotomy of the Mandible

- The mandibulotomy is performed anterior to the mental foramen.
- The osteotomies are marked in a stair-step fashion starting between the lateral incisor and canine teeth.
- The fixation plates are bent to exactly match the external surface of the mandible and screw holes are drilled to ensure proper alignment of the bone fragments during the reconstruction phase. Two plates with four holes are used, two holes for each side of the osteotomy. Monocortical screws are used for the superior plate and bicortical screws for the inferior plate close to the border of the mandible. The bicortical screws are measured with a depth gauge.
- A surgical blade is used to incise the gingiva between the lateral incisor and the canine tooth.
- The incision is carried vertically down to the periosteum.
- An extra-thin oscillating saw perpendicular to the bone is used to perform the vertical alveolar osteotomy between the teeth.
- After passing the level of the tooth roots, the osteotomy is turned laterally at a 90-degree angle.
- Measurements—using panoramic radiography and/or sagittal CT scan cuts—can be made preoperatively to check the length of the dental roots at the mandibulotomy site.
- Panoramic radiography is also helpful in assessing the angulation of the dental roots.
- The horizontal osteotomy progresses laterally for about 0.5 to 1 cm and is then curved inferiorly at a 90-degree angle toward the border of the mandible.
- After the osteotomy is completed, the mucosa of the floor of the mouth is incised and the mandible retracted laterally (Fig. 183.3A).
- Exposure of cancer in the posterior oral cavity and oropharynx is improved when the mylohyoid muscle is divided while the submandibular gland and its associated duct are retracted medially with the tongue.

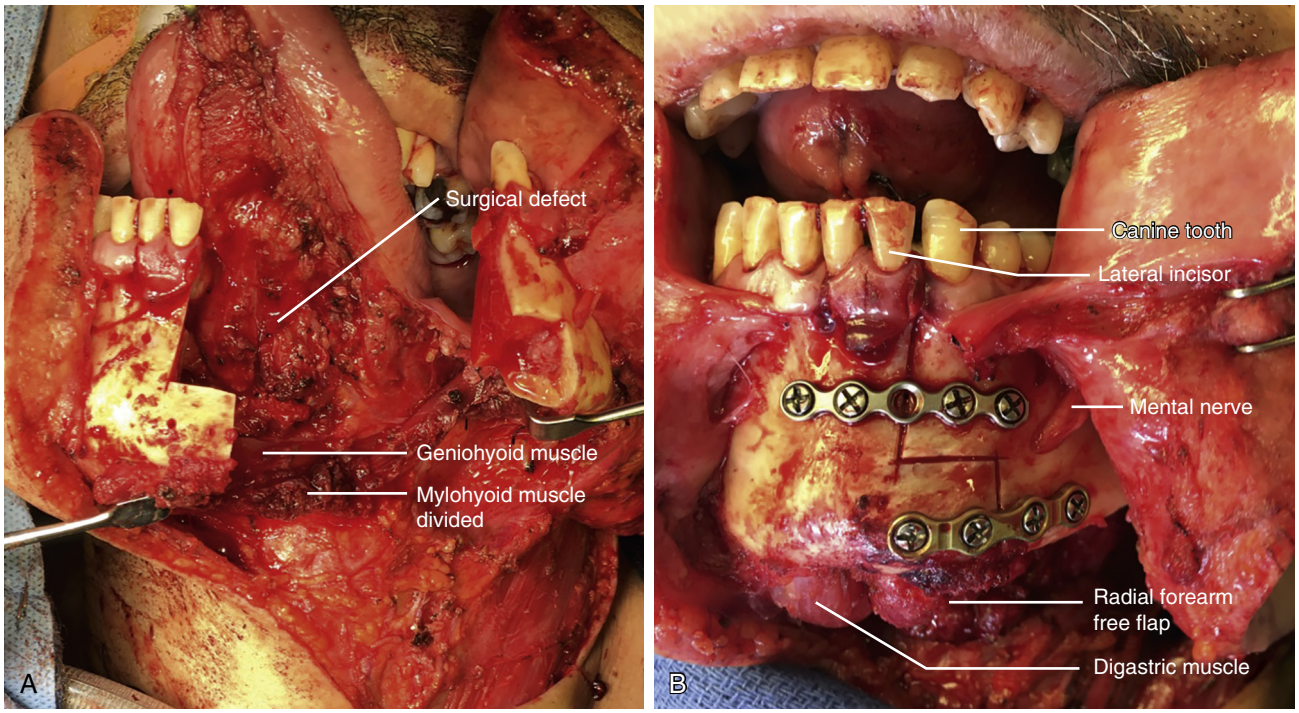

Fig. 183.3. Intraoperative photos from a patient with a T3 squamous cell carcinoma of the left floor of the mouth. A paramedian stair-step mandibulotomy was used to provide exposure, enabling approach and resection of the cancer. A left selective neck dissection, levels 1 to 4, was performed. A radial forearm free flap was used for reconstruction. **A,** Photo after resection of the tumor. The inferior aspect of the incision was extended laterally to provide good exposure for the neck dissection. **B,** After the reconstruction. The fixation plates were bent prior to the mandibulotomy to exactly match the external surface of the mandible; the screw holes were drilled to ensure proper alignment of the bone fragments during the reconstruction phase. The left surgical defect were completely filled with the radial forearm free flap. The mandible segments and teeth are well aligned.

- If exposure of the parapharyngeal space or skull base is intended, the posterior osteotomy can be extended to the anterior tonsillar pillar and soft palate.

Reconstruction (Fig. 183.3B)

- After excision of the cancer, the mandible is once again brought into anatomic position.
- Suturing of mucosa at the floor of the mouth is carried from posterior to anterior using absorbable sutures.
- The mylohyoid muscle is approximated and finally the two segments of the mandible are fixed with plate and screws using the previously drilled holes.
- The soft tissues and skin are approximated, respecting the marked vermilion lines, and the wound is drained as needed.
- In case of a large surgical defect, free flaps are used for reconstruction.

Common Errors in Technique

1. Failure to mark the anterior and posterior vermilion line
   The repair is more challenging and there is a higher risk of cosmetic complications if the vermilion is approximated as marked.
2. The cuff of vestibular mucosa left attached to the bone in the gingivolabial sulcus is inadequate. A cuff of 5 to 8 mm is usually enough to facilitate closure and decrease the risk of wound dehiscence.
3. Inappropriate preosteotomy bending of the titanium plates
   Time should be taken to achieve a perfect match of the plate to the surface of the mandible. A poorly bent plate can cause complications in fixation. Failure to achieve complete stabilization of the mandibulotomy site can result in painful nonunion. In the event of instability, the patient should be returned to the operating room for appropriate fixation. In patients who have been previously treated with radiation therapy, nonunion may result in osteoradionecrosis and sequestration. Bone débridement with bone grafting and fixation may be required to achieve an appropriate union.
4. Use of a thick saw blade for the osteotomy
   A thick saw blade would leave a larger gap between the mandible segments, thus increasing the risk of malunion, nonunion, or delayed union.
5. Failure to complete the osteotomies exclusively with the saw blade
   Undesirable fracture of the mandible may occur. This can cause problems with fixation and ultimately lead to malunion or nonunion of the segments.
6. Besides injury to the inferior alveolar nerve, an osteotomy posterior to the mental foramen may be associated with ischemic necrosis of the mandible, especially in patients who have previously undergone radiation therapy or in those who require postoperative adjuvant radiation therapy.
7. Angled osteotomy cut of the alveolar bone
   This can cause an inadvertent lesion of the dental root and loss of the tooth. Preoperative panoramic radiography to study the angulation of the dental roots at the osteotomy site is important. Usually a straight vertical osteotomy between the dental roots is preferred.
8. Failure to provide adequate soft tissue coverage and watertight closure at the completion of the procedure may result in contamination of the osteotomy by saliva, and contaminated hardware may have to be removed. If drainage

persists beyond 2 months postoperatively, the surgeon may recommend a minor procedure to open the labial sulcus and remove the plate.

9. If marginal resection of the mandible is combined with mandibulotomy, a weak, devascularized segment and subsequent pathologic fracture may result.

POSTOPERATIVE PERIOD

Postoperative Management

1. The patient may return to a liquid or soft diet as soon as healing of the soft tissue has taken place.
2. Intermaxillary fixation is not necessary.
3. The patient should not attempt to chew solid food until approximately the sixth postoperative week.
4. The integrity of the healing mandibulotomy can be ascertained clinically by direct inspection and evaluation of the mandibulotomy site.
5. The decision to use postoperative radiation therapy in patients undergoing resection of malignant tumors is based on established criteria and protocol. Mandibulotomy is to be considered a surgical approach that facilitates resection of the cancer and appropriate reconstruction. When radiation therapy is deemed necessary, it may be undertaken without undue risk. Various investigators have indicated that a mandible-stabilizing plate has minimal effect on the tissue dose of radiation. The plate may minimally reduce the dose in some areas and also cause some "hot spots." Neither of these, however, significantly affects the efficacy or safety of postoperative radiation therapy, and dose adjustments are not required. Patients who have previously undergone radiation therapy may be at increased risk for postoperative osteonecrosis.

Complications

- Recent studies of mandibulotomy have shown a decrease from 30% to 10% in overall postoperative complication rates.
- The complications are related to the soft tissues of the lip, gums, and/or mandible. They can be minor, with no major repercussion in the overall oncologic treatment, but complications can also be severe enough to delay radiation therapy and cause impairment of function.
- Surgeons must recognize any complication promptly and address it in order to prevent any significant delay in treatment.
- Cosmetic deformities and functional issues related to the lip include notching of the lower lip, stenosis of the labial sulcus, fistula, loss of the contour of the chin pad, lip numbness, decreased lip mobility, and so on.
- Dental injuries can culminate in the loss of one or both teeth. Fortunately such injuries are relatively uncommon.
- More severe complications are related to failure of fixation and include malunion, nonunion, malocclusion, and delayed union. With the evolution of the fixation and surgical techniques, complications related to the failure of fixation have decreased to less than 3%.

Alternative Management Plan

1. Transoral robotic surgery, or TORS

   If the cancer can be completely resected with clear margins via a transoral approach, TORS would be preferable to a mandibular osteotomy. Not having to split the lip and mandible avoids the fixation and cosmetic complications that can occur with the latter approach.
2. Advanced cancer

   In cases of inoperable cancer, surgery may be avoided and the treatment based on radiation and chemotherapy.

DISCUSSION

Evidence-Based Medicine Question

What is the best type of osteotomy for the mandible?

In an edentulous patient, the exact site of the osteotomy is not critical. In patients with intact dentition, a tooth can be extracted and the osteotomy performed through the middle of the tooth socket. This preserves the alveolar bone forming the sockets of the adjacent teeth. Currently there is a tendency to avoid dental extraction despite the risk of injury to both teeth during the osteotomy. It is suggested that preservation of the teeth improves the stability of the dental occlusion in the postoperative period.[2] In addition, difficulties with healing of the gingiva over the extracted socket area may result in bone exposure, increasing the risk of complications related to fixation (e.g., malunion or nonunion, osteomyelitis, or osteoradionecrosis). Several studies have shown that dental complications are relatively uncommon following mandibulotomy without tooth extraction. Extra-thin oscillating and reciprocating saws (0.5 mm) are used to minimize the bone gap and decrease the risk of dental injuries. Considering the interdental space, the paramedian osteotomy performed between the lateral incisor and the canine tooth is preferred to the median osteotomy, which is performed in the midline immediately between the central incisors.[10] The stair-step osteotomy has shown considerable advantages, greater resistance to vertical loads, and less bone gap movement compared with the straight vertical mandibulotomy.

Thin osteotomes can be used to finish the osteotomy in the inner cortex of the mandible. Some studies suggest that bone contact and healing will be enhanced if the inner cortex is fractured instead of cut with the saw. The stair-step osteotomy also avoids disrupting the origin of the geniohyoid and genioglossus muscles in the midline. There is concern that trauma to those muscles could increase the postoperative dead space and thus interfere with the swallowing function after surgery.

Editorial Comment

The midline mandibulotomy provides a wide exposure of the oropharynx and infratemporal fossa while allowing control of the great vessels of the neck and pertinent cranial nerves. However, indications for midline mandibulotomy have diminished owing in great part to the advent of TORS and other techniques that can provide exposure of the infratemporal fossa. Nevertheless, the technique of mandibulotomy remains useful and should be part of the armamentarium of every head and neck surgeon.

Eugene N. Myers

Access the review questions and additional sources list online at http://www.expertconsult.com

REFERENCES

1. Butlin HT. Diseases of the Tongue. London: Cassell; 1885. p. 331.
2. Dubner S, Spiro RH. Median mandibulotomy: a critical assessment. Head Neck 1991;13(5):389–393.
3. Bolzoni A, Cappiello J, Piazza C, et al. Diagnostic accuracy of magnetic resonance imaging in the assessment of mandibular involvement in oral-oropharyngeal squamous cell carcinoma: a prospective study. Arch Otolaryngol Head Neck Surg 2004;130:837–843.
4. Schmitt NC, Duvvuri U. Transoral robotic surgery for oropharyngeal squamous cell carcinoma. Curr Opin Otolaryngol Head Neck Surg 2015;23(2):127–131.

5. de Almeida JR, Li R, Magnuson JS, et al. Oncologic outcomes after transoral robotic surgery: a multi-institutional study. JAMA Otolaryngol Head Neck Surg 2015;141:1043–1051.
6. Wax MK, Bascom DA, Myers LL. Marginal mandibulectomy vs segmental mandibulectomy: indications and controversies. Arch Otolaryngol 2002;128:600–603.
7. Brown J. Mechanisms of cancer invasion of the mandible. Curr Opin Otolaryngol Head Neck 2003;11:96–102.
8. Renner GJ. Reconstruction of the lips. In: Shan R. Baker, editor. Local Flaps in Facial Reconstruction. Philadelphia, PA: Elsevier Saunders; 2014. pp. 481–529.
9. Moiseiwitsch JR. Position of the mental foramen in a North American, white population. Oral Surg Oral Med Oral Pathol Oral Radiol Endod 1998;85:457–460.
10. Shinghal T, Bissada E, Chan HB, et al. Medial mandibulotomies: is there sufficient space in the midline to allow a mandibulotomy without compromising the dentition? J Otolaryngol Head Neck Surg 2013 May 2;42:32.

REVIEW QUESTIONS

1. A patient with a T3 carcinoma of the oropharynx presents with severe trismus but no invasion of the periosteum of the mandible. Which is the most suitable surgical approach?
   a. Transoral robotic surgery
   b. Mandibulotomy approach
   c. Marginal mandibulectomy
   d. Segmental mandibulectomy

2. The mandibulotomy approach is performed between the
   a. Central incisors
   b. Central and lateral incisors
   c. Lateral incisor and canine tooth
   d. Canine and first premolar tooth

3. Mark the true sentence about the straight vertical and stair-step mandible osteotomies:
   a. The vertical osteotomy is preferred because it offers better support for the vertical loads.
   b. The stair-step osteotomy is preferred because it offers better support for the vertical loads.
   c. The vertical osteotomy is preferred because it offers better support anteroposterior forces.
   d. The stair-step osteotomy is preferred because it offers better support of anteroposterior forces.

4. Why can the injury to the mandibular canal cause necrosis of the mandible?
   a. Neurogenic atrophy due to injury of the inferior alveolar nerve
   b. Neurogenic atrophy due to injury of the mental nerve
   c. Chronic trauma due to numbness from injury of the inferior alveolar nerve
   d. Ischemia due to injury of the mental artery
   e. Ischemia due to injury of the inferior alveolar artery

ADDITIONAL SOURCES

Dziegielewski PT, Mlynarek AM, Dimitry J, Harris JR, Seikaly H. The mandibulotomy: friend or foe? Safety outcomes and literature review. Laryngoscope 2009;119(12):2369–75.

Na HY, Choi EJ, Choi EC, Kim HJ, Cha IH, Nam W. Modified mandibulotomy technique to reduce postoperative complications: 5-year results. Yonsei Med J 2013;54(5):1248–52.

Shohat I, Yahalom R, Bedrin L, Taicher S, Talmi YP. Midline versus paramidline mandibulotomy: a radiological study. Int J Oral Maxillofac Surg 2005;34(6):639–41.

Steiner T, Raith S, Scherer E, et al. Which kind of frontal mandibulotomy is the smartest? A biomechanical study. J Craniomaxillofac Surg 2015;43(2):199–203.

184 Nasal Fracture

Kenneth D. Rodriguez

INTRODUCTION

- The prominent, central position of the nose on the face makes it highly vulnerable to facial trauma.
- The nasal bones are the most commonly fractured facial bone and the third most common fracture in the human body.[1]
- The most common cause of a nasal fracture is blunt trauma.
- When not promptly identified and treated, resultant nasal deformity and/or nasal airway obstruction may persist.
- Most fractures occur between the thicker proximal segment of the nasal bone and the thinner distal segment and generally result in depression at the point of impact.
- Depending on the severity of the trauma there can be lateral displacement of the contralateral nasal bone, or the fracture may be comminuted (Fig. 184.1).

KEY OPERATIVE LEARNING POINTS

- Nasal fractures should be reduced within 2 weeks of the original injury.
- Not all nasal fractures need to be repaired.
- Careful evaluation of the nasal septum should be performed during the evaluation of a nasal fracture.
- A closed reduction of a nasal fracture can be done under local or general anesthesia (GA).
- The reduction of complex nasal fractures may require an open approach.

PREOPERATIVE PERIOD

History

- Key points include time frame, mechanism of injury, and consideration of whether or not additional injuries may be present.
- It can take several days for the edema associated with nasal trauma to subside. If immediate evaluation is not possible (within hours of the injury), an accurate assessment of cosmetic change may not be possible until the edema subsides in several days.
- Inquire about a history of prior facial trauma and facial fractures, nasal deformity, or nasal airway obstruction.
  - Pre-existing conditions that are not the result of acute injury cannot be repaired using closed techniques.
  - Preinjury photographs can assist in determining a particular area of concern or determining a baseline, but often the quality is not adequate to assess for subtle changes.
  - Patients may not have a clear idea of what their baseline appearance was. Subtle changes to their nose can be perceived as changes when in fact they were present prior to the injury.

Physical Examination

- Externally, the nose should be viewed in all orientations and gentle palpation can identify areas of step-off. However, in the acute phase, soft tissue edema may obscure the fracture site.

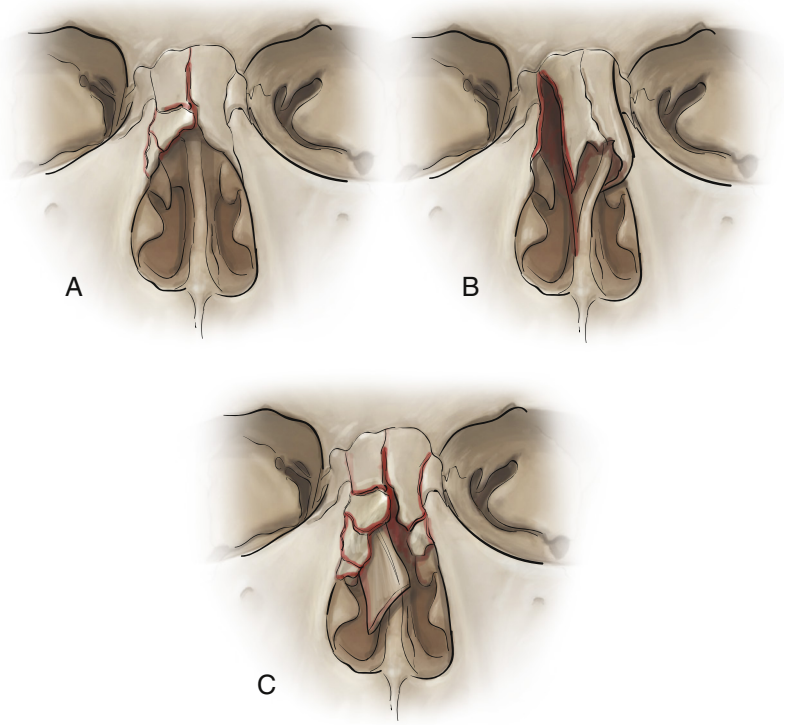

Fig. 184.1. Nasal fracture patterns. **A,** Isolated right nondisplaced nasal bone fracture. **B,** Right and left displaced nasal bone fracture with sepal fracture. **C,** Comminuted fracture of nasal bones with septal fracture.

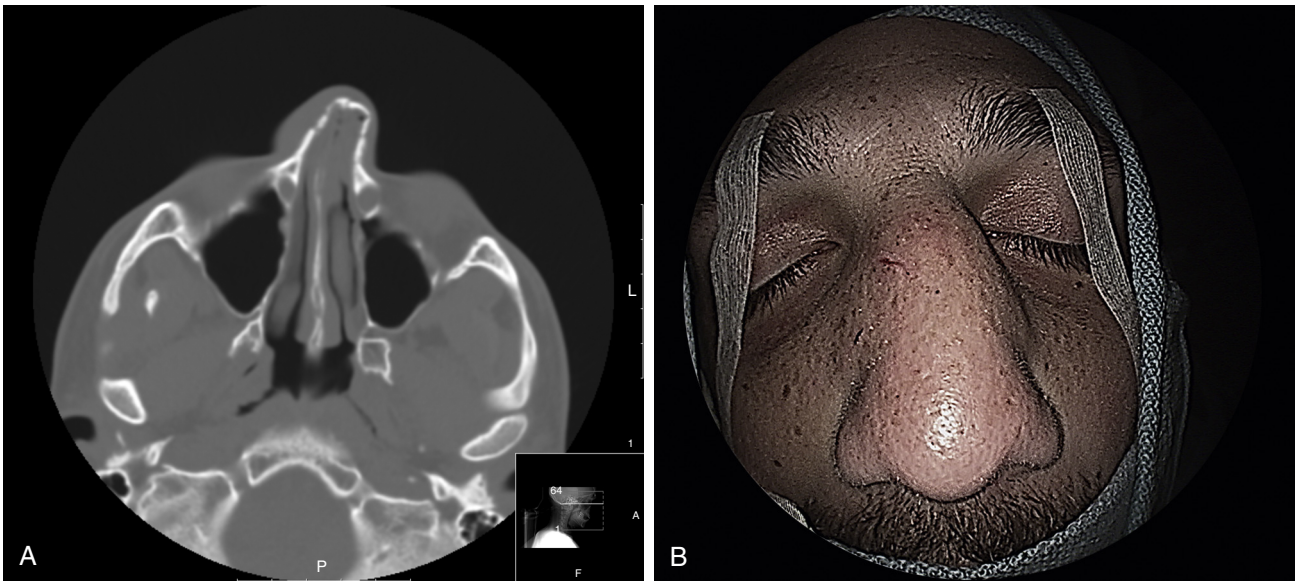

Fig. 184.2. A, Axial noncontrast computed tomography (CT) of a patient struck on the right side of his nose with resultant depression of the right nasal bone and lateral shift of the left nasal bone. **B,** Intraoperative photograph of same patient depicted in the CT demonstrating depression of the right nasal bone and resultant shift to the left side.

- Patient feedback and explanation of the site of injury can aid with the assessment.
- The septum should be evaluated for fracture or hematoma.
  - Septal hematomas should be addressed immediately if present.
- Nasal endoscopy can be used to allow for complete evaluation of the septum.[2]
  - Unrecognized septal trauma is a common indication for need of revision surgery.
- Damage to the upper/lower lateral cartilages are often overlooked and should be carefully examined for.

Imaging

- Nasal fracture is a clinical diagnosis, and imaging is not required to confirm a fracture, although patients often present with imaging obtained through the emergency department (ER) (Fig. 184.2).[3]
- Generally speaking, nasal fracture does not occur without epistaxis. If other facial fractures are suspected, noncontrast high-resolution computed tomography (CT) scan through the facial bones with coronal and sagittal reconstructions is indicated (Fig. 184.3).



Fig. 184.3. Axial noncontrast computed tomography of a patient who fell striking his nose in direct fashion with the ground resulting in severe comminuted bilateral nasal bone fractures. This imaging was obtained secondary to concern for additional orbital fractures. P, posterior. L, left.

Indications

- If the patient is comfortable with his or her external appearance and nasal breathing, the patient can be observed.
- Reduction of nasal fractures can be performed in any age group.
  - Closed reduction:
    - Unilateral or bilateral nasal bone fracture(s) without significant dislocation
  - Open reduction:
    - Extensive fractures of the nasal bones with major dislocation with or without fracture of the caudal septum
    - Open septal fracture or persistent deviation following prior closed reduction[4]

Contraindications

- Isolated nasal fracture repair in the context of a severe naso-ethmoid complex fracture. This can result in cerebrospinal fluid leak or worsen a pre-existing leak.[5] Concurrent repair of the nasal fracture as part of the larger midface repair is indicated.

Preoperative Preparation

- There is no specific preoperative preparation of the patient for nasal reduction. Patients may wish to place ice on their face to further decrease edema.
- If GA is indicated, standard medical risk assessment should be performed.
- In children, it is suggested that the reduction of the fracture be performed within 7 to 10 days to provide for more rapid healing.[6]
- In adults, the general guideline is within 10 to 14 days.[7]

OPERATIVE PERIOD

Anesthesia

- Can be performed under local or GA
- There are data to support the use of local anesthesia for closed nasal reduction, but consideration must be given to patient tolerance, risk of bleeding, and access to proper equipment if the procedure is performed outside of the operating room setting.
  - Local:
    - Topical anesthesia (4% lidocaine) along with a vasoconstrictive agent (oxymetazoline or phenylephrine) is applied to the nasal mucosa on pledgets and left in place for at least 10 to 15 minutes.
    - The position of the pledgets should include the undersurface of the nasal bones, lateral nasal wall in the region of the sphenopalatine artery foramen, floor of the nose, and mid septum.
    - One percent lidocaine with 1:100,000 epinephrine is then injected.
      - Injections should be performed in the region of the nasal dorsum (rhinion to the supratip) for the nasociliary nerve distribution from V1, around each infraorbital foramen (can be performed intra or extra nasal) for the infraorbital nerves, and at the base of the columella and nasal floor (nasopalatine nerve).
      - External injections, when possible, are often better tolerated.
  - General:
    - Following securing of the airway, a topical decongestant as listed above can be used on pledgets to decongest the nasal mucosa. Four percent cocaine is also a reasonable choice if available but is more expensive.
    - Injections can be used to decrease blood loss but are not critical in this setting for closed reductions and can delay the procedure while waiting for the vasoconstrictive effect.

Positioning

- Supine
- The patient should be draped with the nose widely exposed. The face is generally not prepped with betadine for closed reductions.
- It is critical not to distort the facial skin around the nose.

Perioperative Antibiotic Prophylaxis

- Need for perioperative or postoperative antibiotics is unclear for closed nasal reduction
- Recent data on septoplasty with packing and spontaneous epistaxis that requires packing indicate that the routine use of antibiotics (perioperative or post-packing) is not necessary.[8,9]

Monitoring

- No special monitoring is necessary.

Instruments and Equipment to Have Available

- Walsham forceps
- Asch forceps
- Langenbeck elevator
- Back of a knife handle (can be wrapped in gauze)
- Boies elevator ("butter knife")
- Suction
- Topical/injectable products as listed in anesthesia section

Key Anatomic Landmarks

- The nasal bones are paired projections that articulate with the frontal bone superiorly, lacrimal bone laterally, and ascending process of the maxilla inferiorly.
- The nasal bones become thinner and wider in the caudal direction.
- There is significant variability to the size of the nasal bones between men and women, as well as among different races.
- There are also differences in the thickness of the skin and subcutaneous tissue overlying the nasal bones from individual to individual that can serve to mask subtle fractures.
- The caudal aspect of the septum articulates with the maxillary crest. The fibrous connections at that level as well as the intrinsic flexibility of the septal cartilage allow mobility, decreasing the risk of septal fracture.

Prerequisite Skills

- Closed nasal reduction represents a basic skill for the resident in training.
- Open techniques require expertise in rhinoplasty and/or septoplasty and represent a far more advanced skill set that in some cases requires fellowship-level training.

Surgical Technique

- Closed reduction:
  - Palpation of the nasal bones should be performed to determine mobility and to feel for step-offs with the midface articulations.
  - Endonasal examination should be performed if there are concerns for septal injury that could not be fully evaluated in the clinical setting.
  - It is good practice to externally measure the distance between the superior aspect of the nasal bones and the external nasal valve and use that distance as the deepest point of entry into the nose with any instruments.
  - It is often helpful to address the side of most significant deformity first.
  - Using controlled pressure, the fracture fragments can be reduced into improved alignment.
    - Palpation on the bones externally while they are being reduced internally can allow for more precise placement as step-offs can be corrected with visual and tactile feedback (Video 184.1).
      - There is often resultant epistaxis that can be controlled with additional topical decongestant.
  - If there is a concurrent septal fracture, closed reduction can be attempted following the same basic technique as with a closed nasal bone fracture. This can be performed endoscopically or via a speculum.
  - In patients with a comminuted nasal bone fracture, there can be need for internal splinting to keep the fragments in place.
    - Both absorbable and nonabsorbable products can be used for this depending on the patient need.
    - External splints are often employed and include Denver splints or thermoplastic splints. Care must be taken when applying any external splint onto a freshly reduced nasal bone as slight pressure can cause loss of reduction.
  - Open reduction:
    - Septal fractures can be accessed through a hemitransfixion incision, and the nasal bones can be approached via rhinoplasty techniques (both techniques covered elsewhere in this textbook; see Chapter 95).

- Other approaches include the use of a pre-existing laceration, an incision across the glabellar region (open sky incision), or lateral rhinotomy (to access a unilateral fracture).
  - Unfortunately, these incisions create prominent scars as a trade-off for simple access and excellent exposure.
  - A coronal incision can be used without the need of facial incisions to access injuries to the frontal/nasal bone junction. Plating, if indicated by the fracture pattern, can be performed via these open approaches.
- There are multiple current procedural terminology (CPT) codes involving nasal fracture reduction (Table 184.1).

Common Errors in Technique

- It may take significant pressure to reduce a fracture, and it is critical to stay as steady as possible during reduction as slipping off the base of the nasal bones into the soft tissue at that level can cause significant trauma.
- Care should be taken deep to the origin of the nasal bones off the frontal bone as fractures there are uncommon and mucosal trauma caused by pressure underneath nonmobile bone can easily lacerate and cause bleeding.
- It is often helpful to keep an elevator internally holding the reduced fragments in alignment while external pressure is placed to secure the external dressing to prevent depression of fragments.

POSTOPERATIVE PERIOD

Postoperative Management

- Follow-up in 1 week allows for resolution of perioperative swelling.
- External and internal nasal packing are generally removed at the initial visit, although packing can be left for longer if indicated.
- Activities that predispose to nasal trauma should be avoided for at least 1 month.
  - Athletes may benefit from the use of a face mask.

Complications

- Early
  - Septal hematoma, epistaxis, infection, or excessive facial edema or bruising
  - Cerebrospinal fluid (CSF) rhinorrhea may result from disruption of the skull base or worsening of skull base/posterior table fractures during reduction.
- Late
  - Subperichondrial fibrosis from untreated septal hematoma, intranasal scarring, persistent nasal breathing issues, or unfavorable cosmetic appearance

Alternative Management Plan

- If the reduction was challenging, and complete symmetry was not attained, it is often in the best interest of the patient to allow the nasal bones to completely heal and consider rhinoplasty at a later time.
  - Complete healing can take months, and subtle changes can improve or worsen over this time.
  - Patients may be resistant to further operations despite persistent symptoms following closed nasal reduction.
- Outcomes from nasal fracture reduction are variable. Several series of closed nasal fracture results were reviewed and demonstrated an average of 79% patient satisfaction and 37% surgeon satisfaction.[7]

TABLE 184.1 Current Procedural Terminology

21310	Closed treatment of nasal bone fracture without manipulation
21315	Closed treatment of nasal bone fracture without stabilization
21320	Closed treatment of nasal bone fracture with stabilization
21325	Open treatment of nasal bone fracture; uncomplicated
21330	Open treatment of nasal bone fracture; complicated, with internal or external skeletal fixation
21335	Open treatment of nasal bone fracture; with concomitant open treatment of fractured septum

- Some authors advocate initial septorhinoplasty as the best option, and data would suggest less patient dissatisfaction with that approach, but clearly this is not indicated for all individuals.[2] We as surgeons must understand the scope of procedures available to us and appreciate our own limitations. Individually evaluating patients and tailoring procedures to meet their specific needs and expectations will maximize outcomes.

DISCUSSION

Evidence-Based Medicine Question

What is the preferred anesthesia technique to perform closed reduction of a nasal fracture in regard to patient satisfaction with their postoperative appearance?

a. Intranasal pledgets without local injected anesthesia
b. Intranasal pledgets with local injected anesthesia
c. Intranasal pledgets with local injected anesthesia with oral benzodiazepine
d. General anesthesia

A meta-analysis of local versus GA for management of nasal bone fractures supported the use of a general anesthetic. There was a statistically significant difference in favor of patients treated under GA with regard to improvement in the appearance of the nose after treatment ($P = .006$).[10]

Editorial Comments

Nasal fractures are extremely common; nonetheless, the difficulty of their management is grossly underestimated. Although the mechanics of a closed reduction are relatively simple, it requires extreme attention to detail and a thorough assessment of every component of the external and internal nose. The septum and upper lateral cartilages are often undervalued during the assessment, and ignoring their luxation often results in suboptimal outcomes. The idea that a nasal fracture is easily corrected under local anesthesia (and sometimes attempted under topical) in the clinic or ER setting should be dispelled except for highly selected patients or when limited resources dictate the circumstances. The surgeon should be skilled in both closed and open techniques and best apply them according to the severity of the fracture. A universally accepted algorithm is yet to be defined.

Ricardo Carrau

Access the review questions and additional sources list online at http://www.expertconsult.com

REFERENCES

1. Rhee SC, Kim YK, Cha JH, et al. Septal fracture in simple nasal bone fracture. Plast Reconstr Surg 2004;113:45–52.
2. Fernandes SV. Nasal fractures: the taming of the shrewd. Laryngoscope 2004;114(3):587–592.

3. Sharp JF, Denholm S. Routine x-rays in nasal trauma: the influence of audit on clinical practice. J R Soc Med 1994;87:153–154.
4. Mondin V, Rinaldo A, Ferlito A. Management of nasal bone fractures. Am J Otolaryngol 2005;26(3):181–185.
5. Sargent LA. Nasoethmoid orbital fractures: diagnosis and treatment. Plastic Reconstr Surg Dec 2007;120(7 Suppl 2):16s–31s.
6. Yabe T, Tsuda T, Hirose S, Ozawa T. Comparison of pediatric and adult nasal fractures. J Craniofac Surg 2012;23(5):1364–1366.
7. Staffel JG. Optimizing treatment of nasal fractures. Laryngoscope 2002;112:1709–1719.
8. Ricci G, D'Ascanio L. Antibiotics in septoplasty: evidence or habit? Am J Rhinol Allergy 2012;26(3):194–196.
9. Pepper C, Lo S, Toma A. Prospective study of the risk of not using prophylactic antibiotics in nasal packing for epistaxis. J Laryngol Otol 2012;126(3):257–259.
10. Al-Moraissi EA, Ellis E. Local versus general anesthesia for the management of nasal bone fractures: a systematic review and meta-analysis. J Oral Maxillofac Surg 2015;73(4):606–615.

REVIEW QUESTIONS

1. Imaging is required under what circumstances during evaluation of a nasal fracture?
   a. No external changes or breathing issues
   b. Nasal breathing issues without external change
   c. Nasal breathing issues with external change
   d. None of the above

2. If closed nasal reduction under local anesthesia was planned, which of the following nerves would not need to be anesthetized?
   a. Nasopalatine
   b. Supraorbital nerve
   c. Infraorbital
   d. Nasociliary

3. In adults, nasal fractures are best repaired in what time frame?
   a. <1 day
   b. <2 weeks
   c. <3 weeks
   d. All of the above
   e. A and B

ADDITIONAL SOURCES

Cook JA, McRae RD, Irving RM, et al. A randomized comparison of manipulation of the fractured nose under local and general anaesthesia. Clin Otolaryngol Allied Sci 1990;15(4):343–346.

Murray JA, Maran AG, Mackenzie IJ, et al. Open v closed reduction of the fractured nose. Arch Otolaryngol 1984;110:797–802.

Rubinstein B, Strong EB. Management of nasal fractures. Arch Fam Med 2000;9:738–742.

185 Fractures of the Mandible

William Chung, Gaurav A. Shah

INTRODUCTION

There are numerous causes of mandibular fractures including assault, motor vehicle accidents, projectile missiles, and pathologic fractures. Multiple studies have shown motor vehicle accidents and interpersonal assaults as the leading causes for mandibular fractures.[1–3] When a mandible fracture is suspected, careful evaluation of other injuries must be ruled out. A recent study reported a 64.8% association with life-threatening injury such as closed head injury, skull fracture, and body cavity trauma.[1] In the setting of isolated fractures to the maxillofacial skeleton, cervical spine injury ranged from 4.9% to 8.0%.[4]

The mechanism of trauma can provide valuable information to the clinician on the potential injury patterns and locations to the mandible (Fig. 185.1). An anterior impact typically causes a symphyseal fracture with or without condylar involvement, whereas lateral impacts typically result in body or angle fractures.[1] Interpersonal assaults have a high predilection for mandibular angle fractures.[1] The majority of mandibular fractures occur in males in the 25- to 34-year-old age group.[1] Nearly 25% of mandible fractures in women are due to falls, and the practitioner should be wary of and evaluate for non-accidental trauma.[1]

The classification of fractures by location can be further described by the fracture pattern as open (compound), closed (simple), comminuted, green stick, complex, and/or multiple. Open/compound fractures communicate through the skin or mucosa with the external environment. Comminuted fractures include multiple segments of bone that are crushed or splintered. Complex fractures are either an open or closed fracture that are associated with significant soft tissue injury.

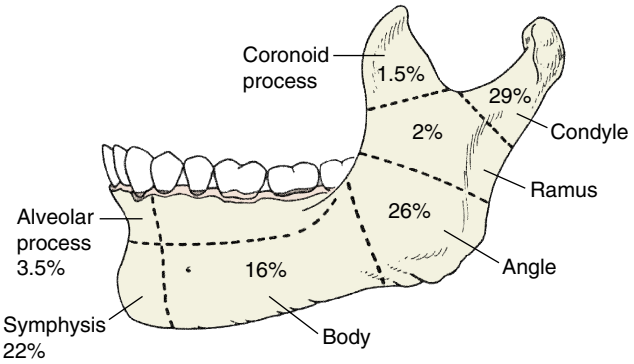

Fig. 185.1. Anatomic classification and percent distribution of mandibular fractures in dentate adult patient.

KEY OPERATIVE LEARNING POINTS

- Understanding the basic principles of dental occlusion is necessary to ensure optimal fracture repair.
- Displacement of fracture segments is defined as either favorable (stable) or unfavorable (unstable) given the biomechanics exerted on the fragments by muscle pull (Fig. 185.2).
- Understanding the interaction of these forces is essential during reduction of fractures as excessive interfragmentary motion during fracture healing interrupts proper bone formation at the histologic level.
- Temporary reduction of significantly displaced fracture segments that include the dentition can be achieved by placement of a bridal wire, which assists in control of flail segment(s) or hemorrhage (Fig. 185.3).

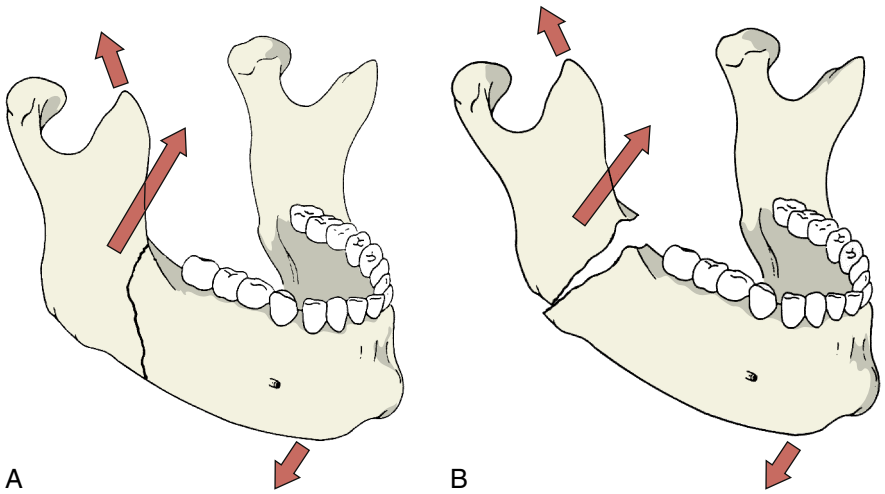

Fig. 185.2. A, Favorable mandibular angle fracture. With the muscular pull of the temporalis and masseteric and the minor influence of the digastrics and suprahyoid musculature, there is a tendency toward further fracture reduction or stabilization. **B,** Unfavorable mandibular angle fracture. With these same muscular forces, there is a tendency toward gapping at the superior border and rotation of the proximal or angle segment upward. This bony step can also be palpated intraorally.

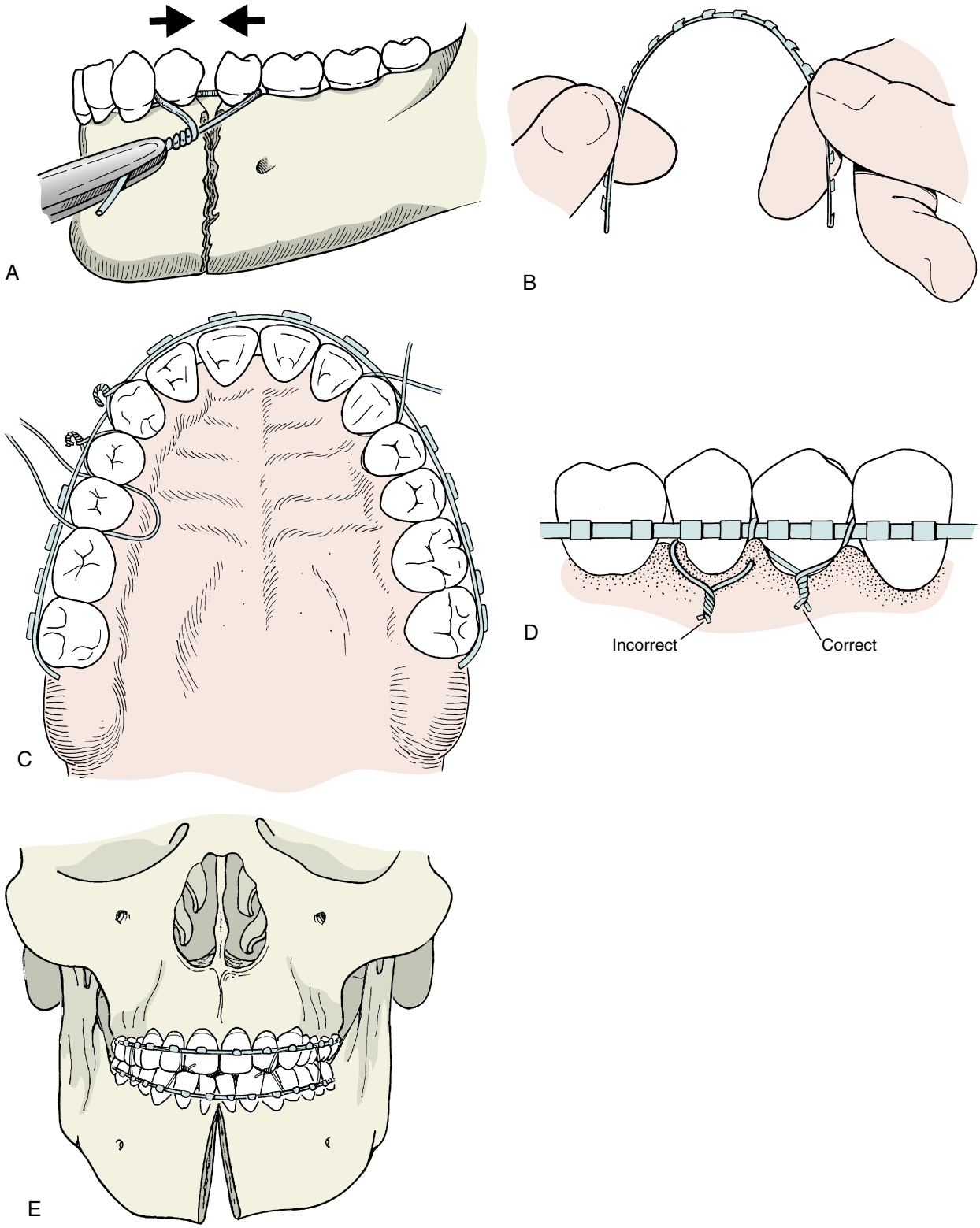

Fig. 185.3. A, A bridal wire is passed around the first and second bicuspids in a left mandibular body fracture to aid in reduction and stabilization. This is performed before fixation of the arch bar and allows the arch bar to be secured to the mandible in an already reduced position. **B,** Arch bar is cut and bent to appropriate length and shape of dentition for fixation. **C,** Arch bar is fixed to posterior teeth with 24-gauge circumdental wires and to anterior teeth with 26-gauge circumdental wires. The wires pass above the bar on the one side of the tooth and below the bar on the other side then twisted in a clockwise fashion. **D,** Wires should pass between tooth and gingival papilla to avoid strangulation of these structures. **E,** Overtightening the maxillomandibular fixation wires in the presence of a symphysis fracture will cause the inferior border of the fracture to splay apart and the occlusion will lean lingually, preventing adequate fracture reduction.

- Intubation is made challenging in cases of flail mandible fractures.
- A prospective cohort study found that inferior alveolar nerve injury was four times more likely in posterior mandibular fractures (56.2%) than in anterior mandibular fractures.[5]
- A unilateral subcondylar fracture often presents with a contralateral open bite with deviation of the mandible to the ipsilateral side upon opening. Bilateral condylar fractures may present as an anterior open bite with premature contact of any posterior teeth.[1]
- In contrast to bicortical fractures, greenstick fractures of the mandible are often difficult to identify by physical exam ination alone. Careful history with focus on mechanism of injury and force of impact are critical for further workup and evaluation in those with a high suspicion for mandibular trauma.
- In mandibular body fractures, masticatory forces create strain or tension above the mandibular canal. Below the canal, compression forces along the inferior border promote bony contact under an occlusal load. Fixation is necessary to neutralize this force.[6]
- Angle fractures are shown to have the highest rate of complication compared with other mandibular fractures partly due to its proximity to the inferior alveolar nerve and masseteric and facial vessels.[7]
- Regardless if a transoral or extraoral approach is used, rigid internal fixation for an angle fracture is necessary to neutralize the tension, compression, and torsional forces encountered at the angle due to the opposing forces of mandibular elevators and depressors in the region.[8]
- A third molar in the line of fracture may be left in place if it does not interfere with reduction, while its removal at time of repair has been shown to increase the risk of infection.[8]
- The marginal mandibular nerve and cervical nerve are 2 cm below the inferior border of the mandible 80% of the time.[9]
- Condylar fractures account for 11% to 16% of all facial fractures and nearly a third of mandibular fractures.[10] Management of these fractures remains highly controversial; many surgeons favor nonsurgical treatment because it results in satisfactory function and esthetics.
- Al-Moraissi and Ellis determined open reduction and rigid internal fixation (ORIF) for subcondylar fractures provided superior functional clinical outcomes compared to maxillomandibular fixation (MMF) when considering maximal incisal opening, laterotrusive movement, protrusive movement, malocclusion, pain, and chin deviation.
- Absolute indications for ORIF of condyle fractures: (1) displacement into the middle cranial fossa; (2) difficulty establishing dental occlusion with closed treatment alone; (3) lateral extracapsular displacement of the condyle; (4) presence of a foreign body; and (5) open fracture with potential for fibrosis[3]
- Coronoid fractures occur in less than 2% of all mandible fractures and are typically due to lateral impact at the level of the zygomatic-maxillary complex. Treatment for coronoid fracture is typically unnecessary.
- Some have recommended that open treatment of atrophic mandible fractures be avoided due to the risk of compromised blood supply over the fracture.
- Atrophic fractures can be classified by the following: Class I—15 to 20 mm of bone height; Class II—10 to 15 mm; and Class III—<10 mm of bone height.
- More rigid fixation is necessary in mandibles with <15 mm of bone height. Fixation must be rigid enough to allow for load-bearing and ideally load-sharing under function.
- When multiple mandible fractures exist, rigid fixation on at least one side is necessary to decrease the chance of a complication.

PREOPERATIVE PERIOD

History

1. History of present illness
   a. Determine patient's level of consciousness and ability to communicate; may need to rely on family or friend(s) in the obtunded patient.
   b. Inquire about pretrauma status of patient's dentition/occlusion.
   c. Determine level of pain and presence of trismus.
   d. Investigate mechanism of trauma.
2. Past medical history
   a. Cardiac disease
   b. Pulmonary disease
   c. Endocrine disorders (e.g., diabetes and adrenal disorders)
   d. Coagulopathies
   e. Immune disorders
3. Past surgical history
   a. Previous facial/mandibular fracture repair; consider use of previous incisions
   b. Be aware of extent of scar tissue from previous surgical procedures.
4. Medications
   a. Anticoagulants, antiplatelet agents
   b. Antihypertensive medications
   c. Diabetic medications
   d. Immune suppression medications
   e. Antibiotics
5. Allergies
6. Social history
   a. Tobacco history
   b. Alcohol use/abuse
   c. Illicit drug use/abuse

Physical Examination

The evaluation of mandibular trauma begins with a systematic assessment and evaluation of the patient during the primary and secondary trauma surveys. Protection of the airway and cervical spine *must* be considered during every exam for mandibular trauma. Bilateral mandibular body or parasymphyseal fractures can cause a flail segment that is pulled back by the genial musculature resulting in airway restriction, making a typical chin lift or jaw thrust maneuver complicated.[4]

Extraoral

1. Symmetry and height of lower third of face
2. Edema and ecchymosis overlying mandible or neck
3. Palpable step-offs at inferior border of mandible
4. Jaw opening pattern and maximum interincisal opening
5. Crepitus in anterior/lateral neck.
6. Lacerations (adjacent to critical structures—nerves, vessels) over mandible or neck
7. Soft tissue loss/avulsions
8. Foreign bodies, tooth fragments within soft tissue wounds
9. Altered sensation along distribution of trigeminal nerve (third division)

Intraoral

1. Integrity of mucosa
2. Edema or ecchymosis in vestibules/floor of mouth
3. Lacerations of mucosa, gingiva, or tongue

4. Missing/fractured teeth, particularly within adjacent lacerations
5. Occlusion
6. Range of motion of the mandible
7. Altered sensation of trigeminal nerve (third division)

Imaging

Imaging is optimally obtained in at least two planes as single plane images may either prohibit a clinician from accurately identifying every fracture or underestimate the technical difficulty required for proper fracture reduction.[8] Plain film radiography combinations that are used for mandibular fracture evaluation include a panoramic radiograph with a posterior-anterior radiograph of the mandible. A horizontally unfavorable fracture can be visualized on a panoramic radiograph, while a vertically unfavorable fracture can be determined on an anteroposterior radiograph.

1. Panorex—most diagnostic plain film image to diagnose mandibular fractures. Overlap of cervical spine may obstruct identification of posterior fractures.
2. PA skull radiograph—Evaluate symphyseal fractures.
3. Open mouth Townes—Evaluate subcondylar fractures.
4. Lateral oblique(s)—are useful for identifying mandibular body and angle fractures
5. Computed tomography (CT) scan—Multiple studies determined that a CT was 100% sensitive in diagnosing mandibular fractures compared to 86% sensitivity noted by panoramic radiograph.[3]
   a. 3-dimensional images helpful in cases of severely comminuted mandible fractures or in conjunction with panfacial fractures

Indications

1. Restore facial form and function.
2. Restore occlusion.
3. Restore mandibular range of motion.
4. Reduce fracture(s) to stop hemorrhage.

Contraindications

1. Neurologically unstable
2. Hemodynamically unstable
3. Acute infection

Preoperative Preparation

Surgical intervention for mandibular fractures should not be delayed to minimize the risk of postoperative infection, improve patient comfort, and facilitate oral nutrition. However, urgent surgical intervention may be delayed due to severe neurologic injuries, hemodynamic instability, or preexisting unstable comorbidities. One study found no increase in complication rates when definitive repair was performed within three days compared with those after 3 days.[3]

When teeth are present on only one side of the fracture, an open technique with rigid fixation is preferred. The requirement for either load-bearing or load-sharing fixation is dependent on the whether or not enough bone stock exists that can bear the load of mastication across the fracture site. Load-sharing fixation requires that the fragments transfer forces across the area, which can be accomplished with mini-plates, compression plates, or lag screws. Load-bearing fixation is a plate that must bear all forces and is used in area of severe comminution or continuity defects.

Occlusion

- Multiple formal classification systems exist to describe occlusal relationships. The Angle system is most widely used.
- In a normal Class I pattern, the mesiobuccal cusp of the maxillary first molar is aligned with the buccal groove of the mandibular first molar.
- In a Class II relationship, the buccal groove of the mandibular first molar is distal to the mesiobuccal cusp of the maxillary first molar when in occlusion.
- In a Class III pattern, the buccal groove of the mandibular first molar is mesial to the mesiobuccal cusp of the maxillary first molar when in occlusion.
- Patients with a pre-existing malocclusion may have molar relationships that are normal in the anterior-posterior plane as described by the Angle system. However, discrepancies in the transverse plane may exist such as dental crowding, misalignment, or cross-bites.
- Obtaining a photograph of the patient smiling before the injury assists the clinician in determining an optimal dental-occlusal relationship.

OPERATIVE PERIOD

Anesthesia

1. Nasal endotracheal intubation is required to allow for intraoperative MMF, unless a concomitant severe nasal fracture is present.
2. Tracheostomy may be required if nasal endotracheal intubation is not possible due to injury.

Positioning

1. Supine
2. Prepare and drape lower third of the face and neck in standard fashion. Prepare oral cavity with chlorhexidine rinse *or* clindamycin-infused normal saline.

Perioperative Antibiotic Prophylaxis

Preoperative antibiotic administration is imperative.[8] This practice is supported by a landmark prospective study from the *New England Journal of Medicine* in 1992 that determined prophylactic antibiotic use, specifically 2 hours before surgery, for clean-contaminated procedures reduced the risk of postoperative wound infection.

1. Choices:
   a. Cefazolin
   b. Ampicillin/sulbactam
   c. Clindamycin is preferred for penicillin-allergic patients.

Monitoring

1. Routine
2. Request the anesthesiologist to HOLD any paralytic agents after induction/intubation to facilitate testing of the facial nerve, when appropriate.

Instruments and Equipment to Have Available

1. Hardware for MMF (surgeon's preference and dependent on status of existing dentition and occlusion)
2. Fixation hardware, when necessary (surgeon's preference)
3. Wire driver and cutter

4. Surgical retractors
5. Hemostats
6. Periosteal elevators
7. Curettes
8. Bone clamps
9. Nerve stimulator
10. Sutures

Key Anatomic Landmarks

1. Dental root(s)
2. Mental nerve and foramen
3. Inferior alveolar nerve and canal
4. Superficial layer of the deep cervical fascia—facilitate location of the marginal mandibular nerve
5. Facial artery and vein
6. Tail of parotid gland
7. Attachment site of genioglossus muscle
8. Platysma muscle layer, especially in submental region. Resuspension critical to avoid chin ptosis

Prerequisite Skills

- Application of Erich arch bars/wires or bone fixation screws for MMF techniques
- Surgical dissection of the mental nerve/foramen
- Surgical dissection of the submandibular region

Surgical Technique

The goals of reconstructing the mandible are to reestablish the lower third of the face in all three dimensions to ensure adequate form and function.

Dentoalveolar Fractures

- Avulsion of deciduous teeth should not be reimplanted as it may cause further damage to permanent tooth.
- Adult teeth should be reimplanted within 1 hour for most favorable prognosis.
- Avoid desiccation of tooth; store tooth in saliva, saline, or Hank's Balanced Salt Solution.
- Gentle assessment of alveolar socket performed to be certain no foreign bodies or lacerations are present while avoiding dislodgment of a developing blood clot
- Initial consideration is given to gently irrigating the socket, followed by referral to a dental practitioner for space maintenance.
- The tooth roots should not be manipulated to avoid harm to the periodontal ligament; the tooth should be replanted into the socket by holding onto only the crown of the tooth. This should be followed by using finger pressure to compress the buccal and lingual/palatal alveolar plates.
- Reduce fracture to proper occlusion when possible with splinting for 2 to 3 weeks.
- Soft diet and vigilant oral hygiene are imperative.

Symphysis/Parasymphysis Fractures

The mandibular symphysis is demarcated by the region anterior to an imaginary vertical line distal to the lower canine teeth.[6] These fractures can be treated closed with MMF or ORIF.

Closed treatment is indicated when the fracture line is appropriately reduced when muscle pull is applied. Erich arch bars or self-tapping bone screws in conjunction with a 24 or 25 gauge wire can be used to place the patient in MMF.[6]

- Symphysis fractures are typically approached through a vestibular incision 8 to 10 mm below the mucogingival junction for ORIF
- Once symphysis is exposed and the fracture reduced, a tension plate is fixated with monocortical screws 2 to 2.5 cm below the incisal edges of the mandibular incisors. This roughly corresponds to the region where the alveolar bone merges with the basal bone forming a depression in the anterior mandible.
- Use of lag screws for an oblique fracture is a well-established technique that can be used to counteract torsion.[6]

Mandibular Body Fractures

- The optimal occlusion is determined, and the patient is then placed into MMF. Nondisplaced body fractures can be treated with 6 weeks of MMF.
- If ORIF is required, a transoral incision 8 to 10 mm below the mucogingival junction is used with attention to identifying and skeletonizing the mental nerve branches during dissection.
- Eversion of the lip mucosa facilitates identification of the peripheral branches of the mental nerve during dissection. Once located, fine-tipped mosquitoes carefully follow and skeletonize the branches down to the foramen.[9]
- A tension band is adapted and fixated with two monocortical screws on either side of the fracture. Placement is typically above the mental foramen and below the root apices.
- A fracture plate is adapted and fixated just above the inferior border, with a minimum of two bicortical screws on either side of the fracture. In complex cases, three screws on either side of the fracture are required.

Angle Fractures

- The decision to open an angle fracture depends on the degree of displacement, presence of dentition, favorability of the fracture, and the surgeon's experience with the anatomy of this region.
- If an extraoral approach is used, an incision is made 2 to 2.5 cm below the inferior border of the mandible within a resting line of tension to minimize postoperative scarring.
- Layered dissection with use of a nerve stimulator minimizes injury to the marginal mandibular and cervical branches of the facial nerve.
- A tension band is placed superiorly and fixated with two monocortical screws on either side of the fracture. A fracture plate is fixated at the inferior border with 2 to 3 bicortical screws on either side of the fracture.
- A layered closure is required.

Condylar/Subcondylar Fractures

- Intracapsular (condylar) fractures can be treated with a 3-week course of MMF, unless the condylar head is dislocated.
- Access for subcondylar fractures is possible through a submandibular incision alone but can be maximized by making both submandibular and preauricular incisions, the latter allows direct visualization of repositioning of the condylar head within the glenoid fossa.
- Fixation of such fractures requires smaller hardware due to the anatomy of the bone, but efforts should be made to place at least two screws on either side of the fracture, when possible.
- Layered closure is required.

Ramus Fractures

Ramus fractures can be treated with MMF for 4 weeks. ORIF is required if a significant malocclusion or facial asymmetry is present. A submandibular or retromandibular incision is ideal for access.

Atrophic Mandible Fractures

- An extraoral or transoral incision can be used to fixate atrophic fractures. The latter incision is associated with a lesser chance of facial nerve injury. However, the inferior alveolar nerve can be closer to the superior aspect of the alveolar crest of an atrophic mandible and can become distorted during fracture manipulation.
- An atrophic mandible fracture is often rigidly fixated with a 2.0-mm plate or compression plate.
- Wound dehiscence is a common complication due to the irritation of the mucosal tissue from the underlying hardware when a functional load is brought against the tissues.

Multiple Fractures

- Establishment of a stable occlusion with MMF before fixation (Fig. 185.4)
- Fixation in the case of multiple fractures should occur starting with the two most stable, largest segments. The combination of fixation and reestablishment of the occlusion decreases the chances of gonial flaring and malocclusion postoperatively.[8]
- The use of locking plates and screws are often useful when added stability is desired and distraction of fracture segments is a concern.

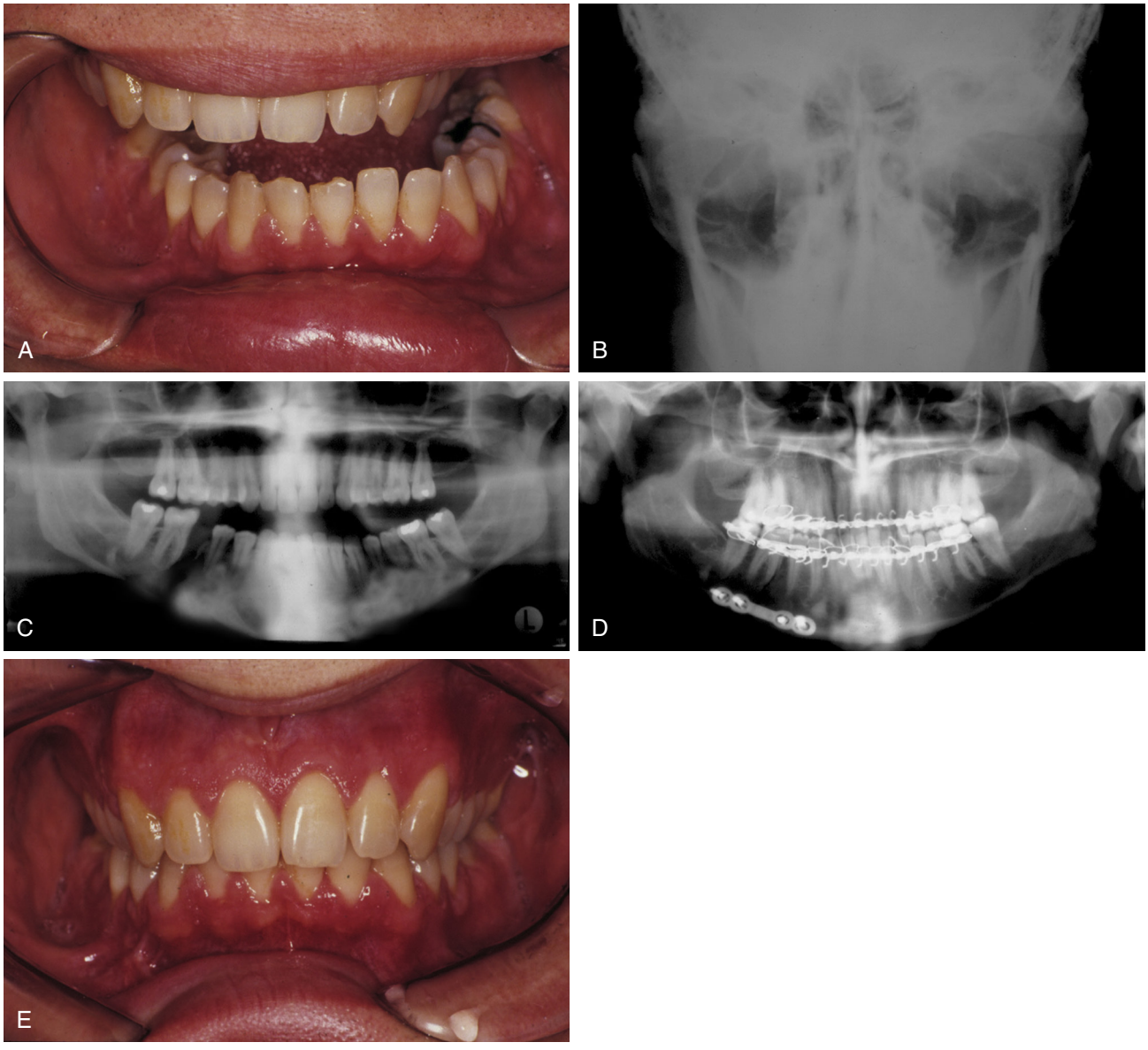

Fig. 185.4. A, Patient presented with deviation of mandible to the left and premature occlusal contact on right posterior teeth. An open mouth reverse Towne view, **B,** and panorex view, **C,** reveal left subcondylar fracture with overlap and displaced right body fracture. **D,** Patient underwent maxillomandibular fixation (MMF) with transoral approach to right body fracture with placement of a fracture plate at the inferior border. The left subcondylar fracture was treated closed with a 2-week period of MMF. **E,** Postoperative occlusion at 6 weeks. Guiding elastics were placed between weeks 2 and 4 on the right side and anterior region to guide the occlusion into place.

Alternative Management Plans

No surgical intervention can be considered for a nondisplaced fracture with no evidence of any malocclusion if the patient is able and willing to be absolutely compliant with a strict liquid diet.

Common Errors in Technique

- Not making a vestibular incision at least 8 to 10 mm below the mucogingival junction can result in loss of vestibular depth and/or excessive senichiae formation along the incision.
- Not holding inward pressure at the mandibular angles when fixating a symphysis fracture can result in flaring of the gonial angles.
- Not ensuring that the occlusion is stable during reduction and fixation of a fracture results in a malocclusion.

POSTOPERATIVE PERIOD

Patients who have been treated with closed treatment are kept in MMF for 3 to 6 weeks depending on the fracture location. Condyle fractures are left in MMF for a shorter duration to reduce the risk for ankylosis of the joint. Therefore fixation is removed by 3 weeks to allow functioning of the cartilaginous disc. Wire cutters should be in the patient's possession at all times with explicit instructions for removal of the fixation wires only for emergent loss of airway secondary to choking. Postoperative instructions for patients who have undergone ORIF include a soft, non-chew diet for 6 weeks to allow for consolidation of bony segments while minimizing functional load. The use of long-term postoperative antibiotics has not been determined to show a statistically significant benefit when ORIF is performed. Postoperative antibiotics may be beneficial in consideration of patient factors such as poor wound healing in the setting of uncontrolled diabetes or tobacco use.

Complications

Posttrauma complications include loss of tooth vitality, malocclusion, exposure of hardware, non-union/malunion, and neurologic deficits such as paresthesias. The risk of inferior alveolar nerve injury was found to be greatest with fracture displacements greater than 5 mm. Patient factors for postoperative complications involve poor hygiene, medical conditions that compromise wound healing, substance abuse, and noncompliance.

DISCUSSION

Evidence-Based Medicine Question

The practitioner, in many instances, may question the adequacy of fixation of comminuted fractures of questionable biomechanical favorability. What is the value of postoperative radiographs in such instances? Do postoperative radiographs offer changes in outcomes such as re-exploration of the fracture or change in morbidity compared with proper postoperative physical examination?

MMF without rigid fixation is still widely used for nondisplaced or minimally displaced biomechanically favorable fractures in patients with a complete complement of teeth and in intracapsular condylar fractures or severely comminuted fractures in which occlusion can be reestablished.

Postoperative radiographs, particularly CT, remain debatable as a review of the literature has shown that the sensitivity, specificity, and positive predictive value in determining complications are below expectations and add little information when supported by physical examination and history-taking. A 2015 study in *JAMA* analyzed the cost analysis of post-fracture reduction imaging as it relates to the complication rate encountered by the surgeon. The study determined that a post-reduction panorex radiograph should be obtained for mandibular fracture repair until the surgeon's complication rate falls below 17.7%.

Editorial Comments

The authors have provided a comprehensive chapter that makes clear that the ideal management of mandibular fractures requires knowledge of a vast array of techniques that can be adjusted to the site, extent, type of fracture, and the patient's needs and circumstances.

Ricardo Carrau

Access the review questions and additional sources list online at http://www.expertconsult.com

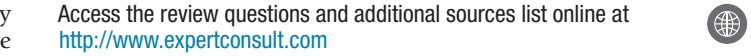

REFERENCES

1. Morrow BT, Samson TD, Schubert W, et al. Evidence-based medicine: mandible fractures. Plast Reconstr Surg 2014;134(6):1381–1390.
2. Haug RH, Prather J, Indresano AT. An epidemiologic survey of facial fractures and concomitant injuries. J Oral Maxillofac Surg 1990;48(9):926–932.
3. Stacey DH, Doyle JF, Mount DL, et al. Management of mandible fractures. Plast Reconstr Surg 2006;117(3):48e–60e.
4. Krishnan DG. Systematic assessment of the patient with facial trauma. Oral and Maxillofacial Surgery Clinics of North Am 2013;25(4):537–544.
5. Ban Guan Tay A, Bin Lai J, Weng Lye K, et al. Inferior alveolar nerve injury in trauma-induced mandible fractures. J Oral Maxillofac Surg 2015;73(7):1328–1340.
6. Goodday RH. Management of fractures of the mandibular body and symphysis. Oral Maxillofac Surg Clin North Am 2013;25(4):601–616.
7. Al-Moraissi EA, Ellis E. What method for management of unilateral mandibular angle fractures has the lowest rate of postoperative complications? A systematic review and meta-analysis. J Oral Maxillofac Surg 2014;72(11):2197–2211.
8. Ellis E, Miles BA. Fractures of the mandible: a technical perspective. Plast Reconstr Surg 2007;120(7 Suppl 2):76S–89S.
9. Haggerty C. Mandibular fractures. In: Haggerty CJ, Laughlin RM, editors. Atlas of Operative Oral and Maxillofacial Surgery. Ames, IA: Wiley Blackwell; 2015. p. 107–140.
10. Chrcanovic BR. Surgical versus non-surgical treatment of mandibular condylar fractures: a meta-analysis. Int J Oral Maxillofac Surg 2015;44:158–179.

REVIEW QUESTIONS

1. A unilateral, moderately displaced subcondylar fracture will typically manifest the following clinical exam finding
   a. Deviation of the chin point toward the ipsilateral side of the fracture due to the unopposed action of the contralateral lateral pterygoid muscle
   b. Deviation of the chin toward the contralateral side of the fracture due to unopposed action of the contralateral lateral pterygoid muscle
   c. Deviation of the chin point toward the ipsilateral side of the fracture due to the action of the masseter muscle
   d. Deviation of the chin point toward the contralateral side of the fracture due to the action of the masseter muscle

2. When discussing favorable versus unfavorable fracture patterns, all of the following are true, except
   a. It requires an understanding of the biomechanics exerted on the fracture segments by muscle pull.
   b. The elevator muscles—masseters, temporalis, and medial pterygoid—can cause displacement of fracture segment in the vertical plane.
   c. Action of the lateral pterygoid and torsional forces by the mylohyoid, digastrics, and geniohyoid muscles causes horizontal displacement of the fracture segment.
   d. All of the above

3. Surgical considerations in treatment planning mandibular fractures include all of the following, except
   a. The presence of posterior occlusion along with its proper reduction allows for greater predictability in treatment outcomes when considering gonial flaring and malocclusion.
   b. The desired method of fixation is highly dependent on the existing dentition and muscle forces.
   c. In a dentate patient with stable teeth on either side of a fracture, closed treatment via maxillomandibular fixation is reasonable.
   d. Consideration for teeth roots and avoiding ischemic necrosis caused by the violation of the oral periodontium are of utmost importance.
   e. All of the above

4. Studies have conclusively determined that all open mandibular fractures must be surgically repaired within the first 48 hours to eliminate any risk of postoperative infections.
   a. True
   b. False

ADDITIONAL SOURCES

Al-Moraissi EA, Ellis E. Surgical treatment of adult mandibular condylar fractures provides better outcomes than closed treatment: a systematic review and meta-analysis. J Oral Maxillofac Surg 2015;73:482–493.

Bak M, Jacobson AS, Buchbinder D, et al. Contemporary reconstruction of the mandible. Oral Oncol 2010;46(2):71–76.

Barrett DM, Halbert TW, Fiorillo CE, et al. Cost-based decision analysis of postreduction imaging in the management of mandibular fractures. JAMA Fac Plast Surg 2015;17(1):28–32.

Bell RB. Contemporary management of mandibular fractures. In: Miloro M, Ghali GE, Larsen P, Waite P, editors. Peterson's Principles of Oral and Maxillofacial Surgery. People's Medical Publishing House; 2012. p. 407–443.

Ceallaigh PO, Ekanayake K, Beirne CJ, et al. Diagnosis and management of common maxillofacial injuries in the emergency department. Part 2: mandibular fractures. Emg Med J 2007;23(12):927–928.

Classen DC, Evans RS, Pestotnik SL, et al. The timing of prophylactic administration of antibiotics and the risk of surgical-wound infection. N Engl J Med 1992;326(5):281–286.

Devireddy SK, Kishore Kumar RV, Gali R, et al. Transoral versus extraoral approach for mandibular angle fractures: a comparative study. Ind J Plast Surg 2014;47(3):354–361.

Ruggiero SL. Diagnosis and management of dentoalveolar fractures. In: Fonseca R, Marciani R, Turvey T, editors. Oral and Maxillofacial Surgery, vol. II. St. Louis, MO: Elsevier; 2009. p. 139–161.

Du SQ, Rinchuse DJ, Zullo TG, et al. Reliability of three methods of occlusion classification. Am J Orthod Dentofacial Orthop 1998;113(4):463–470.

Ellis E. An algorithm for the treatment of noncondylar mandibular fractures. J Oral Maxillofac Surg 2014;72(5):939–949.

Ellis E. Open reduction and internal fixation of combined angle and body/symphysis fractures of the mandible: how much fixation is enough? J Oral Maxillofac Surg 2013;71:726–733.

Ellis E, Price C. Treatment protocol for fractures of the atrophic mandible. J Oral Maxillofac Surg 2008;66:421–435.

Gelesko S, Markiewicz MR, Bell RB. Responsible and prudent imaging in the diagnosis and management of facial fractures. Oral Maxillofac Surg Clin North Am 2013;25(4):545–560.

Halpern LR, Kaban LB, Dodson TB. Perioperative neurosensory changes associated with treatment of mandibular fractures. J Oral Maxillofac Surg 2004;62(5):576–581.

Koshy JC, Feldman EM, Chike-Obi CJ, et al. Pearls of mandibular trauma management. Semin Plast Surg 2010;24(4):357–372.

Miles BA, Potter JK, Ellis E. The efficacy of post operative antibiotic regimens in the open treatment of mandibular fractures: a prospective randomized trial. J Oral Maxillofac Surg 2006;64(4):576–582.

Patel AA, Karlis V. Chapter 33: Principles of fixation for maxillofacial trauma. Pocket Dentistry 2015. Available at http://pocketdentistry.com/33-principles-of-fixation-for-maxillofacial-trauma/#s0025.

Shetty V, McBrearty D, Fourney M, et al. Fracture line stability as a function of the internal fixation system: an in vitro comparison using a mandibular angle fracture model. J Oral Maxillofac Surg 1995;53(7):791–801.

Wittwer G, Adeye WL, Turhani D, et al. Treatment of atrophic mandibular fractures based on the degree of atrophy-experience with different plating systems: a retrospective study. J Oral Maxillofac Surg 2006;64(2):230–234.

186 Fractures of the Cranio-Orbital and Midfacial Skeleton

Bernard J. Costello

INTRODUCTION

Injuries to the upper and middle facial skeleton occur regularly due to a variety of blunt and penetrating etiologies and often require operative intervention.[1–4] Understanding the patterns of injury, diagnosis, treatment, and management of complications are important for any surgeon working in the craniomaxillofacial region to understand.

Into this chapter I review the primary restoration of function and form of bony injuries to the cranio-orbital and midface region. Common injuries to the frontal sinus, orbits, and midface are reviewed. Injuries to the nose, ocular region, and dentoalveolar tooth structures are addressed elsewhere in this book.

KEY OPERATIVE LEARNING POINTS

1. The primary goal of the treatment of facial injury is the restoration of form and function to the pre-injury state, including the proper projection, width, and height of the craniomaxillofacial complex.[5]
2. An accurate diagnosis of the extent of facial injuries is dependent upon a detailed history and physical examination and quality imaging.
3. Understanding the biomechanics involved in each area of concern helps the surgeon make appropriate fixation choices and accomplish reduction of the fractures with adequate stabilization.
4. A high level of skill helps achieve appropriate fixation and a clear understanding of the fixation devices, and all the accompanying armamentaria are necessary to achieve superior results.
5. Maxillary fractures that involve occlusion require a detailed understanding of occlusion and common malocclusions.

PREOPERATIVE PERIOD

History

1. History of present illness
   a. A detailed history of the mechanism(s) of injury clarifies the extent of injury and the potential for secondary injuries to other structures or body systems. The history of the injury may need to be obtained from friends or family.
   b. Advanced trauma life support (ATLS) protocols should guide the evaluation of the injured patient.
   c. The potential for head injury should not be ignored, particularly in those who have a loss of consciousness. Concussion should be considered in the differential diagnosis after significant injury to the head and neck region and concussion protocol initiated.
   d. A history of previous facial injury or facial dysplasia/deformity is important when understanding the extent of injury and the precise goals for reconstruction.

Physical Examination

1. A full examination of the head and neck is performed to identify any soft tissue, bone, or visceral injuries. Particular attention is given to specialized structures such as the brain, cranial nerves, globe, lacrimal system, and other important anatomic structures that may have been injured in conjunction with facial injuries.
2. A complete ophthalmologic examination is helpful when injuries are apparent in the region. At times, a skilled Ophthalmologist may help in performing additional specialized examinations of the cornea, retina, globe integrity and position, or lacrimal system.
3. A detailed neurologic examination can clarify the extent of injury to the brain and spinal cord and may help not only in the primary assessment but also during follow-up. Preoperative assessments using concussion evaluation tools such as the IMPACT assessment tool can clarify functional deficits in cognition.
4. After eliciting a historical understanding of the patient's occlusion, a detailed evaluation of the bite, excursions, maximal opening, and deviation is essential to understand maxillary fractures and their involvement with adjacent areas such as the injured or uninjured mandible.

Imaging

1. Only select injuries with little or no chance of concomitant injuries are treated by physical examination without imaging, such as the isolated nasal fracture. However, most other facial injuries are evaluated using a high-quality spiral computed tomography (CT) formatted in axial, sagittal, coronal, and three-dimensional views. Performing these scans in a manner consistent with navigation and computer-assisted surgery protocols with files saved in digital imaging and communications in medicine (DICOM) format is helpful, and additional technology may be used. CT angiography is helpful for larger caliber vessels, but it is still inadequate for imaging of the smaller vasculature in most areas of the craniomaxillofacial region.
2. Rarely, interventional radiologic techniques can be helpful for treating bleeding vessels that cannot be addressed through typical surgical exposures. Traumatic arterial dissections or bleeding arteries at the cranial base may be addressed with interventional techniques using superselective embolization or other methods.

Indications

1. Displacement of the cranio-orbital or midface bones that cause either aesthetic imbalance and/or functional impairment such as a blocked naso-lacrimal system, diplopia, ocular muscle entrapment, or malocclusion
2. Decision making regarding the timing of operative intervention is typically regarded as most effective in the early

phase of healing. Delayed repair can be associated with increases in infection rates and difficulty with accurate reduction of fragments due to early remodeling.
3. There are many approaches to the cranio-orbital and midface regions, and each presentation requires a customized approach based on complexity and the need for exposure to achieve accurate reduction and fixation. There is significant variability in surgical techniques for each of these procedures.[1,2] The most common examples are described as follows.

Contraindications

1. Medical and/or traumatic comorbidities with increased risk for general anesthesia
2. Significant uncorrected bleeding disorder or nutritional deficiency that would increase risk for complication with wound healing
3. Critical injury to the brain or other structures that would be worsened with an open procedure in the region
4. Critical injury to the globe or optic nerve that would be worsened with manipulation of the contents of the orbit or surrounding region

Preoperative Preparation

1. Discontinue antiplatelet drugs or other medications that affect the ability to mount a clotting response, if possible.
2. Optimize hemodynamics.
3. Evaluation of the cervical spine to avoid worsening an existing injury and stabilization if necessary
4. Consider a staged approach if panfacial fractures are present to allow for reimaging and re-assessment.
5. Consider the use of navigation or intraoperative CT to ensure that the proper equipment is available and that positioning can accommodate the technique desired.
6. Blood products may be considered if extensive fractures requiring complex, lengthy approaches are required.
7. Patients should be counseled on postoperative care including pain management, dietary and activity restrictions, and possible need for secondary revision procedures.

OPERATIVE PERIOD

Anesthesia

1. General: These procedures are routinely performed under general anesthesia with the patient orotracheally or nasotracheally intubated. Occasionally, a tracheostomy is needed for airway management. Often, swelling limited to the face does not impact airway dynamics significantly and is manageable without the use of a tracheosotomy. The decision to manage the occlusion is typically the key variable when considering oral versus another route of intubation.
2. Selective hypotension is helpful to avoid excessive blood loss.

Positioning

- Supine with full access to the head
- If intraoperative navigation or CT is planned, then positioning of the patient and the operating room must accommodate these techniques properly.
- A horseshoe-ring headrest can be used for more complete access to the skull.
- A shoulder roll is often helpful for slight extension of the neck if cervical spine injury has been ruled out.

Perioperative Antibiotic Prophylaxis

- Cephalexin or similar spectrum antibiotic prior to incision
- Clindamycin is used if the patient is allergic to penicillin.

Monitoring

- Consider an arterial line for long procedures and extensive reconstructions.

Instruments and Equipment to Have Available

1. Marking pen, sterile pencil, and/or cotton-tipped applicator and marking solution
2. Corneal protectors with lubrication
3. 0.5% Lidocaine with 1:200,000 epinephrine used at less than a maximum dosage
4. Cranio-orbital instrumentation with a variety of straight and curved periosteal elevators, intra-orbital instruments for retraction of the contents such as malleable retractors
5. Obwegeser retractors of various sizes
6. 10, 15, or 15c blade with long handle
7. Angled beaver blade
8. Absorbable suture, such as fast absorbing gut, polyglycolate, chromic, of various sizes
9. Bipolar and monopolar electrocautery with insulated small needle-point tip
10. Optional scalp clips for bi-coronal approaches
11. Bone wax
12. Small titanium plates and screws. Resorbable options can be considered, but they are typically reserved for growing individuals or those where revision is likely.
13. Maxillomandibular fixation (MMF) instrumentation for setting the bite such as MMF screws, arch bars, or commercially available MMF screw-based systems
14. Craniomaxillofacial fixation system that includes sizes from approximately 1.0- to 2.5-mm diameter screws with accompanying plates

Key Anatomic Landmarks

Coronal Approaches (Fig. 186.1)

- Facial nerve location within the superficial and deep layers of the superficial temporal fascia
- Supraorbital rim
- Supraorbital neurovascular bundle
- Medial canthal ligament attachments
- Zygomaticofrontal (ZF) suture

Orbital Approaches (Fig. 186.2)

- Deep fornix incision made behind the orbital septum and into adipose tissue
- Lacrimal sac and posterior lacrimal fossa medial and Horner's muscle divided medially for a transcarruncular incision
- Inferior limb of the canthal suspension system divided from the attachment superiorly near Whitnall's tubercle for additional orbital exposure
- Lacrimal duct locations for intubation with Crawford tubes

Maxillary Approach

- Mucogingival junction
- Maxillary buttresses at the zygoma and piriform rims
- Infraorbital nerve and foramen
- Parotid duct
- Piriform rims and zygomatic buttresses

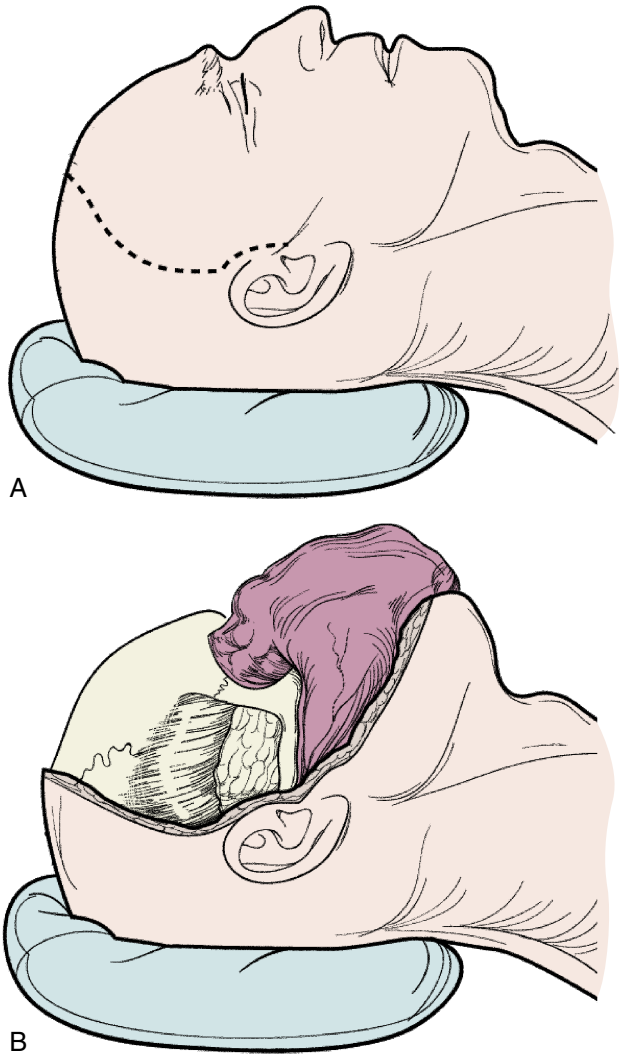

Fig. 186.1. Coronal flap incision with or without approach to the temporomandibular joint. A, A wavy line or sine-wave incision is made with the incision placed more posterior for better aesthetics. Another option can include a posterior-auricular incision for even better aesthetics when access to the joint is less important. Either approach can be used for access to the zygomatic arch. **B,** The dissection is carried deep to the superficial layer of the superficial temporal fascia until about 1 cm above the arch within the temporal adipose tissue pad. Dissecting deep to this layer helps avoid injury to the facial nerve, particularly the frontal branch. When combined with a dissection that proceeds along the nasal bones and anterior orbital rims, 360 degrees of the orbit can be visualized when using this approach.

Prerequisite Skills

1. Detailed understanding of the anatomy of the cranio-orbital complex
2. Training in general trauma care and emergent airway management
3. Training in diagnosis and surgical repair of craniofacial conditions
4. Technical skill using internal fixation techniques such as plate and screw systems
5. Detailed understanding of normal occlusion and common pre-existing malocclusions
6. Experience with surgery in the region including cranio-orbital, peri-orbital, oral cavity, and oropharynx
7. Access and ability to work with other surgeons to address common concomitant injuries to the brain, eye, and dentition

Operative Risks

1. Early complications:
   a. Bleeding
   b. Intracranial bleeding
   c. Wound breakdown/partial dehiscence
   d. Facial nerve injury
   e. Malocclusion
   f. Vision abnormalities (diplopia, blindness, blurry vision)
2. Late complications:
   a. Periorbital scarring (entropion, ectropion)
   b. Temporal wasting with contour irregularities
   c. Enophthalmos
   d. Infection
   e. Malocclusion
   f. Dental injury
   g. Malunion

Surgical Technique

The following surgical technique section includes steps common to cranio-orbital and midface fracture treatment procedures followed by particular steps that are specific to each individual procedure.

For All Procedures

- Intubation with oral ring-adair-elwyn (RAE) endotracheal, nasal straight, nasal RAE (ET) tube, or tracheostomy. I do not favor submental intubation approaches, and I avoid tracheostomy when possible.
- Place patient supine with the neck slightly extended with a shoulder roll.

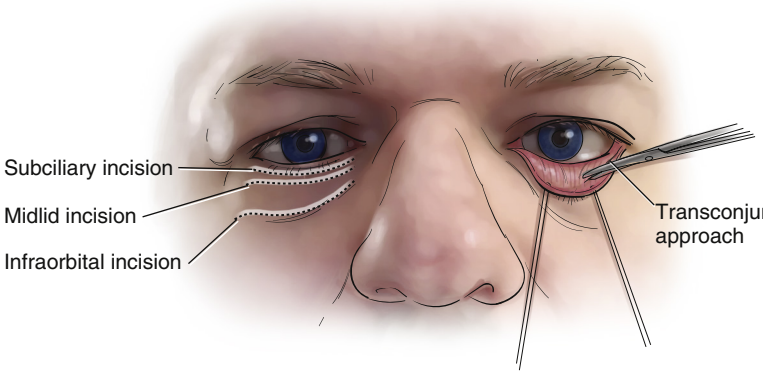

Fig. 186.2. Multiple options for eyelid incisions are shown including the transconjunctival, subcilliary, midlid, and infraorbital incision. *(With permission from Fonseca R, Barber HD, Powers M, et al. Fonseca's Oral and Maxillofacial Trauma, 4th ed. Philadelphia: Saunders; 2013.)*

- Eye protection may be helpful with corneal protectors and eye lubrication or other means.
- Prep face with betadine and brush oral cavity with chlorhexidine gluconate oral rinse.
- Incisions may be marked with a marking pen or the wooden handle of a cotton-tipped applicator dipped in gentian violet or methylene blue. Osteotomies can be marked with a sterile pencil when needed.
- Proposed incisions may be injected with lidocaine and epinephrine in a subdermal, submucosal, and subperiosteal plane, avoiding direct injection to the neurovascular bundles. Subperiosteal injection can aid in hemostasis and facilitate undermining of the mucoperiosteal flaps.
- A marked throat pack may be used to block secretions from entering the gastrointestinal (GI) tract. It should be announced during placement and removal.
- Selective hypotension may be provided from the anesthesia team to minimize blood loss. For simple fractures, an arterial line is often not needed and transfusion is rare. However, for extensive facial fractures with many approaches, these monitoring methods and blood products may be helpful.
- At times, it may be helpful to consider navigation or intraoperative CT to judge effective reduction and reconstruction. Staged procedures can also allow for additional imaging and adjustments of the three-dimensional position of segments if extensive fractures are present.
- At the finish of the procedure, an oral-gastric suction tube is passed to suction the stomach.

Cranio-Orbital Fractures (Figs. 186.3A to M)

- Marking the incision on the scalp is performed in a sine wave or saw-tooth pattern, preferably in a slightly posterior auricular location, unless access is required to the temporomandibular joint.
- A strip can be shaved to allow for the incision to be made, and the hair is washed and prepped in betadine solution. Detergents should be avoided, as they may harm the eyes.
- The incision can be made with a #10 blade or needlepoint bovie on a low setting with hemostasis controlled throughout. I prefer not to use scalp clips, but these are an option.
- Double skin hooks are used to advance the flap in the supraperiosteal plane, just superficial to the deep layer of the superficial temporal fascia over the temporalis musculature. In the central region, the flap is advanced anteriorly just superficial to the periosteum up to the supraorbital ridge.
- A large pericranial flap can be advanced medial to the temporal ridges from posterior to anterior and kept moist throughout the procedure for use in the anterior cranial base as needed.
- A subperiosteal dissection is performed laterally over the edge of the lateral orbital bones, centrally over the nasal bones, and around the orbital tissues superiorly. Osteotomes can be used to mobilize the bone housing the supraorbital neurovascular bundle to gain more flap mobility.
- Medial orbital dissection is done carefully to avoid detaching the medial canthi if they are still intact. If detached from their normal insertions, then a small fragment of bone can almost always be identified.
- Medial canthal attachments can be located by using an Adson forceps with teeth externally at the canthal attachment and flipping the coronal flap inferiorly to then locate the forceps through the tissue. It can then be isolated by suturing it with a 4-0 non-resorbable braided suture. Canthal re-attachment may then occur using a trans-nasal wiring technique.
- Lateral canthal attachments can also be repositioned with a similar technique using pilot holes drilled in the approximate vector of Whitnall's tubercle.
- If the posterior table of the frontal sinus is fractured, displaced, and involves the drainage system inferiorly, then cranialization of the sinus after removal of all mucosa is performed.
- Tears in the dura at the anterior cranial base should be repaired to avoid a chronic leak of cerebrospinal fluid and potential retrograde infection. Endoscopic repairs of small leaks can be considered if an open approach is not needed.
- Anterior table fractures can simply be reduced. Rarely, internal endoscopic balloon techniques can be effective for a localized fracture that is intruded.
- I do not favor obliteration techniques, as these can lead to chronic inflammation in the sinus. Nonresorbable calcium phosphate materials should be avoided in this area.
- Craniofacial bones, including the frontal sinus, can then be reduced and plated. Appropriate three-dimensional positioning of the zygoma, superior orbital rims, and nasal bones is critical to providing the appropriate width, height, and projection of the face. The positioning of the maxilla often depends upon the position of the upper facial skeleton.
- Naso-orbital-ethmoid fractures must be completely reduced and medial cathi re-attached in an appropriate dimension to avoid telecanthus. Trans-nasal wiring secured to a contralateral plate is helpful in achieving proper dimensions.
- Access to the zygoma and nasal bones is also available via this approach. The arch is dissected out separately as needed, making the incision approximately 1 cm superior to the arch into the deep layer of the superficial fascia or adipose tissue pad.
- The bicoronal incision is closed with 2-0 resorbable braided suture using inverted knots in an interrupted fashion. The skin may be closed with staples, running 4-0 monofilament or 4-0 resorbable braided suture.

Zygoma (Figs. 186.4 and 186.5)

- Zygoma fractures are not tripod fractures but articulate at the ZF suture, infraorbital foramen/notch, zygomatic arch, zygomatic buttress, and the greater sphenoid wing. Each articulation point must be adequately reduced prior to fixation.
- Fixation can be fairly minimal, as there is not much force placed on the zygoma. While fixation points at the ZF suture, zygomatic buttress, and infraorbital rim areas are often used, less fixation can often be acceptable.
- The approaches used need to keep accurate reduction and adequate fixation in mind. Often, limited approaches give a limited view of the adequacy of reduction in three dimensions.
- Approaches may include brow, upper eyelid, coronal, maxillary vestibular, and various lower-eyelid approaches.
- Fixation devices used to secure fractures can typically be very small, and a low-profile plating system is preferred in areas that have minimal soft tissue coverage such as the ZF suture area and infraorbital rim.
- While the orbit is involved in most zygoma fractures, it does not always require reconstruction of the floor. After reduction, if the defect is small and not in a critical area where volume loss can occur, then a reconstruction of the floor may not be necessary. Critical areas where volume loss may occur include the bulge in the floor of the orbit and the medial bulge of the medial wall. Enophthalmos can occur if these fractures are not reduced.

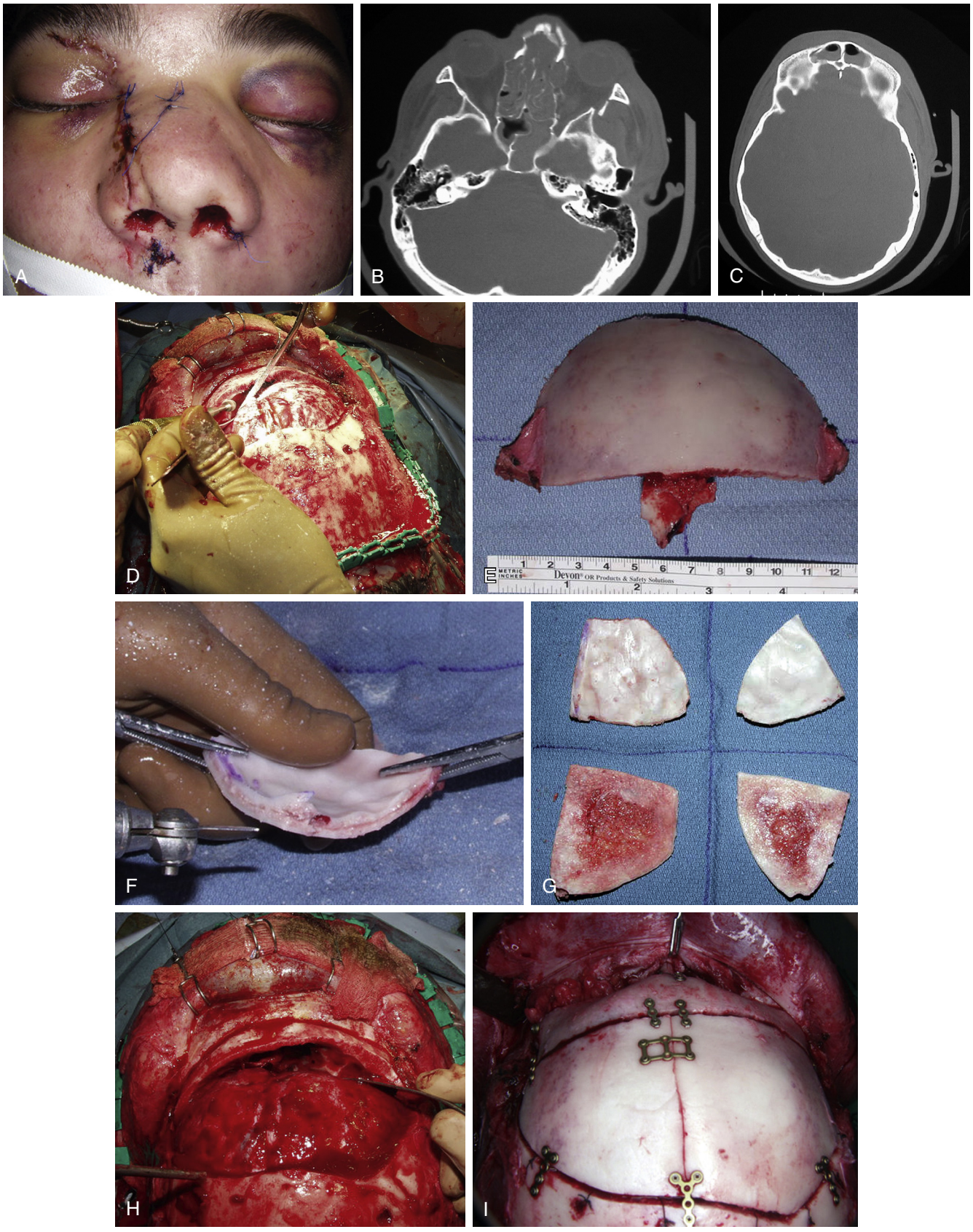

Fig. 186.3, Cont'd

Continued

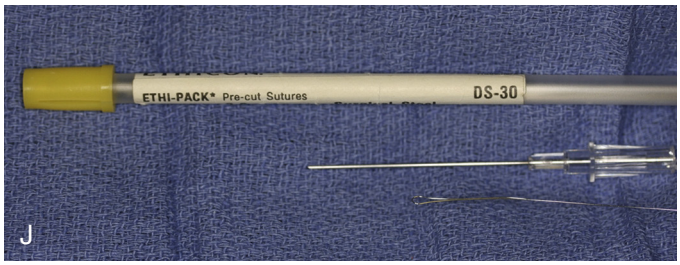







Fig. 186.3. A–C, A young male with telecanthus after sustaining cranial and midface injuries including a posterior cranial vault fracture, Type III naso-orbital-ethmoid fractures, orbital floor fractures, and a Le Fort II fracture. **D,** A transcranial approach was required via bicoronal incision and bifrontal craniotomy with removal of the posterior wall of the frontal sinus. All the mucosa of the frontal sinus was removed. **E–J,** Split-thickness cranial vault bone was used for reconstruction of the orbits and other areas. Transnasal wiring was used to reattach the medial canthal ligaments. **K,** The patient had a pre-existing malocclusion consisting of an open bite, which was recognized due to developmental mammelons on the incisors and a pre-injury plan for orthognathic surgery. **L–M,** Despite an elevated intracranial pressure, the patient recovered with the need for only minor nasal cartilage revision and rhinoplasty due to lacerations associated with the nose.

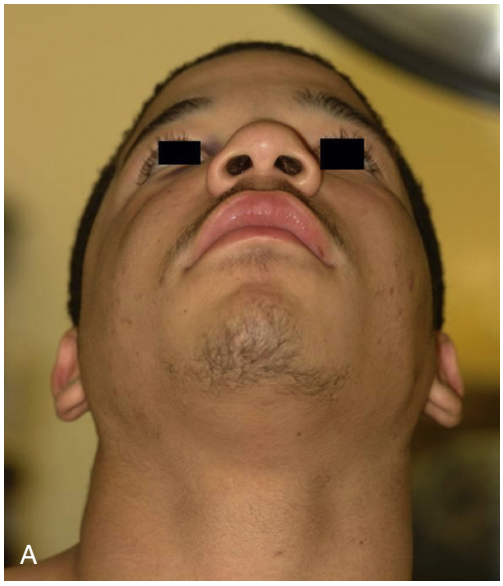

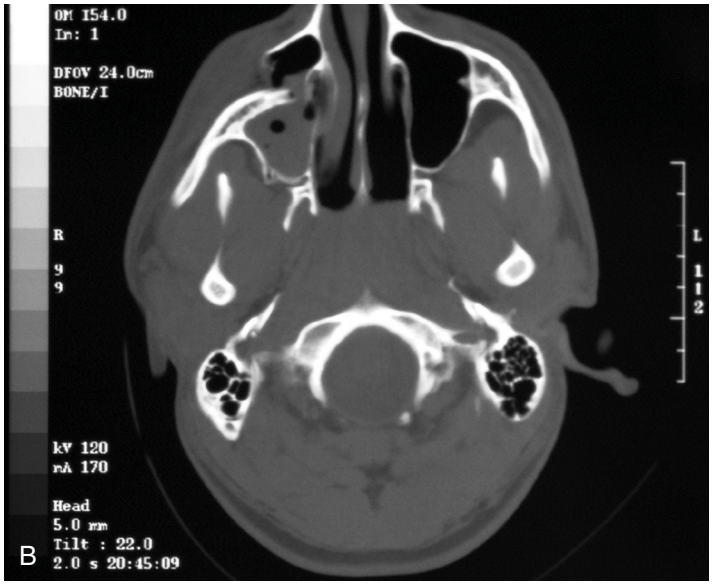

Fig. 186.4. A, A young male who sustained a left fist to the face resulting in a fractured zygoma with medial displacement. **B,** The computed tomography scan shows the typical displacement that requires three-dimensional repositioning via multiple incisions. Brow, intra-oral, and transconjunctival incisions are often used to position and fixate fractures such as these.

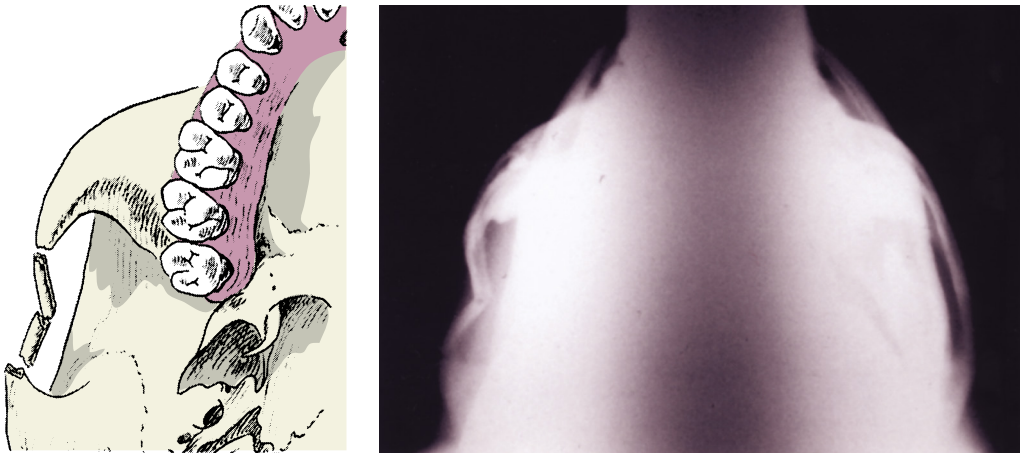

Fig. 186.5. The isolated zygomatic arch fracture is typically found in two or more fragments, requiring a repair that is more of a flat surface than an actual arch.

Orbit (Fig. 186.6)

- The orbital approach is dependent upon the location of the fractures that require reconstruction. Lower-lid approaches such as the deep fornix trans-conjunctival with or without inferior lateral cantholysis, subcilliary, or lid crease incisions can be used depending upon the need for access, existing lacerations, or preferences.[4]
- If a medial wall approach is needed, a trans-caruncular approach may be considered.
- Orbital roof fractures can be approached via a coronal incision, brow, or eyelid incision.
- Fractures of the orbital rim should be reconstructed prior to the interior wall reconstruction. Very small plates and screws are used to avoid a high profile that is palpable through the thin tissues around the eye.
- For reconstructions of the orbital wall, a subperiosteal dissection is used to get just beyond the fracture dimensions, and a substitute material is used for reconstruction. Larger defects benefit from more support with materials that retain a specific shape, such as porous polyethylene with imbedded mesh. Preformed plates are also available in a few standard sizes.
- Custom implants can be fabricated using the patient's CT scan, but this can be expensive.
- The use of navigation as a guide to placement of the reconstructive material and/or the use of intraoperative CT can be helpful in avoiding the need for return trips to the operating room for adjustment.
- When disrupted, it is important to reconstruct the inferior and medial bulges to avoid volume changes that can lead to enophthalmos. These are best reconstructed with preformed or customized reconstructive implants.
- Resorbable materials are not recommended for larger defects, as they eventually resorb and leave a defect in areas that require support.
- If a lateral cantholysis is performed, then the inferior leaflet must be repositioned back to the periosteum and upper leaflet of the suspension system, or an excessively round appearance can occur at the lateral eyelid commissure.
- Transconjunctival incisions do not require a closure with suture, but very small resorbable monofilament suture can be considered. Some surgeons place a small drain in the floor of the orbit to avoid the formation of a hematoma.
- Skin incisions can be closed with 6-0 fast-absorbing suture.
- A Frost suture can be placed to support the eyelid by taping this lower lid suspension suture to the forehead, allowing for access in the early postoperative period to examine the eye.

Le Fort (Fig. 186.7)

- At the beginning of the twentieth century, Rene Le Fort was the first to document a tendency for the occurrence of specific patterns of midface fractures after direct facial trauma.[3] The Le Fort I fracture is a horizontal fracture of the midmaxilla just above the teeth and alveolar bone. The Le Fort II fracture is a pyramidal shaped fracture in the central portion of the face with the base being the maxilla and the apex at the nasofrontal junction. The Le Fort III fracture is a craniofacial dysjunction in which the facial skeleton completely separates from the skull base.
- These fractures often occur due to significant force and may involve displacement of the bones posteriorly and/or superiorly, yielding an "impaction" of the maxilla. When reducing these fractures, it is important to mobilize them back to the proper projection. Maxillary disimpaction forceps can be used for this maneuver.
- The mandibular occlusion can be used as a guide. If multiple facial fractures have occurred and the maxilla is in several fragments, then the mandible is usually reconstructed to its original three-dimensional form. The occlusion is the guide that then can help position the maxilla properly.
- A vestibular incision from the first molar area to an equal point contralaterally is placed approximately 5 to 7 mm above the mucogingival junction. This allows for proper closure later and a good vascular pedicle to anterior maxillary segments.
- A subperiosteal dissection is used to expose the anterior and lateral aspects of the maxilla. Exposure to the infraorbital rims is possible. It is often helpful to expose the anterior nasal floor and interior piriform rim to help align the segments for fixation.
- Incisions of the palate are to be avoided, as this is generally one of the main vascular supplies to the maxillary and alveolar bone. Plating is not recommended in the palatal region, as the tissue is thin in most areas causing plates and screws to become exposed and/or infected.
- Patients are typically placed into MMF with wires between the teeth and jaws, followed by open reduction and fixation of the fractures utilizing small plates and screws. Once

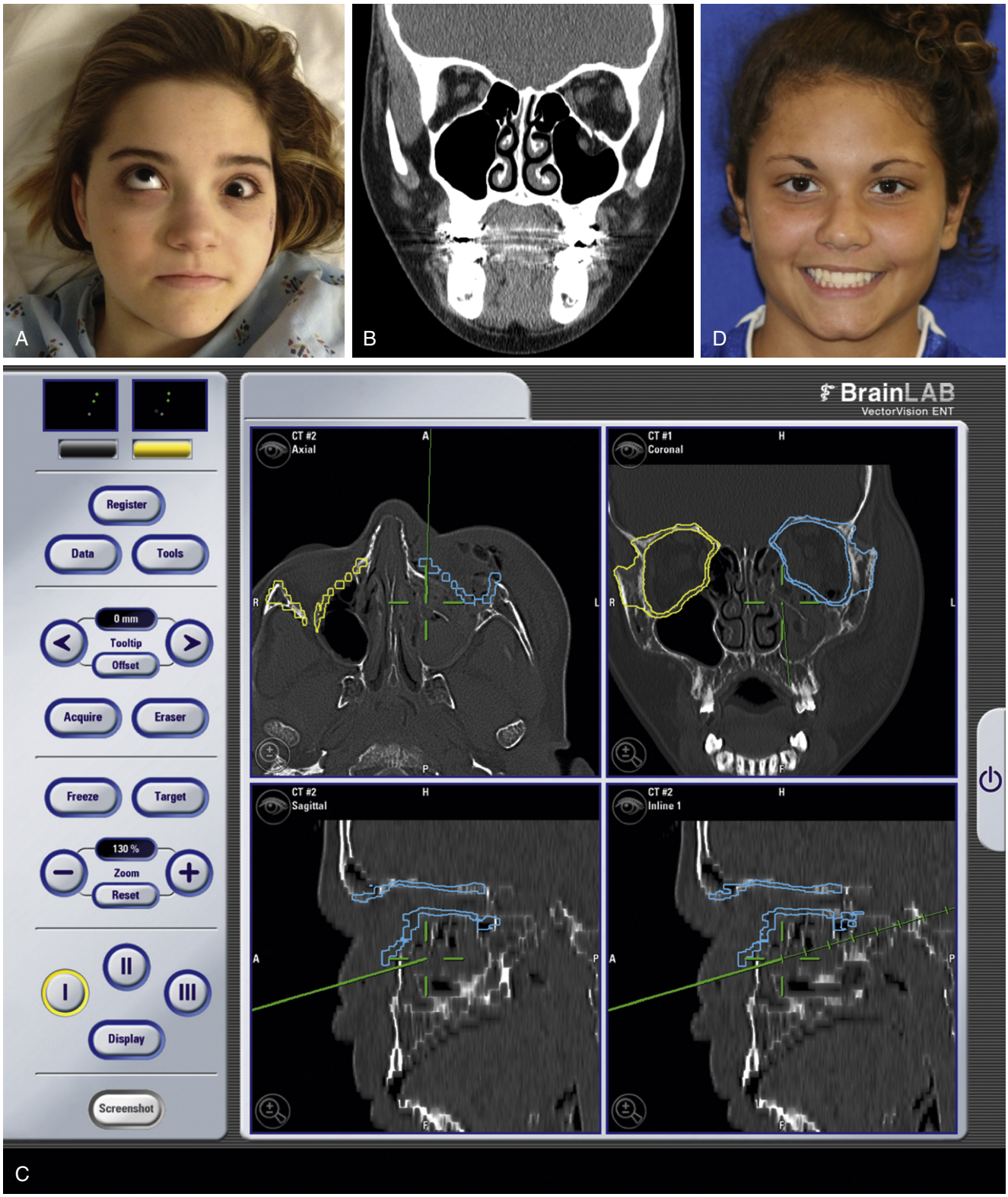

Fig. 186.6. A, The classic clinical appearance of an emergent trap door fracture in a young girl with entrapment. She also exhibits bradycardia and nausea on upward gaze. **B,** A coronal computed tomography scan shows entrapment of periorbita and inferior rectus. **C,** Navigation and mirroring technology can be used to help position an orbital implant into a defect once the periorbita has been released. **D,** If done in a timely fashion, the patient's range of motion and position of the globe can be restored to the pre-injury state.

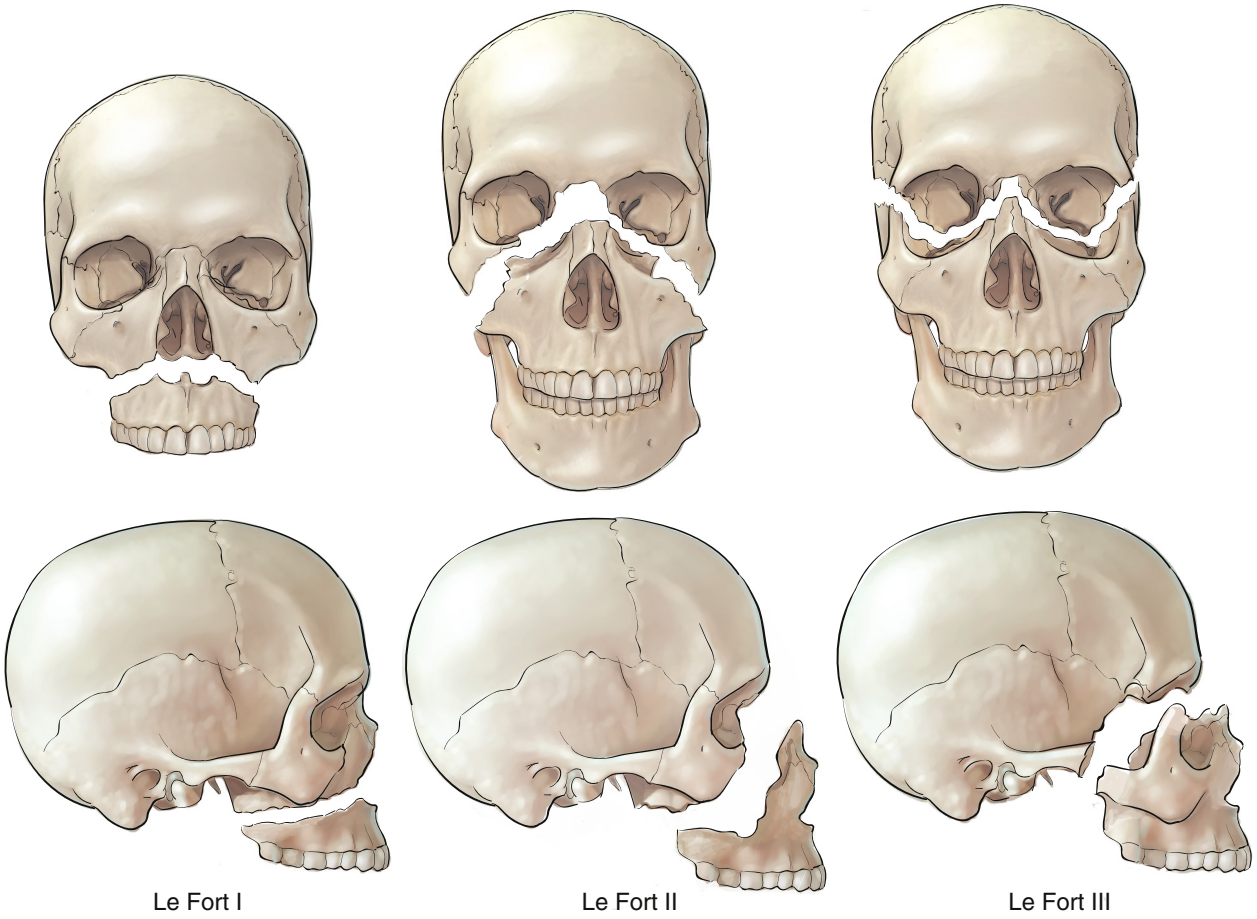

Fig. 186.7. The anterior and lateral views of the Le Fort midface fracture classification are shown highlighting the involvement of the various structures of the midface. *(With permission from Fonseca R, Barber HD, Powers M, et al. Fonseca's Oral and Maxillofacial Trauma, 4th ed. Philadelphia: Saunders; 2013.)*

reduced, the MMF can be removed at the end of the procedure. Palatal fractures are managed effectively with dental or palatal splints. Custom splints can be made of acrylic using dental models, but they can also be fashioned quickly from perforated thermoplastic splint material.

- Internal fixation is the treatment of choice for mobile maxillary fractures. Wiring the teeth together with MMF alone causes the mandible to pull down the mobile maxilla under function and potentially create a non-union. As such, plating systems are often used at the four anterior buttresses of the maxilla to provide fixation. These include the piriform rims and zygomatic buttresses. Thick bone usually exists for placement of monocortical screws of medium size.
- If other upper facial fractures exist, it is important to also set the facial width, projection, and height properly when placing the maxilla in its proper position. Many surgeons use an outside-in approach, by which the mandible and upper cranio-orbital skeleton are reconstructed prior to the maxilla when pan-facial fractures occur.
- The vestibular incision is closed with 3-0 chromic or Vicryl suture.

Common Errors in Technique

1. Failure to achieve adequate three-dimensional reconstruction of fractures prior to fixation or placement of reconstructive implants
2. Dissecting the coronal incision too superficial in the anterior area of the superficial temporal fascia layers may cause frontal nerve branch weakness.
3. Dissecting the coronal incision too deep in the anterior area of the superficial temporal fascia layers into the muscle, causing muscle wasting and a lateral aesthetic defect in the temporal region. Trismus can also occur due to scarring of the temporalis muscle.
4. Complete reconstruction of the eyelid suspension system, resulting in a rounded appearance to the eyelid
5. Incomplete repositioning of the canthi resulting in traumatic telecanthus or poorly suspended eyelids
6. Failure to achieve a stable and repeatable occlusion. This can be difficult to achieve in patients with pre-existing malocclusions.
7. Failure to integrate dento-alveolar fracture treatment with the repositioning of the maxilla and/or mandible when reestablishing the occlusion
8. Failure to refer to a dental specialist for dental injuries either during the initial reconstructive phase or soon thereafter

POSTOPERATIVE PERIOD

Postoperative Management

1. Admit for observation in many cases involving intraorbital surgery. Intensive care may be needed for patients undergoing craniotomies for exposure to cranial base fractures or

extended procedures with significant blood loss or volume shifts.
2. Drains are placed to bulb suction in the scalp and can be removed when fluid collection has decreased markedly.
3. For patients who have had maxillary fractures, a smooth liquid diet is used for at least several weeks. In patients with solid fixation, soft food can be introduced within several weeks. Chewing is to be avoided until adequate bone healing occurs. In many patients with mobile fractures, this may take 6 to 8 weeks.
4. Antibiotics for 7 days postoperative (optional)
5. Facial sutures may be removed at 5 to 7 days when resorbable sutures are not used.
6. Follow up in 1 to 2 weeks

Complications

1. Postoperative nasal/oral bleeding may stop spontaneously if mild or with oxymetazoline spray for nasal bleeding. If persistent, it may require a return to the operating room for control.
2. Cerebrospinal fluid leak due to a persistent fistula or breach at the cranial base into the sinonasal region. Many small leaks can be repaired using an endoscopic approach with or without navigation. Others may require an open approach with pericranial flap placement or other techniques to block the leak. In some cases, a lumbar drain can be placed to change differential pressure for very small leaks. The outcome data on this approach are not clear, but it is occasionally employed as a conservative measure.
3. Acute intraorbital bleeding and/or intra-orbital/retrobulbar hematoma. This may cause the emergent need for decompression at the bedside and/or in the operating room with a lateral canthotomy and release of the hematoma. A drain can be placed at the time of surgery to help avoid this complication.
4. Eyelid scarring causing ectropion or entropion. This can occur with damage to the soft tissue of the eyelids. Secondary reconstruction may be needed to gain adequate coverage of the globe and cornea if this is severe.
5. Enophthalmos due to incomplete reconstruction of the floor or wall of the orbit
6. Malocclusion due to inadequate positioning of bony segments. This may require return to the operating room to reestablish a proper occlusion. Malunions discovered late may require osteotomies, orthognathic surgery, and/or orthodontic therapy to resolve imbalances in the occlusion. Malunions of the zygoma can be masked with an onlay implant or more ideally treated with a zygomatic repositioning osteotomy.
7. Nonunions of the midface are very rare but most often occur at the lower Le Fort level and involve the occlusion. They usually involve overfunction immediately after the initial repair.
8. Infections can occur and usually require antibiotics and sometimes drainage procedures. Plates and screws should be replaced during active healing or removed if the infection occurs after initial healing.

Alternative Management Plan

1. Patients with minimally displaced fractures and a stable occlusion without mobility of the maxilla can be placed on a liquid diet to avoid an operation if they are unable to tolerate it medically or wish to avoid a procedure. Ideal repositioning may not occur if this approach is used. As such, aesthetic and/or functional consequences may occur.

DISCUSSION

Evidence-Based Medicine Question

Which eyelid incision is associated with the least complications?

Data in this area are not strong enough to make definitive statements regarding which incision may be best. Much of the data are self-reported and have inherent bias associated with the study designs. That being said, many surgeons quote an eyelid scarring complication rate such as ectropion, lid lag, or entropion at slightly over 10%. Disruption of the orbital septum, orbicularis oculi, levators, or canthal system usually creates some lid contour irregularity. Some of these may require secondary reconstructive efforts.

Editorial Comment

The keys to achieving superior results with complex facial fractures are as follows:

1. Adequately diagnose, prepare, and then execute approaches to those fractures with proper instrumentation available.
2. Achieve a high level of proficiency with plates and screws and the techniques involved in fixation of the bones.
3. Adequately reconstruct the volume and architecture of the orbit accurately after significant fractures.
4. Understand occlusion and common malocclusions.

Bernard J. Costello

Access the review questions online at http://www.expertconsult.com

REFERENCES

1. Gruss JS, MacKinnon SE. Complex maxillary fractures: role of buttress reconstruction and immediate bone grafts. Plast Reconstr Surg 1986;78(1):9–22.
2. Manson PN, Crawley WA, Yaremchuk MJ, et al. Midface fractures: advantages of immediate extended open reduction and bone grafting. Plast Reconstr Surg 1985;76(1):1–12.
3. Le Fort R. Experimental study of fractures of the upper jaw: parts I and II. Rev Chir Paris 1901;23:208–27. 360–379.
4. Salgarelli AC, Bellini P, Landini B, Multinu A, Consolo U, et al. A comparative study of different approaches in the treatment of orbital trauma: an experience based on 274 cases. Oral Maxillofac Surg 2010 Mar;14(1):23–27. 2010.
5. Fonseca R, Barber HD, Powers M, et al. Fonseca's Oral and Maxillofacial Trauma. 4th ed. Philadelphia: Elsevier; 2012.

REVIEW QUESTIONS

1. Early complications from frontal sinus fractures include all of the following, except
   a. Contour deformity
   b. Frontal lobe injury
   c. Cerebrospinal fluid leak
   d. Mucopyocele

2. Which of the following requires immediate treatment to avoid complications?
   a. Enophthalmos
   b. Ectropion
   c. Entropion
   d. Trapdoor entrapment

3. All the following are viable immobilization techniques for mobile maxillary fractures, except
   a. Maxillomandibular fixation
   b. Skeletal suspension wires
   c. Internal fixation with titanium devices
   d. Wire osteosynthesis

187 Fractures of the Orbit

Tonya Stefko

INTRODUCTION

Because the orbit is made up in part by two of the horizontal beams of facial structure and two of the vertical buttresses, orbital fractures are common, and proper repair of such fractures is critical to restoring normal facial appearance and function. Complicating evaluation and treatment are the vital and complex structures contained within the eye and optic nerve, extraocular muscles, and the lacrimal secretory and excretory systems. Understanding the classes of fractures involving the orbit is critical to their evaluation and prediction of other possible associated injuries. These categories will suggest a systematic approach to their treatment and repair.

The bony orbit is shaped similar to a pyramid with its apex directed posteromedially (Figs. 187.1 and 187.2). The medial walls are approximately parallel, and the lateral walls diverge at approximately 90 degrees. The normal volume of an adult orbit is 30 mL. The periosteum of the orbit is also known as the periorbita, and it surrounds the orbital contents in a continuous sheet except over the various foramina and fissures.

Most fractures involving the bones of the orbit occur because of blunt trauma to the face. Penetrating trauma, such as that caused by a projectile, is less common. Consideration of the probable velocity (momentum and direction) of the inciting object will often give clues to the likely location and severity of the bony involvement. For example, true blowout fractures are frequently the result of low-velocity trauma to the orbit, such as a thrown baseball, whereas a motor vehicle collision or being struck by a baseball bat in the face (high-velocity trauma) may cause a displaced zygomaticofacial complex (ZMC) or Le Fort–type fracture.

KEY OPERATIVE LEARNING POINTS

- Most diplopia will resolve without surgical intervention; this is usually not an initial sole indication for surgery.[1]
- Clues to muscle entrapment include the age of the patient, small fracture size, severe pain on attempted duction, severe limitation of upgaze, and nausea and vomiting (Figs. 187.3 to 187.5). Traction on the inferior rectus is thought to activate the oculocardiac reflex (bradycardia, hypotension, and vomiting) and could theoretically be fatal. In addition, the muscle is compressed and quickly becomes ischemic, thereby rapidly leading to irreversible scarring and permanent diplopia.[2]

PREOPERATIVE PERIOD

Most orbital fracture repairs can be delayed for 7 to 14 days, so consideration of the status of the rest of the patient must be undertaken immediately. The usual trauma evaluation, including establishment of the airway, breathing, and circulation, is performed first. A secondary survey will then uncover less urgent issues, including facial fractures. Delayed repair allows stabilization of the patient, full evaluation of the impact of the injury, and attention to more urgent issues (e.g., decompression craniectomy). However, in some instances, fracture repair will be undertaken more urgently because of intercurrent issues, such as an intractable cerebrospinal fluid leak.

Evaluation of the severity of the fracture must include attention to the orbital contents. A basic eye examination can be performed even on a comatose patient by using a penlight and pair of toothed forceps. In most major trauma centers, an Ophthalmologist is available on call to evaluate the eye and periocular area, which is the safest way to ensure that no occult

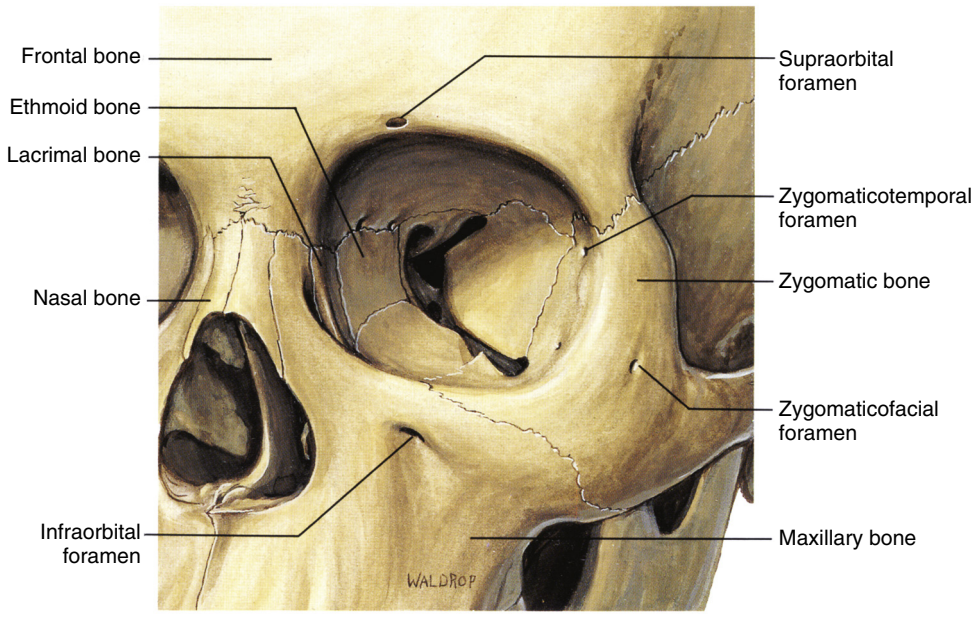

Fig. 187.1. Orbital bones, frontal view. *(From Dutton JJ. Atlas of Clinical and Surgical Orbital Anatomy. Philadelphia: WB Saunders; 1994.)*

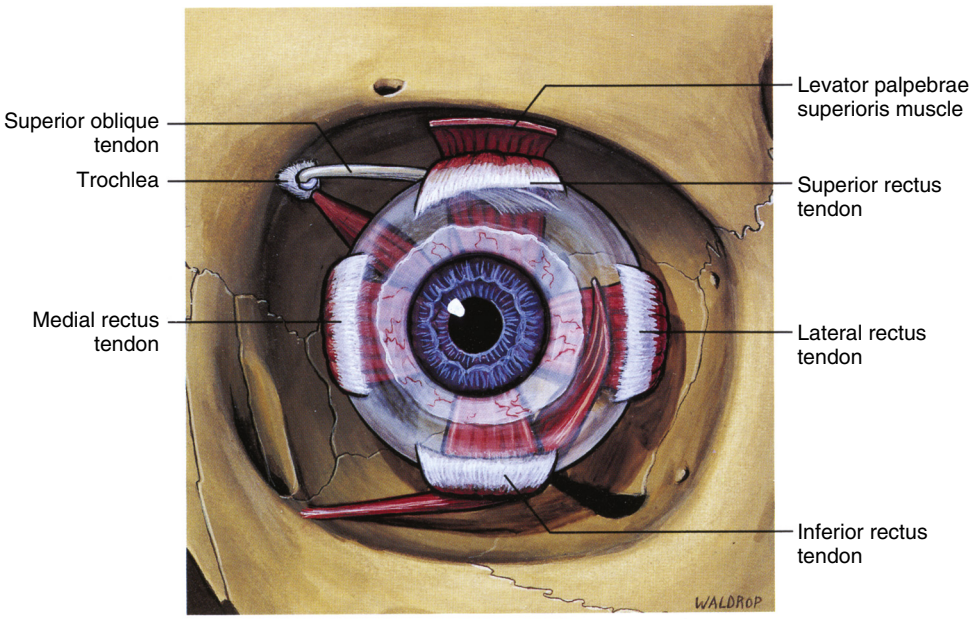

Fig. 187.2. Extraocular muscles, frontal composite view. *(From Dutton JJ. Atlas of Clinical and Surgical Orbital Anatomy. Philadelphia: WB Saunders; 1994.)*



Fig. 187.3. Patient 1: 16-year-old with a blowout fracture of the left orbit.



Fig. 187.4. Patient 1: attempted upgaze.



Fig. 187.5. Coronal scan of a trapdoor fracture of the left eye; note the "hanging drop" sign and small, nondisplaced fracture.

injury is overlooked. In other emergency rooms, the Otolaryngologist will need to at least document vision, and if possible, pupillary reactions, eye movements, and appearance of the eye.

History

- Mechanism of injury
- Previous eye/orbital surgery
- Other injuries
- Other illnesses/medications (Only in the most urgent circumstances, e.g., an entrapped extraocular muscle, should surgery be undertaken with the patient on anticoagulation.)

Physical Examination

- Vital signs
- Examination of the eye by an Ophthalmologist is strongly recommended when an orbital fracture is suspected.
- Vision (in each eye separately)
- Ductions movements of eyes in all directions volitionally, or forced, by the examiner with toothed forceps
- Enophthalmos/exophthalmos (measure with a Hertel or other exophthalmometer if possible)
- Existing lacerations, lids malposition, or scars
- Other associated soft tissue injuries

Imaging

- Fine cut orbit or maxillofacial computed tomography (CT) without contrast with coronal plane reconstruction
- Type of fracture
  - Zygomatic maxillary compound fractures (ZMC)
  - Le Fort 2/3
  - Frontal
  - Naso-orbito-ethmoidal (NOE)
  - Blowout

Force applied to the lower midface region produces variations of the classic fracture patterns described by Le Fort. Rarely do Le Fort fractures occur precisely as he described or symmetrically; however, these divisions help guide repair and provide an orderly and predictable approach. Le Fort II fractures, discussed in more detail in Chapter 122, traverse the maxillary sinus, orbital floor, medial wall, and nasal bones. Le Fort III fractures, also called craniofacial dysjunction, involve the zygomatic bones in the lateral orbital walls, the floor and medial orbital walls, and the nasal bones. Although an air-fluid level noted on CT in one maxillary sinus suggests a sinus or orbital fracture, when this sign is present in both maxillary sinuses, one must assume the presence of a Le Fort II or III fracture until careful examination has proved otherwise. All Le Fort fractures also cause some measure of malocclusion.

Application of significant force to the upper midface area can lead to telescoping nasal fractures and NOE fractures. The hallmark of these injuries is traumatic telecanthus, with the normal intercanthal distance being about 35 mm or less. Fracture lines generally travel posteriorly through the medial orbital walls. The most urgent issues with these fractures involve possible leakage of cerebrospinal fluid with associated meningitis and trauma to the brain and the possibility of involvement of the optic canals posteriorly. Careful consideration must be given to the urgent need for decompression. Repairing these fractures requires re-establishing the normal anatomic relationships of the medial canthi. These injuries are discussed further in Chapter 122.

ZMC fractures involve force directed posteriorly over the malar eminence or zygomatic arch. They were formerly referred to as "tripod" fractures, but this term is not entirely accurate, because this bone articulates in five places, even though two of the five generally do not require fixation during reduction. The characteristic facial deformity of a displaced ZMC fracture is flattening of the malar eminence, with or without apparent enophthalmos, and difficulty opening the mouth completely.

The remaining fractures involving the orbit (fractures of an orbital wall without associated rim fracture) are referred to as blowout fractures. Smith and Regan first described them in 1957 after observing a patient who had been hit in the periorbital area by a hurling ball.

- Size of fracture
  - If this is small and/or minimally displaced, surgery may not be indicated.
  - If there is a linear wall fracture, there is a risk of entrapment of an extraocular muscle or periorbita.[3]

Indications

- The first four types of fractures are covered in Chapter 122.
- Entrapped extraocular muscle mandates immediate open reduction internal fixation.
- Large (>2 cm^2) or displaced fractures should be offered repair to treat/prevent enophthalmos, NOT to prevent diplopia (which will almost always resolve on its own).

It is generally accepted that fractures involving more than 50% of the orbital floor are likely to cause later enophthalmos. Displaced fractures with an area of 2 cm^2 or greater are most significant: Approximately 1 cm^2 produces about 1 mm of enophthalmos, and at a 2 mm or greater difference in projection of the globes, an aesthetic defect is noticed. The area of the medial wall fracture must be accounted for when making this rough calculation; although the medial wall is repaired less frequently, it contributes to later enophthalmos.[4] A recent series of fractures of the orbital floor found that pediatric patients with large fractures who underwent surgery were much less likely to develop enophthalmos than their conservatively managed counterparts but that some children who presented with initial enophthalmos resolved over the following 6 months.[5] In the pediatric population, it is acceptable to defer surgery except in patients with acute enophthalmos, muscle entrapment, or vertical dystopia.[6]

Contraindications

- Systemic comorbidity
- Hyphema or traumatic optic neuropathy
  - Wait at least 5 days for hyphema to clear to prevent rebleeding.
  - Wait up to 6 months for traumatic optic neuropathy, which often improves on its own.[7]
- Frank infection in periorbital area or sinus

Preoperative Preparation

- CT scan available
- Decide what implant material to use and how/whether to fixate.

OPERATIVE PERIOD

Anesthesia

- General anesthesia by endotracheal (GETA) or laryngeal mask airway (LMA)

Positioning

- Patient supine
- Vertex at top of bed
- IV steroid bolus (8 to 12 mg dexamethasone in adult)

Perioperative Antibiotic Prophylaxis

- Cephalexin 1 g within 1 hour of incision in uncomplicated cases
- Repeat q 8 hours for total of three doses
- In situations involving a foreign body, consider adding anaerobic coverage or using clindamycin.

Monitoring

- As per anesthesia

Instruments and Equipment to Have Available

- Implant material
- Fixation system with drill if needed
- Suction (8 Fr works well)
- Needle-tipped bovie (low power)
- Des Marres vein retractors
- Corneal protective lens lubricated with ophthalmic ointment
- Toothed forceps
- Periosteal elevator (we prefer a Cottle-type)
- Ribbon retractors
- Long bipolar
- Flexible drain
- Nylon traction suture (5.0) and Steri-Strips

Key Anatomic Landmarks

- Incision is made postseptal while retracting the lid anteriorly over the rim and retracting the orbital contents with a ribbon retractor
- Isolation of the fracture site is not complete until the posterior medial ledge is cleared to allow the implant to rest on this (for floor fracture) or good support is maintained both superior and inferior (in medial wall fracture, where a small posterior portion may be left unrepaired to avoid any manipulation of the optic nerve).
- Blowout fractures usually occur medial to the infraorbital canal but sometimes lateral, and the nerve should be identified and preserved.
- The optic canal may be as anterior as 38 mm from the anterior lacrimal crest in adults and is found in the posterosuperior medial wall. The posterior ethmoid artery is between 5 and 8 mm anterior to this.
- The anterior and posterior ethmoid arteries are found at the level of the frontoethmoidal suture and should be controlled with bipolar electrocautery or clipped and divided.
- The inferior oblique muscle originates just lateral to the anterior lacrimal crest. Take care to divide the periosteum anterior to it and then elevate it with the remainder of the orbital contents. There is no need to repair this later.

Prerequisite Skills

- Basic macroscopic soft tissue and bone handling techniques
- Familiarity with implants and plating system

Operative Risks

- Blindness from trauma to optic nerve or postoperative hemorrhage
- Diplopia (which is usually short-lived)
- V2 numbness
- Infection
- Malposition of the lower lid
- Damage to the globe

Surgical Technique

- Perform forced ductions.
- Place a protective contact lens lubricated with ointment.
- Retract the lower lid with a Desmarres retractor over the orbital rim and the orbital contents with a ribbon retractor to expose the inferior conjunctival fornix.

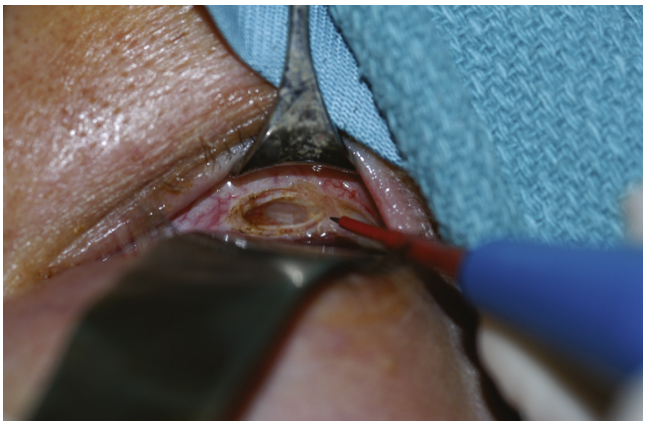

Fig. 187.6. Transconjunctival incision with a Colorado needle.



Fig. 187.7. Measurement of a nylon implant.

- Using a monopolar cautery on low power, make an incision through the conjunctiva and soft tissue in an arc curved posteriorly to expose the orbital rim (Fig. 187.6). Alternatively, make an incision between the plica semilunaris and caruncle and use blunt tenotomy scissors to dissect posteromedially toward the posterior lacrimal crest at about 45 degrees from sagittal to avoid the lacrimal drainage system.
- Use a periosteal elevator (such as a Cottle dissector) to elevate the periosteum and retrieve the orbital contents from the sinus. If an extraocular muscle is entrapped by a fracture, either complete the fracture and gently elevate the muscle, or use a Kerrison punch to enlarge the area of impingement.
- Cut and shape the implant material (Fig. 187.7).
- Place the implant using the as an elevator and the ribbon retractor in the other hand and reduce the fracture being hand to be certain that all orbital contents rest above the plate.
- Perform forced ductions (they should either be completely normal or improved over the beginning of the case).
- Fixate the plate, if desired, by placement of a single titanium screw, while being certain to avoid driving this into the infraorbital canal or above the frontoethmoidal suture. As this is not load bearing, it does not need to be driven perpendicular to the plate (Fig. 187.8).
- Place a Penrose or other soft drain into the orbit to rest on the surface of the implant and emerge from conjunctiva to be sutured loosely to lid skin. It is not necessary to close conjunctiva in either case.
- When repairing a fracture of the orbital floor, place a traction suture (such as 5.0 nylon) through the lower lid and tape to brow to keep the lower lid on upward stretch overnight (Figs. 187.9 and 187.10).

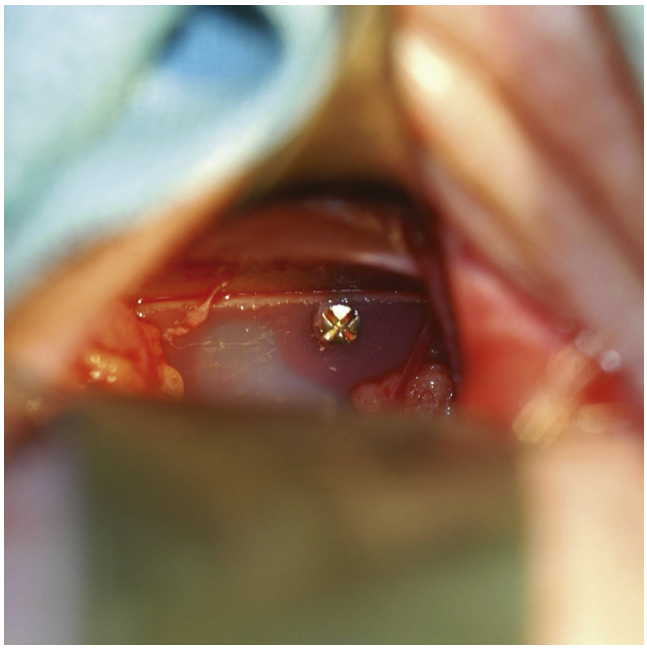

Fig. 187.8. Fixation of the nylon implant with a titanium screw.

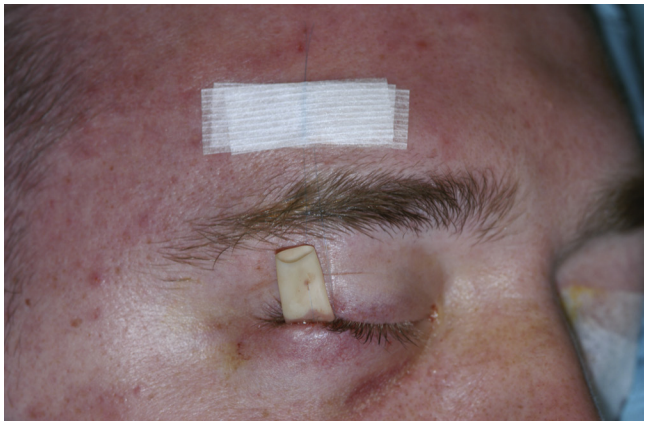

Fig. 187.9. Postoperative view of a patient with a drain and traction suture in place.

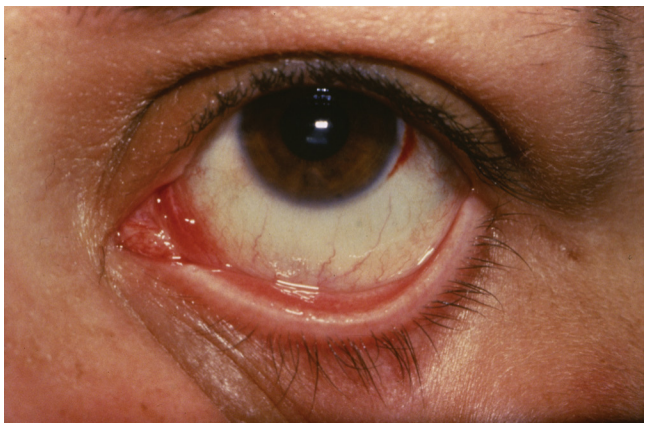

Fig. 187.10. Inferior conjunctival fornix 3 weeks after repair of a blowout fracture via a transconjunctival approach.

Common Errors in Technique

- Making the transconjunctival incision too for anterior can cause vertical shortening of the lid (if the orbicularis contracts during the incision with monopolar electrocautery, reposition the retractor holding the lid).
- Failure to support the implant posteriorly on a shelf of bone will cause the patient to have enophthalmos.
- Trapping of soft tissue under the edge of the implant can cause enophthalmos and diplopia.
- The eye must never be used as a fulcrum.

POSTOPERATIVE PERIOD

Postoperative Management

- Admit for overnight observation and IV antibiotics with steroid.
- No nose blowing or bending below the waist
- Pain and nausea control
- Remove traction suture and drain in the morning prior to discharge from the hospital.

Complications

- Postoperative hemorrhage can potentially result in a blind eye and requires emergent management. If the orbit is tight and there is proptosis not easily remedied by lateral canthotomy and cantholysis, take the patient immediately to the operating room for exploration.
- The risk of diplopia after repair of a blowout fracture is difficult to quantify without a randomized, controlled prospective trial. A small retrospective trial of 54 patients who underwent surgical repair found that approximately a third of the patients continued to have diplopia more than 6 months after repair.[8] However, approximately two-thirds of these patients had combined floor and medial wall fractures, thus making the risk greater than after floor fracture alone, for which it is about 10% to 12%. A more recent meta-analysis of diplopia after fracture (442 patients) found that the risk is more than 3 times greater in fractures repaired later than 2 weeks from injury.[9]

Alternative Management Plan

- In considering the general health of the patient, it is best to frankly discuss with the patient that the repair to be undertaken is for aesthetic reconstruction and occasionally to prevent double vision while not treating abnormal cheek sensation or pain. In most instances, it is necessary to undergo surgery to prevent diplopia from persisting. Thus, a patient in her 80s in a nursing home would be a less likely candidate for intervention than a 22-year-old student with a similar-appearing fracture.
- Observation with avoidance of nose blowing for 4 weeks

DISCUSSION

Evidence-Based Medicine Question

What is predictive of enophthalmos or permanent diplopia following a blowout fracture, indicating need for repair?

Different measurements of increased orbital volume have been suggested with an aim of predicting late enophthalmos. When analyzed by calculation from CT scan, several small studies have shown a correlation between an increase of 11% to 13% in orbital is enough to cause late (measured at later than 1 month) enophthalmos of more than 2 mm, which is

generally accepted as cosmetically acceptable. In an analysis of 211 consecutive patients (who all had blowout fractures of either the floor, the medial wall, or both and who were repaired with bone grafting), only 3% of floor fracture patients had enophthalmos at the 1-year follow-up. In addition, 29% of patients who had both floor and medial wall fractures but repair was only performed on the floor had enophthalmos at 1 year.[10]

Editorial Comment

Reading Dr. Tonya Stefkos's chapter on the management of fractures of the orbit was a bit of a trip down memory lane for me. In 1957, Dr. Byron Smith, a well-known Ophthalmologist in New York City described the blowout fracture of the orbit. He saw a patient who had been hit in the eye with a hurling ball and sustained a fracture of the floor of the orbit and complained of diplopia. The mechanism of the fracture was unique since the floor of the orbit was not fractured by the direct force of the ball but rather by the force transmitted by the globe when struck by the ball. The result was a "trap door" fracture of the floor of the orbit, usually medial to the infraorbital canal, with herniation of orbital adipose tissue into the maxillary sinus and often with entrapment of the inferior rectus muscle accounting for the diplopia.

As a resident at the Massachusetts Eye and Ear Infirmary in the early 1960s many blowout fractures of the orbit were seen in the busy eye clinic and were referred to the ENT service for a Caldwell-Luc procedure. This sublabial, transantral approach provided exposure of the fracture site and gave the Ophthalmologist the exposure necessary to release the orbital adipose tissue and the inferior rectus muscle and to reduce the fracture. In large fractures, a plastic implant was inserted to restore the continuity of the floor, but in most of the patients, the reduction of the orbital floor was maintained in place by packing the maxillary sinus with medicated gauze. I was intrigued by this relatively newly described fracture, and Dr. Lloyd Aiello, a resident in Ophthalmology, and I reviewed the records of all the patients treated in our institution using the technique described above. Our results were similar to those in a more recent report[9] in that early diagnosis and reduction of this fracture (within a 2-week time frame) results in a lesser risk for residual diplopia and enophthalmous.

In the modern era, endoscopic sinus surgery has replaced the Caldwell-Luc procedure when reducing the fracture from below. The transconjunctival approach so eloquently described in this chapter allows for reduction of the fracture and replacement of the orbital contents from above. A plate is then inserted to stabilize the floor and fixated by a single screw. It was interesting for me to observe the evolution in the treatment of this fracture.

Eugene N. Myers

Access the review questions and additional sources list online at http://www.expertconsult.com

REFERENCES

1. Putterman A, Stevens T, Urist M. Nonsurgical management of blow-out fractures of the orbital floor. Am J Ophthalmol 1974;77(2):232–239.
2. Smith B, Lisman R, Simonton J, et al. Volkmann's contracture of the extraocular muscles following blowout fracture. Plast Reconstr Surg 1984;74(2):200–209.
3. Bansagi Z, Meyer D. Internal orbital fractures in the pediatric age group. Ophthalmology 2000;107(5):829–836.
4. Manson P, Grivas A, Rosenbaum A, et al. Studies on enophthalmos. Plast Reconstr Surg 1986;77(2):203–214.
5. Broyles J, Jones D, Bellamy J, et al. Pediatric orbital floor fractures. Plast Reconstr Surg 2015;136(4):822–828.
6. Losee J, Afifi A, Jiang S, et al. Pediatric orbital fractures: classification, management, and early follow-up. Plast Reconstr Surg 2008;122(3):886–897.
7. Chaon B, Lee M. Is there treatment for traumatic optic neuropathy? Curr Opin Ophthalmol 2015;26(6):445–449.
8. Biesman B, Homblass A, Lisman R, et al. Diplopia after surgical repair of orbital floor fractures. Ophthal Plast Reconstr Surg 1996;12(1):9–16.
9. Damgaard OE, Larsen CG, Felding UA, et al. Surgical timing of the orbital "blowout" fracture: a systematic review and meta-analysis. Otolaryngol Head Neck Surg 2016;155(3):387–390.
10. Kronig SA, van der Mooren RJ, Strabbing EM, et al. Pure orbital blowout fractures reconstructed with autogenous bone grafts: functional and aesthetic outcomes. Int J Oral Maxillofac Surg 2016;45(4):507–512.

REVIEW QUESTIONS

1. In what situation is it mandatory that a patient's blowout fracture be repaired immediately?
   a. Presence of traumatic optic neuropathy
   b. Presence of diplopia
   c. Absence of complete abduction of the eye
   d. Entrapped periorbita present on computed tomography (CT)
   e. Entrapped extraocular muscle suggested by CT

2. In repairing an orbital floor fracture, which anatomic structure will be encountered and should be preserved?
   a. Lacrimal gland
   b. Frontal branch of the facial nerve
   c. Optic nerve
   d. Infraorbital neurovascular bundle
   e. Angular artery

3. The efferent limb of the oculocardiac reflex includes all the following, except
   a. Bradycardia
   b. Diplopia
   c. Hypotension
   d. Nausea

ADDITIONAL SOURCES

Aiello LM, Myers EN. Blowout fractures of the orbital floor. Arch Otolaryngol Head Neck Surg 1965;82:638–648.

Choi SH, Kang DH, Gu JH. The correlation between the orbital volume ratio and enophthalmos in unoperated blowout fractures. Arch Plast Surg 2016;43(6):518–522.

Raskin EM, Millman AL, Lubkin V, et al. Prediction of late enophthalmos by volumetric analysis of orbital fractures. Ophthal Plast Reconstr Surg 1998;14(1):19–26.

188 Osseointegrated Implants

Matilda Dhima

INTRODUCTION

The technique of osseointegration was introduced by Per-Ingvar Branemark in the 1980s. The definition of osseointegration as defined by Zarb and Alberktsson is "a time dependent healing process whereby clinically asymptomatic rigid fixation of specifically designed alloplastic materials is achieved and maintained during functional loading."[1] Dental implant therapy has provided an improvement in function and quality of life to replace missing teeth and other structures resulting from surgical ablation of head and neck structures or chemo/radiation therapy.

The recommended parameters for osseointegration are implant biocompatibility, microscopic and macroscopic design of the surface of the implant, host (patient) and implant, surgical protocol, and the loading and prosthetic protocols.[1] Dental implants are made of titanium, with a titanium oxide created on the surface when exposed to air. This oxide layer protects it from corrosion. Osseoinduction and osseoconduction are associated with the healing process.

Growth factors, surface roughness, and the design of the implant body contribute to such healing process. Spraying of various coatings on the surface aims at increasing the surface area of implant body with the goal of increased surface contact with bone as it undergoes the healing process via osseoinduction and osseoconduction. A greater area of surface contact between bone and implant is now considered to be an important factor in the success of implant therapy.

KEY OPERATIVE LEARNING POINTS

- Careful patient selection and patient-centered treatment
- Anatomic region and associated defects from ablation or chemo/radiation therapy are crucial in planning.
- Multidisciplinary management
- Presurgical planning
- Radiation therapy greater than 55 Gy
  - Not a contraindication to implant therapy
  - Greater risk of implant failure
  - No consensus on appropriate time of implant placement
- Hyperbaric oxygen therapy (HBO) if prior radiation therapy
  - Research has not shown a significant impact of HBO therapy.
- Medical comorbidities affecting healing, immune state; smoking, diabetes, oral bisphosphonates, periodontal disease
  - Not contraindications
  - Higher risk of implant failure
- Dental implants can be placed in microvascularized fibula free flaps with or without prior radiation therapy
- Surgical technique
- Management of peri-implant soft tissues is required especially in reconstructions using fibula microvascular transfer
  - Stable peri-implant soft tissue
- Tissue management procedures include one or a combination of
  - Vestibuloplasty
  - Lip switch vestibuloplasty
  - Skin grafting
  - Rigid splinting with implant prosthesis
- Loading protocols of dental implants with prosthesis in patients with large defects or radiation therapy are often staged.
- Regular monitoring of patients is very important to
  - Manage events
  - Complications
  - Monitor for recurrent disease

PREOPERATIVE PERIOD

Unlike natural teeth, dental implants are not at risk for caries, but they are at risk for developing peri-implant mucositis. Recent systematic reviews have shown no significant difference in implant survival at up to 10-year follow-up between patients with no gum (periodontal) disease and those with periodontal disease.

Osteoporosis, diabetes, immunosuppression, and the use of oral bisphosphonates continue to be evaluated, and current evidence shows a slightly higher risk of implant failure in this patient population. However, this does not mean that dental implants are contraindicated in this patient population. Rather, adequate screening and surgical and prosthetic planning with close communication with the managing physician are key to positive outcomes. Studies addressing other medical comorbidities, such as cardiovascular diseases, hypothyroidism/hyperthyroidism, human immunodeficiency virus (HIV), acquired immunodeficiency syndrome, ectodermal dysplasia, and scleroderma have shown no increased failure rate of implants in these patient populations when the comorbidity is medically controlled. It is important to note that these studies remain small in number and more research is needed in this area.

Ultimately, a multidisciplinary approach and patient-centered treatments are key to providing such therapy (Fig. 188.1). Realistic patient expectations and understanding of treatment, especially for maintenance, as well as expected and unexpected events play an important role in acceptance of dental implants. The longest follow-up to 29 years from a patient population at the Mayo Clinic revealed that mechanical events (associated with the prosthesis) occurred approximately three times more often than biologic events (associated with the implants) in edentulous patients treated with dental implants (Figs. 188.2 and 188.3).[2] This same study showed that 92% of prostheses had an overall survival, free of implant failure; however, only 15% survived free of any event. This means that long-term management of the prosthesis is key to improving treatment outcomes.

History

History of Present Illness

Intraoral Defects

1. Extent of structures affected by disease or tooth deficiency
   a. Arch of the maxilla or mandible
   b. Natural teeth present
   c. Periodontal health
   d. Buccal tissues, tongue, speech, soft palate affected

1) Lip competency
2) Impaired tongue movement
3) Impaired soft palate movement
4) Tethering of intraoral/extraoral tissues

e. Risk of aspiration
f. Current quality of life
g. Weight loss
h. Experience with removable prosthesis, such as dentures or obturators

2. Current medical, social history associated with higher risk of implant failure
   a. Smoking
   b. Radiation therapy
   c. Conditions affecting healing (bone, soft tissue, immune status)
   d. Psychological status
   e. Manual dexterity
3. Any reconstruction present

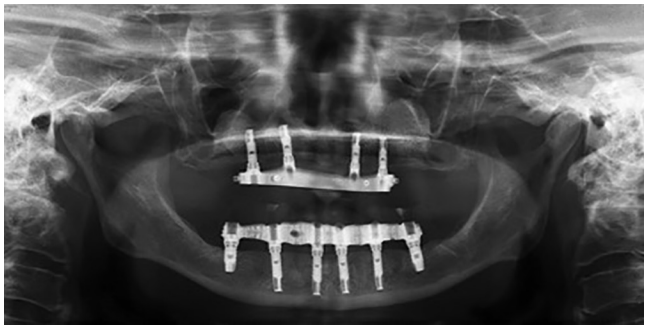

Fig. 188.1. The panoramic radiograph of a patient treated with an implant-supported prosthesis in the maxilla and implant-retained prosthesis in the mandible. The final prosthesis is in place. A digitally designed and milled titanium bar connects the implants and is part of prosthesis.

   a. Bone grafting
   b. Microvascularized fibula free flap
      1) Bulkiness of flap
      2) Mobility of flap
      3) Tethering of adjacent structures
4. Patient expectations of treatment
   a. Esthetics
   b. Function
   c. Quality of life
5. Patient age and location in need of dental implant
   a. Vertical growth of the face is the last to stop. Delay implants in anterior maxilla until growth has plateaued.
   b. If not, teeth on dental implants will look shorter than the rest of the natural teeth

Extraoral Defects. In addition to previous items, assess

1. Presence of skin tags
   a. Ear lobe (retain)
   b. Cartilage remnants
   c. Muscle activity
      1) Twitching
      2) Excessive movement of skin adjacent to defect when speaking/smiling
2. Social activities
   a. Sweating, spending long time outdoors (medical adhesive cannot retain prosthesis)
   b. Makeup use (helps to mask demarcation of prosthesis outline)
3. Location of defect
   a. Any remaining ala, unsupported nasal tip, lip tethering, turbinates
      1) Interfere with stability of prosthesis
   b. Presence of teeth
      1) May affect placement of air implant in the maxilla (nasal prosthesis)
      2) Long-term edentulism
         a) Patients may have very thin anterior maxilla.



Fig. 188.2. Final prosthesis on models prior to insertion for same patient. The maxillary prosthesis is supported by a milled bar connecting dental implants. The maxillary prosthesis is removable by the patient. This design allows for establishing lip support and cleaning of implant parts by removing the prosthesis. The mandibular prosthesis is implant retained and cannot be removed by the patient. The cleaning is done by flossing under the prosthesis. No flange is needed for lip support here in the mandible.



Fig. 188.3. The same patient with both prostheses in place.

Past Medical History

1. Detailed review of systems
   a. Social history (smoking, alcohol use, drug addiction)
   b. Dental history
   c. Pattern of tooth loss, periodontal disease
   d. Medications and allergies
2. Assess what from above would affect patients during surgical procedure and recovery as well as healing and prosthetic rehabilitation.
3. Obtain medical consultation describing the procedure of implant therapy including
   a. Commonly prescribed medications after implant placement, which may include antibiotics, steroids, nonsteroidal anti-inflammatory medications
4. Identify what affects the patient during the implant placement procedure
   a. Cardiovascular system
   b. Endocrine
   c. Respiratory
   d. Neurologic
5. Identify medication or systemic conditions that impact healing
   a. Blood disorders
   b. Medication for osteoporosis
   c. Immunosuppressive drugs
   d. Unstable diabetes
   e. Unstable thyroid disorders
   f. Smoking
   g. Psychiatric disorders
6. Previous history of radiation therapy
   a. Dosage
   b. Mapping
7. Previous history of malignancy
   a. Structures affected
   b. Location
   c. Adjuvant therapies
   d. Types of reconstruction
8. Previous experiences with dental therapy
   a. Any problems with prosthesis
   b. Healing issues
   c. Loss of implants
9. Identify length and extent of surgery with dental implant placement.
   a. Assess systemic conditions.
   b. Ability to metabolize large amounts of local anesthetic specifically liver, kidney, heart
10. Social and mental status
    a. Informed consent ability
    b. Manual dexterity
    c. Swallowing challenges
    d. Speech challenges
    e. Psychologic status
    f. Ability to tolerate transitional prosthesis

Physical Examination

Extraoral Examination

1. Facial asymmetry
   a. Presence of intraoral defects in the buccal and mandibular angles
   b. Neurologic deficit
   c. Evaluate profile, which can give an initial idea of most likely skeletal relationship of jaws.
2. Lips
   a. Incompetence of the lips
   b. Lip length and thickness
   c. Perioral limited oral aperture
   d. Any tethering of the vestibules in the maxilla or mandible as a consequence of surgical ablation
   e. Drooling
3. TMJ
   a. Temporo mandibular joint (TMJ) disorders
   b. Limitations or deviation upon opening, closing, clicks, crepitus
   c. Complications such as mastication muscles atrophy from radiation therapy or ablation
   d. Constriction of mouth opening from perioral structures due to ablation, radiation therapy

These limit access to the oral cavity for implant placement and prosthetic rehabilitation.

4. Presence of unusual skin topography, swelling, edema, or lesions suspicious for malignancy
5. Extent of any missing facial structures
   a. Orbital area, face, and auricular areas
      1) Muscle activity
      2) Prosthesis movement
   b. Skin tags must be removed.
   c. Bony structures including
      1) Mastoid area, tuberosities in nose, nasal bridge, orbital rims

Intraoral Examination

   a. Status of remaining ridges, sizes and location of defect from respective surgery, condition of saliva or mucositis from radiation therapy
   b. Shape of arches in maxilla and mandible
   c. Any discontinuity in arches and discrepancies in their size
   d. Identification and tethering of vestibules, lip, cheek, or tongue (with mandibular arch) suggestive of ablative or reconstructive surgery
   e. Look for areas of exposed bone.
      1) Recurrence of the cancer
      2) Poor healing
      3) Osteoradionecrosis (ORN)
   f. Assess for unusual lesions that may warrant biopsies.
   g. Evaluate remaining teeth.
   h. Assess presence and movement of tongue and soft palate.
   i. History of radiation therapy
      1) Incompetency (neurologic)
      2) Insufficiency (mechanical, surgically removed, or revised)

   j. Limited tongue movement
      1) Revise
      2) Release tethering
      3) Debulk
      4) Hyperplasia
1. Swallow
   a. Percutaneous endoscopic gastrostomy (PEG) tube, reason it is in place
   b. Modified barium swallow (MBS) study
   c. Large defects
   d. Aspiration risk
2. Speech
   a. Articulating errors
   b. Hypernasal, hyponasal speech
   c. Tongue movements
3. Neck
   a. Lymphadenopathy
4. Overall health and disposition

Imaging

1. Panoramic radiographs
2. Full mouth series of radiographs
3. Lateral cephalogram
4. Cone beam computed tomography (CT)
   a. If multiple implants are placed
   b. When bone quality or quantity is questionable
   c. When conducting presurgical virtual planning
   d. When planning virtual or guided implant therapy
   e. Cases involving multiple implant placement
   f. Zygomatic implant placement
   g. Cranial implants
   h. Sinus lift, augmentation
5. Magnetic resonance imaging (MRI)
   a. Only when suspecting pathology; thus rarely needed
6. CT with three-dimensional (3D) imaging reconstruction
   a. Resection, implant placement
   b. Microvascularized fibula free flap (MVFF)
   c. Nerve lateralization
   d. Jaw surgery

Indications

1. Partially edentulous
2. Poor function with removable prosthesis
3. Support extra oral prosthesis
   a. Large defects
   b. Difficulty with using adhesive
4. Support intraoral prosthesis
5. MVFF
6. With surgical ablation of head and neck defects
7. Improve function, quality of life

Contraindications

1. Refractory patients with previous unsuccessful implant, prosthetic therapy
2. Unrealistic expectations of treatment outcomes
3. Medical comorbidities where procedure risks outweigh benefits
4. High risk for cancer recurrence
5. Poor patient compliance
6. Inability of informed consent

Preoperative Preparation

Team evaluation by some or all listed here, depending on complexity of case and structures to be reconstructed surgically and/or prosthetically

1. Head and neck surgeon
2. Plastic surgeon
3. Oral surgeon
4. Speech/swallow therapist
5. Medical/radiation oncologist
6. Prosthodontist/maxillofacial prosthodontist
7. Preoperative evaluation team
8. Primary care physician (PCP) or other medical specialties
9. Anesthesia
10. Postoperative care
11. Nutrition

OPERATIVE PERIOD

Anesthesia

- Local anesthesia
- Sedation
- Antianxiety medications—sometimes
- General anesthesia—long and complex procedures
  - Blood chemistry
  - Follow-up of any abnormal values
- A nasogastric feeding tube for large reconstructions
- A tracheostomy, large resections, mandibular reconstruction, airway compromise

Positioning

- Dental chair or operating room (OR)
  - Depending on arch location, the patient may be at 25 to 30 degrees reclined or laid back at approximately 10 to 15 degrees.
  - Surgeon, patient comfort, ease of access to implant placement

Perioperative Antibiotic Prophylaxis

- Sterile setup
- Surgical area decontaminated
- Intraoral chlorhexidine gluconate oral rinse
- Antibiotic coverage may start 5 to 10 days before procedure and/or administered during anesthesia induction
- Antibiotic coverage 5 to 14 days after procedure
  - Amoxicillin, penicillin, clindamycin, cephalosporins, metronidazole

Monitoring

Implant Therapy

- Identify, avoid perforations
- Avoid overangulation of implant drills to keep proper implant position.
- Use surgical guide to ensure proper implant location, angulation
- Use ample irrigation to avoid bone overheating.
- Assess clinically for good bone quality and quantity to help initial implant stability.
- Identify, mark, avoid nerves
- Identify curve of mylohyoid as landmark to avoid floor of mouth perforation
- Check for excessive bleeding.
- Routine general anesthesia/sedation monitoring
- Assess and record type of implant and stability achieved.
- Assess for proper distance between implants adjacent to teeth or other implants.
- Ensure adequate stable peri-implant tissues, consider performing debulking and/or skin grafting

Flap Reconstruction

- Coronary artery disease (CAD), diabetes, blood dyscrasias at higher risk for flap failure
  - Consult cardiologist, endocrinologist, hematologist
- Avoid areas of compression/tension.
- Observe, control anastomosis
- Consider Doppler use.
- Consider anchor sutures.
- Avoid tracheostomy ties.
- Monitor flap for failure, arterial/venous compromise thrombosis
- First 24 to 48 hours are critical, ensure clinical monitoring of reconstruction, hourly recommended
  - Visual inspection, color, size, temperature, perfusion
  - Other monitoring methods
    - Handheld Doppler use
    - Licox tissue oximeter
    - Laser/implantable Doppler
  - This allows for attempts to salvage reconstruction.
- Blood count/chemistry to avoid anemia, thrombosis
- Ensure patient hydration.
- Bed rest, nothing by mouth (NPO) for first 24 hours
- No consensus on type or dosage of anticoagulation to use
  - Studies suggest aspirin and subcutaneous heparin alone or in combination for postoperative anticoagulation after free tissue transfer.

Instruments and Equipment to Have Available

1. Standard dental (oral surgery) set
2. Implant placement set with appropriate drill series for type of implant system used
3. Various implant sizes
4. Various healing abutment and cover screw sizes
5. Various screw sizes and impression copings if a prosthesis is connected to dental implants at time of surgery
6. Prosthetic components
7. Sometimes, plates—prefabricated by virtual planning, prebent, or standard
8. Preprosthetic surgical guides (Fig. 188.4)
9. Electrocautery
10. Surgical loupes
11. Oscillating saw for alveolectomy
12. Slow-speed burrs for bone re-contouring, alveoloplasty
13. Chromic gut sutures
14. Bone grafting material (bovine, cadaver, harvested from the patient)
15. Standard instruments for head and neck surgery if concurrent resections
16. Standard microvascular reconstructions if concurrent resections
17. Prosthodontic impression, conditioning materials for prosthesis delivery
18. Saline solution
19. Chlorhexidine rinse

Key Anatomic Landmarks

The most common anatomic regions in the head and neck area for consideration of osseintegrated implant therapy can be categorized as intraoral and extraoral.

Intraorally

- Maxilla
- Mandible
- Native alveolar ridge
- Adjacent teeth and roots
- Sinus floor
- Nasal floor
- Bone-grafted sites
- Zygoma
- Areas reconstructed with a fibula microvascular free flap
- Vestibule
- Nerve foramen: mental, infraorbital, lingual
- Curvature of mandible (mylohyoid)
- Lip competence
- Tuberosities

Extraorally

- Facial bones (Fig. 188.5)
- Maxilla
- Orbital rim
- Lateral rim and malar body
- Mastoid area (Fig. 188.6)
- Anterior nasal floor (in edentulous patients)

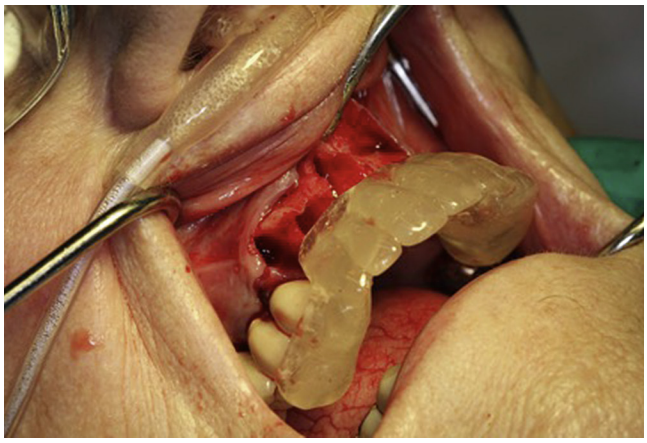

Fig. 188.4. A surgical guide in place during implant placement. The guide reflects the planned tooth positions to mimic final restoration.



Fig. 188.5. A custom-designed bar connecting two cranial implants for support of an auricular prosthesis.

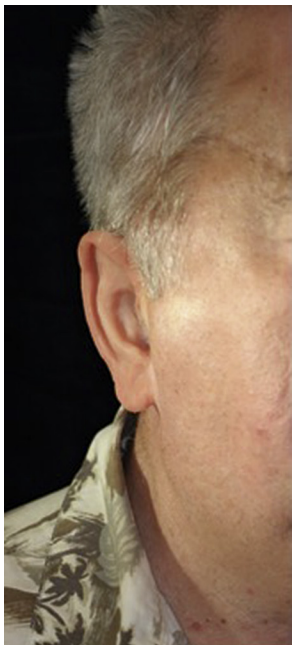

Fig. 188.6. A view of patient in Fig. 188.5 with auricular prosthesis in place.

- Lateral walls of pyriform aperture (in dentate patients)
- Rarely glabella with known unreliable outcomes

Prerequisite Skills

- Dental tooth anatomy and root morphology
- Understanding of differences in arch shapes, bone quality and quantity
- Anatomy of the head and neck
- Parameters for minimum distance between implant to implant, implant to teeth
- Management of complications such as
  - Sinus perforation
  - Nasal floor perforation
  - Floor of mouth perforation
- Identify key anatomic landmarks.
- Implant placement protocol
- Teeth extractions
- Skin grafting
- Plating
- Alveolectomy, alveoloplasty
- Understanding implant components
- Presurgical planning prosthetic, virtual
- Harvesting/completing grafting tissue/bone

Surgical Technique

Presurgical Planning Prosthetic or Virtual

- The presurgical planning is key to a predictable outcome whether for a single dental implant in an otherwise healthy and dentate patient to a more complex patient. In consultation with prosthodontist the appropriate location, size, and restoration type are determined.
  - Transitional prosthesis are often fabricated.
  - These are inserted at the time of the implant placement or later.
  - They serve as transitional prosthesis and oftentimes as a guide to the definitive prosthesis.
  - Surgical guides are used and fabricated based on the final prosthesis plan.
  - They give information in need for additional procedures such as
    - Alveolectomy or alveoloplasty to accommodate implant components and allow adequate space for prosthesis
    - Need for tissue management in peri-implant areas
    - Need for sinus lift
    - Bony or tissue augmentations
- The maxillary and mandibular bones are associated with varying degree of bone quality and quantity, which serve an important role in the planning, surgery, and treatment outcomes with implant therapy.
- The more remaining healthy teeth, the better the outcome for patients.
- Dental implants can be placed in remaining native bone or fibula reconstructions.
- Implant therapy is dictated by type of disease process, adjuvant chemoradiation therapy, and involvement of adjacent structures.

Surgical Approach

- An incision is made to access the bony ridge.
- A crestal incision provides better access to the bony ridge, especially if multiple implants are placed.
- In the maxilla, a palatal incision can be made to minimize risk of implant exposure, allow adequate tissue approximation
- An H-shape incision
- If adjacent teeth are present, the incision is carried through the sulcus of the adjacent tooth.
- The base of the flap should be wider to allow for ample blood supply.
- For more conservative approaches, especially in cases of aesthetic area and single teeth implants, a no flap technique can be used.
- Based on presurgical planning and imaging, the location of implants and the distance between teeth and implants are established
- Bone grafting procedures concurrent or staged are completed prior to or after the implant insertion.
- The tooth extractions planned are completed as atraumatically as possible.
- Tissue management procedures are completed in a staged fashion.
- Alveolectomy or bony recontouring is completed with surgical guides to help.
- Establish the osteotomy site with a small round burr based on presurgical planning.
  - This is more difficult to establish if placing implants at same time of a large bony reconstruction, such as MVFF.
- Usually the osteotomy is placed in the middle of the crest, equidistant if in between two teeth and equidistant if multiple implants unless otherwise planned preoperatively.
- Stay more palatal for anterior maxilla.
- Stay no closer than 4 mm from adjacent teeth.
- Stay no closer than 7 mm from adjacent implant.
- Use ruler and surgical guides to measure and check.
  - Based on well-established guidelines,[3] a simple example shows that a 3.5-mm platform implant should be
    - No less than 3 mm from adjacent implant
    - No less than 2 mm from adjacent tooth
    - Modify implant size (hence platform) to manage above distances
- Incrementally increase osteotomy size (Fig. 188.7) following the established sequence of drills in the implant placement kit to the desired depth and size (based on presurgical planning and radiographic imaging).
  - Use a position marker to assess depth, parallelism (Fig. 188.8), and direction/angulation of the osteotomy while

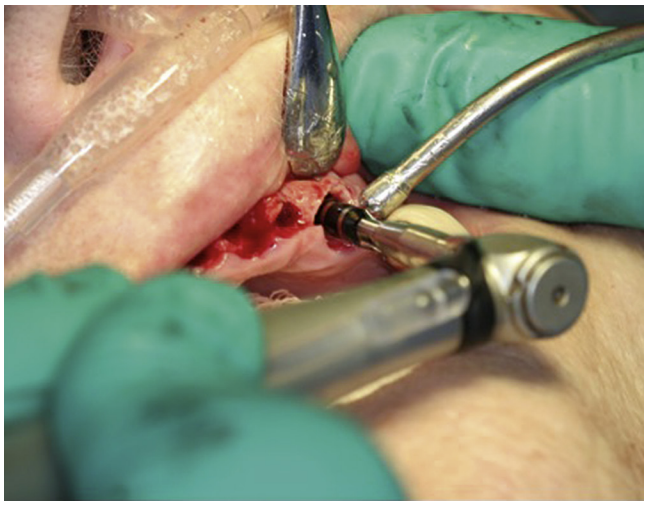

Fig. 188.7. Osteotomy is being prepared with a drill in a sequence. Note the gray lines on the drill are a guide to the depth of osteotomy.

increasing your osteotomy to desired implant dimensions.

- The goal is to have a direction as close to the path of insertion of the prosthesis as possible and multiple implants parallel to each other.
- It is easier to correct the angulation at early stages of narrow and shorter osteotomy.
- Avoid attempts to correct your osteotomy position and angulation when osteotomy size is larger or close to desired width and depth.
  - In these situations, it is best to leave correction for prosthetic components.
  - Correcting osteotomy angulation and location late in the osteotomy series results in a large osteotomy that will not receive a stable implant body and poor initial bone-to-implant contact.
- Use internal irrigation to minimize bone trauma.
- Use a stable up/down motion when creating the osteotomy.
- Do not use pressure from your wrist drilling down in one direction.
- Use condensers in low-density bone.
- Bone tappers and hand reamers should be considered to use in high-density bone.
- If resistance is met during implant insertion with incomplete seating of the implant body
  - Check again your osteotomy depth and drill used.
  - If the above is correct, remove the implant first by a few turns and use the implant as a tapper.
  - Sometimes the whole implant is retrieved, the thread is tapped, and the implant is reinserted.
  - After the implant is inserted (Fig. 188.9), the clinician should obtain an idea of the stability of implant, based several factors.
    - Type of bone quality and quantity
    - Bone-to-implant contact
    - Insertion torque (Ncm) used to place implant
      - An initial insertion torque of 30 to 45 Ncm is often associated with good stability, but it is not the only parameter.
- If the implant is not stable to receive a prosthesis or additional tissue management is required, a cover screw is placed, and the flap is closed.
- If the implant is stable to receive a prosthesis, implant components are seated, and the prosthesis is either immediately loaded or immediately placed without loading (not in function).

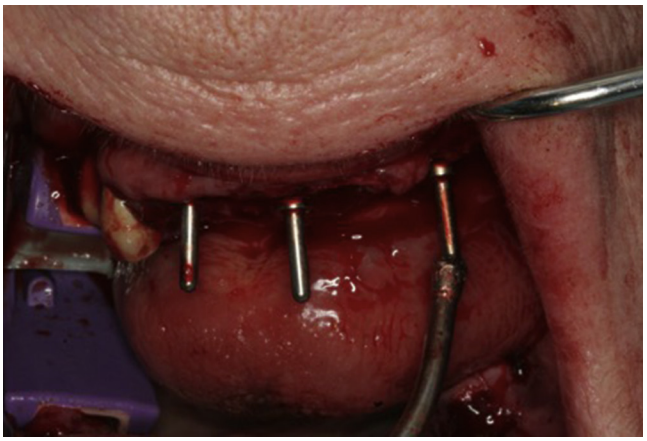

Fig. 188.8. Guide pins in place to assess parallelism in preparation for placement of dental implant.

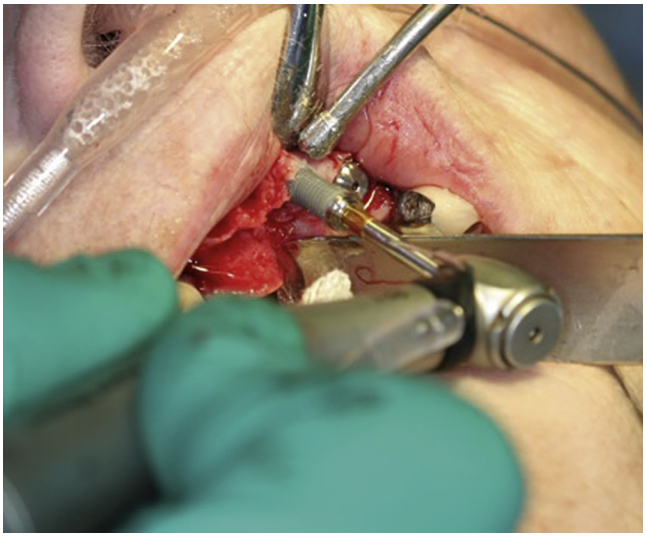

Fig. 188.9. Dental implant being guided into the osteotomy site.

  - Any additional bone grafting or tissue management procedures mentioned previously may be completed.
  - Healing abutment may also be placed.
- *Edentulous/partially dentate patients with intraoral defects*

Maxilla

- The native remaining alveolar ridge is often the first consideration for placement of the dental implant.
- In cases of severely resorbed native remaining alveolar ridge, zygomatic implants can be considered if structure remains on defect side after resection.
- In edentulous remaining alveolar ridge, two, four, or six implants are sufficient. A locator is a part that will connect dental implants to obturator, denture, or crown.
- Zygomatic implants are considered as a last resort for maxillary defects.
- Access to implant is often very difficult for the maxillofacial prosthodontist due to its angulation in the oral cavity.

Mandible

- Similar concepts apply
  - Wide distribution of dental implants for force distribution

- Due to inherent mobility of perioral structures (lips, tongue, cheeks) consider
  - Lip-switch vestibuloplasty
  - Skin graft
- *Mandibular reconstruction with microvascularized fibula free flap reconstruction*
  - Always problems with tissue hyperplasia
    - Pain
    - Erythema
    - Food entrapment
    - Peri-implantitis
    - Bone loss around implants
    - Implant failure
    - Inability to wear prosthesis
  - Mobility and bulkiness of flap affect:
    - Speech
    - Space implant components, prosthesis
    - Pain
    - Peri-implantitis
    - Bone loss
  - Must provide immobile peri-implant tissues
    - Debulking
    - Vestibuloplasty
    - Skin grafting, rigid splint
- *Maxillary reconstruction with microvascularized fibula free flap reconstruction*
  - May replace only missing teeth in reconstruction
    - Only if defect is small
    - Present remaining teeth in maxilla
  - Large or complications result in acquired fistulas
    - Consider dental implants (Fig. 188.10).
    - Native bone
    - Fibula
  - Ensure a good bony union.
  - Provide "tall" and "wide" enough fibula sections to support lengths (6, 10, and 13 mm) of dental implants.
  - Virtual surgical planning to optimize outcome
  - Dental implants are sometimes at same time of reconstruction
    - High degree of inaccuracy for location due to loss of anatomic landmarks
    - Very often, implants end up too palatal or projecting to cheek area
    - Rendered useless
    - Often best to place in staged approach



Fig. 188.10. A patient with a microvascular fibula free flap reconstruction experienced a fistula after healing and adjuvant radiation therapy. Note dental implants were placed at same time as reconstruction. Most distal implant is very buccal and has a projection to the cheek. Also noted is the bulkiness of flap.

- *Adjuvant/neoadjuvant chemo/radiation therapy*
  - Implant placement is often completed 6 to 12 months or longer after radiation therapy.[4]
  - Because osseointegration requires 2 to 6 months, most of these patients cannot delay adjuvant therapy.
  - Sometimes, may place at resection of neoplasm
    - Predictable in native bone
    - In MVFF, best to do after recovery from adjuvant therapies
      - Control of implant placement by planning the prosthesis design
  - Research and clinical experience on benefit from HBO therapy
  - A Cochrane review has shown no additional benefit to HBO therapy when placing dental implants in radiated bone.[5] Longer healing times and monitoring for adequate healing are recommended.
  - The best protocol to load (connect function prosthesis) in this patient population is to delay it or otherwise complete in stages, ensuring stability and waiting for osseointegration of implants.
  - Interaction of the multidisciplinary team including surgeon ear, nose and throat surgeon (ENT), plastic surgery, oral maxillofacial surgery), maxillofacial prosthodontist, oncologist, speech/swallow therapist
  - High risk of recurrence
    - Monitoring is essential.
    - Biopsies

Common Errors in Technique

- Incorrect flap design resulting in lack of access to implant site placement, poor blood supply, loss of tissue
- No presurgical planning and multidisciplinary approach
- No discussion of patients' realistic expectations
- Not following systematic drills for creation of the osteotomy
- Not using drill guides
- Inadequate buccal lingual positioning and distances between teeth, implants
- Poor closure technique
- Lack of tissue management to provide stable peri-implant tissues

Operative Risks

- Bleeding
- Perforation into key anatomic structures
  - Floor of the mouth
  - Sinus/nose
- Paresthesia, inferior alveolar nerve
- Areas of non-bony union if fibula reconstruction
- Loss of blood supply to MVFF
- Inability to place dental implant due to poor bony quality, quantity
- Inability to achieve primary closure due to tissue tethering

POSTOPERATIVE MANAGEMENT

- Antibiotic coverage and bacteriostatic/bacteriocidal oral rinses
- Pain management
- Monitor flap viability when applicable.
- Loading or restoration with any prosthesis
- Follow up to monitor healing, remove any sutures
- Monitor diet modification.
- Follow up with rest of surgical and rehabilitation team.
- Complete any additional HBO therapy when feasible.

Complications

1. Flap failure[8]
   a. Surgical procedure complications
      1) Critical first 24 hours to 5 days postoperative
      2) 5% to 25% may need re-exploring postoperatively due to poor circulation.
      3) Highest failure risk initial postoperatively
      4) 3% to 4% failure rates reported
      5) Microvascular thrombi first 2 to 5 days postoperatively
      6) 54% to 63% reported thrombosed vessels.
   b. Attempt salvage.
      1) Avoid compression/tension areas.
      2) Anchor sutures.
      3) Observe anastomosis before wound closure.
      4) Monitor buried flaps (pharyngeal, tongue) clinically.
2. Implant loss
   a. If no primary stability, cover implant, uncover at second stage
   b. Consider native bone first for implant therapy to improve success rate.
   c. Smoking cessation counseling
   d. HBO therapy consideration if implant in irradiated bone
   e. Monitor hgA1C in diabetic patients.
   f. Provide stable peri-implant tissues with debulking and skin grafting.
   g. Ensure bony union of fibula and native bone to avoid iatrogenic fractures.
3. Prosthetic complications
   a. Consider a simple, easy to maintain prosthesis.
   b. Counsel on diet and oral hygiene to minimize peri-implantitis

Alternative Management Plan

1. Tooth, tissue-supported prosthesis
2. No further treatment

DISCUSSION

Evidence-Based Medicine Question

What is the success of implant therapy in patients with radiation therapy?

Studies have shown that smoking and a history of radiation therapy, especially when greater than 55 Gy, increase the risk of implant failure. This does not mean that implant therapy is contraindicated in smokers and patients with radiation therapy. Patient selection and awareness of higher implant failure are key to treatment and management of this patient population with implant therapy.

There is no current consensus on the most appropriate time to place dental implants in patients who have had radiation therapy whether in native bone, grafted bone, or fibula.

Current literature supports dental implant therapy between 6 and 12 months after radiation therapy or during ablation surgery and before radiation treatment.[4,6]

A recent meta-analysis has shown acceptable survival rates when dental implants are placed on native or grafted bone, whether irradiated or not. However, radiation therapy was associated with higher risks for failure.[7]

Editorial Comment

Maxillofacial and oral prosthodontists design prosthetics (facial, dental, palatal, or tongue prostheses), provide medical therapy, and adjust environmental factors to aid in the rehabilitation of cosmetic as well as functional deficits (i.e., speech and swallowing disorders). Oral and oropharyngeal prostheses help to compensate deficits by optimizing the remaining function, improving valving and bolus propulsion.

Prosthetic rehabilitation is led by a prosthodontist; however, its implementation requires input from all members of the care team, especially the head and neck surgeon and speech language pathologist. For example, a speech language pathologist must assess the speech and swallowing function before, during, and following the fitting of the prosthesis to evaluate its effectiveness. After the device has reached its final fitting, the speech language pathologist establishes a rehabilitation program that maximizes the value of the prosthesis.

Maxillofacial prosthesis can reproduce an organ, such as the nose or the ear, more accurately than a reconstructive surgery. Therefore prosthetic rehabilitation is a critical consideration for the restoration of quality of life in patients needing oncologic head and neck surgery.

Ricardo Carrau

Access the review questions online at http://www.expertconsult.com

REFERENCES

1. Zarb C. Nature of implant attachments. In: Branemark P-I, Zarb C, Albrektsson T, editors. Tissue-Integrated Prostheses Osseointegration in Clinical Dentistry. Chicago: Quintessence Publishing Co.; 1985. p. 88–98.
2. Dhima M, Paulusova V, Lohse C, et al. Practice-based evidence from 29-year outcome analysis of management of the edentulous jaw using osseointegrated dental implants. J Prosthodont 2014;23(3):173–181.
3. Tarnow DP, Magner AW, Fletcher P. The effect of the distance from the contact point to the crest of bone on the presence or absence of the interproximal dental papilla. J Periodontol 1992;63(12):995–996.
4. Schepers RH, Slagter AP, Kaanders JH, et al. Effect of postoperative radiotherapy on the functional result of implants placed during ablative surgery for oral cancer. Int J Oral Maxillofac Surg 2006;35(9):803–808.
5. Coulthard P, Patel S, Grusovin GM, et al. Hyperbaric oxygen therapy for irradiated patients who require dental implants: a Cochrane review of randomised clinical trials. Eur J Oral Implantol 2008;1(2):105–110.
6. Anderson L, Meraw S, Al-Hezaimi K, et al. The influence of radiation therapy on dental implantology. Implant Dent 2013;22(1):31–38.
7. Schiegnitz E, Al-Nawas B, Kammerer PW, et al. Oral rehabilitation with dental implants in irradiated patients: a meta-analysis on implant survival. Clin Oral Investig 2014;18(3):687–698.
8. Salgado CJ, Chim H, Schoenoff S, et al. Postoperative care and monitoring of the reconstructed head and neck patient. Semin Plast Surg 2010;24(3):281–287.

REVIEW QUESTIONS

1. Parameter(s) for osseointegration include all of the following, except
   a. Arch shape
   b. Implant biocompatibility
   c. Surgical protocol
   d. Loading protocol

2. A lower risk for implant failure is associated with:
   a. Unstable diabetes
   b. Osteoporosis
   c. Immunosuppression
   d. None of the above

3. All of the following are important considerations in implant therapy, except
   a. Presurgical planning
   b. Ample irrigation
   c. Peri-implant tissue management
   d. Tooth color

189 Choanal Atresia/Pyriform Aperture Stenosis

Amanda L. Stapleton, Scott Manning

INTRODUCTION

Nasal obstruction in the neonate can lead to severe respiratory distress and failure to thrive if not properly identified and treated. Newborn infants are obligate nasal breathers; therefore, nasal airway obstruction has significant downstream effects. Cyclic apnea, cyanosis, and respiratory distress temporarily relieved by crying should elicit a high index of suspicion for nasal airway obstruction. In the neonate, this can be caused by bilateral choanal atresia or pyriform aperture stenosis (PAS).

Choanal atresia is an excess of mesenchymal tissue that creates an atretic plate that separates the posterior nasal cavity from the nasopharynx. It is believed that the pathogenesis is a persistence of the buccopharyngeal membrane during weeks 4 to 11 of development or a failure of the oronasal membranes to rupture. There are also additional anatomic anomalies that accompany choanal atresia that can compromise the nasal airway. These include septal deviation to the obstructed side, medial bowing of the lateral nasal wall, medialized pterygoid plates, widened vomer, and a narrow nasopharynx. Unilateral atresia is more common than bilateral with the right side more common than the left. Thirty percent are purely bony, and 70% are mixed membranous and bony atresia. Up to 49% of patients with bilateral choanal atresia have an associated congenital malformation. CHARGE syndrome (coloboma, heart disease, choanal atresia, retardation of growth, genital hypoplasia, and ear anomalies), Treacher Collins Syndrome, Crouzon's, Apert's syndrome, or Trisomy D have all been found to be associated with bilateral choanal atresia.[1] Unilateral choanal atresia may not be recognized until later in childhood, adolescence or early adulthood. Patients can present with unilateral nasal obstruction, mouth breathing, rhinorrhea, sinusitis, or loss of their sense of smell.

Congenital nasal PAS is a rare form of nasal airway obstruction. It is caused by medial positioning or overgrowth of the medial nasal process of the maxilla. The pyriform aperture is the narrowest part of the nasal airway. Therefore, any decrease in size can cause significant nasal obstruction in the neonate. These patients have a similar presentation to infants with bilateral choanal atresia. They have nasal obstruction, inability to pass a nasogastric tube, respiratory distress, cyanosis, and feeding difficulty. The diagnostic criteria for PAS is a width less than 11 mm measured as the total width between the medial aspect of the maxilla at the level of the inferior meatus. In addition to PAS, the nasal cavity is also found to have narrowing of the midnasal and choanal regions. Other associated findings with PAS include median central incisor, a triangular-shaped palate, and a medial palatal ridge. If the patient is found to have a median central incisor on computed tomography (CT) scan, then a magnetic resonance imaging (MRI) should be performed to evaluate for holoprosencephaly spectrum disorders. Genetic work up is also recommended if a central neurologic anomaly is suspected.

KEY OPERATIVE LEARNING POINTS

- Endoscopic technique can provide excellent visualization of the choana and entire nasal cavity/airway.[2]
- Resection of the hypertrophied vomer and posterior septum is essential in preventing restenosis
- Postoperative stenting has not been shown to improve outcomes in choanal atresia repair patients.[3] However, stenting should strongly be considered/used in the neonate after repair to provide a patent nasal airway. They are also recommended for use in patients with CHARGE association. The stent provides a reliable nasal airway that gives immediate relief to neonatal nasal obstruction while the operative site is healing.
- Syndromic patients (CHARGE) have a lower success rate due to their cardiopulmonary medical issues. They can have a flat skull base and less room for repair in the nasopharynx. They have a higher chance of requiring a tracheostomy in early infancy to establish a stable airway.
- Routine endoscopy and removal of crusting and granulation 7 days after surgery improves postoperative outcomes.[4]
- Infants (<28 days old) likely require several postoperative dilations after trans-nasal repair. This can be performed in the operating room or in the office with ureteral dilators. Balloon dilators can also be used in the operating room (OR) or office setting.
- Mitomycin C has not been shown to decrease restenosis rates in large meta-analysis studies. However, some studies show a trend toward reduced granulation tissue formation and decreased re-stenosis in the neonate population when used during initial surgical repair. This should be considered in the neonate population.
- Failure to reduce the inferior turbinates in PAS can also lead to failure and the need for surgical airway intervention.

PREOPERATIVE PERIOD

Bilateral choanal atresia can lead to a medical emergency with cyclical desaturations, cyanosis, and distress in the neonate. It must be expeditiously evaluated and treated to prevent respiratory distress and prolonged intubation. A McGovern nipple can be used to help maintain the infant's airway. This can also allow the infant to start feeding in most cases. If the infant continues to have respiratory distress with the McGovern nipple in place, then laryngotracheal mask (LMA) or endotracheal intubation may be required. In some circumstances, a tracheostomy may need to be performed if the definitive repair needs to be delayed due to other health issues (i.e., cardiac disease). PAS can lead to the same clinical presentation due to the bilateral nasal obstruction it causes. Unilateral choanal atresia can often be managed less urgently. Most infants are

able to maintain a nasal airway without a McGovern Nipple or intubation until a repair is performed.

Inability to pass a 6 French nasogastric catheter through the nasal cavity/nasopharynx and absence of fogging of a mirror when placed beneath the nose all point to possible choanal atresia/PAS. This should then be evaluated by an Otolaryngologist who can perform a bedside nasal endoscopy to look for patency of the nasal cavity and posterior choanae. If the flexible scope cannot be passed through one or both sides of the nose, then a CT scan is indicated to evaluate the nasal cavity and choanae. The CT scan can also be used to evaluate the inner ear for anomalies associated with many of the related syndromes.

PAS should initially be treated medically, and surgery is then recommended if the conservative management does not provide an adequate nasal airway in the neonate. Conservative management includes using saline nasal drops, oxymetazoline spray, nasal corticosteroid drops, temporary stenting of the anterior nares if possible with a nasal airway, and use of a McGovern nipple. The traditional surgical management of PAS is a sublabial drill out procedure with stenting. Recent studies have also reported addressing the inferior turbinate as it arises from the lateral border of the pyriform aperture and can contribute to nasal airway narrowing/obstruction. Dilating the pyriform aperture using ureteral/cervical dilators or balloon provides a nondestructive surgical option to open the pyriform aperture. There are no current literature guidelines for when surgical management of PAS is required. Some authors suggest that nasal obstruction with respiratory distress, apnea, or feeding difficulties requires surgical management, and other studies have suggested that width <5.7 mm is associated with surgical management.[5]

All patients should be consented for a direct laryngoscopy and rigid bronchoscopy as part of a complete airway evaluation at the start of the surgical procedure. There is a risk of laryngomalacia, tracheomalacia, and subglottic stenosis in this cohort of patients. Identifying a secondary airway lesion can be imperative in postoperative management of these patients. Pre and postoperative gastroesophageal reflux disorder (GERD) management is also important in these patients.

History

1. History of present illness
   a. Respiratory distress since birth?
   b. 5-French nasogastric tube—pass through both nasal cavities?
   c. Cyanotic episodes
   d. Cyclical desaturations with crying
   e. Feeding difficulty?
   f. Poor weight gain
2. Past medical history
   a. Premature or full-term infant?
   b. Other congenital anomalies?
   c. CHARGE syndrome?
   d. Genetic disorders in the family?
   e. Prenatal screening?

Physical Examination

1. Nasal endoscopy: flexible fiberoptic nasal endoscopy: evaluate for narrowing at the pyriform aperture, midnasal cavity, and the nasopharynx. Are both choana patent?
2. Head and neck examination: other congenital abnormalities: cleft lip/palate, midface hypoplasia, concern for central incisor, eye examination
3. Facial examination: evidence of deformity: upper lip, eye, midface
4. Airway—evidence of stridor, sternal retractions, stertor, nasal flaring

Imaging

1. CT maxillofacial with and without contract with image navigation—evaluate the choana for evidence of a bony, membranous, or mixed atretic plate. Evaluate posterior septum (widened vomer), medialized ptyergoid plates, and configuration of lateral nasal wall. Measure the width of the pyriform aperture on axial CT scan. If PAS is evident, evaluate for central incisor (Fig. 189.1A and B).



Fig. 189.1. A, Axial computed tomography (CT) scan of choanal atresia: bony left, membranous on right. **B,** Axial CT scan of pyriform aperture stenosis: 6 mm width measured.

2. MRI is used to further evaluate the patient for intracranial pathology. Holoprosencephaly spectrum can present with PAS and a central incisor. Evaluation for other neurologic congenital anomalies.
3. Electrocardiogram (EKG)/Echo evaluates for cardiac anomalies

Indications

1. Respiratory distress in the newborn
2. Inability to feed
3. Persistent nasal obstruction or sinusitis
4. Prolonged mechanical ventilation

Contraindications

1. Severe medical comorbidities
2. PAS - Improvement with medical management alone

Preoperative Preparation

1. Maximize oral airway—McGovern nipple, oral tracheal intubation, tracheostomy
2. Preoperative medical management: topical decongestants (oxymetazoline), nasal steroid sprays, saline spray
3. Preoperative CT to confirm diagnosis and evaluate length of nasal cavity/nasopharynx. Help to identify problem areas that will need dilation/drilling
4. Preoperative MRI to evaluate for holoprosencephaly in PAS with central incisor
5. EKG/echocardiogram—evaluate for cardiac anomalies

OPERATIVE PERIOD

Anesthesia

General anesthesia with oral tracheal intubation for protection of the airway due to bleeding from the nasal cavity and nasopharynx

Positioning

Supine: The patient is positioned with the head turned slightly toward the surgeon. No shoulder roll needed.

Perioperative Antibiotic Prophylaxis

Antibiotic coverage against upper airway pathogens is recommended as a single intraoperative dose: Unasyn or clindamycin

Monitoring

No somatosensory evoked potential (SSEP) or electromyography (EMG) required

Instruments and Equipment to Have Available

1. Endoscopic sinus surgery instrument set
2. Urethral sound dilators
3. Hager cervical dilators
4. High-speed drill
5. Microdebrider with diamond drill bit
6. Endotracheal tubes (ETTs) available for stenting if required
7. Endoscopic bipolar cautery

Key Anatomic Landmarks

1. Pyriform aperture: narrowest segment of the nasal cavity
2. Vomer of septum
3. Pterygoid plates
4. Nasopharynx
5. Location of bilateral greater palatine artery in lateral palate

Prerequisite Skills

Endoscopic sinus surgery skill set: ability to operate endoscopically with drill, back biter, microdebrider

Operative Risks

1. Injury to sphenopalatine artery and posterior nasal septal artery leading to hemorrhage
2. Inability to control bleeding
3. Injury to nasal mucosa leading to scarring and contraction
4. Inadequate opening of the nasal airway leading to failed extubation and persistent obstruction
5. Injury to the skull base (possible cerebrospinal fluid (CSF) leak) due to incorrect use of dilators

Surgical Technique

1. Choanal atresia repair
   a. Endoscopic technique
      - Afrin soaked pledgets placed in both nasal cavities; Inject 0.5% lidocaine with 1:200,000 epinephrine into posterior septum, lateral wall, and atretic plate
      - Patient suspended using a Dingman Mouth Retractor
      - A 120-degree rigid endoscope is placed in a palate retractor to provide direct endoscopic view of the posterior choana (Fig. 189.2A)
      - A 0-degree rigid endoscope is advanced into the nasal cavity to examine the atretic plate
      - Urethral sounds (starting at 8 to 10 French) are then advanced through the nasal cavity to puncture the atretic plate under direct visualization with the endoscope. Pressure directed inferomedially along atretic plate (Fig. 189.2B)
      - Anterior mucosal flaps can be created to preserve mucosa over the atretic plate (will help prevent circumference scarring). A sickle knife can be used to incise the mucosa, and then a Cottle elevator is used to elevate the mucosa (Fig. 189.3A and B). Some surgeons prefer to create a small posterior nasoseptal flap to protect the mucosa over the posterior choana. We do not find this technique to be useful in the neonate population due to limited space and a small nasal cavity to protect the nasal flap while repairing the atresia.
      - If the bony atresia is too thick to puncture with the urethral sounds, then a curved microdebrider diamond drill can be carefully inserted into the nasal cavity and used to create an opening in the posterior choana. Drilling inferiorly and medially is the safest location to start the atresia opening (Fig. 189.4A).
      - Once an opening has been created in the atresia plate, it is then progressively enlarged using larger urethral sounds.
      - Next, a 2.7-mm endoscope is advanced into the nasopharynx to visualize the vomer
      - A backbiter is then used to remove the posterior aspect of the hypertrophied vomer.
      - A microdebrider drill is then used to remove the additional bony vomer
      - Additional drilling of the lateral pterygoid plate/posterolateral sphenopalatine wall may be required to achieve an adequate opening
      - The mucosal flaps are then repositioned and an attempt should be made to cover any exposed bone

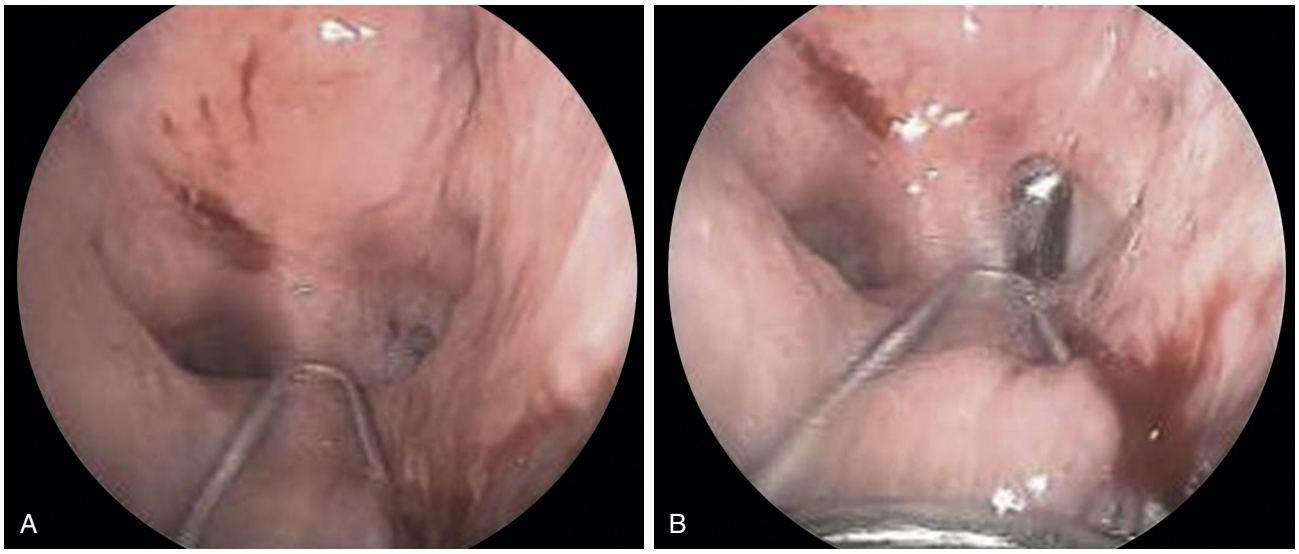

Fig. 189.2. A, Endoscopic view of nasopharynx/choanal atresia. **B,** Dilation with urethral sounds through atretic plate.

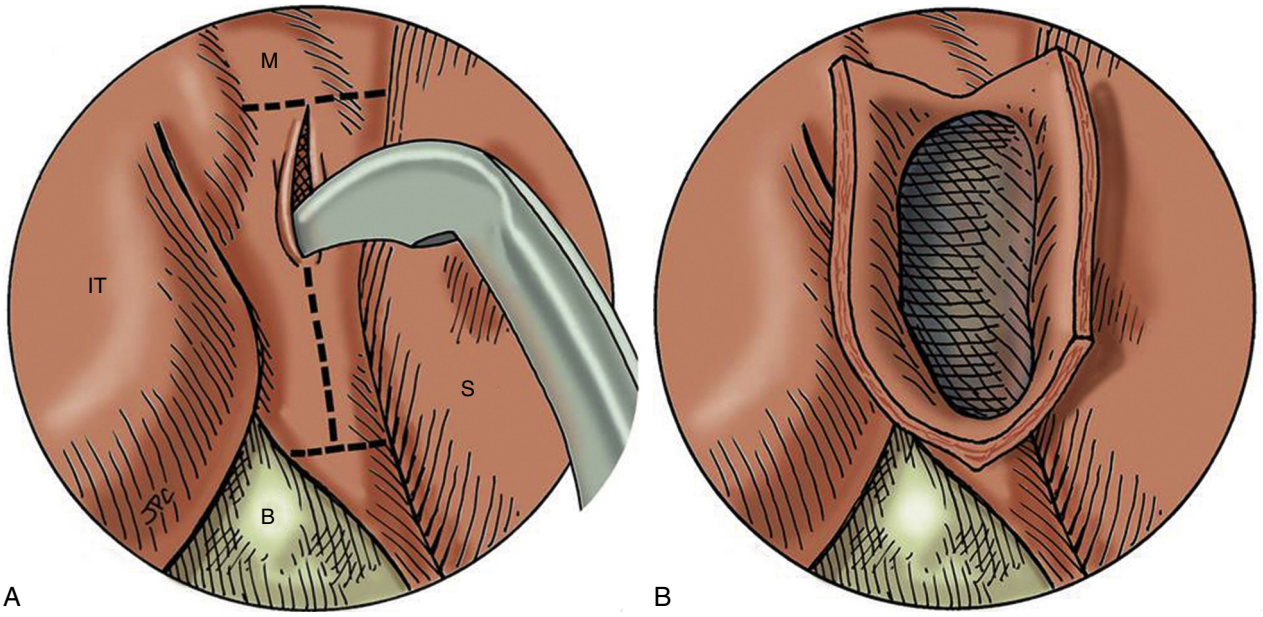

Fig. 189.3. A, Endonasal view of mucosal flap creation. Sickle knife used to incise mucosa. *B*, Bone; *IT*, inferior turbinate; *M*, mucosa; *S*, septum. **B,** Cottle elevator used to retract mucosa.

- Hemostasis is achieved with bipolar or suction cautery.
- Nasal cavity and nasopharynx are copiously irrigated with saline to remove all mucous, bone, and debris (Fig. 189.4B).
- Oxymetazoline placed in the nose bilaterally
- Patient extubated and taken to the neonatal intensive care unit (NICU) for postoperative monitoring

Note: Stent Placement: The surgeon may choose to place a nasal stent. A 3.5 mm ETT is cut so that the milled distal edge sits above the palate and the cut edge sites in the vestibule of the nose. One tube is placed in each side of the nose. A small piece of silastic can be placed on both sides of the caudal septum and then the stent is secured through the ETT and silastic pieces using a 4-0 nylon suture. The silastic protects the septum from pressure erosion. The nursing team is then taught to lift the tip of the nostril slightly to then insert the suction catheter through the endotracheal tube lumen. Some authors suggest using an oral-RAE right angle endotracheal tube, because it has a more natural downward curve that follows the nasal curvature of the nose. The timing of stent removal varies. It can range from 5 to 42 days. Most surgeons remove the stents within 7 to 21 days.

Many surgeons choose not to use stents due to the secondary damage they may create. They can damage the nasal mucosa, which then leads to granulation tissue, scarring, crusting, and impaired healing. This all leads to decreased nasal airway patency and possible revision surgery. Other complications such as alar injury, vestibular stenosis, and stent blockage can all occur. A recent meta-analysis[1] showed that success rates were similar with or without nasal stenting but that stents have more complications.

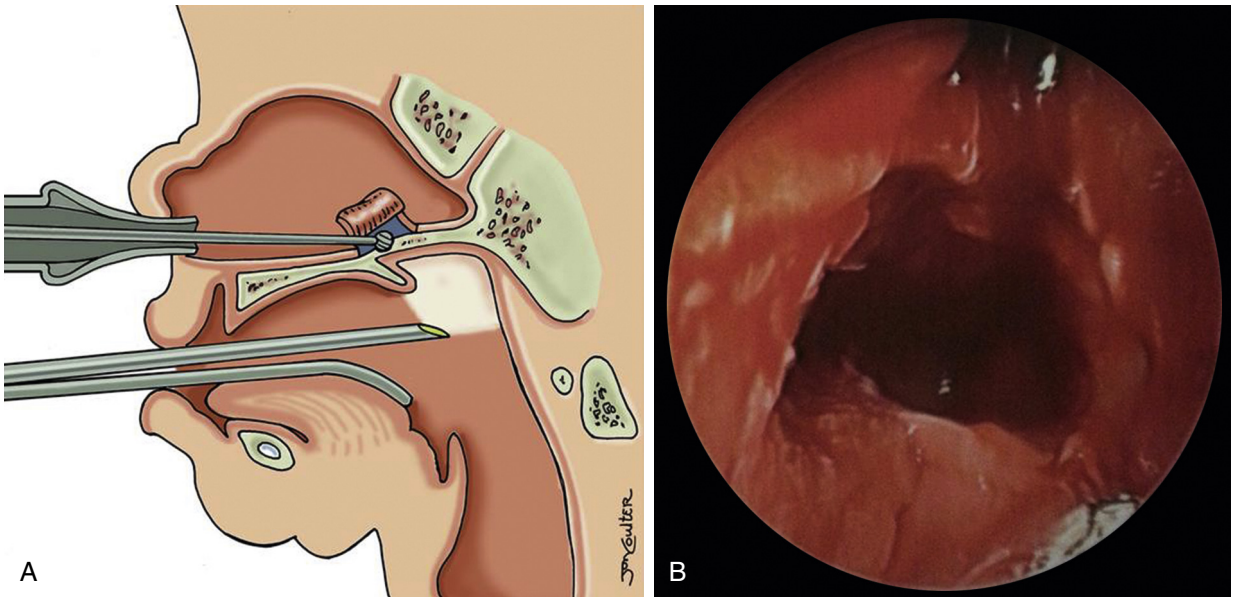

Fig. 189.4. A, Transnasal drilling of atretic plate under direct visualization through the endoscope. **B,** Transnasal endoscopic view of the nasopharynx immediately post operation.

b. Transpalatal Technique: indicated when the bony atretic plate is too thick to be punctured with a urethral sound or nasal stenosis does not allow the use of the endoscope within the nasal cavity
- Dingman mouth retractor placed and oral cavity suspended
- Palate injected with 0.5% lidocaine with 1:200,000 epinephrine
- Midline incision made through mucoperiosteum to create a "U" shaped mucosal flap based on the greater palatine vessels
- Mucoperiosteum undermined with Cottle elevator to the junction of the hard and soft palate.
- Care should be taken to preserve the greater palatine arteries—ligating both arteries will lead to necrosis/poor wound healing due to loss of blood supply to the soft palate
- Muscular aponeurosis and nasopharyngeal mucosa of soft palate is incised transversely
- Palate is retracted posteriorly and superiorly towards the nasopharynx
- Bone of the posterior 1/3 of the hard palate is removed with a rongeur until nasal mucosa can be identified
- Bony atresia plate and posterior 1/3 of the vomer is removed with a rongeur or a curette (Fig. 189.5A and B)
- Preserve nasal mucosal flap to prevent stenosis
- Performed under direct visualization; Can use laryngeal mirror to visualize the atretic plate
- Nasal stents placed bilaterally and sutured to the septum
- Palatal flap is returned to midline anatomic position and closed with 3-0 silk

Note: The transpalatal technique is not considered first line therapy since the widespread use of the endoscopic technique. It has a risk of fistula development, growth retardation of the palate/midface growth, flap necrosis, and a 50% risk of crossbite deformity. High arched palate deformity and need for orthodontic treatment is also seen in this surgical group. It is also associated with longer hospitalization and increased blood loss. It is often only recommended in patients >5 years of age after adequate growth of the palate has occurred.

2. PAS repair
1. Sublabial drill out procedure
- Nasal endoscopy is performed to evaluate the level of nasal obstruction
- The sublabial region is injected with 0.5% lidocaine with 1:200,000 epinephrine
- A needle tip bovie is then used to make a sublabial incision and release of the upper lip frenulum
- The incision is carried down through the bone and then the soft tissue over the maxilla is carefully elevated using a Freer elevator. The soft tissue is elevated superiorly over the nasal spine and this exposes the pyriform aperture bilaterally (Fig. 189.5C)
- The nasal mucosa over the pyriform aperture is then carefully dissected away from the anterior wall of the pyriform aperture using blunt dissection
- An otologic drill with a 1 mm diamond drill burr is then used to reduce the anterior wall of the pyriform aperture.
- Care is taken to avoid entering or injuring the adjacent posterior nasolacrimal duct.
- Hemostasis is obtained with oxymetazoline-soaked Gelfoam
- The sublabial incision is then closed with absorbable sutures (3-0 vicryl and 4-0 chromic).
- A V-Y advancement can be used to close the frenulum site and provide improved length of the upper lip.
- The inferior turbinates should be outfractured using a 2 to 3 mm Hegar cervical dilator or small butter knife to maximize the width of the nasal cavity.
- Short term nasal stenting can be performed bilaterally to help keep the anterior nasal cavity patent during the immediate postoperative window (3 to 5 days)

2. Dilation
- Oxymetazoline soaked pledgets are placed in both nasal cavities
- Nasal endoscopy with a flexible or rigid endoscope is attempted to identify the areas of stenosis
- Hegar cervical dilators and then used to slowly dilate the pyriform aperture and out fracture the inferior turbinates to provide maximal space in the nasal cavity
- Start with 2 mm dilator—using adequate lubrication, it is advanced through the pyriform aperture and into

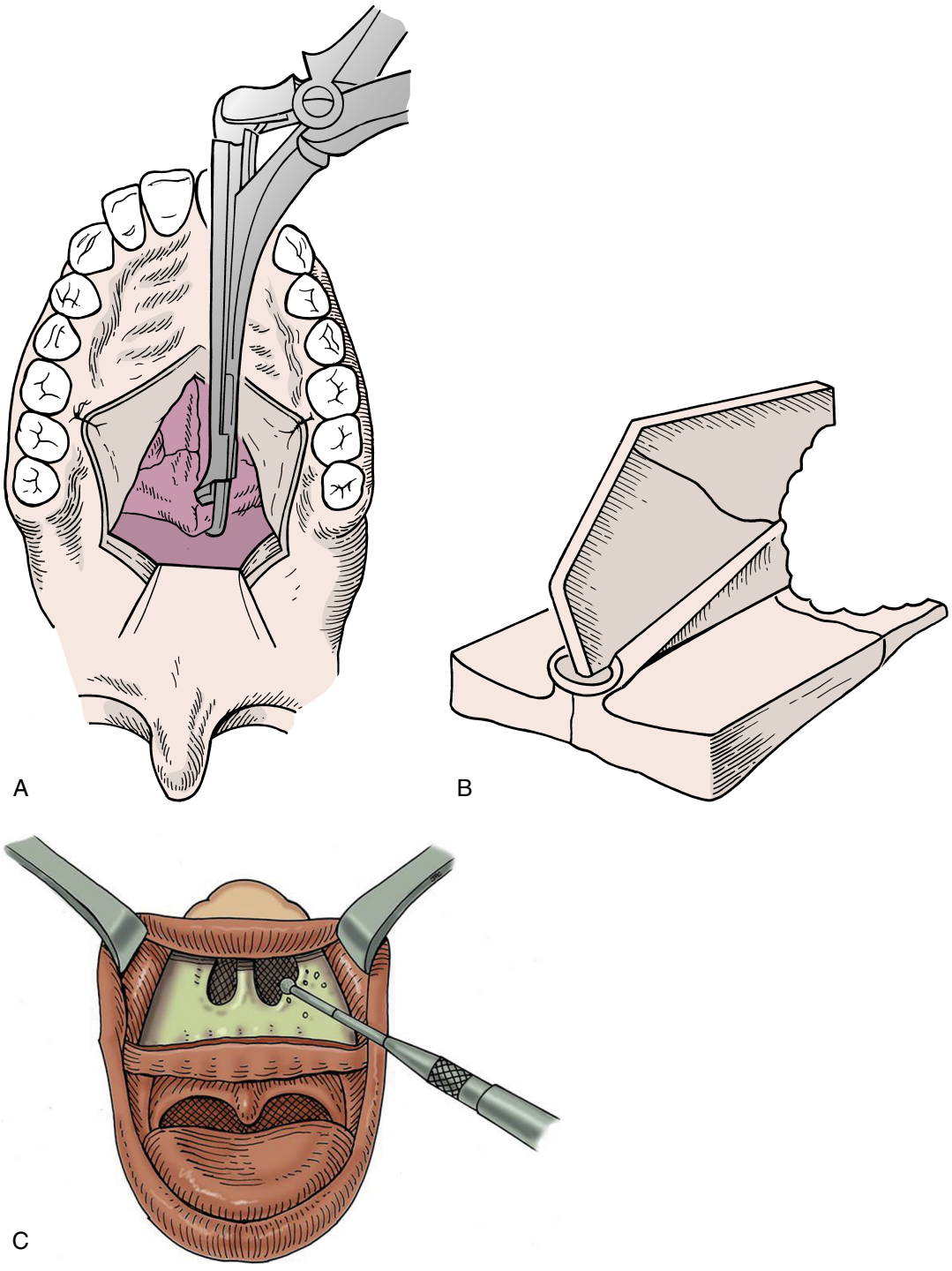

Fig. 189.5. A, A rongeur is used to remove the posterior aspect of the hard palate. **B,** Removal of a portion of the hard palate and vomer **C,** Sublabial drill-out procedure for pyriform aperture stenosis: Mucosa elevated and retracted away from pyriform aperture. A 1 mm diamond burr used to open the lateral wall of the pyriform aperture bilaterally.

the posterior nasal cavity. Care is taken not to advance the dilator past the nasopharynx and thus prevent any skull base damage
- Continue bilateral dilation from 2 mm up to 4 to 5 mm dilators.
- The nasal cavity is then suctioned free of all mucous and debris and the endoscope is then advanced into the nasopharynx to confirm an adequate nasal airway
- Patients are then extubated and observed in the neonatal ICU.
- They are continued on oxymetazoline for 5 days, nasal saline drops, nasal corticosteroids, and frequent suctioning to ensure adequate airway

Common Errors in Technique

1. Inadequate width of choana opening leading to re-stenosis
2. Inadequate drilling/removal of the vomer or pterygoid plate can lead to inadequate choanal opening
3. Failure to address the inferior turbinates in PAS can lead to surgical failure

POSTOPERATIVE PERIOD

Postoperative Management

1. If stent is present: apply ciprodex topical drops three times daily
   a. Q2 hour suctioning
   b. Saline spray Q2 hours
   c. Removal of stent at 5 to 21 days
2. If no stent is present: apply ciprodex topical drops three times daily
   a. Q2 hour suctioning
   b. Saline spray Q2 hours
3. Repeat nasal endoscopy, debridement, and possible balloon or ureteral catheter dilation within the first 7 days to remove crusting, granulations, and early scarring is essential in the non-stent group.
4. Prophylactic anti-GERD management—key risk factor that must be treated
5. Endoscopic surveillance Q2–3 weeks—under anesthesia and then office endoscopy once tolerated.
6. Repeat dilation as needed (urethral sound dilators)
7. Monitor weight gain and respiratory status
8. Management of comorbid medical conditions (CHARGE)
9. Revision surgery is more frequently required in bony atresia compared to mixed or membranous. Syndromic patients also have higher revision rates.
10. Mitomycin C has been used in the past to help prevent tissue regrowth and decrease revision rates. The literature does not currently support routine use of Mitomycin C. However, it should be considered in neonates.

Complications

1. Restenosis of choana: Risk factors: bilateral choanal atresia, pure bony atresia, associated congenital anomalies/syndromes, low body weight, age <10 days at surgical procedure all have higher rates of restenosis
2. Restenosis of pyriform aperture
3. Respiratory distress requiring intubation or other airway management
4. Poor weight gain/inability to feed
5. Nasal cavity stenosis
6. Long term—external nasal deformity

Alternative Management Plan

1. PAS: trial of medical management initially
2. Delayed surgical management of choanal atresia if other medical comorbidities do not allow immediate repair. Some patients may require tracheostomy for airway management until surgical repair.

DISCUSSION

Evidence-Based Medicine Question

Is stenting required postoperatively after repair of bilateral choanal atresia?

A recent meta-analysis of the published literature concluded that: success rates were similar with and without the use of nasal stents. The use of nasal stents can be associated with additional nasal complications. Also, the use of mitomycin C has not been proven as a success therapeutic adjunct in the postoperative management of choanal atresia.[1]

Editorial Comment

The evaluation, diagnosis, and treatment of choanal atresia and pyriform aperature stenosis are essential in all neonates who present with nasal obstruction. A complete evaluation including imaging and evaluation for comorbid conditions/syndromes is imperative to making appropriate management decisions for the patient. Timely relief of their nasal obstruction via noninvasive measures, dilation, or surgical repair can allow the neonate to grow and thrive. Close postoperative monitoring and consideration of other airway lesions will ensure of the best outcome for the patient.

Sukgi Choi

Access the review questions and additional sources list online at http://www.expertconsult.com

REFERENCES

1. Burrow TA, Saal HM, de Alarcon A, et al. Characterization of congenital anomalies in individuals with choanal atresia. Arch Otolaryngol Head Neck Surg 2009;135:543–547.
2. Newman JR, Harmon P, Shirley P, et al. Operative Management of Choanal Atresia: a 15-year experience. JAMA Otolaryngol Head Neck Surg 2013;139:71–75.
3. Strychowsky JE, Kawai K, Moritz E, et al. To stent or not to stent? A meta-analysis of endonasal congenital bilateral choanal atresia repair. Laryngoscope 2016;126:218–227.
4. Teissier N, Kaguelidou F, Couloigner V, et al. Predictive factors for success after transnasal endoscopic treatment for choanal atresia. Arch Otolaryngol Head Neck Surg 2008;134:57–61.
5. Gonik NJ, Cheng J, Lesser M, et al. Patient selection in congenital pyriform aperture stenosis repair—14 year experience and systematic review of literature. Int J Pediatr Otorhinolaryngol 2015;79:235–239.

REVIEW QUESTIONS

1. What other syndrome is associated with choanal atresia?
   a. Pierre-Robin sequence
   b. CHARGE syndrome
   c. Hemifacial microsomia
   d. Beckwith-Wiedemann syndrome

2. What other anomalies can be associated with PAS:
   a. Lateral incisor syndrome
   b. Neural tube defects
   c. Holoprosencephaly
   d. Down syndrome

3. What is the normal width of the pyriform aperture at birth?
   a. 4 to 6 mm
   b. 6 to 8 mm
   c. 8 to 10 mm
   d. >11 mm

4. What is the most common type of choanal atresia?
   a. Membranous
   b. Bony
   c. Mixed: Membranous-bony

5. Mitomycin C has been shown to decrease scarring and decrease restenosis rates in choanal atresia repair?
   a. True
   b. False

ADDITIONAL SOURCES

Wine TM, Dedhia K, Chi DH. Congenital nasal pyriform aperture stenosis: is there a role for nasal dilation? JAMA Otolaryngol Head Neck Surg 2014;140:352–356.

Merea VS, Lee AHY, Peron DL, et al. CPAS: surgical approach with combined sublabial bone resection and inferior turbinate reduction without stents. Laryngoscope 2015;125:1460–1464.

Wormald R, Hinton-Bayre A, Bumbak P, et al. Congenital nasal pyriform aperture stenosis 5.7 mm or less is associated with surgical intervention: a pooled case series. Int J Pediatr Otorhinolaryngol 2015;79:1802–1805.

Kinis V, Ozbay M, Akdag M, et al. Patients with congenital choanal atresia treated by transnasal endoscopic surgery. J Craniofac Surg 2014;25:892–897.

Carter JM, Lawlar C, Guarisco JL. The efficacy of mitomycin C and stenting in choanal atresia repair: a 20 year experience. Int J Pediatr Otorhinolaryngol 2014;78:307–311.

190 Midline Nasal Masses

Todd M. Wine

INTRODUCTION

Midline nasal masses and nasolacrimal duct cysts (NLDC) are pathologies that afflict infants and children. The pathophysiology of the midline nasal masses and NLDC is distinct, and the treatment of each of them is just as distinct. When a child presents with a mass near or within the nose, congenital nasal masses and NLDC are in the differential diagnosis.

NLDC are intranasal cysts occurring in the inferior meatus. NLDC occur when a dacryocystocele expands into the nasal cavity under the inferior turbinate. A dacryocystocele forms when there is distal obstruction of the valve of Hasner and proximal dysfunction of the valve of Rosenmeuller.[1] NLDC should be ruled out in any infant presenting with a dacryocystocele, dacryocystitis, or nasal obstruction.

Congenital midline nasal masses consist of multiple pathologies, but for the purposes of this chapter, I will discuss nasal dermoid cyst, glioma, and encephalocele, due to their similarities in anomalous embryogenesis of the anterior neuropore.[2,3] These masses can present as an external or intranasal mass, and there can be intracranial extension. Other lesions included in the differential diagnoses are tumor, hemangioma, and vascular malformation.

Nasal dermoid cyst is a congenital cyst that can occur externally anywhere from the tip of the nose to the glabella and internally, along the nasal septum, prenasal space, at the level of the skull base near the foramen cecum and crista galli, and intracranially. This is the most common midline nasal mass, and theoretical embryogenesis is related to failure of dural and dermal precursors to detach from one another, resulting in dermal elements becoming trapped. Intracranial extension of this mass occurs about 20% of the time.[4]

Glioma is also known as glial heterotopia. Gliomas are composed of neural tissue without direct intracranial connection, although they may connect to the intracranial space through a fibrous stalk.[2] These masses commonly occur near the glabella and can be midline or off midline externally. Externally, they can be smooth, noncompressible masses, but intranasally they can also occur as a pale mass.

Unlike nasal dermoid cysts or glial heterotopia, encephaloceles have a communication with the intracranial space. An encephalocele will contain cerebrospinal fluid, meninges, and neural tissue herniating through a defect in the skull base. This can result in an external or intranasal mass. Encephaloceles can occur through many different defects in the skull base. Frontonasal encephaloceles are those occurring via a defect in fonticulus frontalis, while nasoethmoidal encephaloceles protrude via the foramen cecum.[2] Other encephaloceles occur in various regions of the skull base.

Key Operative Learning Points

- Always assess the contralateral nasal cavity for an occult NLDC.
- Preoperative imaging is mandatory in the assessment of congenital nasal masses and allows for a more accurate surgical plan.
- A variety of approaches could be used in each mass encountered. Consider using the approach that best allows visualization, exposure, and minimization of morbidity. Sometimes a combination of approaches provides the best solution.
- Do not biopsy a midline nasal mass prior to imaging studies.

PREOPERATIVE PERIOD

History

- When was the mass recognized? How long has it been present? Most midline nasal masses will be noticed at birth but not necessarily. External nasal masses can be more easily seen, but even external nasal dermoid cysts can be present but escape notice by the parents. NLDC are located within the nasal cavity and will usually not present unless they obstruct the nasal cavity.
- What color is the mass?
- Is there any nasal obstruction or breathing problems?
- Is there difficulty feeding?
- Does the patient have epiphora, eyelid swelling, redness?
- Has there been any recent infection?
- Has there been any trauma to that area of the face?
- Is there an opening or pit in the skin? Has drainage from it been noticed?
- Is there any change to the mass induced by crying (i.e., increased intracranial pressure)?

Physical Examination

- NLDC
  - Facial examination: The facial examination will often be abnormal, especially if the infant is presenting with dacryocystitis. If there is no dacryocystitis, there can still be a mild abnormal swelling near the medial canthus of the eye.
  - Nasal examination: NLDC will be visualized in the inferior meatus. When it is associated with acute infection, the cyst can be more forceful and displace the inferior turbinate superiorly (Fig. 190.1).
  - Ocular examination: This is most important when there is an infected dacryocystocele. This can cause erythema and edema of the inferior eyelid, and a proper ophthalmologic examination is important to rule out other ocular pathology.
- Congenital nasal mass
  - Examination of the face: A mass in the face can often by missed by parents. It is important to look for a mass along the dorsum of the nose from the nasal tip to the glabella. Most often the mass will be in the midline, but paramedian locations can also occur. Hypertelorism can also occur. Discoloration of the lesion is more consistent with a glioma. A positive Furstenberg sign occurs if crying or occlusion of the jugular vein results in enlargement of the mass. This suggests that there is an intracranial communication related to the mass. The presence of a pit or sinus in the skin, with

or without a hair, suggests a nasal dermoid cyst is suspected (Fig. 190.2A and B).
- Examination of the nose: It is always important to make sure that there is no evidence of an intracranial portion of the mass. Some masses can be solely intranasal, some combined intranasal and extranasal, and some entirely extranasal.
- Examination of the oral cavity: In very large midline nasal masses, there can be extension of the mass into the oral cavity. Examine for a cleft in the hard or soft palate, as it could be an associated defect of the midline.
- Examination of the eyes: This is usually normal, but assessment for hypertelorism is important.

Imaging

- NLDC
  - Imaging studies are not warranted for most presentations of NLDC, as there will be a cyst visualized in the middle meatus in a patient presenting with nasal obstruction or dacryocystitis. If the presentation seems atypical, however, imaging with facial computed tomography (CT) or magnetic resonance imaging (MRI) is recommended.
- Midline nasal mass
  - Plain films: not indicated
  - Ultrasound: not indicated
  - Computed tomography scan of the face and brain: Computed tomography (CT) highlights the ossified bony anatomy and can also depict the mass. The anterior midline skull base is not ossified at birth, and interpretation of the integrity of the skull base requires knowledge of the normal ossification pattern and timing of the anterior skull base (Fig. 190.3).[2]
  - Magnetic resonance imaging of the face and brain: Magnetic resonance imaging (MRI) is the imaging modality of choice for frontonasal congenital masses. MRI differentiates tissue type better than CT, can more likely identify a tract, and can assess for concomitant intracranial anomalies.[2]

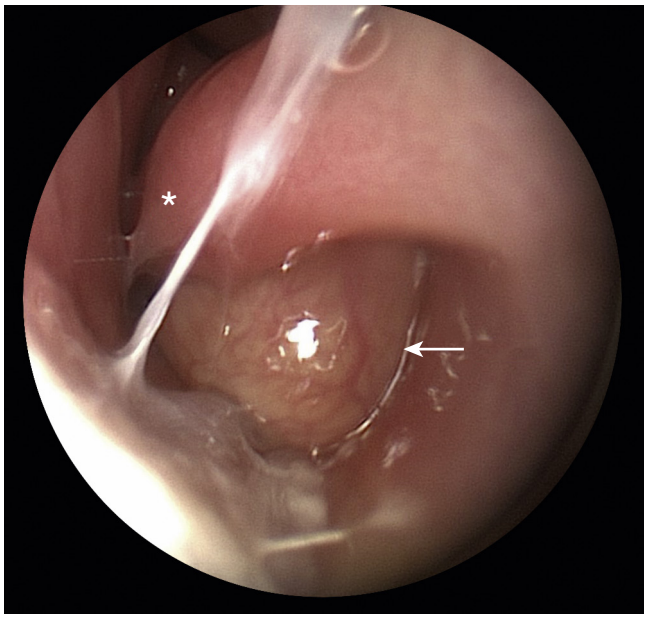

Fig. 190.1. Intranasal endoscopy demonstrating a large nasolacrimal duct cyst *(arrow)* in the inferior meatus causing superior-medial displacement of the inferior turbinate *(asterisk)*.

Indications

- NLDC: Once diagnosed, surgery is recommended.
- Nasal dermoid cyst: nasal mass that causes deformity and may carry the risk of meningitis if there is an intracranial connection
- Nasal glioma: nasal mass
- Nasal encephalocele: nasal mass carrying the risk of meningitis and progressive craniofacial deformity

Contraindications

- Severe medical comorbidities that prevent general anesthesia
- Active infection with/without meningitis for glioma, dermoid, or encephalocele

Preoperative Preparation

- NLDC: Consultation with an Ophthalmologist is recommended. This will allow concurrent probing of the lacrimal duct and the placement and management of lacrimal duct stents.
- Midline nasal mass: Preoperative imaging is mandatory, and this allows proper surgical planning. The preoperative

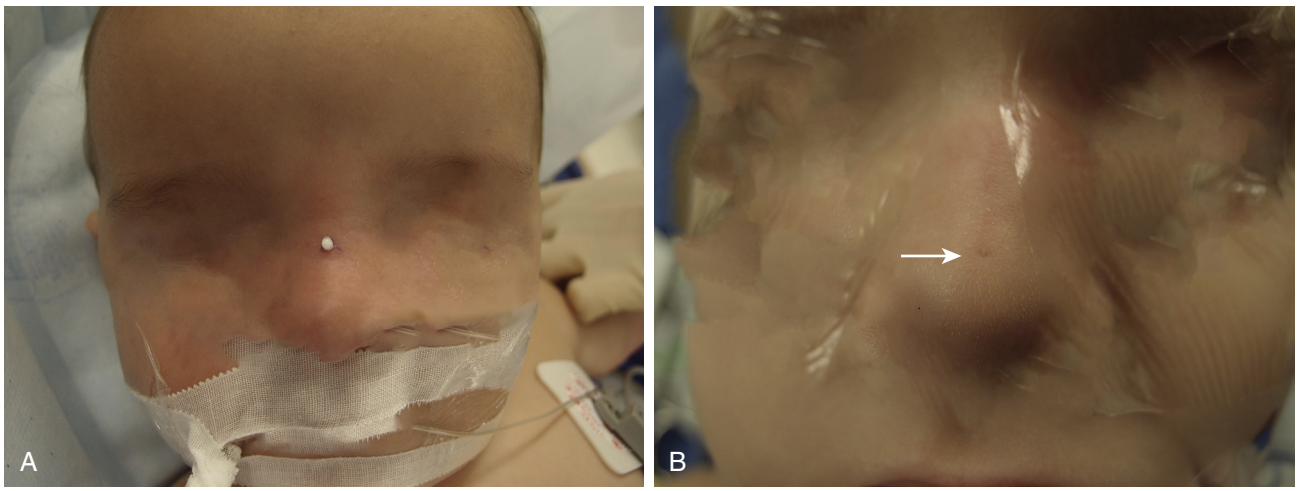

Fig. 190.2. A, Preoperative photograph of child with active drainage from the midline sinus tract of a nasal dermoid cyst. **B,** Small punctum noted near nasal tip *(arrow)*.

imaging guides the approach and the extent of surgery. As such, consider consultation with neurosurgery and craniofacial surgery as indicated.

OPERATIVE PERIOD

Anesthesia

- NLDC: General endotracheal anesthesia
- Midline nasal mass: General endotracheal anesthesia

Positioning

- Patients are placed in the supine position.

Perioperative Antibiotic Prophylaxis

- NLDC: not indicated
- Midline nasal mass: If there is an external skin incision only and the case remains a clean procedure (not clean-contaminated), antibiotic prophylaxis is not necessary. The risk of clean surgeries in the head and neck (particularly if not related to cancers) having a surgical wound infection is less than 1%.[5] If there is an external incision only and craniotomy, cefazolin or clindamycin is recommended.
- Midline nasal mass with intracranial extension: If exposure to intranasal/sinus cavity and craniotomy, prophylaxis is recommended. Ampicillin-sulbactam or cefazolin (or cefuroxime) plus metronidazole.[5] Clindamycin is an alternative for the aerobic and anaerobic portion of this coverage in those with β-lactam allergy.

Monitoring

- NLDC: No monitoring is needed.
- Midline nasal mass without intracranial involvement: No monitoring is necessary.
- Midline nasal mass with intracranial involvement: No monitoring is necessary.

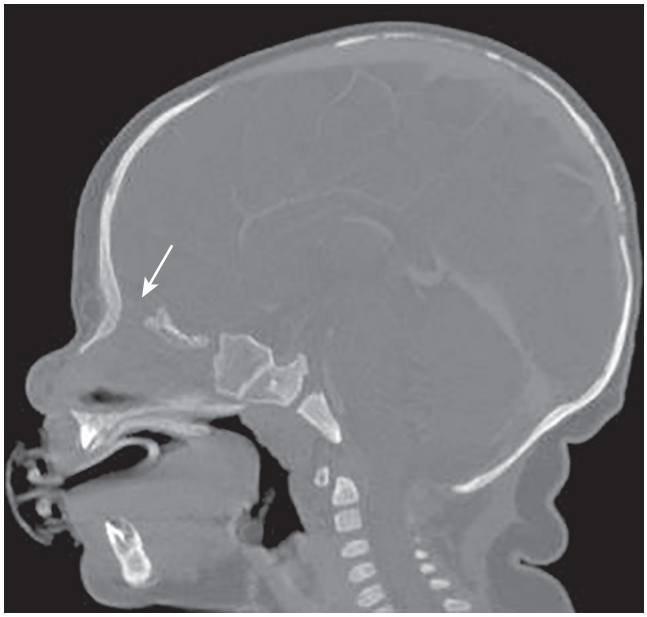

Fig. 190.3. Computed tomography scan of the skull base in a child with a congenital nasal mass. *Arrow* points to the region of the anterior skull base that is not ossified.

Instruments and Equipment to Have Available

- NLDC:
  - Pediatric sinus or otology instrument set
  - Microdébrider equipped with 3 mm sinus microdébrider or an inferior turbinate blade
  - Lacrimal duct probes: Probing the lacrimal duct can confirm the location of the cyst and aid in adequate removal of the cyst. It is more important to consider this in cases of dacryocystitis. This portion of the surgery will often be performed by an Ophthalmologist.
  - Nasolacrimal duct stent: This may be recommended by the Ophthalmologist.
- Nasal dermoid cyst without intracranial extension or nasal glioma on the surface of face/nose:
  - Facial plastics instruments are necessary if an external incision is required. This would include an open septorhinoplasty set.
  - Endoscopic sinus instruments including zero- and 30-degree endoscopes and sinus instruments
  - Image guidance systems could also be considered, depending on the case.
- Nasal dermoid cyst with intracranial extension:
  - Facial plastic surgery set
- Nasal encephalocele:
  - Facial plastics instruments are necessary for the external approach.
  - If the encephalocele is large, and an osteotomy is required, then a sagittal saw, piezoelectric system is needed.
  - If a craniotomy is required, a neurosurgical set, including a saw and plating system, is necessary.
- Intranasal midline mass without intracranial extension:
  - Rhinoplasty set
  - Endoscopic sinus set

Key Anatomic Landmarks

- NLDC:
  - Inferior meatus: The nasolacrimal duct drains into the space between the inferior turbinate and the lateral nasal wall. An NLDC will often fill this space and will herniate from this space into the nasal cavity and often elevate the inferior turbinate superiorly (Fig. 190.1). An NLDC can cause varying degrees of nasal obstruction.
  - Valve of Rosenmueller: This is the proximal valve between the canaliculi and the lacrimal sac. This valve is dysfunctional in dacryocystocele but not in routine nasolacrimal duct obstruction commonly seen in newborns.
  - Valve of Hasner: This is the distal valve of the nasolacrimal duct. Obstruction at the level of this valve causes engorgement of the nasolacrimal duct and sac and is the cause of nasolacrimal duct obstruction often seen in infancy. If this occurs with dysfunction of the valve of Rosenmueller, a dacryocystocele can form.[1]
- Midline nasal mass with intracranial extension:
  - Prenasal space: This is a funnel-shaped dural projection in the midline. It extends from the crista galli and nasal cartilage to the posterior aspect of the nasal bones (Fig. 190.4).[2] This space is often traversed by a fibrous tract that extends to the foramen cecum or intracranially through the foramen cecum.
  - Foramen cecum: This is an embryologic communication that extends from the intracranial region into the prenasal space to what becomes the skin over the dorsum of the nose. The mass can extend through this region (Fig. 190.5).
  - Fonticulus frontalis: Transient fontanelle between the inferior frontal bone and the nasal bones. This is an embryologic space that should become obliterated, but in



Fig. 190.4. Sagittal computed tomography scan of the face highlighting the prenasal space highlighted by an *arrowhead*.

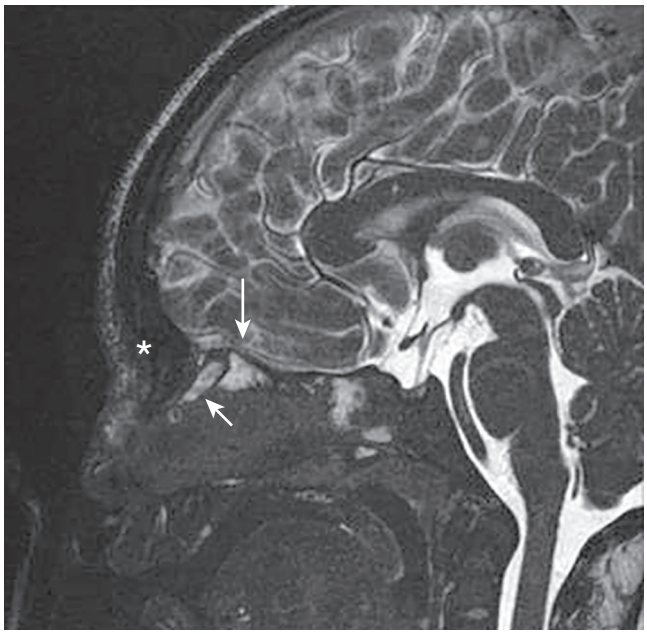

Fig. 190.5. Sagittal magnetic resonance imaging of the face demonstrating the extension of the mass *(small arrow)* through the foramen cecum. *Large arrow* points to the crista galli. The nasal bones are represented by the *asterisk*.

some cases of a nasal mass, an intracranial connection can occur through this space (Fig. 190.6A and B).
  - Nasal bones: In some nasal masses, the intracranial tract will extend through the prenasal space under the nasal bones heading toward the foramen cecum. Following the tract to the intracranial space may require mobilization of the nasal bone to allow better visualization.
  - Crista galli: A bifid crista galli can signify that there is a nasal dermoid cyst present at that location.
- Nasal glioma: Similar to midline nasal mass with a possible tract extending to the foramen cecum or the fonticulus frontalis. The anatomy will be varied based on the particular mass.
- Nasal encephalocele: The importance of the anatomic landmarks will vary based on the location of the defect in the skull base associated with the encephalocele, but the anatomic concepts listed previously apply. Encephaloceles are defined by the location of the defect in the skull base. Frontonasal encephaloceles will extend through the fonticulus frontalis into the region of the glabella, while frontoethmoidal encephaloceles occur through the foramen cecum and will extend into the prenasal space and then present on the dorsum of the nose or intranasally.[2]

Prerequisite Skills

- NLDC: Intranasal examination and surgery. Endoscopic skills are helpful.
- Midline nasal masses: The skills necessary are varied and are dependent on the approach used to remove the mass.
  - Endoscopic surgery skills are necessary for any intranasal portion of the mass. Endoscopic surgery skills are also helpful when dissecting in the prenasal space or assessing the facial side of the skull base.
  - Open rhinoplasty and lateral rhinotomy skills: Open rhinoplasty is a good surgical approach to masses of the nose and is particularly well suited for masses without an external sinus and for masses that are more distal in their location on the nose. Lateral rhinotomy can be helpful in certain circumstances for similar reasons.
  - Bifrontal craniotomy: This is essential for the intracranial portion of a nasal dermoid cyst or for encephaloceles.
  - Skull base reconstruction. This is always necessary when there is a defect of the skull base, which is present with every encephalocele and in those nasal dermoid cysts with intracranial extension. Reconstruction of the skull base depends on the technique used to extirpate the intracranial portion of the mass.
  - Craniofacial reconstruction: In more severe cases of frontonasal encephalocele, correction of the midline defect may require more extensive craniofacial procedures and manipulation of the anterior craniofacial skeleton.

Operative Risks

- NLDC:
  a. Recurrence, injury to nasolacrimal duct, scar formation
- Midline nasal mass: recurrence, scar, infection, bleeding, anosmia, cerebrospinal fluid leak, meningitis, encephalitis, encephalomalacia, and stroke

Surgical Technique

The surgical technique used to treat NLDC and other midline nasal masses is dissimilar. Most NLDC are addressed in a routine manner. The other congenital nasal masses will require a more individualized approach to their surgical treatment based on physical examination and preoperative imaging. The surgical approaches include transcutaneous alone, intranasal alone, combined transcutaneous and intracranial, and combined transcutaneous/intranasal and intracranial. Despite having numerous variations, there are key principles that can help frame the understanding of these varied procedures.

- NLDC: The surgical treatment of NLDC features marsupialization of the NLDC.[1,6]
  - Topical vasoconstriction with oxymetazoline is performed. This allows mucosal decongestion and better visualization of the anatomy and pathology of the nasal cavity.

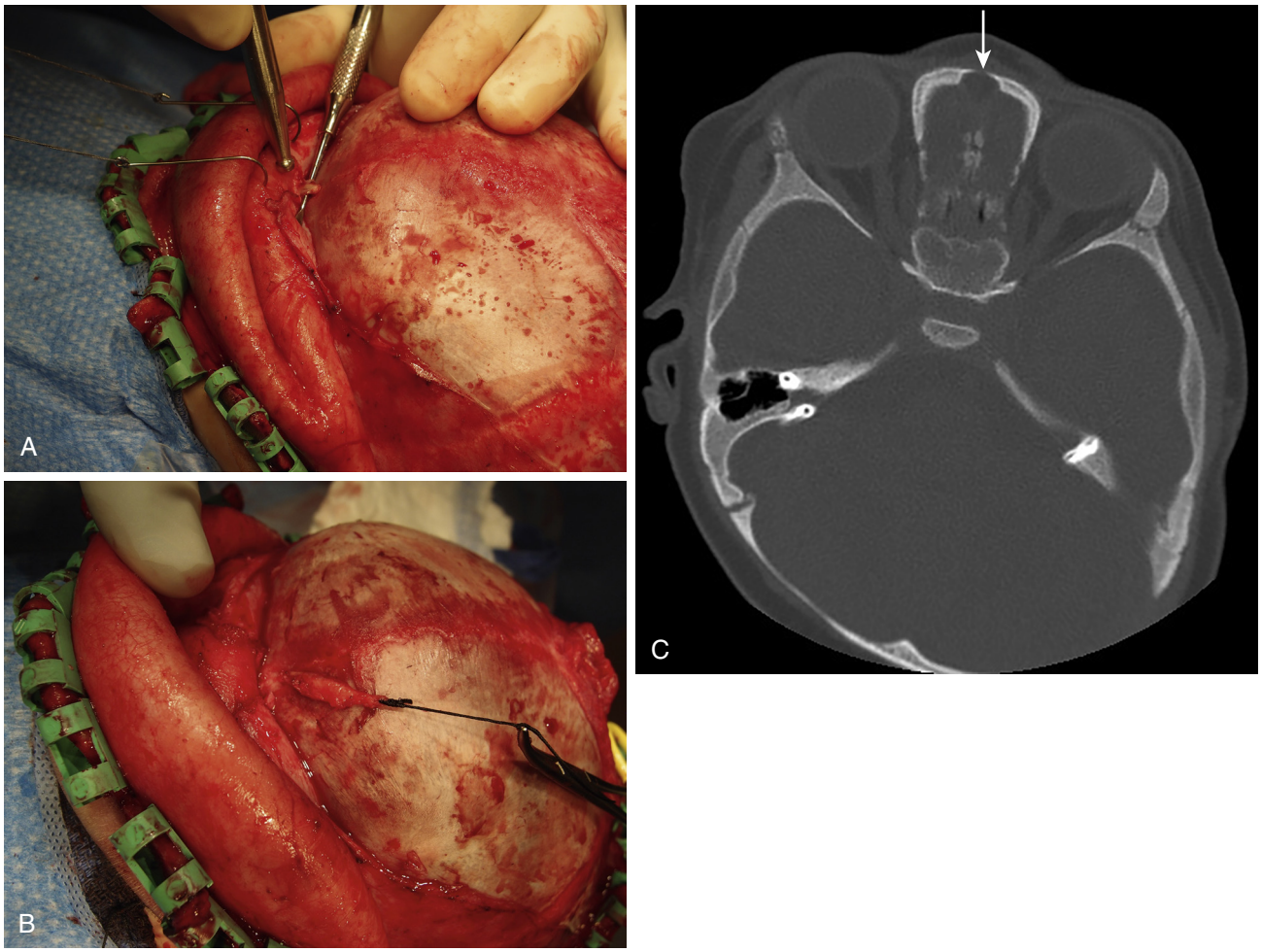

Fig. 190.6. A, Photograph of a dermoid cyst involving the skin and dermis and traversing through a defect located at the fonticulus frontalis. **B,** Photograph of a dermoid cyst with a suture tied to the distal aspect. **C,** Computed tomography scan of the face demonstrating the defect *(arrow)*.

- The nasal cavities are examined using bilateral nasal endoscopy, which allows assessment of the NLDC. Even in the setting of unilateral NLDC, contralateral nasal endoscopy is recommended to evaluate for asymptomatic NLDC.
- Marsupialization of the NLDC is performed. This can be carried out with 45-degree up Blakesley forceps, small cup forceps, or a microdébrider with 2-mm turbinate blade or smallest sinus blade (Video 190.1).
- Probing of the lacrimal duct. This is performed by the ophthalmologist before, during, and/or after marsupialization of the NLDC. It should always be performed following marsupialization, as it can allow identification of tissue that will benefit from further débridement (see Video 190.1).
- Irrigation of the nasolacrimal duct
- Placement of the nasolacrimal duct stent is determined by the ophthalmologist (Fig. 190.7).

- Nasal dermoid cyst with a cutaneous sinus tract:
  - A fusiform incision is placed around the sinus. Alternatively, consideration can be given to using a smaller incision around the fistula (to minimize the scar on the nasal dorsum) and dissecting the dermoid cyst through an open rhinoplasty or lateral rhinotomy approach. Inject the planned incision site with lidocaine with epinephrine.
  - Through this incision, elevate skin flaps allowing dissection of the underlying dermoid cyst. Take care to avoid rupturing the cyst wall.
  - Dissection of the cyst. If there is no evidence of a deeper tract or intracranial tract, remove the cyst in its entirety by circumferential dissection.
  - Irrigate and close the incision using standard facial plastic wound techniques for skin closure.
- Nasal dermoid cyst with cutaneous sinus and deeper tract extending toward the skull base or intracranially:
  - Complete the steps listed previously.
  - At the deeper aspect, dissect the tract toward the skull base. Preoperative imaging may allow planning of the dissection to occur in the direction of the foramen cecum or the fonticulus frontalis (Fig. 190.6A).
    1) If the dissection takes place in the prenasal space, disarticulation of the nasal bones will allow better exposure of the tract toward the foramen cecum. The use of endoscopes can also be helpful in this situation, since the external view is limited. Once the skull base is reached, the external component is excised. If a residual tract extends intracranially, proceed with the operative plan for the intracranial component. Consider frozen section pathology analysis of residual tissue at/on the skull base. This provides more certainty that there is no further intracranial portion.

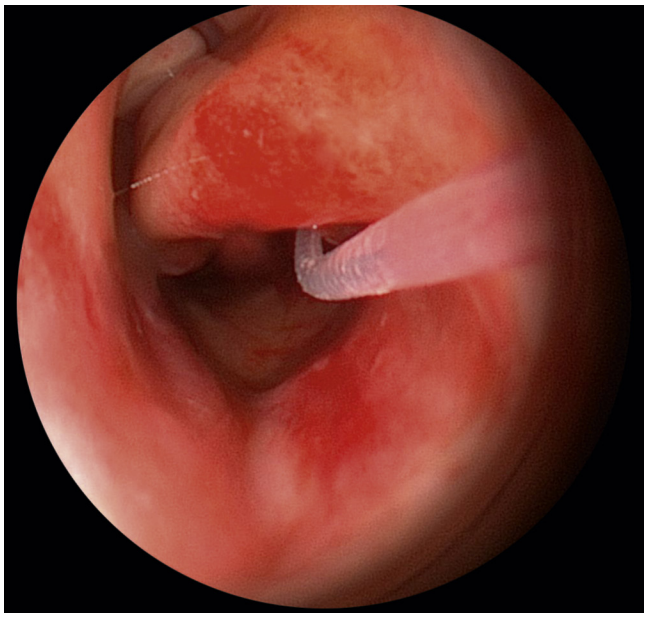

Fig. 190.7. Endoscopic placement of the stent following removal of a nasolacrimal duct cyst.

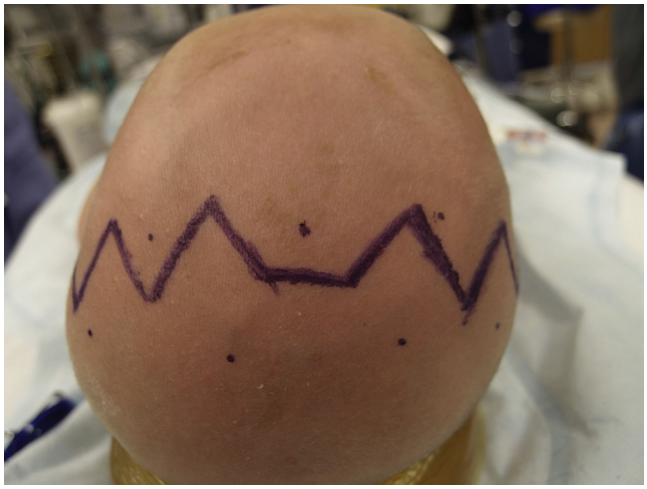

Fig. 190.8. Nonlinear bicoronal incision is used.

2) If the dissection of the tract extends toward the fonticulus frontalis, follow the tract toward the defect in the frontal bones, place a suture ligature around the tract as it enters the intracranial space, and excise the external cyst and tract.

- Intracranial component: The intracranial component has classically been addressed through a bifrontal craniotomy performed by a neurosurgeon. A nonlinear incision (Fig. 190.8) should be used for a bifrontal craniotomy incision as the resultant scar and alopecia will be less noticeable. The frontal lobes are able to be retracted to allow visualization of the cranial defect (Fig. 190.9). Once the neurosurgeon removes the intracranial portion, inspect the communication from the intracranial space and external wound for evidence of any residual cyst. Thoroughly irrigate the wound. Repair of the skull base is performed as indicated.
  1) If an intracranial portion exists, the chief alternatives to frontal craniotomy are more direct approaches to the skull base. These include endoscopic, direct excision, subfrontal craniotomy, and direct craniotomy through a small window osteotomy.[7-10] Use of these approaches requires the ability to address CSF leak, repair dural defects, and reconstruct skull base defects via this extended external approach. The primary advantages to these approaches are potentially less neurologic morbidity and avoidance of a large bifrontal craniotomy incision.
  - Close the external portion of the incision using standard facial plastic wound closure techniques.
- Glioma in an external location:
  - Plan the excision of the mass to occur using an open rhinoplasty, lateral rhinotomy, or direct incision over or near the lesion. Consider the cosmetic outcome of the scar and the possibilities of complete excision of the mass when selecting a technique. Using an incision that is not along the nasal dorsum helps adhere to the subunit principles of external nasal incisions. If feasible, consider an endoscopic approach.
  - Circumferential dissection of the glioma and the tract is performed, and the specimen is removed en bloc.
  - Close the wound using standard facial plastic wound closure techniques.
- Nasal encephalocele:
  - See the previous section on intracranial components. With encephaloceles, there can be a much larger bony skull base defect and more significant effect of the mass on the craniofacial skeleton. As such, removal of the encephalocele is only part of the procedure. Should a very large encephalocele be present, craniofacial reconstruction is part of the procedure.
- Intranasal midline nasal mass:
  - Endoscopic intranasal techniques, open rhinoplasty, or midface degloving techniques may all be appropriate. With the advancement of endoscopic anterior skull base surgery, consider the endoscopic approach to intranasal congenital midline nasal masses.
    1) If there is an intracranial portion, this can be addressed with endoscopic techniques or standard bicoronal craniotomy.

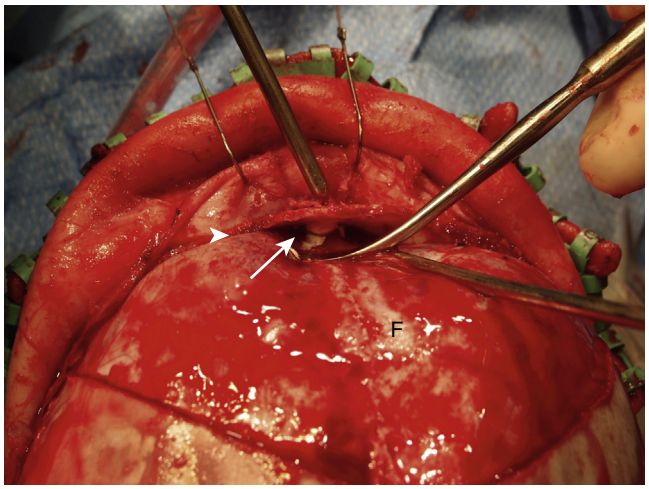

Fig. 190.9. The intracranial portion of the dissection is shown with retraction of the frontal lobes. *Arrow* points to dermoid extending through the frontal defect at fonticulus frontalis. *Arrowhead* points to the margin of the frontal bone osteotomy. *F* indicates the frontal lobe.

Common Errors in Technique

- NLDC:
  - Failure to inspect an asymptomatic contralateral side could lead to a symptomatic NLDC that could have been addressed under the same general anesthetic.

- Failure to adequately marsupialize the cyst
- Midline nasal masses:
  - Inadequate exposure of the tract extending to the skull base. This may compromise dissection of the tract. If dissecting in the prenasal space, better exposure can be achieved by disarticulating the nasal bones. Consider the use of nasal endoscopes when following the tract in order to aid with exposure.
  - Dissection of the tract through an external incision that is too small can lead to inadvertent cutaneous tear of the skin of the nasal dorsum, converting a linear scar to an irregular or T-shaped scar.

POSTOPERATIVE PERIOD

Postoperative Management

- NLDC:
  - Use saline drops to help prevent crusting in the nasal cavity. This will help the infant continue to have good nasal respiration.
  - Continue antibiotics if there was an infected dacryocystocele.
  - Postoperative pain is not severe, and usually acetaminophen is sufficient. Narcotics are not usually necessary.
- Midline nasal mass:
  - Recommend local wound care depending on the wound closure technique.
  - Control pain using acetaminophen as first-line therapy. Further pain control should be using narcotic at low doses, unless the infant is older than 6 months and ibuprofen can be given more safely.

Complications

- NLDC:
  - Epistaxis that can quite easily be controlled by topical decongestion and/or oxymetazoline or phenylephrine-soaked nasal pledgets if needed
  - Recurrence of cystic intranasal swelling
  - Injury to the nasolacrimal duct causing epiphora
- Midline nasal masses:
  - Hemorrhage. This could occur externally, intranasally, or intracranially.
  - Wound infection
  - Widened scar
  - Cerebrospinal fluid leak
  - Meningitis
  - Stroke
  - Encephalomalacia
  - Recurrence

Alternative Management Plan

- NLDC: If the infant is tolerating feedings, breathing well, and without acute dacryocystitis, it may be tempting to observe for resolution of the cyst. This is unlikely to treat the cyst and would likely delay the recommended marsupialization.
- Midline nasal mass with intracranial communication. Alternatives to surgical excision of a midline nasal mass depend on the nature of the mass. If there is an intracranial component to the mass, the only realistic alternative to proceeding with surgery as soon as possible is to educate the family that delaying surgical repair places their child at risk for meningitis and its concomitant morbidities and potential for mortality.
- Midline nasal mass without intracranial extension: Medical observation is reasonable, assuming there is no significant risk for intracranial infection. This occurs most commonly after initial diagnosis and workup, particularly if the infant is very young. In this age group, waiting until the patient is 18–24 months old may help decrease some of the perioperative risks. Waiting does carry the potential risk of further enlargement of the mass and disfigurement of the native craniofacial structures.

DISCUSSION

Evidence-Based Medicine Question

What is the recommended first-line antimicrobial prophylaxis for excision of a nasal dermoid without intracranial or intranasal extension?

Surgical antibiotic prophylaxis has guidelines outlining proper usage.[5] The guidelines account for the location of the surgery and the classification of the wound created. Excising a midline nasal mass could be either a clean wound or a clean-contaminated wound. If the wound breaches the nasal epithelium, the wound classification would be clean-contaminated and comparable to rhinoplasty or septoplasty in terms of risk of infection. If there is intracranial extension of the mass, the wound classification does not change, but the location of the tissue includes the intracranial space, and thus new consideration is required.

Excising a dermoid cyst or glioma (neither with intranasal or intracranial extension), surgical antibiotic prophylaxis is not needed, as it is a clean wound within the head and neck.[5] In the head and neck, a clean wound has a very low rate of infection (<1%).

If the midline nasal mass extends to involve the nasal mucosa, the use of prophylaxis is harder to determine. Traditionally, antibiotics are given for clean-contaminated procedures of the head and neck, but they are not routinely given for septoplasty and tonsillectomy. Since no literature specifically addresses midline nasal masses, individual judgment is required. First-line therapy for clean-contaminated wounds in the head and neck are cefazolin plus metronidazole or ampicillin-sulbactam.

If the mass extends into the intracranial space, antibiotic prophylaxis is unequivocally recommended.[5] Typically, prophylaxis for a craniotomy involves coverage of typical skin flora (i.e., cefazolin). If the wound is clean-contaminated due to the nasal cavity, it is reasonable to broaden the coverage to include gram-positive and gram-negative bacteria (cefazolin + metronidazole or ampicillin-sulbactam).[5]

Editorial Comment

In evaluating a child with a midline nasal mass, one must avoid biopsy of the mass prior to imaging studies, which demonstrates a lack of intracranial extension. CT scan and MRI are complementary, and thus obtaining both studies is often ideal for evaluation. There have been significant improvements in surgical instruments, including endoscopes, powered instrumentation, and image guidance, which have facilitated surgical excision of these lesions. Many of the midline masses can be excised without an external scar, by using the external rhinoplasty or facial degloving approach and endoscopes. Close collaboration with our neurosurgical colleagues is crucial in addressing the intracranial extensions of these lesions. A surgeon must keep in mind that the first excision offers the best chance at a complete excision. Finally, meticulous attention is needed in reconstructing the skull base in order to prevent serious postoperative complications.

Sukgi Choi

Access the review questions and additional sources list online at http://www.expertconsult.com

REFERENCES

1. Wong R, VanderVeen D. Presentation and management of congenital dacryocystocele. Pediatrics 2008;122:e1108–e1112.
2. Hedlund G. Congenital frontonasal masses: Developmental anatomy, malformations, and MR imaging. Pediatric Radiol 2006;36: 647–646.
3. Sessions RB. Nasal Dermal Sinuses—new concepts and explanations. Laryngoscope 1982;92:1–28.
4. Hanikeri M, Waterhouse N, Kirkpatrick N, et al. The management of midline transcranial nasal dermoid sinus cysts. Brit J. Plastic Surgery 2005;58:1043–1050.
5. Bratzler DW, Dellinger EP, Olsen KM, et al. Clinical practice guidelines for antimicrobial prophylaxis in surgery. Am J Health-Syst Pharm 2013;70:195–283.
6. Friedman N, Luck M, Scapa V. Excision of congenital nasolacrimal duct cyst with powered instrumentation. Laryngoscope 2011;121:135–136.
7. Cheng J, Kazahaya K. Management of pediatric nasal dermoids with intracranial extension by direct excision. Otolaryngol Head Neck Surg 2013;148(4):694–696.
8. Heywood RL, Lyons MJ, Cochrane LA, et al. Excision of nasal dermoids with intracranial extension – anterior small window craniotomy approach. Int J Pediatr Otorhinolaryngol 2007;71(8):1193–1196.
9. Goyal P, Kellman RM, Tatum 3rd SA. Transglabbellar subcranial approach for the management of nasal masses with intracranial extension in pediatric patients. Arch Facial Plast Surg 2007;9:314–317.
10. Adil E, Robson C, Perez-Atayde A, et al. Congenital nasal neuroglial heterotopia and encephaloceles: An update on current evaluation and management. Laryngoscope 2016;126:2161–2167.

REVIEW QUESTIONS

1. Which statement best describes the underlying valvular malfunction that is necessary to create an NLDC?
   a. The distal valve of Hasner is obstructed, and the proximal valve of Rosenmueller is dysfunctional often creating a functional or mechanical obstruction
   b. The distal valve of Hasner is obstructed, and the proximal valve of Rosenmueller is functioning normally.
   c. The valve of Hasner is normal, and the proximal valve of Rosenmueller has a functional obstruction.
   d. Both valves are normal, and the cyst occurs due to an anatomic abnormality of the inferior meatus and inferior turbinate.

2. What is the proper terminology referring to the physical examination finding that the midline nasal mass does not increase in size with internal jugular vein occlusion or crying?
   a. Positive Tullio phenomenon
   b. Negative Hennebert sign
   c. Positive Histelberger sign
   d. Negative Furstenberg sign

3. What imaging study is indicated for a patient presenting with dacryocystitis and evidence of a cyst in the inferior meatus?
   a. MRI face
   b. CT face
   c. Combine CT and MRI face
   d. No imaging study is indicated

4. What is the name of the space that is directly posterior to the nasal bones, through which a tract can extend from the dorsum of the nose to the foramen cecum?
   a. Fonticulus frontalis
   b. Cribriform plate
   c. Prenasal space
   d. Fovea ethmoidalis

5. In which of the following pathologies is frozen section analysis during the surgery potentially helpful?
   a. Dissection of encephalocele
   b. Dissection of glioma
   c. Dissection of tract of nasal dermoid cyst toward the skull base
   d. Marsupialization of the NLDC

ADDITIONAL SOURCES

Johnson JT, Wagner RL. Infection following uncontaminated head and neck surgery. Arch Otolaryngol Head Neck Surg 1987;113:368–369.
Pinheiro-Neto CD, Snyderman CH, Fernandez-Miranda J, et al. Endoscopic endonasal surgery for nasal dermoids. Otolaryngol Clin North Am 2011;44:981–987.

191 Adenoidectomy

Kitirat Ungkanont

INTRODUCTION

The adenoid is a part of the Waldeyer's ring of lymphoid tissue, which consists of palatine tonsil, adenoid or pharyngeal tonsil, tubal (eustachian) tonsil, and lateral pharyngeal band. The adenoid is a single, lobulated lymphoid tissue located on the roof of the nasopharynx. The entire nasopharynx is lined by respiratory epithelium, which covers the adenoid and the eustachian tube to the tympanic cavity. There are variations in shape and size of the adenoid, which can occupy some part of the nasopharynx or fill the entire nasopharyngeal cavity and obstruct the view of the choanae. The adenoid is the lymphatic tissue without the afferent lymphatic channel. The efferent drainage is to the retropharyngeal lymph nodes to the upper deep cervical lymph nodes and posterior triangular lymph nodes.

Adenoid tissue consists mainly of lymphocytes. The percentage of adenoid lymphocytes is highest in children age 0 to 5 years (about 75%), and it decreases with time, with significant decrease in children after 10 years of age.[1] The subpopulations of lymphocytes are approximately 50% B cells and 30% T cells. The adenoid is considered to be the gatekeeper of the upper respiratory tract, performing both protective and immunologic function. The microorganisms entering the airway are presented as antigens to the adenoid. The lymphoid cells in the adenoid are then stimulated, resulting in continuous immunologic reactions. B cells are transformed into plasma cells that produce antibodies. T-helper cells stimulate B cells in the transforming process and cytotoxic T cells (CD8) kill antigen by releasing cytokines. The adenoid and the tonsils are involved in both local and systemic immunity. In addition, the adenoid is different from the tonsils in that it produces local mucosal antibody, secretory IgA, with the secretory component that does not exist in the tonsil. Adenoid surface secretion contains antibody-secreting cells, which produce IgG and IgA against pathogenic bacteria. The function of the adenoid is active in children, but its role decreases in adolescence.

The adenoid is the reservoir of bacteria in the nasopharyngeal area, including *Streptococcus pneumoniae*, nontypable *Haemophilus influenzae*, and *Moraxella catarrhalis*, which are common pathogenic bacteria for otitis media and sinusitis. The location of the adenoid is in the vicinity of the Eustachian tube and the ostiomeatal complex so that the bacteria in the adenoid is the contributing factor for infections of the middle ear and sinuses. The bacterial load in the adenoid, particularly *H. influenzae*, stimulates the lymphoid cells, causing increased activity of the antigen-stimulated B lymphocyte and polyclonal B-cell proliferative response. Adenoid hypertrophy causes nasal obstruction and obstructive sleep disorders in children, when accompanied by tonsillar hypertrophy. Adenoidectomy is recommended in the guidelines for the treatment of pediatric otitis media with effusion (OME) and sinusitis, to eliminate the source of infection.[2,3] Adenoidectomy or adenotonsillectomy is recommended in hypertrophic adenoid for chronic infection, nasal obstruction, or obstructive sleep apnea (OSA) in children.

KEY LEARNING POINTS

1. The adenoid is located on the roof of the nasopharynx, which is attached to the base of the skull under the sphenoid bone. The floor of the nasopharynx is the upper surface of the soft palate.
2. The anterior boundary of the nasopharynx is the choanae, which is a continuation from the nasal cavity. The posterior boundary of the nasopharynx is the pharyngeal wall, which consists of the mucosa, the pharyngobasilar fascia, and the superior constrictor muscle.
3. The *torus tubarius* is the nasopharyngeal end of the Eustachian tube, which opens into the lateral wall of the nasopharynx on both sides of the adenoid. The slit-like recess formed by the Eustachian tube and the concave upper border of the superior constrictor muscle is called the pharyngeal recess or the fossa of Rosenmùller. Hypertrophic adenoid can extend laterally, encroaching upon the torus tubarius, which is the nasopharyngeal prominence overlying the cartilage of the Eustachian tube, and care must be taken to avoid injury to the Eustachian tube while removing the adenoid.
4. Bleeding from adenoidectomy is mostly raw surface bleeding. Hemostasis is achieved by electrocautery and nasopharyngeal packing with vasoconstrictors. The blood supply of the adenoid is from the ascending palatine branch of the facial artery, ascending pharyngeal artery, pharyngeal branch of the internal maxillary artery, and ascending cervical branch of the thyrocervical trunk. Venous drainage is through the pharyngeal plexus to the pterygoid plexus, facial vein, and internal jugular vein.

PREOPERATIVE PERIOD

Adenoidectomy is a surgical procedure that is performed mostly in children. Adenoidectomy is usually done for the relief of nasal obstruction or elimination of the source of infection. According to the guidelines,[2,3] adenoidectomy is done in pediatric patients with OME, chronic sinusitis, or OSA. Each condition has its own indications for adenoidectomy, but there usually are overlapping conditions in the same patient since the pathogenesis of otitis media, sinusitis, and obstructive adenoid hypertrophy may originate from chronic infection of the adenoid. Sometimes one condition contributes to the timing of surgery for another condition. For example, in a child who reaches the indication for myringotomy for having middle ear fluid for more than 90 days, adenoidectomy should be done in the same setting if the child also has the problem of adenoid obstruction or chronic sinusitis. Performing adenoidectomy with myringotomy and ventilation tube insertion eliminates the source of infection for both conditions and decreases the need for multiple general anesthesias.

History

1. History of present illness
   - Persistent middle ear effusion for more than 90 days
   - Hearing loss
   - Speech delay
   - Chronic rhinorrhea
   - Chronic cough
   - Chronic nasal obstruction, snoring
   - OSA
   - Behavioral issues that may be the result of OSA: Daytime sleepiness, irritability or hyperactivity, nocturnal enuresis
2. Past medical history
   - Allergic rhinitis
   - Asthma
   - Cardiac conditions that may be the complications of OSA: Pulmonary hypertension, right ventricular hypertrophy, cor pulmonale
   - Previous surgery, abnormal bleeding during surgery, or family history of abnormal bleeding
   - Medications: Anticoagulants, oral or intranasal steroids

Physical Examination

- Adenoid facies: Patients with long-standing nasal obstruction from adenoid hypertrophy may have the appearance of "adenoid facies," which is the result of chronic mouth breathing. Malocclusion, excessive showing of the upper gum, and lack of lip seal are characteristics of adenoid faceies.
- Hyponasal speech
- Presence of middle ear effusion
- Abnormality of the tympanic membrane: Retraction, decreased mobility of the tympanic membrane by pneumatic otoscopy
- Visible hypertrophic adenoid: The adenoid can be visualized through anterior rhinoscopy or endoscopy if the turbinate is not congested. An obstructing adenoid can sometimes be seen protruding through the choanae (Fig. 191.1).
- Postnasal drip and nasopharyngeal discharge are seen in chronic adenoid infection.
- Nasal discharge at the middle meatus is suggestive of sinusitis.

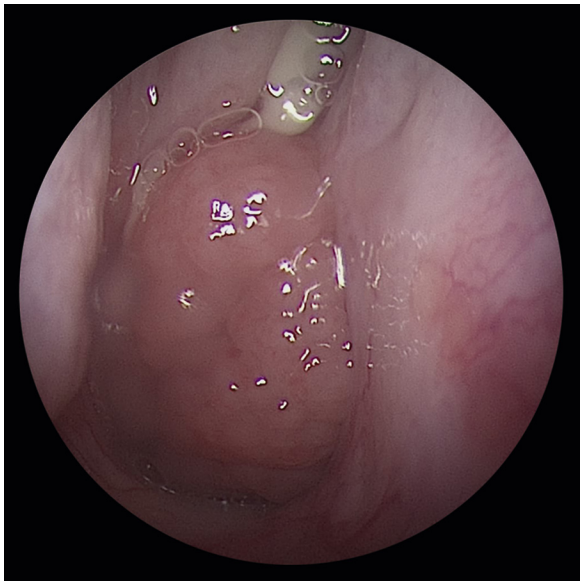

Fig. 191.1. Preoperative adenoid mass: Endoscopic view of hypertrophic adenoid protruding through the choana.

Imaging

- Chest radiograph
- Lateral nasopharyngeal radiograph

Evaluation of the adenoid size is done by radiographic imaging or imaging obtained from nasal endoscopy. Plain lateral radiograph of the nasopharynx is used for the measurement of the adenoid-nasopharyngeal (A/N) ratio. The most popular method is the measurement by Fujioka et al. used since 1979.[4] A/N ratio is the ratio of the distance from the maximal convexity of the adenoid to the anterior margin of basiocciput (adenoid width) divided by the distance between the posterior edge of the hard palate to the anteroinferior edge of the sphenooccipital synchondrosis (nasopharyngeal width). An average value of normal A/N ratio is 0.63 to 0.73.

The ratio of the adenoid tissue to the choanal opening is measured from the image obtained by the zero degree rigid nasal endoscope. The ratio of the area of the adenoid to the choanal opening is calculated by the Photoshop program. A/N ratio was found to have good correlations with nasal endoscopic examination and intraoperative mirror examination.

Surgical Indications

Adenoidectomy in Otitis Media With Effusion

- Adenoidectomy is done with the first set of tympanostomy tube insertion if the patient has the concurrent problem of the adenoid such as chronic nasal obstruction, OSA, or chronic sinusitis.[2]
- For the patients who do not have problems with the adenoid, adenoidectomy is indicated for OME when myringotomy is done for the insertion of the second set of tympanostomy tubes, regardless of the size of the adenoid, provided that the patient does not have any contraindications for adenoidectomy.

Adenoidectomy in Chronic Sinusitis

- Chronic or recurrent sinusitis that fails medical management[3]: Adenoidectomy is the first-line surgical management of chronic sinusitis in children before functional endoscopic sinus surgery, especially in children aged up to 6 years. In children aged 6 to 12 years, adenoidectomy is also considered effective as a first-line treatment according to the clinical consensus statement in pediatric chronic rhinosinusitis.[5]

Adenoidectomy in Obstructive Sleep Apnea

- Adenotonsillar hypertrophy with symptoms and signs of OSA

Contraindications

- Cleft palate
- Submucous cleft palate and velopharyngeal insufficiency (VPI): Adenoidectomy can cause worsening of VPI and hypernasal speech; therefore it should be avoided. If necessary, superior pole adenoidectomy can be done in some cases.
- Hematologic conditions causing coagulopathy: Some of the conditions can be reversed before surgery and therefore are considered as relative contraindications, such as in patients who are using anticoagulants, which should be withdrawn 7 to 14 days before surgery. Consultation with a hematologist should be obtained in patients with von Willebrand disease and other coagulopathy.

Preoperative Preparation

- Informed consent
- Routine preoperative laboratory preparation with special attention to coagulation profile and special screening test for von Willebrand disease in patients with history of abnormal bleeding or have family history of abnormal bleeding
- Preoperative physical examination: Patients must be free from upper respiratory tract infections (URIs) at least 2 weeks before surgery to avoid acute inflammation of the tissue that may lead to excessive bleeding during surgery.
- Investigation for OSA
  - Polysomnography: To assess the severity of the disease. Patients with severe symptoms should have polysomnography to evaluate the apnea-hypopnea index (AHI) and degree of oxygen desaturation.
  - Investigation for complications of OSA: Physical examination of the cardiovascular system and echocardiogram to rule out right ventricular hypertrophy, pulmonary hypertension, and systemic hypertension
- Admission for postoperative monitoring is required for high-risk patients.
- Investigation for special populations: Special populations such as patients with Down syndrome, craniofacial, or syndromic anomalies should have specific preoperative investigations according to their conditions. Patients with Down syndrome should have an evaluation of the cervical spine to rule out subluxation because the surgery is done with neck extension. Patients with craniofacial anomalies or obesity who have OSA should have polysomnography to assess the degree of severity and desaturation.

OPERATIVE PERIOD

Anesthesia

- Preoperative sedation should be avoided in children with OSA.
- The anesthesiologist should be notified in advance if the patients have severe OSA or have problems that will increase risks of general anesthesia.
- General anesthesia is done with oral endotracheal intubation.
- The endotracheal tube should be secured in the midline position, especially when tonsillectomy is to be performed with adenoidectomy.
- Once the patient's neck is extended, the anesthesiologist should check the position of the endotracheal tube. Stability of the endotracheal tube and airway pressure should be checked again after the placement of the mouth gag.

Positioning

- Supine position with neck extension on a shoulder roll (Rose position)
- A head ring is placed to stabilize the head of the patient.
- The eyes are protected with eye ointment and taped shut.
- The head and part of the face are draped, protecting the eyes and leaving the exposure for the nose and the oral cavity.

Perioperative Antibiotic Prophylaxis

- Perioperative antibiotics are not routinely administered.
- Antibiotics prophylaxis for bacterial endocarditis can be given to patients with underlying cardiac disease as necessary.

Monitoring

- Routine anesthesia monitoring

Instruments and Equipment to Have Available

- The complete set of instruments for conventional technique of adenoidectomy is shown in Fig. 191.2.
- Adenoid curettes are available in different widths and angles (Fig. 191.3). The curette is used with a nasopharyngeal mirror for the removal of the adenoid under the direct vision.
- St. Clair Thompson adenoid forceps are used for grasping the tissue or cutting with its sharp inner surface (Fig. 191.4).
- Suction electrocautery



Fig. 191.2. Complete set of instruments for conventional adenoidectomy. Adenoid curettes and adenoid forceps are used for removal of the adenoid.



Fig. 191.3. Various sizes of adenoid curettes.



Fig. 191.4. St. Clair Thompson adenoid forceps.

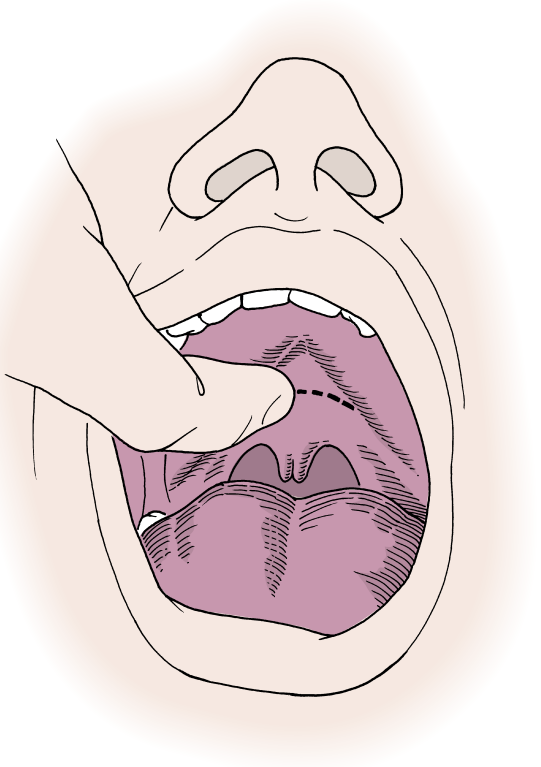

Fig. 191.5. Palpation of the palate to rule out submucous cleft.

Key Anatomic Landmarks

- The choana: The vomer and posterior end of the turbinates
- The roof of the nasopharynx
- The torus tubarius and the eustachian tube

Prerequisite Skills

- Nasopharyngeal mirror examination
- Nasal endoscopy
- Suction cautery
- Special skills for specific instruments (optional): Coblator, microdebrider, harmonic scalpel

Operative Risks

- Eye injuries, especially corneal injuries, are preventable by taping the eyes shut with caution. When the head is draped, be careful not to place the catheters or instruments such as towel clips or clamps over the eye area.
- Injuries to the lips, upper teeth, mucosa of the oral cavity, and posterior pharyngeal wall can occur during endotracheal intubation and during the application of the mouth gag.
- Injury to the torus tubarius and the Eustachian tube
- Bleeding from the nasopharyngeal bed

Surgical Technique

- The McIvor mouth gag with a slotted tongue depressor is inserted and the mouth is opened. The mouth gag is suspended to the Mayo stand.
- Palpation of the palate to rule out the submucous cleft (Fig. 191.5). Bifid uvula, notched hard palate, and absence of the muscle of the soft palate (zona pellucida) are signs of submucous cleft palate.



Fig. 191.6. Patient positioning and soft palate retraction for adenoidectomy.

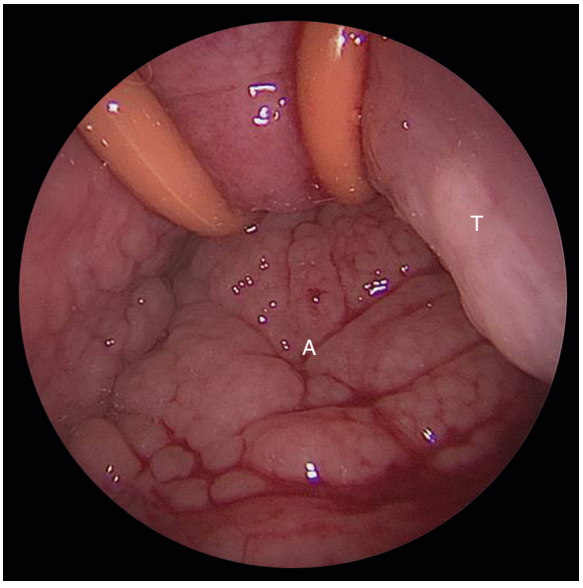

Fig. 191.7. Adenoid in the operative site: The soft palate is retracted by the red rubber catheters; adenoid mass *(A)* is exposed with the torus tubarius *(T)* on the lateral side.

- The throat is packed with roll gauze to prevent the blood from entering the larynx. A few drops of 0.025% of oxymetazoline are put in the nostrils to decongest the nasal cavity.
- A red rubber catheter (Fr 6 or 8) is passed through each nostril to the nasopharynx and retrieved through the oral cavity. The catheter is clamped on both ends to retract the soft palate and passed over the head drape (Fig. 191.6).
- The adenoid is then visualized through a nasopharyngeal mirror, and both sides of the torus tubarius are identified (Fig. 191.7).
- The nasopharyngeal mirror is held in the left hand, and the adenoid curette is applied by the right hand using the right thumb as a fulcrum. The adenoid curette is used to remove the adenoid under vision. Most of the adenoid mass is removed through the first few swipes using the wide-shaped adenoid curette. The removed adenoid is shown in Fig. 191.8.
- The rest of the nasopharyngeal lymphoid tissue is removed with the smaller sized curette or the adenoid forceps and suction cautery.

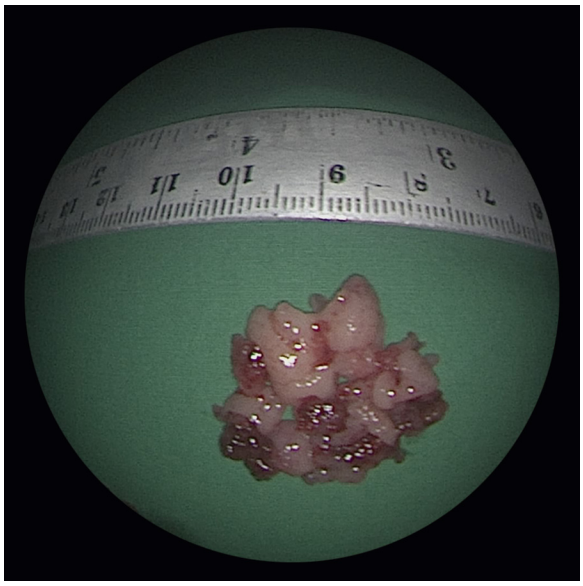

Fig. 191.8. The removed adenoid mass.

BOX 191.1 Hint and Tips

1. Identify both torus tubarius before curetting the adenoid.
2. Visualize the adenoid and the nasopharyngeal bed with nasopharyngeal mirror during the cutting; do not cut blindly when there is bleeding in the nasopharyngeal bed.
3. Bleeding is mostly from the raw surface; hemostasis is achieved with electrocautery and adequate nasopharyngeal packing.
4. Complete view of the choana should be visualized at the end of the procedure.

- Normal saline is irrigated through the nose and suctioned out of the oropharynx to provide the clear view of the nasopharyngeal cavity.
- Bleeding is stopped with gauze packing soaked with oxymetazoline.
- Hints and tips for the procedure are shown in Box 191.1.
- Other techniques or instruments: Electrocautery, coblator, microdebrider, harmonic scalpel, laser

Trends of the instruments used in adenotonsillectomy changed over time. A survey by Walner et al.[6] showed that the most popular instrument was electrocautery, followed by coblation, cold dissection with electrocautery, and cold dissection with bipolar electrocautery. The techniques and instruments for adenoidectomy had been compared to each other in many studies. Cold curettage was done with less mean operative time but more blood loss when compared to coblation. Rate of revision surgery was not different between suction coagulation and cautery compared to the microdebrider. Adenoidectomy by suction coagulation provided less blood loss when compared to a historical control group of adenoidectomy by cold curettage.

Common Errors in Technique

- Injury to the torus tubarius is most likely to occur during the removal of large adenoid pads that obscure the view of the nasopharynx.
- Curetting too deep in the nasopharynx may cause excessive bleeding.

POSTOPERATIVE PERIOD

Postoperative Management

- Admission and postoperative monitoring is required in the high-risk patients.

Adenoidectomy can be performed as a day surgery in healthy children not younger than 3 years old with no underlying diseases or suspicious history of abnormal bleeding.

High-risk patients with OSA undergoing adenotonsillectomy, according to the guideline,[7] are children younger than 3 years, patients with severe OSA diagnosed by polysomnography, patients with cardiac complications of OSA, patients with underlying craniofacial anomalies or neuromuscular disorder, and patients with obesity or failure to thrive.

- Close observation for airway obstruction: The patients should be placed in semiprone position with continuous monitoring of vital signs and oxygen saturation. The effect of residual sedative medication after the operation should be monitored to avoid respiratory depression.
- Assessment for bleeding: Periodic examination of the oropharynx should be done to assess bleeding dripping down from the nasopharynx. Vasoconstrictor nose drops can be administered as necessary for minor bleeding.
- Pain control: Acetaminophen should be administered. The guideline for tonsillectomy[8] suggests that acetaminophen with codeine is not superior to acetaminophen alone. The use of nonsteroidal anti-inflammatory drugs is controversial. Pain from adenoidectomy without tonsillectomy is not severe, so nonsteroidal anti-inflammatory drugs may not be necessary.
- Intravenous fluid is routinely administered in the postoperative period. Without tonsillectomy, the patients usually tolerate oral intake well because there is no wound in the oral cavity.

Complications

Complications of adenoidectomy are divided into perioperative and delayed complications.

Perioperative Complications

- Trauma or burns to the facial and oropharyngeal area: Eye injuries, injuries to the lips, upper teeth, and mucosa of the oral cavity and posterior pharyngeal wall
- Malposition or obstruction of the endotracheal tube after extension of the neck or after the insertion of the mouth gag
- Airway complications during the induction of general anesthesia: In patients with OSA, desaturation and airway obstruction may occur during induction period.
- Pulmonary edema: In patients with prolonged history of airway obstruction from adenotonsillar hypertrophy, sudden relief of airway obstruction during endotracheal intubation can result in acute pulmonary edema and desaturation. Treatment is endotracheal intubation with positive end-expiratory pressure (PEEP) ventilation. Patients with preoperative pulmonary hypertension or high AHI are at risk for pulmonary edema.
- Hemorrhage is an important perioperative complication of adenoidectomy. Bleeding from the nasopharyngeal bed is mostly raw surface bleeding, which is usually stopped by cautery and nasopharyngeal packing with the use of a vasoconstrictor. Avoid dissection too deep in the nasopharyngeal mucosa to prevent excessive bleeding. Good visualization allows for precise hemostasis.
- Injury to the Eustachian tube: The adenoid and the Eustachian tube should be visualized clearly for the precise cut.

Delayed Complications

- Regrowth of the adenoid: Incidence of symptomatic regrowth of the adenoid in the literature is less than 1% to 3%. Rate of revision surgery is approximately in the same range for all of the popular instruments: for microdebrider, 0.84%; for suction coagulator, 1.5% to 1.7%; and for curettage, 1.6%.
- Nasopharyngeal stenosis is a rare complication of adenoidectomy resulting from inflammation of nasopharyngeal raw surface followed by fibrosis of the nasopharynx. Symptoms are recurrences of nasal obstruction or OSA. The onset of symptoms varies from 3 to 10 weeks after surgery. Laser adenoidectomy by potassium titanyl phosphate (KTP) laser was reported in the literature to cause seven cases of nasopharyngeal stenosis. VPI was mentioned in the literature as a possible complication of adenoidectomy. This can be avoided by a careful history taking and preoperative physical examination. History suggestive of VPI includes nasal regurgitation and hypernasal speech. Physical examination can reveal cleft palate or short, tight soft palate, or bifid uvula.
- Grisel syndrome is one of the rare complications that can occur after adenotonsillectomy or other surgical procedures of the head and neck. It occurs mostly in children. The pathology is nontraumatic atlanto-axial subluxation due to an inflammation in the prevertebral area. Periligamentous inflammation of the anterior transverse ligament causes laxity of the ligament and imbalance of the cervical spine. Nasopharyngeal infection/inflammation and other infections such as otitis media, tonsillitis, and surgical procedures such as mastoidectomy had been reported to be the cause of Grisel syndrome, which occurs within a week after surgery or infection. The patient presents with painful torticollis and limited neck motion. The patient should be evaluated with imaging of the cervical spine and neurosurgical consultation. Treatment includes conservative management with anti-inflammatory drugs, antibiotics, and immobilization. Surgical management can be considered if the condition progresses.

Alternative Management Plan

- Antibiotics
- Intranasal steroid
- Leukotriene antagonist (montelukast)

DISCUSSION

Evidence-Based Medicine Question

What is the outcome of adenoidectomy for otitis media with effusion, obstructive sleep apnea, and chronic sinusitis?

There was a Cochrane review confirming the benefit of adenoidectomy in the resolution of OME. The benefit is not confirmed in acute otitis media (AOM). There has been a review in 51,373 children in Australia who had adenoidectomy with their first myringotomy; the odds for subsequent myringotomy are less than the group of first myringotomy without adenoidectomy[9] (odds ratio 0.61, 95% CI 0.52 to 0.72, $P < .001$).

The relationship between the adenoid and pediatric sinusitis was proven by the correlation of bacteria in the middle meatus and the adenoid. There was a report of significant reduction of recurrent sinusitis and obstructive sleep disorder after adenoidectomy.[10] Meta-analysis showed that the pooled effect of symptomatic relief of pediatric sinusitis after adenoidectomy was 69.3%.

Editorial Comment

Adenoidectomy has been performed for over two centuries. During this period, new tools and technologies have been introduced, but the basic technique of adenoidectomy has remained unchanged. The indications for the procedure, however, have been revised based on scientific evidence. Although considered to be a simple procedure, there may be significant complications, both immediate and delayed. The surgeon should be aware of these complications and have a comprehensive discussion with the patient's family prior to embarking on surgery.

Sukgi Choi

Access the review questions and additional sources list online at http://www.expertconsult.com



REFERENCES

1. Musiatowicz M, Wysocka J, Kasprzycka E, et al. Lymphocyte subpopulations in hypertrophied adenoid in children. Int J Pediatr Otorhinolaryngol 2001;59(1):7–13.
2. Rosenfeld RM, Culpepper L, Doyle KJ, et al. Clinical practice guideline: otitis media with effusion. Otolaryngol Head Neck Surg 130(Suppl. 5):S95–118.
3. Fokkens WJ, Lund VJ, Mullol J, et al. EPOS 2012: European position paper on rhinosinusitis and nasal polyps 2012. A summary for otorhinolaryngologists. Rhinology 2012;50(1):1–12.
4. Fujioka M, Young LW, Girdany BR. Radiographic evaluation of adenoidal size in children: adenoidal-nasopharyngeal ratio. AJR Am J Roentgenol 1979;133(3):401–404.
5. Brietzke SE, Shin JJ, Choi S, et al. Clinical consensus statement: pediatric chronic rhinosinusitis. Otolaryngol Head Neck Surg 2014;151(4):542–553.
6. Walner DL, Parker NP, Miller RP. Past and present instrument use in pediatric adenotonsillectomy. Otolaryngol Head Neck Surg 2007;137(1):49–53.
7. Marcus CL, Brooks LJ, Draper KA, et al. Diagnosis and management of childhood obstructive sleep apnea syndrome. Pediatrics 2012;130(3):576–584.
8. Baugh RF, Archer SM, Mitchell RB, et al. Clinical practice guideline: tonsillectomy in children. Otolaryngol Head Neck Surg 2011;144(Suppl. 1):S1–30.
9. Kadhim AL, Spilsbury K, Semmens JB, et al. Adenoidectomy for middle ear effusion: a study of 50,000 children over 24 years. Laryngoscope 2007;117(3):427–433.
10. Ungkanont K, Damrongsak S. Effect of adenoidectomy in children with complex problems of rhinosinusitis and associated diseases. Int J Pediatr Otorhinolaryngol 2004;68(4):447–451.

REVIEW QUESTIONS

1. Which of the followings is *not* an indication for adenoidectomy?
   a. Recurrent acute otitis media
   b. Persistent middle ear effusion for more than 90 days
   c. Chronic sinusitis that fails medical management
   d. Obstructive sleep apnea from adenoid hypertrophy

2. Which of the following structures can be injured during adenoidectomy?
   a. Vomer
   b. Torus tubarius
   c. Middle turbinate
   d. Nasolacrimal duct

3. Which of the following patients is a high-risk patient that needs admission for close observation?
   a. A 5-year-old boy with delayed development
   b. A 4-year-old boy with adenotonsillar hypertrophy
   c. A 9-year-old obese girl with severe obstructive sleep apnea
   d. A 6-year-old girl with immotile cilia syndrome

ADDITIONAL SOURCES

Bernstein JM, Dryja D, Murphy TF. Molecular typing of paired bacterial isolates from the adenoid and lateral wall of the nose in children undergoing adenoidectomy: implications in acute rhinosinusitis. Otolaryngol Head Neck Surg 2001;125(6):593–597.

Brietzke SE, Brigger MT. Adenoidectomy outcomes in pediatric rhinosinusitis: a meta-analysis. Int J Pediatr Otorhinolaryngol 2008;72(10):1541–1545.

Brodsky L, Koch RJ. Bacteriology and immunology of normal and diseased adenoids in children. Arch Otolaryngol Head Neck Surg 1993;119(8):821–829.

Caylakli F, Hizal E, Yilmaz I, et al. Correlation between adenoid-nasopharynx ratio and endoscopic examination of adenoid hypertrophy: a blind, prospective clinical study. Int J Pediatr Otorhinolaryngol 2009;73(11):1532–1535.

Darrow DH, Derkay CS, Mitchell R. Tonsillectomy and adenoidectomy. In: Bluestone CD, Simons JP, Healy GB, editors. Bluestone and Stool's Pediatric Otolaryngology, vol. 2. 5th ed. Shelton, Connecticut, CT: People's Medical Publishing House; 2014. p. 1189–1222.

Dearking AC, Lahr BD, Kuchena A, et al. Factors associated with revision adenoidectomy. Otolaryngol Head Neck Surg 2012;146(6):984–990.

Giannoni C, Sulek M, Friedman EM, et al. Acquired nasopharyngeal stenosis: a warning and review. Arch Otolaryngol Head Neck Surg 1998;124(2):163–167.

Hollinshead WH. The pharynx and larynx. In: Hollinshead WH, editor. Anatomy for Surgeons: the Head and Neck, vol 1. Philadelphia, PA: Harper & Row, Publishers, Inc.; 1982. p. 389–483 3rd ed.

Ivarsson M, Lundberg C, Quiding-Jarbrink M. Antibody production directed against pneumococci by immunocytes in the adenoid surface secretion. Int J Pediatr Otorhinolaryngol 2004;68(5):537–543.

Lertsburapa K, Schroeder Jr JW, Sullivan C. Assessment of adenoid size: a comparison of lateral radiographic measurements, radiologist assessment, and nasal endoscopy. Int J Pediatr Otorhinolaryngol 2010;74(11):1281–1285.

Ozkiris M, Karacavus S, Kapusuz Z, et al. Comparison of two different adenoidectomy techniques with special emphasize on postoperative nasal mucociliary clearance rates: coblation technique vs. cold curettage. Int J Pediatr Otorhinolaryngol 2013;77(3):389–393.

Patino M, Sadhasivam S, Mahmoud M. Obstructive sleep apnoea in children: perioperative considerations. Br J Anaesth 2013;111(Suppl. 1): i83–95.

Ruda JM, Krakovitz P, Rose AS. A review of the evaluation and management of velopharyngeal insufficiency in children. Otolaryngol Clin North Am 2012;45(3):653–669. viii.

Rynnel-Dagoo B, Agren K. The nasopharynx and the middle ear. Inflammatory reactions in middle ear disease. Vaccine 2000;19(Suppl 1):S26–31.

Sapthavee A, Bhushan B, Penn E, et al. A comparison of revision adenoidectomy rates based on techniques. Otolaryngol Head Neck Surg 2013;148(5):841–846.

Skilbeck CJ, Tweedie DJ, Lloyd-Thomas AR, et al. Suction diathermy for adenoidectomy: complications and risk of recurrence. Int J Pediatr Otorhinolaryngol 2007;71(6):917–920.

van den Aardweg MT, Schilder AG, Herkert E, et al. Adenoidectomy for otitis media in children. The Cochrane database of systematic reviews 2010;(1):CD007810.

Walker P. Pediatric adenoidectomy under vision using suction-diathermy ablation. Laryngoscope 2001;111(12):2173–2177.

Zielnik-Jurkiewicz B, Jurkiewicz D. Implication of immunological abnormalities after adenotonsillotomy. Int J Pediatr Otorhinolaryngol 2002;64(2):127–132.

192 Tonsillectomy

Phillip Huyett, Joseph E. Dohar

INTRODUCTION

Tonsillectomy was first performed over 2000 years ago, with the oldest reference to the procedure dating back to 1000 BC.[1] As the safety and indications evolved, so did the popularity of tonsillectomy. Most notably, the 1970s and 1980s saw a transition of the most common indication for tonsillectomy from recurrent throat infections to sleep-disordered breathing (SDB).[2,3] Today, more than 500,000 tonsillectomies are performed annually in the United States, making it the most common major surgery and the second most commonly performed procedure on children behind myringotomy with tube insertion.[4] As a consequence, tonsillectomy has garnered significant attention in the literature with high-quality evidence in the form of randomized controlled trials, systematic reviews, and the 2011 clinical practice guideline (CPG) published by the American academy of otolaryngology-head and neck surgery (AAO-HNS).[5]

Unless otherwise specified, tonsillectomy refers to the removal of the palatine tonsils bilaterally. Continuous with the adenoids, lingual tonsils, Eustachian tonsils, and lateral pharyngeal bands, the palatine tonsils make up Waldeyer's ring, a collection of lymphoid organs belonging to the secondary immune system. This lymphoid tissue is ideally situated to serve as a first barrier for sampling of antigens entering the upper aerodigestive tract. The tonsils have deep, epithelial-lined crypts that significantly enhance interaction between antigen-presenting cells and foreign substances. The peak immune activity and size of the palatine tonsils occurs between age 3 and 10 years.[6] Such a proposed function notwithstanding, there is little to no evidence to suggest that children who undergo bilateral pharyngeal tonsillectomy sustain clinically significant immune deficiency.[7]

KEY OPERATIVE LEARNING POINTS

- Tonsillectomy is most commonly indicated for SDB and recurrent pharyngotonsillitis.
- Identification of the plane between the capsule of the tonsil and the constrictor muscle will facilitate the procedure.

PREOPERATIVE PERIOD

History

History of Present Illness

In patients referred for the evaluation of SDB, sleep symptoms such as enuresis, snoring, gasping, choking, coughing, and frank apneas are reported by the caregiver. The treating physician can confirm this with sleep video-sonograms readily recorded by caretakers given the widespread availability of cellular telephone video cameras. Caregivers and schoolteachers may also report a range of nonsleep manifestations and consequences including poor school performance, growth failure, and behavioral problems such as aggression, hyperactivity or hypersomnolence, and depression.

The otolaryngologist is rarely consulted for recurrent tonsillitis in the midst of an acute episode of pharyngotonsillitis. Hence, to meet evidence-based criteria to justify tonsillectomy, each episode of sore throat must be documented by the primary care physician with accompanying fever greater than 38.3°C, positive group A β-hemolytic streptococcal (GABHS) culture, tonsillar exudate, tender cervical lymphadenopathy, or lymph nodes greater than 2 cm. Primary care records are often no longer a single source of documentation with the evolution of acute care (express and urgent care centers) where health care providers diagnose and treat this common disorder. Patients may also present with complaints of chronic halitosis, recurrent tonsil stones, dysphagia, or muffled voice.

Past Medical History

- Prior treatment
  - Multiple courses of oral systemic antibiotics
  - Continuous positive airway pressure (CPAP)
  - Other surgeries (see Alternative Management Plan)
- Past medical history
  - Bleeding disorders or signs of easy bleeding or bruising (given the risk of posttonsillectomy hemorrhage)
- Family history
  - A family history of rheumatic fever or heart disease should prompt a discussion of tonsillectomy in a child with GABHS pharyngotonsillitis, regardless of the frequency.
  - Because this often represents a child's first operation, family history of excessive bleeding or adverse reactions to anesthesia should be queried.
- Medications
  - Medications with anticoagulant activity should be noted and, if possible, discontinued prior to and immediately following surgery.
- Allergies
  - Patients who have developed multiple antibiotic allergies during the treatment of recurrent pharyngotonsillitis may be offered tonsillectomy.

Physical Examination

- Tonsils are most commonly graded from 0 to 4+, based on their position relative to the tonsillar pillars and oropharyngeal opening (Fig. 192.1).[8] Interestingly, Brodsky tonsil size (see Fig. 192.1) does not correlate with the severity of obstructive sleep apnea (OSA); however, patients with larger tonsils are more likely to have complete resolution of SDB after removal.[9]
- The examiner should carefully evaluate for the presence of a bifid uvula, zona pellucida, and notch of the posterior hard palate bearing, in mind that even in the absence of any of these oropharyngeal stigmata of submucous cleft palate, an occult submucous cleft palate may nonetheless be present and may become symptomatic following an their adenoidectomy.
- A narrow hard palate in a child with OSA may require palatal expansion in addition to adenotonsillectomy.
- A patient with adenoid hypertrophy, which frequently coexists with tonsillar hypertrophy, may exhibit an elongated face, open mouth breathing, and hyponasal speech.

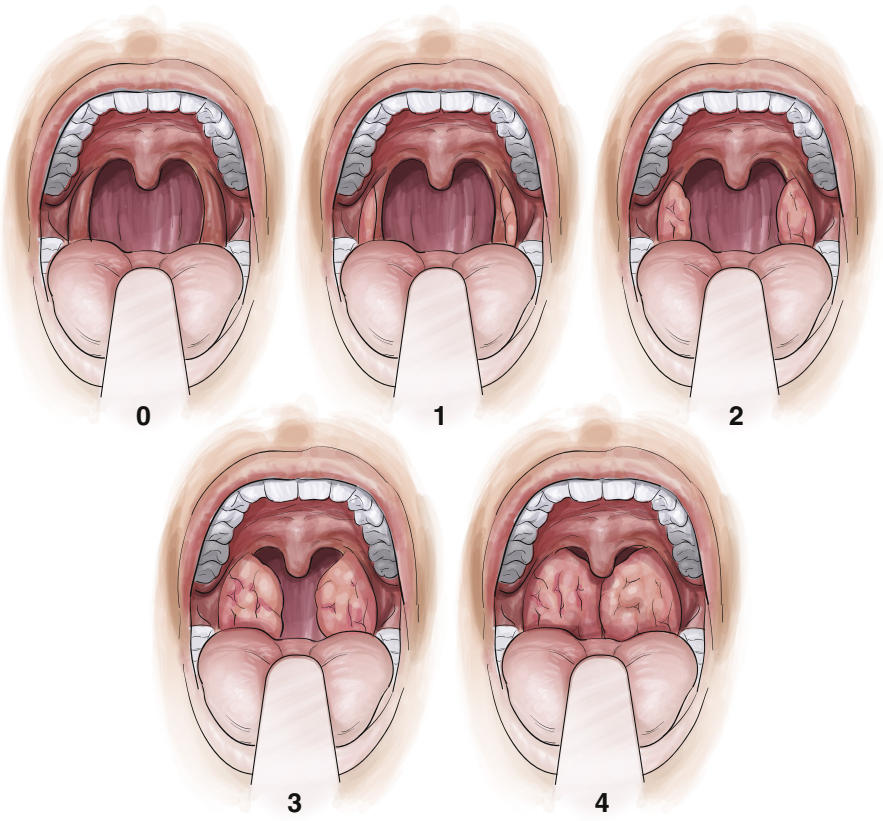

Fig. 192.1. Brodsky tonsillar grading system. *(From Baugh RF, Archer SM, Mitchell RB, et al.: Clinical practice guideline: Tonsillectomy in children. Otol Head Neck Surg 144(1 Suppl):S1-S30, 2011, with permission.)*

- If adenoidectomy is being considered, nasal endoscopy, a lateral neck radiograph, or physical examination at the time of tonsillectomy can reveal adenoid hypertrophy.

Imaging/Diagnostics

1. No imaging is indicated prior to routine tonsillectomy.
2. Flexion/extension cervical spine films should be obtained in Down syndrome children due to the risk of C1-C2 subluxation.
   a. Alternative: Cervical spine magnetic resonance imaging (MRI)
   b. The appropriate age at which such evaluations are appropriate and the most cost-effective studies are subjects of ongoing debate.
   c. Many experts consider clinical manipulation of the neck in the office to elicit symptoms and no evaluation at all to be sufficient.
   d. Shoulder roll should be avoided regardless.
3. A computed tomography (CT) angiogram may be pursued in a child with 22q11.2 syndrome to assess the degree of carotid artery medialization.[10]
4. In-lab overnight polysomnography (PSG) is the gold standard for the diagnosis of OSA.
   a. Home sleep study has not yet been approved for the diagnosis of pediatric OSA.
   b. An apnea-hypopnea index (AHI) of 1 to 5 represents mild OSA, 5 to 15 moderate OSA, and greater than 15 severe OSA.
   c. O_2 saturation of less than 92% is considered abnormal in children.
   d. PSG is indicated in children with a discordance between reported severity of signs/symptoms and tonsil size as well as those with complex medical histories such as Down syndrome, obesity, craniofacial abnormalities, sickle cell anemia, neuromuscular disorders, or mucopolysaccharidoses.
5. Drug-induced sleep endoscopy (DISE) is a useful adjunctive tool in children with OSA but an uncertain level of obstruction.
6. Sleep cine-MRI has been suggested as a valuable diagnostic means by which to investigate patients with persistent OSA despite adenotonsillectomy surgery.

Indications

- SDB describes partial or complete upper airway obstruction during sleep and affects approximately 12% of children. The condition ranges from nonobstructive snoring to OSA, which occurs in about 1% to 3% of children. Adenotonsillar hypertrophy is the most common cause of SDB in children and thus SDB represents the most common indication for pediatric tonsillectomy.
  - An AHI greater than 1 and oxygen desaturations below 92% are indications for tonsillectomy, but the decision to proceed with surgery should be made in the context of the history and physical examination.
  - Children with a history strongly suggestive of SDB or OSA and physical examination revealing tonsillar and/or adenoid hypertrophy do not necessarily require a preoperative PSG. Indeed, about 90% of children proceed to tonsillectomy based on clinical history and physical examination alone.

TABLE 192.1 Paradise Criteria

Criterion	Definition
Minimum frequency of sore throat episodes	7 or more episodes in the preceding year, OR 5 or more episodes in each of the preceding 2 years, OR 3 or more episodes in each of the preceding 3 years
Clinical features (sore throat plus the presence of one of more qualifies as a counting episode)	Temperature >38.3°C, OR Cervical lymphadenopathy (tender lymph nodes or >2 cm), OR Tonsillar exudate, OR Positive culture for group A β-hemolytic streptococcus
Treatment	Antibiotics were administered in conventional dosage for proved or suspected streptococcal episodes.
Documentation	Each episode and its qualifying features were substantiated by contemporaneous notation in a clinical record, OR *If not fully documented,* subsequent observance by the clinician of 2 episodes of throat infection with patterns of frequency and clinical features consistent with the initial history*

*This last statement allows children who meet all other criteria for tonsillectomy except documentation to nonetheless qualify for surgery if the same pattern of reported illness is observed and documented by the clinician in two subsequent episodes. Because of this tendency to improve with time, a 12-month period of observation is usually recommended prior to consideration of tonsillectomy as an intervention.

From Baugh RF, Archer SM, Mitchell RB, et al.: Clinical practice guideline: tonsillectomy in children. Otolaryngol Head Neck Surg, 2011.

- **Recurrent pharyngotonsillitis** represents the second most common indication for tonsillectomy. The definitions for a sore throat episode and requirements for tonsillectomy are based on randomized controlled trial data from 1984 (Table 192.1).
  - The "Paradise criteria" state that at least seven documented episodes of pharyngotonsillitis in 1 year, five in each of the last 2 years, or three in each of the last 3 years should be present to perform tonsillectomy for recurrent pharyngitis. There should be complete medical record documentation rather than caregiver report.
- There are several other infectious indications for tonsillectomy that are less stringently defined (Table 192.2):
  - Acute or Quinsy tonsillectomy for **acute tonsillitis** or peritonsillar abscess, generally when causing severe illness, airway obstruction, or refractory to incision and drainage.
  - Interval tonsillectomy for recurrent **peritonsillar abscesses** (PTAs), generally after two or more. Once the tonsils are removed, recurrent PTA is exceptionally rare.
  - In **Lemierre syndrome** (thrombophlebitis of the internal jugular vein most often related to tonsillitis and peritonsillar abscess), it is reasonable to perform tonsillectomy following acute treatment with antibiotics and incision and drainage, although there is scant evidence on the incidence of recurrence of Lemierre syndrome.
  - Tonsillectomy is an effective treatment for periodic fever, aphthous stomatitis, pharyngitis and adenitis **(PFAPA)** and reduces the number, frequency, duration, and severity of episodes as well as the need for steroids.
  - In pediatric autoimmune neuropsychiatric disorders associated with streptococcal **(PANDAS)** infections, the role of tonsillectomy is not as clear.
  - A child with **tonsillar asymmetry** alone is not a candidate for tonsillectomy in the absence of other indications or signs and symptoms concerning for lymphoma.
  - Acute **upper airway obstruction** due to tonsillar enlargement is most often seen in **infectious mononucleosis.** Acute tonsillectomy for this indication has been shown to reduce the number subsequent episodes of tonsillitis.
- Many indications lack concrete evidence and require thorough clinical evaluation and documentation (Table 192.2):
  - Excessive illness requiring significant missed school time
  - Febrile seizures related to tonsillitis
  - The development of multiple antibiotic allergies related to treatment of recurrent tonsillitis
  - Severe halitosis
  - Recurrent **tonsillithiasis** is an indication in patients in whom improved oral hygiene and self-removal techniques have failed.
  - Malocclusion related to tonsillar hypertrophy
  - Guttate psoriasis

Contraindications

- In patients with significant bleeding disorders, tonsillectomy is not contraindicated but the risks should be adequately justified by the benefits and clearly outlined to the patient and family.

Preoperative Preparation

- Informed consent from the caregiver and assent from the patient where appropriate should include the major risks described in the following sections. The child should plan to miss 1 to 2 weeks of school.
- When a personal or family history is suggestive of a bleeding disorder, serologic coagulation testing with consideration of a hematology consultation should be obtained.
- Routine blood tests are not cost-effective.

OPERATIVE PERIOD

Anesthesia

- General anesthesia
- Oral intubation
- Endotracheal tube is centered on the base of tongue and taped in the midline to the mentum.
- After positioning, confirm that the endotracheal tube was not inadvertently removed or kinked.
- Fraction of inspired oxygen (FiO_2) less than 30% if electrocautery is to be used to avoid an airway fire

Positioning

- The bed is rotated such that the surgeon sits or stands above the head of the patient.

TABLE 192.2 List of Indications

Airway	Infectious	Quality of Life
• Sleep-disordered breathing • Airway obstruction • Tonsillar asymmetry • Removal of foreign body	• Recurrent pharyngotonsillitis • PFAPA • Recurrent peritonsillar abscess • Lemierre syndrome • Psoriasis (guttate) • Severe illness • Febrile seizures • Significant missed school time • PANDAS	• Severe halitosis • Tonsillithiasis • Malocclusion • Dysphagia

PANDAS, Pediatric autoimmune neuropsychiatric disorders associated with streptococcal; *PFAPA*, periodic fever, aphthous stomatitis, pharyngitis, and adenitis.

- In the absence of a contraindication (Down syndrome), a shoulder roll is placed.
- An appropriately sized McIvor or Crowe-Davis mouth gag is placed and suspended from a Mayo stand to displace the tongue and endotracheal tube inferiorly.
- The rubber portion of the curved wire should be hooked on the lateral incisors or canines of the maxillary dentition and not the upper lip, being mindful of the presence of loose teeth.
- A plastic lip-cheek retractor or moist gauze may be placed to protect the lips and perioral soft tissue from thermal burns.
- The endotracheal tube should adequately protected within the midline groove of the tongue blade.
- Most of the tongue base is covered by the blade. If there is excessive tongue base or lateral tongue herniating into the field, the blade of the mouth gag is too small.
- If the tongue prolapses around the blade, it may become necessary to position the blade for removal of the first tonsil and then reposition it for removal of the second tonsil.
- Draping is based on surgeon preference, but taping and protecting the eyes with a blue towel are recommended at a minimum.
- We discourage the use of a throat pack to eliminate the potential for a retained/airway foreign body.
- This combination of positioning facilitates visualization of the palatine tonsils, especially the inferior pole (Fig. 192.2).



Fig. 192.2. Positioning of the McIvor mouth gag.

Perioperative Antibiotic Prophylaxis

- Preoperative antibiotics are strongly recommended against based on the lack of apparent benefit with risks including rash, allergy, gastrointestinal upset, and antimicrobial resistance.[5]
- The CPGs[5] also strongly recommend the administration of intravenous steroids intraoperatively. There is a reduction in postoperative nausea, vomiting, time to resuming oral diet, and pain. Generally, 0.15 to 1.0 mg/kg of dexamethasone is given in a single dose.

Monitoring

- No routine monitoring

Instruments and Equipment to Have Available

- Standard tonsillectomy and adenoidectomy set, which typically includes a mouth gag, different-sized tongue blades, a Hurd retractor, Allis clamp, Yankauer suction, laryngeal mirror, forceps, and clamps by preference
- Tonsil balls, red rubber catheters, and a plastic cheek retractor are often used.
- The advantages and disadvantages of different tonsillectomy instruments are summarized in Table 192.3.

Key Anatomic Landmarks

- The tonsils are bounded by the palatoglossus muscle anteriorly and palatopharyngeus muscle posteriorly. Along with the overlying mucosal covering, these muscles make up the anterior and posterior tonsillar pillars, respectively.
- Lateral to the tonsillar capsule is the superior constrictor muscle, and the loose areolar tissue between constitutes the peritonsillar potential space.
- The blood supply arises from the ascending palatine, lingual (dorsal lingual), facial (tonsillar and ascending palatine), and maxillary (descending/lesser palatine) arterial branches of the external carotid system. Venous drainage is via the tonsillar veins of the external palatine, pharyngeal, and facial veins.
- The internal carotid artery lies 2 to 2.5 cm posterolateral to the tonsil in the poststyloid parapharyngeal space.
- Sensation from this region is transmitted via the lesser palatine (V2) and glossopharyngeal nerves. Branches of the glossopharyngeal nerve to the tongue base pass deep to the palatine tonsil to provide sensation and taste.
- Lymphatic drainage is to level 2 and retropharyngeal lymph nodes.

Prerequisite Skills

- Bimanual dexterity allows the surgeon to remove each tonsil with the hand that is ipsilateral to it.

TABLE 192.3 Comparison of Methods for Tonsillectomy and Tonsillotomy

Method	Advantages	Disadvantages
Monopolar electrocautery	Low cost, short operative time	Increased postoperative pain
Coblation	Reduced pain	Increased cost, possible higher rate of late PTH
Cold steel	Inexpensive, lower PTH, compatible with medical devices, decreased pain	Increased intraoperative bleeding and operative time
Diode laser	Decreased operative time and blood loss	Increased postoperative pain
Bipolar scissors	Ease of use, decreased operative time	Increased cost and PTH
Harmonic scalpel	Decreased intraoperative bleeding and post op pain	Increased cost
LigaSure	Decreased intraoperative bleeding, operative time and postoperative pain	Increased cost
Tonsillotomy (CO_2 laser, microdébrider, radiofrequency ablation, coblation)	Less pain and bleeding risk, similar reduction in infectious, sleep, quality of life, and behavioral symptoms	Risk of symptom recurrence, tonsil regrowth, relative contraindication for recurrent tonsillitis

PTH, Posttonsillectomy hemorrhage.

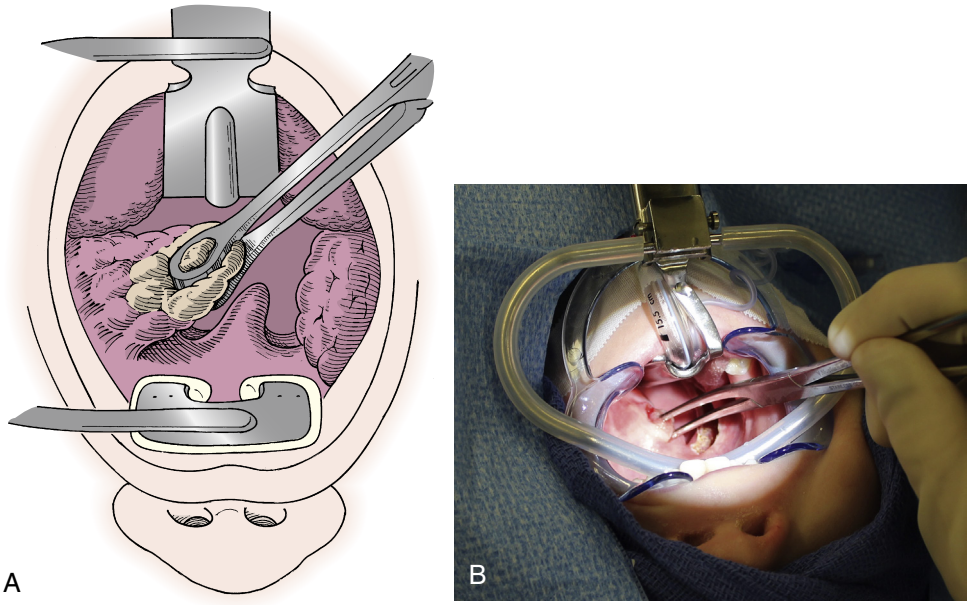

Fig. 192.3. Grasping the tonsil and retracting inferomedially. (***A,*** *Redrawn from Hibbert J: Tonsils and adenoids. In Evans JNG, [ed]: Pediatric Otolaryngology. In Kerr AG, [ed]: Scott Brown's Otolaryngology. London: Butterworth-Heinemann; 1987, pp 368-383.)*

Operative Risks

- Temporomandibular joint dislocation or condyle fracture
- Airway fire
- Intraoperative bleeding
- Vascular injury
- Burns or trauma to lips, teeth, gums, or soft palate
- Laryngospasm
- Dysgeusia

Surgical Technique

Tonsillectomy

- Regardless of the dissection instrument used (summarized in Table 192.3), the goal of tonsillectomy is to identify the tonsillar capsule and dissect between it and the superior constrictor muscle.
- The tonsil is grasped and retracted medially with a curved Allis forceps (Fig. 192.3). This is generally held with the hand opposite the tonsil being removed (e.g., left hand for right tonsil).
- By increasing and decreasing the force of retraction, the surgeon gets a sense of the depth of the tonsillar tissue.
- Enter the mucosal reflection of the anterior tonsillar pillar superolaterally. Here the palatoglossus muscle can be identified and preserved to prevent increased collapsibility of the soft palate, potentially worsening OSA (Fig. 192.4).
- With inferomedial retraction, the tonsillar capsule is readily identified deep to this initial incision.
- After repositioning the Allis clamp to the exposed superior pole and providing a more inferior vector of retraction, the tonsil is dissected from superior to inferior while rolling medially toward the posterior pillar along the capsular plane.
- Countertraction provided by the palate itself can be augmented by an assistant with a Yankauer suction.
- As the tonsil is dissected along a broad front, blood vessels are readily identified and controlled with electrocautery, clips, or ties prior to hemorrhage (Fig. 192.5).
- The loose areolar tissue between the tonsillar capsule and the constrictor muscle should be left in the patient because this likely reduces pain and bleeding associated with exposed muscle fibers.
- Keep the line of the mucosal incision directly adjacent to the tonsil because deviating from this approach results in unnecessary mucosal loss and pain.

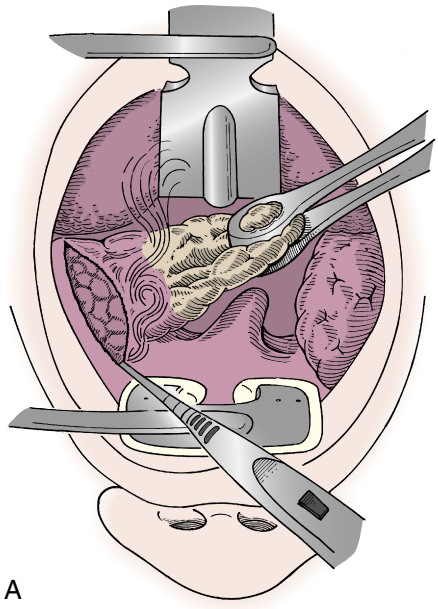



Fig. 192.4. Dissection through the anterior pillar mucosa, preserving the palatoglossus muscle and finding the capsule of the tonsil. (***A,*** *Redrawn from Hibbert J: Tonsils and adenoids. In Evans JNG, [ed]: Pediatric Tolaryngology. In Kerr AG, [ed]: Scott Brown's Otolaryngology. London: Butterworth-Heinemann; 1987, pp 368-383.)*

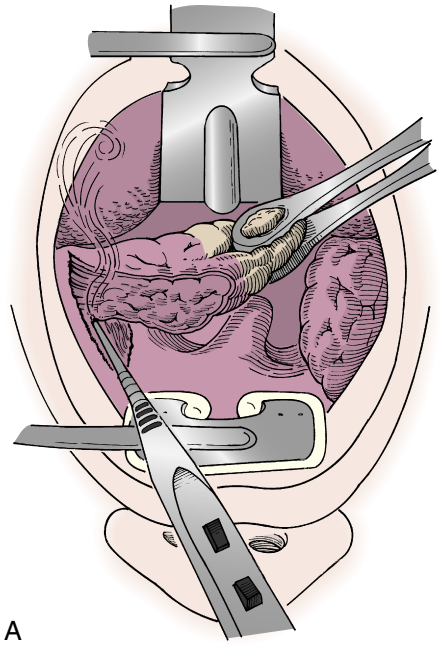

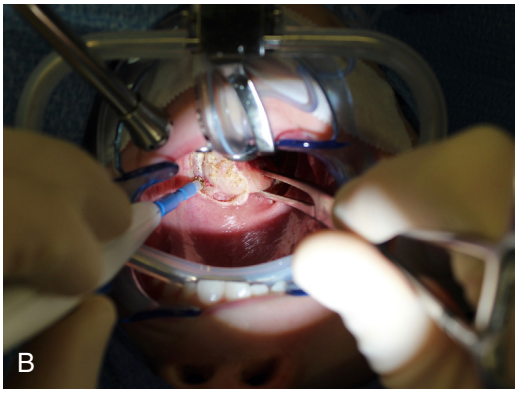

Fig. 192.5. Dissection continues along the plane of the capsule of the tonsil, cauterizing blood vessels as they are encountered. The inferior pole is arbitrarily divided because there is often not a distinct division between the palatine and lingual tonsils. (***A,*** *Redrawn from Hibbert J: Tonsils and adenoids. In Evans JNG, [ed]: Pediatric Tolaryngology. In Kerr AG, [ed]: Scott Brown's Otolaryngology. London: Butterworth-Heinemann; 1987, pp 368-383.)*

- When the inferior pole is poorly defined, an arbitrary end point is chosen to avoid extending the dissection to the tongue base or hypopharynx.
- There is often increased vasculature inferiorly, which can present a challenge to control postoperatively, so careful coagulation of these vessels is optimally done at the time of amputation of the tonsil while the vessels are stretched.
- The same procedure is performed on the contralateral tonsil.
- The pharynx is irrigated with saline solution and the stomach suctioned with an orogastric tube.
- The mouth gag should be closed and left open for a few moments to ensure that bleeding is not evident because of vessel stretch and collapse resulting from mouth gag compression.
- Bleeding of any kind should be controlled immediately. Thus it is critical that the operating room team not remove electrocautery devices or the suction tubing before the patient exits the operating room.
- Difficult emergence from anesthesia and extubation with coughing, "bucking," or laryngospasm triggered by blood and secretions on the vocal cords can result in immediate postoperative bleeding and occasionally airway catastrophe. The surgeon should remain in the OR until the patient has been safely extubated and is comfortably and spontaneously ventilating.
- Should nasal or oral airways be needed to prevent airway obstruction, it is preferable for the surgeon to place these devices between the fresh surgical beds.
- At our institution, tonsils are routinely sent for gross pathologic examination individually, although the utility of this has been questioned. Routine microscopic analysis of all tonsillectomy specimens is not cost-effective. Asymmetric or otherwise concerning tonsillar specimens should be sent fresh for histopathologic evaluation as lymphoma represents the most common occult malignancy in pediatric tonsillectomy specimens.

Intracapsular Tonsillectomy (Tonsillotomy)

- Intracapsular tonsillectomy or tonsillotomy was introduced in the mid-1990s in Sweden by Densert and coauthors under the hypothesis that a subtotal tonsillectomy would reduce postoperative morbidity while still relieving upper airway obstruction in children with SDB/OSA.
- Indeed, many studies have demonstrated equivalent efficacy, less postoperative bleeding and pain, with shortened recovery times and fewer readmissions for dehydration as compared to traditional tonsillectomy.
- As this inherently leaves tonsillar tissue behind, this procedure is generally not performed for recurrent tonsillitis and results in approximately 6% tonsillar regrowth.
- Tonsillar regrowth can be treated with observation if objective OSA is absent or with traditional tonsillectomy.
- The technique was initially described using a CO_2 laser but has been successfully performed with a microdébrider, diathermy scissors, radiofrequency ablation, coblation, and others.
- Tonsillotomy uses the same surgical setup as described earlier for tonsillectomy.
- The tonsil is grasped and retracted medially while the dissecting instrument removes the tonsil medial to the tonsillar capsule.
- Alternatively, the tonsillar tissue may be reduced with the dissecting instrument, ending the dissection medial to the tonsillar capsule.

Control of Posttonsillectomy Hemorrhage

- Active bleeding in the oropharynx should be treated as an airway emergency. This is most commonly first encountered by the emergency room physician who should consider the possibility of intubation prior to further management.
- If the airway is not secured, leaning over a kidney basin will help divert blood away from the airway.
- A hemoglobin and hematocrit should be measured and intravenous access obtained.
- If the patient is old enough and the bleeding is minor or a clot is present, examination and control with silver nitrate cautery at the bedside may be possible.
- More commonly, the child is unwilling to allow adequate examination, let alone intervention.
- In our institution, all actively bleeding children are brought to the operating room for emergent and definitive control. The presence of a blood clot requires a 24-hour admission and observation for further bleeding at a minimum.
- The anesthesiologist will often perform a rapid sequence induction and intubation because the patient has likely ingested significant quantities of blood and is in NPO (nothing by mouth) violation.
- The otolaryngologist must be present, gloved, gowned, and equipped with a headlight during the intubation because the procedure is made more difficult by bleeding. The room should be fully set up with two suctions readily available.
- Once the patient is safely intubated, the surgeon positions the child as if performing primary tonsillectomy.
- The pharynx is thoroughly irrigated to remove old blood and clots. Most often, the source of bleeding is active or has a fresh appearing clot overlying it.
- If bleeding is profuse, it may be controlled with direct pressure applied by a tonsil ball with or without a vasoconstricting substance while a plan is established.
- Generally, suction electrocautery is sufficient to clear bleeding and control ruptured vessels.
- Occasionally, a figure-of-eight suture is needed to oversew the vessel. Typically, an absorbable suture on a tapered needle is used.
- Once active bleeding is controlled, it is advisable to identify other potential sites of bleeding. This can be performed by "roughing up" the tonsillar fossae with the Hurd retractor or tonsil ball.
- The stomach must be suctioned of blood contents because this is likely to cause significant nausea and vomiting, the retching associated with which can instigate further bleeding. As the blood clots in the stomach frequently block the suction, repositioning of the orogastric tube and irrigation with saline are often needed to completely evacuate and decompress the stomach.

Common Errors in Technique

- Failure to grasp a large enough bite of tissue will lead to excessive bleeding or loss of plane from regrasping or tearing tonsillar tissue.
- Failure to identify the proper plane of dissection may result in cumbersome bleeding.
- "Chasing" inferior pole tonsillar tissue rather than creating an arbitrary transition between tonsillar lymphoid tissue and lingual lymphoid tissue may result in troublesome immediate and delayed bleeding.
- Excessive removal of mucosa and exposure of the superior constrictor muscle will result in increased postoperative pain.

POSTOPERATIVE PERIOD

Postoperative Management

- Criteria for inpatient admission postoperatively include OSA (AHI >10 and/or O_2 nadir <80%), younger than 3 years of age, obesity, cardiopulmonary comorbidities, neuromuscular disorders, failure to thrive, recent illness, and craniofacial abnormalities.[5]
- Patients with poor oral intake or oxygen desaturations in the Post-Anesthesia Care Unit (PACU) should also be admitted.
- In keeping with the CPG recommendations against the use of codeine, there have been several studies relating the efficacy and safety of alternating liquid acetaminophen (15 mg/kg every 4 hours, maximum of 5 doses/24 hours) and ibuprofen (10 mg/kg every 6 hours) for postoperative pain management. Be mindful of maximum daily doses.
- Nonsteroidal anti-inflammatory drugs (NSAIDs), with the exception of ketorolac, have not been shown to increase posttonsillectomy hemorrhage rates.
- Maintaining adequate hydration and administering medication on a scheduled basis are strategies to minimize pain.
- When a child is refusing by-mouth (PO) intake, rectal formulations of acetaminophen may be tried.
- If stronger pain medication is needed, we generally use a hydrocodone- or oxycodone-based elixir.
- There have been mixed results when examining the efficacy of postsurgical antibiotics in reducing pain. When analyzed together, the data suggest that routine prescription of postoperative antibiotics should not be given.
- There may be a role for postoperative oral steroids, because reduction in pain and improvement in activity, PO intake, and tonsillar fossa epithelialization were demonstrated when compared to children who did not receive oral steroids.
- The role of other adjunctive medications such as mouth rinses and sprays is less clear and generally prescribed in a provider-preference fashion.

Complications

- The number and severity of posttonsillectomy complications (Table 192.4) highlight the misconception that tonsillectomy is a minor procedure.
- Nausea, vomiting, and dehydration/poor PO intake represent the most common complications of tonsillectomy and are most often related to inadequate pain control.
- Posttonsillectomy hemorrhage (PTH) is the most commonly encountered serious complication after tonsillectomy.
  - Bleeding occurring during the first 24 hours is known as primary PTH and occurs approximately 0.2% to 2.2% of the time.
  - Primary PTH is probably due to inadequate hemostasis at surgery.
  - Secondary PTH occurs after 24 hours but tends to peak at 7 to 10 days postoperatively. The cause of late bleeding is unclear but is believed to be related to the shedding of eschar formed at the time of surgery. Secondary PTH occurs 0.1% to 3% of the time.
  - In a large review from the United Kingdom, patients with recurrent tonsillitis (3.7%) had higher bleeding rates than those with OSA only (1.4%). The highest rates were in patients undergoing a Quinsy tonsillectomy (5.4%).
  - The method of tonsillectomy and PTH rates have been scrutinized with conflicting results. In general, "hot" surgical techniques (coblation, monopolar cautery) have increased secondary PTH rates when compared to cold steel techniques with packing or ligature. This is likely related to the vessel injury and eschar formed by the electricity, which becomes exposed in a delayed fashion.
  - As mentioned earlier, there is no increased rate of PTH associated with NSAIDs in tonsillectomy; however, there may be an increased rate in tonsillotomy.
- Post-obstructive or negative pressure pulmonary edema is the sudden onset of pulmonary edema following the relief of obstruction. It may occur following the relief of an acute obstruction (e.g., laryngospasm, strangulation) and rarely occurs following the relief of chronic upper airway obstruction as seen in tonsillectomy. The diagnosis is made by history, physical, and chest radiograph and, once recognized, is treated with supportive care (diuretics, supplemental oxygen, and positive airway pressure).
- Death is exceptionally rare following tonsillectomy (1/16,000 to 1/35,000) and is most often related to severe hemorrhage, aspiration, cardiopulmonary failure, or electrolyte imbalance.

Alternative Management Plan

- CPAP and watchful waiting for SDB/OSA
- Although tonsillectomy and adenoidectomy are considered first-line surgical treatment for SDB/OSA, several other procedures are successfully used in appropriately selected children with persistent OSA following tonsillectomy and adenoidectomy:
  - Lateral pharyngoplasty
  - Lingual tonsillectomy
  - Lingualplasty
  - Laser/radiofrequency/coblation midline glossectomy
  - Maxillomandibular advancement
  - Transpalatal advancement pharyngoplasty
  - Mandibular distraction osteogenesis
  - Uvulopalatopharyngoplasty
  - Nasal septoplasty and inferior reduction turbinoplasty
  - Supraglottoplasty
  - Genioglossal advancement with hyoid myotomy or thyrohyoid suspension
  - Tracheotomy
- In the absence of coindications of recurrent tonsillitis discussed earlier (peritonsillar abscess, significant school absenteeism), observation for at least 12 months may be appropriate due to the lack of available data on performing tonsillectomy prior to 1 year of recurrent tonsillitis. Many patients with recurrent tonsillitis will resolve spontaneously within this time frame.

DISCUSSION

Evidence-Based Medicine Question

Is tonsillectomy an effective treatment for SDB/OSA?

In 2015 Cochrane meta-analyses of the Childhood Adenotonsillectomy Trial (CHAT), Goldstein et al. and Sudarsan et al. found moderate quality evidence that children with mild to moderate OSA benefit from early adenotonsillectomy in objective quality of life measures and caregiver-reported symptoms and behavior. There was high-quality evidence that adenotonsillectomy improves polysomnographic results. The comparison groups in these studies were watchful waiting or children treated with CPAP. In practice, the success of tonsillectomy is most often measured by reported improvement in symptoms by caregivers. In otherwise healthy children, postoperative PSG is only pursed on the basis of persistent symptoms or moderate to severe pretonsillectomy OSA. Additionally, a postoperative PSG should be repeated in children with obesity, craniofacial anomalies, and neurologic disorders.

Is Tonsillectomy an Effective Treatment for Recurrent Tonsillitis?

Since the introduction and near-universal adoption of the Paradise criteria, there have been many studies conveying the success rate of tonsillectomy for recurrent infectious pharyngotonsillitis. One systematic review of tonsillectomy for recurrent infections found that the frequency of infections was reduced by 43% compared to nonsurgical intervention.

TABLE 192.4 List of Complications

- Pain
- Nausea and vomiting
- Poor feeding/dehydration
- Electrolyte imbalance
- Voice changes
- Primary or secondary hemorrhage
- Death (aspiration, cardiopulmonary failure)
- Post–obstructive pulmonary edema
- Laryngospasm
- Airway fire
- Condyle fracture, TMJ dysfunction
- Subcutaneous emphysema
- Dysgeusia/ageusia/phantogeusia
- Tongue paresthesia
- Grisel syndrome
- IJV thrombosis
- Vascular injury
- Trauma or burns to lips/teeth/gums pharyngeal wall, soft palate

IJV, Internal jugular vein; *TMJ,* temporomandibular joint.

A recent Cochrane review found that tonsillectomy reduced the frequency and duration of sore throat in the first year following surgery. The success rate of tonsillectomy for recurrent throat infections depends on adherence to Paradise criteria, because the more relaxed the indications, the lower the benefit.

Editorial Comment

I am pleased to write an editorial for this excellent chapter on tonsillectomy because it gives me an opportunity to reflect on my 50-plus years of experience with this procedure. In the early 1960s, I performed tonsillectomy primarily at the Children's Hospital of Pittsburgh, for what I thought were reasonable indications, because at that time there were no published evidence-based indications. Then in 1971, my colleague in pediatrics, Jack Paradise, called me about a child he thought might benefit from the procedure and when he asked my opinion I replied that I wasn't sure. Jack then said, "Let's do a clinical trial," which I gladly accepted. When we met in 1971 to establish the indications to be studied, he suggested seven episodes of throat infections in one year, five or more per year for 2 years, or three or more per year for 3 years. I thought they were too stringent because a third-party carrier had recommended that four episodes in 1 year was an indication. Jack replied that if the stricter indications were effective, then the next step would be to address more moderate rates.

In 1973, we were awarded a grant from the National Institutes of Health (NIH) to study the problem. In 1975, I was asked by the Centurion Society, an otolaryngology society that no longer exists, to convene a workshop on tonsillectomy and adenoidectomy. The deliberations were published but it was received with some derision by those who commissioned it, because our conclusion stated that at that time, the indications were "uncertain." In 1978 the first publication from our NIH-funded trial revealed that undocumented histories where unreliable to warrant tonsillectomy and we strongly recommended that clinical trials were sorely needed to determine strict criteria for indications.

In 1984, our first trial was published confirming that the strict criteria were effective. Then in 2002, the next trial addressed my concerns about children who were only moderately affected, which did not find tonsillectomy to be efficacious.

In 2011 the American Academy of Otolaryngology–Head and Neck Surgery published its Clinical Guideline for Tonsillectomy; this guideline accepted our 1984 indications, which had not been the case before. Then my colleague Jack Paradise called me and said, "Finally, your august Academy accepted our guideline." I replied, "Jack, it only took 27 years for it to sink in, whereas in the 1840s when Ignaz Philipp Semmelweis (1818–65) pleaded with obstetricians to wash their hands before delivering babies to prevent puerperal sepsis and probable death and it took over 40 years until Lister recommended handwashing before performing surgery. Sometimes it takes medicine a long time to catch on."

I'm proud that the relatively recent dramatic reduction in the frequency of tonsillectomy is due to awareness on the part of physicians and third-party carriers of our guidelines for the surgery when recurrent throat infection is the reason to consider it.

Charles D. Bluestone

Access the review questions and additional sources list online at http://www.expertconsult.com

REFERENCES

1. McNeill RA. A history of tonsillectomy: two millenia of trauma, haemorrhage and controversy. Ulster Med J 1990;29(1):59–63.
2. Rosenfeld RM, Green RP. Tonsillectomy and adenoidectomy: changing trends. Ann Otol Rhinol Laryngol 1990;99(3 Pt 1): 187–191.
3. Erickson BK, Larson DR, St Sauver JL, et al. Changes in incidence and indications of tonsillectomy and adenotonsillectomy, 1970–2005. Otolaryngol Head Neck Surg 2009;140(6):894–901.
4. Cullen KA, Hall MJ, Golosinskiy A. Ambulatory Surgery in the United States, 2006. US Department of Health and Human Services; 2009.
5. Baugh RF, Archer SM, Mitchell RB, et al. Clinical practice guideline: tonsillectomy in children. Otolaryngol Head Neck Surg 2011;144(Suppl. 1):S1–30.
6. Richardson MA. Sore throat, tonsillitis, and adenoiditis. Med Clin North Am 1999;83(1):75–83. viii.
7. Bitar MA, Dowli A, Mourad M. The effect of tonsillectomy on the immune system: a systematic review and meta-analysis. Int J Pediatr Otorhinolaryngol 2015;79(8):1184–1191.
8. Brodsky L. Modern assessment of tonsils and adenoids. Pediatr Clin North Am 1989;36(6):1551–1569.
9. Tang A, Benke JR, Cohen AP, et al. Influence of tonsillar size on OSA improvement in children undergoing adenotonsillectomy. Otolaryngol Head Neck Surg 2015;153(2):281–285.
10. Dyce O, McDonald-McGinn D, Kirschner RE, et al. Otolaryngologic manifestations of the 22q11.2 deletion syndrome. Arch Otolaryngol Head Neck Surg 2002;128(12):1408–1412.

REVIEW QUESTIONS

1. Which artery does not typically provide blood supply to the palatine tonsil?
   a. Facial artery
   b. Lingual artery
   c. Ascending pharyngeal artery
   d. Occipital artery
   e. Maxillary artery

2. Which item meets the Paradise criteria as an indication for tonsillectomy?
   a. 7 sore throat episodes over 2 years
   b. 3 sore throat episodes in each of last 2 years
   c. 5 sore throat episodes in 1 year
   d. 6 sore throat episodes in each of last 2 years
   e. 2 sore throat episodes over 1 month

3. Which medication is not recommended for posttonsillectomy pain control?
   a. Acetaminophen
   b. Codeine
   c. Ibuprofen
   d. Oxycodone

ADDITIONAL SOURCES

Aurora RN, Zak RS, Karippot A, et al. Practice parameters for the respiratory indications for polysomnography in children. Sleep 2011;34(3):379–388.

Aydin S, Taskin U, Altas B, et al. Post-tonsillectomy morbidities: randomised, prospective controlled clinical trial of cold dissection versus thermal welding tonsillectomy. J Laryngol Otol 2014;128(2):163–165.

Baugh RF, Archer SM, Mitchell RB, et al. Clinical practice guideline: tonsillectomy in children. Otolaryngol Head Neck Surg 2011;144 (Suppl. 1):S1–30.

Bedwell JR, Pierce M, Levy M, et al. Ibuprofen with acetaminophen for postoperative pain control following tonsillectomy does not increase emergency department utilization. Otolaryngol Head Neck Surg 2014;151(6):963–966.

Blakley BW, Magit AE. The role of tonsillectomy in reducing recurrent pharyngitis: a systematic review. Otolaryngol Head Neck Surg 2009;140(3):291–297.

Bluestone CD. Workshop on tonsillectomy and adenoidectomy. Ann Otol Rhinol Laryngol 1975;84(Suppl. 19):1–79.

Booth CL, Wang J. Occult hematologic malignancy in routine tonsillectomy specimens: a single institutional experience and review of the literature. Am J Clin Pathol 2013;140(6):807–812.

Burton MJ, Glasziou PP, Chong LY, et al. Tonsillectomy or adenotonsillectomy versus non-surgical treatment for chronic/recurrent acute tonsillitis. Cochrane Database Syst Rev 2014;11:Cd001802.

Burton MJ, Pollard AJ, Ramsden JD, et al. Tonsillectomy for periodic fever, aphthous stomatitis, pharyngitis and cervical adenitis syndrome (PFAPA). Cochrane Database Syst Rev 2014;9:Cd008669.

Chan SC, Dawes PJ. The management of severe infectious mononucleosis tonsillitis and upper airway obstruction. J Laryngol Otol 2001;115(12):973–977.

Chow W, Rotenberg BW. Discontinuing routine histopathological analysis after adult tonsillectomy for benign indication. Laryngoscope 2015;125(7):1595–1599.

Curtis JL, Harvey DB, Willie S, et al. Causes and costs for ED visits after pediatric adenotonsillectomy. Otolaryngol Head Neck Surg 2015;152(4):691–696.

Densert O, Desai H, Eliasson A, et al. Tonsillotomy in children with tonsillar hypertrophy. Acta Otolaryngol 2001;121(7):854–858.

Dhiwakar M, Clement WA, Supriya M, et al. Antibiotics to reduce post-tonsillectomy morbidity. Cochrane Database Syst Rev 2012;12:Cd005607.

Dohar JE, Bonilla JA. Processing of adenoid and tonsil specimens in children: a national survey of standard practices and a five-year review of the experience at the Children's Hospital of Pittsburgh. Otolaryngol Head Neck Surg 1996;115(1):94–97.

D'Souza JN, Schmidt RJ, Xie L, et al. Postoperative nonsteroidal anti-inflammatory drugs and risk of bleeding in pediatric intracapsular tonsillectomy. Int J Pediatr Otorhinolaryngol 2015;79(9):1472–1476.

Duarte VM, Liu YF, Shapiro NL. Coblation total tonsillectomy and adenoidectomy versus coblation partial intracapsular tonsillectomy and adenoidectomy in children. Laryngoscope 2014;124(8): 1959–1964.

Elbadawey MR, Hegazy HM, Eltahan AE, et al. A randomised controlled trial of coblation, diode laser and cold dissection in paediatric tonsillectomy. J Laryngol Otol 2015;129(11):1058–1063.

England RCoSo. National prospective tonsillectomy audit: final report of an audit carried out in England and Northern Ireland between July 2003 and September 2004, 2005.

Ericsson E, Graf J, Lundeborg-Hammarstrom I, et al. Tonsillotomy versus tonsillectomy on young children: 2 year post surgery follow-up. J Otolaryngol Head Neck Surg 2014;43(1):26.

Farmer SE, Khatwa MA, Zeitoun HM. Peritonsillar abscess after tonsillectomy: a review of the literature. Ann R Coll Surg Engl 2011;93(5):353–355.

Fedorowicz Z, van Zuuren EJ, Nasser M, et al. Oral rinses, mouthwashes and sprays for improving recovery following tonsillectomy. Cochrane Database Syst Rev 2013;9:Cd007806.

Gabriel P, Mazoit X, Ecoffey C. Relationship between clinical history, coagulation tests, and perioperative bleeding during tonsillectomies in pediatrics. J Clin Anesth 2000;12(4):288–291.

Galluzzi F, Pignataro L, Gaini RM, et al. Drug induced sleep endoscopy in the decision-making process of children with obstructive sleep apnea. Sleep Med 2015;16(3):331–335.

Goldstein NA, Pugazhendhi V, Rao SM, et al. Clinical assessment of pediatric obstructive sleep apnea. Pediatrics 2004;114(1):33–43.

Haddow K, Montague ML, Hussain SS. Post-tonsillectomy haemorrhage: a prospective, randomized, controlled clinical trial of cold dissection versus bipolar diathermy dissection. J Laryngol Otol 2006;120(6):450–454.

Hultcrantz E, Linder A, Markstrom A. Long-term effects of intracapsular partial tonsillectomy (tonsillotomy) compared with full tonsillectomy. Int J Pediatr Otorhinolaryngol 2005;69(4):463–469.

Kim JW, Mun SJ, Lee WH, et al. Post-tonsillectomy hemorrhage in children: a single surgeon's experience with coblation compared to diathermy. Eur Arch Otorhinolaryngol 2013;270(1):339–344.

Lachanas VA, Hajiioannou JK, Karatzias GT, et al. Comparison of LigaSure vessel sealing system, harmonic scalpel, and cold knife tonsillectomy. Otolaryngol Head Neck Surg 2007;137(3):385–389.

Lachanas VA, Prokopakis EP, Bourolias CA, et al. Ligasure versus cold knife tonsillectomy. Laryngoscope 2005;115(9):1591–1594.

Lee MS, Montague ML, Hussain SS. Post-tonsillectomy hemorrhage: cold versus hot dissection. Otolaryngol Head Neck Surg 2004;131(6):833–836.

Lewis SR, Nicholson A, Cardwell ME, et al. Nonsteroidal anti-inflammatory drugs and perioperative bleeding in paediatric tonsillectomy. Cochrane Database Syst Rev 2013;7:Cd003591.

Liu C, Ulualp SO. Outcomes of an alternating ibuprofen and acetaminophen regimen for pain relief after tonsillectomy in children. Ann Otol Rhinol Laryngol 2015;124(10):777–781.

Marcus CL, Moore RH, Rosen CL, et al. A randomized trial of adenotonsillectomy for childhood sleep apnea. N Engl J Med 2013;368(25):2366–2376.

Mattos JL, Robison JG, Greenberg J, et al. Acetaminophen plus ibuprofen versus opioids for treatment of post-tonsillectomy pain in children. Int J Pediatr Otorhinolaryngol 2014;78(10):1671–1676.

Mitchell RB, Pereira KD, Friedman NR. Sleep-disordered breathing in children: survey of current practice. Laryngoscope 2006;116(6):956–958.

Mowatt G, Cook JA, Fraser C, et al. Systematic review of the safety of electrosurgery for tonsillectomy. Clin Otolaryngol 2006;31(2):95–102.

O'Leary S, Vorrath J. Postoperative bleeding after diathermy and dissection tonsillectomy. Laryngoscope 2005;115(4):591–594.

Paradise JL, Bluestone CD, Bachman RZ, et al. Efficacy of tonsillectomy for recurrent throat infection in severely affected children. Results of parallel randomized and nonrandomized clinical trials. N Engl J Med 1984;310(11):674–683.

Paradise JL, Bluestone CD, Bachman RZ, et al. History of recurrent sore throat as an indication for tonsillectomy. Predictive limitations of histories that are undocumented. N Engl J Med 1978;298(8):409–413.

Paradise JL, Bluestone CD, Colborn DK, et al. Tonsillectomy and adenotonsillectomy for recurrent throat infection in moderately affected children. Pediatrics 2002;110(1 Pt 1):7–15.

Park SK, Kim J, Kim JM, et al. Effects of oral prednisolone on recovery after tonsillectomy. Laryngoscope 2015;125(1):111–117.
Patel HH, Straight CE, Lehman EB, et al. Indications for tonsillectomy: a 10 year retrospective review. Int J Pediatr Otorhinolaryngol 2014;78(12):2151–2155.
Ragab MA, Atef A, Mosleh M, et al. Bipolar scissors tonsillectomy: what are the advantages? J Otolaryngol Head Neck Surg 2011;40(3):256–260.
Rokkjaer MS, Klug TE. Malignancy in routine tonsillectomy specimens: a systematic literature review. Eur Arch Otorhinolaryngol 2014;271(11):2851–2861.
Roland PS, Rosenfeld RM, Brooks LJ, et al. Clinical practice guideline: polysomnography for sleep-disordered breathing prior to tonsillectomy in children. Otolaryngol Head Neck Surg 2011;145(Suppl. 1): S1–15.
Roth JA, Pincock T, Sacks R, et al. Harmonic scalpel tonsillectomy versus monopolar diathermy tonsillectomy: a prospective study. Ear Nose Throat J 2008;87(6):346–349.
Shay S, Shapiro NL, Bhattacharyya N. Revisit rates and diagnoses following pediatric tonsillectomy in a large multistate population. Laryngoscope 2015;125(2):457–461.
Simon LM, Matijasec JW, Perry AP, et al. Pediatric peritonsillar abscess: quinsy versus interval tonsillectomy. Int J Pediatr Otorhinolaryngol 2013;77(8):1355–1358.
Soderman AC, Odhagen E, Ericsson E, et al. Post-tonsillectomy haemorrhage rates are related to technique for dissection and for haemostasis. An analysis of 15734 patients in the National Tonsil Surgery Register in Sweden. Clin Otolaryngol 2015;40(3):248–254.
Stevenson DS, Webster G, Stewart IA. Acute tonsillectomy in the management of infectious mononucleosis. J Laryngol Otol 1992;106(11):989–991.
Sudarsan SS, Paramasivan VK, Arumugam SV, et al. Comparison of treatment modalities in syndromic children with obstructive sleep apnea—a randomized cohort study. Int J Pediatr Otorhinolaryngol 2014;78(9):1526–1533.
Thottam PJ, Christenson JR, Cohen DS, et al. The utility of common surgical instruments for pediatric adenotonsillectomy. Laryngoscope 2015;125(2):475–479.
Udeshi A, Cantie SM, Pierre E. Postobstructive pulmonary edema. J Crit Care 2010;25(3):508. e1-e5.
Uliel S, Tauman R, Greenfeld M, et al. Normal polysomnographic respiratory values in children and adolescents. Chest 2004;125(3):872–878.
Van Kooy MA, Gargiulo RF. Postobstructive pulmonary edema. Am Fam Physician 2000;62(2):401–404.
Venekamp RP, Hearne BJ, Chandrasekharan D, et al. Tonsillectomy or adenotonsillectomy versus non-surgical management for obstructive sleep-disordered breathing in children. Cochrane Database Syst Rev 2015;10:Cd011165.
Walker P, Gillies D. Post-tonsillectomy hemorrhage rates: are they technique-dependent? Otolaryngol Head Neck Surg 2007;136 (Suppl. 4):S27–31.
Walner DL, Miller SP, Villines D, et al. Coblation tonsillectomy in children: incidence of bleeding. Laryngoscope 2012;122(10):2330–2336.
Windfuhr JP, Savva K, Dahm JD, et al. Tonsillotomy: facts and fiction. Eur Arch Otorhinolaryngol 2015;272(4):949–969.
Wood JM, Cho M, Carney AS. Role of subtotal tonsillectomy ('tonsillotomy') in children with sleep disordered breathing. J Laryngol Otol 2014;128(Suppl. 1):S3–7.

193 Laryngomalacia

Prasad John Thottam, Sukgi Choi

INTRODUCTION

Laryngomalacia-associated breathing was first described in 1851 by the French physician Rilliet in a case report of a benign inspiratory noise from an infant. This sound was subsequently termed stridor in 1853 by Rilliet and Barthez in their textbook, *Of Diseases of Children*. It was not until 1897 that the laryngoscopic physical findings associated with this disorder were accurately described in 16 patients by Sutherland and Lack as congenital laryngeal obstruction, while the actual term "laryngomalacia" ("malacia," Greek *malakia*—softening of part of tissue) was not used until 1942 when Chevalier Jackson described this disorder.

The underlying etiology for laryngomalacia remains relatively unknown. The predominant underlying concepts to explain this supraglottic instability are excess redundant mucosa, poor cartilaginous support, and/or abnormal neurologic laryngeal tone.[1] Kletzker observed mucosal hypertrophy in histologic normal supraglottic tissues and proposed that pulsion forces from the back and forth of mucosa on overlying cartilage resulted in hypermobility and redundancy, which then becomes obstructive.[2] The lack of cartilaginous support (chondromalacia) theory has become controversial by histologic studies demonstrating similar cartilage in patients having laryngomalacia when compared to controls.[1,3]

The predominant theory to date is that laryngomalacia may be a result of delayed neurologic function and tone in the supraglottic laryngeal structures.[3] The work by Thompson correlated increased laryngopharyngeal sensory testing thresholds with laryngomalacia severity,[3] while a recent supraglottic histologic study demonstrated increased neural perimeter and surface area innervation by the superior laryngeal nerve branch of vagus in patients with laryngomalacia when compared to controls.[4] This information supports altered vagal neuronal innervation and stimulation in this patient population.

Laryngomalacia affects approximately 35% to 75% of infants presenting with stridor and is the most common cause of stridor in the pediatric age group.[1] This disorder primarily presents with inspiratory stridor as early as 2 weeks of age, with progressive worsening up to 4 to 8 months and resolution typically by 12 to 18 months without requiring surgical intervention. Respiratory symptoms are often exacerbated with feeding, exertion, and supine positioning. Swallowing dysfunctions (penetration or aspiration) have been reported in up to 88% of patients with severe laryngomalacia.[5] A discoordinated suck, swallow, breath sequence can result in respiratory distress and arrest, insufficient weight gain/failure to thrive, feeding complications, poor quality of life, and high parental anxiety.[6]

Clinically, this condition is often separated into mild, moderate, and severe categories based on feeding and obstructive symptomatology.[3] Mild disease is described as inconsequential intermittent stridor and sporadic feeding difficulties, and moderate disease presents with dyspnea and consistent feeding difficulties.[3] Severe laryngomalacia is present in approximately 20% of infants with stridor and is characterized by recurrent cyanosis, apneic events, and difficulty with feeding, often with associated penetration/aspiration and failure to thrive.[3]

Anatomically, laryngomalacia is described as the collapse of supraglottic tissue with associated inspiratory stridor and upper airway obstruction.[1] This supraglottic dysfunction is primarily represented by prolapse of arytenoid cartilage or redundant tissue (Figs. 193.1 and 193.2), foreshortened aryepiglottic (AE) folds (Fig. 193.3; also see Fig. 193.2), and/or epiglottal prolapse/omega-shaped epiglottis (see Fig. 193.3).[7] This prolapse of tissue causes obstruction of the glottic introitus upon inspiratory associated negative pressure, resulting in airway distress.

First described in 1922 by Iglauer, supraglottoplasty is a generalized term used to describe a surgical technique in which the supraglottic structures of the larynx are altered in a manner to prevent further collapse and subsequent obstruction of the glottic introitus. This technique did not replace the tracheostomy for relief of laryngomalacia until the 1980s when refined and modernized by Drs. Lane and Seid.

Supraglottoplasty has a reported success rate of over 90% in otherwise healthy children with this disease.[8] Infants with underlying neurologic conditions require surgical intervention at higher rates and have higher failure rates.[9] As high as 70% of neurologically delayed children with laryngomalacia will require revision supraglottoplasty, and up to 60% of supraglottoplasty failures in the neurologically delayed may require tracheostomy.[9]

Today the modern supraglottoplasty is considered the standard of care in the treatment of severe laryngomalacia. This procedure is performed transorally using suspension laryngoscopy and microlaryngeal instruments. It has a high success and a low morbidity rate, making it a first-line option for the otolaryngologist.

Key Learning Points

1. Laryngomalacia is the most common cause of stridor in the pediatric age group.
2. Laryngomalacia is predominately self-limiting, with resolution typically by 18 months of age.
3. Children with laryngomalacia can present with various aerodigestive complaints that can affect overall child health as well as child and parental quality of life.
4. Supraglottoplasty is a surgical technique reserved for severe laryngomalacia and is a safe procedure.
5. Supraglottoplasty is the surgical treatment of choice when conservative therapy fails.

PREOPERATIVE

History

1. Complete prenatal and birth history should be obtained:
   a. Were prenatal visits and care completed?
   b. Maternal exposure to alcohol, tobacco, drugs, or teratogens
   c. Birthing history (complications, cesarean section, vaginal delivery)
   d. Full or preterm birth—number of weeks
   e. APGAR score

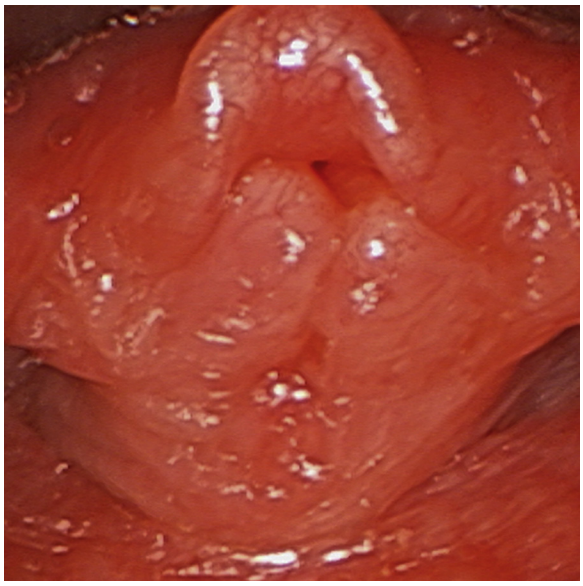

Fig. 193.1. Arytenoid prolapse obstructing the glottis introitus.

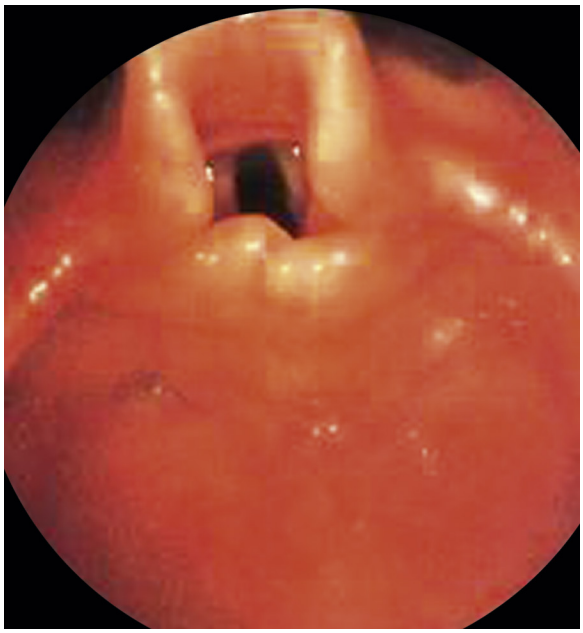

Fig. 193.2. Shortened aryepiglottic folds.

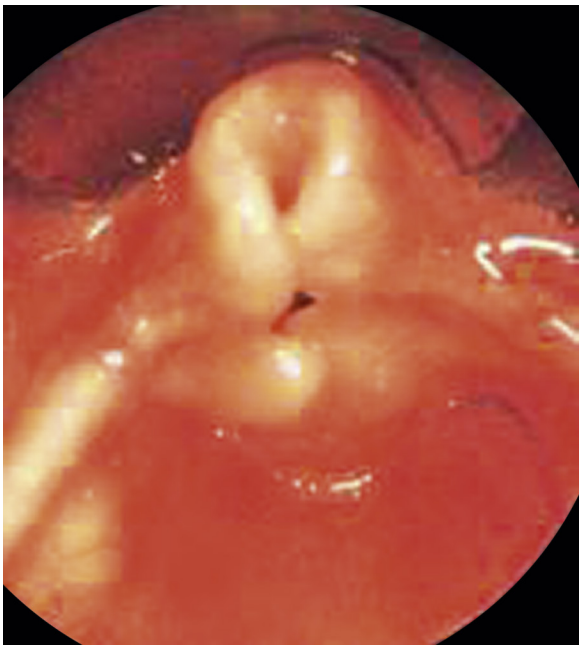

Fig. 193.3. Omega-shaped epiglottis.

f. Intubation history, ICU stay, and any further interventions should be documented.
g. Congenital anomalies and syndromes
   1) Estimated in 8% to 20% of patients with laryngomalacia and up to 40% in patients diagnosed with severe laryngomalacia[3,8]
   2) Down syndrome is the most common associated genetic disorder.[3,8]

2. Questions directed toward laryngomalacia and airway complaints
   a. When did the breathing problems begin?
   b. Does the child having any problems feeding?
   c. Can you please describe the stridor?
      1) Inspiratory: Caused by obstruction above the vocal folds and is most commonly secondary to laryngomalacia
      2) Biphasic: Caused by obstruction or narrowing at or directly below the vocal folds and is demonstrated in vocal fold immobility, croup, or subglottic stenosis
      3) Expiratory: Caused by proximal and distal trachea pathology and most commonly a sign of tracheomalacia
   d. Is patient's breathing or stridor worsened with head or body position?
      1) Laryngomalacia-associated stridor and respiratory distress are worsened with head flexion and when lying in the supine position. They are often improved with head extension and prone positioning.[3]
   e. Please describe any other situations in which stridor or breathing is worsened?
      1) Classically, laryngomalacia-associated complaints are worse with agitation, excitement, and feeding.
   f. The presence of GERD and swallowing dysfunction–associated signs and symptoms as well as possible treatments should always be questioned in these patients.
      1) Coughing or choking with or after feeds, frequent regurgitation, presence of agitation or back arching when lying supine
3. Medications
   a. Antireflux therapy
      1) The high incidence of GERD in patients having laryngomalacia suggests that antireflux medication and feeding modification are essential in these patients prior to and after both conservative and surgical therapy.
   b. Antiplatelet medications and herbal supplementation associated with increased bleeding should be discontinued prior to surgical intervention.
4. Prior treatment
   a. If GERD is present, it should be controlled prior to supraglottoplasty.
      1) Gastroenterology consult should be considered if reflux is not controlled with conventional management.
      2) Nissen fundoplication can be considered for most severe cases of GERD with laryngomalacia.
5. Family history
   a. No significant link to family history of laryngomalacia

Physical Examination

1. General
   a. Patient's general appearance and overall well-being should be examined.
      1) Patient size and weight for age
   b. Patient's respiratory status should be evaluated.
      1) How audible and consistent is the stridor?
      2) Presence of tachypnea or dyspnea
      3) Cyanosis of lips and/or extremities
2. Nasal examination
   a. Assess for nasal flaring and proper air movement.
   b. Piriform aperture stenosis, choanal stenosis, and choanal atresia should be ruled out by nasal endoscopy or at the minimum cannulation with a 6- or 8-French nasogastric tube.
3. Oral examination
   a. Assess for micro- or retrognathia.
      1) Patients often will have airway obstruction secondary to retro-displacement of tongue.
   b. Assess for macroglossia.
      1) Patients can have airway obstruction secondary to enlargement of the tongue.
   c. Assess the size of the tonsils.
4. Neck and chest examination
   a. Assess for supra-, inter-, and/or substernal retractions.
   b. A stethoscope can be placed over the neck, specifically over the supraglottis, glottis, subglottis, and over the thorax to localize stridor and/or wheezing.
   c. Assess for pectus excavatum.
      1) Defined as concavity of sternocostal cartilage of the anterior chest wall
      2) Can be associated with laryngomalacia and primarily seen in moderate and severe cases
5. FFL ± fiberoptic endoscopic examination of swallowing (FEES)
   a. Allows for complete evaluation of upper airway
   b. Allows for examination of supraglottic structures on inspiration and associated pathology contributing to laryngomalacia
   c. GERD changes can be demonstrated by arytenoid, postglottic, and vocal fold edema and/or erythema.
   d. FEES can be performed to assess swallowing status.
      1) This can be performed with a speech pathologist.
      2) Aids in assessment of disease severity and effect on swallowing
      3) Allows for assessment and management of safe consistencies for feeding in order to prevent aspiration and penetration

Imaging/Further Diagnostic Evaluation

None
In most situations, clinical history and physical examination provide adequate information for the nonsurgical or surgical management of laryngomalacia.
Polysomnogram—optional
Patients with laryngomalacia often demonstrate associated sleep apnea and hypopnea. A polysomnogram (PSG) allows the physician to document the degree of disease and can provide objective information of apnea status for poor historians—clinical histories that do not correlate with anatomic findings and vice versa. It is also useful when treating patients with associated comorbidities and/or SALs, as you can objectively follow the course of the disease and response to treatment.
Modified barium swallow (MBS) study—optional
MBS can be used to assess aspiration and penetration status in patients that do not tolerate FEES, have an incomplete FEES, or if the status is questionable.

Indications

1. Severe laryngomalacia
2. Direct laryngoscopy and bronchoscopy with possible supraglottoplasty should be performed on all of the following:[7]
   a. Infants with laryngomalacia and severe respiratory distress, failure to thrive, apnea events, or recurrent pneumonia
   b. Infants with symptoms that do not match the degree of laryngomalacia noted on flexible fiberoptic laryngoscopy (FFL) to rule out synchronous airway lesions (SALs)

Contraindications

1. Medical comorbidities with increased risk of anesthesia and inability to tolerate spontaneous ventilation
2. Patients currently intubated or tracheostomy tube dependent secondary to ventilator dependence (e.g., bronchopulmonary dysplasia)
3. SALs of higher contribution to airway obstruction
   a. SALs are present in 27% of patients with laryngomalacia[10]

Preoperative Preparation

1. Respiratory and swallowing status should be stabilized to the best scenario prior to surgery (supplemental oxygen, hospital admission, thickening of feeds, and nasogastric tube feeding).
2. GERD should be controlled prior to surgery.
3. Discontinuation of any anticoagulants at appropriate time or reversal
4. Complications and indications of the procedure should be discussed at length with responsible individuals.

OPERATIVE

Anesthesia

General with spontaneous or jet ventilation
Combustion precautions taken if lasers are used (oxygen <30%)

Positioning

Supine, shoulders elevated, and neck extended with suspension laryngoscope secured on Mayo stand

Medication Prophylaxis

No antibiotics
Dexamethasone 0.5 mg/kg up to 20 mg pre- or intraoperatively

Monitoring

Pulse oximetry

Instruments and Equipment to Have Available

1. Lindholm, Parson, or Dedo suspension laryngoscope
2. Lewy or Benjamin-Parson laryngoscope holder
3. Mayo stand
4. Microlaryngeal cup forceps
5. Microlaryngeal scissors (curved or straight)
6. Zero degree rigid endoscope (4-mm 0 Hopkins rod) or surgical microscope with 400-mm objective lens
7. Optional: CO_2 laser (2 to 4 watts) or KTP laser (1 to 2 watts)
8. Optional: Angled tip laryngeal microdébrider

Key Anatomic Landmarks

1. AE fold
2. Arytenoid cartilage
3. Cuneiform cartilage
4. Corniculate cartilage
5. Epiglottis

Prerequisite Skills

1. Basic microsuspension laryngoscopy
2. Direct laryngoscopy and bronchoscopy

Operative Risks

1. Intraoperative bleeding and airway occlusion
   a. To avoid this, a long laryngeal suction and an appropriate-sized endotracheal tube should be available.
2. Airway fire (when laser or electrocautery is utilized)
   a. Heat-based instruments should only be used when oxygen is below 30%.
   b. Bulb syringe with normal saline should be readily available for copious irrigation.
3. Supraglottic swelling and associated obstruction
   a. Ensure good position prior to suspension with release during prolonged cases.

b. Intravenous dexamethasone can be utilized prior, during, and post surgery to decrease swelling.

Surgical Technique

1. Direct laryngoscopy and laryngotracheal anesthesia
   a. Using a laryngoscope in the left hand, the oral cavity is entered from the right side medial to the oral commissure. The tongue is then swept to the left, and the laryngoscope is inserted into the vallecula.
   b. Using an anterior superior motion, the tongue is brought out of view, the epiglottis is moved to the anterior superior position, and all supraglottic structures are now in view.
   c. Once in position, laryngotracheal anesthesia is administered using a composition of topical 4% lidocaine HCl solution.
      1) Lidocaine HCl topical solution should be less than 300 mg lidocaine and should not exceed 4 mg/kg of body weight.
   d. Bronchoscopy should be performed prior to supraglottoplasty in order to rule out SALs.
2. Laryngoscope position and suspension laryngoscopy
   a. Once in proper/desired view of the supraglottic anatomy, the laryngoscope holder is then connected, and the stabilizing arm is lowered onto the Mayo stand to secure the suspended view.
      1) Jet ventilation or passive oxygen can be administered through side ports on certain laryngoscopes.
      2) If a laser is being used, suction can be administered through side ports on certain laryngoscopes for smoke evacuation and oxygen administered should be below 30%.
      3) The microscope should be adjusted to provide proper view of the supraglottic anatomy while allowing adequate distance for operating.
3. Incision of foreshortened AE folds (laryngomalacia type I)
   a. Ensure proper view of AE folds.
   b. Using cup or grasping forceps, apply adrenaline-saturated pledgets to area of planned incision.
      1) The planned incision should be at the anterior aspect of the AE fold where it attached to posterior aspect of the epiglottis.

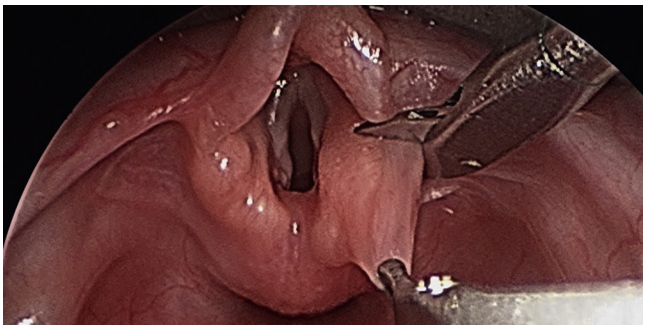

Fig. 193.4. Incision of the right aryepiglottic fold using microlaryngeal scissors and a microlaryngeal cup-forcep.

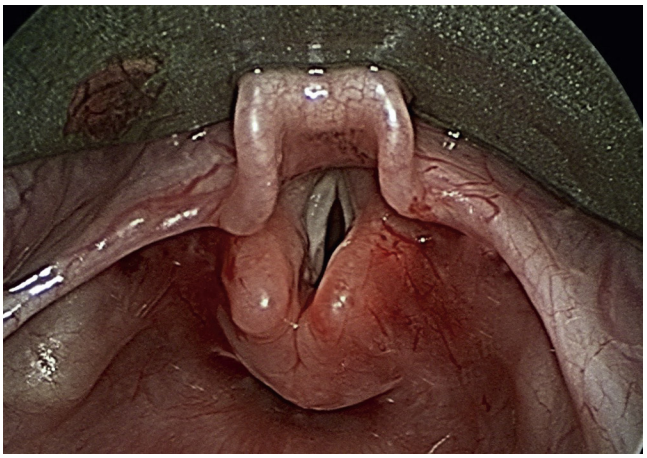

Fig. 193.5. Supraglottis after bilateral incisions of the aryepiglottic folds.

   c. Using microlaryngeal scissors, divide the AE fold down to the level of the false vocal fold (Fig. 193.4).
      1) Using a two-handed instrumentation technique, the opposing hand can be used to assist in tensing the AE fold mucosa by grasping the mucosa of the ipsilateral posterior arytenoid and providing opposing posterior force.
   d. Control any bleeding with adrenaline-soaked pledgets and microlaryngeal suction.
   e. Repeat on the contralateral side.
   f. Fig. 193.5: Supraglottis postincision of AE folds
4. Excision of redundant arytenoid mucosa (laryngomalacia type II)
   a. Ensure proper view of the arytenoids with focus on the posterior lateral aspects.
   b. Using cup or grasping forceps, apply adrenaline-saturated pledgets to area of planned excision.
      1) The planned excision should be at the posterior lateral aspect of the superior portion of the arytenoid mucosa.
   c. Using microlaryngeal scissors and cup forceps, the redundant mucosa on the arytenoid is removed in a medial to lateral, inferior to superior fashion (Fig. 193.6).
5. Epiglottopexy (laryngomalacia type III)
   a. The laryngoscope is positioned to ensure proper view of the lingual surface of the epiglottis and the base of the tongue.
   b. Needle-point cautery (CO_2 or KTP laser could also be used) is used to remove mucosa from both the lingual surface of the epiglottis and the base of the tongue.

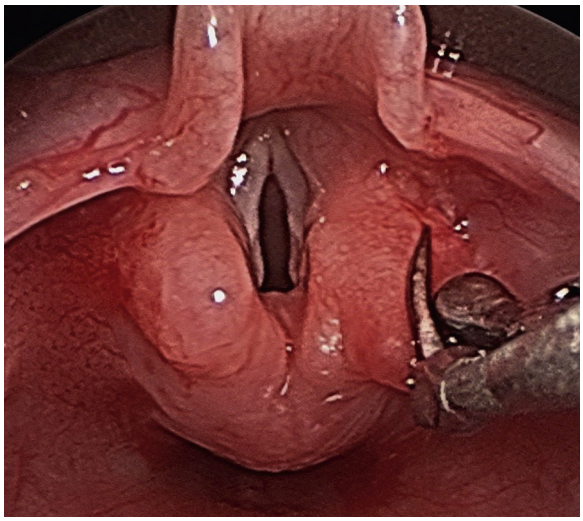

Fig. 193.6. Excision of redundant right arytenoid tissue using curved microlaryngeal scissors and a microlaryngeal cup forcep.

   c. Sutures are placed through the superior aspect of the denuded lingual surface of the epiglottis and then through the base of the tongue.
      1) For this procedure, 5-0 polydioxanone suture (PDS) on a P-2 needle is used.
   d. Knots are secured with an endoscopic knot-pushing instrument.
   e. Two to three sutures are usually adequate for desired result.

Common Errors in Technique

1. Inadequate release/incision of AE folds or inadequate excision of redundant mucosa
   a. Without proper release and incision down to directly above the false vocal folds, incomplete results can occur.
   b. This often requires revision supraglottoplasty.
2. Overly aggressive excision of supraglottic tissue
   a. Supraglottic stenosis can occur as a result of overly aggressive excision of supraglottic tissue. This occurs when excision of redundant arytenoid mucosa is performed in a medial direction toward the glottis introitus and/or toward the interarytenoid region.
   b. Aspiration or penetration can result from overly aggressive surgery in which the supraglottic mucosa has decreased sensation or too much tissue and associated protective elements are removed.
3. Prolonged suspension
   a. Care must always be taken to release the suspension element and ensure that excessive and prolonged pressure are not placed on delicate tissue. When in suspension, check lips, tongue, and supraglottic tissue position.
      1) A 20-minute maximum suspension time is often used to prevent pressure necrosis and/or related swelling.

POSTOPERATIVE

Postoperative Care

1. It is routine for patients after supraglottoplasty to be observed overnight in the intensive care unit (ICU).
2. O_2 level should be monitored using continuous pulse oximetry.
3. Dexamethasone can be administered every 6 to 8 hours for airway edema.
4. Optional: On postoperative day 1, a bedside swallowing evaluation by a speech pathologist can be performed to evaluate safety of oral intake.
5. Patient can be discharged after 24 hours if stable.

Complications

1. Postoperative edema and associated airway obstruction
2. Dysphagia
3. Aspiration or penetration
4. Residual laryngomalacia
5. Supraglottic stenosis

Alternative Management Plan

1. Observation is the most appropriate form of management for the majority of non life-threatening cases of laryngomalacia, as most symptoms will resolve by 18 months of age. During this time, associated factors such as reflux can be managed conservatively.
2. Historically, tracheotomy was the standard therapy for severe laryngomalacia, though this is now only used in as an absolute last resort after failed supraglottoplasty attempts and is primarily performed on children with other comorbidities.

DISCUSSION

Evidence-Based Medicine Questions

1. Are laryngomalacia and gastroesophageal reflux disease related? How do they affect each other?

Gastroesophageal reflux disease (GERD) has been reported in up to 70% of patients with laryngomalacia and has been suggested as a potential causative factor in laryngomalacia exacerbation. GERD prevalence in laryngomalacia may be the result of two distinct factors. The lower esophageal sphincter (LES) is theorized to have similar vagal innervation as the supraglottic and thus decreased tone in children with laryngomalacia. Anatomically, the augmented labored respiratory pattern and increased intrathoracic pressure generated in these patients may encourage extraesophageal reflux. GERD in such situations can result in worsening of laryngomalacia by causing increased edema of the supraglottic tissue and further desensitization.

2. When is supraglottoplasty indicated, and how successful is supraglottoplasty in the treatment of laryngomalacia?

Supraglottoplasty is the mainstay of surgical treatment for laryngomalacia.[1] Though the decision as to who requires surgical intervention is surgeon dependent, absolute indications include severe airway obstruction with witnessed apneas or retractions, cor pulmonale, development of pectus excavatum, and failure to thrive.[1] Relative indications are aspiration with recurrent pneumonia, weight loss, and difficulty with feeding despite reflux management.[1] In patients with both clinical and anatomic findings consistent with laryngomalacia, supraglottoplasty success rates have been reported to be as high as 94% in otherwise healthy infants.[8] Failure and revision rates are reported to be between 19% and 45% and are directly related to associated comorbidities.[3] Proper parental/guardian education must be performed preoperatively.

3. Does supraglottoplasty increase the risk of aspiration or penetration postoperatively?

A study published in 2009 sought to answer this question.[5] In the study, after supraglottoplasty, no patients demonstrated new onset of aspiration or penetration, while 82% had resolution of their preoperative swallowing dysfunction.[5]

Editorial Comment

Laryngomalacia is the most common cause of pediatric stridor and is a disease that is encountered by all clinicians involved in the care of children. Though primarily self-limiting, the surgical indications for supraglottoplasty have increased over the past decade as more has been learned about this disease and its global effect on the upper aerodigestive system. Laryngomalacia has been demonstrated to be associated with swallowing dysfunction, GERD, OSA, child and caregiver quality of life, as well as more traditional respiratory complaints. Supraglottoplasty is a relatively safe procedure and can improve or resolve all the above ailments when properly performed on indicated children.

Sukgi Choi



Access the review questions and additional sources list online at http://www.expertconsult.com

REFERENCES

1. Landry AM, Thompson DM. Laryngomalacia: disease presentation, spectrum, and management. Int J Pediatr 2012;753526.
2. Kletzker GR, Bastian RW. Acquired airway obstruction from histologically normal, abnormally mobile supraglottic soft tissues. Laryngoscope 1990;100:375–379.
3. Thompson DM. Abnormal sensorimotor integrative function of the larynx in congenital laryngomalacia: a new theory of etiology. Laryngoscope 2007;117:1–33.
4. Munson PD, Saad AG, El-Jamal SM, et al. Submucosal nerve hypertrophy in congenital laryngomalacia. Laryngoscope 2011;121:627–629.
5. Richter GT, Wootten CT, Rutter MJ, et al. Impact of supraglottoplasty on aspiration in severe laryngomalacia. Ann Otolo Rhinol Laryngol 2009;118:259–266.
6. Thottam PJ, Simons JP, Choi S, et al. Clinical relevance of quality of life in laryngomalacia. Laryngoscope 2015;126:1232–1235.
7. Olney DR, Greinwald Jr JH, Smith RJ, et al. Laryngomalacia and its treatment. Laryngoscope 1999;109:1770–1775.
8. Richter GT, Thompson DM. The surgical management of laryngomalacia. Otolaryngol Clin N Am 2008;41:837–864.
9. Hoff SR, Schroeder Jr JW, Rastatter JC, et al. Supraglottoplasty outcomes in relation to age and comorbid conditions. Int J Pediatr Otorhinolaryngol 2010;74:245–249.
10. Gonzalez C, Reilly JS, Bluestone CD. Synchronous airway lesions in infancy. Ann Otol Rhinol Laryngol 1987;96:77–80.

REVIEW QUESTIONS

1. What is the most common cause of infant stridor?
   a. Subglottic stenosis
   b. Tracheomalacia
   c. Laryngomalacia
   d. Croup

2. Laryngomalacia primarily presents with what type of stridor?
   a. Inspiratory
   b. Biphasic
   c. Expiratory
   d. None

3. What are the two most common medical comorbidities associated with laryngomalacia?
   a. Asthma and neurologic disease
   b. GERD and neurologic disease
   c. Congenital heart disease and GERD
   d. Genetic disorders and congenital heart disease

4. The success rate of supraglottoplasty in uncomplicated patients is approximated as
   a. 30%
   b. 50%
   c. 70%
   d. >90%

ADDITIONAL RESOURCES

Bibi H, Khvolis E, Shoseyov D, et al. The prevalence of gastroesophageal reflux in children with tracheomalacia and laryngomalacia. Chest 2001;119:409–413.

Chandra RK, Gerber ME, Holinger LD. Histological insight into the pathogenesis of severe laryngomalacia. Int J Pediatr Otorhinolaryngol 2001;61:31–38.

Dobbie AM, White DR. Laryngomalacia. Pediatr Clin N Am 2013;60:893–902.

Ferguson CF. Congenital abnormalities of the infant larynx. Otolaryngol Clin N Am 1970;3:185–200.

F R. De la dyspepsie acescente, consideree come cause predisposante des affections choleriques. Revue Medico-chirurgicale 1851;5:380.

Giannoni C, Sulek M, Friedman EM, et al. Gastroesophageal reflux association with laryngomalacia: a prospective study. Int J Pediatr Otorhinolaryngol 1998;43:11–20.

Hadfield PJ, Albert DM, Bailey CM, et al. The effect of aryepiglottoplasty for laryngomalacia on gastro-oesophageal reflux. Int J Pediatr Otorhinolaryngol 2003;67:11–14.

Iglauer S. Epiglottidectomy for the relief of congenital stridor with a report of a case. Laryngoscope 1922;32:56–59.

Jackson C, Jackson CL. Diseases and Injuries of the Larynx: A Textbook for Students and Practitioners. New York, NY: Macmillan; 1942.

Kelemen G. Congenital laryngeal stridor. Am Med Assoc Archiv Otolaryngol 1953;58:245–268.

Kilpatrick LA, Boyette JR, Hartzell LD, et al. Prospective quality of life assessment in congenital laryngomalacia. Int J Pediatr Otorhinolaryngol 2014;78:583–587.

Lane RW, Weider DJ, Steinem C, et al. Laryngomalacia. A review and case report of surgical treatment with resolution of pectus excavatum. Arch Otolaryngol 1984;110:546–551.

Matthews BL, Little JP, McGuirt Jr WF, et al. Reflux in infants with laryngomalacia: results of 24-hour double-probe pH monitoring. Otolaryngol Head Neck Surg 1999;120:860–864.

May JG, Shah P, Lemonnier L, et al. Systematic review of endoscopic airway findings in children with gastroesophageal reflux disease. Ann Otol Rhinol Laryngol 2011;120:116–122.

Munson PD, Saad AG, El-Jamal SM, Dai Y, et al. Submucosal nerve hypertrophy in congenital laryngomalacia. Laryngoscope 2011;121:627–629.

Rilliet F, Barthez E. Traite clinique et pratique des maladies des enfants. Paris: Germer Eailliere; 1853.

Schaerer D, Virbalas J, Willis E, et al. Pectus excavatum in children with laryngomalacia. Int J Pediatr Otorhinolaryngol 2013;77:1721–1723.

Seid AB, Park SM, Kearns MJ, et al. Laser division of the aryepiglottic folds for severe laryngomalacia. Int J Pediatr Otorhinolaryngol 1985;10:153–158.

Smith GJ, Cooper DM. Laryngomalacia and inspiratory obstruction in later childhood. Arch Dis Childhood 1981;56:345–349.

Suskind DL, Thompson DM, Gulati M, et al. Improved infant swallowing after gastroesophageal reflux disease treatment: a function of improved laryngeal sensation? Laryngoscope 2006;116:1397–1403.

Sutherland GA, Lambert Lack H. Congenital laryngeal obstruction. Lancet 1897:653–655.

Thomson J, Turner Logan A. On the causation of congenital laryngeal stridor of infants. Br Med J 1900:1561–1563.

Walner DL, Neumann DB, Hamming KK, et al. Supraglottoplasty in infants: a staged approach. Ann Otol Rhinol Laryngol 2015;124:803–807.

Wang W, Tovar JA, Eizaguirre I, et al. Airway obstruction and gastroesophageal reflux: an experimental study on the pathogenesis of this association. J Pediatr Surg 1993;28:995–998.

194 Subglottic Stenosis

Renee E. Park, Sukgi Choi

INTRODUCTION

Subglottic stenosis (SGS) used to be primarily congenital in etiology, and managed conservatively with a tracheostomy tube. Long-term intubation, especially in premature infants, was introduced in the latter part of the 20th century and resulted in increasing rates of acquired SGS, which was associated with worse outcomes as compared with congenital SGS. Laryngotracheal reconstruction (LTR) was introduced in the 1970s, and has expanded to include various open and endoscopic techniques.

The larynx provides several functions, including air transport, phonation, and airway protection during deglutition. As in all surgical intervention, the sequelae of surgery must be weighed carefully, and patient selection is paramount. It is critical to ensure a safe and secure airway. Expansion of a stenotic airway should not come at the cost of dysphonia or dysphagia.

A diagnostic airway endoscopy is required in the evaluation of SGS to assess the location and severity of stenosis, as well as to identify synchronous lesions. Potential causes of airway obstruction must be evaluated, including choanal atresia, piriform aperture stenosis, adenotonsillar hypertrophy, micro-retrognathia, macroglossia, lingual tonsillar hypertrophy, hypotonia, laryngomalacia, vocal cord paralysis, vascular ring, or tracheobronchomalacia. The Myer-Cotton grading scale is used to describe the severity of SGS (Table 194.1).[1] During endoscopy, a nasopharyngeal and/or tracheal culture can be obtained to test for methicillin-resistant *Staphylococcus aureus* (MRSA).[2] It is important to ensure adequate pulmonary function. An evaluation of swallow function is also recommended with a functional endoscopic evaluation of swallow (FEES) or modified barium swallow (MBS). Esophagoscopy with biopsy may also be considered to be sure that reflux esophagitis or eosinophilic esophagitis (EE) are not present prior to reconstruction, as they are associated with granulation, restenosis, or failed decannulation.

To ensure a safe airway, prerequisite skills include basic endoscopic airway techniques including suspension laryngoscopy, management of airway foreign bodies, cricothyroidotomy, and tracheotomy. Direct laryngoscopy with microscopic or endoscopic assistance improves visualization and enables photographic documentation. Bronchoscopy can be performed with either a telescope alone or a rigid bronchoscope. The diameter of the telescope alone is smaller than the bronchoscope, limiting tissue trauma. However, the rigid bronchoscope allows for passive oxygen insufflation, suctioning, or other endotracheal manipulations. Close communication with the anesthesiology team is required to ensure safety, since throughout the various portions of the procedures, it may be required to occlude the airway or tolerate intermittent apnea.

TABLE 194.1 Myer-Cotton Subglottic Stenosis Grading System

Grade	Percent of Subglottic Stenosis
I	<50%
II	51%–70%
III	>70% with any detectable lumen
IV	No lumen

A leak (10–25 cm H_2O) should be encountered with the appropriately sized endotracheal tube.[2]

Endoscopic approaches to SGS are most appropriate for low-grade stenosis, and for immature stenosis. Continuous radial expansion (CRE) balloons have replaced traditional rigid laryngeal dilators secondary to decreased shearing trauma. Radial incisions (laser or cold knife) of the stenosis can be considered prior to dilation. Preservation of healthy mucosa between incisions aids in preventing cicatricial scarring. When serial dilations fail in an infant with SGS after prolonged intubation, an anterior cricoid split may be an option to expand the airway enough to allow for extubation and to avoid tracheostomy tube placement. This can be done endoscopically if exposure is adequate,[3] or transcervically, as originally described.[4] However, in higher grade or mature stenosis, LTR or cricotracheal resection (CTR) should be considered.

LTR creates vertical incisions of the anterior and/or posterior cricoid cartilage ring, and augments the diameter of the airway with cartilage grafts. This can be done as a single or multistaged procedure. Single-stage LTR (SS-LTR) requires prolonged sedation and hospitalization, whereas double-stage LTR (DS-LTR) maintains a tracheostomy tube after the first procedure, and places a trans-laryngeal stent that requires subsequent procedures for stent removal and eventual decannulation. DS-LTR is considered for patients with multilevel stenosis, high-grade stenosis, difficult oral intubation due to craniofacial anomalies or cervical spinal disorders, or patients with significant pulmonary disease.

Various cartilage donor sites have been described, but the most common are the thyroid ala or costal cartilage. The thyroid ala is accessible within the surgical site, but is best suited for patients age 2 or younger because of the limited size. When a larger graft, or both anterior and posterior grafts are required, costal cartilage is ideal. Often a single rib is adequate; a second rib is more likely to be required in patients less than 1-year-old due to size.

Restenosis is a risk, and more likely with higher Myer-Cotton grades. An alternative to LTR is partial CTR, in which the anterior cricoid and stenotic laryngotracheal segment is excised, resulting in thyrotracheal end-to-end anastomosis.[5] This is more effective in high grade stenosis, but introduces the risk of dehiscence and increased risk of injury to the recurrent laryngeal nerve (RLN). CTR has been found to be more effective for Myer-Cotton grade 3 or 4, but may not be suitable in a high level or long-segment stenosis. A minimum distance between the stenotic segment and the true vocal folds of 3 mm,[6] and resection length no greater than 30% of the trachea, has been recommended.[7] Tension-free anastomosis is paramount for success.

Operative risks are numerous and include scarring, infection, dehiscence of the anastomosis, recurrent stenosis including posterior glottic stenosis, inability to extubate or decannulate, airway obstruction, pneumonia, pneumomediastinum, hypoxia, and cardiorespiratory arrest. Airway obstruction can occur due to occlusion or aspiration, edema, granulation tissue, or graft dislodgment. The RLN can be injured during dissection or retraction. Dysphonia and dysphagia may occur. Risks of costal cartilage harvest include scarring, infection,

and pneumothorax. Postoperative myopathy and opioid withdrawal is common after prolonged sedation.

Proper postoperative management is critical. Patients who have had minor endoscopic procedures such as dilation may be observed overnight. Procedures that incise the airway and expose cartilage often require prolonged sedation to promote graft healing. Single-stage procedures require intubation for 7 to 10 days, which allows for stenting while securing the airway. During this time, daily sedation holidays with lifting of neuromuscular blockade limits muscle atrophy and atelectasis. Multistaged procedures create immature tracheostoma, with tube change planned on postoperative day 5. Antibiotic prophylaxis and proton-pump inhibitor treatment is recommended during the period of sedation/intubation or until graft mucosalization. Repeat endoscopy is recommended 2 weeks after extubation for single-stage procedures, and 4 weeks after multistaged procedures for removal of the stent.

Several alternative or adjuvant treatments are available. Topical Mitomycin C is an antineoplastic agent that prevents fibroblast proliferation, and has been used in the prevention of granulation and scarring. Several small studies have suggested improved healing, but a randomized control trial failed to demonstrate a discernible benefit.[8] In addition, risks include myelosuppression, pulmonary toxicity, and possible carcinogenicity. Systemic or topical corticosteroids may improve inflammatory stenosis. Perioperative administration of Decadron is helpful as an adjuvant to airway procedures, and can facilitate extubation. Injection of corticosteroids into SGS is also a common adjuvant treatment. Finally, a tracheostomy may be required if the patient is not a candidate or fails reconstruction, or if the patient is unable to be decannulated.

KEY OPERATIVE LEARNING POINTS

- Important goals are to create a safe airway, alleviate airway obstruction, and eliminate tracheostomy tube dependence, while preserving swallowing and phonation.
- Appropriate patient selection, preoperative evaluation, and surgical planning are critical.
- Daily sedation and paralytic holidays after reconstruction are important to limit muscular atrophy and atelectasis in the perioperative period.

PREOPERATIVE PERIOD

History

1. Respiratory history
   a. Stridor, dysphonia, dyspnea, retractions, cyanosis, and respiratory failure
   b. Ventilator dependence
2. Dysphagia history
   a. Dysphagia, coughing or choking with feeds, failure to thrive
   b. Reflux or EE, including symptoms of frequent spit-up, emesis, food impaction, or atopy
3. Neonatal history
   a. History of prematurity, low birth weight, neonatal intensive care unit (NICU) admission
4. Past medical history
   a. Pulmonary status, including a history of chronic lung disease, aspiration, recurrent pneumonia, reactive airway disease.
   b. Comorbidities such as gastroesophageal reflux disease (GERD), diabetes, or congenital syndromes
5. Past surgical history
   a. Prior intubations, prior surgeries, or trauma, including a history of cardiac or thyroid surgery
6. Medications
   a. Reflux medication
   b. Chronic use of steroids

Physical Examination

1. General
   a. Syndromic features
   b. Failure to thrive, low weight
2. Head and neck examination, assessing for upper airway obstruction
   a. Microretrognathia
   b. Macroglossia
   c. Adenotonsillar hypertrophy
   d. Dysphonia
   e. Health of tracheostomy site, if present
3. Respiratory
   a. Respiratory distress, retractions, stridor
   b. Hypoxia, cyanosis
   c. Ventilator dependence
4. Flexible fiberoptic laryngoscopy
   a. Assess vocal fold mobility
   b. Evaluate for synchronous lesions

Imaging

1. MBS or FEES
2. A computed tomography (CT) may be required if laryngotracheal stenosis is too narrow to allow for bronchoscopy,

Indications

1. Endoscopic dilation
   a. Initial
   b. Low-grade stenosis
2. Anterior cricoid split
   a. Failed extubation
   b. Adequate pulmonary reserve
   c. Isolated SGS
3. Posterior cricoid split + graft
   a. Posterior stenosis or bilateral true vocal fold paralysis
4. LTR
   a. SS-LTR
      1) Medium grade stenosis (Grade 2 or 3)
      2) No other site of airway obstruction
      3) Adequate pulmonary reserve to tolerate prolonged sedation and atelectasis
   b. DS-LTR
      1) Glottic lesion requiring stenting
      2) High grade stenosis (Grade 3 or 4)
      3) Complex reconstruction
      4) Potentially difficult oral reintubation
      5) Family is able to care for a tracheostomy tube or T-tube.
5. CTR
   a. High grade stenosis (Grade 3 or 4) with 3 mm distance between the vocal folds and stenosis
   b. Tracheal stenosis length ≤30%
   c. Failed LTR

Contraindications

1. Active infection such as croup or tracheitis
2. Poor pulmonary function

Relative Contraindications

1. Uncontrolled GERD
2. EE

3. Cardiovascular or endocrine conditions that would preclude corticosteroid administration
4. Chronic respiratory failure and ventilator dependence
5. The lack of a facility adept at postoperative care of critically ill pediatric patients

Preoperative Preparation

1. Diagnostic direct laryngoscopy, bronchoscopy, esophagoscopy with biopsy
2. Treatment of comorbidities such as GERD, EE, dysphagia, or aspiration
3. Endoscopic airway procedures that do not expose cartilage generally do not require antibiotic prophylaxis. An airway procedure with cartilage exposure is considered clean/contaminated, and coverage for oral flora, anaerobes, and pseudomonas is recommended.[9,10] MRSA prophylaxis if positive preoperative culture.

OPERATIVE PERIOD

Endoscopic Dilation

1. **Anesthesia**
   a. General mask or IV anesthesia with spontaneous ventilation
   b. Lidocaine is used to topically anesthetize the larynx and trachea
2. **Instruments and Equipment to Have Available**
   a. Laryngoscope
   b. Bronchoscope
   c. Suspension microlaryngoscopy
   d. CRE balloon dilator
3. **Surgical Technique**
   a. Place the patient into suspension using an appropriately sized laryngoscope.
   b. Consider triamcinolone injection within the submucosa of the stenotic segment.
   c. Consider radial incisions in the area of stenosis from medial to lateral, avoiding the party wall.
   d. Dilate with appropriately sized CRE balloon, holding for 60 seconds or until desaturation. May repeat to achieve effect.
4. **Postoperative care**
   a. Consider overnight observation in selected patients.
   b. Repeat endoscopy 1 to 4 weeks postoperatively.

Anterior Cricoid Split

1. **Anesthesia**
   a. General mask or IV anesthesia with spontaneous ventilation
   b. Lidocaine is used to topically anesthetize the larynx and trachea.
2. **Instruments and Equipment to Have Available**
   a. Laryngoscope
   b. Bronchoscope
   c. Suspension microlaryngoscopy
   d. CRE balloon dilator
3. **Surgical Technique**
   a. Endoscopic
      1) Place the patient into suspension using an appropriately sized laryngoscope.
      2) Incise the anterior cricoid in the midline using a sickle knife. Counterpressure on the anterior neck is helpful.
      3) Dilate with CRE balloon approximately 2 mm greater in diameter than normal subglottic size, holding for 60 seconds or until desaturation.
      4) Reintubate the patient orotracheally or nasotracheally
      5) Stent for 7 days with endotracheal tube one-half size greater than normal; then wean to extubate.
   b. Transcervical
      1) Create a horizontal skin incision, and elevate subplatysmal flaps.
      2) Divide the strap muscles in the midline, and expose the thyroid and cricoid cartilages and proximal trachea.
      3) Sharply incise the anterior cricoid cartilage lamina and the proximal two tracheal rings, and distract apart.
      4) Loosely reapproximate the strap muscles, and close the skin over a Penrose drain.
      5) The patient is reintubated orotracheally or nasotracheally with one-half size larger than normal endotracheal tube for 7 days, followed by extubation, direct laryngoscopy, and bronchoscopy.
4. Dressings, drains only for transcervical approach
   a. Penrose drain removed on POD3
   b. Nonocclusive cervical dressing
5. **Postoperative care**
   a. Repeat endoscopy 1 week postoperatively, with possible repeat dilation

Cartilage Harvest

1. **Anesthesia**
   a. General anesthesia
   b. Local anesthetic is injected into the planned skin incisions.
2. **Instruments and Equipment to Have Available**
   a. Doyen elevator
   b. Soft tissue set
3. **Surgical Technique**
   a. Thyroid ala (Fig. 194.1)
      1) Expose thyroid lamina from the midline to the oblique line.
      2) Incise the superior border of the alar perichondrium.
      3) Retract lamina laterally with a skin hook.
      4) Incise a fusiform graft, ensuring that the incision is above the true vocal cords.
      5) Elevate cartilage off the deep perichondrium with a Cottle elevator.
   b. Costal cartilage
      1) Size of graft is determined at preoperative endoscopy, or after anterior cricoid incision is created and measurements are taken.
      2) Sterilely prepare and drape the chest as a separate surgical site.
      3) A skin incision is made along the expected inframammary crease or just overlying the rib. The fifth and sixth ribs are the most common donor sites for costal cartilage, and an incision is commonly created at the anticipated inframammary crease in girls.
      4) Muscle is divided using electrocautery until the perichondrium is identified.
      5) The intercostal muscles are then dissected off of the perichondrium.
      6) A 22-gauge needle is useful to identify the lateral bony-cartilaginous junction.
      7) The perichondrium is incised at the superior and inferior border of the rib.
      8) A Freer or Cottle elevator is used to elevate the posterior perichondrium off of the cartilage.
      9) Once a perichondrial tunnel has been elevated, a Doyen elevator can be used to elevate the remainder.

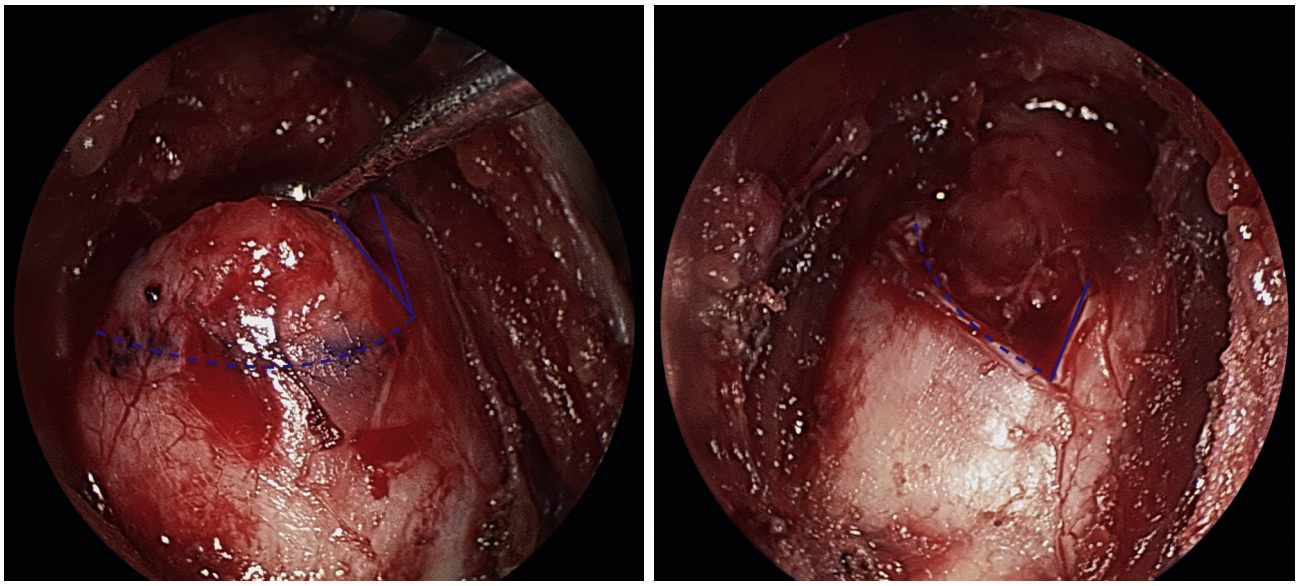

Fig. 194.1. Thyroid ala graft.

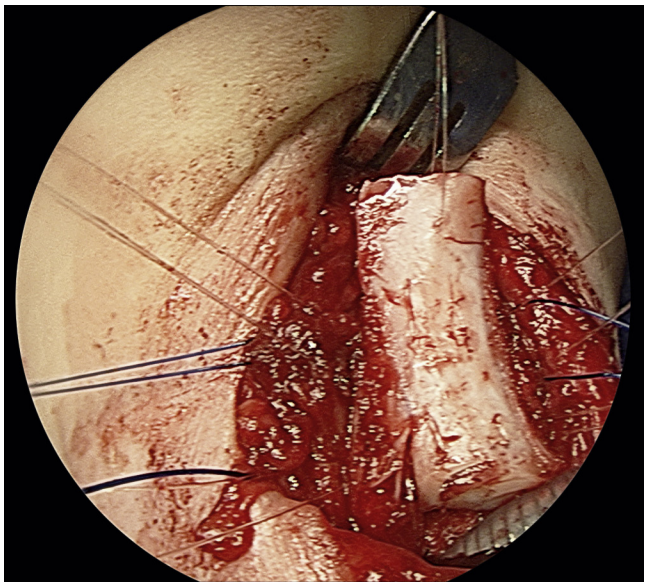

Fig. 194.2. Costal cartilage harvest.

10) Using the Doyen elevator to protect the pleura, the lateral bony-cartilaginous junction is sharply divided.
11) A skin hook is then used to retract the costal cartilage medially, to expose the undersurface of the graft and allow preservation of the perichondrium (Fig. 194.2).
12) The cartilage is then divided at the medial aspect at the appropriate length.
13) A second rib graft may be required.
14) Fill the wound with saline and hold Valsalva to test for an air leak.
15) Place a Penrose drain, reapproximate the muscular layer, close the skin, and apply a sterile dressing.
16) The preserved perichondrium will be used within the lumen of the airway.
17) Shape the cartilage and keep it moist.
    a) The anterior graft is shaped with a circumferential shelf of 1 to 2 mm, with a fusiform or hexagonal shape for SS-LTR and a pentagon for DS-LTR (Fig. 194.3).
    b) The posterior graft is shaped like a trapezoid to allow the graft to snap into position (Fig. 194.4).

4. Dressings, drains
   a. Penrose drain in thoracic incision removed on POD2
   b. Sterile dressing over thoracic incision

Posterior Cricoid Split With Graft

1. **Anesthesia**
   a. General mask or IV anesthesia with spontaneous ventilation
   b. Lidocaine is used to topically anesthetize the larynx and trachea.
   c. Local anesthetic is injected into the planned skin incisions.
2. **Instruments and Equipment to Have Available**
   a. Laryngoscope
   b. Bronchoscope
   c. Suspension microlaryngoscopy set
   d. CO_2 laser
   e. Costal cartilage tray
3. **Surgical Technique**
   a. Endoscopic
      1) Place the patient into suspension using an appropriately sized laryngoscope.
      2) Using the CO_2 laser, divide the posterior cricoid lamina preserving the posterior perichondrial layer.
      3) A previously harvested costal cartilage posterior graft is shaped.
      4) A subperichondrial pocket is carefully elevated with microlaryngeal instruments.
      5) A right-angle clamp is used to distract the cricoid, and the graft is placed into the pocket with perichondrium facing the lumen.
      6) The patient is intubated orotracheally or nasotracheally for 7 days.
      7) Extubation, direct laryngoscopy, and bronchoscopy is then planned for 1 week after the initial procedure.

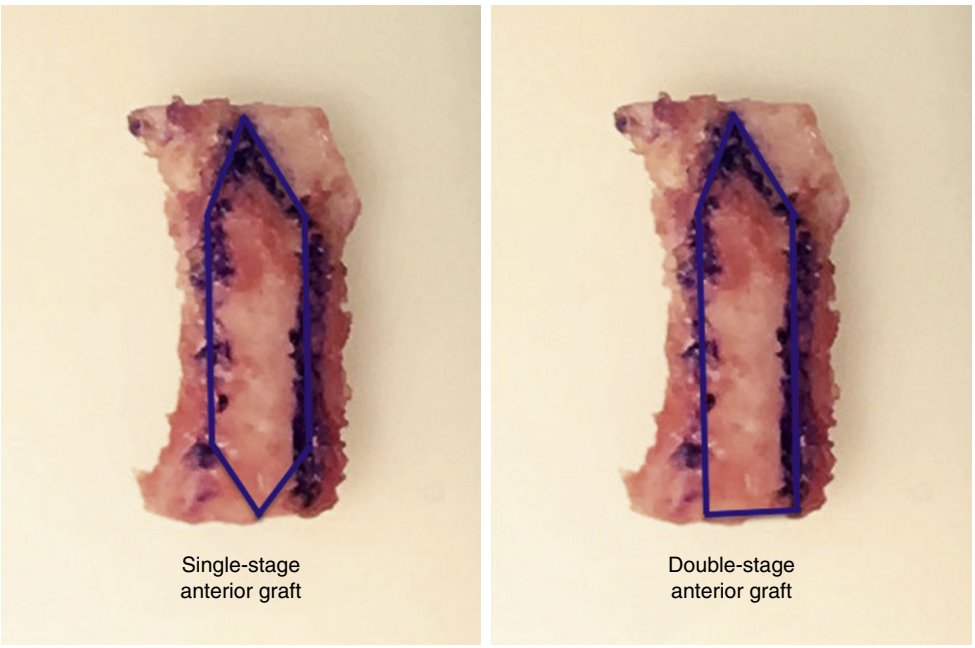

Fig. 194.3. Anterior graft for single-stage and double-stage laryngotracheal reconstruction.

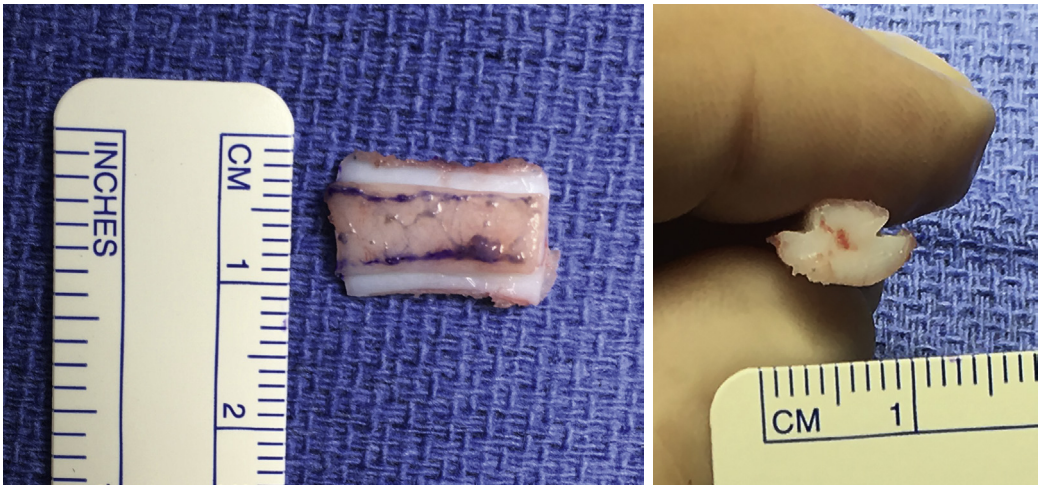

Fig. 194.4. Posterior graft.

b. Transcervical
   1) Create a horizontal skin incision and elevate subplatysmal flaps.
   2) Divide the strap muscles in the midline, and expose the thyroid and cricoid cartilages.
   3) Incise vertically the cricothyroid membrane, and the inferior thyroid cartilage in the midline, taking care to stop inferior to the anterior commissure. Complete laryngofissure is not necessary.
   4) If no tracheostomy tube is present, the patient may need to be reintubated through the surgical site at this time. Intermittent apnea may be required to ensure adequate exposure of the posterior cricoid lamina.
   5) Divide sharply the posterior cricoid lamina.
   6) A previously harvested costal cartilage posterior graft is shaped.
   7) A subperichondrial pocket is carefully elevated with a Cottle elevator.
   8) The cricoid is distracted, and the graft is placed into the pocket, with the perichondrium facing the lumen.
   9) Reintubate the patient orotracheal or nasotracheally.
   10) Reapproximate the thyroid cartilage and secure with interrupted 3-0 PDS sutures
   11) Loosely reapproximate the straps, and close the skin over a Penrose drain.
   12) The patient is intubated for 7 days, followed by extubation, direct laryngoscopy, and bronchoscopy.
4. Dressings, drains
   a. Penrose drain in thoracic incision removed on POD2
   b. Penrose drain in cervical incision removed on POD3
   c. Sterile dressing over thoracic incision
   d. Nonocclusive cervical dressing
   e. Consider the placement of a postpyloric feeding tube.
5. Postoperative care
   a. Repeat endoscopy 1 week postoperatively, with possible dilation

Single-Stage Laryngotracheal Reconstruction

1. **Anesthesia**
   a. General inhalation or IV anesthesia via endotracheal tube secured in the existing tracheostomy or in a separately placed inferior tracheostomy incision
   b. Local anesthetic is injected into the planned skin incisions.
2. **Instruments and Equipment to Have Available**
   a. Laryngoscope
   b. Bronchoscope
   c. Suspension microlaryngoscopy
   d. Costal cartilage set
   e. Head and neck set
3. **Surgical Technique**
   a. Anterior graft
      1) Create a horizontal skin incision through the tracheostoma if a tracheostomy tube is present, or at the inferior border of the cricoid if no tracheostomy tube is present.
      2) Elevate subplatysmal skin flaps from the hyoid to the sternal notch.
      3) Divide the strap muscles in the midline, and retract laterally.
      4) Isolate and divide the thyroid isthmus, exposing the larynx and trachea.
      5) Generally the RLNs do not require identification if care is taken to remain on the trachea and limit lateral dissection.
      6) Enter the area of stenosis vertically, and extend the incision superiorly through the anterior cricoid. Inspect the lumen of the trachea and extend the incision to the inferior border of the stenosis. If the location and length of the stenosis is difficult to determine externally, perform a bronchoscopy and insert 25-gauge needles to identify the borders of the stenosis.
      7) Intubate the patient through the operative site or an inferiorly placed tracheostomy incision.
      8) Place the carved anterior graft into position, with the perichondrium facing the lumen.
      9) 4-0 PDS interrupted or horizontal mattress sutures are then placed. The needle starts laterally on the outside of the trachea, and advances through the submucosa to the cartilage graft.
         a) For a thyroid ala graft, the needle travels under the perichondrium and through the cartilage graft.
         b) For a costal cartilage graft, the needle pierces the intersection of the hexagon and the shelf, and comes through the cartilage graft (Fig. 194.5).
      10) Circumferential sutures are placed around the graft.
      11) The patient is reintubated nasotracheally.
      12) The graft is then parachuted into position (Fig. 194.6). The sutures are then tied over the trachea to ensure maximal vascularity to the free cartilage graft.
      13) The wound is filled with saline and a Valsalva is held to identify any leaks around the cartilage graft, which are then reinforced with interrupted 4-0 PDS sutures until no leak is identified.
      14) Loosely reapproximate the strap muscles, and close the skin over a Penrose drain.
      15) Place a nonocclusive dressing.
   b. Posterior graft
      1) Start with harvesting the cartilage and dividing the anterior cricoid, as described previously.
      2) The patient is intubated, and the posterior cricoid lamina is identified and incised in the midline.
      3) Posterior perichondrial flaps are elevated with a Cottle elevator to create a tight pocket.
      4) Distract the posterior cricoid and place the graft in place. It should snap securely into position (Fig. 194.7).
      5) Anterior graft sutures are placed circumferentially.
      6) The patient is intubated nasotracheally.
      7) The anterior graft is parachuted into position, and the sutures are tied.
      8) Close as described previously.
4. Dressings, drains
   a. Penrose drain in thoracic incision removed on POD2
   b. Penrose drain in cervical incision removed on POD3
   c. Nonocclusive cervical dressing
   d. Sterile dressing over thoracic incision
   e. Consider postpyloric feeding tube placement.
5. **Postoperative care**
   a. Prophylactic antibiotics and proton-pump inhibitor administered while intubated.
   b. Perioperative steroids will be started on the day prior to extubation.
   c. Sedation and neuromuscular blockade for 7 to 10 days, with daily holidays.

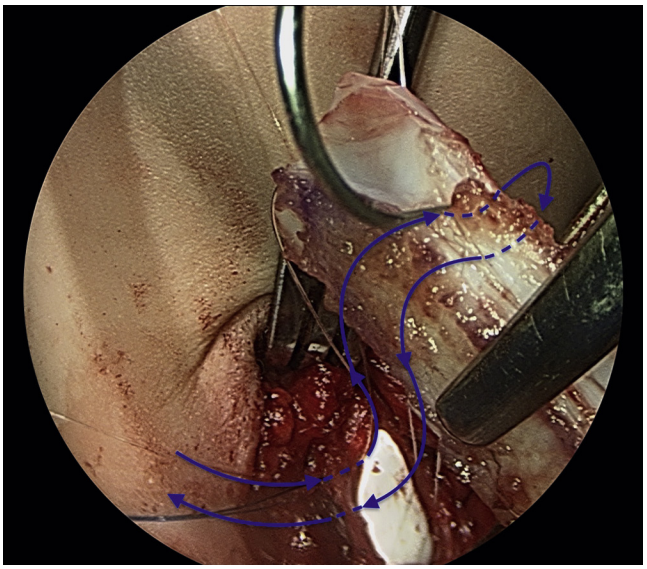

Fig. 194.5. Suture placement of the anterior graft.

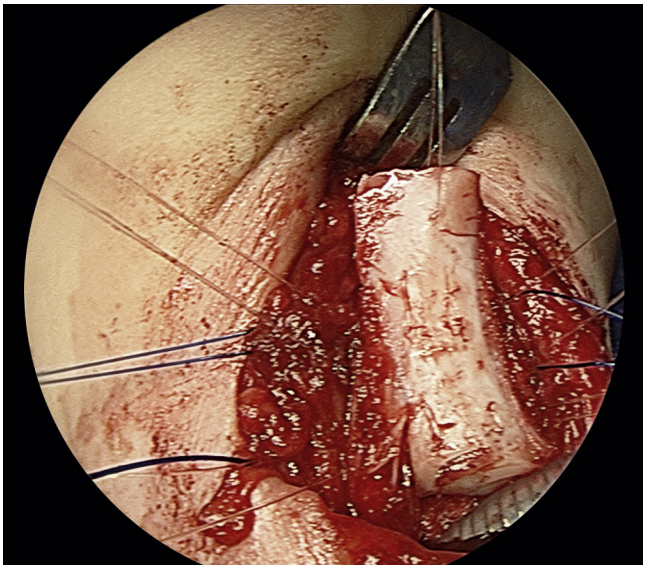

Fig. 194.6. Parachuting of anterior graft into position.

d. Extubate and repeat endoscopy 7 to 10 days postoperatively.
e. Repeat endoscopy 2 weeks later.

Double-Stage Laryngotracheal Reconstruction

1. **Anesthesia**
   a. General inhalation or IV anesthesia via endotracheal tube placed in this existing tracheostomy or in a separately placed inferior tracheotomy incision
2. **Instruments and Equipment to Have Available**
   a. Laryngoscope
   b. Bronchoscope
   c. Suspension microlaryngoscopy
   d. Costal cartilage set
   e. Head and neck set
3. **Surgical Technique**
   a. Start with harvesting the cartilage, and proceed with anterior and posterior cricoid incision and posterior cartilage placement, as described in the SS-LTR section.
   b. After the posterior graft is secured, a laryngotracheal stent is placed.
   c. The stent extends from the superior aspect of the stoma to above the glottic aperture (Fig. 194.8). Direct laryngoscopy ensures proper positioning. The stent is then secured into position, either to the superior skin flap, or through the neck using a Silastic button or angiocatheter bolster, and a 2-0 polypropylene suture. The suture and bolster should be easily identified at the time of stent removal.
   d. Continue with the anterior graft as described previously. The anterior graft will resemble a house or pentagon.
   e. The patient's tracheostomy tube is then placed, and secured in the standard fashion. This is considered a new tracheostomy site, and requires 5 to 7 days to establish a stoma.
   f. The straps are loosely reapproximated. The lateral skin edges are then closed in the usual fashion, leaving the tracheostoma open.
4. Dressings, drains
   a. Penrose drain in thoracic incision removed on POD2
   b. Penrose drain in cervical incision removed on POD3
   c. Nonocclusive cervical dressing
   d. Sterile dressing over thoracic incision
   e. Consider the placement of a postpyloric feeding tube.
5. **Postoperative care**
   a. Prophylactic antibiotics and proton-pump inhibitor are recommended until the tracheostomy tube change.
   b. Sedation and ventilation for 0 to 5 days in pediatric intensive care unit with daily sedation/paralytic holidays
   c. Tracheotomy tube change on POD5–7
   d. Repeat endoscopy and stent removal 4 weeks postoperatively

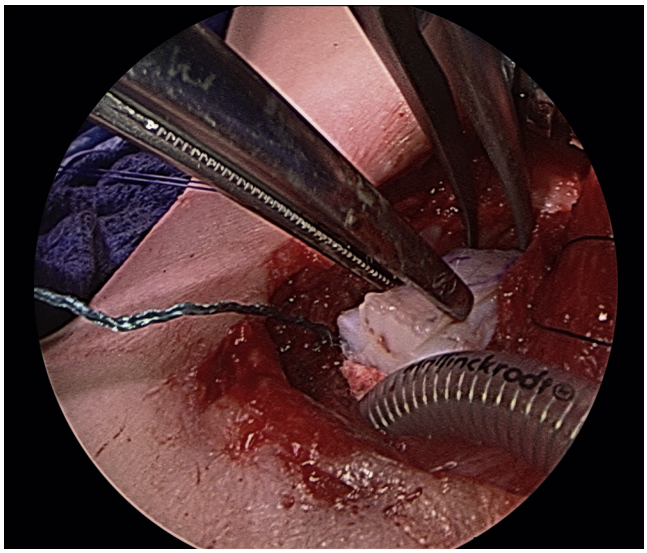

Fig. 194.7. Posterior graft placement.

Cricotracheal Resection

1. **Anesthesia**
   a. General inhalation or IV anesthesia via endotracheal tube placed in this existing tracheostomy or in a separately placed inferior tracheotomy incision
2. **Instruments and Equipment to Have Available**
   a. Laryngoscope
   b. Bronchoscope
   c. Suspension microlaryngoscopy
   d. Head and neck set
3. **Surgical Technique**
   a. Place a bougie into the esophagus to define it.
   b. Create a horizontal skin incision through the tracheostoma if a tracheostomy tube is present, or at the

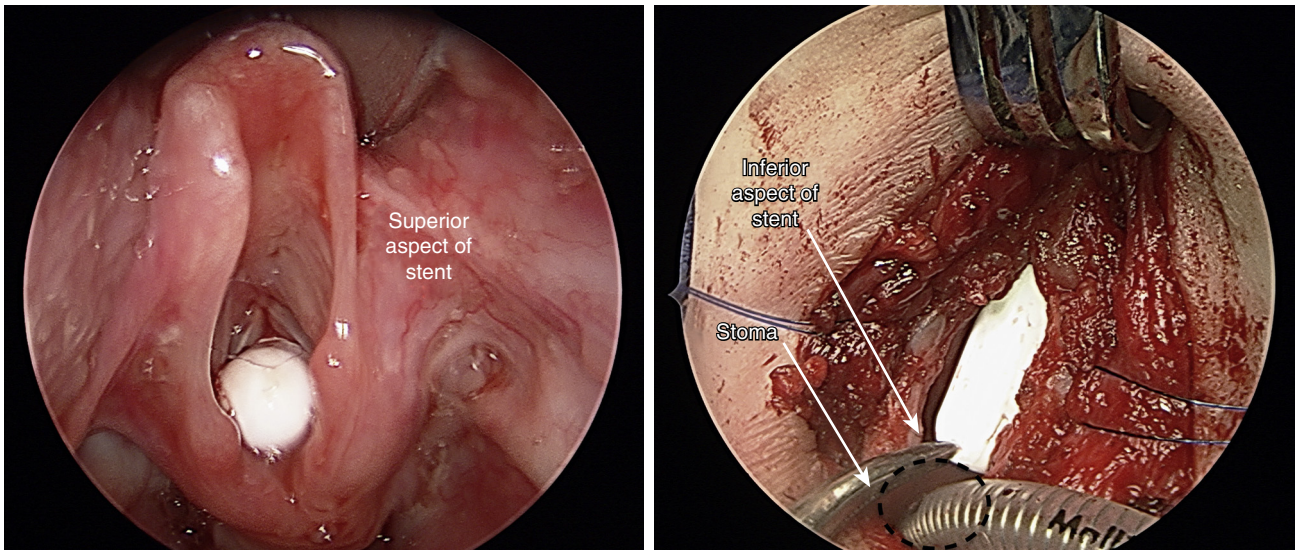

Fig. 194.8. Double-stage laryngotracheal reconstruction laryngeal stent.

inferior border of the cricoid if no tracheostomy tube is present.

c. Elevate subplatysmal skin flaps from the hyoid to the sternal notch.
d. Divide the strap muscles in the midline, and retract them laterally.
e. Isolate and divide the thyroid isthmus, exposing the larynx and trachea.
f. Generally, the RLNs do not require identification if care is taken to remain on the trachea and limit lateral dissection.
g. Using blunt finger dissection, free the inferior anterior tracheal wall from its attachments, with care taken to identify the innominate artery, and avoid overdissection of the lateral borders in order to preserve the vascular supply.
h. Place two 2-0 PDS retaining mattress sutures at the distal end of the trachea to prevent retraction into the mediastinum (Fig. 194.9).
i. Enter the area of stenosis vertically, and extend the incision superiorly through the cricoid. Inspect the lumen of the trachea and extend the incision to the inferior border of the stenotic segment. The tracheostoma should be included in the excision if there are less than two tracheal rings between the stenosis and the stoma.
j. Intubate the patient through the operative site or inferiorly placed tracheostomy incision.
k. Incise the lateral walls of the stenotic segment, ensuring that the incisions are anterior to the tracheoesophageal groove, and remove the stenotic segment of the trachea.
l. Elevate the cricothyroid muscles off the cricoid from medial to lateral, with care taken to limit dissection at the cricothyroid joint to prevent injury to the RLN.

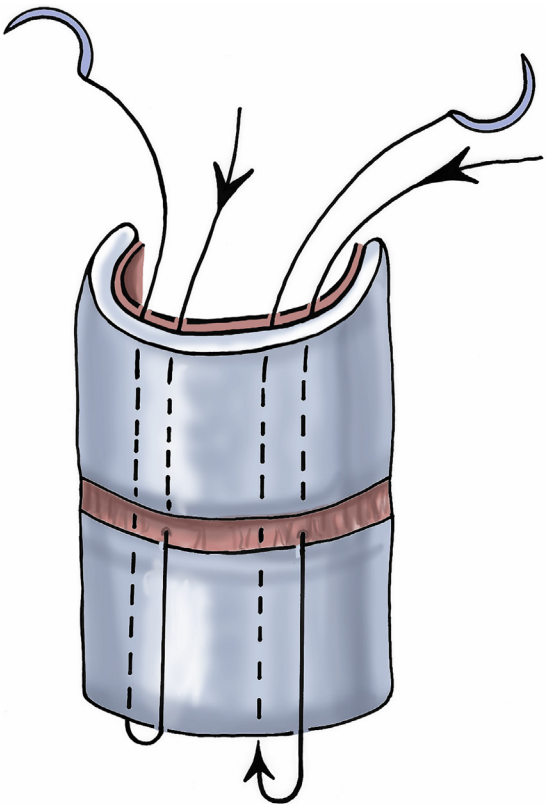

Fig. 194.9. Cricotracheal resection retaining mattress sutures for distal trachea.

m. Incise and remove the exposed anterior cricoid segment, followed by the lateral cricoid cartilage, being sure to preserve the cricothyroid joints.
n. This results in removal of approximately 50% to 66% of the anterior cricoid ring and the stenotic segment of the trachea.
o. Inject the posterior cricoid mucosa with local anesthetic. Incise the mucosa horizontally below the cricoarytenoid joints, and elevate it off of the posterior cricoid using a Freer elevator or a round knife. The membranous wall of the trachea is then carefully dissected off the esophagus, preserving its posterolateral blood supply.
p. If there is prominent stenosis of the posterior cricoid cartilage, use a diamond burr to thin the posterior cricoid lamina.
q. Remove the shoulder roll to eliminate neck extension.
r. Reapproximate the thyroid cartilage and the trachea, using the 3-0 PDS stay sutures securing the lateral thyroid cartilage to the two most proximal tracheal rings, staying submucosal on the intraluminal surface.
s. Consider suprahyoid release if required to relieve tension.
t. Secure the distal trachea to the posterior thyroid and cricoid cartilage using a double-armed 4-0 PDS baseball suture. Alternatively, 4-0 PDS interrupted sutures can be used, with the initial posterior sutures resulting in intraluminal knots. Continue these sutures circumferentially, from the posterior aspect to the lateral trachea. Knots can be placed extraluminally on the lateral and anterior aspects (Fig. 194.10).
u. Reintubate the patient nasotracheally prior to tying the anterior sutures.
v. Consider securing the previously placed retaining sutures around the hyoid as an internal Grillo suture using a Keith needle.
w. If a discrepancy in the diameter of the lumen is noted between the thyroid cartilage and the trachea, an inferior midline thyrotomy can be performed up to the anterior commissure, and a triangular wedge can be created from the anterior trachea to insert into the thyrotomy (Fig. 194.11).
x. Reapproximate the strap muscles loosely.
y. Place Penrose drains over the strap muscles and close the skin.
z. Consider C-collar to prevent neck extension.

4. Dressings, drains
   a. Penrose drain removed on POD2
   b. Nonocclusive dressing
   c. Consider the placement of a postpyloric feeding tube.
5. **Postoperative care**
   a. Broad spectrum antibiotics and antireflux medication until extubation
   b. Sedation and neuromuscular blockade for 7 to 10 days, with daily holidays
   c. Extubate and repeat endoscopy 7 to 10 days postoperatively.
   d. Repeat endoscopy 2 weeks postoperatively.

Common Errors in Technique

1. Inadequate evaluation and treatment of comorbidities such as GERD, EE, aspiration
2. Overexposure of lateral laryngeal complex, increasing risk of injury to RLN
3. Injury to true vocal folds during splinting, increasing risk of glottic stenosis
4. Incomplete assessment and treatment of multilevel obstruction

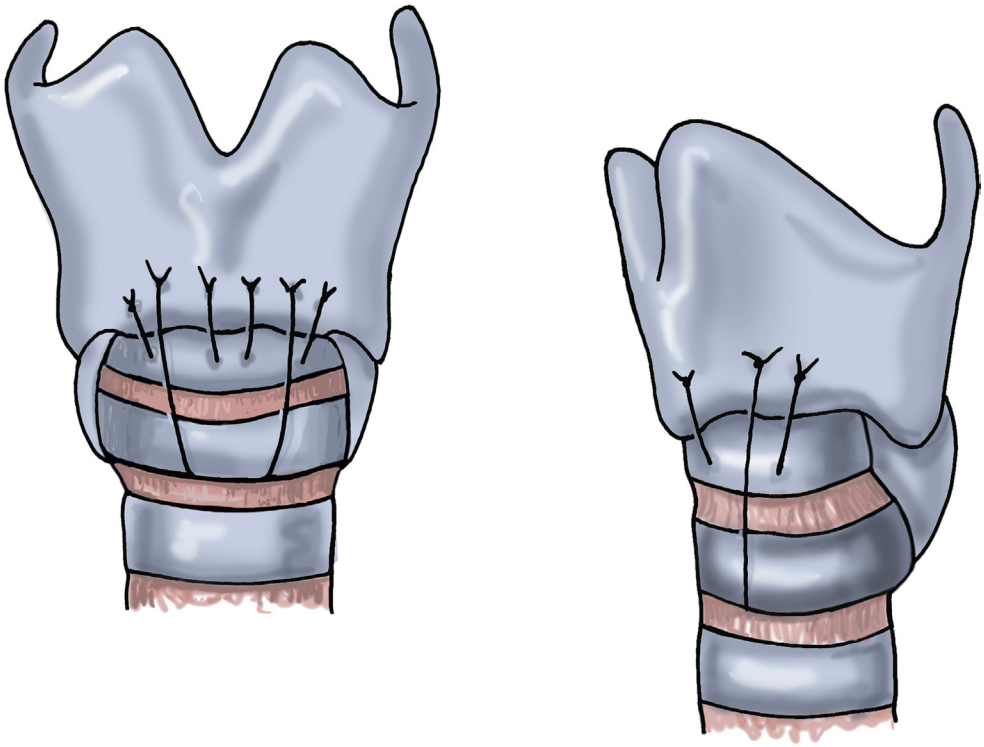

Fig. 194.10. Cricotracheal resection anastomosis.

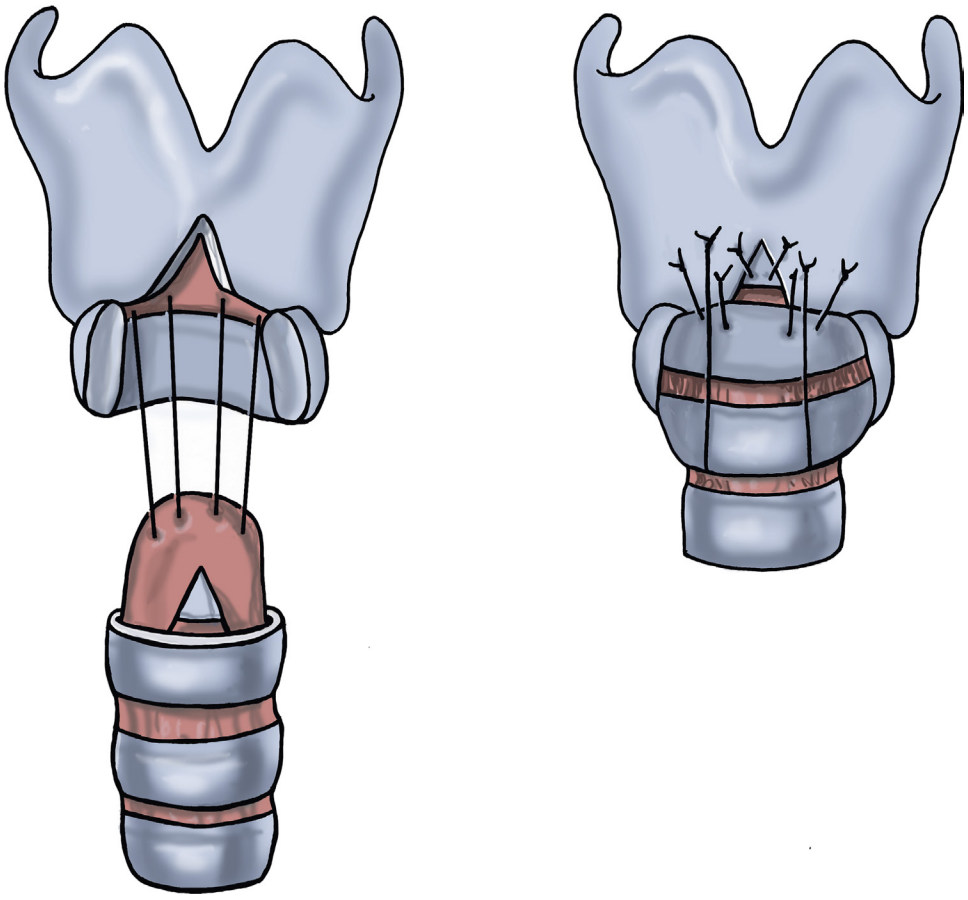

Fig. 194.11. Inferior midline thryotomy with tracheal wedge used to address significant discrepancies luminal diameter in cricotracheal resection.

DISCUSSION

Evidence-Based Medicine Question

Does the choice of antibiotic prophylaxis matter?

A retrospective study of 36 LTR patients demonstrated a significant decrease in perioperative infections complications with the use of clindamycin and either ticarcillin/clavulanic acid or ceftazidime (8%) versus other antibiotics or no antibiotic coverage (50%).[9] MRSA colonization was found in 32.5% of a retrospective cohort of 180 patients undergoing open airway surgery. Previous studies have suggested that MRSA wound infections can severely compromise open airway healing. Those MRSA positive patients who received vancomycin demonstrated the same rate of complications as those who did not test negative for MRSA, and had no MRSA related wound infections postoperatively.[2]

Editorial Comment

Great medical advancements were achieved in the late 20th century, including improved neonatal survival. This was in part due to increase use of prolonged intubation and ventilation. However, iatrogenic SGS became increasingly prevalent, and thus the era of open airway reconstruction began. Due to advances in neonatal airway management, the incidence of iatrogenic SGS has decreased. In parallel, endoscopic surgical techniques improved and have gained increasing popularity. Accordingly, management has trended away from open procedures in favor of minimally invasive approaches when applicable. Endoscopic procedures are associated with lower morbidity and fewer interventions.[10]

Sukgi Choi


Access the review questions online at http://www.expertconsult.com

REFERENCES

1. Myer 3rd CM, O'Connor DM, Cotton RT. Proposed grading system for subglottic stenosis based on endotracheal tube sizes. Ann Otol Rhinol Laryngol 1994;103(4 Pt 1):319–323.
2. Statham MM, de Alarcon A, Germann JN, et al. Screening and treatment of methicillin-resistant *Staphylococcus aureus* in children undergoing open airway surgery. Arch Otolaryngol Head Neck Surg 2012;138(2):153–157.
3. Mirabile L, Serio PP, Baggi RR, Couloigner VV. Endoscopic anterior cricoid split and balloon dilation in pediatric subglottic stenosis. Int J Pediatr Otorhinolaryngol 2010;74(12):1409–1414.
4. Cotton RT, Myer 3rd CM, Bratcher GO, Fitton CM. Anterior cricoid split, 1977–1987. Evolution of a technique. Arch Otolaryngol Head Neck Surg 1988;114(11):1300–1302.
5. Monnier P, Lang F, Savary M. Cricotracheal resection for pediatric subglottic stenosis. Int J Pediatr Otorhinolaryngol 1999;49(Suppl 1):S283–S286.
6. Walner DL, Stern Y, Cotton RT. Margins of partial cricotracheal resection in children. Laryngoscope 1999;109(10):1607–1610.
7. Wright CD, Graham BB, Grillo HC, et al. Pediatric tracheal surgery. Ann Thorac Surg 2002;74(2):308–313.
8. Hartnick CJ, Hartley BE, Lacy PD, et al. Topical mitomycin application after laryngotracheal reconstruction: a randomized, double-blind, placebo-controlled trial. Arch Otolaryngol Head Neck Surg 2001;127(10):1260–1264.
9. Simoni P, Wiatrak BJ. Microbiology of stents in laryngotracheal reconstruction. Laryngoscope 2004;114(2):364–367.
10. Yellon RF, Parameswaran M, Brandom BW. Decreasing morbidity following laryngotracheal reconstruction in children. Int J Pediatr Otorhinolaryngol 1997;41(2):145–154.

REVIEW QUESTIONS

1. Indications for a two-stage laryngotracheal reconstruction include all of the following, *except*:
   a. Caretaker ability to care for tracheostomy tube or T-tube
   b. Low-grade stenosis
   c. Difficult reintubation
   d. Complex reconstruction

2. Cricotracheal resection is ideally limited to the following condition(s):
   a. At least 3 mm distance between the stenosis and the true vocal folds
   b. At least 1 mm distance between the stenosis and the true vocal folds
   c. Stenosis involving less than 30% of trachea
   d. a and c

3. Preoperative assessment includes evaluation for:
   a. Dysphagia
   b. Eosinophilic esophagitis
   c. Gastroesophageal reflux
   d. All of the above

195 Surgery for Aspiration: Laryngeal Cleft Repair and Laryngotracheal Separation

Bianca Siegel, Franklin L. Rimell, Sukgi Choi

INTRODUCTION

Feeding and swallowing problems are commonly encountered issues in pediatric otolaryngology. The incidence of feeding disorders has been estimated at 25% to 45%; the incidence of swallowing disorders is unknown but is increasing with improved life expectancy of premature babies. Oropharyngeal dysphagia has been estimated to affect up to 85% of children with underlying neurologic disorders.[1] Dysphagia is the result of a problem during one or more of the phases of swallowing: the oral phase, the pharyngeal phase, or the esophageal phase. Of particular concern in children with dysphagia is the presence of aspiration, which can lead to pulmonary complications such as chronic cough or aspiration pneumonia. Pediatric dysphagia is multifactorial in nature, and these children benefit from being evaluated in a multidisciplinary manner.[1,2] Services involved in the care and management of these children include Neurology, Pulmonology, Gastroenterology, and Otolaryngology.

An important part of the complete evaluation for children with dysphagia and suspected aspiration typically includes consultation with an Otolaryngologist. Laryngoscopic examination allows for assessment of any anatomic abnormalities that may contribute to dysphagia. Although the majority of cases of pediatric dysphagia are neurologic in nature,[2-4] there are patients who have certain anatomic abnormalities that may predispose them to aspiration. Patients with posterior laryngeal cleft are a particular subset who may benefit from surgical intervention.

Historically, the incidence of laryngeal cleft has been estimated at approximately 1:10,000 to 1:20,000 newborns.[5] In recent years, however, with increased awareness of milder forms of laryngeal cleft, including mild type 1 cleft such as low interarytenoid height, this entity is being diagnosed more frequently. The most commonly used classification system remains that described by Benjamin and Inglis in 1989.[6] Type 1 clefts are limited to the interarytenoid region and have also been referred to historically as "occult clefts." They are believed to be caused by issues that involve interarytenoid muscular development or lack of normal arytenoid cartilage development that may involve the cuneiform or corniculate cartilage. Type 2 clefts involve the upper portion of the cricoid cartilage, type 3 clefts extend through the entire height of the cricoid cartilage, and type 4 clefts extend into the thoracic trachea. Patients with more severe type 3 and 4 clefts typically present in the first few days of life with significant aspiration or recurrent apneic/hypoxic episodes, whereas patients with milder clefts typically have much milder symptoms, resulting in a delay in diagnosis.

Surgery is the mainstay of treatment for patients with laryngeal cleft. Historically, open approaches via thyrotomy, cricothyrotomy, tracheofissure, and lateral pharyngotomy have been described. With advances in endoscopic instrumentation over the past several decades, an endoscopic approach is generally favored when it is feasible, is widely used for type 1 and 2 clefts,[7-9] and has even been described for certain type 3 and 4 clefts.[10]

Injection augmentation of the interarytenoid region for aspiration in mild posterior laryngeal cleft was first described in 1995 and has been widely used for type 1 clefts since that time. The advantage of injection augmentation for milder clefts is that it can provide a significantly less invasive means of treatment for these patients, also provides clarification of the cleft contribution to the child's dysphagia, and can help guide further management including a possible formal repair.

For children with severe and intractable aspiration despite maximal management of comorbid conditions, laryngotracheal separation provides a last-resort management option.

KEY LEARNING POINTS

1. Dysphagia and aspiration are commonly encountered problems in pediatric otolaryngology, and a multidisciplinary approach should be employed in the evaluation and management of these patients.
2. Laryngeal cleft is a surgically correctable entity, and surgical management should be considered in symptomatic patients.
3. Surgical management of laryngeal clefts ranges from injection laryngoplasty in mild or uncertain cases, to endoscopic repair in types 1 to 3 and some type 4 clefts, to open repair for more extensive clefts or revision cases.
4. Injection laryngoplasty could be used to help diagnose a type 1 laryngeal cleft when injection is performed with a temporary substance.
5. Laryngotracheal separation may be considered as a last resort for children with intractable aspiration despite maximal management of any comorbid conditions.

PREOPERATIVE PERIOD

History

1. Feeding history
   a. What type of diet is the patient currently on?
   b. Is there coughing and choking with feeds? What types of consistencies cause coughing and choking?
   c. Have any dietary modifications been tried? Did this help?
   d. Any difficulty breathing or noisy breathing with feeds?
   e. Is the patient gaining weight adequately?
   f. Any reflux symptoms? Frequent spit up/burps? Excessive vomiting? Nocturnal cough?
2. Respiratory history
   a. Any cyanotic or apneic episodes?
   b. History of pneumonia? Bronchiolitis?
   c. Any history of chronic cough or recurrent croup?
   d. Any stridor?
3. Neonatal history
   a. History of prematurity?
   b. Did the child require admission to the neonatal intensive care unit (NICU)?
   c. Any need for respiratory support, including supplemental oxygen, positive pressure support, or intubation?

4. Past medical history
   a. Cardiac or pulmonary disease?
5. Past surgical history
   a. Intubation for any surgical procedures?
   b. History of cardiac procedures?
6. Medications
   a. Reflux medications?

Physical Examination

1. General appearance
   a. Any abnormal or syndromic features?
      1) Opitz syndrome: Laryngeal malformations, pinna abnormalities, cleft lip and palate, hypertelorism, genitourinary abnormalities, other malformations of the ventral midline
      2) Pallister-Hall syndrome: Laryngeal cleft, bifid epiglottis, genitourinary malformations, neurologic malformations, and syndactyly
      3) CHARGE syndrome: Coloboma, heart defects, choanal atresia, growth and mental retardation, genitourinary malformations, and ear malformations
      4) VACTERL association: Vertebral, anal, cardiac, tracheoesophageal, ear, renal, and limb malformations
   b. Does the child appear malnourished/failure to thrive?
2. Head and neck examination
   a. Any masses or pits on neck?
   b. Any other midline anomalies such as cleft palate or submucous cleft palate?
3. Respiratory examination
   a. Respiratory distress/stridor
   b. Retractions/nasal alar flaring
   c. Respiratory rate
4. Flexible laryngoscopy
   a. Evaluate both choanae for patency.
   b. Evaluate supraglottis for any significant reflux changes or laryngomalacia.
   c. Examine for any evidence of deep interarytenoid notch or laryngeal cleft, although this is difficult to see on fiberoptic examination alone.
5. Fiberoptic endoscopic evaluation of swallowing
   a. A flexible endoscope is advanced through the nose and the larynx is visualized while the patient is feeding.
   b. Advantages: Allows for evaluation of anatomy and vocal cord mobility, presence of any premature spillage or presence of residue in the hypopharynx following swallow, and presence of supraglottic laryngeal penetration or laryngeal aspiration
   c. Disadvantages: Some discomfort to patient, and some patients may not cooperate with swallowing. Unable to assess the pharyngeal phase of swallow due to white-out. Rarely, may cause laryngospasm or vasovagal reaction

Imaging

1. Modified barium swallow study
   a. Fluoroscopy is performed during feeding of foods mixed with barium contrast material.
   b. Advantages: No significant discomfort, tolerated well by most children. Allows evaluation of pharyngeal phase of swallowing
   c. Disadvantages: Requires exposure to radiation. Unable to directly visualize laryngeal anatomy
   d. Posterior pattern of aspiration is suggestive of laryngeal cleft.
2. Chest radiograph
   a. For evaluation of aspiration pneumonia when suspected
3. Diagnostic direct laryngoscopy/bronchoscopy
   a. Palpate and visualize interarytenoid area (Fig. 195.1) for evidence of type 1, type 2, and type 3 laryngeal clefts on direct laryngoscopy.

Indications

1. Injection laryngoplasty for laryngeal cleft
   a. Type 1 laryngeal cleft with symptoms of dysphagia/aspiration
   b. Deep interarytenoid notch/low interarytenoid height with symptoms of dysphagia/aspiration
   c. Minimal or no improvement following feeding therapy and texture modifications
   d. Can also be considered in patients with chronic aspiration and normal anatomy. A recent study evaluated interarytenoid injection for children with chronic aspiration and found that 50% of patients with normal anatomy had improved.
2. Endoscopic repair of laryngeal cleft
   a. Symptomatic type 1 or type 2 cleft
   b. Certain type 3 and 4 laryngeal clefts, if adequate exposure can be achieved through an endoscopic approach
   c. Patients with deep interarytenoid notch/low interarytenoid height who have previously undergone injection with improvement in symptoms and subsequent recurrence of symptoms after injection dissolves
3. Open repair of laryngeal cleft
   a. Type 3 and type 4 clefts that are not amenable to endoscopic exposure
   b. Type 1 and type 2 clefts that have failed endoscopic management
4. Laryngotracheal separation
   a. Reserved for patients with intractable aspiration despite maximal conservative management of aspiration, including food texture modifications, feeding via feeding tube, parenteral alimentation, medical management of reflux disease, Nissen fundoplication, and management of any other comorbidities

Contraindications

1. Injection laryngoplasty for laryngeal cleft and endoscopic repair of laryngeal cleft
   a. Presence of concomitant upper airway obstruction. Patients with sites of upper airway obstruction, such as subglottic stenosis or laryngomalacia, in addition to a deep interarytenoid notch or type 1 laryngeal cleft, may develop worsening upper airway obstruction following injection. This must be considered prior to offering injection.
   b. Asymptomatic type 1 cleft
2. Open repair of laryngeal cleft
   a. If endoscopic repair is feasible, it should be used as the first-line approach.
   b. No oth er contraindications

OPERATIVE

Surgical Technique

Laryngeal Cleft Injection

1. Anesthesia
   a. Spontaneous ventilation is ideal.
   b. Apneic technique is also acceptable if spontaneous ventilation cannot be achieved.
   c. No antibiotics needed
   d. Consider an intraoperative dose of steroids.

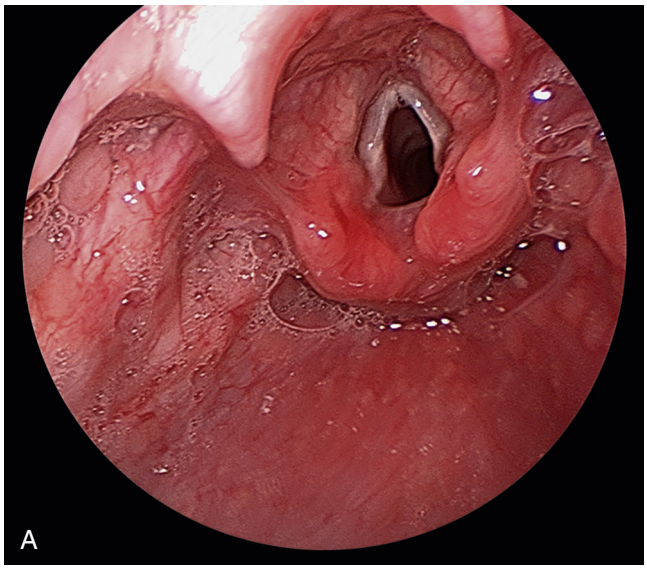

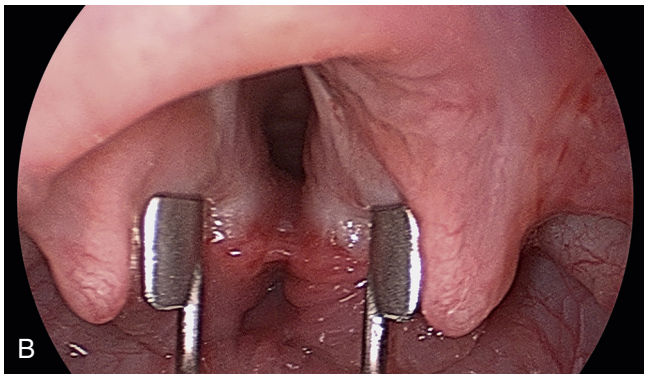

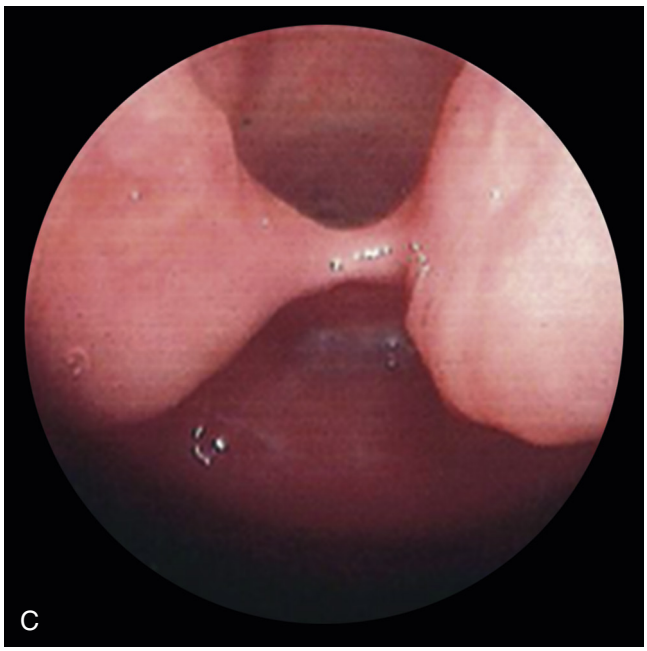

Fig. 195.1. Laryngeal cleft. A, Type 1 laryngeal cleft, which extends to but not beyond, the level of the vocal cords. **B,** Type 2 laryngeal cleft, which extends inferior to the level of the vocal cords into the cricoid cartilage but not through the cricoid cartilage. **C,** Type 3 laryngeal cleft, which extends all the way through the cricoid cartilage.

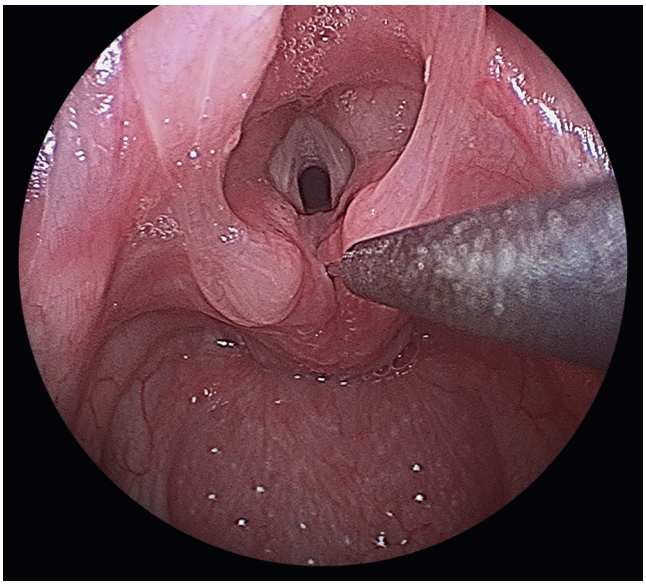

Fig. 195.2. Laryngeal cleft injection. The patient is placed in suspension and the postcricoid area is visualized. The needle is inserted with the bevel facing posteriorly, and the injection material of choice is injected until the notch visibly fills in (approximately 0.2 cc).

2. Positioning
   a. Supine, with suspension microlaryngoscopy setup
   b. Shoulder roll for neck extension if needed for exposure
3. Instruments/equipment to have available
   a. Microlaryngoscopy set with endoscopic needle
   b. Injection material of choice (Radiesse, Prolaryn, Gelfoam, etc.)
   c. Suspension arm for laryngoscope
   d. Microscope or 0-degree telescope for visualization
4. Technique
   a. Load and prime the needle with injection material.
   b. Under direct visualization, insert the needle into the apex of the cleft with the bevel aimed posteriorly (Fig. 195.2).
   c. Inject until the notch/cleft has been visibly reduced, usually approximately 0.2 cc.
   d. Consider injection of the medial surface of each arytenoid around the surface of the corniculate cartilage, approximately 0.1 cc per side.
5. Common errors in technique
   a. Poor exposure of interarytenoid area
   b. Overinjection with infiltration of injection material into the subglottis or cricopharyngeal surface, which can potentially cause airway compromise or dysphagia
6. Postoperative care
   a. Overnight admission with airway monitoring
   b. Consider steroids if there is any concern regarding the airway.
   c. After awakening from anesthesia, consider clinical speech evaluation to assess swallow prior to resuming oral feeds.
   d. Outpatient follow-up with an Otolaryngologist (ENT) and speech; repeat modified barium swallow study (MBS) to assess response to the injection
7. Complications
   a. Airway compromise
      1) This can occur due to postoperative edema as a result of manipulation or injection that infiltrated the subglottis.

2) It is important to aim the bevel of the needle posteriorly during injection to avoid infiltration into the airway and to carefully watch the airway during injection to determine if the injection material is causing a narrowing of the airway.

b. Persistent aspiration

Endoscopic Repair of Laryngeal Cleft

1. Anesthesia
   a. Spontaneous ventilation
   b. Requires careful titration of intravenous anesthetic to maintain spontaneous ventilation for up to 30 to 40 minutes
   c. If a laser is being used, room air must be employed during laser use.
   d. No antibiotics are needed.
   e. Intraoperative steroids should be given.
2. Positioning
   a. Supine, with suspension microlaryngoscopy setup
   b. Shoulder roll if needed for suspension
3. Instruments/equipment to have available
   a. Standard microlaryngoscopy set, including vocal cord spreader, which may be helpful to visualize the entire depth of the cleft
   b. Suspension arm for laryngoscope
   c. Microscope or 0-degree telescope for visualization
   d. Endoscopic needle driver and knot pusher
   e. Multiple 4.0 polydioxanone sutures (PDSs) on a P2 needle
   f. CO_2 laser, if using
4. Technique
   a. Incise the cleft to create a laryngeal flap and an esophageal flap (Fig. 195.3A).
      1) Can be done using either a laser or sickle knife
      2) If using a knife, consider applying afrin pledgets prior to incision for hemostasis.
   b. Use endoscopic scissors to ensure adequate depth of incision and to develop laryngeal and esophageal flap.
   c. Suture the left esophageal flap to the right esophageal flap, using an endoscopic needle driver and 4.0 PDS suture on a P2 needle. This may require use of the vocal cord spreader for visualization (see Fig. 195.3B).
   d. Suture the left laryngeal flap to the right laryngeal flap using an endoscopic needle driver and 4.0 PDS suture on a P2 needle.
      1) Buried knot on laryngeal side: Avoid suture material that contacts the laryngeal mucosa because this can be very irritating.
   e. May require multiple sutures on either side, depending on the depth of the cleft. Completed cleft repair is shown in Fig. 195.3C.
5. Common errors in technique
   a. Inadequate depth of incision
   b. Excessive manipulation of tissues resulting in significant airway edema
   c. Loosely tied suture
6. Postoperative care
   a. Overnight admission to intensive care unit for airway observation
   b. Perioperative steroids for 24 hours
   c. Consider overnight intubation only if there are concerns with the degree of potential airway edema at the end of the procedure.
      1) Avoid nasal or oral feeding tubes during intubation to prevent bilateral pressure on the surgical site in the immediate postoperative period.
   d. Perform a speech/swallow evaluation prior to initiating oral feeding.
   e. Discharge on postoperative day 1 if there is no respiratory distress or oxygen requirements overnight and if tolerating oral feeds well.
   f. Follow up with ENT and speech; repeat MBS to assess any residual aspiration.
7. Complications
   a. Airway compromise
      1) More common than in laryngeal cleft injection, due to longer operative time
      2) Try to avoid prolonged operative time.

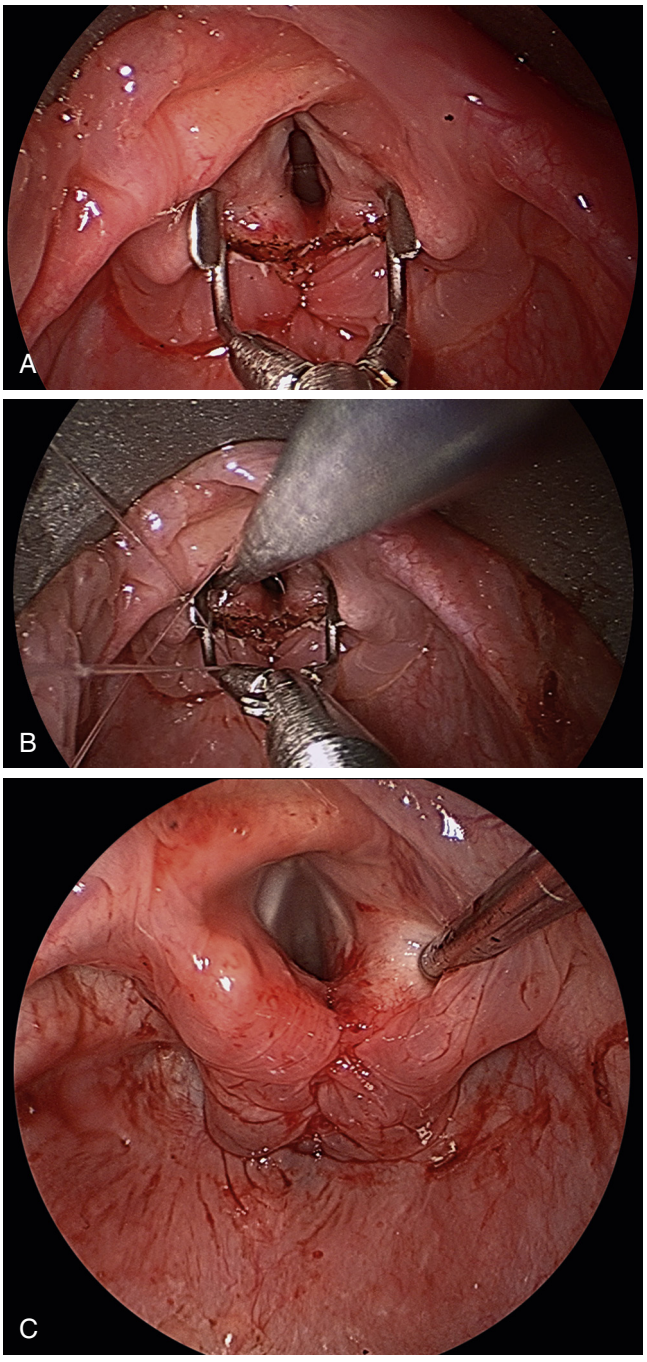

Fig. 195.3. Endoscopic repair of laryngeal cleft. A, An incision has been made using a CO_2 laser, resulting in an anterior laryngeal flap and a posterior esophageal flap. **B,** Endoscopic suture technique, using a vocal cord spreader for improved visualization. **C,** Completed cleft repair.

3) Routine administration of steroids
4) May require overnight intubation if there is a significant amount of airway edema at the end of the case

b. Breakdown of repair
1) Avoid esophageal feeding tube if patient requires intubation to prevent bilateral pressure on surgical repair.
2) Avoid exposed suture tails on the laryngeal surface to prevent irritation/cough, which may contribute to breakdown.

c. Persistent aspiration
1) Identified on follow-up MBS
2) Consider breakdown of repair, if a persistent posterior pattern of aspiration is visualized.
3) Consider concomitant neurologic issues causing aspiration.

d. Posterior glottis stenosis

Open Repair of Laryngeal Cleft

1. Anesthesia
   a. General anesthesia, intubated
   b. Broad-spectrum antibiotics
2. Positioning
   a. Supine
   b. Shoulder roll for neck extension
3. Instruments/equipment to have available
   a. Standard head and neck tray
   b. Suture: 4.0 vicryl or PDS
4. Technique
   a. Horizontal skin incision in the anterior neck, with dissection of subcutaneous tissues
   b. Divide the strap muscles in the midline and retract laterally. Divide the thyroid isthmus if needed for exposure.
   c. Dissect superiorly to expose the cricoid and thyroid cartilage.
   d. Open the airway by incising the cricoid cartilage and thyroid cartilage vertically in the midline. Extend inferiorly to include tracheal rings as needed for exposure of the cleft. Extend superiorly up to but not through the anterior commissure (Fig. 195.4A). May need to divide the anterior commissure if exposure of the cleft is limited
   e. Retract the airway laterally for exposure of the cleft.
   f. Incise the cleft bilaterally from the inferior aspect of the arytenoids to the apex of the cleft. Dissect to create an anterior laryngotracheal mucosal plane and a posterior pharyngoesophageal mucosal plane. Use an otoscopic round knife or small iris scissors to help establish planes (see Fig. 195.4B).
   g. Closure of the posterior plane
      1) Approximate using interrupted sutures, starting at the apex and moving superiorly toward the arytenoids (see Fig. 195.4C).
      2) Avoid excess tension by ensuring adequate submucosal dissection.
   h. Place an interposition graft if desired.
      1) Costochondral cartilage, fashioned in a similar manner as a posterior cartilage graft in laryngotracheal reconstruction
      2) Lateral edges are notched to fit between the residual cricoid ring for stability, and particular attention is paid to ensure that the superior height of the graft is near the aryepiglottic folds (see Fig. 195.4D).
   i. Closure of anterior plane
      1) Close laryngotracheal mucosa using simple interrupted sutures, starting at the apex of the cleft and extending superiorly.
      2) Ensure that sutures are buried, with no exposed suture material in the airway (see Fig. 195.4C).
   j. Close the anterior laryngeal incision using simple interrupted sutures.
   k. Close skin and strap muscles, leaving a Penrose drain in place.
   l. Consider leaving the patient intubated for 2 to 5 days when laryngeal edema with potential airway obstruction is present to avoid the need for reintubation.
5. Common errors in technique
   a. Inadequate exposure of the cleft: Make sure to extend the incision adequately superiorly and inferiorly to allow adequate visualization. This may require a laryngofissure. Could also consider placing superior-most sutures endoscopically if needed to avoid laryngofissure
   b. Inadequate closure: Ensure meticulous closure of posterior and anterior layers.
   c. Leaving exposed suture on tracheal side of repair
6. Postoperative care
   a. Admit to the intensive care unit.
   b. Consider keeping intubated for 2 to 5 days, if concerned about airway edema.
      1) For milder clefts or minimal airway edema, extubate in the operating room.
   c. Remove the Penrose drain after 24 to 48 hours.
   d. Consider broad-spectrum perioperative antibiotics.
   e. Consider reflux medications while intubated.
   f. Consider peri-extubation steroids if the patient remains intubated.
   g. Feeding
      1) For patients with a g-tube, feed via g-tube in the postoperative period, and consider a trial of PO (by mouth) feeds 1 week postoperatively.
      2) For patients without a g-tube, place a small-caliber feeding tube for postoperative feeding if patient remains intubated. Following extubation, consider a clinical feeding trial with thickened feeds versus a modified barium swallow study.
   h. Perform follow-up endoscopy 10 to 14 days postoperatively to evaluate the repair and evaluate for evidence of residual tracheoesophageal fistula.
7. Complications
   a. Tracheoesophageal fistula
   b. Breakdown of surgical repair with residual cleft
      1) Consider revision surgery with interposition material such as sternocleidomastoid muscle flap or temporalis fascia.
   c. Airway granuloma: Avoid exposed suture material in the airway; tie all knots on the esophageal side.
   d. Blunting of anterior commissure

Laryngotracheal Separation

1. Anesthesia
   a. General anesthesia; ventilate via endotracheal tube or tracheostomy tube (if patient has a trach)
   b. Broad-spectrum antibiotics
2. Positioning
   a. Supine
   b. Shoulder roll for neck extension
   c. Prep and drape neck similar to tracheostomy.
3. Instruments/equipment to have available
   a. Standard head and neck set
   b. Penrose drain
   c. Suture: Nonabsorbable sutures such as silk, nylon, or prolene for stump closure and stoma maturation
4. Technique
   a. Horizontal skin incision that incorporates the tracheostomy stoma if present

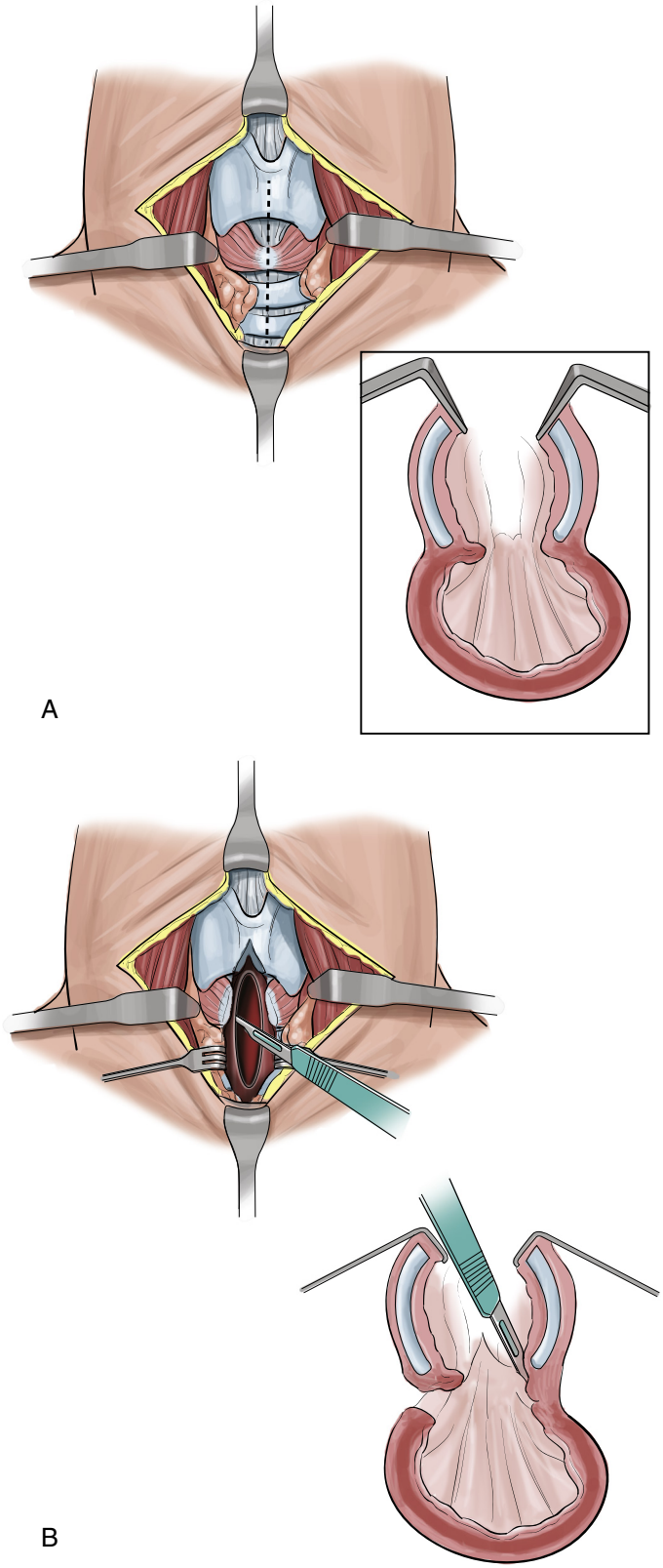

Fig. 195.4. Open repair of laryngeal cleft. A, Exposure. Tracheal wall, cricoid cartilage, and inferior half of the thyroid cartilage are incised and opened. **B,** The cleft is divided into two separate layers: The anterior layer will become the posterior tracheal wall, and the posterior layer will become the anterior esophageal wall. **C,** Closure of two separate layers with sutures. The tracheal suture knots must face posteriorly, away from the airway. **D,** Repair with interposition cartilage graft.

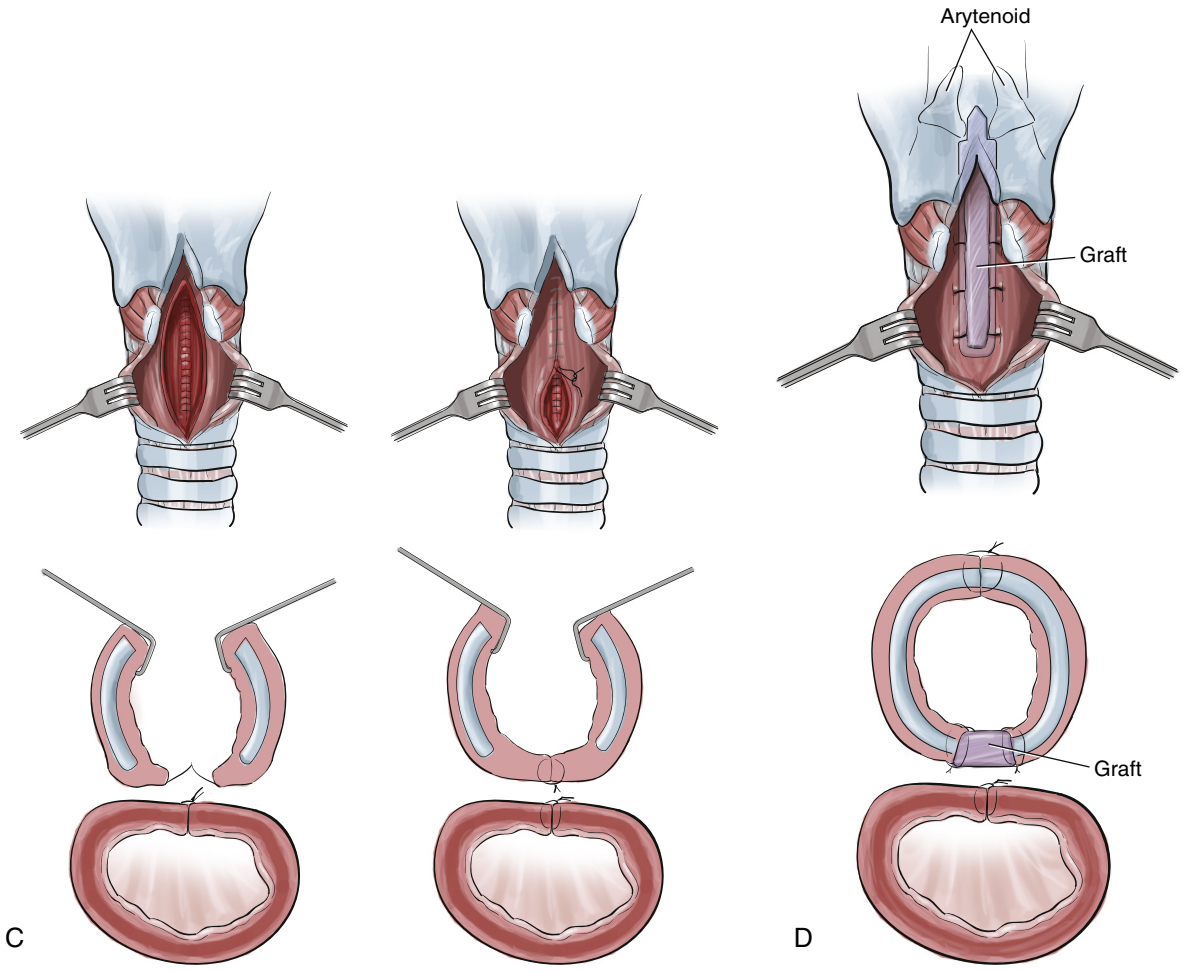

Fig. 195.4, cont'd

b. Divide the strap muscles in the midline and retract laterally.
c. Divide the thyroid isthmus.
d. Identify the site of laryngotracheal separation: This should be approximately between the level of the 3rd and 4th tracheal rings or at the site of the tracheostomy stoma.
e. Expose the trachea laterally, taking care to dissect immediately adjacent to the trachea to avoid injury to the recurrent laryngeal nerves.
f. Transect the trachea and place the endotracheal tube into the distal trachea for the remainder of the procedure.
g. Carefully divide the posterior tracheal wall, taking care not to enter the esophagus.
h. Once the trachea has been transected, dissect it free inferiorly and superiorly.
i. Close proximal stump.
   1) Incise the fascia to expose the inferior-most ring in the upper stump. Dissect the ring free and remove the cartilage, keeping the underlying mucosa intact (Fig. 195.5A).
   2) Divide the second-to-last ring anteriorly to allow the ring to collapse on itself and reduce tension on the mucosal closure.
   3) Close the mucosa in a running inverting fashion similar to a pharyngeal closure in laryngectomy (see laryngectomy) (see Fig. 195.5B).
   4) Reinforce closure using additional interrupted suture through the divided tracheal ring.
j. Form stoma.
   1) The distal trachea is brought to the skin, and a stoma is formed similar to a laryngectomy stoma (see Fig. 195.5C).
   2) Use half mattress sutures to mature stoma to the skin.
k. Close the remaining incision laterally using running closure. Leave the Penrose drain in place. See Fig. 195.5D for a schematic that shows the final result.
l. Remove the endotracheal tube and place the tracheostomy tube into the airway.

5. Common errors in technique
   a. Inadequate mucosal closure of the proximal stump, resulting in fistula
   b. Excessive dissection laterally, resulting in damage to recurrent laryngeal nerves
6. Postoperative care
   a. Admit to the intensive care unit, and keep sedated and comfortable for the first several days.
   b. Continue broad-spectrum antibiotics for 5 to 7 days.
   c. Remove the Penrose drain after 24 to 48 hours.
   d. May resume oral feeds as soon as tolerated by the patient, as early as postoperative day 3. Some patients will require enteral feeds due to their neurologic condition.
   e. Routine stomal care, with daily cleaning and débridement of stoma
   f. Must communicate the nature of the surgery to other care providers, because the patient is now no longer orally intubatable. We recommend placing a sign over the bed that identifies the patient as a "total neck breather" to remind other caregivers that the patient's only airway is the stoma.

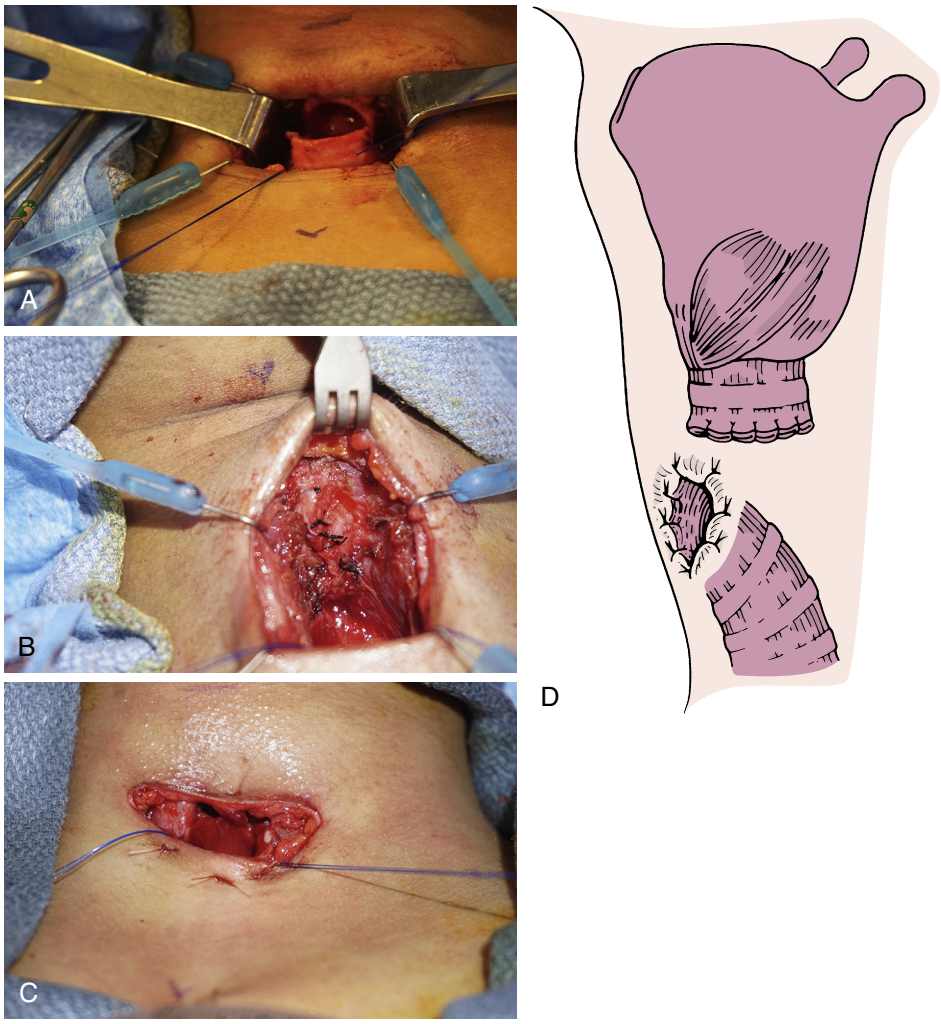

Fig. 195.5. Laryngotracheal separation. A, After the trachea has been divided, the lowest ring on the superior part of the trachea is removed to provide adequate mucosa for stump closure. **B,** The mucosa is closed in a running inverting fashion. **C,** Appearance of the stoma. **D,** Laryngotracheal separation. The proximal trachea is closed as a blind pouch, and the distal trachea is brought to the skin and a stoma is formed.

7. Complications
   a. Tracheocutaneous fistula: Usually secondary to difficulty closing the proximal tracheal stump
   b. Dysphagia: Can be a complication of the procedure or may be due to the underlying neurologic disease. Patients may require enteral nutrition.
   c. Tracheoinnominate fistula is often fatal.

DISCUSSION

Evidence-Based Medicine Question

What is the difference between a type 1 laryngeal cleft and a deep interarytenoid notch, and should they be managed differently?

Historically, type 1 laryngeal cleft has been described as an absence or hypoplasia of the interarytenoid musculature, resulting in a cleft that can extend as far inferior as the level of the true vocal cords. However, a superior limit for type 1 laryngeal cleft has not been described. Therefore, although historically a diagnosis of type 1 laryngeal cleft was reserved for patients who had a cleft extending to the level of the true vocal cords, many patients are now being diagnosed who have a cleft that is deemed deeper than "normal" but does not extend all the way to the level of the true vocal cords. The terms *deep interarytenoid notch* and *type 1 laryngeal cleft* have been used interchangeably to describe this entity.

In recent years, the incidence of type 1 laryngeal cleft has increased significantly, likely due to increased awareness and increased diagnosis of the more subtle clefts. Even among patients with more subtle clefts, they often respond favorably to injection augmentation, suggesting that these clefts are clinically significant. Therefore, most Pediatric Otolaryngologists treat these entities similarly in symptomatic patients. One recent study looked at injection augmentation for all pediatric patients with chronic aspiration, regardless of the presence of a type 1 cleft, and found benefit in patients with normal anatomy as well as in those with a type 1 laryngeal cleft. This suggests that there may be even more subtle variants that we are not easily identifying or that these patients have a functional cleft rather than an anatomic cleft. Further work is needed to define a superior limit for making the diagnosis of a deep interarytenoid notch and to further study functional versus anatomic clefts.

Editorial Comment

Dysphagia and aspiration are problems that are commonly encountered by the Pediatric Otolaryngologist. Although fairly uncommon, it is important to maintain a high index of suspicion for laryngeal cleft, because this condition can potentially be treated surgically. Laryngeal clefts can range from very subtle deep interarytenoid notches to type 4 clefts that extend a variable distance into the trachea. Over the past

several years, the popularity of injection laryngoplasty has increased significantly, with tremendous benefit to many patients with dysphagia. In cases where the diagnosis is uncertain, injection can help to establish a diagnosis of type 1 laryngeal cleft. Additionally, even in patients with chronic aspiration and normal anatomic findings, injection has been shown to have significant benefit. This is an exciting area within Pediatric Otolaryngology and an area ripe for further study.

Sukgi Choi


Access the review questions and additional sources list online at http://www.expertconsult.com

REFERENCES

1. Vaquero-Sosa E, Francisco-González L, Bodas-Pinedo A, et al. Oropharyngeal dysphagia, an underestimated disorder in pediatrics. Rev Esp Enferm Dig 2015;107(2):113–115. [Epub 2015/02/11].
2. Arvedson JC. Assessment of pediatric dysphagia and feeding disorders: clinical and instrumental approaches. Dev Disabil Res Rev 2008;14(2):118–127.
3. Beer S, Hartlieb T, Müller A, et al. Aspiration in children and adolescents with neurogenic dysphagia: comparison of clinical judgment and fiberoptic endoscopic evaluation of swallowing. Neuropediatrics 2014;45(6):402–405. [Epub 2014/10/25].
4. Bae SO, Lee GP, Seo HG, et al. Clinical characteristics associated with aspiration or penetration in children with swallowing problem. Ann Rehabil Med 2014;38(6):734–741. [Epub 2015/01/08].
5. Leboulanger N, Garabédian E-N. Laryngo-tracheo-oesophageal clefts. Orphan J Rare Dis 2011;6:81.
6. Benjamin B, Inglis A. Minor congenital laryngeal clefts: diagnosis and classification. Ann Otol Rhinol Laryngol 1989;98(6):417–420. [Epub 1989/06/01].
7. Chiang T, McConnell B, Ruiz AG, et al. Surgical management of type I and II laryngeal cleft in the pediatric population. Int J Pediatr Otorhinolaryngol 2014;78(12):2244–2249.
8. Ojha S, Ashland JE, Hersh C, et al. Type 1 laryngeal cleft: a multidimensional management algorithm. JAMA Otolaryngol Head Neck Surg 2014;140(1):34–40. [Epub 2013/11/23].
9. Rahbar R, Rouillon I, Roger G, et al. The presentation and management of laryngeal cleft: a 10-year experience. Arch Otolaryngol Head Neck Surg 2006;132(12):1335–13341.
10. Adil E, Al Shemari H, Rahbar R. Endoscopic surgical repair of type 3 laryngeal clefts. JAMA Otolaryngol Head Neck Surg 2014;140(11):1051–1055. [Epub 2014/10/17].

REVIEW QUESTIONS

1. Which of the following correctly describes a type 2 laryngeal cleft?
   a. Cleft to the level of the false vocal cords
   b. Cleft that extends to the level of the true vocal cords
   c. Cleft that extends into the cricoid cartilage
   d. Cleft that extends through the cricoid cartilage and into the trachea

2. Which syndrome is associated with laryngeal cleft?
   a. Down syndrome
   b. Pallister-Hall syndrome
   c. Crouzon syndrome
   d. Pfeiffer syndrome

3. Which option is a disadvantage of fiber **optic** examination of swallowing compared to a modified barium swallow study?
   a. Unable to directly visualize anatomy
   b. Unable to assess for silent aspiration
   c. Requires radiation
   d. Unable to assess pharyngeal phase of swallowing

4. When performing an endoscopic or open repair of a laryngeal cleft, which of the following is true regarding the suture repair?
   a. Tie sutures with tails on the laryngeal side of the repair.
   b. Tie sutures with tails on the esophageal side of the repair.
   c. It is best to use all vertical mattress sutures.
   d. It is best to use all horizontal mattress sutures.

ADDITIONAL SOURCES

Horn DL, DeMarre K, Parikh SR. Interarytenoid sodium carboxymethylcellulose gel injection for management of pediatric aspiration. Ann Otol Rhinol Laryngol 2014;123(12):852–858.

Leishman C, Monnier P, Jaquet Y. Endoscopic repair of laryngotracheoesophageal clefts: experience in 17 cases. Int J Pediatr Otorhinolaryngol 2014;78(2):227–231. [Epub 2013/12/18].

Nakahara S, Tayama N, Tsuchida Y. A minor laryngeal cleft (type 1-a) diagnosed in infancy. Int J Pediatr Otorhinolaryngol 1995;32(2):187–191.

196 Recurrent Respiratory Papillomatosis

Craig Derkay, Travis Reeves

INTRODUCTION

Recurrent respiratory papillomatosis (RRP) is a disease of viral etiology, caused by human papillomavirus (HPV) types 6 and 11, associated with exophytic lesions of the airway. Although it is a benign disease, RRP has potentially morbid consequences due to its involvement of the airway, its propensity to recur, and its risk of malignant conversion. Surgical therapy for RRP requires a skilled team consisting of otolaryngologists, anesthesiologists, and operating room personnel working together in a facility properly equipped to manage the difficult pediatric airway.

KEY OPERATIVE LEARNING POINTS

1. The goal of surgical therapy is to maintain a patent airway, improve the quality of the voice, and avoid harm.
2. Close coordination with a pediatric anesthesiologist is critical for successful surgical management of patients with RRP.
3. Many adjuvant therapies, such as Avastin and cidofovir, are available for severe cases of RRP.

PREOPERATIVE PERIOD

History

1. History of present illness
   a. The quality of the patient's voice should be assessed. If hoarseness is present, then the onset and timing of the voice changes should be documented.
   b. Respiratory distress, shortness of breath, and exercise intolerance are common presenting symptoms. The timing, quality, and severity of these symptoms should be investigated carefully. Rapid onset with severe symptoms warrants urgent intervention.
   c. The patient should be assessed for other possible lesions of the upper aerodigestive tract. An exhaustive history should be taken that would include other symptoms such as dysphagia, weight loss/failure to thrive, diet, and risk factors such as smoking and alcohol use (in the adult population).
2. Past medical history
   a. Maternal history of human papilloma virus (HPV) infection and any history of HPV vaccinations should be documented.
   b. Prior treatment:
      1) Previous RRP surgical procedures (obtain operative notes, pathology reports and/or photos if possible)
      2) Adjunct medical therapies
   c. Other medical illnesses
   d. Other surgical procedures
   e. Family history:
      1) Anesthetic complications
      2) Bleeding disorders
   f. Medications (prescription and over-the-counter [OTC] drugs)

Physical Examination

Fiberoptic laryngoscopy: Careful, sequential inspection of the nose, nasopharynx, pharynx, hypopharynx, larynx, and subglottis provides the critical information necessary to make the diagnosis of RRP and allows estimation of lumen size, vocal cord mobility, and the urgency of operative intervention. Further, this examination allows the surgeon to comprehensively examine the larynx to rule out other etiologies for the patient's presenting symptoms such as vocal cord paresis, functional voice disorder, and other benign vocal cord processes (i.e., nodules, polyps). Papillomas have a distinctive appearance on laryngoscopy, but definitive diagnosis requires biopsy and pathologic examination (Fig. 196.1).

Imaging

Rarely, recurrent respiratory papillomatosis can spread to the lower airway.

A chest radiograph or chest computed tomography (CT) could be considered if there is concern for lower airway obstruction such as a history of recurrent pneumonia or hemoptysis. A CT of the neck would only be performed if there was a concern for upper airway malignancy, which is rare in children.

Indications

- Biopsy needed to confirm diagnosis at initial presentation
- Symptoms of airway obstruction
- Hoarseness and voice disturbance

Contraindications

1. Medical comorbidities with increased risk for general anesthesia in elective cases

Preoperative Preparation

1. Control other medical comorbidities.
2. Discontinue antiplatelet drugs if possible.

OPERATIVE PERIOD

Anesthesia

General anesthesia is preferred for extensive disease, acute airway obstruction, and the pediatric population. Utilization of an anesthesiologist with pediatric expertise and familiarity with this entity is crucial to ensure safety in juvenile-onset recurrent respiratory papillomatosis (JORRP).

- Induction
  - Induction typically proceeds with mask induction through the use of sevoflurane with or without nitrous oxide (NO). NO increases the speed of induction and reduces the time spent in stage II, where laryngospasm is most prevalent. Conversely, its use reduces the fraction of inspired oxygen (FiO_2) giving the anesthesiologist less time before a desaturation event if an airway emergency were to occur.
- Airway management
  - Intubation:
    - Continuous: The endotracheal tube (ETT) is placed after induction and remains throughout the surgical



Fig. 196.1. Characteristic appearance of RRP on fiberoptic laryngoscopy.

procedure. This provides a definitive airway for the anesthesiologist regardless of paralyzation status. It also allows for the use of volatile anesthetics. However, it can distort laryngeal anatomy, obscure the operative sight for the otolaryngologist, and provide fuel for an airway fire if a laser is being used.

- Intermittent: The ETT is removed intermittently and replaced when oxygenation and ventilation are required. This provides the otolaryngologist with an unobstructed, nonmobile view but can lead to hypercapnia, hypoxia, and subglottic, laryngeal, or tracheal swelling due to multiple intubations. Ideally, ventilation with the ETT in place should last as long as needed to return the peripheral capillary oxygen saturation (SpO_2) and partial pressure or maximal concentration of carbon dioxide ($EtCO_2$) to baseline prior to the next extubation.

- Nonintubation:
  - Total intravenous anesthesia (TIVA) is preferred for this method.
  - Spontaneous ventilation: Oxygen can be administered through the laryngoscope using the insufflation port by connecting it to the anesthesia circuit via an ETT adaptor.
  - Jet ventilation: A small catheter is positioned distally to allow high-flow oxygen to inflate the lungs and allow for small-volume ventilation. Unfortunately, jet ventilation has a higher risk of pneumothorax and may be ineffective in obese patients or those with extensive, small airway disease.

Local: Topical anesthesia can be used with fiberoptic laryngoscopes for biopsy and administration of laser therapy. This technique is appropriate for limited disease in the adult population.

Positioning

Supine: The patient is positioned in a standard fashion for direct laryngoscopy. Many surgeons prefer a "sniffing" position or shoulder roll for optimal alignment with the larynx.

Perioperative Antibiotic Prophylaxis: Antibiotic prophylaxis is not typically used.

Perioperative Steroids: These are administered to reduce the risk of postoperative nausea/vomiting and airway edema.

Monitoring

Routine anesthesia monitoring to include pulse oximetry, electrocardiogram (ECG), and temperature

Instruments and Equipment to Have Available

1. Basic direct laryngoscopy set
   a. Laryngoscope (Parson, Lindholm, Dedo)
   b. Suspension device
   c. Light sources
   d. Microscope or magnified telescope
   e. Video tower
   f. Suction
2. Age-appropriate rigid ventilating bronchoscope available as needed for acute airway obstruction
3. Laser safety equipment as indicated
4. Microdébrider
5. Filtered suction
6. Smoke evacuator unit
7. Assortment of laryngeal biopsy forceps, alligators, suctions
8. Laryngeal (vocal cord) spreader (optional)

Key Anatomic Landmarks

1. A thorough understanding of the laryngeal anatomy is critical to performing surgery for RRP. Structure and function of the larynx should be maintained to preserve the patient's voice and to prevent abnormal scarring.
   a. Vocal cords: The vibratory surface of the cords should be protected as much as possible. Removal of the deep musculature of the vocal cords is unnecessary for this epithelial disease and is avoided to preserve function.
   b. Anterior commissure: This area is critical to laryngeal function and voice preservation. Care should be taken NOT to address the anterior aspect of both vocal cords during a single operation as abnormal scarring can result in an acquired laryngeal web.
   c. Supraglottic structures: The epiglottis, false vocal cords, and arytenoids comprise the supraglottis and are often involved in RRP.
2. The subglottis and lower airway are more rarely involved in RRP; however, if disease has spread to these areas, then it is important to avoid circumferentially disrupting the mucosa to prevent cicatricial scar formation.

Prerequisite Skills

1. Suspension laryngoscopy
2. Rigid bronchoscopy

Operative Risks

1. Acute airway obstruction during induction secondary to papilloma. Spontaneous ventilation should always be used to reduce this risk. Communication and collaboration with anesthesiologists are crucial.
2. Laryngeal scarring and web formation
3. Permanent voice changes

Surgical Technique

- Induce the patient into general anesthesia with spontaneous ventilation (usually with sevoflurane), then establish IV access. Paralysis should be avoided until the airway is secure. If paralysis is used, then an apneic or jet technique is required for ventilation.
- If prior (office) flexible fiberoptic nasopharyngoscopy/laryngoscopy have not been performed, then this can be done in the operating room (OR) to document vocal cord dynamics and assess for papillomas (or other pathologies) above the larynx.

- Direct laryngoscopy is then performed with a magnified telescope to map the affected areas. The larynx is sprayed with topical lidocaine to reduce reactivity to instrumentation. Photos are taken for documentation and to follow the effectiveness of therapy over time. Scoring of the extent of disease is useful at this point for documentation, assessment of response to therapy, communication with colleagues, and determining the next surgical interval (Fig. 196.2).[1]
- After laryngoscopy, the telescope should be advanced into the tracheobronchial tree for visualization of the subglottis, trachea, and main stem bronchi. If the airway is not secure due to bulky disease, then a rigid ventilating bronchoscope should be used.
- Suspension laryngoscopy is then performed according to the surgeon's preference. Dedo, Parson, Benjamin, and Lindholm laryngoscopes are all commonly used. We prefer a slight reverse Trendelenburg position to aid in visualization and surgeon comfort (particularly if the microscope is needed). After adjusting for excellent visualization, the microscope or magnified telescope can be used to perform the operation. Various techniques are commonly employed, but the goals of therapy are the same.
- Biopsy of the papillomatous lesion is performed. This should be repeated at subsequent RRP operations yearly (sooner if there is a change in the frequency of surgery, distal spread of papillomas, or institution of potentially carcinogenic adjuvant therapies).[2] Subtyping of the papilloma is desirable (if facilities are available) to help determine prognosis (HPV 11 tends to act more aggressively than HPV 6).[3]
- Goals of any therapeutic RRP regimen include eradication of disease from the airway, improvement in voice quality, control of disease spread, and decrease in the number of trips to the operating room for surgical débridement.
- A number of different techniques can be employed to obtain these treatment goals, and the preferred modality depends on the surgeon's comfort and training.
- Laser treatment for RRP has been used for more than 30 years and is a popular treatment modality.[4]
  - CO_2 laser:
    - The CO_2 laser has an emission wavelength of 10,600 nm and converts light to thermal energy. It provides a controlled destruction of tissues with vaporization of water and also cauterizes tissue surfaces.
  - Pulse dye laser (PDL):
    - The PDL is a nonablative laser that selectively targets the microvasculature of the lesion, thus sparing the epithelium through a photoangiolytic effect. The wavelength of the PDL is 585 nm. The PDL takes advantage of the chromophore in oxyhemoglobin, which has peaks at both 540 nm and 585 nm. The PDL can be employed in the operating room or in an office-based setting.
  - Potassium titanyl phosphate (KTP) laser:
    - The KTP laser has a wavelength of 532 nm, which is similar to one of the peak absorption wavelengths of hemoglobin. The KTP laser can be used in the office or operating room setting to treat papillomatous lesions in a fashion similar to the PDL.
    - No study yet has determined the optimum energy delivery necessary to affect tissue coagulation and/or effectively cause photoangiolysis.
- General technique for laser surgery of the larynx
  - The laser is not used until the oxygen in the anesthesia mixture is lower than 40% and ideally between 26% and 30%.
  - Moistened neuro patties may be placed at the laryngeal inlet to decrease the air leak and to provide a backstop for errant laser shots. (These must be kept moist because they too can act as a source of combustion.)
  - A small-caliber suction device is kept close to the laser impact site to remove the hot steam of vaporization. The suction can also be used to remove eschar and as a retractor of the vocal folds to allow for exposure of the subglottic region.
  - Neuro patties soaked in oxymetazoline are used for removal of eschar and for hemostasis.
  - Care is taken to avoid injuring the anterior commissure, and at least 1 mm of untreated mucosa should be left in this region so that a web does not develop during the healing period. Similar precautions are taken when addressing the posterior commissure.
- Microdébrider
  - In a survey of pediatric otolaryngologists conducted in 2004, the majority of respondents (52%) identified the microdébrider as the preferred technique for removal of papilloma.[5]
  - Advantages of this technique include: improved voice outcomes, minimal collateral laryngeal mucosal thermal trauma, less procedure time, fewer personnel required in the operating room, reduced cost when compared to the laser, and no increase in pain scores. Safety advantages include no risk of laser fire or burns and reduced risk of exposure of operating room personnel to aerosolized viral particles.[6]
  - Surgical technique
    - A proper length Xomed (Medtronics, Minneapolis, Minnesota) laryngeal Skimmer blade is chosen (18 cm vs. 22 cm depending on the relative size of the child). A 250-cc bag of sterile saline or water is used for irrigation, and the microdébrider unit is typically set between 600 and 1000 rpm in oscillation mode.
  - The surgeon must be comfortable working with the microdébrider in either hand; the removal of a papilloma from the left side of the larynx is best accomplished when the device is used in the right hand, while disease from the right side should be removed with the microdébrider in the surgeon's left hand. The hand opposite the device holds a microsuction, which is used to help retract tissue and evacuate blood.
  - To minimize the risk of web formation, it is essential to avoid creating opposing raw surfaces at both the anterior and posterior commissure with the microdébrider. Care should also be taken when removing sessile papillomas from the true vocal cord surface, erring on the side of leaving disease as opposed to sacrificing a portion of the vocal fold.
  - The microdébrider does allow for removal of papillomas in the subglottis and proximal one-third of the trachea by placing a 7200-A telescope in one hand and the microdébrider in the other.
- Adjunctive therapy
  - Medications can be administered via submucosal injection during RRP surgery. These adjunctive therapies have been shown to improve long-term outcomes.[7]
  - Technique: A spinal needle, laryngeal cord injector, or butterfly needle on an alligator forceps can be used for submucosal injections and is administered under telescopic or microscopic guidance.
  - Medications
    - Bevacizumab (Avastin): This antiangiogenic agent has been shown in small studies to work synergistically with the photoangiolytic KTP laser.[8]
      - Dose: Typically patients will receive 5 to 10 mg per treatment encounter.
    - Cidofovir[2]
      - Dose: 3 mg/kg given at a concentration of 2.5 to 10 mg/mL. Usually less than 2 mL is given per treatment

A. Clinical Score

DATE OF SURGERY _____ SURGEON _____

INSTITUTION _____

1. Describe the patient's voice today:
   normal ___ (0), abnormal ___ (1), aphonic ___ (2)
2. Describe the patient's stridor today:
   absent ___ (0), present with activity ___ (1), present at rest ___ (2)
3. Describe the urgency of today's intervention:
   scheduled ___ (0), elective ____ (1), urgent ___ (2), emergent ___ (3)
4. Describe today's level of respiratory distress:
   none ___ (0), mild ___ (1), moderate ___ (2), severe ___ (3), extreme ___ (4)

Total score for questions 1 through 4 = _____

B. Anatomic Score

For each site, score as: 0 = none, 1 = surface lesion, 2 = raised lesion, 3 = bulky lesion

LARYNX:

Epiglottis: Lingual surface ___ Laryngeal surface ___

Aryepiglottic folds: Right ___ Left ___

False vocal cords: Right ___ Left ___

True vocal cords: Right ___ Left ___

Arytenoids: Right ___ Left ___

Anterior commissure _____

Posterior commissure _____

Subglottis _____

TRACHEA:

Upper one-third _____

Middle one-third _____

Lower one-third _____

Bronchi: Right ___ Left ___

Tracheotomy stoma ____

OTHER:

Nose _____

Palate _____

Pharynx _____

Esophagus ___

Lungs _____

Other _____ Total Score for Anatomic _____

C. Total Score

Total Anatomic Score plus Total Clinical Score _____

Fig. 196.2. Laryngoscopic and clinical assessment scale for recurrent respiratory papillomatosis.

encounter. This medication should be administered once per month for 4 to 6 months to see optimal treatment effect.

- Risks: There are concerns about an increase in the risk of malignancy with cidofovir, but it is unclear whether the risk exceeds that of the disease process itself.
  - Indications
  - More than six surgeries per year
  - Increasing frequency of surgery
  - Extralaryngeal or bulky disease

Common Errors in Technique

1. Inadequate exposure with poor visualization of the laryngeal structures
2. Bilateral mucosal injury at the anterior commissure resulting in laryngeal web formation and voice disruption

POSTOPERATIVE PERIOD

Postoperative Management

1. Continuous pulse oximetry in the postanesthesia care unit (PACU)
2. Albuterol and racemic epinephrine nebulizers are ordered for patients in the PACU on an as-needed basis.
3. Pain medication: Patients would not be expected to have much pain following this operation. Nonsteroidal anti-inflammatory drugs such as ibuprofen may be administered. Occasionally a dose of steroids is administered postoperatively if the patient has symptomatic obstruction secondary to mucosal edema.
4. Humidified air and supplemental oxygen are given as needed.

Complications

1. Vocal cord scarring
2. Laryngeal web formation
3. Cicatrix formation in the lower airway
4. Voice changes
5. Perioperative airway obstruction
6. Recurrence of papillomas and/or distal spread
7. Iatrogenic exposure of HPV to OR personnel and subsequent patients (this is minimized by the use of a laser-safe mask and changing of anesthesia tubing between cases).
8. Potential complications of laser surgery include the development of anterior commissure webs, laryngeal and subglottic stenosis, burns to the patient or operating room personnel, and laser-induced endotracheal tube fire.
9. Laser fire

This event is more likely to occur when there are high oxygen concentrations and in the presence of a polyvinyl chloride endotracheal tube. Direct thermal injury to local tissues or a chemical burn may result from such a mishap. To prevent a laser fire, the oxygen concentration should be limited to less than 40%, or alternately the patient can be ventilated with room air. Avoidance of any flammable object (i.e., an endotracheal tube) in the operating field can eliminate this risk. In the event of a laser fire, emergency care consists of immediate extubation of the patient and disconnection of the tube from its oxygen source. The child is then reintubated and examined through a ventilating bronchoscope. Antibiotics are given and a tracheotomy may be necessary based on the degree of damage. Tertiary care consists of positive end-expiratory pressure (PEEP) and reverse isolation.

Alternative/Additional Management Plan

1. Systemic chemotherapeutic medications[7]
2. Zeitels has advocated local injection of Avastin and KTP laser treatment for recurrent RRP.[8]
3. Tracheostomy.[9] Use of tracheostomy for management of RRP is controversial. In a limited-resource setting, this may be the safest means of managing the disease. With access to tertiary care pediatric facilities and providers, tracheostomy may lead to spread of the disease outside of the larynx and complicate future management.
4. Prevention though HPV vaccination.[10] This is the most promising development in RRP in the past decade. The introduction of the quadrivalent HPV vaccine (and recent approval of the 9-valent vaccine) for use in boys and girls before they become sexually active (i.e., before they are exposed to HPV) may significantly reduce the future incidence of RRP (and some forms of head and neck cancer) in the population via herd immunity. Otolaryngologists should work with their colleagues in pediatrics, family medicine, and gynecology to advocate for HPV vaccination of teenagers.
5. Collaboration of research with the RRP Task Force. With orphan disease such as RRP, it is difficult for a single center to have enough patients to test out innovative treatments. Consequently, it is desirable to coordinate research endeavors and evaluate research ideas with colleagues at other institutions. This has been facilitated through the creation of the RRP Task Force. See additional readings later in this chapter for further information.

Evidence-Based Medicine Question

Is Subepithelial Injection Performed at the Same Time as Routine RRP Surgery as Effective as Laser/Microdebrider Alone?

Consensus of the cidofovir working group and the RRP Task Force is that use of adjuvant subepithelial injections are more effective when combined with the surgical ablation of papillomas (Volsky reference/Derkay-Wiatrak review article).

Editorial Comment

Recurrent respiratory papillomatosis is a frustrating, capricious disease with the potential for morbid consequences due to its involvement of the airway and the risk of malignant degeneration. The goals of surgical therapy are to maintain a safe airway with a serviceable voice while avoiding excessive scarring. Surgical therapy for RRP requires a skilled team consisting of otolaryngologists, anesthesiologists, and OR personnel working together in a facility properly equipped to manage difficult pediatric airways. Although adjuvant therapies such as Avastin and cidofovir can improve on surgical outcomes, the only truly effective treatment for RRP is prevention through HPV vaccination. As vaccination rates rise, we hope to see a dramatic decrease in the incidence of papillomatosis. Numerous questions remain related to HPV vaccination. Ongoing studies are seeking to understand these issues, which include the relationship between vaccination and rates of laryngeal HPV infection, the protective effect of antibodies transferred to infants born to vaccinated mothers, and the potential for preventing squamous cell carcinoma in the adult population. Standards of care for vaccination are changing, and the HPV vaccine is now in mainstream use; however, societal acceptance of a vaccine for a sexually transmitted disease is still lacking. Otolaryngologists should advocate for administration in their communities and in coordination with local pediatricians.

Craig Derkay

Access the review questions and additional sources list online at http://www.expertconsult.com

REFERENCES

1. Derkay CS, Hester RP, Burke B, et al. Analysis of a staging assessment system for prediction of surgical interval in recurrent respiratory papillomatosis. Int J Pediatric Otorhinolaryngol 2004;68:1493–1498.
2. Derkay CS, Volsky PG, Rosen CA, et al. Current use of intralesional cidofovir for recurrent respiratory papillomatosis. Laryngoscope 2013;123(3):705–712.
3. Buchinsky FJ, Donfack J, Derkay CS, et al. Age of child, more than HPV type, is associated with clinical course in recurrent respiratory papillomatosis. PLoS One 2008;3(5):e2263.
4. Koufman JA, Rees CJ, Frazier WD, et al. Office-based laryngeal laser surgery: a review of 443 cases using three wavelengths. Otolaryngol Head Neck Surg 2007;137:146–151.
5. Derkay CS, Schraff S. Survey of ASPO membership regarding management of RRP distal spread and the use of adjuvant therapies. Arch Otolaryngol Head Neck Surg 2004;130:1039–1042.

6. Pasquale K, Wiatrak B, Wooley A, et al. Microdebrider versus CO_2 laser removal of recurrent respiratory papillomatosis: a prospective analysis. Laryngoscope 2003;113:139–143.
7. Gallagher TQ, Derkay CS. Pharmacotherapy of recurrent respiratory papillomatosis: an expert opinion. Expert Opin Pharmacother 2009;10(4):645–655.
8. Zeitels SM, Barbu AM, Landau-Zemer T, et al. Local injection of bevacizumab (Avastin) and angiolytic KTP laser treatment of recurrent respiratory papillomatosis of the vocal folds: a prospective study. Ann Otol Rhinol Laryngol 2011;120(10):627–634.
9. Shapiro AM, Rimell FL, Shoemaker D, et al. Tracheotomy in children with juvenile-onset recurrent respiratory papillomatosis: The Children's Hospital of Pittsburgh experience. Ann Otol Rhinol Laryngol 1996;105:1–5.
10. Derkay CS, Buchinsky FJ. Preventing RRP and other HPV-associated head and neck disease with prophylactic HPV vaccines. Otolaryngol Head Neck Surg 2007;26(7):60–61.

REVIEW QUESTIONS

1. Which of the following HPV subtypes is most commonly associated with RRP?
   a. Types 1 and 2
   b. Types 6 and 11
   c. Types 16 and 18
   d. Types 53 and 57
   e. Types 62 and 69

2. Which of the following factors predisposes to a more severe clinical course in children with JORRP?
   a. Diagnosis of RRP at less than 3 years of age
   b. HPV subtype 6
   c. Maternal history of condylomata
   d. Family history of RRP

3. Which of the following is the most commonly used adjuvant for RRP among members of the American Society of Pediatric Otolaryngology (ASPO)?
   a. Bevacizumab (Avastin)
   b. Intralesional cidofovir
   c. Celecoxib (Celebrex)
   d. Interferon

4. RRP demonstrates a predilection for which of the following sites?
   a. Junction of ciliated and squamous epithelium
   b. The undersurface of the vocal folds
   c. The laryngeal ventricle
   d. All of the above

5. Which option includes the most common presenting symptoms in children with RRP?
   a. Dysphagia and poor weight gain
   b. Dyspnea with exertion
   c. Progressive hoarseness and stridor
   d. Odynophagia

6. Which of the following statements best describes the management of RRP?
   a. Complete eradication of disease is essential.
   b. The goal of surgical therapy is to maintain a patent airway, improve voice quality, and do no harm.
   c. Adjuvant therapies such as cidofovir should be used in children with mild RRP who require surgical intervention two or fewer times per year.
   d. Tracheostomy is a mainstay of treatment and should be considered in all infants diagnosed with RRP.

ADDITIONAL SOURCES

Campisi P, Hawkes M, Simpson K, et al. The epidemiology of juvenile onset recurrent respiratory papillomatosis derived from a population level national database. Laryngoscope 2010;120:1233–1245.

Derkay CS, Wiatrak B. Recurrent respiratory papillomatosis (RRP): a review. Laryngoscope 2008;118(7):1236–1247.

Reeves WR, Ruparellia SS, Swanson KL, et al. National registry for juvenile-onset RRP. Arch Otolaryngol 2003;129(9):976–982.

197 Exit Procedure

David Mandell, Jeffrey P. Simons

INTRODUCTION

The ex utero intrapartum treatment (EXIT) procedure is a technique for managing fetal airway obstruction at the time of delivery. The key component of the procedure is that a fetal airway is established while maintaining fetal oxygenation with the uteroplacental circulation.[1]

Fetal airway obstruction is typically first identified via an incidental finding on routine prenatal ultrasonography, which then leads to more detailed imaging with fetal magnetic resonance imaging (MRI).[2] Having identified fetal upper airway obstruction in advance, clinicians can plan an EXIT procedure in an attempt to improve fetal outcome. At the time of delivery, maternal-fetal circulation (uteroplacental gas exchange) is maintained while the fetus is partially delivered, allowing time to establish the fetal airway (via orotracheal intubation or tracheostomy), after which the umbilical cord can be clamped.[1] Optimal maintenance of uteroplacental support during delivery requires cesarean section with inhibition of uterine contractility.[3] With traditional cesarean section, removal of the fetus from the uterine cavity leads to uterine contraction followed by placental separation typically within 5 minutes, by which time fetal anoxic brain injury would be expected to occur if the fetal airway had not yet been established. With the EXIT procedure, the uteroplacental circulation can be maintained for approximately 60 minutes after the fetus has been removed from the uterine cavity, allowing more time to establish a fetal airway.[4] A longer duration of uteroplacental support after hysterotomy is achieved via deep maternal general anesthesia, which suppresses uterine contractility.[3] However, suppression of uterine contractility during the EXIT procedure makes maternal blood loss from the hysterotomy a significant concern.[4]

KEY OPERATIVE LEARNING POINTS

- Fetal upper airway obstruction (intrinsic structural obstruction or extrinsic compression from a neck mass) can lead to catastrophic birth.
- Fetal upper airway obstruction is typically first identified via an incidental finding on routine prenatal ultrasonography, which then leads to more detailed imaging with fetal MRI.
- If fetal upper airway obstruction is identified in advance, an EXIT procedure can be planned to improve fetal outcome.
- The key feature of the EXIT procedure is that, at the time of delivery, maternal-fetal circulation (uteroplacental gas exchange) is maintained while the fetus is partially delivered, allowing time to establish the fetal airway (orotracheal intubation or tracheostomy), after which the umbilical cord can be clamped.
- Optimal maintenance of uteroplacental support during delivery requires cesarean section with inhibition of uterine contractility.
- With traditional cesarean section, removal of the fetus from the uterine cavity leads to uterine contraction, followed by placental separation typically within 5 minutes, by which time fetal anoxic brain injury would be expected to occur if the fetal airway had not yet been established.
- With the EXIT procedure, the uteroplacental circulation can be maintained for approximately 60 minutes after the fetus has been removed from the uterine cavity, allowing more time to establish a fetal airway.
- A longer duration of uteroplacental support after hysterotomy is achieved via deep maternal general anesthesia, which suppresses uterine contractility.
- Suppression of uterine contractility during the EXIT procedure makes maternal blood loss from the hysterotomy a significant concern.

PREOPERATIVE PERIOD

History

- Maternal: Standard anesthetic history
- Ask about maternal shortness of breath or light-headedness (could suggest circulatory compromise by the gravid uterus).
- Ask about maternal severity of gastroesophageal reflux disease (GERD).
- Pregnancy history (gravida and para status, any past or current pregnancy complications)
- Fetal: Findings on prenatal imaging

Physical Examination

- Standard maternal anesthetic physical examination
- Estimated fetal weight (based on examination and ultrasound; determines dosage of fetal drugs given during the procedure)

Imaging

- Routine prenatal ultrasound provides first view of fetal neck mass.
- Giant neck mass can cause distortion and compression of the larynx and/or trachea.
- Fetal lungs produce amniotic fluid; upper airway obstruction preventing egress of this fluid results in pulmonary expansion.
- Sonographic findings suggestive of tracheal obstruction/increased intratracheal pressure include bilateral expanded lungs, flattened or everted diaphragm, and dilated airway distal to obstruction.
- Subsequent fetal MRI obtained after fetal ultrasound (determines extent of the obstructing mass, airway patency, degree of obstruction, anatomy for determining feasibility of tracheostomy)
- Serial MRI to track changes
- Assess for hydrops fetalis: Distended respiratory tree directly compresses vena cava leading to ascites, hydrops
- Assess for polyhydramnios (results from large neck mass obstructing fetal swallowing, suggests that there is probably tracheal obstruction)
- Fetal echocardiography (increased intracardiac pressure from compression from distended respiratory tree)
- Estimated fetal weight (based on examination and ultrasound; determines dosage of fetal drugs given during the procedure)
- Assess location of placenta (affects patient positioning and cesarean-section incision site).

Indications

- The need for an EXIT procedure most commonly arises when prenatal imaging demonstrates fetal airway obstruction that would not be compatible with the life of the infant after delivery.
- Congenital high airway obstruction syndrome (CHAOS) is an adverse physiologic cascade of events precipitated by complete internal obstruction of the fetal airway (common etiologies include laryngeal web, congenital subglottic stenosis, and laryngeal atresia).
- Large congenital neck mass (most common: teratoma and lymphatic malformation; others include neuroblastoma, goiter, and branchial cleft cyst) (Figs. 197.1 and 197.2)
- Congenital fetal oropharyngeal tumors (such as epignathus) or oromaxillofacial tumors (such as epulis)



Fig. 197.1. Patient with a large cervical teratoma with tracheostomy immediately after EXIT procedure. *(Reproduced with permission from Otteson TD, Hackam DJ, Mandell DL: The ex utero intraoartum treatment (EXIT) procedure. Arch Otolaryngol Head Neck Surg 2006;132:686-689.)*



Fig. 197.2. Patient with large right cervicofacial lymphatic malformation successfully intubated transorally during EXIT procedure. *(Reproduced with permission from Otteson TD, Hackam DJ, Mandell DL: The ex utero intraoartum treatment (EXIT) procedure. Arch Otolaryngol Head Neck Surg 2006;132:686-689.)*

- Severe fetal micrognathia (such as in Pierre Robin sequence, which can include micrognathia, glossoptosis, airway obstruction, and cleft palate)
- Unilateral pulmonary agenesis, severe bilateral pleural effusion
- In order to secure the airway and place vascular access in preparation for extracorporeal membrane oxygenation (ECMO) if fetus has severe congenital diaphgragmatic hernia or severe aortic stenosis/hypoplastic left heart syndrome (e.g., EXIT to ECMO)
- As a strategy for the resection of a large chest mass compressing the thoracic trachea while the fetus is on placental support
- Conjoined twins

Contraindications

- Preterm gestational age (this is a relative contraindication; if there is premature rupture of membranes/premature labor, EXIT can be performed, but the ideal time is at term)
- Maternal medical comorbidities with increased risk of general anesthesia

Preoperative Preparation

- Teamwork: A multidisciplinary team is required, including a Pediatric Anesthesiologist, Obstetric Anesthesiologist, high-risk Obstetrician (maternal-fetal medicine specialist), Pediatric Otolaryngologist, Pediatric General Surgeon, Neonatologist, Radiologist, and dedicated operating room (OR) and nursing staff.
- Serial team meetings must be held to follow at-risk patients during pregnancy.
- It is ideal for the Pediatric Otolaryngologist who is going to be involved with the procedure to meet with the parents before the time of delivery to discuss the procedure, explain the role of the otolaryngologist, and talk about the risks, benefits, and alternatives.
- It is important to have a contingency plan for management of the neonatal airway in case the EXIT procedure must be aborted and there is an emergent delivery.
- A neonatal resuscitation team is needed to receive the newborn if EXIT is successful.
- A second OR team is required if resection of a neck mass/further surgical airway access is anticipated.
- Cross-matched blood must be available for the mother and warm type O-negative blood for the fetus.

OPERATIVE PERIOD (FIG. 197.3)

Anesthesia

- Maternal
  - Deep general anesthesia (complete uterine relaxation is needed to decrease likelihood of labor during fetal manipulation and also to maintain uteroplacental circulation, preserve uterine volume, and prevent placental abruption)
  - For reflux prophylaxis, a second large-bore intravenous (IV) line is required owing to the risk of bleeding; for thromboprophylaxis, be prepared to counteract maternal hypotension, using tocolytic agents as adjuncts to encourage myometrial relaxation.
  - Place high lumbar epidural for postoperative analgesia.
  - Turn off volatile inhaled anesthetic and give oxytocin IV to induce uterine contractions (and thus help control bleeding) as soon as the umbilical cord has been clamped and the fetus delivered.

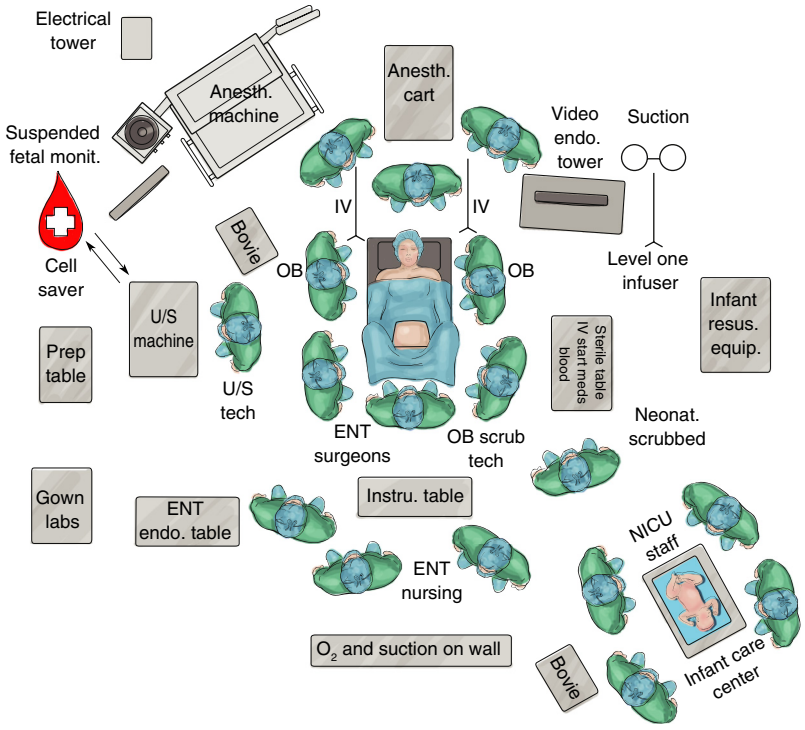

Fig. 197.3. The typical layout of a setup for an EXIT procedure.

- Fetal
  - Goal: To achieve a surgical level of fetal anesthesia without cardiac depression; maternal anesthetic agents do reach the fetus via the placenta
  - Fetal anesthesia can be supplemented by the surgical or neonatology team with a single intramuscular injection of an opioid (e.g., fentanyl) and atropine and a muscle relaxant (e.g., vecuronium).
  - Fetal IV access (24-gauge) can be obtained but should not interfere with the team establishing the airway while the fetus is on placental support.

Positioning

- Supine maternal position
- If needed, maternal positioning left side down can be considered to counteract aortocaval compression and hypotension.

Perioperative Antibiotic Prophylaxis

- First-generation cephalosporin given prior to the start of cesarean section

Monitoring

- Maternal
  - Standard monitoring (pulse oximeter, continuous electrocardiogram, core body temperature) for general anesthesia, with the addition of an arterial catheter (small changes in maternal blood pressure [BP] can have dramatic effects on fetal perfusion as well as heart rate and function) and bladder catheter
- Fetal
  - Pulse oximeter placed on upper extremity.
  - Sterile continuous intraoperative fetal echocardiography
  - If there is fetal bradycardia related to maternal or fetal bleeding/maternal hypotension, blood products should be readily available.
  - Umbilical blood gas measurement if needed

Instruments and Equipment to Have Available

- Complete set of equipment used for cesarean section (by the obstetrics team)
- Complete set of pediatric airway equipment on a sterile side table
  - Rigid neonatal laryngoscope with straight blades (i.e., Parsons laryngoscope)
  - Rigid ventilating bronchoscopes (sizes 2.5 and 3), with 0-degree neonatal telescope, sterile camera, and video tower
  - Uncuffed neonatal endotracheal tubes (sizes 2.0, 2.5, 3.0, 3.5)
  - Complete set of instruments used for neonatal tracheostomy
  - Sterile circuit with manometer on OR table to manually ventilate fetus after airway has been established

Key Anatomic Landmarks

- For cesarean section: Wide low transverse laparotomy, halfway between symphysis pubis and umbilicus
- Site for hysterotomy should be chosen 6 cm or more from marked placental edge
- For neonatal laryngoscopy: If the neck mass is unilateral, the laryngotracheal airway is often severely deviated to the contralateral side.
- For neonatal tracheostomy: Uneven retraction can easily pull the airway away from the midline, so frequent confirmation of the location of the trachea with palpation is required during the dissection.
- For neonatal tracheostomy: The cricoid cartilage and the first three tracheal rings are important landmarks.

Prerequisite Skills

- Pediatric direct laryngoscopy and rigid bronchoscopy
- Pediatric tracheostomy
- Communication skills are very important, as many people from many services will be working together to take care of both mother and fetus.

Operative Risks

- Fetal distress (from umbilical cord compression/kinking, placental separation, inadequate uterine relaxation, maternal hypotension, fetal hypothermia)
- Inability to secure a neonatal airway via endoscopic or open techniques
- Uterine atony/maternal hemorrhage (from suppression of uterine contractility)

Surgical Technique

- Obstetrical team
  - Wide low transverse laparotomy, halfway between symphysis pubis and umbilicus
  - Intraoperative sterile ultrasound used to map position and the edge of the placenta in order to plan site of hysterotomy (must be at least 6 cm away from edge of placenta)
  - Hysterotomy made with uterine stapling device (to decrease bleeding)
  - Uterine cavity filled with continuous warm crystalloid solution to maintain amniotic volume and fetal temperature (amnioinfusion)
  - Fetus only partially delivered to expose only the necessary anatomy (uterine contraction and placental separation occurs too rapidly with complete delivery)
  - Pulse oximetry and 24-gauge IV catheter placed via upper extremities of fetus
  - Continuous sterile intraoperative fetal echocardiography performed
- Pediatric Otolaryngology/surgical team
  - Attempt direct laryngoscopy and transoral endotracheal intubation (Fig. 197.4).
  - If initial intubation is unsuccessful, perform rigid bronchoscopy to assess laryngotracheal anatomy and assist intubation.
  - Can use 0-degree telescope alone or with ventilating bronchoscope (no need to ventilate as long as there is ongoing placental support)
  - Often useful to place a size 3.0-endotracheal tube over a 2.7-mm (neonatal) Hopkins rod telescope and intubate under direct visualization with the Seldinger technique
  - Armored endotracheal tube intubation can be attempted if endoscopy shows that intubation is possible.
    - If unable to intubate transorally, perform a tracheostomy (Fig. 197.5):
  - Transverse incision 1 to 2 fingerbreadths above sternal notch
  - Expose the first several proximal tracheal rings.
  - Dissect superiorly to visualize cricoid and thyroid cartilage and confirm correct location.
  - If there is time, place a vertically oriented 4.0 Neurolon suture several millimeters from each side of midline through the second and third tracheal rings (traction sutures).
  - Make a vertical midline incision with #11 or #15 blade through second and third tracheal rings (once in the lumen, turn the sharp side of the blade outward, away from the lumen, to complete the incision (to avoid harming the posterior tracheal wall)).
  - Insert neonatal tracheostomy tube, secure with shoelace cotton ties around the neck (and suture via the tracheostomy tube flanges if desired)
  - Connect Mapleson circuit to tracheostomy tube and make sure that manual bag ventilation in the field is successful by observing chest expansion and auscultated breath sounds, increases in fetal oxygen saturation, presence of end-tidal CO_2
  - Confirm correct tracheostomy tube placement with pediatric flexible fiberoptic tracheoscopy via the indwelling tracheostomy tube.
  - Surfactant is often given if the fetus has had less than 34 weeks' gestation.
  - If the neck mass is compressing the trachea too much to allow for endotracheal intubation or is impeding access to the trachea for tracheostomy, partial resection of the mass on placental support is necessary, or the mass (if cystic) can be decompressed with needle aspiration.
  - Umbilical cord is clamped and divided once the airway is secure
  - Newborn taken to incubator in the room for further evaluation and resuscitation by the neonatology team, after which the newborn is taken to the neonatal intensive care unit.



Fig. 197.4. Patient undergoing direct laryngoscopy and transoral endotracheal intubation on uteroplacental support during an EXIT procedure.



Fig. 197.5. Patient with a large cervical teratoma undergoing a tracheostomy on uteroplacental support during an EXIT procedure. *(Reproduced with permission from Otteson TD, Hackam DJ, Mandell DL: The ex utero intraoartum treatment (EXIT) procedure. Arch Otolaryngol Head Neck Surg 2006;132:686–689.)*

Common Errors in Technique

- Failing to separate maternal fluids and drugs from fetal fluids and drugs, especially during tense moments of the procedure
- Performing the hysterotomy too close to the placenta, leading to bleeding and more rapid delivery or separation of the placenta
- Ventilation of fetal lungs performed before a secure airway has been confirmed and the umbilical cord is clamped (lung ventilation leads to transition to neonatal circulation, losing the benefits of operating on placental support)

POSTOPERATIVE PERIOD

Postoperative Management

- After the placenta has been delivered, the obstetric anesthesiology team rapidly reverses uterine relaxation (giving oxytocin and decreasing the concentration of inspired volatile anesthetic), after which the obstetrical team closes the uterus and maternal abdominal wall in a similar fashion to a typical cesarean section.
- Epidural catheter dosed for maternal postoperative analgesia
- Postoperative maternal tocolysis continues with magnesium infusion, transitioned to oral nifedipine.
- Once the neonatal airway has been established and the newborn is stable, further evaluation of the infant can occur.
- For a patient with a mass in the neck, often additional imaging is obtained (computed tomography [CT], MRI, or ultrasound) prior to planning for excision.
- For a patient with severe micrognathia, a facial CT is often obtained and further treatment options are discussed, such as mandibular distraction or tracheostomy (if the patient is intubated).
- For a patient with laryngeal atresia or significant upper airway stenosis, laryngotracheal reconstruction will eventually be performed.

Complications

- Umbilical cord compression or kinking or premature separation from uterus (abruption), either from loss of amniotic fluid or from surgical manipulation: rapid deterioration of the fetus, in which case the umbilical cord may have to be divided prematurely and an immediate attempt at establishing an airway (with intubation, rigid bronchoscopy, or tracheostomy) on a side table will be needed (with intubation, rigid bronchoscopy, or tracheostomy)
- Pneumothorax during tracheostomy due to high lung apices in the neonate
- Injury to larynx, trachea, or esophagus during intubation or endoscopy
- Inability to secure a neonatal airway via endoscopic or open techniques
- Uterine atony/maternal hemorrhage (from suppression of uterine contractility)

Alternative Management Plan

- It is an option in some cases to have a normal cesarean section delivery without an EXIT procedure, with the Otolaryngology service in the delivery room ready to assist in establishing a fetal airway on the back table without uteroplacental circulation. The risk to the mother is lower with this technique but the risk of fetal death from inability to establish an airway is higher.
- In some instances, depending on the severity of fetal abnormalities, the parents may elect to not attempt heroic resuscitation measures; this decision can raise many ethical issues.

DISCUSSION

Evidence-Based Medicine Question

Research in the literature available to date suggests that indications for an EXIT procedure may include all of the following ***except:***

A. Congenital fetal oropharyngeal tumors
B. CHAOS
C. Thyroglossal duct cyst
D. Unilateral pulmonary agenesis
E. Fetal micrognathia
F. Conjoined twins

Explanation: Answers A, B, D, E, and F are all possible indications for an EXIT procedure. A thyroglossal duct cyst (answer C) does not typically cause significant enough airway obstruction to require an EXIT procedure. In addition, thyroglossal duct cysts are frequently not even detected at the time of birth.

Reference: Moldenhauer JS: Ex utero intrapartum therapy. Semin Pediatr Surg 2013, 22:44-49.

Editorial Comment

The EXIT surgical procedure described in this chapter is as complex as it is uncommon, but it is an important technique to be aware of as it can save the lives of newborns that, due to upper airway obstruction, would otherwise not survive after delivery.[1,3] The complexity arises mainly from the logistical organization needed to carry out the procedure. Each component of the multistep operation is well known (e.g., cesarean section, direct laryngoscopy and bronchoscopy, tracheostomy). What makes the EXIT procedure complex, however, is the sequential placement of all of these components and the unique adaptation of each of these steps to the dangerous and high-risk nature of the patients and their disease processes.[5] Just as important as the surgical technique is the complex organizational approach to the EXIT procedure. The degree of multidisciplinary coordination and teamwork required for a successful EXIT procedure can be daunting and may be the most unique aspect of this challenging procedure. Although it may be difficult to orchestrate, the end result often leads to a remarkably euphoric sense of accomplishment for all parties involved and, most importantly, a life potentially saved.

David Mandell

Access the review questions list online at http://www.expertconsult.com



REFERENCES

1. Moldenhauer JS. Ex utero intrapartum therapy. Semin Pediatr Surg 2013;22:44–49.
2. Laje P, Howell LJ, Johnson MP, et al. Perinatal management of congenital oropharyngeal tumors: the ex utero intrapartum treatment (EXIT) approach. J Pediatr Surg 2013;48:2005–2010.
3. Lin EE, Tran KM. Anesthesia for fetal surgery. Semin Pediatr Surg 2013;22:50–55.
4. Taghavi K, Beasley S. The ex utero intrapartum treatment (EXIT) procedure: application of a new therapeutic paradigm. J Paediatr Child Health 2013;49(9):E420–427.
5. Otteson TD, Hackam DJ, Mandell DL. The ex utero intrapartum treatment (EXIT) procedure: new challenges. Arch Otolaryngol Head Neck Surg 2006;132:686–689.

REVIEW QUESTIONS

1. From the maternal standpoint, the EXIT procedure requires all of the following key features ***except:***
   a. Deep maternal general anesthesia
   b. Maintenance of uterine tone to prevent maternal bleeding
   c. Use of a stapler device for hysterotomy
   d. Placement of high lumbar epidural catheter

2. Prenatal imaging characteristics that indirectly suggest fetal upper airway obstruction include
   a. Fetal pulmonary hypoplasia
   b. Collapse of the distal airway lumen
   c. Everted diaphragms
   d. Decreased intracardiac pressure

3. During an EXIT procedure, it important to perform which of the following steps regarding the fetus after hysterotomy:
   a. Fetal injection of IM opioid
   b. Fetal electroencephalography
   c. Placement of a fetal arterial line
   d. Delivery of as much of the fetus and the umbilical cord will allow

4. While on uteroplacental support, all of the following fetal procedures can be performed ***except:***
   a. Placement of a catheter for extracorporeal membrane oxygenation
   b. Excision of large neck or chest masses
   c. Fetal bronchoscopy
   d. Congenital diaphragmatic hernia repair

5. Common causes of CHAOS include
   a. Laryngeal atresia
   b. Cervical teratoma
   c. Cervical lymphatic malformation
   d. Severe micrognathia

198 Tracheoscopy, Bronchoscopy, and Airway Foreign Bodies

Jeffrey P. Simons, Sukgi Choi

INTRODUCTION

Rigid tracheoscopy and bronchoscopy are important methods for evaluating the airway in infants and children. During this procedure, a rigid telescope with or without a rigid ventilating bronchoscope is inserted transorally to evaluate the larynx, trachea, and bronchi. Rigid tracheoscopy and bronchoscopy can be both diagnostic and therapeutic, because a variety of airway abnormalities can be discovered and treated.[1] Instruments such as optical forceps, nonoptical instruments, lasers, and balloons can be passed through the bronchoscope to treat a variety of different airway conditions. It is important for all Otolaryngologists to be familiar with the instruments and techniques required for rigid tracheoscopy and bronchoscopy.

Flexible fiberoptic bronchoscopy is another technique used to evaluate the airway in infants and children; this procedure is more commonly performed by Pulmonologists. Rigid airway endoscopy and flexible bronchoscopy can be complementary methods to evaluate the airway in children. Each technique has its own indications, but they are sometimes performed together.

Foreign bodies of the airway can lead to significant morbidity and mortality in children. They are the fourth most common cause of accidental death in toddlers, accounting for about 3000 deaths per year in the United States.[2-4] Aspiration of foreign bodies occurs most commonly in children younger than 5 years of age.[2-4] Foreign bodies of the airway must be in the differential diagnosis in this age group for all nonspecific pulmonary symptoms, such as coughing and wheezing. Approximately half of the patients with foreign bodies of the airway do not have a history of a witnessed foreign body aspiration event.[5] Therefore, clinical history, physical examination, and radiologic studies are important tools to help determine which patients should undergo bronchoscopy.[5] Prompt diagnosis of aspiration of a foreign body and its removal using rigid bronchoscopy are critical in preventing morbidity and mortality.

KEY LEARNING POINTS

- Rigid tracheoscopy and bronchoscopy are important methods for evaluating the airway in infants and children; it is important for all Otolaryngologists to be familiar with these techniques.
- Rigid tracheoscopy and bronchoscopy can be performed with a Hopkins rod telescope alone or with a rigid ventilating bronchoscope (which can also have a Hopkins rod telescope to improve visualization).
- Tracheoscopy and bronchoscopy can be used to diagnose and treat a variety of abnormalities involving the larynx, trachea, and bronchi.
- Flexible bronchoscopy can be a useful technique in evaluating certain airway abnormalities in children, particularly abnormalities involving the more distal airway.
- For rigid airway endoscopy, the Hopkins rod telescope or bronchoscope is typically introduced through direct laryngoscopy.
- Rigid bronchoscopy is an important technique for the diagnosis and treatment of foreign bodies of the airway in children.
- Foreign bodies of the airway can lead to significant morbidity and mortality in children, and delay in diagnosis can increase the risk of complications.
- Aspiration of the foreign body occurs most commonly in children younger than 5 years of age.
- The most common foreign bodies of the airway are food products (nuts and seeds), followed by pieces of plastic toys, and then metal objects.
- The most common site for foreign bodies of the airway is the right main stem bronchus.

PREOPERATIVE PERIOD

History

- History of previous surgeries, including previous direct laryngoscopy and rigid bronchoscopy procedures, previous airway surgery, or history of tracheotomy
- History of endotracheal intubation or a stay in the intensive care unit
- Ask about personal or family history of problems with anesthesia.
- History of abnormalities of the spine, spine surgery, or abnormalities of the brain
- History of stridor or stertor: inspiratory, expiratory, or biphasic; duration; severity; exacerbating or mitigating factors
- History of witnessed aspiration of a foreign body
- History of coughing, choking, gagging, dyspnea, respiratory distress, wheezing, hoarseness, or dysphagia
- Only about 50% of patients with aspiration of a foreign body have a witnessed aspiration event.[5]

Physical Examination

- Standard anesthesia physical examination
- Ability of the patient to extend the neck
- Ability of the patient to open the mouth and expose oropharynx to enable direct laryngoscopy, which is important for the introduction of a rigid telescope or a rigid ventilating bronchoscope

- Mallampati classification can be used to predict ease of direct laryngoscopy.
- Patients with a foreign body of the larynx can have hoarseness, aphonia, respiratory distress, or significant stridor.
- Patients with a foreign body of the trachea may present with the classic physical examination triad of an audible slap (impact of mobile foreign body against the wall of the trachea), palpable thud over the trachea, or asthmatoid wheeze over the trachea.[2]
- Patients with a foreign body of the bronchi may have wheezing and decreased air entry with decreased breath sounds on the obstructed side.[2]
- 5% to 40% of patients who have a foreign body have no obvious findings on physical examination.[2,3,5]

Imaging

- Radiographs of the cervical spine in flexion and extension should be obtained in children with Down syndrome or other disorders with concern for instability of the cervical spine, although the diagnostic accuracy of this technique has been debated.[6,7]
- Patients with significant respiratory distress should not be taken to radiology for imaging prior to undergoing airway endoscopy in the operating room.
- Most foreign bodies of the airway are radiolucent (about 80%).
- Posteroanterior (PA) and lateral chest radiographs in the inspiratory and expiratory phase can be obtained in the assessment of patients with possible foreign body aspiration. Air trapping on the side of a foreign body is the most common abnormal radiographic finding in patients with a foreign body of the airway; this finding can be accentuated in the expiratory phase.[5]
- In patients who are unable to cooperate with inspiratory and expiratory phase radiographs, lateral decubitus radiographs can be obtained. In lateral decubitus films, air trapping can be seen when the foreign body side is dependent ("down").
- PA and lateral neck radiographs can sometimes reveal evidence of a foreign body of the larynx or subglottis.
- The most common radiographic abnormalities in patients with aspiration of a foreign body include air trapping or hyperinflation and atelectasis (Fig. 198.1).
- About 40% of patients with a foreign body of the airway have a completely normal chest radiographs.[3,5]

Indications

- Rigid tracheoscopy and bronchoscopy are used to evaluate the airway in infants and children with a variety of conditions; these techniques can be both diagnostic and therapeutic.
- Almost all children with biphasic or expiratory stridor require evaluation via rigid airway endoscopy in the operating room.
- Children with isolated inspiratory stridor can often be evaluated first in the office via flexible fiberoptic nasolaryngoscopy; however, if laryngomalacia or another etiology for the inspiratory stridor is not seen on flexible laryngoscopy, these patients also should undergo rigid airway endoscopy in the operating room to evaluate the entire airway.
- The rigid ventilating bronchoscope can be used as a tool to secure the airway in patients with significant airway obstruction who cannot be intubated with an orotracheal tube by traditional techniques.
- Patients with suspected aspiration of a foreign body should undergo rigid tracheoscopy and bronchoscopy for diagnosis and, if present, treatment of the foreign body.
- Patients with subglottic or tracheobronchial pathology such as a stricture, web, or granulation tissue can undergo rigid tracheoscopy and bronchoscopy and subsequent endoscopic treatment of the abnormalities with lasers, balloon dilation, optical instruments, and/or injection of steroids.
- Infants and children with chronic tracheostomy dependence often undergo interval rigid airway endoscopy for surveillance of complications of the tracheostomy tubes, such as suprastomal granulation tissue or tracheal erosion at the tip of the cuff of the tracheostomy tube.
- Patients with acute bacterial tracheitis often must undergo rigid tracheoscopy and bronchoscopy for débridement of thick mucopurulent secretions and desquamated epithelium.
- Patients with plastic bronchitis often require rigid airway endoscopy for débridement of obstructing bronchial casts. This relatively rare disorder, characterized by obstruction of the large airways by thick mucus plugs and bronchial casts, can occur in patients with asthma, cystic fibrosis, sickle cell disease with acute chest syndrome, and cyanotic congenital heart disease following palliation surgery.[8]
- Flexible bronchoscopy provides improved visualization of the distal airway.
- There are a variety of indications for flexible bronchoscopy, including chronic cough, recurrent pneumonia, unexplained or persistent wheezing, and hemoptysis.

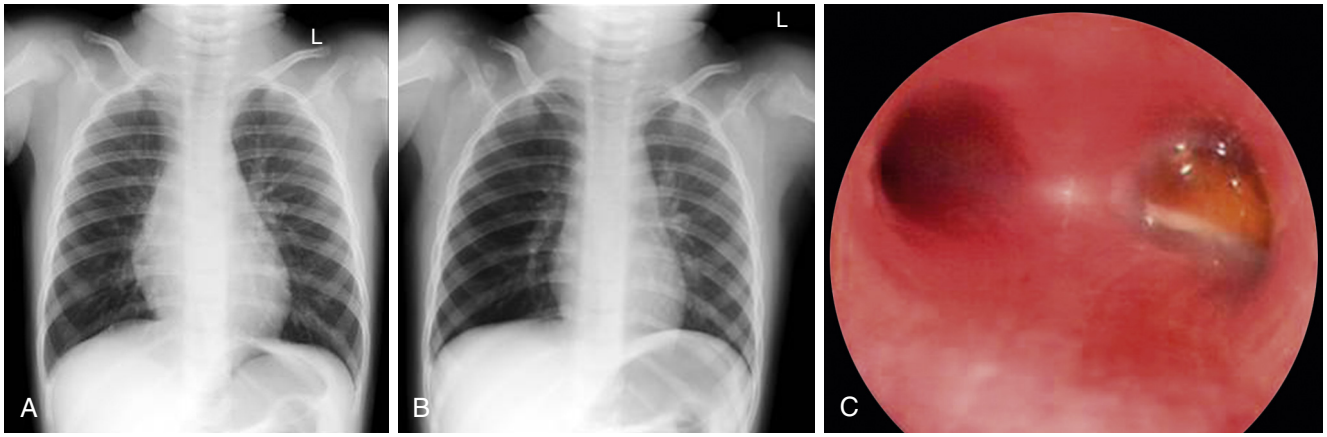

Fig. 198.1. Inspiratory, **A,** and expiratory, **B,** chest radiographs of a patient with an almond in the right main stem bronchus, demonstrating air trapping and hyperinflation of the right lung. **C,** Endoscopic view of the almond in the right main stem bronchus.

Contraindications

- Multiple medical comorbidities or medically fragile patients at significant increased risk for anesthesia (relative contraindication)
- Inability to extend the neck due to cervical spine instability, cervical spine fusion, or diseases involving the cranio-cervical junction (such as severe Chiari malformation) make rigid airway endoscopy challenging.
- Ankylosis of the temporomandibular joints or other abnormalities of the oral cavity and oropharynx, making direct laryngoscopy very difficult; flexible bronchoscopy can be an alternative in these patients

Preoperative Preparation

- History, physical examination, and imaging studies as descri bed above
- Discussion of risks and benefits with patient and family. Risks of procedure include injury to the teeth, injury to the aerodigestive tract, inability to successfully remove a foreign body, and the possible need for open surgery.

OPERATIVE PERIOD

Anesthesia

- Careful communication between the surgeon and anesthesiologist in airway endoscopy cases is critical.
- Avoid preoperative sedation in patients with stridor or a potential foreign body in the airway.
- In infants and children, induction is often performed with an inhalational anesthetic agent if there is not already intravenous access. Intravenous access should then be obtained prior to beginning the procedure.
- With a rigid ventilating bronchoscope, the patient can be ventilated, and oxygen and anesthetic gas can be administered through the bronchoscope. If there is a large leak around the bronchoscope, consideration should be given to turning off the anesthetic gas and using intravenous agents at that point, to prevent significant escape of anesthetic gas into the operating room environment.
- When there is a potential foreign body of the airway, spontaneous ventilation is preferred over an apneic technique.
- In a patient with a foreign body of the airway, it is ideal to avoid too much positive pressure ventilation to help prevent the foreign body from being displaced more distally in the airway.
- The initial laryngoscopy in a patient with a foreign body of the airway should ideally be performed by the endoscopist rather than the anesthesiologist in case a foreign body is encountered in the larynx.

Positioning

- Patients are positioned supine on the operating table.
- For rigid airway endoscopy in infants and children, the head is extended, and a shoulder roll is placed.
- The head is typically placed in a gel ring to help stabilize it.

Perioperative Antibiotic Prophylaxis and Steroid Administration

- Antibiotic prophylaxis is not typically necessary for routine bronchoscopy and tracheoscopy procedures or for most foreign bodies of the airway, unless there is concern for an infection secondary to the foreign body.
- A dose of intravenous steroids is typically given at the beginning of the airway endoscopy procedure to help prevent or decrease edema of the airway and to help prevent postoperative nausea and vomiting.

Monitoring

- Standard monitoring (pulse oximeter, continuous electrocardiogram, core body temperature) for general anesthesia
- In rare instances when there is concern for instability of the cervical spine, after consultation with Neurosurgery, the head can be positioned and the procedure performed with somatosensory evoked potential (SSEP) monitoring. However, in these cases it is also important to limit head extension and to keep the neck in as neutral a position as possible.

Instruments and Equipment to Have Available

- Laryngoscope (either Philips or Miller laryngoscope from anesthesiology or Parsons laryngoscope). It is important to have an age-appropriate size.
- Hopkins rod telescope (0 degree)
- Rigid ventilating bronchoscopes with a 0-degree Hopkins rod telescope, camera, and video tower (Fig. 198.2)
- Rigid laryngeal and tracheal suction catheters
- Flexible suction catheters to fit through the side port of the bronchoscope
- Optical forceps (alligator, peanut, and cup) (see Fig. 198.2)
- Nonoptical forceps (forward grasping, rotation, globular object, hollow object) (see Fig. 198.2)
- Fogarty catheters for difficult distal foreign bodies
- Ureteral baskets for difficult distal foreign bodies
- Flexible fiberoptic bronchoscope

Key Anatomic Landmarks

- For direct laryngoscopy, the base of the tongue, vallecula, epiglottis, arytenoids, and true vocal folds are identified.
- For rigid bronchoscopy, the subglottis, trachea, carina, main stem bronchi, and lobar bronchi are important landmarks.

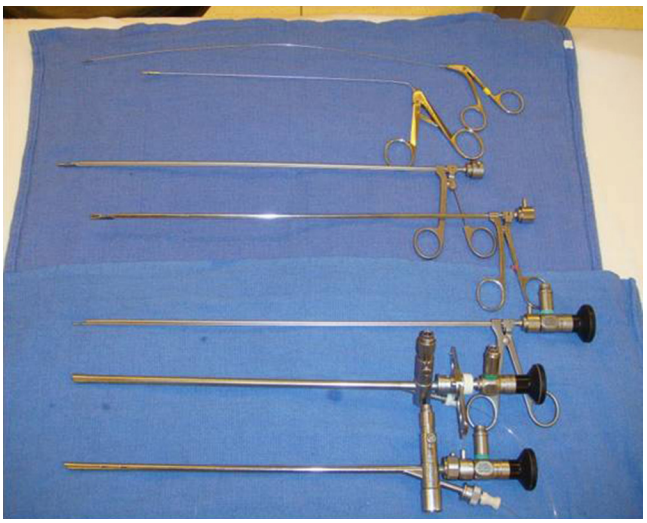

Fig. 198.2. Rigid bronchoscope, optical forceps, and nonoptical forceps used for rigid tracheoscopy and bronchoscopy with foreign body removal.

- For transnasal flexible fiberoptic bronchoscopy, the nasal cavity, nasopharynx, soft palate, epiglottis, arytenoids, and true vocal folds are visualized in passing the bronchoscope into the trachea.

Prerequisite Skills

- Direct laryngoscopy and flexible laryngoscopy in the pediatric age group
- Tracheostomy in the pediatric age group

Operative Risks

- Injury to the teeth
- Injury to the pharynx, larynx, trachea, or bronchi
- Bleeding into the airway
- Pneumothorax or pneumomediastinum
- Inability to remove the foreign body, requiring repeat endoscopy, thoracoscopy, or thoracotomy

Surgical Technique

Rigid Diagnostic Tracheoscopy and Bronchoscopy

- A tooth guard is inserted to protect the maxillary dentition. If there are no upper teeth, a moist gauze sponge is used.
- A direct laryngoscopy is performed with an anesthesia (i.e., Miller or Phillips) laryngoscope or otolaryngologic (i.e., Parsons) laryngoscope.
- The laryngoscope is inserted along the right side of the tongue, and the tongue is displaced to the left.
- The tip of the laryngoscope blade is then placed into the vallecula, and the epiglottis, arytenoids, and vocal folds are identified.
- A defogging solution is typically used to prevent condensation and clouding of the lens of the telescope.
- The telescope or rigid bronchoscope is then introduced transorally, and the oropharynx, hypopharynx, and larynx are examined (Fig. 198.3).
- The telescope or rigid bronchoscope is then advanced through the glottis. If a rigid bronchoscope is used, it should be advanced using the following technique:
  - The bronchoscope is turned 90 degrees counterclockwise to align the leading edge of the tip of the bronchoscope in a plane with the true vocal folds.
  - The tip of the bronchoscope is then passed beyond the true vocal folds and then rotated 90 degrees clockwise once the tip is in the subglottis.
  - This technique is used to avoid injury to the true vocal folds or vocal processes of the arytenoids by the tip of the bronchoscope (Fig. 198.4).
- Once the tip of the bronchoscope is in the trachea, the laryngoscope is removed, and the bronchoscope is supported by the thumb and forefinger to help protect the upper gingiva and teeth (Fig. 198.5).
- If the Hopkins rod is used for the bronchoscopy without a rigid bronchoscope, the laryngoscope is typically kept in place, and the Hopkins rod is advanced to examine the trachea and bronchi.
- The rigid bronchoscope has a port for connection to the anesthesia circuit, and the patient can be ventilated through the bronchoscope. This aspect of the rigid bronchoscope allows it to be used to establish an airway in an emergent or difficult airway situation.
- The trachea, carina, and bronchi are examined with the telescope or rigid bronchoscope.

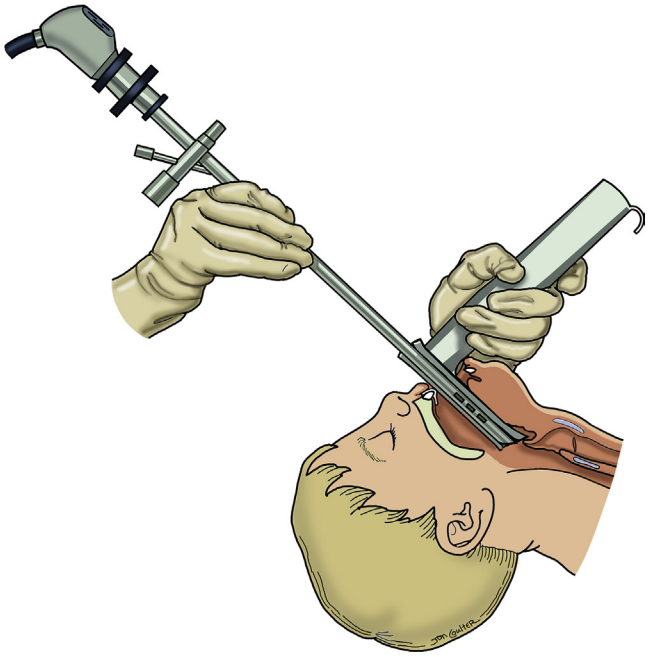

Fig. 198.3. The proper method for inserting a rigid bronchoscope after performing a direct laryngoscopy is demonstrated. The laryngoscope is inserted along the right side of the tongue, and the tongue is displaced to the left. The tip of the laryngoscope blade is then placed in the vallecula and the epiglottis, arytenoids, and vocal folds are identified. The telescope or rigid bronchoscope is then introduced transorally, and the oropharynx, hypopharynx, and larynx are examined.

- To examine the right main stem and lobar bronchi, the patient's head is turned to the left, and the tip of the bronchoscope is rotated clockwise.
- To examine the left main stem and lobar bronchi, the patient's head is turned to the right, and the tip of the bronchoscope is rotated counterclockwise.
- Secretions can be removed through a long, rigid metal suction that fits through the main channel of the bronchoscope or through a flexible suction catheter that fits through the side port of the bronchoscope.

Flexible Bronchoscopy

- In children, this procedure is typically performed under general anesthesia.
- A flexible fiberoptic bronchoscope can be advanced transnasally, through the pharynx, and passed through the glottis into the trachea and bronchi.
- The flexible fiberoptic bronchoscope can also be passed through a laryngeal mask (LMA), endotracheal tube, or tracheostomy tube.
- Care must be taken to select a proper size bronchoscope that will fit through the LMA, endotracheal tube, or tracheostomy tube.
- Silicone lubricant is applied to the bronchoscope to facilitate passage through the LMA, endotracheal tube, or tracheostomy tube.
- A right-angled ventilation adaptor with a perforated rubber diaphragm can be placed on the LMA, endotracheal tube, or tracheostomy tube to allow the patient to be ventilated while the bronchoscope is in place.
- Topical lidocaine is applied to the vocal folds and carina through the side port of the bronchoscope.

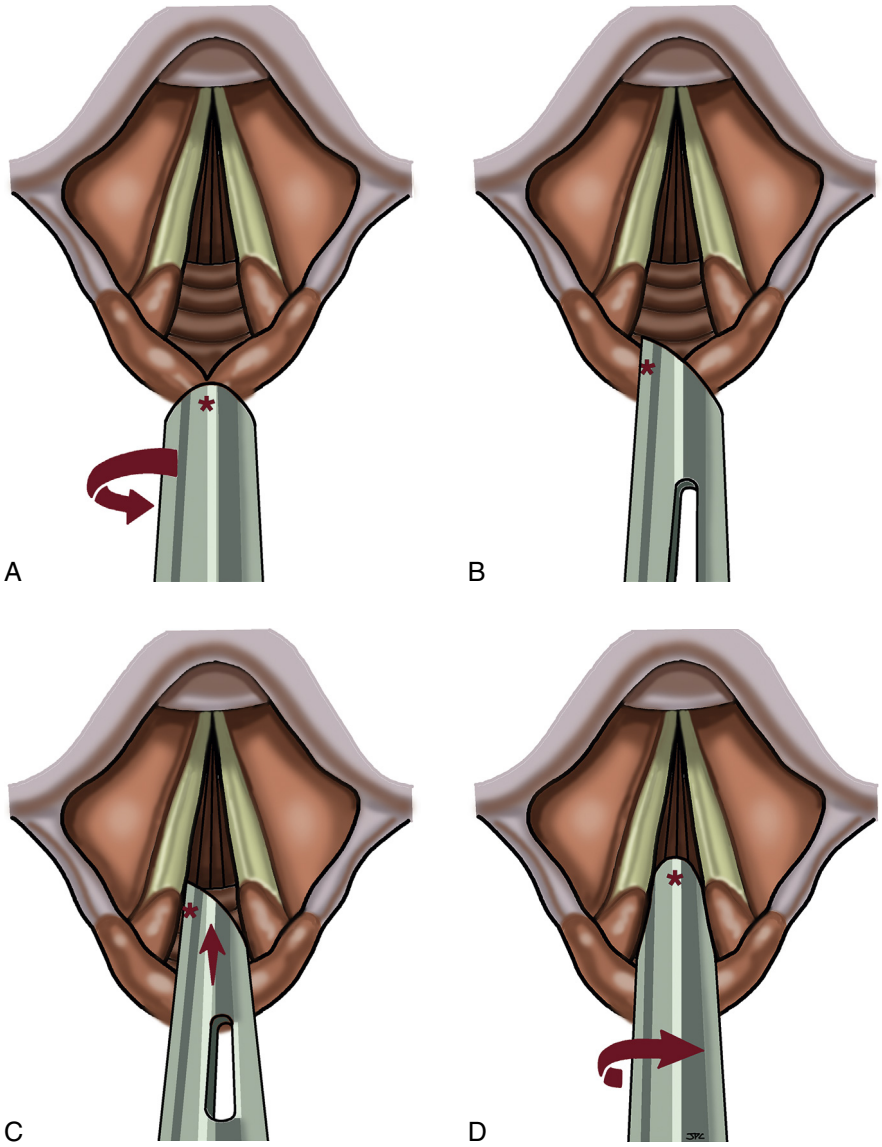

Fig. 198.4. Four-part illustration demonstrating the correct technique for advancing the rigid bronchoscope beyond the subglottis to avoid injury to the true vocal folds or vocal processes of the arytenoids. The bronchoscope is turned 90 degrees counterclockwise to align the leading edge of the tip of the bronchoscope* in a plane with the true vocal folds, **A** and **B**. The tip of the bronchoscope is then passed beyond the true vocal folds, **C,** and then rotated 90 degrees clockwise once the tip is in the subglottis, **D**.

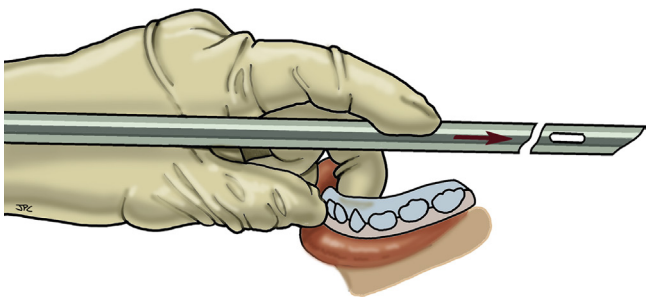

Fig. 198.5. Once the tip of the bronchoscope is in the trachea, the laryngoscope is removed and the bronchoscope is supported by the thumb and forefinger to help protect the upper gingiva and teeth.

- A broncho-alveolar lavage can be performed through the side port of the flexible bronchoscope.
- Flexible bronchoscopy can be very useful in the diagnosis of airway abnormalities, particularly of the lower airway.
- Some therapeutic procedures, such as treatment with lasers, can be performed through a flexible bronchoscope.
- Flexible bronchoscopy is not typically a good technique for removing airway foreign bodies but may be an adjunct to rigid bronchoscopy for difficult distal foreign bodies.

Removal of a Foreign Body from the Airway

- Rigid bronchoscopy is the first-line therapy for all foreign bodies of the tracheobronchial tree; the technique can be both diagnostic and therapeutic.
- Rigid bronchoscopy is required when there is any suspicion of a foreign body of the airway; the technique should be

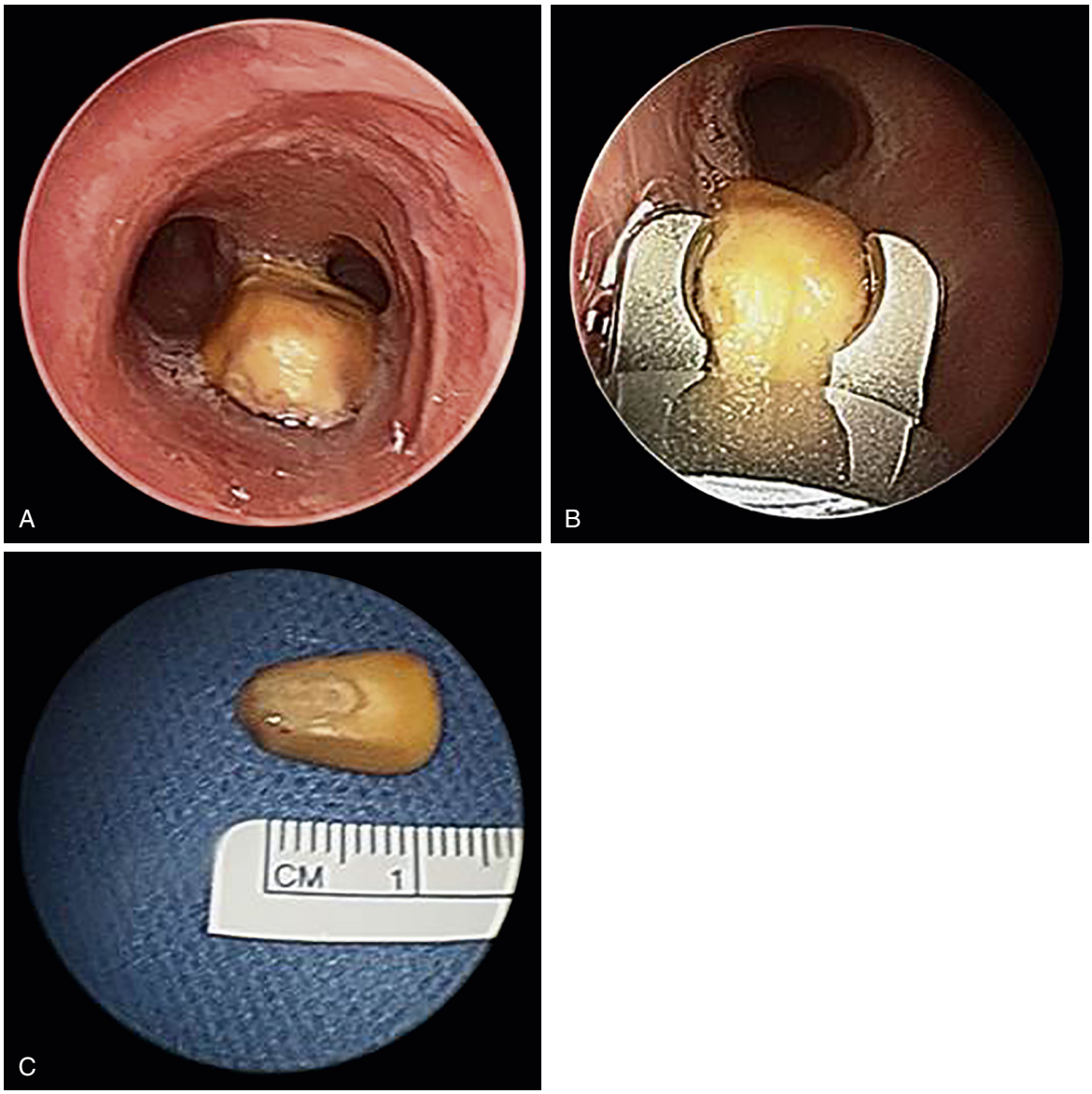

Fig. 198.6. A, Endoscopic view of a foreign body (dry corn kernel) in the distal trachea. **B,** The corn kernel is carefully grasped and removed with an optical peanut forceps. **C,** Corn kernel once removed from the airway.

strongly considered when the history, physical examination, or radiologic studies (any of the three) suggest a possible foreign body.

- It is ideal to have an experienced endoscopist, Anesthesiologist, and OR team.
- Obtaining a duplicate foreign body from the caregivers can be very helpful in planning removal.
- Secretions are suctioned, and the shape and position of the foreign body are carefully assessed.
- Attempts should be made to protect sharp objects within the bronchoscope or to allow their points to trail, to minimize injury to the mucosa.
- Care must be taken to avoid pushing the foreign body more distally.
- If possible, the foreign body should be rotated into the sagittal plane, which has the largest laryngeal diameter.
- The choice of instruments used through the bronchoscope depends upon the type of object aspirated. For example, peanuts and other nuts are often best grasped with optical peanut forceps. Sharp objects are often best managed with alligator forceps (Figs. 198.6 and 198.7).
- The foreign body should be carefully grasped under direct visualization with a Hopkins rod telescope through the bronchoscope.
- If the foreign body will fit into the sheath of the bronchoscope, it is safest to remove the foreign body, forceps, and bronchoscope *en bloc*, to help prevent the foreign body from getting stuck at the glottis, shearing off and moving distally, or lacerating the mucosa.
- If there is bleeding or granulation tissue around the foreign body, a vasoconstrictive agent such as oxymetazoline can be instilled.
- If the foreign body becomes dislodged in the subglottis or trachea during extraction and airway obstruction occurs, it may be easier to push the object back into the right main stem bronchus to allow ventilation before attempting to remove the foreign body again.

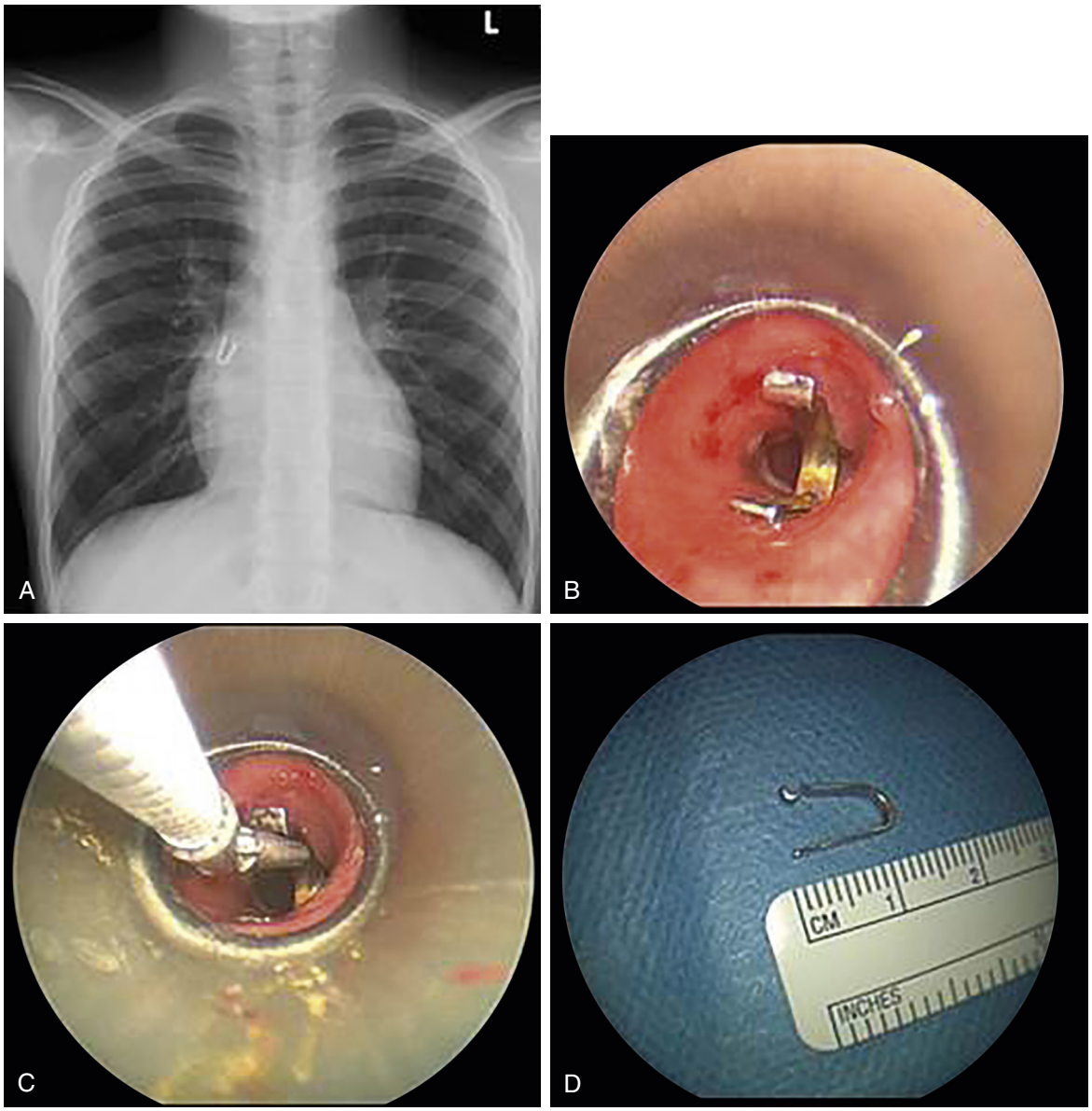

Fig. 198.7. A, Chest radiograph demonstrating a radiopaque foreign body (pen clip) in the right main stem bronchus. **B,** Endoscopic view of pen clip in right main stem bronchus. **C,** Metal pen clip is carefully grasped and removed with an alligator forceps. **D,** Metal pen clip once removed from the airway.

- A repeat rigid bronchoscopy should be performed once the foreign body is removed to evaluate for any injury or possible additional foreign bodies.
- If the entire foreign body cannot be removed because there is too much bleeding, edema, or granulation tissue present, the surgeon should safely remove as much of the foreign body as possible, observe the patient in the hospital for a few days on antibiotics and steroids, and then take the patient back to the operating room for another attempt at foreign body removal, once the inflammation has subsided.

Common Errors in Technique

- Failing to properly prepare for the removal of a foreign body of the airway, including carefully checking equipment before the procedure
- Hastily grasping the foreign body, causing it to break into pieces or migrate distally
- Allowing the foreign body to become dislodged at the glottis/subglottis, leading to airway obstruction
- Failing to recognize that a foreign body was incompletely removed or that there is residual foreign body or an additional foreign body present

POSTOPERATIVE PERIOD

Postoperative Management

- Diagnostic rigid bronchoscopy can be performed as an inpatient or ambulatory procedure depending on the indications and age of the patient.
- Most patients under 6 months of age should be observed overnight with continuous pulse oximetry after rigid airway endoscopy to ensure that edema after instrumenting an already small airway does not lead to airway obstruction.
- Children with underlying significant airway abnormalities are often also observed overnight after rigid airway endoscopy,

either in the ICU or on a regular floor, depending on the severity of their airway problems.
- Most children are observed overnight in the hospital after removal of a foreign body, although older children and adolescents with an otherwise normal airway can sometimes be discharged the same day after removal of the foreign body.
- A postoperative chest radiograph should be obtained after removal of a foreign body, particularly when there is any potential concern for complications such as pneumothorax, pneumomediastinum, or atelectasis.
- After removal of a foreign body, bronchodilators such as albuterol can be given when there is concern for bronchospasm.
- Several doses of corticosteroids can be administered after removal of a foreign body of the airway when significant edema of the airway is present.
- A course of antibiotics is often prescribed after removal of a foreign body, particularly if the foreign body has been present for a long period of time and there is suspicion for infection.

Complications

- See "Operative Risks" section for intraoperative complications.
- Early postoperative complications include atelectasis, wheezing, stridor, edema of the larynx, traumatic laryngitis, pneumonia, post-obstructive pulmonary edema, pneumothorax, pneumomediastinum, and lung abscess.
- Late postoperative complications include formation of a broncho-pleural fistula, stricture, and laryngotracheal stenosis.

Alternative Management Plan

- Rigid bronchoscopy is the first-line and criterion-standard therapy for the diagnosis and treatment of foreign bodies of the tracheobronchial tree.
- Radiographic studies may be useful but are not sufficiently sensitive or specific alone to predict the presence of an airway foreign body.
- Computed tomography (CT) scanning with or without "virtual bronchoscopy" can be useful in diagnosing some challenging or unusual foreign bodies of the airway.
- There are no good alternatives to rigid airway endoscopy for the initial management of foreign bodies of the airway.
- Rarely, a foreign body of the airway cannot be removed endoscopically, and a thoracotomy or thoracoscopic approach is necessary.

DISCUSSION

Evidence-Based Medicine Question

The current literature suggests that all of the following are indications for rigid tracheoscopy and bronchoscopy EXCEPT:

A. Suspected foreign body aspiration
B. Subglottic web or stricture
C. Inspiratory stridor from laryngomalacia
D. Tracheostomy dependence with obstructing suprastomal granuloma
E. Unexplained biphasic stridor
F. Plastic bronchitis

Explanation: Answers A, B, D, E, and F are all indications for rigid tracheoscopy and bronchoscopy. Laryngomalacia (answer C) is typically diagnosed with flexible fiberoptic laryngoscopy in the office or at the bedside and does not usually require rigid airway endoscopy as part of the diagnosis, unless there are airway symptoms that are out of proportion to or inconsistent with the degree of laryngomalacia seen on flexible laryngoscopy.[1,9]

Editorial Comment

It is important for all Otolaryngologists to be familiar with the techniques of rigid tracheoscopy and bronchoscopy. These procedures are very important in the diagnosis and treatment of many airway disorders in infants and children.[1] Almost all children with biphasic or expiratory stridor should be evaluated using rigid tracheoscopy and bronchoscopy under general anesthesia.[1] Rigid bronchoscopy can also be a very useful method in establishing an emergent airway in patients with significant airway obstruction who cannot be intubated by traditional techniques. Flexible bronchoscopy is often performed by Pediatric Pulmonologists and can be a complementary technique to rigid airway endoscopy for evaluation of the airway in the pediatric age group.

Rigid airway endoscopy is the criterion standard for the management of foreign bodies of the airway, which can lead to significant morbidity and mortality in children.[2-5] A variety of techniques and instruments can be used working through a rigid bronchoscope to extract foreign bodies of the airway. Although history, physical examination, and radiographic findings are important in the evaluation of a child with possible aspiration of a foreign body, there needs to be a high index of suspicion and a low threshold for rigid endoscopy to optimize outcomes.

Jeffrey P. Simons

Access the review questions and additional sources list online at http://www.expertconsult.com

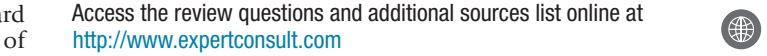

REFERENCES

1. Chan KH, Friedman N, Polaner DM, Riding KH, Stool SE. Endoscopy of the upper aerodigestive tract. In: Bluestone CD, Rosenfeld RM, editors. Surgical Atlas of Pediatric Otolaryngology. Hamilton, Ontario: BC Decker, Inc; 2002. p. 555–583.
2. Darrow DH, DeMarcantonio MA. Foreign bodies of the larynx, trachea, and bronchi. In: Bluestone CD, Simons JP, Healy GB, editors. Bluestone and Stool's Pediatric Otolaryngology. 5th ed. Shelton, CT: PMPH-USA; 2014. p. 1609–1625.
3. Digoy GP. Diagnosis and management of upper aerodigestive tract foreign bodies. Otolaryngol Clin North Am 2008;41:485–496.
4. Shah RK, Patel A, Lander L, Choi SS. Management of foreign bodies obstructing the airway in children. Arch Otolaryngol Head Neck Surg 2010;136:373–379.
5. Sink JR, Kitsko DJ, Georg MW, Winger DG, Simons JP. Predictors of foreign body aspiration in children. Otolaryngol Head Neck Surg 2016;155(3):501–507.
6. Abramson PJ, Todd NW, Holt PJ, Allen AT, Hayden GB. Neck flexion and extension in children with Down syndrome: a somatosensory study. Laryngoscope 1995;105:1209–1212.
7. Hankinson TC, Anderson RCE. Craniovertebral junction abnormalities in Down syndrome. Neurosurgery 2010;66:A32–8.
8. Silva RC, Simons JP, Chi DH, Yellon RF, Alper CM. Endoscopic management of plastic bronchitis. Arch Otolaryngol Head Neck Surg 2011;137:401–403.
9. Thompson DM. Abnormal sensorimotor integrative function of the larynx in congenital laryngomalacia: a new theory of etiology. Laryngoscope 2007;117(Suppl. 114):1–33.

REVIEW QUESTIONS

1. The most common site for an airway foreign body is the:
   a. Trachea
   b. Right main stem bronchus
   c. Glottis
   d. Left main stem bronchus

2. The best method to evaluate a child with biphasic stridor is:
   a. In the office with flexible fiberoptic laryngoscopy
   b. In the operating room with flexible bronchoscopy
   c. In the operating room with rigid tracheoscopy and bronchoscopy
   d. In the radiology suite with fluoroscopy

3. Which of the following is a contraindication for rigid bronchoscopy?
   a. Age under 3 months
   b. Stridor and respiratory distress
   c. History of previous tracheotomy
   d. Inability to extend the neck due to instability of the cervical spine

4. Which of the following is the most common abnormality seen on chest radiographs in patients with aspiration of a foreign body?
   a. Air trapping/hyperinflation
   b. Radiopaque foreign body
   c. Widening of the mediastinum
   d. Mediastinal shift toward the side of the foreign body

5. All of the following are potential *early* postoperative complications after removal of a foreign body, except
   a. Edema of the larynx
   b. Post-obstructive pulmonary edema
   c. Pneumothorax
   d. Stricture formation

ADDITIONAL SOURCES

Jackson C, Jackson CL. Diseases of the Air and Food Passage of Foreign Body Origin. Philadelphia, PA: WB Saunders Co.; 1936.

Reilly BK, Stool D, Chen X, Rider G, Stool SE, Reilly JS. Foreign body injury in children in the twentieth century: a modern comparison to the Jackson collection. Int J Pediatr Otorhinolaryngol 2003;67(S1):S171–174.

199 Management of Tracheal Stenosis

Carlton J. Zdanski, Jonathan Walsh

INTRODUCTION

Pediatric tracheal stenosis is the clinical presentation of a diverse and complex spectrum of disease processes. Etiologies range from iatrogenic injury, trauma, infection, congenital malformations, neoplasms, gastroesophageal reflux disease (GERD), autoimmune processes, and granulomatous diseases. Classification is necessary in order to better define the stenosis and the spectrum of causes and to determine appropriate management. Stenosis can be classified as acquired versus congenital, intraluminal versus cartilaginous framework versus extrinsic compression, and short versus long segment.

The pathogenesis of acquired stenosis includes injury to the tracheal lining or its cartilaginous framework, resulting in scarring or loss of support. The laryngotracheal cartilaginous framework depends on the perichondrium for its blood supply. Ischemic cartilage can lose its mechanical integrity and collapse, thereby leading to a functional stenosis. Furthermore, exposed cartilage deprived of its blood supply can necrose rapidly and act as a foreign body; the ensuing inflammatory reaction causes further tissue destruction and scarring. This injury can result in a variety of stenoses ranging in severity from thin tracheal webs to severe long-segment stenosis.[1,2]

Congenital tracheal stenosis (CTS) results from tracheomalacia, external vascular compression or rings, tracheal hypoplasia, funnel stenosis, segmental stenosis, complete tracheal rings, and tracheal agenesis. Cantrell and Guild[3] first described intrinsic congenital tracheal stenoses and classified them into three morphologic types: (1) generalized hypoplasia, (2) funnel stenosis, and (3) segmental stenosis (Fig. 199.1).

An in-depth discussion of the pathogenesis of tracheal stenosis is beyond the scope of this chapter. With regard to CTS, the definitive pathogenesis is unknown. Additionally, several theories of embryologic tracheal development are still being debated.

Surgical techniques available for management of tracheal stenosis are endoscopic dilation, endoscopic stent placement, costochondral cartilage tracheoplasty, pericardial patch tracheoplasty, tracheal autograft tracheoplasty, tracheal resection with reanastomosis, and slide tracheoplasty. There have also been a few reports of tracheal transplantation for extreme cases. Many forms of acquired stenosis are amenable to endoscopic management. Although small-segment acquired tracheal stenosis may be amenable to balloon dilation, this technique is not recommended for the treatment of complete tracheal rings. Slide tracheoplasty and tracheal resection with reanastomosis have evolved as the current recommended primary open techniques for pediatric tracheal stenosis and owing to their wide acceptance and application; these techniques are discussed in this chapter.

KEY OPERATIVE LEARNING POINTS

1. It is essential in management decision making to classify the stenosis with the etiology, degree of narrowing, length of stenosis, and whether it is intraluminal or involves deformed cartilage.
2. Slide tracheoplasty is the surgical treatment of choice for long-segment stenosis and complete tracheal rings; it can be used for a variety of lengths of stenosis.
3. For mild stenosis of the trachea, observation can be a safe and reasonable option.
4. Some 50% to 70% of congenital tracheal stenoses have associated cardiovascular malformations; preoperative cardiac evaluation is recommended.
5. Previous open airway surgery or chest surgery has produced a scarred or shortened trachea, which can make resection with anastomosis difficult or impossible to perform.

PREOPERATIVE PERIOD

History

1. History of present illness
   a. What symptoms are present? The degree of dysfunction and therefore the clinical manifestations of tracheal stenosis vary widely. Patients with tracheal stenosis may complain of shortness of breath, dyspnea on exertion, expiratory or biphasic stridor, hoarseness, dysphagia, aspiration, difficulty clearing secretions, recurrent pneumonia, or any combination of these symptoms and signs. Children often have a history of recurrent croup or cardiopulmonary problems. Symptom severity likely correlates with degree of stenosis.[1,2]
   b. Are symptoms present at rest? Symptoms result from a narrowed airway lumen, which limits the physiologic demands of mucociliary clearance, tidal volumes, and gas exchange. It is generally estimated that the presence of symptoms with activity indicates a 50% stenosis of the tracheal lumen; symptoms at rest occur with a 75% stenosis.
   c. What was the age of symptom onset? Neonatal: Typically severe stenosis and critically ill. Cantrell and Guild[3] type 1 occurs more commonly and is often accompanied by significant cardiovascular malformations. There is a 70% to 100% mortality when patients with CTS present in a critically ill state.[2] Infancy: Stenosis symptoms present at several months of age, when there is an increase in physical activity and tidal volumes. Childhood/adolescence: Often incidental findings, present with mild symptoms and typically mild stenosis. Exercise-associated symptoms are common.[2]
   d. What is the severity of symptoms and quality of life effects?
      1) Are there frequent emergency department visits? Admissions? Treatments?
      2) What exacerbates the symptoms? Activity? Infection? Position?
2. Past medical history
   a. Birth history of prematurity or admissions to the neonatal intensive care unit (Neonatal Intensive Care Unit)
   b. Recurrent croup
   c. Apparent life-threatening events (ALTEs)
   d. Other congenital malformations: Stenoses are associated with pulmonary, cardiovascular, and gastrointestinal malformations.

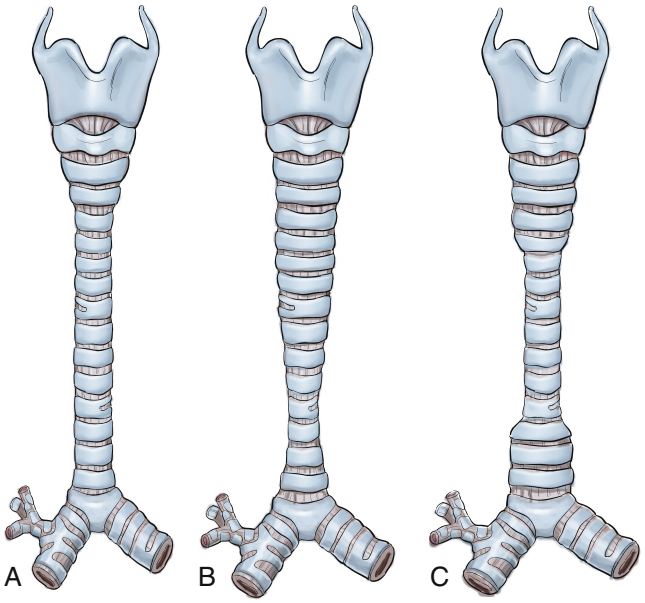

Fig. 199.1. Cantrell and Guild congenital tracheal stenosis classification: **A,** generalized hypoplasia, **B,** funnel stenosis, **C,** segmental stenosis.

e. Intubations: Multiple factors play a role in the etiology of tracheal stenosis after endotracheal intubation. Time of intubation, size of the tube relative to the airway, pressure and friction by the tube or cuff, repeated intubation, foreign-body reaction to the tube, release of toxic substances used for sterilization, use of a stylet, route of intubation (nasal or orotracheal), nursing care techniques (suctioning, fixation), and anatomic differences between the genders are among many important factors that can be correlated with the development of postintubation stenosis. Because the microcirculation of the tracheal mucosa is impaired at a pressure of 30mm Hg, a low-volume, high-pressure cuff is more likely to cause an ischemic injury than a high-volume, low-pressure cuff. Nonetheless, an overinflated, high-volume cuff can impede the microcirculation and produce the same injury as a low-volume cuff.
f. Infections or autoimmune disorders: Tuberculosis, histoplasmosis, blastomycosis, diphtheria, leprosy, and syphilis are endemic in several parts of the world. Stenosis due to inflammation, chondritis, or necrosis can occur. Diseases such as relapsing polychondritis and Granulomatosis polyangiitis (GPA) can destroy the cartilaginous framework and thereby lead to collapse of the airway. Stenosis occurs in 10% to 20% of patients with Granulomatosis polyangiitis, and the mainstay of treatment remains medical. These causes are important to identify preoperatively because tracheal repair in an active state of disease can exacerbate the disease or predispose to restenosis.

3. Past surgical history
   a. Bronchoscopies
   b. Endoscopic airway procedures
   c. Open airway reconstruction
   d. Tracheostomies
   e. Tracheoesophageal fistula (TEF) repair
   f. Cardiothoracic surgery
4. Medications
   a. H2 blockers/proton pump inhibitors (PPIs)
   b. Steroids
   c. Inhaled/nebulized bronchodilators

Physical Examination

1. General
   a. Weight/height/growth curve
2. Respiratory
   a. Tachypnea
   b. Expiratory or biphasic stridor
   c. Biphasic wheezing
   d. Tripod positioning
   e. Nasal flaring
   f. Intercostal, sternal, or suprasternal retractions
   g. Cyanosis
3. Face and oral cavity: Examination can reveal additional sites of airway obstruction and possibilities of a difficult airway, such as craniofacial abnormalities, trismus, retrognathia, micrognathia, or tonsillar/lingual hypertrophy.
4. Neck: Scars, length, restriction of mobility, tracheostomy. These findings can indicate prior surgical interventions as well as the feasibility of future procedures.
5. Fiberoptic laryngoscopy: Evaluate for vocal fold mobility, upper airway sites of obstruction, and glottic lesions.
6. Laryngoscopy/bronchoscopy: Visualization is crucial in determining laryngomalacia, tracheomalacia, length of stenosis, grade of stenosis, dynamic or static stenosis, thin webs, fresh versus mature stenosis, or complete tracheal rings. It is of utmost importance to avoid trauma to the mucosa of the stenosis during examination, especially with complete tracheal rings. Any worsening edema or scarring may create an unstable airway that can be extraordinarily difficult to manage. Consider passing a scope through the stenotic segment only if it can be passed with minimal contact and no trauma to the surrounding mucosa. Otherwise distal evaluation of the airway during bronchoscopy should be avoided. Fig. 199.2 demonstrates the endoscopic view of complete tracheal rings and complex tracheal stenosis. Video 199.1 demonstrates a bronchoscopic examination of complete tracheal rings.

Imaging

Chest radiograph: Plain films can help to evaluate the extent of the lesion, external compression, or pneumonia. In small children, soft tissue radiographs may be sufficient to localize and grade the stenosis with the addition of direct visualization.

Computed tomography (CT)/CT angiography (CTA)/magnetic resonance imaging (MRI): If the patient's status allows for imaging, CT and MRI can provide excellent evaluations of tracheal lesions as well as possible cardiovascular anomalies. Some 50% to 70% of CT examinations show associated cardiovascular malformations.[4] CT better ascertains the integrity of the cartilaginous framework. Spiral CT with three-dimensional reconstruction enables evaluation of the extent, shape, and site of the stenosis (Fig. 199.3). Although for narrow stenosis it may lack adequate spatial resolution, three-dimensional reconstruction allows for the possibility of "virtual" endoscopy. MRI allows direct imaging in the sagittal and coronal planes, which may be useful in planning treatment. Limitations of MRI are both the long scanning time and artifacts created by cardiac and respiratory movement; however, it can offer better detail of cardiovascular anomalies.

Pulmonary function testing with flow-volume loops: Useful in cases of mild to moderate stenosis with symptoms presenting later in life (Fig. 199.4)

Echocardiography: Obtained to evaluate for a high incidence of cardiovascular anomalies

Esophagogastroduodenoscopy (EGD): If symptoms of reflux, food intolerance, and significant airway edema are present, then a gastrointestinal (GI) evaluation for uncontrolled

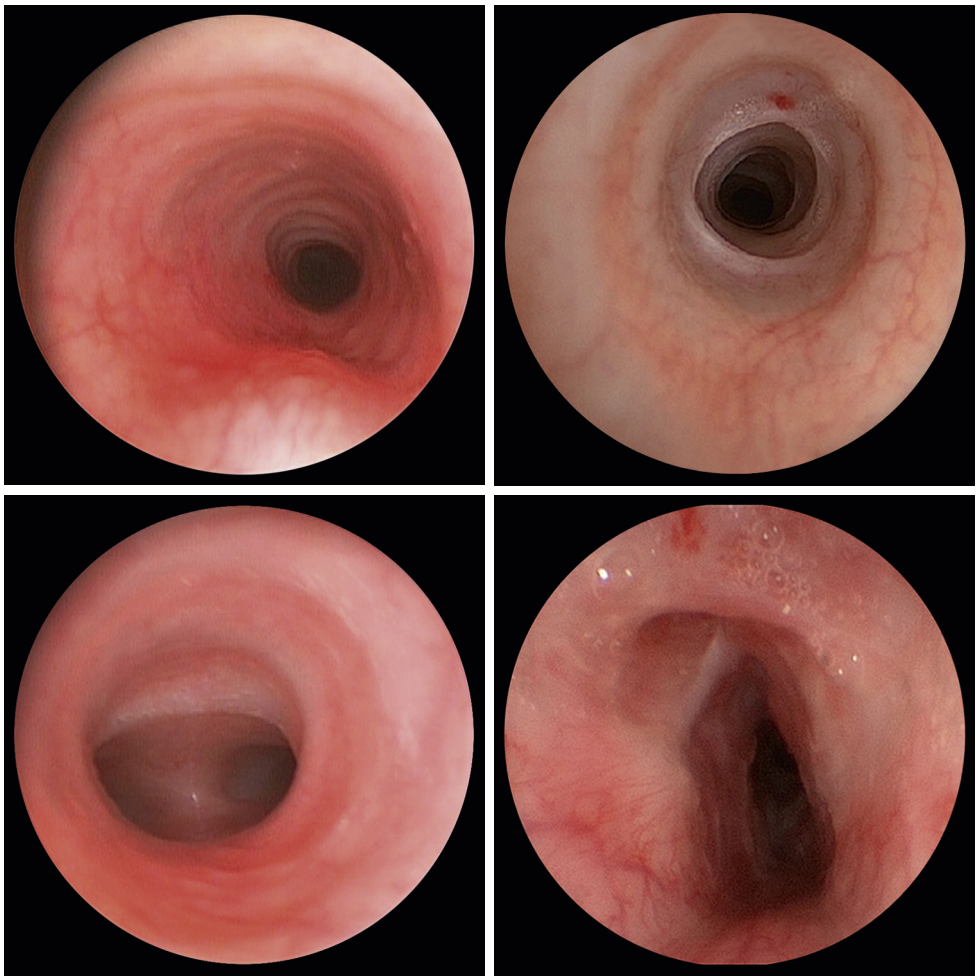

Fig. 199.2. Endoscopic images of tracheal stenosis (clockwise from top left): Complete tracheal rings viewed from upper trachea, complete rings midtrachea, complete rings distal trachea, complex tracheal stenosis with scarring.

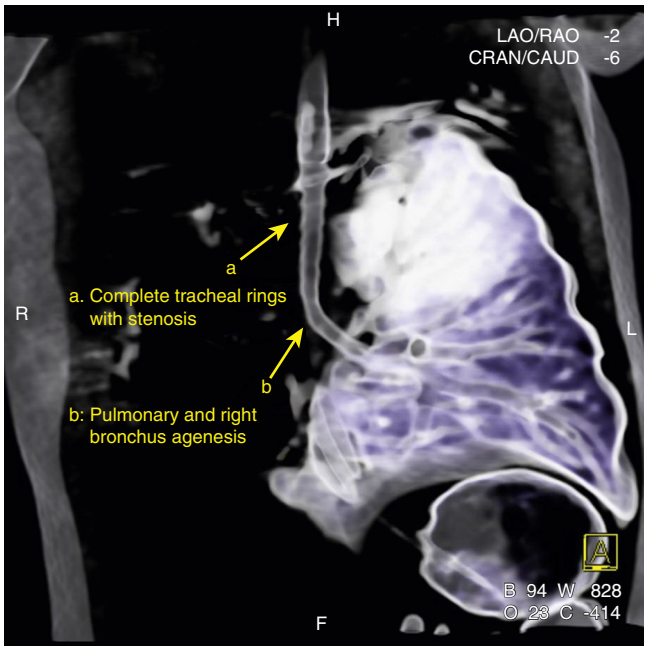

Fig. 199.3. High-resolution CT with 3D airway reconstruction demonstrating tracheal stenosis.

reflux or eosinophilic esophagitis and its management is warranted. Chronic inflammation from pepsin and acid can contribute to mucosal injuries and exacerbate existing stenosis. Patients with stenosis should be carefully monitored and aggressively treated for gastroesophageal reflux and eosinophilic esophagitis.

Laboratory data: Complete blood count, coagulation studies, and blood chemistry are needed if significant blood loss is expected or if cardiovascular anomalies are being simultaneously repaired with cardiopulmonary bypass (CPB) or extracorporeal membrane oxygenation (ECMO).

Indications

1. Critical stenosis with or without underlying cardiovascular anomalies
2. Symptomatic stenosis with significant impairment in quality of life
3. Neonatal stenosis with anticipated symptoms and future respiratory impairment

Contraindications

1. Unstable, critically ill patients with multiple comorbidities who are unable to tolerate surgery
2. Incidental stenosis without symptoms or expected future risk

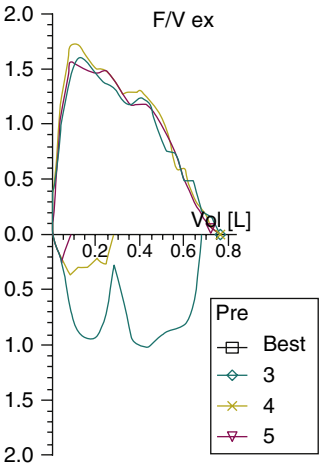

PULMONARY FUNCTION ANALYSIS

		Ref	LLN	Pre	Pre % Ref
FVC	L	1.37	1.18	0.79	57.3
FEV 1	L	1.19	1.00	0.73	61.3
FEV1/FVC	%	91	81	93	102.0
FEF 25–75%	L/s	1.53	1.14	1.08	70.3
ISOFEF 25–75%	L/s			1.08	
FEF 50%	L/s	1.66	0.48	1.25	75.0
PEF	L/s	2.77	2.52	1.77	64.0
FET 100%	s			1.67	
FVC IN	L	1.37	1.37	0.70	51.0
FIF 50%	L/s			0.80	
FEF 50% MIF 50	%			156.21	
PIF	L/s			1.02	
V backextrapolation ex	L			0.03	

Fig. 199.4. Flow-volume loop in a patient with mild tracheal stenosis demonstrating flattening of inspiratory and expiratory phases.

Preoperative Preparation

1. Establish an airway management algorithm for the procedure and coordinate the plan with the anesthesiology team.
2. Determine if CPB or ECMO will be needed for surgical access or for any combined cardiovascular procedures.
3. Consider screening for methicillin-resistant *Staphylococcus aureus* (MRSA), *Pseudomonas*, and gram-negative bacterial colonization.

OPERATIVE PERIOD

Anesthesia

General: General anesthesia with spontaneous ventilation if bronchoscopy is to be performed initially. If bronchoscopy is to be performed after CPB/ECMO, intubate above the stenotic segment until bypass is initiated.

Positioning

Supine: The patient is positioned with a shoulder roll and neck extension to allow for full access to the trachea.

Perioperative Antibiotic Prophylaxis: Clean-Contaminated Case Classification

Baseline: Ampicillin/sulbactam or third- or fourth-generation cephalosporin + metronidazole
MRSA-positive or high risk: Vancomycin or clindamycin
Pseudomonas risk: Piperacillin/tazobactam or third- or fourth-generation cephalosporin + metronidazole or fluoroquinolone (depending on local resistance patterns)
Penicillin allergy: Clindamycin

There are several factors to consider in choosing perioperative antibiotics. Head and neck cases are considered clean-contaminated and cefazolin alone is most often recommended. However, patients with airway stenosis have been demonstrated to have as much as 30% MRSA colonization.[5] Additionally, stenotic segments have increased rates of biofilms and colonization of gram-positive, gram-negative, and anaerobic bacteria. Tracheostomy tubes or long-standing endotracheal stents have increased rates of biofilms as well as *Pseudomonas* colonization. Although there are no specific guidelines for antibiotic prophylaxis in pediatric airway surgery owing to the increased risk of colonization, a directed prophylaxis at these high-risk patients is appropriate.

Monitoring

None necessary

Instruments and Equipment to Have Available

1. Endoscopic/bronchoscopic/emergency airway surgery cart
2. CO_2 laser
3. Airway balloons
4. Rapid ability to place patient on CPB or ECMO if necessary
5. Pediatric (cardiac) anesthesia

Key Anatomic Landmarks

1. Cricoid cartilage
2. Carina
3. Tracheal rings
4. Posterior tracheal membrane
5. Sternum

Prerequisite Skills

1. Endoscopic laryngoscopy and bronchoscopy
2. Endoscopic airway management
3. Open airway reconstruction

Operative Risks

1. Airway obstruction
2. Tracheal perforation
3. Airway bleeding
4. Tracheal dehiscence
5. Tracheitis
6. Mediastinitis
7. Granulation tissue
8. Tracheomalacia
9. Restenosis (circumferential or figure of eight)
10. Injury to the recurrent laryngeal nerves
11. Pneumothorax

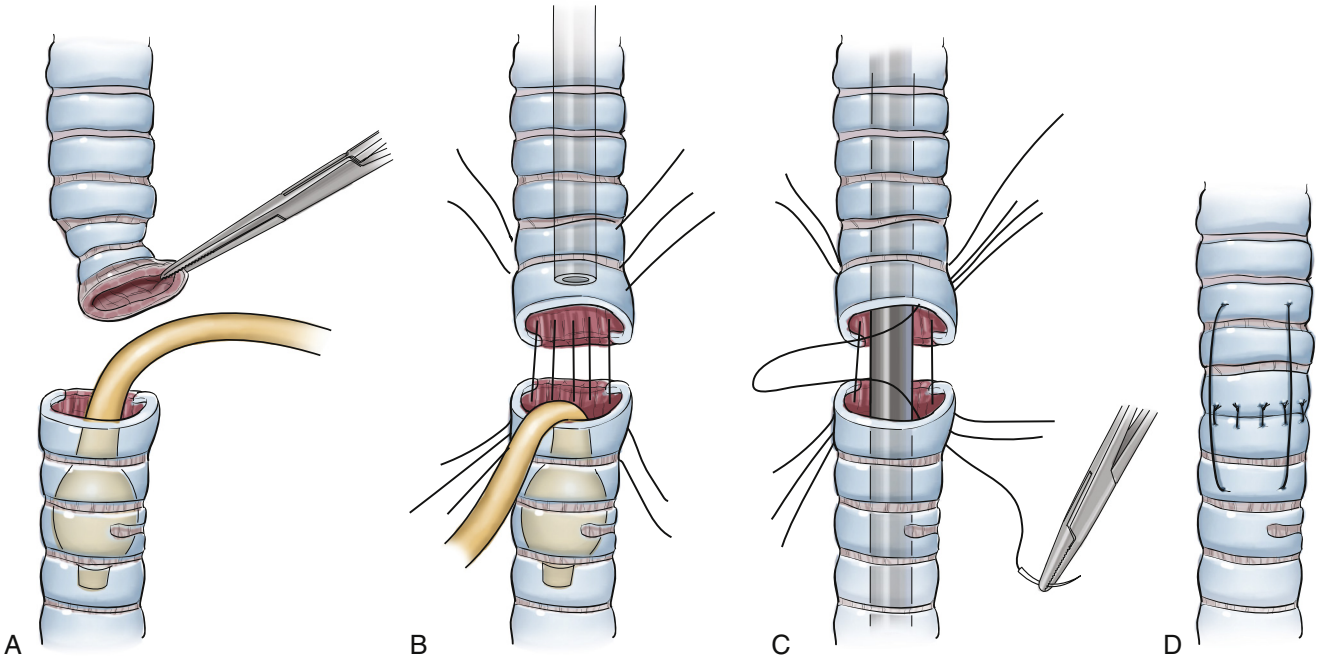

Fig. 199.5. Tracheal reanastomosis steps: **A,** dissection and resection of stenotic segment, **B,** placement of posterior sutures approximating trachealis muscle, **C,** placement of sutures approximating tracheal rings, **D,** closure of trachea and supporting sutures.

Surgical Technique

Segmental Resection and Reanastomosis

- Perform diagnostic laryngoscopy/bronchoscopy.
  - Confirm the lesion's characteristics and classification.
  - Obtain cultures from the airway for postoperative culture-directed antibiotics if needed.
  - Intubate with direct visualization. Use a smaller tube below the stenosis for mild to moderate stenosis. Use a larger tube above the stenosis for moderate to severe stenosis.
- A horizontal incision is made through the skin and subcutaneous adipose tissue of the lower neck.
- Strap muscles are identified and divided vertically at the midline raphe.
- The trachea is isolated above and below the stenosis; anterior dissection is performed from hyoid bone to the needed release inferiorly.
- The total length of excision needed is identified (up to 30% of the trachea may be excised safely).[6]
- Only the area of lateral trachea that is to be resected is dissected in order to preserve the lateral blood supply for the remaining trachea. For circumferential lesions, the posterior trachealis muscle is dissected from the esophagus.
- The endotracheal tube (ETT) is pulled back above the stenosis.
- 2-0 Prolene suture(s) are placed into the inferior trachea vertically as safety traction suture(s).
- Division of the trachea with a #15 blade. May leave the posterior wall of the trachea if it is not involved in the stenosis (Fig. 199.5A)
  - This may be a horizontal resection or vertical incision to define the intraluminal extent of stenosis.
- The stenotic segment of the trachea is excised (see Fig.199.5B).
- A new ETT is placed via the neck into the distal trachea for ventilation.
- Tension-free approximation of the tracheal segments is ensured.
  - If there is too much tension, releasing maneuvers can be performed.
    - Anterior tracheal dissection is continued down to the carina/peritracheal release.
    - Suprahyoid release, first described by Montgomery in 1974, causes less dysphagia than infrahyoid techniques.
    - Infrahyoid release
- Interrupted 4-0 Vicryl sutures are placed posteriorly to close the tracheal mucosa.
- The patient is intubated transnasally with a new appropriate-sized ETT to be used as postoperative stenting; distal ETT is removed.
- Interrupted 3-0 and/or 4-0 Vicryl and/or PDS sutures are placed circumferentially between the superior and inferior segmental rings. They are placed submucosally in order to avoid intraluminal sutures as possible sites for the formation of granulation tissue. Knots should be extraluminal (see Fig. 199.5C).
- Two to three submucosal sutures through two rings above and below the anastomosis are placed as additional supporting sutures to limit tension (see Fig.199.5D).
- The site is irrigated thoroughly.
- Anastomosis leak is tested with Valsalva.
- Repair can be augmented with fibrin glue application.
- Strap muscles are reapproximated.
- A passive surgical drain is used.
- The skin is closed.
- Chin-to-chest sutures (Grillo sutures) are used by some.

Slide Tracheoplasty

- Diagnostic laryngoscopy/bronchoscopy is performed.
  - Some centers use bronchograms for atraumatic diagnosis and evaluation of severity of lesion.
  - The lesion's characteristics and classification are confirmed.
  - Airway cultures for postoperative culture-directed antibiotics are obtained if needed.

  - The patient is intubated under direct visualization. For mild to moderate stenosis, a smaller tube is used below the stenosis. For moderate to severe stenosis, a larger tube is used above the stenosis.
- If CPB/ECMO is to be used or sternotomy, pediatric cardiothoracic surgeons perform median sternotomy, cannulate, and expose the entire trachea.
- Any comorbid cardiovascular anomalies are repaired.
- If CPB/ECMO and sternotomy are not needed, a horizontal neck incision through the skin in the lower neck and subcutaneous adipose tissue is made.
- Strap muscles are identified and divided vertically at the midline.
- The trachea is divided above and below the stenosis; anterior dissection is performed from hyoid to point inferiorly.
- The ETT is pulled back above the stenosis if the patient is not on CPB/ECMO.
- The superior, midpoint, and inferior extent of the stenosis are confirmed with bronchoscopy and 27- or 30-g needle placement through the trachea.
  - Some complete rings may be subtle when viewed endoscopically, and the extent of the lesion may be underestimated.
- Once the midpoint has been confirmed, the area of stenotic trachea to be divided is dissected. Circumferential dissection of the entire trachea is to be avoided to prevent injury to the lateral blood supply and recurrent laryngeal nerves.
- Large 2-0 Prolene sutures are placed into the inferior trachea vertically through 3 tracheal rings as safety traction sutures.
- The trachea is divided at the midpoint of stenosis with a #15 blade (Fig. 199.6A).
- A vertical incision is made on the anterior wall of the distal trachea for the entire length of the stenosis. This incision can be extended into a bronchus if needed (*Note:* Many surgeons reverse the orientation and make the vertical incision on the anterior wall of the proximal trachea and the posterior wall of the distal trachea. This decision is made based on the characteristics of the stenosis and surgeon's preference) (see Fig. 199.6B).
- A new ETT is placed via the neck into the distal trachea for ventilation.
- A vertical incision is made on the posterior wall of the proximal trachea for the entire length of the stenosis (*Note:* See variation of technique in step above) (see Fig. 199.6C).
- The distal and proximal segments are trimmed to facilitate an airtight closure without overlapping of segments.
- Tension-free approximation of tracheal segments is ensured (see Fig. 199.6D). In general, slide tracheoplasty has less need for releasing maneuvers, as the length of pull is 50% of the length of the stenosis. Additionally, the tension is spread over a longer length of anastomosis compared with tracheal resection techniques.
  - If there is too much tension, releasing maneuvers can be performed.
    - Anterior tracheal dissection is continued down to the carina/peritracheal release.
    - Suprahyoid release
    - Infrahyoid release
- The trachea is anastomosed with running double needle 4-0 PDS sutures or interrupted 3-0 or 4-0 PDS sutures placed circumferentially between the superior and inferior segment rings submucosally. Intraluminal knots are to be avoided and also the placement of knots near vascular structures (see Fig. 199.6E).
- The patient is intubated transnasally, with a new appropriate-sized ETT to be used as postoperative stenting prior to completing the anastomosis.
- The ETT is placed under direct visualization at the midpoint of the anastomosis and the distal ETT (if used) is removed.
- The site is thoroughly irrigated.
- Anastomosis leak is tested with Valsalva.
- Repair can be augmented with fibrin glue application.
- The proximal and distal limits of the repair may be marked with clips for postoperative x-ray visualization and ETT repositioning.
- The strap muscles are reapproximated.
- A passive surgical drain or suction drains are used in the setting of sternotomy.
- The skin is closed.
- Chin-to-chest sutures (Grillo sutures) are used by some.

Common Errors in Technique

1. Incorrectly classifying the degree and extent of the stenosis
2. Incorrectly identifying the midpoint of the stenosis prior to dividing the trachea for slide tracheoplasty
3. Underestimating the length of the stenosis and number of complete rings
4. Performing excessive dissection of the trachea, thus disrupting the lateral blood supply
5. Leaving a repair with too much tension without performing adequate releasing techniques

POSTOPERATIVE PERIOD

Postoperative Management

1. The patient is admitted to the Cardiothoracic intensive care unit/Pediatric intensive care unit (CTICU/PICU).
2. Chin-to-chest sutures (Grillo sutures) and/or passive neck flexion with a pillow may be used to maintain or limit suture tension.
3. Humidified saline air/oxygen or ventilation is utilized to limit mucosal drying.
4. Sedation and mechanical ventilation are applied as needed; older children or adults may not require either.
5. Antireflux medication may be given.
6. Depending on the patient's preoperative respiratory status, the cardiovascular comorbidities repaired, and the length of stenosis repaired, some patients can be extubated on the postoperative day; many patients will remain intubated for 7 to 10 days. Extubation typically is performed within 24 to 48 hours postoperatively for slide tracheoplasty and 0 to 7 days for tracheal resection.
7. Postoperative antibiotics are continued for 7 days or longer if endotracheal tube intubation was prolonged.
8. Optional direct laryngoscopy and bronchoscopy in the operating room in 5 to 7 days for inspection of anastomosis and granulation tissue; extubation if there is appropriate tissue healing. Many patients may be reintubated with a 0.5-size smaller endotracheal tube for an additional 24 hours prior to extubation. Dexamethasone 0.5 mg/kg or appropriate dose every 8 hours for 24 hours prior to extubation is recommended.
9. Prior to feeding, a flexible laryngoscopy is performed to confirm vocal cord function.
10. A formal feeding evaluation for symptoms of dysphagia, aspiration, or vocal cord impairment should be obtained.
11. Repeat a direct laryngoscopy and bronchoscopy in 4 weeks to evaluate the anastomosis. Be prepared for balloon dilation, laser removal of granulation tissue, and possible steroid injection and mitomycin-C application as needed. The timing of follow-up endoscopies will be determined by findings at this time.

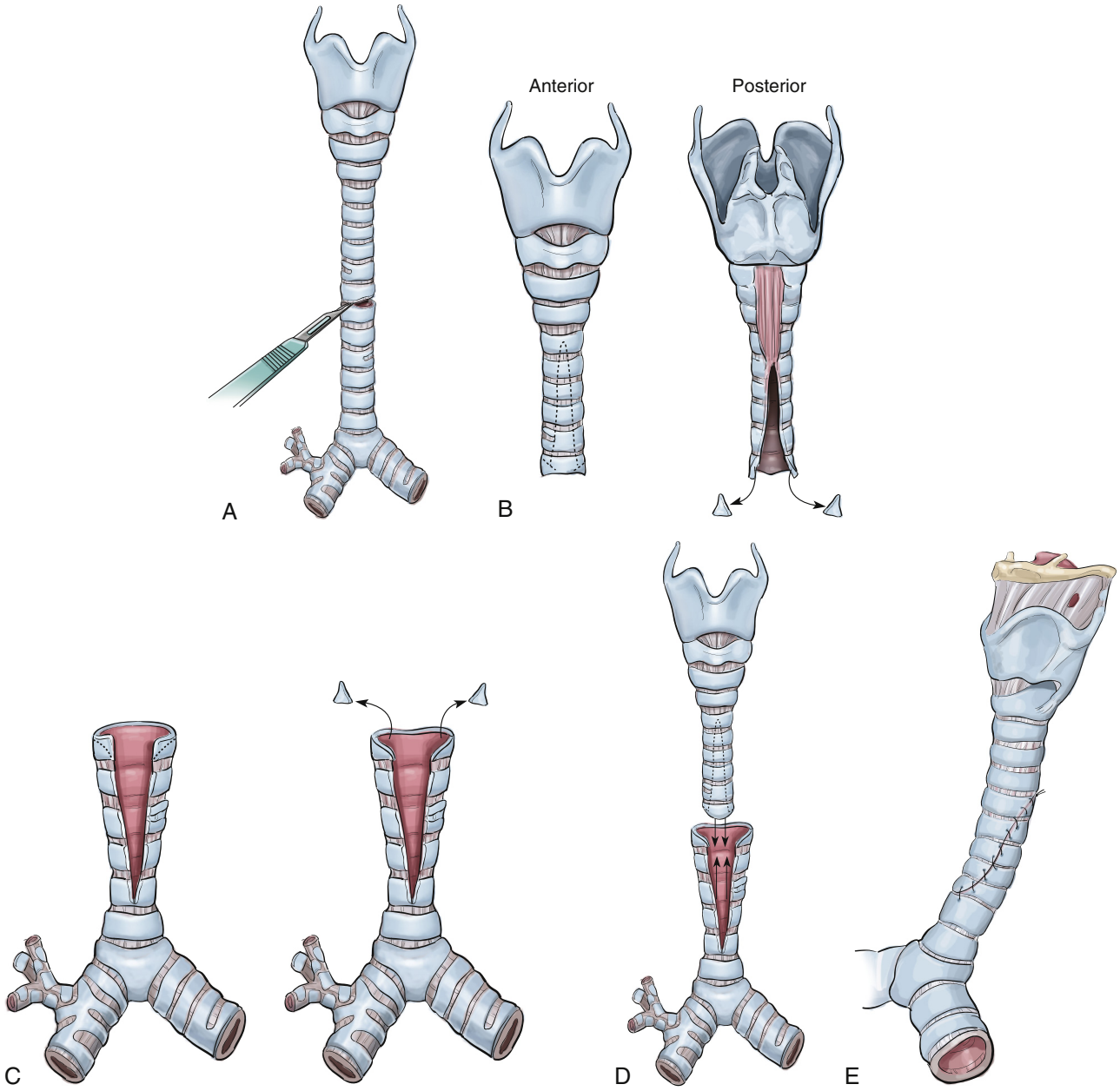

Fig. 199.6. Slide tracheoplasty steps: **A,** isolation and identification of stenosis midpoint, **B,** posterior vertical incision of proximal segment and trimming,* **C,** anterior vertical incision of distal segment and trimming,* **D,** sliding of segments for anastomosis, **E,** lateral view of suture closure after completion of anastomosis (*see note in text for technique variation).

Complications

1. Airway hemorrhage: Fresh clot can easily occlude an airway, especially if dry. Frequent suctioning and aggressive humidification or saline nebulizers are needed.
2. Tracheal dehiscence: Treatment depends on the timing and size of the defect. In general, continuation of appropriate antibiotics until the airway is healed is recommended. If it is noted at the time of surgery, then correction at that time is recommended. If dehiscence is noted in the early postoperative period (<7 days), confirmation of the extent of the defect and whether there are signs of infection by direct laryngoscopy and bronchoscopy is needed. An endotracheal tube can be passed beyond the defect for distal ventilation and airway stenting until the airway has healed. It is important to avoid high-pressure ventilation. This may require ECMO if ventilation is not adequate. If there is a late dehiscence (>7 days), there should be a strong suspicion for infection and chondritis. Treatment may require neck or mediastinal washout, longer-term airway stenting, revision surgery, and long-term ECMO. Postoperative infections and dehiscence are more often associated with both MRSA and *Pseudomonas* infections. Preoperative cultures to evaluate and treat for these organisms prior to repair (if possible) are recommended.
3. Granulation tissue: On follow-up direct laryngoscopy/bronchoscopy (DLB) at 4 weeks postoperatively, granulation tissue can be removed gently with débridement, cup forceps, or gentle laser ablation. One must be careful to not induce more trauma to the mucosa and tracheal cartilage and further chondritis.

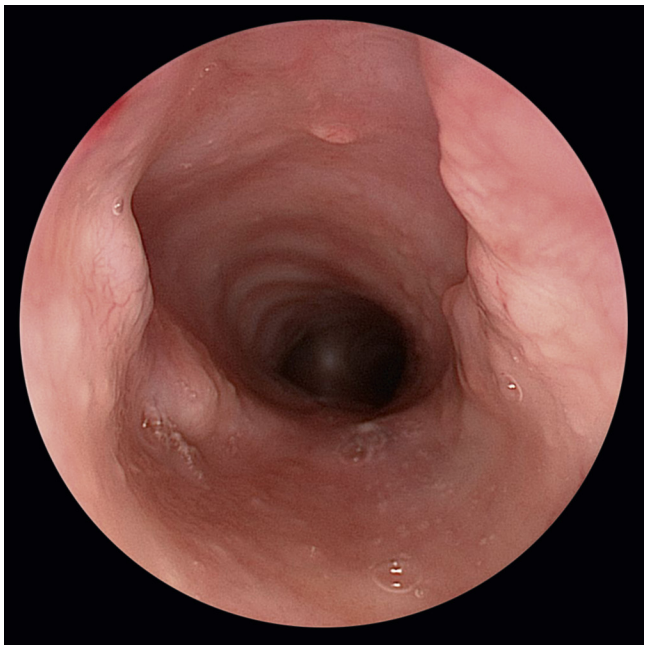

Fig. 199.7. Endoscopic view of figure-of-eight deformity following slide tracheoplasty.

4. Restenosis: Both repair techniques are at risk for restenosis. With tracheal resection and reanastomosis, the repair is typically in the horizontal plane. One may see circumferential stenosis that can be dilated with airway balloons. For slide tracheoplasty techniques, the repair suture line is on an oblique plane. Less circumferential stenosis is noted, but the lateral anastomotic edges can fold inward, creating a figure-of-eight deformity (Fig. 199.7). Although most figure-of-eight tracheas do not require treatment, a trachea can be dilated with airway balloons if needed. Adjunctive treatments with steroid injection or topical mitomycin-C can be applied in these settings.
5. Pneumonia may occur at a high rate, as many patients are colonized with organisms, are ventilated postoperatively, and may have had blood and secretions in the distal airway secondary to surgery.
6. Postextubation narcotic withdrawal occurs frequently in patients who require sedation and ventilation and should be appropriately identified and treated.

Alternative Management Plan

1. Observation. For mild stenosis with limited symptoms, conservative management has been proven to be safe. Additionally, some amount of tracheal growth may occur.[7]
2. Tracheal stenting. For patients too critically ill for surgical repair, temporizing measures with endoscopically placed stents can be utilized. Biodegradable stents should be considered over permanent stents, which are associated with a higher rate of potentially devastating complications.

DISCUSSION

Evidence-Based Medicine Question

What percentage of tracheal length can be managed with tracheal resection and reanastomosis?

Based on retrospective data, typically 30% or more was the point at which postoperative complications increased. This percentage was determined by dividing the length of resection by the patient's age and tracheal length nomograms. Once 30% or greater trachea was resected, postoperative airway complications increased from 13% to 46%. The conclusions based on the investigators' retrospective data were that "children tolerate anastomosis tension less well than adults; resections [of] more than 30% have a substantial failure rate."

Wright C, Graham B, Grillo H, et al.: Pediatric tracheal surgery. Ann Thorac Surg 2002. 74:308–314.

Editorial Comment

Tracheal stenosis is a rare, potentially life-threatening condition due to narrowing of the tracheal lumen. Tracheal stenosis may be congenital, due to incomplete tracheal rings, or the result of prolonged intubation or the compression of vascular structures. Historically tracheal stenosis has had a poor prognosis, with high morbidity and mortality. Significant advances in radiographic, cardiac bypass, endoscopic, and surgical techniques have led to better overall survival and reduced morbidity. The most common techniques currently used include endoscopic dilation, tracheal resection, and slide tracheoplasty, which have replaced the technique of pericardial patch tracheoplasty used previously. Because tracheal stenosis is a complex condition, an individualized treatment plan for each patient must be formulated by a multidisciplinary team.

Sukgi Choi

Access the review questions and additional sources list online at http://www.expertconsult.com

REFERENCES

1. Ho A, Koltai P. Pediatric tracheal stenosis. Otolaryngol Clin N Am 2008;41:999–1021.
2. Hofferberth S, Watters K, Rahbar R, et al. Management of congenital tracheal stenosis. Pediatrics 2015;136(3):660–669.
3. Cantrell J, Guild H. Congenital stenosis of the trachea. Am J Surg 1964;108:297–305.
4. Butler C, Speggiorin S, Rijnberg F, et al. Outcomes of slide tracheoplasty in 101 children: a 17-year single-center experience. J Thorac Cardiovasc Surg 2014;147(6):1783–1789.
5. Statham M, de Alarcon A, Germann J, et al. Screening and treatment of methicillin–resistant *Staphylococcus aureus* in children undergoing open airway surgery. Arch Otolaryngol Head Neck Surg 2012;138(2):153–157.
6. Wright C, Graham B, Grillo H, et al. Pediatric tracheal surgery. Ann Thorac Surg 2002;74:308–314.
7. Cheng W, Manson D, Forte V, et al. The role of conservative management in congenital tracheal stenosis: an evidence based long term follow up study. J Pediatr Surg 2006;41:1203–1207.

REVIEW QUESTIONS

1. The blood supply of the trachea is predominately located where?
   a. Midline anterior tracheal wall
   b. Intraluminal mucosa
   c. Posterior trachealis
   d. The lateral longitudinal submucous plexus

2. Congenital tracheal stenosis has a 50% to 70% association with
   a. Malformation of the posterior fossa
   b. Web of the anterior glottis
   c. Cardiovascular malformations
   d. Limb malformations

3. The classic appearance for slide tracheoplasty intraluminal restenosis is?
   a. Figure of eight
   b. Circumferential
   c. A-frame
   d. Hourglass

4. When symptoms of tracheal stenosis are present, the luminal stenosis is estimated to be at the following, respectively:
   a. 50% stenosis with symptoms at rest, 10% stenosis with symptoms with activity
   b. 10% stenosis with symptoms at rest, 50% stenosis with symptoms with activity
   c. 50% stenosis with symptoms at rest, 75% stenosis with symptoms with activity
   d. 75% stenosis with symptoms at rest, 50% stenosis with symptoms with activity

ADDITIONAL SOURCES

Carcassonne M, Dor V, Aubert J, et al. Tracheal resection with primary anastomosis in children. J Pediatr Surg 1973;8(1):1–8.

Grillo H. Development of tracheal surgery: a historical review. Part 1: techniques of tracheal surgery. Ann Thorac Surg 2003;75:610–619.

Grillo H. Development of tracheal surgery: a historical review. Part 2: techniques of tracheal surgery. Ann Thorac Surg 2003;75:1039–1047.

Grillo H. Slide tracheoplasty for long segment congenital tracheal stenosis. Ann Thorac Surg 1994;58(3):613–619.

Kimura K, Mukohara N, Tsugawa C, et al. Tracheoplasty for congenital stenosis of the entire trachea. J Pediatr Surg 1982;17(6):869–871.

200 Thyroglossal Duct Cyst

Samantha Anne, Andrew F. Inglis, Jr.

INTRODUCTION

Thyroglossal duct cysts (TGDCs) are the most common congenital midline cervical anomalies in children and account for approximately 70% of all congenital neck lesions.[1] The differential diagnosis of a midline mass in the neck mass in a child includes TGDC, dermoid, lymph node, lipoma, hemangioma, ranula, and inflammatory lesion. One study that evaluated preoperative computed tomography (CT) and histopathologic findings of excised midline neck lesions found that TGDCs were most common (55% of cases). Other common findings were dermoids in 21%, ranula in 10%, and the remaining were inflammatory lesions.[2]

During embryogenesis, the foramen cecum develops at the floor of the primitive pharynx. The thyroid tissue begins to descend from the foramen cecum anterior to the hyoid bone and laryngeal cartilages to finally reach its normal adult pretracheal position. The proximal portion of the diverticulum that connects the thyroid gland and foramen cecum typically obliterates and atrophies over time. TGDCs are thought to occur due to failure of the thyroglossal duct to obliterate after the thyroid gland completes its descent into the inferior aspect of the neck.[3]

TGDCs tend to present in childhood as a painless midline mass just inferior to the hyoid at the level of the thyrohyoid membrane (65%). Other locations include the suprahyoid location in up to 20% to 25% of the cases and at the level of the hyoid in 15% to 50% of the cases.[4] TGDCs usually occur in equal frequencies in males and females.[5] Because this is a congenital lesion, it would not be surprising for the most common age of presentation to be in childhood. One of the largest reviews of patients with TGDCs revealed that these lesions occur frequently in children with nearly one-third of the cases in children less than 10 years of age. However, nearly one-third of the cases occurred in patients in their third decade or older. Similarly, recent reports suggest a bimodal incidence with the most common average age in children to be 6 years and in adults to be 41 to 45 years.[5] TGDCs are benign cysts that mainly consist of abundant colloid and are lined predominantly with ciliated columnar epithelium.[6] Carcinoma has been shown to occur rarely in these cysts, with an incidence of 1%.[7]

KEY OPERATIVE LEARNING POINTS

- The most common location for TGDC is in the midline, just inferior to the hyoid bone.
- The Sistrunk procedure, which involves removing the midportion or body of the hyoid bone with the cyst and a core of tongue muscle, is the recommended surgery for TGDC.
- The thyroid notch is used as a landmark to mark the midline of the neck.
- The cricoid cartilage in very small children can be high in the neck and mistaken for the hyoid bone.

PREOPERATIVE PERIOD

Surgical excision of a midline mass in the neck is useful for diagnostic and therapeutic purposes. Indications for excision of a midline mass in the neck mass include diagnosis, cosmetic appearance, prior infection, and possibility of malignancy. The recommended surgery for TGDC is a Sistrunk procedure that includes removal of the cyst along with the central portion of the hyoid bone, including a core tissue at the base of the tongue. The Sistrunk procedure has been shown to decrease the rate of recurrence to approximately 5%.

Thorough history taking and a physical examination are essential to diagnosis. The majority of the patients present with the history of a rapidly enlarging midline mass in the neck and oftentimes report a history of a preceding upper respiratory illness. When acutely infected, the mass can be painful, erythematous, and warm to touch. Some may present with recurrent infections that have been previously treated and improved on antibiotics.[8] Others may have had incision and drainage procedures due to misdiagnosis. Patients may be completely asymptomatic or can have dysphagia, odynophagia, and a feeling of obstruction if severely enlarged.

On examination, cysts usually measure 1 to 2 cm but can be as large as 10 cm. The mass is characteristically described as moving with swallowing or protrusion of the tongue due to its attachment to the hyoid bone. Cysts are usually nontender unless acutely infected. Some patients may have a draining tract from the site of a prior incision and drainage, recurrence due to incomplete excision, or a ruptured cyst.

History and physical examination are the mainstay for diagnosis and therapeutic planning in terms of TGDC. However, a number of studies have been used to aid in diagnosis when not clear and when there is suspicion for extensive disease beyond the appearance of a cyst. These include radionuclide studies, ultrasonography (US), CT, and magnetic resonance imaging (MRI).

Historically, radionuclide studies were used to identify functional thyroid tissues and to eliminate the possibility of mistaking ectopic thyroid gland for TGDC. Excision of ectopic thyroid gland with no functioning thyroid gland elsewhere will result in hypothyroidism. Radionuclide studies are now less used to avoid the unnecessary radiation with minimal diagnostic advantage offered in comparison to US, CT, or MRI.

US is an invaluable initial test for evaluation of TGDC. It avoids the exposure to ionizing radiation from CT scans and possible need for sedation in MRI studies, especially in young children, and is low cost. In addition, it has been shown to have sensitivity and accuracy comparable to CT or MRI19. An uncomplicated TGDC appears as an anechoic, well-circumscribed, thin-walled cyst. At times, the presence of proteinaceous fluid can give a pseudosolid appearance, while prior infection and hemorrhage may give a heterogeneous appearance.[9]

CT and MRI can be useful to delineate the extent of the lesion when it is extensive and help if there is difficulty ascertaining the diagnosis on US. On CT, TGDCs tend to be smooth, well circumscribed, midline, and closely related to the hyoid bone. They tend to be unilocular but can have septations. In the setting of prior infection, there may be a thickened cyst wall, increased fluid attenuation, and loss of tissue planes. MRI features are usually homogeneous low signal on T1-weighted images and homogeneous high signal on T2-weighted images due to the fluid within the cysts. The duct tract can sometimes be traced on T2-weighted fat saturated images.[9]

If presurgical imaging is attained, suspicion of malignancy should arise if dense or enhancing mural nodules, calcification, or both are seen within the lesion. Calcifications are best seen on CT and are due to psammoma bodies, the histologic hallmark of papillary carcinoma. However, the diagnosis of carcinoma is usually made incidentally on histologic examination of pathology specimens following surgical excision.

History

1. History of present illness
   a. Onset of cyst and relation to upper respiratory illnesses
   b. Symptoms of obstruction (e.g., dysphagia, odynophagia, stridor)
   c. Prior infections in the same locations
2. Past medical history
   a. Prior surgical incision and drainage procedures or excisions of cysts
   b. Prior treatment with antibiotics
3. Medications
   a. Vitamin E, nonsteroidal anti-inflammatory drugs, homeopathic medications
   b. Allergies to antibiotics

Physical Examination

1. Oral cavity and oropharynx; the cyst moves with protrusion of the tongue
2. Neck
   a. Cystic lesion measuring up to 10 cm
   b. Can be nontender or tender if acutely infected
   c. Prior scarring or fistulous tracts
   d. The mass moves up and down with swallowing

Imaging

1. Ultrasound
   a. Anechoic, well-circumscribed, thin-walled cyst
   b. Valuable initial test: Inexpensive and avoids radiation
2. CT
   a. Calcifications raise concern about possible malignancy.
3. MRI
   a. To avoid radiation when further imaging is needed
   b. Can be used to trace duct on T2-weighted fat saturated images

Indications

- Midline mass in the neck
- Recurrent injections
- Failed prior resections or incision and drainage procedures

Contraindications

- Comorbidities make patient unsafe for anesthesia and surgery
- Inadequate social support and support during recovery

Preoperative Preparation

1. Evaluation by
   a. Otolaryngologist
   b. Primary care physician for medical clearance when significant comorbidities present
2. Discontinue nonsteroidal anti-inflammatory drugs (NSAIDs) and other drugs that increase the chance of bleeding.

OPERATIVE PERIOD

Anesthesia

The procedure is typically performed via a general anesthetic. A nasal RAE tube facilitates intraoral manipulations and is desirable.

Positioning

- The patient is positioned supine on a shoulder roll with the neck extended.
- The lower face and neck are sterilized and appropriately draped.

Perioperative Antibiotic Prophylaxis

- The typical recommendations for clean-contaminated head and neck surgery apply to this procedure, since oral contamination may occur.
- Antibiotics are administered during induction of anesthesia and continued for 24 hours.
- Choices
  - Clindamycin
  - Ampicillin-sulbactum
  - Cefazolin and metronidazole

Monitoring

- Routine anesthesia monitoring
- Consider requesting that patient not be paralyzed in order to facilitate monitoring for hypoglossal nerve.

Instruments and Equipment to Have Available

1. Basic soft tissue surgical set
2. Hyoid or other bone-cutting scissors
3. Headlight
4. For recurrences, or TGDCs at high risk for recurrence, use the following:
   - Jennings self-retaining oral retractor
   - Perforating towel clip
   - 3.5-inch 18-Ga spinal needle
   - Heavy suture such as #2 (not 2-0) braided polyester
   - Tonsil clamp
   - Sterile button or 2-cm section of 14-Fr red-rubber catheter

Key Anatomic Landmarks

1. Foramen cecum: Junction of the anterior two-thirds of the tongue with the posterior one-third in the midline
2. Midportion or body of the hyoid bone: A 1- to 2-cm section, depending on patient age/size, of the central portion of the hyoid bone is removed.
3. Thyroid notch in the thyroid cartilage: This landmark can be used to mark the midline of the neck.
4. Cricoid cartilage: In very small children, this may be quite high in the neck and mistaken for the hyoid bone.

Prerequisite Skills

1. Basic soft tissue surgical skills

Operative Risks

1. Recurrence from incomplete resection
   - Goal of the surgery: Remove the cyst and any associated ductal remnants and secretory tissue.
   - Ductal remnants and secretory tissue are generally scattered and likely difficult or impossible to identify intraoperatively.
   - Complete extirpation of these elements is most likely achieved by an en bloc excision with a specimen consisting of the cyst, soft tissues between the cyst and midportion of the hyoid bone, and soft tissue attached to the superior surface of the hyoid connected to a core of tongue muscle extending to the foramen cecum.
2. Intraoperative hemorrhage from the lingual artery
   - If the dissection in the tongue base strays from the midline, the lingual artery may be encountered.
   - The lingual artery can be avoided by using a traction suture to maintain midline orientation as described later in this chapter or feeling for the midline with a double-gloved finger in the mouth applying downward pressure to the foramen cecum.
3. Postoperative hematoma or infection
   - These complications may be mitigated by placing a drain.
   - Known regional cases of hematoma leading to catastrophic airway obstruction
   - For this reason, the central portion of the wound can be closed loosely over a quarter inch Penrose drain, which is generally removed the following morning, in the hopes that this will lessen the chance of this very rare but potentially devastating complication.
4. Pharyngocutaneous fistula
   - May result from a breakdown of the closure of the tongue-base mucosa. These will generally close spontaneously in several days.

Surgical Technique (Fig. 200.1)

- Subcutaneous tissues in a suitable upper-neck skin crease are infiltrated with a bupivacaine/epinephrine solution, and the patient is sterilely draped.
- If the cyst is not attached to the dermis, a simple horizontal transverse incision is performed straddling the midline of the neck, usually just below the body of the hyoid in a natural skin crease. Dermal attachments or inflammation may require removal of a fusiform section of overlying skin. Dissection is then carried down to the anterior surface of the cyst.
- If the cyst appears to have mucoid or purulent material within, a modified Sistrunk procedure is performed as described later in the chapter. If there has been no prior history of infection and the cyst appears filled with whitish or cream-colored contents, it is likely a dermoid and a simple excision can be performed. If after removal it is confirmed that the cyst contents consist of thick cheesy material, the wound can be closed.
- Upon deciding to perform a modified Sistrunk procedure, the cyst is then partially freed via dissection around its anterior, inferior, lateral, and posterior surfaces, but soft tissue attachments between the cyst and the hyoid bone are left intact, as these may contain microscopic ductal and secretory elements. The cyst is elevated and a plane is developed posterior to the body of the hyoid bone.
- Dissection then proceeds in a layer just superficial to the anterior face of the body of the hyoid bone along the midline, and the hyoid is divided on either side of the midline such that a 1- to 1.5-cm central segment is freed up. The hyoid bone can be cut with a needle-tipped cautery in small children and bone cutter or hyoid scissors in larger patients. Soft tissue attachments to the superior aspect of the hyoid bone are left undisturbed.
- The suprahyoid portion of the procedure is then performed. To accomplish this, the now free-floating section of hyoid bone is grasped with an Allis or Leahy clamp and pulled anteroinferiorly, and a cylinder of tissue at the base of the tongue is created through a superiorly aimed dissection with an insulated needle-tipped cautery. In general, we recommend a more aggressive tongue base excision when there is a history of prior infection, as these are more likely to recur.
- If the pharynx is entered, it is readily closed with a row of simple interrupted sutures. Exposure can be facilitated by using the first suture placed as a traction suture and cutting it after later sutures have been placed. The remainder of the wound is then closed in layers according to the surgeon's preference.

Modification of Surgical Technique: Traction Suture and Transhyoid Pharyngotomy

- Placing a traction suture to guide the tongue-base resection, improve exposure, and facilitate the safe resection of a more generous portion of the tongue base may be helpful in the following circumstances[8]:
  - Situations where the risk of recurrence is high, such as patients who have had previously operated TGDCs or primary surgery on TGDCs that have had previous infection
  - Large patients with a "bull neck"
- The suture is placed prior to the sterile neck prep and after the patient is positioned. The patient's mouth is kept opened with a Jennings mouthgag. The tongue is grasped with a perforating towel clip, and an assistant pulls the tongue anteriorly. The surgeon places a long 18-Ga spinal needle through the skin overlying the body of the hyoid bone and advances the tip through the tongue mucosa at the foramen cecum. The stylet is removed and a #2 braided polyester suture is advanced through the needle, the end is grasped in the mouth with a tonsil clamp, and the needle is withdrawn. A "stopper" consisting of either a sterile button or a short section of 14-Fr catheter is tied to the intraoral section of the suture with a long tail of suture brought out through the mouth and tagged with a clamp (Fig. 200.2). The neck is then prepped and draped in the usual sterile fashion.
- Intraoperatively, the suture is identified, pulled through the skin into the wound, and is pulled anteroinferiorly during the tongue base resection, while a core of tongue tissue is developed around it. This traction on the tongue base serves as both a guide to the resection, keeping it in the midline, and also delivers the upper part of the tongue base into the wound, greatly improving exposure of the upper part of the resection (Fig. 200.3).
- When operating on recurrent TGDCs, dissection includes a cylinder of tongue tissue, including the tongue mucosa (Fig. 200.4). The traction suture is divided and the intraoral section removed by the anesthesiologist. The pharyngotomy is carefully closed in layers with interrupted absorbable suture over a Penrose drain. Further details of the procedure are described by Perkins et al.[8]
- Alternatively, a curved retractor may be placed through the mouth with the tip in the vallecula. Pressure on the retractor brings the base of the tongue into the wound, facilitating the excision of the block of tissue at the foramen cecum.

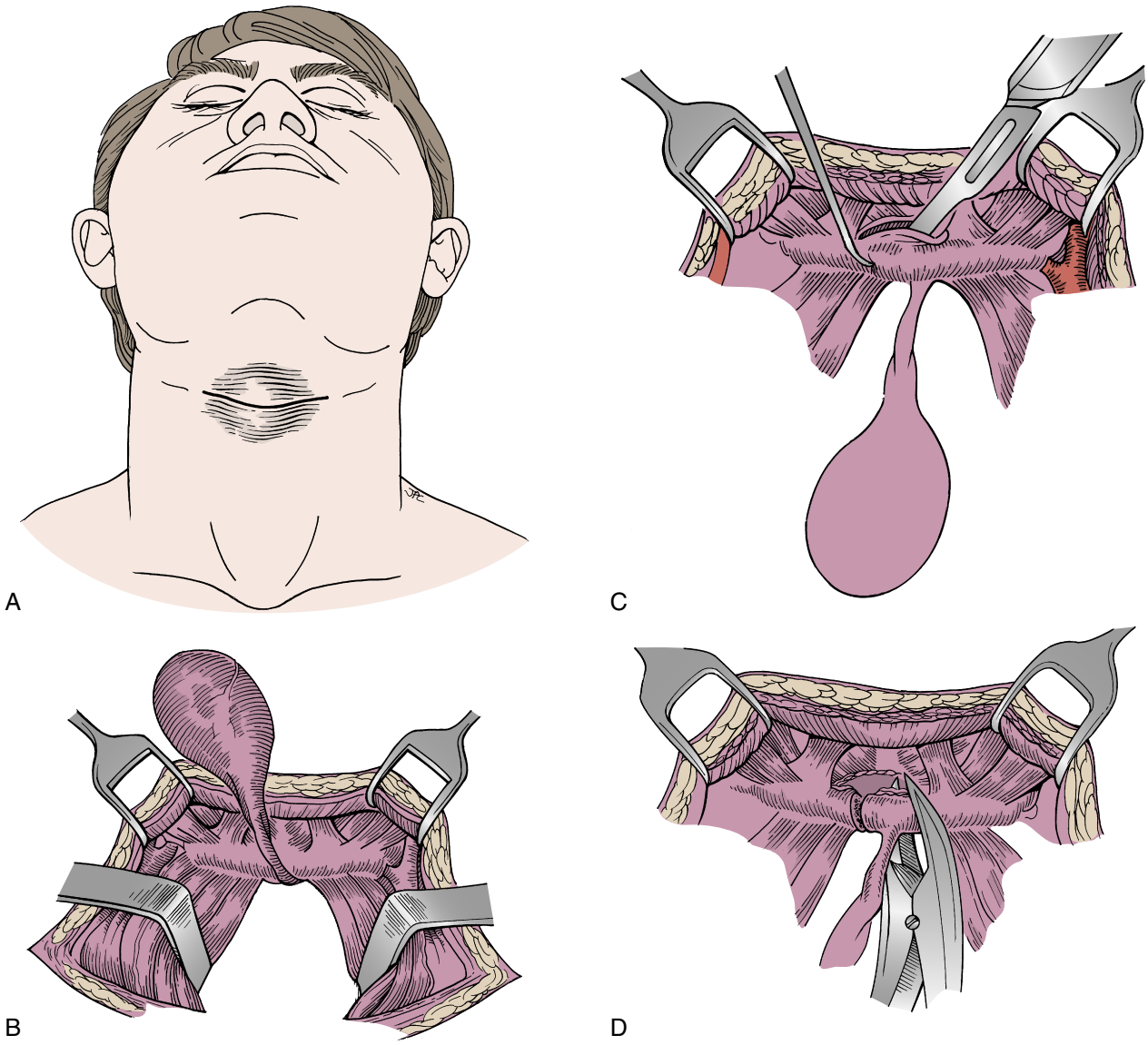

Fig. 200.1. A, The incision is placed in the major skin crease in the midline of the neck. **B,** The cyst is identified, the strap muscles are retracted, and the cyst is pedicled on the hyoid bone. **C,** The hyoid bone is grasped with a tenaculum and skeletonized. **D,** The hyoid bone is transected with a bone cutter.

Common Errors in Technique

1. The vallecula is entered posterior to the hyoid bone: Only a thin layer of tissue may separate the mucosa from the posterior surface of the hyoid.
2. The dissection may stray from the midline: Landmarks need to be checked frequently.
3. Too little tongue tissue may be removed:
   - Surgeons have reported low recurrence rates with removal of only a very limited cuff of tissue above the body of the hyoid.
   - Most surgeons suggest the ideal resection includes a core of tongue tissue of approximately 1 cm in diameter extended to the foramen cecum and either ending the dissection just shy of the mucosa superiorly or including a small disc of mucosa with the excision.
4. The superior skin flap may be injured or "button-holed" during the dissection. Vigilance is necessary, and an adequate incision must be made.
5. The incision heals with excessive dimpling in the midline. The strap muscles must be brought together medially to help fill the dead space created by the loss of the midportion of the hyoid bone and the superficial soft tissues.

POSTOPERATIVE PERIOD

Postoperative Management

1. Routine pain management with acetaminophen, ibuprofen, and oxycodone may be started immediately.
2. Patients may prefer a soft diet for a few days.
3. A drain, if placed, may be removed the following morning.
4. Select patients may be discharged on the day of surgery.

Complications

1. Hemorrhage: The wound should be opened and re-explored. Catastrophic airway obstruction at the tongue base is a possibility.
2. Infection: Mild infections may be managed with oral antibiotics. More severe infections typically require reopening the wound for drainage.
3. Salivary fistula: These usually close spontaneously within several days in patients who do not have any medical conditions that may inhibit wound healing. Oral antibiotics will usually suffice in suppressing infection.

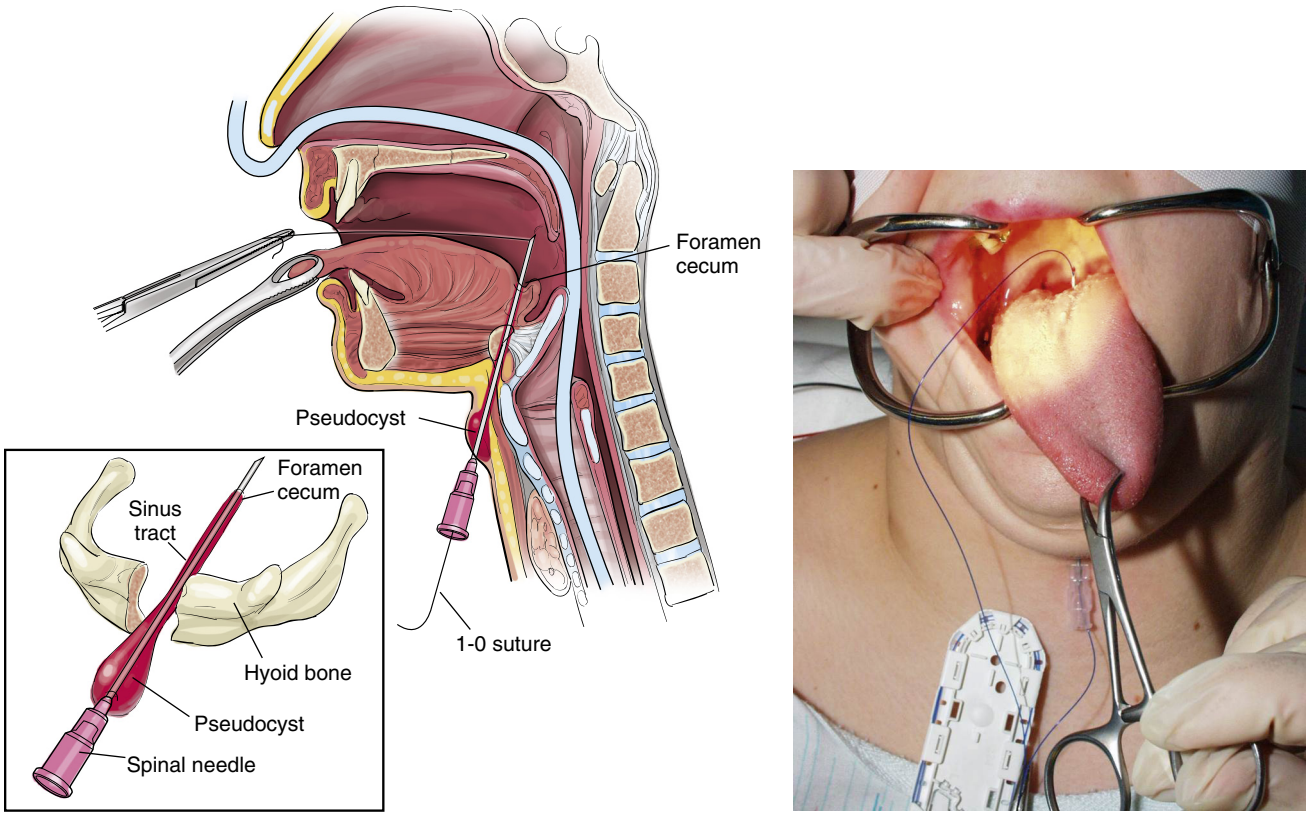

Fig. 200.2. Placement of a traction suture to guide the tongue-base resection through the foramen cecum.

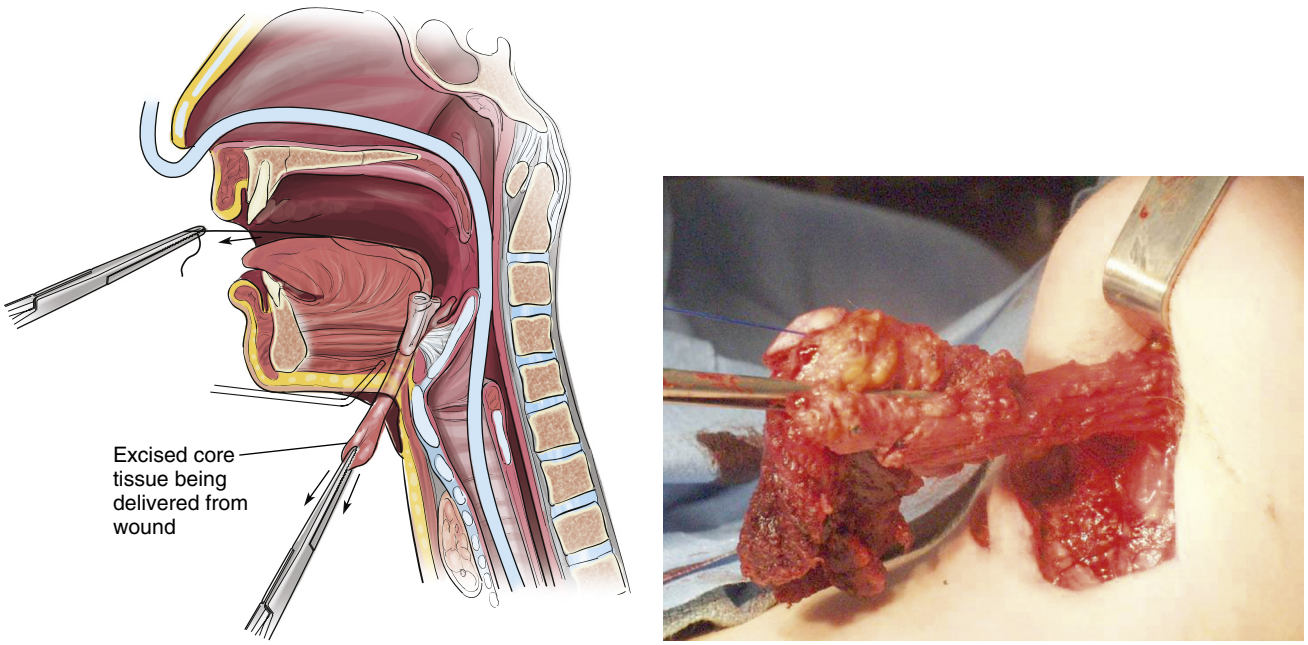

Fig. 200.3. Use of a traction suture to deliver the upper part of the tongue base into the wound to improve exposure of the upper part of the resection.

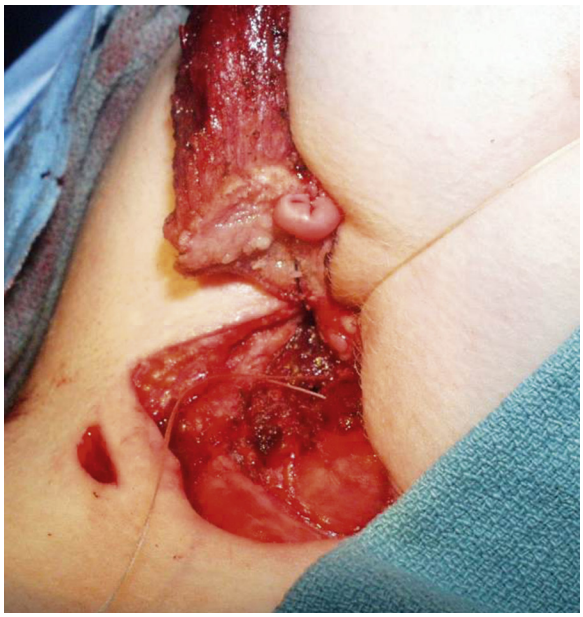

Fig. 200.4. For recurrent TGDCs, dissection includes a cuff of tongue tissue including the tongue mucosa; the pharyngotomy is carefully closed in layers.

4. Recurrence: Incomplete excision of secretory material, almost invariably situated in the tongue base if the hyoid has been previously resected, may produce a pseudocyst located virtually anywhere in the anterior neck. Most become apparent within a few months of the original procedure. Treatment requires reexcision via a technique such as the suture-guided transhyoid pharyngotomy or other approach to the tongue base.

Alternative Management Plan

Sclerotherapy: Some success has been reported with percutaneous ethanol sclerotherapy of TGDCs, and this may be a consideration for patients who are poor surgical candidates.

DISCUSSION

Evidence-Based Medicine Question

TGDCs are the most common congenital midline cervical anomalies in children. Primary surgical excision using the Sistrunk procedure is the recommended management. This entails an en bloc excision of the cyst and its tract to the foramen cecum, including the midportion of the hyoid bone with cuff of tissue from the base of the tongue in the specimen. When untreated, recurrent infections, fistulas to skin, and signs of obstruction from increasing size of the lesion can occur. The Sistrunk procedure is a relatively safe procedure with low complications and risks, and when done properly, this has a very low recurrence risk for the cyst. The procedure is also adequate treatment for incidentally discovered thyroid cancer in the TGDC.

Editorial Comment

What other options exist for TGDC and what are the risks and benefits?

A number of small series have reported some success with percutaneous sclerotherapy of TGDCs. However, there are risks associated such as inflammation, hematoma, fever, or hypersensitivity. In addition, the subsequent excision of lesion, if there is recurrence, can become more difficult due to leaked sclerotic agents that can cause tissue inflammation and scarring. A transoral approach, endoscopically assisted, has been reported recently with the benefit of not producing an external scar. However, no long-term results and subsequent reports are available.

Samantha Anne

Access the review questions and additional sources list online at http://www.expertconsult.com

REFERENCES

1. Galluzzi F, Pignataro L, Gaini RM, et al. Risk of recurrence in children operated for thyroglossal duct cysts: a systematic review. J Pediatr Surg 2013;48(1):222–227. http://dx.doi.org/10.1016/j.jpedsurg.2012.10.060.
2. Lee DH, Jung SH, Yoon TM, et al. Preoperative computed tomography of suspected thyroglossal duct cysts in children under 10 years of age. Int J Pediatr Otorhinolaryngol 2013;77(1):45–48.
3. Fancy T, Gallagher 3rd D, Hornig JD. Surgical anatomy of the thyroid and parathyroid glands. Otolaryngol Clin N Am 2010;43(2):221–227. http://dx.doi.org/10.1016/j.otc.2010.01.001.
4. Deaver MJ, Silman EF, Ltfipour S. Infected thyroglossal duct cyst. West J Emerg Med 2009;10(3):205.
5. Brousseau VJ, Solares CA, Xu M, et al. Thyroglossal duct cysts: presentation and management in children versus adults. Int J Pediatr Otorhinolaryngol 2003;67(12):1285–1290.
6. Shahin A, Burroughs FH, Kirby JP, et al. Thyroglossal duct cyst: a cytopathologic study of 26 cases. Diagn Cytopathol 2005;33(6):365–369.
7. Branstetter BF, Weissman JL, Kennedy TL, et al. The CT appearance of thyroglossal duct carcinoma. Am J Neuroradiol 2000;21:1547–1550.
8. Perkins JA, Inglis AF, Sie KC, et al. Recurrent thyroglossal duct cysts: a 23-year experience and a new method for management. Ann Otol Rhinol Laryngol 2006;115:850–856.
9. Ahuja AT, Wong KT, King AD, et al. Imaging for thyroglossal duct cyst: the bare essentials. Clin Radiol 2005;60(2):141–148.

REVIEW QUESTIONS

1. Which of the following structures does not need to be removed as part of the Sistrunk procedure?
   a. Cuff of tissue at base of tongue
   b. Mid-section of hyoid
   c. Adherent dermis in an infected cyst
   d. Lesser horn of the hyoid

2. Which of the following does not increase the chance of recurrence of a cyst?
   a. History of prior surgical excision
   b. History of prior infection
   c. Incomplete removal of the cuff of tissue at base of tongue
   d. Removal of 1 to 2 cm of mid-hyoid bone as part of resection of specimen

3. Which is not an advantage of using ultrasound as an initial test for TGDC?
   a. Doesn't require anesthesia usually
   b. Avoids radiation
   c. Shows clear delineation of extent of lesion and markers of malignancy
   d. Inexpensive

ADDITIONAL SOURCES

Bratzler DW, Dellinger EP, Olsen KM, et al. Clinical practice guidelines for antimicrobial prophylaxis in surgery. Am J Health Syst Pharm 2013;70(3):195–283.

Chow TL, Choi CY, Hui JY. Thyroglossal duct cysts in adults treated by ethanol sclerotherapy: a pilot study of a nonsurgical technique. Laryngoscope 2012;122(6):1262–1264. http://dx.doi.org/10.1002/lary.23254. PubMed PMID: 22461135.

201 Branchial Cleft Cysts and Sinuses

Steven Hamilton, Michael Cunningham

INTRODUCTION

Anomalies of branchial derivation should always be considered in the differential diagnosis of a mass in the neck, particularly in children but also in adults. Such anomalies are second only to thyroglossal duct cysts as the most common masses of congenital origin and are the most common congenital masses presenting in the lateral neck.[1] Depending on the branchial cleft or pouch of origin, these anomalies can manifest anywhere from the auricular region to the supraclavicular fossa. They are most commonly located in the anterior neck, lateral to the midline and medial to the sternocleidomastoid (SCM) muscle. A branchial anomaly can present as a cyst, sinus, or fistula. The differential diagnosis of branchial cysts includes dermoid cysts and lymphatic vascular malformations. Infected branchial cysts can mimic suppurative cervical lymphadenitis. Cystic malignant metastases must be ruled out in adults. The physical presence of a cutaneous sinus or fistula tract strengthens this diagnosis.

The surgical management of these anomalies varies depending on the cleft or pouch of origin and whether the anomaly is a cyst, sinus, or fistula. A detailed knowledge of the embryology of these lesions is therefore necessary for both definitive diagnosis and proper therapeutic intervention.

KEY LEARNING POINTS

- A branchial anomaly may present as a cyst, sinus tract, or fistula tract.
- The anatomic location of the cyst, sinus, or fistula reflects the branchial system of origin.
- A variety of imaging studies—ultrasonography, computed tomography (CT), magnetic resonance imaging (MRI), and contrast swallow studies—can enhance diagnostic accuracy and surgical management.
- In adults, the possibility of a malignant metastasis with cystic degeneration should be ruled out before an anterolateral neck cyst is excised.
- Incision and drainage of infected branchial cysts should be avoided if possible; needle aspiration is preferred to avoid disrupting the cyst.
- Complete surgical excision is the definitive therapy for most branchial anomalies.
- Operative direct laryngoscopy should be performed prior to the excision of an inferior anterolateral neck mass of suspected third or fourth branchial origin to rule out the possibility of an internal sinus tract communicating with the pyriform sinus.
- The risk of postoperative recurrence of all branchial anomalies increases if there has been previous infection or unsuccessful surgical intervention.

PREOPERATIVE PERIOD

Preoperative Assessment

The proper surgical management of branchial anomalies requires detailed knowledge of the embryology and anatomy associated with this system.

Many of the symmetrically paired structures of the head and neck arise from the branchial system, which appears during the fourth to seventh weeks of fetal development as six ridges on the superolateral surface of the head. These ridges are known as branchial arches owing to their resemblance to the gill arches of fish. Each arch represents a condensation of mesoderm, from which cartilage, muscle, and bone will form. The arches are separated from one another by an external cleft of ectodermal origin and an internal pouch of endodermal origin. As fetal maturation proceeds, most of the external clefts and internal pouches resorb and the arches fuse. Anomalies of the branchial system can form from any aberration in this process including failure of the external clefts and internal pouches to recede. Anomalies of the branchial system present in any of three distinct forms: sinus tracts, fistula tracts, and cysts. A sinus tract opens into either the pharynx or the skin and ends blindly in the neck; it is representative of a vestigial pouch or cleft. A fistula tract has both cutaneous and pharyngeal communications and is thought to arise from a persistence of both cleft and pouch with dissolution of the dividing plate. A branchial cyst is essentially a residual pouch or cleft with no external or internal communication. The anatomic location of the cyst, sinus, or fistula reflects the branchial system of origin, designated by the superior of the two arches (first, second, third, or fourth) separated by the cleft and pouch (Fig. 201.1).

Branchial anomalies most commonly arise from the second (65% to 90%) and first (8% to 25%) branchial systems; anomalies of the third and fourth systems are comparatively rare.[2] Third and fourth branchial anomalies have a left-sided predominance; second branchial anomalies tend to occur more often on the right.[3] Although these lesions can manifest at any age, the average age of presentation is less than 5 years, and no gender predilection is apparent. Branchial cleft anomalies with cutaneous sinus or fistula tracts are typically apparent at birth; cysts and branchial pouch anomalies with pharyngeal communications tend to present later in life. Within the adult population, the mean age of diagnosis of branchial cysts has been reported as 40 years, with a slight female predominance.

First Branchial Anomalies

First branchial cleft anomalies are often divided into two subgroups or types. The historic Work classification system is based on histopathology.[4] Work type I anomalies consist of only ectodermal (squamous epithelium) elements representative of exclusively cleft remnants. Work type II anomalies consist of both ectodermal (squamous epithelium) and mesodermal (cartilage) elements reflective of both cleft and arch remnants.

Subsequent anatomic classifications have greater surgical relevance. Type I anatomic anomalies manifest as a sinus tract and/or cyst (Fig. 201.2A). If there is a cutaneous opening, it is located anterior, inferior, or (rarely) posterior to the auricle above the level of the mandible. The sinus tract or cyst in type I anomalies is superficial to the parotid gland and facial nerve; the tract typically parallels but does not communicate with the external auditory canal, ending blindly.

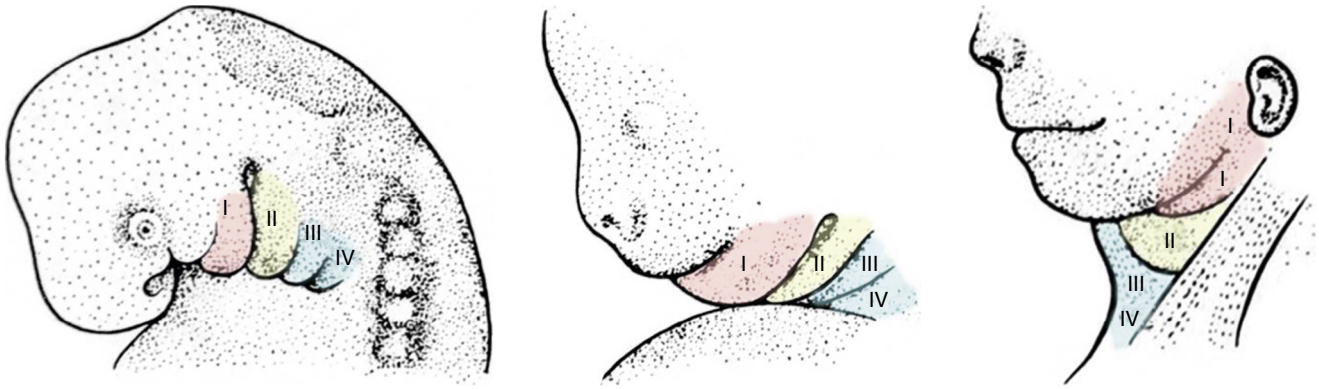

Fig. 201.1. Schematic diagram of the developing branchial system. I - First branchial apparatus, II - Second branchial apparatus, III - Third branchial apparatus and IV - Fourth branchial apparatus.

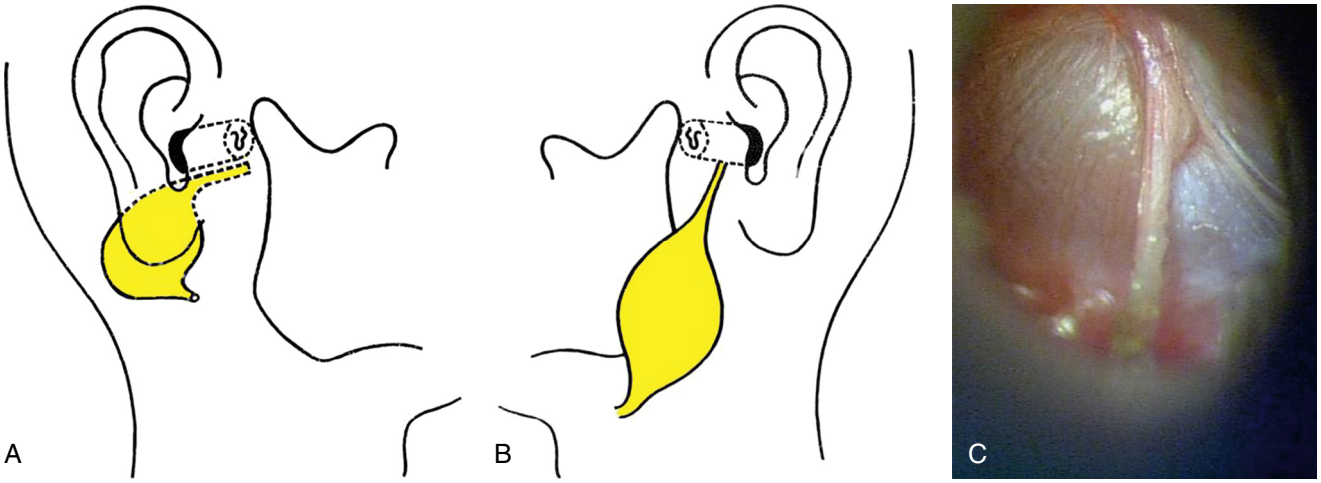

Fig. 201.2. A, Type I first branchial anomaly. **B,** Type II first branchial anomaly. **C,** Extension of a type II first branchial anomaly to the tympanic membrane.

A type II anatomic anomaly may present as a sinus tract, fistula tract, or cyst (see Fig. 201.2B). The cutaneous cervicofacial opening, if present, is typically at or below the angle of the mandible and always superior to the level of the hyoid. The course of the sinus or fistula tract or location of the cyst is highly variable with respect to the parotid gland and facial nerve. Tracts may be superficial or deep to the main branches of the facial nerve and may even course between specific branches. Type II fistula tracts of the first branchial cleft communicate directly with the ipsilateral external ear canal and may even extend to the tympanic membrane (see Fig. 201.2C).

Second Branchial Anomalies

A second branchial anomaly may present as a cyst, sinus tract, or fistula tract. Isolated branchial cysts most commonly originate from the second branchial system. On histopathologic examination, lymphoid tissue is characteristically found within the cyst walls. The external opening of a second branchial cleft remnant, if present, is typically found at the anterior border of the SCM muscle, always inferior to the level of the hyoid bone and superior to the level of the cricothyroid cartilages. The course of a complete second branchial fistula tract would run superior and lateral to both the glossopharyngeal and hypoglossal nerves and then between the internal and external carotid arteries, opening internally into the ipsilateral tonsillar fossa (Fig. 201.3A).

Third Branchial Anomalies

Anomalies of the third branchial system are most often sinus tracts or cysts; the occurrence of a true fistula is very rare. The pharyngeal opening of a third branchial pouch remnant, is within the base of the ipsilateral pyriform sinus. An internal sinus tract runs transversely from the thyrohyoid membrane into the neck, then traveling inferior and posterior to the glossopharyngeal nerve and superior to the hypoglossal nerve and finally coursing posterior to the internal carotid artery. The cutaneous opening of a third branchial cleft remnant is typically in the anteroinferior neck at the anterior border of the SCM (see Fig. 201.3B). A third branchial cyst may occur anywhere along this theoretical course. Because of the pharyngeal pouch component of a third branchial anomaly, thymic tissue may be present within the cyst walls; some consider cysts of the third branchial pouch to be synonymous with thymic (thymopharyngeal) cysts.

Fourth Branchial Anomalies

Fourth branchial anomalies likewise manifest solely as sinus tracts or cysts. A complete fistula tract would be highly unlikely given its predicted long tortuous course (see Fig. 201.3C). Similar to third branchial anomalies, the cutaneous opening of a fourth branchial cleft remnant, if present, is in the anteroinferior neck at the anterior border of the SCM. In contrast to third branchial anomalies, the internal opening of a fourth

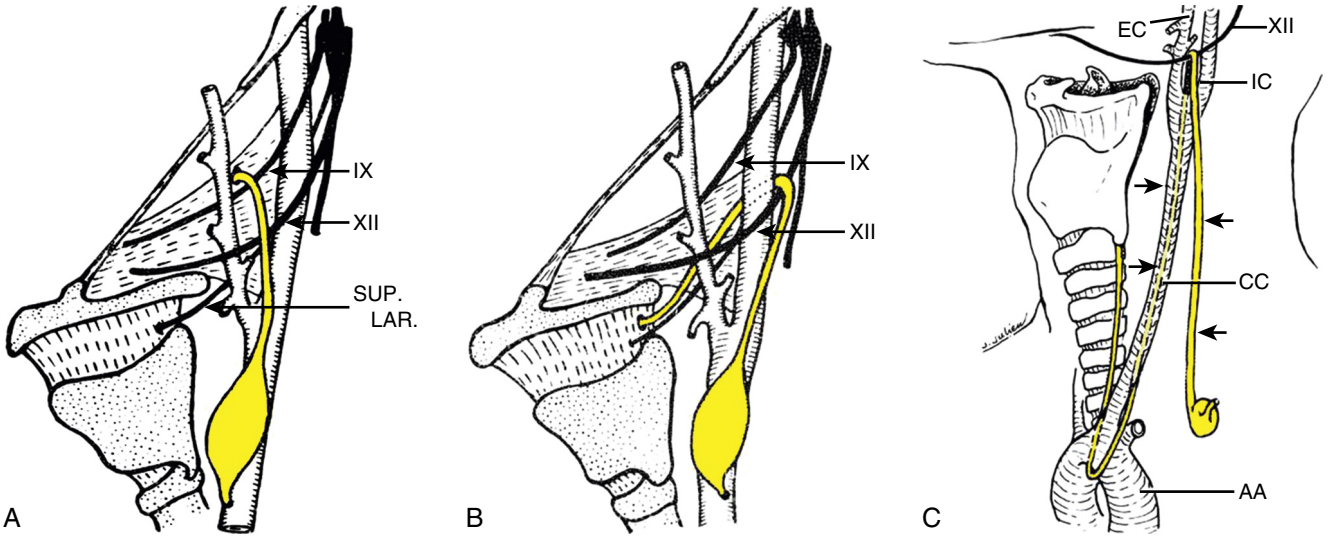

Fig. 201.3. A, Second branchial anomaly. **B,** Third branchial anomaly. **C,** Fourth branchial anomaly. IX - Glossopharyngeal Nerve, XII - Hypopharyngeal Nerve, Sup. Lar. - Superior Laryngeal Nerve, EC - External Carotid Artery, IC - Internal Carotid Artery, CC - Common Carotid Artery.

branchial pouch remnant should be at the apex, not base, of the ipsilateral pyriform sinus. An internal sinus tract arising from the apex of the pyriform sinus would pierce the cricothyroid membrane to enter the neck, theoretically coursing inferiorly and deep to the superior laryngeal nerve and superficial to the recurrent laryngeal nerve. This course would bring the tract into close proximity to the superior pole of the ipsilateral thyroid gland.

Given the anatomic course of third and especially fourth branchial anomalies, abscess formation or recurrent infection of the thyroid gland should raise suspicion of a third or more likely fourth branchial pouch remnant. An internal communication to the ipsilateral pyriform sinus must be ruled out in such cases.

Clinical History

1. Presenting history
   a. When and how did the anomaly first present (cervicofacial cutaneous opening, evident neck mass, or both)?
   b. Has there been any evidence of secondary infection such as fluctuation in size, pain, or erythema of the overlying skin? (This could be due to an internal pharyngeal communication or the activation of lymphoid aggregates in the cyst wall secondary to an upper respiratory tract infection.)
   c. If a cervicofacial cutaneous opening is present, has there been drainage? (This would most likely be due to glandular secretions from the lining of the sinus tract but could also reflect saliva if there were a true fistula with a pharyngeal communication.)
   d. Has there been any evidence of compromise to the aerodigestive tract, such as dysphagia or stridor?
2. Past medical/surgical history
   a. Confirmed previous infection?
   b. Previous surgical intervention such as needle aspiration or incision and drainage?
3. Family history
   a. Similar presentation?
   b. Syndromic background?
   c. Bleeding disorders or adverse reactions to general anesthesia (in preparation for surgical excision)?
4. Medications
   a. Particularly any medications that would complicate anesthesia or increase the risk of hemorrhage
5. Social history
   a. A history of alcohol and/or tobacco use is of significance in adults owing to the possibility of cystic cervical neoplastic metastases.

Physical Examination

- Complete examination of the head and neck with a focus on the anatomic location and size of the neck mass as well as the presence of any ipsilateral or bilateral cervicofacial cutaneous openings. A detailed examination of the ear is particularly important if there are any periauricular sinus tract openings.
- A flexible endoscopic laryngopharyngeal examination is necessary in adults to look for a primary malignancy; such an examination, unfortunately, would not be an adequate means of establishing the presence or absence of a tract in the pyriform sinus.
- Evaluation for other craniofacial and systemic physical examination findings suggestive of an underlying syndrome
  - Branchio-oto-renal (BOR) syndrome: Hearing loss, preauricular appendages or tags, malformations of the pinna, stenosis/atresia of the external auditory canal, mild to severe renal impairment
  - Oculo-auriculo-vertebral (Goldenhar, hemifacial microsomia) spectrum: Facial asymmetry, malformations of the pinna and external ear canal, preauricular tags or pits, conductive hearing loss, aplasia or hypoplasia of the mandibular condyle, ophthalmologic abnormalities
  - DiGeorge syndrome: Complete or partial absence of the thymus gland; micrognathia; small low-set ears; blunting, clefting, or indentation of the nose; hypertelorism; cardiac anomalies; cleft palate; hypocalcemia/hypoparathyroidism
  - Treacher Collins (mandibulofacial dysostoses) syndrome: Downward-sloping palpebral fissures, depressed cheek bones, malformed pinna, Pierre Robin sequence, malformations of the external and middle ear, short neck
- Fine-needle aspiration of a cystic mass in the neck in adults is recommended to rule out the possibility of a cervical metastasis.

Imaging Studies

- Ultrasonography is useful as an initial imaging modality, particularly in children, because it is easily obtained and avoids radiation exposure. The ultrasonographic characteristics of a branchial cyst include uniform low echogenicity and lack of internal septation with no acoustic enhancement. Ultrasound can distinguish solid from cystic masses and facilitate fine-needle aspiration if indicated. Three-dimensional ultrasonography has been used to diagnose large branchial cysts prenatally.[5]
- High-resolution CT with contrast is the most widely used imaging modality for a mass in the neck owing to its relative ease of use and clear demarcation of the size, depth, and location with respect to surrounding anatomic structures. A branchial cyst typically appears as a well-defined nonenhancing mass. Sinus and fistula tracts are typically visible on CT only if there is distention of the tract secondary to associated infection or inflammation. If an external cutaneous opening is present, a contrast CT fistulogram may be performed to outline the tract. The main drawback of CT is the associated radiation exposure and potential need for sedation in children.
- MRI with gadolinium contrast is an alternative to CT because of the lack of radiation exposure and excellent soft tissue detail. It is especially helpful with respect to lesions in the parotid gland region to help define the relationship of the mass to the facial nerve. A branchial cyst typically is hypointense on T1 imaging, hyperintense on T2 imaging, and does not enhance with gadolinium. Disadvantages include the comparatively high expense, study duration, and frequent need for sedation and possibly general anesthesia in children.
- A contrast swallow study may be useful in the evaluation of patients with recurrent neck abscesses or suppurative thyroiditis. Such studies should be performed after the acute inflammation has resolved. An internal tract arising in the pyriform sinus should be sought (Fig. 201.4C).

Surgical Indications

- Previous mass in the neck, infection, or draining cutaneous tract
- A symptomatic mass in the neck
- Progressive enlargement of a mass
- Cosmetic deformity
- Diagnostic confirmation

Contraindications

- Patient not fit for general anesthesia

Relative Contraindications

- The excision of an acutely infected branchial anomaly should be avoided if possible owing to increased postoperative morbidity and the risk of recurrence.
- In a healthy infant with a nondraining cutaneous sinus or fistula tract, surgical excision may be delayed for a few years to allow for a larger operative field and decreased risk of injury to surrounding structures. Such a delay also avoids the use of general anesthesia in an infant, given recent concerns of potential adverse effects on the child's subsequent neurologic development.[6] Any other comorbid condition that would preclude surgery under normal circumstances would also constitute a relative contraindication.

Preoperative Preparation

- Suspected infection of a branchial anomaly should ideally be managed before an attempt at definitive resection of the lesion. Systemic oral or parenteral antibiotic therapy is necessary.
- Needle aspiration may enhance medical management and provide a sample of infected material for culture-driven antimicrobial therapy.
- Incision and drainage of infected branchial cysts occasionally proves necessary. If at all possible, this should be avoided so as to prevent disruption of the cyst wall and formation of fibrosis with a view to future excision.

OPERATIVE PERIOD

Anesthesia

- General anesthesia is typically necessary.
- Neuromuscular blockade is contraindicated to allow for intraoperative neural monitoring, particularly in type II first branchial anomalies (facial nerve monitoring) and third and fourth branchial pouch anomalies (recurrent laryngeal nerve monitoring).
- A local anesthetic with epinephrine is often additionally used on the skin for hemostasis.

Positioning

- Positioning may depend on the specific location of the lesion. Patients are typically supine, and a shoulder roll and rotation of the head are often used to enhance exposure.

Perioperative Antibiotic Prophylaxis

- Antibiotics should be administered per standard head and neck procedural prophylaxis protocol. Antimicrobial coverage may have to be broadened in the event of a recent or concurrent infection.
- Postoperative antibiotics may be indicated for intraoperative evidence of infection or the need for postoperative wound drainage.

Instruments and Equipment to Have Available

- Standard head and neck surgical set
- Monopolar and bipolar electrocautery
- Laryngoscopes and telescopes for direct laryngoscopy and pharyngoscopy
- Lacrimal probes, catheters, and blunt needles for possible methylene blue injection to help define a sinus or fistula tract
- Electrophysiologic neural monitoring capability

Key Anatomic Landmarks

- See the sections titled "Preoperative Period" and "Surgical Technique."

Prerequisite Skills

- Surgical competence with respect to parotidectomy, thyroidectomy, and neck dissection procedures

Operative Risks

- The patient and/or guardians should give consent regarding intraoperative risks to adjacent anatomic structures (particularly facial nerve injury with first branchial anomalies and recurrent laryngeal nerve injury with third and fourth branchial anomalies), immediate postoperative risks (infection and hematoma or seroma formation), and longer-term postoperative risks (scar formation and recidivism/recurrence).

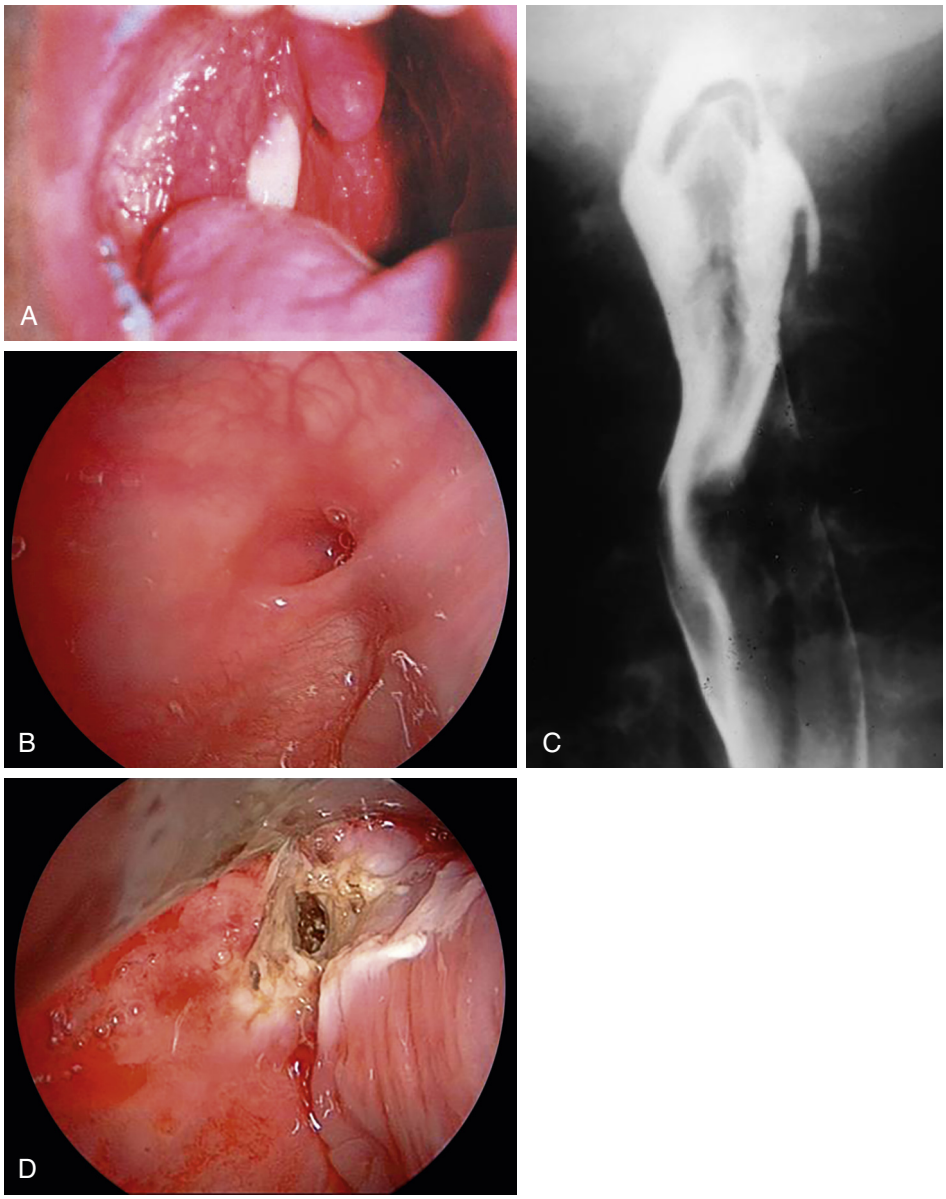

Fig. 201.4. A, Sinus opening within the tonsillar fossa. **B,** Sinus opening at the apex of the pyriform sinus. **C,** Contrast swallow study revealing a communication from the left pyriform sinus into the neck. **D,** Cauterization of pyriform sinus opening.

Surgical Technique

1. First branchial anomalies
   a. The goal of surgery for type I first branchial anomalies is complete excision of the sinus tract and/or cyst. The sinus tract may be defined with a lacrimal probe or injection of methylene blue. This is ideally completed prior to the administration of local anesthetic. An elliptical incision is outlined around the tract. If possible, this may be oriented within the auricular crease. If the site is too distant from the auricle to do so, an ellipse around the sinus opening and a separate incision within the auricular crease may be necessary (Fig. 201.5A and B). Since type I lesions are always superficial to the parotid gland, the parotid and temporalis fasciae serve as ideal landmarks with respect to the depth of excision. Superficial to these tissue planes, a cuff of soft tissue surrounding the sinus tract and cyst can be excised in a circumferential fashion toward the external ear canal. Care is taken to make sure that no violation of the tract or cyst takes place. A shave excision of tragal or external ear canal perichondrium and cartilage is typically necessary at the termination site of the tract. The wound is irrigated and the incision closed in layered fashion. Placement of a drain is infrequently required.
   b. The goal of surgery for type II first branchial anomalies is complete excision of the sinus/fistula tract and cyst. In contrast to type I anomalies, type II anomalies require a superficial parotidectomy approach for identification and preservation of the facial nerve; this is facilitated by intraoperative facial nerve monitoring. An elliptical incision is made around the cutaneous cervicofacial opening, as is a standard S-shaped parotidectomy incision within the preauricular crease extending inferiorly over the mandible (see Fig. 201.5C and D). The procedure

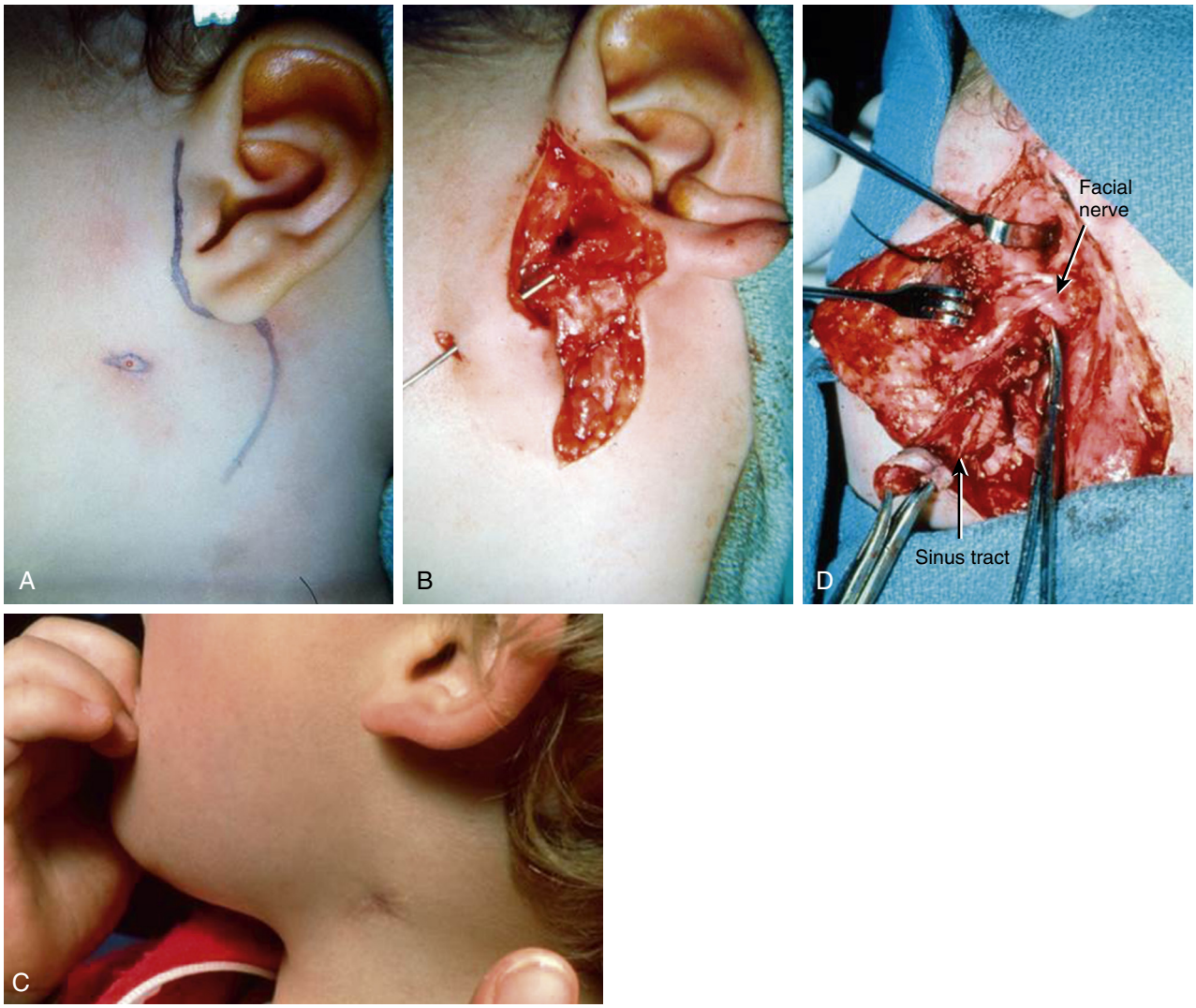

Fig. 201.5. A, Preauricular pit with planned excision of type I first branchial anomaly. **B,** Lacrimal probe following course of type I sinus tract. **C,** Skin defect associated with type II first branchial anomaly. **D,** Excision of type II first branchial anomaly with identification of the facial nerve.

is carried out concurrently on two fronts. The tract, potentially demarcated as described for type I lesions, is carefully dissected with a surrounding cuff of skin and soft tissue toward the parotid gland. The superficial parotidectomy allows initial identification of the facial nerve trunk and subsequent clarification of the course of the tract relative to the branches of the facial nerve. This approach also clearly demarcates the external auditory canal, into which a type II fistula tract will penetrate. A portion of the cartilaginous canal may have to be excised to remove the tract completely. The wound is irrigated and the incision closed in a layered fashion, typically over a small suction drain.

2. Second branchial anomalies
   a. A cyst of suspected second branchial origin is managed similar to any isolated mass in the neck. An incision is placed in a skin crease either overlying or just inferior to the mass. If there is a scar from a previous incision and drainage site, this is incorporated into the incision. Subplatysmal flaps are elevated, and the anterior border of the SCM muscle is identified and retracted. The cystic mass, once clearly defined, is dissected in circumferential fashion, care being taken to avoid disruption of the cyst. A large mass may benefit from decompression using needle aspiration to facilitate atraumatic removal. Once the mass has been removed, the wound is irrigated and the incision closed in a layered fashion, typically over a small suction drain.
   b. For sinus or fistula tracts of suspected second branchial cleft origin with a cutaneous opening, an elliptical incision is outlined around the site of the sinus/fistula. The tract can be further defined with a lacrimal probe, a flexible catheter, or methylene blue injection if desired. A cuff of connective tissue surrounding the tract is excised in order to be certain that all epithelial components have been removed. The anterior border of the SCM muscle is identified and retracted, and the tract is traced both medially and superiorly. A second parallel "step-ladder" incision may have to be made cephalad to the first incision to facilitate the removal of long tracts; this allows for the avoidance of disfiguring vertical scars (Fig. 201.6). The majority of second branchial cleft remnants are sinus tracts that end blindly. However, a true fistula tract extending to the pharynx at the level of the tonsillar fossa is possible (see Fig. 201.4A). An ipsilateral tonsillectomy is sometimes necessary in such cases to allow for adequate access to the pharyngeal communication so that it can be closed.



Fig. 201.6. "Stepladder" incision used to remove a long fistula or sinus tract.

3. Third and fourth branchial anomalies
   a. Sinus tracts of third and fourth branchial cleft origin are typically short tracts that end blindly at the border of the SCM muscle or just deep to it. They are managed in identical fashion to second branchial cleft anomalies, with the important proviso of preparation for the possibility of longer, deeper tracts following the embryologic anatomy described earlier in this chapter.
   b. Third and fourth branchial pouch anomalies pose a much more significant operative challenge. Historically these lesions have been approached via a lateral-to-midline curvilinear incision designed to allow adequate exposure of the ipsilateral aspect of the laryngotracheal airway. Both the thyrohyoid (third pouch) and cricothyroid (fourth pouch) membranes need to be identified to determine the origin of the branchial pouch tract. An ipsilateral thyroid lobectomy may be necessary to identify the tract, especially if there has been previous inflammation with subsequent scarring. A thyroid lobectomy in such circumstances also facilitates identification of the recurrent laryngeal nerve. Intraoperative monitoring of the recurrent laryngeal nerve additionally enhances the likelihood of preserving neural function.[7]
   c. Concurrent with the external approach already described, direct laryngoscopy and pharyngoscopy is highly recommended to identify a suspected pyriform sinus communication (see Fig. 201.4B). The location of this opening at either the base or apex of the pyriform sinus can guide the external exploration, as can the passage of a catheter into the sinus tract.
   d. Solely endoscopic management of identified pyriform sinus tract openings is an initial alternative to transcervical resection. Electrocauterization with a Bugbee diathermy electrode or chemical cauterization with sliver nitrate or trichloroacetic acid (TCA) has been used to scarify the opening of the pyriform sinus, ideally eliminating the pharyngeal communication and egress of bacteria-laden secretions into the neck (see Fig. 201.4D). Cure rates of 78% and 75% have been reported with electrocauterization and TCA cauterization respectively.[8,9]
   e. Third and fourth branchial pouch anomalies refractory to such endoscopic and external approaches can be managed via a hypopharyngeal pharyngoplasty, which entails stapling of the pyriform sinus defect (Fig. 201.7).[10] This technique may even be considered the first alternative if endoscopic management fails.

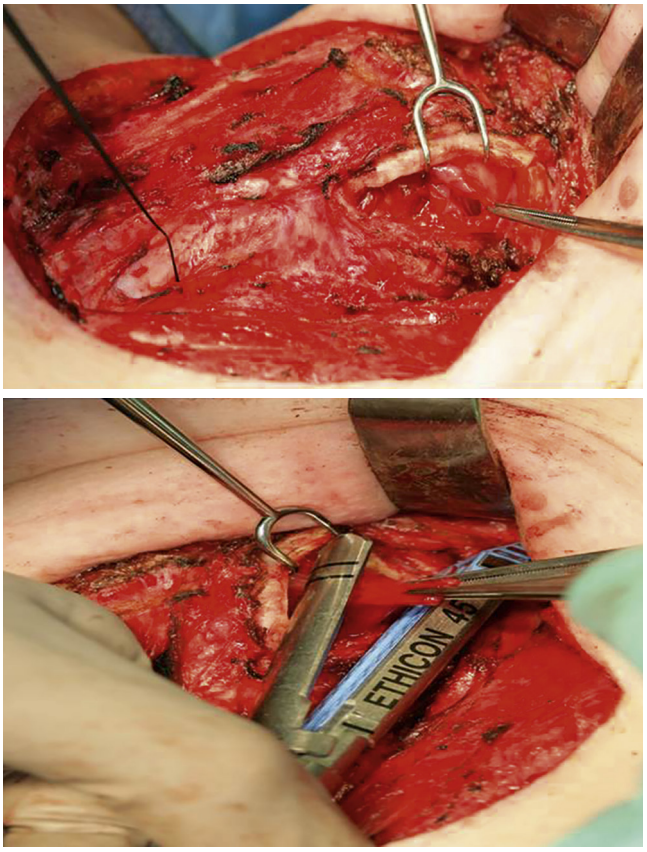

Fig. 201.7. Hypopharyngeal pharyngoplasty technique; the pyriform sinus defect is first identified and then stapled.

Common Errors in Technique

- See the section titled "Complications."

POSTOPERATIVE PERIOD

Postoperative Management

- Postoperative admission is necessary for those cases requiring drain placement.
- Standard postoperative management of neck incision is followed.

Complications

- Potential short-term postoperative complications include wound infection and hematoma or seroma formation. Appropriate surgical technique and drain utilization will typically suffice to prevent these complications.
- Failure to completely excise a sinus or fistula tract may lead to recurrent clinical manifestations. Subsequent surgery in such situations can be challenging. Whereas recurrence rates are approximately 3% for branchial anomalies with no preceding surgeries or infections, this rate rises to approximately 20% if there was a previous unsuccessful surgery. The recurrence rate following the excision of a sinus or fistula tract is approximately twice that following the excision of an isolated cyst.[2]
- Failure to properly identify and monitor the facial nerve when a type II anomaly of the first branchial cleft is being excised increases the risk of postoperative facial nerve paresis.

- The excision of second, third, and fourth branchial anomalies potentially places cranial nerves IX, X, XI, and XII at risk. Fibrosis from previous surgery or infection makes this morbidity more likely. The identification and monitoring of the recurrent laryngeal nerve when anomalies of the third or fourth branchial pouch are being excised can lessen this risk.[7]
- Unidentified entry into the pharynx during procedures involving anomalies of a branchial pouch can lead to pharyngocervical fistula formation and wound infection.

DISCUSSION

Evidence-Based Medicine Question

What are the treatment options for pyriform sinus third and fourth branchial pouch openings?

See the previous discussion on the treatment of third and fourth branchial anomalies.

Editorial Comment

Branchial cysts and sinuses are the second most common congenital neck masses. Knowledge of the embryology of the branchial apparatus is crucial for making an accurate diagnosis, understanding the anatomy of these lesions, and excising them successfully. Despite advances in diagnostic modalities, ultrasound remains the imaging modality of choice in an uncomplicated branchial anomaly, with CT and MRI being reserved for the more complex lesions. The surgical management of branchial cysts and sinuses has remained essentially the same over the years except for the addition of endoscopic management of third and fourth branchial anomalies. The first attempt at excision represents the best chance for complete excision of the branchial anomaly, as the recurrence rate tends to increase with previous surgical procedures and infections.

Sukgi Choi

Access the review questions and additional sources and online at http://www.expertconsult.com



REFERENCES

1. LaRiviere CA, Waldhausen JH. Congenital cervical cysts, sinuses, and fistulae in pediatric surgery. Surg Clin N Am 2012;92(3):583–597.
2. Choi SS, Zalzal GH. Branchial anomalies: a review of 52 cases. Laryngoscope 1995;105:909–913.
3. Maddalozzo J, Rastatter JC, Dreyfuss HF, et al. The second branchial cleft fistula. Int J Pediatr Otorhinolaryngol 2012;76(7):1042–1045.
4. Work WP. Newer concepts of first branchial cleft anomalies. Laryngoscope 1972;82:1581–1593.
5. Tsai PY, Chang CH, Chang FM. Prenatal imaging of the fetal branchial cleft cyst by three-dimensional ultrasound. Prenat Diagn 2003;23:599–610.
6. Jevtovic-Todorovic V. Anesthesia and the developing brain: are we getting closer to understanding the truth? Curr Opin Anaesthesiol 2011;24(4):395–399.
7. White WM, Randolph GW, Hartnick CJ, et al. Recurrent laryngeal nerve monitoring during thyroidectomy and related cervical procedures in the pediatric population. Arch Otolaryngol Head Neck Surg 2009;135(1):88–94.
8. Chen EY, Inglis AF, Ou H, et al. Endoscopic electrocauterization of pyriform fossa sinus tracts as definitive treatment. Int J Pediatr Otorhinolaryngol 2009;73(8):1151–1156.
9. Kim KH, Sung MW, Koh TY, et al. Pyriform sinus fistula: management with chemocauterization of the internal opening. Ann Otol Rhinol Laryngol 2000;109(5):452–456.
10. Richer SL, Yelken K, Cunningham MJ, et al. Hypopharyngeal pharyngoplasty for the management of piriform fossa sinus. Laryngoscope 2010;120:500–503.

REVIEW QUESTIONS

1. While excising a congenital mass in the neck, a sinus tract is noted that runs between the internal and external carotid arteries and travels both superior and lateral to the glossopharyngeal and hypoglossal nerves. This tract is mostly likely an anomaly of what branchial apparatus?
   a. First
   b. Second
   c. Third
   d. Fourth

2. During the operative excision of a suspected branchial cleft cyst and tract, the tract is noted to course posterior to the internal carotid artery and between cranial nerves IX and XII. The internal communication of this tract is expected to course to the
   a. Tonsillar fossa
   b. Apex of the pyriform sinus
   c. Base of the pyriform sinus
   d. External auditory canal

3. Which of the following syndromes is associated with branchial anomalies?
   a. DiGeorge syndrome
   b. Down syndrome
   c. Apert syndrome
   d. Pendred syndrome

ADDITIONAL SOURCES

Androulakis M, Johnson JT, Wagner RL. Thyroglossal duct and second branchial cleft anomalies in adults. Ear Nose Throat J 1990;69: 318–322.

Chandler JR, Mitchell B. Branchial cysts, sinuses and fistulas. Otolaryngol Clin N Am 1981;14:175–186.

Reynolds JH, Wolinski AP. Sonographic appearance of branchial cysts. Clin Radiol 1993;48:109–110.

Schroeder JW, Mohyuddin N, Maddalozzo J. Branchial anomalies in the pediatric population. Otolaryngol Head Neck Surg 2007;137(2):289–295.

Som PM, Smoker WRK, Curtin HD, et al. Congenital lesions of the neck. In: Som PM, Curtin HD, editors. Head and Neck Imaging. 5th ed. St Louis, MO: Elsevier & Mosby publishers; 2011. p. 2235–2252.

202 Mandibular Distraction

Noel Jabbour, Jesse Goldstein

INTRODUCTION

The classic Pierre Robin sequence (PRS) refers to a constellation of physical findings characterized by microretrognathia and glossoptosis; cleft palate is an associated feature but is not required for the diagnosis of PRS. The posterior displacement of the base of the tongue functionally obstructs the airway, causing apnea, stridor, difficulty with feeding, and retarded growth. The clinical severity of this obstruction can range from subtle hypopneas, which may be noted only on a sleep study, to dramatic life-threatening respiratory compromise that requires emergent airway intervention.

Initial nonsurgical management of tongue-base-related obstruction includes prone positioning and placement of a nasopharyngeal airway. However, these measures may complicate already tenuous feedings and may increase the risk for sudden infant death in an unmonitored setting. Tongue-base-related obstruction has traditionally been surgically addressed by tracheostomy to bypass the obstruction. However, this carries a low, but real risk of mortality from mucous plugging and other airway compromise. For this reason, other surgical options, including tongue-lip adhesion (TLA) were developed to address the retrodisplacement of the tongue. However, high rates of dehiscence, feeding difficulties, and recurrence of obstruction have been reported.[1]

Mandibular distraction osteogenesis (MDO) has gained popularity as a treatment to address the underlying microretrognathia, which leads to tongue base collapse. While distraction osteogenesis was developed in the 1920s by a Russian orthopedic surgeon, it was not adapted for use in the mandible until the 1990s, and was not applied to neonatal patients with PRS until more recently. Since then, several studies have demonstrated objective improvement in both feeding and airway measures, including reduced apnea-hypopnea index, relief of hypoxemia and hypercapnia, and increased rates of per oral nutrition. MDO also has been successfully used to alleviate airway obstruction in patients with other causes for tongue base collapse, including neurologic impairment.[2]

As microretrognathia and glossoptosis occur in a spectrum from mild to severe, careful history taking, physical examination, and preoperative planning is necessary to identify patients who may benefit from MDO.

KEY OPERATIVE LEARNING POINTS

1. Patients with PRS are best treated by an interdisciplinary team, including Pediatric Otolaryngologists, Surgeons trained in craniofacial surgery, Neonatal Intensivists, Pulmonologists, Geneticists, and Speech-Language Pathologists.
2. The diagnosis of PRS is made clinically when microretrognathia and glossoptosis are detected. The normal difference between the maxillary and mandibular arches is usually less than 5 mm. In most infants with PRS requiring airway intervention, this distance of maxillary overjet resulting in class II occlusion is often greater than 10 mm.
3. A full airway evaluation prior to, or coordinated with, MDO is prudent as secondary airway lesions, such as laryngomalacia, subglottic stenosis, or tracheomalacia, are common.
4. Careful handling of soft tissue during access to the infant mandible is essential in avoiding iatrogenic nerve injury.
5. Co-linear vectors are important to maintaining symmetric distraction.

PREOPERATIVE PERIOD

History

1. History of present illness
   a. It is important to take a careful birth history, including prenatal diagnosis by ultrasound or eliciting any complications with pregnancy or delivery.
   b. Birth history should also include any initial airway distress and need for airway intervention, including prone positioning, nasopharyngeal airway, or intubation.
   c. Any symptoms of airway distress including stridor, increased work of breathing, cyanosis, or acute life-threatening events (ALTEs) should be discussed.
   d. If the infant is feeding orally, the parents should be asked about a typical feeding, including the quantity of feeds, the duration of each feeding, and any concerns for aspiration. Decreased volumes or increased time for feeding may indicate a problem with the coordination of breathing and swallowing.
2. Past medical history
   a. A careful review of the birth history, initial hospitalization, previous evaluations, and interventions to address airway and feeding concerns should be undertaken.
   b. Any ALTEs or cardiopulmonary arrests should be discussed.
   c. Other medical issues, congenital anomalies, or known genetic diagnosis should be reviewed.

Physical Examination

1. Examination of the airway
   a. Observation of the infant breathing at rest may reveal signs of stridor or stertor, nasal flaring, subcostal or suprasternal retractions.
   b. Flexible nasolaryngoscopy may be performed at the bedside to assess the patency of the choanae bilaterally, laryngomalacia, and degree of tongue base collapse. Due to the very stimulating nature of the examination,

bedside laryngoscopy likely significantly underestimates the degree of tongue base collapse that exists while the patient is sleeping,

2. Examination of the palate (Fig. 202.1)
   a. A cleft palate is often associated with PRS, but it is not always present and is not essential for the diagnosis. Varying degrees of orofacial clefting can be seen with PRS from a normal palate to a bilateral complete cleft lip and palate. However, a Veau I or Veau II cleft palate is often noted.
3. Examination of the mandible
   a. Measurement of the discrepancy between the central portion of the maxillary alveolar process and the mandibular alveolar process can be made easily by placing the wooden end of a cotton-tipped applicator along the anterior edge of the mandibular gingiva in the midline. The patient can then be placed into occlusion. The maxillary gingiva will then touch the wooden applicator, creating a natural marking on the wood due to saliva. However, if this is unclear, then markings may be made by pinching with two fingers or by a marking pen. The distance from the tip of the applicator to the marking indicates the degree of maxillary overjet. The upper limit of normal is considered to be 5 mm. Care must be taken to avoid posterior pressure on the mandible, which can cause retropositioning of the mandibular condyle out of the immature glenoid fossa, thereby accentuating the maxillary-mandibular discrepancy.
   b. Mandibular asymmetry should be assessed to evaluate for hemifacial microsomia.
4. Craniofacial examination
   a. All patients with suspected PRS should undergo a thorough craniofacial exam ination to evaluate for common accompanying syndromic diagnoses. Evaluation of the shape of the head can identify co-existing craniosynostosis. Orbital morphology can help distinguish Stickler syndrome, 22q deletion syndrome, or Treacher-Collins/Nager syndrome. Malar projection should be noted as should any anomalies of the ear, including microtia, pre-auricular remnants, or branchial arch anomalies. Assessment of the maxillary projection is critically important. Patients with significant maxillary hypoplasia may demonstrate minimal maxilla-mandibular discrepancy despite having severe micrognathia.

Imaging

Computed tomography (CT): a craniofacial CT including 3D reconstructions is carried out in advance of surgery for preoperative planning of osteotomy sites and placement of the distractor (Fig. 202.2).

Indications

1. Patients with tongue base collapse due to microretrognathia who demonstrate signs of airway obstruction by increased work of breathing, desaturation, hypoxemia, hypercapnia, or obstructive sleep apnea on polysomnogram.
2. Patients with tongue base collapse due to microretrognathia who have been intubated and are not able to be safely extubated due to their severe microretrognathia.
3. Patients with an existing tracheostomy who cannot be successfully decannulated due to microretrognathia and tongue base obstruction.

Contraindications

1. Medical co-morbidities with increased risk for general anesthesia.
2. Significant secondary airway lesions that cannot be addressed without tracheostomy.
3. Severe central sleep apnea. In patients with mixed apnea, it has been demonstrated that many of the central apneic events noted on sleep studies improve after resolution of the obstructive component. However, patients with severe central sleep apnea or central hypoventilation will require positive pressure ventilation and should be considered for a tracheostomy.



Fig. 202.1. Preoperative view of oral examination in an infant with Pierre Robin sequence. Microretrognathia, glossoptosis, and a wide Veau II cleft palate are noted.

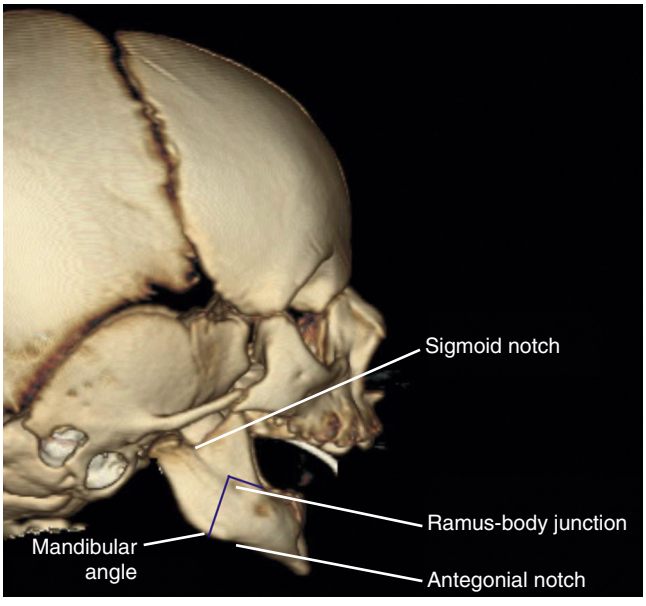

Fig. 202.2. Computed tomography scan of the mandible with 3D reconstruction showing key landmarks in white and planned "inverted-L" osteotomy in blue. This osteotomy position avoids the most posterior developing tooth bud, which is generally located in the position marked "Ramus-Body Junction." Significant maxillary-mandibular discrepancy is noted.

Preoperative Preparation

1. Photo-documentation (Fig. 202.3)
2. Polysomnogram
3. Bedside nasolaryngoscopy
4. Flexible sleep endoscopy and rigid laryngoscopy and bronchoscopy
5. CT scan of mandible with 3D reconstruction

OPERATIVE PERIOD

Anesthesia

General: Intubation of patients with PRS is often very challenging due to the microretrognathia. Assistive devices, such as a videolaryngoscopy, may be helpful in intubation. In our center, we perform laryngoscopy and bronchoscopy with an endotracheal tube loaded on a Hopkins-rod telescope. The endotracheal tube is passed over the Hopkins-rod telescope in a Seldinger technique when the scope is just above the carina. Often a suture in the tongue is employed to distract the tongue anteriorly during laryngoscopy.

Positioning

Supine: The patient is positioned on a shoulder roll such that the neck is extended and able to be turned from side to side.

Perioperative Antibiotic Prophylaxis

Weight-based cephazolin is administered within 30 minutes prior to the skin incision. Prophylactic antibiotics are continued until the extension rods are removed when activation is complete.

Monitoring

None.

Instruments and Equipment to Have Available

1. Fifteen blade
2. Small tenotomy scissors
3. Periosteal elevator
4. Mosquito hemostats
5. Piezoelectric Saw (DePuy Synthes, West Chester, Pennsylvania), or similar
6. KLS Martin Micro-Zurich ratcheting mandibular distractor set (KLS Martin, Jacksonville, Florida), or similar
7. Soft tissue instruments (needle drivers, pickups, suture scissors)
8. Loupe magnification
9. Narrow malleables

Key Anatomic Landmarks

1. Inferior border of the mandible
2. Platysma muscle
3. Deep cervical fascia
4. Submandibular gland
5. Mandibular angle
6. Antegonial notch
7. Retromolar trigone region
8. Sigmoid notch

Prerequisite Skills

1. Experience with submandibular/Risdon approach to the mandible
2. Experience with craniofacial osteotomies and fixation techniques
3. Experience with the surgical care of neonatal patients

Operative Risks

1. Early complications:
   a. Pin-site infection
   b. Hardware failure
   c. Injury to the marginal mandibular nerve
   d. Asymmetry
   e. Failure to relieve airway obstruction
2. Late complications:
   a. Growth restriction/relapse requiring further airway intervention
   b. Inferior alveolar nerve/mental nerve insensibility
   c. Damage to second/third molar tooth follicles

Surgical Technique

- Prepare/drape, excluding the oral cavity from the operative field
- Mark a 2 cm incision 1 cm below the mandibular border extending from the angle anteriorly in a relaxed skin tension line

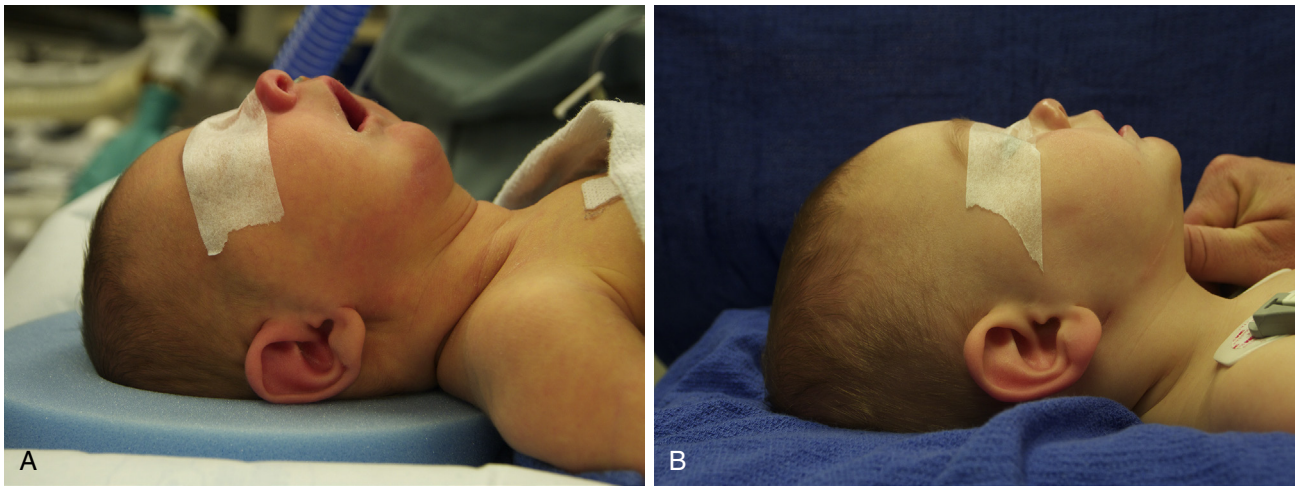

Fig. 202.3. A typical preoperative view showing marked microretrognathia **(A)** and a postoperative view of the same patient just prior to removal of distractor hardware **(B)**. The mandible is being gently guided into occlusion. Resolution of the class II occlusion has been achieved. Minimal scarring is noted from the incision and extension rod sites.

- Infiltrate with local anesthetic/epinephrine
- Access the mandible:
  - Sharply dissect through skin, subcutaneous tissue, and platysma
  - Bluntly dissect through investing cervical fascia, just above the submandibular gland parallel to the course of the marginal mandibular nerve
  - Dissect in this plane superiorly to the inferior border of the mandible at the level of the antegonial notch
  - Sharply incise the pterygomasseteric sling
- Dissect the mandible in the subperiosteal plane to identify the following landmarks (mandibular angle, body-ramus junction, which is immediately opposing the retromolar trigone, antegonial notch, sigmoid notch)
- Mark out an "inverted L" osteotomy extending posteriorly from the trigone, then inferiorly to the border of the mandible at the antegonial notch (Fig. 202.4)
- Cut/bend the distractor to fit along the inferior border of the mandible so there is one plate on either side of the marked osteotomy
- Create an exit site behind the lobule of the ear for the distracter barrel. To avoid injury to the facial nerve or its branches, make a skin only incision at the desired exit site and then bluntly dissect between the angle of the mandible and the exit site to create a tunnel.
- With the piezoelectric saw[3], make two-thirds of the osteotomy, but do not complete the osteotomy
- Place the distractor into the pocket with the barrel exiting posteriorly through the pin site
- Fixate the distractor to the mandible with 6 mm 1.0 screws
- Complete the osteotomy with the piezoelectric saw
- Activate the distractor to ensure completion of the osteotomy, then reverse the distractor until bone segments are in contact
- Irrigate the pocket and close in a layered fashion (3-0 vicryl, 4-0 vicryl, 5-0 monocryl)
- Repeat on contralateral side, making sure that the distraction barrels are parallel to each other

Common Errors in Technique

1. Traumatizing the marginal mandibular nerve can occur either during the placement or the removal of the devices. Care should be taken to use a non-traumatic technique and to avoid monopolar electrocautery.



Fig. 202.4. Intraoperative photo of mandibular distractor placement showing activation rod exiting just inferior to the lobule.

2. Disparate distraction vectors: avoid these by ensuring that the distractor barrels are placed parallel to the mandibular boarder. Prepare both sides of the mandible and ensure vectors are co-linear by placing malleables on the barrels, pointed anteriorly, and confirming they are parallel.

POSTOPERATIVE PERIOD

Postoperative Management

1. The patient is transferred directly to the neonatal intensive care unit (NICU) intubated. Signs are placed in the NICU bed and in the patient's chart indicating that the patient is a "critical airway." Deep sedation is achieved with a combination of fentanyl and midazolam not only to minimize movement but also to avoid continuous infusion of paralytics.
2. The head of the bed is elevated 30 degrees.
3. An additional analgesic (acetaminophen) dose is given 30 minutes prior to the turns of the activation rods.
4. Continuous feeds via a nasogastric tube are started 24 hours after surgery
5. Pin site care: bacitracin ointment three times daily for 2 days, then change to dilute hydrogen peroxide solution.
6. Antibiotics are continued until distractor extension arms are removed.
7. There is a 24 to 48 hours latency period prior to activating distractors.
8. The activation rods are turned at a rate of 2 mm daily divided into twice daily turns (each side) for 5 days in order to rapidly clear the airway for extubation, followed by 1 mm daily (once a day) until distraction is complete.
9. Steroids are administered 24 hours prior to extubation.
10. Extubation is usually performed on postoperative day 5 in the operating room with airway equipment available for intubation if needed. Usually, laryngoscopy and tracheoscopy are performed to rule out any granulation tissue or other causes of potential airway obstruction secondary to intubation. Flexible nasolaryngoscopy can be performed as well to assess the position of the base of the tongue post-extubation.
11. Turning of the activation rods is discontinued when it is deemed that the airway is widely patent without collapse of the base of the tongue as confirmed by bedside flexible nasolaryngoscopy.
12. Distractor extension arms are then removed at the bedside after confirmation of airway patency.
13. Six to eight weeks is given for consolidation prior to removing the distractor (see Fig. 202.3B).

Complications

1. Injury to the facial nerve—If weakness of the facial nerve is noted postoperatively, this may represent neuropraxia due to retraction and should improve in several weeks. Transection of the marginal mandibular nerve is rare if following the above approaches to the mandible and reoperation for neurorrhaphy is not usually undertaken.
2. Persistent airway obstruction—In large series, the "failure" rate of mandibular distraction has been estimated to be just under 10% of cases. That is, 10% of patients may still require tracheostomy. This should be clearly explained to parents preoperatively. Vigilant attention to preoperative airway assessment and postoperative evaluation prior to completion of distraction may be useful in minimizing this risk.
3. Hardware failure—Whenever introducing hardware into the human body there is a risk of failure. Most concerning is the "backing down" of the distractors, but translocation

of the pins within the bone has also been observed. To avoid these, chose a distractor system with a ratcheting mechanism that ensures "one-way" movement, and make sure to have at least four solid screws on either side of the osteotomy.
4. Wound infection or pin site infection—This is a relatively common complication, which can be minimalized by adhering to strict pin site care.

Alternative Management Plan

1. For patients with very mild symptoms, watchful waiting and home monitoring may be considered. An outpatient sleep study may be prudent to ensure that sleep apnea is not overlooked.
2. MDO may also be performed with external distraction devices. In this technique, the mandible is exposed with either an external or internal approach; osteotomies are performed near the angle of the mandible. Two transcutaneous pins are fixated on either side of the osteotomy and secured to the external distraction device. Distraction and consolidation phase care is similar to the internal device method, except that the patient must wear the external distractor during the consolidation phase.
3. TLA may be considered in the patient who has relatively normal occlusion but significant collapse of the base of the tongue. In some centers, this is still routinely performed as a primary surgery instead of MDO.
4. Tracheostomy with or without gastrostomy must be considered in patients who are not good candidates for either MDO or TLA.

DISCUSSION

Evidence-Based Medicine Question

Is mandibular distraction cost effective compared to tracheostomy in the management of neonatal tongue base obstruction?

New surgical tools and techniques often provide elegant solutions to longstanding problems potentially at significant increased cost relative to current standards of care. Therefore, it would seem that MDO may be costly due to the nature of the surgery and the expense of the implanted device. However, two separate costs analyses have been performed comparing MDO to the previous standard of care: tracheostomy.[3]

Recently, a cost analysis from Nova Scotia by Hong et al.[4] compared 21 patients who underwent MDO to 31 patients who underwent tracheostomy. The average total cost of MDO was found to be $57,649 CAD ($43,184 USD), and the cost of tracheostomy was $92,164 CAD ($69,040 USD). In this study, MDO had a higher operative cost and equipment cost, but a significantly lower cost related to hospital length of stay.

An earlier study in the United States, by Kohan et al.,[5] reported that the total cost of care for MDO was nearly half of that for tracheostomy. The average per patient cost for MDO was $193,126 USD compared to $382,246 USD for tracheostomy. The majority of the increased expense was from costs associated with hospital stay. Postoperatively, decreased costs were also mostly related to decreased rates of inpatient pneumonia care and emergency room visits.

Both of these studies demonstrate that the initial cost of MDO is greater than that for tracheostomy due to operating room cost and equipment cost. However, the cost of hospital stay, home nursing, home-care equipment, hospital charges for subsequent tracheostomy evaluations, and increased emergency department visits make tracheostomy an expensive intervention when considering total cost per patient. Thus, from a cost perspective, MDO compares favorably to tracheostomy, with significant long-term cost savings.

Editorial Comment

Mandibular distraction offers a relatively new tool in the armamentarium of surgeons caring for patients with micro/retrognathia. Traditionally, the surgical treatment for these patients was primarily limited to two surgical procedures, TLA and tracheostomy. Each of these procedures has its own set of complications.

This chapter outlines the preoperative assessment of patients with micro/retrognathia, and the operative and postoperative care for MDO. As this is a relatively new tool, parents should be cautioned that there are limited data on the long-term dental and orthodontic outcomes associated with this procedure. However, the inverted-L osteotomy described above, should, theoretically, minimize the possible trauma to the molars.

Data does support the use of mandibular distraction to improve both sleep apnea and dysphagia in patients with mandibular distraction. Readers should note that this chapter primarily focuses on internal distraction devices, which are used in a large number of centers. Some centers do use external distraction devices. Further description of this technique can be found in the references.

Sugki Choi

Access the review questions and additional sources list online at http://www.expertconsult.com

REFERENCES

1. Cladis F, Kumar A, Grunwaldt L, et al. Pierre Robin sequence: a perioperative review. Anesth Analg 2014;119(2):400–412.
2. Goldstein JA, Chung C, Paliga JT, et al. Mandibular distraction osteogenesis for the treatment of neonatal tongue-based airway obstruction. J Craniofac Surg 2015;26(3):634–641.
3. Chung CU, Yu JW, Bastidas N, et al. Utility of the ultrasonic scalpel in mandibular distraction osteogenesis. J Craniofac Surg 2012;23(5):1279–1282.
4. Hong P, Bezuhly M, Mark Taylor S, et al. Tracheostomy versus mandibular distraction osteogenesis in Canadian children with Pierre Robin sequence: a comparative cost analysis. J Otolaryngol Head Neck Surg 2012;41(3):207–214.
5. Kohan E, Hazany S, Roostaeian J, et al. Economic advantages to a distraction decision tree model for management of neonatal upper airway obstruction. Plast Reconstr Surg 2010;126(5):1652–1664.

REVIEW QUESTIONS

1. Potential short-term complications from mandibular distraction osteogenesis (MDO) include all of the following, *except*:
   a. Pin-site infection
   b. Growth restriction
   c. Marginal mandibular nerve injury
   d. Asymmetry
   e. Failure to relieve airway obstruction

2. Potential long-term complications from MDO include which of the following?
   a. Growth restriction/relapse requiring further airway intervention
   b. Inferior alveolar nerve/mental nerve insensibility
   c. Damage to second/third molar tooth follicles
   d. Marginal mandibular nerve weakness
   e. All of the above

3. Compared to tracheostomy, MDO has been shown to have decreased costs related to all of the following *except*:
   a. Hospital stay
   b. Operative procedure
   c. Emergency department visits
   d. Care for pneumonia
   e. Total per-patient cost

ADDITIONAL SOURCES

McCarthy JG, Schreiber J, Karp N, et al. Lengthening the human mandible by gradual distraction. Plast Reconstr Surg 1992;89(1):1–8.

This is the first description of distraction osteogenesis principles to lengthen the mandible.

Preciado DA, Sidman JD, Sampson DE, et al. Mandibular distraction to relieve airway obstruction in children with cerebral palsy. Arch Otolaryngol Head Neck Surg 2004;130(6):741–745.

This article describes the use of MDO as a tool to avoid tracheostomy or move toward tracheostomy decannulation in patients with cerebral palsy.

Sidman JD, Sampson D, Templeton B. Distraction osteogenesis of the mandible for airway obstruction in children. Laryngoscope 2001;111(7):1137–1146.

This is a first case series describing the use of MDO in the otolaryngology literature. It provides an elegant description of preoperative, operative, and postoperative management for MDO using external distraction devices.

203 Otitis Media, Myringotomy, Tympanostomy Tube, and Balloon Dilation in the Pediatric Population

Cuneyt M. Alper

INTRODUCTION

Myringotomy is the creation of an opening in the tympanic membrane (TM) with the use of a knife. *Tympanocentesis* is defined as the performance of this operation with a needle. Myringotomy or tympanocentesis may be indicated when there is an urgent need for relief of pressure and pain, to obtain a bacterial sample before the initiation of antibiotic treatment, or when there is a high risk of an unknown pathogen; it may also be done when a delay in definitive surgical treatment is anticipated owing to the need for further testing, imaging, or preparation for the medical or surgical treatment. Indications for these two procedures may overlap; however, myringotomy is preferred when there is a need for a broader opening that can stay open longer.

KEY OPERATIVE LEARNING POINTS

- Tympanocentesis involves puncturing the TM with a needle in order to relieve pressure and/or obtain an effusion sample for culture and sensitivity.
- Myringotomy involves making an incision in the TM with a knife in order to achieve a larger, longer-lasting opening for better drainage.
- There are very limited indications for myringotomy and tympanocentesis in the treatment of acute otitis media (OM).
- The most common indication is urgency in creating an opening in the TM.
- Myringotomy may be considered when a child with acute OM (AOM) or OM with effusion (OME) is under anesthesia. Temporary opening of the TM is conveniently achieved under anesthesia to relieve pressure and pain in the presence of AOM with a bulging TM. There is also the small potential benefit of earlier resolution of AOM or OME with myringotomy.
- The safest location for tympanocentesis is the anteroinferior quadrant of the TM.
- The anterior superior quadrant may be chosen because of the deeper space between the TM and the promontory.
- Tympanocentesis is preferred when there is a need to obtain a quick sample of the effusion; myringotomy is preferred when there is a need for a longer-lasting opening of the TM in order to ensure adequate relief of pressure with prolonged drainage through the TM. This is typical when medical management is the more likely treatment course.
- In order to extend the benefit of continued drainage through the unhealed TM after a myringotomy, the horizontal incision may be extended in a "smile" shape from anteroinferior to posteroinferior.
- Myringotomy is not reasonable if there is already a plan to insert a ventilation tube (VT) within the next several hours or the next day.
- Neither procedure would be indicated if there were no otologic complication, no suspicion of a complication, the child were not in pain with a bulging TM, and the choice of antibiotic would not be affected by an effusion sample.

PREOPERATIVE PERIOD

History

- AOM with severe pain, leading to constant crying and the inability to sleep
- Persistent high fever (>104°F) despite the administration of analgesics and antipyretics for more than 48 hours
- Persistent AOM with ongoing fever (>102°F) and moderate to severe pain for more than 5 to 7 days
- Multiple failures of treatment with antibiotics in the presence of an AOM episode
- Newborn with an AOM (in the first 4 weeks of life) because of the likelihood of unusual bacteriology not suitable for routine antibiotic choices[1]
- OME with sepsis even though there are no acute signs or symptoms of AOM
- AOM in the intensive care unit (ICU) or neonatal ICU (NICU), when it is not feasible or preferred to take the child to the operating room
- Fever of unknown origin in a child with middle ear effusion (MEE) in the ICU, as part of the work-up for fever of unknown origin in a child with middle ear effusion in the ICU[2]
- Fever of unknown origin in an immunocompromised child with a MEE even in the absence of signs or symptoms of an AOM
- Suspicion of an otologic complication when an early sample of MEE for culture and sensitivity will be beneficial and/or for relief of pressure and pain from the OM. Other indications include a need for time for further re-evaluation (such as imaging) and/or when there will be a delay in initiating definitive surgical treatment.
- Presence of an otologic complication, when obtaining an MEE sample for culture and sensitivity, prior to the initiation of intravenous empiric antibiotic therapy will be beneficial. This is done first to obtain a stat Gram stain to narrow the antibiotic options instead of starting double or triple therapy and, second, to discontinue or change the previously initiated antibiotics.

Physical Examination

- High (>104°F) fever
- Severely bulging TM with an imminent perforation, manifested by localized bulging of the TM and/or the presence of one or multiple bullae on the TM filled with purulent material[3]
- Behavior consistent with severe pain originating from the ear, such as holding or pulling at the ear with constant crying and the inability to sleep
- When there are signs and symptoms and/or imaging evidence of an extracranial or intracranial complication, tympanocentesis or myringotomy is considered for culture purpos and to create means of drainage through the TM in order to reduce the progression of the conditions that caused the complications, and/or to prevent additional complications.

Imaging

- Imaging is not necessary for the performance of tympanocentesis or myringotomy procedures; however, it may be necessary in order to assess the ear and possible complications.

Indications

- Severe otalgia. Tympanocentesis or myringotomy is a painful procedure. However, if there is severe ear pain from the OM or its complications, the procedure is considered to be justified because it can instantly resolve pain due to the stretch and pressure of the TM from the purulent exudate confined in the middle ear (ME). If the otalgia does not improve after tympanocentesis and myringotomy, there may be blockage of the drainage pathways between the mastoid and the opening on the TM. Limitation or complete blockage of the drainage pathways may be due to (1) lack of ME space owing to significant mucosal hypertrophy and/or the formation of granulation tissue (which is more commonly seen in *Streptococcus pyogenes* infections), (2) obstruction of the anterior and posterior isthmus connecting the epitympanum to the mesotympanum, (3) obstruction of the aditus ad antrum connecting the antrum to the epitympanum, and (4) blockage of aeration/drainage pathways within the mastoid, most commonly by Koerner's septum between the lateral and medial groups of mastoid cells.
- To have a controlled TM perforation at a preferred location. The site of most TM fullness and bulging is commonly at the posterosuperior quadrant. This is more commonly the case if the mucosal folds between the stapes, incus, and malleus limit communication between the epitympanum and mesotympanum. If a perforation at the posterosuperior quadrant does not heal, sequelae and/or complications are more likely. If the TM heals, the healed TM section may be atrophic and therefore will be more prone to the development of retraction pockets, cholesteatoma, and erosion of the ossicles. Any secondary acquired (from perforation) or primary acquired (from a retraction pocket) cholesteatoma developing at the posterosuperior quadrant will pose a higher risk of ossicular erosion, hearing loss, extension to the attic and into the mastoid, and other complications. Therefore a controlled opening of the TM will likely relieve pressure on the TM in the posterosuperior quadrant and lessen the chance of sequelae and complications.
- In order to identify the pathogen prior to starting antibiotic treatment.[4] If an intravenous antibiotic is administered, it will pose the risk of producing a negative culture result. In an infectious condition where selection of the correct antibiotic as quickly as possible has critical importance, accurate identification is secured by tympanocentesis or myringotomy. This procedure also narrows the spectrum of antibiotics by getting a stat Gram stain, which not only differentiates between gram positives and gram negatives but also points to characteristics of the organisms that may help in narrowing down the possibilities, thus helping to determine the choice of antibiotic.
- To relieve the pressure in the presence of an otologic complication until imaging is performed and/or the patient/ preoperative workup/surgical team is ready. A patient may have or be suspected to have a complication from OM. To verify the presence of a complication or for surgical planning or preparation, there may be a need extra time, during which the purulent exudate under pressure from OM that is suspected to have caused or has the potential to cause a complication has the potential to progress and worsen. To release the purulent effusion under pressure in the middle ear, in the presence or suspicion of an otologic comuntil imaging is performed and/ or the patient/ operating room/ surgical team are ready, tympanocentesis or myringotomy can buy time and also lessen the risk for progression of complications until definitive treatment can be administered.
- To identify the pathogen precisely in a patient with a high risk for a fulminant or aggressive infectious course (immunocompromised, ICU, NICU). While awaiting identification of the pathogen in such patients, it is more important to instantly identify the group and likely species of the pathogen.
- To identify a pathogen that is likely to be highly resistant. Because many bacteria are highly resistant today, it is helpful to have a sample for culture and sensitivity with results obtainable within days.

Contraindications

- When the indications are not strong enough to justify a painful procedure to be done in an awake patient. These procedures are painful. In the absence of concern for a complication, the sole justification is extreme pain and the goal of relieving it. If there is not much pain, the procedure is not necessary.
- When it is not possible to perform such a procedure safely (applicable to awake procedures). Performing tympanocentesis or myringotomy safely requires almost complete immobility of the patient. This is achieved by restraining the child with the help of parents or support staff. Additional restraint can be achieved by using a papoose or by swaddling a newborn or an infant with a sheet. Such restraints may not be acceptable to the parents.
- When a child is above 2 or 3 years of age, this painful procedure under restraint may be too traumatic, having a lasting negative effect on the child's relationship with the physicians and even the parents who permitted it.
- When a child is very strong, almost complete restraint may not be possible, making it unsafe to instrument the ear canal and TM with sharp instruments. Any sudden movement, even of a few millimeters, can lead to inadvertent ear canal trauma and bleeding, making instrumentation even more challenging. Furthermore, if a larger than planned opening or an irregular incision in the TM is produced, it could pose a greater risk for permanent perforation or cholesteatoma formation with inversion of irregular edges of the TM.

- When the patient and/or parents have previously experienced similar procedures under restraint, it may be impossible to convince them of the need of tympanocentesis or myringotomy.
- Topical anesthesia with lidocaine solution takes a long time to implement and is not very effective. The use of phenol may pose a risk for spilling or spreading inadvertently and therefore may be dangerous in a noncompliant child.
- When these procedures cannot be done without anesthesia or if the "nothing by mouth" (NPO) status is a contraindication
- When preparation/performance of these procedures may delay the necessary workup or initiation of treatment
- When there is already an indication for VT placement, a separate procedure of tympanocentesis or myringotomy may not be justified. Therefore the need and timing of these procedures may be adjusted according to the circumstances.

Preoperative Preparation

- Assess the optimal conditions for the procedure based on the indications and priorities. The options are performing the procedure under general anesthesia, with topical anesthesia, or with no anesthesia but possible analgesia. These decisions will be made based on the indications, alternatives, risks, and the timeline of planned evaluation and treatment.
- If the procedure is to be done under general anesthesia, verify NPO status and the potential contraindications for general anesthesia.
- If the procedure is to be done under topical anesthesia or no anesthesia, it is necessary to spend sufficient time with the child and family to prepare them, explaining what to expect, and to consider administering analgesia.

OPERATIVE PERIOD

Anesthesia

- General
- Awake sedation
- Topical anesthesia
- No anesthesia with analgesia

Although this procedure can be done with the patient awake or under sedation, general anesthesia is preferred for patient comfort. Based on the indications, conditions, and limitations, one of the previously mentioned options may be preferred. When there is an urgency to perform tympanocentesis or myringotomy in the clinic, emergency department, ICU, or NICU for the reasons outlined earlier, the options should be discussed with the family, the child (if of an appropriate age), and the other physicians/health care professionals and services as applicable.

Positioning

- Supine: The patient is positioned supine with the head turned away from the surgeon for each ear.

Perioperative Antibiotic Prophylaxis

None necessary

Monitoring

None necessary

Instruments and Equipment to Have Available

- Operating microscope
- Otoscope for outpatient or bedside tympanocentesis or myringotomy
- Speculum, curette, myringotomy knife, suction, 5-, 7-, and 3-Fr suction catheters
- For culture purposes, an attached suction trap for collecting the effusion or a swab to touch the effusion by inserting it into the canal
- For tympanocentesis in the office or at bedside, an 18-gauge spinal needle attached to a tuberculin syringe to withdraw after going through the TM

Key Anatomic Landmarks

- Manubrium malleus, parts of umbo, and lateral process (Fig. 203.1)
- Pars flaccida and pars tensa
- Pars tensa quadrants
- Annulus

Prerequisite Skills

- Microscope use and handling of the instruments (Fig. 203.2A to E)
- Cleaning of the ear canal

Operative Risks

The procedure has risks mostly associated with either inadequate restraining, inexperience, or both. These risks include trauma and bleeding from the ear canal, TM, and/or ME mucosa. One very serious but extremely rare risk is damaging the TM and/or disrupting the ossicular chain. Failure to identify the anatomic landmarks, especially with an inflamed swollen ear canal and TM, may increase the risk

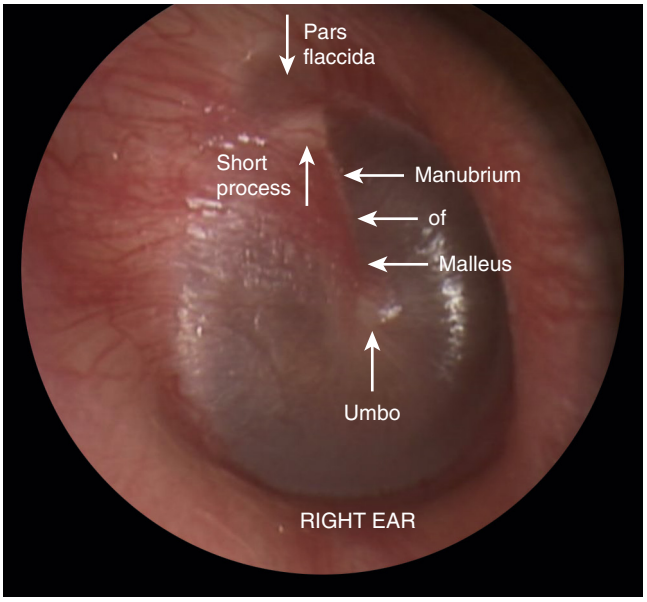

Fig. 203.1. Tympanic membrane landmarks. It is critical to identify the landmarks to be able to perform tympanocentesis or myringotomy in the correct location and to avoid complications.

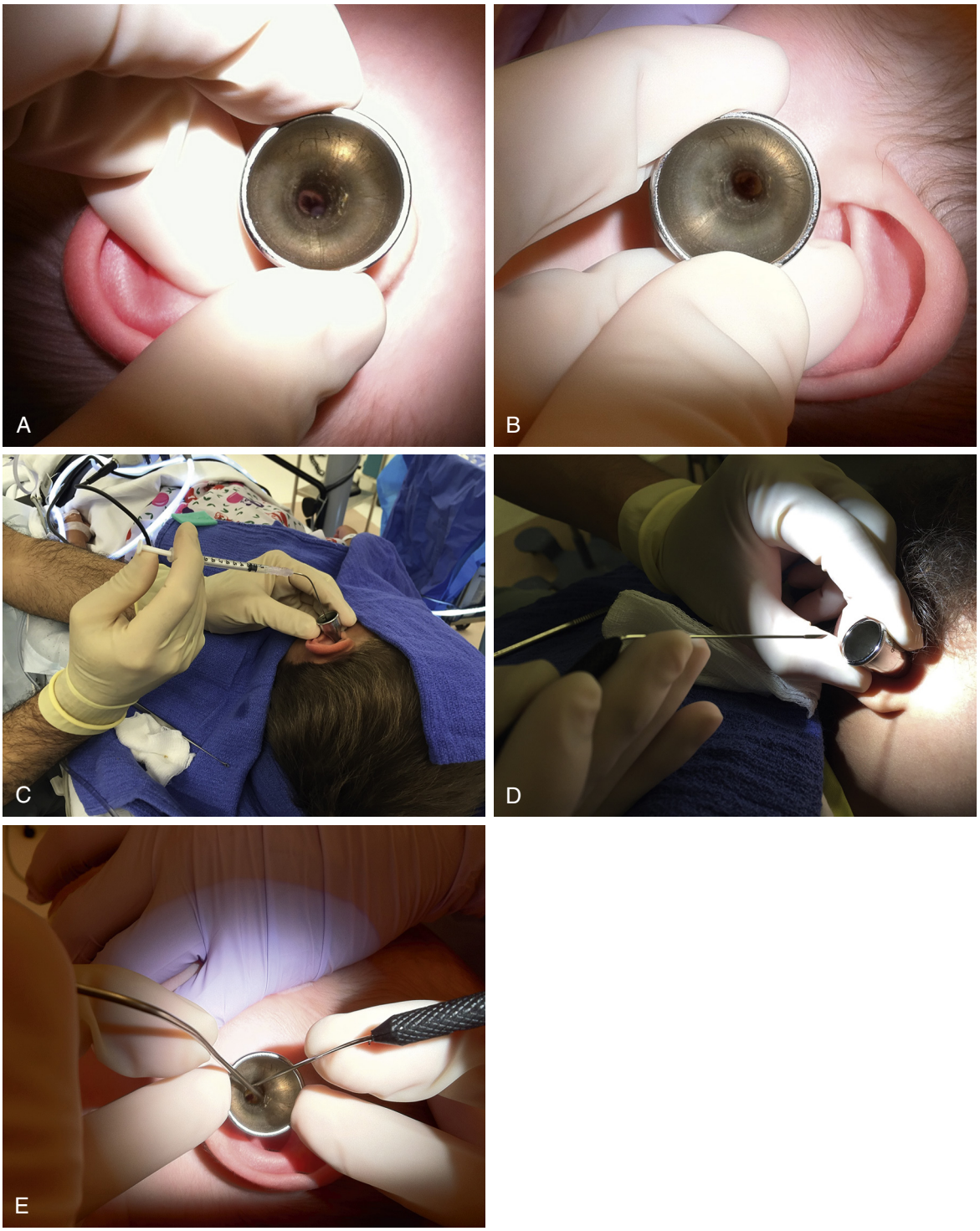

Fig. 203.2. A, The speculum is held as shown for the right ear for a right-handed surgeon; the third finger is placed in the concha to retract the pinna in the posterosuperior direction so that the ear canal can be straightened with one hand. **B,** The speculum is held as shown for the left ear for a right-handed surgeon; the third finger is passed inferior to the speculum and placed in the concha to retract the pinna in the posterosuperior direction so that the ear canal can be straightened with one hand. **C,** If a trap with suction is not available, tympanocentesis may be performed with a spinal needle and a tuberculin syringe. **D,** To handle the myringotomy knife, the thumb and index finger hold the handle while the third finger stabilizes the shaft of the knife, freeing up the fourth finger to be anchored on the speculum edge and the fifth finger to be anchored on the head if possible. **E,** Bimanual handling of the speculum, myringotomy knife, and suction. Instruments are held as described earlier, both fourth fingers anchored on the speculum and both fifth fingers anchored on the head for stabilization.

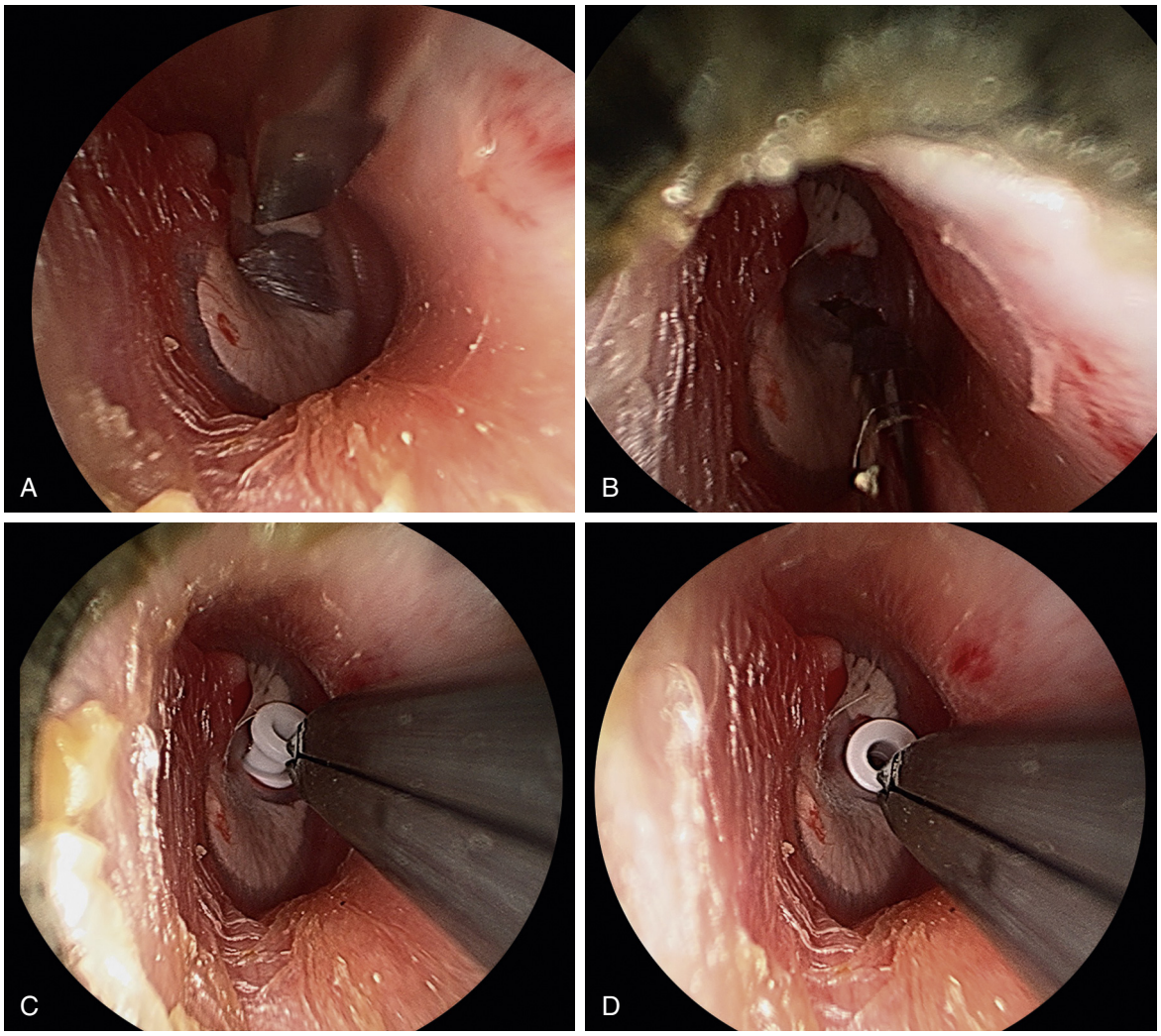

Fig. 203.3. A, Performance of a radial myringotomy at the anteroinferior quadrant of the tympanic membrane (TM). The incision size should not exceed a third of the length between the umbo and the annulus. **B,** Aspiration of effusion if present. **C,** Initially halfway insertion into the TM incision is adequate. The tube will be stable when released, pushing the ventilation tube (VT) into the incision in the same direction, as the tube is initially held with the alligator forceps may result in trauma to the TM, especially from the leading edge of the outer flange. **D,** Complete insertion of the VT requires a shift in the axis of VT from the initial insertion angle to the end result, where the VT shaft is parallel to the TM surface. This 30- to 45-degree change in the axis of the VT is easily achieved by pushing the outer flange with the barely open tip of the alligator forceps, applying gentle pressure from the lateral most aspect of the tube perpendicularly toward the incision but without holding the VT. This maneuver can also be achieved with a Rosen needle. Both methods lead to the least traumatic method of VT insertion.

for misplaced opening of the TM, especially in less experienced hands.

Surgical Technique

- Stabilize the child and the head.
- Use the third finger of the holding hand to push the concha posterosuperiorly in order to straighten the ear canal (see Fig. 203.2A and B).
- Place the fourth and fifth fingers at the edge of ear speculum and on the head, respectively, in order to stabilize the instrumentation and to prevent inadvertent injury from movement of the anesthesiologist or the patient.
- Clean the ear canal for complete visualization of the TM.
- Reorient the center of the field of the microscope toward the anteroinferior (or any other preferred) site.
- If the microbiologic information is critical, sterilize the ear canal with 70% alcohol for 1 minute, then dry it completely before making the incision.
- Make a circumferential incision parallel to the annulus, halfway between the umbo and the annulus. If the myringotomy is to be kept open, create a smile-shaped incision at the inferior part of the TM.
- If a tympanocentesis is performed, anteroinferior or anterosuperior quadrants are preferred, where there is a greater distance between the TM and the promontory.

Common Errors in Technique

- Inadequate stabilization of the child and/or the head
- Suboptimal use of microscope for visualization and magnification
- Failure to work atraumatically

POSTOPERATIVE PERIOD

Postoperative Management

- Ear drops
- Gram stain- and culture-directed antibiotic treatment as indicated

Complications

- Trauma to the external ear canal is usually due to inadequate restraint. Such trauma is rarely serious, but it is often painful and makes the procedure more challenging owing to worsened movement and obstruction of landmarks from the bleeding.
- Although extremely rare, with a traumatic procedure there is a potential risk of disrupting the ossicular chain.
- If a caustic agent such as phenol is used for local anesthesia on the TM, inadvertent application on a broad area may result in a large perforation. Inadequate securing of the phenol bottle may result in spillage and a chemical burn at the spilled site.

Complications are extremely rare in trained hands.

Alternative Management Plan

1. Initiation of antibiotic treatment without obtaining an effusion sample for culture and sensitivity is an option.
2. Similarly, more optimal pain management may obviate the need for tympanocentesis or myringotomy.

DISCUSSION

Evidence-Based Medicine Question

Does the culture obtained with a tympanocentesis or myringotomy affect the outcome?

In infants and children with AOM with a high risk of having an unusual or a resistant bacterium or in the presence of suspected serious complications, culture and sensitivity can facilitate an earlier and better outcome.[1,2] Immediate Gram stain results can narrow the guesswork regarding the likely organism and guide a more accurate selection of antibiotic treatment.

Access the review questions and additional sources list online at http://www.expertconsult.com

REFERENCES

1. Bland RD. Otitis media in the first six weeks of life. Diagnosis bacteriology and management. Pediatrics 1978;49:187–197.
2. Arriaga MA, Bluestone CD, Stool SE. The role of tympanocentesis in the management of infants with sepsis. Laryngoscope 1989;99:1048–1051.
3. Alper CM. Acute and recurrent otitis media in children: current evidence. Ch102. In: Paparella M, Da Costa SS, Fagan J, editors. Global Otolaryngology (Head and Neck Surgery). India: Jaypee Brothers Medical Publishers (P) Ltd.; 2018.
4. Belmont MJ. Myringotomy and tympanocentesis. In: Alper CM, Bluestone CD, Casselbrant ML, Dohar JE, Mandel EM, editors. Advanced Therapy of Otitis Media. Hamilton, London: BC Decker Inc.; 2004. p. 58–62.

Ventilation Tube

INTRODUCTION

A ventilation tube (VT) is inserted after the myringotomy in order to prevent closure of the TM.

KEY OPERATIVE LEARNING POINTS

VTs are beneficial when there is a need for a long-lasting opening to drain the MEE, reduce the risk of a new OM, and equalize the pressure between the ME and the ambient.

PREOPERATIVE PERIOD

History

Chronic OM with effusion (COME)
Recurrent AOM
Delayed development of speech
Eustachian tube dysfunction (ETD)
Recurrent barotrauma

Physical Examination

MEE
AOM
Retraction of the TM and/or retraction pocket
Precholesteatoma
Cholesteatoma

Imaging

Not necessary for VT insertion

Indications

COME with hearing loss for 3 months or longer if bilateral and 6 months or longer if unilateral
Recurrent AOM, three or more episodes in 6 months or four or more in a year, one being recent, and presence of effusion during the consideration of VT insertion[1]
Intracranial or extracranial complication from AOM in addition to treatment of the complication
Recurrent or chronic otalgia or pressure from ETD
Recurrent perforation of the TM
Significant conductive hearing loss from effusion
If there is significant atrophy and severe retraction of the TM, especially in the likely sites for VT insertion (which poses an increased risk of early extrusion) or if there is a prediction that the patient will need VTs for at least several years because of his or her age at the time of insertion and history of multiple sets of tubes before this time, a long-lasting tube (T-tube) may be preferred.

Contraindications

None

Preoperative Preparation (See Section on Myringotomy)

None necessary

OPERATIVE PERIOD

Anesthesia

General anesthesia
Older teenagers may tolerate topical anesthesia

Positioning (See Section on Myringotomy)

Supine: The patient is positioned supine with the head turned away from the surgeon for each ear.
Or same as Myringotomy.

Perioperative Antibiotic Prophylaxis

None necessary

Monitoring

None necessary

Instruments and Equipment to Have Available (See Section on Myringotomy)

Rosen needle
Alligator forceps
VT

Key Anatomic Landmarks (See Section on Myringotomy)

None necessary

Prerequisite Skills (See Section on Myringotomy)

None necessary

Operative Risks (See Section on Myringotomy)

Placement of too small an incision requiring a forceful and traumatic insertion
Placement of incision too close to the annulus increases the difficulty of insertion.
Placement of too large a myringotomy incision poses the risk of medialization or early extrusion of the VT.
Placement of the incision in the posterior superior quadrant has the risk of injury to the ossicles, conductive hearing loss, and, after the extrusion of VT, atrophy or perforation at a site for higher risk of complications or sequelae.
Tearing of the thin/atrophic TM
Medial displacement of VT into the ME
Additional trauma and bleeding from insertion of the VT into the ear canal

Surgical Technique (See Section on Myringotomy)

Place a radial incision at the center third of a line between the umbo and annulus and suction the effusion (Fig. 203.3A and B).
Carry the VT with an alligator forceps away from the anterior bony overhang.
Insert the leading edge of the inner flange in a vertical direction (as much as possible) to the surface of the TM at the insertion site (see Fig. 203.3C).
Release the VT from the alligator when halfway inserted into the incision.
Push the outer flange of the tympanostomy tube at the most lateral edge of the VT with a barely open alligator forceps tip without holding the tube, allowing the tube to change its axis from insertion angle to the complete horizontal angle to the surface (see Fig. 203.3D). A Rosen needle can be used instead.[2]
Suction any residual effusion and/or blood, waiting adequate time to assess any further oozing of blood that can dry in or over the VT.
Instill ear drops and pump the tragus to facilitate passage of the drops through the tube VT and into the ME.
When a long-lasting tube is inserted, at least half of the shaft of the T-tube is cut off. Holding the flanges straight with the alligator forceps, slowly release the forceps when the tips of the flanges are past the incision so as to allow opening of the flanges in the opposite direction. Secure the proper positioning of the angle of the tube and flanges for optimal function and surveillance.[3]
If a long-lasting tube is inserted, special techniques will have to be used.[4] It is better to shorten the shaft of a T-tube by at least a half in order to reduce the risk of blockage, allow drops to go through more easily if needed, and reduce the risk of the tip of the shaft reaching the cerumen-producing site of the ear canal, leading to attachment of the shaft to the cerumen and the canal. This can result in earlier than desired extrusion of the tube. With T-tube having long flanges that are supposed to stay parallel to the TM, the flanges are straightened with the alligator forceps and released after passing through the incision site. A Rosen needle is often needed to insert or align the flanges and the shaft in the desired direction.

Common Errors in Technique (See Section on Myringotomy)

Trauma and bleeding of the ear canal, TM, and ME with the passing and insertion of the tube

POSTOPERATIVE PERIOD

Postoperative Management (See Section on Myringotomy)

Avoid exposure to dirty water, as in lakes and rivers.[5]
Avoid diving under water.

Complications (See Section on Myringotomy)

Failure to keep the VT in place due to the overly large myringotomy incision
Medial displacement of the VT into the ME
Blockage of the VT from dried blood and/or effusion
Placement of the VT too inferiorly and centrally, resulting in limited drainage of effusion and increasing the risk of blockage when the inner opening of VT faces the ME mucosa on the promontory
Myringosclerosis
TM atrophy
Retention of VT
Otorrhea
Granuloma
Cholesteatoma

Alternative Management Plan (See Section on Myringotomy)

Watchful waiting for COME
Watchful waiting or repeated antibiotic therapy when indicated for the episodes of AOM
Adenoidectomy
Autoinflation for ETD and COME
Balloon dilation of the ET (BDET)

DISCUSSION

Evidence-Based Medicine Question

Does insertion of a VT make a difference in speech and language development?

There is mixed evidence regarding the role of delayed VT insertion. Major studies have failed to demonstrate a difference between early and late VT insertion for COME. However, despite this and because of the well-known association between hearing loss and speech delay, the criteria for insertion of a VT in a child with speech delay are different. As per the most recent guidelines for VT insertion, there is no need to verify the presence of effusion in order to decide for VT insertion when there is a speech and language delay. This modification in the guidelines for VT insertion clearly indicates that VT insertion makes a difference in speech and language development.



Access the review questions and additional sources list online at http://www.expertconsult.com

REFERENCES

1. Casselbrant ML. Ventilation tubes for recurrent acute otitis media. In: Alper CM, Bluestone CD, Casselbrant ML, et al., editors. Advanced Therapy of Otitis Media. Hamilton, London: BC Decker Inc.; 2004. p. 113–116.
2. Bluestone CD. Myringotomy and tympanostomy tubes for otitis media. In: Alper CM, Bluestone CD, Casselbrant ML, et al., editors. Advanced Therapy of Otitis Media. Hamilton, London: BC Decker Inc.; 2004. p. 194–198.
3. Allen CG. Ventilation tube placement in ears with thin eardrum or myringosclerosis. In: Alper CM, Bluestone CD, Casselbrant ML, et al., editors. Advanced Therapy of Otitis Media. Hamilton, London: BC Decker Inc.; 2004. p. 199–202.
4. Goode RL. Long lasting tubes for otitis media with effusion. In: Alper CM, Bluestone CD, Casselbrant ML, et al., editors. Advanced Therapy of Otitis Media. Hamilton, London: BC Decker Inc.; 2004. p. 214–217.
5. Rosenfeld RM, Schwartz SR, Pynnonen MA, et al.: Clinical practice guideline: tympanostomy tubes in children. Otolaryngol Head Neck Surg 149(Suppl 1): S1–S35.

Balloon Dilation of the Eustachian Tube

INTRODUCTION

ME gas is constantly being exchanged with dissolved gas in the blood. This exchange would ultimately result in a pressure of approximately −600 mm H_2O if the ET were unable to open and supply a bolus of gas in order to replace the absorbed gas. The ET must remain closed to protect the ME from pressure variations, sounds, and secretions that might contain viruses and/or bacteria. The ET must also clear mucosal secretions and effusion. The present discussion regards the Eustachian tube function (ETF) that is relevant to the equalization of the ME pressure (MEP) to the ambient. The ET may open passively when the pressure gradient between the ME and the ambient exceeds the ET resistance from tissue pressures. The usual mechanism of opening of the ET is by widening of the ET with active muscular function while swallowing or yawning.[1] The ET may be unable to open under normal physiologic conditions owing to high tissue pressures around it (ET obstruction), inadequate active muscular function (ET functional obstruction), or a combination of both.[2] These conditions may be overcome by increasing the pressure gradient with the Valsalva maneuver, enhancing active muscle function with the Toynbee maneuver, or to do both with Diver's maneuver (Lowry technique). Devices are also used to enhance the ET's ability to increase intranasal pressure. The traditional and most common method of treatment is VT insertion, which temporarily bypasses the need for a pressure-equalizing function. However, new surgical treatment methods involving the ET have recently been described, including laser tuboplasty and cartilage framework tuboplasty or BDET.[3] Of these, the least invasive and most promising method is BDET. Despite a number of studies demonstrating its safety in adults, there is limited evidence on the efficacy of BDET for ETD.[4] While more studies are needed before routine clinical application for BDET, especially in children, this chapter includes information regarding the indications, technique, and problems regarding BDET.

KEY OPERATIVE LEARNING POINTS

ET tube anatomy
ETF and ETD
Types of ETD
Treatment options for ETD
Indications, technique, consequences, and potential complications of BDET

PREOPERATIVE PERIOD

History

COME recurring after extrusion of tube and prior adenoidectomy
TM retraction or retraction pocket with progression
Recurrent barotrauma, otalgia, OME, AOM, or hemotympanum with exposure to significant ambient pressure changes (flying and diving)
Tympanoplasty or myringoplasty graft failures
Recurrence of retraction pocket or retraction pocket cholesteatoma after tympanoplasty

Physical Examination

MEE, AOM, hemotympanum
TM, retraction pocket, atelectasis, adhesive otitis
MEE or negative pressure with pneumatic otoscopy
Endoscopy of nasopharynx and ET orifice to rule out pathology causing ETD

Testing

Tympanometry showing type B or C or a large volume from a perforation or VT
Degree of ability to correct the MEP differences with swallowing, yawning or Valsalva, Toynbee, and Lowry maneuvers
ETF test with tympanometry, using the resident software and method or the 9-Step test
Sonotubometry
Inflation-deflation test
Forced response test
Tubomanometry

Other than the tympanometric tests, the mentioned test methods are available and used in a few centers; however, their sensitivity and specificity in diagnosing ETD are not well established. This brings a diagnostic dilemma, indicating that there is a risk for misdiagnosis of the ETD. Until studies establish better test methods to identify ETD and controlled studies demonstrate a clear benefit over the other treatment methods, the BDET procedure should be avoided, especially in children.

Imaging

CT scan of the temporal bone

Imaging is currently used to rule out anatomic abnormality and a dehiscent carotid canal; however, yield and benefit are questionable.

Indications

Development of significant negative MEP and/or MEE after extrusion of VTs
Development of barotrauma with unavoidable ambient pressure variations
Test results demonstrating ETD with obstruction
a. Test results demonstrating inability to passively open the ET despite large pressure differences
b. High opening and closing pressures
Test results demonstrating ETD with functional obstruction
a. Inability to open the ET despite the addition of swallow in the presence of large pressure differences
b. Inability to increase airflow with swallow

These indications imply that the BDET procedure could be indicated for ears that need reinsertion of a VT for significant negative MEP; its sequelae or complications include recurrent MEE or hemotympanum from barotrauma and test evidence of obstruction or functional obstruction of the ET.

Contraindications

Ears that do not develop MEE or significant sustained or recurrent negative MEP
Large adenoid tissue pad impinging the ET cartilage or blocking the ET orifice, in which case adenoidectomy should be performed first, and the ETD refractory to treatment should be verified
Untreated nasal allergies, chronic sinusitis, gastroesophageal reflux disease (GERD), in which case these conditions should be treated first and the ETD refractory to treatment should be verified
Patulous or semipatulous ET
Dehiscent carotid canal
ETD due to a skull base, parapharyngeal, or nasopharyngeal mass

Preoperative Preparation

None specific for BDET

OPERATIVE PERIOD

Anesthesia

General anesthesia
Eustachian tube function

Positioning

Supine

Perioperative Antibiotic Prophylaxis

None necessary

Monitoring

None necessary

Instruments and Equipment to Have Available

Nasal speculum
Bayonet forceps
Zero-degree endoscope (thin and fat)
45-degree endoscope (thin and fat)
30- to 70-degree guide catheter
Balloon 6×16 mm^2 or 5×16 mm^2
Balloon inflation device

The instruments and BDET devices that are currently available are used for the balloon dilation of sinuses. Balloons and delivery devices specific for the ET are not currently available in the United States; however, they are available in Europe and are being developed and tested in the United States and elsewhere.

Key Anatomic Landmarks

Choana
Torus tubarius
Fossa of Rosenmüller
ET orifice (Fig. 203.4A)

Prerequisite Skills

Endoscopic sinus surgery and balloon dilation skills and experience

Operative Risks

ET mucosal tears
Bleeding
Emphysema
False passage
Fracture of bony ET
Internal carotid artery injury or occlusion leading to ischemic cerebral injury

Surgical Technique

Use a topical nasal decongestant (oxymetazoline) for easier and less traumatic access through the nasal passages.
Examine the nasopharynx, torus tubarius, and nasopharyngeal orifice of the ET with 0-and 45-degree telescopes.
Load the balloon through the guide catheter up to the tip and pass through the nose (see Fig. 203.4B).
Position the guide catheter at the ET orifice in a superolateral direction (see Fig. 203.4C).
If there is significant resistance, pull back, assess the direction, check for false passage, and retry. If there is continued resistance, consider downsizing the balloon and reinsert.
Gently insert the balloon into the ET lumen (see Fig. 203.4D).
Make sure that the mark indicating the proximal end of the balloon is visible outside the ET orifice.
Inflate the balloon to 10 to 12 atm for 1 to 2 minutes, then deflate and remove.
Reexamine with an endoscope for any bleeding or complication (see Fig. 203.4E).

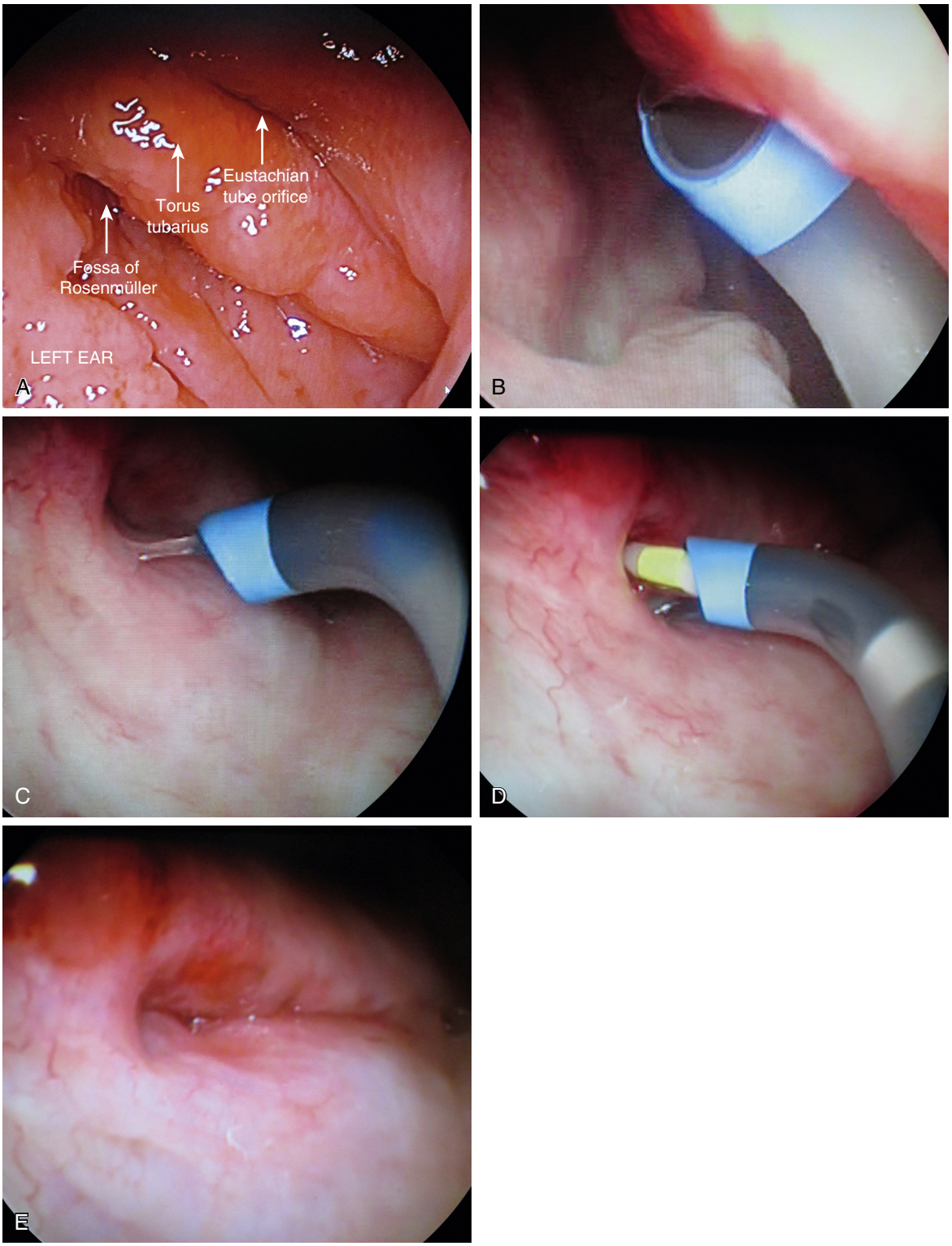

Fig. 203.4. A, Anatomic landmarks of the left Eustachian tube (ET) nasopharyngeal orifice. It is important to avoid insertion to the fossa of Rosenmüller or a false passage within the ET lumen. **B,** Advancement of the guide catheter through the nasal passage is achieved after adequate decongestion, with the guidance of endoscopes. **C,** Positioning of the catheter at the ET orifice in the direction of the ET lumen. **D,** A balloon is inserted to the level of a yellow ring, and the pressure is increased by inflating the special syringe to the desired pressure for the desired duration. **E,** The appearance of postdilation ET orifice is checked with an endoscope before terminating the procedure (Acclarent 6×16 mm^2 sinus balloons and a 70-degree guide catheter with inflation device were used for the procedure displayed in the figures).

Common Errors in Technique

Failure to insert the balloon
Insertion of the balloon beyond the cartilaginous ET
Insertion of balloon into the fossa of Rosenmüller

POSTOPERATIVE PERIOD

Postoperative Management

Pain management, routine for the first 24 hours and as needed thereafter
Topical decongestant as needed for minor epistaxis
Patient cautioned to avoid blowing the nose for 1 week

Complications

Bleeding
Emphysema (if there is forceful nose blowing in the postoperative period)
Patulous ET (poses a higher risk if patient selection is without testing and verification of the "obstructive" ETD)

Alternative Management Plan

VT
Use of autoinflation maneuvers
Devices that enhance or facilitate nasal autoinflation

DISCUSSION

Evidence-Based Medicine Question

There is currently no evidence that BDET is more effective than the control, even in adults.[4] Evidence is mostly subjective and based on some objective measures; sensitivity and specificity are questionable. Should the current noncontrolled limited evidence be considered sufficient to perform this procedure in patients suffering from ETD and its consequences and complications, especially in children?

Editorial Comment

When medical treatment for OM has failed, surgical treatment should be considered, as OM causes mild to moderate hearing loss that may interfere with speech-language development and balance as well as the child's quality of life. The most common surgical procedures for OM include myringotomy/tympanocentesis and tympanostomy tube insertion. Whereas myringotomy/tympanocentesis is currently performed mainly for more acute conditions, tympanostomy tube insertion has, since its introduction in the 1950s, become the most common outpatient surgery in children. This procedure has been shown to be efficacious for treatment of recurrent acute OM (rAOM), persistent COME, and ETD. In recent years balloon dilation, a new procedure, has been introduced for ETD and has gained popularity. However, the efficacy of this procedure has not yet been established. In an effort to avoid over- or undertreatment, guidelines for both physicians and parents have been published recommending diagnostic criteria as a basis for selection of treatment as well as for care of the tympanostomy tubes.

Margaretha L. Casselbrant

Access the review questions and additional sources list online at
http://www.expertconsult.com



REFERENCES

1. Alper CM, Swarts JD, Singla A, et al. Relationship between the electromyographic activity of the paratubal muscles and eustachian tube opening assessed by sonotubometry and videoendoscopy. Arch Otolaryngol Head Neck Surg 2012;138(8):741–746.
2. Alper CM, Teixeira MS, Swarts JD, et al. Quantitative description of eustachian tube movements during swallowing as visualized by transnasal videoendoscopy. JAMA Otolaryngol Head Neck Surg 2015;141(2):160–168.
3. Jufas N, Patel J. Transtympanic balloon dilatation of the eustachian tube: systematic review. Laryngol Otol 2016;30(5):425–430.
4. Norman G, Llewellyn A, Harden M, et al. Systematic review of the limited evidence base for treatments of eustachian tube dysfunction: a health technology assessment. Clin Otolaryngol 2014;39(1):6–21.

REVIEW QUESTIONS

1. Indications for myringotomy include all of the following, except
   a. New-onset AOM
   b. Constant crying in a febrile infant with a bulging eardrum
   c. Failed third-line antibiotic therapy for OM in a symptomatic child
   d. AOM in an immunocompromised child in the ICU

2. The following statements about tympanocentesis and myringotomy are accurate, except
   a. Tympanocentesis and myringotomy can be performed in office or at bedside
   b. Tympanocentesis provides an adequate opening on the TM for continued drainage
   c. Myringotomy may be extended to prevent early closure and provide adequate ongoing drainage
   d. Both can be performed prior to the first dose of antibiotics in children with suspected complications

3. Anesthesia required for tympanocentesis or myringotomy includes all of the following, except
   a. General anesthesia
   b. Topical anesthesia
   c. No anesthesia
   d. Nerve block

REVIEW QUESTIONS

1. Recent (2013) clinical practice guidelines developed by American Academy of Otolaryngology - Head and Neck Surgery (AAO-HNS) on VT insertion for recurrent AOM suggest all of the following, except
   a. Three or more well-documented and separate AOM episodes in the past 6 months or four or more well-documented and separate AOM episodes in the past 12 months with at least one or more in the past 6 months
   b. Children should have unilateral or bilateral MEE at the time of assessment for tube candidacy, verified with pneumatic otoscopy or tympanometry
   c. Each AOM episode should qualify as moderate to severe bulging of the TM, new onset of otorrhea not due to acute otitis externa, or mild bulging of the TM and recent onset of ear pain or intense erythema of the TM
   d. All of the above

2. The requirement of presence of unilateral or bilateral MEE at the time of assessment for tube candidacy may be waived in the following conditions, except
   a. Permanent hearing loss independent of MEE
   b. Suspected or confirmed speech and language delay or disorder
   c. Developmental delay
   d. All of the above

3. Long-lasting tubes may be considered in all the following conditions, except
   a. Very thin TM with ME effusion
   b. Severely retracted and atelectatic TM with ME effusion
   c. Multiple early tube extrusions
   d. First set of tubes in an infant or toddler

REVIEW QUESTIONS

1. ET opening is enhanced with all of the following, except
   a. Blowing through nose when nostrils are pinched (Valsalva maneuver)
   b. Yawning
   c. Swallowing
   d. None of the above

2. Indications for BDET include all of the following, except
   a. Development of effusion after extrusion of tubes
   b. Recurrent retraction pocket cholesteatoma
   c. Otophonia
   d. Recurrent barotrauma

3. For ETD, when indicated, all of the following procedures may be utilized, except
   a. BDET
   b. Adenoidectomy
   c. Submucosal injection of filling material by the ET orifice
   d. Z-plasty of levator veli palatine muscles if there is a submucous cleft

ADDITIONAL SOURCES

Alper CM, Bluestone CD, Casselbrant ML, et al. Advanced Therapy of Otitis Media. Hamilton, Ontario: BC Decker Inc.; 2004.
Bluestone CD, Rosenfeld RM. Surgical Atlas of Pediatric Otolaryngology. Hamilton, Ontario: BC Decker Inc.; 2002.

ADDITIONAL SOURCES

Alper CM, Bluestone CD, Casselbrant ML, et al. Advanced Therapy of Otitis Media. Hamilton, Ontario: BC Decker Inc.; 2004.
Bluestone CD, Rosenfeld RM. Surgical Atlas of Pediatric Otolaryngology. Hamilton, Ontario: BC Decker Inc.; 2002.

ADDITIONAL SOURCES

Bluestone CD. Eustachian Tube Structure, Function, Role in Otitis Media. Hamilton, Ontario: BC Decker Inc.; 2005.

204 Congenital Malformations of the Middle Ear

David H. Chi

INTRODUCTION

Congenital anomalies of the ear are estimated to occur in 1 in 11,000 to 15,000 patients.[1] Isolated middle ear anomalies with a normal pinna and external ear canal account for a fraction of these anomalies, whereas approximately one-fourth of congenital middle ear anomalies are associated with syndromes.[2]

Congenital malformations of the middle ear are usually encountered in two situations. First, these may be suspected when a child has an unknown cause of conductive hearing loss not attributable to otitis media or trauma. The otoscopic examination or computed tomography (CT) scan may help to identify the malformation, and the findings are confirmed at the time of surgery.

The otologic surgeon may also encounter middle ear malformations incidentally during tympanoplasty or middle ear exploration for stapes surgery. Regardless, the surgeon has to be aware of the various potential anomalies and management options when these anomalies are encountered.

KEY OPERATIVE LEARNING POINTS

1. Middle ear malformations should always remain in the differential diagnosis in children with conductive or mixed hearing loss.
2. An incidental encounter with a congenital middle ear malformation may occur during any otologic surgery.
3. A CT scan should be obtained in pediatric patients with conductive hearing loss not associated with otitis media.
4. Inner ear causes of conductive hearing loss such as superior semicircular canal dehiscence, large vestibular aqueduct, and large internal auditory canals should be evaluated prior to middle ear surgery.
5. The surgeon should be familiar with various reconstructive methods and verify their availability prior to surgery.
6. An aberrant facial nerve may be associated with anomalies of the middle ear, and the surgeon has to be vigilant to recognize this possibility to avoid injury.

PREOPERATIVE PERIOD

History

1. History of present illness involves a comprehensive otologic history. For infants, the newborn hearing screen may help initially to identify congenital conductive hearing loss. For older children and adults, the duration of the hearing loss is important. Congenital hearing loss is suspected when hearing loss has been present since childhood.
2. Otologic history: otalgia, otorrhea, tinnitus, vertigo
3. History of prior otologic surgery
4. Family history of hearing loss and surgery to improve hearing
5. Social and developmental history: impact of hearing loss on speech and language development and performance in school
6. Review of systems may reveal ophthalmologic, cardiac, renal, or other medical problems suggestive of a syndromic diagnosis.

Physical Examination

1. Other craniofacial anomalies that may make congenital ear anomalies more likely
   a. Abnormalities of the pinna or preauricular skin tags or pits
   b. Branchial arch anomalies, such as defects of the mandibular arch (e.g., Treacher Collins syndrome). These findings also may predict difficulties in securing the airway during anesthesia.
2. The external auditory canal must be evaluated to determine adequacy for exposure and visualization during surgery.
3. The tympanic membrane should be examined for any apparent middle ear anomalies, such as vascular defects or anomalies of the malleus.
4. Tuning fork testing should be performed to establish consistency with audiologic testing.

Imaging

CT of the temporal bone is indicated when conductive hearing loss is present and not attributable to otitis media in a pediatric patient. Careful evaluation of the temporal bone may determine the etiology of the hearing loss. In addition, inner ear causes of conductive hearing loss may be identified. For example, semicircular canal dehiscence or dilatation of the internal auditory canal with X-linked gusher syndrome may result in nonsurgically reparable conductive hearing loss. Mutations in the gene encoding the POU3F4 transcription factor have been implicated in at least one form of X-linked progressive mixed hearing loss. Perilymph gusher may occur with opening of the footplate. This is thought to be secondary to patent cochlear aqueduct or a defect in the lateral end of the dilated internal auditory canal. Superior canal dehiscence syndrome and a large vestibular aqueduct may also be an inner ear cause of conductive hearing loss (Fig. 204.1). The conductive loss is thought to be secondary to the third window phenomenon. Surgery is not indicated in these cases.

CT images should be examined carefully for abnormalities of the ossicular chain and to assess for an aberrant course of the facial nerve.

Indications for Surgery

1. Middle ear exploration is indicated when a patient presents with conductive hearing loss without an identifiable etiology on physical examination or CT.
2. CT finding that may account for the hearing loss and is amenable to reconstruction

Contraindications

1. Medical comorbidities that will increase the risks of general anesthesia
2. Only hearing ear

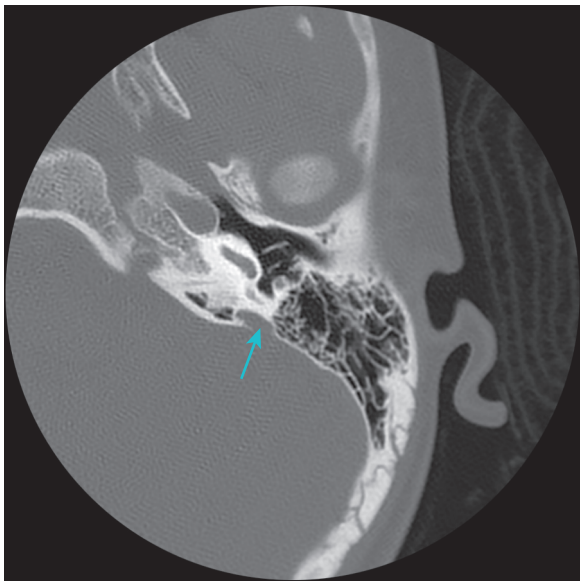

Fig. 204.1. Temporal bone computed tomography of a child with left conductive hearing loss and large vestibular aqueduct *(arrow)*. Interestingly, the sister also has large vestibular aqueducts and sensorineural hearing loss. No surgery is recommended for this patient.

3. Vascular anomaly that may not be surgically correctable or increases the risk of vascular trauma
4. Otitis-prone child
5. Inner ear causes for conductive or mixed hearing loss. Surgery may increase the risk of perilymphatic gusher.

Preoperative Preparation

1. Audiogram to determine baseline hearing. Testing may be challenging in a pediatric patient. Conductive hearing loss is common in children, secondary to otitis media. It is important to confirm that the air-bone gap closes after the middle ear aerates in these children to rule out congenital middle ear anomalies that are accounting for the hearing loss. Tympanometry should also be considered in children to help to confirm otoscopic findings.

OPERATIVE PERIOD

Anesthesia

- Children require general anesthesia so that surgery can be performed comfortably and safely.
- In select adults, exploratory surgery may be done under local anesthesia with intravenous sedation. Benefits include less postoperative analgesia, quicker patient mobilization, reduced risk for aspiration, the ability to test hearing during surgery, and immediate feedback about potential vestibular injury.
- Long-acting paralytics should be avoided if facial electromyography (EMG). Monitoring is anticipated.

Positioning

The patient is placed in the supine position with the head turned so that the operative ear is facing toward the surgeon.

Preoperative Antibiotics

None necessary

Monitoring

Facial nerve monitoring with facial electromyography should be considered to assist when dissecting along the facial nerve or when facial nerve anomalies are suspected.

Instruments and Equipment to Have Available

1. Basic tympanoplasty/mastoidectomy set
2. Microscope or otoendoscope, per surgeon preference
3. CO_2 laser if middle ear adhesions or stapedectomy with laser is preferred
4. Drill, if severe bony overhangs or bony anomalies are encountered
5. Ossicular reconstruction prosthesis

Key Anatomic Landmarks

1. Malleus
2. Incus and stapes superstructure
3. Footplate of the stapes
4. Cochlear promontory and round window
5. Cochleariform process and horizontal position of the facial nerve
6. Aberrant vascular structures, such as high-riding jugular bulb, aberrant carotid artery, or persistent stapedial artery

Prerequisite Skills

1. Tympanoplasty
2. Ossciuloplasty
3. Stapedectomy

Operative Risks

1. Tympanic membrane perforation from the elevation of the tympanomeatal flap
2. Dysgeusia from injury to the chorda tympani nerve
3. No improvement or worsened hearing to the point of profound deafness
4. Balance disruption
5. Facial nerve injury resulting in facial paralysis
6. Vascular injury requiring further surgery or interventional radiology
7. Cerebrospinal fluid leak

Surgical Technique

Overview

The majority of the operative techniques used in addressing congenital middle ear malformations are similar to other tympanoplasty methods. Procedures for middle ear reconstruction after eradication of chronic middle ear disease are adaptable in addressing congenital middle ear anomalies. The surgeon may use various methods to correct conductive hearing loss. It is important that equipment and prosthesis are available in the operating room. Surgeon preference will determine whether autologous grafts (incus interposition graft, cartilage) or prosthetics (titanium, plastipore, hydroxyapatite, bone cement) are used. Appropriate drills and laser equipment should be available if necessary.

Regardless of the materials chosen, the basic principles for reconstruction of the middle ear conductive hearing apparatus include placement of the appropriately sized prosthesis in an adequately aerated middle ear. Accurate sizing and measurement takes patience and experience. Short prostheses may not adequately conduct sound and are prone to slippage. A long

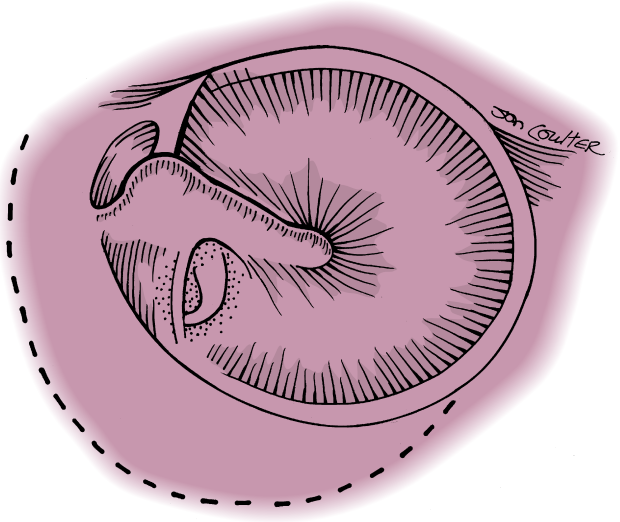

Fig. 204.2. Incision for tympanomeatal flap.

prosthesis is at risk for extrusion or potential subluxation into the vestibule. Certain total or partial ossicular reconstruction prostheses (TORP or PORP, respectively) may require cartilage grafting to prevent extrusion.

1. Surgery for middle ear anomalies begins with a four quadrant injection of local anesthetic in combination with epinephrine to minimize bleeding during elevation of the tympanomeatal flap.
2. The tympanomeatal flap is elevated to enter the middle ear space (Fig. 204.2). The flap should extend far enough superiorly to allow for removal of the scutum, if necessary. If a high-riding jugular bulb is present, care should be taken when entering the middle ear posteroinferiorly, as the jugular bulb may be entered during flap elevation.
3. Upon entering the middle ear, the landmarks are visualized and the ossicles are palpated to determine if any levels of fixation are present. The following techniques are related to the various abnormalities identified in the middle ear.
   a. **Anomalies of the stapes.** Defects of the stapes are the most frequently encountered of all ossicular defects. However, the significance is based on the impact on hearing. Even defects such as a monopedal stapes are clinically unimportant unless hearing loss is present (Fig. 204.3A). The shape of the crura and obturator foramen needs to be assessed (see Fig. 204.3B). Mobility of the superstructure and footplate along with its attachment to the incus is determined.
      1) Bony bridges may attach the superstructure to the promontory (see Fig. 204.3C). These bridges may be separated by fracturing or dividing them with CO_2 laser.
      2) The stapes structure may not be in contact with the footplate (see Fig. 204.3D). The arch defect is detached from the incus. Reconstruction may occur with an ossicular reconstruction prostheses or stapes prosthesis based on the status of the remaining ossicles and mobility of the footplate.
      3) Congenital footplate fixation. This finding develops as a blending of the bone of the footplate with the surrounding otic capsule and the absence of a visible annular ligament (see Fig. 204.3E). The fixed stapes is often deformed. Surgical results for stapes fixation in the setting of isolated fixation are quite good. However, the outcomes are diminished in the presence of associated abnormalities of the incudomalleolar complex. The lower outcome is thought to be secondary to decreased stability of the reconstruction when the prosthesis extends to the malleus or to the tympanic membrane. On occasion, the footplate is thickened and may require a drillout. This is performed in a fashion similar to that used for obliterative otosclerosis. The oval window is gradually saucerized with a microdrill until the footplate is bluelined. Fenestration of the footplate is performed in the usual manner, followed by placement of the stapes prosthesis.
      4) Footplate defects are rare findings associated with inner ear anomalies (Fig. 204.4). Clinically, children may present with recurrent meningitis or CSF otorrhea or rhinorrhea. Treatment usually involves exploration of the middle ear, removal of the remnant footplate, and obliteration of the opening with soft tissue.
   b. **Anomalies of the incus**
      1) The most common defect of the incus is hypoplasia of the long or lenticular process resulting in a fibrous incudostapedial joint (Fig. 204.5). This finding is similar to the incus erosion that occurs with chronic otitis media and tympanic membrane retraction. Surgical options for this malformation include bone cement to reattach the incus to the stapes. Other alternatives include incus interposition graft or PORP.
      2) The incudomalleal joint fusion is a common finding in aural atresia but may also occur in isolation (Fig. 204.6). Bony attachments may occur within the attic or to the manubrium. Bony attachments to the malleus may require separation with a malleus nipper or with CO_2 laser. Fixation in the epitympanum may be addressed with mobilization, but this has been associated with risk of refixation. Alternatively, the incudostapedial joint may be separated, and the incus interposition graft or PORP may be used.
   c. **Anomalies of the malleus.** Anomalies of the malleus are uncommon.
      1) Complete absence of the malleus has been described only in the presence of multiple abnormalities.
      2) Absence or discontinuity of the manubrium from the neck and head has been reported (Fig. 204.7). This defect may be addressed with disarticulation of the incudostapedial joint and placing a PORP onto the stapes.
      3) Separation of the malleus from the tympanic membrane. This defect may be addressed with tympanoplasty grafting medial to the malleus. Alternatively, the PORP may be placed from the stapes to the tympanic membrane.
      4) Fixation of the malleus may also occur to create a conductive hearing loss. Bony or fibrous attachments may occur at the scutum. The malleus may also be fused to the incus. Initial attempts at mere division have resulted in refixation and recurrence of the hearing loss. Thus division of the incudostapedial joint is recommended, followed by separation of the manubrium from the head of the malleus. This is followed by PORP placement or incus interposition graft.
   d. **Anomalies of the facial nerve**
      1) The surgeon must be familiar with the anatomy of the facial nerve and the most common aberrant course.

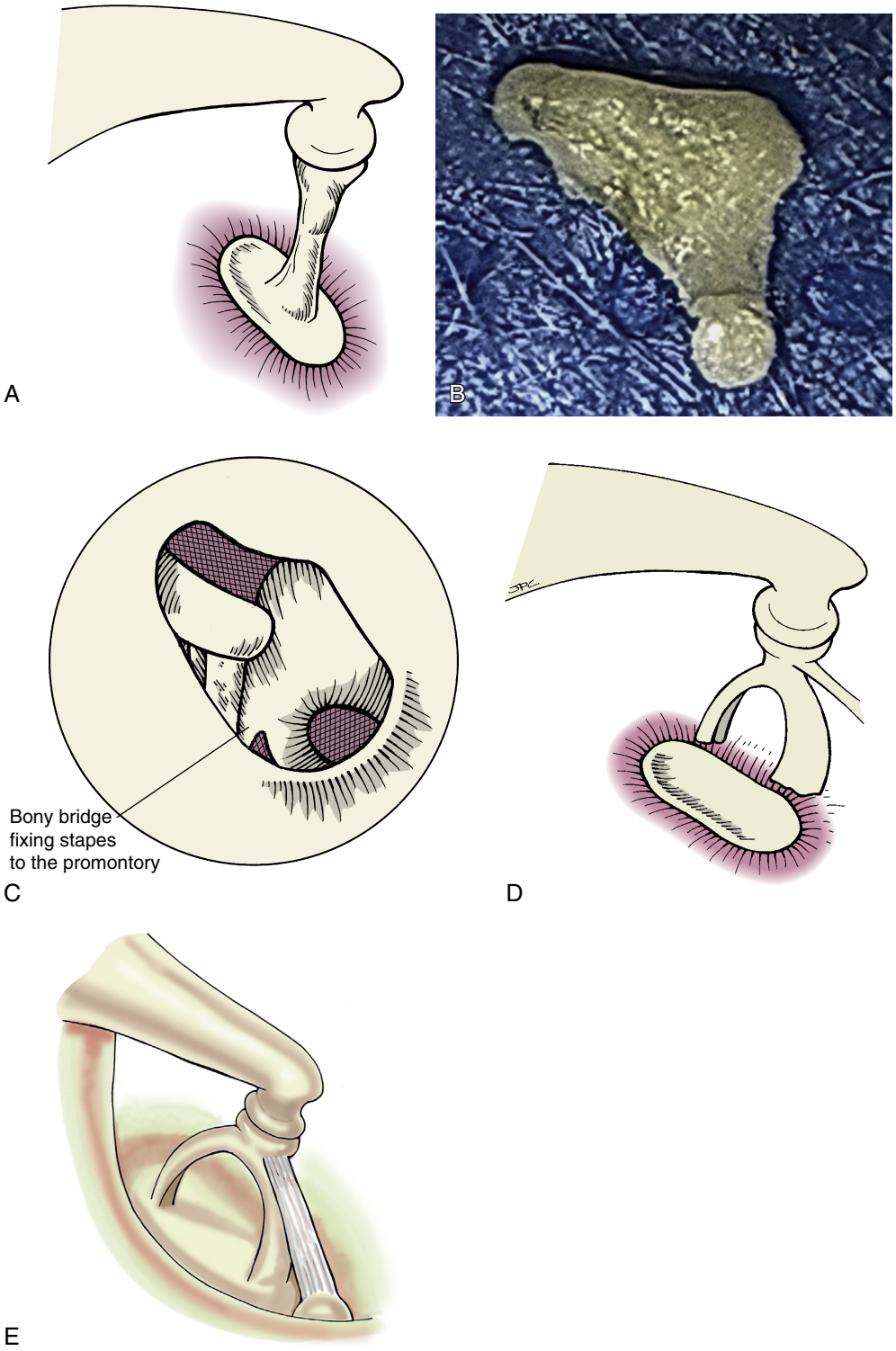

Fig. 204.3. **A,** Monopedal stapes superstructure. **B,** Stapes of patient with fused crura and a malformed footplate. **C,** Bony attachment from promontory to stapes. **D,** Congenital discontinuity of the stapes superstructure to the footplate. **E,** Congenital footplate fixation with absence of the annular ligament.

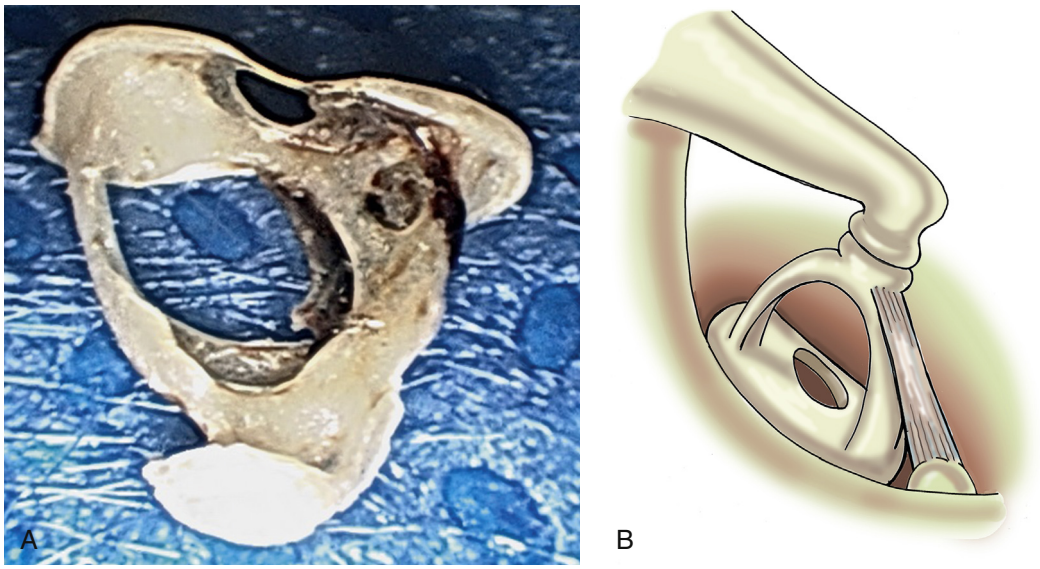

Fig. 204.4. Stapes of a child with cerebrospinal fluid rhinorrhea and a defect in the footplate.

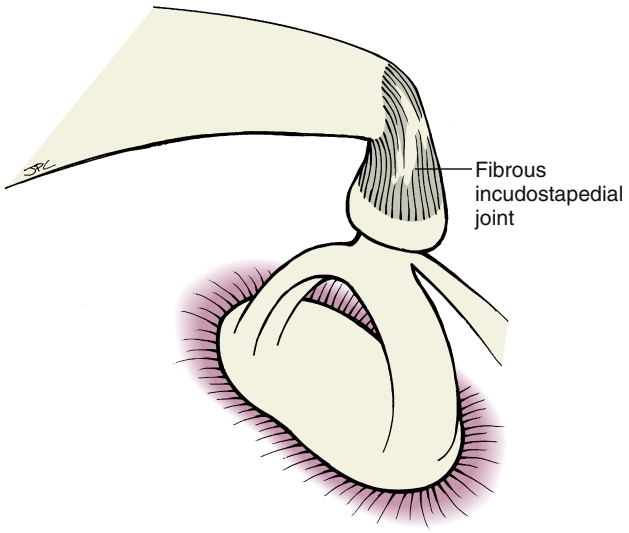

Fig. 204.5. Fibrous incudostapedial joint.

2) Dehiscence of the horizontal facial nerve is very common and may be considered a normal variant. The surgeon has to recognize this finding and avoid trauma to this area.
3) Prominent overhang of the facial nerve may make access to the oval window more challenging when a prosthesis is necessary. Gentle retraction of the nerve may allow for access to the oval window. A stapes prosthesis may be placed in close contact to the nerve and may even make an indentation in the epineurium.
4) The facial nerve may subdivide into several branches and may not even be within a bony fallopian canal. The nerve may course over the oval window, preventing access to the footplate (Fig. 204.8). In these cases, surgery should be abandoned. On occasion the vertical portion of the facial nerve is displaced anteriorly and traverses across the hypotympanum.

e. **Vascular anomalies**
   1) Aberrant carotid artery may be seen coursing through the middle ear and appears on CT as a soft tissue mass along the promontory that enters the horizontal carotid canal through a dehiscence in the lateral carotid plate (Fig. 204.9A). This finding is not amenable to surgical therapy. The danger is mistakenly considering that the mass represents a glomus tumor. Puncture or biopsy may lead to significant hemorrhage and potential neurologic sequelae.
   2) High-riding jugular bulb. The jugular bulb is defined as being high riding when the most cephalad portion reaches superiorly to the level of the floor of the external auditory canal. Occasionally, a diverticulum of the bulb may reach even farther cephalad (see Fig. 204.9B). The high-riding jugular bulb is usually asymptomatic and does not require intervention. Occasionally, it reaches superior enough that symptoms may arise including pulsatile tinnitus and conductive hearing loss. If symptoms are present, the bulb may be skeletonized and displaced inferior to the round window by a cartilage or cortical bone graft.
   3) Persistent stapedial artery. Small remnants of the artery usually present no problem, and the small amount of bleeding will cease. Large remnants (Fig. 204.10) of the stapedial artery require careful attention. Access to the footplate is possible by working anterior or posterior to the vessel.

f. **Anomalies of the round window.** Congenital absence of the round window is a rare finding. As the otic capsule ossifies during development, a cartilaginous ring prevents bone depositions at the site of the round window. Improper formation of this cartilaginous ring is thought to result in an absent round window. Fenestration of the promontory to create a round window is not advised because of the significant risk of sensorineural hearing loss.

Common Errors in Technique

1. Limited visualization of the middle ear secondary to inadequate exposure from the tympanomeatal flap

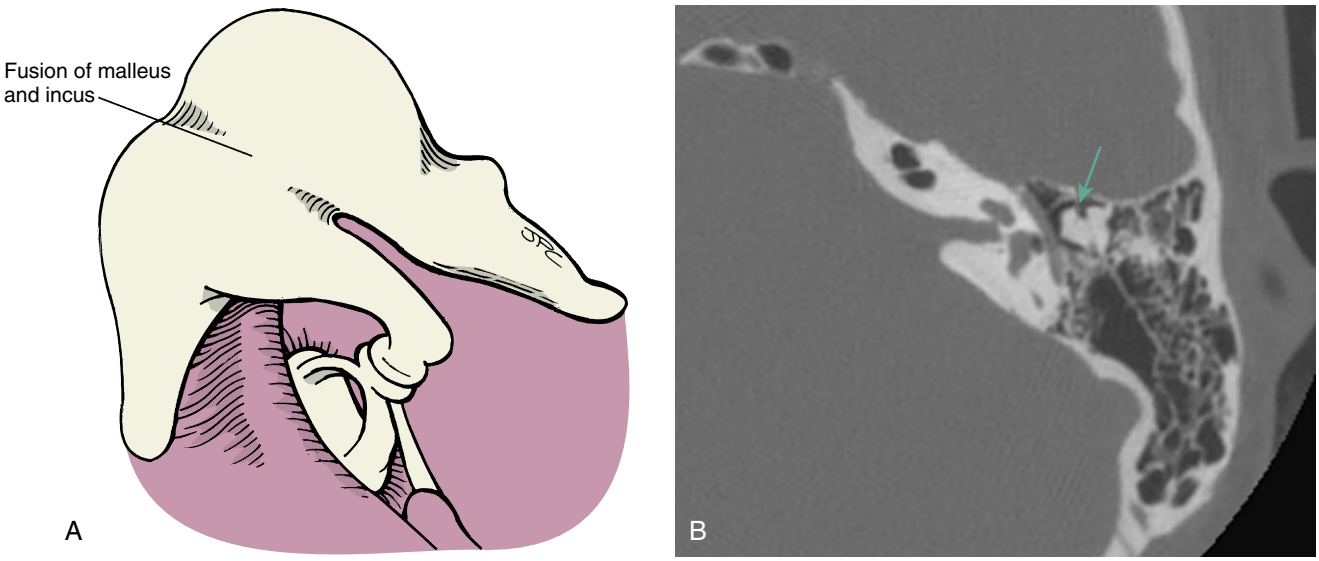

Fig. 204.6. A, Fused malleus and incus. **B,** Computed tomography of fused malleus and incus *(arrow)*.

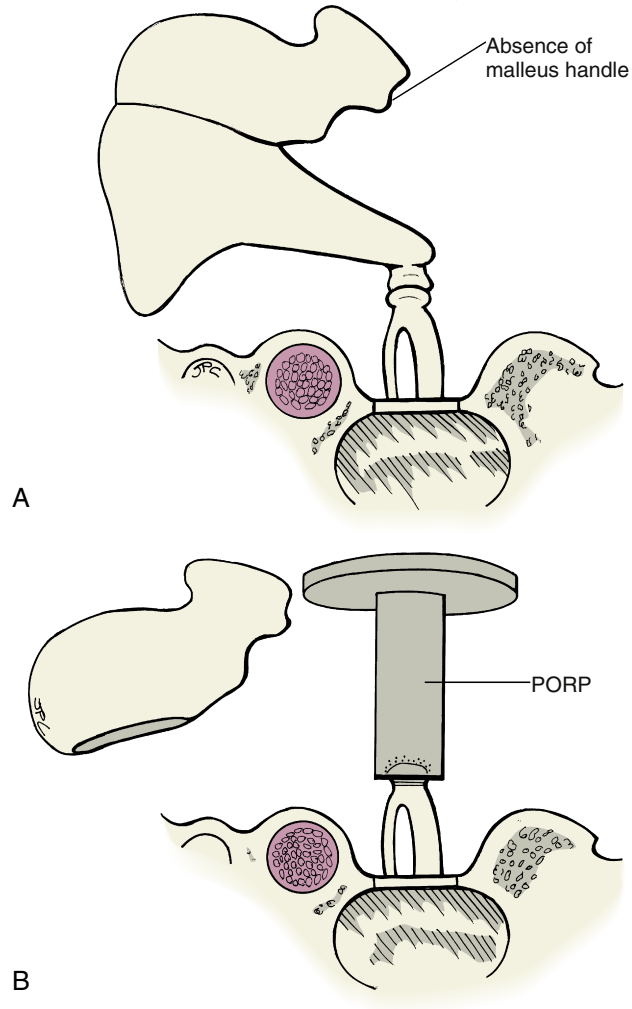

Fig. 204.7. A, Absent manubrium. **B,** Repair with a partial ossicular reconstruction prosthesis.

2. Inadequate assessment of the mobility of the ossicular chain
3. Inadequate fitting of the ossicular prosthesis

POSTOPERATIVE PERIOD

Postoperative Management

1. Ear dressing is left on for 2 to 3 days.
2. Limited activities for 4 weeks
3. No water exposure to the ear canal for 4 weeks. May use ear plug or cotton ball coated with Vaseline petroleum jelly or antibiotic ointment in the ear canal starting 3 days after surgery
4. When a perilymph gusher is encountered, the head is maintained at an elevation of at least 30 degrees. Stool softeners are ordered to minimize Valsalva maneuvers. If drainage persists, a lumbar drain may be required.

Immediate Complications

1. Facial nerve injury. Temporary facial paralysis may occur from diffusion of local anesthetic toward the stylomastoid foramen. A brief period of observation will soon identify these cases. Delayed onset of facial paralysis is followed expectantly because this finding is thought to be from edema of the facial nerve. When complete paralysis is immediate and without explanation, re-exploration may be necessary to rule out disruption of the facial nerve.
2. Deafness. In the immediate postoperative period, hearing loss may be evaluated with a tuning fork. Conductive hearing loss is expected because of packing in the canal and effusion in the middle ear.
3. Perilymphatic gusher. Excessive flow of perilymph after opening into the vestibule is more common with congenital footplate fixation than otosclerosis. When encountered, the head of bed should be elevated. The surgeon should avoid suctioning the vestibule. A fascia graft should be placed over the defect. An intraoperative lumbar drain may be considered if conservative measures fail to resolve the leak. The preoperative CT scan should be reviewed to identify

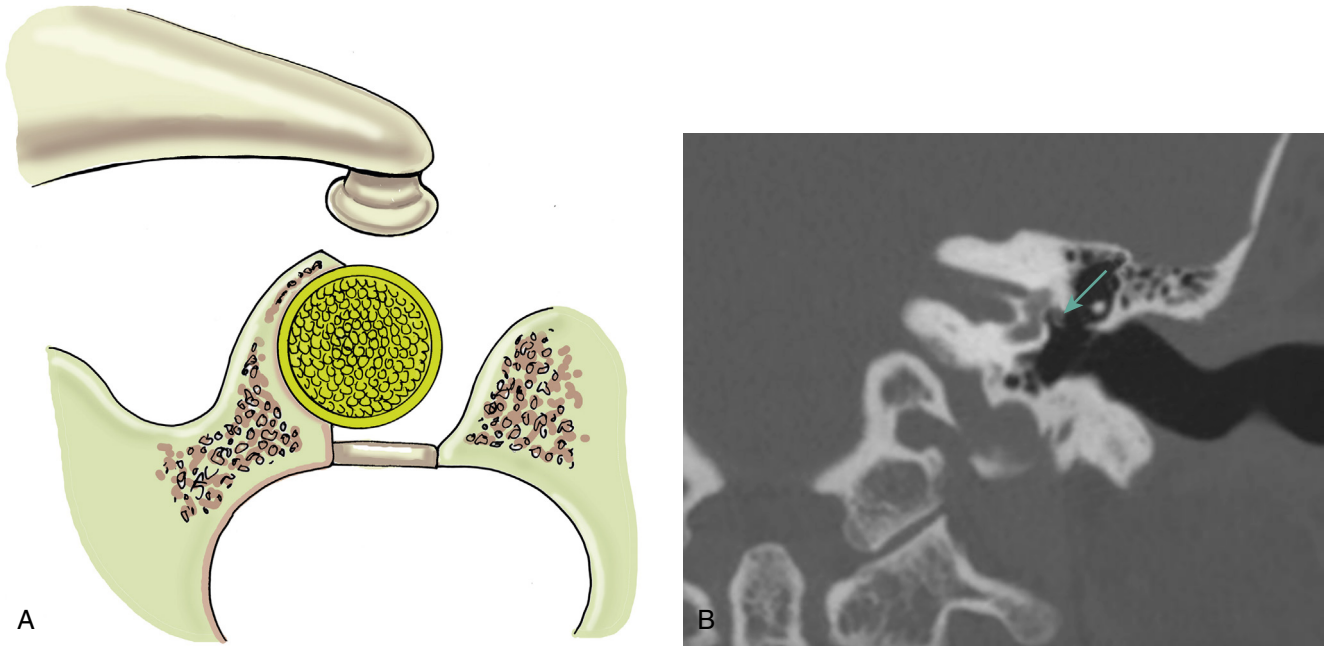

Fig. 204.8. A, Facial nerve coursing over the footplate. **B,** Computed tomography of facial nerve *(arrow)* over oval window.

any inner ear malformations that may have accounted for the gusher.

4. Vertigo. Mild vertigo may occur with any otologic surgery but is more common in cases that involve opening the oval window. Severe vertigo suggests a potentially serious problem. Fistula, subluxation of the footplate, and long prosthesis extending into the vestibule are part of the differential diagnosis. Sensorineural hearing loss can occur with this finding. Surgical exploration should be considered if these causes are suspected.
5. Tympanic perforation. Fascia grafting may be necessary if a significant tear is recognized intraoperatively.
6. Vascular injury. Bleeding secondary to injury to the jugular bulb will typically stop with packing the middle ear with Surgicel. Injury to the carotid artery may be catastrophic. The ear should be packed and interventional radiology should be consulted urgently. Type and cross of blood should be obtained immediately.

Long-Term Complications

1. Conductive hearing loss

The prosthesis may become displaced, resulting in ossicular discontinuity and loss of hearing. When using a prosthesis that is in contact with the tympanic membrane with or without cartilage, extrusion may occur resulting in conductive hearing loss.

2. Cholesteatoma

May occur from the epithelial trapping during healing of the tympanomeatal flap

Alternative Management Plan

1. Hearing aids are an option for those who are not candidates for surgery.
2. Observation for those with minimal hearing impairment or those who do not desire intervention

DISCUSSION

Evidence-Based Medicine Question

How are the surgical outcomes for congenital footplate fixation (CFF) compared with juvenile otosclerosis (JO)?

Stapes surgery in children is uncommon compared with stapedectomy for otosclerosis in adults. Controversy remains regarding stapedectomy in pediatric patients because hearing aids provide good rehabilitation, and some surgeons prefer that a child be old enough to participate in the decision-making process. JO usually presents later with progressive, low-frequency hearing loss, whereas CFF typically presents earlier with greater hearing loss.[3] Family history of otosclerosis is usually present in 53% of JO cases and only 9.8% of CFF cases.[4] The majority of cases demonstrate that CFF is the etiology of the conductive hearing loss compared with JO.[5]

A meta-analysis of surgical outcomes for juvenile otosclerosis versus congenital footplate fixation showed the air-bone gap was less than 10 dB in 80.2% of cases in JO and 54% for CFF. Combined, the overall success rate is 69.9%.[6] Unfortunately, the differentiation of the two causes is at the time of middle ear exploration.

Editorial Comment

With the advances in cochlear implant technology for pediatric patients, the management of pediatric sensorineural hearing loss has been revolutionized. Medical literature and outcomes research support cochlear implants as the accepted standard of care for children with severe to profound sensorineural hearing loss who do not benefit with hearing aids alone.

In contrast, the treatment of conductive hearing loss due to congenital middle ear anomalies has received comparatively little attention. Surgical techniques have been refined, but controversies in the timing of intervention and in the specific approaches to treatment of these relatively uncommon anomalies persist.

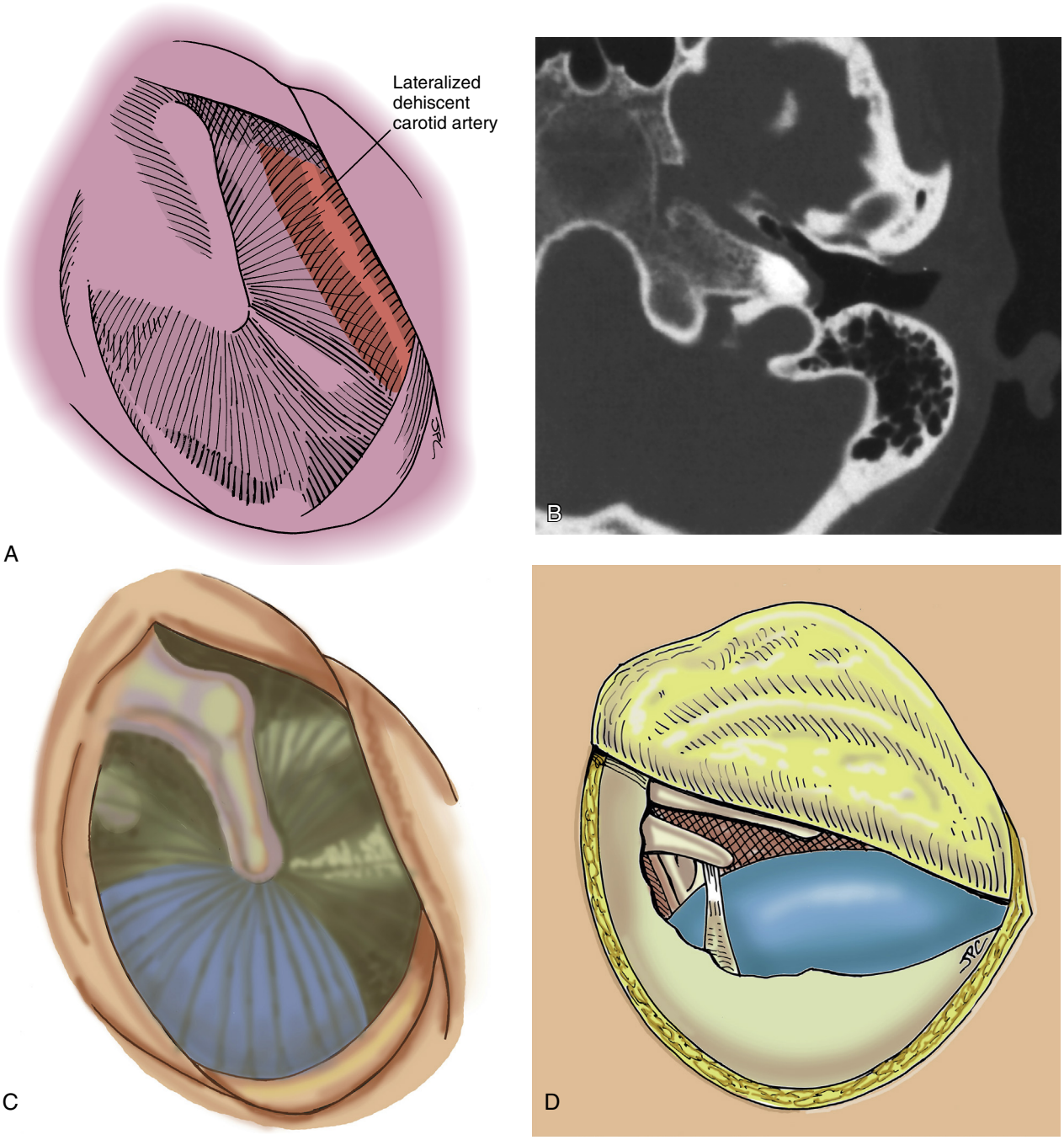

Fig. 204.9. A, Aberrant carotid artery as seen through tympanic membrane. **B,** Computed tomography of aberrant carotid artery. **C,** High-riding jugular bulb as seen through tympanic membrane. **D,** High-riding jugular bulb abutting the stapes superstructure.

The author of this chapter has ably and concisely summarized the current guidelines and has highlighted areas of persistent controversy and uncertainty. The reader is reminded that middle ear anomalies may be seen in children with conductive hearing loss, with or without active middle ear disease, and also that middle ear anomalies may be encountered incidentally during middle ear surgery for reasons such as tympanoplasty.

CT scan of the temporal bone is recommended when conductive hearing loss is present in the absence of middle ear disease. Rare inner ear causes of conductive hearing loss will be seen occasionally, which will impact the decision for surgery, as may vascular anomalies or abnormalities of the facial nerve.

Malformations of the middle ear are uncommon, a wide variety of autologous grafts and prostheses are available, surgical techniques differ from one surgeon to another, and the congenital anomalies are not all of one type. For these and other reasons, outcomes are not well established, and consensus on the timing and nature of surgical intervention has not been reached. Advances in surgical technique, technology for amplification, and clinical outcome measurement together hold the promise for a better understanding of the optimal treatment for children with conductive hearing loss due to congenital malformations of the inner ear.

Ellis M. Arjmand

Access the review questions online at http://www.expertconsult.com

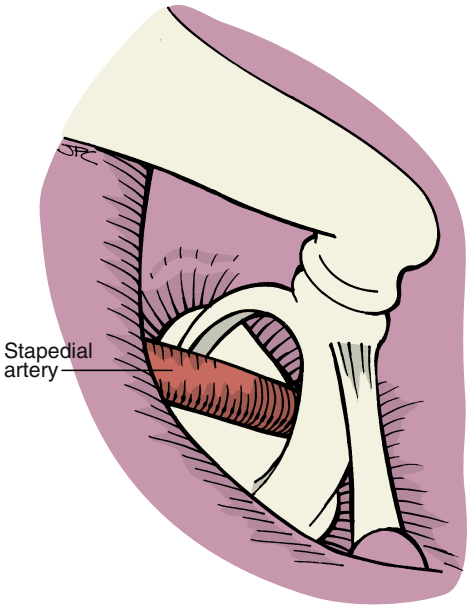

Fig. 204.10. Persistent stapedial artery.

Acknowledgments

Drs. Donald B. Kamerer, Arpita I. Mehta, and Yael Raz are acknowledged for their contributions to the previous editions. In addition, Dr. Barton Branstetter is recognized for generously sharing radiographic images of middle ear malformations.

REFERENCES

1. Farrior JB. Surgical management of congenital conductive deafness. South Med J 1987;80(4):450–453.
2. Cremers CW, Teunissen E. The impact of a syndromal diagnosis on surgery for congenital minor ear anomalies. Int J Pediatr Otorhinolaryngol 1991;22(1):59–74.
3. Carlson ML, Van Abel KM, Pelosi S, et al. Outcomes comparing primary pediatric stapedectomy for congenital stapes footplate fixation and juvenile otosclerosis. Otol Neurotol 2013;34(5):816–820.
4. De la Cruz A, Angeli S, Slattery WH. Stapedectomy in children. Otolaryngol Head Neck Surg 1999;120(4):487–492.
5. Denoyelle F, Daval M, Leboulanger N, et al. Stapedectomy in children: causes and surgical results in 35 cases. Arch Otolaryngol Head Neck Surg 2010;136(10):1005–1008.
6. Asik B, Binar M, Serdar M, et al. A meta-analysis of surgical success rates in congenital stapes fixation and juvenile otosclerosis. Laryngoscope 2016;126(1):191–198.

REVIEW QUESTIONS

1. Which ossicle(s) is/are associated with highest proportion of congenital anomalies?
   a. Malleus
   b. Incus
   c. Stapes
   d. Fused malleus incus

2. Which statement about stapes surgery in children is CORRECT?
   a. The most common indication is juvenile otosclerosis.
   b. Hearing outcomes are similar for otosclerosis and congenital footplate fixation.
   c. Aberrant course of the facial nerve is rare in congenital footplate fixation.
   d. Hearing outcomes are better for congenital footplate fixation when other ossicular anomalies are absent.

3. Which of the following is NOT an appropriate option for malleoincudal fixation?
   a. Incus interposition graft
   b. Stapedectomy
   c. Partial ossicular reconstruction prosthesis
   d. Total ossicular reconstruction prosthesis

205 Pediatric Cochlear Implantation

Michael S. Cohen, David H. Chi

INTRODUCTION

The cochlear implant (CI) is unique among medical devices in that it serves as a neurosensory prosthesis capable of restoring or providing de novo the sense of hearing to its users. As technology advances with hardware, sound processing algorithms, and mapping strategies, CI users have achieved ever more impressive outcomes in both hearing and speech development. Many children born with severe to profound hearing loss today will go on to participate in mainstream curricula with the help of CIs. The US food and drug administration (FDA) has approved the use of CIs in children at least 1 year of age, and in certain cases, surgeons will implant children off-label at substantially younger ages. With careful patient selection, attention to surgical technique, and comprehensive postoperative rehabilitation, the CI is an extremely viable option for restoring hearing in children with severe to profound hearing loss.

KEY OPERATIVE LEARNING POINTS

- Careful patient selection is the key to achieving optimal hearing and speech outcomes
- Use of intraoperative facial nerve monitoring is recommended
- Review of imaging prior to surgery is critical to anticipate anatomic variants, such as:
  - High-riding jugular bulb
  - Low-hanging dura
  - Narrow facial recess width
  - Bifid or dehiscent facial nerve
  - Stenotic round window niche
  - Cochleo-vestibular abnormalities, including enlarged vestibular aqueduct
- Be sure to calculate an appropriate weight-based volume of local anesthetic prior to injection. In very young children, the maximum allowable volume is often less than 10 cc of 1% lidocaine.
- To increase symmetry for bilateral simultaneous implantation, use metal templates to determine optimal location for incisions and for subperiosteal pocket development.
- Hemostasis at each step is critical, especially in very young children. Allow adequate time for vasoconstrictor effect, have bipolar cautery available (especially for the second side on bilateral surgery), use bone wax for unpneumatized diploic bone during mastoidectomy.
- Fixation can be achieved with a traditional well, with stay sutures, or with a tight subperiosteal pocket. Be prepared to use any of the above options if needed to ensure the secure positioning of the receiver stimulator.
- Device manufacturer and electrode choice will depend upon patient preference, anatomic considerations, and surgeon/implant program experience and routine. Be familiar with the device electrode to be implanted as there are subtle but critically significant differences among them.
- Soft surgery techniques can optimize outcomes not only by preserving residual hearing, but by preserving spiral ganglion neurons. These may include:
  - Use of systemic and/or topical steroids intraoperatively
  - Use a slow drill speed when drilling on the otic capsule
  - Slow electrode insertion to minimize intracochlear pressure during insertion
  - Choice of anterioinferior cochleostomy site confluent with round window or use of the round window approach to ensure scala tympani insertion
- Plugging of the cochleostomy (if performed) is usually accomplished with temporalis fascia or muscle. In bilateral simultaneous cases, harvest enough tissue for both cochleostomies from the first side to eliminate a second step and reduce the potential for bleeding from the contralateral side, particularly when electrocautery can no longer be used.
- Layered closure using absorbable suture.
- A tight mastoid dressing should be left in place for 48 hours. This can be replaced with a Glasscock dressing by the family, to be used during sleep for comfort, or if the child is manipulating the incision.
- Activation is typically performed 3 to 4 weeks postoperatively.

PREOPERATIVE PERIOD

Extensive preparation is necessary prior to embarking upon CI in a child. It is critical to use a multidisciplinary approach for patient selection and preparation of the family and patient for surgery. While the surgery itself takes only a few hours, successful CI use requires months to years of intense therapy, continued device maintenance, and enrollment in an appropriate academic setting that will support the development of speech and language using electronic hearing. Patients should be evaluated by a CI program with experience implanting and habilitating children with hearing loss. Evaluation by Otolaryngology, Audiology, and Speech and Language Pathology are essential to determine candidacy for implantation. Collaboration with other specialties including genetics, social work, developmental pediatrics, neurology, and neuropsychology can help to predict postoperative rehabilitation challenges and set appropriate expectations for performance.

For children with congenital deafness, better speech and hearing outcomes are correlated with earlier age at implantation.[1] The FDA has approved cochlear implantation for children with bilateral severe-to-profound cochlear implantation at 1 year of age or older. Off-label implantation at a younger age is frequently considered, particularly in conditions such as post-meningitic hearing loss, where progressive labyrinthitis ossificans can obliterate the cochlear duct, preventing successful electrode insertion. Children as young as 3 months of age have been successfully implanted.[2]

It is difficult to overstress the importance of establishing a relationship between the family and the entire implant team. Educating families regarding the implant process, especially with regard to the necessary postoperative therapy required for successful use of the device, is critical in preventing implant failure in the form of non-use. While CI technology is certainly one of the more miraculous developments in modern medicine, it is by no means a cure-all, and success requires much more than good surgical technique. Partnering with families in advance to reach this understanding will make the habilitation process a much more positive experience for all parties involved. For families with a language barrier, limited socioeconomic support, or other comorbid medical conditions

requiring frequent appointments, the process is often felt to be overwhelming. It can be helpful to involve social work to facilitate transportation, parking, and coordination of multiple appointments. Often, helpful insight can be obtained from teachers, audiologists, and speech pathologists from the child's school, early childhood program, or early intervention service. Obtaining releases from the parents so providers can discuss cases with these individuals can lead to greater understanding of the needs of the patients and their families. Often creative solutions to problems can be reached in this manner.

Many cases require complex decision making regarding whether the patient will experience overall benefit from a CI. In pre-lingually deafened individuals, neural plasticity decreases over time, limiting the potential benefit of CIs in a time-dependent manner. Still, every case varies and any given child can have results, which exceed expectations. This is an especially important conversation to have with pre-lingually deafened teenagers who come seeking CIs. It is most important to ask what the patient's expectations are in this situation; that is, why do they want an implant? Sound awareness for safety and speech pattern perception to augment and support lip-reading are reasonable expectations in such cases, whereas use of the telephone and development of typical speech are unreasonable expectations.

History

1. History of present illness
   a. Duration and onset of hearing loss
   b. Modality of diagnosis
   c. Etiology of hearing loss, if known
   d. Associated symptoms (if not congenital, e.g., fever, tinnitus, vertigo)
   e. Prior evaluation (diagnostic testing, imaging)
2. Prenatal history
   a. Prenatal ultrasound findings
   b. Maternal screening
   c. Maternal infection
   d. Maternal diabetes
3. Perinatal history
   a. Prolonged labor
   b. Hypoxia
   c. Neonatal intensive care unit (NICU) or special care nursery admission
   d. Intubation/mechanical ventilation
   e. Hyperbilirubinemia
   f. Antibiotic use
   g. Diuretic use
   h. Cytomegalovirus (CMV) infection
4. Other medical history
5. Medications
6. Allergies
7. Vaccination history
   a. Children with hearing loss and children with CIs are at a higher risk for meningitis than the general population.
   b. The Advisory Committee on Immunization Practices of the Centers for Disease Control offers specific guidelines for vaccination of CI recipients (CDC Website link, 2016 https://www.cdc.gov/vaccines/vpd/mening/hcp/dis-cochlear-gen.html)
8. Developmental history
   a. Evaluation by a developmental pediatrician or neuropsychologist to assess for hearing-related and non-hearing-related developmental delays
9. Family history
10. Interventions and social support
    a. Early intervention
    b. Speech therapy
    c. Hearing aid trial/use
    d. Early childhood hearing loss programs
    e. 504 plan or individualized education plan (IEP)
    f. Family understanding and acceptance of diagnosis

Physical Examination

1. General appearance
   a. Level of alertness and interaction with examiner
   b. Dysmorphism/syndromic features
2. Skin
   a. Jaundice
   b. Café au lait spots
3. Head
   a. Microcephaly/macrocephaly
   b. Hair color/white forelock
4. Eyes
   a. Conjugate gaze (if age appropriate)
   b. Heterochromia
   c. Dystopia canthorum
   d. Coloboma
5. Ears
   a. Auricular abnormalities
   b. Microtia
   c. Pits/tags
   d. Middle ear status
6. Nose
   a. Shape
7. Patency throat
   a. Cleft palate
8. Neck
   a. Pits, cysts, masses
9. Extremities
   a. Syndactyly/webbing

Imaging

1. High resolution computed tomography (CT) scan of the temporal bones
   a. Axial and coronal view to evaluate the cochlear anatomy and identify cochleovestibular abnormalities
   b. Assess bony anatomy for surgical approach
      1) Low-hanging dura
      2) Anterior sigmoid sinus
      3) High-riding jugular bulb
      4) Width and density of facial recess
      5) Anatomy of round window
   c. Narrow internal auditory canal (IAC) or cochlear aperture stenosis may suggest cochlear nerve deficiency
   d. Presence of enlarged vestibular aqueduct associated with a higher risk of perilymph gusher
2. Magnetic resonance imaging (MRI) of the temporal bones
   a. Determine the presence of the cochlear nerve
   b. Assess for cochlear ossification, particularly in cases of hearing loss secondary to meningitis
3. Imaging decision making
   a. MRI and CT are complementary studies, with MRI more precise in determining surgical candidacy and CT more useful for technical planning of surgery.
   b. While it is preferable to have both studies, either study is acceptable; the presence abnormal anatomic findings may justify the second study for further delineation of the anatomy.
   c. The risks of each study should be discussed with the family, with CT resulting in radiation exposure and MRI often requiring sedation or anesthesia.

Indications

- Bilateral severe-to-profound sensorineural hearing loss
- Unilateral severe-to-profound sensorineural hearing loss with contralateral progressive hearing loss or at-risk ear (e.g., with enlarged vestibular aqueduct)
- Indications for cochlear implantation in other hearing loss configurations continue to evolve, such as unilateral severe-to-profound loss with stable contralateral hearing, or normal low frequency hearing with mid-high frequency severe to profound loss

Contraindications

1. Patient factors
   a. Medically unstable for the procedure
2. Family factors
   a. Unable to reliably attend mandatory postoperative rehabilitative therapy sessions
   b. Significant family disagreement/dissent regarding diagnosis or surgical plan
3. Anatomic factors
   a. Absent cochlea
   b. Absent cochlear nerve
   c. Severe cochleovestibular abnormalities (relative, consider auditory brainstem implant)
   d. Cochlear nerve deficiency (relative, consider auditory brainstem implant)

Preoperative Preparation

1. Decision by implant team to offer CI
2. Informed consent from family, including understanding of reasonable postoperative expectations for hearing and speech, and required commitment for ongoing therapy
3. Up-to-date vaccination status, specifically with age-appropriate pneumococcal vaccination

OPERATIVE PERIOD

Anesthesia

- No long-acting paralytics due to active monitoring of the facial nerve
- Active communication regarding dosing of local anesthetic use particularly for very young children
- The anesthesia machine is positioned at the foot of the table to create space for the microscope and to switch sides for bilateral simultaneous CI surgery

Positioning

- The patient is kept supine with the head turned approximately 45 degrees away from the surgeon.
- In bilateral simultaneous cases, facial nerve monitoring leads may be placed bilaterally at the start of the case, draping wires in the midline over the forehead, and protecting the skin with a 4 × 4 gauze or sponge

Perioperative Antibiotic Prophylaxis

- Antibiotics are administered during induction of anesthesia and continued for 7 days postoperatively
- Choices
  - Amoxicillin-clavulanate
  - Cephalosporin
  - Clindamycin

Monitoring

- Routine anesthesia monitoring
- Facial nerve monitoring
- Consider intraoperative neural response testing following electrode insertion

Instruments and Equipment to Have Available

  - Post-auricular device template and receiver stimulator templates should be available for non-sterile use for planning incision and subperiosteal pocket location
- Mastoidectomy
  - Otologic surgery set
  - High speed otologic drill
  - Protected or angled 1.5 and 1 mm diamond burs can be helpful for completing facial recess and drilling down round window overhang in young children
  - Craniofacial screws for securing tie-down sutures
- Device insertion
  - Manufacturer-specific device insertion instruments
    - Advance-off-stylet forceps
    - Jeweler's forceps
    - Claw tool
  - 0.3 mm Stapes rasp

Key Anatomic Landmarks

- Mastoid:
  - See mastoidectomy chapter (Chapter 134) for details of mastoidectomy
  - Special consideration must be made to limit bleeding during mastoidectomy, especially in very young children. Bone wax may be used for hemostasis in non-pneumatized marrow containing bone.
  - The facial nerve exit via the stylomastoid foramen is more superficial in young children. Care must be taken to limit the inferior extent of the skin incision to avoid injury to the facial nerve
  - Complete saucerization of the mastoid tip is critical to admit enough light through the facial recess and to allow access to instruments at the appropriate angle for electrode insertion.
- Facial recess:
  - See mastoidectomy chapter (Chapter 134) for details of facial recess dissection
  - In pediatric cochlear implantation, bone removal at the inferior apex of the facial recess is critical for adequate visualization of the round window
- Cochleostomy:
  - Round window overhang
    Variable in extent
    Typically must be drilled away to expose round window membrane
  - Round window membrane
    Pseudomembrane may be present, and may be lysed with Rosen needle or small right angle hook
  - Relationship to stapes footplate/oval window
    Round window will be no more than 2 mm inferior to oval window
    Use a 2 mm round knife to measure, if necessary
  - Appearance of subcochlear tunnel
    Air cell tract appearing adjacent to anterior pillar of round window niche
    Can be mistaken for round window
  - Anatomy of direction of cochlear turns
    Direction of basal turn at the level of round window points toward the top of the head

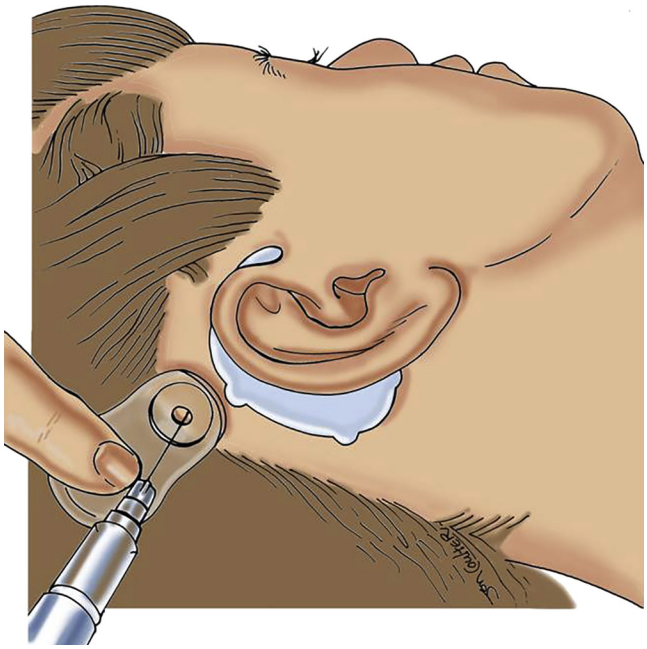

Fig. 205.1. Marking the location of the well with template and methylene blue.

Prerequisite Skills

- Mastoidectomy
- Facial recess: standard and extended
- Extensive knowledge of middle and inner ear anatomy, particularly in cases of middle or inner ear abnormalities

Surgical Technique

- Surgical planning
  - Post-auricular scalp is shaved
  - Anticipated skin incision is demarcated
  - Templates are used to demarcate the location of the receiver-stimulator and the behind the ear processor. Methylene blue in a 3 cc syringe with a 27 gauge needle may be used to mark the cortical bone (Fig. 205.1). The implant needs to be placed sufficiently posterior so that it does not abut the processor.
    Be consistent with the method of marking so the location of the implant is as symmetric as possible when bilateral implants are performed
    The orientation of the implant should be at least 45 degrees from horizontal. In infants, the implant is oriented in even more of a vertical orientation so that the posterior limit of the implant does not overly the occiput
- Soft tissue preparation
  - Skin incision down to level of temporalis fascia
  - Extended anteriorly based subperiosteal flap is created encompassing the location of the well.
  - Subperiosteal pocket is created to accommodate the receiver-stimulator. A dummy silastic or metallic template is used to confirm adequacy of the pocket (Fig. 205.2).
  - A small subtemporalis pocket is made for the ground electrode if present on the CI
  - Temporalis fascia and muscle is harvested and set aside for packing of the cochleostomy.
    If bilateral simultaneous implants are planned, harvest additional fascia and muscle for the contralateral side.

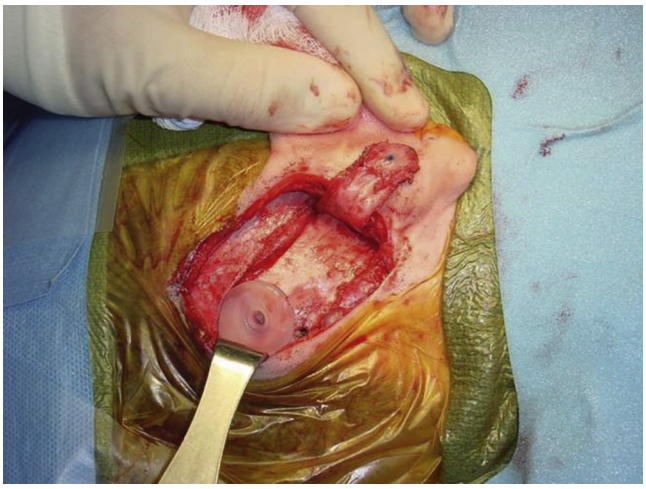

Fig. 205.2. Confirming the adequacy of the subpericranial pocket with a template.

- Mastoidectomy
  - A simple mastoidectomy is performed while identifying common landmarks of the tegmen, the posterior external canal wall, the horizontal semicircular canal, and the short process of the incus.
    Posterior canal wall must be thinned to the level of translucence for adequate visualization of the facial recess
    In a contracted mastoid or when sigmoid sinus is anterior, the scroll region of the posterior canal wall may need to be lowered slightly to allow an adequate view into the facial recess
- Facial recess
  - The facial recess is opened with the landmarks (Fig. 205.3A and B)
    Short process of the incus pointing to the recess
    Incudal buttress: superior border
    Vertical facial nerve: posterior/medial border
    Chorda tympani nerve: anterior/lateral border
    Full dissection of the facial recess is a critical step for successful identification of and access to the round window niche and membrane
  - The middle ear is identified
    Stapedial tendon and incudostapedial joint
    Round window niche
- Preparation of the round window
  - The mucosa of the promontory around the round window may be pre-emptively removed to minimize bleeding; gelfoam with epinephrine may be applied topically for vasoconstriction
  - The round window overhang is removed to identify the round window using a 1 mm or 1.5 mm diamond bur (Fig. 205.4A and B)
  - Drill speed is lowered when removing otic capsule bone
- Preparation of the well
  - A template is used to demarcate the size of the well
  - Per surgeon preference, a well may be drilled to lower the profile of the device
    In infants and young children, limited calvarial thickness may require dural exposure to create adequate depth for the receiver stimulator
    Care must be made not to violate dura
    Tie down holes with sutures may be used. Tying 3-0 silk or nylon suture around the heads of 3 mm craniofacial plating screws may be used as an alternative to drilling holes

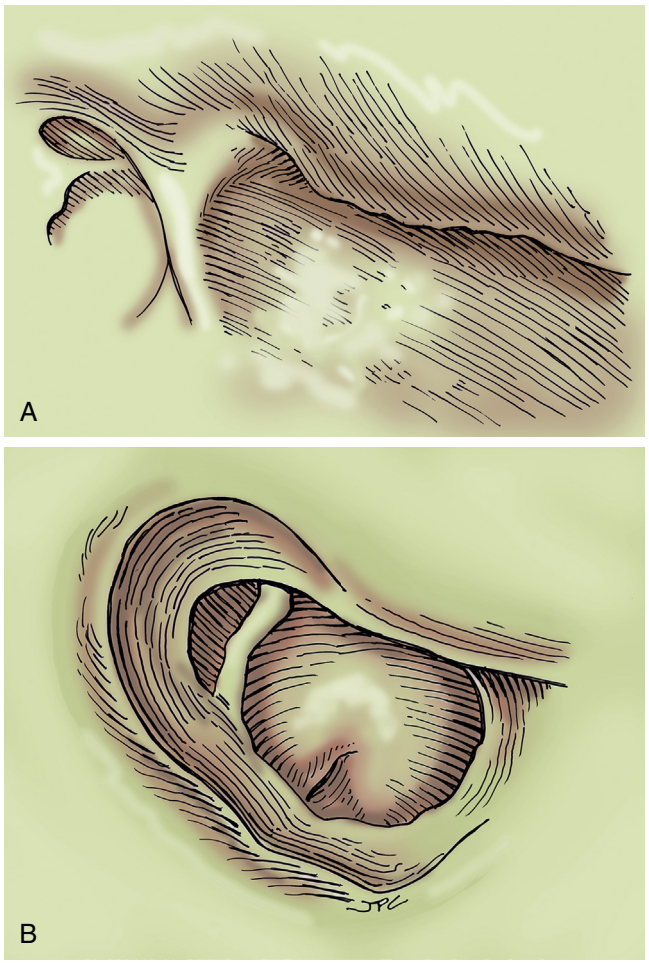

Fig. 205.3. A, Facial recess prior to opening. **B,** Facial recess after opening.

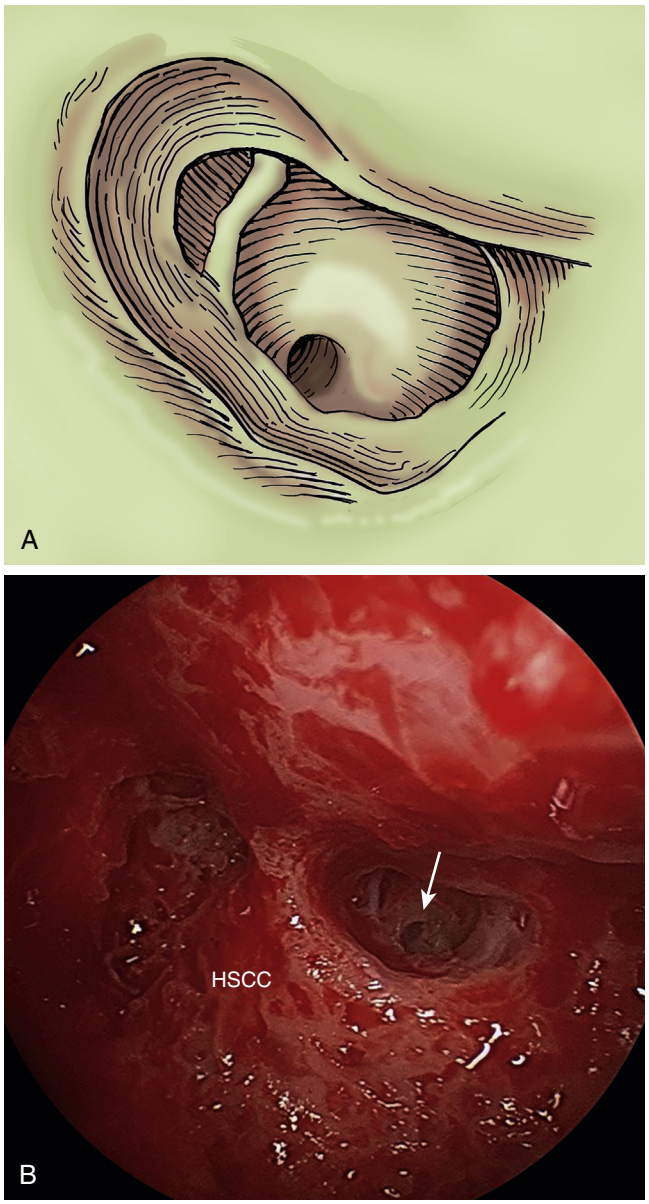

Fig. 205.4. A, Round window overhang is removed to expose the round window. **B,** Mastoid cavity with facial recess opened. *HSSC*, Horizontal semicircular canal. *Arrow* on cochlea.

for tie down sutures (Fig. 205.5). An alternative technique is a tight periosteal pocket to avoid tie down holes or screws
- Trough is made from the well to the mastoid cavity for the electrodes

- Cochleostomy and electrode insertion
  - Wound is copiously irrigated to clear bone dust
  - Implant is placed in the subperiosteal pocket and seated within the well. The electrode is gently draped posteriorly and rested on a clean, lint-free surgical sponge

    Tie down sutures are secured, if this technique is preferred
  - The round window is inspected
  - If cochleostomy is preferred, a 1 mm bur is used to thin the cochlea inferior and slightly anterior to the round window

    Preferably, the endosteum of the cochlea is kept intact

    The endosteum is incised to enter the scala tympani
  - If round window insertion is preferred, the round window membrane is incised with a right angle hook or Rosen needle to enter the scala tympani
  - The electrode is passed through the cochleostomy/round window under direct visualization (Fig. 205.6)

    It is critical to be familiar with the various electrode types prior to insertion, and to practice on cadaveric temporal bones prior to using a new electrode type

    This is especially relevant as manufacturers regularly update electrode sizes and configurations

    Insertion tools are provided for some electrodes and may or may not be used per the surgeon's preference

    For styletted electrodes, the surgeon must be familiar with the appropriate depth of insertion prior to advancing-off-stylet and with the technique for reloading the stylet in the event that reinsertion is required

    If the electrode does not pass without resistance, the electrode may be rotated to help it pass. An anatomically normal cochlea should offer very little resistance to insertion. The need for forceful insertion may kink the electrode and suggests a false cochleostomy, anatomic abnormality, or cochlear ossification

    Slower speed of insertion has been shown to result in lower intracochlear pressure, which may result in the preservation of spiral ganglion neurons
  - After insertion, pieces of temporalis fascia and muscle are packed around the cochleostomy

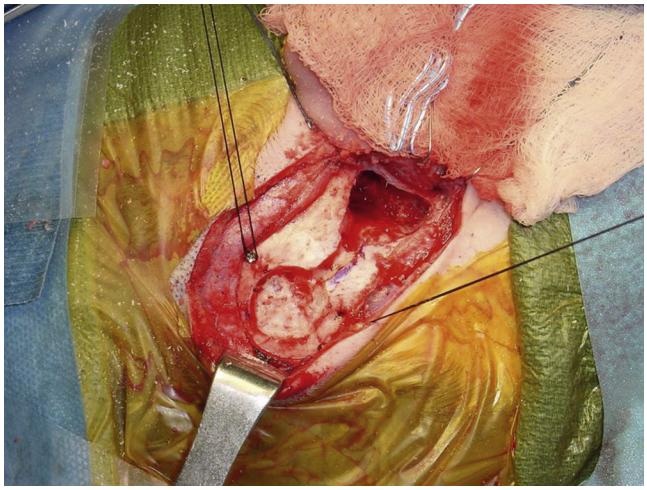

Fig. 205.5. Tie down sutures around head of screws.

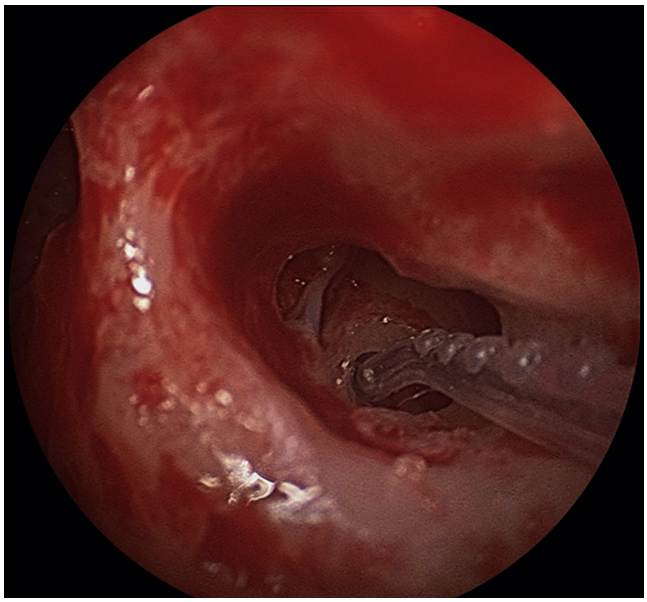

Fig. 205.6. Electrode placed through the round window.

- Unique cases
  - In cases of ossification, a perilymphatic space may not be identifiable. In these situations, alternative techniques may be necessary
    - The basal turn is drilled to identify the scala tympani. A depth gauge may be used to confirm a lumen beyond the basal turn
    - If limited space is identified in the scala tympani, the scala vestibule may be opened to identify a lumen
    - If no space is identifiable in the scala tympani or vestibuli, a cochlear drillout may be performed. A trough is made for the electrode along the expected cochlear turns. The electrode is placed in the trough (Fig. 205.7A and B)
    - A double array electrode may be considered
      - Initial drilling is performed in the region of the round window
      - A second cochleostomy is performed in the apical turn. The incus and the buttress is removed (Fig. 205.8). The stapes superstructure may also be removed for exposure. The cochleariform process is identified and a second cochleostomy is performed anterior to the oval window and inferior to cochleariform process (Fig. 205.9A and B)
    - If a cerebrospinal fluid (CSF) gusher is encountered,
      - Place the patient in reverse Trendelenburg
      - Allow for egress to slow
      - Place electrode and pack cochleostomy with fascia and muscle
      - Lumbar drain if leak persists
- Closure
  - The excess electrode is coiled within the mastoid cavity
  - Ground electrode, if present, is placed in the subtemporalis pocket
  - Periosteal flap is closed
  - Incision is closed in layers
  - Mastoid dressing is secured
- Intraoperative diagnostics
  - If desired, neural response testing can be performed during closure to evaluate whether the device is functioning
  - Mastoid radiograph can be performed to confirm electrode position within the cochlea. In cases of abnormal anatomy or if there concern regarding insertion, intraoperative radiograph or fluoroscopy can be performed

Common Errors in Technique

- Receiver/stimulator placed too close to the auricle and thus the skin over the implant is in contact with the behind-the-ear processor, risking skin necrosis
- The facial recess is not adequate to visualize the round window. Limited exposure makes round window identification and electrode insertion impossible. At every step of the operation, the surgeon must consider whether the extent of dissection is adequate for exposure of the round window. Skin incision, mastoid tip development, inferior and superior extent of facial recess dissection, and removal of perifacial bone medial to the facial nerve are all critical for adequate round window exposure
- The cochleostomy is too small to accommodate the electrode without resistance
  - Adequate cochleostomy size is electrode dependent; an awareness of the characteristics of the electrode to be used is critical

POSTOPERATIVE PERIOD

- Antibiotics for 7 days
- Mastoid dressing is placed for 2 days
- Glasscock dressing is worn for comfort and to protect the ear during sleep for 1 to 2 weeks postoperatively, as needed

Complications

- Early:
  - Hematoma
    - A small hematoma may be managed with a pressure dressing and close observation. Exploration and evacuation in the operating room is necessary for larger hematomas.
  - Malplacement of the electrode (over/underinsertion, false cochleostomy)
    - Electrode position can be confirmed intraoperatively with device-specific neural response measurements and with

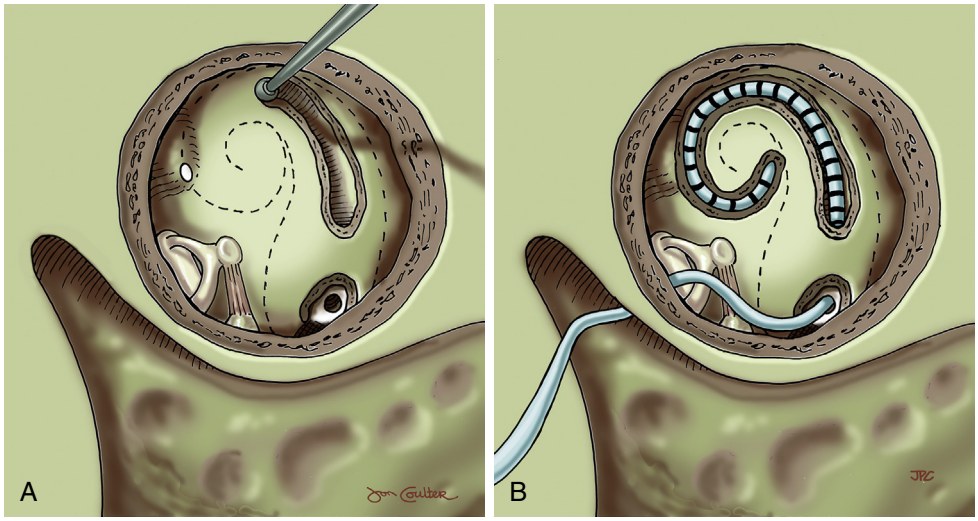

Fig. 205.7. Cochlear drillout. A, The trough is drilled. **B,** The electrode is placed along the trough.

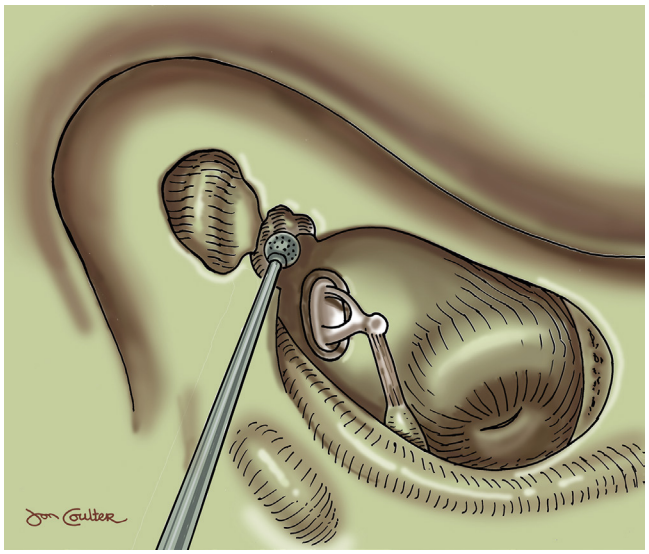

Fig. 205.8. The incus buttress is removed.

a mastoid x-ray to assess electrode position. Malpositioned electrodes should be repositioned.

- Wound infection
  All wound infections should be treated aggressively with broad-spectrum antibiotic coverage. In cases of exposure of the device, explantation may be necessary for healing. The electrode should be cut from the receiver/stimulator and left in place to preserve the cochlear lumen for future reimplantation.
- Facial nerve injury
  Immediate weakness may be due to local anesthetic if used; observe 2 to 3 hours for spontaneous resolution. If persistent, re-exploration and nerve decompression may be warranted. Oral steroid taper may be used for late onset weakness with close clinical follow-up.
- Vertigo
  Usually spontaneously resolves after several days. May treat with a benzodiazepine in the short term. For severe dizziness, mastoid radiograph or CT to assess electrode position may be warranted to rule out malpositioned electrode.
- Dysgeusia
  May occur due to stretch, inflammation, or transection of chorda tympani nerve. Patients should be counseled in advance of this possible complication. In most cases, symptoms resolve spontaneously after several months.
- CSF leak
  Intraoperatively, plugging of the insertion site with fascia and muscle usually controls CSF leak. Postoperatively, manage conservatively with elevated head of bed, stool softeners, bed rest. A lumbar drain is rarely needed.

- Late:
  - Migration of the device
    Can usually be managed with alternate placement of the external device. If migration is significant, exploration for repositioning and fixation may be required.
  - Hard or soft failure
    Device failure can occur due to loss of hermeticity, trauma to the site, or for unexplained failure of the hardware. The internal receiver stimulator should be replaced in such cases.
  - Skin irritation ("magnetitis")
    Often due to the use of a high-strength magnet. Remove device for several days until inflammation improves. If skin appears wet or any breakdown is noted, discontinue use of the device and treat with oral and topical antibiotics, with low threshold for conversion to intravenous (IV) antibiotics if no improvement is seen. Decrease magnet strength when resuming use.
  - Extrusion
    Requires broad-spectrum IV antibiotic coverage and, in most cases, removal of the device with eventual replacement. Coverage with vascularized tissue flaps has been described.

Alternative Management Plan

Communication via sign language, cued-speech, lip-reading.

DISCUSSION

Evidence-Based Medicine Question

Is there a difference between round window versus cochleostomy electrode insertion?

Much debate exists surrounding the optimal surgical approach for electrode insertion in CI surgery. The two most common techniques employed are cochleostomy versus round window insertion. Advances in electrode thickness

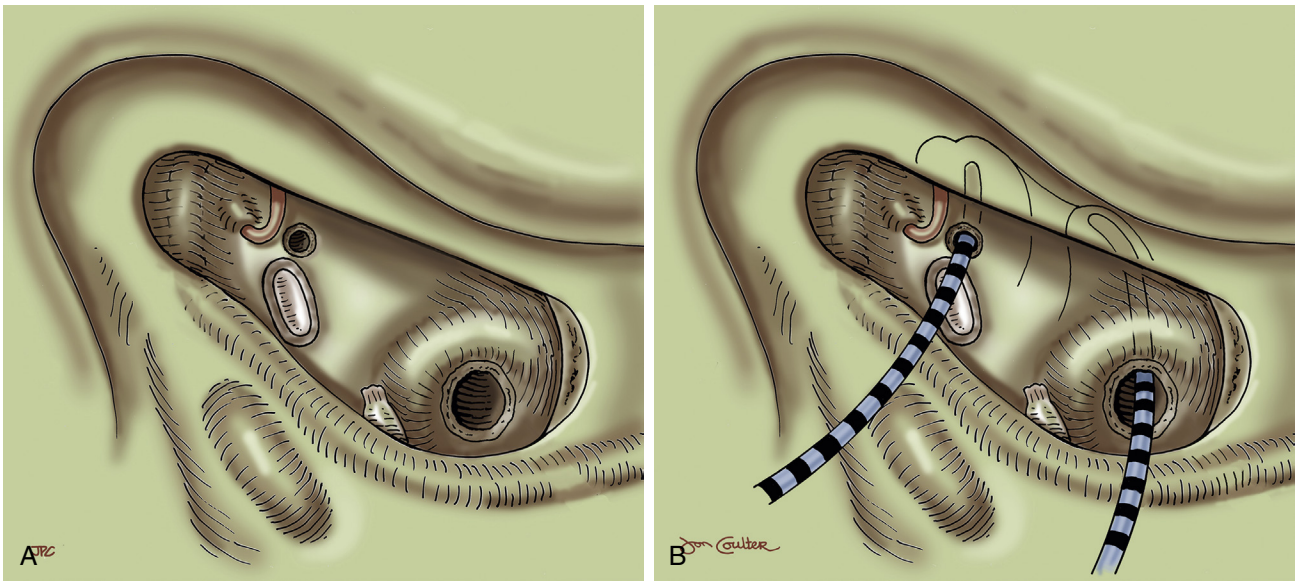

Fig. 205.9. A, A cochleostomy is placed at the basal turn, and a second cochleostomy is placed in the apical turn anterior to the oval window and inferior to the cochleariform process. **B,** Double array electrodes are placed.

and flexibility have allowed for an increasing ability to preserve residual hearing in CI surgery, thus leading to a desire to find the optimal method for hearing preservation. The "soft surgery" approach includes creating a minimal anteroinferior cochleostomy with a low drill speed, avoiding suctioning of perilymph, slow electrode insertion, and sealing the cochleostomy in some manner. The round window approach involves directly incising the round window membrane, with drilling of the bony round window overhang as necessary, and directly inserting the electrode through the round window membrane. A third approach, the peri-round window insertion, combines elements of both, with a small cochleostomy that overlaps and includes the round window membrane. Several authors have sought to determine whether the "soft surgery" cochleostomy technique versus the round window approach affords superior hearing preservation and speech performance outcomes. A systematic review of prospective studies and case series[3] found that there was no significant difference in hearing preservation rates between the "soft surgery" cochleostomy technique and the round window approach, with total hearing loss in 0% to 26% in the cochleostomy group and 3% to 20% in the round window group. Zhou and colleagues[4] reported that in fresh human temporal bones, cochleostomy and peri-round window insertions were less likely to result in histologic trauma, and were more likely to have a linear insertion than round window insertions. Todt and colleagues[5] reported an increase in intracochlear pressure proportional to electrode insertion speed, and posited that a slower speed of insertion may correlate with better preservation of the intracochlear structures. Work remains to be done to clarify the optimal insertion techniques for hearing preservation and speech outcomes.

Editorial Comment

CI surgery and habilitation have markedly advanced since the pioneering days of a single electrode with a large body-worn processor. Improvements in microchip technology, electrode design, and refinements in processing software have provided remarkable outcomes in the restoration of hearing in postlingual recipients and the development of language in prelingual infants and toddlers.

The authors identify a number of key aspects regarding CI surgery that pave the way to success. Choosing the appropriate patient and family is critical in setting the path to success or failure. It is unique to pediatric recipients that they receive comprehensive educational support for the development of language and hopefully speech in those with perinatal deafness. This must be fully reinforced with family support.

Infants with bilateral severe to profound sensorineural hearing loss are now encouraged to undergo bilateral surgery. In the past it was thought that the child should delay implantation of the second ear pending anticipated improvements in implant technology. Fortunately, these advances have been made in processing software and external stimulation devices. The internal receiver-stimulators have been forward compatible with refinements in speech coding strategies.

There is a steep learning curve in the surgical execution of pediatric cochlear implantation. Surgery in adults who subsequently lose substantial hearing and are eligible for an implant almost always have favorable anatomy of the otic capsule. In contrast, pediatric patients may have a poorly developed mastoid cavity and, even more challenging, altered cochlear anatomy. There are numerous electrode designs suited for dysplastic or ossified cochleae. The surgeon must be comfortable with choosing the appropriate electrode to meet the possible limitations posed by the inner ear anatomy. CT imaging provides this information as well as the anatomy of the mastoid, facial nerve, facial recess, and tegmen. If the existence of the cochlear nerve is in question, T2 sagittal MR images can verify its presence.

As experience and technology continue to progress, the role of implant surgery in single-sided deafness will become defined. This also holds true for auditory brainstem implant (ABI) surgery for those without a functioning cochlear nerve. ABI is currently approved for use in patients with NF 2 where the cochlear nerve has been resected. It is now being done through research protocols in patients with cochlear nerve agenesis. Stimulating the cochlear nucleus at the brainstem with the appropriate electrical signal remains a technologic and software challenge.

Barry E. Hirsch

Access the review questions online at http://www.expertconsult.com

REFERENCES

1. Niparko JK, Tobey EA, Thal DJ, et al. Spoken language development in children following cochlear implantation. JAMA 2010;303(15):1498–1506.
2. Colletti L, Mandalà M, Colletti V. Cochlear implants in children younger than 6 months. Otolaryngol Head Neck Surg 2012;147(1):139–146.
3. Havenith S, Lammers MJ, Tange RA, et al. Hearing preservation surgery: cochleostomy or round window approach? A systematic review. Otol Neurotol 2013;34(4):667–674.
4. Zhou L, Friedmann DR, Treaba C, et al. Does cochleostomy location influence electrode trajectory and intracochlear trauma? Laryngoscope 2015;125(4):966–971.
5. Todt I, Mittmann P, Ernst A. Intracochlear fluid pressure changes related to the insertional speed of a CI electrode. Biomed Res Int 2014; 2014:507241.

REVIEW QUESTIONS

1. What is the most common complication of a cochlear implant?
   a. Skin flap infection
   b. Facial nerve injury
   c. Device failure
   d. Permanent vertigo

2. What is not a contraindication for pediatric cochlear implantation?
   a. Absent cochlear nerve
   b. Absent cochlea
   c. Mondini malformation
   d. Unrealistic family expectations

3. Which statement about infant cochlear implant is FALSE?
   a. The cochlea is smaller in an infant
   b. Blood loss must be closely observed
   c. The calvarium is thin, and the dura may be easily exposed during preparation of the well
   d. The implant is placed in a more vertical orientation

206 Cleft Palate and Velopharyngeal Dysfunction

Noel Jabbour, Bernard J. Costello

INTRODUCTION

Comprehensive care of cleft palate deformities and velopharyngeal dysfunction (VPD) requires a thorough understanding of the full spectrum of palatal abnormalities and their effect on feeding, airway, and speech, from infancy through adolescence. Palatal clefts may range in their severity from subclinical, submucosal clefts of the soft palate to very wide clefts of the primary and secondary palate, with significant feeding and airway concerns in the neonatal period. Surgeons with formal training and experience in cleft palate repair and speech surgery must be involved, ideally as part of a multidisciplinary team, in the evaluation and treatment planning for this wide spectrum of abnormalities.

The secondary palate is composed of the hard palate (bony) anteriorly and the soft palate or "velum" posteriorly. Within the soft palate, the levator veli palatini muscle forms a dynamic sling that elevates the velum toward the posterior pharyngeal wall during speech. Other muscle groups within the velum, the tonsillar pillars, the pharyngeal walls, and the adenoid size and position also affect the quality of resonance. The combination of the soft palate and pharyngeal wall musculature jointly forms what is described as the velopharyngeal valve mechanism. This mechanism functions as a sphincter valve for regulating airflow between the oral and nasal cavities to create a combination of orally based and nasally based sounds.

Velopharyngeal insufficiency (VPI) refers to resonance abnormalities that result from the inability to completely close the soft palate to the posterior pharyngeal wall or adenoid pad during speech. This often results in nasal air escape, or hypernasality. This may be present with or without an overt cleft of the palate. In the English language, the velopharyngeal valve should close completely for all phonemes, except /m/, /n/, and /ng/, which are nasal sounds.

Nasal air escape may result from palatal fistulas or unrepaired cleft palates. However,VPI may occur despite an intact palate, or in patients without overt palatal clefts. VPI may also be encountered in patients after adenoidectomy, orthognathic surgery, especially midface advancement, or even with sudden growth spurts in adolescence that may decrease the size of the adenoid and increase the distance from the soft palate to the skull base.

Children born with a cleft palate or a submucous cleft palate have, by definition, a malformation that has a dramatic impact on the components of the velopharyngeal valving mechanism. Specifically, clefting of the secondary palate causes a division of the musculature of the velum into separate muscle bellies with abnormal insertions along the posterior edge of the hard palate. Velopharyngeal dysfunction (VPD) and hypernasality is a major concern for patients with a cleft. The incidence of VPI following primary palatoplasty ranges from 5% to 50%, with approximately 20% requiring further surgical management for persistent hypernasality.

Surgeons caring for patients with palatal clefts or with VPD must work closely with colleagues from speech and language pathology, as many of the symptoms are related to feeding and speech. This chapter presents a technical overview of the reconstruction of palate deformities as well as operative procedures to address VPD.

KEY OPERATIVE LEARNING POINTS

1. The main goals of cleft palate repair are closure of the oral–nasal communication and anatomic repair of the musculature within the soft palate.
2. The soft palate muscles play a critical role in velopharyngeal opening and closure. Palatal clefts involve abnormal anterior position of the palatal muscles. Realignment and posterior positioning of the muscles is key to improved velopharyngeal function.

PREOPERATIVE PERIOD

History

1. History of present illness
   a. When was the cleft palate first diagnosed? The diagnostic accuracy of detection of cleft palate abnormalities by prenatal ultrasound is increasing. Cleft lips are easier to detect with ultrasound when compared with palate clefts. Some patients may have had a prenatal diagnosis of cleft palate by ultrasound. For others, it may be found at the time of the newborn examination.
   b. Birth history should include any initial airway distress and need for airway intervention, as a subset of children with cleft palate will have microretrognathia, leading to collapse of the base of the tongue and airway obstruction. Any subsequent symptoms of airway distress, including stridor, stertor, cyanosis, or acute life-threatening events (ALTE) should be discussed.
   c. Parents should be asked about typical feeding patterns. Clefts of the palate prohibit the infant from forming a seal with the oral cavity due to the oral–nasal communication. Typically, infants with cleft palate will require special bottles for feeding, such as a Haberman nipple or Pigeon nipple, which do not rely on suction. The surgeon should inquire about whether the child is being fed with breast milk or formula, the caloric density of the formula, the type of bottle being used, the ease of feeding, and the length of time for each feeding. Prolonged feeding time may be an indication of

discoordinated breathing and swallowing. Further airway evaluation may be necessary. When a typical cleft of the palate occurs, breast feeding is typically not possible due to an inability to produce suction; although breast milk pumping and feeding with a cleft palate bottle is encouraged.

d. For the older child being evaluated for VPD, a further line of inquiry into speech concerns is needed. Parents should be asked about the timing of speech development during infant and toddler years, the history of speech therapy, the frequency of therapy appointments, and what particular concerns are being addressed in therapy. Care should be taken to note whether the speech patterns seemed to be improving, plateauing, or worsening over recent months. In some cases, fatigue and worsening speech may occur over the course of the day.
e. Both infants and older children should be asked if milk or other contents are noted to come out the nose, as this is potentially an early sign of an incompetent velopharyngeal mechanism.
f. As Eustachian tube dysfunction is common with palatal abnormalities, parents should be asked about hearing screening results, history of recurrent otitis media, any previous tympanostomy tube placement or otologic surgery, and any hearing concerns that they may have.

2. Past medical history
   a. A careful review of previous evaluations and treatment strategies to address feeding and airway concerns should be undertaken.
   b. Previous surgeries to the oral cavity and oropharynx should be discussed. Specifically, in the child being referred for VPD, it should be known if previous surgery has been performed on the adenoids or tonsils. As children rely on veloadenoidal closure, an adenoidectomy may unmask a previously subclinical VPD. Hypernasality following adenoidectomy may occur in up to 1 in 1000 patients, and may improve spontaneously within months. Surgical intervention may be considered if the hypernasality persists for more than 6 months.
   c. Family history of orofacial clefts, congenital heart disease, or speech and language difficulties should be ascertained.

Physical Examination

1. Examination of the palate—A clear view of the hard and soft palate must be obtained. The extent of clefting and the laterality of the involvement in the hard palate should be documented. The LAHSHAL classification and the Veau classifications are common methods of documenting degree of palatal clefts. In patients being evaluated for VPD, the elevation pattern of the soft palate should be noted. Activation of the palate is best accomplished by stimulating a gag reflex with a tongue depressor while focusing on the soft palate. A submucous cleft palate is classically described as a triad of a bifid uvula, a notch in the hard palate, and a zona pellucida (clear strip of mucosa only in the midline of the soft palate). In milder forms of submucous cleft palate, one or more of the components of this triad may be absent. More subtle palatal abnormalities, such as occult submucous cleft palate, may be seen only with palatal activation, where a vault-shaped elevation of the soft palate, a midline muscular deficiency, and an anterior position of the levator muscles may be noted.
2. Examination of the airway—Stridor, stertor, or any signs of increased work of breathing should be noted and addressed.
3. Perceptual speech evaluation—Despite several available instruments for assessment, the gold standard diagnostic tool for VPD remains perceptual, subjective, speech evaluation. Training and experience in evaluating speech is necessary for accurate diagnosis. Currently, there is no reliable objective measure of VPD as it relates to intelligibility. As a result, close collaboration between the surgeon and a speech and language pathologist is essential to make this nuanced decision to treat with surgery.
4. Examination of the ears—Presence or absence of middle ear effusions should be documented. Often bilateral myringotomy and tympanostomy tube placement can be performed at the time of palate repair for children with persistent middle ear effusions or recurrent acute otitis media.
5. Nasal endoscopy—The pattern of closure of the velopharyngeal port may be viewed by nasopharyngoscopy. The flexible scope should be passed above the inferior turbinate to obtain a birds-eye-view of the velopharyngeal closure. The patient is asked to repeat certain test phrases that require velopharyngeal closure, while direct observation is obtained of palatal motion, lateral pharyngeal wall motion, and posterior pharyngeal wall contribution to velopharyngeal closure. Air bubbling may be noticeable and correlates to the perceptual evaluation of a nasal rustle. Additionally, for patients being considered for possible pharyngeal flap, assessment of adenoid size is necessary as preoperative total adenoidectomy is often useful prior to pharyngeal flap.
6. Craniofacial examination—Common accompanying syndromic diagnoses, such as Stickler syndrome, 22q11.2 deletion syndrome, or Treacher-Collins syndrome, may be suspected based on orbital and nasal morphology and other classic facial features.

Imaging

None: Imaging is not routinely necessary. Speech videofluoroscopy may be used in the evaluation of VPD to evaluate the velopharyngeal closure patters. This is an ideal imaging modality for patients who do not tolerate nasendoscopy. Videofluoroscopy is used to radiographically examine the upper airway during phonation with the aid of an oral and nasal contrast material. This allows for dynamic testing of the velopharyngeal mechanisms from multiple views. A speech-language pathologist should be present in the radiology suite for verbal prompting and testing. If a pharyngeal flap is being considered, the size of the adenoids also can be examined from the lateral views, to aid in decision making regarding the need for preoperative adenoidectomy.

With videofluoroscopy and nasendoscopy, the closure pattern of the palate is documented and should be differentiated. The closure patterns may help determine the success of various secondary palatal procedures designed to augment anatomic deficiencies. The most common closure patterns are:

- Coronal (55% of the normal population)—Posterior movement of the soft palate to the posterior pharyngeal wall with little movement from the lateral walls. Approximately 45% of patients with VPI have this pattern of closure.
- Sagittal (10% to 15% of population)—Primary closure is by movement of the lateral walls without significant anterior-to-posterior closure. This pattern is seen in 10% to 15% of all children with VPI.
- Circular (10% to 20% of population)—Circular closure with Passavant's ridge includes lateral wall and soft palate movement, as well as anterior movement of the posterior pharyngeal wall. Approximately 20% to 25% of children with VPI demonstrate this closure pattern.

Indications

1. Cleft palate. Palatoplasty is usually undertaken between 10 and 14 months of age. However, there are some recent data that suggest that the palate can be repaired safely as early as 3 to 5 months of age. While early repair can be accomplished, the growth consequences on the midface do not typically outweigh any measurable benefit in speech outcome. Alternatively, repair may be delayed in patients with developmental or speech delay who have not initiated verbal communication, or patients with very wide clefts.
2. Persistent and symptomatic oral-nasal fistula following primary palate repair.
3. VPD that is persistent and is related to an anatomic problem. Timing of repair is usually between 2.5 and 5 years of age. In younger children, the child's language and articulation development and lack of compliance during speech evaluations may compromise the diagnostic accuracy of preoperative assessment.

Decision making regarding which surgical repair option is best suited for a particular patient is often made as a team with the surgeon and speech and language pathologist working in close collaboration, taking into consideration palatal anatomy and velopharyngeal closure patterns. Overall, there are three surgical procedures that may be used to address VPI: Furlow palatoplasty, pharyngeal flap, and sphincter pharyngoplasty. The following are basic guidelines used in decision making:

a. Furlow palatoplasty—Usually performed in patients with anteriorly positioned levator musculature. This may be due to congenital submucous cleft palate or secondary to palatoplasty with insufficient muscular repositioning.
b. Pharyngeal flap—Usually performed in patients with intact levator sling mechanism and good lateral wall motion on either nasendoscopy or videofluoroscopy but either large anterior to posterior distance between the soft palate and posterior pharynx or poor anterior to posterior motion.
c. Sphincter pharyngoplasty—Ideal for patients with good anterior and posterior motion but poor lateral wall motion on nasendoscopy or videofluoroscopy.

There is significant variability in surgical technique for each of these procedures, and each can be customized to fit the particular velopharyngeal closure pattern. It should be noted that the combination of Furlow palatoplasty and sphincter pharyngoplasty is performed by some surgeons with good results. The authors do not routinely perform this combined procedure due to concern for nasopharyngeal stenosis.

Contraindications

1. Medical comorbidities with increased risk for general anesthesia.
2. Significant, uncorrected bleeding disorder or nutritional deficiency that would increase the risk for complications in wound healing.
3. Severe obstructive sleep apnea may be made worse by palatoplasty or pharyngoplasty procedures. Full evaluation of the airway and treatment of sleep apnea should be initiated prior to consideration of surgical intervention.

Preoperative Preparation

1. Discontinue antiplatelet drugs if possible.
2. Discontinue the use of a bottle and switch to cup or sippy-cup with a short tip.
3. Patients should be counseled on postoperative care including pain management, dietary instructions, and possible need for arm restraints.

OPERATIVE PERIOD

Anesthesia

General: These procedures are routinely performed under general anesthesia with patient orotracheally intubated.

Positioning

Supine.

Perioperative Antibiotic Prophylaxis

Unasyn.
Clindamycin if the patient is allergic to penicillin.

Monitoring

None.

Instruments and Equipment to Have Available

1. Dingman or ratchet mouth retractor
2. Marking pen or cotton tipped applicator and gentian violet
3. 0.5% Lidocaine with 1:200,000 epinephrine or 1% lidocaine with 1:100,000 epinephrine for older children
4. Routine oral cavity surgical set with periosteal elevators, Freer elevators, skin hooks, and long tenotomy scissors
5. 15 blade or 15c blade with long handle
6. Angled beaver blade
7. 3-0 and 4-0 absorbable suture, such as polyglactin (Vicryl) or chromic
8. Bipolar and monopolar electrocautery with insulated needle-point tip
9. Optional—70-degree endoscope and drape tape for video recording and real-time viewing by operating room personnel

Key Anatomic Landmarks (Fig. 206.1)

- Bony landmarks
  - Incisive foramen
  - Palatine process of maxilla
  - Horizontal plate of palatine bone
  - Greater and lesser palatine foramina
  - Hamulus of pterygoid
  - Vomer
- Muscular anatomy—Differences between the muscular anatomy of a normal palate and a palate in a patient with a cleft are shown in Fig. 206.1.

Prerequisite Skills

1. Detailed understanding of the anatomy of the palate and velopharyngeal mechanism
2. Training in surgical repair of cleft palate and surgical treatment for VPI
3. Experience with surgery and suturing in the oral cavity and oropharynx

Operative Risks

1. Early complications:
   a. Bleeding

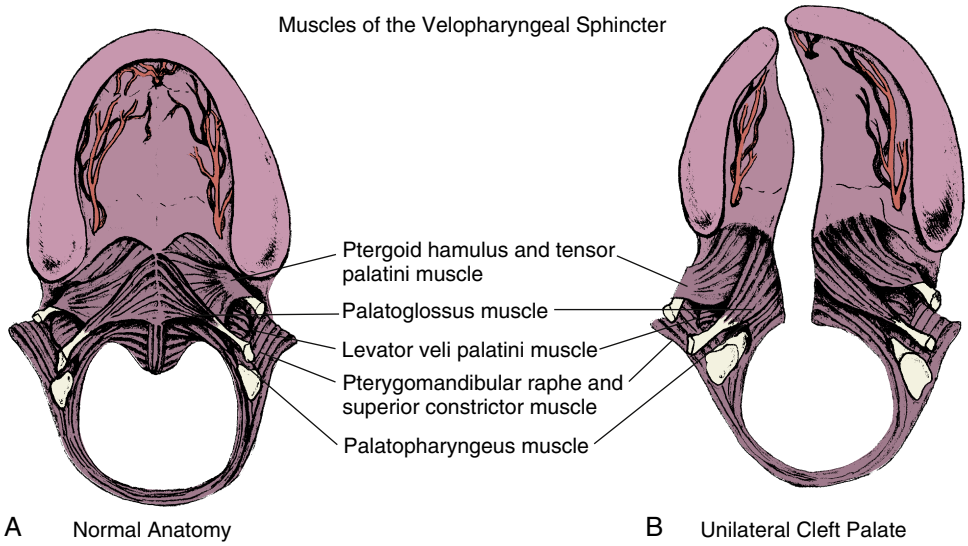

Fig. 206.1. Anatomy of the palate and the velopharyngeal valve mechanism. A, Normal anatomy. **B,** Unilateral cleft of the primary and secondary palate. Note anterior attachment of the levator muscles to the bony edge of the hard palate.

   b. Airway obstruction
   c. Wound breakdown/partial dehiscence
2. Late complications:
   a. Palatal fistula
   b. Persistent VPI
   c. Obstructive sleep apnea

Surgical Technique

The following surgical technique section includes steps common to all palatal and pharyngeal procedures followed by particular steps that are specific to each individual procedure.

For All Procedures

- Orotracheal intubation with oral RAE endotracheal (ET) tube. Tape ET tube to midline taking care to avoid injury to the lower lip.
- Place the patient in the supine position with the neck slightly extended using a shoulder roll.
- Prep the face with betadine and brush oral cavity with chlorhexidine gluconate oral rinse.
- Insert Dingman or ratchet mouthgag so that a maximal view of the oral cavity and oropharynx is obtained and the ET tube is secured to the tongue in the midline. The mouthgag should be relaxed every 20 to 30 minutes throughout the case to allow for perfusion of the tongue.
- Incisions may be marked with a marking pen or a wooden handle of a cotton-tipped applicator dipped in gentian violet or methylene blue.
- Proposed incisions may be injected with lidocaine and epinephrine in a submucosal and subperiosteal plane in the hard palate, avoiding direct injection to the neurovascular bundles. Subperiosteal injection can aid in hemostasis and facilitate undermining of the mucoperiosteal flaps.
- Optional—A 70-degree endoscope may be positioned parallel to the mouthgag and rest on the Mayo stand. This allows for real-time viewing of the surgical procedure by all personnel in the room.
- At the conclusion of the procedure, pass an orogastric (OG) tube to suction the stomach.

Two-Flap Palatoplasty With Intravelar Veloplasty

- Incise medial incisions—Nasal flaps are designed so a strip of mucoperiosteum is left on the medial edge of the hard palate cleft. For wider clefts, a wider strip of mucoperiosteum should be left. Usually, at least 2 mm is needed. When these flaps are elevated, they should meet each other or the vomer flaps without tension. The incisions should continue superficially to the tip of the uvula on each side (Fig. 206.2).
- Incise lateral incisions—Laterally, flaps are designed to include oral mucoperichondrium only without gingiva.
- Elevate the mucoperiosteal flaps bilaterally to identify and preserve the neurovascular pedicle from the greater palatine foramen. Elevation is started anterolaterally in a subperiosteal plane.
- Isolate the neurovascular bundle to allow medial mobility of the flaps. On both sides of the neurovascular bundle, detach all muscular and tendinous attachments to the posterior aspect of the hard palate, with a combination of blunt and sharp dissection. This should leave the flaps attached to the hard palate by the neurovascular bundle and the lateral pedicle only.
- Blunt dissection in the space of Ernst allows for further medialization of the soft palate. If additional medialization is necessary, the hamulus may be infractured.
- Gentle traction can be used to pull the neurovascular bundle out of the greater palatine foramen. The palatine foramen is surrounded by a periosteal cone that can be incised superficially on either side and posteriorly to allow maximal mobilization of the flap.
- Elevate the medial incisions with a periosteal elevator off of the floor of the nose to further mobilize the nasal mucoperiosteal flaps.
- Veau's muscle (a clefted muscle consisting of the levator and the palatopharyngeus) should be further dissected off of the posterior edge of the hard palate and the nasal mucoperiosteum with sharp scissors or scalpel.
- Close the nasal layer with 4-0 absorbable suture beginning anteriorly and continuing to the base of the uvula. Sutures are tied with knots on the nasal surface.
- Reposition Veau's muscle posteriorly and medially and suture the muscles on each side together in the midline with 3-0 absorbable suture.
- Approximate each side of the uvula with horizontal mattress sutures.
- Close the oral layer from anterior to posterior with 4-0 or 5-0 interrupted or mattress sutures with knots tied on the oral surface.
- Combined oral mucoperichondrial flaps may be anchored to the nasal mucoperiosteal closure with one 4-0 absorbable suture at about the midpoint. Secure the tip

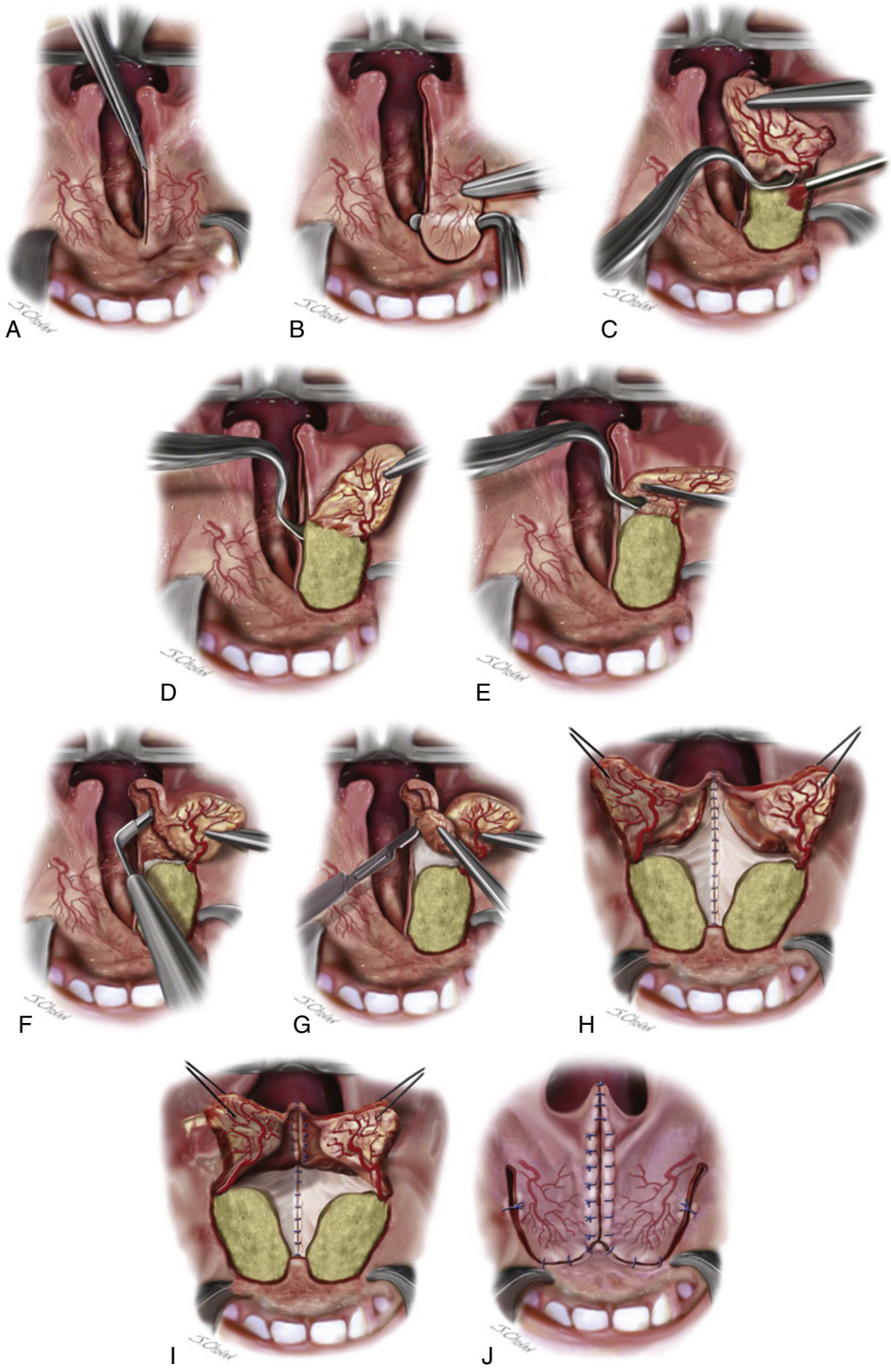

Fig. 206.2. 2-Flap palatoplasty. A, A mucosal incision is made sharply, 1 to 2 mm lateral to the oral-nasal mucosal junction to allow adequate tissue for nasal layer closure. **B,** Once mucosal incisions are complete, periosteal elevators are used to elevate the mucoperiosteal flap from anterior to posterior. **C,** The greater palatine neurovascular pedicle is identified and preserved with careful dissection around the pedicle. **D,** The nasal mucoperiosteal flap is then elevated with careful dissection in the subperiosteal plane. **E,** Dissection continues posteriorly to elevate off the abnormally attached levator muscles from the posterior edge of the hard palate. **F,** The levator muscle is then sharply dissected from the overlying oral mucosa, avoiding oral mucosal perforation. **G,** The levator muscle is similarly dissected from the underlying nasal mucosa. **H,** The nasal mucosa is closed primarily. **I,** Then, the levator muscles are sutured together posteriorly, properly reorienting the muscles, and completing the intravelar veloplasty. **J,** The oral layer is then closed in the midline, medializing the pedicled flaps and leaving lateral donor sites open. Lateral stay sutures may be employed, as shown. *With permission from Gailey D, Smith K. Cleft palate. In Kademani D, Tiwana P (eds): Atlas of Oral and Maxillofacial Surgery, 1st ed. St Louis, Elsevier, 2016, pp 561–568.*

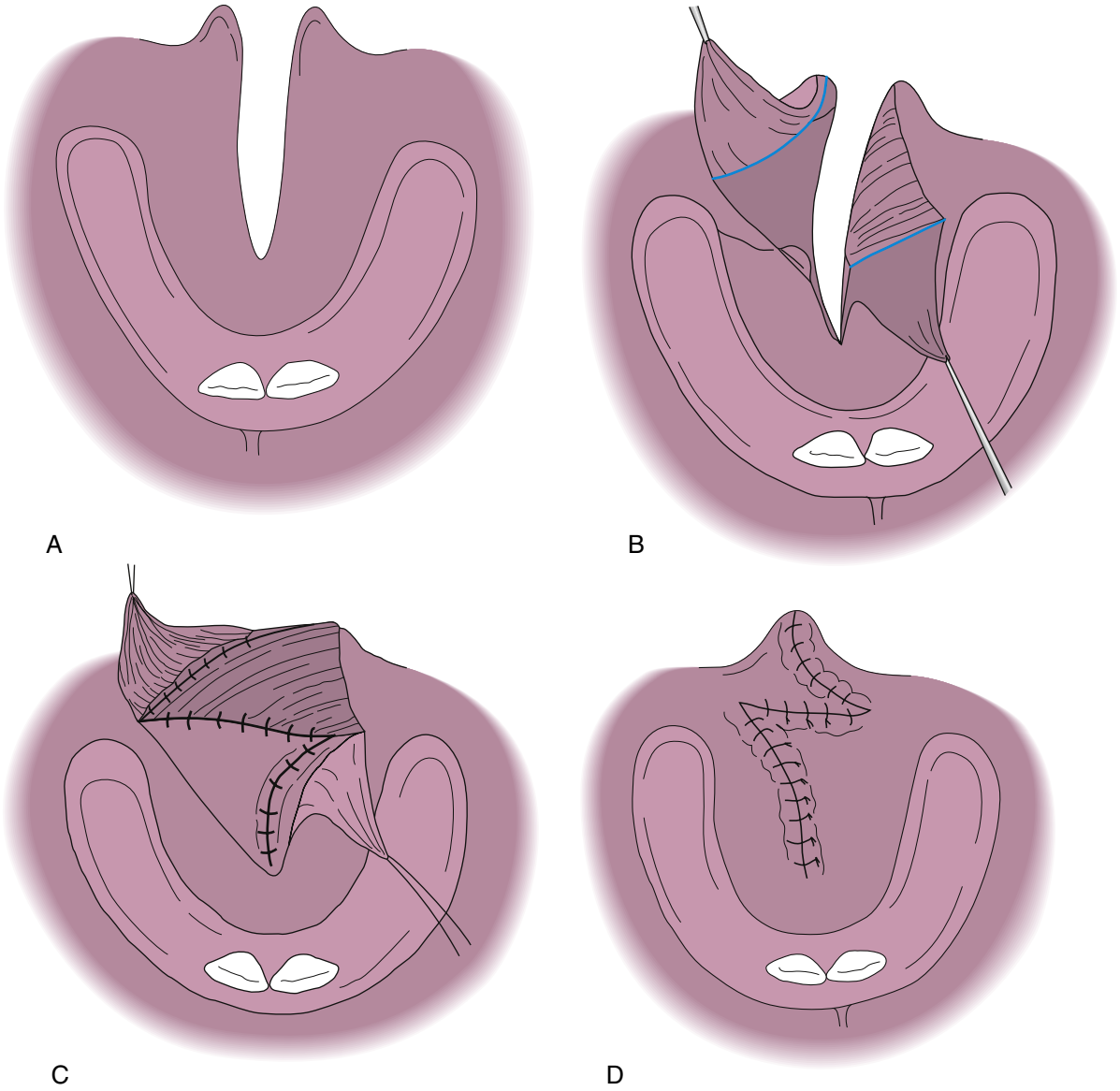

Fig. 206.3. A, A Veau II cleft of the hard and soft palate is shown; the cleft extends from the incisive foramen to the uvula. **B,** The Furlow double-opposing Z-plasty technique requires that separate Z-plasty flaps be developed on the oral and then the nasal layers. The cutbacks creating the nasal layer are shown in blue. **C,** The nasal layer flaps are then transposed and the nasal layer is closed with the posteriorly based nasal myomucosal flap transposed posteriorly. **D,** The oral layer is closed with the posteriorly based oral myomucosal flap transposed posteriorly. This lengthens the soft palate, reorients the muscle fibers transversely, and creates more muscular bulk posteriorly for velopharyngeal closure.

of the flaps to the gingiva anteriorly with interrupted 4-0 absorbable sutures.

As an alternative to the intravelar veloplasty, the above two-flap technique may be combined with a double-opposing Z-plasty in the soft palate.

Furlow Palatoplasty (Double-Opposing Z-Plasty)

- Palpate the hamulus of the pterygoid bone bilaterally. This should feel like a bony elevation just medial and posterior to the maxillary tuberosity.[4]
- Mark the oral incision from the left hamulus to the bony edge of the hard palate and from the right hamulus to the base of the uvula (Fig. 206.3).
- Mark the midline incision from the hard palate to the base of the uvula in patients with a submucous cleft palate. For patients with unrepaired clefts of the palate, this incision should be placed approximately 2 mm lateral to the cleft margin.
- Incise the midline incision with a scalpel.
- Incise the left lateral incision from the hamulus to the edge of the hard palate in the midline.
- Separate the clefted muscles off of the bony edge of the hard palate with sharp and blunt dissection. Elevate the muscle off of the underlying nasal mucosa to raise a posteriorly-based oral myomucosal flap.
- Incise the right lateral incision from the base of the uvula to the right hamulus. Back elevate an anteriorly based mucosa and submucosa flap on the right. Elevation should continue until the edge of the hard palate.
- Separate the clefted muscles on the right from the edge of the hard palate to preserve a rim of nasal mucosa to sew to.

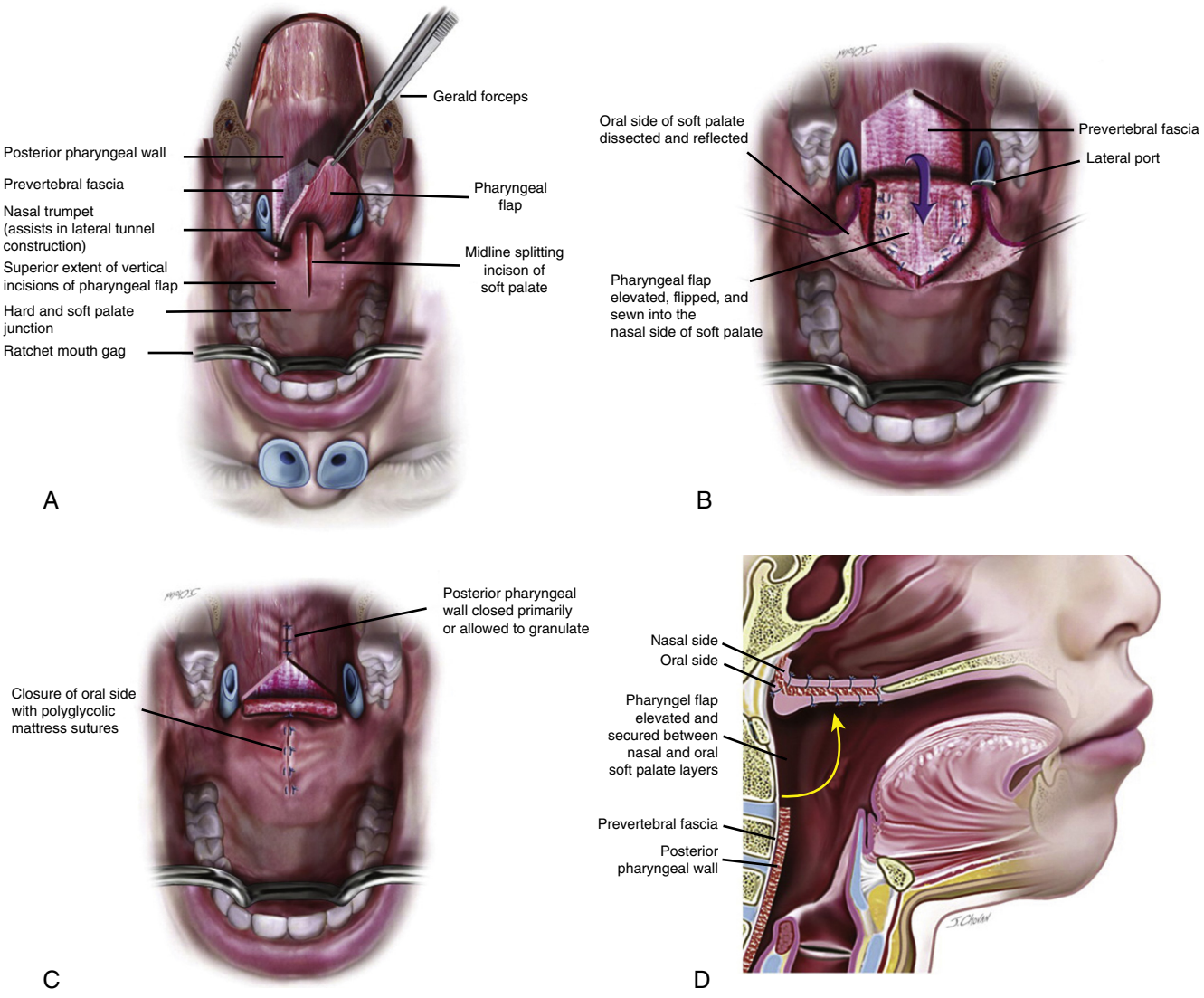

Fig. 206.4. Pharyngeal flap. A, Elevation of superiorly based pharyngeal flap with midline soft palate incision. **B,** Flap is inset to the soft palate. **C,** Soft palate oral incision and posterior pharyngeal wall donor site are closed primarily. **D,** Lateral view demonstrating position of the pharyngeal flap above the transverse plane of the palate and inset between the oral and nasal layers of the palate. (*With permission from Costello BJ, Ramon R. Pharyngoplasty for velopharyngeal incompetence. In Kademani D, Tiwana P (eds): Atlas of Oral and Maxillofacial Surgery, 1st ed. St Louis, Elsevier, 2016, pp 578–588).*

- Create an anteriorly based left nasal mucosal flap by incising the left nasal layer from the base of the uvula to just medial to the taurus tuberus.
- Create a posteriorly based right myomucosal flap by incising the nasal layer on the right from the edge of the hard palate to just medial to the taurus tuberus.
- Once all flaps are elevated, ensure hemostasis.
- Closure of the nasal layer should begin from anterior to posterior. The anteriorly based nasal mucosal flap should be transposed to the right and sewn to the nasal mucosa at the edge of the hard palate on the right with 4-0 absorbable sutures in a simple interrupted fashion.
- Next, the right posteriorly based myomucosal flap is transposed and sewn toward the left superior constrictor muscle. This flap is then sewn to the adjacent mucosal edges on each side; anteriorly to the nasal mucosal flap from the right, and posteriorly to the edge of the nasal incision along the posterior edge of the soft palate.
- Approximate the uvula with simple interrupted and mattress sutures.
- Close the oral layer from anterior to posterior. The right anterior-based myomucosal flap should be transposed to the left and sewn to the oral mucosa at the edge of the hard palate.
- Transpose the left posteriorly based myomucosal flap to the right, then sew anteriorly to the previously inset mucosa only flap, and posteriorly to the free edge of the oral mucosal incision on the right.

Superiorly Based Pharyngeal Flap

- Mark out the incision along the posterior pharyngeal wall and palate (Fig. 206.4). The tip of this flap should be near the most inferior aspect of the pharynx that can be viewed with the mouthgag in place.[5]
- Inject lidocaine with epinephrine.
- Incise the midline of the palate with slightly more dissection on the oral layer than the nasal layer, with respect to the anterior extent of the incision.
- Incise the marked out area of the pharyngeal wall down to the prevertebral fascia. Elevate the superiorly based myomucosal

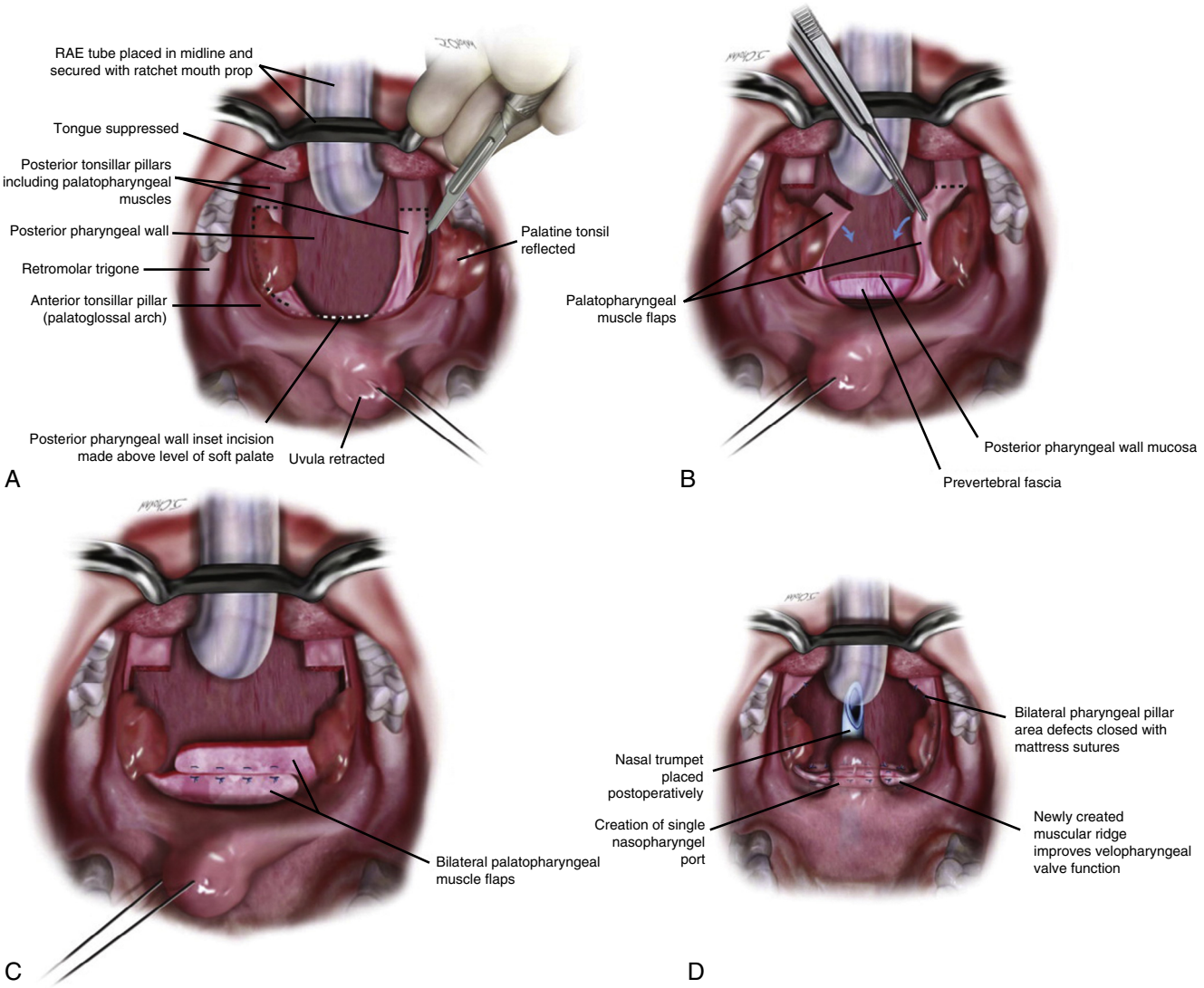

Fig. 206.5. Sphincter pharyngoplasty. A, Outlined incisions for sphincter pharyngoplasty involving posterior tonsillar pillar and inset incision in the posterior pharyngeal wall. **B,** Flaps are elevated and medially rotated. **C,** Flaps are sutured together and inset with mucosal surfaces superficial and muscle-surface deep. **D),** Single nasopharyngeal port is thus created; donor site mucosal wounds are closed primarily. *(With permission from Costello BJ, Ramon R. Pharyngoplasty for velopharyngeal incompetence. In Kademani D, Tiwana P (eds): Atlas of Oral and Maxillofacial Surgery, 1st ed. St Louis, Elsevier, 2016, pp 578–588).*

flap off of the prevertebral fascia, with a combination of blunt and sharp dissection. The flap should be elevated toward the skull base, in a plane at or above the level of the hard palate. The size of the port can be customized using nasal trumpets as a guide, and suturing the divided palate more posteriorly to narrow the port as needed.

- Obtain hemostasis with bipolar electrocautery.
- Sew the tip of the pharyngeal flap to the nasal layer at the most anterior aspect of divided palate with 4-0 absorbable suture. Continue this inset laterally on each side with mattress sutures until the flap is well secured to the palate.
- Reapproximate the oral mucosa of the midline palatal incision over the pharyngeal flap.
- On each side, the aperture of each port can be adjusted with the final few sutures.
- Ensure final hemostasis, especially in the most superior aspect of the base of the flap, which is a common area for bleeding.
- Place a nasal trumpet or 4-0 endotracheal tubes on each side of the nose and visualize passage into the pharynx through the ports. Once in an adequate position, these can be secured together with a transseptal stitch; nasal trumpets may simply be taped to avoid dislodgement.
- Close the donor site in the posterior pharyngeal wall with 3-0 absorbable suture.

Sphincter Pharyngoplasty

- Retract the uvula anteriorly with a suture.
- Mark out incisions along the posterior tonsillar pillar and the horizontal inset incision in the posterior pharyngeal wall (Fig. 206.5).
- Inject local anesthetic.
- Incise and elevate myomucosal flaps from each posterior tonsillar pillar from inferior to superior, including as much of the palatopharyngeus muscle as possible.[5]
- Incise inset incision down to the prevertebral fascia and spread slightly with peanut and Kittner forceps.
- Ensure hemostasis with bipolar electrocautery.
- The myomucosal flaps are inset into the horizontal incision and to the surrounding mucosa with 4-0 absorbable

suture. The flaps may be sewn end to end or in an overlapping fashion. The aperture of the single velopharyngeal port may be controlled by the length of the flaps and the degree of overlap.
- Close the defects of the posterior tonsillar pillars with 4-0 absorbable suture.

Common Errors in Technique

1. Failure to elevate the flaps adequately to promote tension-free closure.
2. Inadequate hemostasis resulting in postoperative bleeding or hematoma.
3. Not relaxing the mouthgag frequently, resulting in postoperative edema of the tongue.

POSTOPERATIVE PERIOD

Postoperative Management

1. Admit for observation until oral intake is adequate
2. Arm restraints at all times for 2 weeks except when held and supervised for a short period of time
3. Smooth liquid diet for 2 weeks
4. No pacifiers, bottles, or sippy cups with long spouts
5. Follow-up in 1 to 2 weeks
6. Antibiotics for 7 days postoperatively (optional)
7. For younger children, encourage sips of water after every meal to keep the mouth clean; older children should use chlorhexidine gluconate oral rinse twice a day(BID) × 14 days.

Complications

1. Postoperative bleeding—May stop spontaneously or with oxymetazoline spray. If persistent, may require return to operating room for control.
2. Palatal dehiscence—Continue liquid diet and watchful waiting. If fistula develops, may need to repair secondarily.
3. Persistent VPI—Continue watchful waiting and speech therapy for at least 1 year prior to consideration of repeat speech surgery, as speech may progressively improve.
4. Nasopharyngeal stenosis—Possible complication of both pharyngeal flap and sphincter pharyngoplasty. It is may result from cicatricial scar in velopharyngeal port; surgical repair is necessary if it develops.

Alternative Management Plan

1. Speech obturator or palatal lift appliance—Useful in patients who have contraindications to surgery or who have severe sleep apnea that may be made worse by surgery.
2. Injection augmentation of posterior pharyngeal wall—Injection of a filling agent, such as calcium hydroxylapatite or adipose tissue grafting, into the posterior pharyngeal wall has been described and may be useful for small gaps and for pressure VPI in woodwind and brass musicians.

DISCUSSION

Evidence-Based Medicine Question

Does isolated orofacial clefting pose an increased risk of sleep apnea?

Patients with orofacial clefting have increased rates of sleep-disordered breathing and obstructive sleep apnea compared to the general pediatric population. This is easily predicted in patients with obvious airway obstruction from craniofacial abnormalities, such as midface hypoplasia, microretrognathia, or glossoptosis. However, it may still be present, though more inconspicuous, in non-syndromic patients.

In 2011, Robison and Otteson,[1] reported a review of 459 patients with cleft lip, cleft palate, or cleft lip and palate. A total of 172 patients (37.5%) had symptoms of sleep-disordered breathing, with 89 of them (51.7%) undergoing surgery for sleep-disordered breathing or sleep apnea, most commonly tonsillectomy and adenoidectomy. Similarly, in 2014, Silvestre et al.[2] reported the results of the Pediatric Sleep Questionnaire completed as a screening tool by 867 patients and families in a tertiary care cleft clinic. Of these, 489 had isolated cleft lip and/or palate. A positive screen was noted in nearly 15% of these patients. In a separate paper, the same group reported a 28% positive screening rate in non-syndromic patients evaluated in a craniofacial clinic.[3]

It is important to note that all of the cleft surgeries, described above, are designed to minimize the velopharyngeal port size and thus may increase the airway resistance, placing children at increased risk for primary snoring or apnea. Cleft surgeons should routinely inquire about patient sleep habits and symptoms, even in patients with isolated cleft lip and or palate. Screening with a polysomnogram should be considered in symptomatic patients, as airway interventions may be indicated.

Editorial Comment

VPD is a challenging component of cleft care, which requires multidisciplinary collaboration to accurately diagnose and successfully treat patients. As always in cleft surgery, the goal is to achieve a competent velopharyngeal port at the time of the initial palate surgery. Even in expert hands, this is not always possible.

This chapter details several surgical interventions designed to address VPD either primarily or secondarily when VPD develops after an initial palate repair. Although successful speech results are the rule in any type of palate repair, our center has shown increased incidence of VPD after straight-line palatoplasty where, either due to altered growth or scarring, the levator muscles often migrate anteriorly with time. This can lead to anatomic abnormalities similar to an unrepaired submucosal cleft palate (SMCP) and variable VPD.

Our first-line treatment in these challenging patients is to lengthen the palate and posteriorly position the muscles with a conversion to a Furlow palatoplasty similar to patients with SMCP. Indeed, we have moved away from straight-line repair and now employ the Furlow technique for all primary cleft palates. We have found that even with wide clefts, the Furlow technique can be used successfully in most patients.

Jesse Goldstein

Access the review questions and additional sources list online at http://www.expertconsult.com

REFERENCES

1. Robison JG, Otteson TD. Increased prevalence of obstructive sleep apnea in patients with cleft palate. Arch Otolaryngol Head Neck Surg 2011;137(3):269–274.
2. Silvestre J, Tahiri Y, Paliga JT, Taylor JA. Incidence of positive screening for obstructive sleep apnea in patients with isolated cleft lip and/or palate. Plast Surg (Oakv) 2014;22(4):259–263.
3. Paliga JT, Tahiri Y, Silvestre J, Taylor JA. Screening for obstructive sleep apnea in children treated at a major craniofacial center. J Craniofac Surg 2014;25(5):1762–1765.
4. Gailey D, Smith K. Cleft palate. In: Kademani D, Tiwana P, editors. Atlas of Oral and Maxillofacial Surgery. 1st ed. St. Louis: Elsevier; 2016. pp. 561–568.
5. Costello BJ, Ramon R. Pharyngoplasty for velopharyngeal incompetence. In: Kademani D, Tiwana P, editors. Atlas of Oral and Maxillofacial Surgery. 1st ed. St. Louis: Elsevier; 2016. pp. 578–588.

REVIEW QUESTIONS

1. Early complications from palatoplasty include all of the following, *except*:
   a. Bleeding
   b. Wound breakdown/dehiscence
   c. Tongue swelling
   d. Scarring

2. Late sequelae of palatoplasty include all of the following *except*:
   a. Scarring, causing foreshortening of the palate
   b. Sleep-disordered breathing
   c. Persistence of velopharyngeal insufficiency
   d. Hearing loss

3. In the English language, all of the following consonant phonemes require the velopharyngeal valve to be open (nasal resonance), *except*:
   a. /f/
   b. /ng/
   c. /m/
   d. /n/

ADDITIONAL SOURCES

Furlow LT. Jr: Cleft palate repair by double opposing Z-plasty. Plast Reconstr Surg 1986;78(6):724–738.

This is the original description of the double opposing Z-plasty. It is a must-read for all cleft surgeons.

Li CH, Shi JY, Zheng Q, et al. The Children's Hospital of Philadelphia modification of the Furlow double-opposing Z-palatoplasty: 30-year experience and long-term speech outcomes. Plast Reconstru Sugr 2014;133(3):429e–431e.

This article describes a modification of the Furlow palatoplasty.

Sie KC, Chen EY. Management of velopharyngeal insufficiency: development of a protocol and modifications of sphincter pharyngoplasty. Facial Plas Surg 2007;23(2):128–139.

In this article an algorithm for management of velopharyngeal insufficiency used at Seattle Children's Hospital is discussed and outcomes are presented.

Tessier P. Anatomical classification facial, cranio-facial and latero-facial clefts. J Maxillofac Surg 1976;4(2):69–92.

This is Tessier's initial description of the standard classification scheme for orofacial clefting.

207 Microtia

Arturo Bonilla, Noel Jabbour

INTRODUCTION

The prevalence rates of microtia and aural atresia vary widely in different regions of the world, from 0.83 to 17.4 per 10,000 live births. The vast majority of these anomalies are sporadic, but also they may be found in association with other congenital anomalies or known syndromes, such as oculo-auriculo-vertebral syndrome, CHARGE syndrome, or Treacher-Collins syndrome. Microtia may be unilateral or bilateral, with over 85% of cases being unilateral.

Auricular reconstruction for microtia is a challenging but rewarding endeavor. Patients often present in infancy, years before any surgical intervention is possible. This provides the microtia surgeon and the family time to develop a relationship and to consider appropriate surgical and nonsurgical options. When the time comes, successful surgical reconstruction of the auricle requires an extensive knowledge of the normal anatomy of the auricle, meticulous attention to detail, and atraumatic handling of tissues.

Throughout the years of counseling, patients should be advised regarding all options for surgical repair, including watchful waiting, costochondral graft, external prosthesis, and use of an alloplastic implant. Worldwide, the most common method of repair remains the costochondral cartilage graft. This chapter will primarily cover this method of reconstruction. Reference is made at the conclusion of the chapter to classic articles covering alternative methods.

KEY OPERATIVE LEARNING POINTS

1. The costochondral cartilage graft technique is a safe procedure as long as meticulous tissue handling is applied and strict postoperative care is followed.
2. Careful handling of the cartilage and awareness of the proximity of the pleura is very important. A preoperative contingency plan should be in place for the unlikely occurrence of a pleural injury or pneumothorax.
3. An understanding of the thickness of the recipient skin pocket is critical to avoid both extremes: (1) too thick with subsequent loss of ear definition; and (2) too thin with compromise of the skin from ischemia. An appropriate skin flap will result in excellent detail of the sculpted cartilaginous framework.
4. Similarly, there is a progressively popular incentive to complete the reconstructive process at increasingly earlier ages and in fewer stages. This sense of urgency must be balanced with a fair measure of judicious waiting until an appropriate age when there is enough rib material in the donor site, maturity of the patient to handle postoperative care, and adequate time between stages to allow for appropriate neovascularization.

PREOPERATIVE PERIOD

History

1. History of present illness
   a. Most auricular deformities will have been present from birth, but it is important to elicit any changes in development of the ear or history of trauma to the auricle.
   b. Parents should be asked about how bothered the child is by the auricular deformity. How is it affecting the child's development, school performance, or socialization in daycare?
   c. Any concerns regarding hearing should be addressed. Did the child pass the newborn hearing screening? What plans are in place already for hearing habilitation, if any?
   d. The surgeon's experience and the realistic expectations of the patient and/or parent should be addressed (Fig. 207.1).



Fig. 207.1. The synchondrosis between the sixth and seventh rib has been harvested along with the eighth rib cartilage. These will be used to construct the framework of the reconstructed ear. An x-ray film template is helpful both for marking the skin and for fashioning the cartilage framework.

2. Past medical history
   a. Has the child had any previous attempts at auricular surgery or has an auricular prosthetic ever been used? Surgical repair is optimal in a recipient bed whose vascular supply has not been compromised by trauma, scarring, or previous surgery.
   b. Prior evaluation. Has the child had any of the following?
      1) Genetics work-up
      2) Renal ultrasound
      3) Electrocardiogram (EKG)
      4) Temporal bone computed tomography (CT) scan
   c. At the initial visit, careful questioning regarding birth history and neonatal exposure history may uncover potential causes of the microtia. This should be approached cautiously as usually the cause of microtia is never found. In the absence of any known teratogen use in pregnancy, anxious parents should be reassured that there is no evidence that they did anything wrong to cause this malformation.
   d. Concomitant medical issues: Parents should be asked about previous hospitalizations including neonatal intensive care unit (NICU) stay as well as known medical conditions and outcome of genetic testing if previously performed.
   e. Family history: Is there a family history of microtia, atresia, skin tags, cleft-craniofacial abnormalities, congenital cardiac abnormalities, kidney disease, or hearing loss?
   f. If the time for surgical repair is near, assess risk for bleeding or wound-healing difficulty by asking about:
      1) Known bleeding disorders in the family
      2) Antiplatelet drugs
      3) Patient or family history of keloid formation
      4) Herbal products
      5) Smoking or smoke exposure
      6) Nutritional status
   g. When considering a costochondral graft, it is important to ask about any known pulmonary disease, skeletal dysplasias, or rib anomalies. Has the child ever had a chest radiograph?

Physical Examination

1. Examination of the auricle
   - Careful examination and documentation of the anatomy of the auricle is critical. If there is an unaffected side, careful measurement of the auricular dimensions and projection is useful. Photodocumentation of the microtic ear and the normal auricle is essential. Examination of the preauricular area may reveal accessory tragi or sinus tracks that may be addressed before or during one of the stages of surgery. The extent of the microtic deformity may be graded as follows:
     - Grade I—nearly normal ear with deficiency in at least one dimension
     - Grade II—ear with structural deficiencies but recognizable anatomy
     - Grade III—rudimentary soft-tissue with small "peanut" remnant
     - Grade IV/anotia—absent auricle
2. Otoscopic examination
   - Bilateral examination of the ear canals, if present, with an otoscope is essential in assessing for aural atresia and external auditory canal stenosis. In unilateral cases, it is very important to document the examination of the tympanic membrane of the unaffected side, as this may be the only hearing ear. Effusions in the normal ear should be followed closely until resolution.
3. Facial symmetry
   - Especially in unilateral cases of microtia, the presence of facial asymmetry, hemipalatal paresis, or jaw discrepancy, may indicate a need for further assessment for hemifacial microsomia. If any significant crossbite or jaw asymmetry is noted, this may warrant orthodontic or oral surgical evaluation prior to microtia repair, as the ultimate position of the reconstructed auricle may change with these interventions.
4. Audiometric evaluation
   - Parents should be reminded that hearing is the first priority. Assessing hearing status on physical examination in an infant or young child is unreliable. Aural atresia will result in a maximal conductive hearing loss. If the hearing status of the contralateral ear or the bone conduction thresholds of the affected ear cannot be confirmed, then auditory brainstem response (ABR) testing should be ordered.
5. Examination of the rib donor site
   a. Anthropometric measurements—Having adequate costochondral graft material for surgical repair of microtia is dependent upon the patients height and weight even more so than on age. An average 7-year-old will have an appropriate amount of costochondral graft material. Assessing the position of the patient on the growth chart will aid in determining the proper timing of surgery. If the patient is very high on the growth curves, surgery may be considered at an earlier stage. Alternatively, in the patient who is below the 10th percentile, consideration should be given to delaying repair for at least 1 more year.
   b. An examination of the chest wall should reveal any skeletal abnormalities, including pectus excavatum, which may present a challenge for cartilage harvest. Palpation of the lower border of the ribs will reveal any contour irregularities that may be present.

Imaging

Chest radiograph—A two-view, frontal and lateral, chest radiograph should be reviewed preoperatively to rule out any chest wall or cardiac silhouette abnormalities.

CT—A maxillofacial CT scan is not required but should be considered in patients with jaw asymmetry, facial asymmetry, or hemifacial-microsomia. We perform one CT scan of the temporal bones in patients with aural atresia, usually around age 5, to assess candidacy for atresiaplasty and to rule out congenital cholesteatoma.

Indications

1. Microtia with desire to correct auricular deformity.
2. Realistic expectations for surgical outcome (Fig. 207.2).

Contraindications

1. Medical comorbidities with increased risk for general anesthesia.
2. Significant, uncorrected bleeding disorder or nutritional deficiency that would increase the risk for complications with wound healing.
3. Chest wall skeletal abnormalities, such as significant scoliosis or pectus excavatum.
4. Unrealistic expectations or psychological instability (Fig. 207.3).

Preoperative Preparation

1. Photodocumentation with standard lateral view, frontal, and oblique views. A birds-eye-view may be useful to assess conchomastoid angle discrepancies.



Fig. 207.2. An example of "closed framework" on the left (Bonilla); details of the cartilage are carved into the framework; tragus has been carved and will be attached to the main framework prior to insertion. An example of "open framework" on the right (Jabbour); antihelix is augmented with pieces of cartilage sutured to the main framework. Both include the eighth rib sutured to the framework for the helix.



Fig. 207.3. Typical examples of postoperative view immediately following stage I reconstruction *(left)* and 1-week postoperative *(right)*. Drains are left in place for 5 to 7 days.

2. A template of the unaffected ear or of a sibling or parent's ear, in bilateral cases, may be fashioned by tracing the auricular features onto x-ray film. The film then may be cut to develop a template that may be sterilized for use in the first stage of surgery.
3. Discontinue antiplatelet drugs if possible.
4. Patients should be counseled on the importance of postoperative care and advised on realistic surgical outcomes.

OPERATIVE PERIOD

Anesthesia

General: Due to the need to harvest a costochondral graft, the first surgical stage should always be performed under general anesthesia. In adults, the subsequent stages may be performed with local anesthesia and sedation; however, general anesthesia is preferred for patient comfort.

Positioning

Supine: The patient is positioned supine so that both ears may be viewed and accessed during the procedure.

Perioperative Antibiotic Prophylaxis

First-generation cephalosporin
Second-generation cephalosporin
Clindamycin if allergic to penicillin.

Monitoring

None.

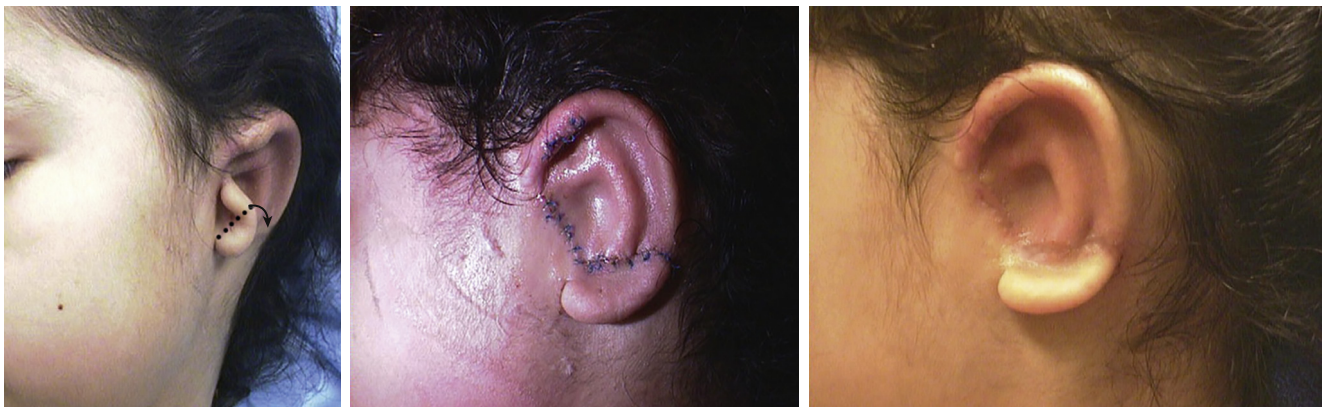

Fig. 207.4. Progression of steps for second stage reconstruction with lobule transposition. A Z-plasty is marked to transpose the lobule posteriorly. A pocket is created in the lobule to insert the inferior aspect of the cartilage framework. Excess skin on the superior aspect of the lobule is used to deepen the conchal bowl, and multiple smaller W-plasty incisions are performed to irregularize the scar. Two-week postoperative view is shown on the right.

Instruments and Equipment to Have Available

1. Basic surgical set with fine instruments for soft-tissue dissection
2. Rib harvesting set, with periosteal elevators and Doyen elevators
3. Suture: 4-0 undyed nylon suture, 3-0 and 4-0 Vicryl suture, 5-0 monocryl suture, or similar
4. Depending on surgeon preference, bipolar scissors or contact laser for fine-control rib excision (optional) (Fig. 207.4)

Key Anatomic Landmarks

1. Normal auricular anatomy
2. Muscular anatomy of the lower chest wall
   a. Rectus abdominus—inserts to cartilaginous components of fifth, sixth, and seventh ribs and xyphoid process.
   b. External abdominal oblique muscles—origin is external surfaces of ribs 5 to 12; inserts to abdominal aponeurosis.
   c. Internal abdominal oblique muscles—has insertions into ribs 8 to 12 and abdominal aponeurosis.
   d. External intercostal muscles.
   e. Internal intercostal muscles.
3. Intercostal space—Neurovascular bundle runs in the superior aspect of each intercostal space in the order of vein, artery, nerve, from superior to inferior.
4. Costochondral junction—The bony to cartilaginous junction of each rib can be identified by the changes in color at the junction and confirmed with a 25-gage needle intraoperatively after exposing the rib, as the needle will pass more easily into the cartilaginous portion.

Prerequisite Skills

1. Experience in costochondral graft harvest
2. Skill and experience in carving costochondral cartilage for microtia reconstruction
3. Soft tissue reconstruction techniques, including skin-grafting
4. Thorough knowledge of the normal anatomy of the auricle

Operative Risks

1. Early complications:
   a. Seroma or hematoma
   b. Wound infection and/or breakdown
   c. Ischemia of skin overlying cartilage framework
2. Late complications:
   a. Unsatisfactory aesthetic result
   b. Asymmetry
   c. Scarring

Preoperative Preparation

- Design of auricular template from flipped image of contralateral auricle (if available). This can be performed by printing a horizontally-flipped photo in photo editing software or by tracing the contralateral ear with transparency film.
- The authors use x-ray film, which can be sterilized, for the auricular template.

Surgical Technique

There are two techniques: (1) three-stage Bonilla technique and (2) four-stage technique.

Stage I—Creation and Insertion of Cartilage Framework and Tragus

- Preoperative
  - Mark patient ear and rib to confirm laterality in preoperative area.
  - Confirm final sizing of template and send for fast sterilization.
- Induction/preparation
  - Ancef.
  - Decadron.
  - Inject lidocaine 1% or 2% with 1:100,000 epinephrine into the proposed incision of chest wall.
  - Prep ear and face as well as chest.
  - During rib harvest, keep the patient's head facing up to avoid soreness of the neck from prolonged lateral positioning.
  - Drape in such a way that the contralateral ear may be viewed if needed. Have the nose exposed, as the angle of the nasal dorsum parallels the ideal auricular angle.
- Rib harvest
  - Make a 3 to 4 cm incision overlying rib 7. This will allow access to ribs 6 to 8.
  - The contact laser or bipolar cautery is used to divide the adipose and muscular layer overlying the ribs (use of the contact laser allows less thermal injury, less bleeding, and less postoperative pain).

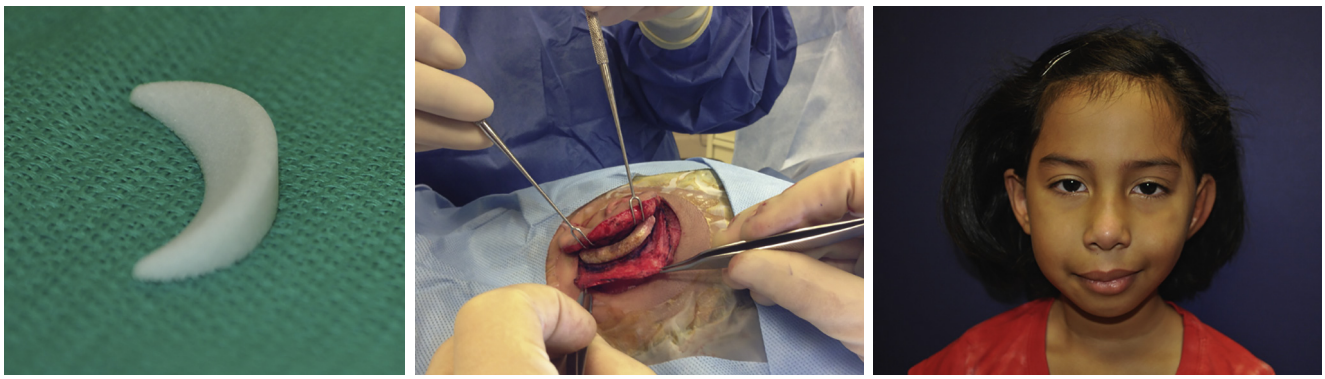

Fig. 207.5. Progression of steps for third (separation) stage. The framework is elevated and a polyethylene implant wedge is placed for projection and is covered with a conchal-based flap and full-thickness skin graft. The picture on the right is the final result.

- The ribs are handled carefully with skin hooks to avoid trauma to the perichondrium.
- The contact laser or bipolar cautery is used to dissect the soft tissue away from the ribs with the ability to avoid the area of the pleura and to control hemostasis.
- The cartilaginous portion of the first floating rib (eighth rib) is excised medially to laterally until the bony-cartilaginous junction is identified. A small layer of cartilage is left covering the junction to avoid a hard, pointed remnant of the bony rib.
- The synchondrosis of ribs 6 to 7 is identified and marked with a sterile marking pen using the preoperative template that was sterilized.
- Using the contact laser, the marked synchondrosis is carefully excised with care to stay close to the cartilage and away from the pleura.
- The cartilage is placed in sterile saline with antibiotic solution.
- The cavity is evaluated for any bleeding.
- A 10 French JP drain is placed deep to the muscle layer.
- The muscular and adipose layers are closed separately with interrupted 4-0 Vicryl sutures.
- The skin is closed with a running subcuticular suture with either 4-0 Vicryl or 5-0 monocryl.
- Dermabond, Mastisol, and Steri-Strips are used to reinforce the skin closure.

- Analgesics
  - Depending on the surgeon's preference, pain control is attained by the anesthesiologist with an epidural injection or a paravertebral block. The timing of this placement is variable; if placed prior to rib harvest, decreased narcotic use during the case may be possible; if placed during the cartilage carving, decreased operative time may be achieved.
- Cartilage carving
  - The rib grafts are kept moist and are handled very carefully to avoid trauma to the perichondrium.
  - Soft tissue is removed from the cartilage with tenotomy scissors.
  - The floating rib (eighth rib) is first cleaned of soft tissue. This will be the future helix. The most medial part of this floating rib will be the crus of the helix. The helical crus is then formed by excising the most medial portion of the eighth rib cartilage to make a slightly pointed edge. In order to cause a bend of the cartilage, the outer edge is trimmed and the perichondrium is removed very carefully with a scalpel. Care must be given to avoid excising too much cartilage. This would cause the cartilage to become too thin with eventual buckling.
  - The synchondrosis is also cleaned by removing the soft tissue. The x-ray template is then placed over the synchondrosis in order to size the new ear. A sterile marking pen is used to mark the outer area of the template. This cartilage is then excised. If the synchondrosis cartilage is too thick, it may be thinned by trimming with a scalpel.
  - The helix (eighth rib) is then placed on the outer edge of the framework and secured with 4-0 clear nylon sutures with the knots kept on the undersurface.
  - The triangular fossa is then sculpted with the scalpel or skin punch and the scaphae is deepened with a 4 mm skin punch or cartilage gouge.
  - An extra piece of cartilage is then sculpted into the shape of the tragus.
  - This piece is then anchored to the area of the helical crus superiorly and to the lower framework inferiorly with a 4-0 clear nylon suture in a mattress fashion with knots on the undersurface of the cartilage framework.
  - The completed framework is kept in normal saline with antibiotic solution (Fig. 207.5).
- Recipient pocket
  - Inject 1% or 2% lidocaine with 1:100,000 epinephrine just anterior to the microtic vestige.
  - A marking pen is used to make a vertical incision just anterior to the microtic vestige.
  - Make an incision on the marking with a #15 scalpel blade.
  - Undermine a skin pocket with the tenotomy scissor with very careful attention to stay immediately under the subdermal plexus. If the skin pocket is too thick, the new ear will lack definition. If the skin pocket is too thin, there will be a risk of ischemia and potential necrosis of the skin with subsequent exposure of cartilage.
  - The pocket is undermined to 3 mm lateral to the outer ear marking that was placed preoperatively.
  - Hemostasis is controlled with the needlepoint cautery or bipolar with careful attention to avoid cauterization on the actual skin (this can cause damage to the subdermal plexus).
  - The vestigial cartilage is excised with the tenotomy scissor with care to avoid buttonholing the skin.
- Insertion of cartilage framework
  - A #10 French drain is inserted approximately 2.5 cm posterior–inferiorly to the future ear.
  - The cartilaginous framework is then placed into the skin pocket and the appropriate orientation and position is attained; suction is then applied to the JP drain.
  - The skin is closed with a running 6-0 prolene suture, and the drain is secured with a 3-0 prolene suture.

- Antibiotic ointment is placed over the incision site and the drain site, and a telfa dressing is then applied over the ear.
- A sterile ear dressing is then applied without pressure on the ear.

Stage II—Lobule Reconstruction and Deepening of Conchal Base (2 Months After First Stage)

- The height of the normal ear is measured preoperatively in order to maintain the same height on the microtic ear.
- Inject 1% or 2% lidocaine with 1:100,000 epinephrine anterior and posterior to the microtic vestige with care to avoid injecting inferiorly to avoid vestige ischemia and necrosis of the skin.
- Also inject into the inferior aspect of the framework over the future site of the lobule transposition.
- An incision is made in the front of the skin vestige, and continued superiorly then posteriorly to the vestige. The incision is continued posteriorly to the edge of the framework.
- The inferior part of the cartilaginous framework is then exposed with the tenotomy scissor.
- The skin vestige is then rotated posteriorly to its future location.
- A small pocket is then made in the lobule, and the inferior part of the exposed cartilaginous framework is then inserted into the skin pocket. This maneuver allows the ear to keep its vertical height.
- The conchal skin is then undermined and soft tissue is excised in order to deepen the conchal base.
- The base is anchored with 6-0 prolene sutures and all of the remaining skin edges are then closed with interrupted 6-0 prolene sutures.
- Antibiotic ointment is placed over the incision site and a telfa dressing is then applied over the ear.
- A sterile ear dressing is then applied without pressure on the ear.

Stage III—Creation of Postauricular Sulcus and Elevation of Framework (2 Months After the Second Stage)

- Full-thickness skin graft harvest
  - The ear and groin area are prepped.
  - A marking pen is used to mark approximately 2 mm around the cartilaginous framework. In addition, the groin is marked where the full-thickness skin graft will be harvested.
  - Inject the markings on the ear and the groin with 1% or 2% lidocaine with 1:1,00,000 epinephrine.
  - A full-thickness skin graft is harvested from the groin area (~2 cm × 6 cm).
  - The soft tissue is closed with interrupted 4-0 mersilene or Vicryl sutures.
  - The subcuticular layer is closed with a running 4-0 Vicryl or 5-0 monocryl suture.
  - Steri-Strips are then applied.
  - The skin graft is then placed in betadine and then in normal saline with antibiotic solution.
- Elevation of framework
  - The auricular incision is then made from the superior helix to the lobule.
  - The ear is undermined anteriorly to approximately half of the framework with the tenotomy scissor or needlepoint cautery with care to avoid exposure of the cartilage. A moist sterile gauze is then placed over the wound.
  - Projection of the ear can be accentuated with a wedge implant. This can be constructed from costochondral rib harvested and banked during the first stage or from a porous polyethylene wedge implant. Care should be taken to ensure that the wedge implant is fully covered prior to skin grafting. This can be accomplished either by the creation of a tunneled pocket in the post-auricular sulcus, or by the elevation of an anteriorly based temporo-occipital flap that can be rolled anteriorly to cover the wedge implant. The implant is totally covered and secured with interrupted 4-0 mersilene sutures.
  - The posterior skin edges are then advanced anteriorly and anchored to the mastoid periosteum with 4-0 mersilene sutures. The full-thickness skin graft is then placed on the undersurface of the elevated framework, and the skin edges are closed with interrupted 6-0 prolene sutures or absorbable sutures, depending on the surgeon's preference. A sterile sponge or xeroform gauze is lightly applied as a bolster over the skin graft and secured with interrupted 4-0 prolene sutures.
  - Antibiotic ointment and a telfa dressing is then placed over the ear.
  - An ear dressing is then applied without pressure.

Stage IV—(Only If Using the Four-Stage Technique) Tragus Formation (2 to 3 Months After the Third Stage)

If tragus is constructed in stage I, then a fourth stage may be avoided by the microtia surgeon. However, if patient is a candidate for aural atresiaplasty, the following can be performed to accentuate the tragus at the time of the canaloplasty.

- An anteriorly based tragus flap is outlined by marking out a curvilinear incision in the conchal bowl just posterior to the tragus.
- The proposed incision is injected with 1% lidocaine with epinephrine 1:100,000. The incision is made with a 15-blade.
- An anteriorly based skin flap is elevated superficial to the tragal cartilage (if present).
- Dissection deep to the tragal cartilage is performed.
- The anteriorly based flap is wrapped around the tragal cartilage and secured to the underlying soft-tissue with buried absorbable sutures.
- If performed with canaloplasty, the skin edges are then secured to the split-thickness skin graft harvested for the canal reconstruction (see chapter on aural atresia).
- If not performed with canaloplasty, a full-thickness skin graft may be utilized from the contralateral postauricular skin to address the donor site defect in the conchal bowl.

Common Errors in Technique

1. Rough handling of the cartilage: If the electrocautery is too close to the cartilage during rib removal, this can cause thermal injury that may become apparent later with eventual resorption of injured cartilage.
2. Skin pocket thickness: This is one of the most important parts of the reconstruction. If the skin pocket is too thick, this will not allow the skin to develop good definition over the cartilaginous framework secondary to thickness. If the skin pocket is too thin, this can cause ischemia and necrosis of the skin with subsequent exposure of the cartilage.
3. Lack of postoperative care: The ear must be cared for very meticulously for 4 to 6 months after surgery. The patient can resume normal activities, but use of the ear cup (during sleep) without pressure is very important to allow the skin to adhere to the cartilaginous framework without constant pressure on the skin.



Fig. 207.6. Patient A: Preoperative grade III microtia *(left)* and postoperative view after completing all stages of total Auricular reconstruction. Patient B: with right microtia and atresea and following reconstruction.

POSTOPERATIVE PERIOD

Postoperative Management

1. Wrap the head to protect the pinna. Should wear initial head-wrap until postoperative visit in 1 week and then at night thereafter.
2. Pain medication: When managed by an epidural injection or a paravertebral nerve block, the pain after the first stage is usually quite minimal. Acetaminophen or ibuprofen may be administered as first-line treatment for pain. Narcotic pain medication may be used for breakthrough pain. Patients should be expected to have less pain in subsequent stages. Pain beyond expectation in the early postoperative period may indicate hematoma or early infection.
3. Parents are instructed on drain management and are expected to record outputs of drains. Drains will be removed at the 1-week postoperative visit.
4. Postoperative photodocumentation (Fig. 207.6).

Complications

Short term:

1. Pneumothorax during rib cartilage harvest can occur. See chapter on cartilage harvest.
2. Seroma, hematoma, or wound infection—This may require needle aspiration or incision and drainage. Any purulence should be cultured, and appropriate antibiotic management prescribed.
3. Exposure of cartilage framework—If skin breakdown occurs over the cartilage framework, the exposed cartilage should be débrided back to healthy, white cartilage. If the area is small, the skin may re-epithelialize over the area of breakdown. Antibiotic ointment may be used to cover this area to keep it moist and clean. If re-epithelialization does not occur, this exposed cartilage will need to be covered with either a local flap or a temporalis flap and skin grafts.

Long term:

1. Unsatisfactory cosmetic result—Realistic patient expectations coupled with a well-executed surgical plan are keys to prevention. If revision surgery is required, it is possible to undergo repeat cartilage surgery, placement of a prosthetic, or reconstruction with an alloplastic implant (if the temporoparietal flap has not been previously compromised).
2. Chest-wall deformity (rare) —It is best to prevent this by retracting muscles rather than splitting them.

Alternative Management Plan

1. Watchful waiting.
2. Prosthetic auricle—A silicone-based prosthesis may be fashioned by an anaplastologist. This may be fixated with tape, glue, or surgically implanted anchors. It may require surgical removal of the microtic ear in order to allow for a proper fit.
3. Costochondral graft with fewer surgical stages: "Nagata technique."
4. Reconstruction with an alloplastic implant. The implant is covered by a temporoparietal flap and skin grafts.

DISCUSSION

Evidence-Based Medicine Question

What is the earliest age that microtia reconstruction should be initiated?

The optimal age for microtia reconstruction is dependent upon both psychosocial and physical factors. Completing all of the stages of surgery prior to entry into primary school is often desired. However, it is often not feasible, as the eighth rib length should ideally measure close to 6 to 8 cm in order to fashion the helical rim from one piece of cartilage.

In an effort to identify the normal growth curve of costochondral cartilage in children, Andreoli et al.[1] reviewed 360 chest CT scans in children aged 3 to 20 years. Rib cartilage growth was found to be nearly linear in childhood, with the height of ribs 6 to 8 approaching adult size by 8 years of age. In that study, rib size was consistently larger in males and on the left side. At age 6, rib 8 measured 6.33 cm ± 1.01 cm and increased to 8.95 cm ± 1.99 cm at age 8.

In children who are at or above average on their growth charts, it may be feasible to proceed with stage I of surgery closer to age 6. Keeping this in mind, for children who are small for their gestational age, waiting until 7 to 8 years of age may be reasonable.

Editorial Comment

Microtia reconstruction is part art and part science. Few other surgeries in the head and neck require such attention to detail both in sculpting the cartilaginous framework and in careful handling of the soft tissue.

This chapter outlines the steps used for total auricular reconstruction. In the future, technological advances may allow for other methods for autologous cartilage reconstruction using 3D printing of complete cartilage frameworks, bio-scaffolds for cartilage ingrowth, or some combination of these. Until then, some variation of the above multi-stage technique remains the standard for total auricular reconstruction worldwide. Surgeons and their patients should be fully aware that results can vary significantly between surgeons, and even for high-volume microtia surgeons with consistent outcomes, results may vary from patient to patient. Nevertheless, cosmetically pleasing results have been achieved with consistency using the above technique.

Noel Jabbour

Access the review questions and additional sources list online at http://www.expertconsult.com

REFERENCES

1. Andreoli SM, Mills JC, Kilpatrick LA, et al. CT measured normative cartilage growth in children requiring costochondral grafting. Otolaryngol Head Neck Surg 2013;149(6):924–930.
2. Brent B. Microtia repair with rib cartilage grafts: a review of personal experience with 1000 cases. Clin Plast Surg 2002;29(2):257–271. vii.
3. Hamming KK, Lund TW, Lander TA, Sidman JD. Complications and satisfaction with pediatric osseointegrated external ear prostheses. Laryngoscope 2009;119(7):1270–1273.
4. Moon IY, Oh KS, Lim SY, et al. Estimation of eighth costal cartilage in surgical timing of microtia reconstruction. J Craniofac Surg 2015;26(1):48–51.
5. Watanabe M, Asato H. Deciding on the timing and method of surgery. Adv Otorhinolaryngol 2014;75:57–59.
6. Yellon RF. Combined atresiaplasty and tragal reconstruction for microtia and congenital aural atresia: thesis for the American Laryngological, Rhinological, and Otological Society. Laryngoscope 2009;119:245–254.

REVIEW QUESTIONS

1. The most common option worldwide for correction of microtia is:
   a. Prosthetic
   b. Costochondral graft
   c. Watchful waiting
   d. Alloplastic implant

2. A possible early complication from rib cartilage harvest for stage I microtia reconstruction include all of the following, *except*:
   a. Hematoma
   b. Wound infection
   c. Pneumothorax
   d. Chest wall deformity

3. A microtic ear with structural deficiencies, but recognizable anatomy, may be described as:
   a. Grade I microtia
   b. Grade II microtia
   c. Grade III microtia
   d. Grade IV microtia

ADDITIONAL SOURCES

Aguilar EA 3rd, Jahrsdoerfer RA. The surgical repair of congenital microtia and atresia. Otolaryngol Head Neck Surg 1988;98(6):600–606.

Artunduaga MA, Quintanilla-Dieck MD, Greenway S, et al. A classic twin study of external ear malformations, including microtia. N Engl J Med 2009;361(12):1216–1218.

Baluch N, Nagata S, Park C, et al. Auricular reconstruction for microtia: a review of available methods. Plast Surg (Oakv) 2014;22(1):39–43.

Brent B. Auricular repair with autogenous rib cartilage grafts: two decades of experience with 600 cases. Plast Reconstr Surg 1992;90(3):355–374. discussion 375–376.

Nagata S. A new method of total reconstruction of the auricle for microtia. Plast Reconstr Surg 1993;92(2):187–201.

208 Congenital and Acquired Atresia and Stenosis of the External Auditory Canal

Robert Yellon

INTRODUCTION

In the management of congenital aural atresia (CAA) and congenital external auditory canal stenosis (CEACS), the surgical challenge arises from anatomic variation and absence of standard landmarks. The incidence of microtia/CAA is approximately 1 in 10,000. In a large series, 58% of cases of microtia were right-sided, 32% left-sided, and 9% bilateral. Frequently associated anomalies include facial asymmetry, seventh nerve weakness, cleft lip/palate, urogenital anomalies, and cardiovascular anomalies.

The etiology of microtia/CAA includes in utero ischemia with obliteration of the stapedial artery, increasing maternal age, and chromosomal aberrations. Teratogens for microtia/CAA include thalidomide, isotretinoin, vincristine, and colchicine. Syndromes with microtia/CAA/CEACS include oculoauriculovertebral spectrum and Treacher-Collins syndrome. Oculoauriculovertebral spectrum may include cardiac, cervical spine, auricular, ocular, and renal anomalies. Such patients require ophthalmologic, genetic, and dental/craniofacial consultation. Associated airway and feeding problems require treatment.

Parents are educated that the two important factors are early improvement of hearing and later optimal cosmesis. The plan for reconstruction of both the auricle and CAA will require staged surgeries. Parents should be educated about options for microtia reconstruction, as well as BAHA (Cochlear, Centennial, Colorado), Ponto (Oticon, Askim, Sweden), Sophono (Boulder, Colorado), Vibrant Soundbridge middle ear implants (Cochlear), and Softbands. Possible complications of the surgeries are discussed.

Acquired external auditory canal atresia (AEACA), which results from inflammation, infection, trauma, or surgery will also be discussed.

KEY OPERATIVE LEARNING POINTS

a. Patients with CAA have maximal (60 dB) conductive hearing loss (CHL) but rarely sensorineural hearing loss (SNHL). Behavioral testing, otoacoustic emissions, and auditory brainstem response (ABR) may be needed to determine hearing thresholds.
b. Hearing rehabilitation is more important for bilateral CAA/CEACS than for unilateral cases. However, unilateral CAA/CEACS can cause speech and school difficulties.[1]
c. Grading systems including the Yeakley and Jahrsdoerfer[2] and modified Dedhia et al.[3] systems for grading of computed tomography (CT) of the temporal bone help determine which patients are candidates for atresiaplasty based on anatomy.
d. Surgery for hearing should be coordinated with a microtia surgeon to develop a plan that considers all hearing and cosmetic options.[4]
e. Some surgeons combine stages of microtia reconstruction with atresiaplasty.
f. Atresiaplasty can be performed with anterior (lateral) or canal wall-down techniques. Anterior (lateral) technique is preferred to avoid mastoid bowl issues.
g. CEACS must be followed closely with serial CTs, even if no surgery is initially planned, to watch for possible canal cholesteatoma.
h. Complications of atresiaplasty may include external auditory canal (EAC) stenosis, recurrent infections, lateralization of the tympanic membrane (TM), persistent CHL, and, rarely, facial nerve injury and SNHL.[4]

PREOPERATIVE PERIOD

History

CAA/CEACS

A consult for a patient with microtia and CAA/CEACS is often requested shortly after birth. A history of airway, feeding, or other potentially life-threatening issues should be determined, as well as familial microtia/CAA or intrauterine teratogen exposure. A history of school and speech problems is important for older children.[1]

AEACA

AEACA usually involves soft tissue but occasionally bony obliteration of the EAC. The common pathway in AEACA is a history of exuberant fibroproliferative inflammation. Causes of AEACA include chronic otitis externa, chronic suppurative otitis media, fractures or burns of the EAC, tympanomastoid surgery, or chronic dermatitis.

Physical Examination

CAA/CEACS

A physical examination should be performed with special attention to the ears. CAA versus CEACS, syndromic appearance, and airway, feeding, and cardiac status are evaluated. Microtia is graded as follows: grade 1, nearly normal ear with some minor anomaly; grade 2, an ear with moderate structural deficiencies; grade 3, classic severe "peanut deformity" (Fig. 208.1); and grade 4, anotia or no auricle and earlobe.

CEACS should be débrided while restraining the child using a microscope, if possible, to examine the EAC and TM.

Ongoing evaluations are important since otitis media occurs in higher frequency in the normal ear than in the general population. Tympanostomy is performed if indicated. The child is examined every 6 to 12 months or more frequently, if necessary.

AEACA

The debris in the ear canal should be suctioned and cultured. The presence of ongoing inflammation versus mature scar in the EAC is determined.

Imaging

CAA/CEACS

For CAA/CEACS, high resolution CT of the temporal bones, in both axial and coronal planes, is obtained at 5 years



Fig. 208.1. Grade 3 microtia with congenital aural atresia.

TABLE 208.1 Jahrsdoerfer Grading System for Computed Tomography of Congenital Aural Atresia/Congenital External Auditory Canal Stenosis

Anatomic Structure	Points
Stapes normal or abnormal but present	2 or 1
Oval window open	1
Middle ear well pneumatized	1
Facial nerve favorable position	1
Malleus/incus well formed	1
Incudostapedial joint intact	1
Mastoid well pneumatized	1
Round window open	1
Auricle normal	1
Maximum total	10
If total ≥6, favorable for atresiaplasty	—
If total <6, unfavorable for atresiaplasty	—

With permission from Yeakley J, Jahrsdoerfer RA: CT evaluation of congenital aural atresia: what the radiologist and surgeon need to know. J Comput Assist Tomogr 20:724-731, 1996.

to evaluate the anatomy for atresiaplasty and to rule out cholesteatoma. The incidence of congenital cholesteatoma in CAA/CEACS is 0% to 7%. Even if no surgery is planned, an initial CT should be obtained, as well as a later CT to rule out cholesteatoma not initially evident.

CAA/CEACS—Grading Systems of Favorability for Atresiaplasty

Candidacy for reconstruction of CAA/CEACS is dependent on the anatomy. Yeakley and Jahrsdoerfer[2,4] devised a grading system to evaluate CT of the temporal bone and auricle to identify favorable candidates for atresiaplasty.

Each favorable factor is awarded one point (Table 208.1). A score of <6 indicates that the patient is not a candidate for atresiaplasty, while ≥6 indicates a favorable candidate. The higher the total number, the more likely a good hearing result after atresiaplasty.

A normal stapes is the only factor awarded two points, while an anomalous stapes is awarded one point. An absent stapes receives no points. If no stapes or oval window (OW) can be identified on CT or intraoperatively, the procedure should be declined or aborted, respectively.

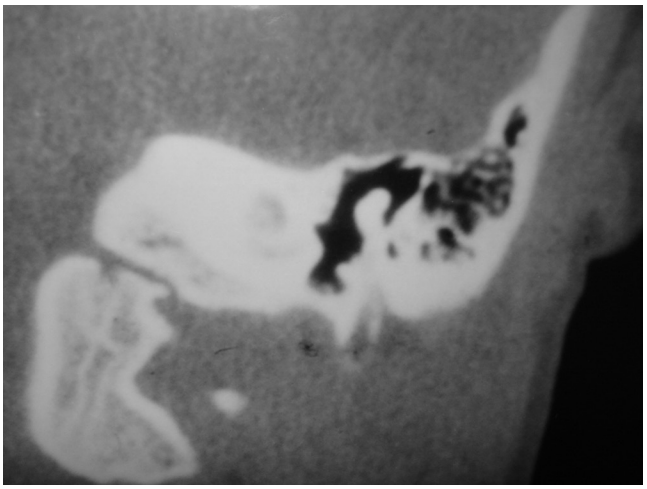

Fig. 208.2. Coronal CT of left temporal bone with congenital aural atresia. Note high tegmen mastoideum, well-pneumatized mastoid and middle ear, and malleus attached to atretic plate.

TABLE 208.2 Modified Jahrsdoerfer Grading System for Computed Tomography of Congenital Aural Atresia/Congenital External Auditory Canal Stenosis

Anatomic Structure	Points
Stapes normal or abnormal but present	2 or 1
Oval window open	1
Middle ear well pneumatized	1
Malleus/incus well formed	1
Incudostapedial joint intact	1
Mastoid well pneumatized	1
Round window open	1
Auricle normal	1
Tegmen mastoideum normal or mildly low	2 or 1
Malleus–incus versus stapes position normal	1
Facial N. at oval window normal	1
Facial N. posterior (not lateral) to middle ear	1
Maximum total	14

With permission from Dedhia K, Yellon RF, Branstetter BF, et al.: Anatomic variants on computed tomography in congenital aural atresia. Otolaryngol Head Neck Surg 147(2):323-328, 2012.

A well-pneumatized middle ear space is associated with better hearing outcomes. The position of the facial nerve is critical. When favorable, the facial nerve lies superior to the OW in its horizontal portion and then courses inferiorly at the second genu to pass inferiorly through the mastoid cavity. When unfavorable, the facial nerve may totally or partially cover the OW/stapes, thus precluding a surgical approach to the window. A second possible anomaly in CAA is that the facial nerve may pass anterolaterally at the second genu, rather than inferiorly. Thus, the facial nerve crosses lateral to the middle ear and may be injured during an anterior (lateral) surgical approach.

In CAA, it is very common to find a fused malleus–incus complex (MIC), which is fixed to the bony atretic plate (Fig. 208.2). It is favorable when the MIC is well formed and not hypoplastic. A normal incudostapedial joint on CT is also favorable. The presence of a round window is favorable because obliteration impairs sound energy delivery into the cochlea. A normal auricle is awarded a point because it is formed earlier during embryogenesis than the middle ear, and this usually suggests less middle ear deformity.

Dedhia et al.[3] described useful modifications of the Jahrsdoerfer grading system for atresiaplasty (Table 208.2).

New and/or modified anatomic considerations and their respective incidences in CAA CTs included the presence of (1) moderately low-lying tegmen mastoideum (13%); (2) severely low-lying tegmen mastoideum (4%); (3) MIC large and positioned directly lateral to stapes rather than normal anterolateral position (24%); (4) facial nerve obstructing OW (41%); and (5) facial nerve turning anterolateral (21%).

The anterior (lateral) approach to the middle/attic may be more difficult yet still possible if the tegmen mastoideum is mildly low; however, a severely low-lying tegmen precludes atresiaplasty. A large MIC that is directly lateral to the stapes will block access to the incudostapedial joint and stapes, making it difficult or impossible to assess incudostapedial joint discontinuity and/or stapes fixation, which may result in persistent CHL. Presence of these anomalies may make atresiaplasty impossible or more difficult.

In the usual setting of bilateral chronic ear disease, the worse hearing ear is traditionally operated on first. In contrast, in bilateral CAA/CEACS, the ear with the most favorable anatomy is selected first to maximize chances for a good hearing outcome while minimizing risks.

AEACA

CT imaging is helpful in differentiating bony from soft tissue atresia, detecting cholesteatoma, and assessing the mastoid, middle ear, and ossicles.

Indications

Unilateral Versus Bilateral CAA/CEACS

With bilateral CAA/CEACS and CHL, there is greater need to provide hearing rehabilitation than for unilateral cases. The need for hearing rehabilitation for unilateral CAA/CEACS is more controversial, and some argue that there are risks and that gains are smaller than for bilateral cases.

In the past, for unilateral CAA, no intervention was recommended other than preferential seating and close monitoring of the normal ear. Recently, up to 43% of children with unilateral CAA were shown to have school problems and require extra services, including speech therapy and educational intervention programs.[1] Rehabilitation should be offered to children with language or school difficulties, but otherwise some wait for a decision by the child when older. For unilateral CAA/CEACS, binaural hearing, improved sound localization, and optimization of hearing in noise are desirable.

CEACS

Schuknecht described the type A anomaly as isolated meatal stenosis, which is easiest to repair. Canal cholesteatoma may develop. Middle ear anatomy is fairly normal. The Lempert endaural approach (described later) is used for severe stenosis.

The type B anomaly is more extensive CEACS affecting the entire EAC. Middle ear anomalies are more common. Canaloplasty/atresiaplasty is performed if narrowing is severe, or if there is canal cholesteatoma, or significant CHL (dependent on CT grading). The incidence of type A and B anomalies is approximately equal. Yellon observed that 50% of cases of CEACS will have a partial atretic plate, hypoplastic TM, and/or ossicular anomalies. Jahrsdoerfer and Chole reported a 50% incidence of canal cholesteatoma by age 20 with EAC diameter <4 mm. It is likely that some of these cases were untreated as children. A neonate with an EAC diameter of ≥2.5 mm who is examined and débrided in the office or operating room every 6 months will often outgrow the problem after 4 to 5 years. Canal cholesteatoma is much more likely when the EAC is ≤2 mm. Frequently cerumen occludes the CEACS causing CHL. Examination of the ear by a non-otolaryngologist will be difficult if not impossible, and pathology may go undetected.

AEACA

CHL is the indication for repair of AEACA.

Contraindications

CAA/CEACS

Any degree of SNHL that is more than mild will preclude atresiaplasty. Any anomaly of the inner ear precludes atresiaplasty because of an increased incidence of SNHL following surgery.

AEACA

Inflammatory processes must be resolved prior to surgical repair.

Preoperative Preparation

Alternatives for Hearing Rehabilitation in CAA/CEACS

Nonsurgical Devices

Children with bilateral CAA/CEACS or selected cases of unilateral CAA/CEACS may be fitted with a sound processor clipped to a Velcro headband (Softband) during the first year of life. Devices include the BAHA, Ponto, and Sophono sound processors with headbands. These devices may also be used as a trial prior to implantation.

The bone conduction hearing aid with metal headband is a less expensive option. A hearing aid is an option with a normal auricle.

Timing and Sequence of Surgeries for Microtia/CAA/CEACS.

CAA usually occurs with microtia (see Fig. 208.1), although there are occasional cases without microtia. When associated with microtia, CAA reconstruction may be undertaken before, after, or in combination with microtia reconstruction. Most surgeons advocate for atresiaplasty after microtia reconstruction. Previous operations may compromise blood supply and decrease success of cartilage implantation.

In contrast, one group reported a series of early atresiaplasties followed by later microtia reconstruction using Medpor implants with temporoparietal flaps. Another group reported on 1460 ears that had canal wall-down atresiaplasty at the time of microtia reconstruction with rib graft, as a combined first stage of reconstruction.

Optimal age to begin microtia reconstruction is generally considered ≥7 years. Proponents for early reconstruction argue for minimizing psychologic trauma. Proponents for later reconstruction argue that better cosmetic results are obtained when rib cartilage is larger, and that older pediatric patients are more cooperative.

Proponents of early atresiaplasty contend that acquisition of binaural hearing, sound localization, and improved ability to hear sound in noise are beneficial. Proponents for late atresiaplasty believe the decision should be delayed until the patient understands risks.

For the occasional case of CAA without microtia and for isolated CEACS, atresiaplasty may be performed at ≥4 years if otitis media has resolved.

AEACA

In the early phase, aggressive cleaning and ototopical corticosteroid-antimicrobial drops control infection and minimize granulation tissue. Wicks help in the delivery of ototopical drops and act as a stent. Cultures are helpful. Active dermatitis does not provide a good environment for successful reconstruction.

Once mature fibrosis is present, CHL is the concern. Amplification is offered. An osseointegrated implant is considered for patients who decline atresiaplasty or are unable to use a conventional hearing aid.

OPERATIVE PERIOD

Anesthesia

General anesthesia required. Neuromuscular blockade contraindicated

Positioning

Since surgery may last 3 to 6 hours, padding must be used to avoid pressure sores.

Perioperative Antibiotic Prophylaxis

Antimicrobials are administered for *Staphylococcus* and *Pseudomonas* species.

Monitoring

Facial nerve monitoring required

Instruments and Equipment to Have Available

Tympanomastoidectomy set, ossiculoplasty prostheses, facial nerve stimulator, ototelescopes, laser, Silastic sheet, and Merocel (Mystic, Connecticut) packing should all be available.

Key Anatomic Landmarks

CAA

- The more anterior or toward the temporomandibular joint (TMJ) and superior (toward the dura) one drills, the safer it is because this area is usually furthest from the facial nerve. There may be multiple tiny pits or a vestige of the tympanic portion of the temporal bone (cribriform area) that are landmarks used to begin drilling.[4] Three-dimensional CT can help define the location to begin drilling.
- The middle fossa dura is a very useful landmark, but dural exposure is avoided. Drilling continues medially until the thin bony atretic plate and opening into the attic are identified. Entry is into the attic rather than middle ear to find the MIC. The fused MIC is usually partially fixed to the bony atretic plate (see Fig. 208.2).
- It is important to know whether (1) the MIC is large and positioned directly lateral to stapes rather than the normal anterolateral position; (2) the facial nerve is obstructing the OW; and (3) the facial nerve turns anterolateral and is at risk from anterior (lateral) surgical approach.
- Ideally, the EAC and bony annulus should be widened up to 15 mm; however, this is often limited by dura, TMJ, facial nerve, or mastoid air cells.

Prerequisite Skills

Extensive experience with tympanoplasty, mastoidectomy, ossicular reconstruction, stapedectomy, atresiaplasty, and some knowledge of microtia reconstruction is required.

Operative Risks

Injury to the dura, TMJ, and facial nerve must be avoided. Avoid drill trauma to ossicles during separation from and removal of the atretic plate.

Surgical Technique

CAA

- Atresiaplasty via canal wall-down mastoidectomy was advocated by earlier surgeons but fell out of favor due to poorer hearing results and possibility of mastoid cavity problems. Recently, acceptable hearing results with canal wall-down atresiaplasties have been reported (discussed later).
- A majority of surgeons favor the anterior (lateral) approach as described by Jahrsdoerfer. A postauricular incision is made, and the reconstructed auricle is elevated in the plane of the temporalis fascia. Care is taken to leave perichondrium on the auricular graft and to preserve its anterior blood supply. An incision is made through the temporalis fascia. Soft tissue is elevated and the zygomatic root, linea temporalis, and TMJ are identified.
- Drilling begins as described in the Key Anatomic Landmarks section provided previously. The middle fossa dura is a useful landmark. Drilling continues medially until the thin bony atretic plate and opening into the attic are identified. An angled telescope is used to identify ossicles through an opening in the atretic plate. The fused MIC is usually partially fixed to the bony atretic plate, and excessive drill energy may be transmitted. Diamond burs are used to thin the atretic plate to eggshell thickness, and then it is gently removed with picks and curets. When mobilizing a fixed ossicle, it is important to remove significant bone near the fixation site, lest new bone and fibrosis cause recurrent fixation. The CO_2 laser is very helpful for removal of bone. The MIC should be widely exposed (Fig. 208.3). Successful use of CT-based image guidance navigation for atresiaplasty has been reported.
- Ossicular anatomy is quite variable in CAA. In congenital CHL, the stapes may be fixed in 4% of cases. The full armamentarium of ossiculoplasty techniques may be required. If stapes surgery is required, it is preferable as a second stage procedure after complete healing.
- If the MIC is large and directly lateral to the stapes, it is more difficult to assess the mobility of the stapes and incudostapedial joint. In such cases, the MIC is left in situ and the temporalis fascia graft is placed directly over the MIC to create the TM.
- The EAC should be 15 mm in diameter; however, this is often limited by dura, TMJ, facial nerve, or mastoid air cells. Most reconstructed EACs undergo postoperative narrowing, especially at the meatus.
- Temporalis fascia is used to reconstruct the TM. A split-thickness skin graft is used to line the EAC. Jahrsdoerfer recommended placing a small disc of thick Silastic over

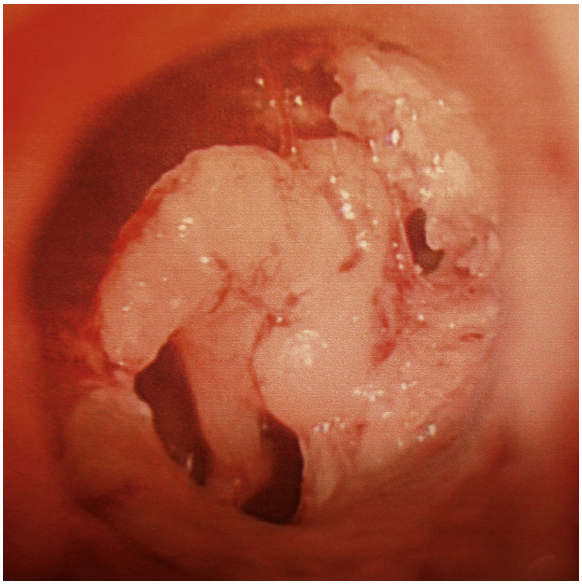

Fig. 208.3. View of malleus–incus complex during atresiaplasty.

the temporalis fascia graft and the partially overlapping skin graft to prevent lateralization (Fig. 208.4). Merocel packing coated with bacitracin is placed and expanded with ofloxin drops.

A large external auditory meatus is created by excising a disc of tissue from the reconstructed auricle after a pedicled skin flap has been preserved. The external auditory meatus and the bone of the EAC are beveled to create a smooth transition. The reconstructed auricle is then replaced in position. The skin graft is brought out through the external auditory meatus and sutured to the skin and flap from the meatus. More packing is placed.

Combined Microtia and Atresiaplasty

Surgeons have combined microtia reconstruction with atresiaplasty. Seigert developed a three-stage technique for complete reconstruction of microtia and CAA. Cho and Lee developed a two-stage microtia reconstruction with atresiaplasty. Yellon reported that atresiaplasty may be combined with tragal reconstruction following microtia reconstruction (Fig. 208.5).

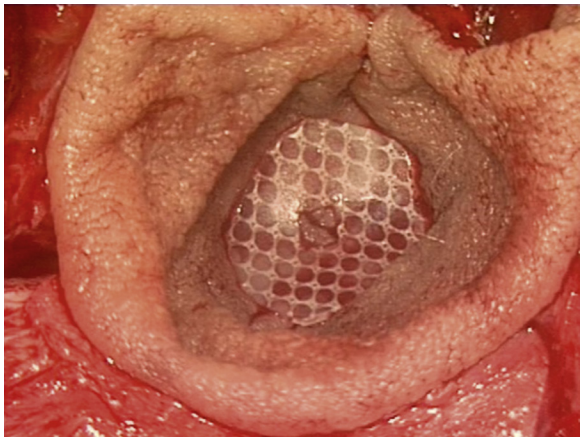

Fig. 208.4. External auditory canal lined with split-thickness skin graft and Silastic disc over temporalis fascia graft.



Fig. 208.5. Final result for reconstruction of microtia with rib grafts and atresiaplasty.

CEACS

For CEACS, the endaural approach as described by Lempert is preferred, although some recommend a postauricular approach. The first incision is in the incisura (between the root of helix and tragus). Externally, the incision is extended superiorly just anterior to the root of the helix. Temporalis fascia is harvested from this incision. In the superior EAC, this incision is extended medially just past the hair-bearing skin at the bony-cartilaginous junction. Anterior and posterior canal incisions are made from this point to create two triangular flaps that are back-elevated. Self-retaining retractors hold the flaps and improve exposure.

The tympanomeatal flap is elevated, and the TM is elevated from superior to inferior. In severe cases, the EAC is so narrow that drilling must be performed before the tympanomeatal flap can be injected with epinephrine and elevated. Canal cholesteatoma and bone erosion may be present. The bony EAC is drilled to enlarge it, while avoiding the dura, TMJ, and mastoid air cells. If a partial atretic plate is attached to the MIC, the plate is removed as for CAA, as described previously. Ossiculoplasty is performed if indicated. Removal of the partial atretic plate and enlargement of the bony annulus necessitates placing an underlay fascia graft to enlarge the hypoplastic TM.

If the area of exposed bone in the EAC is moderate, for example, 50% of the circumference of the EAC, then a thin full-thickness skin graft is used. If exposed bone is extensive/circumferential, then a split-thickness skin graft is required since full-thickness skin is too bulky.

The two lateral triangular flaps are thinned and replaced in the EAC. Merocel sponges are packed, as described previously.

AEACA

Goals of surgery are to remove the fibrosis, expose the TM, and re-epithelialize the EAC with healthy skin. After epinephrine injection, a circumferential incision is made at the junction of the normal medial EAC skin and the lateral aspect of the stenosis/atresia. A postauricular approach is performed for wide exposure and the auricle is elevated forward. Ear canal skin and fibrous tissue are elevated off the bony EAC. This dissection proceeds medially until the TM is identified. There is usually a plane between the EAC scar and the fibrous layer of the TM. The drill is used to enlarge the EAC in cases of bony atresia. The goal of canaloplasty is to view the entire TM through the external auditory meatus. Middle ear exploration is advised if preoperative CHL is >20 to 30 dB, expected for AEACA alone.

Generally, little skin can be salvaged from the canal because of fibrosis. Therefore, a skin graft is required, as described previously for CAA. The EAC is packed and managed as described for CAA.

Common Errors in Technique

CAA/CEACS

A planned anterior (lateral) approach may require conversion to a canal wall-down procedure due to drilling into mastoid air cells. Small openings are repaired with fascia and/or cartilage.

If no stapes can be identified intraoperatively, the procedure should be aborted.

Make sure that the surgeon's hands are braced during freeing the MIC from the atretic plate to avoid subluxation.

Make the EAC as wide as possible to decrease stenosis.

POSTOPERATIVE PERIOD

Postoperative Management

CAA/CEACS and AEACA

- The packing and Silastic are removed after 8 to 12 days. Ototopical antimicrobial/corticosteroid drops are used for 6 weeks.
- Infections should be suctioned, cultured, and treated aggressively with ototopical and oral/IV antimicrobials if indicated.
- The reconstructed EAC may require periodic débridement.

Complications

Complications of Atresiaplasty

- Following atresiaplasty, stenosis is the most common complication (0% to 25%) and most common indication for revision surgery. Triamcinolone injection into the meatus at surgery or subsequently may prevent or improve stenosis.[4] Lining the meatus with a pedicled full-thickness skin graft can decrease stenosis. Wicks, stents, and molds decrease or prevent stenosis and may be required for 6 months.
- Revision atresiaplasty for CHL may be required. In a systematic review, the average hearing gain for atresiaplasty was 24 dB (516 ears), while the average gain for percutaneous osseointegrated implants was 38 dB (100 ears).[5] The TM becomes lateralized and requires revision atresiaplasty for CHL in 0% to 18% of cases. Although cosmetically undesirable, BAHA/Ponto/Sophono surgeries are fast and generally have better hearing and less risk. However, the best possible outcome is an uncomplicated continuous excellent cosmetic and hearing result from atresiaplasty with no requirement for electronic devices.
- Facial nerve injury has been reported in 0% to 7% of cases. A higher incidence of injury was associated with a lower Jahrsdoerfer grading score, indicating less favorable anatomy. SNHL has been reported in 0% to 7.5%. It likely occurs from transmission of drill energy to ossicles during removal of the atretic plate. There is often only insignificant high frequency SNHL. Horizontal semicircular canal fenestration or labyrinthotomy is contraindicated and can cause SNHL.

Alternative Management Plan

Alternatives for Hearing Rehabilitation in CAA/CEACS/AEACA

- Nonsurgical Devices
  - See section "Preoperative Period."
- Implantable Hearing Aids in Children
  - Several types of implantable devices may be used for CAA/CEACS in children ≥5 years: percutaneous osseointegrated devices (BAHA, Ponto), transcutaneous osseointegrated magnet devices (Sophono, BAHA Attract), and active middle ear implant (Vibrant Soundbridge). In the United States, the minimum age for BAHA, Ponto, and Sophono is 5 years and 18 years for the Vibrant Soundbridge. In other countries, all are implanted at <5 years.
  - BAHA/Ponto/Sophono devices are useful for CAA with unfavorable anatomy, poor candidates for a lengthy surgery for medical reasons, or for families that desire improved hearing with less risk. In series of percutaneous BAHAs in children, severe cutaneous complications ranged from 9% to 37%, and loss of implant ranged from 14% to 26%. Transcutaneous magnet-based implants have a much lower complication rate.
  - The Bonebridge (Med-El, Innsbruck, Austria) is not yet approved in the United States and is usually too large for a child's atretic temporal bone.

Evidence-Based Medicine Question

Systematic review of the literature comparing atresiaplasty versus transcutaneous osseointegrated implants showed that the average hearing gain

a. for atresiaplasty was 38 dB
b. for atresiaplasty was 24 dB
c. for osseointegrated implants was 38 dB
d. for osseointegrated implants was 24 dB
e. b and c

Editorial Comment

The choice for surgery and type of surgery in CAA/CEACS/AEACA depends on the patient's age, hearing, severity of the middle ear/canal malformation, thickness of cortical bone, surgeon's experience, and the choice of the patient/family.

Eugene N. Myers

Access the review questions and additional source list online at http://www.expertconsult.com

REFERENCES

1. Jensen DR, Grames LM, Lieu JE. Effects of aural atresia on speech development and learning: retrospective analysis from a multidisciplinary craniofacial clinic. JAMA Otolaryngol Head Neck Surg 2013;139(8):797–802.
2. Yeakley J, Jahrsdoerfer RA. CT evaluation of congenital aural atresia: what the radiologist and surgeon need to know. J Comput Assist Tomogr 1996;20:724–731.
3. Dedhia K, Yellon RF, Branstetter BF, et al. Anatomic variants on computed tomography in congenital aural atresia. Otolaryngol Head Neck Surg 2012;147(2):323–328.
4. Jahrsdoerfer RA. Congenital atresia of the ear. Laryngoscope 1978;88(Suppl. 13):1.
5. Nasdaraja GS, Gurgel RK, Kim J, et al. Hearing outcomes of atresia surgery versus osseointegrated bone conduction device in patients with congenital aural atresia. Otol Neurotol 2013;34:1394–1399.

REVIEW QUESTIONS

1. In the Jahrsdoerfer grading system, the anatomic structure awarded two points is
   a. Large MIC
   b. Normal facial nerve
   c. Open round window
   d. Normal stapes

2. Complications of atresiaplasty include
   a. Facial nerve injury
   b. SNHL
   c. Meatal stenosis
   d. Persistent CHL
   e. All of the above

3. Disadvantages of percutaneous osseointegrated implants include all of the following except
   a. Severe skin problems
   b. Loss of implant
   c. Revision surgery
   d. Poor cosmesis
   e. Persistent CHL

4. Advantages of atresiaplasty include
   a. Fast surgery
   b. A chance for continuous excellent hearing
   c. Good cosmesis
   d. b and c

ADDITIONAL SOURCE

Yellon RF, Denoyelle F. Evaluation and management of congenital aural atresia. In: Flint PW, Haughey BH, Lund VJ, et al., editors. Cummings Otolaryngology Head and Neck Surgery. 6th ed. Philadelphia, PA: Elsevier Saunders; 2015. p. 3006–3018.

209 Otoplasty

Noel Jabbour

INTRODUCTION

Auricular deformities are quite common in the general population. Children with auricular deformities, particularly prominent ears, may be the subject of teasing by peers, which can affect psychosocial development, self-esteem, and school performance. In part, this may be due to how prominent ears draw the eye of the viewer away from the central face and eyes of the subject and toward the auricular deformity. In addition, in popular culture and political cartoons, prominent ears are often used to depict an individual with decreased intelligence.

Otoplasty represents a relatively simple surgical solution with potentially very gratifying results. One challenge for the novice surgeon is that more than 200 techniques have been described in the literature. The goal of corrective surgery is to restore the normal contours and dimensions of the auricle, symmetry, and degree of protrusion from the scalp. Proper analysis of the deformity preoperatively is essential to developing an appropriate surgical plan to optimize results and patient satisfaction.

KEY OPERATIVE LEARNING POINTS

1. Patients generally present with one or both of the following (Fig. 209.1):
   a. Underdevelopment of the antihelical fold
   b. Deep, overly projected conchal bowl
2. The surgical plan seeks to address the previous points by reconstituting an antihelical fold, excising excessive conchal cartilage, and creating a more acute conchomastoid angle (Fig. 209.2).

PREOPERATIVE PERIOD

History

1. History of present illness
   a. Most auricular deformities will have been present from birth, but it is important to elicit any changes in ear development or auricular trauma by asking: What did the ear(s) look like at birth? How has the ear changed since then?
   b. How bothered is your child by his or her ears? How is it affecting him or her in school or in daycare?
   c. Do you have any hearing concerns?
   Occasionally a child may present for consideration of otoplasty and may actually have grade I microtia or even aural atresia or external auditory canal stenosis. It is crucial to address hearing concerns.
   d. What are your goals for how the ear(s) would ideally look?
2. Past medical history
   a. Prior treatment: Did the child have any taping/splinting attempted in infancy? Has the child had any previous auricular surgeries?
   b. Medical illness: Does the child have known bleeding disorders?
   c. Surgery: Has the child had previous surgeries? Has he or she had any complications from surgery or anesthesia?
   d. Family history: Is there a family history of bleeding disorders, connective tissue disorders, or auricular deformities?
   e. Ask about medication exposures that may affect bleeding or wound healing, such as:
      1) Antiplatelet drugs
      2) Herbal products
      3) Smoking or smoke exposure

Physical Examination

1. Examination of the auricle: Careful examination and documentation of the auricular anatomy is crucial, including measurement of the auricular dimensions, projection, and degree of development of the conchal bowl and antihelix. Examination of the preauricular area may reveal accessory tragi or sinus tracks that may be addressed concurrently. Gentle pressure on the posterior-superior aspect of the helical rim may be used to recreate an antihelical fold and is useful in assessing preoperatively if this is sufficient to correct the deformity.[1]
2. Otoscopic examination
   Examination of the ears with an otoscope may rule out external auditory canal stenosis or atresia.
3. Facial symmetry
   Especially in unilateral cases of auricular deformity, the presence of facial asymmetry, hemipalatal paresis, or jaw discrepancy may indicate a need for further assessment for hemifacial microsomia.

Imaging

Imaging is not routinely necessary. Photo documentation is helpful for preoperative planning; potentially for insurance authorization and for medicolegal purposes.

Indications

1. Prominent ear deformity with desire to correct auricular proportions or projection
2. Realistic expectations for surgical outcome

Contraindications

1. Medical comorbidities with increased risk for general anesthesia
2. Significant, uncorrected bleeding disorder or nutritional deficiency that would increase risk for complication with wound healing
3. Unrealistic expectations or psychologic instability

Preoperative Preparation

1. Photo documentation with standard lateral, frontal, and oblique views. A bird's-eye view may be useful to assess conchomastoid angle discrepancies.
2. Discontinue antiplatelet drugs if possible.

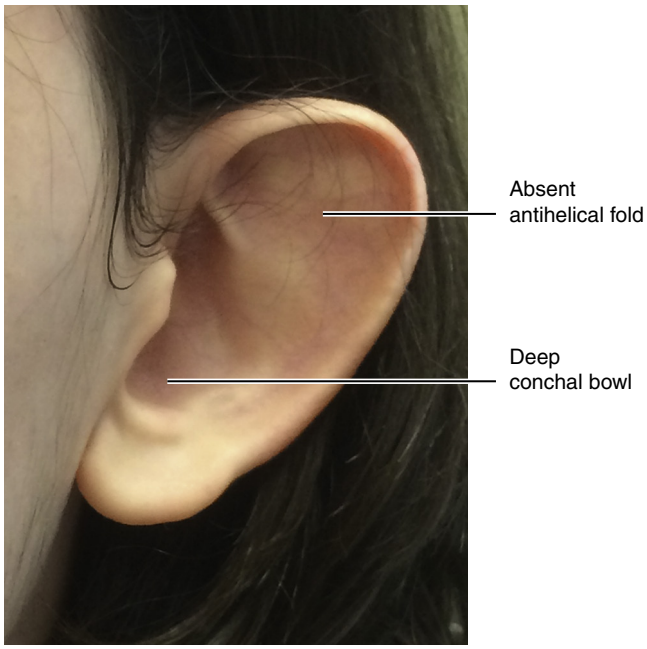

Fig. 209.1. Auricular deformity commonly seen in an otoplasty patient.



Fig. 209.2. Typical postoperative view of the auricle after addressing the underdeveloped antihelix and deep conchal bowl, with intentional overcorrection of antihelix.

3. Patients should be counseled on postoperative care and advised on realistic surgical outcomes, including that mild asymmetry of auricular shape and protrusion is natural and absolutely perfect symmetry is unrealistic.

OPERATIVE PERIOD

Anesthesia

General: Although this procedure can be done with local anesthesia in older children and adults, general anesthesia is preferred for patient comfort.

Positioning

Supine: The patient is positioned supine such that both ears may be viewed and accessed during the procedure.

Perioperative Antibiotic Prophylaxis

First-generation cephalosporin
Second-generation cephalosporin
Clindamycin if allergic to penicillin

Monitoring

Routine for general anesthesia

Instruments and Equipment to Have Available

1. Basic surgical set with fine instruments
2. Suture: 5-0 dyed nylon suture, 4-0 clear nylon suture, 4-0 Vicryl suture, 5-0 fast-absorbing suture, or similar

Key Anatomic Landmarks

1. Helix (Fig. 209.3)
2. Antihelix
3. Superior crus and inferior crus of antihelix
4. Scapha
5. Tragus
6. Antitragus
7. Cymba concha
8. Cavum concha
9. Postauricular sulcus

Prerequisite Skills

1. Soft tissue reconstruction techniques
2. Thorough knowledge of normal auricular anatomy

Operative Risks

1. Early complications:
   a. Seroma or hematoma
   b. Wound infection and/or breakdown
2. Late complications:
   a. Recurrence of deformity over time
   b. Asymmetry
   c. Scarring
   d. Other unsatisfactory cosmetic result due to telephone deformity, reverse telephone deformity, cartilage irregularities

Surgical Technique

- Prepare ear and inject proposed area of postauricular incision with 1% lidocaine with epinephrine 1:100,000 (Fig. 209.4).
- Excise postauricular skin—this may vary in size but a fusiform excision measuring no greater than 15 mm in width is often used; the excision is biased toward the posterior auricle so as not to obscure the postauricular sulcus.
- Dissect down to expose the postauricular perichondrium behind the antihelix.
- Use 5-0 nylon suture from anterior surface of ear to temporarily recreate the antihelical fold using temporary placed mattress sutures.[2]
- Cartilage scoring (optional)—Create vertical incision into proposed area of antithetical fold and develop a narrow subperichondrial pocket posteriorly in the proposed area

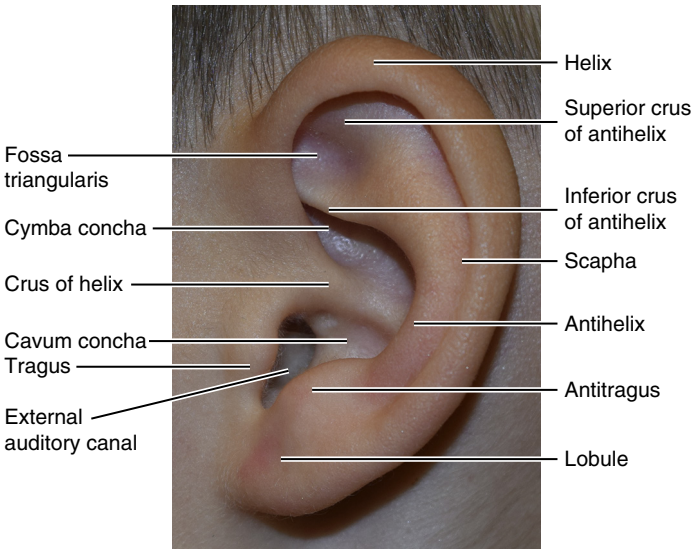

Fig. 209.3. Normal auricular anatomy.

of the antihelical fold. The pocket should be just wide enough to place the smallest rasp to score the cartilage. Alternatively, the beveled edge of an Adson-Brown tissue forceps may be used for cartilage scoring. Care should be made to ensure that all fragments of cartilage are suctioned or expressed out of the pocket.

- Place Mustardé sutures from postauricular approach. Full-thickness horizontal mattress sutures using 4-0 undyed nylon suture, or similar, from the postauricular approach to recreate the antihelical fold. These should be tightened up to and just past the point of creating a natural antihelical fold. Slight overcorrection is necessary to account for some relaxation of the fold with time (see Fig. 209.2). Overcorrection may create unnaturally sharp edges of the antihelical fold.
- Remove anteriorly placed dyed nylon sutures as each Mustardé suture is secured. Three Mustardé sutures are often used.
- One Mustardé suture may used in a similar fashion to recreate the superior crus of the antihelix if needed. Rarely, the inferior crus may need to be defined in a similar fashion.
- Address an excessively deep conchal bowl by excising a small fusiform strip of cartilage from the concha cavum, taking care to avoid injury to the crus of the helix and leaving the perichondrium and the skin of the external auditory canal intact.
- If needed, conchomastoid sutures may be placed in a radial fashion to prevent external auditory canal meatal stenosis. 4-0 clear nylon sutures, or similar, are placed in a mattress fashion from the posterior aspect of the conchal bowl to the premastoid fascia or periosteum. If this suture is placed too far posteriorly, the suture itself may be palpable or even visible and create tenting of the postauricular skin. Placing the sutures in a radial fashion is useful in preventing external auditory canal meatal stenosis.
- Close the deep layer of the incision with 4-0 Vicryl in an interrupted, buried fashion and the superficial layer with 5-0 plain or fast-absorbing suture, or similar.
- If the lobule seems to be overly protruding, a small M-plasty may be fashioned at the inferior aspect of the incision to address the lobule protrusion.
- Apply antibiotic ointment and nonadherent dressing to the incision, fluffs, and a lightly compressive dressing.

Common Errors in Technique

1. Excessive skin resection creating tight closure
2. Creating unnatural contours of the antihelix by overtightening the Mustardé sutures or leaving behind small fragments of cartilage after rasping
3. Undercorrection of lobule and superior aspect of auricle—telephone deformity
4. Overcorrection of lobule and superior aspect of auricle—reverse telephone deformity
5. Asymmetric correction

POSTOPERATIVE PERIOD

Postoperative Management

1. Wrap head to protect pinna. Should wear initial head-wrap until postoperative visit in 1 week. A less conspicuous head-wrap or headband may be worn thereafter for 2 to 3 weeks to maintain ear position during initial healing.
2. Pain medication: Patients should be expected to have mild pain after this operation. Acetaminophen or ibuprofen may be administered as first-line treatment for pain. Narcotic pain medication may be used for breakthrough pain. Pain beyond expectation in the early postoperative period may indicate a hematoma or early infection.
3. If using a replaceable head-wrap, such as a Glascock dressing, topical antibiotic ointment may be use on the incision for 3 days followed by Aquaphor ointment, thereafter.
4. Postoperative photodocumentation

Complications

1. Seroma or hematoma—may require needle aspiration or opening of incision for drainage
2. Wound infection and/or breakdown—Any purulence should be cultured and appropriate antibiotic management prescribed. A portion of the wound may need to be opened to allow for drainage and healing by secondary intention.
3. Recurrence of deformity over time—family should be preoperatively counseled regarding this risk and prevention may be achieved by overcorrection

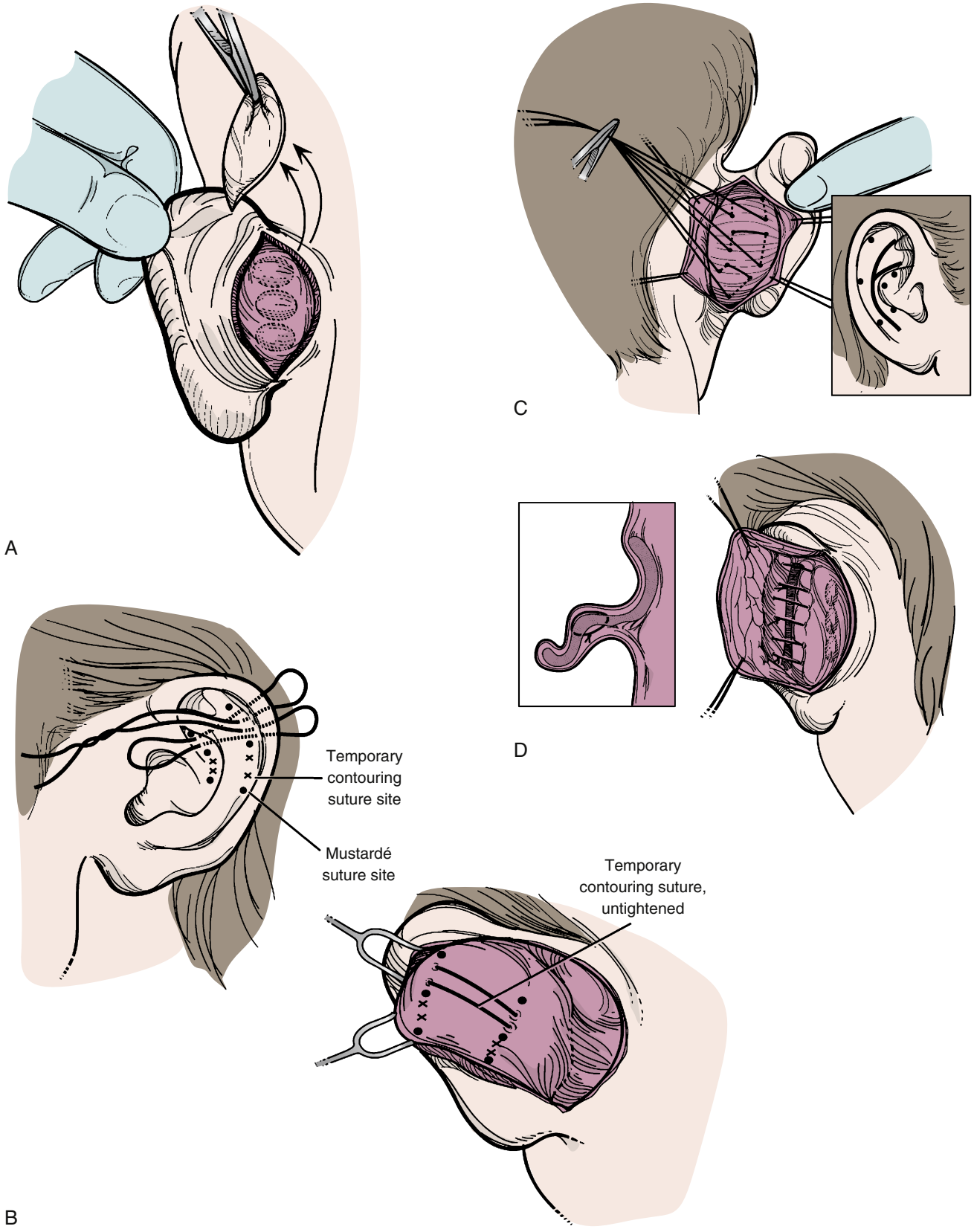

Fig. 209.4. Surgical steps, including excision of postauricular skin in fusiform fashion, **A,** placement of temporary contouring sutures, **B,** and placement of Mustardé horizontal mattress sutures from behind the ear, **C** and **D**.

4. Unsatisfactory cosmetic result—Realistic patient expectations coupled with a well-executed surgical plan are keys to prevention. Revision surgery is rarely needed but may be necessary in select cases.
5. External auditory canal meatal stenosis—Again, prevention is key by checking external auditory canal patency at the conclusion of the procedure and by placing conchomastoid sutures in a radial fashion. Intraoperatively, if there is concern for stenosis, despite these measures, a canal stent may be placed for 1 week and removed at the first postoperative visit. If stenosis does develop, auditory canal meatoplasty may be necessary.

Alternative Management Plan

1. Watchful waiting
2. Taping and/or molding if initiated in first 3 months of life
3. "Incisionless" otoplasty—detailed in references below

DISCUSSION

Evidence-Based Medicine Question

Should antibiotic prophylaxis be used routinely in otoplasty?

There is little evidence to support or to oppose the use of antibiotic prophylaxis routinely for otoplasty. The rate of postoperative wound infection is quite low in the literature. In 2009 a literature review of complications of otoplasty by Limandjaja et al.[3] demonstrated that few studies report the rate of infection or mention antibiotic prophylaxis. Of the 20 studies between 2000 and 2007 that met the inclusion criteria for review, only one mentioned a wound infection, with a rate of 3.5%; the wound infection rate in the remaining studies was 0%. Of the studies without a reported wound infection, only four explicitly described use of prophylactic antibiotics.

In 2004 a Cochrane review demonstrated that there is no strong evidence to support antibiotic prophylaxis in clean and clean-contaminated ear surgery.[4] Although this review is not specific to otoplasty, auricular reconstruction should be considered clean surgery so long as the ear canal is properly prepped. However, there is likely an underreporting bias in the literature, such that most complications in otoplasty are not reported. Thus, although evidence is limited to support its use, I do use cephalexin by mouth for 7 days following the procedure, in addition to bacitracin ointment on the incision for 3 days.

Editorial Comment

Otoplasty may be challenging techniquely for the surgeon but gratifying for the patient. It restores the natural shape of the ear to create an immediate physical change. Equally important is the psychological impact on a developing child.

This chapter outlines the essential operative techniques in otoplasty. Knowledge of the normal anatomic contours of the ear is crucial for the success of otoplasty.

Like many facial plastic surgery procedures, a variety of described methods exist to accomplish the same goal. A novice surgeon can be overwhelmed by various described techniques. The most significant variations are for marking the antihelix, for cartilage contouring, and for cartilage excision. In my practice, I mark the desired suture locations for the antihelix with needles placed on the anterior aspect of the pinna. Additionally, I tend to avoid any cartilage scoring or cartilage excision, if possible. Over the years, I have begun to slightly overcorrect the auricular deformity with the expectation that, over time, the ears tend to lateralize.

Patients should be pre-operatively counseled that the range of normal is quite broad with regard to the size, shape, and projection of the pinna. The method described above provides a sound approach to achieving the desired patient outcomes and creating a natural, reproducible appearance and symmetry between the ears.

David H. Chi

Access the review questions and additional sources list online at http://www.expertconsult.com



REFERENCES

1. Sie KC, Ou H. Otoplasty: an alternative approach to management of the deep conchal bowl. Laryngoscope 2006;116:2092–2094.
2. Hilger P, Khosh MM, Nishioka G, et al. Modification of the Mustardé otoplasty technique using temporary contouring sutures. Plast Reconstr Surg 1997;100(6):1585–1586.
3. Limandjaja GC, Breugem CC, Mink van der Molen AB, et al. Complications of otoplasty: a literature review. J Plast Reconstr Aesthet Surg 2009;62(1):19–27.
4. Verschuur HP, de Wever WW, van Benthem PP. Antibiotic prophylaxis in clean and clean-contaminated ear surgery. Cochrane Database Syst Rev 2004;3:CD003996.

REVIEW QUESTIONS

1. Early complications from otoplasty include all of the following, except
   a. Hematoma
   b. Wound infection
   c. Scarring
   d. Bleeding

2. Late complications of otoplasty include all of the following, except
   a. Scarring
   b. External auditory canal stenosis
   c. Recurrence of deformity
   d. Hearing loss

3. The most common deformities addressed in otoplasty for prominent ears include all of the following, except
   a. Underdevelopment of the cymba choncha
   b. Underdevelopment of the antihelical fold
   c. Overdevelopment of the cavum concha
   d. Obtuse conchomatoid angle

ADDITIONAL SOURCES

Matsueo K, Hirose T, Tomono T, et al. Nonsurgical correction of congenital auricular deformities in the early neonate: a preliminary report. Plast Reconstr Surg 1984;73(1):38–50.
This report discusses taping for nonsurgical correction of lop-ear, cup-ear, prominent ear, and Stahl's ear deformities.

Mehta S, Gantous A. Incisionless otoplasty: a reliable and replicable technique for the correction of prominauris. JAMA Facial Plast Surg 2014;16(6):414–418.
This report discusses the postoperative outcomes of 72 patients who underwent incisionless otoplasty. A video supplement demonstrating suture placement is available.

Fritsch MH. Incisionless otoplasty. Laryngoscope 1995;105(5 Pt 3 Suppl. 70):1–11.
This is the first report by Fritsch regarding "incisionless" otoplasty. Further reports by Fritsch from 2004 and 2009 may also be useful to review.