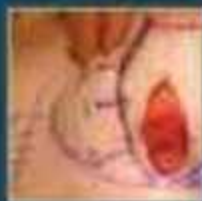
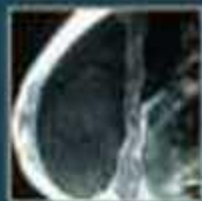
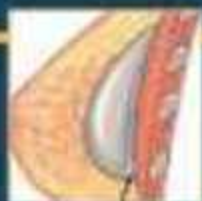


DENNIS C.
HAMMOND

ATLAS OF
AESTHETIC **BREAST**
SURGERY



SAUNDERS
ELSEVIER

SAUNDERS an imprint of Elsevier Inc.

© 2009, Elsevier Inc. All rights reserved.

First published 2009.

No part of this publication may be reproduced or transmitted in any form or by any means, electronic or mechanical, including photocopying, recording, or any information storage and retrieval system, without permission in writing from the publisher. Permissions may be sought directly from Elsevier's Rights Department: phone: (+1) 215 239 3804 (US) or (+44) 1865 843830 (UK); fax: (+44) 1865 853333; e-mail: healthpermissions@elsevier.com. You may also complete your request on-line via the Elsevier website at <http://www.elsevier.com/permissions>.

ISBN: 978-1-4160-3184-0

British Library Cataloguing in Publication Data

Hammond, Dennis C.

Atlas of aesthetic breast surgery

I. Mammoplasty

I. Title

618.1'90592

Library of Congress Cataloging in Publication Data

A catalog record for this book is available from the Library of Congress

Notice

Medical knowledge is constantly changing. Standard safety precautions must be followed, but as new research and clinical experience broaden our knowledge, changes in treatment and drug therapy may become necessary or appropriate. Readers are advised to check the most current product information provided by the manufacturer of each drug to be administered to verify the recommended dose, the method and duration of administration, and contraindications. It is the responsibility of the practitioner, relying on experience and knowledge of the patient, to determine dosages and the best treatment for each individual patient. Neither the Publisher nor the author assume any liability for any injury and/or damage to persons or property arising from this publication.

The Publisher

ELSEVIER

your source for books,
journals and multimedia
in the health sciences

www.elsevierhealth.com

Working together to grow
libraries in developing countries

www.elsevier.com | www.bookaid.org | www.sabre.org

ELSEVIER

BOOK AID
International

Sabre Foundation

The
Publisher's
policy is to use
paper manufactured
from sustainable forests

Printed in China

Last digit is the print number: 9 8 7 6 5 4 3 2 1

PREFACE

The material presented in this book represents strategies and techniques that I have either learned or developed over the past 15 years of building an aesthetic and reconstructive breast surgery practice. In aesthetic breast surgery, there is little room for long learning curves, and each of the procedures included in the book has allowed me to provide consistent aesthetic results with a minimum of complications. However, particularly with aesthetic breast surgery, there are frequently many different ways to achieve the same end, and it is important to recognize and embrace a healthy academic respect for these different approaches. Only then can the surgeon truly identify those variables that have the greatest effect on the final result and then understand how to manipulate those variables to maximal effect. With this in mind, I have attempted to differentiate between principles and preferences when it comes to performing aesthetic breast surgery. By recognizing this difference, each surgeon will be able to apply his or her own unique artistic flair to the task at hand and yet respect those variables that are common to all. For instance, a principle that must be respected in breast augmentation is to set and maintain the level of the inframammary fold. Once this is done, any of several different implants can provide an aesthetic result.

But perhaps more important than the fine details of each procedure is the basic approach to the task at hand of the operating

surgeon. A successful breast surgeon must be, to a greater or lesser degree, a perfectionist. Markings in preparation for surgery must be accurately applied in an unhurried fashion. There must be little bleeding and the operative field must be clean and uncluttered. Breast shape must be evaluated in the upright position. Whenever possible, it is highly advisable to tailor tack to create the optimal result before you cut. There must be no hesitancy to use sizers when needed to enhance the creation of symmetry in implant cases. And there must be a willingness on the part of the surgeon to retighten, resuspend or generally redo any aspect of the procedure as needed, with the ultimate goal being to create the finest result possible. Aesthetic breast surgery provides the surgeon the opportunity to artistically sculpt living tissue, and each breast must be approached with this in mind. It is a responsibility that must not be taken lightly as our patients deserve nothing less. It is my hope that the information contained in this book enhances your results and allows you to reach your full potential as an aesthetic breast surgeon.

Dennis C. Hammond M.D.
2008

DEDICATION

For my parents, James and Frieda Hammond; my wife Machelles; and my children, Rebecca, Sarah, and Andrew. Your love and support make everything possible.

ACKNOWLEDGEMENTS

I would be remiss if I did not recognize the contributions of all the people who have contributed in ways big and small to the creation of this book. From early on in my education, I was exposed to academic excellence and will always remember Fred Case and Robert Enzer, as they nurtured my interest in science and the human body. In medical school I was introduced to plastic surgery at the University of Michigan and had the opportunity to operate with Lou Argenta, Tom Stevenson, Reed Dingman, and Steve Mathes. Each of these men, by the power of their excitement for plastic surgery, convinced me that plastic surgery was to be my chosen profession. However it was left to John Beernink, the program director for the Plastic Surgery residency in Grand Rapids, Michigan to provide me the defining opportunity to become a plastic surgeon as he accepted me into the program in Grand Rapids. Dr. Beernink is a fine surgeon and a patient mentor, but he is an even finer person and role model. Although he will have none of it, I will always be indebted to him for making everything that has happened in my professional life possible. While the program in Grand Rapids prepared me well for the future, it was left to Pat Maxwell and Jack Fisher in Nashville, Tennessee to show me a glimpse of what can be achieved. As I completed a one year research/clinical fellowship with these two remarkable men, I was introduced to the finest that aesthetic and reconstructive breast surgery has to offer. To achieve outstanding results in surgery of the breast, you must first know what to aspire to, and these two men, each in their own way, defined for me what excellence in surgery should be. My year in Nashville was the finest, most invigorating, most inspiring year of my training life. It was a privilege to study and train with both of them and nearly every concept that is introduced in this book as well as any success I may have in my professional life can be traced back to my experience in Nashville. It is my great pleasure to count both of these men as my friends. As I continued my training at the Medical College of Wisconsin, completing a hand and microsurgery fellowship, I was introduced to the technical expertise and dedication of David Larson, Hani Matloub, Jim Sanger, and John Yousef. It was here that I gained the microsurgical expertise that would later help me deal with complex reconstructive problems of the breast with ease. Throughout this training process, I worked with some outstanding co-residents and fellows including Joe Mlakar, Bill Dwierzynski, Phil Sonderman, Tom Kinney, and my future partner Ron Ford. There is a special bond that forms with the people you train with, and I continue to follow with pride the careers of each of these fine men.

Nearly every successful plastic surgeon has a nurse/clinical coordinator/first assistant who makes everything else possible, and often times, this person becomes synonymous with the surgeon himself to all who know the inner workings of the practice. I am no exception and for me, there is one person who fills this role and has been with me from the time I began practice. Joanie Dowling has been my nurse, assistant, confidant, and friend over these past 15 years and there is nothing she does not know about plastic surgery of the breast. Words cannot express my admiration and appreciation for all she has done and continues to do to make me a better surgeon. As well, my practice could not run without my executive assistant, Marie Smith. Marie has also been with me from the beginning and I have seen her ever expanding role grow into managing several different clinical implant studies with seeming ease, keeping my academic calendar organized, getting me to and from meetings around the world safely and on time, and just about anything else I can think of. These two fine women have mastered the art of “taking a message to Garcia”. To the remaining long-time members of my staff, Jan Wabeke (a breast cancer survivor), Cheryl Lusby, Beth VanDam, and Becca Essing, I express my deepest thanks and I want you all to know you make up one of the finest plastic surgery offices in the world. I am a better surgeon thanks to your efforts.

Finally I wish to thank my wife and children for their patience, support and understanding. It is not easy being the wife, son or daughter of a plastic surgeon. As we all know, there are many long days, many late nights, and a seemingly endless number of scientific meetings. Events are missed, time passes, and yet I have been blessed with a supportive and loving family that allowed this book to be completed. Therefore, to my wonderful family, and all who played a role in making this book possible, let me say in the sincerest way possible, thank you.

Special Thanks

This book would not have been completed were it not for the gentle patience, constant cajoling, and expert guidance of Sue Hodgson and Ben Davie from Elsevier Publishers. It has been a pleasure to work with these two fine people and, largely as a result of their persistence and understanding, they deserve much of the credit for the completion of this book. I will be forever indebted to them.

FIGURE COURTESY LINES

The following figures are used Courtesy of Mentor Corporation ©: 3.3a–e

The following figures are used with permission from Hammond DC, Present Technology and Future Directions. Innovations in Plastic Surgery: Cohesive Gel Implants. 1(3):121–131, 2007. 3.23d–e

The following figures are used from Handel N, Silverstein M. Breast Cancer, 2nd edition, 2006, with kind permission of Walsworth Publishing Company: 5.36a–c, 5.36g, 5.36h, 5.36j, 5.36k, 5.36m & 5.36n

The following figures are used with permission from Hammond DC, Augmentation Mastopexy: General Considerations. In: Spear SL et al (eds), Surgery of the Breast: Principles and Art, 2nd edition, © Wolters-Kluwer 2006: 6.7a, 6.7b, 6.14a, 6.14c, 6.14e–i, 6.17a, 6.17e, 6.30a–d, 6.30g–m, 8.1a, 8.2a, 8.2b, 8.4b, 8.4d, 8.4e, 8.5a, 8.5c, 8.8a–e, 8.12a, 8.12b, 8.12f, 8.12g, 8.12h & 8.13a–f

The following figures are used with permission from *Can. J. Plast. Surg.* 2006; 14(1):37–40: 7.2a–c

The following figures are used with permission from Hammond DC, Short Scar Periareolar Inferior Pedicle Reduction (SPAIR) Mammoplasty. In Hamdi M, Hammond DC, Nahai F, Vertical Scar Mammoplasty, published 2005. With kind permission of Springer Science and Business Media: 8.7a & 8.7b

Applied Anatomy

General Considerations

When considering the anatomy of the breast as it relates to aesthetic breast surgery, it is helpful to distinguish between physiologic anatomy and structural anatomy. Physiologic anatomy relates to the arterial and venous supply, innervation and lymphatic drainage of the breast. Essentially, these are the anatomical features of the breast which must be respected and manipulated appropriately during the various types of aesthetic procedures described in this book. For instance, failure to adequately preserve arterial inflow to the nipple–areola complex (NAC) during a redo augmentation mastopexy can result in disastrous consequences with potential loss of this very important structure. For this reason, it is imperative that the informed aesthetic surgeon fully understand the various sources of innervation and vascular supply to the breast. Structural anatomy is inherently much more interesting. The support structure of the breast includes the parenchyma, fat, skin and, most importantly, the fascial architecture of the breast. When it comes to surgically manipulating the breast, understanding how these variables interrelate to one another can profoundly affect the quality and success of the overall result. Included in the structural anatomy of the breast is the underlying musculature. Although not part of the breast, the location and attachments of the pectoralis major and minor muscles and, to a lesser extent, the serratus anterior and the rectus abdominis can all affect the final result after aesthetic breast surgery as a result of the common practice of placing implants under these muscles. Understanding where these muscles are located in relation to the overlying breast can greatly facilitate their use and avoid implant malposition.

Embryology

The breast develops initially as a ventral ectodermal thickening along the so-called ‘milk line’ in mammals (Figure 1.1). Through a process of regression and maturation, discrete collections of nascent breast progenitor cells collect at specific sites along this milk line. This line extends from the axilla all the way down to the groin. Occasionally full regression fails to occur and ectopic breast formation outside of the usual location at the fourth intercostal space can develop anywhere along this line. Most commonly this is represented as an accessory nipple located at the left inframammary fold (Figure 1.2 A,B). Occasionally, a surprisingly well-formed rudimentary areola can form in association with the ectopic nipple (Figure 1.2 C). Also, it is not unusual for some women to undergo actual accessory breast parenchymal

development. This usually occurs in the axilla, either unilaterally or bilaterally, and may or may not be associated with an overlying nipple or areola rudiment. This tissue can actually enlarge during pregnancy to the point where surgical excision is desired once the post-gestational period is reached (Figure 1.3 A–D). Typically, however, the breast bud located at the fourth intercostal space eventually develops on each side into the mature breast. Development starts with the onset of puberty, usually around the age of 11 or 12, and variably continues through the teenage years. Generally speaking, initial primary breast growth is completed by the age of 18 to 20. Subsequent secondary changes in the size and shape of the breast then continue under the influence of a wide variety of causes including pregnancy, weight gain or loss, hormonal changes, aging and breast-feeding. The net result is that the breast undergoes an evolution of change in appearance over the life of a woman. It is important for the aesthetic surgeon to understand this evolution when surgical alterations in breast size or shape are considered. Certainly, how the breast looks today may not necessarily be how the breast looks in ten years.

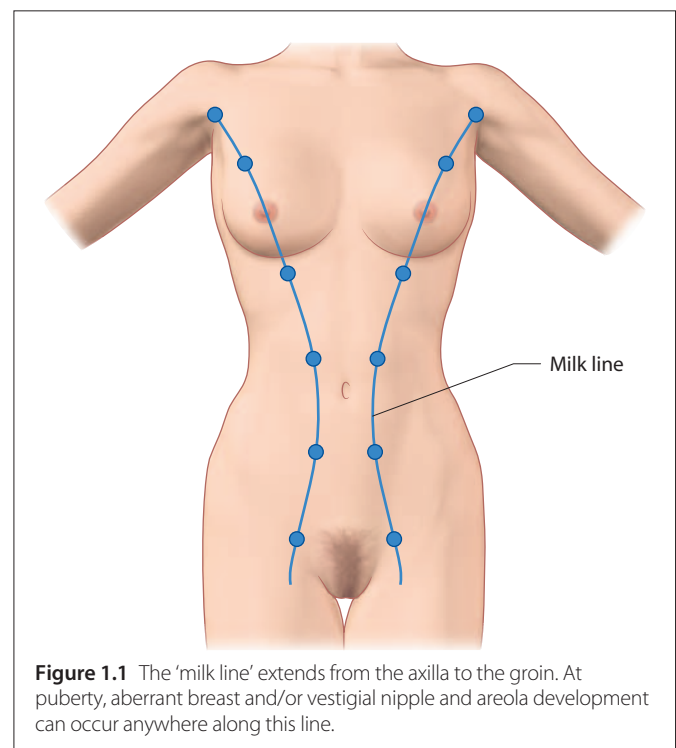


Figure 1.1 The ‘milk line’ extends from the axilla to the groin. At puberty, aberrant breast and/or vestigial nipple and areola development can occur anywhere along this line.

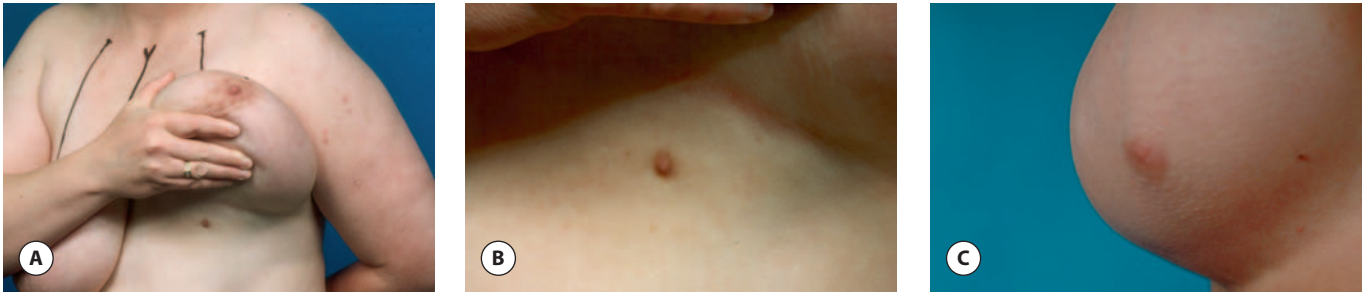

Figure 1.2 (A,B) An accessory nipple located just below left inframammary fold. (C) A rudimentary nipple and areola located on the breast just above the right inframammary fold along the embryonic 'milk line'.

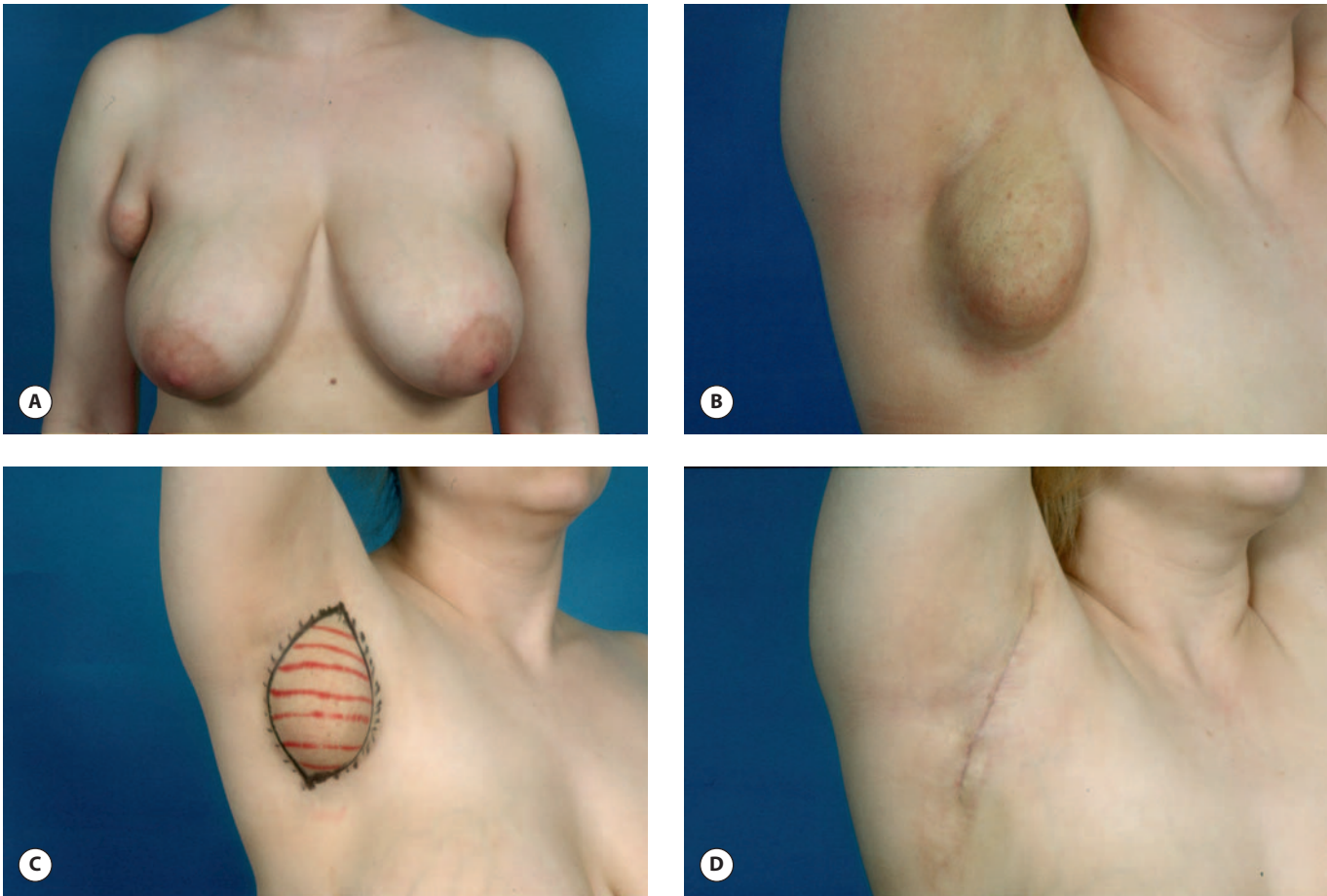


Figure 1.3 (A,B) Preoperative appearance of a woman with persistent unilateral aberrant axillary breast development after pregnancy. (C) The involved skin and underlying gland is marked for excision. (D) Final appearance after local excision of the involved tissue.

Understanding and, when possible, predicting these changes can greatly improve the results of aesthetic breast surgery.

Arterial Anatomy

Understanding of the arterial anatomy of the breast is enhanced when it is realized that this anatomy is in place and fixed before the breast even begins to develop. Essentially, it is the vascular anatomy of the chest wall. Then, as the breast begins to enlarge, the available arterial and venous supply simply grows with the breast. As a result, the blood supply of the breast is diffuse and

comes from a variety of potential sources including the internal thoracic artery via large anteriorly located intercostal perforators, the lateral thoracic artery, branches from the thoracoacromial axis through perforators running through the pectoralis major muscle, and anterior and posterior branches from the intercostal arteries, particularly branches from the 5th and 6th intercostal spaces (Figure 1.4). As a result, the breast can be accessed through many different incisions using a host of variably oriented pedicles and still have blood supply to the NAC preserved. Despite this diffuse blood supply, it is helpful to note that the dominant blood supply to the breast comes from the internal mammary system.

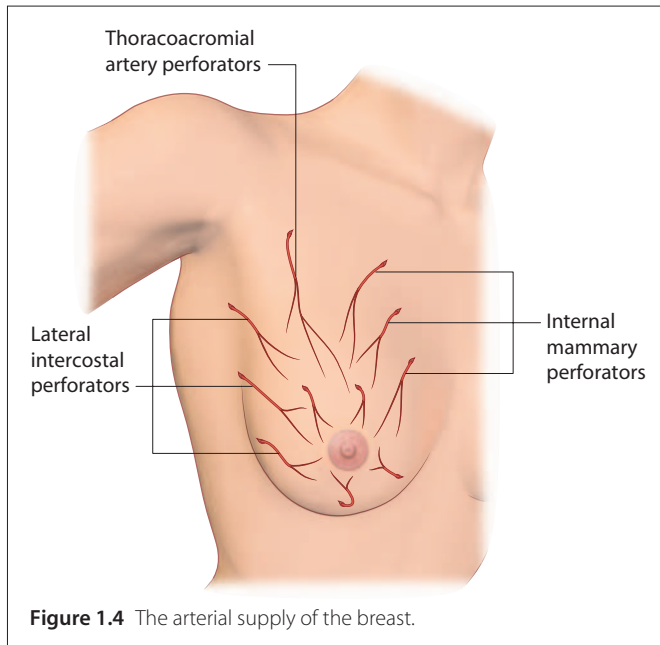


Figure 1.4 The arterial supply of the breast.

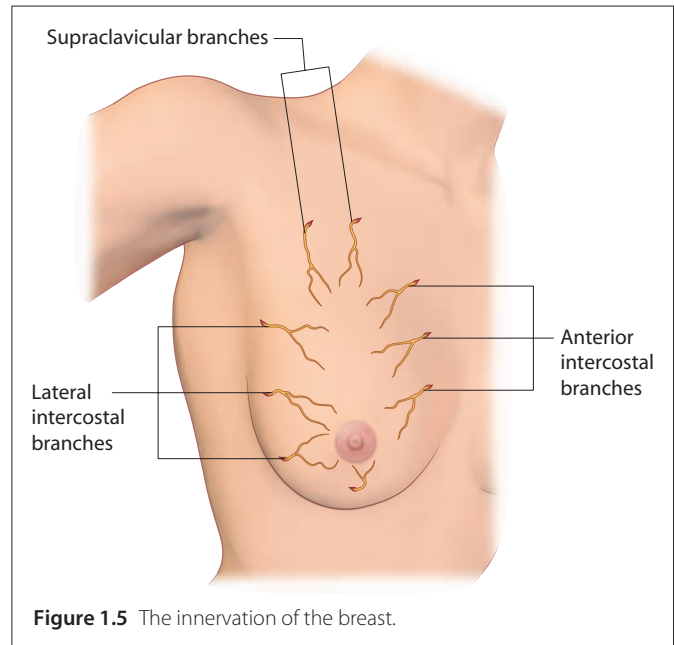


Figure 1.5 The innervation of the breast.

These perforators off the internal mammary have an impressive pressure head due to their proximity to the heart, as anyone who has done a free flap anastomosis to the internal mammary can attest. Also, the internal mammary perforators interconnect with all other vascular sources to the breast. For this reason, throughout this book, many of the described procedures will preserve the internal mammary perforators whenever possible. The versatility these vessels provide allows division of all other vascular sources without risk of tissue necrosis.

Venous Drainage

The patterns of venous drainage mirror the arterial inflow. However, the superficial venous system is well developed and, in some patients, can often be prominently visualized through the skin. During surgical procedures, preservation of this superficial venous network is performed whenever possible as this may prevent venous congestion postoperatively. It is important to note that patients who have a prominent superficial venous arcade preoperatively may experience a distressing increase in the prominence of these vessels after a procedure such as a breast augmentation. Discussing these types of issues preoperatively may head off disappointment after the procedure if patients are adequately informed ahead of time.

Lymphatic Drainage

The lymphatic drainage of the breast is also diffuse and variable. Traditionally recognized lymphatic basins include the axillary nodes as well as the nodes along the internal mammary vessels. Typically, while aesthetic breast procedures may interrupt some lymphatic channels in the breast, the drainage pattern is diffuse enough that there are essentially no untoward sequelae to lymph drainage of the breast after cosmetic breast surgery. Certainly, as opposed to reconstructive breast surgery, because the lymph nodes are left largely undisturbed by nearly any type of aesthetic

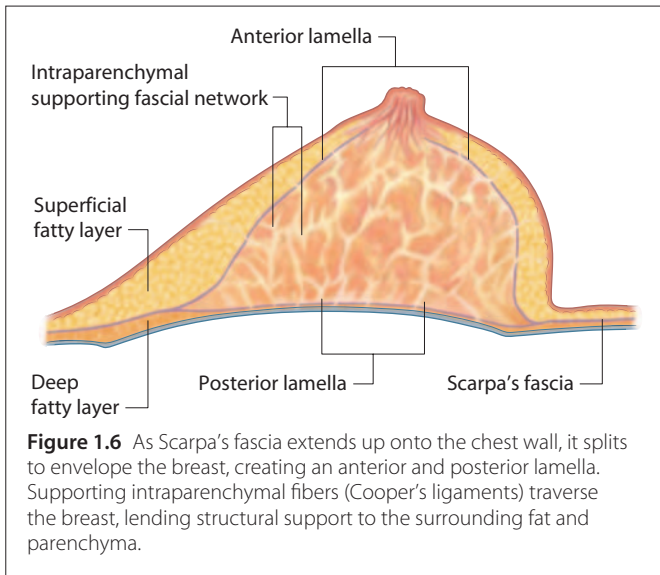
breast procedure, lymph flow proceeds unimpeded and does not become an issue postoperatively.

Innervation

In keeping with the tone set by the vascular supply to the breast, the innervation of the breast is also diffuse and variable. Multiple nerve branches from the lateral and anterior cutaneous branches of the 2nd through 6th intercostal nerves as well as the supraclavicular nerves enter and ramify within the breast (**Figure 1.5**). As for the all-important innervation to the NAC, the anterior and lateral branches of the intercostal nerves and, in particular, the lateral branch of the 4th intercostal nerve tend to ramify predominantly to the subareolar plexus, although lesser and variable contributions from other surrounding intercostal nerves also ramify to the area. Generally speaking, the contributions of the lateral branches are more significant than the smaller anterior branches. The location of the nerves within the breast varies as well. After passing through the intercostal spaces, the nerves ramify within the breast, sometimes passing along the deep fascia, sometimes passing superficially through the substance of the breast. Clearly, many of the various pedicle procedures for mastopexy and breast reduction will inevitably disrupt some nerve fibers. In addition, creating a pocket under the breast for the placement of an implant will also sever some nerve fibers. If possible, every effort should be made to avoid injury to the main anterior and lateral nerve branches as they pass through the intercostal spaces anteriorly and laterally and enter the breast. Once in the breast, inevitable severing of nerve fibers must be accepted as a consequence of surgically altering the breast.

Fascial Support Structure

The mature breast demonstrates both a superficial and a deep fascial support system. Essentially, the breast bud develops within Scarpa's fascia as it extends up onto the chest wall and the fascia



splits to form an anterior and posterior lamella. Anteriorly, this lamella serves as a dissection plane for many surgeons when performing a mastectomy. The posterior lamella separates the breast from the underlying pectoralis major muscle and serves as the plane of dissection for subglandular breast augmentation. Within the breast, between these two lamellae lie interdigitating connective tissue fibers extending throughout the breast (Cooper's ligaments), which contribute to the general support and shape of the breast (Figure 1.6).

While the interdigitating fascial network is diffusely distributed, there is a well-documented and distinct fascial septum that is oriented horizontally across the breast at approximately the level of the 5th rib. This septum roughly separates the breast into a superior two-thirds and an inferior one-third. The septum takes origin from the pectoral fascia and is associated with a well-defined vascular arcade which extends with the septum up to the NAC. On the cranial side of this septum lies a vascular network which takes origin from perforating branches of the thoracoacromial artery and a branch of the lateral thoracic artery. On the caudal side are perforating branches from the intercostal arteries. The varied and diffuse nerve supply to the breast also courses, at least partly, within this septum. As such, this fascial condensation forms a connective tissue mesentery along which passes an important source of neurovascular support to the breast and, in particular, the NAC (Figure 1.7). This septum was first described as an independent entity by Wuringer and colleagues and, in my view, their contribution remains as one of the most important tools yet described to allow meaningful understanding of the intraparenchymal vascular and structural anatomy of the breast. This septum is so distinct that Wuringer has been able to describe a breast reduction technique that bases the blood supply to the NAC on this intraparenchymal vascular mesentery. Although uniformly present in breasts with any degree of hypertrophy, the septum and its associated mesentery tend to be more distinct in thinner patients who exhibit more of a fibrous nature to their breast (Figure 1.8). In breasts with a greater fat content, and particularly in the obese, the septum becomes less readily identifiable. However, the principles of pedicle management that the presence of this septum mandates do not change, no matter how distinct it is. For instance, when using an inferior

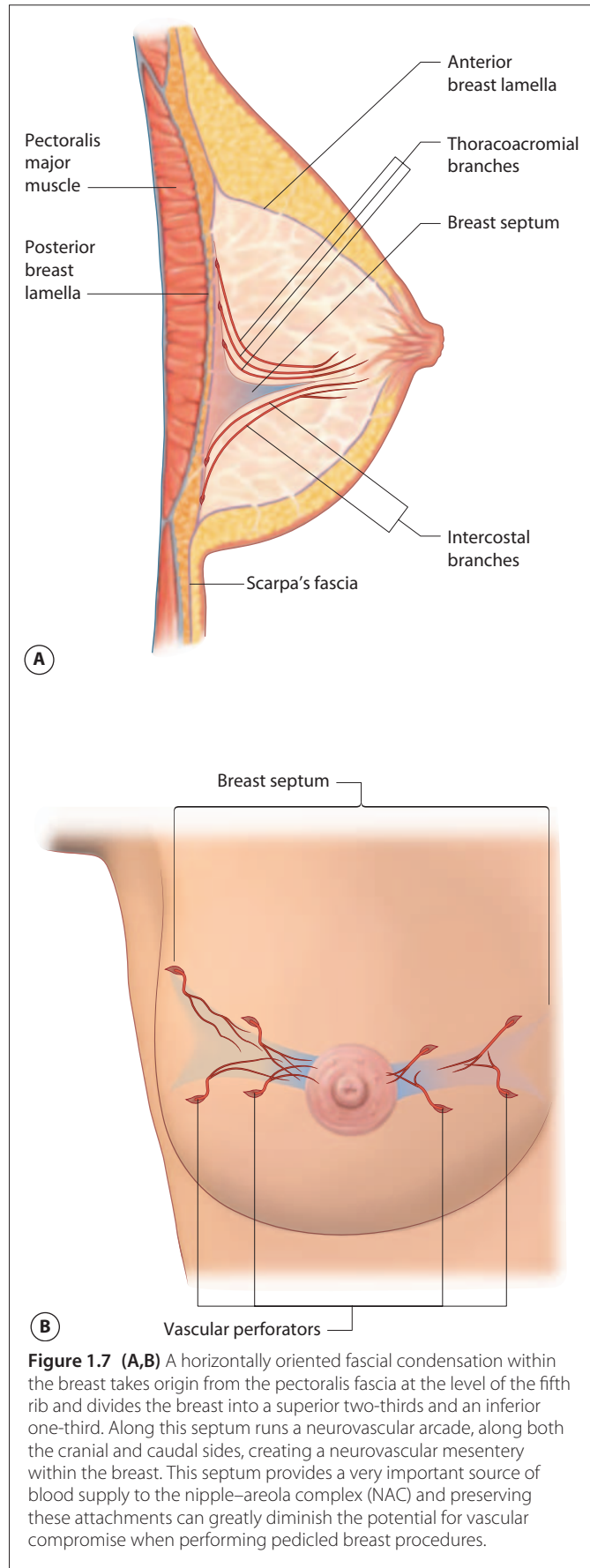

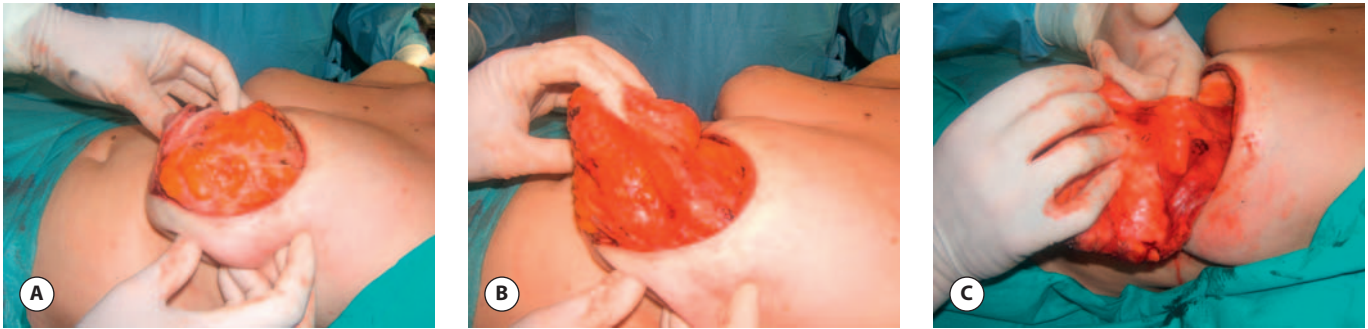


Figure 1.8 (A) Intraoperative appearance of patient undergoing an inferior pedicle breast reduction. The pedicle has been dissected free from the surrounding flaps and the superior, medial and lateral portions of the pedicle have been debrided to accomplish the reduction. (B) As the superior portion of the pedicle is lifted up, the breast septum can be visualized. The caudal septum remains intact and several large perforators can be seen running along the mesentery. The deep origin of the cephalad portion of the septum has been cut, which allows the superior end of

the inferior pedicle to rotate away from the chest wall. (C) The inferior portion of the inferior pedicle has been bluntly separated away from the caudal portion of the septum, allowing full visualization of the entire septal mesentery. Several perforating vessels can be seen running in the septum. Any inferior pedicle technique should optimally preserve this vascular and connective tissue support and excessive undermining of the pedicle is best avoided to ensure adequate vascular inflow to the tissues of the inferior pedicle and the nipple–areola complex (NAC).

pedicle technique to preserve the blood supply to the NAC, it becomes quite counterproductive to undermine the pedicle to such an extent that the caudal vascular sheet coming up into the pedicle becomes disrupted. The blood supply to the NAC at that point becomes based on dermal collateral flow, which can be less vigorous than the direct axial flow provided by the intercostal perforators running within the septal mesentery. Of course, as the length of the pedicle increases in larger breast reductions, preserving this vascular arcade becomes more critical in ensuring a viable NAC postoperatively. Although subtle, once I personally became aware of this anatomic relationship, I was able to locate it and respect the vascular pattern contained within the mesentery in every patient. It is interesting to postulate what effect inadvertent division of this breast septum may have had on previously reported instances of NAC ischemia after inferior pedicle breast reduction.

Understanding and identifying the subtle anatomical relationships noted at the level of the inframammary fold between the breast, Scarpa's fascia and the anterior and posterior lamellae is of infinite importance in successful aesthetic breast surgery as a stable and properly positioned inframammary fold is the foundation upon which all other breast manipulations are based. For this reason, it is important to manipulate this anatomy to optimal advantage. The superficial fat of the anterior abdominal wall is divided into two distinct fatty layers. The superficial layer of fat is thicker, dense and more compact than the thinner and more areolar deeper layer. These two fatty layers are separated by a well-defined fascial condensation called Scarpa's fascia (Figure 1.9). Along the inferior pole of the breast, Scarpa's fascia inserts into the lamellar framework of the breast where the anterior and posterior lamellae fuse. As the enlarging breast develops, the mass effect of the tissue located just superior to this fusion point folds over itself inferiorly to passively form the inframammary fold (Figure 1.10 A,B). When incisions are made in the inframammary fold during breast augmentation, there is a tendency to incise through Scarpa's fascia thus exposing the two fatty layers to forces from above in the form of the implant. Because the deep layer of fat is areolar and easily stretches open under the influence of any kind of force, any operative technique that opens this layer surgically can have the ultimate effect of inadvertently lowering the fold to a point lower than was initially

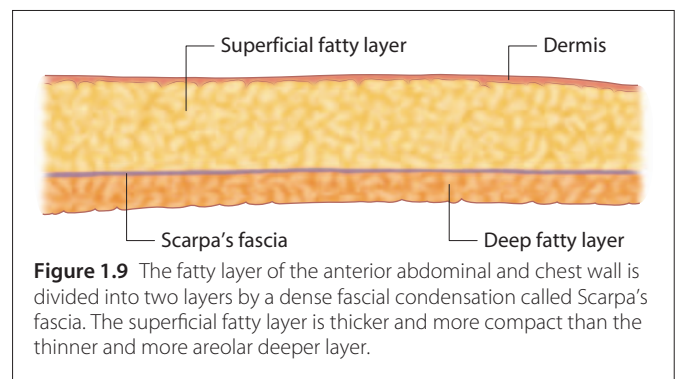


Figure 1.9 The fatty layer of the anterior abdominal and chest wall is divided into two layers by a dense fascial condensation called Scarpa's fascia. The superficial fatty layer is thicker and more compact than the thinner and more areolar deeper layer.

planned as the weight of the overlying implant forces the loose subscarpal space open over time. In essence, abdominal skin below the planned incision is incorporated into the new breast skin envelope. This unplanned expansion of the lower pole of the breast and the resulting inferior implant malposition can have a decidedly negative impact on the shape of the resulting breast (Figures 1.11, 1.12 A,B). Alternatively, accessing the underside of the breast on top of Scarpa's fascia protects the subscarpal space from potentially deforming pressure from above and, instead, any forces exerted by either implants or parenchyma are realized by the firmer and more compact superficial layer of fat, which is much less likely to give way. In this fashion, the location of the inframammary fold can be surgically positioned with greater confidence (Figures 1.13, 1.14 A,B). Incision strategies and fold management will be discussed in greater detail in subsequent chapters.

Parenchyma and Fat

The breast parenchyma and associated fat make up the bulk of the volume of the breast. The proportion that each contributes to this volume is subject to tremendous variability, not only between patients but also within the same patient, depending on any of the many variables which can effect the breast

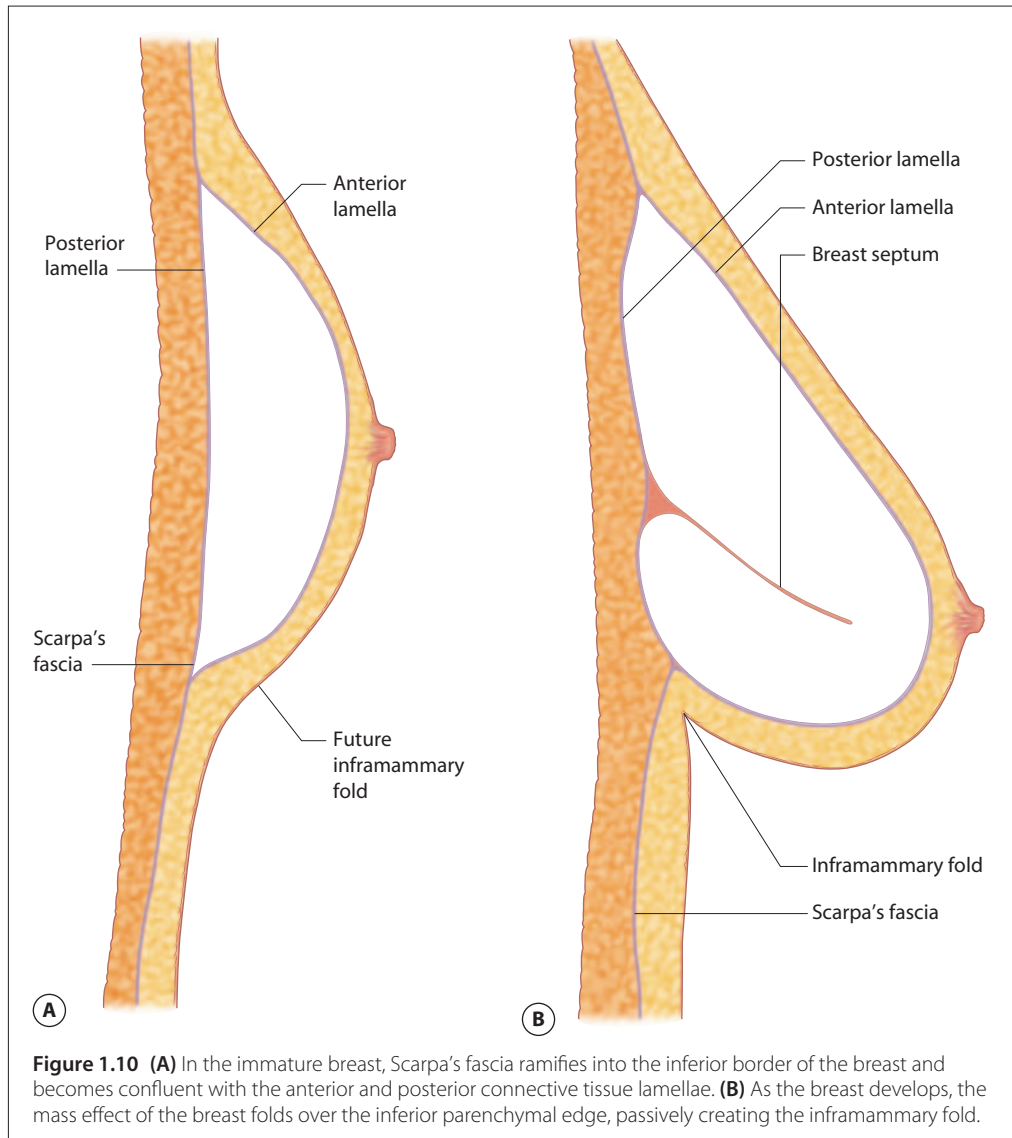


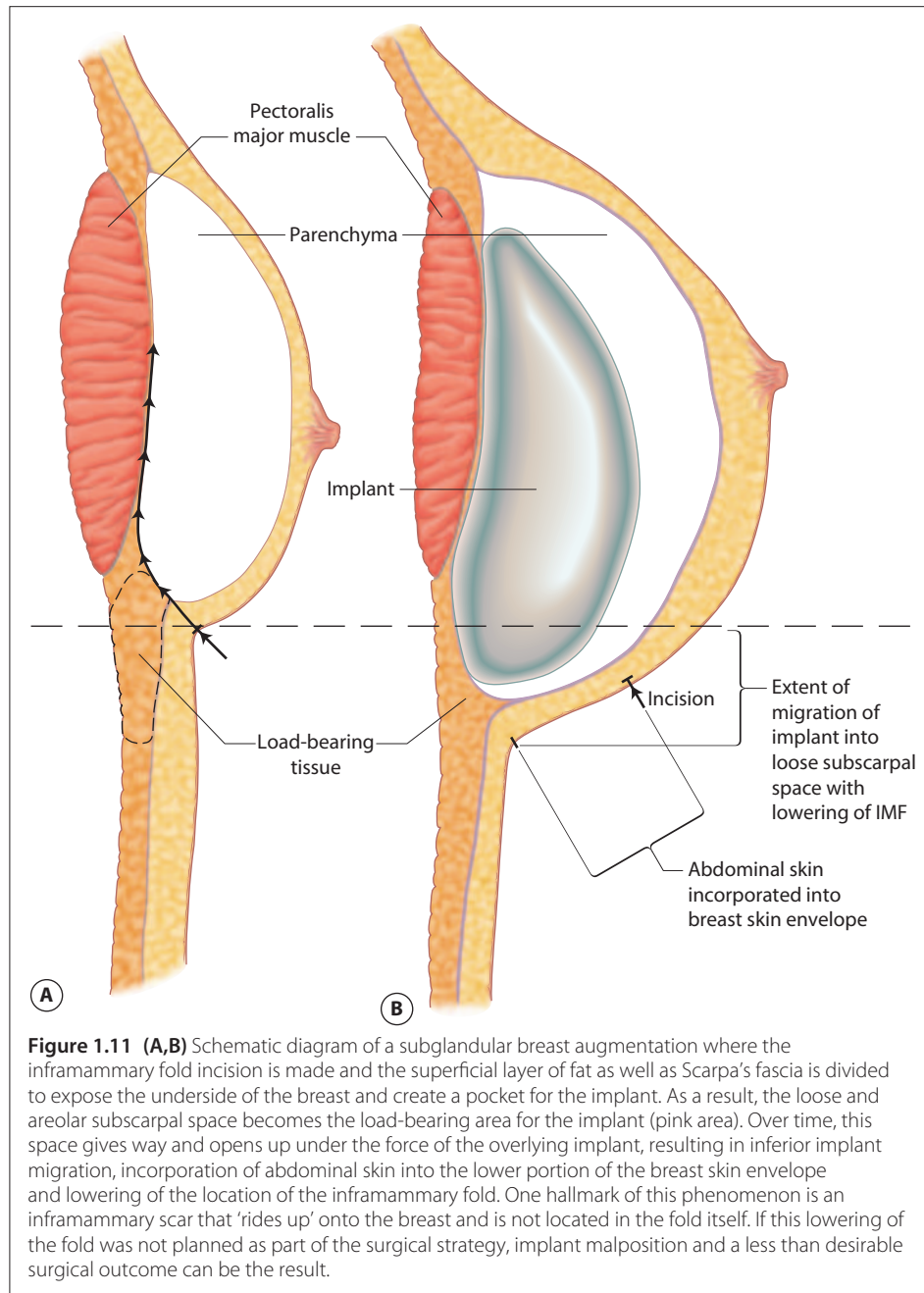
Figure 1.10 (A) In the immature breast, Scarpa's fascia ramifies into the inferior border of the breast and becomes confluent with the anterior and posterior connective tissue lamellae. (B) As the breast develops, the mass effect of the breast folds over the inferior parenchymal edge, passively creating the inframammary fold.

including age, weight, pregnancy, hormonal changes and genetics. Breasts that are particularly fibrous can be more difficult to sculpt surgically than predominantly fatty breasts. Also, not all fat is the same, as some patients have a blocky, firm consistency to their fat while others have a very loose and elastic texture to the fat. Preoperatively predicting what type of fat a patient has may impact what types of surgical maneuvers may be required to shape the breast appropriately, particularly in cases of mastopexy and reduction. For instance, patients with a firm, blocky fat will require greater precision in flap and pedicle development as their tissue will not mold together and conform as easily as a patient who has a looser and more elastic type of fat. Conversely, a patient with firmer fat may not need internal shaping sutures while the patient with a more elastic fatty consistency will often require internal parenchymal support to achieve the optimal result.

Skin

The skin of the breast can play a vital role in the outcome of any aesthetic breast procedure. As with other structures within the

breast, the character of the skin of the breast can vary dramatically from patient to patient. In youth, the skin of the breast often has a compact consistency, exhibits excellent rebound when stress is applied to it and, generally, provides firm support to the underlying parenchyma and fat, which contributes greatly to the uplifted appearance of the youthful breast. Then, as a result of many influences including genetic factors, advancing age, weight gain and pregnancy, the dynamics of the skin of the breast change. As the underlying breast enlarges, the overlying skin becomes thinned particularly around the NAC, loses its ability to rebound and cannot support the volume of the breast as before. With increasing size, stretch marks can develop and the breast becomes variably ptotic with loss of shape. Either due to an inferior location initially or due to fluctuations in the filling out of the skin envelope, the location of the NAC can appear low in relation to the breast mound. Perhaps more importantly, after surgical alteration of the breast, the tendency for the breast skin to stretch seems to increase in many patients. This observation is easy to understand in light of the fact that during many aesthetic breast procedures the internal support structure



of the breast is variably released. When this is coupled with any procedure which increases the volume of the breast, as in breast augmentation, it is understandable that the breast skin could stretch. Properly assessing the quality of the breast skin as well as the surface area of the skin envelope in relation to the underlying volume becomes quite important when designing a surgical strategy to improve the aesthetics of the breast. Accurately judging how the skin will react to an underlying force such as a breast implant or repositioned breast parenchyma can greatly impact the long-term aesthetic result. Generally speaking, any aesthetic procedure which places undue reliance on the skin envelope of the breast to provide shape will eventually fail. It is far more reliable to provide a stable inner breast support

structure and then allow the skin to simply redrape around the surgically created mound.

Muscles

From an aesthetic standpoint, the muscles of the chest wall are important in breast surgery for two reasons. First, perforators from the main feeding vessels of the chest wall travel through the muscles to supply the breast. Therefore, for instance, the pectoralis major serves as a conduit for many perforators to enter the breast from the thoracoacromial system. Secondly and perhaps more importantly, breast implants are commonly placed under these chest wall muscles. Therefore, the location

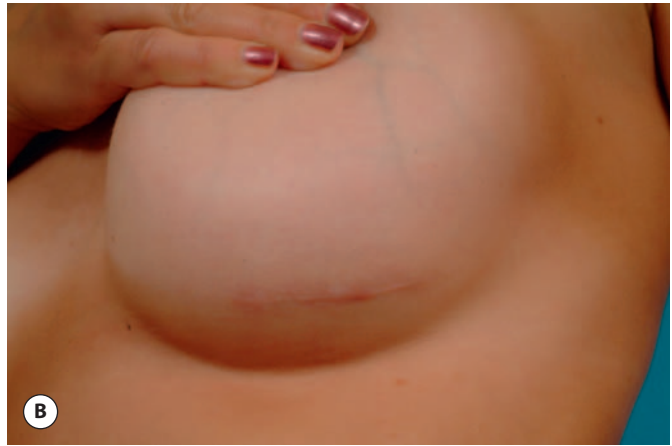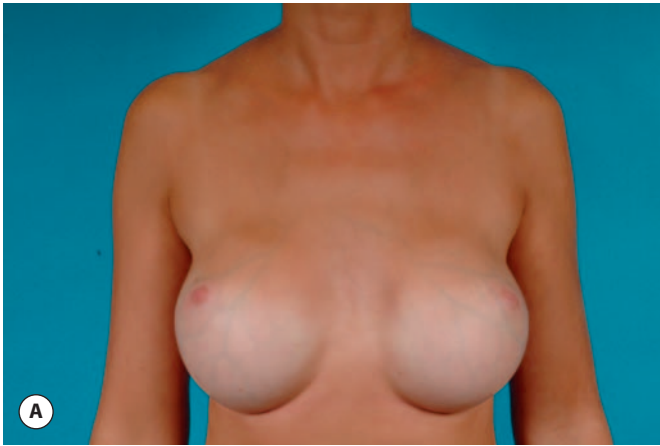


Figure 1.12 (A,B) Appearance of a patient after breast augmentation with loss of the inframammary fold in association with inferior implant malposition. Note that the incision has migrated up onto the lower breast

as abdominal wall skin has been recruited to become part of the breast skin envelope.

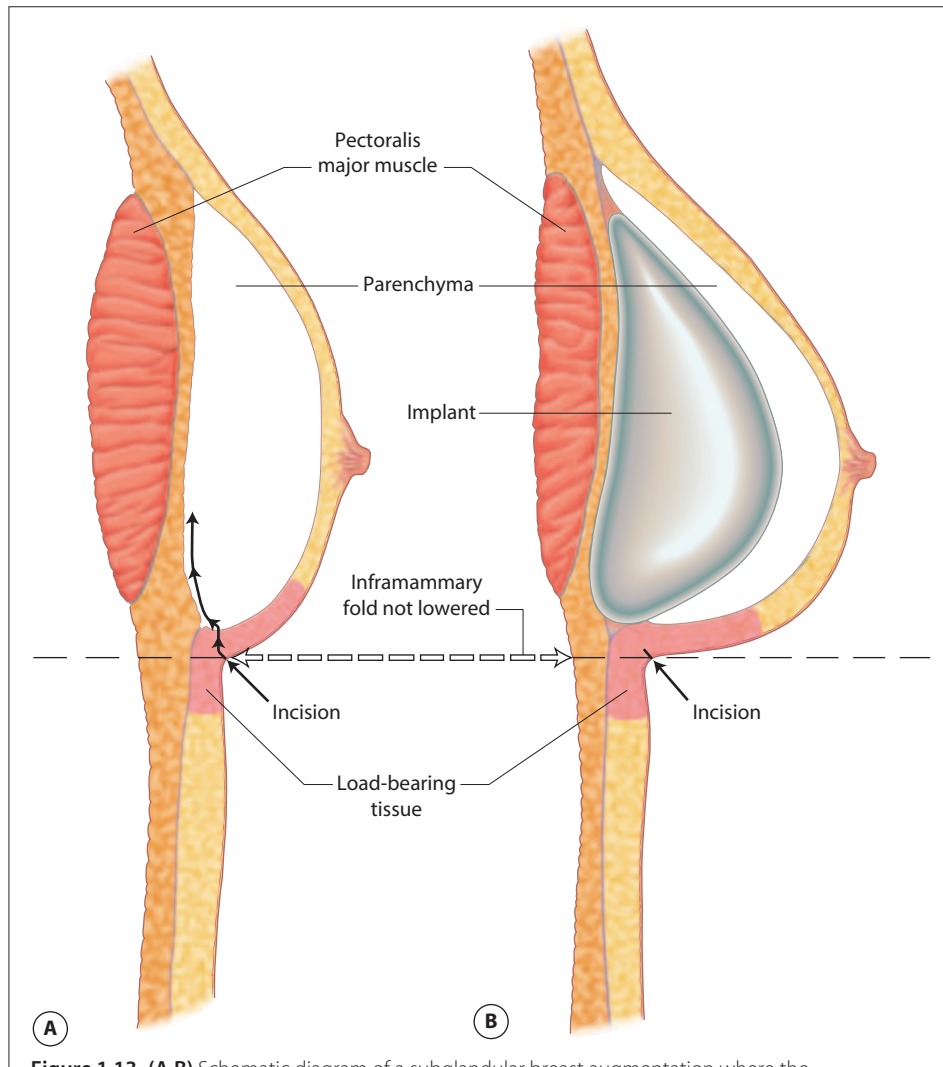


Figure 1.13 (A,B) Schematic diagram of a subglandular breast augmentation where the inframammary fold incision is made, and Scarpa's fascia is preserved. Dissection proceeds on top of Scarpa's fascia until the underside of the breast is reached, where the pocket is then developed. In this fashion, the loose subscarpal space is never opened up and the firmer and more dense superficial layer of fat becomes the load-bearing tissue for the implant (pink area). This tissue is better able to withstand the force applied to it by the overlying implant and is resistant to stretch. In this way, the implant remains properly positioned and the fold is not lowered. As a consequence, the resulting inframammary fold scar stays in the fold and does not ride up onto the breast.

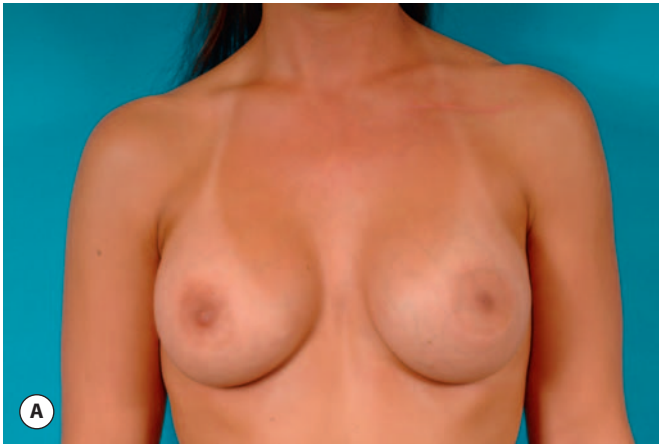
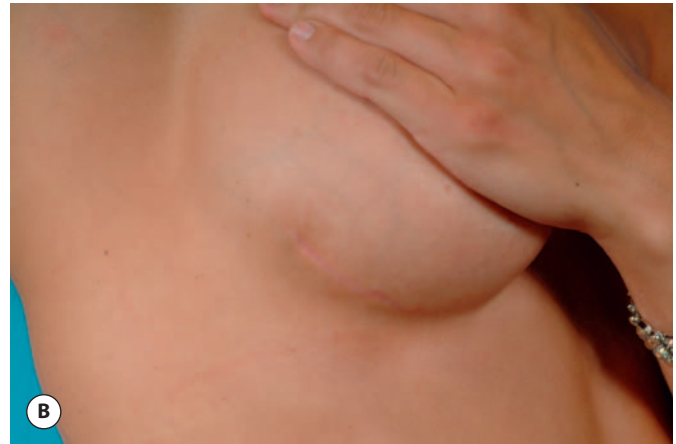

Figure 1.14 (A,B) Appearance of a patient after subglandular breast augmentation with preservation of the fold as described. Note that the



implant remains properly positioned and, as a result, the scar remains directly in the fold.

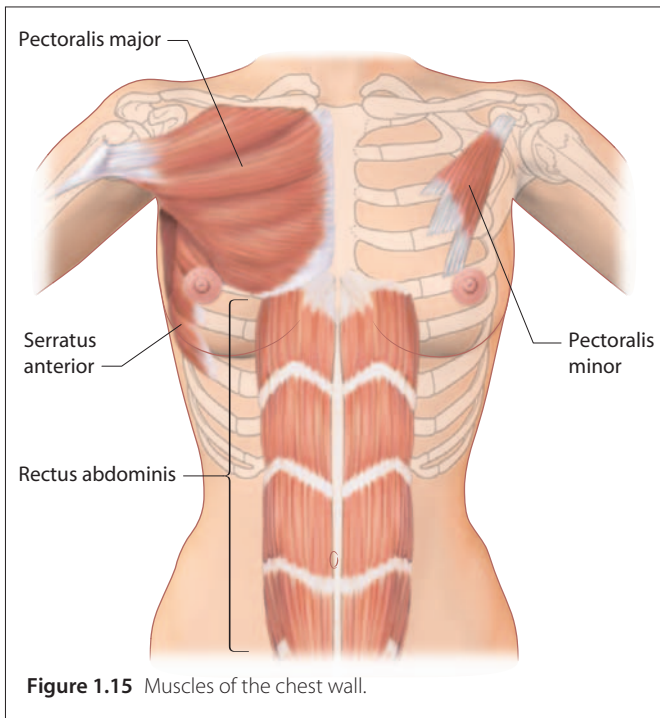


Figure 1.15 Muscles of the chest wall.

of these muscles in relation to the overlying breast becomes very important in determining the shape of the surgically altered breast (**Figure 1.15**). Although several chest wall muscles support the upper torso, the muscle which impacts most directly on the breast is the pectoralis major. This muscle takes origin from a wide attachment along the inner sternal area and this origin

extends from the medial clavicle, down along the entire lateral sternal border and then variably onto the lower medial cartilages of ribs 6 and 7. Occasionally, the origin can extend down to the rectus abdominus fascia and the upper fibers of the external oblique muscle. Additionally, there are accessory fibers of origin which extend from the underside of the muscle and connect to the anterior bony surfaces of ribs 4 through 6. Vascular perforators from the intercostal system often accompany these accessory muscle origins. As a result, a wide area of origin for the pectoralis major is present and this area can cover as much as the medial fourth of the overlying breast contour. Recognizing this wide area of origin is very important when making a subpectoral pocket for breast augmentation and this anatomy will be discussed further in subsequent chapters. From this wide area of origin, the fibers converge into a thick tendon which inserts in a spiral fashion into the intertubercular groove of the humerus.

The blood supply to the pectoralis major muscle is diffuse, with the most direct named vessel being the thoracoacromial artery, although other branches enter the muscle via perforators from the internal mammary artery and anterior and lateral perforators from the intercostal arteries. Nerve supply to the pectoralis major comes from the medial and lateral pectoral nerves, which are named for the cord of origin in the brachial plexus rather than the anatomic location of the branches. The medial pectoral nerve courses through the pectoralis minor muscle to innervate the lateral and lower fibers of the pectoralis major muscle. This nerve is commonly encountered during the creation of a subpectoral breast pocket as it is typically seen running from the pectoralis minor up into the pectoralis major. The lateral pectoral nerve courses medial to the pectoralis minor muscle and enters the underside of the pectoralis major to provide innervation for the upper and medial portion of the muscle.

Summary

The eventual objective of the aesthetic breast surgeon is to manipulate the structural anatomy of the breast to create the desired result while, at the same time, respecting and preserving the functional anatomy. The focus of the remainder of this

book will be to describe how this can be optimally achieved to maximize the aesthetic result and minimize any potential complications.

Optimizing Success in Aesthetic Breast Surgery

General Concepts

In many respects, quality breast surgery is as much a product of intelligent preoperative preparation and planning as it is sound technical skill. In fact, much of the most useful information that hopefully will come from this book will be contained in this chapter. As I have built my breast practice over the years, a pattern for success has emerged that has improved my personal results in both aesthetic and reconstructive breast surgery. This approach has made these results more consistent and helped tremendously in holding complications to a minimum. This approach can be divided into preoperative and intraoperative considerations.

Preoperative Considerations

The specifics of the standard preoperative consultation for each aesthetic breast procedure covered in this book will be addressed in the appropriate chapters. However, for all breast procedures, a preoperative office appointment 1–3 days before the actual procedure is performed is highly recommended. For a Monday surgery, this appointment takes place either Thursday or preferably Friday. At this appointment, the procedure is reviewed in detail and the goals and expectations of the patient are once again confirmed. If there was any question as to the exact nature of the procedure to be performed, these uncertainties are eliminated as much as possible and final decisions concerning breast implant size, bra cup size, incision location or implant position are determined. If there are variables or unknowns related to a specific portion of the procedure, these are once again reviewed and how these unknowns will be handled at the time of surgery are decided upon. One example of this relates to the inframammary fold. After total capsulectomy, the fold sometimes drops, which necessitates suture plication to provide symmetry with the opposite breast. This is notoriously an unpredictable and difficult undertaking and a certain percentage of patients will require a revisionary procedure to obtain the best result. While covered during the initial consult, these limitations are best stressed again at this preoperative visit to remind the patient of what the important considerations are for a specific procedure and how problems will be managed. If, in fact, complications do occur, the patient will be better educated and have a greater understanding of her condition if the case is managed in this proactive fashion. Attempting to explain complications after the fact is tolerated only by the most realistic of patients and can result in great medicolegal risk for the treating physician, even in cases where true malpractice is not even remotely an issue.

In addition to issues which fall into the category of appropriate informed consent, basic procedural matters are efficiently and easily managed at this visit. All required paperwork can be completed at this time, including history and physical completion, writing of the operative note and postoperative orders, reviewing the appropriate procedure-related preprinted discharge instruction sheets and filling out prescriptions for antibiotics and analgesics as indicated. Arrangements for postoperative follow-up can also be made, understanding that specific times and dates may change. Such an organized approach, while somewhat labor intensive on the front end, pays significant dividends later on. Most importantly, many potential postoperative problems are eliminated because they will have been managed ahead of time. Issues such as antibiotic allergies or analgesic intolerances can be addressed at this time rather than later over the phone with nurses or pharmacists. On-call responsibilities are greatly minimized, which eliminates over-the-phone decision making. Perhaps most importantly, patient confidence in the entire process is greatly facilitated, which creates the best environment for postoperative management. All of the above enhance overall patient safety and reduce the potential for complications.

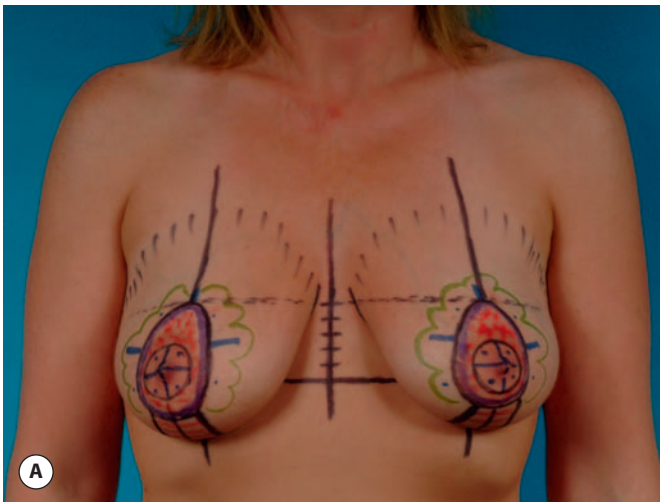
The second major goal of the preoperative visit is technical and relates to patient marking. As opposed to the often harried environment which is present in the hospital or surgical center, marking in the office allows the surgeon to apply all his or her energies to the task at hand in a quiet, controlled environment without interruption by anesthesia staff or nurses. All marking supplies will be readily available and experienced nursing staff assistance is assured. Marking done in conjunction with the administrative functions described previously assures that all issues will be addressed and greatly minimizes the potential for either significant or insignificant errors. Standard ‘permanent ink’ skin markers are used to identify pertinent landmarks as the patient stands upright in a relaxed position. Various multi-colored packs of markers are available, with my personal preference being the ‘Sharpie’ brand, which offers up to 24 different colors (Figure 2.1). Besides the standard black and red, various other colors can be used to signify the particular surgical steps to be undertaken. For instance, areas of skin to be resected can be designated one color and areas where undermining is to be performed can be outlined in another. Any color scheme is appropriate and when this scheme is applied uniformly from patient to patient, the accuracy of the preoperative plan becomes enhanced. Essentially, the entire operative sequence is performed in the surgeon’s mind’s eye during the marking procedure with the marks documenting the surgical steps. In my opinion, the more detailed the marking pattern, the better the likelihood the proposed surgical procedure will be successful (Figure 2.2 A,B).

One additional device which is quite useful is a standard laser leveler, which is available at most hardware stores. By dimming the lights and using the red laser light to reveal the true horizontal plane across the chest, accurate placement of important breast landmarks such as the top of the areola can be assured. Using this device can be very helpful, particularly in patients with preoperative asymmetries, where landmarks can be sometimes difficult to identify correctly and symmetrically (Figure 2.3 A,B).

At this point, it is very important to note the patient's natural shoulder position. Many patients will have an asymmetry in their shoulder level, which affects the position of the breast when the shoulder is artificially raised or lowered (Figure 2.4). This asymmetry must be replicated during surgery when the patient is placed upright on the operative table to allow accurate intraoperative assessment of important landmarks such as the location of the nipple and areola or the level of the inframammary fold. Another important yet subtle maneuver to perform is



Figure 2.1 Multicolored 'Sharpie' markers allow versatility and accuracy in designing and documenting a preoperative surgical plan.



the 'arm abduction test'. Here, the patient slowly raises her arms up from the sides to a position extending straight out from the torso at 90 degrees. As this is done, the effect of this position on the shape and position of the breast is noted. In some patients, no significant change in breast shape occurs and it is perfectly acceptable to position the arms at 90 degrees on armboards at the time of surgery. However, in some patients, the breast begins to become distorted in some fashion at about 45 degrees and worsens with continued arm abduction (Figure 2.5 A-C) (DVD clips 1.02, 1.03). In these patients, it is important to position the arms on armboards during surgery at no more than 45 degrees in order to assure the most accurate intraoperative assessment of breast shape that can be obtained (Figure 2.6 A,B). This may necessitate working above the arm in some cases but is well worth the effort to afford the most control over the final result.

Once the marks have been made, it is very important to obtain photographs which clearly document the preoperative plan. One of the greatest teaching tools a plastic surgeon can provide to ensure steady improvement as his or her practice matures is a photograph of the preoperative marks. Not only can these images provide useful medicolegal documentation, but also they can serve as effective visual reminders to support the operative note once the result has matured over a prolonged period of time. When examining the patient after full healing has occurred, often many months to a year may have elapsed. These photographs can be used to correlate decisions made at the time of surgery with their long-term result. Such information is vital to the development of an aesthetic breast surgeon. Photographic standards must also be developed and adhered to for both pre- and postoperative images. Standard views include an AP and lateral image taken from each side with the hands and arms resting comfortably against the sides. The photograph must include the tops of the shoulders and extend down to mid-way between the inferior pole of the breast and the umbilicus. Centering the patient in front of a crisp colored background completes an artistic image. While various shades of gray or brown are effective, it is my personal preference to use a bright

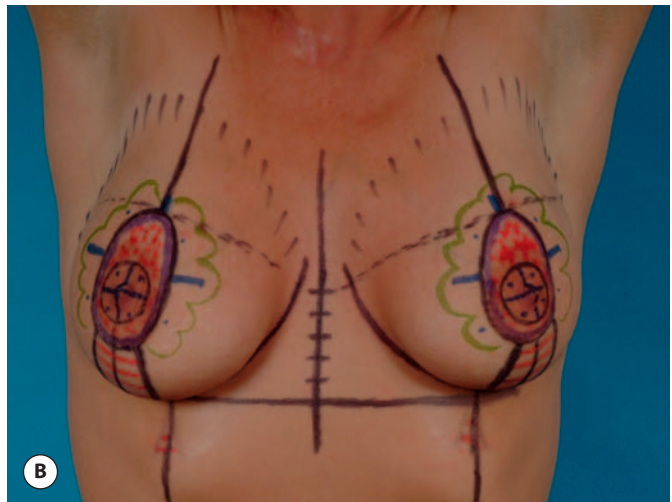


Figure 2.2 (A,B) Using the multicolored markers, a detailed and visually descriptive surgical plan can be instantly appreciated. Such detailed markings are helpful not only at the time of surgery, but also later on after full healing has occurred. By referring back to the marking photographs,

the accuracy and success of the overall surgical strategy can be assessed. In this way, the maximum amount of information and learning can be obtained from each patient experience.

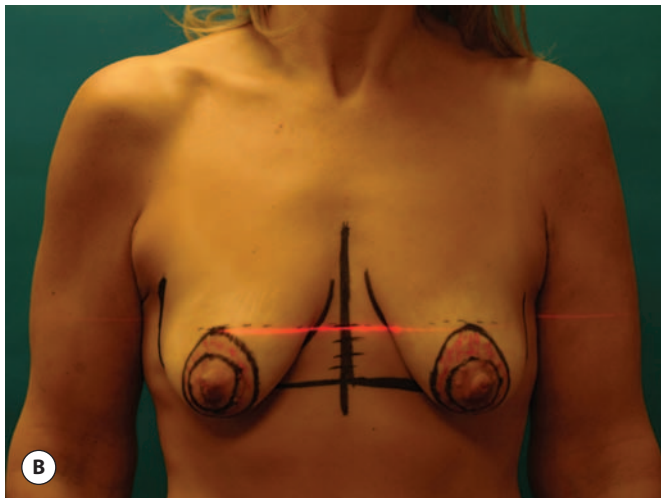


Figure 2.3 (A) A standard laser level which emits a straight line laser beam can assist in evaluating symmetry from side to side in a patient. (B) By turning down the lights, the laser beam can assist in drawing patterns which are symmetric. In this case, the beam is confirming symmetry in the top of the periareolar pattern on each side.

blue as a background color. This tends to provide a pleasing contrast to the patient's skin color, which enhances the visual effect of the photograph (Figure 2.7 A–C). Additional views particular to the individual procedure can also be included. These additional views commonly include 3/4 views, both arms overhead, bending forward slightly to visualize implant wrinkling, breast elevation to expose scars and hands pressing in against the sides to show the effect of pectoralis major muscle contraction on breast and implant shape (Figure 2.8 A–G).

It is strongly recommended to utilize the tremendous advances which have been made in digital photographic technology when building the photo suite. The ability to view the photos immediately ensures that proper views have been obtained and are of good quality. The images can also be printed immediately and taken to surgery the next day, a practice which is highly recommended to assist in intraoperative decision making. Storage is also easily facilitated and immediate recall of patient-specific images is performed without difficulty, a fact which streamlines subsequent pre- and postoperative comparison of results.

Lighting is a critical variable in the generation of high-quality images. A good basic photographic studio is relatively easy to set up and should include a backdrop with an even contrasting color (blue is recommended) and at least two photographic lights with diffusing umbrellas. The lighting system must be adjustable and

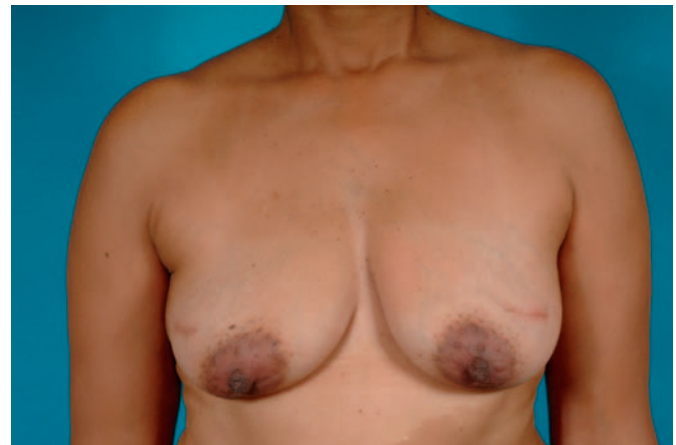

Figure 2.4 The preoperative appearance of a patient who is presenting for mastopexy. Failure to recognize the marked asymmetry in shoulder height could potentially lead to inappropriate surgical positioning of the nipple-areola complex (NAC) during the mastopexy procedure.

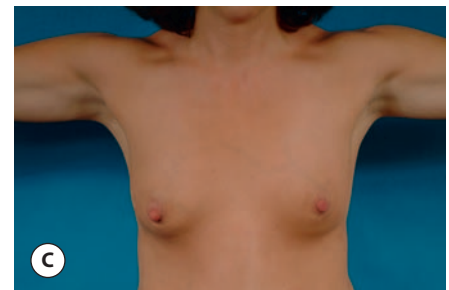
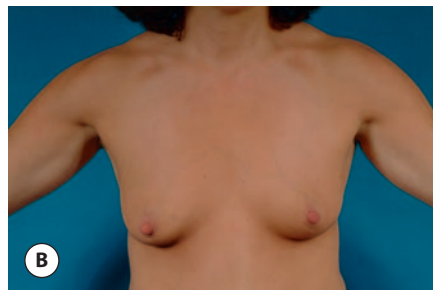
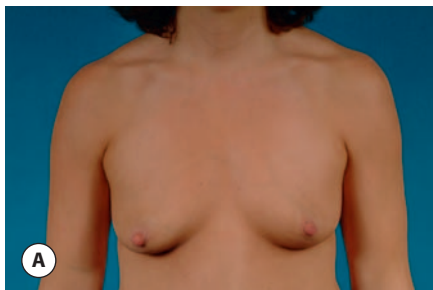


Figure 2.5 (A–C) The preoperative appearance of a patient presenting for breast augmentation. Note that, as the arms are raised, the breast begins to elevate as the arms extend out 90 degrees from the torso. In this patient, in

order to obtain the most accurate information about breast shape during the procedure, the armboards would optimally be extended out only 45 degrees away from the patient to avoid breast distortion when upright.

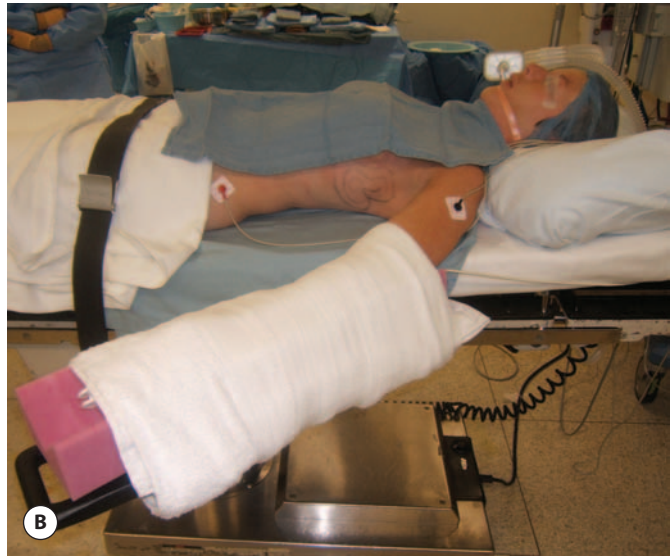
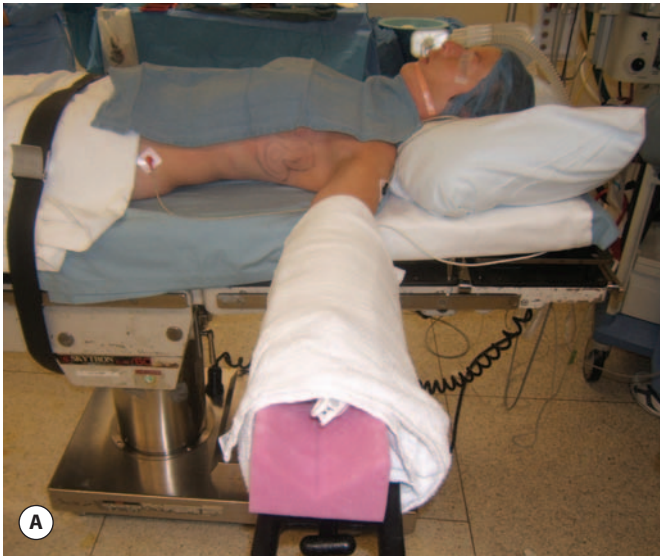
Figure 2.6 (A,B) After wrapping the arm in preparation for sitting the patient up during surgery, the armboard can be lowered to a 45 degree

angle as needed to avoid breast distortion.


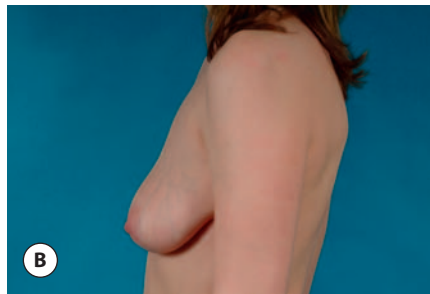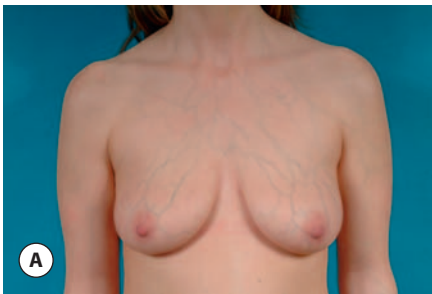


Figure 2.7 (A–C) Standard photographic views obtained during preoperative evaluation include an AP and straight lateral of each side.

synched to the camera for best results. Any camera store or photographic supply business can equip a basic studio, which can be up and running immediately.

I would add a special note about photography. There are clearly inappropriate images and poses, which continue to be presented at major meetings and published in books and journals even today. In any breast image, the patient's face must not be visible. Uniformity in magnification and framing indicates a careful and considered approach to the entire presentation of the case, which can only enhance the professionalism which is demonstrated. Backgrounds which include light sockets, power cords, doorknobs and windows bespeak a lack of concern for detail and detract from the overall result, no matter how aesthetic. In short, there is not enough emphasis which can be given to proper attention to photographic detail.

Intraoperative Considerations

Preparing for surgery begins before the patient even enters the operating room (OR). Here, an experienced surgical staff or a dedicated nurse working closely with the surgeon can greatly facilitate the preparation of the room. Perhaps the most important

piece of equipment required to successfully complete the case is the operating table. The table must sit up to 90 degrees to allow the patient to be placed upright intraoperatively. This maneuver allows the breast to be evaluated with the patient in the sitting position, a process which facilitates successful intraoperative decision making. Many operating tables do not have this capability or only sit up partially to 45 degrees or less. These tables are of limited utility and ideally would be replaced with a table that sits up a full 90 degrees to allow the best results to be obtained ([Figure 2.9 A,B](#)).

Once in the room and after the successful induction of anesthesia, the patient is positioned so the head is directly at the top of the table and is well supported by a foam headrest ([Figure 2.10](#)). This assures that the tops of the shoulders can be incorporated into the surgical prep without risk of contamination by pillows, towels or other types of head wraps commonly placed by the anesthesia staff. The arms must then be secured to allow the patient to be placed upright safely during surgery. Armboards are placed at shoulder level and foam pads are placed under the arms. The arm is then secured to the board and the foam pads with a soft gauze towel followed by a gentle circumferential wrap of gauze which runs from the axilla to the hand. This even application of pressure gently secures the arm to the armboard without

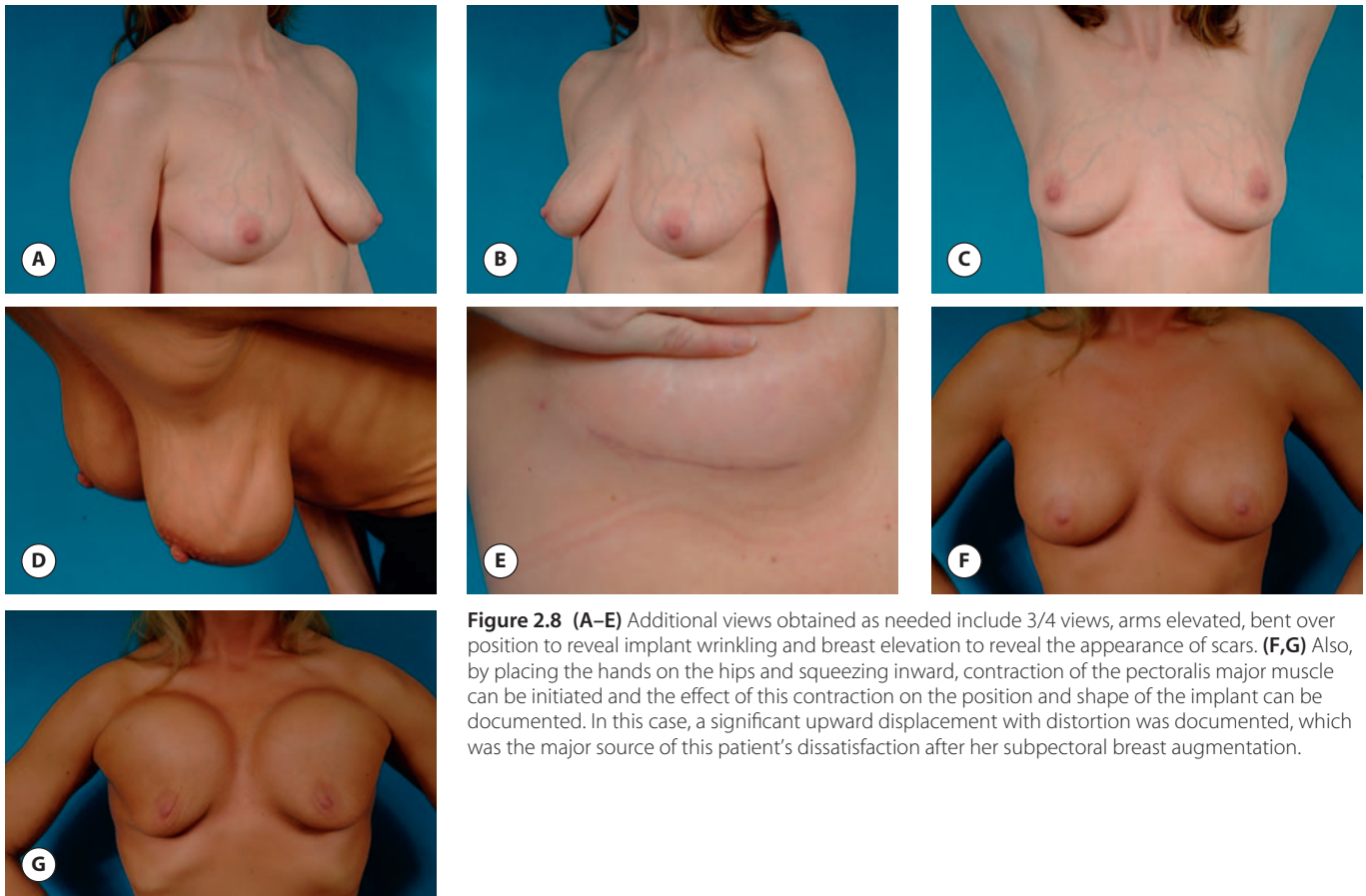


Figure 2.8 (A–E) Additional views obtained as needed include 3/4 views, arms elevated, bent over position to reveal implant wrinkling and breast elevation to reveal the appearance of scars. (F,G) Also, by placing the hands on the hips and squeezing inward, contraction of the pectoralis major muscle can be initiated and the effect of this contraction on the position and shape of the implant can be documented. In this case, a significant upward displacement with distortion was documented, which was the major source of this patient's dissatisfaction after her subpectoral breast augmentation.

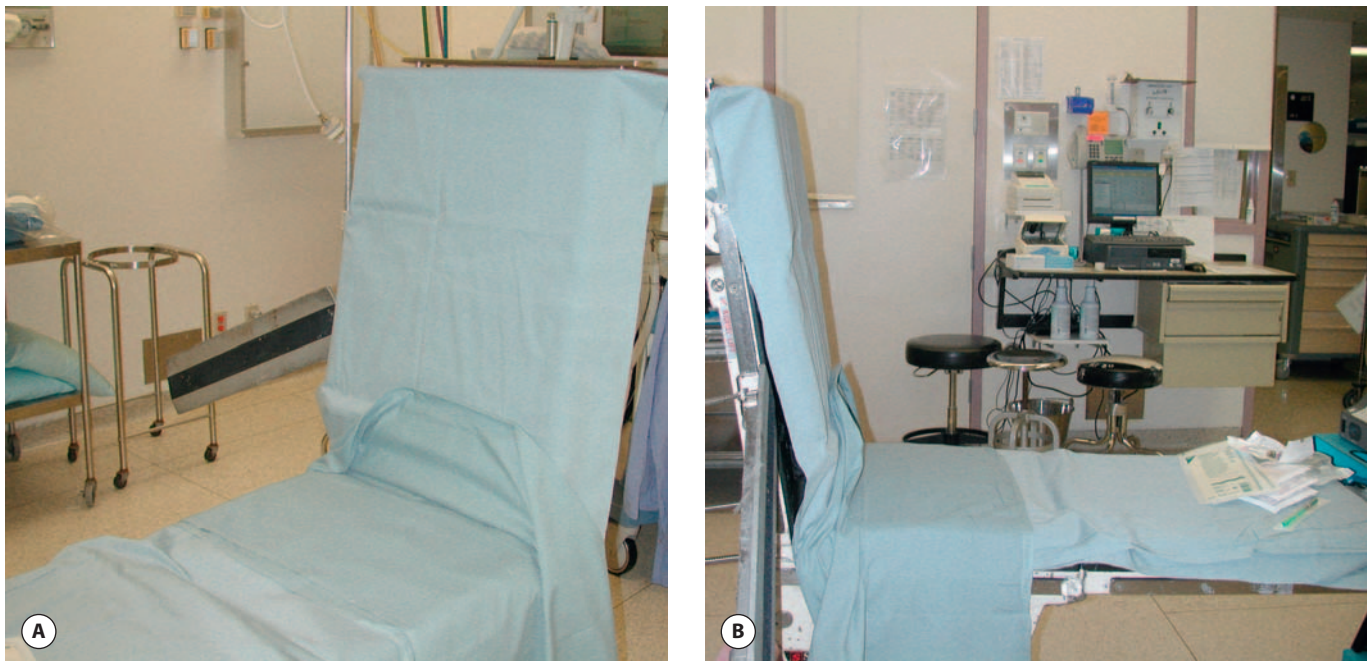

Figure 2.9 (A,B) To be most useful, the operative table should have the capability of being raised a full 90 degrees to allow upright evaluation of breast shape.

risk of nerve compression during what can be long operative procedures (Figure 2.11 A–C). It is imperative that a single constricting band not be used to secure the arm to the armboard as this can lead to a troublesome pressure point and possible nerve compression. The armboard is then adjusted to an angle which will not distort the breast once the patient is placed upright. To relieve pressure on the back while upright, a pillow is placed under the knees and foam pads positioned under the heels to prevent pressure necrosis (Figure 2.12). It can also be very helpful to position the patient preliminarily into a mild beach chair position before the surgical prep. By elevating the back of the OR table 20 to 30 degrees and flexing at the hips slightly, a head start on the upright position which will be used during the operative procedure can be obtained. This will make placing the patient upright during the procedure easier and may reduce anxiety on the part of the OR staff who may be unfamiliar with the upright position. Also, any tethering points which may have been created during patient positioning can be appropriately and easily identified and corrected (Figure 2.13). It has been our practice to utilize a heated air-warming device for all cases, no matter how long or short the planned procedure is, and this

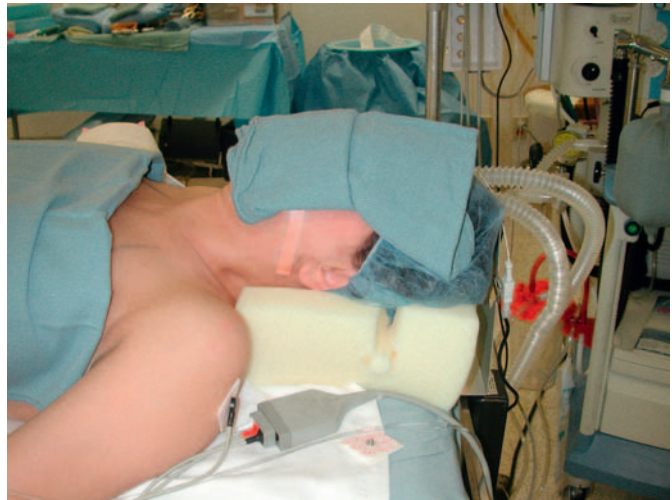

Figure 2.10 After the induction of anesthesia, a foam headrest is positioned under the head to prevent unwanted movement or twisting of the head and neck when the patient is placed upright during the procedure.

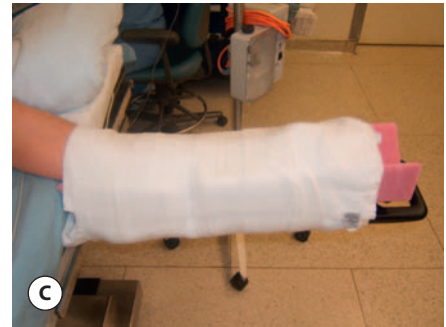
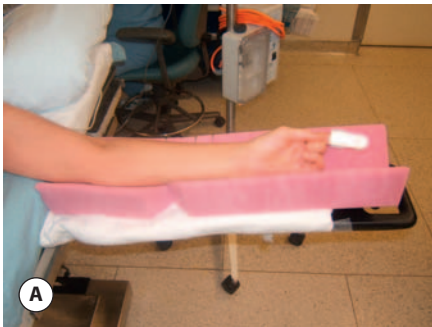


Figure 2.11 (A–C) To prepare for the upright position, the arm is first placed on a foam pad. A towel is then gently wrapped around the arm to secure it to the armboard over a wide area of contact; this is then secured

with a soft gauze wrap. This prevents any pressure points from developing, which could possibly result in nerve compression.

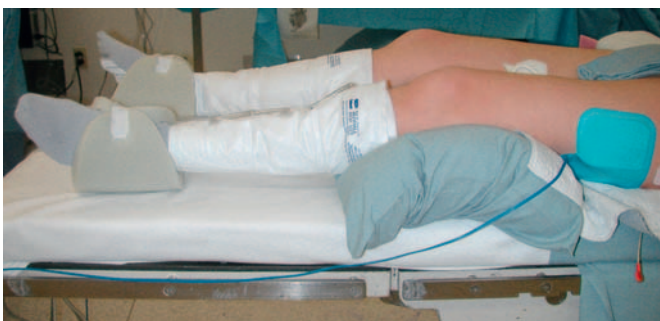

Figure 2.12 A pillow is placed under the knees to relieve stress on the lower back and foam supports are placed under the heels to prevent any possibility of pressure-induced localized ischemia.

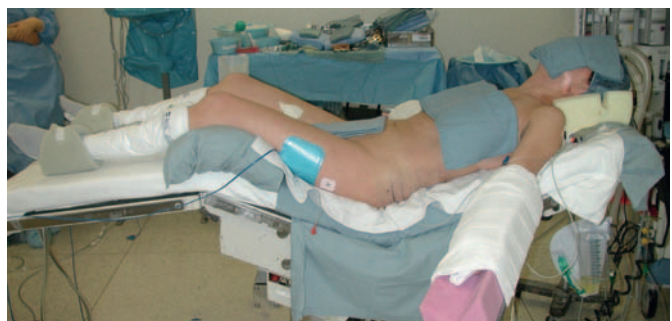

Figure 2.13 Before prepping the patient, it is sometimes helpful to place the OR bed in a mild preliminary beach chair position. This allows any tethering points to be identified and makes it easier for the patient to be raised into the upright position during surgery. In selected cases where patients may present with limited mobility due to previous injury or surgery, this maneuver can be performed with the patient awake to ensure that the position is comfortable for the patient.

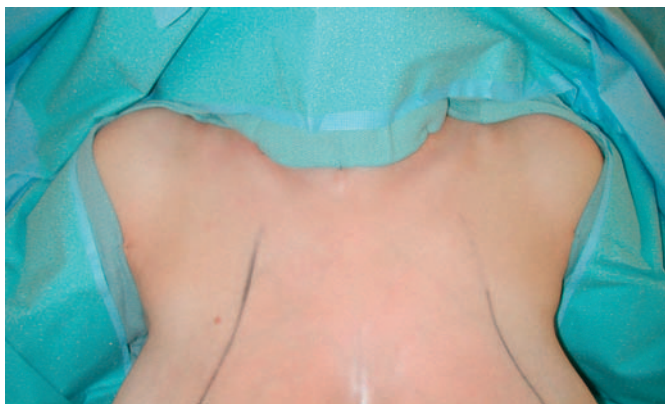

Figure 2.14 In order for the shoulder level to be visualized during surgery, the prep must extend over the top of the shoulders to allow the drapes to be placed high enough for the shoulder level to be assessed with the patient upright.

warming blanket is applied to the lower body as a final maneuver in preparation for applying the surgical prep (**DVD clip 1.04**).

During the surgical prep, it is mandatory that the tops of the shoulders be included and then appropriately draped to allow assessment of the shoulder position when upright (**Figure 2.14**). Here, it may be necessary to adjust the shoulder position to recreate any preoperative asymmetries which were noted during the preoperative evaluation. Finally, it must be stressed to the nursing staff that the previously applied marks not be completely washed off for obvious reasons.

The preoperative photos are taped to IV stands at the head of the table so they can be readily consulted as needed during the procedure. It is very helpful to run all cords and tubing related to electrical equipment and suction downward toward the foot of the bed as these tend to interfere with the process of placing the patient upright.

When the decision is made to sit the patient up, it is very important to bring the back of the bed up to at least 80 degrees.

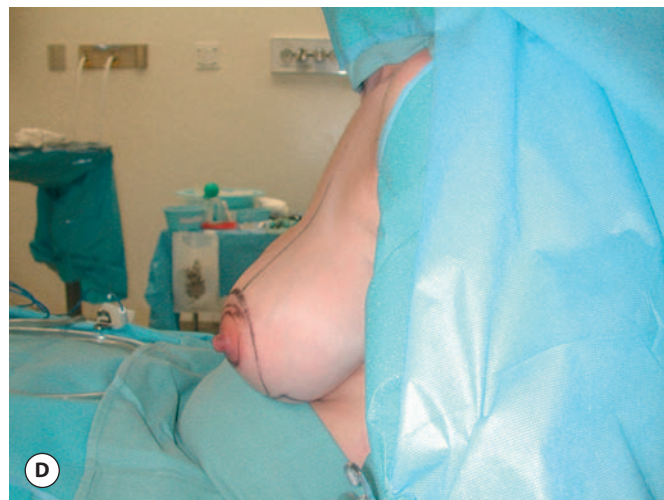
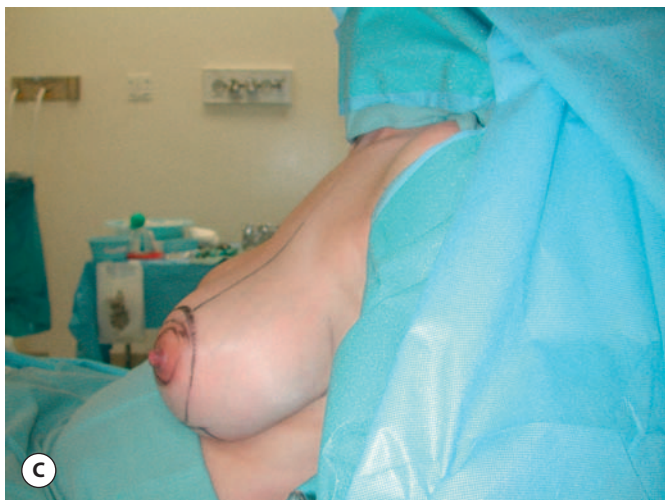
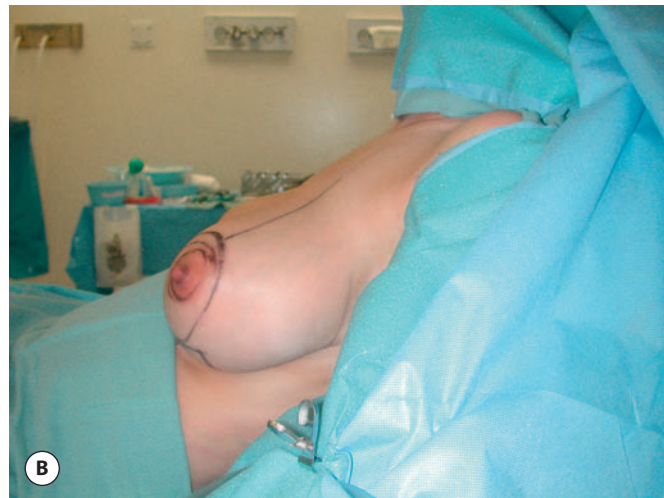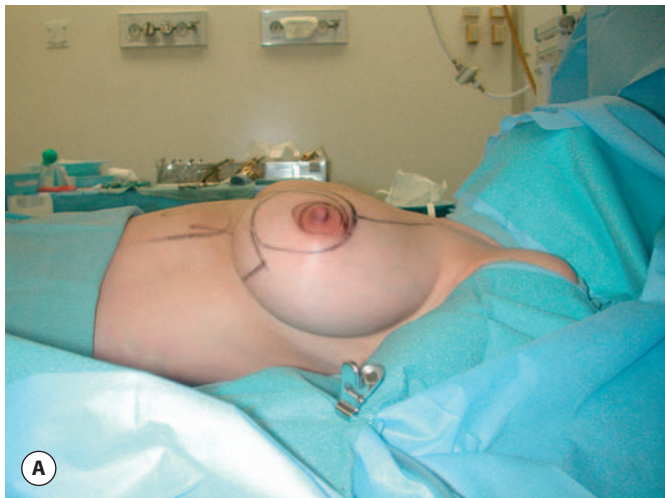Figure 2.15 (A–D) When observing from the side, as the patient is elevated from supine (**A**) to first 30 degrees (**B**), then 60 (**C**) and finally 90 degrees (**D**), the shape of the breast can be seen to change dramatically. Under the influence of gravity, the lower pole of the breast fills out and a concavity in the upper pole becomes apparent. Significantly, a continuing

change in the shape of the breast is noted even as the patient moves from 60 (**C**) to 90 (**D**) degrees. This observation underscores the importance of placing the patient as upright as possible during the procedure to obtain the most accurate assessment that can be made of the shape of the breast during the procedure.

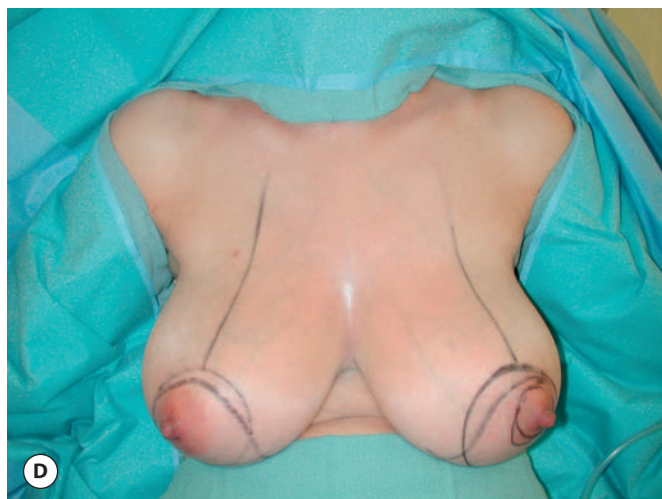
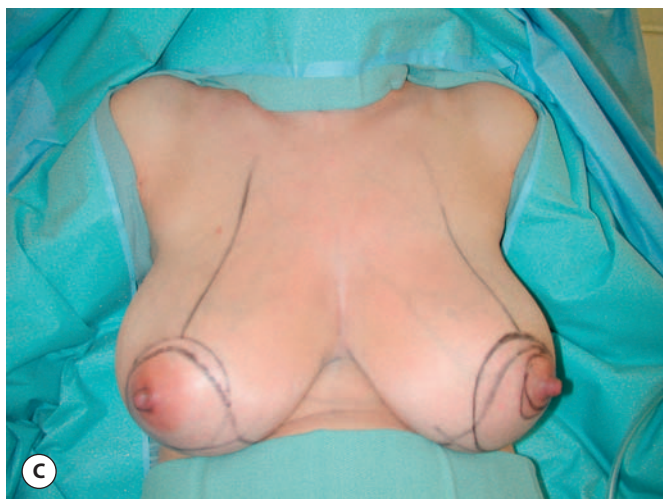
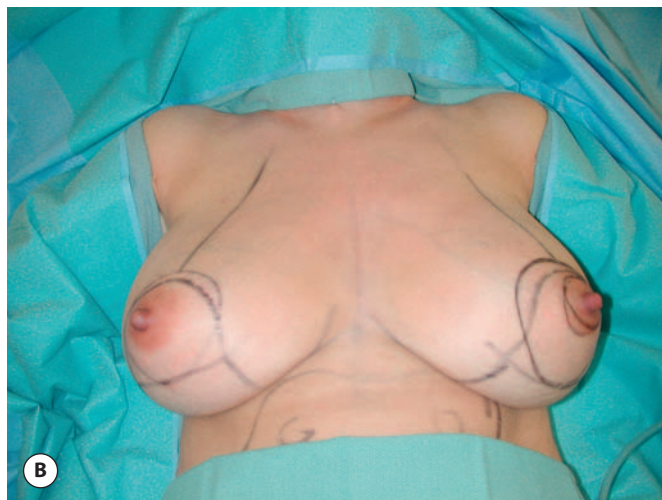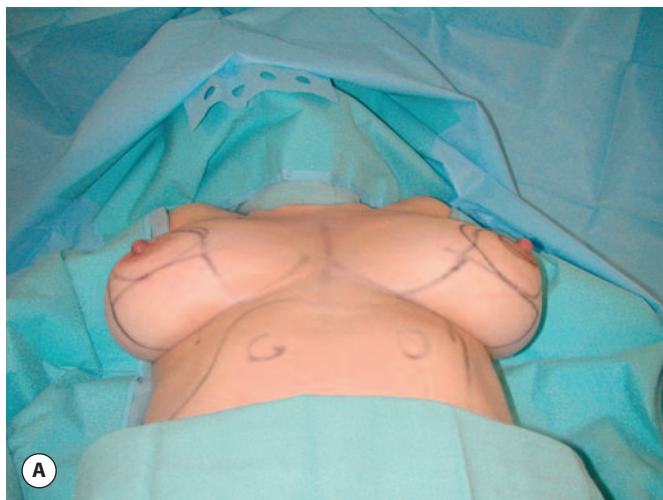Figure 2.16 (A–D) When observed from the front, the same observation can be made. As the patient is elevated from supine (A) to first 30 degrees (B), then 60 (C) and finally 90 degrees (D), the shape of the breast becomes progressively more ptotic. In moving from 60 to 90 degrees, the position of the nipple–areola complex (NAC) relative to the position of the breast

mound changes in a slight but significant way. Failure to recognize these relationships can lead to a host of postoperative shape and position problems in both the breast and the NAC, which can detract from the overall result.

It is in these last few degrees that the breast can be seen to settle significantly under the influence of gravity. Only then and with proper attention to shoulder level and the angle of the arm-board can the most accurate assessment of the breast be made (Figures 2.15 A–D and 2.16 A–D).

Finally, after careful preparation at each step along the way, every possible variable that can interfere with the performance

of a smooth and controlled operative procedure will have been accounted for. With all of these details properly attended to, the full attention of the surgeon can be focused on the procedure at hand and the best environment for success will have been created. All that remains is for the surgeon to apply his or her own technical expertise in a fashion that will provide the best result possible.

Summary

The importance of a detailed approach to preoperative preparation and planning cannot be overemphasized as it relates to delivering consistent results in aesthetic breast surgery. By incorporating the preoperative principles of management and preparation described in this chapter, the environment for

surgical success is optimized and the best chance for an optimal result is created. Incorporation of these principles and practices is strongly recommended as a means to provide quality results in a consistent fashion.

Implant Basics

There are many factors that combine to determine the quality of the aesthetic result obtained when an implant is placed under the breast. Some of these factors are relatively fixed and are therefore subject to limited control by the surgeon. Perhaps the most important variable that falls into this category is the nature of the pre-existing soft tissue framework of the breast. However, one variable that is most decidedly under the control of the surgeon is the nature of the implant that is chosen to perform the procedure. By intelligently choosing the correct combination of implant characteristics, the results obtained after breast augmentation can be optimized as much as possible. Therefore, while other decisions that are made when planning a breast augmentation such as incision location and pocket placement are without question of great importance, choosing the 'right' breast implant is one of the most critical decisions to be made in breast augmentation.

It bears emphasizing that the effect of the implant on the ultimate result after breast augmentation is directly related to the thickness of the soft tissue cover of the breast. In patients where there is a relatively thick layer of parenchyma and fat, essentially any breast implant will provide an acceptable result if the proper volume is provided. There is no reason to use, for instance, a shaped device in these patients as the advantage of the anatomic shape is overwhelmed by the volume of the surrounding soft tissue and the subtleties of the shaped concept are so obscured as to be rendered inconsequential. In fact, when the volume of the breast implant ends up providing 50% or less of the overall volume of the breast, any shaping advantage afforded by an anatomic device, or any more subtle 'feel' effect associated with, for instance, a silicone gel implant, ends up being obscured by the volume of the native breast. As the percentage of overall breast volume that the implant provides increases, the effect that the shape, size and consistency of the chosen breast implant has on the final result becomes more pronounced. Generally speaking, when the implant provides more than 75% of the volume of the breast, variables such as shape, fill material and projection begin to have an increasingly noticeable effect on the overall result (Figures 3.1, 3.2).

Implant Construction

In order better to understand how a breast implant will interact with the overlying soft tissue cover, it is helpful to have a basic understanding of how an implant is made. Very simply, there are two basic components which become important in breast implant construction: the shape of the outer shell and the nature of the material used to fill the implant to give it volume.

The outer shell is made of a silicone rubber that is cured onto a form called a mandril. The mandril is specifically constructed to create an implant of a specific size and shape. For a given implant design, there are generally whole families of mandrils which maintain the basic shape but exhibit a wide range of graduated dimensions and volumes. Either the mandrils are dipped into liquid silicone or the silicone is sprayed on to apply a thin coat of the material to the mandril. This thin layer of liquid silicone is allowed to dry and the mandril is then dipped again. After a series of dips, the silicone layer that is now attached to the mandril has a uniform thickness sufficient to hold reliably a given volume, the configuration of which is determined by the shape and dimensions of the mandril that made the shell. The flexible silicone shell is cut free from the dipping rod attached to the mandril and the elastic form is stretched and pulled off. For saline implants, the circular defect created by freeing the shell from the mandril is patched and a small fill valve is inset into the patch to complete the construction of the shell. For silicone gel implants, the shell is filled with a prescribed volume of the chosen gel and the defect is then patched to seal the gel inside the shell (Figure 3.3 A-E).

Implant Behavior

Although there are many variables involved in the design of a breast implant, the two that most directly influence how the implant will perform in a patient are the inherent shape of the outer shell as determined by the mandril and the volume and consistency of the filling material that is added to the elastic shell. How these two variables interact with each other directly affects how well the implant will function. In simple terms, the eventual shape of the implant is governed by the laws of physics as they apply to the act of adding volume to a confined space. This can be best understood by considering how an implant shape changes as it goes from being completely empty to being slightly overfilled.

When an implant shell is completely empty, the outer shell is wrinkled and the shape of the device is correspondingly distorted. As volume is added to the implant, the wrinkles are filled out and the shape progressively improves until, eventually, a volume is reached where the shell is completely filled and, without any other outside influences, the shape of the implant exactly approximates the shape of the mandril that made the device. However, because the outer silicone rubber shell is elastic, it is possible to continue to fill the implant to a point beyond the fill volume determined by the mandril. As a result, the surface area

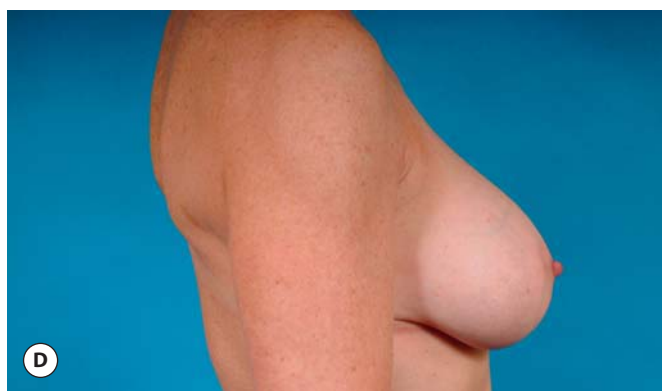
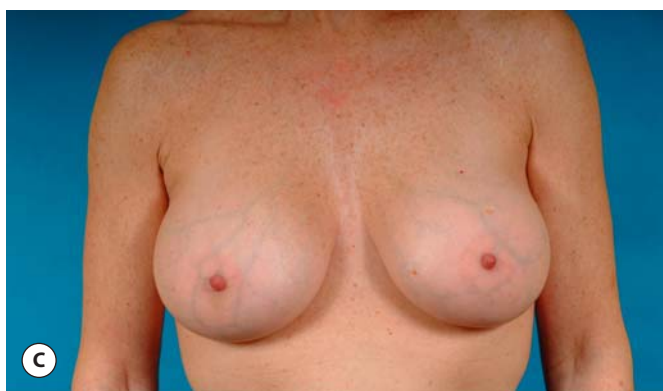
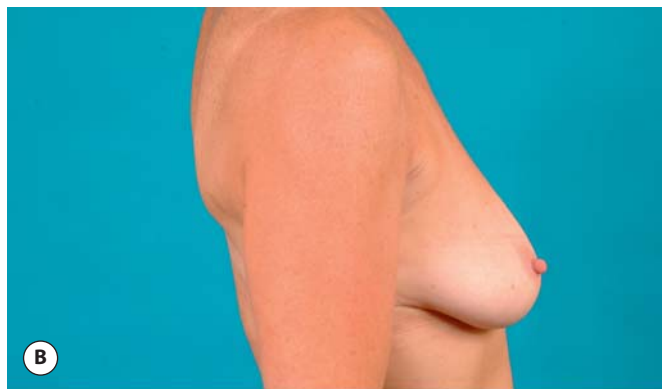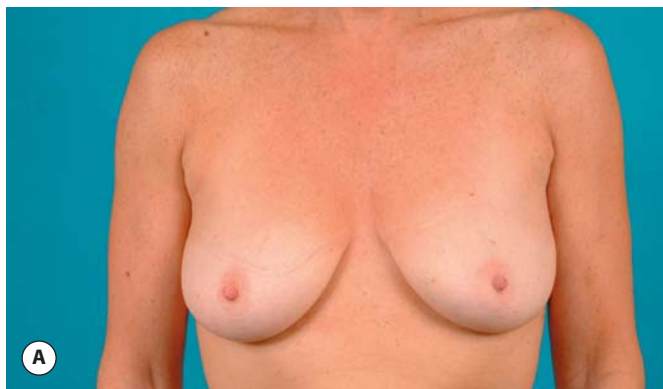Figure 3.1 (A, B) Preoperative appearance of a 48-year-old woman in preparation for breast augmentation. Her preoperative breast appearance is notable for a fairly substantial soft tissue thickness in the tissues of the breast and surrounding chest wall. As a result, essentially any style of breast implant will provide an aesthetic result. **(C, D)** Postoperative appearance after undergoing a subglandular breast augmentation through an inframammary fold incision using a 380 cc high-profile saline implant filled

to 400 cc. This combination of variables is perhaps the most challenging with regards to creating a natural-appearing breast with no excess of upper pole fullness and, yet, her AP and lateral views demonstrate an aesthetic result with a natural breast shape. This case demonstrates that the aesthetic quality of the final result is often most directly affected by the adequacy of the pre-existing soft tissue cover of the breast.

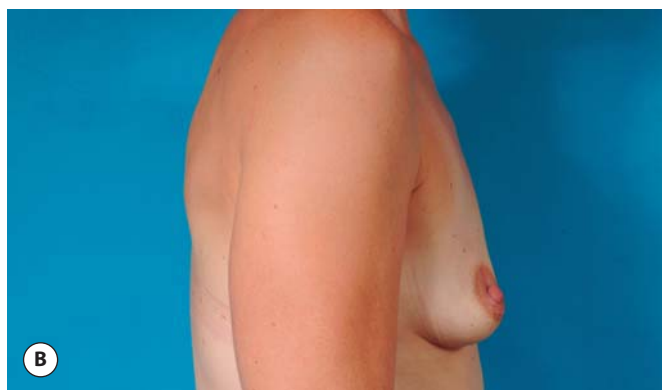
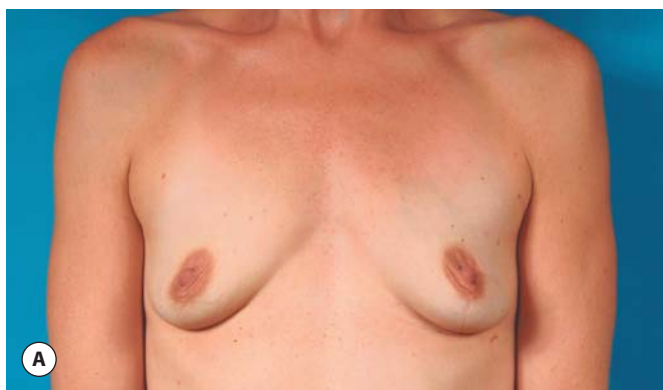

Figure 3.2 (A, B) Preoperative appearance of a 48-year-old woman in preparation for breast augmentation. Her preoperative appearance demonstrates a paucity of soft tissue and, as a result, the implant will be

providing a greater proportion of the overall volume of the breast. In this case, it will be important to choose a device that will complement as optimally as possible the existing soft tissue framework of her breast.

of the implant expands slightly and the intraluminal pressure of the device increases (Figure 3.4). It is at this point that the physics-based relationships between surface area and volume become important. Very simply, for a given volume, the smallest surface area that can contain that volume assumes the shape of a sphere. Put another way, a sphere describes a surface area to

volume relationship that is maximally efficient. This explains why breast implants appear rounded when they are subjected to the forces of capsular contracture. Because the volume of the device is fixed, as the surface area of the capsule decreases due to the contracture, the relationship between the surface area of the capsule and the volume of the implant becomes more efficient and

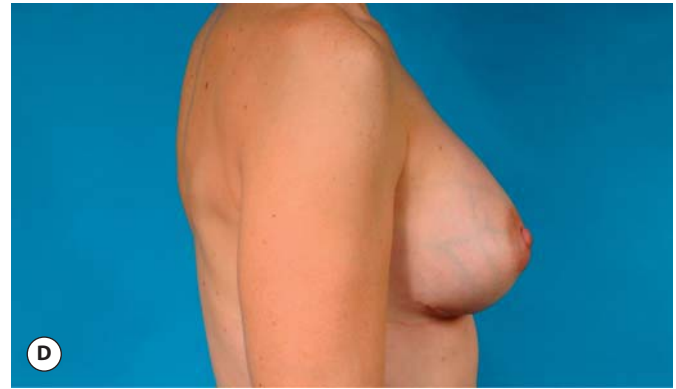
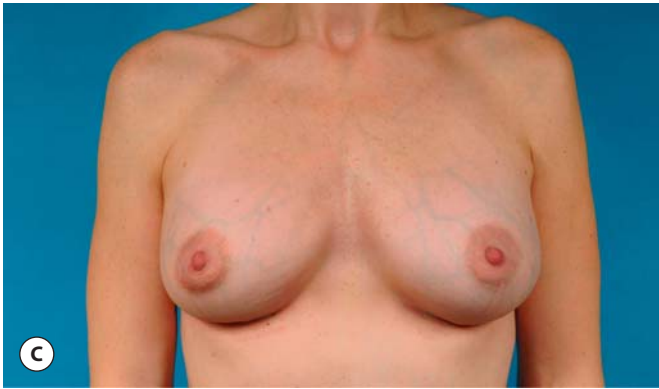
Figure 3.2 (Continued) (C, D) Postoperative appearance after undergoing a partial subpectoral breast augmentation through an inframammary fold incision using a 295 cc anatomically shaped cohesive gel breast implant. Here, the shaped device has created an anatomic

volumetric filling out of the breast skin envelope without creating any unnatural bulging in the upper pole of the breast. In this case, the choice of a shaped implant likely resulted in a more natural-appearing breast than if a round implant had been used.

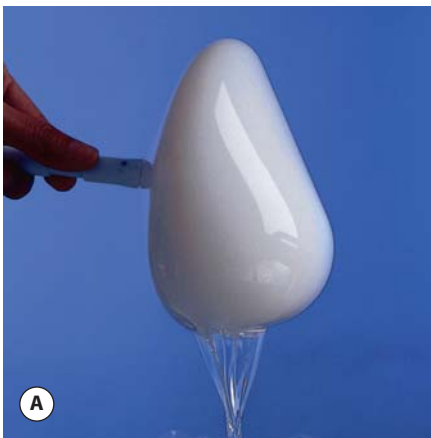

Figure 3.3 (A) Appearance of an anatomically shaped mandril attached to a dipping rod just after it has been submerged into a vat of liquid silicone. The excess silicone can be seen running off the most dependent portion of the mandril. Once the excess silicone has been removed, a thin silicone layer is left to dry around the mandril. After several 'dips', a shell of uniform thickness is created around the mandril. **(B)** After the silicone rubber in the shell has cured, the shell is cut free from the dipping rod and pulled off

the mandril. The elastic nature of the rubber allows this to be performed without damaging the shell. **(C)** Appearance of the fully formed shell after it has been removed from the anatomically shaped mandril. **(D)** A patching process is utilized to repair the circular defect created in the back of the shell by cutting the shell free from the mandril. **(E)** Appearance of the final breast implant after filling the anatomically shaped shell with a cohesive silicone gel. Courtesy of mentor Corporation ©

gradually assumes the shape of a sphere (Figure 3.5 A,B). Therefore, with a perfectly spherical implant shell, overfilling would result in an increased intraluminal pressure and a symmetrically realized increase in the surface area of the implant

with no distortion in the shape of the device (Figure 3.6). Essentially, all that would result would be a slightly bigger sphere that felt a little firmer. However, breast implants are not spherical in shape and it is very important to realize that

what are commonly referred to as round implants are round only in two dimensions. Typically, in the horizontal and vertical planes, the devices are symmetric. However, in the sagittal plane, the dimensions of the implant are different and, in that regard, what is typically referred to as a round implant is actually shaped (Figure 3.7). Although this typical 'round' implant does not approach the degree of shape that the more standard 'anatomical' implant does, it is shaped nonetheless as it has asymmetrical dimensions in one plane and therefore functions as an asymmetric device. This asymmetry in shell design has implications in how the implant responds to filling. As the implant proceeds

from an empty state to one of progressive inflation, the shape will improve until that point is reached where the exact volume that corresponds to that of the mandril is reached. This is the optimal fill volume for the implant. As this optimal fill volume is exceeded and the implant becomes overfilled, the surface area of the device increases slightly and the pressure inside the device increases. As continued filling proceeds, the ability of the outer shell to stretch to accommodate the increasing volume becomes overwhelmed and the increase in the surface area of the implant tails off rapidly such that the surface area measurement becomes more or less fixed. At this point, the laws of surface area to volume physics become applied and the device gradually becomes more spherical and the projection in the sagittal plane increases and the vertical height and horizontal width diminish. Because the contour of the radius of the device is more aggressively shaped as compared to the smoother dome-like contour of the front and back of the implant, the ability of the elastomer in this part of the shell to stretch smoothly to re-accommodate the increasing volume of the implant is limited. Therefore, as the projection of the implant increases, the change in the shape of the device cannot be smoothly accommodated along the radius of the device and stress risers form at the implant edge. This is a well-recognized phenomenon noted particularly in saline implants and this edge distortion is known as 'scalloping' (Figures 3.8–3.10, DVD clip 1.05). As the implant is overfilled even further and becomes more spherical, the edge scalloping becomes more severe. Recalling the example of capsular contracture, where the volume remains fixed and the surface area gradually decreases, here in the case of an overfilled implant, it is the surface area which becomes more or less fixed and the volume which increases. In either instance, it is the physics of adding of fluid to a confined space that ultimately governs the resulting shape of a breast implant.

By applying these concepts, it is possible to gain a better understanding of implant behavior with regard to, in particular,

DVD
1.05

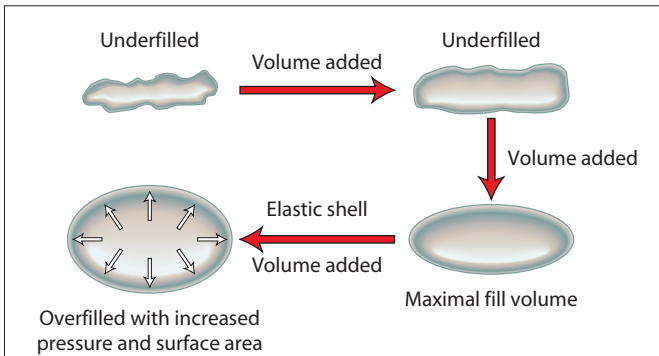
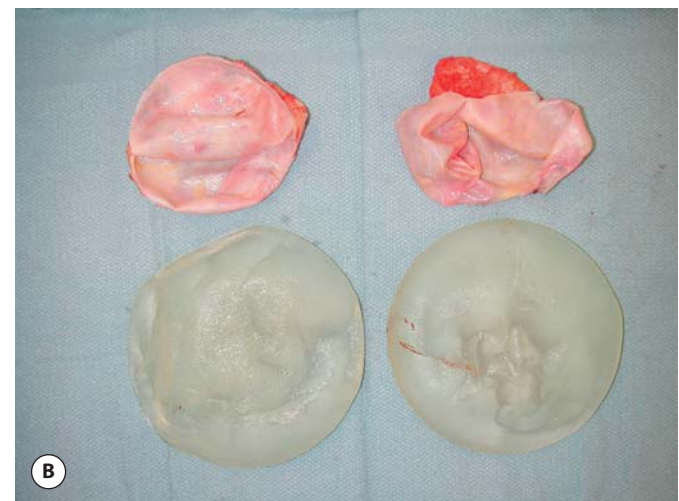


Figure 3.4 Schematic diagram depicting the course of events that occurs as a breast implant is filled. Initially, the implant begins as an empty shell devoid of any shape. As fluid is added to the device, the shape gradually improves until the maximum volume of fluid is added to the device as dictated by the volume associated with the mandril that made the shell. It is at this point that the shape of the implant most directly corresponds to the shape dictated by the mandril. Because the outer silicone rubber shell is elastic it is possible to overfill the implant beyond the optimal fill volume. When this occurs, the surface area of the device expands slightly and the pressure inside the implant increases.

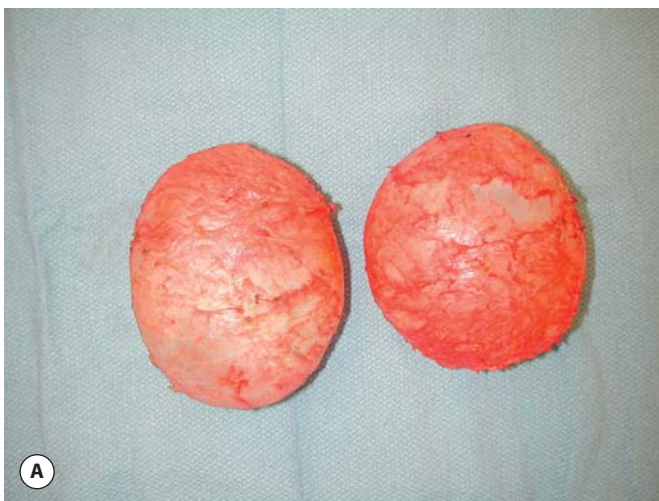

Figure 3.5 (A) Appearance of the operative specimen after bilateral complete capsulectomy in a patient with severe capsular contracture after breast augmentation. In each breast, the implant and the surrounding capsule were removed en masse. Note that each breast implant has been forced into a rounded shape as the fixed volume of the device was constrained by the contracted capsule. This phenomenon is predicted by



the laws of physics as the fixed volume of the implant becomes encased in the smallest surface area possible as a result of the contracted capsule, the shape of which approaches that of a sphere. (B) After the capsule is removed, the implant is allowed to relax and the surface area of the shell effectively increases. As a result, the implant readily assumes the shape dictated by the mandril that made the shell.

saline implants. **Figure 3.11** represents a stylized graph showing implant shape on the Y axis and degree of implant fill on the X axis. Initially, the implant is empty and the shape is an unfilled shell. Then, as fluid is added to the device, the wrinkles

in the device are filled out and the shape gradually improves until the optimal fill volume, or the fill volume determined by the implant mandril, is reached. As further filling proceeds, scallops develop at the edge of the implant and the shape begins to deteriorate. Therefore, with the optimal fill volume as the apex of the desired shape, there is a small window of fill volume variability either side of which will still allow an acceptable shape to be created in the implant. Falling too far short of the optimal fill volume will result in progressively prominent wrinkling in the shell and exceeding the optimal fill volume by too great a degree will result in scalloping of the implant edge (**Figure 3.11**). This fill volume window has long been recognized by plastic surgeons and manufacturers and it is generally accepted that the optimal fill volume of a saline implant can be exceeded by roughly 10% without creating an obvious shape distortion. Such flexibility in implant filling is one of the advantages afforded by the use of saline implants. By differentially filling an implant of the same basic size and dimension without causing a significant distortion in the shape of the device, patients who present with mild asymmetries in breast size can be treated effectively without the potentially troubling need to resort to implants of different base diameters.

These principles are equally applicable to ‘round’ silicone gel implants. However, when comparing the characteristics of saline


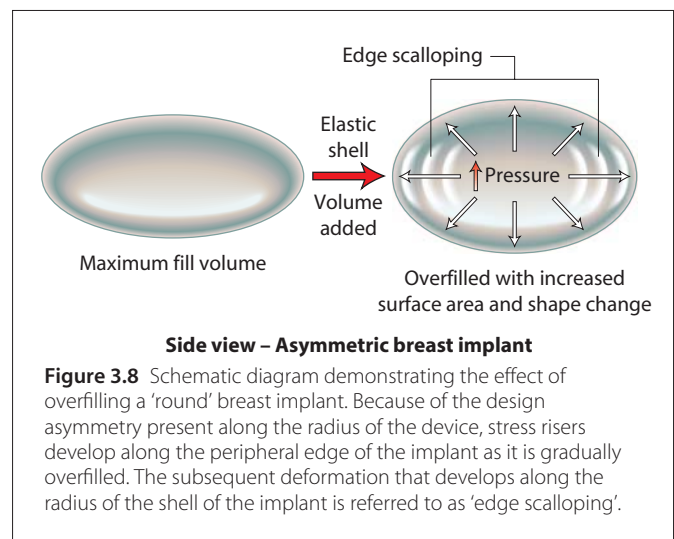
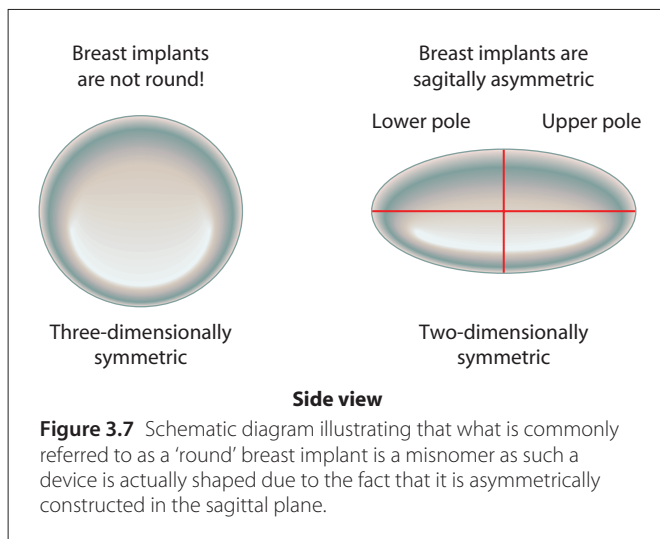
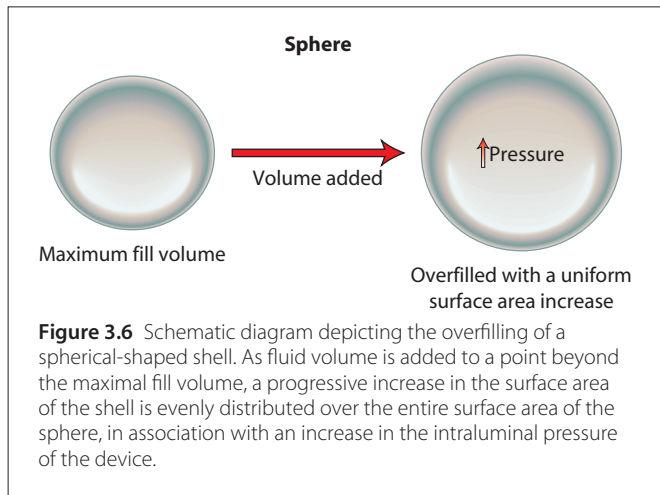


Figure 3.9 (A) Lateral view of a smooth round saline implant that is underfilled relative to the optimal fill volume. (B) As the implant is filled to the optimal fill volume, the projection increases and the overall shape of the shell is smooth with no irregularities. (C) As the implant becomes

overfilled, the projection increases as the device becomes more spherical, resulting in the development of prominent edge scalloping along the radius of the device.

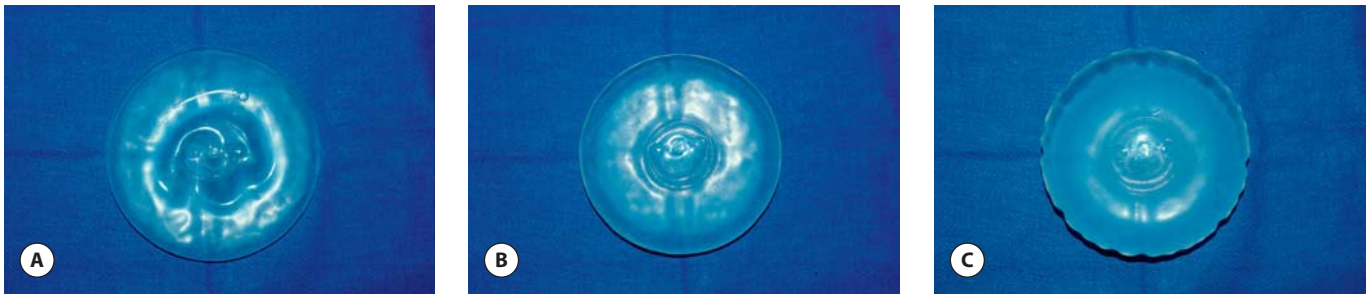
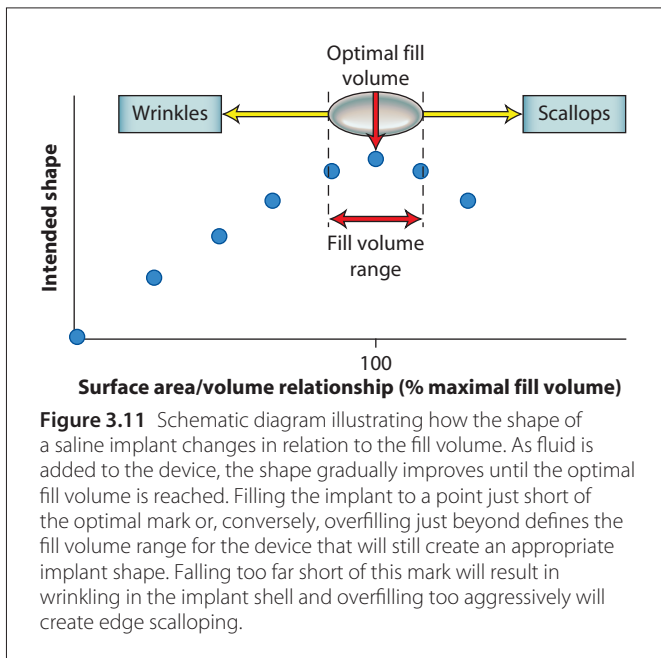


Figure 3.10 (A) The same underfilled smooth round saline implant viewed from the top. Note the central depression in the shell indicative of the fact that the implant is filled to a point that falls short of the optimal fill

volume. (B) When the implant is filled to the optimal fill volume the central depression disappears. (C) When the implant is overfilled, prominent edge scalloping can be readily identified.



versus silicone gel implants, it is important to recognize two major differences. First, the volume of a silicone gel implant is fixed, a feature that actually simplifies the use of these devices to a certain extent. Second, every silicone gel implant, whether it be a moderate-, moderate plus- or high-profile device, is underfilled relative to the optimal implant volume created by the mandril. This mismatch in fill volume relative to the available surface area of the device, along with the thicker consistency of the gel, results in an implant which has a decidedly softer feel than a properly filled saline implant. When a silicone gel implant is placed on a flat surface, the degree to which it is underfilled can be assessed by noting the variable degree of collapse of the central part of the shell in the middle of the device (Figure 3.12 A,B). This central shell collapse can be temporarily corrected by gently placing an evenly applied force to the surface of the implant. The implant then assumes a properly filled appearance without deformation. A similar phenomenon occurs when the implant is placed upright 90 degrees. The underfilled device will collapse in the upper pole, sometimes markedly, and this collapse can be partially overcome by applying force to the anterior surface of the device (Figure 3.13 A,B). In situ, this external force is applied to the implant by the surrounding soft tissue framework of the breast. Therefore, the outward appearance of a breast augmented with an underfilled fixed-volume silicone gel implant will depend upon the degree of underfilling of the

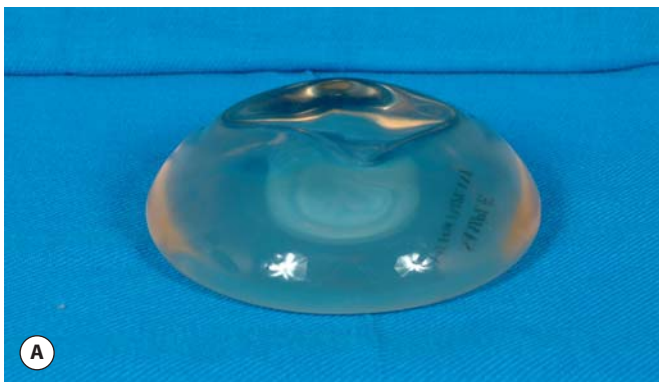


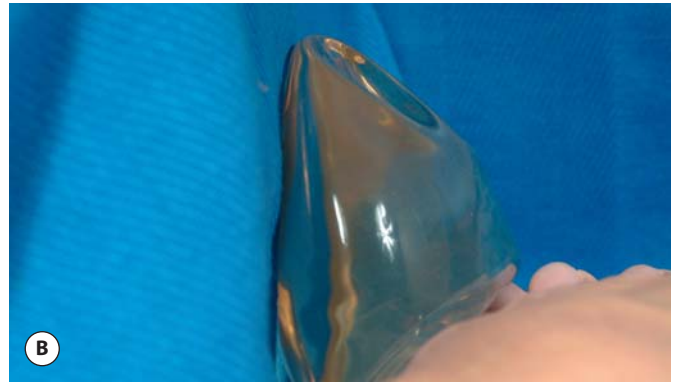
Figure 3.12 (A) Lateral view of a moderate-profile smooth-walled silicone gel implant. A prominent area of central collapse is noted, indicating that the implant is underfilled relative to the optimal fill volume created for this particular shell by the mandril. (B) Lateral view of a high-profile smooth-walled silicone gel implant. The central collapse is less prominent, indicating



that this device, although slightly underfilled, more closely approximates the volume of the mandril that made the shell. For this reason, high-profile devices are less likely to form prominent wrinkles in situ as they do not undergo the same degree of positional deformation that moderate-profile implants sometimes demonstrate.



Figure 3.13 (A) When a silicone gel implant is placed upright 90 degrees, the upper pole of the device collapses as, under the influence of gravity, the gel preferentially fills the lower pole of the implant. **(B)** When a counterbalancing force is applied to the lower pole, some of the gel is forced back up into the upper pole such that the degree of deformation



in the upper pole becomes less. Clinically, this can be observed when the soft tissue framework of the breast is somewhat tight. The lower pole of the implant is not allowed to expand unchecked and the degree of upper pole collapse is reduced.

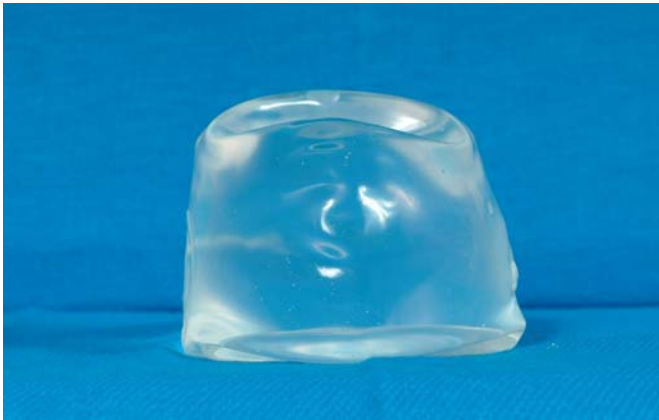

Figure 3.14 Because saline is a much more free-flowing filler than silicone gel, the degree of upper pole collapse seen in an upright saline implant tends to be more pronounced than that seen in gel implants.

device as modified by the nature of the external forces applied by the soft tissue framework of the breast.

Given these variables, it can be deduced that saline-filled devices must be filled to a level at or near the optimal fill volume of the device lest the resulting surface irregularities which would develop, either wrinkles or scallops, become visible through the breast. These surface irregularities become even more pronounced when what appears to be a properly filled saline implant is placed upright 90 degrees. In this position, the pressure of the saline falling to the lower pole of the breast creates collapse of the upper pole with pronounced folding and wrinkling being the result (**Figure 3.14**). Applying force to the surface of the device, as happens with a relatively constricted soft tissue envelope, will counteract the tendency for the saline to fall to the bottom of the shell and upper pole distortion will tend to be corrected. However, in a lax skin envelope, if the soft tissue cover is thin enough, these irregularities develop unchecked and implant distortion with visible contour irregularities in the breast can potentially be seen. Silicone gel implants are under less severe constraints and can be underfilled without causing the same degree of potential surface irregularity. This is due to the fact that the denser consistency of the gel and the softer

elasticity of a silicone gel implant shell combine to form softer wrinkles, which create edges which are less sharp than in saline devices. As a result, a fixed-volume, underfilled, silicone gel implant can settle to the bottom of a breast pocket and can fold and wrinkle according to the dictates of the overlying soft tissue framework to assume a shape other than that imparted to the shell by the shape of the mandril. Simply stated, the wrinkles associated with a standard round silicone gel implant tend to be much softer than those which form in saline devices and result in visible surface irregularities only in the thinnest of patients. In actuality, this shape is variably and at times markedly anatomical, a fact which has been documented in supine, prone and most importantly upright magnetic resonance imaging (MRI) evaluations of patients with fixed-volume silicone gel implants in place (**Figure 3.15 A-G**). When the soft tissue envelope is sufficiently lax, the underfilled gel device settles to the bottom of the pocket and forms folds and wrinkles in a patient-specific fashion to create, along with the overlying breast tissue, the final shape of the resulting augmented breast. This is actually a very powerful way to use a breast implant as each device is molded into a custom-made shape specific for each patient. When the volume and eventual configuration of the round gel implant complements the native breast well, very aesthetic results can be reliably and consistently obtained in breast augmentation.

However, in assessing the shape of an in situ breast implant, the presence of wrinkles in the implant shell and what effect these wrinkles might have in both the short and the long term must be carefully considered. As long as these wrinkles form softly enough to allow the implant to settle into a smooth anatomic shape and cannot be seen through the soft tissue cover of the breast, they are well tolerated. However, over time, wrinkles eventually create weak points in the implant shell and may well be the major etiologic cause of ultimate implant failure (**Figure 3.16 A,B**). It is here that the anatomically shaped implant concept offers particular advantage. Because most of the mass of an anatomic implant is centered in the lower part of the device, when the implant is placed upright, the magnitude of the distorting forces across the peripheral upper edge of the implant is minimized. As a result, anatomically shaped implants are inherently less likely to wrinkle or otherwise develop a shape distortion than 'round' devices, a fact that can afford the surgeon a greater ability to control

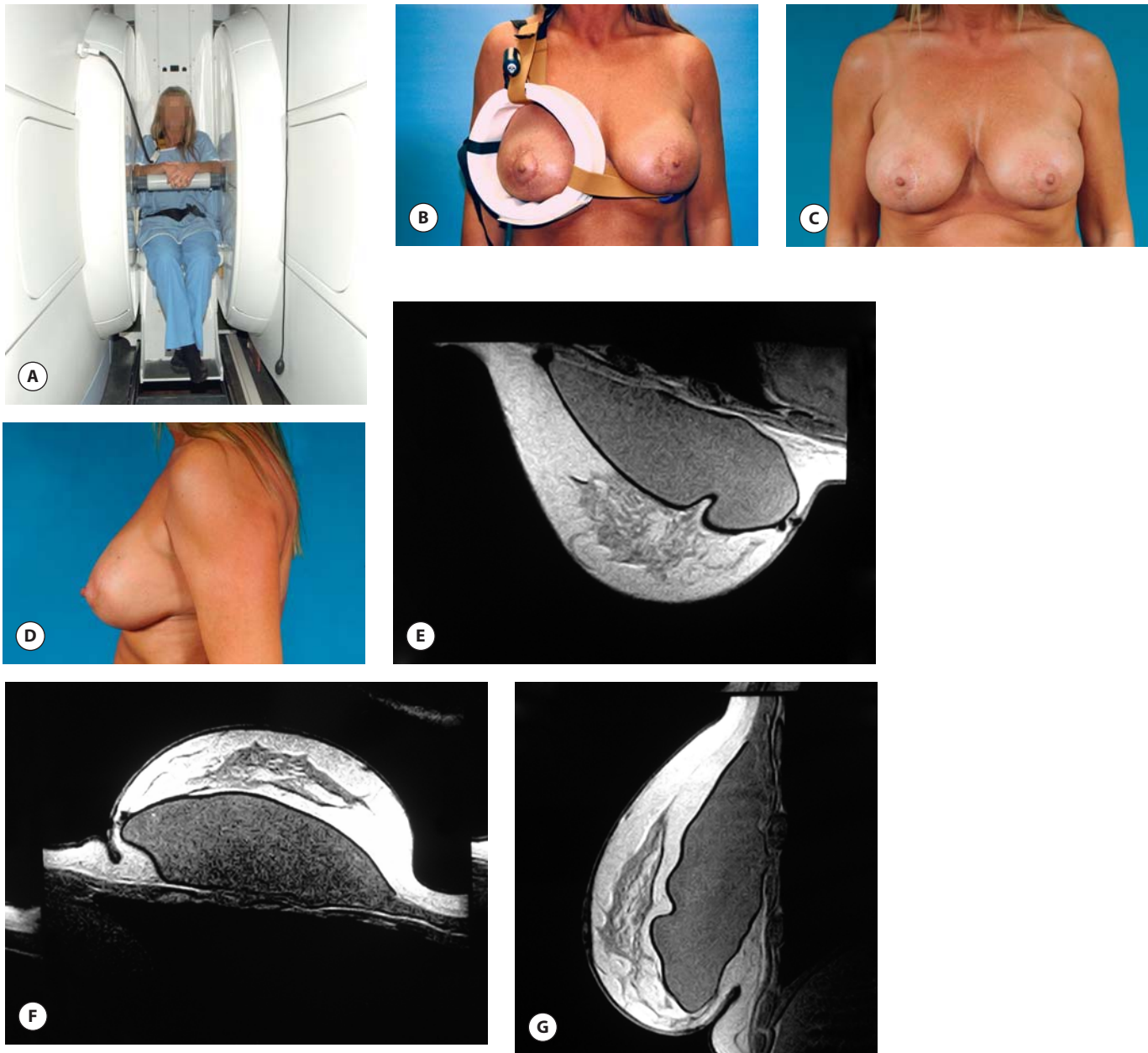


Figure 3.15 (A) View of a patient seated in an upright .6 Tesla MRI scanner. (B) A specialized breast coil is placed on the patient to allow upright imaging of the implant. (C, D) AP and lateral views of a patient after undergoing an augmentation mastopexy using a 325 cc smooth, round, moderate-profile silicone gel implant placed in the subglandular plane. (E) In the prone position, a prominent fold is noted in the anterior portion of the implant shell. (F) In the supine position, the breast and the underlying implant rotate superiorly, resulting in a smoothing out of the shell of the implant. (G) In the upright position, the takeoff point of the apex of

the device forms an acute angle, which in a sense, creates an anatomic implant shape. Also, the folds return to the anterior surface of the implant. These findings demonstrate that the underfilled moderate-profile device is molded by the soft tissue framework of the breast into a patient-specific shape that, together with the existing breast volume, combines to create an aesthetic breast contour. This strategy of using an underfilled device that is shaped by the overlying breast is a very versatile and powerful method of optimizing the result in breast augmentation.

the shape of the upper pole of the breast (Figure 3.17 A-F). This tendency to maintain shape when placed upright is further enhanced when the fill material has enough structural integrity to support the implant shell. Both saline and standard viscosity gel do not tend to provide strong enough support to the upper pole of an anatomically shaped implant shell and wrinkles and folds can form when these devices are placed under a lax skin envelope. As such, these types of devices are subject to potential fold flaw

failure with rupture over time. However, with the newer cohesive gels, which have an enhanced level of viscosity, strong structural support is provided to the entire implant shell and these devices do maintain their shape well, even when placed upright under a lax skin envelope (Figure 3.18 A,B). To support the outer shell further, anatomically shaped cohesive gel devices are filled to a level which much more closely approximates the optimal fill volume determined by the anatomically shaped mandril which

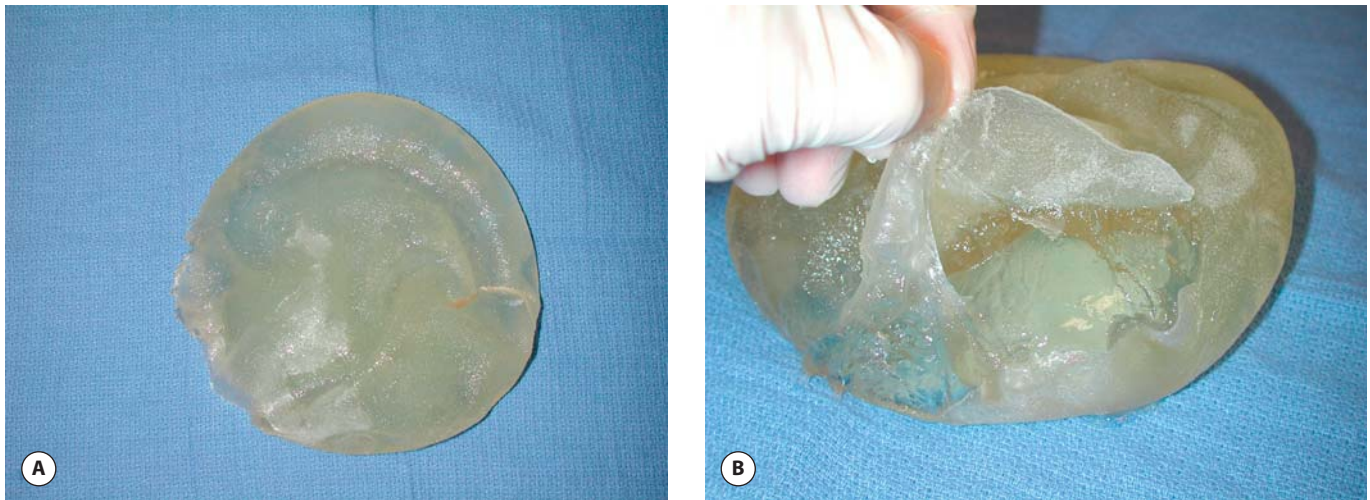


Figure 3.16 (A, B) Appearance of a spontaneously ruptured semi-cohesive, textured, anatomically shaped silicone gel implant after explantation. A mild

capsular contracture created sharp folds in the implant, which resulted in a stress-related crack in the shell with eventual failure of the device.

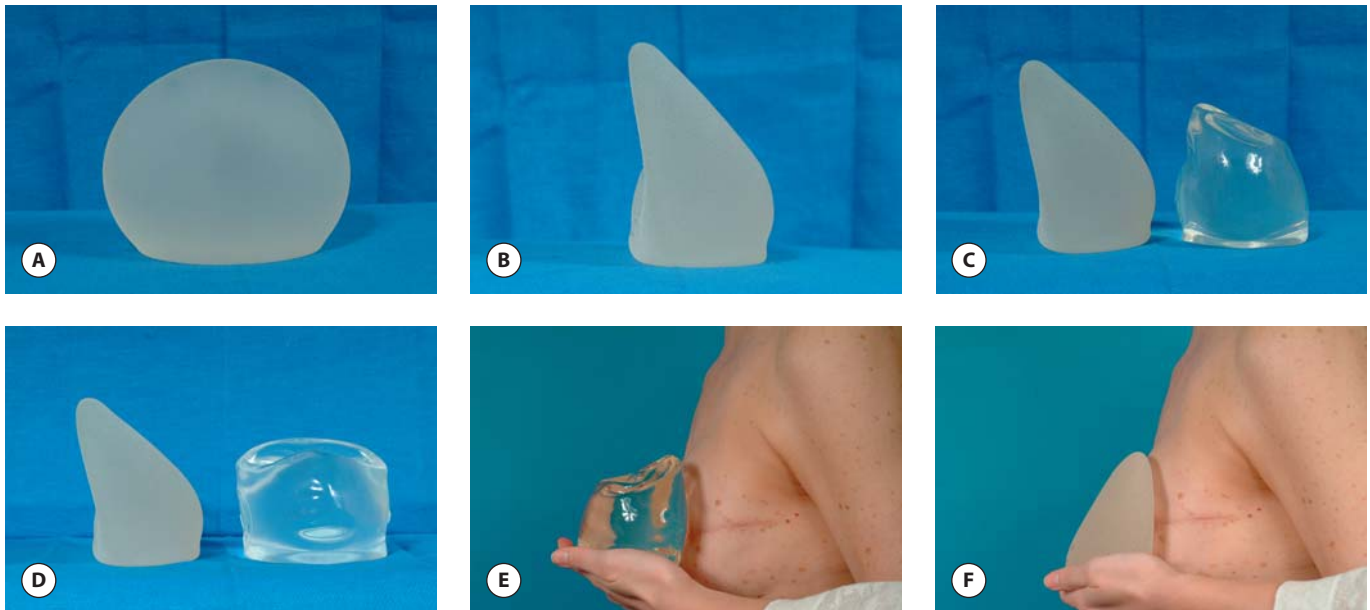


Figure 3.17 (A, B) Front and side upright views of a textured, anatomically shaped, cohesive silicone gel implant. As a result of both the anatomically shaped shell as well as the firm support provided by the stiffer cohesive gel, the magnitude of the distorting forces that are present about the upper pole of the device are minimized and the implant maintains an anatomic shape without wrinkling even in the upright position. **(C)** Side view of an upright cohesive anatomic implant as compared to an upright round silicone gel device, demonstrating the marked degree of upper pole collapse that occurs

in the round as compared to the anatomic implant. **(D)** Similar observations can be made comparing the anatomic device to an upright saline implant. **(E, F)** Schematic demonstration illustrating the positive effect that the use of a cohesive anatomic implant is postulated to have on the contour of the upper pole of the breast. Because the anatomic implant maintains its shape in the upright position, better control of the upper pole contour of the breast can be afforded with the shaped device.

made the device. As a result, these types of anatomically shaped cohesive gel devices are very resistant to wrinkle or fold formation and therefore are associated with very low rupture rates (**Figure 3.19 A-C**).

Figure 3.20 represents a graphical summary of these concepts. The quality of the aesthetic result is represented on the Y axis and the percentage of filling of the implant relative to the optimal fill volume is represented on the X axis. The left side of the graph demonstrates that the result provided by a relatively underfilled round gel implant with a less cohesive gel consist-

ency which falls to the bottom of the pocket and assumes an anatomic shape is generally very aesthetic. Thinking about it another way, it is the breast that shapes the implant, which is a very versatile and powerful way to use a device. At the other end of the graph is the result provided by a completely filled, anatomically shaped cohesive gel implant, which can also provide a very aesthetic result. In this instance, it is most decidedly the implant which is shaping the breast, which is also an excellent strategy for using a breast implant. It must be noted, however, that when using the anatomically shaped, cohesive gel devices,



Figure 3.18 (A, B) Cutaway view of an anatomically shaped cohesive gel implant, demonstrating the enhanced support the gel provides for the

implant shell, even in the upright position.

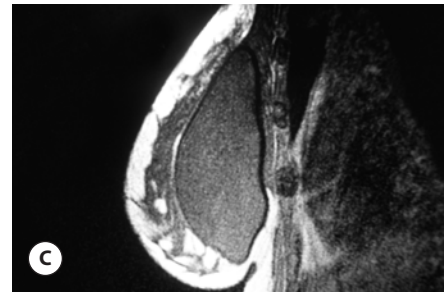
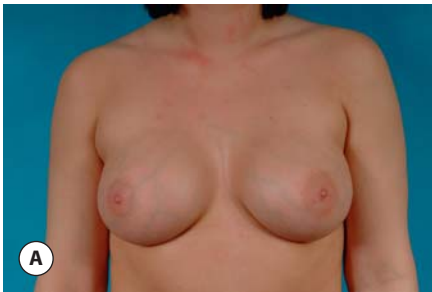


Figure 3.19 (A, B) AP and lateral views of a patient after undergoing breast augmentation with a 280 cc cohesive, textured, anatomic silicone gel implant placed in the subglandular plane. **(C)** The upright MRI

demonstrates that the implant maintains the anatomic configuration in the upright position without the formation of any wrinkles or folds in the shell of the device.

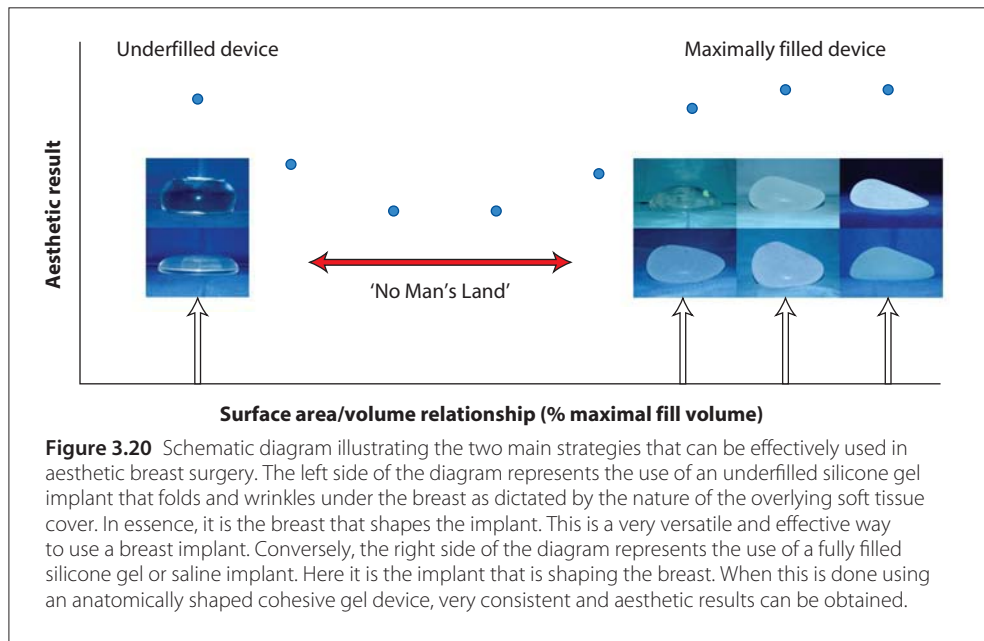


Figure 3.20 Schematic diagram illustrating the two main strategies that can be effectively used in aesthetic breast surgery. The left side of the diagram represents the use of an underfilled silicone gel implant that folds and wrinkles under the breast as dictated by the nature of the overlying soft tissue cover. In essence, it is the breast that shapes the implant. This is a very versatile and effective way to use a breast implant. Conversely, the right side of the diagram represents the use of a fully filled silicone gel or saline implant. Here it is the implant that is shaping the breast. When this is done using an anatomically shaped cohesive gel device, very consistent and aesthetic results can be obtained.

a premium is placed on accurately matching an implant of the proper dimensions to the basic measurements obtained from the patient. Because the implant does not conform at all to pressure from the overlying skin envelope, it must be matched well to

the existing soft tissue framework to provide the best result. For this reason, anatomically shaped cohesive gel devices are generally less forgiving with regard to sizing errors than their smooth round gel counterparts.

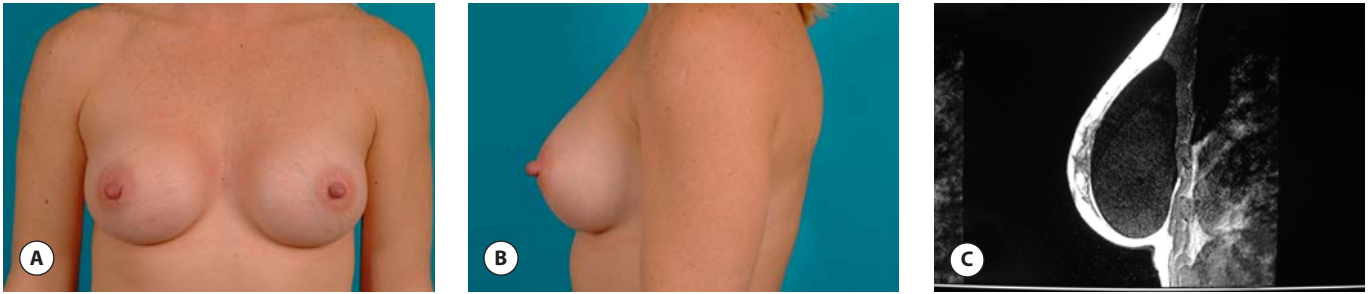

Figure 3.21 (A, B) AP and lateral views of a patient after undergoing breast augmentation with a 310cc high-profile, smooth, round saline implant filled to 350cc in the subglandular plane. (C) The upright MRI demonstrates that the modestly overfilled implant remains fully inflated in

the upright position with no wrinkling being evident in the implant shell. Despite the use of a high-profile saline implant in the subglandular plane, a complementary interaction between the implant and the soft tissues has resulted in an aesthetic breast contour.

Special note must be made regarding the center portion of the graph. Here, the aesthetic quality of the result has been denoted as being less favorable as compared with the results obtained using the devices noted on either end. The reason for this is related to both the fluid characteristics of the filling material and the shape of the implant shell. As noted earlier, underfilled round implants will form wrinkles when placed upright under the breast. When the implant is a silicone gel device made with a gel that has a soft consistency, the wrinkles tend to fold smoothly and are much less likely to create a visible surface irregularity. Therefore, although the potential for fold flaw failure in these devices is present, experience has shown that these implants can last for decades without rupturing. However, with saline implants, the wrinkles that form tend to be more sharply demarcated and create a sharper edge in the implant shell. The same is true for any type of round or anatomically shaped cohesive gel device that is underfilled. If the stiffness of the gel is not sufficient to support the shell, very sharply demarcated folds will form particularly across the upper pole. Not only does this pose a risk for potentially creating a visible contour deformity in the breast, but the folded shell edge will weaken over time, ultimately leading to implant rupture. One strategy that can be utilized to combat this tendency for a saline implant to wrinkle in the upper pole is to overfill it slightly to help ensure that the volume of the upper pole will be maintained when the device is placed upright (Figure 3.21 A–C). Caution must be used in these circumstances, however, as, while this strategy may help reduce the tendency for the implant to demonstrate upper pole wrinkling, it also tends to create a rounded appearance that might become objectionable in thinner patients.

Surface Texturing of Breast Implants – Historical Perspective

It was not long after the introduction of the very first generation of silicone gel implants that an anatomically shaped version became available. Intuitively it made sense, even in those early days of implant experience, that if the device was anatomically shaped, a more aesthetic result could be created using such a device. The problem of rotation was recognized early on and one of the first anatomically shaped devices available for general use was manufactured with a series of dacron patches attached to the back. These patches incited a tenacious tissue ingrowth response which locked the device into position and prevented rotation. Unfortunately, these implants were also associated with

a capsular contracture rate which approached 100%. The dacron patch was thought to be at least partially responsible for this unacceptably high capsular contracture rate and this device fell from favor (Figure 3.22 A–D). During this time period from the late 1960s and into the 1970s, other design modifications were investigated including the development of saline devices, double-chambered devices and various types of gel implants, most with a ‘round’ shape, and the concept of an anatomically shaped implant became a distant concern. Ultimately, an implant coated with a thin layer of polyurethane foam was developed in an attempt to alter the surface interaction of the device with the surrounding capsule (Figure 3.23 A–C). The resulting capsular contracture rate associated with these devices was very low and ultimately several different designs became available including a round version known as the Meme implant and an anatomic version known as the Replicon (Figure 3.23 D,E). Since that time, several other manufacturers have developed similar devices. This was a critical moment in implant design as it represented one of the first attempts to merge the concept of a using a shaped device with a textured surface that promoted capsular ingrowth. By using this strategy, the shaped device becomes locked into position such that it cannot rotate postoperatively, a critical factor in effectively using a shaped implant. The early shaped polyurethane-coated devices were only mildly anatomic and still maintained a fair amount of upper pole fullness. As a result, early efforts to improve the anatomic shape provided by the devices included a technique of implant ‘stacking’. This involved using a round polyurethane-coated base implant and then positioning, or ‘stacking’, a smaller round polyurethane-coated device on the lower pole of the base implant in an attempt to increase the overall lower pole projection of the breast. The friction provided by the polyurethane coating, along with the tissue ingrowth which occurred along the surface of the devices, tended to maintain the position of the two implants on top of one another to create an overall anatomic appearance.

The mechanism of action for the reduced rate of capsular contracture associated with the use of polyurethane-coated implants was eagerly investigated. It had been demonstrated previously that the polyurethane foam lattice network of the polyurethane foam-coated implant underwent gradual degradation over time and that, histologically, multinucleated giant cells could be identified in microscopic sections of capsules from patients augmented or reconstructed with polyurethane foam-coated devices. Small defects could be seen in the foam structure indicative of this gradual degradation. Eventually, over a span

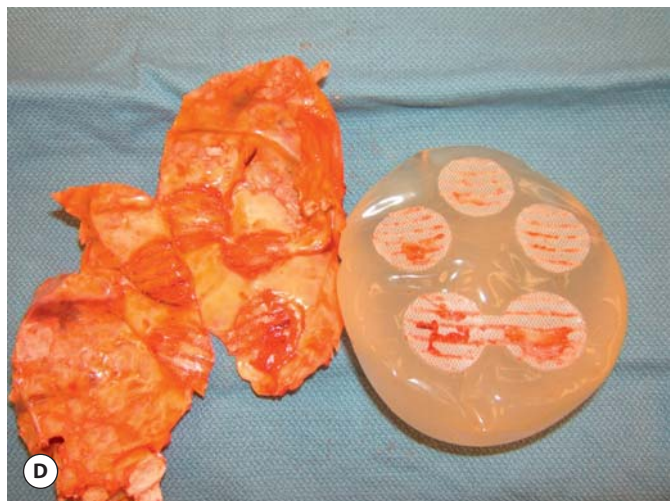
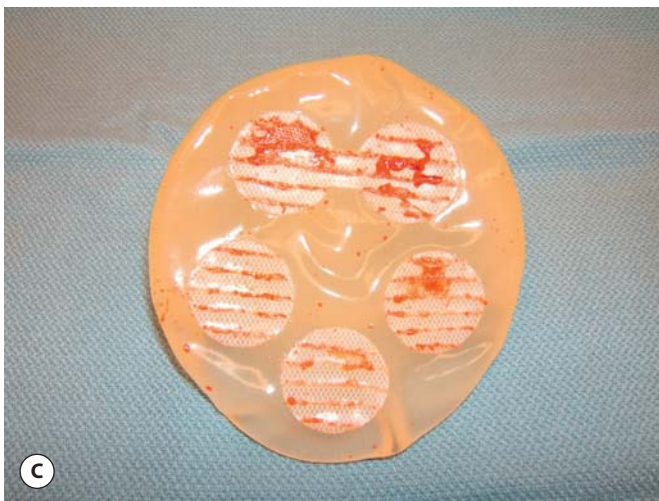
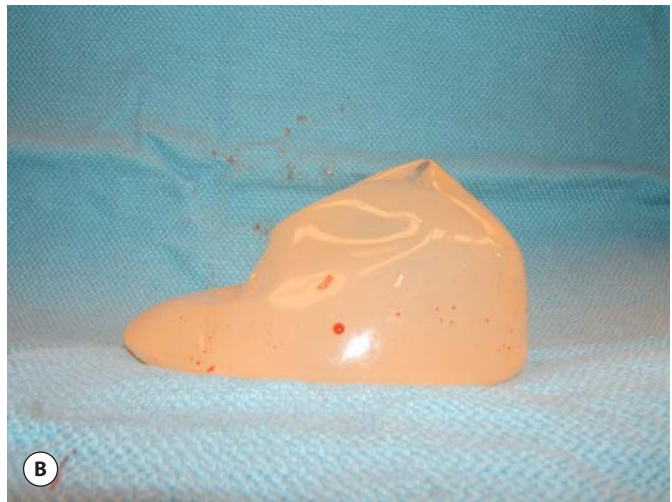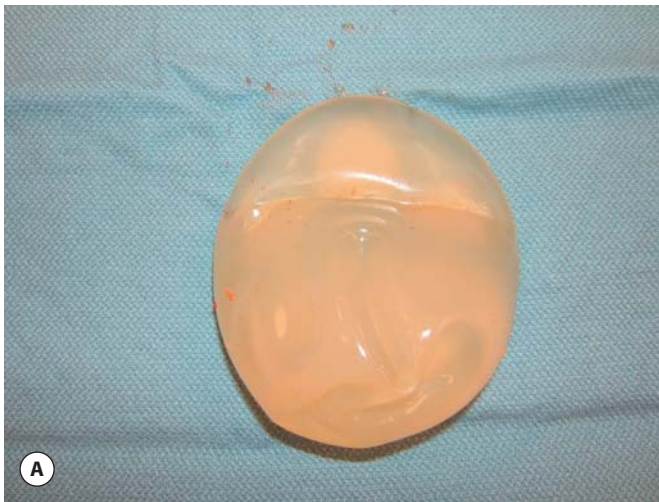Figure 3.22 (A, B, C) AP, lateral and posterior views of one of the early shaped silicone gel implants manufactured with five separate dacron patches on the back. These patches were designed to help hold the anatomic device in the proper orientation. **(D)** Appearance of the capsule

after complete capsulectomy. Note the mirror image dacron patch imprints made in the capsule. These patches functioned solidly to bond the patch to the posterior capsule.

of up to 20 years, it has been demonstrated that the foam covering is completely digested away, converting the device into a smooth-walled silicone gel implant (see [Figure 3.23 F,G](#)). Coincident with this complete removal of the foam covering has been the development of a contracture in some patients. As a result, it is generally accepted that this mild chronic inflammatory response was either responsible for, or indicative of, a process which prevented the capsule from contracting. Once this foam lattice network was completely removed, the device became simply a smooth round gel implant with an associated rate of capsular contracture indicative of any smooth round gel device. As a by-product of investigation into this process of gradual foam degradation, claims were made that certain breakdown products of the metabolism of the foam were carcinogenic. Although later shown to be of no significant consequence, the results of these claims led to the discontinuation of polyurethane foam-coated implants from production, at least in the USA. Also, the design and use of anatomically shaped implants was sharply curtailed due to the loss of the ability to ensure the devices would maintain their proper orientation.

With the loss of polyurethane foam as an interface between the shell of the implant and the surrounding capsule, efforts were made to replicate in other ways the polyurethane effect. As a result, several different types of surface texturing of standard silicone breast implant shells were developed, each attempting to break up the linear deposition of collagen in the capsule that eventually forms around the implant. Essentially, two different types of surface textures have persisted and are commonly used today in both implants and expanders.

Biocell

This surface texture is manufactured by layering salt granules into a tacky implant shell and then washing them out once the shell has completely cured. The result is an open pore lattice network that creates a roughened surface to the device ([Figure 3.24 A-C](#)). Because this is the most aggressive of the textures, actual ingrowth of the capsule can occasionally be demonstrated, particularly when used with tissue expanders, which creates an interesting

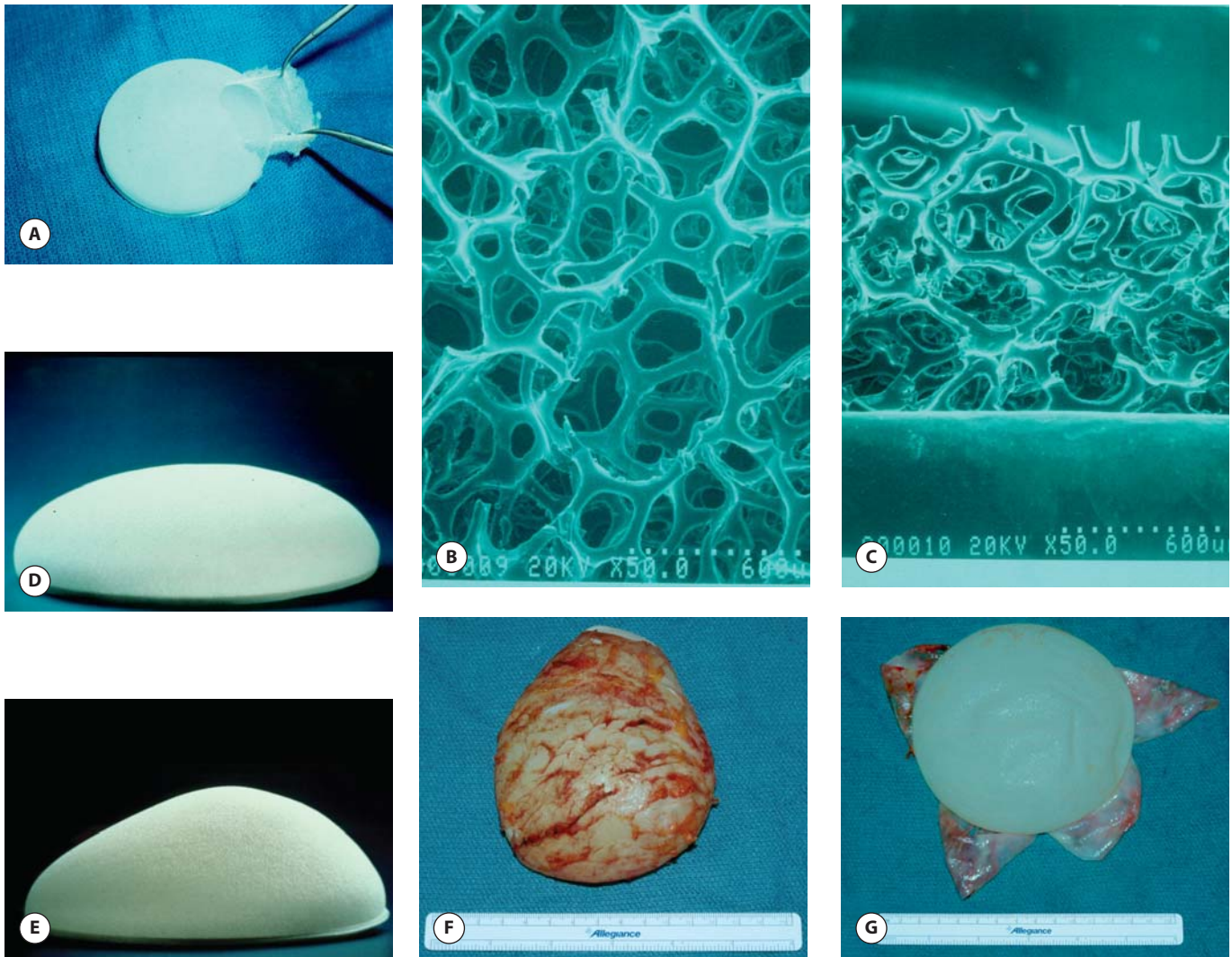


Figure 3.23 (A) A polyurethane foam-covered implant. Here the thin layer of foam has been partially freed from the surface of the device to reveal the underlying implant. (B, C) Scanning electron micrograph of the foam structure reveals an open lattice network that allows ingrowth of the capsule into the foam. (D) The Meme implant manufactured by Surgitek combined the polyurethane foam covering with a round silicone

gel implant. (E) The Replicon implant, also manufactured by Surgitek, combined an anatomically shaped gel implant with the polyurethane foam covering. (F) Appearance of a Meme implant that has been removed along with the investing capsule. (G) After cutting the capsule free, the dimensions of the implant are restored. The foam has been completely broken down over time, leaving behind the silicone gel implant.

Velcro-like effect once the device is removed and the capsule is forcibly separated away from the textured surface (Figure 3.24 D). Although the effect of textured surfaces on the rate of capsular contracture remains controversial, there is no doubt that, when textured ingrowth of the capsule occurs, the device is locked into position and cannot rotate. This finding greatly facilitated the subsequent development of a new generation of anatomically shaped tissue expanders and implants and was perhaps one of the most important advances in implant technology in the modern era. Unfortunately, ingrowth of the capsule into the Biocell textured surface is an unpredictable occurrence. Certainly with the anatomically shaped tissue expanders used today, as the device is expanded, the shell of the expander is forced into the capsule as the pressure in the expander increases with each inflation. As a result, it is very common to be able to

demonstrate textured ingrowth into the surface of the device when the expander is removed and replaced with the permanent implant. Even here, however, ingrowth is very often incomplete and portions of the surface of the expander do not demonstrate any ingrowth. But there is usually enough to stabilize the anatomic expander in position and nearly every tissue expander manufactured today has some type of textured surface to help stabilize expander position and orientation. With anatomically shaped implants, however, the compressive forces around the implant are invariably less vigorous and there is less impetus for the capsule to grow into the Biocell textured surface. As a result, textured ingrowth is found much less commonly in both round and anatomically shaped implants.

One interesting observation noted with Biocell textured devices is the occasional formation of a 'double capsule' around

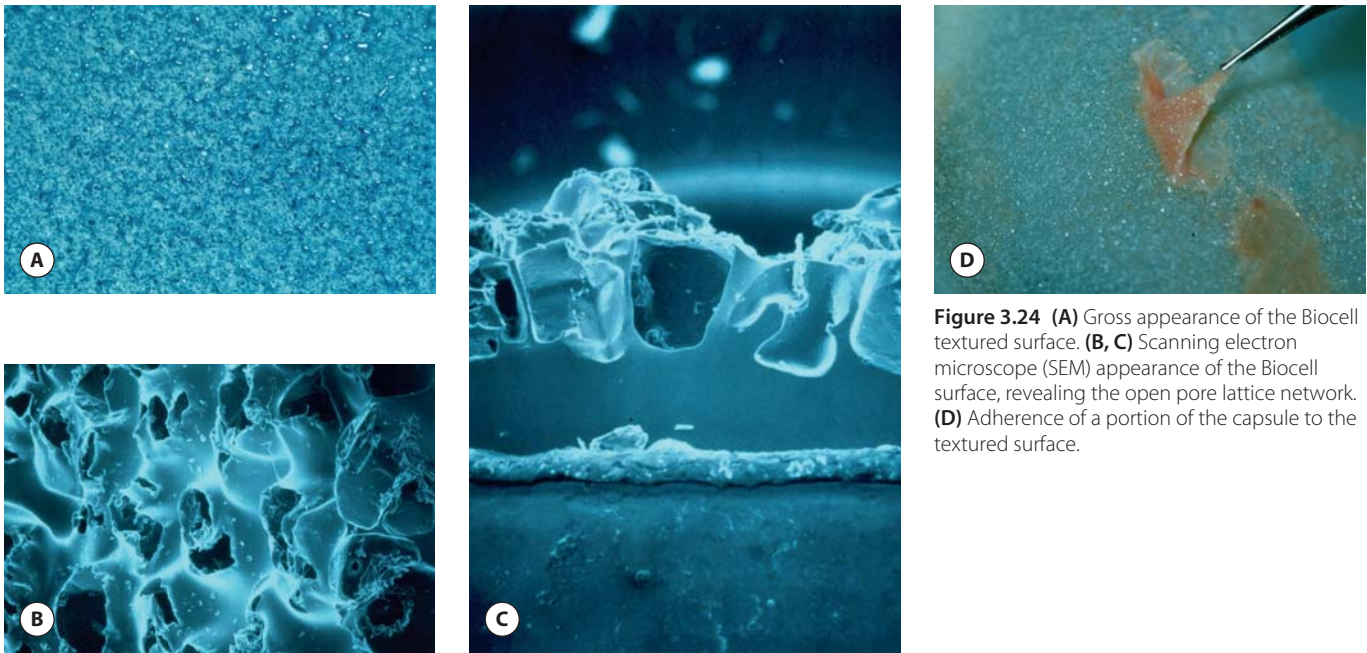


Figure 3.24 (A) Gross appearance of the Biocell textured surface. (B, C) Scanning electron microscope (SEM) appearance of the Biocell surface, revealing the open pore lattice network. (D) Adherence of a portion of the capsule to the textured surface.

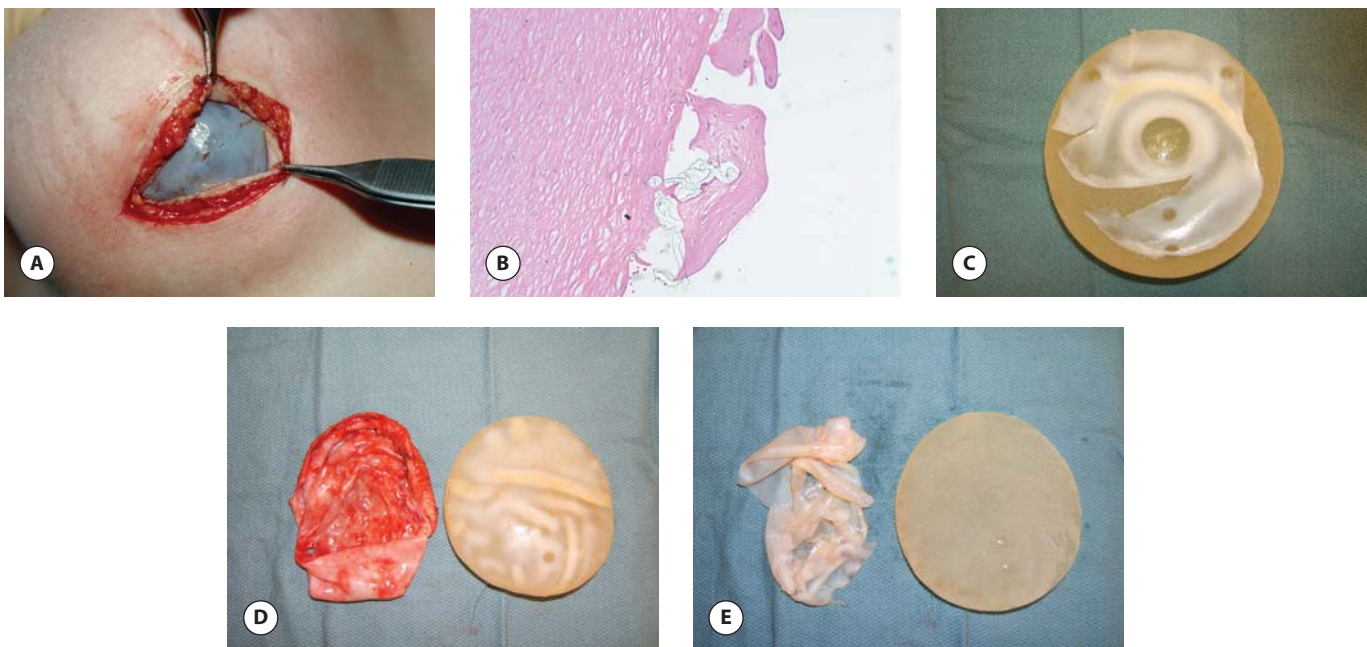


Figure 3.25 (A) Appearance of the inner pseudocapsule attached to the Biocell textured implant. (B) Histologic appearance of the inner capsule reveals a sparse population of fibroblasts in association with a multilaminar layered collagen matrix. Small retractive bodies are present in the surface and represent small pieces of silicone rubber from the textured surface that were broken off when the capsule was peeled away from the implant. (C) Appearance of the posterior surface of a

Biocell textured implant, demonstrating partial coverage of the posterior portion of the device with an inner pseudocapsule. (D) Appearance of a Biocell textured anatomically shaped cohesive gel implant along with the capsule that surrounded it. The implant is completely coated with an inner pseudocapsule. (E) Appearance of the implant after the pseudocapsule is peeled away from the implant.

the implant. Inside the capsule that forms in association with the surrounding soft tissue of the pocket is a second pseudocapsule that becomes densely adherent to the textured surface of the device (Figure 3.25 A). This inner capsule has a smooth outer

surface and demonstrates solid ingrowth into the textured surface that must be peeled away from the implant to be effectively removed. Histologically, this tissue is characterized by a multilaminar scaffold of collagen within which is interspersed a sparse

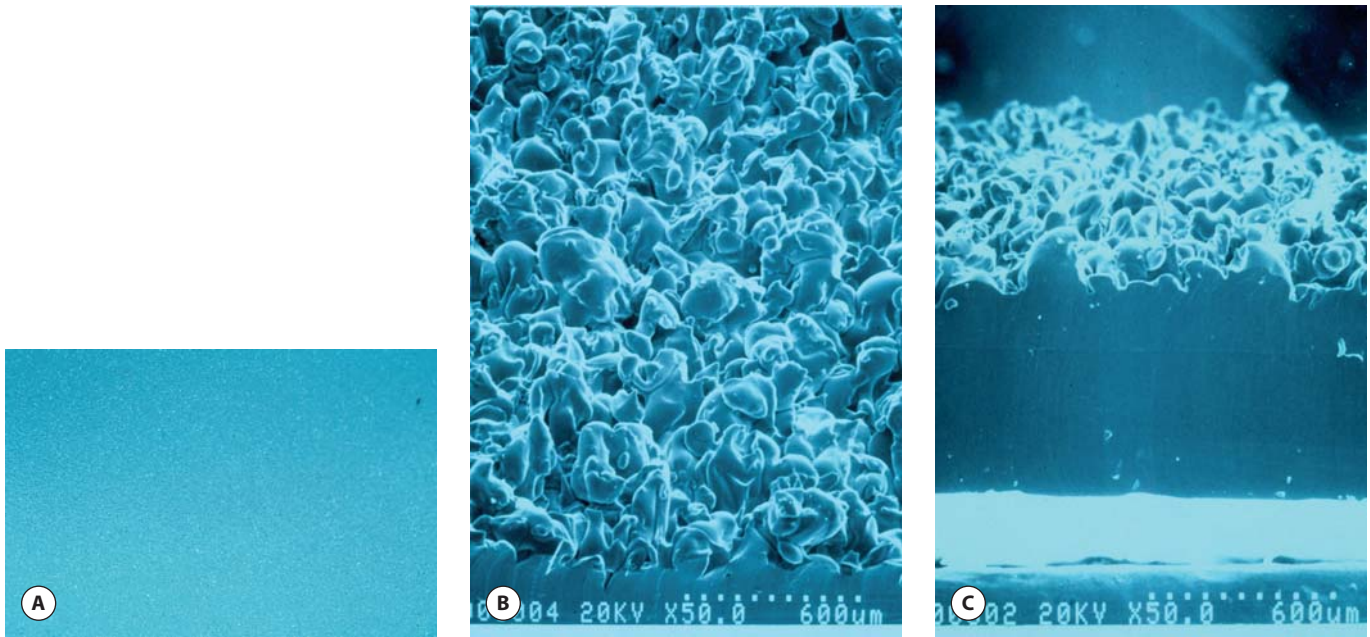


Figure 3.26 (A) Gross appearance of the Siltex textured surface.

(B, C) SEM appearance of the Siltex textured surface.

population of fibroblasts (Figure 3.25 B). This is an extremely interesting finding given that the inner capsule is a separate tissue layer that maintains no direct link to the surrounding capsule and therefore has no apparent source of vascular supply. It can be postulated that these cells have a very low metabolic requirement and are surviving on diffusional sources of oxygen and energy alone. One possible etiology for the formation of the inner capsule may be related to seroma formation in the pocket around the implant, although exactly how the fibroblasts are able to populate the surface of the device and then proliferate enough to form a distinct fibrous layer remains unknown. In most instances, the development of an inner capsule is a benign occurrence that only partially involves the surface of the implant and, as such, simply represents an area where the outer capsule cannot grow into the textured surface of the device (Figure 3.25 C). Occasionally, however, the implant becomes completely surrounded by the fibrous layer of the inner capsule and since the interspace between the two very smooth capsules is mildly lubricated, the implant can rotate and flip in the pocket with ease. As a result, when double capsule formation occurs in association with a shaped implant, the risk of undesirable implant rotation becomes greater (Figure 3.25 D,E).

Siltex

This surface texture is manufactured by pressing a layer of polyurethane foam into a thin tacky sheet of silicone rubber which has been affixed to the shell of an otherwise smooth implant. In this fashion, an imprint of the irregular polyurethane foam surface is reproduced on the surface of the textured device. This design was meant to duplicate the pore size of the interstices of the native polyurethane foam and thus, theoretically, duplicate the positive effect polyurethane has on reducing the rate of capsular contracture. The net effect of this technique is a less aggressive texture which does not promote tissue ingrowth (Figure 3.26 A-C).

The effect of this texture, and also, the Biocell texture when ingrowth does not occur, is to provide a rough surface that tends to stabilize the implant and inhibit sliding of the implant across the smooth surface of the capsule. It is analogous to the effect the ridges present in fingertips have on grasping ability. By creating a rough surface on the device, sufficient friction is created to inhibit implant rotation and, along with other factors such as pocket dimensions, help keep an anatomically shaped tissue expander or implant properly oriented.

Capsular Contracture

Although textured surfaces can assist in preventing implant rotation, the major impetus for designing the various types of textures was to mimic the effect that polyurethane foam had on capsular contracture. Since their introduction, many reports have focused on this very issue and, at this point, the question of whether or not textured surfaces reduce the rate of capsular contracture remains unanswered. Despite the differences which have been described between the two types of textures, several well-designed studies appear to show a reduction in the rate of capsular contracture using both textured surfaces. Conversely, there are other studies which demonstrate no protective effect. To accept the hypothesis that surface texturing of a silicone shell will prevent capsular contracture, a viable mechanism of action must be presented. One theory is based on the fact that the capsule becomes disorganized as it grows into the interstices of the textured surface and this somehow inhibits the ability of the capsule to contract. In fact, the collagen layers outside the zone of ingrowth become layered as in any other capsule, rendering this hypothesis questionable at best. Also, I have seen many instances of a severe capsule formed around a Biocell textured device where there was near complete ingrowth of the inner layers of the capsule into the textured surface, with no apparent protective effect on the development of the contracture.

Additionally, if textured ingrowth was responsible for reducing the capsular contracture rate, then the Siltex surface should not be associated with any similar effect since it does not promote tissue ingrowth. Yet, several studies show a positive effect with the Siltex surface. Finally, the effect of polyurethane foam was to create a low-grade inflammatory response in the capsule. Somehow, this observation was linked to reduction in the rate of capsular contracture. There is no such low-grade inflammatory response in the capsule which forms around a textured implant. Looking at all these data as objectively as possible, it is difficult to conclude with certainty what effect surface texturing has on the rate of capsular contracture. Currently, it is my opinion that textured surfaces do not impact significantly on the rate of capsular contracture. Future studies hopefully will shed further light on this important question.

Implant Types

Round

As noted previously, what are commonly referred to as 'round' implants are actually shaped devices that are asymmetrical in the sagittal plane. For the purposes of this discussion, 'round' will refer to any device in which the horizontal width and vertical height are the same and the shape of the implant on either side of these reference lines is symmetrical. With this as a basic definition, there are a whole host of different round devices available from several different manufacturers. Between the different styles of round devices, there are subtle differences in the shape of the peripheral margins of these various implants. In some, the radius of the peripheral edge lies midway up the overall vertical height of the device. Others keep the apex of this peripheral margin closer to the base of the implant (Figure 3.27). This variable is controlled by the shape of the mandril that made the shell. Although this difference is subtle, such design features can provide an advantage. By using implants that have a peripheral radius located closer to the base of the implant, a less dramatic contour change is created between the implant and the chest wall, which can provide a more natural-appearing result with less of a contour break in the upper pole of the breast in thin patients, or patients with ptosis.

Round devices can be filled with saline or gel, with some specialty devices being a combination of the two. One of the obvious advantages associated with a saline device is the ability to control the volume, whereas with a silicone gel-filled device, the

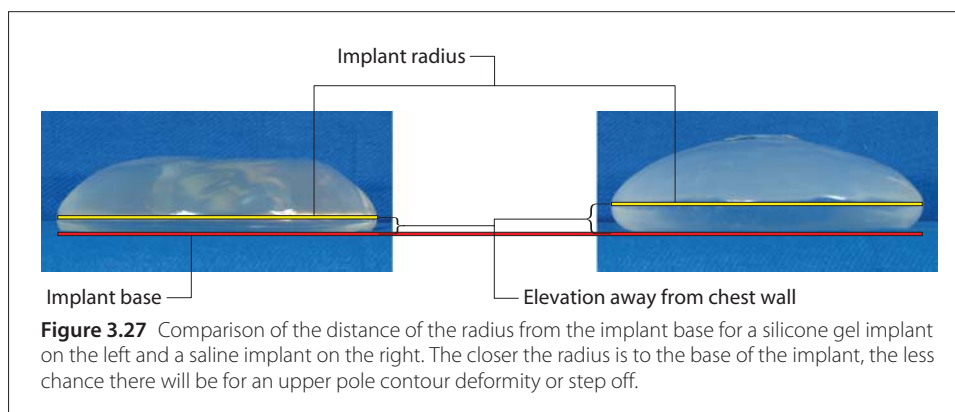
volume is fixed. The round combination devices offer the softness and versatility of an outer silicone gel layer with an inner saline bladder which affords volume adjustability. Typically, these combination devices have a remote fill valve which is eventually removed once the final volume is chosen.

Round implants are made with several different projections or profiles, with most manufacturers offering three, which are variously referred to as low-, mid- and high-profile devices. These profile differences can impact significantly on the performance of a round implant and strategically utilizing these profile differences can improve the results obtained in aesthetic breast implant surgery.

In order to understand the effect of projection on the performance of a breast implant, it is helpful to analyze it in conjunction with the other two variables which govern implant design, namely volume and dimension. This will be discussed in more detail in Chapter 4, which deals with breast augmentation. But to summarize, when volume is held constant for a particular implant, as projection increases from low to mid to high, the base diameter of the device decreases (Figure 3.28 A,B). This makes intuitive sense since more of the volume is concentrated in the central portion of the device, to provide the increased projection, therefore there can be less to distribute peripherally, which results in a decrease in the horizontal and vertical dimension of the implant. Therefore, for a given implant volume, there will be three categories of projection to choose from and, as projection increases, the base diameter of the implant decreases. This basic relationship has several implications for use in aesthetic breast surgery.

Shape As the projection of a round implant increases, the contour change in the upper pole of the breast as the implant lies against the chest wall becomes more abrupt. In thin patients, this can create an artificial 'augmented' appearance, which may be undesirable in some patients. Also, the narrowed base diameter may not fit well with the pre-existing dimensions of the native breast. Alternatively, a low-profile device may create a smoother contour break in the upper pole of the breast, but yet the associated base diameter might be excessive. Correctly balancing these variables for a given patient can improve the aesthetic results obtained using round implants.

Wrinkling A moderate-profile implant will have a relatively widened width and height as compared to the projection. In essence, it is more dramatically 'shaped' than a high-profile device,



where the measured width, height and projection are relatively more closely aligned. As a result, when the moderate-profile device is placed upright, it has a greater tendency to collapse and wrinkle than the high-profile implant. Where this functions as an advantage is in the breast which has a lax skin envelope. Here, in the ideal setting, the moderate-profile implant will fold, wrinkle and finally settle to the bottom of the pocket, assuming the shape dictated by the influences of the overlying soft tissue framework. As was noted previously, this is a very versatile way to use a breast implant, as long as the wrinkles are not visible and do not appreciably weaken the shell. If, however, after breast augmentation, folds and wrinkles are visible in the breast, using a high-profile device may be one potential solution as the tendency to form prominent folds and wrinkles is less for a high-profile device in the upright position.

Rebalancing the skin envelope to volume relationship One of the aesthetic goals of breast augmentation is to fill out the skin envelope in patients who demonstrate any degree of skin laxity preoperatively. In these patients, utilizing a moderate-profile implant may be a less than ideal choice as it is likely that the limits of an appropriate base diameter choice may be reached before a volume adequate enough to completely fill out the skin envelope is provided. The result could well be a loose and ptotic breast with the nipple-areola complex (NAC) hanging off the contour created by the breast implant, or what has been referred to as a 'double bubble' deformity. In this case, a high-profile device would be a better choice as the laxity of the skin envelope in the sagittal plane is taken up by the increased projection of the device and volume is not wasted in the horizontal and vertical dimensions.

Dual-chambered Implants

As an extension of the round implant design, dual-chambered combination gel/saline implants have been developed. These devices combine an outer soft silicone gel layer with an inner saline bladder connected to a fill tube which runs through the gel layer to a remote fill valve. In this fashion, the implant combines the soft feel of a silicone gel implant with the volume adjustability of a saline device. Clinically, the device is inserted and the volume adjusted using the remote fill valve. If desired, the final volume can be added immediately and the fill valve simply removed to engage the self-sealing valve attached to the tubing inside the device. Alternatively, the remote valve can be buried

at a selected site in the surrounding soft tissues and the volume can be adjusted postoperatively by accessing the palpable valve and filling the inner saline bladder to the desired amount. At a second procedure, the fill valve is exposed and removed as before. Although this strategy could be employed in breast augmentation, it has yet to gain wide popularity. It is much more common for this device to be used in breast reconstruction after mastectomy, where the device functions as both the expander and the eventual implant.


Anatomically Shaped Saline Implants

With the advent of silicone texturing of the outer shell of breast implants and the realization that surface texturing could stabilize the shaped devices into position came renewed interest in the development of anatomically shaped breast implants. From an historical perspective, this timeline coincided with the United States government's review of the safety data regarding silicone gel implants, which ultimately resulted in severe restrictions being placed on the use of these devices. As this Food and Drug Administration (FDA) review proceeded over the ensuing years, implant design modifications were focused on saline-filled devices, which resulted in several different types of anatomically shaped saline implants being developed (Figure 3.29 A,B). Each of these devices was constructed using an anatomically shaped mandril with varying degrees of shape. Although initially received with enthusiasm, these devices fell from favor and failed to generate sustained positive results for several reasons.

Shape The same filling issues discussed with regard to round devices are applicable for anatomically shaped saline devices. There is a filling window below which wrinkles form and above which edge scalloping results. However, the fact that the device was constructed to present and maintain a specific orientation altered these dynamics slightly. As has been noted, when a saline implant is placed upright, the very minimally cohesive fluid drops to the bottom of the device and any degree of underfilling promptly results in collapse of the upper pole. In fact, even if the device is filled to the optimal fill volume, in the upright position there continues to be a mild fluid shift inferiorly, which can result in loss of volume in the upper pole with collapse. Therefore, to counteract completely any tendency for the implant to deform in the upright position, a mild overfilling strategy is optimal. This tends to work against the shaped concept as a mild bulging of the upper pole of the implant can

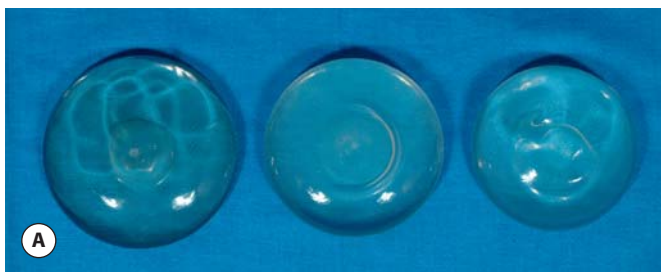

Figure 3.28 (A, B) Appearance of a moderate-profile (left), moderate plus-profile (center) and high-profile (right) 300cc smooth-walled silicone gel breast implant as seen from above and from the side. Note that the



horizontal width and the vertical height all decrease as the projection increases.




Figure 3.29 (A, B) Various designs of anatomically shaped saline implants.

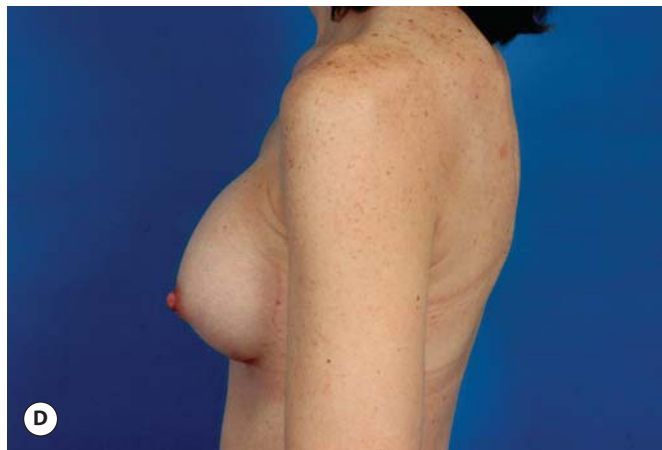
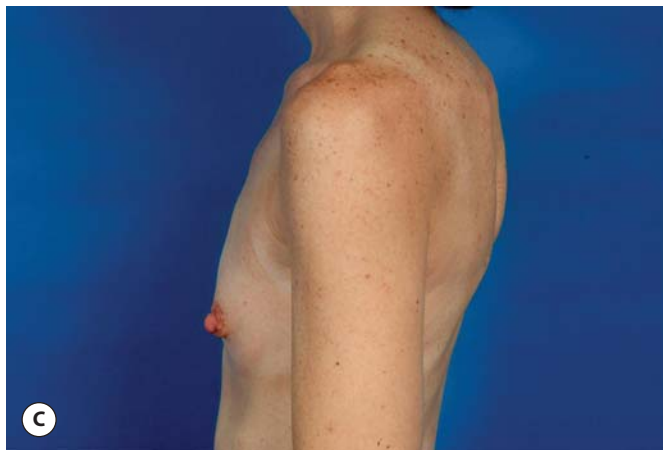
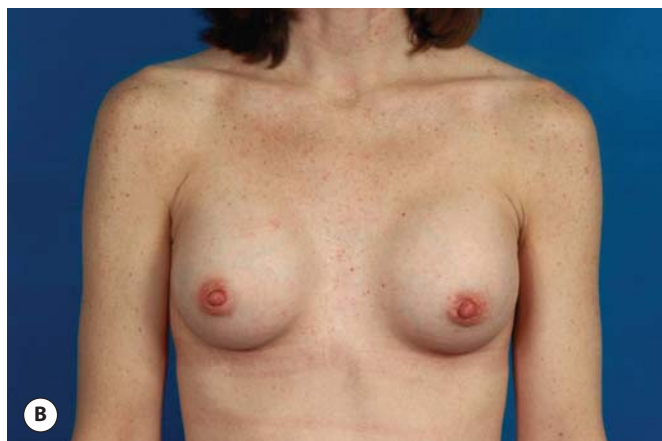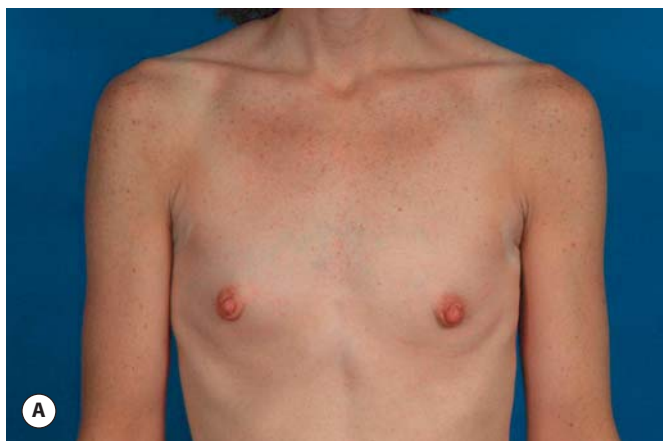Figure 3.30 (A–D) Postoperative result after undergoing partial subpectoral breast augmentation with an anatomically shaped saline implant. Paradoxically, as a result of having to overfill the implant to

prevent upper pole collapse in the upright position, a contour deformity is actually created in the upper pole of the breast.

result and a common complaint associated with the use of these devices is that the patients demonstrate too much upper pole fullness (Figure 3.30 A–D). Also, any degree of overfilling of the implant tends to create a firmer breast than was perhaps normally found with round saline implants or silicone gel devices. This phenomenon was more evident with the taller height versions of the anatomic saline implants, with shorter height devices being somewhat immune to these problems. Because of the reduced vertical dimension, the fluid shifts were less marked

in the shorter implants, making them easier to use. However, one unfortunate outcome of this experience, which was the first experience many surgeons had with shaped devices, was the impression that the shaped concept was not valid and offered no particular advantage in aesthetic or reconstructive breast surgery. The simple fact was that, for a variety of reasons, these early shaped saline implants were not anatomic enough to demonstrate effectively the improved results that are possible with the use of properly shaped devices.

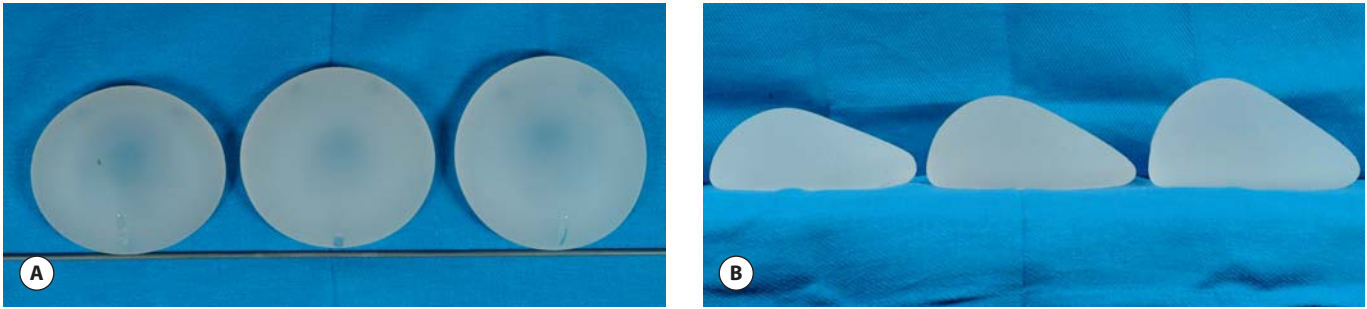


Figure 3.31 (A, B) A family of anatomically shaped, textured, cohesive gel breast implants (CPG – Contour Profile Gel, Mentor Corporation) is shown,

demonstrating three different heights and three different projections.

Rotation One new concern associated with the use of a device that was designed to maintain a specific orientation was post-operative rotation with an associated deleterious effect on the shape of the breast. As was noted previously, the textured surfaces used on these devices resulted in tissue ingrowth somewhat sporadically. When ingrowth does occur, the device is locked into position and cannot rotate. When ingrowth does not occur, implant rotation becomes a possibility. For this reason, operative technique becomes an important variable when using not only anatomically shaped saline devices but anatomically shaped gel devices as well. It is important that the pocket not be over-dissected to help prevent the implant from slipping out of position.

Rupture It can be said that the two most stressful days in the life of an implant are the day it is textured and the day it is inserted. Insertion places stress on an implant for obvious reasons as the shell is stretched and manipulated in an effort to slide the device through a small incision into a pocket. However, the process of texturization is also a stressor for the implant shell. With the Biocell surface, the salt granules used to create the open pore lattice network in the shell must be scrubbed away after the silicone cures. With Siltex, the implant shell is aggressively stretched over a disc before the thin sheet of textured silicone is attached to the surface. Both techniques place mechanical stress on the implant shell. Also, both techniques increase the thickness of the implant shell. The thicker shell is less pliable and subject to the formation of harder, sharper wrinkles than smooth-walled devices. The end result is that textured devices tend to be more prone to rupture than their corresponding smooth-walled counterparts. As a result of each of these potential problems, it is easy to understand why the shaped concept was slow to gain acceptance in the plastic surgery community.

Anatomically Shaped Gel Implants

As the previously mentioned FDA review of silicone gel implants was completed, these implants returned to the marketplace under the guise of jointly sponsored clinical studies overseen by both the FDA and the implant manufacturers. Coincident with this return of gel devices for use in breast augmentation and reconstruction was an implant design strategy that focused on applying anatomic principles to silicone gel implants. Using silicone gel as the filling material provides several advantages over saline when using anatomically shaped shells. The cohesive properties of the gel can be altered to make the gel more viscous so that the anatomically shaped shell is better supported. This

helps prevent wrinkling and, in particular, upper pole deformation. Also, sharper contours can be built into the device and a flatter upper pole contour can be manufactured into the shape. In short, the device presents a more aggressive anatomic shape than an analogously shaped anatomic saline device.

As noted previously, because the implant maintains its shape and does not conform to the pressures applied by the overlying soft tissue framework, it is now the implant that is shaping the breast and there is less room for error in appropriately picking an implant for a given patient than with smooth round gel devices. Therefore, it was recognized that a wider selection of devices would be required to meet the needs of a variety of clinical situations. As a result, each manufacturer offers a matrix of devices which vary in height, projection and the degree of cohesiveness of the silicone gel (Figure 3.31 A,B).

When using cohesive gel anatomically shaped implants, several additional factors must be taken into account.

Incision length Because the consistency of the gel is thicker, a larger incision is required to insert the device than with other less cohesive devices. Otherwise the forces required to coax the implant into the pocket could potentially rupture the shell or permanently fracture the gel matrix, resulting in a shape alteration to the implant. For this reason, smaller periareolar incisions and transaxillary incisions are less than ideal choices when using anatomically shaped gel implants.

Orientation Once the device is in the pocket, it must be properly oriented to ensure the optimal breast shape. This can be deceptively difficult to do; therefore, each device has manufactured into the shell various orientation marks which can be palpated and, at times, seen through the incision. By noting the position of these marks, it can be accurately determined that the 12 o'clock position on the implant is located at the corresponding 12 o'clock position under the breast.

Implant height For many surgeons, this is a new variable to consider when it comes to picking a specific implant for a patient. Previously, with round devices, the height was a default dimension and was simply the same measurement as the width. With anatomically shaped cohesive gel devices, the height can and should be carefully matched to the patient's body habitus and breast size to avoid overfilling of the upper pole of the breast. Simple stated, smaller patients with smaller breasts do better with low- to mid-height devices, whereas taller patients with broader chests are better candidates for full-height devices.

Personal Thoughts

At first glance, breast implants appear to be simple devices. However, designing, manufacturing, using and understanding breast implants can be a surprisingly difficult task. For patients who have a thick soft tissue layer over the chest wall, these decisions are not so hard and basically any type of implant will provide variably excellent results. Where the difficulty arises is in just those patients who tend to present for breast augmentation, namely women who have a small breast, who are thin and who do not have an adequate soft tissue layer to mask the deficiencies associated with a poorly chosen implant. Here, all these variables come together and a premium is placed on proper implant selection to provide the best result possible.

From my perspective, after having used all of the devices discussed in this chapter, there are several general conclusions I believe to be valid and these conclusions continue to guide my implant selection process today:

- Gel implants are easier to use than saline devices. The fact that they do not need to be filled at the time of surgery eliminates one step in the operative procedure. Also, sizes which exactly reproduce the effect the chosen implant will have on the breast are available and can be used very effectively to increase the precision and reliability of the result. The consistency of the gel creates a softer, more natural peripheral breast contour and an overall softer feel to the breast. When wrinkles and folds do form, they tend to be softer and less visible than with saline devices. As a result, gel devices are more forgiving than saline implants.
- Anatomically shaped implants provide better and more consistent upper pole control than round implants. This is most notably true for cohesive gel implants and not necessarily true for saline devices. I, like many of my colleagues, had difficulty using anatomically shaped saline implants as they tended to create too much upper pole fullness, which was the very contour that was supposed to be controlled. However, with the advent of the various types of cohesive gel devices that have become available, this upper pole control problem was solved and the results I have seen using anatomically shaped cohesive gel implants, not only in my own patients but in the results of surgeons around the world, have been outstanding.
- Surface texturing does not inhibit capsular contracture but it is helpful in preventing rotation of a shaped device. As a result, whenever I use a round device, I prefer it to be smooth. It is easier to insert a smooth device, the shell is thinner, therefore, the wrinkles that do form tend to be softer and potentially the rupture rate will be decreased. The smooth surface also allows the device to settle to the bottom of the pocket more readily and not become inadvertently distorted due to the textured surface hanging up against the surface of the pocket, preventing the device from lying flat.
- The round smooth silicone gel implant still plays an important role in aesthetic breast surgery. Because anatomically shaped cohesive silicone gel breast implants are somewhat more difficult to use, the workhorse device for many surgeons remains the smooth round gel implant. Due to the versatility this device affords in size and projection, it can be used successfully in almost any patient. When the device settles to the bottom of a lax skin envelope and assumes the shape dictated by the various soft tissue forces which overlie it, it almost becomes a custom-made shaped implant, which is a very versatile way to use a device. The question that remains is what effect the resultant wrinkles will have on the long-term rupture rate of these types of devices.

Summary

In this chapter, I have attempted to outline the various physical factors that govern how an implant will perform once it is filled to a certain volume and then placed under the soft

tissue framework of the breast. Understanding and applying these concepts to maximum advantage is vital in order to obtain the best results possible in aesthetic breast surgery.

Breast Augmentation

Introduction

In many respects, breast augmentation is the defining procedure for the aesthetic breast surgeon and the ability to obtain outstanding results in a consistent fashion requires sound judgment, technical expertise and fastidious attention to detail. However, with experience comes the realization that developing this skill is harder than it might first appear to be. Perhaps the most significant reason for this relates to the tremendous variability that exists in the preoperative appearance of patients who present for breast augmentation (Figure 4.1) with differences in body habitus, breast size, nipple position and skin elasticity being just a few of the many variables that can significantly influence the final result. Also, there can be significant variability in the

goals patients have for their surgical outcome. However, perhaps the most stressful facet of the procedure that must always be respected relates to the fact that these patients will almost uniformly have very high expectations for the quality of their result. Coupling all this with the fact that this high-quality result must be delivered in one operation with the barest minimum of complications highlights the importance that a sound surgical strategy performed with exacting technical expertise will have on achieving a successful outcome.

To this end, over the past decade, many of the finer details of the operation have been re-examined and new techniques described, all in the hope of improving the aesthetic results and minimizing complications. However, despite this in-depth review, for many surgeons the subject of breast augmentation

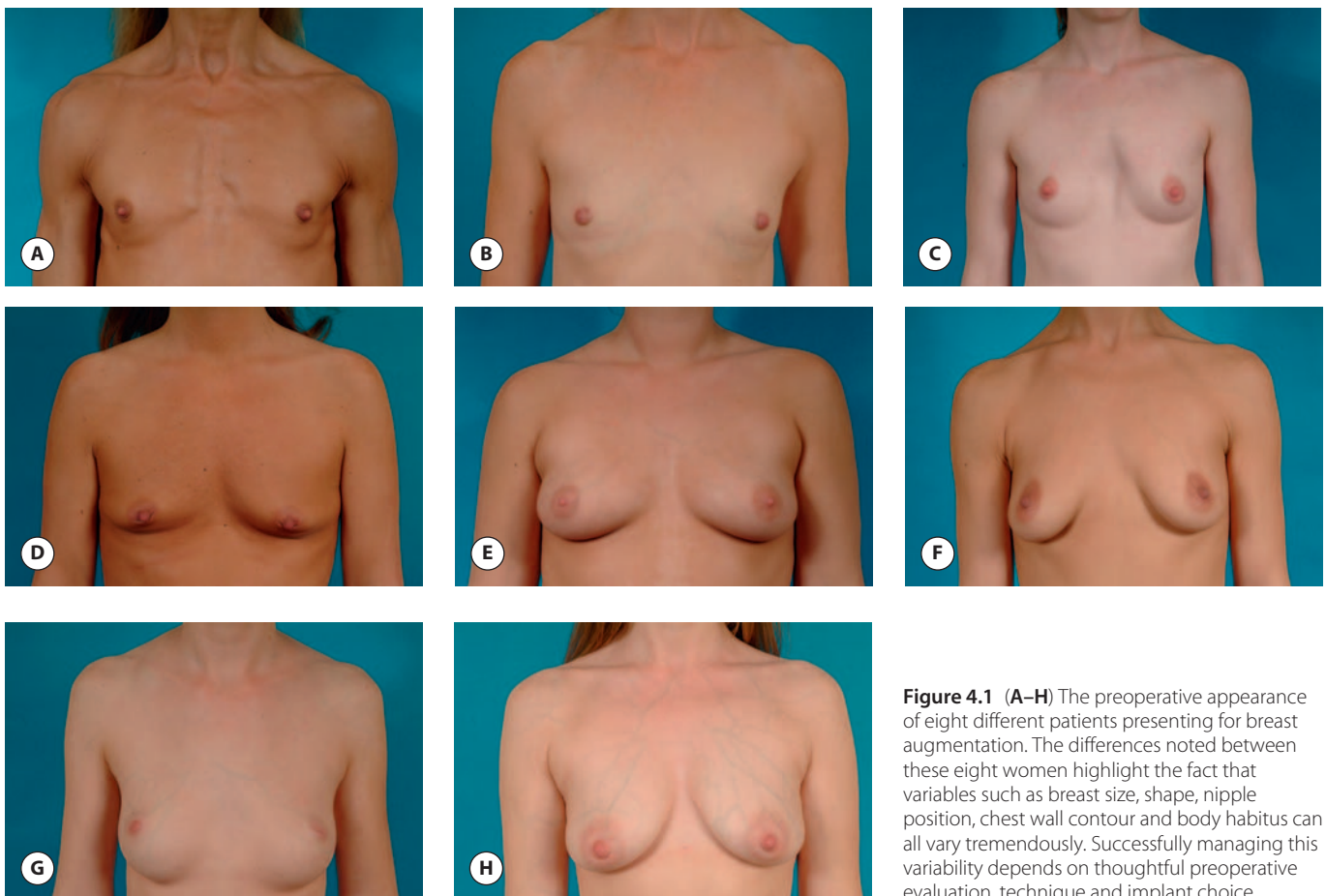
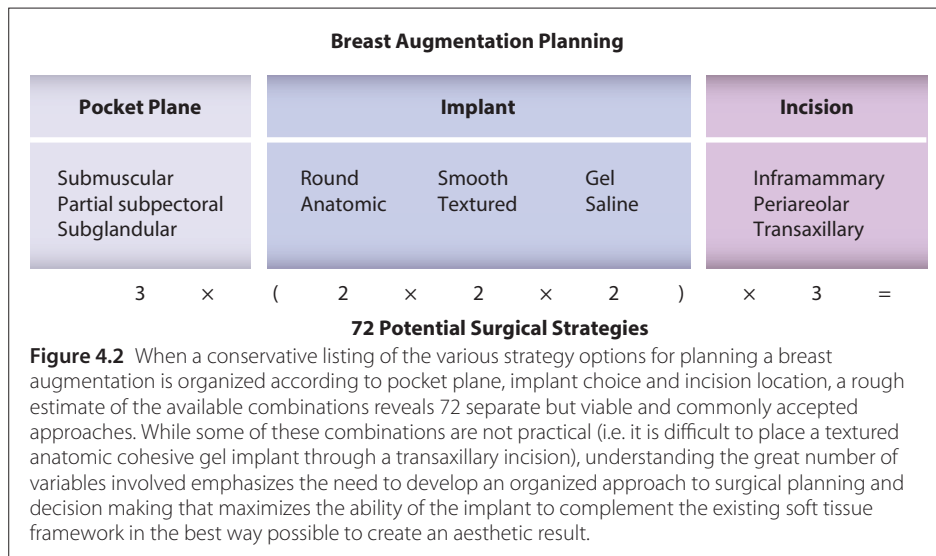


Figure 4.1 (A–H) The preoperative appearance of eight different patients presenting for breast augmentation. The differences noted between these eight women highlight the fact that variables such as breast size, shape, nipple position, chest wall contour and body habitus can all vary tremendously. Successfully managing this variability depends on thoughtful preoperative evaluation, technique and implant choice.



remains as confusing and controversial as ever. This is a direct result of the fact that there are multiple surgical options that can be mixed and matched in numerous ways to create a viable operative strategy (Figure 4.2). For instance, in a given patient one surgeon might choose a smooth round saline implant placed in a partial subpectoral plane through a transaxillary incision, while another might choose a textured round gel implant placed in the subglandular plane through an inframammary fold incision. It is very likely that both approaches would produce equally acceptable aesthetic results that could very well be indistinguishable from each other. Further complicating the matter is the fact that, for nearly every technical decision that is made in planning and executing a breast augmentation, each advantage is directly offset to a greater or lesser degree by a specific compromise or disadvantage. For instance, the subglandular plane can be used to eliminate the potential for postoperative breast animation; however, the risk for a visible implant edge in the upper pole of the breast will be greater. For the novice surgeon, organizing the variables involved in planning a breast augmentation and predicting how the various decisions and approaches will interact with each other can create confusion when attempting to decide the *optimal* surgical approach for a given patient. It is helpful to step back from this confusing and, at times, contradictory exercise and realize that the basic procedure of breast augmentation simply involves making a pocket and inserting a spacer (implant) that, together with the existing soft tissue, will create the final breast form. When the existing soft tissue layer is thin, the implant and pocket location will to a greater degree determine the eventual shape of the breast and greater care will be required in choosing the best implant and pocket plane to provide an optimal result. When the soft tissue layer is thicker, these variables will have a comparatively less significant impact on the shape of the breast, and specific implant and pocket plane selection becomes less important. The goals of this chapter will be to describe the variables that need to be addressed when evaluating an individual patient for breast augmentation, provide a system for implant selection that can help guide the surgeon to select the optimal implant for a specific patient and to describe the technical details of the various surgical approaches that must be mastered successfully to perform the procedure.

Preoperative Planning

When planning a breast augmentation, it is helpful to realize that there are three basic decisions that must be made when designing a surgical strategy to augment the breast. These decisions involve choosing the location of the access incision, choosing the desired pocket plane and selecting an appropriate implant that will create the desired result. Choosing from the available options for each decision in such a way that each choice complements the other in the best way possible is the basic goal of preoperative planning.

Incision

When planning an incision for breast augmentation, the need for locating the incision in a position that allows for easy pocket dissection and implant insertion must be balanced with the desire to 'hide' the incision in an inconspicuous area. With this in mind, there are four potential incision locations for breast augmentation (Figure 4.3).

Inframammary fold Placing the incision in the inframammary fold (IMF) affords perhaps the best compromise between providing direct access to the breast at the expense of creating a scar. The IMF incision offers straightforward exposure for pocket dissection with the aid of a simple lighted retractor. Submuscular, subpectoral, subfascial and subglandular pockets can all be created with ease and the limits of the dissection can be determined under direct vision. Complete hemostasis can also be assured as individual vessels can be controlled and pocket manipulation with precise soft tissue release is also easily facilitated. The position of the inframammary fold can be maintained or lowered with accuracy due to the direct access afforded by the proximity of the incision. Implant insertion and positioning are also easily accomplished, a fact that is particularly advantageous when using shaped implants that must be oriented correctly. The disadvantage relates to the creation of a telltale cutaneous scar in the vicinity of the breast. For this reason, it is best to place the scar directly in the IMF as it tends to be quite inconspicuous in this location, particularly when the breast is of sufficient size to fall over the fold (Figure 4.4). In these situations,

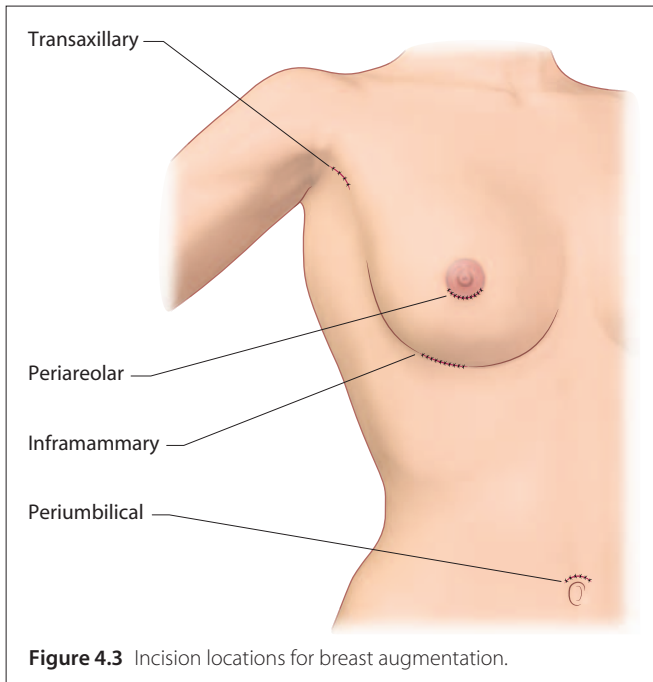


Figure 4.3 Incision locations for breast augmentation.

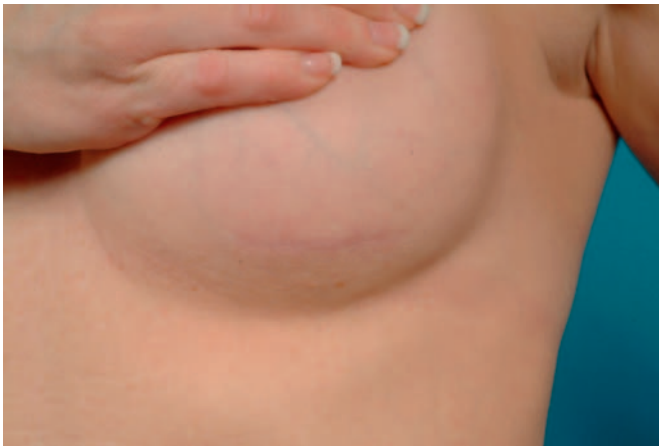

Figure 4.4 Appearance of the scar in the inframammary fold 1 year after breast augmentation.

the scar will only be visible when the patient lies flat or raises her arms up over her head.

Periareolar Although in terms of popularity, the periareolar incision is second to the inframammary fold incision, it remains as an attractive option for many plastic surgeons for two reasons. First, the resulting scar generally heals in a fine line fashion and is essentially imperceptible in many patients (Figure 4.5). The fact that the scar is situated at the junction of the pigmented areolar skin with the lighter lower pole breast skin assists greatly in visually masking the scar. Second, the only time the scar is potentially visible is when the breast is bare which, for many women, occurs only in controlled private settings. One unique situation where the periareolar incision has particular advantage is in the patient who presents with very small breasts with little to no inframammary fold. Here, the breast often cannot be augmented enough to cause the breast to fold over an inframammary fold incision with

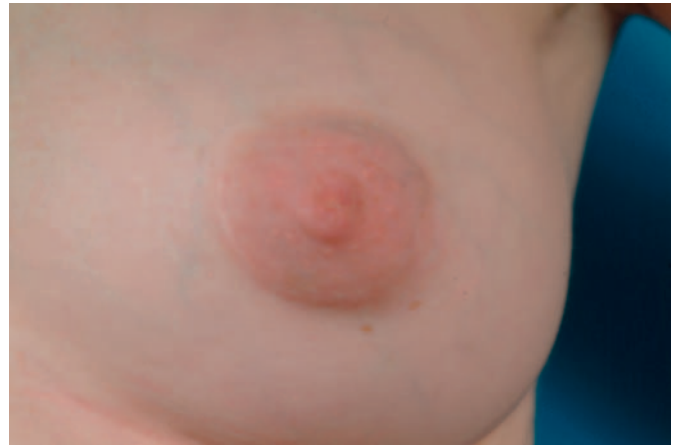

Figure 4.5 Appearance of the scar along the inferior border of the areola 1 year after breast augmentation.

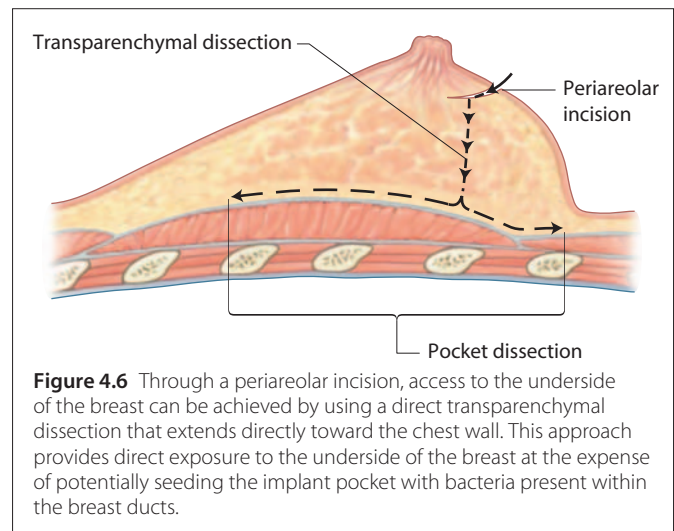


Figure 4.6 Through a periareolar incision, access to the underside of the breast can be achieved by using a direct transparenchymal dissection that extends directly toward the chest wall. This approach provides direct exposure to the underside of the breast at the expense of potentially seeding the implant pocket with bacteria present within the breast ducts.

the result being an immediately obvious and visible inframammary fold scar. In these cases, rather than risk scar visibility, a better option is the periareolar incision location, where the scar is better camouflaged. Other advantages of the periareolar incision location include the fact that, as with the IMF incision, direct access is afforded to the breast, which allows accurate pocket dissection and direct hemostasis. The incision is generally made along the inferior hemisphere of the areola, at the junction with the lighter lower pole breast skin. From here, two approaches can be used to access the underside of the breast and create the pocket:

- The most direct approach involves dissecting straight down through the breast to the subglandular space (Figure 4.6). With this approach, any pocket can be created, as in the IMF incision. Along with excellent access to the breast that is provided by this incision location, there are several other important advantages afforded by this approach. By dividing the breast parenchyma essentially in half, tethering contractures that can result from a tight parenchymal envelope can be partially released, allowing the placement of an appropriately sized implant of sufficient size to augment the breast adequately. Also, it is easier to dissect accurately

Table 4.1 The circumference of a circle can be calculated using the formula $\pi \times \text{diameter}$. By using this formula and dividing the circumference by two, the static length of a periareolar incision can be calculated for areolas of several different commonly encountered dimensions

Areolar diameter (cm)	Incision length (cm)
3.0	4.7
3.5	5.5
4.0	6.3
4.5	7.1
5.0	7.9

and position the inframammary fold by approaching it from above through a periareolar incision rather than through an incision made directly in the fold itself. By approaching the fold from above, the entire sweep of the fold can be assessed as it is dissected free without the potentially distorting influence of an incision made directly in the fold. Therefore, accurately maintaining or, more importantly, lowering the fold can be performed with greater precision. As with the IMF incision, placement and orientation of virtually any device is easily performed through this approach. It must be emphasized, however, that all of these manipulations will be hindered by an incision length that is too short. Remembering that the circumference of a circle can be calculated using the formula $\pi \times D$, where π is roughly 3.14, a 4 cm areola will provide a static inferior hemiareolar incision length of 6.3 cm (Table 4.1). The elasticity of the skin and surrounding soft tissue will also influence the ease with which an implant is inserted. Generally speaking, however, any attempt to use the periareolar approach with pre-existing areolar diameters of less than about 4 cm can become problematic when attempting to place larger round silicone gel implants, implants that are textured or any of the various 'cohesive' or stiffer anatomical gel implants that are also textured. The potential to damage the implant during the process of insertion becomes greater when attempting to 'stuff' or force an implant through a restricted opening. Shorter incisions can be used with saline implants of virtually any size without difficulty as these implants' shells can be inserted unfilled and then brought to volume once the shell is positioned in the pocket. The major disadvantage of the direct transparenchymal approach relates to the potential release of bacteria from the breast ducts that are divided during the dissection. Should these bacteria successfully seed the pocket around the implant, the potential for postoperative infection with loss of the implant would likely increase. Also, should the bacteria simply colonize the pocket, biofilm formation could develop, resulting in varying degrees of capsular contracture.

- The second approach to pocket development through a periareolar incision involves leaving the breast mound undisturbed and instead angling inferiorly and elevating a lower breast flap at the level of the superficial fascia down to the inframammary fold (Figure 4.7). At the fold, dissection then turns superiorly deep to the breast to create the desired

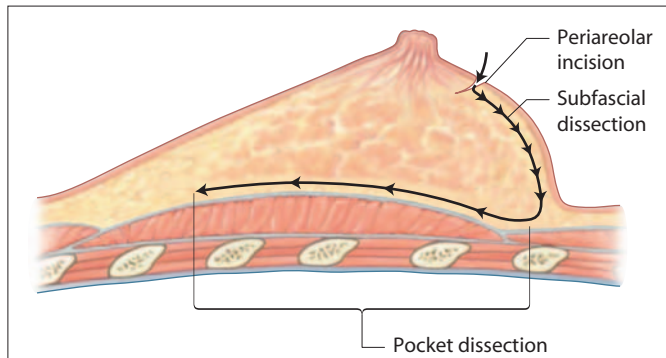


Figure 4.7 To avoid exposing the implant to bacteria contained in the breast ducts, an alternative approach to the underside of the breast through the periareolar incision can be created by dissecting along the breast fascia inferiorly down to the inframammary fold. Once at the fold, dissection then proceeds superiorly to create the desired pocket.

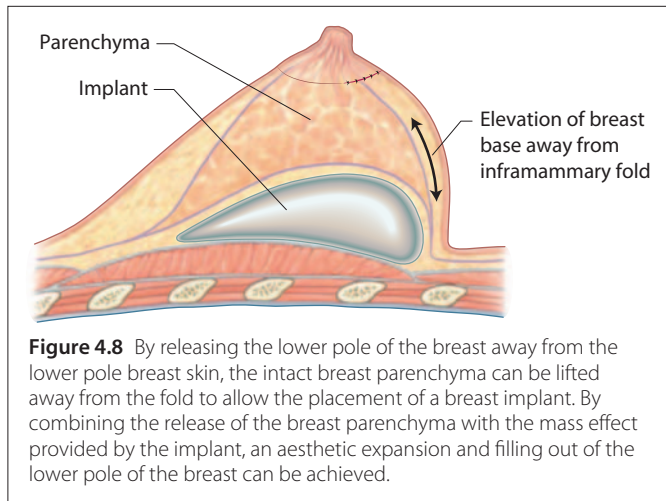


Figure 4.8 By releasing the lower pole of the breast away from the lower pole breast skin, the intact breast parenchyma can be lifted away from the fold to allow the placement of a breast implant. By combining the release of the breast parenchyma with the mass effect provided by the implant, an aesthetic expansion and filling out of the lower pole of the breast can be achieved.

pocket. This approach, as with direct division of the gland, provides for accurate identification of the level of the inframammary fold as it is approached from above. Also, the volume of the pocket can be increased by allowing the lower pole of the gland to ride up away from the fold during closure after the implant has been placed. If the skin envelope is sufficiently elastic, this maneuver can expand the pocket space and thus allow the placement of a larger device when indicated without creating undue tension due to pocket restriction. If the breast is allowed to slide up away from the fold to allow a larger implant to be placed, a smooth interface between the lower breast flap, the implant and the remaining breast parenchyma must be present to prevent a lower pole contour deformity (Figure 4.8). The disadvantage of this approach is that the dissection is more complicated and accurate identification of the breast fascia and creating what amounts to a lower mastectomy flap evenly can be a technical challenge, particularly when the periareolar incision length is short. Also, the exposure is more limited than with other approaches and implant insertion can be more difficult. There is also theoretical concern about affecting sensibility of the nipple-areola complex (NAC). Although there is literature support which documents that the periareolar incision is no

more prone to altering the sensation of the NAC than the inframammary fold incision, if retaining sensation is of vital concern to the patient, it might be more prudent to use an incision remote to the NAC to avoid any further possibility that nerves could be inadvertently sectioned or stretched during flap dissection and pocket development.

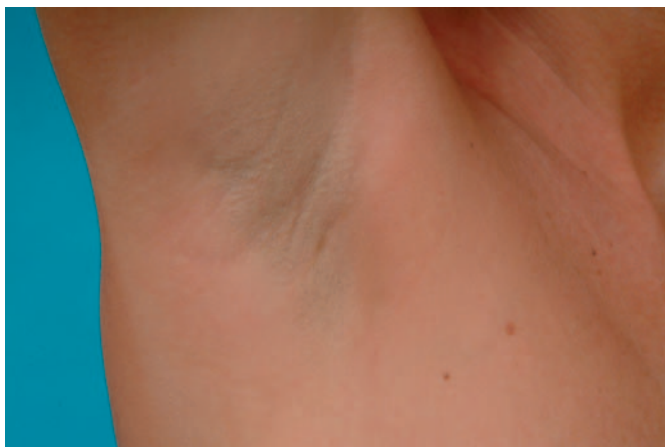

Figure 4.9 Appearance of the scar in the axilla 1 year after transaxillary breast augmentation.

Transaxillary The transaxillary incision provides an access site to the breast which heals with a well-hidden and, in most instances, imperceptible scar that is not located on or near the breast (Figure 4.9). As such, it is not generally recognized as a telltale sign of previous breast surgery. This significant advantage must be weighed against the potential for compromised accuracy in pocket dissection due to the remote location of the incision as well as the occasional patient who forms a bad scar in this otherwise visible location. There are two techniques to utilize this incision as it relates to pocket development. In both methods, the incision is located high in the axilla and is oriented horizontally at a point just lateral to the lateral margin of the pectoralis major muscle. The skin is incised and spreading dissection is used to identify the lateral border of the pectoralis major. At this point the underside of the pectoralis can be separated bluntly using a sound-type elevator to develop this plane, which opens up very easily. Crossing vessels from the chest wall to the muscle are simply avulsed and go into spasm, which usually checks the bleeding. Any tethering of the fibers of origin of the pectoralis major that adversely affect the shape of the breast are released by likewise avulsing these fibers loose until the pocket of the desired shape and dimension is developed. The implant is inserted and the incision closed. Clearly, the major difficulties associated with this approach involve the blunt and relatively blind nature of pocket development and the potential for uncontrolled bleeding due to the lack of direct control of bleeding points. Even with these potential difficulties, it must be pointed out that many surgeons can and do use this approach with success. However, in an attempt to increase the control afforded by this approach, some surgeons have incorporated endoscopic technique into the procedure. Once the plane on the underside of the pectoralis major is developed, an endoscope is inserted and, with the aid of standard endoscopic instruments, bleeding points are controlled and the fibers of origin of the pectoralis major muscle are released as needed under direct endoscopic vision to accurately create the desired pocket and

position the inframammary fold with precision. Combining the use of the endoscope with the well-concealed transaxillary incision is an excellent way to combine the advantages of direct pocket development with a remote and imperceptible scar. The disadvantages are related to the requirement for extra instrumentation, the additional technical expertise required to utilize the endoscope and the potential for bleeding that may be difficult to control even with the aid of the endoscope, particularly if the second intercostal perforator in the upper inner portion of the pocket is inadvertently divided. Additionally, plane selection is limited as, although it may be technically feasible to utilize the subglandular plane with this approach, it is difficult and, practically speaking, most surgeons use the subpectoral plane with this technique. It must also be pointed out to the patient ahead of time that, should future problems develop such as capsular contracture or implant malposition, many patients are going to receive an additional scar on the breast in the course of correcting the problem. Finally, this technique allows saline implants to be placed without difficulty; however, larger gel devices, textured devices and anatomically shaped cohesive gel devices all may prove to be variably difficult to insert without damaging the implant. These potential disadvantages do not diminish the utility of the transaxillary approach and many surgeons do use it successfully. However, all of these factors must be taken into account when contemplating the use of the transaxillary incision location.

Transumbilical In a further effort to erase any stigmata of a procedure on the breast, the transumbilical breast augmentation (TUBA) procedure has been developed. In this approach, an incision is made in the umbilicus and a hollow trocar is bluntly inserted through the subcutaneous tissue, angling upwards toward each breast. The pocket, either subpectoral or, more recently, subglandular, is bluntly opened enough to allow the passage of an uninflated temporary 'expander'. This device is attached to a long fill tube which exits through the umbilicus. By over inflating the 'expander' with air, the pocket is developed bluntly as the muscle and/or breast is avulsed away from the more rigid chest wall. The more dense attachments of the inframammary fold prevent to some degree inadvertent lowering of the fold, and the pocket opens more or less under the breast. The 'expander' is deflated and removed and the final saline implant shell is passed through the trocar uninflated and attached to a second long fill tube. The implant is filled with saline to the desired fill volume and the fill tube and trocar are removed to complete the procedure. TUBA remains a controversial procedure. It must be stated that the scar generally is well hidden and some surgeons are able to obtain consistent aesthetic results using the technique. However, the disadvantages and potential complications are significant and must be taken into serious consideration when contemplating the approach. Due to the limited access tunnel, it is possible to use only saline implants, which limits implant selection. Also, because pocket dissection is performed bluntly from a remote location, control over the size, location and symmetry of the dissection space is compromised compared to the direct control afforded by incisions located closer to the breast. If bleeding occurs, it cannot be stopped other than with direct pressure, which increases the potential risk for hematoma development. One potential complication unique to the TUBA procedure involves the creation of permanent soft tissue distortion with visible grooving in the upper abdomen extending up from the umbilicus to the breast that can develop in trim patients as a result of the trocar passing

through the thin subcutaneous layer. Finally, any revisionary procedure that cannot be performed through the periumbilical access site will require an additional separate incision on the breast. For these reasons, TUBA is viewed less than favorably by many surgeons and the lack of direct control of many of the factors involved in offering consistent results in breast augmentation is deemed enough of a disadvantage to make the remote and inconspicuous umbilical scar an unreasonable tradeoff.

Pocket Plane

As with many aspects of breast augmentation, selection of the most appropriate pocket plane for placement of the implant has been an evolving concept as operative technique has matured over the years. As a result, there are four basic options for pocket plane development.

Complete submuscular Early on in the development of breast augmentation as a viable aesthetic procedure, it made intuitive sense to place the implant directly under the breast on top of the underlying musculature. It soon became clear, however, that, with this technique, capsular contracture was an alarmingly common complication and one possible etiology was thought to be bacterial contamination of the implant space from the ducts in the overlying breast. Therefore, in an attempt to isolate completely the breast implant from the overlying breast parenchyma and thus minimize any bacterial contamination, the submuscular pocket was developed. In this procedure, a pocket is created under the pectoralis major muscle by lifting the lateral margin of the muscle away from the chest wall and undermining the muscle over to the medial fibers of origin just lateral to the sternum. Typically, every attempt is made to keep the fibers of origin along the inframammary fold intact to prevent the implant from slipping out from under the muscle inferiorly thus preserving the completely submuscular location of the pocket. Laterally, the muscle fibers or simply the superficial fascia of the serratus anterior muscle are elevated away from the chest wall and the implant is slipped under this muscle/fascial layer. By approximating the lateral margin of the pectoralis major to the serratus muscle/fascia, the implant is completely isolated from the overlying breast parenchyma (Figure 4.10). Theoretically, providing a barrier to potential bacterial seeding of the implant space from the breast ducts will prevent or at least moderate the subsequent development of capsular contracture. Also, keeping the inferior muscle fiber attachments intact is thought to provide strong support to the inferior pole of the breast, which can prevent postoperative inferior migration or 'bottoming out' of the breast implant. Also, by covering the implant with a layer of muscle, the contours of the superior and superomedial borders of the breast along the edge of the implant are softened, creating a more natural breast shape. While these factors may be an advantage, there are significant drawbacks to this technique. Perhaps the greatest problem associated with the use of the completely submuscular pocket is the potential for superior implant malposition. This is because anatomically, in many patients, the position of the inferiormost fibers of origin of the pectoralis major muscle can be located slightly above the location of the attachments of the inframammary fold (Figure 4.11). When this relationship is present, placing an implant in a completely submuscular pocket or, for that matter, even in a subpectoral pocket, without release of the inferior fibers of origin of the pectoralis major muscle will not allow the breast

implant to sit low enough and it will appear to be superiorly malpositioned in relation to the position of the breast mound on the chest wall. The resulting breast contour will then very likely demonstrate a superior pole bulge with the breast appearing to fall away from the inferior pole of the implant. When severe, this appearance has been referred to by some as a 'snoopy dog' type deformity (Figure 4.12). The identification of a mismatch in breast position versus implant position can be difficult to appreciate intraoperatively as the implant malposition may not become apparent until the patient is placed upright. Lying supine, the breast mound tends to shift superiorly and an implant in a submuscular pocket may appear to be well matched to the breast positionally. It is only later when the patient is seen upright in the office that the malpositioned breast implant becomes apparent.

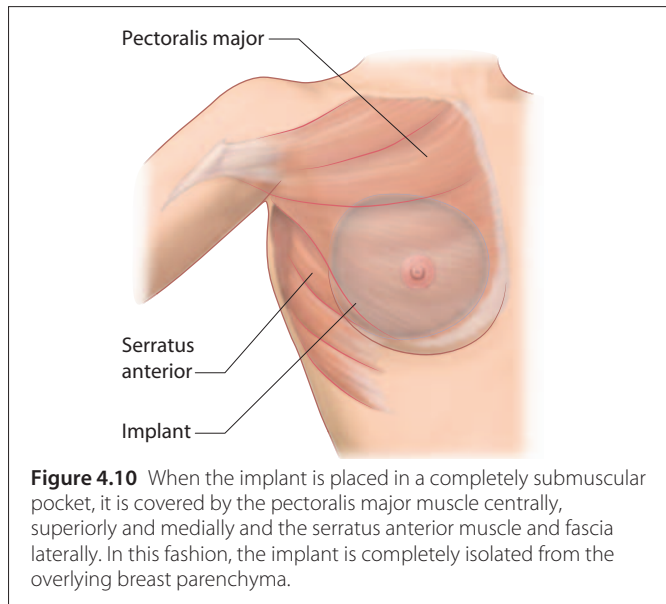


Figure 4.10 When the implant is placed in a completely submuscular pocket, it is covered by the pectoralis major muscle centrally, superiorly and medially and the serratus anterior muscle and fascia laterally. In this fashion, the implant is completely isolated from the overlying breast parenchyma.

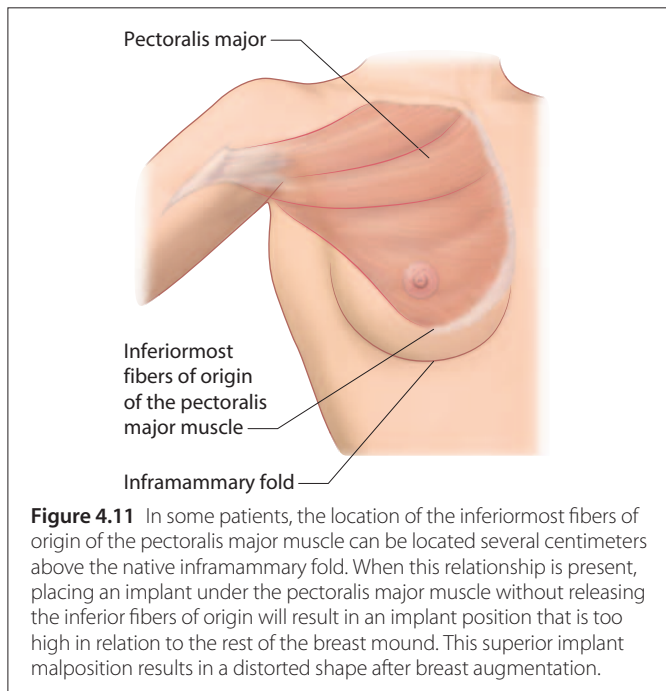


Figure 4.11 In some patients, the location of the inferiormost fibers of origin of the pectoralis major muscle can be located several centimeters above the native inframammary fold. When this relationship is present, placing an implant under the pectoralis major muscle without releasing the inferior fibers of origin will result in an implant position that is too high in relation to the rest of the breast mound. This superior implant malposition results in a distorted shape after breast augmentation.

It is likely that this phenomenon is at least partially responsible for the widely held opinion that submuscular implants tend to 'ride high'. It may be that the so-called high-riding implant more accurately represents an implant that was unwittingly malpositioned superiorly at the time of surgery. This observation is but one of many that underscores the importance of sitting any breast patient up 80 to 90 degrees during the procedure so these types of relationships can be accurately assessed intraoperatively and appropriate changes made in implant position as needed. Another limitation associated with the use of a submuscular pocket relates to the volume of the space that can be opened up under the muscles. The pectoralis major and serratus anterior muscles are normally closely applied to the chest wall in their resting state and the degree to which they can be elevated

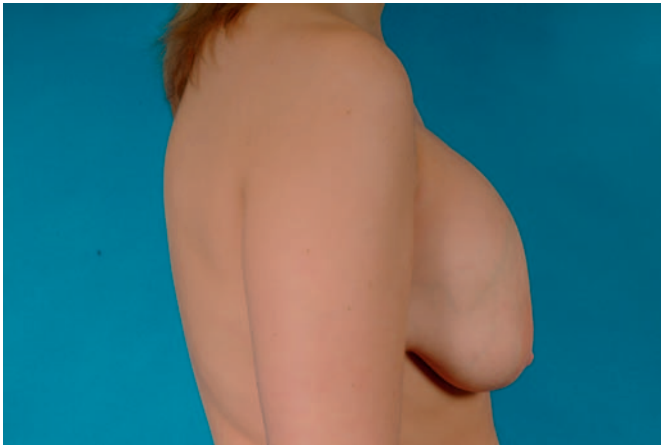
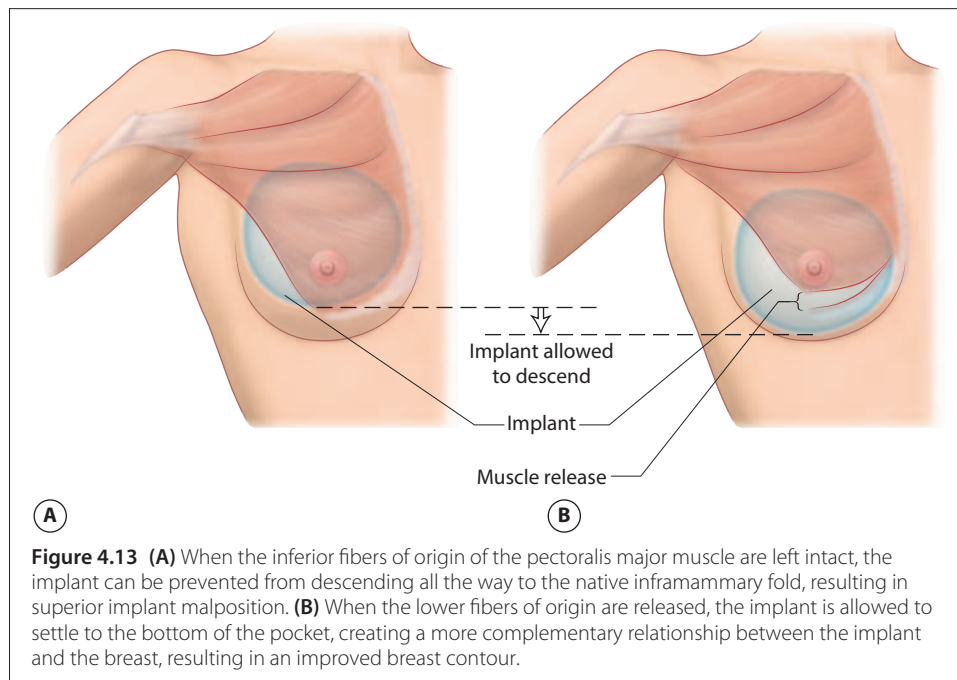


Figure 4.12 Lateral view of a patient after undergoing subpectoral breast augmentation without release of the inferior fibers of the pectoralis major. The implant is superiorly malpositioned, creating a prominent superior pole bulge. Also, the main substance of the breast can be seen extending away from the inferior edge of the implant, creating a very unaesthetic breast contour that has been referred to as a 'snoopy dog' type of deformity.

away from the chest wall and still keep the peripheral attachments intact is limited. For this reason, larger implants may not comfortably fit within the confines of the dissected pocket. Also, should the pocket be constricted at all, due either to an inelastic muscle cover or to the use of a large volume device, there is a tendency for the implant to become compressed, particularly in the lower pole, resulting in lower pole flattening and excess upper pole fullness. It is for these reasons that the total submuscular pocket is used only sparingly in breast augmentation.

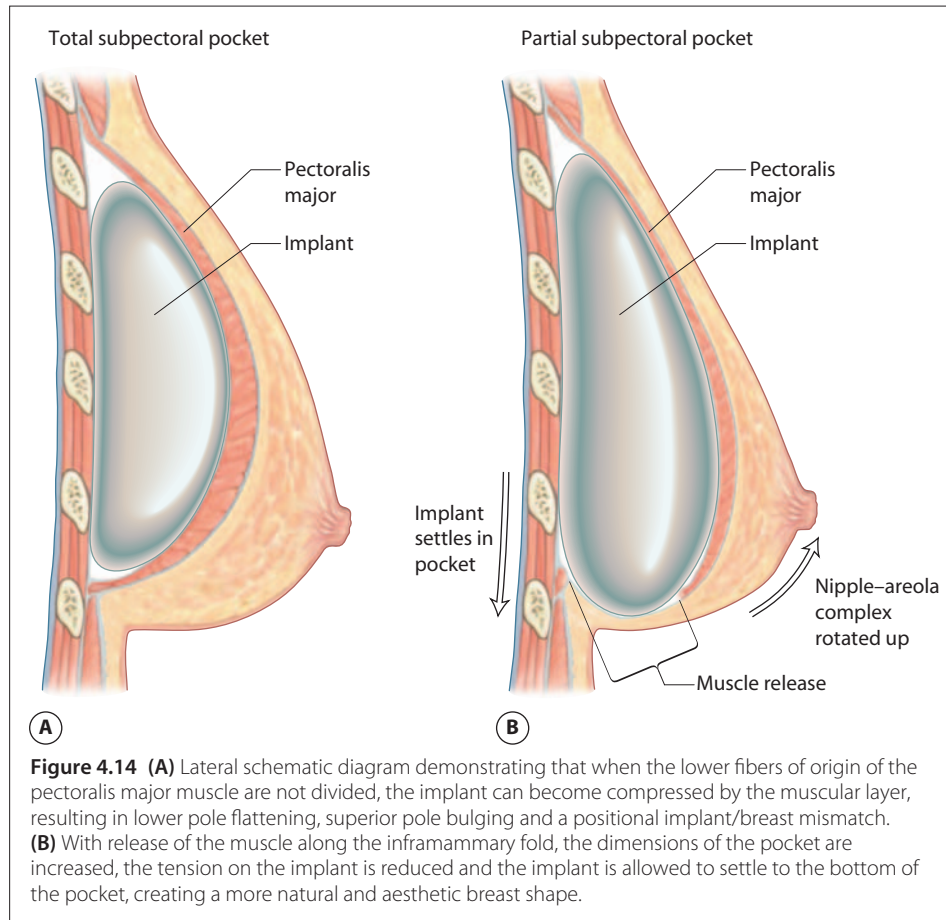
Partial subpectoral In an attempt to address the apparent difficulties associated with the completely submuscular pocket, the partial subpectoral pocket was developed. In this procedure, the pectoralis major is released along the lateral border of the muscle and the subpectoral space is developed as before. Here, however, no portion of the serratus anterior is elevated at all and the inferomedial fibers of attachment of the pectoralis major muscle are released, allowing the muscle to retract up and away from the inframammary fold. The net effect of this release is twofold. First, the tension on the pocket is reduced significantly as a result of releasing the muscle fiber attachments. When the total submuscular pocket is used, the broad, flat pectoralis major can function as a tethering layer, preventing the pocket from expanding fully to accommodate the implant. By releasing the inferior attachments of this tethering layer, the muscle is released and the skin envelope of the lower pole of the breast is recruited to assist in defining the dimensions of the pocket. The result is a bigger pocket with less compressive force on the implant and a more compliant soft tissue/implant interface, allowing the creation of a softer breast. Second, as a result of releasing the muscle along the inframammary fold, the implant can now be positioned low enough to place the inframammary fold in an anatomically correct position. As a result, the upper portion of the implant remains covered by the pectoralis major muscle but the lower portion of the device is in contact with the underside of the breast (**Figures 4.13, 4.14**). The portion of the implant that is covered by muscle will change



(A)

(B)

Figure 4.13 **(A)** When the inferior fibers of origin of the pectoralis major muscle are left intact, the implant can be prevented from descending all the way to the native inframammary fold, resulting in superior implant malposition. **(B)** When the lower fibers of origin are released, the implant is allowed to settle to the bottom of the pocket, creating a more complementary relationship between the implant and the breast, resulting in an improved breast contour.



from patient to patient as breast position on the chest wall and the exact point of origin of the pectoralis major is subject to anatomic variation. However, the ultimate effect of this pocket plane is to once again soften the upper medial pole of the breast due to the padding created by the muscle and yet allow the breast implant to be positioned low enough on the chest wall to anatomically fill out the breast contour. The pocket is also very easily developed either under direct vision or bluntly through any incision location. The subpectoral pocket is also the preferred pocket location for women undergoing mammographic screening of the breast as the breast implant is relatively easily pushed up and out of the way, a maneuver that affords better breast compression and a more complete mammogram.

While the use of a partial subpectoral pocket successfully addresses several of the problems noted with a total submuscular pocket, there are some disadvantages associated with the technique. Technical skill must be exercised in the undermining and releasing of the muscle to create a breast shape that will be symmetric from side to side. While this may seem to be a straightforward endeavor, it can actually require a fair bit of care to accomplish symmetric release of the muscle inferiorly as factors such as pre-existing asymmetry in the fibers of origin as well as a basic asymmetry in breast size and shape itself can come into play. Failure to release the muscle symmetrically can lead to postoperative implant malposition. Also, due to the fact that the integrity of the total muscle cover is interrupted, a portion of the implant becomes exposed to the overlying breast parenchyma. Theoretically, bacterial seeding of the implant space could occur,

possibly leading to capsular contracture. Despite this concern, numerous studies have concluded that the subpectoral plane is associated with a reduced capsular contracture rate as compared to the subglandular plane. This apparent inconsistency between theory and observation underscores the fact that capsular contracture is a multifactorial process that remains incompletely understood even today. Therefore, despite the technical challenges that use of the partial subpectoral pocket presents, the advantages associated with use of this technique are significant and it remains as the standard approach for the vast majority of plastic surgeons who perform breast augmentation.

When either the total submuscular or partial subpectoral pocket plane is used, it must be recognized that the overlying musculature retains its contractile ability. As a result, when a breast implant is placed under the pectoralis major muscle, the implant will be compressed when the muscle contracts. Typically, this movement tends to draw the implant in an up and out direction and this directed compression creates a contour deformity in the breast that can easily be seen when the patient places her hands on the hips and pushes inward. Occasionally, the deformity is so prominent that the distortion in breast shape can be seen through tight-fitting clothes. The magnitude of the deformity caused by this breast animation is highly variable and, fortunately, it is usually only minimal to moderate in severity (Figures 4.15, 4.16). However, at times, the degree of the distortion created by contraction of the pectoralis major muscle can be dramatic (Figure 4.17) and, in revisionary patients, undesired breast animation is often one of many issues that can lead patients to seek

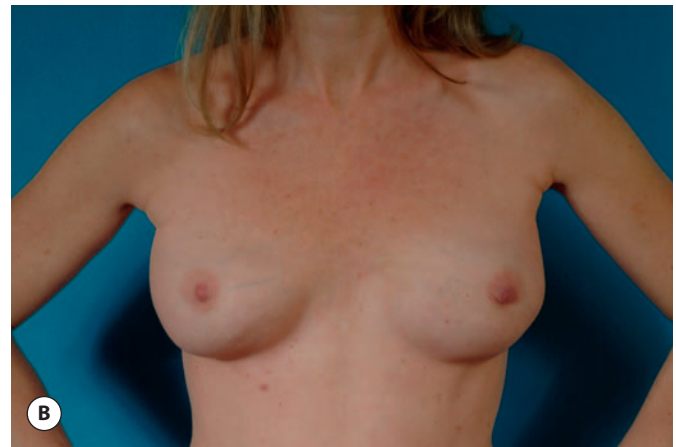
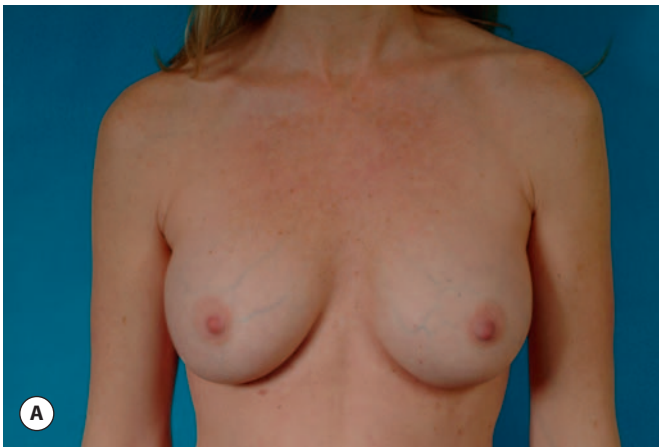

Figure 4.15 (A) Five-year postoperative appearance of a patient after partial subpectoral breast augmentation using a smooth-walled saline implant. With the arms resting comfortably at the side and with no contraction of the pectoralis major muscle, the breasts have a pleasing aesthetic contour. **(B)** As the patient places her hands on her hips and pushes inward, the pectoralis major muscle contracts, drawing the

underlying implant laterally and slightly upward. The intermammary distance increases as the implants are pulled laterally and the lower pole of the breast flattens along with the medial portion of the inframammary fold. This case is fairly typical of the degree of breast animation that occurs after partial subpectoral breast augmentation.

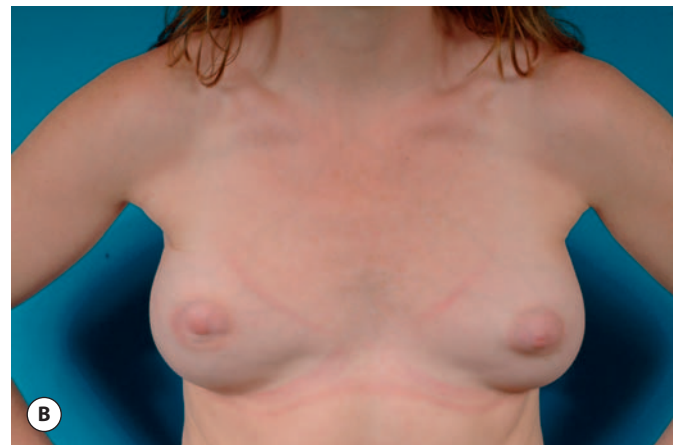
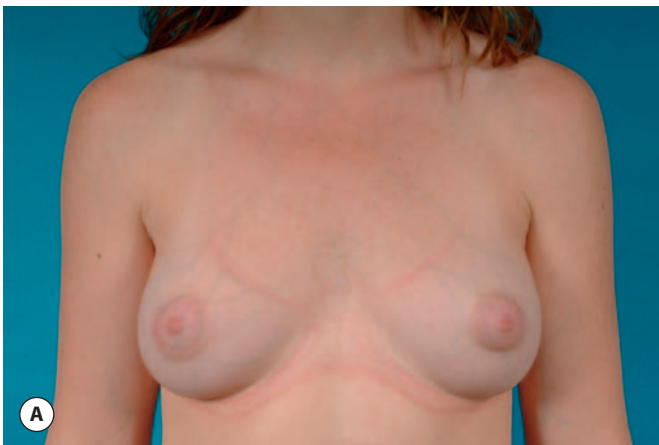
Figure 4.16 (A) Four-year postoperative appearance of a patient after partial subpectoral breast augmentation using an anatomically shaped cohesive gel implant. Again, with the arms resting at the side, a pleasing and natural breast contour is demonstrated. **(B)** With the hands pushing on the hips, the pectoralis major muscle contracts, creating the same pattern of breast

animation seen with the saline implant. This case is representative of the fact that, while it may make intuitive sense that firmer cohesive gel devices might protect against breast animation, in fact these devices are subject to the same forces as any other implant and react in exactly the same fashion.


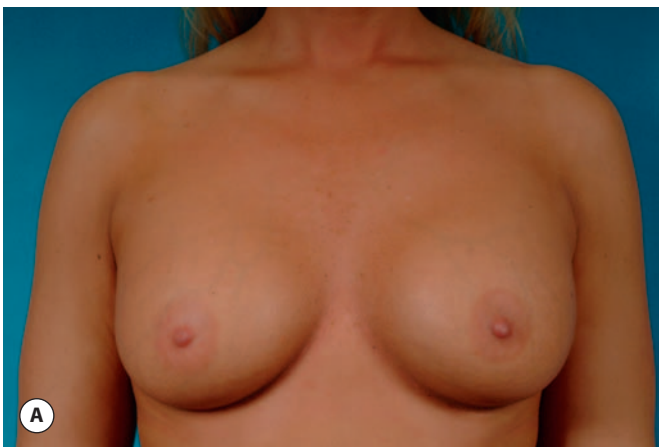


Figure 4.17 (A) Two-year postoperative appearance after partial subpectoral breast augmentation with a smooth round saline implant. At rest, a pleasing result is demonstrated. **(B)** With contraction of the pectoralis major muscles, significant displacement of the implant into the

upper pole of the breast with associated distortion and flattening of the implant is noted. This degree of breast animation can understandably be a major source of patient dissatisfaction.

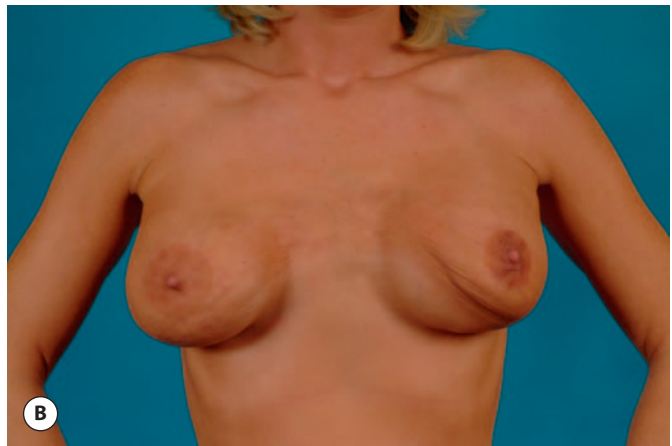
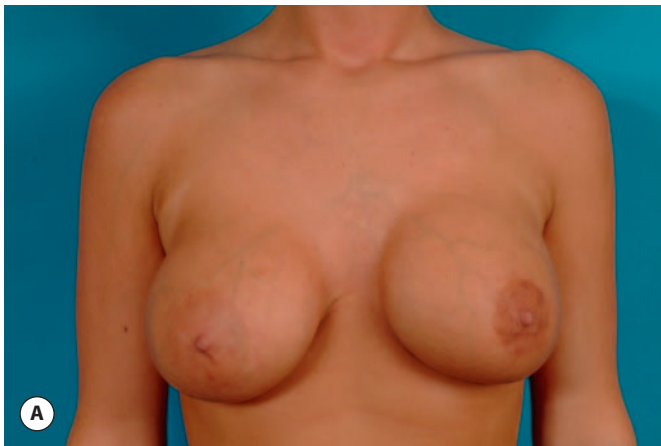
Figure 4.18 (A) Preoperative appearance of a patient who has previously undergone periareolar mastopexy. Her static postoperative result reveals a significant breast asymmetry, widening of the right areola and left-sided capsular contracture. **(B)** As the patient contracts her pectoralis major muscle, a significant deformity develops in each breast. Again, both breasts are drawn laterally and superiorly and the intermammary distance

widens markedly. On the left, the released inferior edge of the pectoralis major remains attached to the overlying tissue such that, as it is drawn superolaterally, a prominent cleft is created in the inferomedial breast contour. This cleft is not present on the right, possibly indicating that the muscle was asymmetrically released at the original procedure. This degree of deformity is much less common and would be described as marked.

re-operation (**Figure 4.18**). In an attempt to head off any potential postoperative dissatisfaction and ensure a fully informed patient, it is very reasonable to discuss breast animation as a potential complication during the preoperative evaluation and education of the patient. Short video clips (**DVD clips 2.01, 2.02, 2.03, 2.04**) are very instructive and can ensure that the patient understands completely the rationale for using the partial subpectoral pocket and what effect that decision may well have on her postoperative result.

Subglandular The second most commonly utilized pocket for breast implant placement is the subglandular pocket. In this procedure, the subglandular space above the pectoralis major muscle is opened leaving the pectoralis muscle fascia attached to the muscle (**Figure 4.19**). The space dissects open readily and the limits of pocket development can be precisely controlled, which eases the technical challenge of dissecting pockets of the same dimension and location for each breast. Crossing vessels and nerves can be identified and preserved medially and laterally as desired and the pocket can be easily accessed through either a periareolar or an inframammary fold incision. Any type of implant can be used with a subglandular pocket and shaping maneuvers such as scoring of the underside of the breast to release tethering constrictions are greatly facilitated due to the direct exposure of the gland. As a result of placing the implant above the muscle, postoperative animation of the breast is markedly diminished and, at most, only a slight shape change may occasionally be noted with contraction of the pectoralis major muscle due to tethering of the capsule to the muscle. Typically, the recovery after undergoing a subglandular breast augmentation is more straightforward with many patients reporting a less painful experience overall. Despite these advantages, the subglandular pocket is used with care as the disadvantages can be significant. Perhaps, most importantly, it is generally agreed that the incidence of capsular contracture is greater in subglandular breast augmentation. What remains unknown is what effect that newer breast implant designs will have on this complication. More recent silicone gel breast implants have been designed to have an outer shell that is much more resistant to gel bleed than earlier implants and recent studies have reported rates of capsular contracture that are not much different from those associated with subpectoral placement. Perhaps just as important is the effect of the subglandular pocket on breast shape. Because the upper inner portion of the pocket is not padded by the pectoralis major muscle, implant edge visibility and palpability in this area can become an issue in thinner patients who do not have enough native breast parenchyma to mask the shape of the underlying device. This implant visibility becomes

One of the most common complaints I have noted in patients who present for revision after primary breast augmentation relates to the degree of breast animation that is present as a result of the implant being placed under the pectoralis major muscle. At times, this is the major presenting complaint and, whether true or not, most patients are adamant that they were never counseled that such animation could occur. As a result of this experience, it is now my practice to show every potential breast augmentation patient a short video clip of a mild animation as well as a major animation deformity. This is then contrasted with a video clip of a patient who has undergone a subglandular augmentation with no animation deformity. It has been my observation that most patients are quite put off by the potential for breast animation when they have the opportunity to see an example of it preoperatively and will opt instead for the subglandular plane, if they are otherwise appropriate candidates. If the patient is not a candidate for subglandular placement or capsular contracture is a prominent concern, there is at least an understanding as to what the sequelae may be when the implant is placed under the muscle. Although this discussion represents a small part of the overall process of patient education, the benefits have been significant in that the potential for patient misunderstanding regarding this issue is essentially eliminated. This exercise is an example of an old axiom relating to the art of a successful practice, 'if you tell a patient about a complication beforehand and it occurs, you are a prophet. If you try to explain away the complication after it occurs, you are covering up.'

DVD
2.01, 2.02,
2.03, 2.04

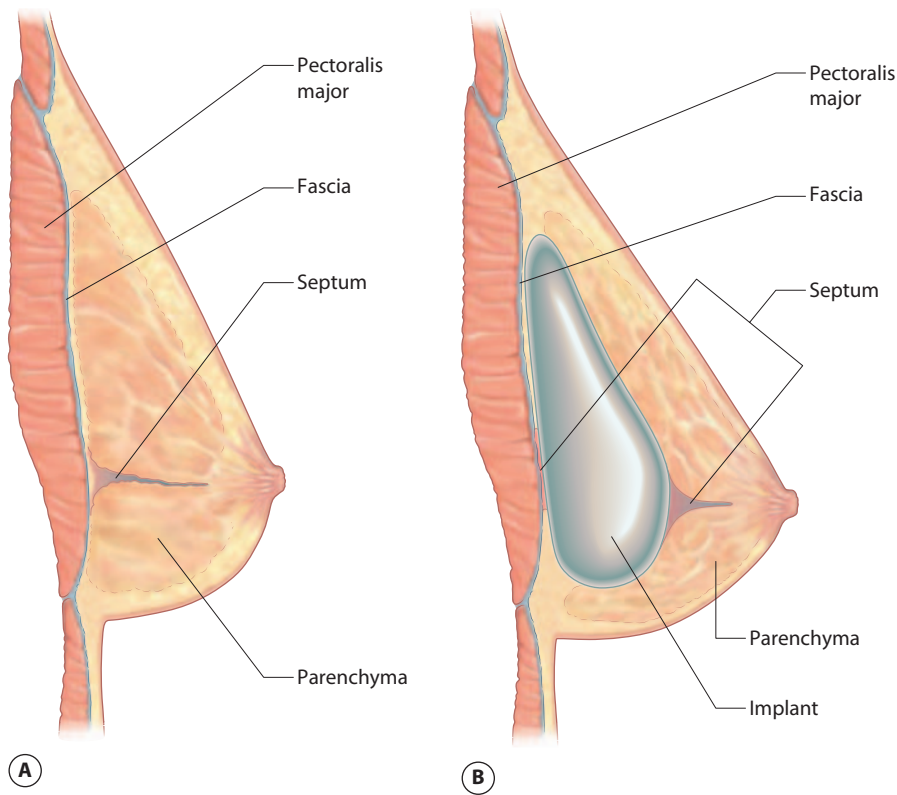


Figure 4.19 (A) Schematic lateral cutaway diagram of the breast prior to subglandular breast augmentation showing the pectoralis major muscle, parenchyma and fascia. (B) Same view after subglandular breast augmentation. The implant is positioned on top of the pectoralis major muscle and fascia and lies underneath the breast parenchyma, as well as the skin and fat of the chest wall.

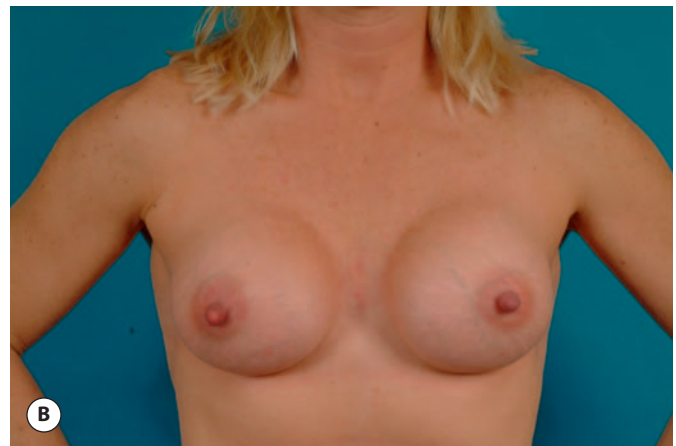
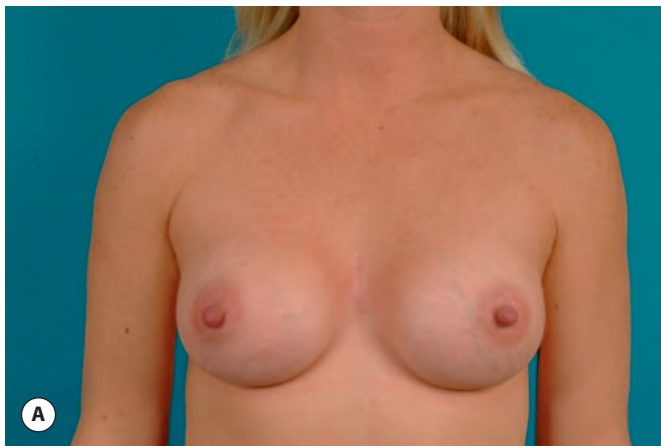
Figure 4.20 (A) Postoperative appearance of a patient after subglandular breast augmentation. At rest, the contours of the breast are soft with no prominent edges or step offs being noted at the periphery of the implant. (B) As the pectoralis major muscle contracts, the effect of the muscle pulling on the overlying soft tissue framework tightens the skin envelope,

creating sharper contours around the periphery of the implant. Therefore, although there is no animation deformity as is noted after subpectoral breast augmentation, thinner patients can exhibit increased implant visibility when the implant is placed in the subglandular plane.

more apparent as the patient flexes the pectoralis major muscles and a sharper medial and superior implant margin can become evident (**Figure 4.20**). For these reasons, many surgeons limit the use of the subglandular pocket to those patients who have an upper chest soft tissue thickness of 2 cm or more, or in patients who will require soft tissue scoring on the underside of the breast as in patients who present with a tubular breast deformity. Also, in mastopexy patients, the soft tissue lifting effect of placing an implant under the breast is enhanced if the pectoralis major muscle is not positioned as a potentially tethering layer

inhibiting implant projection. As a result, many surgeons will choose the subglandular plane for those patients undergoing augmentation mastopexy.

Subfascial Closely related to the subglandular space is the subfascial pocket. This technique was designed in an attempt to minimize the potential disadvantages traditionally associated with the partial subpectoral pocket related to postoperative breast animation and yet preserve the improved upper and medial pole contour that the partial subpectoral pocket can provide. In this technique,

the lower border of the breast is elevated along with the investing fascia of the pectoralis major muscle. Initially, this plane can be somewhat difficult to develop as the attachments of the breast septum must be dissected free as they course transversally across the mid-aspect of the pectoralis major muscle. Associated with this fascial attachment will be several prominent perforators that are easily controlled. Above this point, however, the fascia comes up easily and any small bleeding points that are encountered are easily controlled. Dissection then continues superiorly under the breast until the superior extent of pocket dissection is complete (Figure 4.21). Although quite thin, theoretically this fascia is thought to provide a tethering force around the perimeter of the breast implant that then softens the contours of the peripheral edges of the breast, leading to less implant visibility. It is postulated that this effect is similar to the softening of the superomedial implant edges that occurs with partial subpectoral placement, but without the attendant subpectoral distortion that variably occurs when an implant is placed under the pectoralis major muscle. In practice, this plane is rather easy to develop; however, the fascial layer is quite thin and any resulting improvement in breast shape that occurs is modest at best with other factors including body habitus, implant style and size and implant fill exerting a much more profound impact on breast shape. For this reason, use of the subfascial pocket has yet to attain wide popularity. One unexpected advantage that can be seen when using this plane relates to the accuracy of pocket dissection. By elevating the fascia with the breast in the medial portion of the pocket, it is technically easier to identify and preserve the medial internal mammary perforators and avoid inadvertent injury to this vigorous source of blood supply to the breast. Another more theoretical advantage relates to a potential shaping advantage afforded by differentially scoring the fascia in the lower half of the breast. The resulting

release of tension in the lower half of the pocket coupled with a mild fascial-induced tethering in the upper half can create differential tension on the pocket that tends to restrict upper pole fullness and maximize lower pole projection. However, whether or not such differential pocket dissection can aid in 'shaping' the subsequent breast implant, creating an improved breast shape over the long term, remains to be demonstrated.

Implant Choice

After selecting an incision location and a pocket plane, the last and arguably most important decision to be made involves selecting a breast implant. A properly chosen breast implant that artistically complements the overlying soft tissue framework has a tremendous impact on the quality of the overall result. To this end, there are a host of different devices that have been developed over the years, all designed to improve the aesthetic results of breast augmentation while minimizing the potential complications. Design variables such as round versus anatomically shaped devices, smooth versus textured surfaces, saline versus gel fill, different types of gel fill (i.e. cohesive gel), implants of differing projections and combination gel/saline implants can all mix and match in numerous ways to create hundreds of different devices. In the face of this complexity, choosing the 'optimal' implant for a specific patient can be a daunting challenge.

Despite this apparent complexity, the fact remains that there are a wide range of different implants that, for a given patient, would be equally optimal and even more that would be practically acceptable. The ultimate determining factors become the thickness of the overlying soft tissue cover of the breast and the degree of ptosis. Patients with 2 cm or more of fat and breast

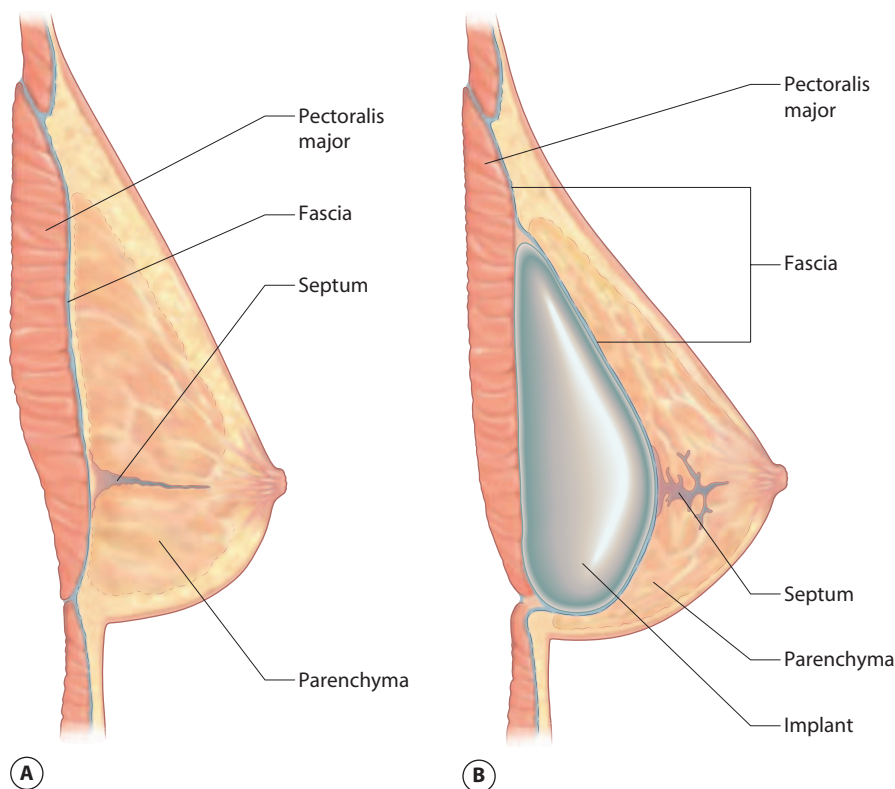


Figure 4.21 (A) Lateral schematic diagram demonstrating the relationship of the pectoralis major muscle and fascia to the overlying breast. (B) After creation of a subfascial pocket, the pectoralis major fascia remains attached to the underside of the breast and the implant is positioned between the muscle and the fascia.

parenchyma at the peripheral margins of the breast and, in particular, in the superior pole of the breast will do very well with almost any type of implant. In these patients, any asymmetry, wrinkle or mild malposition problem will be masked by the native breast volume. Put another way, when the implant provides roughly 75% or less of the total volume of the breast, less stress is placed on the implant to determine the final shape of the breast. However, as patients become thinner, or as increasing degrees of ptosis become present, specific implant selection begins to play a more important role and must be more carefully individualized for each patient as any imperfection in the implant will tend to be more noticeable and may potentially detract from the quality of the aesthetic result.

Preoperative Evaluation

Prior to performing breast augmentation, a basic breast history is obtained that notes the changes that have taken place in the breast over time and documents the current condition of the breast. Pertinent issues such as the number of pregnancies and deliveries are noted along with information about whether or not breast-feeding was performed and for how long. It is very helpful to inquire of patients how big their breasts became with breast-feeding as this is often the aesthetic goal these women are seeking after breast augmentation. A history of any previous breast biopsy is noted and the location of that biopsy and the associated scar is documented as particularly prominent or long scars could potentially influence access incision choice. The current bra size is noted as is the patient's height and weight. Any fluctuations in the patient's weight over the past year should be noted as it is advisable for the patient to present for surgery at a weight that is stable before making decisions about implant size. Lastly, the patient is asked in precise terms, what she would like to accomplish with the procedure. Issues such as volume, shape, ptosis and firmness are common concerns that motivate many women to pursue breast augmentation and what role each of these variables plays in determining the goals of the patient must be documented so that the surgeon has a clear understanding of what the patient's expectations are for the procedure. Heading off any misunderstandings at this point is very important in preventing patient dissatisfaction postoperatively.

When evaluating a patient for breast augmentation, it is incumbent on the physician to recognize the propensity of the breast to undergo malignant transformation. For this reason, preoperative mammographic screening of the breast is liberally utilized. Certainly, for any patient who has either a personal history of any previous breast pathology or mass, or for any patient with a family history of breast cancer, a preoperative mammogram is highly recommended. If no risk factors are present, a reasonable approach used by many surgeons is to obtain a mammogram for anyone over the age of 25 prior to performing a breast augmentation. Should any type of suspicious or questionable abnormality be noted on the mammogram, breast augmentation is delayed until the abnormal area has been proven to be benign, most preferably via biopsy, although at times further views on mammogram may help confirm the benign nature of a suspicious area.

Examination of the breast must be performed to assess for the presence of any discrete mass or other questionable area. Thorough palpation of the breast and axilla is performed with the patient lying supine and the arm extended over the head, so as to place the breast under tension thus thinning the breast and

facilitating the palpation of any suspicious masses. Should a mass be identified, biopsy must be performed to document the nature of the lesion. This may take many forms, ranging from simple aspiration of a breast cyst to open biopsy in the operating room.

Once these basic issues have been addressed, evaluation of the breast in preparation for breast augmentation can be performed. Two sets of measurements are obtained to help guide the surgical approach as well as implant selection. These are broken down into positional measurements and observations and breast-shaping measurements.

Positional Measurements

These measurements are intended to document the position of the breast and NAC on the chest wall. Making note of these measurements not only highlights where the breast and NAC are located in relation to other important landmarks, including the clavicle and inframammary fold, but also triggers discussion between the patient and the surgeon about what the proposed breast augmentation will accomplish and, perhaps more importantly, what it may not completely address.

Clavicle to nipple This distance is measured from the mid-aspect of the sternum in line with the visual breast meridian down to the nipple (Figure 4.22). This measurement will vary based on the degree of ptosis as well as the height of the patient and the size of the breast. Typically, it ranges from 17 cm in a petite patient to 20 cm or more in very ptotic patients. The measurement is noted for both breasts and it is not uncommon for the measured distance to vary significantly from one side to the other. Possible etiologies for this include asymmetry in nipple position or breast size, or just as commonly asymmetry in the position of the clavicle. By noting this measurement, all of these relationships are brought into focus, which is important as they can adversely influence the final result if these asymmetries are not recognized ahead of time. For instance, if the same measured distance from the clavicle to the nipple on each side is used as the determinant of nipple position and the clavicles are asymmetric, then the resulting NAC position will also be asymmetric. Also, since this measurement focuses attention on shoulder position, asymmetries can be recognized preoperatively

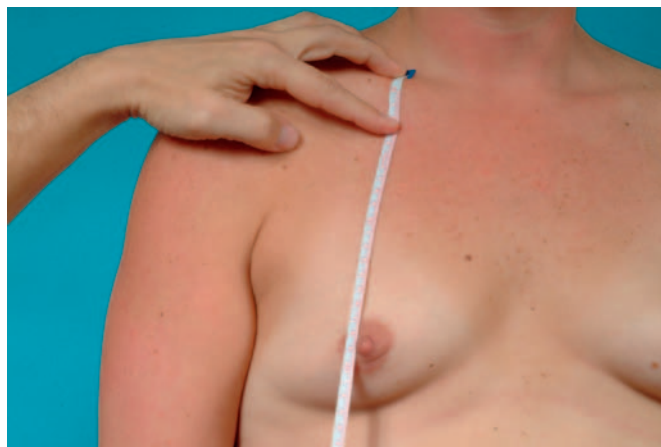

Figure 4.22 The midclavicle to nipple distance is measured and compared from side to side to highlight any asymmetry in either the position of the NAC or the position of the clavicles and shoulders.

and appropriate adjustments in shoulder position can be made intraoperatively to allow accurate breast shaping and NAC positioning to be performed.

Sternal notch to nipple This distance is measured from the sternal notch down to the nipple on each side (Figure 4.23). Because the sternal notch point is static, this measurement becomes a more accurate and consistent indicator of nipple location asymmetry, which can then trigger appropriate discussions with the patient about how this asymmetry will be managed and what effect the asymmetry may have on the final result.

Inframammary fold to nipple This distance is measured along the contour of the lower pole of the breast from the existing fold up to the nipple (Figure 4.24). This measurement is related to the size of the breast, the position of the fold and the position of the nipple on the breast. There can be great variability in this measurement with the distance measuring as little as 3–4 cm in very small patients and up to 9 cm or more in taller patients, patients with larger breasts and in patients with pseudoptotic expansion of the lower pole breast skin envelope. Noting this measurement triggers discussion of issues related to fold position,

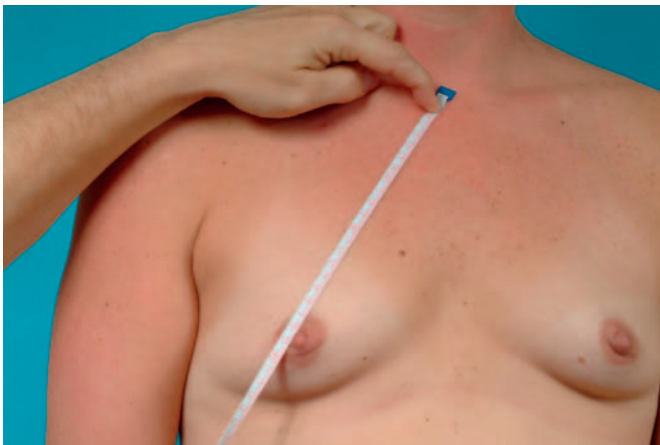

Figure 4.23 The sternal notch to nipple distance is measured and compared from side to side to document asymmetry in the position of the NAC.

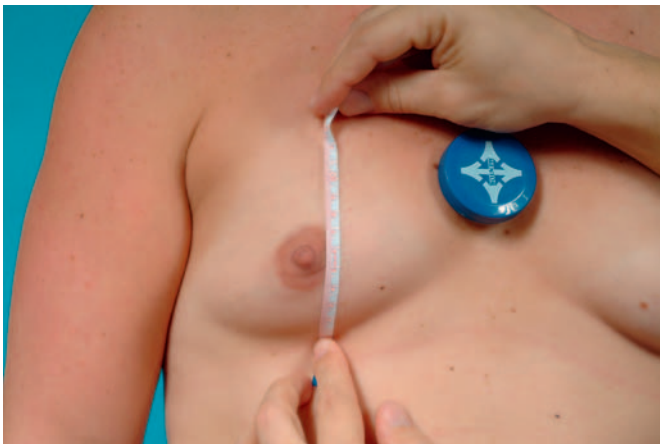

Figure 4.24 The inframammary fold (IMF) to nipple distance is measured to document the adequacy of the lower pole soft tissue envelope of the breast to accept the implant and to help determine whether or not the IMF will need to be lowered.

nipple position, selection of implant projection, the need for mastopexy and postoperative breast size. As such it is a very important measurement to document.

Inframammary fold to nipple under stretch This distance is measured from the inframammary fold up to the nipple with the lower pole breast skin placed under stretch. The skin is stretched by stabilizing the fold with the thumb and using the index finger placed at the nipple to maximally stretch the lower pole breast skin upward (Figure 4.25). By comparing this measurement to the resting distance from the inframammary fold to the nipple, a rough estimate is provided regarding the elasticity of the lower pole soft tissue skin envelope of the breast. By noting the degree of elasticity, variables such as implant volume and implant projection can be better matched to the soft tissue characteristics of the patient and errors in implant selection can be avoided. Specifically, when the degree of stretch is 3 cm or more, a more projecting implant is indicated to fill out appropriately the lax skin envelope. When the degree of stretch is less than 3 cm, the use of a highly projecting implant can create pressure on the implant secondary to the inelastic soft tissue cover, making a moderate-profile implant a better choice.

Intermammary distance This measurement reflects the distance between the most medial aspect of each breast as the breast is slightly pushed inward to accentuate this landmark (Figure 4.26). By itself, this measurement does not directly impact breast implant selection but it does highlight the patient's pre-existing anatomy and triggers a very important discussion concerning 'cleavage'. Many patients present with the assumption that a breast augmentation will significantly enhance the degree to which the breasts will touch in the midline. This is often misinterpreted by patients as an expected outcome of an increase in the size of the breast. However, many patients have breasts that are positioned somewhat laterally on the chest wall and present with a wide distance across the sternum between the breasts. Any attempt to create 'cleavage' in a patient such as this may be ill advised as the skin in this portion of the breast and over the sternum is so thin that unacceptable implant visibility or palpability may result. Also, to expand the base diameter of the implant to try to fill in this medial contour may result in the use of an implant that is so big that it distorts the other contours of the breast. These are very

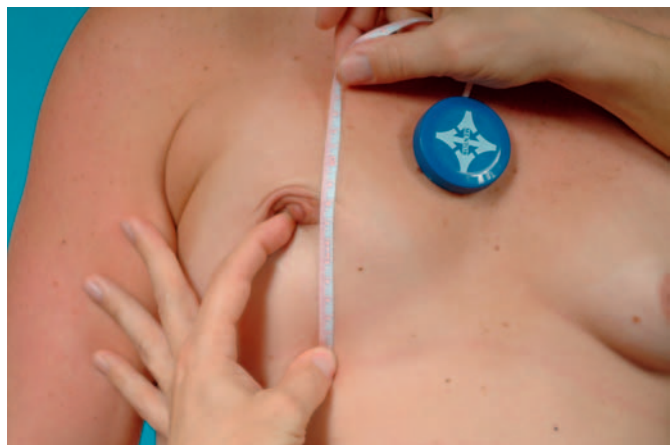

Figure 4.25 The inframammary fold to nipple distance under stretch is measured to document the elasticity of the soft tissue envelope.

important discussions to have with the patient preoperatively and any limitation in the amount of cleavage that can be safely created by the breast augmentation procedure must be documented and agreed upon ahead of time to prevent potential postoperative patient dissatisfaction (Figure 4.27).

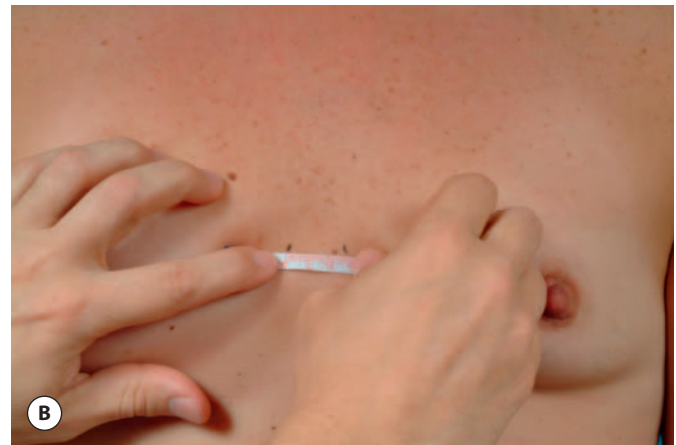NAC dimensions The width and length of the areolar diameter is measured under no tension and preferably before the areola is manipulated so that contracture of the areolar smooth muscle fibers does not artificially constrict the areola (Figure 4.28). Again, by itself, this measurement does not directly affect implant selection; however, it does identify those patients who present with an enlarged areola. In these patients (resting areolar diameters of >5 cm), breast augmentation can often cause the areola to stretch to excessive dimensions that detract from the overall result (Figure 4.29). To prevent this from occurring, some patients may elect to undergo an areolar-reducing purse-string procedure to restore a proportionate relationship between the

areola and the breast. In addition, should the areolar dimensions be asymmetric, appropriate discussions are triggered with regard to how the final result will be affected and what, if anything, might be done to restore symmetry. Discussing this aspect of the procedure ahead of time can again help head off any potential for patient disappointment. It also helps to identify those patients who might benefit from a periareolar approach to access the breast for placement of the implant.

NAC asymmetry This is an observation that can be demonstrated by laying an extended tape measure or shining a laser leveler across the chest at the level of the nipple to visualize any asymmetry that might be present in the location of the NAC (Figure 4.30). Surprisingly, many times patients are unaware of their asymmetric NAC position and it can be helpful to have the patient stand in front of a mirror and visualize for themselves the degree of asymmetry that is present. NAC asymmetry is a key preoperative anatomic relationship to recognize and discuss with



Figure 4.26 (A) The intermammary distance is measured by marking the medialmost extent of each breast when slight pressure is placed on the breast laterally. (B) Noting the distance between these two points provides



an estimate of how much 'cleavage' the patient can expect to achieve after breast augmentation.

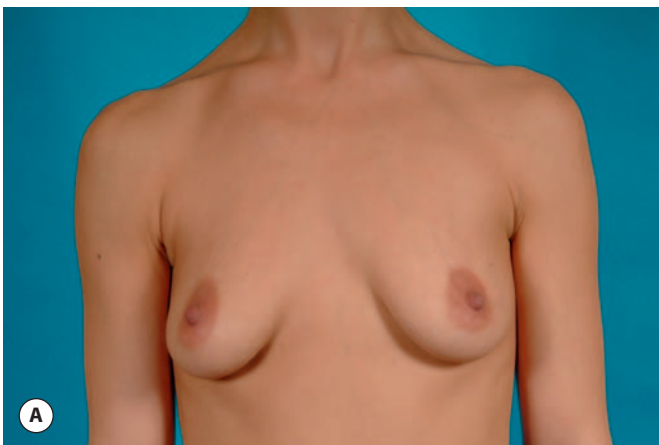
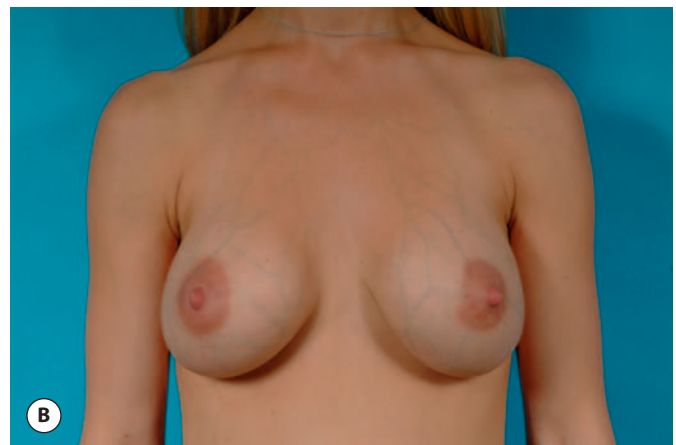


Figure 4.27 (A) Preoperative appearance of a 28-year-old woman who presents for breast augmentation. She demonstrates a wide intermammary distance along with breasts that are slightly laterally displaced on the chest wall. As a result, there is little chance of providing 'cleavage' without undermining the very thin skin over the sternum and risking both implant visibility and palpability along with implant malposition. (B) Postoperative appearance after undergoing subglandular breast augmentation using



an anatomically shaped cohesive gel implant. Despite the pleasing size, shape and symmetry demonstrated by her result, there remains a widened distance between the breasts with a flat pre-sternal contour and no 'cleavage'. If this lack of 'cleavage' had not been discussed with the patient preoperatively, the patient might very well have been dissatisfied with her postoperative result.

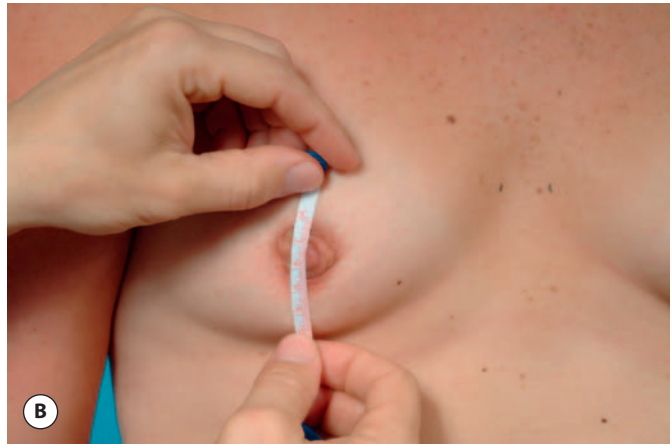
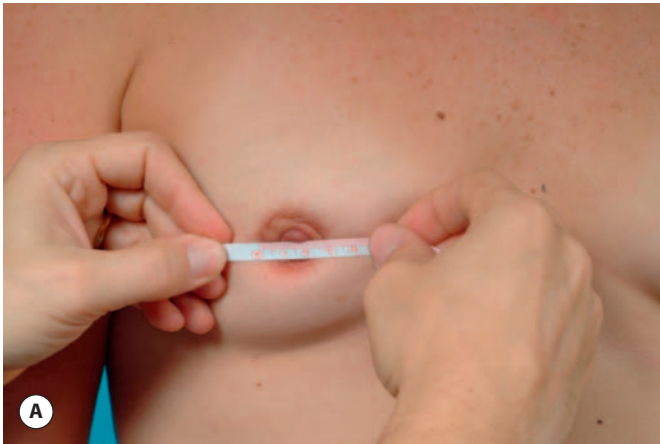
Figure 4.28 (A,B) The dimensions of the areola are measured to determine the adequacy of a periareolar incision and to help predict

whether or not excessive postoperative areolar spreading will occur.

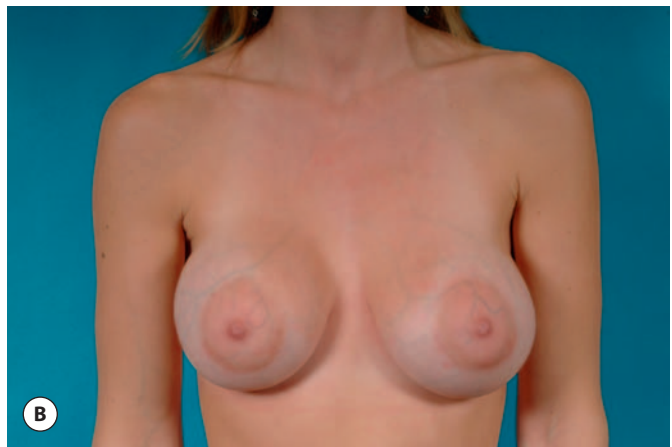
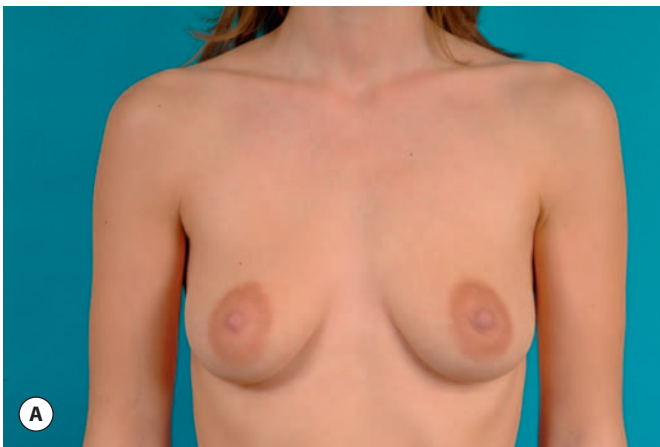


Figure 4.29 (A,B) Preoperative and 1 year postoperative appearance of a patient after undergoing breast augmentation using smooth round saline implants in the subglandular plane. Due to the fact that the areolar diameter was wide to begin with, the postoperative appearance of the areola becomes excessive as the skin of the breast is stretched by the

underlying implant. This possibility must be pointed out to the patient ahead of time to prevent postoperative dissatisfaction or perhaps trigger discussion of possible periareolar reduction as part of the primary augmentation procedure.

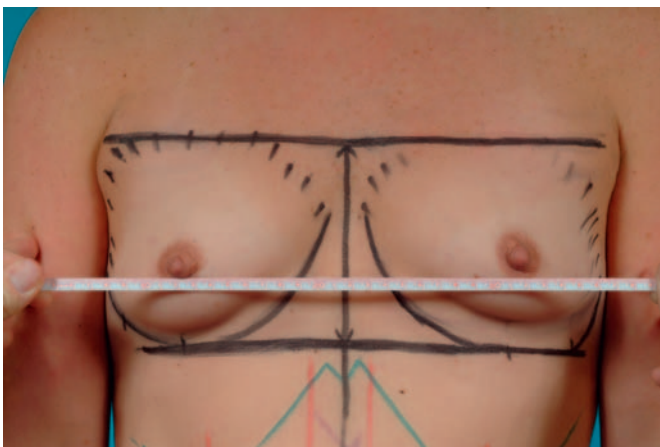


Figure 4.30 The degree of symmetry in the location of the NAC is assessed by extending a tape measure across the chest parallel to the ground and noting where each NAC lies in relation to this landmark.

the patient during the preoperative evaluation because, should NAC asymmetry persist postoperatively, it can be a major cause of patient dissatisfaction. By noting preoperative differences in nipple height, appropriate discussions are triggered with the patient about whether or not the asymmetry will be addressed with the operative plan.

Inframammary fold asymmetry By similarly using an extended tape measure or laser leveler, any asymmetry in the most inferior aspect of the inframammary fold on each side can be demonstrated and this asymmetry can be measured and documented (**Figure 4.31**). Asymmetry in the position of the inframammary fold is very important to identify preoperatively as differences in the location of the fold can have a tremendous impact on the shape and overall symmetry of the augmented breast. When asymmetry in fold location is present, some alteration in operative technique is very often required to restore a sense of symmetry to this critical breast landmark.

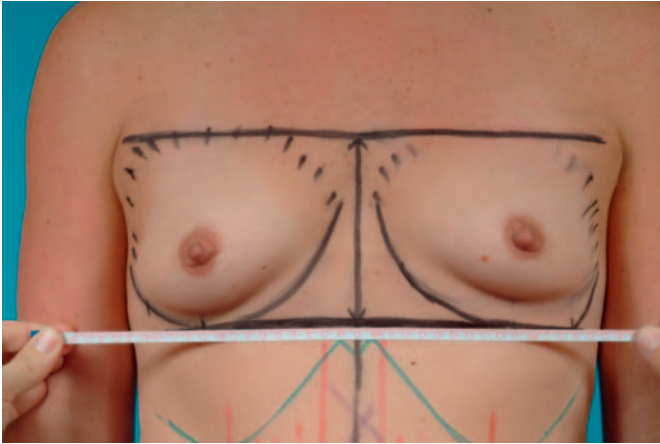


Figure 4.31 The degree of symmetry in the location of the inframammary fold is assessed by noting where the most inferior aspect of each fold lies in relation to a straight edge held across the chest. In this case, the left fold is higher than the right, indicating that some alteration in surgical technique will be required to compensate for this preoperative asymmetry.

In my opinion, setting and *maintaining* the position of the inframammary fold is the most critical element of not only breast augmentation, but really of any procedure designed to augment, reduce, lift or reconstruct the breast. If the inframammary fold is inaccurately set, or if the position of the fold is lost during the postoperative maturation process, nearly every other contour is adversely affected including the shape of the upper pole, the shape of the lower pole, the position of the NAC, the position of the breast on the chest wall and the degree of symmetry that is evident from side to side. Therefore, recognizing and addressing preoperative asymmetry in the level of the fold becomes an extremely important part of the overall operative plan. It cannot be stated emphatically enough that the inframammary fold is the *foundation* of the breast and developing operative technique that appropriately sets and maintains the position of this key landmark is a vital component of successful aesthetic breast surgery.

Breast volume The volume of each breast is determined by gently cupping the breast and estimating the contained volume (Figure 4.32). The accuracy of this estimate will be subject to variability depending on the experience of the surgeon; however, the true utility of this maneuver is to compare the estimated volume from side to side in an attempt to identify any volume asymmetry in the breast that might be corrected with the use of different-sized implants.

Chest wall asymmetry The general appearance of the chest wall is noted with particular attention directed at any asymmetry that may be present in the shape or prominence of the ribs or sternum. When the basic structural support of the chest wall and, therefore, the breast is distorted or asymmetric, the effect on the shape of the breast after augmentation can be significant. It is very important to observe and discuss any degree of chest wall asymmetry ahead of time and point out any limitations this may place on the quality of the overall result. Such observations may alter the surgical

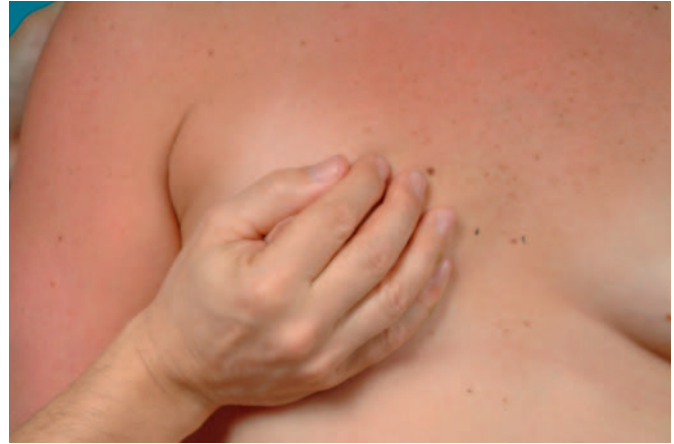

Figure 4.32 By using a gentle cupping maneuver, the preoperative volume of the breast can be estimated. By comparing this estimate from side to side, the need for implants of differing volume can be assessed.

plan to try to correct for any asymmetry. For instance, if the rib contour on one side is slightly depressed, a larger implant on the involved side may help create the illusion of better symmetry. These observations can often be subtle, but recognizing these factors can assist in preventing postoperative patient dissatisfaction.

Shaping Measurements

These are, comparatively speaking, the most important measurements made during the preoperative evaluation as they directly guide the selection of a breast implant. They are meant to assess the adequacy of the soft tissue cover of the breast, which then allows a breast implant of the appropriate dimension to be selected that will best complement the native breast to optimize the aesthetic result. Also, guidance as to the optimal surgical technique is provided, based on the results of these measurements.

Desired breast base diameter This measurement is designed to identify the maximal base diameter of the breast after augmentation. A slide rule is positioned under the breast and the measuring points are positioned where it is estimated that the medial and lateral breast contours of the augmented breast will be located (Figure 4.33). This estimated measurement therefore includes not only the width of the breast implant but also the thickness of the soft tissue cover located at the medial and lateral edges of the breast.

Medial and lateral pinch thickness Standard skin fold measuring calipers are used to measure the thickness of the soft tissue cover present at the medial and lateral margins of the breast. These calipers are readily available and have been used to good effect in determining body fat percentages for patients undergoing weight loss and, in particular, for athletes preparing for bodybuilding and fitness competitions. With experience, repeatable and accurate measurements can be obtained. By pulling the soft tissues of the breast away from the chest wall and pinching the breast such that a fold is created that includes the skin and underlying breast parenchyma and fat, the thickness of this fold can be directly measured by placing the calipers across the fold and noting the thickness measured in millimeters (Figures 4.34, 4.35).

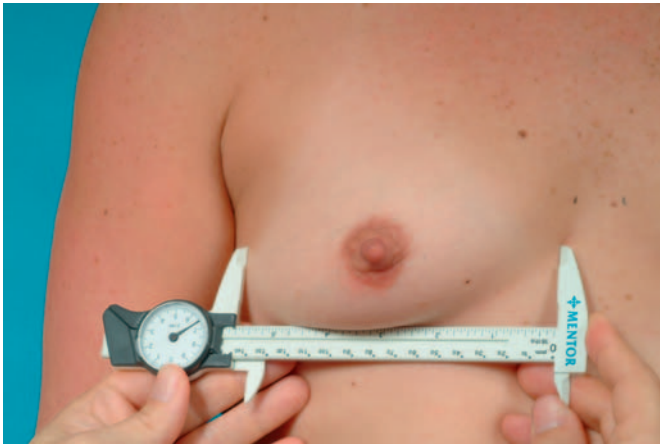

Figure 4.33 The base diameter of the breast that will result after augmentation is estimated by positioning a slide rule under the breast and opening the sliding mechanism to the desired diameter.

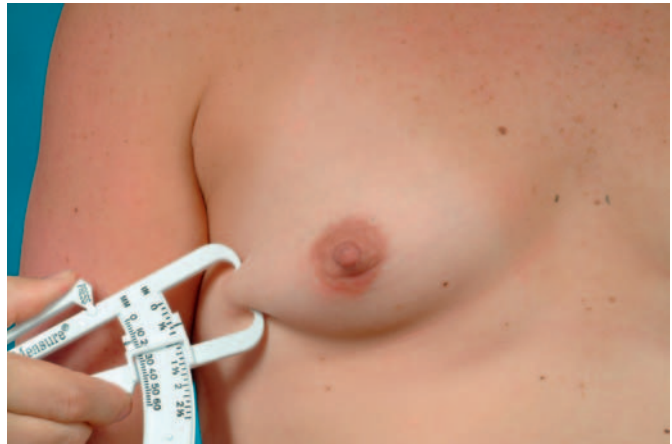

Figure 4.35 The contribution of the lateral soft tissue fold is assessed in a similar fashion.

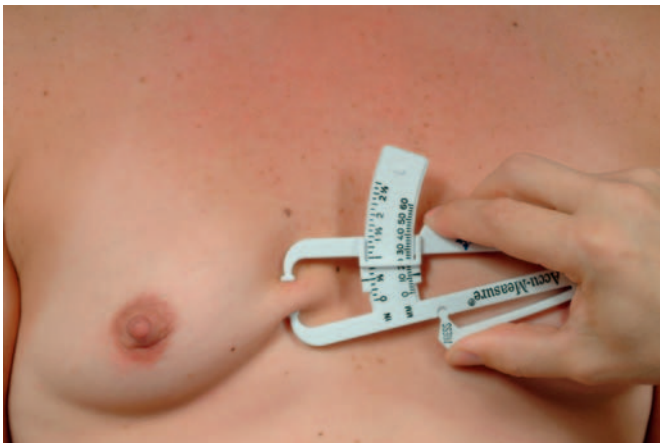

Figure 4.34 The thickness of the soft tissue layer of the medial aspect of the breast is assessed with the use of a body fat caliper. By using this device, which is set to compress the tissue at a consistent tension, the contribution of the soft tissue to the overall shape and volume of the breast in this location can be directly measured by taking the skin fold measurement and dividing by two, since the measurement actually represents the skin fold doubled over on itself.

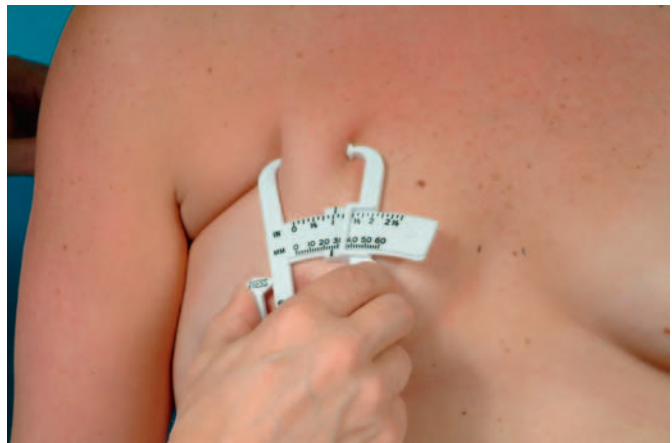

Figure 4.36 The thickness of the soft tissue cover in the superior pole of the breast where the top edge of the implant is estimated to be positioned is measured with the skin fold calipers. This measurement can be used to identify those patients who may be candidates for augmentation using the subglandular plane.

It must be remembered that the actual thickness of the soft tissue cover in these two areas will be half of the measured fold thickness as the skin fold is doubled on itself with the pinching maneuver. These measurements indicate what the contribution of the medial and lateral aspects of the soft tissue cover of the breast will be to the overall base diameter of the augmented breast.

The use of skin calipers can provide a more accurate and reproducible way to measure skin fold thickness than simple estimation done by pinching the skin with the index finger and thumb. However, using skin fold calipers does require some understanding of how they work. Every caliper is designed to apply a preset amount of compression to the measured fold as the jaws of the caliper pinch down against the skin. In this fashion, a reproducible result will be obtained with every

measurement. Some calipers accomplish this with a spring mechanism loaded into the device itself, others use a built-in compression latch that snaps into place when the proper amount of compression is applied. Whatever type of caliper is used, a proper understanding of how the compression is set will ensure that accurate and reproducible readings will be obtained.

Upper pole pinch thickness This measurement is made in the upper pole of the breast at the point where it is expected that the most superior aspect of the breast implant will be positioned (Figure 4.36). By pinching the skin and fat of the upper pole of the breast together, it is possible to apply the calipers to measure the thickness of the resulting fold. As with the reading obtained at the medial and lateral margins of the breast, the thickness of the soft tissue cover will be one half the measured skin fold thickness. This measurement can be used to assist in making the decision of which pocket plane to use. If this soft tissue thickness is measured at 1.5–2 cm (actual fold thickness of 3–4 cm),

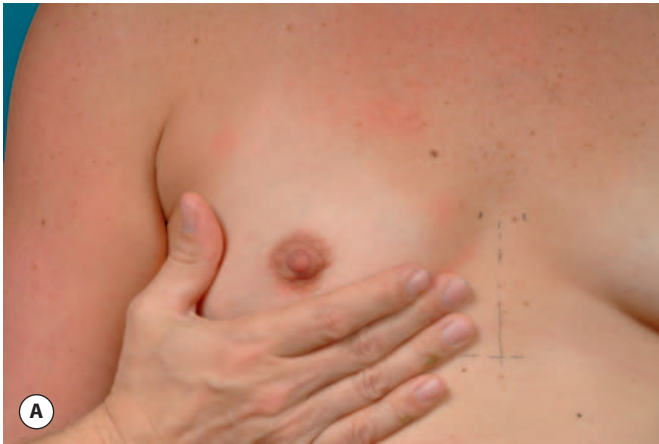
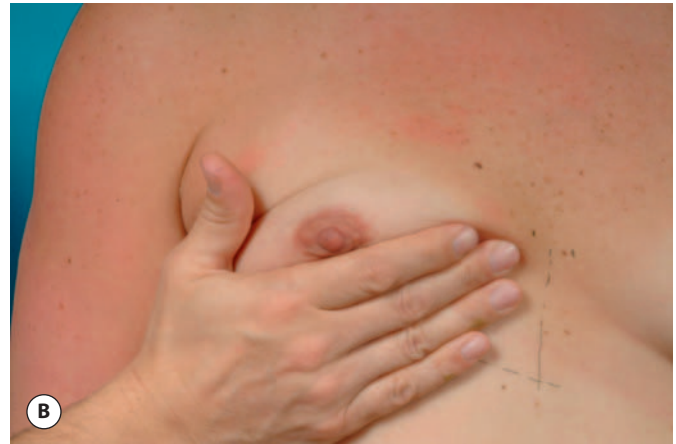
Figure 4.37 (A,B) By gently cupping the inferior pole of the breast and displacing the breast upward, a crease forms along the superior pole.



This crease represents the top of the breast where the implant will taper off to the chest wall.

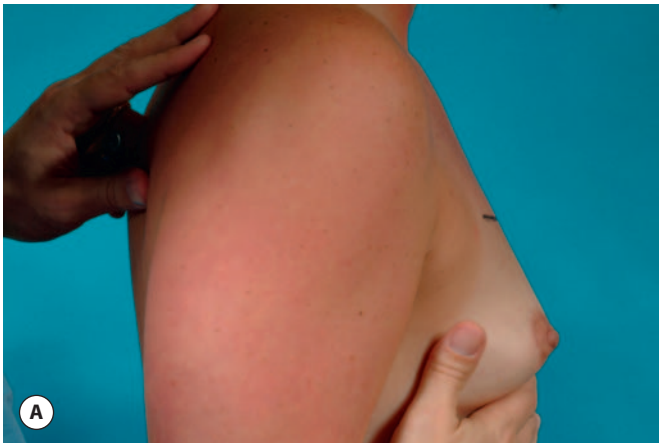
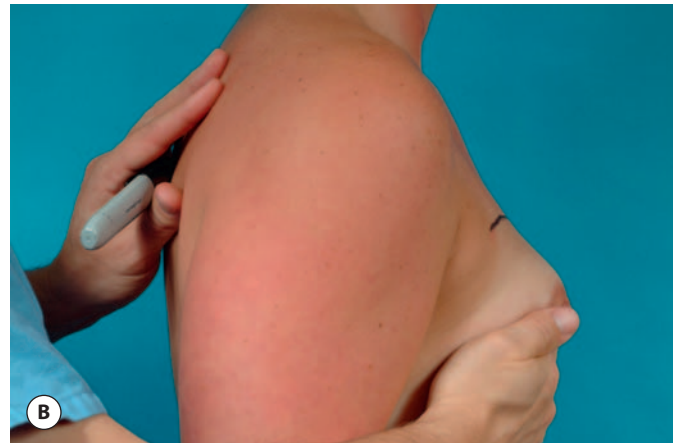
Figure 4.38 (A,B) Lateral view of the same maneuver showing the prominent crease that forms across the top of the breast. This location



represents where the top of the implant will be optimally positioned to create a natural slope in the superior pole of the augmented breast.

then there will be enough of a soft tissue cover to allow a round, firm and potentially distorting saline implant to be used in the subglandular plane without risking a visible or palpable implant edge. For round silicone gel implants, this soft tissue thickness measurement can be reduced to 1–1.5 cm as gel implants settle into the pocket in a more conforming way and there is less of a risk for upper pole show due to the implant. Finally, for cohesive anatomic gel implants that provide a more contoured upper pole takeoff in the device, this measurement can be reduced further to 0.5–1 cm. It must be remembered that these measurement recommendations are approximations and all the other variables that can affect the postoperative result must be taken into account when considering the subglandular pocket plane.

Breast height The height of the breast must be measured when using anatomically shaped cohesive gel implants as these devices have specific vertical dimensions that must be accurately matched to the patient to obtain the optimal result. To measure vertical height, the proposed level of the inframammary fold is set and marked. The breast is then translocated superiorly with the cupped hand until a break point or fold is observed in the

superior pole of the breast and this point is marked (Figures 4.37, 4.38). This represents the eventual top of the augmented breast or the point at which the soft tissues will begin to pull away from the chest wall as the implant is inserted underneath. By carrying the location of these two points over to the sternum and measuring the distance between them, the vertical height of the implant can be estimated (Figure 4.39).

Implant base diameter Once these variables have been measured, the optimal base diameter for the implant can be calculated by taking the maximal base width and subtracting one half the medial and lateral soft tissue pinch thicknesses (Figure 4.40). Theoretically, this would be the base diameter measurement of the implant that would best fit under the soft tissues of the breast to appropriately fill out the skin envelope. Practically speaking, this measurement can be expanded or reduced by as much as 1 cm in some instances and still provide for an excellent result. This is due to the distensibility of the skin and the role that other factors such as body habitus, breast size and the desires of the patient have on the ultimate shape of the breast. When picking an implant, this measured parameter provides an

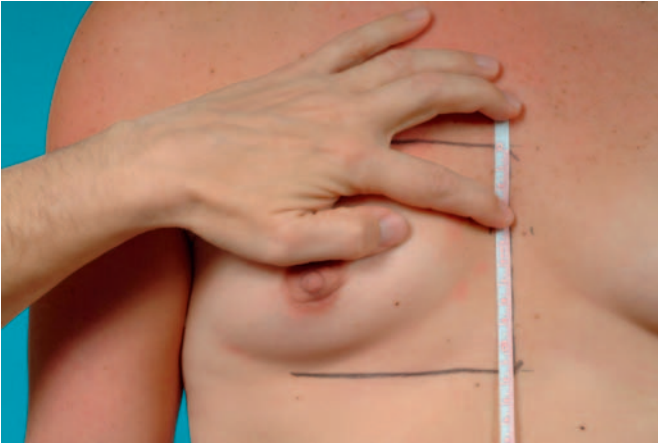


Figure 4.39 A parallel line is drawn from the proposed inframammary fold and the superior breast contour over to the sternum. A midsternal line is then drawn connecting these two points. By measuring the distance between these two points, the vertical height of the breast can be estimated. This measurement becomes particularly important when using cohesive anatomic gel implants that are available in differing heights.

excellent starting point which can then be modified according to other variables.

Skin Envelope Characteristics

Once the breast sizing measurements have been taken, a subjective assessment of the skin envelope is performed. By examining

and palpating the breast, the elasticity of the skin envelope is graded as tight, moderate or loose (**Figure 4.41A-C**). Also, the presence of any ptosis is noted. The importance of this assessment relates to the projection of the implant that is ultimately chosen. For a tight skin envelope, a moderate- or moderate plus-type implant is more appropriate as a high-profile implant with enhanced projection may not fit under the skin envelope without appearing crowded with prominent edges being noted around the periphery of the device. Conversely, for a loose skin envelope, a moderate-profile device may not effectively fill out the skin envelope and a high-profile device may be a better option.

Finally, once these measurements and observations have been made, the desires of the patient with regard to the size and shape of the resulting breast are documented according to a controlled and graded scale. This is one of the most important elements of the preoperative consultation as it provides the surgeon and the patient an opportunity to communicate accurately and agree on what the patient is hoping to achieve with the procedure. This scale is described in its entirety before the patient indicates what type of result she is seeking.

Result type 1 (**Figure 4.42**)

A very modest breast augmentation which gently fills out the skin envelope, but does not distort the breast. Even close friends may not notice that the breast has been operated on. Postoperative bra size may not change. The implant size is small and falls short of the maximal size that could be used in another circumstance.

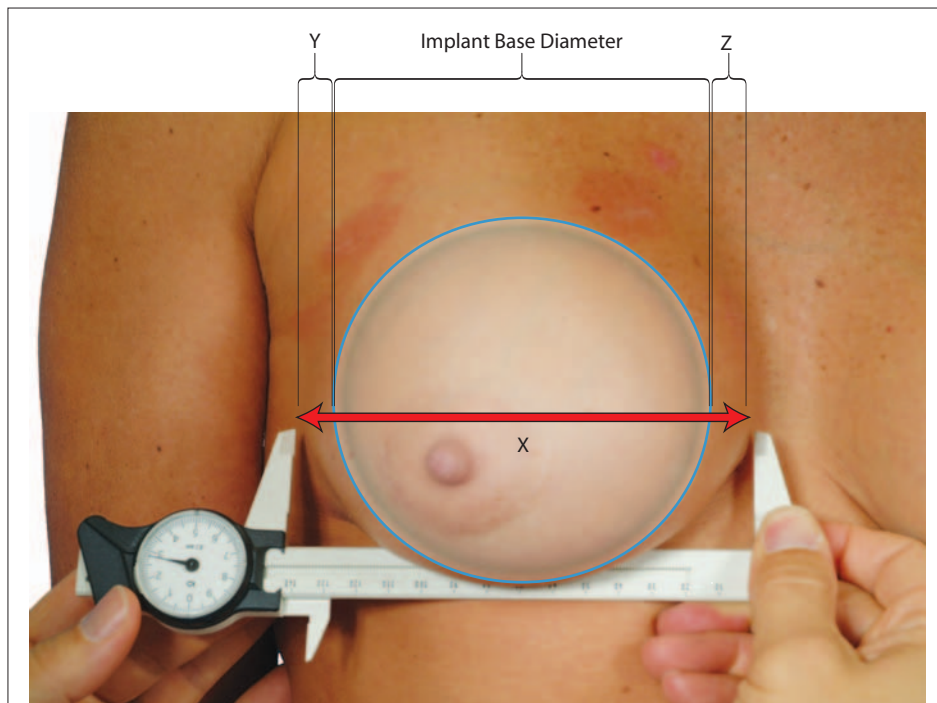


Figure 4.40 To calculate the base diameter of the implant that would optimally fit under the soft tissue framework of the breast, the maximal base diameter of the augmented breast (X) is estimated with the slide rule and the soft tissue pinch thickness at the lateral (Y) and medial (Z) borders of the inframammary fold is measured with the skin fold calipers. The base diameter of the implant would then be represented by the formula $\text{implant base diameter} = X - (1/2 Y + 1/2 Z)$.

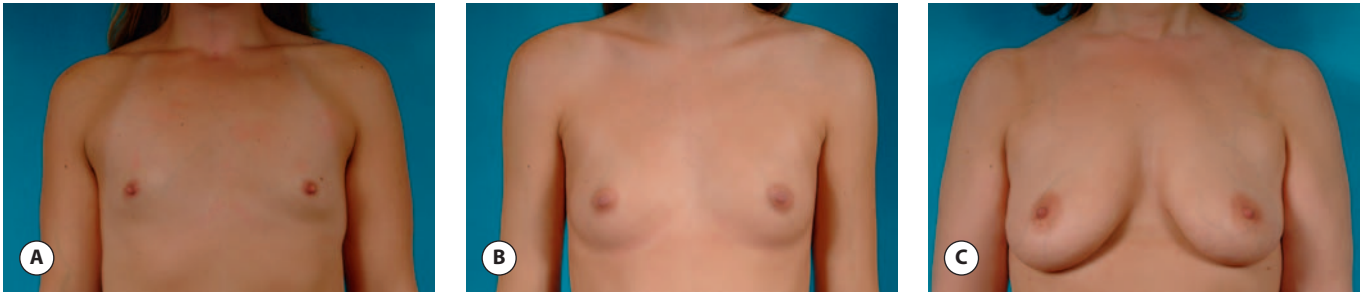

Figure 4.41 (A) This patient would be graded as a tight skin envelope. The breast is severely hypoplastic and the overlying skin is inelastic and tightly applied to the chest wall. In this clinical situation, low- or moderate-profile implants will provide the most natural result. (B) This patient would be graded as a moderate skin envelope. There is some breast parenchyma and the overlying skin has some elasticity to it and therefore has some capacity to expand. Here, a slightly higher profile implant can be used to take

advantage of the more elastic skin envelope and a mid- or moderate-profile plus device will provide the most natural result. (C) This patient would be graded as a loose skin envelope. What breast parenchyma that exists is ptotic and the skin envelope is excessive to the point of being redundant. The skin is quite elastic and has the capacity to expand significantly. Here a high-profile implant is best used to fill out appropriately the skin envelope in a smooth and even fashion.

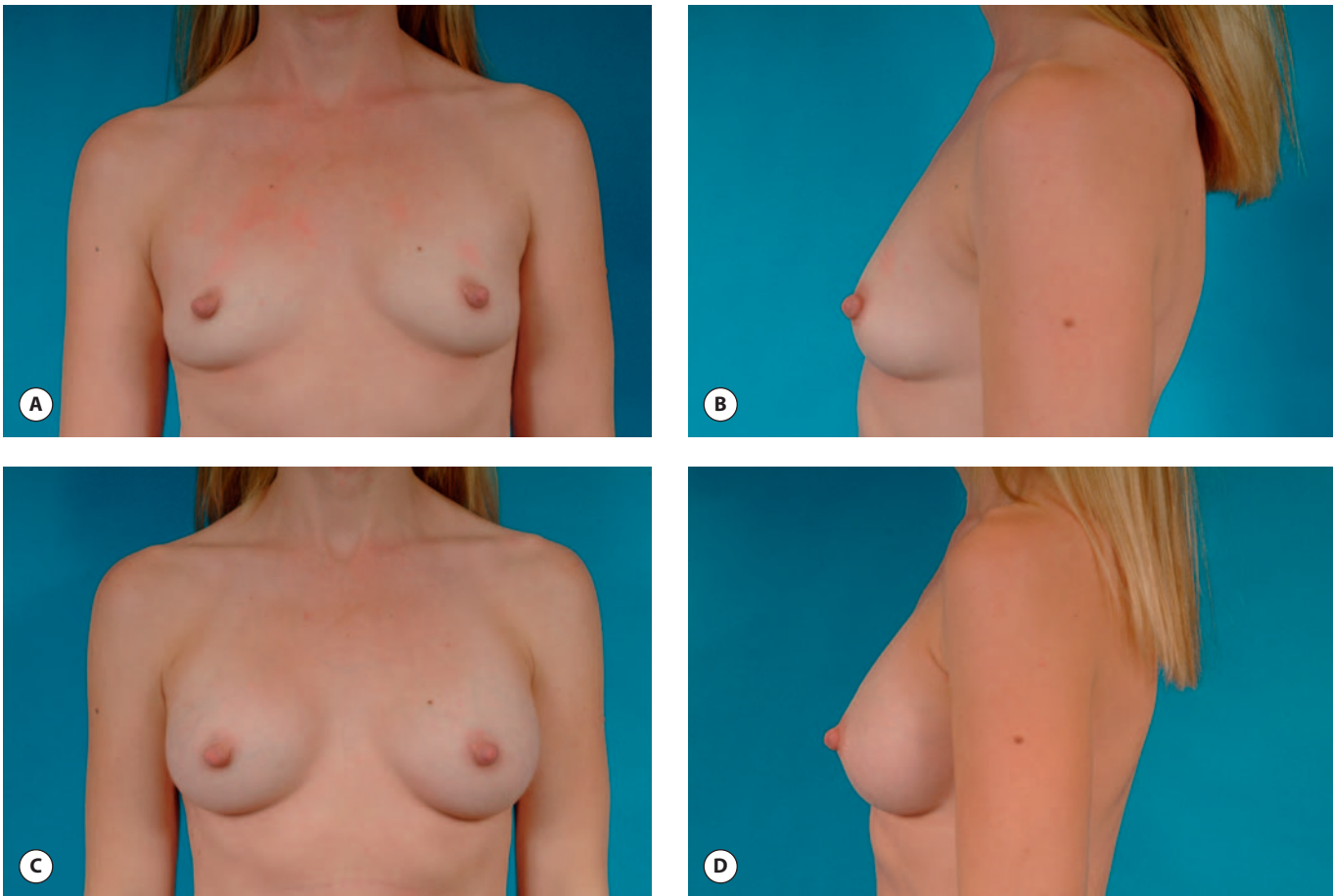

Figure 4.42 (A,B,C,D) Preoperative appearance of a 35-year-old woman in preparation for breast augmentation. She desires a type 1 result with a modest filling out of the skin envelope and a very natural contour to the breast. One-year postoperative result after placement of 280 cc mid-height

low-profile textured anatomic cohesive silicone gel implants in the partial subpectoral plane. The patient demonstrates a conservative filling out of the breast skin envelope and a very natural contour to the augmented breast.

Result type 2 (Figure 4.43)

A more aggressive breast augmentation that completely fills out the skin envelope. The breast is enlarged to the point where it is fuller, but still has a natural appearance. Most importantly, there is

no excessive bulging in the upper pole of the breast. In a bathing suit it will not be obvious or, at the most, some question will exist as to whether or not the breast has been augmented. Close friends will likely notice the size change and the bra size will go up.

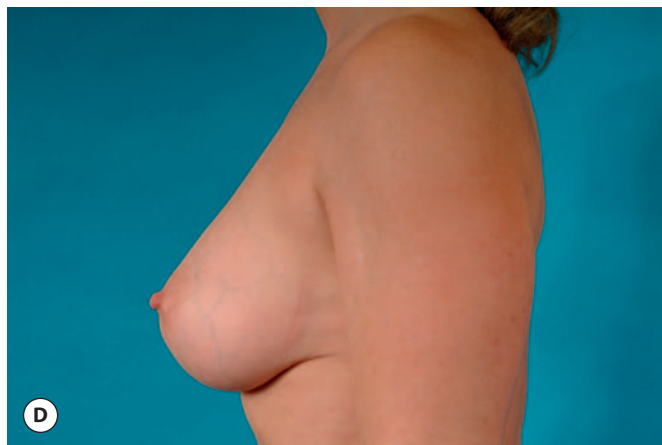
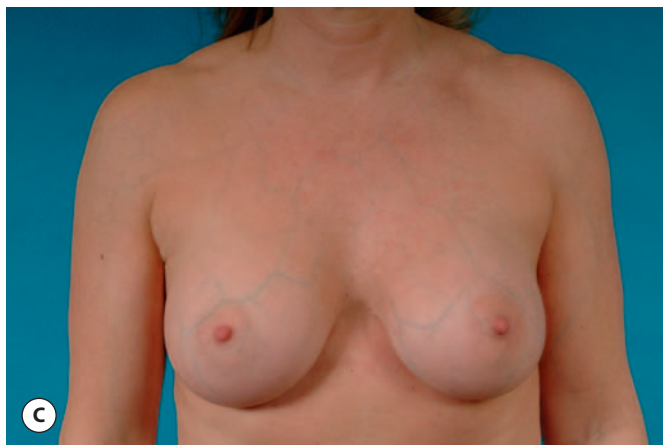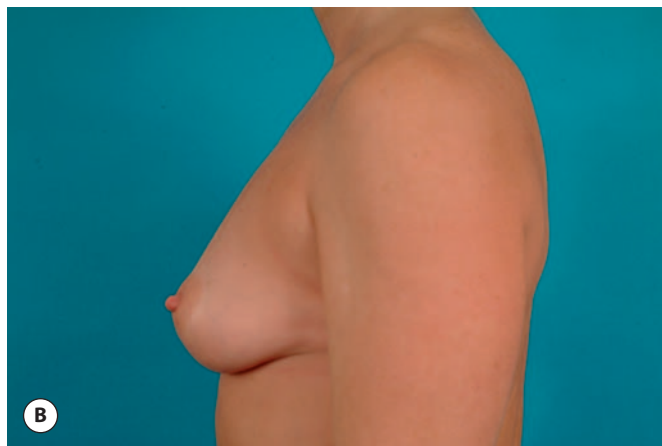
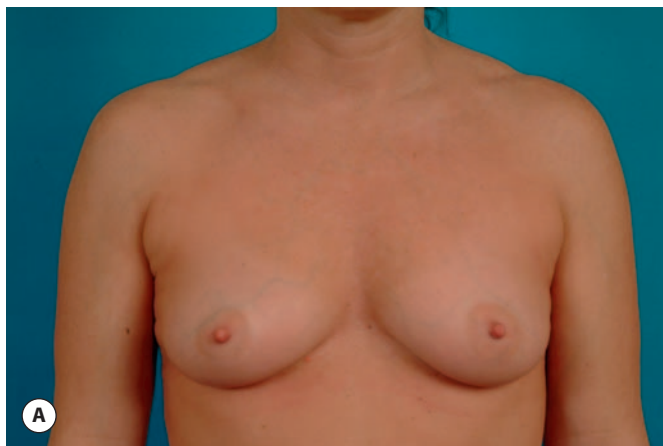


Figure 4.43 (A,B) Preoperative appearance of a 44-year-old woman in preparation for breast augmentation. She desires a type 2 result with a full natural breast that completely fills out the skin envelope but does not go so far as to appear artificial. **(C,D)** Two-year postoperative result after placement of 310cc full-height mid-projection anatomically shaped

cohesive silicone gel implants in the subglandular plane. The patient demonstrates a very natural appearance to the augmented breast with a complete filling out of the breast skin envelope without any excess fullness in the upper pole of the breast

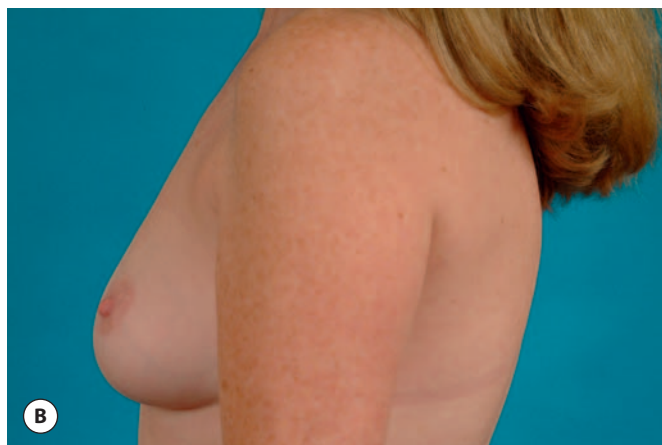
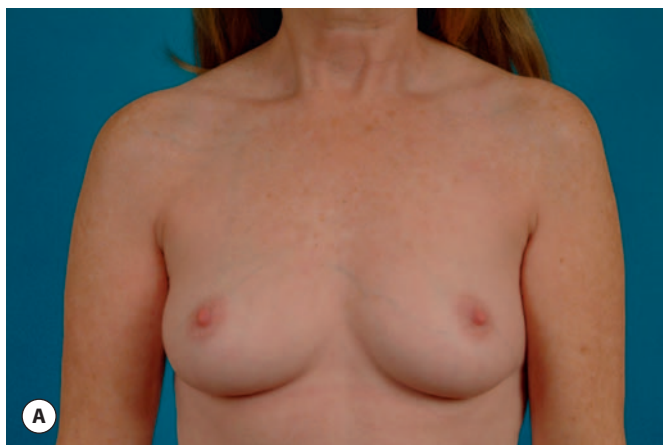
Figure 4.44 (A,B) Preoperative appearance of a 49-year-old woman in preparation for breast augmentation. She desires a type 3 result with a substantial increase in the size of the breast. **(C,D)** Four-month postoperative result after placement of 360cc moderate-profile smooth

round saline implants filled to 400cc in the subglandular plane. The patient demonstrates a very full breast contour that stands in stark contrast to the remainder of her body habitus.

Result type 3 (Figure 4.44)

An even more aggressive breast augmentation where not only is the breast completely filled out but it has a mildly artificial appearance. This can manifest as excessive upper pole fullness or

simply a breast that is so large that it appears out of proportion to the remainder of the body habitus. It is obvious that a breast augmentation has been done and even casual acquaintances will notice the size change.

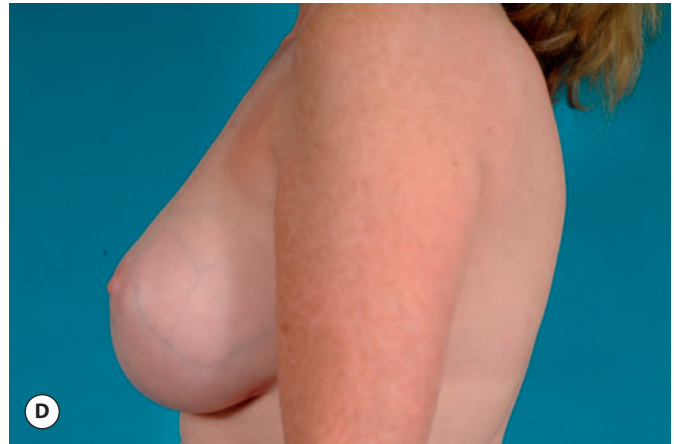
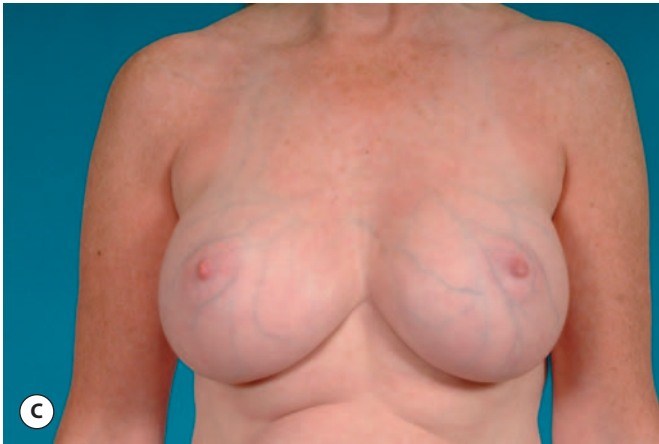
Figure 4.44 (Continued) (C,D) Four-month postoperative result after placement of 360 cc moderate-profile smooth round saline implants filled to 400 cc in the subglandular plane. The patient demonstrates a very full

breast contour that stands in stark contrast to the remainder of her body habitus.

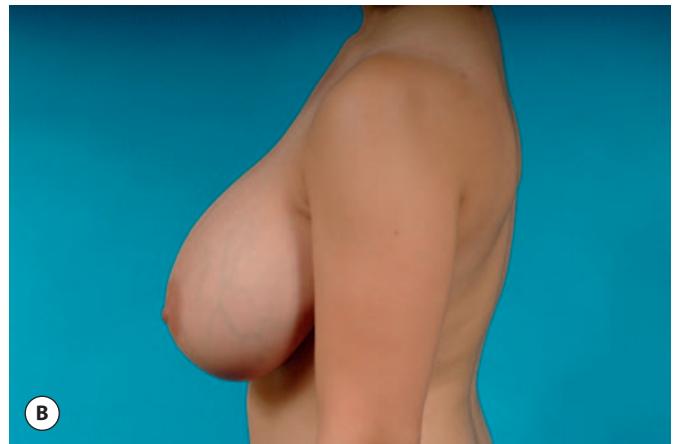
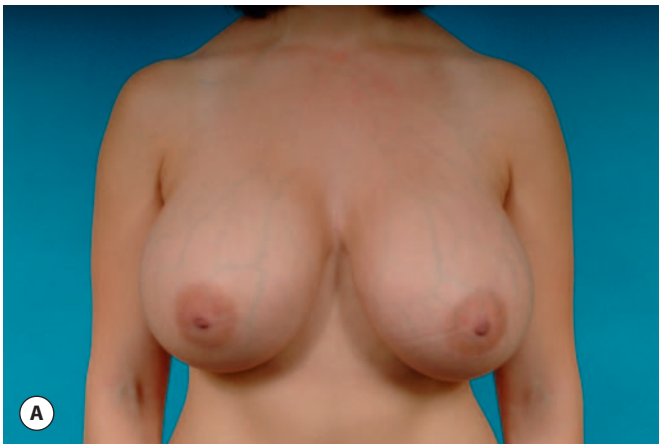


Figure 4.45 (A,B) Four-year postoperative appearance of a 24-year-old woman after placement of 800 cc high-profile smooth round silicone gel implants in the partial subpectoral plane. The breasts appear markedly

enlarged with a bulging upper pole contour and are significantly out of proportion to the remainder of the body habitus.

Result type 4 (Figure 4.45)

A significant breast augmentation using the largest breast implant possible with no regard for the shape of the breast. A markedly artificial appearance to the breast is created.

Using this result classification accomplishes two very important tasks. First, it allows a clear understanding on the part of the surgeon as to what type of result the patient is hoping for. This can greatly reduce the chance for a misunderstanding between the patient and the surgeon leading to unfortunate re-operations for size change. Secondly, it describes the desired result more in terms of shape rather than focusing only on volume. This is important as patients typically do not have the knowledge base to understand that specific size requests can often have adverse effects on breast shape. By re-focusing the discussion with regards to the final postoperative result on the appearance of the breast, rather than volume, the surgeon is more accurately describing what the operation can and cannot provide and the limitations that may result from choosing larger implants can be discussed. With this system, patient goals

involving a specific bra cup size are minimized and a more meaningful discussion can be had regarding breast shape and what limitations the patient's own pre-existing anatomy may have on that shape. In this fashion, patients generally become very well educated about the process of selecting a breast implant and are able to accept the fact that the bra cup size may vary, but the intended size and shape will be influenced more by the limitations of their own anatomy rather than trying to achieve a particular bra cup size. Most tellingly, bra cup size typically does not enter into the equation until after all the decisions have been made. At this point, many patients will inquire about what bra cup size might result from the chosen implant with the understanding that it is the end result of all the variables discussed beforehand rather than the over-riding factor governing a specific implant choice. Using this system of measurements and goal assessment has greatly enhanced the understanding that patients eventually gain about the breast augmentation procedure and it is rare to have any degree of patient dissatisfaction postoperatively related to the size of the breast.

Choosing an Implant

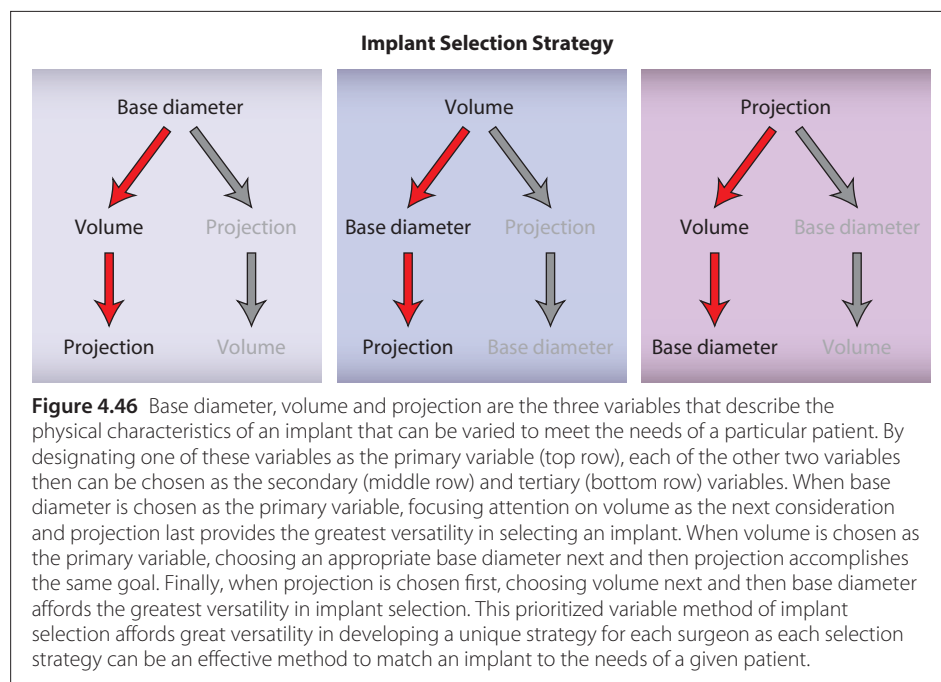
Now armed with patient-specific measurements, the process of selecting an implant to optimally match the breast can be performed. Most simply, for any round breast implant there are three structural design variables that describe how the breast will interact with the soft tissues of the breast to define the eventual breast shape and these include *projection*, *volume* and *base diameter* (Figure 4.46). Each of these variables has unique characteristics that can be thoughtfully manipulated to optimally select a particular implant for a specific patient. Combining these variables requires an organized approach with a specific goal in mind as to how the implant will interact with the soft tissues to provide the optimum result. To do this, it is helpful to designate one of the structural variables in implant design as the *primary variable* and then manipulate the other two in a fashion that maximizes choice to provide the desired result. This strategy is called the prioritized variable method of implant selection.

Projection as the primary variable For some patients, choosing the correct projection will be the most important decision that determines which implant will provide the best result. This decision is largely determined by the capacity of the existing breast skin envelope to expand to accept the underlying implant. Should this capacity be limited, it would be unwise to attempt to insert a high-profile implant under such a breast as the pressure exerted on the apex of the device could flatten the implant enough to create a rounded contour along the edges of the implant. This rounded contour could show through, particularly in the upper pole of the breast, creating an unwanted breast distortion. Conversely, if the skin envelope is lax, inserting a low-profile implant runs the risk of incompletely filling out the breast and creating a 'snoopy dog' type of deformity where the loose anterior breast skin and parenchyma falls off the front of the implant. Therefore, using projection as the primary variable ensures that the existing skin envelope is filled out properly and allows the next two variables to be

chosen in a complementary way with regard to the patient's existing anatomy. The next or secondary variable that must be chosen is therefore either base diameter or volume. Since small changes in base diameter (1 cm or less), which would have a negligible effect on the appearance of the breast, are associated with much larger changes in volume, which could greatly affect the appearance of the breast, it is advisable to use volume as the next variable. Combining projection with volume then generally mandates a particular base diameter and this measurement is checked to confirm that it falls within the parameters for base diameter developed during the breast evaluation process.

Volume as the primary variable For experienced surgeons, using volume as the primary variable is a very common technique for implant selection as previous experience with the operation allows a certain artistic judgment to be applied to reliably determine that a specific implant volume will fill out the skin envelope according to the patient's desires. Once this decision is made, either base diameter or projection must then be chosen as the secondary variable. Of the two variables, base diameter can have the greater impact on breast shape as once the volume is set, it can be more important to be certain that the chosen volume will fill out the breast from side to side (base diameter) as opposed to front to back (projection). Also, there is a greater range of incrementally increasing acceptable base diameters that can be selected for a given volume whereas, for projection, there are only three choices. For these reasons, base diameter becomes the second variable and projection is chosen third.

Base diameter as the primary variable By using the evaluation system outlined previously, an implant base diameter measurement will have been determined and this measurement can be used as the primary variable in implant selection. It is important to realize that this measurement represents the midpoint of what is actually a range of base diameters that will provide an acceptable result and this range can vary up to 1 cm or more depending



on the body habitus of the patient. This leaves volume and projection as potential choices for the secondary variable. If volume is chosen as the second variable, a range of potential volumes that are separated by small increments can be considered to meet the goals of an individual patient. However, similar to the situation noted with volume as the primary variable, projection has only three potential choices and this can be somewhat limiting when it comes to matching the correct implant to a given patient. Therefore, after taking first base diameter and then volume into consideration, projection is chosen third such that it will optimally allow the implant to fit the patient.

Method application No matter what variable is chosen as the primary variable, it is important to realize that all three methods of implant selection can provide an effective means to optimally select an implant that will effectively complement the existing soft tissue framework of the breast to provide the best result possible. In fact, it would be expected that each selection scheme would end up identifying the same implant or range of implants that would be an appropriate choice for a given patient. In practice, the most common strategy for many surgeons is to consider the base diameter and volume variables almost simultaneously when choosing a breast implant and then choose the projection that best fits their needs. Also, when each of the three variables is combined as described, it is not uncommon to adjust the parameters of one variable to allow the parameters of a second variable to be similarly adjusted to achieve a specific goal. For example, if a measured base diameter will not allow an implant of appropriate volume to be used, as determined by the surgeon, then the parameters of base diameter can be increased slightly to allow an implant of greater volume to fit into the selection system. No matter what sequence is utilized, isolating the thought process into primary, secondary and tertiary variables does help to organize the strategy involved in choosing an implant. Whether the surgeon is new and inexperienced, or mature and capable, conceptualizing the thought process behind managing these three variables in this fashion will increase the consistency and improve the accuracy of choosing a well-matched breast implant for an individual patient. Finally, it must be pointed out that, despite efforts to base implant selection on measured parameters, in many respects the process of choosing an implant is at times more art than science and it is important to recognize that artistic

impression can be just as helpful as any measurement and should never be ignored.

While I have used all three selection schemes to choose an implant for a specific patient, I have found the use of projection as the primary variable to be particularly helpful for many patients. I rely considerably on the portion of the evaluation process that describes the skin envelope as tight, moderate or loose, and I correspondingly use low-, medium- and high-projecting implants for these patients. I then have an estimated volume that I think will provide the result the patient is looking for and then finally check to be sure the projection/volume combination I have chosen matches the range of base diameter measurements developed during the evaluation process. Therefore, by first assuring that the implant I choose will appropriately fill out the skin envelope, the volume and base diameter can be adjusted to meet my needs.

Sizers Once either a particular implant or even an implant range has been selected, many surgeons will then utilize external sizers to help confirm the implant choice. These sizers allow the patient to participate in implant selection and provide a very rough idea of what the augmented breast might look like. Many different strategies for sizer construction have been utilized, ranging from very rudimentary devices such as baggies filled with rice to more sophisticated shaped forms designed to be put inside a bra (Figures 4.47, 4.48). Whatever type of external sizer is utilized, it is undeniable that many patients become very engaged in the implant selection process when afforded the opportunity to use these sizers. While the exact shape of the breast may not be accurately predicted by the use of external sizers, the degree of patient education that occurs is well worth the effort as patients begin to understand how their own anatomy will interact with the volume provided by the breast implant. Perhaps just as importantly, the volume of the external sizer that the patient selects can help confirm to the surgeon what type of result the patient is looking for and can trigger appropriate discussion as to whether or not that result is advisable and/or achievable.

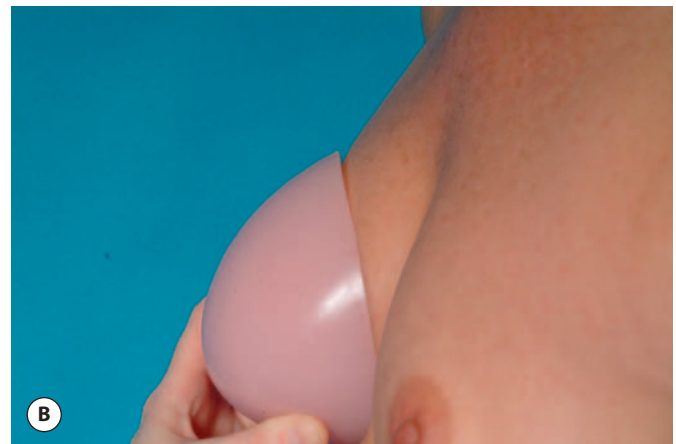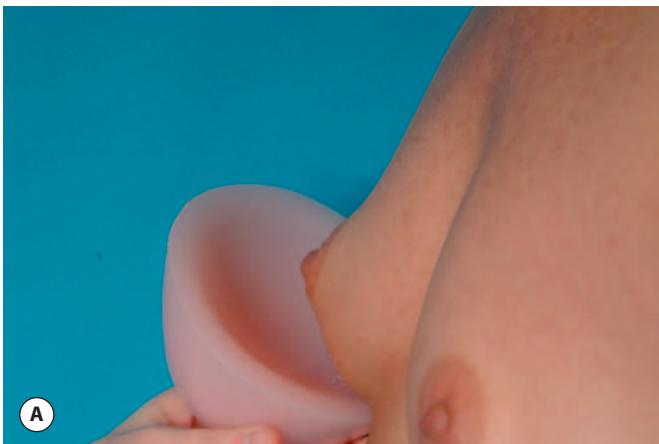


Figure 4.47 (A–B) Patient demonstrating a form-fitting sizer used to assist

in estimating implant volume in preparation for breast augmentation.

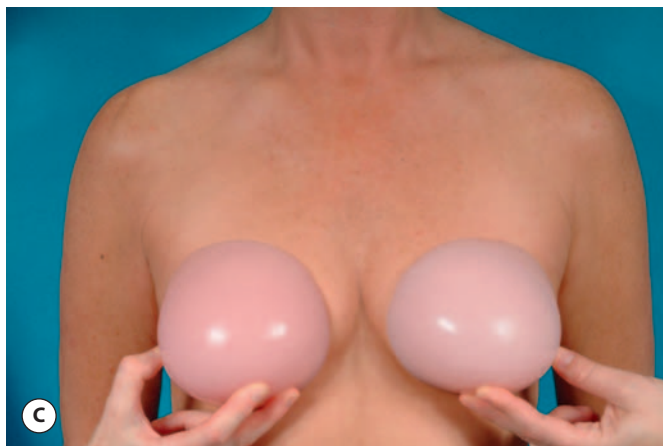

Figure 4.47 (C–D) (Continued).

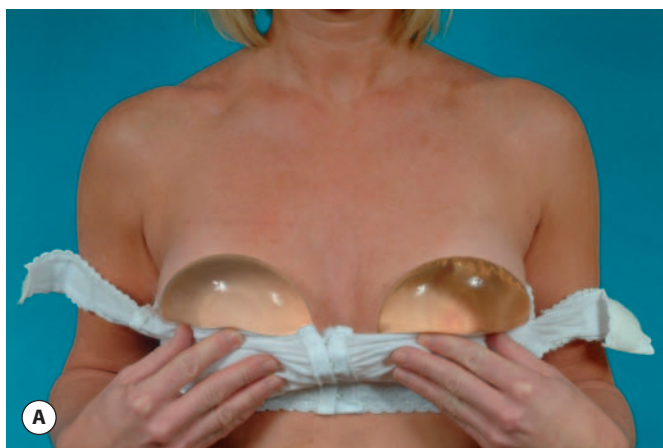
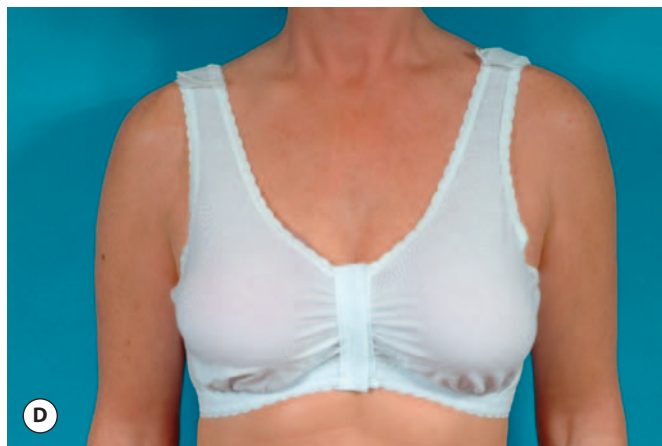
Figure 4.48 (A,B) Another strategy used to estimate volume is to insert a



silicone gel sizer that is a replica of an actual implant into a soft bra.

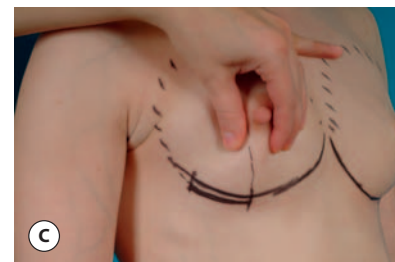
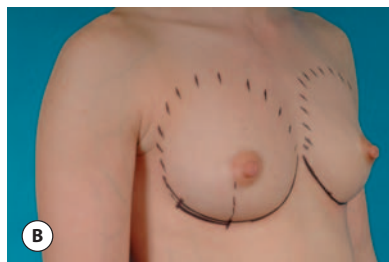
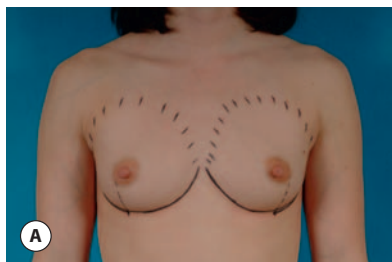


Figure 4.49 (A) The existing inframammary fold and the limits of the proposed dissection space are marked. (B) A line is dropped down from the lateral margin of the areola to the inframammary fold and the incision is then extended laterally along the fold. (C) Here the incision is lowered just

slightly to compensate for the expansion of the lower pole skin envelope that will occur when the implant is inserted. In this fashion, the scar will remain hidden directly in the fold and will be much less likely to ride up onto the breast.

Basic Technique

Inframammary Fold Subglandular Breast Augmentation

Patient marking The patient is marked in the upright standing position with the arms hanging loosely at the sides. The existing inframammary fold is marked and comparison is made from side to side to ensure symmetry. Although it is common practice to center the inframammary fold incision directly on

the breast meridian in the center of the breast, controlling the exact location of the fold can sometimes be a technical challenge when the incision is located directly in the fold as there can be a tendency to inadvertently lower the fold as the skin edges are retracted during the dissection of the remainder of the pocket. For this reason, the incision is moved laterally by drawing a perpendicular line down from the lateral margin of the areola to the inframammary fold. The incision line then extends laterally from this point along the fold for a distance of 3–6cm depending on which type of implant is to be used (Figure 4.49). In this

fashion, the access portal to the dissection space is moved away from the main portion of the fold, which allows this very important contour to be dissected and positioned accurately without distortion. In patients where the fold must be lowered to accommodate the implant, the location for the proposed new fold is

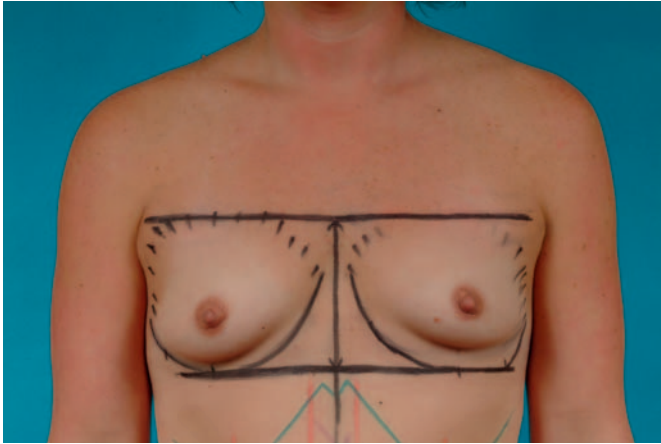


Figure 4.50 In cases where the inframammary fold must be lowered, the location of the new fold is marked and the incision is drawn at the level of this new fold, again extending laterally away from a perpendicular line dropped down from the lateral margin of the areola.

marked and the incision is marked as before in this new fold location (**Figure 4.50**). The lateral, medial and superior extent of the proposed pocket dissection is then outlined and the patient is readied for surgery.

Pocket development At surgery, the accuracy of the incision location is confirmed by pulling the breast away from the chest wall and applying downward pressure on the lower pole of the breast (**Figure 4.51A,B**). This maneuver mimics the forces that an implant will exert on the breast and can be used to make sure that the location of the incision will fall directly at the level of the inframammary fold. The incision is then made through the skin after first infiltrating the dermis with a dilute solution of local with epinephrine (**Figure 4.51C**). Dissection is carried through the dermis and superficial layer of fat until Scarpa's fascia is identified (**Figure 4.51D**). By placing hooked retractors in the superior skin edge and pulling upward, the plane between the superficial layer of fat and Scarpa's fascia can be easily delineated. Dissection is performed with bovie cautery and proceeds superiorly on top of Scarpa's fascia until it blends with the fibers of the anterior lamella of the breast (**Figure 4.51E**). At this point, the fibers of the anterior breast lamella are divided and the underside of the breast is entered on top of the posterior lamella of the breast (**Figure 4.51F**). Superiorly directed dissection will

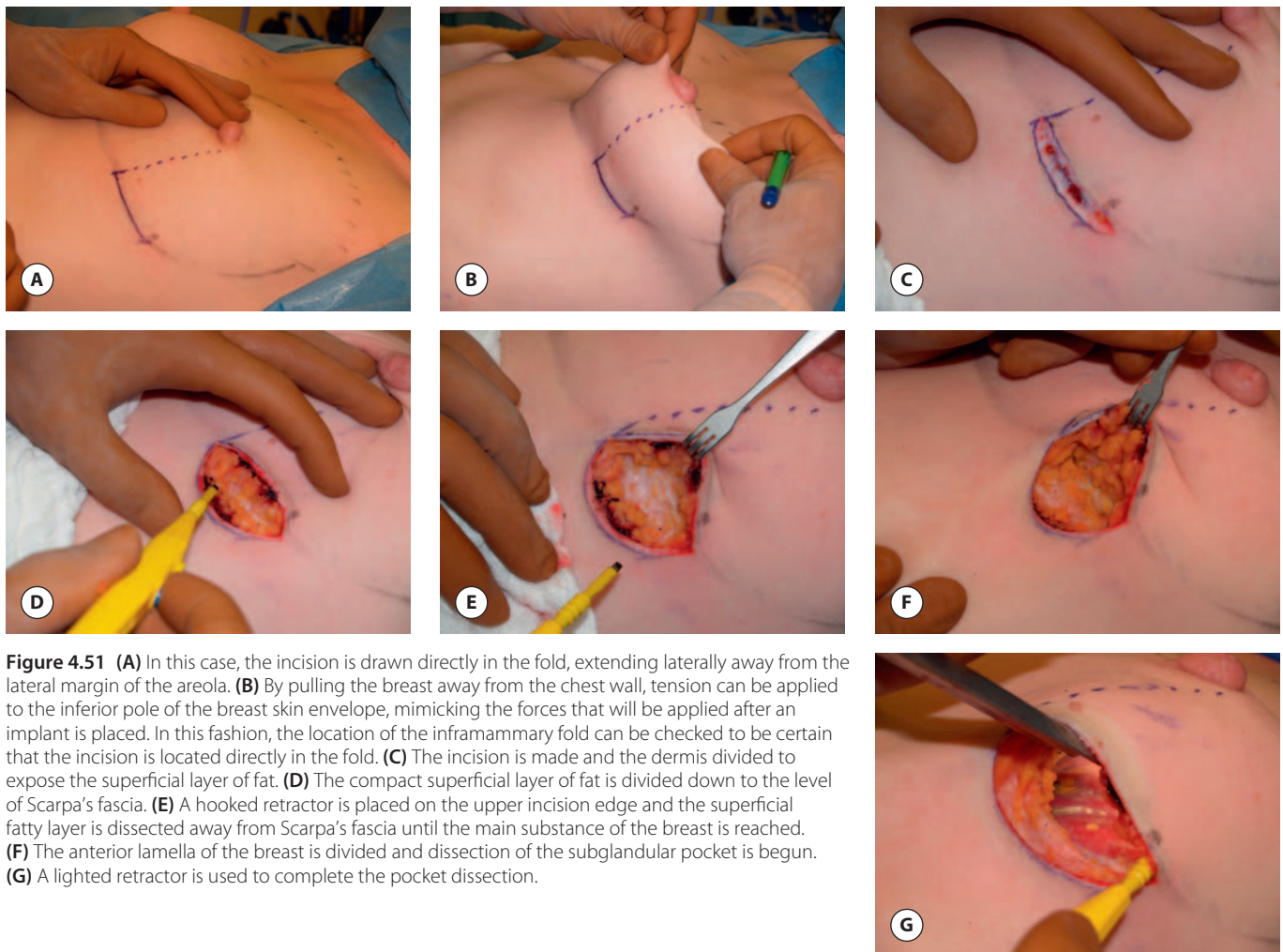


Figure 4.51 (A) In this case, the incision is drawn directly in the fold, extending laterally away from the lateral margin of the areola. (B) By pulling the breast away from the chest wall, tension can be applied to the inferior pole of the breast skin envelope, mimicking the forces that will be applied after an implant is placed. In this fashion, the location of the inframammary fold can be checked to be certain that the incision is located directly in the fold. (C) The incision is made and the dermis divided to expose the superficial layer of fat. (D) The compact superficial layer of fat is divided down to the level of Scarpa's fascia. (E) A hooked retractor is placed on the upper incision edge and the superficial fatty layer is dissected away from Scarpa's fascia until the main substance of the breast is reached. (F) The anterior lamella of the breast is divided and dissection of the subglandular pocket is begun. (G) A lighted retractor is used to complete the pocket dissection.

now identify the lateral border of the pectoralis major muscle. At this point, a lighted retractor is inserted into the pocket and, with strong upward traction, the dissection space just above the fascia of the pectoralis major muscle is opened (Figure 4.51G).

It is important realize that the technique of angling superiorly once the incision has been made is a technique that has been used successfully by many surgeons for years as it has long been realized that to dissect straight down to the chest wall risks inadvertent inferior implant malposition. The 'fascial sparing' technique described in the text is simply an anatomical explanation for this common observation.

In the lower portion of the pocket, this plane is somewhat adherent as this corresponds to the location of the breast septum, which extends from medial to lateral across the lower portion of the pectoralis major muscle. Perforating vessels and nerve branches can often be seen extending up into the breast in this area during this maneuver. These structures are divided under direct vision to provide absolute hemostasis. Once the lower portion of the pocket is dissected free, the area above the zone of adherence where the septum of the breast is located opens up into a loose areolar plane that dissects very easily. The entire upper portion of the pocket is then developed from medial to lateral. Medially, the pocket is developed over to the internal mammary perforators and every effort is made to avoid inadvertently dividing these vessels. It can be helpful to switch to the subfascial plane in the medial portion of the pocket as this can allow easier identification of the internal mammary perforators as the pocket is being opened.

The internal mammary perforators and, in particular the second intercostal perforator, are sizable branches of the internal mammary system and provide a significant source of vascularity to the breast. It is highly recommended to avoid injuring these vessels for several reasons. When these vessels are intact, in essence an axial pattern type of flap physiology is provided to the breast and it can be extrapolated from the physiology associated with muscle flaps used to cover complex wounds that the more robust the blood supply to the breast, the greater the ability of the breast to be resistant to infection. Also, if these vessels are injured, it can be difficult to control the subsequent bleeding as the pressure head behind these vessels is substantial. Even if the dissection stopped just short of the perforators, unrecognized injury secondary to the proximity of the bovie can occur, leading to late rupture and large, sudden hematoma formation. Finally, once these vessels are divided, the dissection space begins to extend over onto the sternum, which can result in visible and/or palpable implant edges.

Laterally, the pocket is opened under direct vision over to the lateral intercostal perforators. The anterior branches of the lateral intercostal nerves are closely aligned anatomically with these perforators and every effort is made to avoid injuring these structures so as to ensure as much as possible unaltered sensation

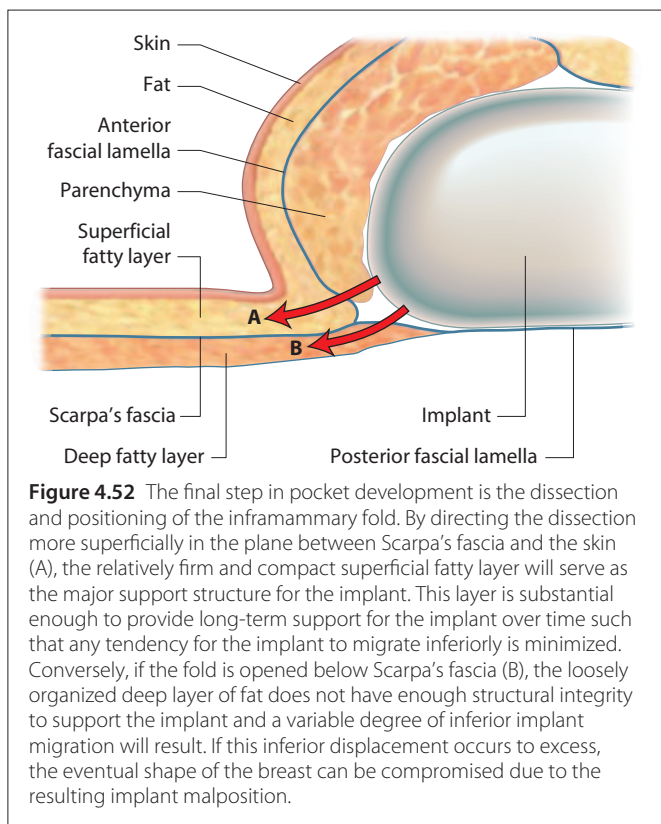


Figure 4.52 The final step in pocket development is the dissection and positioning of the inframammary fold. By directing the dissection more superficially in the plane between Scarpa's fascia and the skin (A), the relatively firm and compact superficial fatty layer will serve as the major support structure for the implant. This layer is substantial enough to provide long-term support for the implant over time such that any tendency for the implant to migrate inferiorly is minimized. Conversely, if the fold is opened below Scarpa's fascia (B), the loosely organized deep layer of fat does not have enough structural integrity to support the implant and a variable degree of inferior implant migration will result. If this inferior displacement occurs to excess, the eventual shape of the breast can be compromised due to the resulting implant malposition.

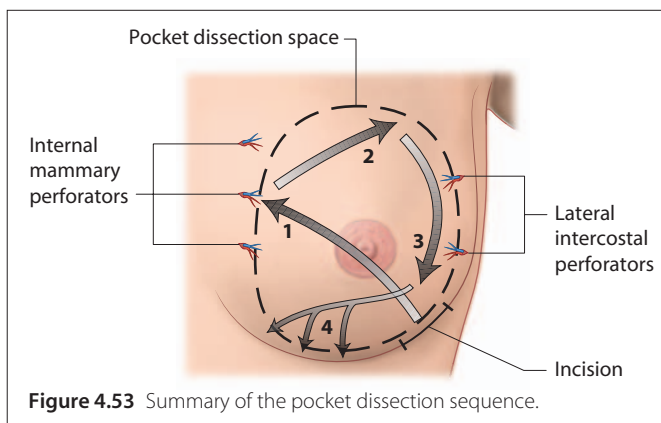


Figure 4.53 Summary of the pocket dissection sequence.

to the skin of the breast as well as the NAC. Care must be exercised when opening the lateral pocket, particularly when anatomically shaped cohesive gel implants are being used as it is easy inadvertently to over-dissect the pocket in this area, which could predispose to implant rotation.

Once the dissection of the main portion of the pocket has been completed, the critical inferior and inferomedial limits of the pocket along the inframammary fold are carefully dissected free. This is done by again respecting the insertion of Scarpa's fascia into the anterior breast lamella. By directing the release of the breast more superficially along the fold in the plane between Scarpa's fascia and the skin, the insertion of Scarpa's fascia into the posterior breast lamella remains undisturbed and inadvertent opening up of the loose subscarpal space will be avoided. In this fashion, any tendency for the breast implant to migrate inferiorly

over time will be prevented as the stronger, more fibrous superficial fatty layer becomes the major support structure for the inferior pole of the breast (Figures 4.52, 4.53).

At this point, the pocket is fully developed and the adequacy of the pocket dimensions are checked by inserting a sterilized

breast sizer that corresponds to the size chosen according to the preoperative measurements and the patient is placed fully upright 80 to 90 degrees. Any modifications of pocket shape or size are performed at this point to ensure a smooth aesthetic contour to the augmented breast.

Many instances of postoperative implant malposition have as their root cause unrecognized pocket over- or under-dissection at the time of surgery. To prevent this from occurring and to increase the overall accuracy of pocket dissection, several different maneuvers can be used to properly assess the pocket. An air-filled implant sizer can be inserted and inflated to see the true pocket dimensions. Lap sponges can also be inserted with some pressure to accomplish the same goal. One very simple maneuver is to insert the fingers of the operating hand up into the pocket and pull the breast up and away from the chest wall.

The resulting vacuum causes air to be sucked up into the pocket. By then occluding the incision with the base of the fingers, the air becomes trapped inside the breast. By pressing on the outer skin envelope to increase the pressure inside the pocket, the true limits of pocket dissection can easily be seen as the balloon effect of the compressed air magnifies the step off created at the edges of the dissection space. This quick and simple maneuver not only shows the limits of pocket dissection but also outlines the shape of the edges of the pocket to help ensure smooth even contours after breast augmentation (Figure 4.54).

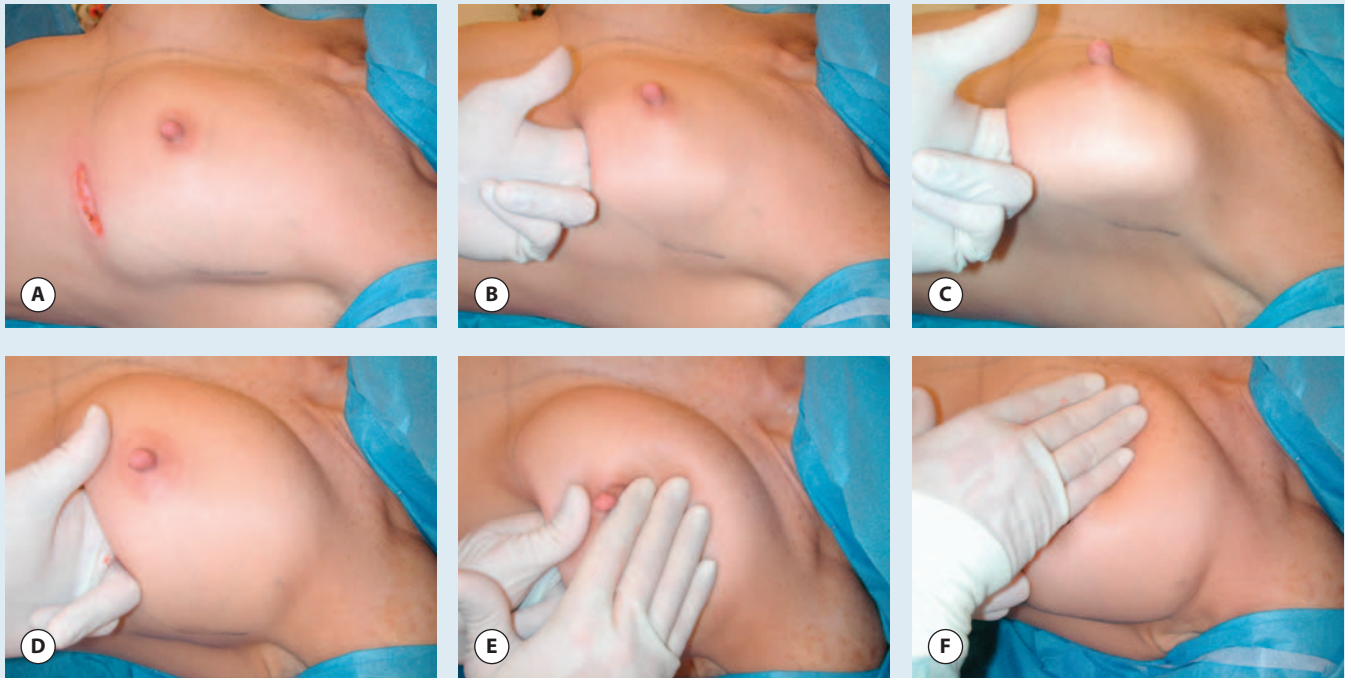


Figure 4.54 (A) Appearance of the breast after initial creation of a subglandular breast pocket in preparation for augmentation mammoplasty. (B,C) The index and long fingers of the left hand are inserted into the pocket and the breast is pulled away from the chest wall, causing air to

insufflate into the pocket. (D) By occluding the incision with the base of the fingers, the air is trapped in the pocket. (E,F) With gentle pressure applied to the breast, the medial and lateral limits of pocket dissection as well as the shape of the pocket become readily apparent.

Once the pocket dimensions and shape are confirmed, the patient is laid back down flat on the operative table. One nuance associated with the subglandular pocket that can be taken advantage of at this point is release of any tightness in the breast due to either fascial or parenchymal constriction. By gently and superficially scoring the underside of the breast in a checkerboard type fashion, a noticeable release of the underside of the breast can often be achieved. This can either allow an implant to fit more comfortably in the pocket and minimize a certain degree of upper pole fullness or allow a larger implant to be used in patients who were on the borderline between two sizes of implants. Once the pocket has been finalized, it is irrigated with saline until clear and hemostasis is rechecked. Very little

blood loss should have been noted during this entire dissection as each potential bleeding point is controlled immediately under the direct vision afforded by the inframammary fold incision.

Implant insertion In preparation for implant insertion, the pocket is irrigated with a combination solution of the antibiotics Ancef (1g), gentamicin (80mg) and bacitracin (50000 units). An occlusive drape is applied to the breast such that it covers the NAC as well as the incision and an access portal is cut in the drape. The chosen implant is opened and immediately covered with the antibiotic solution to prevent airborne surface contamination of the device. The surgical gloves are changed and washed in the antibiotic solution and the implant is then inserted into the pocket (Figure 4.55).

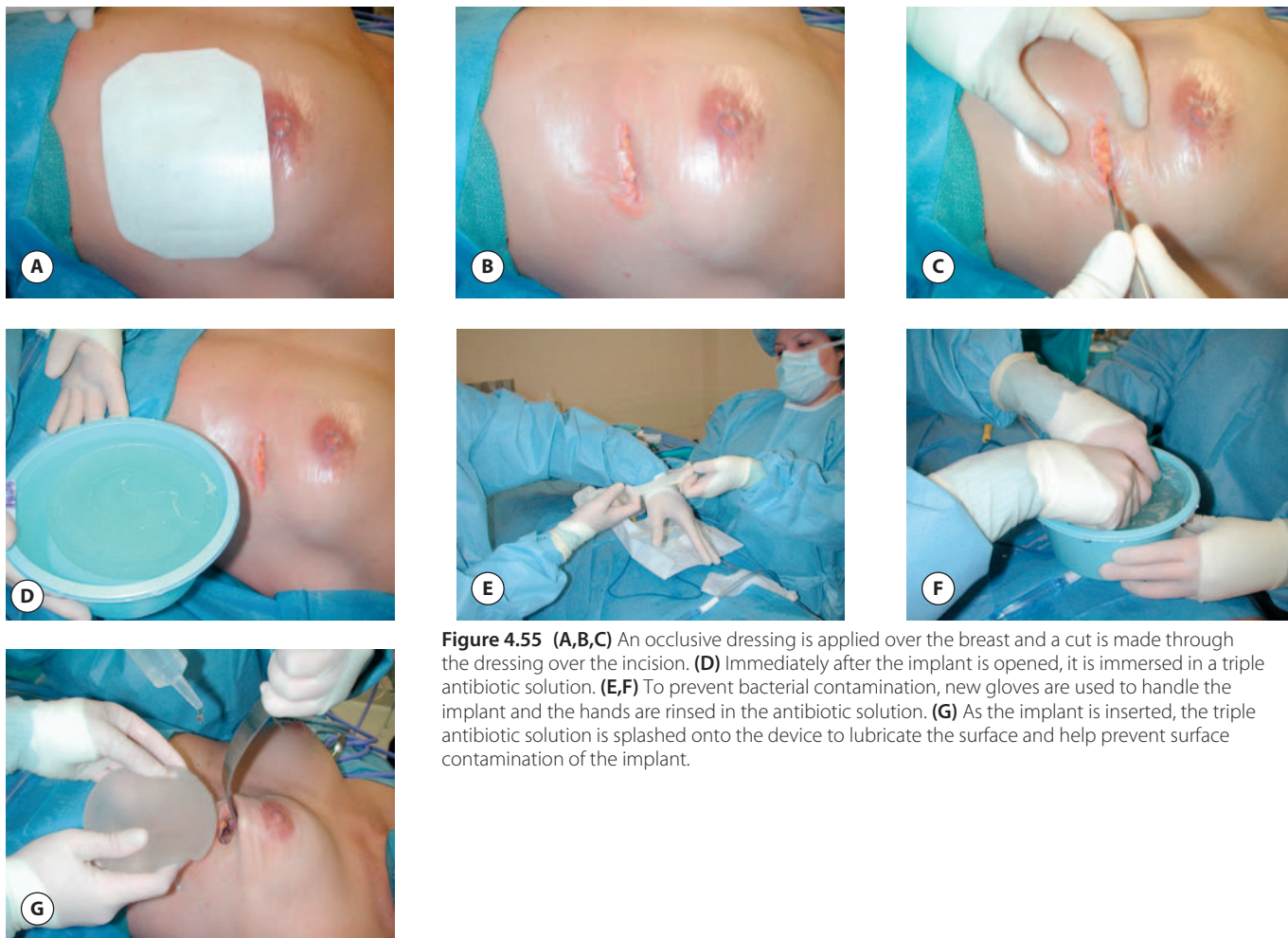

Figure 4.55 (A,B,C) An occlusive dressing is applied over the breast and a cut is made through the dressing over the incision. (D) Immediately after the implant is opened, it is immersed in a triple antibiotic solution. (E,F) To prevent bacterial contamination, new gloves are used to handle the implant and the hands are rinsed in the antibiotic solution. (G) As the implant is inserted, the triple antibiotic solution is splashed onto the device to lubricate the surface and help prevent surface contamination of the implant.

It may be helpful to cover the nipple with an occlusive drape even at the beginning of the procedure (Figure 4.56). During the manipulation of the breast, pressure is applied to the ductal system that could result in fluid contaminated with bacteria to spill out of the nipple onto the breast. It has been postulated

that seeding of the implant pocket with bacteria could be one potential cause of capsular contracture, therefore, covering the nipple in this fashion may help prevent such inadvertent contamination of the operative field.

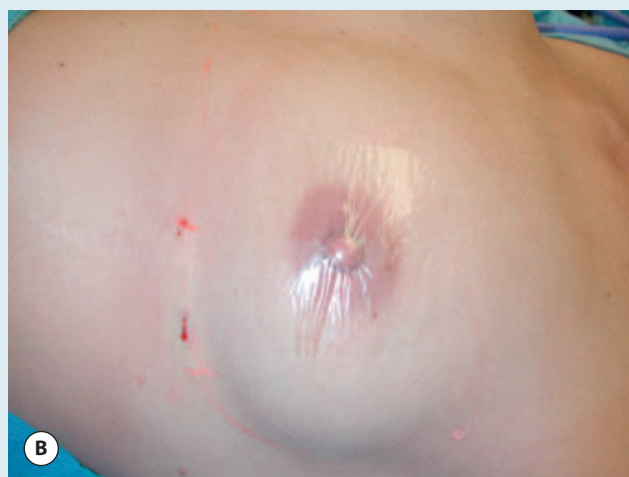
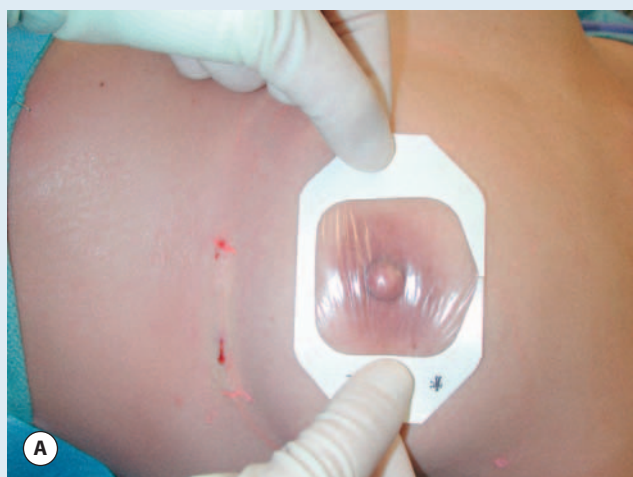
Figure 4.56 (A,B) A small occlusive dressing applied to the NAC at the beginning of the procedure can prevent any possible contamination of the operative field by bacteria present in the ductal system of the breast.

Prevention of such contamination may impact favorably on the rate of capsular contracture.

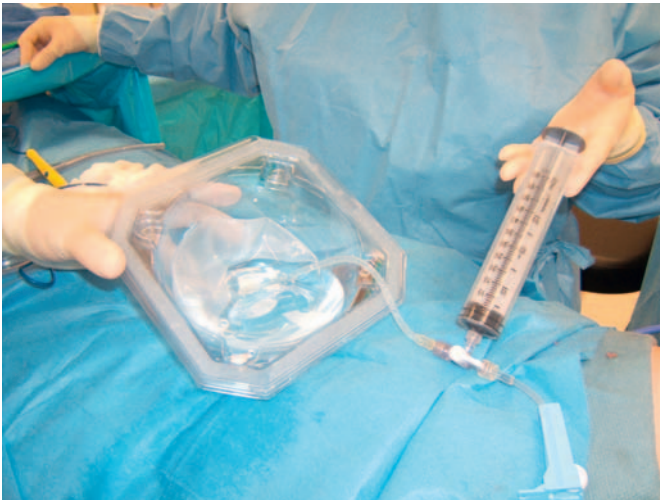

Figure 4.57 The closed system for filling saline breast implants involves drawing saline from an IV bag into a large sterile syringe and then, with the aid of a three-way stopcock, redirecting the flow of fluid into the implant. A closed system prevents inadvertent contamination of the fluid that can occur when saline poured into an open basin is used to fill the device.

Silicone gel implants are inserted using a gentle pressure/counterpressure maneuver that gradually works a different portion of the implant through the incision with each repeating advance of the index finger while stabilizing the remainder of the device with the other hand as the implant is worked into the pocket. The antibiotic solution is splashed onto the implant and incision as the device is inserted to reduce friction and ease implant insertion. Saline implants are inserted pre-filled with only 50–100 cc of fluid and any residual intraluminal air is evacuated. The implant is inserted easily through the incision in this markedly underfilled state and the final volume is added using a closed system with the fill valve attached to an IV saline bag via a three-way stopcock (**Figure 4.57**). The closed system approach eliminates the possibility of surface contamination of the saline should it be allowed to sit in a bowl exposed to airborne contamination, or to inadvertent direct contamination as the tip of the filling syringe is inserted into the bowl repeatedly as the implant is progressively filled. Anatomic shaped cohesive gel implants are inserted using the same technique as round gel devices; however, closer attention needs to be given to proper implant orientation. One simple technique is to turn the anatomic implant clockwise 90 degrees as insertion is begun and then, with each pass of the index finger, easing a portion of the implant into the pocket, the device is slowly rotated into the upright position as it is finally positioned completely in the pocket. With any style of implant, it is necessary at this point to manipulate the implant/soft tissue interface inside the pocket with the index finger to be certain the device is properly seated against the chest wall and the breast without any fold, ridges or other catch points and that the inferior portion of the implant is seated directly at the inframammary fold. This is particularly true of both round and anatomic textured devices as the textured surface may create enough friction between the implant and the overlying tissue to prevent the implant from lying smoothly. One final check with anatomic cohesive gel devices involves making sure the orientation marks on the device are properly aligned and, in particular, the mark on the bottom midline of the implant is located at the bottom midline of the breast (**Figure 4.58**). When being sure that the implant is properly seated, it can be helpful to have the

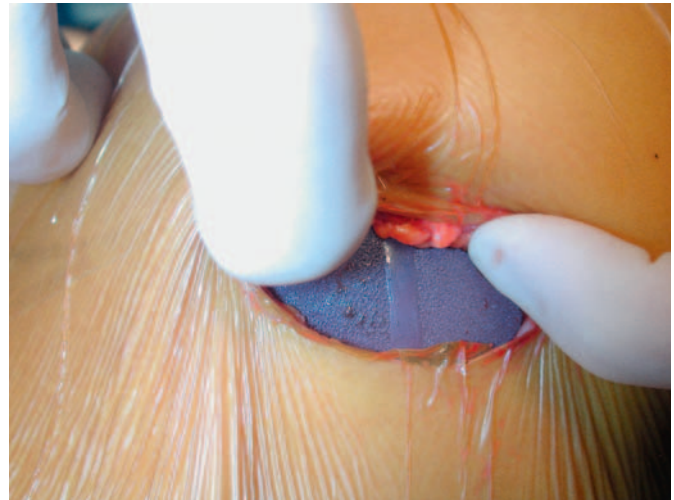

Figure 4.58 Proper orientation of an anatomic shaped cohesive gel implant can be checked by visualizing the orientation stripe that is molded into the shell of the device.

patient raised to the 80 to 90 degree position. This will help minimize the tendency for implants and, in particular, textured devices to get hung up in the superior portion of the pocket. By reaching under the device with the index finger, the base of the implant can be rolled downward and outward to be certain that the implant is properly seated directly at the inframammary fold.

Incision closure It is important to realize that the inframammary fold in the area of the incision can be distorted by placing deep sutures designed to either support the inframammary fold or reapproximate fascial layers. Placing such sutures must be done with care and their effect on the fold must be assessed intraoperatively with the patient upright. If any irregularity in the contour of the inferior pole of the breast is noted after placement of deep sutures, either they must be redone or a simple two-layer technique can be used using a 4-0 absorbable monofilament dermal interrupted suture followed by a running subcuticular stitch to finish the closure. Whatever technique is used, it is important to allow the new three-dimensional relationships between the soft tissues and the implant to settle smoothly to create an aesthetic contour along the fold. After final closure, a small occlusive dressing is applied to the incision followed by the placement of a support garment.

Postoperative care Patients are maintained on oral antibiotics for 1 week and oral pain medication is gradually weaned during that same time period. The support garment is worn to comfort as desired by the patient. The patient is seen back in the office at approximately 1 week, where the occlusive dressing is removed and the exposed suture ends on either side of the incision are clipped. Instructions for postoperative implant displacement exercises are reviewed in cases where a 'round' implant, either silicone or saline, was used and these exercises are begun as soon as they can be performed with comfort. Vigorous activity is restricted for 4 weeks postoperatively, at which point return to aerobic activities is gradually resumed. Return office visits are planned at 6 weeks, 6 months and 1 year postoperatively (**Figures 4.59–4.63**).

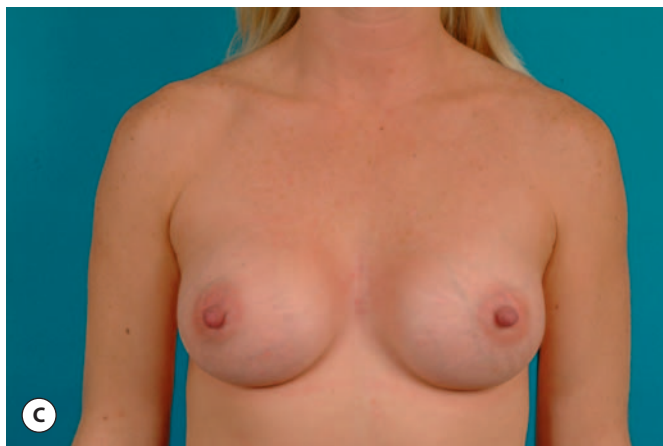
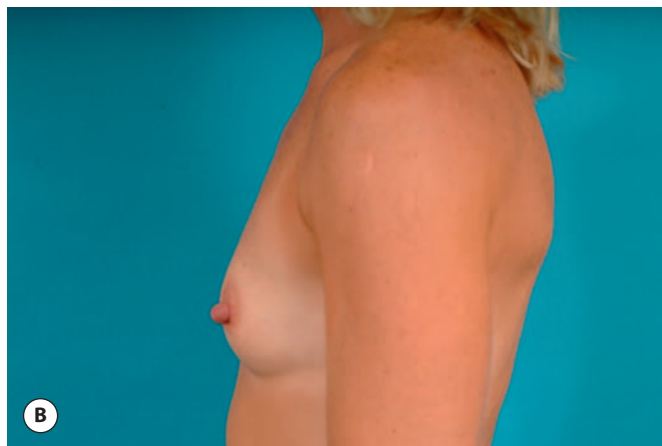
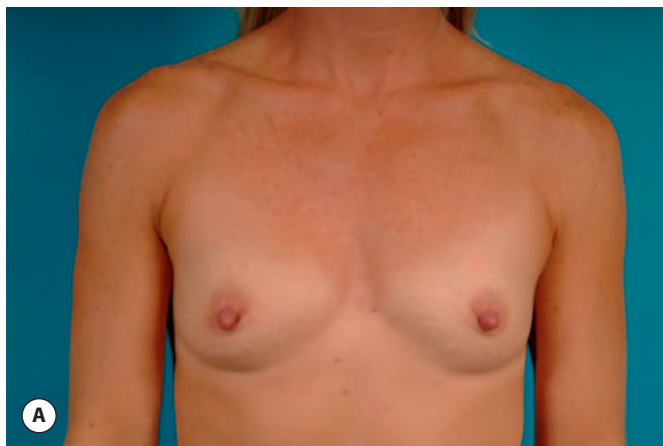
Figure 4.59 (A,B) Preoperative appearance of a 41-year-old woman in preparation for breast augmentation. She desires a type 2 result with a full natural appearance to the augmented breast. **(C,D)** One-year postoperative result after placement of 310cc high-profile smooth round saline implants

filled to 350 cc in the subglandular plane. Despite the use of a high-profile saline implant in the subglandular plane, a natural contour in the upper pole of the breast has been created.

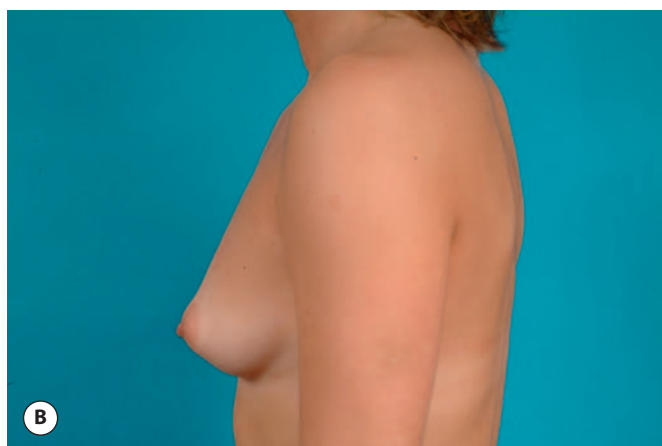
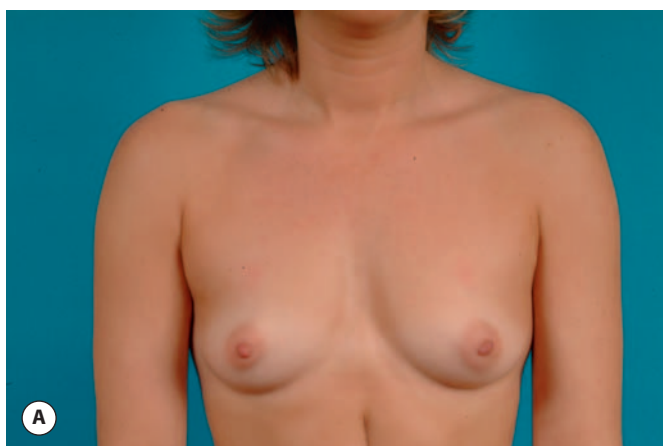


Figure 4.60 (A,B) Preoperative appearance of a 39-year-old woman in preparation for breast augmentation. She desires a type 2 result with a full

natural appearance to the augmented breast.

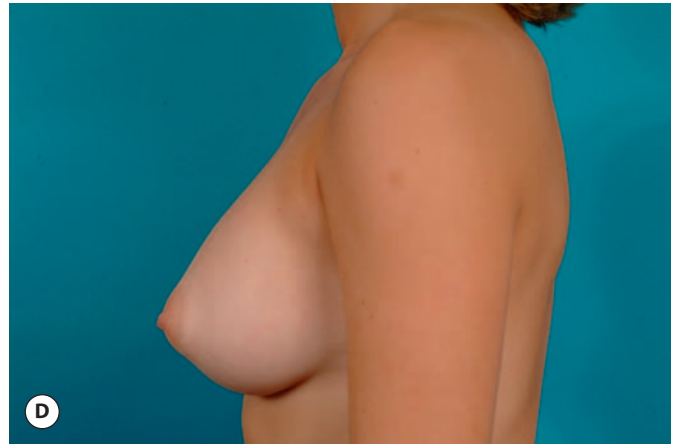
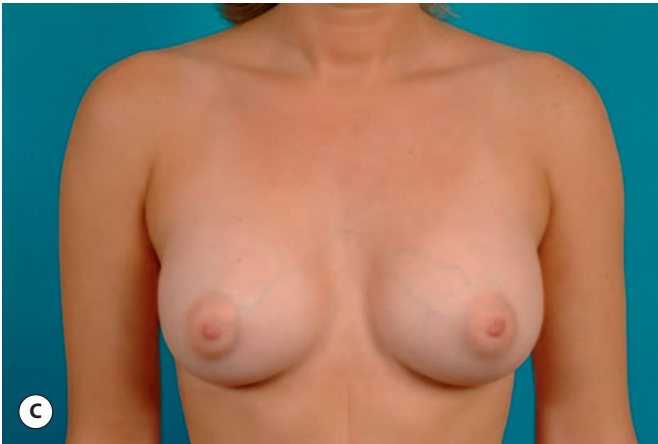


Figure 4.60 (Continued) (C,D) Six-month postoperative result after placement of 270 cc high-profile smooth round saline implants filled to

270 cc on the left and 300 cc on the right in the subglandular plane.

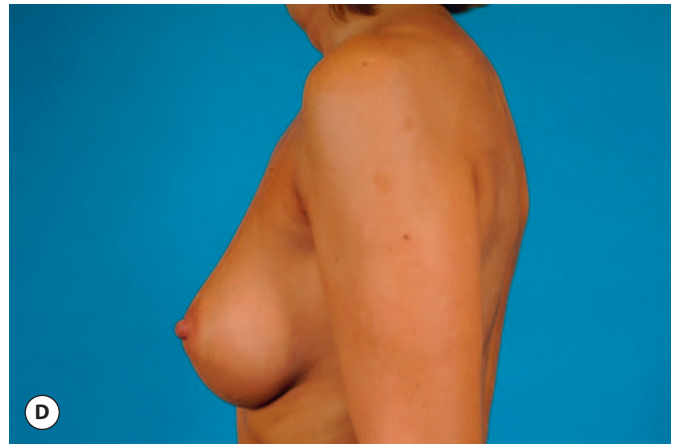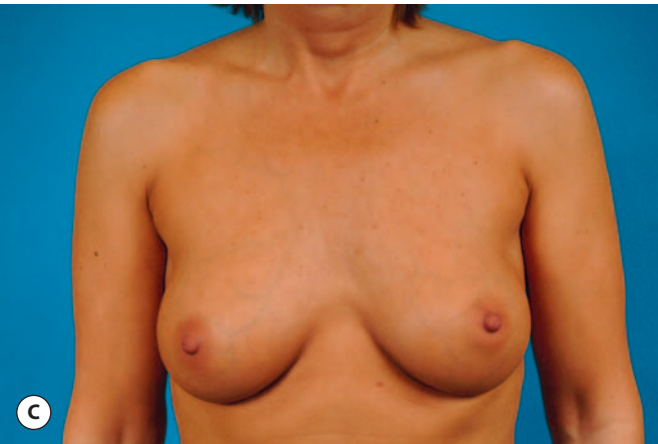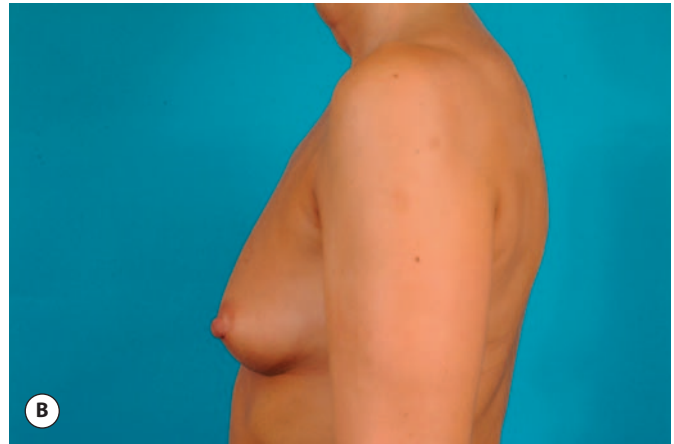


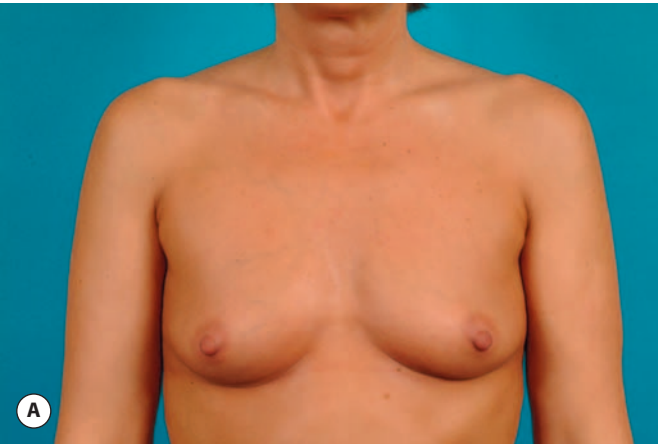Figure 4.61 (A,B) Preoperative appearance of a 44-year-old woman in preparation for breast augmentation. She desires a type 1 result with a modest filling out of the skin envelope and a very natural contour to the breast. **(C,D)** One-year postoperative result after placement of 200 cc

moderate-profile smooth round saline implants filled to 225 cc in the subglandular plane. The patient demonstrates a conservative filling out of the breast skin envelope and a very natural contour to the augmented breast.

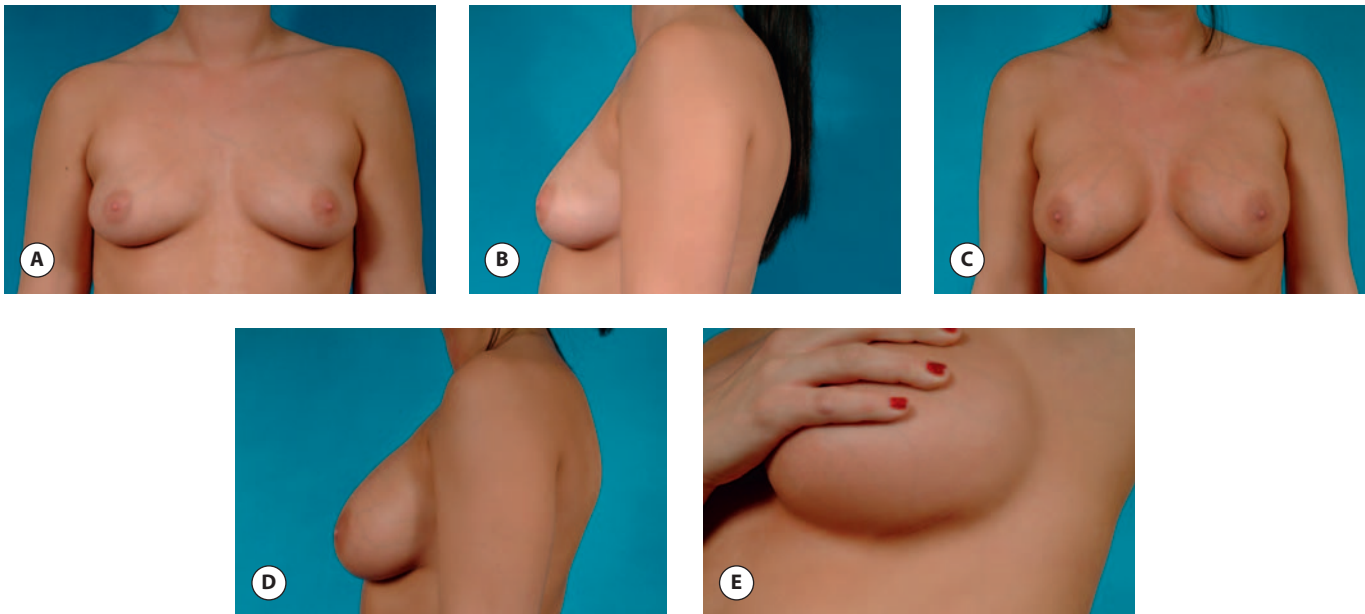


Figure 4.62 (A,B) Preoperative appearance of a 21-year-old woman in preparation for breast augmentation. She desires a type 2 result with a full natural appearance to the augmented breast. **(C,D)** One-year postoperative result after placement of 280 cc mid-height low-projection anatomically shaped textured cohesive silicone gel implants in the subglandular plane.

A natural shape to the augmented breast has been created with no excessive upper pole fullness. **(E)** Appearance of the scar in the lateral inframammary fold. By limiting the dissection along the fold to the space above Scarpa's fascia, the position of the fold can be set with certainty and the scar remains positioned in the fold once full healing has occurred.

Implant displacement exercises have been utilized for years by plastic surgeons around the world and, although conclusive scientific data are lacking, many such surgeons are convinced that this technique can help prevent capsular contracture. In theory, by purposely over-dissecting slightly the dimensions of the pocket at the time of implant insertion and then forcibly moving the implant within the pocket during the early healing period, the dimensions of the surface area of the pocket that is ultimately defined by the capsule will be larger than the surface area of the implant itself. As a result, the implant will be able subtly to change position and move in the pocket depending on the position of the patient. When this relationship between capsule and implant is maintained over time, it is then mainly the physical characteristics of the implant that determine how soft the breast feels. I agree with this concept and have actually seen it at work in several patients at the first postoperative visit. By initiating implant displacement exercises at 1 week, occasionally it can be observed that the pocket has already begun to seal off at the edges of the breast, particularly laterally, creating a tighter space for the implant to rest in. By translocating the implant laterally, superiorly and medially with gentle pressure, the pocket can be seen and felt to pop open as the original pocket dimensions are reclaimed, creating a softer breast. My protocol for using displacement exercises includes initiation at the 1 week

visit with breast manipulation being done twice a day, morning and night, until the 6-week visit. The patient is instructed to use the heel of the hand gently to push the implant laterally until the lateral breast contour is seen to bulge under the influence of the device as it presses against the skin and this position is held for 10 seconds. The same process is repeated pushing the implant superiorly and then medially. It is suggested that doing so during a hot shower will enhance the ability of the soft tissues to stretch as the implant is pushed against the capsule. It is unlikely that the continuation of displacement exercises beyond 6 weeks has any lasting effect on the prevention of capsular contracture as expanding an existing capsule can be difficult to do without surgical intervention. Displacement exercises are best utilized with smooth-walled devices that can move inside the pocket without the friction created by textured surfaces, which is one of the reasons why I generally prefer smooth-walled implants for primary breast augmentation. It must be remembered, however, that, when using anatomically shaped cohesive gel devices, displacement exercises are contraindicated due to the risk of causing implant rotation. In my opinion, displacement exercises do assist in helping to prevent early capsular contracture and can play a role in selected patients in the early postoperative management after breast augmentation.

Inframammary Fold Subpectoral Breast Augmentation

When placing an implant in the subpectoral space, the marking, incision placement and development, implant insertion and

closure proceed exactly as in the subglandular technique. What is different is the development of the subpectoral pocket. As the incision is opened, the lateral margin of the pectoralis major muscle will be visualized. By grasping this muscle edge and pulling upward, the areolar space under the muscle will become

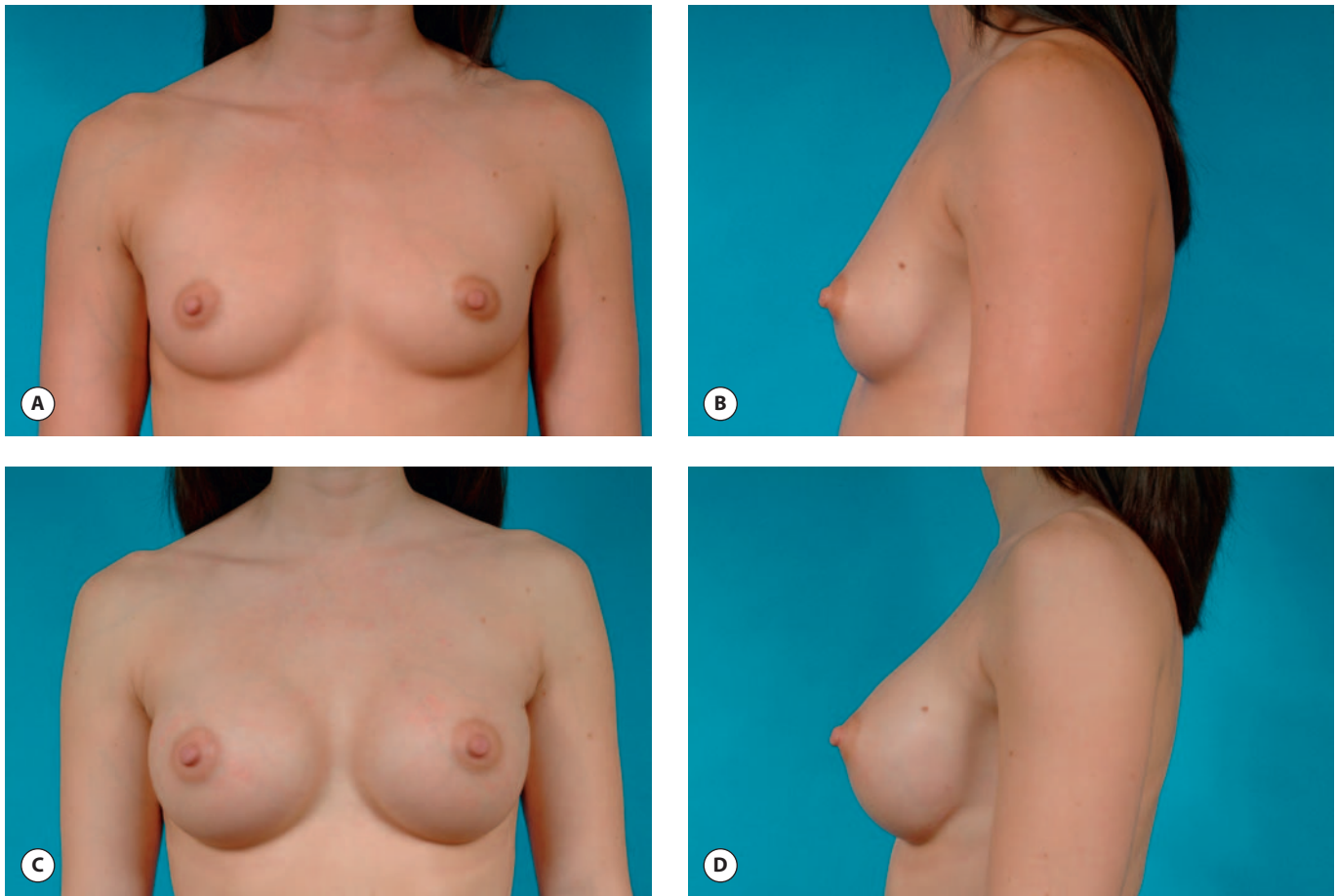


Figure 4.63 (A,B) Preoperative appearance of a 24-year-old woman in preparation for breast augmentation. She desires a type 2 result with a full natural appearance to the augmented breast. **(C,D)** Ten-month postoperative result after placement of 280 cc mid-height low-projection anatomically shaped textured cohesive silicone gel implants in the

subglandular plane. Despite the placement of the same implant that was used in [Figure 4.62](#), the breast has a slightly more rounded appearance due to the thinner body habitus of this patient, an observation that underscores the importance of correctly matching the implant size and shape to the patient's pre-existing anatomy to achieve the desired result.

evident. Using a lighted retractor, the space under the muscle can be opened under direct vision by dividing the loose areolar fibers which separate the pectoralis major muscle from the underlying pectoralis minor. Large intercostal crossing vessels can be directly controlled with bovie cautery. At this point, the accessory fibers of origin will be encountered and they can cause confusion, leading to the inaccurate conclusion that the medial border of the muscle has been reached. However, release of the fibers directly at the level of the rib reveals a new space extending beyond to the next accessory fiber. Generally, there are two to three of these muscular bands extending from the anterior cranial surfaces of the ribs up into the muscle. All these accessory fibers must be divided until the true medial border of the pocket is reached. Even here, the band of origin of the main substance of the muscle can be up to 2 cm thick. When required, the medial portion of this main band of origin can be released further to enlarge the pocket. It is here that some variability in muscular anatomy may become evident. Some patients have a muscular origin that extends directly down to the level of the fold. In these patients, it is not necessary to completely divide the muscular origin in the inferomedial corner as the implant can be properly positioned at the

level of the fold and still be completely covered by muscle. If the muscular cover does not flatten the breast and distort the breast shape, these fibers can be left intact to support the breast implant and prevent inferior migration of the device. If there is some degree of flattening, all but the most superficial muscle fibers and fascia can be divided to release tension in this area and improve the shape of the breast. If, however, the muscular origin is located above the inframammary fold or if the retained muscle fibers are restricting the shape of the breast in the lower inferomedial fold area, these fibers of origin must be completely released. Technically, this can create some difficulty as releasing the same amount of muscle on each side can be a challenge and it is possible for an asymmetrical muscle release to lead to implant malposition and an overall breast asymmetry. Conversely, if not enough of the muscle is released, an overly wide parasternal flattening with lateral implant malposition can be the result. Also, it can be relatively easy to over-release the muscular origin in the inferomedial corner of the breast, leading to a step off deformity in the medial portion of the augmented breast with implant visibility or palpability. Finally, with release of the inferomedial corner of the muscular origin, sometimes an inadvertent and unintended

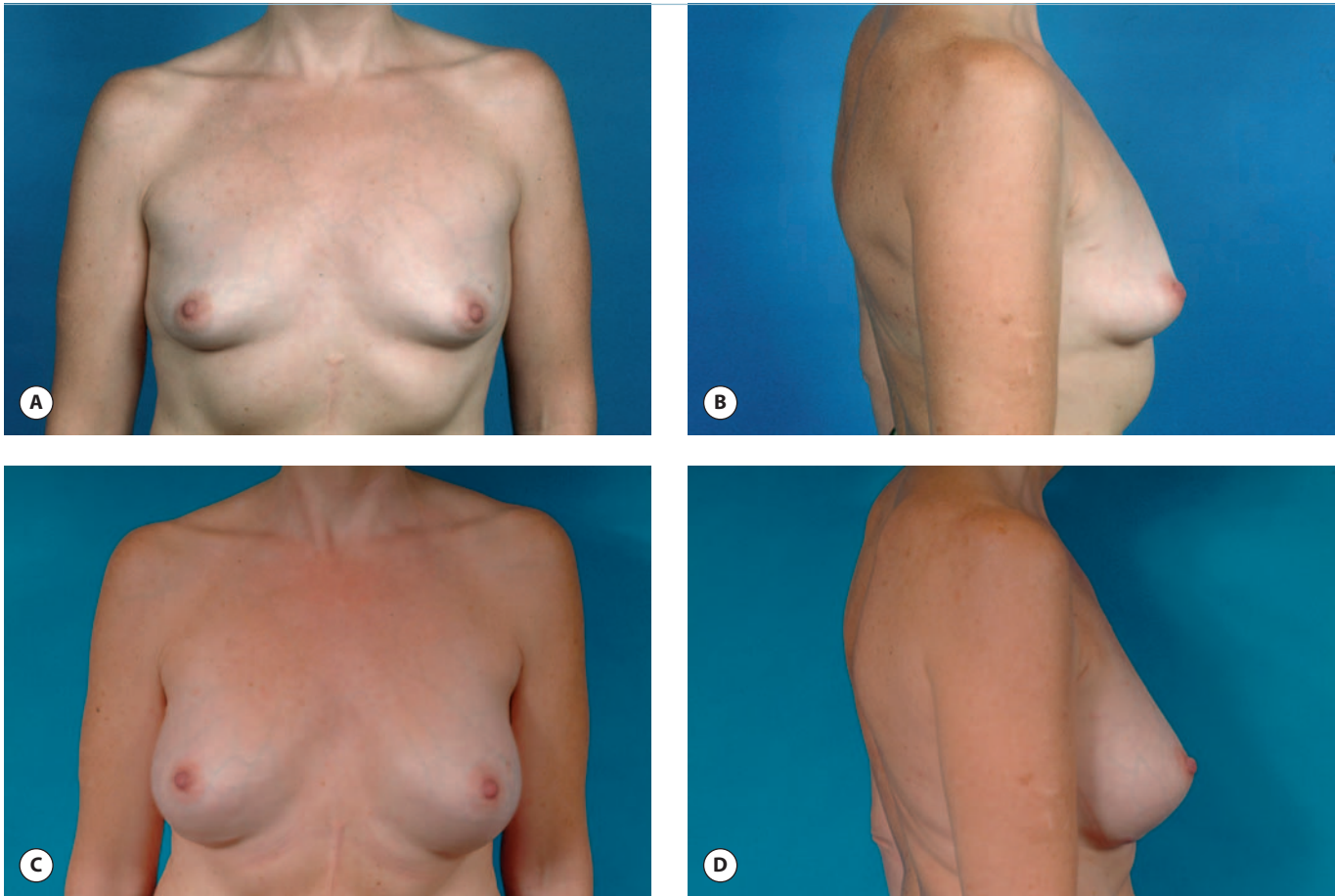


Figure 4.64 (A,B) Preoperative appearance of a 43-year-old woman in preparation for breast augmentation. She desires a type 2 result with a full natural appearance to the augmented breast. (C,D) Five-year postoperative result after placement of 310 cc full-height mid-projection anatomically

shaped textured cohesive silicone gel implants in the partial subpectoral plane. This result demonstrates the longevity that breast augmentation patients can demonstrate with regards to maintaining an aesthetic result over time.

lowering of the inframammary fold can result in inferior implant migration. For these reasons, it is my preference to perform this muscular origin management under direct vision with a lighted retractor and bovie cautery rather than using a blunt technique. Muscle fibers are released carefully under direct vision until the pocket is dissected precisely as planned. If the inferomedial corner of the subpectoral pocket does need to be released, care is taken to release only the muscle fibers and not the soft tissues on the other side of the muscle. If the fold does need to be lowered further, it is done as in subglandular pocket development by dissecting through the anterior breast lamella and then on top of Scarpa's fascia. By paying close attention to these details and recognizing the variable anatomy that can be associated with the origin of the pectoralis major muscle, accurate pocket preparation can be accomplished (Figure 4.64).

Notes on the 'dual plane' technique In patients where some degree of constriction of the lower pole of the breast is noted after placement of the implant in the subpectoral pocket, it is possible to release this constriction, at least partially, by variably dissecting on top of the pectoralis major muscle and releasing the lower border of the muscle from the overlying gland. In essence, this amounts to creating a partial subglandular pocket in

addition to the subpectoral pocket, which allows the pectoralis major muscle to ride up slightly away from the lower pole of the breast. If there are any tethering points present at this junction, they will be released and will result in a softer interface between the implant and the surrounding pocket.

While this technique is often discussed in isolation as a useful technical maneuver in breast shaping, it is important to realize that 'dual plane' dissection addresses just one of several tissue-related variables that can adversely affect the shape of the breast after breast augmentation. Essentially, when an implant is placed under the breast, the best results will be obtained in cases where there is minimal tension on the device itself from the overlying soft tissue. In this ideal situation, the implant settles to the bottom of the pocket and conforms to the pressures placed on it by the overlying soft tissue framework. If there is any tendency for the soft tissue framework to constrict, tether or otherwise alter the shape of the pocket, the aesthetic results can be adversely affected. In the breast, there are several tissue layers that can create such a constriction and potentially alter the shape of the breast, including the skin, fat and parenchyma, investing breast fascia and muscle. When faced with an intraoperative situation where the shape of the newly augmented breast is less than ideal, it is incumbent on the surgeon to determine

what layer is causing the distortion. This is best performed by working from deep to superficial. Using this constricting layer model of breast shaping in breast augmentation, the pectoralis major muscle is the first layer that must be considered. It is here that the dual plane technique can offer advantage in releasing any constriction which may be present. By dissecting on top of the muscle as described or even more effectively releasing more of the inferomedial fibers of origin, the tendency for the muscle to constrict the lower pole of the breast can be minimized or even eliminated. In this regard, it is important to note that an even more effective way to prevent the muscle from distorting the shape of the breast, either actively or passively, is simply to remove it from the equation altogether and utilize instead a subglandular plane if the supporting soft tissue framework is of sufficient thickness to cover the implant appropriately. Once the muscle has been eliminated as a potential cause of shape distortion, the fascia along the underside of the breast is considered. It is technically straightforward to score the underside of the breast lightly with the bovie cautery to release any tendency for this fascial envelope to restrict the ability of the underlying implant to fit comfortably in the dissection pocket. This is easily done when using the subglandular pocket. When using the subpectoral pocket, only the lower portion of the underside of the breast can be treated in this fashion, but still, the effect can be significant. As the scoring is performed, the effect can be immediately discerned as the tightness of the pocket is relieved. Occasionally, it is possible strategically to release the underside of the breast fascia just in the lower pole of the breast, in an attempt to create differential forces within the pocket. By scoring the underside of the lower pole of the breast, but leaving the upper pole intact, an anatomically shaped fascial release pattern can be created that could theoretically at least create a tendency for a round gel implant to assume an anatomic shape due to the differential stresses placed on the device. The resulting shape of the augmented breast is therefore improved and any tendency toward excess upper pole fullness can be minimized. In cases of tuberous breast deformity, the constriction goes beyond simply fascia or muscle and often the fat and parenchyma itself is responsible for distorting the shape of the breast. In these cases, it is necessary to score through the breast fat and parenchyma in addition to simply releasing the deep fascial layer to allow the soft tissue framework to relax enough to comfortably accept an implant. Commonly, it is necessary to release the constricting elements of the parenchyma and fat all the way to the dermis, particularly in the lower pole of the breast in order to obtain an acceptable breast shape. Eventually, it becomes necessary to consider the skin envelope as the final constricting layer of the breast. The skin can be restrictive because there is simply not enough of it as can be seen in very hypoplastic breasts, or can have a history of injury due to previous surgery, scarring or radiation. Unfortunately, of the four layers that can potentially affect the shape of the breast, this layer is relatively immune to immediate surgical manipulation. In very hypoplastic breasts, it is possible to lower what is usually a high fold so as to recruit abdominal skin to assist in forming the lower pole of the newly augmented breast. In reconstruction or in cases of tuberous breast deformity, tissue expanders can be used to stretch the available breast skin better to accept an underlying implant. However, in breast augmentation, tissue expansion plays virtually no role in basic surgical technique and outside of lowering the fold to recruit upper abdominal skin, there is no

easy way to increase the skin surface area of the breast without resorting to reconstructive techniques. For this reason, when the adequacy of the skin envelope becomes the limiting factor in breast augmentation, it is a far better option to tailor the implant choice to the limitations imposed by the tight skin envelope rather than to attempt to make the skin envelope fit around a poorly chosen implant. To a great extent, how well the surgeon can recognize and manipulate these potentially constricting layers and choose an implant that will best complement the soft tissue framework of the breast will, to a great extent, determine the quality of the overall result in breast augmentation.

Periareolar Breast Augmentation

The periareolar incision is the favored access site to the breast for many surgeons when performing breast augmentation. When using this incision, the basic tenants of preoperative evaluation, implant choice and pocket development are the same as described previously. One limitation involves the length of the incision as patients who present with a small areola of less than 3 cm diameter can have limited access for dissection of the pocket and insertion of the implant. While this may not be a major limiting factor when using saline implants, attempting to insert a textured gel implant or, in particular, an anatomically shaped textured cohesive gel device can be very difficult through incisions that are less than 5 cm in length. When undue pressure with implant deformation is placed on a cohesive gel device during insertion, cracks in the structure of the gel can develop that are permanent. This break in the structural integrity of the device can potentially result in a visible contour deformity in the shape of the breast and may accentuate folds or cracks in the shell, which predisposes to failure of the device over the long term.

Technically, the incision is placed at the junction of the darker areolar skin with the lighter skin of the lower pole of the breast along the inferior hemisphere of the areola. It is helpful to place small tattoo marks of methylene blue on either side of the incision prior to incising the skin to aid in accurate re-approximation of the skin edges at the completion of the procedure. This small technical detail is actually quite helpful as it is very easy to misalign the skin edges at the time of closure due to the accentuated elasticity of the areolar skin. Such misalignment can adversely affect the quality of the resulting scar. Once the skin incision has been made, the desired pocket is developed as described previously by either dissecting directly through the gland or curving around the lower border of the gland to avoid the breast ducts. Once the underside of the breast is reached, either a subglandular or a subpectoral pocket can be developed as with any other incision. In patients with smaller areolas, the incision length can be a limiting factor and dissection of the main implant pocket can be more of a technical challenge than that seen with the inframammary fold incision.

One very important advantage afforded by the periareolar approach is that the inframammary fold is approached from above. The entire fold can be visualized without any possibility of distortion created by an incision in the fold as can happen with the inframammary fold incisional approach. As such, the shape and position of the fold can be easily assessed with the patient upright and the effect of an implant sitting on the fold can be immediately seen. Small alterations in fold position

or contour can be made with accuracy even with the implant in place by simply gently moving the implant aside and releasing any restricting bands that might be tenting the fold. Also, the previously noted anatomical arrangements concerning Scarpa's fascia are easily respected from this approach and the fold can be lowered as desired by dissecting through the anterior lamella and into the superficial layer of fat. This firm fatty/connective tissue layer provides excellent support for the implant, resists inferior fold migration and provides a reliable framework that can be surgically manipulated to help accurately position the implant and aesthetically shape the breast.

Despite these advantages, periareolar incisions tend to be shorter than inframammary fold incisions and this limited exposure can at times make pocket dissection and implant insertion difficult. In particular, the technique of dissecting down and around the breast to avoid dividing the gland can be a particular technical challenge in smaller patients with a relatively inelastic skin envelope, particularly when it comes to implant insertion. As a result, the periareolar approach is optimally used in patients who have an enlarged areola preoperatively (>4 cm) such that exposure will not be a problem, or in patients who are undergoing a periareolar mastopexy (Figure 4.65).

Transaxillary Breast Augmentation

As with the other techniques, the basic tenets of pocket development and inframammary fold management are the same. The incision is placed in the axilla just posterior to the edge of the pectoralis major muscle. After the skin has been incised, spreading scissors dissection exposes the underside of the pectoralis major, and the loose areolar plane between this and the pectoralis minor muscle is opened up with blunt finger dissection. Although blunt release of the muscle can be accomplished, endoscopic control of the pocket dimensions does afford better control of the implant space and also provides for direct hemostasis as needed. The origins of the pectoralis major muscle are released and the fold position is determined and dissected free as with the other approaches. Saline implants are easiest to insert through this approach as the empty implant shell is rolled into a cylinder and inserted into the pocket and then brought to the desired volume. Round silicone gel implants are more difficult to insert, particularly if they are textured. Anatomically shaped cohesive gel implants present a particular challenge in that they are always textured and additionally must be properly oriented. Therefore, to reduce the risk of injuring the implant

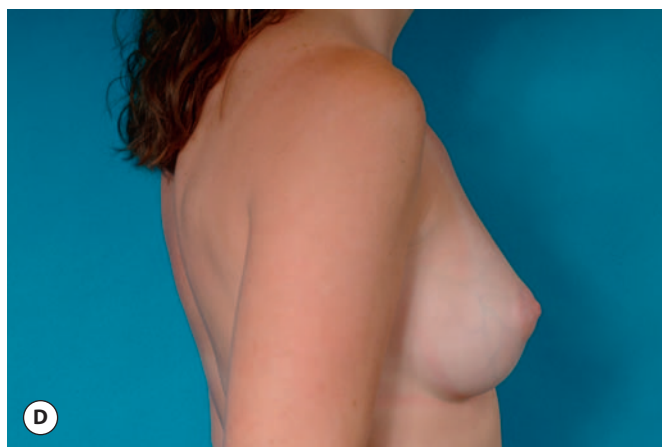
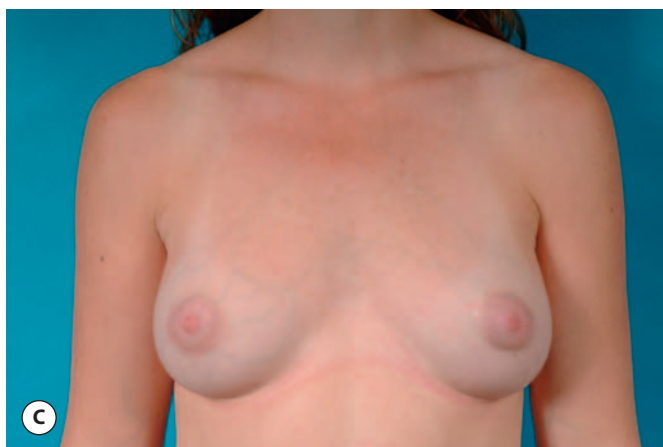
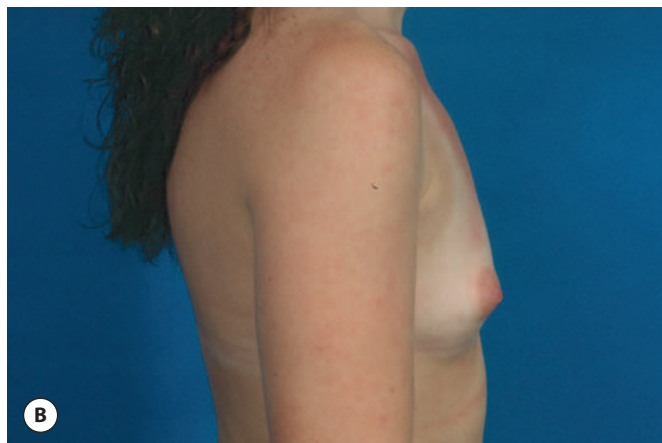
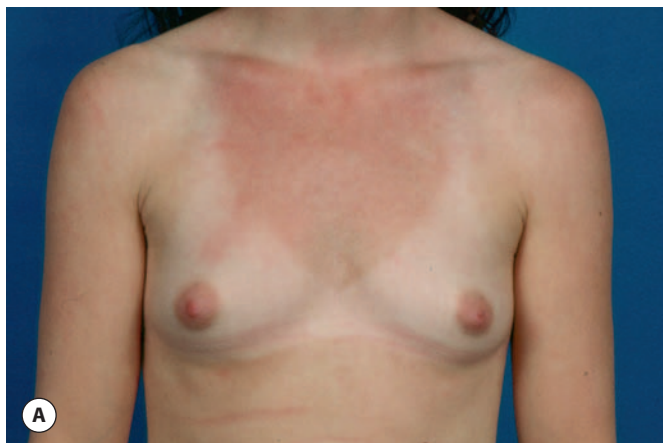
Figure 4.65 (A,B) Preoperative appearance of a 27-year-old woman in preparation for breast augmentation. She desires a type 2 result with a full natural appearance to the augmented breast. (C,D) Five-year postoperative result after placement of 255 cc full-height full-projection anatomically

shaped textured cohesive silicone gel implants in the partial subpectoral plane. Despite the relative firmness of the cohesive gel as compared to standard gel or saline, the periareolar incision was sufficient to allow implant insertion into the partial subpectoral pocket with ease.

during insertion and to ensure proper positioning and orientation, either the inframammary or periareolar approach is a better incision choice when using these devices.

Blunt Pocket Development

When using the partial subpectoral pocket through any incision, a very common technique for pocket development is to separate bluntly the pectoralis major from the underlying ribs and pectoralis minor muscle. Not only can bleeding be an issue with this technique, but accurate development of smooth pocket contours can be problematic and it can be difficult to avulse the muscle fibers in a controlled fashion medially or along the fold. At times, what appears to be an accurately positioned pocket is simply the result of stretched muscle fibers that can heal back together to create pocket asymmetry and implant malposition. It is a far better choice to dissect the pocket under direct visual control, either with the aid of a lighted retractor through the inframammary or periareolar approaches, or with the aid of an endoscope via the transaxillary approach. In this fashion direct hemostasis can be obtained and consistent, accurate pocket development can be assured to maximize the quality of the aesthetic result.

Round versus Anatomic Implants

In patients who demonstrate any tendency toward ptosis of the skin envelope or the position of the NAC, a round implant may accentuate the contour of the upper pole of the breast to a fault and create an unnatural or 'augmented' breast appearance. This likelihood is increased in trim patients as there is less soft tissue to mask the shape of the round implant (Figure 4.66). In these patients, anatomic textured cohesive silicone gel implants can negate this tendency toward excessive upper pole fullness as a result of the aggressive inherent shape engineered into these devices (Figure 4.67). By limiting the degree of upper pole fill, a more tapered contour can be created that avoids excess fullness in the upper pole of the breast (Figure 4.68). Almost as important is the tendency for shaped gel implants to preferentially fill out the lower pole of the breast. This has the net effect of lifting the position of the NAC relative to the rest of the breast volume (Figure 4.69). By utilizing the contour control afforded by the these implants in conjunction with the lifting effect on the NAC, very aesthetic results can be obtained in challenging patients who are trim and have hypoplastic breasts with an inferiorly positioned NAC (Figure 4.70).

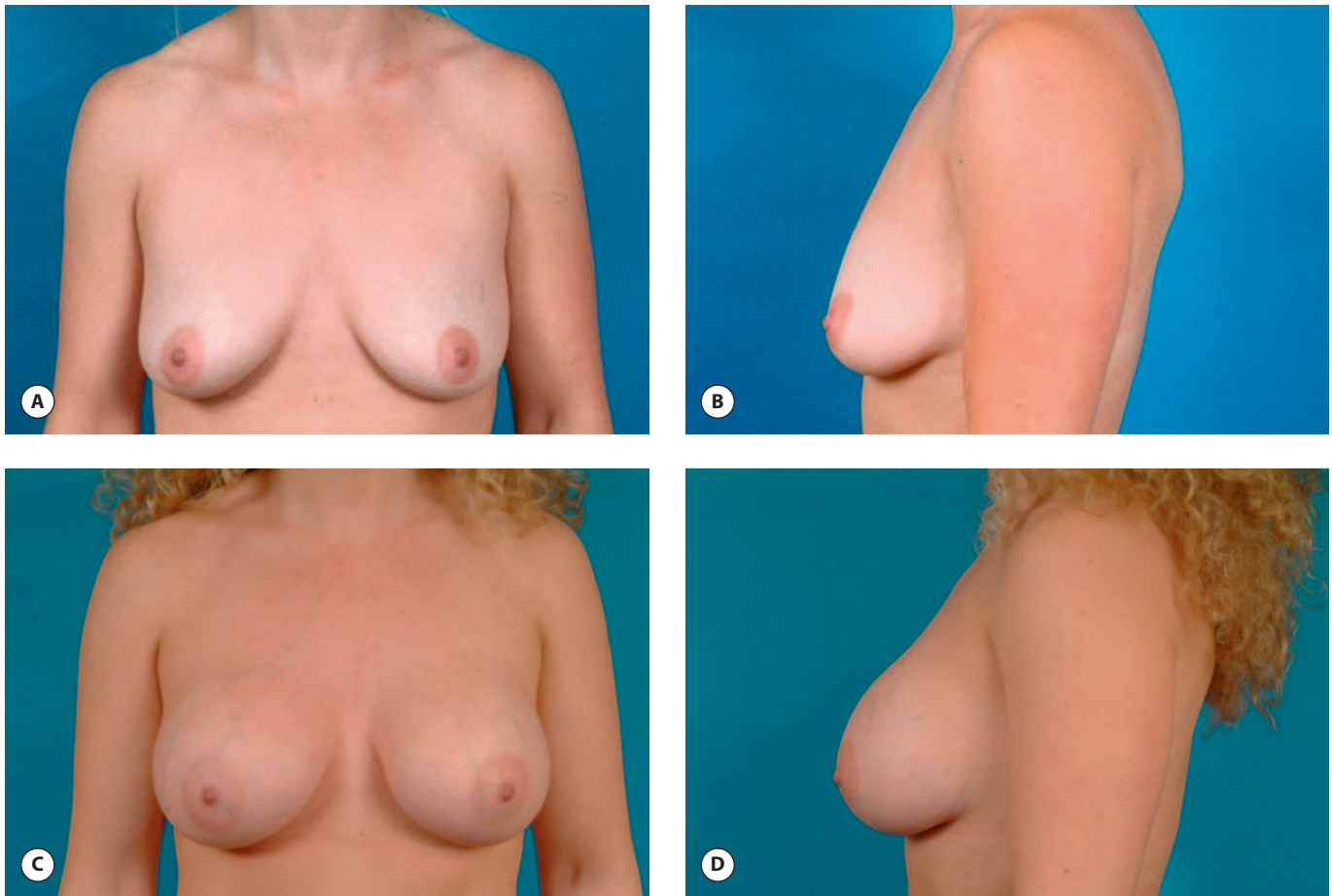


Figure 4.66 (A,B) Preoperative appearance of a 43-year-old woman in preparation for breast augmentation. She desires a type 2 result with a full natural appearance to the augmented breast. (C,D) Seven-month postoperative result after placement of 310cc high-profile smooth round

saline implants in the partial subglandular plane. The combination of a mildly ptotic breast along with a slender body habitus and a high-profile saline implant results in a mild fullness in the upper pole of the breast. When this contour is present to excess, it can detract from the overall result.

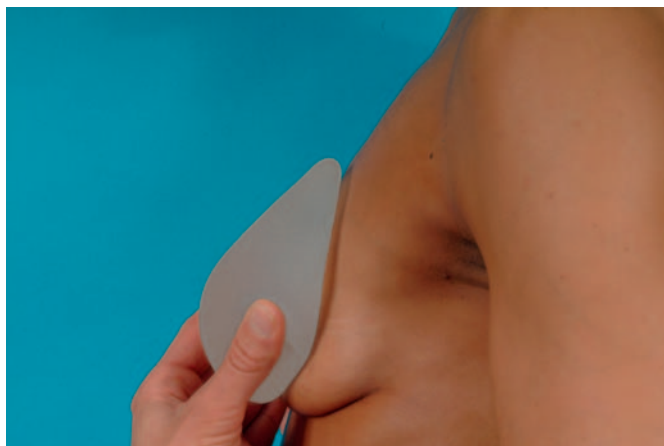


Figure 4.67 When an anatomically shaped cohesive gel implant is placed against the breast, the advantage afforded by the tapered upper pole becomes evident. Using this type of device in slim patients or patients with ptosis may provide a more natural upper pole contour than similarly sized round devices.

Lowering the Fold

In patients with particularly hypoplastic breasts, or in patients who present with tubular breasts, the native inframammary fold can be high and the distance from the fold to the NAC can be inordinately short. Placing a breast implant in a patient with such a high fold and failing to create a new fold that is properly positioned lower on the chest wall can lead to significant deformity with superior implant malposition. In these types of patients, the new fold must be accurately located and the position of the fold must remain stable over time.

To locate properly the position of the new fold and thus identify where the inframammary fold incision should be made, the dimensions of the breast implant must be determined. This measurement comes directly from the preoperative measurement system described earlier in this chapter. The base width (X) of the implant that is felt to most likely give the optimal result is centered on the midline of the breast. From the midline over to the medial extent of the pocket will represent half this

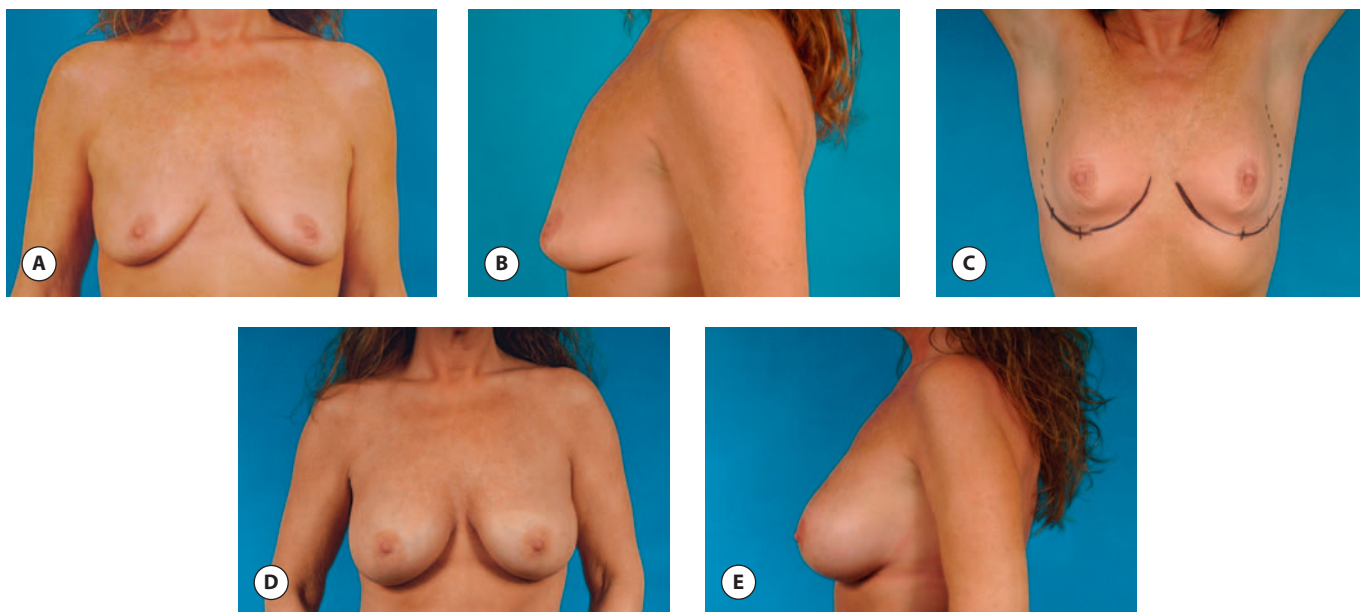


Figure 4.68 (A,B) Preoperative appearance of a 40-year-old woman in preparation for breast augmentation. She has a very loose skin envelope and an element of ptosis to the position of the NAC and desires a type 3 result with a very full appearance to the augmented breast. (C) Preoperative marks showing the laterally positioned inframammary fold incision and the planned location of the inframammary fold. (D,E) 1 year postoperative result after placement of 640cc mid-height low-projection anatomically

shaped textured cohesive silicone gel implants in the subglandular plane. Due to the relative redistribution of the volume of the implant in the lower pole, the NAC ptosis has been partially corrected without the need for a mastopexy. Also, a pleasing yet full volumetric increase in the breast has been accomplished without creating excessive fullness in the upper pole of the breast. It is in these types of patients that anatomically shaped cohesive silicone gel implants may be used to maximum effect.

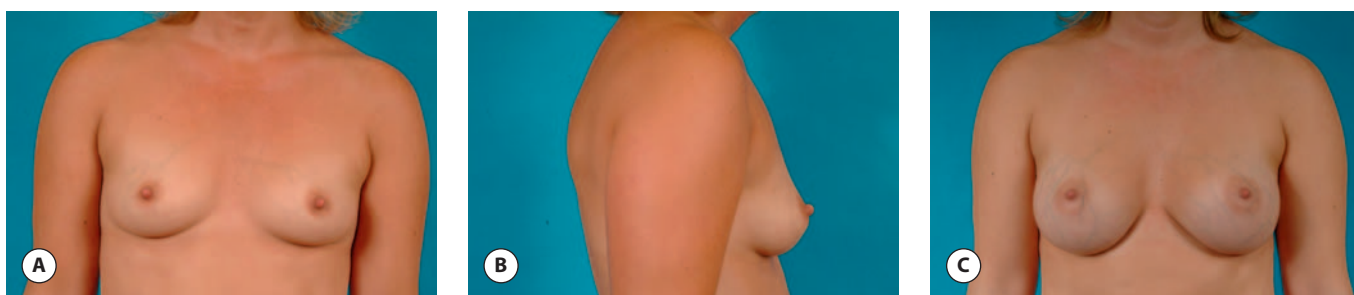


Figure 4.69 (A,B) Preoperative appearance of a 39-year-old woman in preparation for breast augmentation. She desires a type 2 result with

a full natural appearance to the augmented breast. (C,D) Three-year postoperative result after placement of 295 cc mid-height full-projection

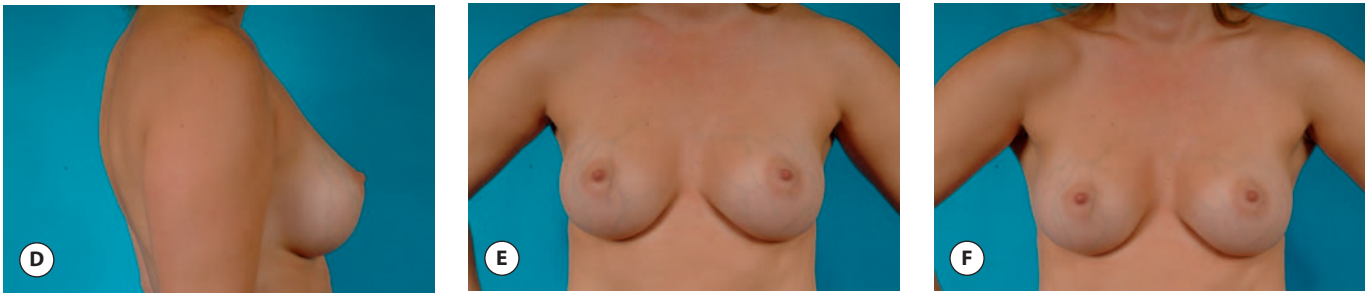

Figure 4.69 (Continued) anatomically shaped textured cohesive silicone gel implants in the subglandular plane. When the lifting effect associated with the anatomically shaped device is coupled with the mildly elevated NAC position seen in this patient, the final position of the NAC can end up

slightly above the point of maximal projection of the breast. **(E,F)** As a result of the implant being placed above the muscle in the subglandular plane, there is no breast animation seen with contraction of the pectoralis major muscle.

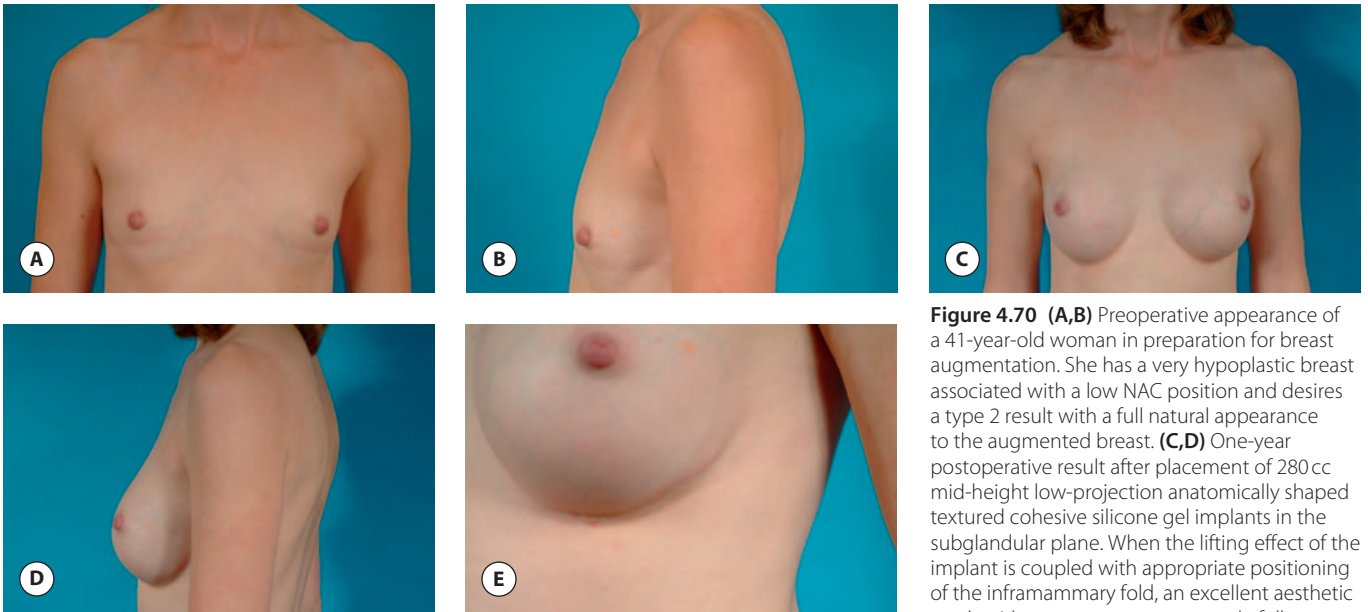


Figure 4.70 (A,B) Preoperative appearance of a 41-year-old woman in preparation for breast augmentation. She has a very hypoplastic breast associated with a low NAC position and desires a type 2 result with a full natural appearance to the augmented breast. **(C,D)** One-year postoperative result after placement of 280 cc mid-height low-projection anatomically shaped textured cohesive silicone gel implants in the subglandular plane. When the lifting effect of the implant is coupled with appropriate positioning of the inframammary fold, an excellent aesthetic result without any excess upper pole fullness can be achieved. **(E)** With stable fold positioning, the scar remains located directly in the fold.

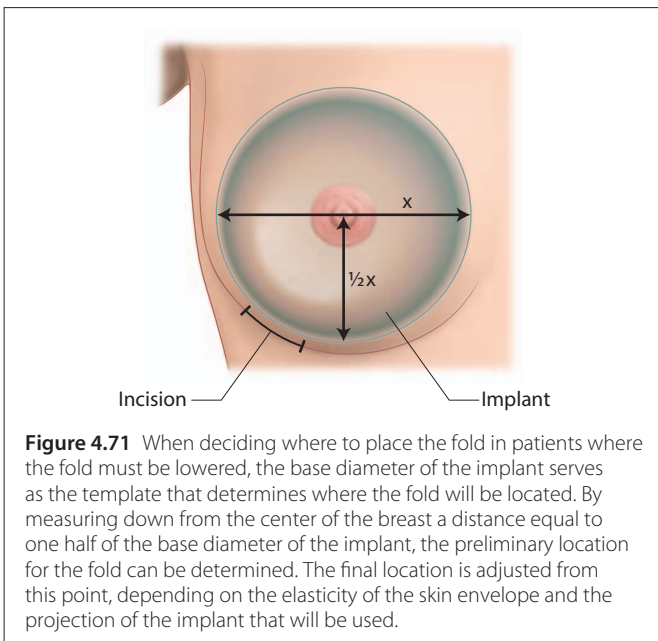


Figure 4.71 When deciding where to place the fold in patients where the fold must be lowered, the base diameter of the implant serves as the template that determines where the fold will be located. By measuring down from the center of the breast a distance equal to one half of the base diameter of the implant, the preliminary location for the fold can be determined. The final location is adjusted from this point, depending on the elasticity of the skin envelope and the projection of the implant that will be used.

measurement ($1/2 X$), as will the distance from the midline over to the lateral extent of the pocket. It follows then that measuring from the center of the proposed breast (usually the NAC) downward to the new inframammary fold will also be $1/2 X$ and this measurement will define the inferior border of the pocket (**Figure 4.71**). These measurements are most consistently made with the patient supine as the distorting and unidirectional effect of gravity is removed with the breast in this position. Once the basic position of the fold has been determined, an allowance must then be made for the elasticity of the skin as influenced by the distending effect of the underlying implant and the position of the fold must be adjusted lower. This is because the mass effect of the implant will pull the inferior pole breast skin away from the chest wall and the effective distance between the NAC and the inframammary fold will increase. The degree of adjustment will vary from patient to patient; however, for moderate- to mid-profile implants, the proposed incision and fold location must be lowered up to 5 mm to ensure placement of the scar in the inframammary fold. For mid- to high-profile implants, the proposed incision location as well as the position of the fold must be lowered up to 1 cm.

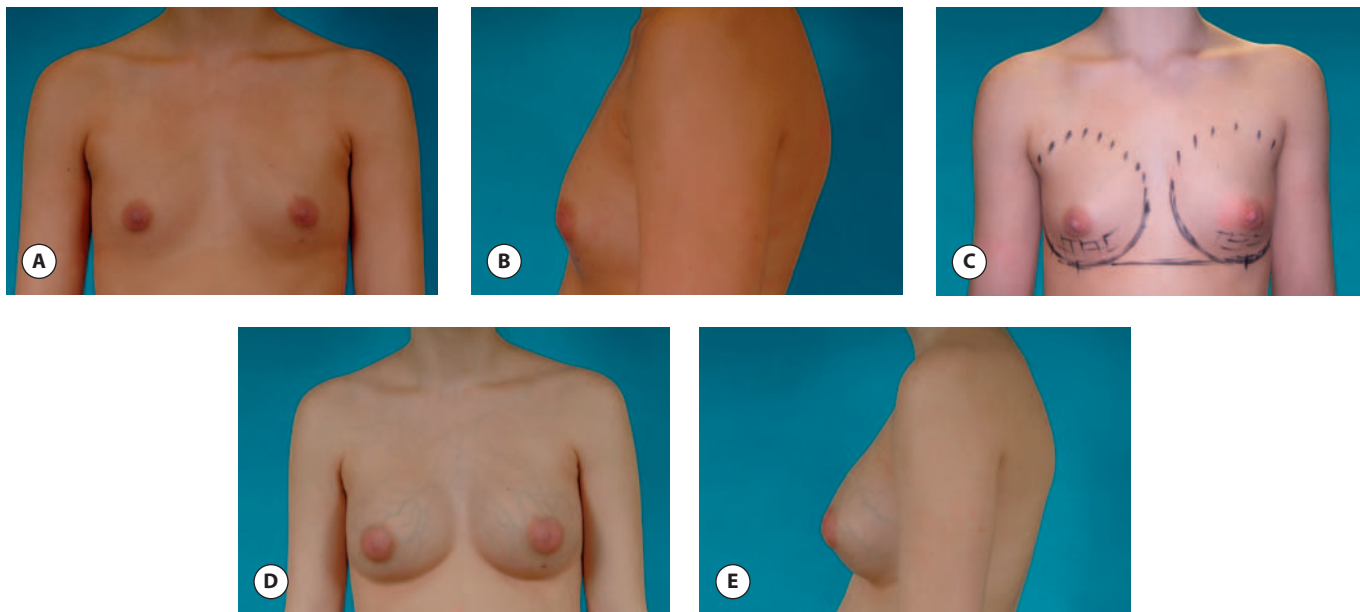


Figure 4.72 (A,B) Preoperative appearance of a 21-year-old woman in preparation for breast augmentation. She has a hypoplastic breast associated with a high inframammary fold position and desires a type 2 result with a full natural appearance to the augmented breast. (C) Preoperative marks showing the desired position of the new inframammary

fold in conjunction with soft tissue release of the lower pole of the breast. (D,E) Two-year postoperative result after placement of 315 cc mid-height low-projection anatomically shaped textured cohesive silicone gel implants in the subglandular plane. The inframammary fold has been set accurately and has maintained a stable position over time.

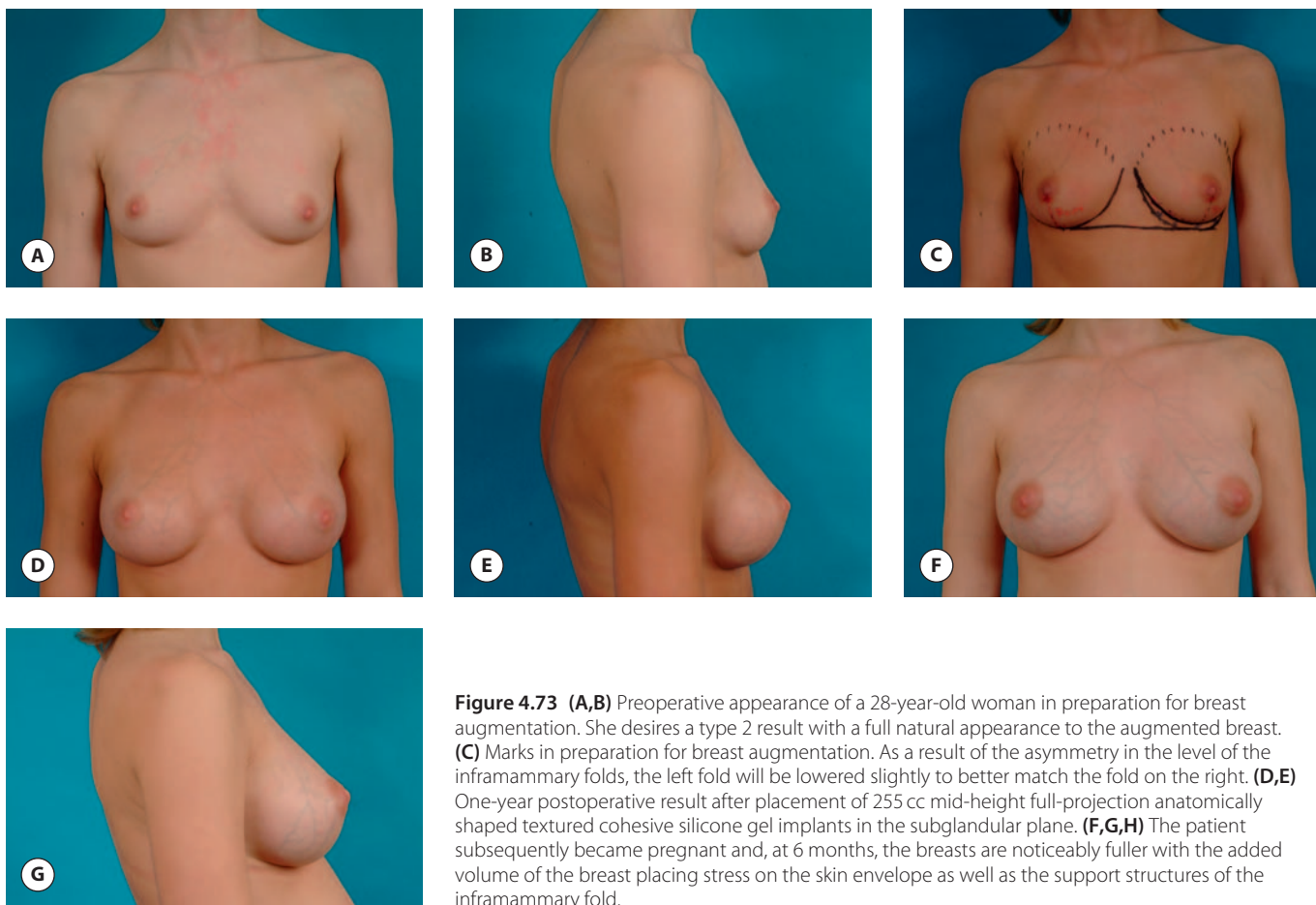


Figure 4.73 (A,B) Preoperative appearance of a 28-year-old woman in preparation for breast augmentation. She desires a type 2 result with a full natural appearance to the augmented breast. (C) Marks in preparation for breast augmentation. As a result of the asymmetry in the level of the inframammary folds, the left fold will be lowered slightly to better match the fold on the right. (D,E) One-year postoperative result after placement of 255 cc mid-height full-projection anatomically shaped textured cohesive silicone gel implants in the subglandular plane. (F,G,H) The patient subsequently became pregnant and, at 6 months, the breasts are noticeably fuller with the added volume of the breast placing stress on the skin envelope as well as the support structures of the inframammary fold.

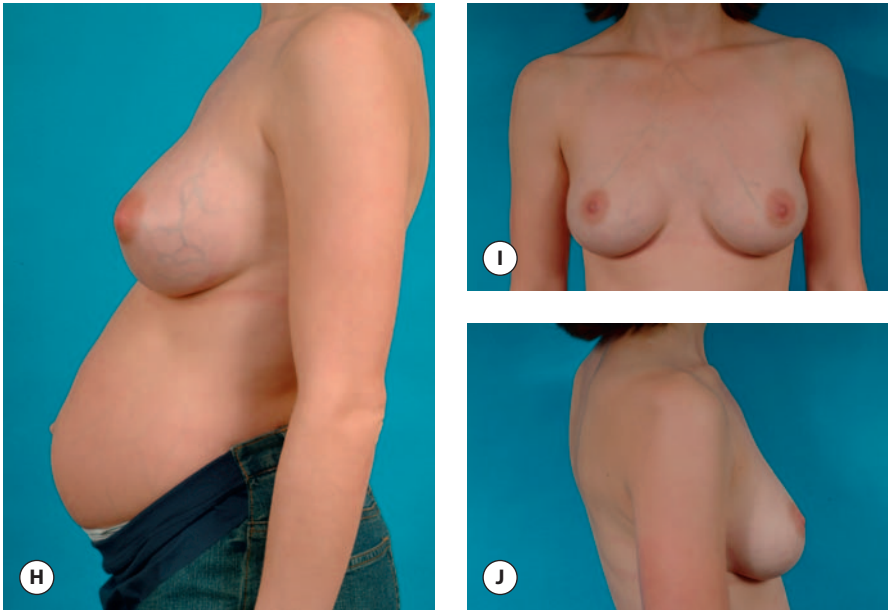


Figure 4.73 (Continued) (I,J) Three-year postoperative result after two pregnancies. The patient breast-fed both infants successfully. Despite the volumetric stress applied to the soft tissue envelope of the breasts by two pregnancies and breast-feeding, the shape of the breasts remains largely unchanged when compared to the initial postoperative result and the location of the fold has remained stable.

Once the location of the fold has been set, the dissection techniques described previously are used to be certain that the eventual fold is not lowered any further due to inadvertent release of the fascial support structure of the breast. By dissecting on top of Scarpa's fascia and using the strong superficial fatty layer to support the breast implant, a stable fold position can be created that withstands the forces placed on it over time (Figure 4.72). Even in cases where the patient has become pregnant and has breast-fed, the fold has held up and provided solid support for the overlying implant with no subsequent implant malposition or breast distortion (Figure 4.73). By determining fold location in this fashion and technically creating the fold as described,

a stable foundation can be set that allows the other variables of pocket plane and implant selection to be manipulated to maximal effect.

The implant selection system described in this chapter has been formalized in conjunction with the Mentor Corporation into a self-contained kit called the Bodylogic Implant Selection System. This kit contains a patient evaluation form, a slide ruler, skin calipers, and an implant selection booklet along with an instructional CD that describes how to perform the measurements described in this chapter and then use the information to optimally select an implant for a given patient. This kit can be obtained from your local Mentor sales representative.

Summary

The basic tenants of breast augmentation involve in the simplest of terms, making an incision, creating a pocket and inserting an implant. By recognizing and analyzing the multiple

variables that can affect the result and strategically applying the technical details outlined in this chapter, consistent and aesthetic results can be obtained.

Mastopexy

One of the primary goals of any aesthetic procedure is to restore aged or otherwise injured structures to a rejuvenated and youthful appearance. In fact, it is the youthful ideal that serves as a template for nearly every aesthetic procedure commonly performed in plastic surgery today. To that end then with regards to the breast, in order better to understand the surgical principles involved in mastopexy, it is helpful to review the attributes of the youthful breast that help identify it as an object of beauty and femininity. Then, understanding how these attributes are altered in the ptotic patient allows an organized and complete surgical plan for the operative correction of ptosis to be developed.

Breast Ptosis – Definitions

From an anatomical standpoint, the youthful breast is positioned in the middle of the chest, with the inframammary fold variably located at the level of the 4th to 6th intercostal space. In fact, when considering the proportions that define the aesthetics of the body, the breast is clearly a chest wall structure that is distinctly separate from the abdomen. In this position, a breast with a full rounded lower pole contour and a nipple-areola complex (NAC) that is positioned directly at the point of maximal projection can accentuate and provide a pleasing contrast to the decidedly female contours of an aesthetic abdomen. By keeping these relationships in mind, four elements of breast ptosis can be described.

Positional Breast Ptosis

Many patients who present for ptosis surgery in fact have developed descent of the entire breast complex on the chest wall such that the normal aesthetic ideals are altered. These patients present with a low inframammary fold and an often underfilled and lax breast skin envelope that overhangs the fold and rests on the lower rib cage, masking the contour of the upper abdomen (**Figure 5.1**). This anatomic relationship is referred to as positional breast ptosis and it represents an under-recognized component of the overall presentation of the ptosis patient. It is most commonly seen in the massive weight loss patient where, after weight loss, the overall soft tissue expansion of the skin envelope of the breast caused by the obesity results in physical descent of the entire breast complex including the inframammary fold inferiorly on the chest wall. In some patients, the breast can actually be seen to fall as low as halfway down the length of the torso (**Figure 5.2**). Positional breast ptosis is very difficult to correct surgically and can actually be made worse very easily if the attachments of

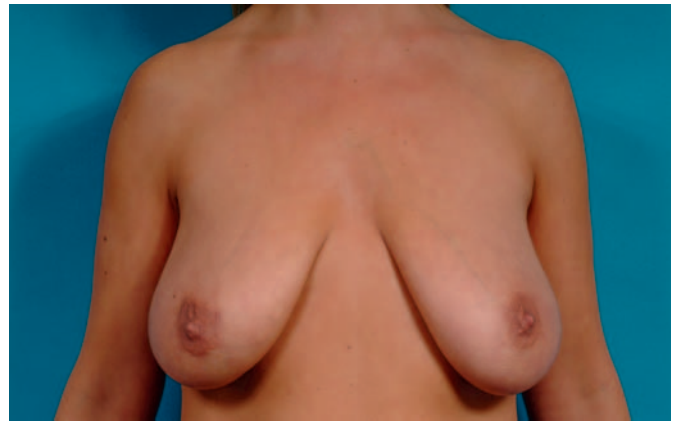


Figure 5.1 The location of the breast is ideally in the upper third of the torso. When the inframammary fold falls below the upper third, the entire breast appears malpositioned inferiorly in relation to the torso. This is referred to as positional breast ptosis.

the inframammary fold are disrupted in any way. For this reason, recognizing positional ptosis is critical in allowing appropriate management of the breast to optimize the final result.

Volume Ptosis

Assuming that the inframammary fold and overall position of the breast is properly located, it is then very common for the existing breast volume to become ptotic. In the aesthetic youthful breast, the support structures in the breast as well as the skin are strong, uninjured and are able to contain the developing breast volume without inordinately stretching. As a result, the volume of the breast is symmetrically distributed over the chest wall. When the patient stands upright, a mild descent in the volume distribution occurs that creates a pleasing, full and rounded lower pole along with an upper pole contour that has a smooth takeoff from its attachments to the upper chest and results in a straight line contour extending down to the point of maximal projection, where, ideally, the NAC is located (**Figure 5.3**). Alteration in these relationships contributes significantly to the appearance of the ptotic patient. Over time, and under the influence of other factors such as pregnancy, weight fluctuations or simply aging, the support structure of the breast can change. As the internal ligamentous support of the breast stretches, particularly with the changes in breast volume that occur with pregnancy and subsequent breast-feeding, stress is placed on the skin. Gradually, the skin gives way and the inherent elastic character becomes diminished.

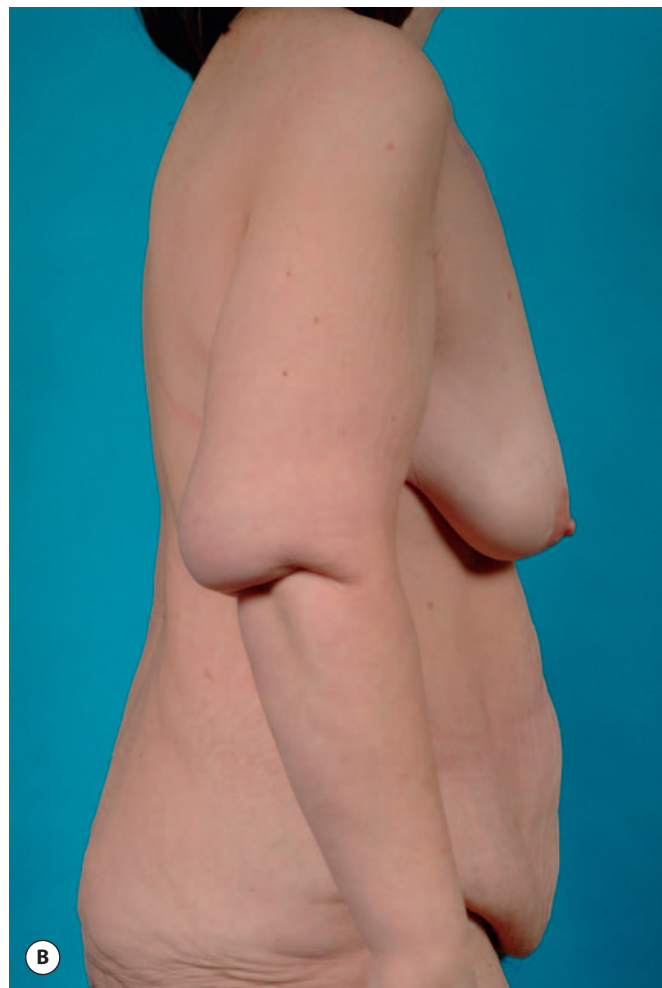
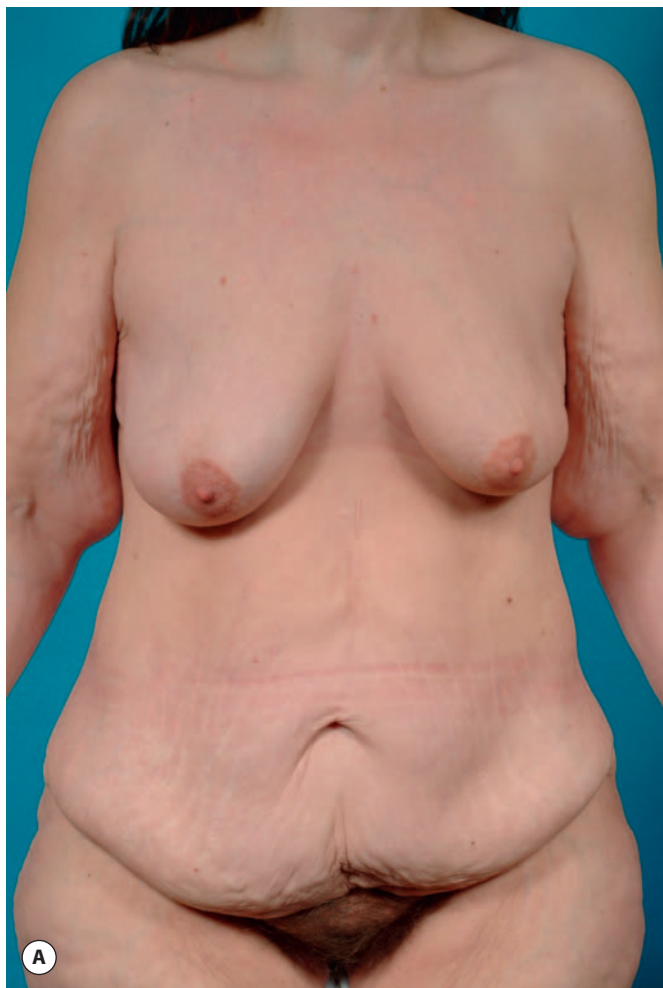
Figure 5.2 (A,B) This patient underwent a 150 pound (68 kg) weight loss after gastric bypass surgery. While she was obese, the volume effect of the underlying fat expanded the skin envelope of the entire chest wall. Then, with the deflation of the skin envelope that occurred as a result of the weight loss, the entire breast complex shifted inferiorly, creating a *positional breast ptosis* characterized by inferior malposition of the inframammary fold and ptosis of the redundant skin envelope. As a result,

when the entire length of the torso is considered from the shoulders to the pubis, the most inferior portion of the breast can be seen to fall approximately halfway down the length of the torso. Another indicator of the inferior positioning of the breast can be identified by noting that the location of the inframammary fold is significantly below the midpoint of the humerus, which serves as an additional commonly used marker for the ideal location of the inframammary fold.

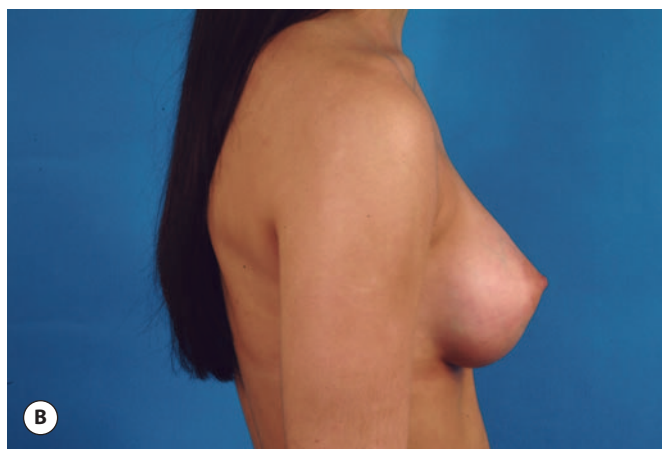
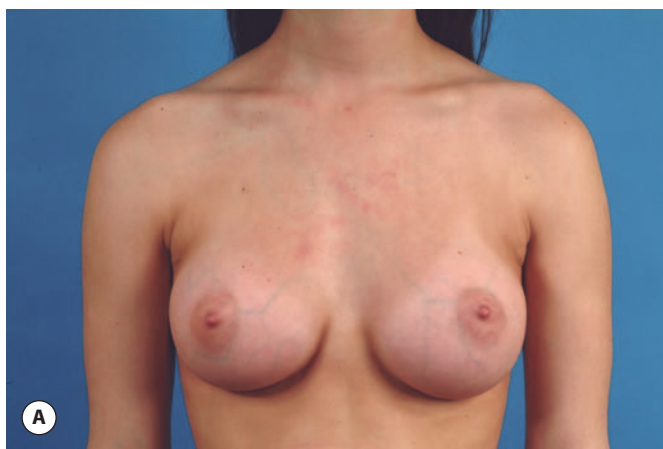

Figure 5.3 (A,B) In the ideal breast, a full rounded lower pole contour is present with the NAC positioned at the apex of the breast mound. When viewed from the side, a straight line contour from the take off point from

the chest wall down to the nipple is created that is the hallmark of the aesthetically mature, unaugmented breast.

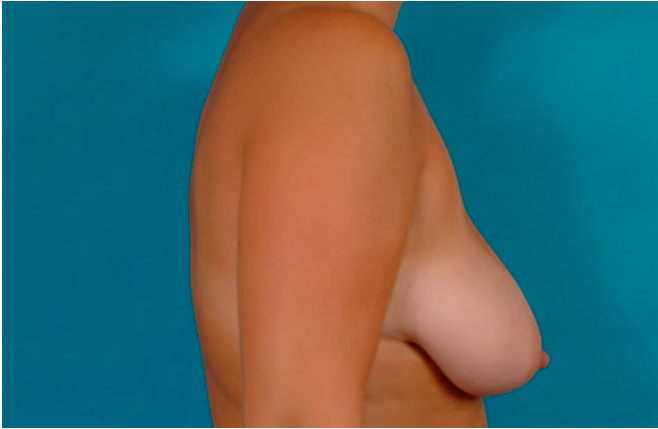


Figure 5.4 In patients with an exaggerated elastic character to the skin and connective tissue framework of the breast, the support provided by these structures can be overcome over time by the mass effect of the parenchyma, creating a condition called *volume ptosis*. When this occurs, the overall breast contour appears inferiorly malpositioned on the chest wall as the entire breast is drawn inferiorly. Often there is an associated upper pole concavity.

The result is tissue stretching with descent of the majority of the volume of the breast into the inferior portion of the skin envelope. This volume ptosis can result in a concavity in the contour of the upper pole of the breast and a breast that appears elongated (Figure 5.4). Occasionally, ptosis of the volume of the breast disproportionately involves only the skin envelope of the lower pole and as the breast gradually descends, a new point of maximal projection is created by the newly configured breast contour. In these patients, the existing NAC actually assumes a position in the upper pole of the breast above the point of maximal projection and the distance from the nipple down to the inframammary fold becomes disproportionately lengthened. This form of volume ptosis is known as *pseudoptosis* (Figure 5.5).

Breast Skin Ptosis

With aging, weight loss or after pregnancy, the breast fat and parenchyma can variably involute, resulting in a decrease in breast volume. Typically, however, the skin surface area does not appreciably change and the breast becomes underfilled and redundant with the result being ptosis of the breast skin envelope. In these patients, the breast often demonstrates a wide and flattened contour that drapes over the inframammary fold, creating a very unaesthetic appearance to the breast. Also, it is very common in these types of patients for the NAC to be positioned very low on the breast mound (Figure 5.6).

NAC Ptosis

Finally, the position of the NAC can further accentuate these changes. In the aesthetic breast, the nipple is located just at the point of maximal projection of the breast mound. For some, even just a hint of an upturn in the nipple location adds a visual element of softness to the breast that some find aesthetic (Figure 5.7). However, any shift in the position of the nipple below the point of maximal projection is most decidedly unaesthetic and detracts from what might otherwise be an acceptable breast contour in selected patients. For this reason, any nipple position that is

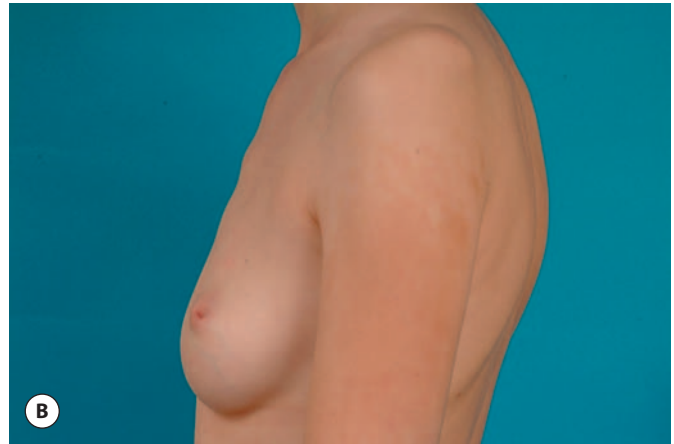
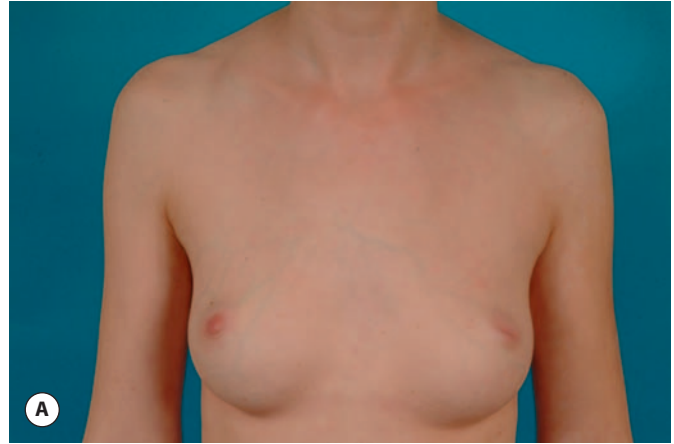

Figure 5.5 (A,B) In selected cases, the lower pole of the breast can expand preferentially, creating an anatomical configuration called *pseudoptosis*, which is characterized by marked expansion of the lower pole skin envelope along with a superiorly malpositioned NAC. In this patient, the inferiorly directed pull on the fixed position of the nipple is so severe that the nipple is actually inverted as the underlying breast parenchyma falls away under the influence of gravity.

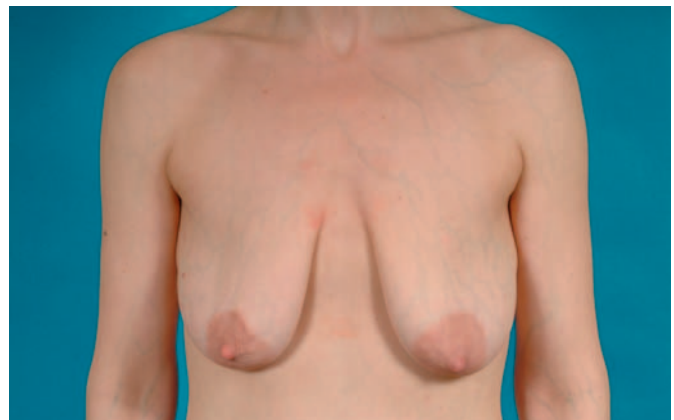

Figure 5.6 Patients with mild to moderate degrees of breast hypertrophy who then undergo involution of the breast with loss of breast volume will present with a redundant skin envelope that hangs over the inframammary fold, creating what is termed *breast skin ptosis*. In these patients, the breast has a very wide and flat appearance that is often associated with severe ptosis of the NAC.

noted to be below the point of maximal projection is termed *NAC ptosis*. Traditionally, this type of ptosis has been graded as:

- Grade 1 – Nipple at the most projecting point of the breast
- Grade 2 – Nipple between the most projecting point and the lower breast contour
- Grade 3 – Nipple at the lower breast contour (Figure 5.8).

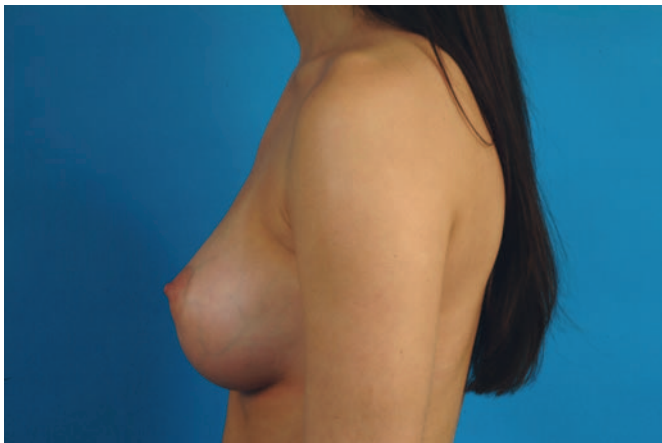


Figure 5.7 A slightly upturned nipple position can be viewed as aesthetically pleasing when it is associated with a full rounded breast contour.

It must be recognized, however, that this classification system is incomplete and misses a very important relationship that directly affects the surgical management of the position of the NAC. In many patients, the nipple is located directly at the point of maximal projection; however, because the skin envelope is ptotic as well, the overall position of the NAC is low and therefore requires lifting to optimally restore an aesthetic relationship between the breast mound and the position of the NAC (Figure 5.9). The structure that defines this position is the inframammary fold and where the NAC lies in relation to the fold must also be described. This is performed by noting where the nipple lies in relation to the inframammary fold when looking at the patient from the front. By drawing a line that connects the inframammary fold on each side across the midline, the position of the nipple in relation to this line can be assessed by simply standing back and observing the relationship with the aid of a straight edge. The following classification is utilized:

- Grade A – Nipple above the inframammary fold line
- Grade B – Nipple at the inframammary fold line
- Grade C – Nipple below the fold line.

By combining the two classifications, a useful indicator of nipple position can be developed that can guide surgical management of NAC ptosis. For example, a patient with a nipple that is at or slightly above the point of maximal projection and lies above the inframammary fold (1A) does not require lifting of the NAC.

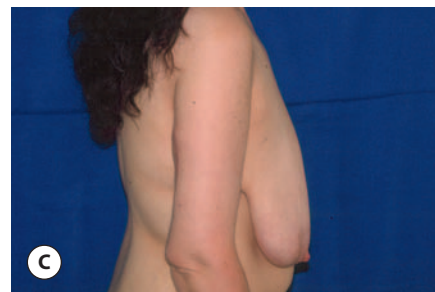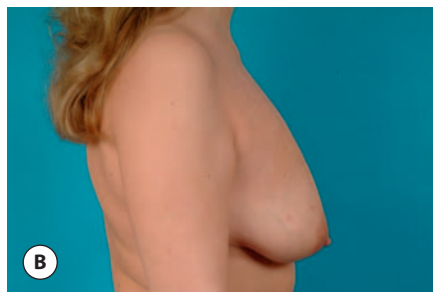
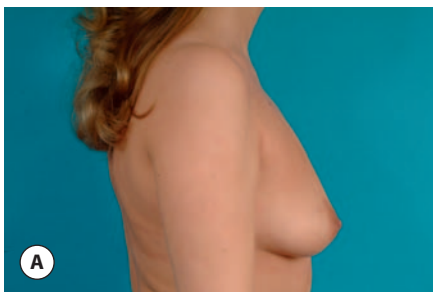


Figure 5.8 (A) An example of grade 1 ptosis where the nipple is directly at the point of maximal projection on the breast mound. (B) An example of grade 2 ptosis with the nipple being located at a point between the point

of maximal projection and the lower breast contour. (C) An example of grade 3 ptosis where the nipple is located at the level of the lower breast contour.

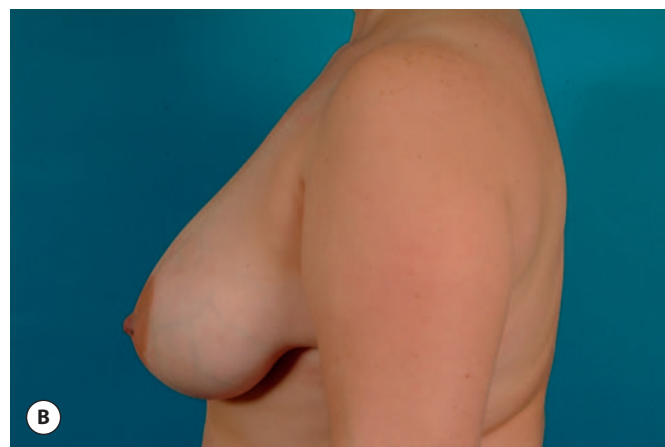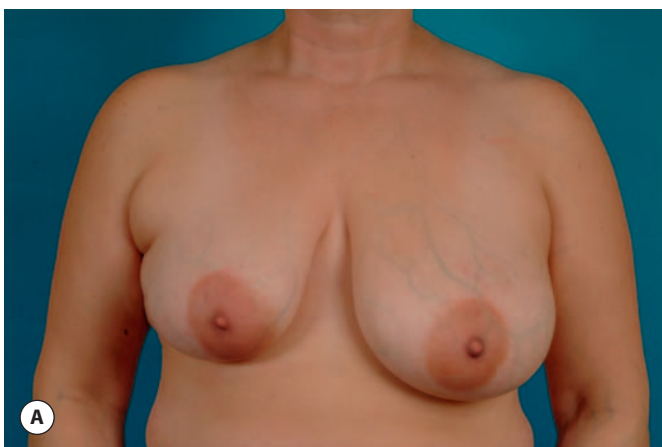
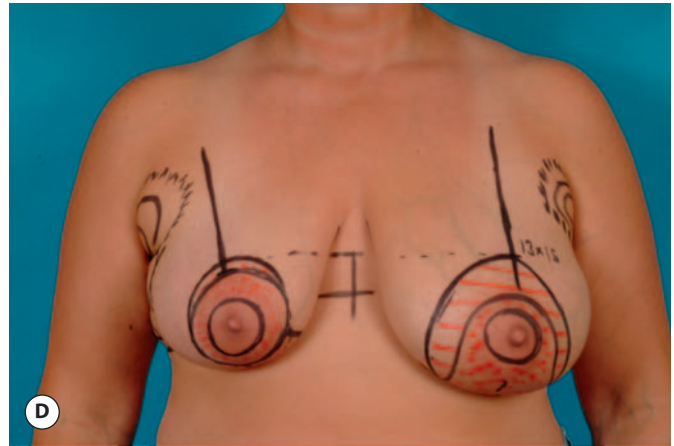


Figure 5.9 (A–C) The preoperative appearance of a patient with a mild tubular breast deformity in association with macromastia and asymmetry. Despite the presence of the nipple at the most projecting point of the

breast mound on each breast, as seen particularly on each lateral view (grade 1 ptosis), the overall appearance of each breast is one of ptosis due to the fact that both nipples lie below the inframammary fold.

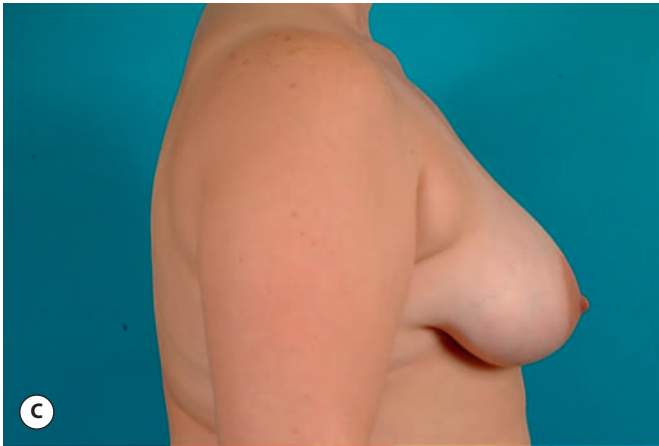

Figure 5.9 (Continued) (D) When the level of the fold is drawn across the midline, it becomes apparent that both nipples are below the fold with the left being lower than the right. Nipple ptosis in relation to the fold is an



important relationship to note and must be considered in conjunction with nipple position on the breast mound to optimally design a sound surgical plan for operative correction.

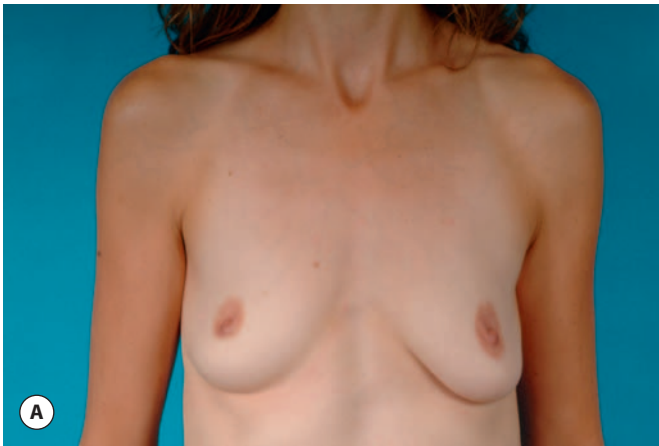
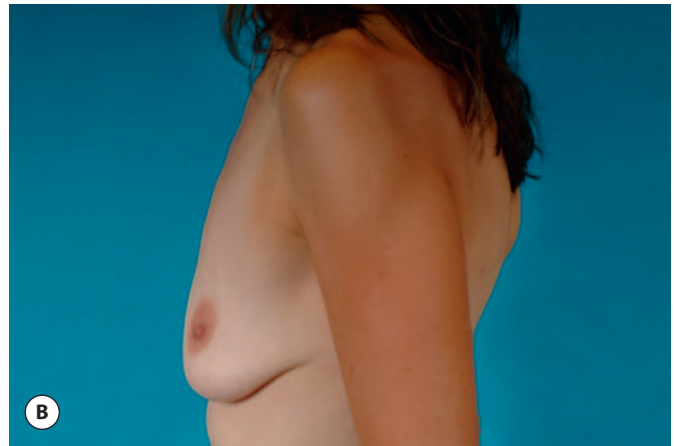
Figure 5.10 (A,B) Preoperative appearance of a patient with asymmetry and pseudoptosis of the left breast. The NAC is located at the apex of the breast and is above the level of the inframammary fold, therefore, according to the described classification, she demonstrates a 1A NAC position. As a



result, despite the fact that she requires a left-sided tightening of the lower pole skin envelope to restore an aesthetic appearance to the breast, no lifting of the NAC position is required.

Such a relationship is seen with pseudoptosis, where operative correction would be aimed at lifting the volume of the breast to position it properly under the NAC (Figure 5.10). However, a patient with a nipple at the point of maximal projection that lies below the inframammary fold (1C) will require not only lifting of the NAC but also reduction of the redundant skin envelope to restore an aesthetic relationship between the NAC position and the breast mound (Figure 5.11). For patients who have a nipple at the point of maximal projection that lies directly at the inframammary fold (1B), several surgical options may be appropriate including mild lowering of the fold, augmentation particularly with shaped cohesive gel breast implants, periareolar mastopexy or some combination of these techniques (Figures 5.12, 5.13).

the lower fold. Basing treatment decisions on NAC placement is therefore best done relying on the new lower fold position. Alternatively, in mastopexy alone, utilization of the vertical technique in particular can elevate the lower fold relatively easily, therefore, in this circumstance, treatment decisions regarding placement of the NAC would best be made based on the new higher fold position.

Whatever technique is used, in most instances it is best to set the position of the fold and then reposition the NAC based on this chosen fold position.

When patients present with asymmetry in the level of the inframammary fold, treatment decisions must then be made based on the proposed final fold position. For instance, in augmentation mastopexy, it is far easier to lower the high fold to create symmetry with the opposite side than it is to raise

Evaluation of the Ptotic Patient

When designing a surgical strategy for the correction of ptosis, it must be recognized that each of the four elements of ptosis can be variably present and these elements will combine to determine the overall appearance of the breast. Therefore, the goal of the preoperative evaluation is to determine the presence and extent of each of these elements to allow for an appropriate

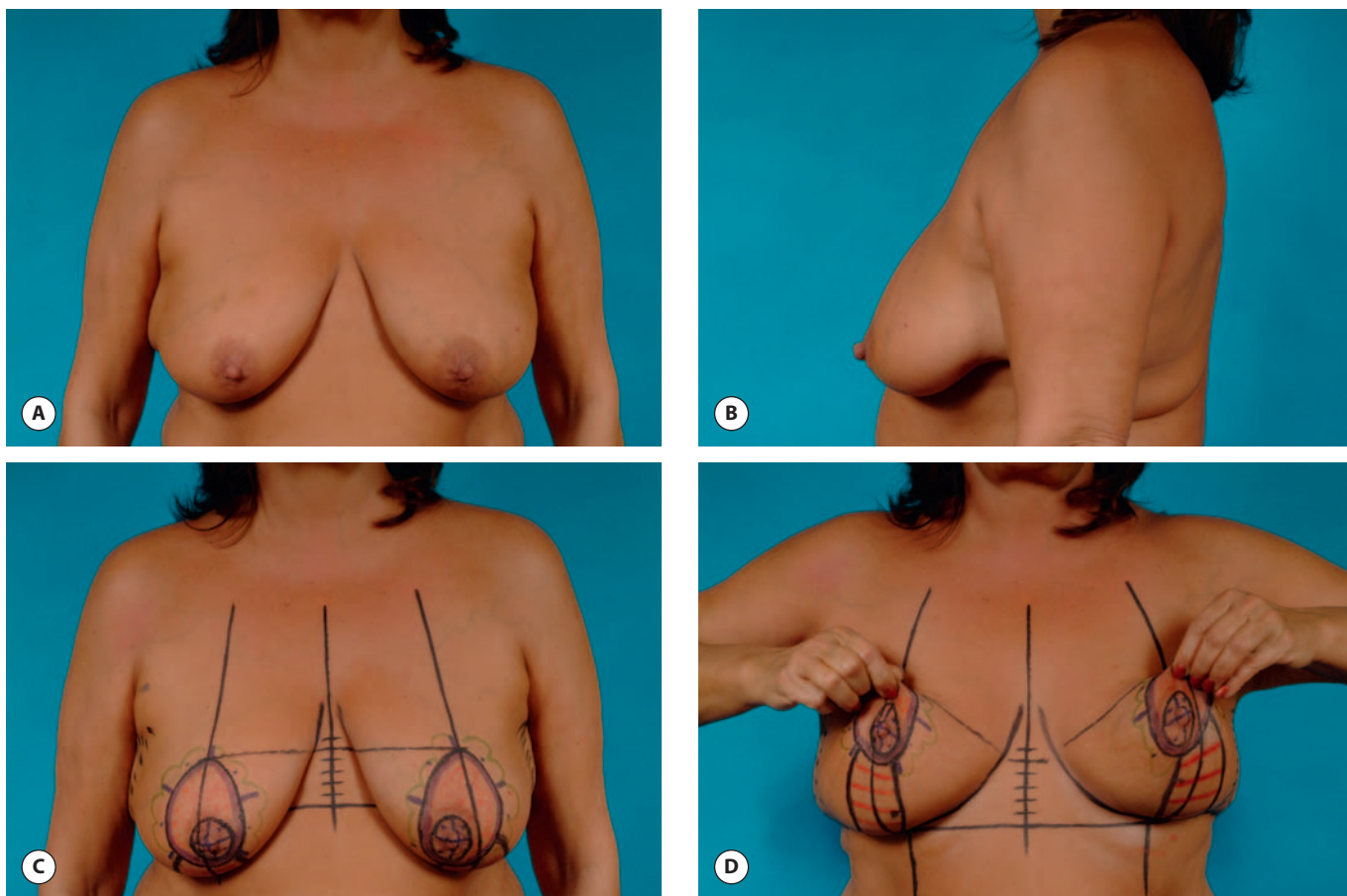


Figure 5.11 (A–D) Preoperative appearance of a patient with ptosis of the skin envelope and the gland. Here the NAC is at the most projecting point of the breast mound but falls well below the inframammary fold. Therefore, she demonstrates a 1C NAC position. This combination represents the most

complex of ptosis conditions, therefore, she will require a full circumvertical skin pattern along with internal reshaping to restore an aesthetic shape to the breast.

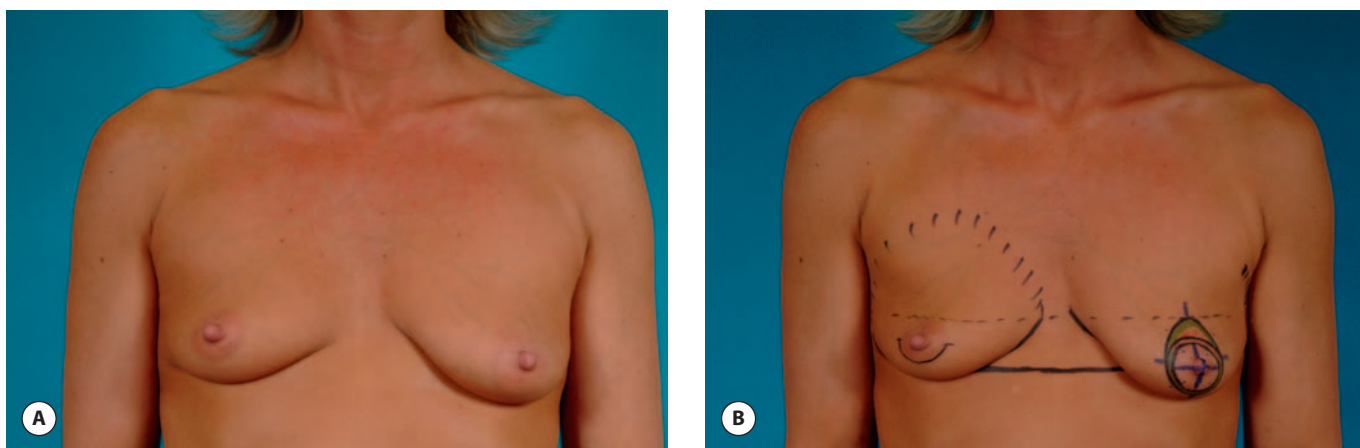


Figure 5.12 (A,B) Preoperative appearance of a patient with asymmetry and ptosis of the left NAC. Here the left NAC is at the most projecting point of the breast and is located directly at the level of the inframammary fold, therefore, she demonstrates a 1B NAC position. Because of the relationship

between the NAC and the fold, she will require a periareolar procedure to restore an aesthetic relationship between location of the NAC and the breast mound.

surgical strategy for correction to be devised. This must be done in conjunction with an overall evaluation of the patient's health, with particular attention placed on conditions that can affect the size and shape of the breast. Any history of previous breast problems

must be obtained and the presence of breast scars from previous biopsies is noted as this can alter the surgical approach with regard to skin incisions or pedicle choice. Inquiry is made into any family history of breast cancer that might be present and the date of the


		Ptosis grade in reference to breast contour		
		1	2	3
Ptosis grade in reference to inframammary fold	A	Nipple at apex Nipple above fold No lift	Nipple below apex Nipple above fold Periareolar lift, augmentation, lower fold	
	B	Nipple at apex Nipple at fold Periareolar lift, augmentation, lower fold	Nipple below apex Nipple at fold Periareolar lift, augmentation, lower fold	Nipple at lower border Nipple at fold Periareolar lift, augmentation, lower fold
	C	Nipple at apex Nipple below fold Circumvertical lift	Nipple below apex Nipple below fold Circumvertical lift	Nipple at lower border Nipple below fold Circumvertical lift

Figure 5.13 General summary algorithm combining fold relationship with breast contour as it related to treatment of ptosis. A1 describes a normal NAC breast contour relationship and requires no repositioning of the NAC. B1, A2 and B2 describe mild disproportion between the position of the fold and the location of the NAC in relation to the breast contour. Typically, periareolar lifting, augmentation, lowering of the fold or some combination of these maneuvers will restore an overall aesthetic breast appearance. C1, C2 and C3 represent significant ptosis not only of the NAC but also the skin envelope. Here, more aggressive skin envelope management is typically required in the form of a circumvertical lift. The B3 relationship is seen in severe cases of tuberous breast deformity. The A3 relationship does not apply.

last mammogram and the result is documented. A reproductive history is obtained, including the number of pregnancies, deliveries and any plans for future children. Particular note is made with regard to breast-feeding. How many children were breast-fed and how long this process continued can provide insight into the forces applied to the breast that may have significantly influenced the patient's present condition. If further pregnancies are planned, it is best to inform the patient that this may have an adverse effect on the ultimate result, necessitating a revision in the future.

Examination of the breast and chest wall is performed to document the presence of any suspicious masses as well as make note of any asymmetries in the shape, size or position of the breasts. Asymmetries in the level of the inframammary fold as well as the nipple are noted. Measurements that document the distance from the clavicle to the nipple, the sternal notch to the nipple and the inframammary fold to the nipple as a static measurement and with the lower pole breast skin under stretch, as well as the intermammary distance are made. The rationale for these measurements is the same as for breast augmentation as this information documents asymmetries and triggers appropriate discussion with the patient about what can be achieved with mastopexy.

Once the basic appearance of the breasts has been documented, the goals of the patient must be assessed. One of the first decisions to be made centers around whether or not a breast implant will be required to achieve the desired result. In the most straightforward circumstance, the patient has decided ahead of time that she does not want a breast implant. In this instance, the decision-making process is simplified and centers on lifting and reshaping the existing

breast as needed to achieve the optimal result. Alternatively, some patients are open to the possibility of using a breast implant if it will improve the postoperative aesthetics of the breast. In these patients, the benefits of providing additional volume to the breast with the addition of an implant must be weighed against the potential complications that come into play when an implant is used. If there is enough volume in the breast preoperatively to achieve a proportional result and all that is required is lifting and reshaping of the existing breast volume, it is best to avoid the use of an implant. The procedure is more predictable, simpler and if all goes as planned, avoids any of the potential complications that can occur over the long term if an implant is placed. The need for an implant is assessed by simply cupping the lower pole of the breast and lifting it up to a youthful position. This maneuver lifts the entire breast including the skin, parenchyma and NAC to try to provide for the patient some rough idea of how big the breast will be with a lift alone. If it appears that this size will be satisfactory to the patient, a mastopexy without an implant is planned. If the patient seems to want a bigger breast than that seen with this breast transposition maneuver, discussion over the merits and potential complications of adding an implant must be entertained.

When discussing breast size after mastopexy, it is helpful to stress to the patient that the size of the breast very frequently appears smaller after the procedure (Figure 5.14). The simple act of removing skin to tighten the skin envelope can create the illusion of a smaller breast despite the fact that no parenchyma was removed. This is due to the fact that a breast with variable ptosis of the skin envelope and volume looks bigger than it actually is. Once the volume is lifted and the redundant skin envelope is reduced, the true volume of the breast becomes evident. As a result, for some patients the newly shaped and proportioned breast can appear smaller than expected. It is important to discuss this ahead of time with the patient, particularly when the use of an implant is being considered, to avoid the potential for postoperative patient dissatisfaction.

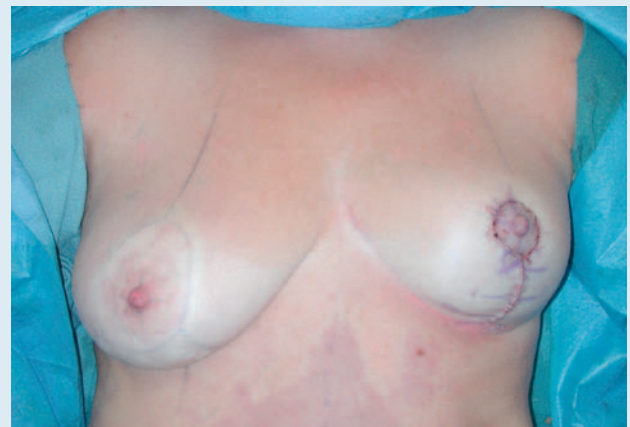

Figure 5.14 Intraoperative appearance of a patient after undergoing a left mastopexy using the SPAIR technique. Although no fat or parenchyma was removed from the breast, the overall size of the breast appears smaller than the untreated side. This case demonstrates that simple tightening of the skin envelope with repositioning of the ptotic breast parenchyma superiorly can create a breast that appears smaller than what otherwise might be expected.

Beyond the questions about whether or not to use an implant, other common patient requests include lifting the entire breast higher on the chest wall, increasing the fullness in the upper pole, lifting the position of the NAC, reducing the diameter of an enlarged and out of proportion areola and creating a firmer consistency to the breast. Each of these goals can be achieved using the techniques described in this chapter, either alone or in combination.

Surgical Techniques in Mastopexy

There are three surgical goals that must be variably accomplished to correct breast ptosis and provide a firm, uplifted and aesthetic result. These include, lifting the NAC position in relation to the breast mound, managing the excess skin envelope and reshaping the breast.

Lifting the NAC

When the nipple is located at or below the point of maximal projection of the breast, it must be lifted to adequately restore an aesthetic breast contour. It is important to remember, however, that the point of maximal projection is assessed in relation to the new surgically altered and uplifted contour of the breast. As such, a preoperative nipple location that appears to be non-ptotic can appear to be low on the breast mound after the ptosis of the breast volume has been corrected. For this reason, nearly every patient who presents for mastopexy will require some

degree of lifting of the NAC, even in those cases where the NAC did not appear to be inferiorly displaced preoperatively.

Repositioning the NAC superiorly requires an asymmetrical periareolar skin excision with the amount of skin removed above the NAC being greater than the amount removed below. When the outer periareolar skin incision is sutured to the incision made in the areola, the result is an overall lifting of the position of the NAC as well as a reduction in the diameter of the areola. Although the periareolar lift is a well-described and accepted technique in aesthetic surgery of the breast, there are several well-recognized complications that can compromise the aesthetic result. Critically examining these complications as well as their cause can lead to surgical maneuvers that can prevent or at least limit their effect and improve the results and consistency of periareolar techniques.

Asymmetrical areolar shape One of the recognized techniques for lifting the areola involves an incision around the upper half of the areola that is then combined with an excision of a wedge of skin above the areola. This technique, called a crescent mastopexy, is intended to provide a distracting force that lifts the top of the areola but limits the scar to the upper border of the areola where it joins with the breast skin. While limiting the scar is an attractive goal, in actuality, the net effect of the asymmetrical force that is applied to the areola is to stretch it along the vertical axis with the result being an oval-shaped and widened areolar diameter. The resulting distorted areolar size and shape compromises the appearance of the areola and creates a less than optimal aesthetic result (Figure 5.15). From this experience

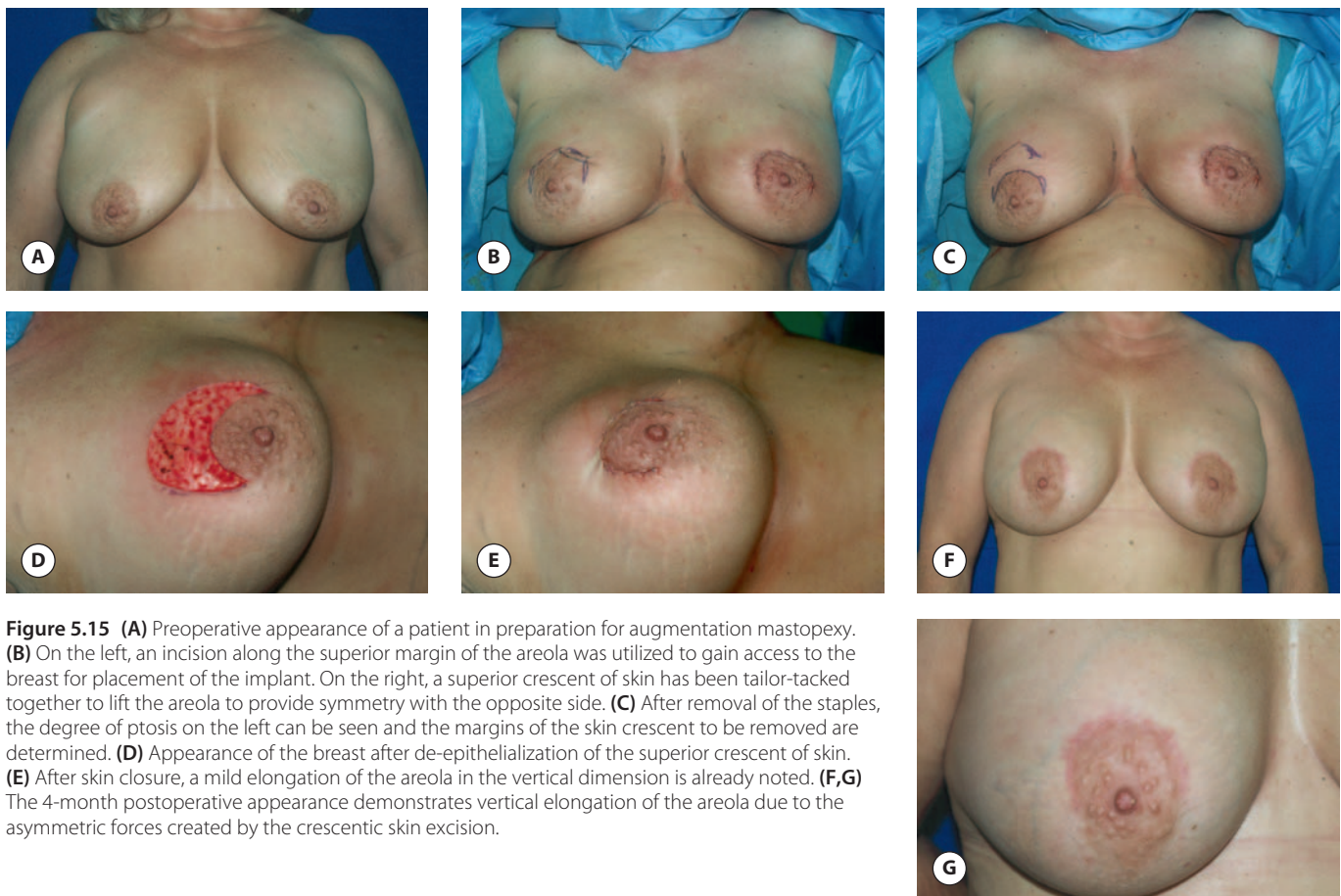


Figure 5.15 (A) Preoperative appearance of a patient in preparation for augmentation mastopexy. (B) On the left, an incision along the superior margin of the areola was utilized to gain access to the breast for placement of the implant. On the right, a superior crescent of skin has been tailor-tacked together to lift the areola to provide symmetry with the opposite side. (C) After removal of the staples, the degree of ptosis on the left can be seen and the margins of the skin crescent to be removed are determined. (D) Appearance of the breast after de-epithelialization of the superior crescent of skin. (E) After skin closure, a mild elongation of the areola in the vertical dimension is already noted. (F,G) The 4-month postoperative appearance demonstrates vertical elongation of the areola due to the asymmetric forces created by the crescentic skin excision.

is derived one of the technical concepts that governs successful periareolar surgery, namely that, *to achieve a round and properly positioned areola, the periareolar incision must be carried around the entire peripheral margin of the intended areolar diameter in order to redistribute evenly and adequately the forces around the subsequent closure.* In this fashion, a controlled and consistently round areolar shape can be created.

Widened areolar diameter Another and perhaps more widely recognized complication of periareolar surgery is widening of the areolar diameter postoperatively. The skin of the areola has an exaggerated elasticity compared to the surrounding breast skin and possesses a tremendous ability to stretch when placed under tension. As result, when there is tension placed on the wound closure around the areola after a periareolar procedure, the areola can spread over time, creating a larger areolar diameter than was initially created at the time of surgery. At times, this postoperative spreading can be dramatic and the distorted proportion that the wide areola creates can significantly detract from the overall aesthetic appearance of the breast (Figures 5.16, 5.17). Clearly, the etiology of postoperative spreading of the areola is related to tension on the areolar closure. From this experience is derived the second of the technical concepts that governs periareolar surgery, namely that *the tension on the wound closure must be minimized as much as possible.* Minimizing tension can be accomplished using a number of different technical modifications, including adding a vertical segment to a periareolar skin pattern whenever possible to reduce the dimensions of the outer periareolar skin incision, limiting the amount of skin removed in

the horizontal dimension and using smaller implants in cases of augmentation mastopexy. But perhaps the most effective technique involves stabilizing the dimensions of the periareolar opening with the use of a periareolar purse string suture. By evenly cinching down the outer skin incision to the desired dimension, tension on the areola can be greatly minimized, leading to a reduced incidence of postoperative areolar spreading.

The technique of applying a purse string suture involves strategically utilizing the appropriate suture material, along with optimizing the technique of suture placement to evenly distribute the tension around the periareolar opening.

Suture material The optimal suture material is a permanent monofilament, which slides much more easily through the dermis than a braided suture which tends to catch and become resistant to movement as it is passed through a dermal length of more than 3 or 4 cm. When the suture material passes easily through the dermis, it facilitates an even cinching down of the periareolar opening without any asymmetrically positioned crimping or bunching of the skin edges. The use of a permanent suture also provides long-term support to the periareolar closure. When absorbable materials are used, reabsorption of the suture can occur before scar stabilization of the tissues has occurred. By using a permanent suture, the chances for postoperative areolar spreading are minimized. Although materials such as nylon and prolene can be used for smaller diameter openings, the ideal suture for this purpose is Gore-Tex (Gore Tex Corporation, Flagstaff, Arizona). This material, which comes from the disciplines of vascular and cardiovascular surgery, where it has been used in conjunction with

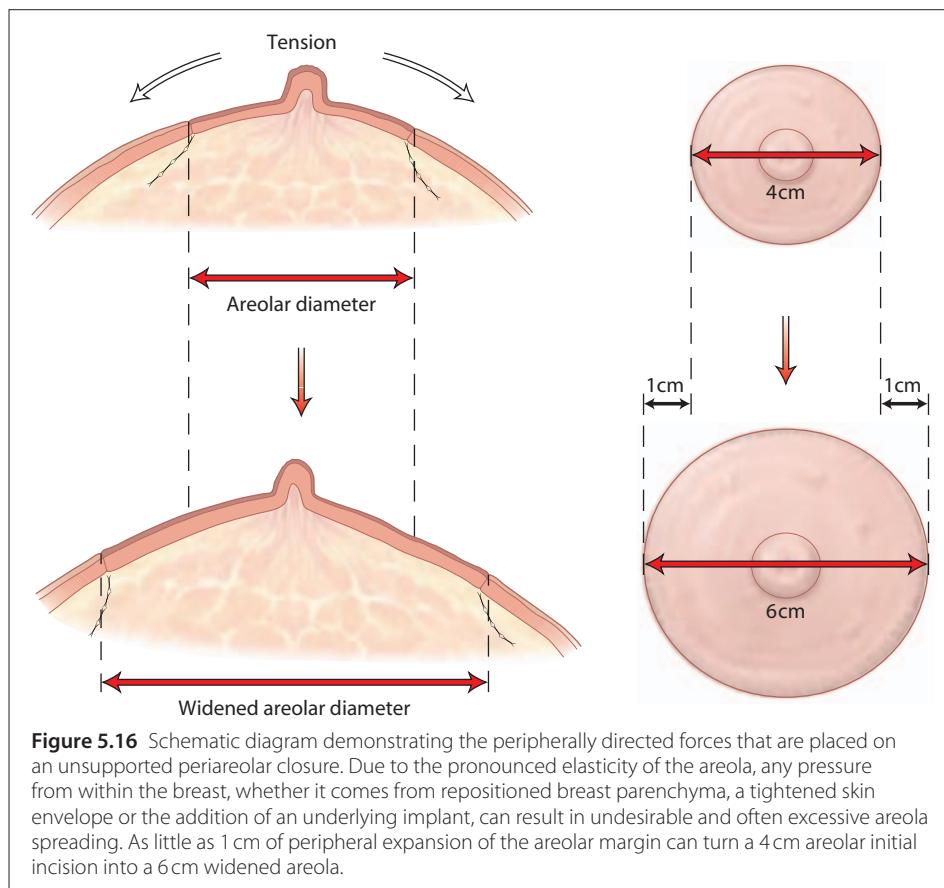

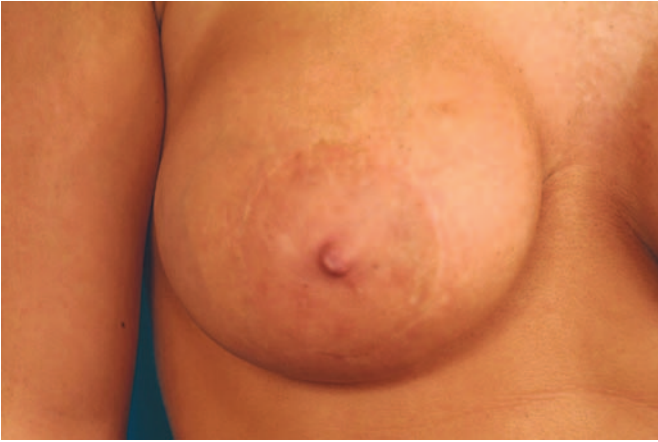


Figure 5.17 Widened areola after periareolar augmentation mastopexy.

vascular grafts for years, is a very strong, smooth and permanent material that slides through tissues with ease. The optimal suture size to use is CV-3, which has a soft and manageable pliability and great strength, all with the size of about a 2-0 prolene suture. By cutting off the curved needles on either end and threading the suture onto a straight needle, long passes with the needle through the dermal layer of the outer periareolar incision can be made, which speeds suture placement. Alternatively, a slightly larger but stronger CV-2 suture may be used. This particular suture comes already swedged onto a straight needle, which obviates the need to thread the suture separately (Figure 5.18). Once the suture is placed, it then becomes very easy to cinch the periareolar defect down to the desired dimension as the Gore-Tex easily slides through the soft tissues without catching or bunching. Using this suture material provides for a precise and controlled management of the periareolar opening over and above that which is possible with any other suture material.

Suture placement When performing a periareolar lift, there are several technical maneuvers that can improve the chances for success and can minimize the potential for areolar spreading, wound dehiscence and irregular, widened or prominent scars. Initially, the limits of the outer periareolar incision are outlined. Vertically, the top of the pattern is located at the point where the top of the areola will be positioned. Inferiorly, the pattern skirts the lower border of the areola. Medially and laterally, the pattern again skirts the areola to avoid unnecessary removal of skin in the horizontal plane that can create a tight closure. This pattern variably assumes the shape of an elongated oval. The width of the planned areolar incision varies from 40 to 44mm. Using a wider areolar incision can predispose to areolar spreading with an excessive areolar diameter developing postoperatively (Figure 5.19). The initial incisions are made just into the dermis and the intervening skin between the outer periareolar incision and the inner areolar incision is de-epithelialized. To place the purse string suture effectively and securely, it is helpful to create a small dermal shelf around the periphery of the periareolar defect. This is as opposed to cutting through the dermis directly at the margin of the periareolar incision. By dividing the dermis approximately 5–6mm away from the de-epithelialized skin edge, a dermal cuff is created that provides a firm scaffold to hold the Gore-Tex suture. By then passing the straight needle directly within the substance of the dermal shelf and minimizing any gaps

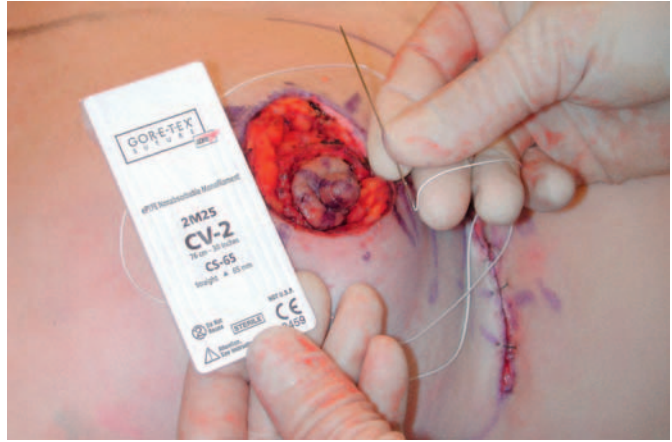


Figure 5.18 Gore-Tex non-absorbable monofilament CV-2 suture on a CS-65 straight needle. This material is smooth, flexible, strong and permanent. It has excellent handling characteristics and passes easily within the dermal framework of a periareolar incision. As a result, excellent control of the dimensions and shape of the periareolar opening can be achieved.

that are present as the various passes with the straight needle are made, the tension on the purse string suture is evenly distributed in the strong and stable architectural framework of the dermis. This helps prevent the suture from rupturing through the dermal cuff and pulling out. Also, because the tension is evenly distributed, the surrounding breast skin is evenly pulled down to the areolar diameter, which prevents uneven gathering of the pleats which inevitably form when the purse string is cinched down. Avoiding intermittent skip areas in the dermal shelf when placing the suture also prevents the development of stress points in the suture strand once it is pulled down that could potentially lead to the suture breaking. It is important to note that the width of the dermal cuff should not be any wider than 5–6mm. If a dermal shelf wider than this is used, then the periareolar opening that results after the purse string suture is cinched down can become quite small and can crowd the areola as it is pulled through the opening, possibly resulting in swelling, NAC ischemia and areolar necrosis.

Once the dermal shelf is developed, the underside margin of the periareolar incision is undermined for a distance of 1–2cm directly at the level of the dermis in all directions. Undermining at this level for a limited distance is well tolerated and does not result in necrosis of the breast skin edges. Nor does it interrupt the parenchymal blood supply to the NAC as long as skin elevation is done under the dermis only with no extension of the dissection into the breast parenchyma. This release of the dermis prevents the fat and parenchyma of the breast from being pulled inward once the purse string is cinched down. If this occurs, a tissue crowding effect can be created around the areola that exerts pressure around the periphery of the areola, creating a slightly depressed areolar contour in relation to the remainder of the breast mound. The resulting contour irregularity results in a flattened breast appearance that detracts from an otherwise smooth and shapely breast mound.

After development and undermining of the dermal shelf, the purse string suture is placed. Ultimately, the suture will be cinched down and secured with 8–10 square knots as the very smooth surface of the Gore-Tex material has a tendency to cause the knot to slip unless a sufficient number of 'throws' are used

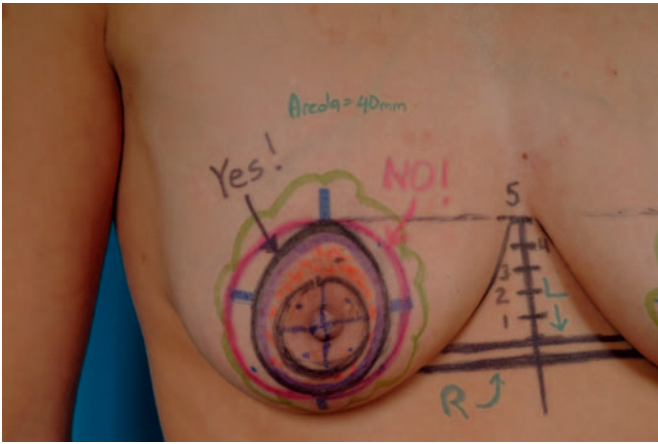


Figure 5.19 When diagramming a periareolar incision, there is a tendency to use a circular pattern designed to match the circular incision made in the areola (pink line). However, this incision pattern unnecessarily removes skin medially and laterally on either side of the areola and results in increased tension on the subsequent closure that can predispose to areolar widening postoperatively. A better option is to limit the amount of skin removed by drawing the pattern so that it just skirts the medial and lateral border of the areola (black line). In this fashion, there will be less tension on the periareolar closure and the shape of the areola will still be circular once the purse string suture is applied and cinched down.

to secure the knot. This creates a knot complex that is quite bulky and, if it is not buried securely under a healthy layer of tissue, postoperative exposure of the knot can occur. Therefore, to begin suture placement, the needle is passed from deep under the dermal edge to superficial and then once the purse string has been placed, it ends by passing the needle from superficial to deep. This positions the knot securely under the dermal shelf and away from the skin closure. Once the knot is tied down, it is then very easy simply to tuck the knot under the dermal shelf so that it will be reliably buried under healthy tissue and will completely prevent subsequent erosion with exposure of the knot. It is my preference always to place the knot at the most medial aspect of the areola in the event that, for whatever reason, it becomes necessary to remove the Gore-Tex suture. For the right breast this would mean starting the purse string at the 3 o'clock position and for the left breast the 9 o'clock position. Then, if the Gore-Tex needs to be removed, it is very easy to simply spread with scissors to separate the incision at the location of the knot, gently pull the intact suture strand away from the skin edge and cut it to pull the suture out. If the location of the knot is not known, this process can be somewhat difficult as, when the suture is cut midstrand and an attempt is made to remove the suture, the knot catches in the scar around the areola, which prevents easy removal.

When placing the purse string suture with the straight needle, the ideal technique is to pass the needle directly through the substance of the dermal shelf for as long a pass as can easily be made, given the length of the needle. This is as opposed to taking intermittently spaced 'bites' around the periphery of the defect. Generally speaking, the fewer the passes, the better, as this means that most of the suture will be in contact with the dermal shelf and skip areas are minimized. In this fashion, any pleats or redundancies that form due to a mismatch in the circumference of the periareolar incision as compared to the areolar incision can be more evenly distributed over the entire periareolar

opening, which enhances the likelihood that postoperative scar contraction along the scar line will cause these pleats to settle. If an uneven distribution of the pleating is left uncorrected, an exaggerated bunching in one portion of the periareolar closure could lead to persistent wrinkling in the skin of the breast. It is not necessary to pass the needle back away from the skin edge and incorporate large 'bites' of dermis from the surrounding breast skin in the purse string closure. This technique simply creates unnecessary bunching of the skin edge once the purse string suture is cinched down, which can create permanent contour irregularities along the suture line. One added benefit of this technique is that the purse string suture is actually buried in the most inner portion of the dermal ledge under the areola as the areola is advanced to meet the skin incision around the periareolar opening. This suture/flap relationship protects the Gore-Tex and helps prevent postoperative exposure.

Once the purse string suture has been placed, the outer periareolar incision is cinched down to the desired diameter. The Gore-Tex suture is secured with 8–10 'throws' and the knot complex is buried under the dermal ledge. It should be noted that, if redundancy with pleating of the periareolar skin becomes evident, this pleating tends to become particularly prominent along the superomedial margin of the periareolar opening and the inferolateral margin tends to form more of a one-to-one length relationship with the areolar skin. By redistributing these pleats more evenly around the periphery of the closure, the likelihood that scar contracture will effectively minimize or even eliminate these pleats is enhanced. It is advisable to cinch the opening down to a smaller size than what ultimately is desired for two reasons. First, despite the positive effects of the purse string suture on maintaining the areolar diameter, a modest amount of areolar stretching almost always occurs postoperatively. By adding an element of overcorrection to the operative strategy, the effects of this postoperative spreading on the quality of the final result can be minimized. Second, if the shape of the areola is not round, a small additional amount of very superficial de-epithelialization can be performed as needed to make the periareolar defect round and this maneuver can enlarge the areolar diameter slightly. Care must be taken during this maneuver not to inadvertently cut the Gore-Tex suture. If the suture is cut, it is a simple matter to simply reinsert a new purse string suture; however, the stress dynamics of the new suture are invariably different from the first and the opening must frequently be modified with additional de-epithelialization to create a round areola. Once the purse string is in place and the defect has the proper shape, the areola is inset with 4–0 absorbable monofilament dermal sutures placed in a buried inverted, interrupted, fashion followed by a running subcuticular suture to complete the procedure (**Figure 5.20**).

Interlocking Gore-Tex suture technique Even with the described technical modifications, it is not at all unusual for some degree of postoperative spreading of the areola to occur. This can also be associated with distortion and asymmetry in the shape of the areola. The reason for this relates back to the marked ability of the areola to stretch under tension. Despite the placement of the supporting Gore-Tex purse string suture located deep within the dermis of the periareolar breast skin, it is possible for the areolar dermis to be pulled over the top of this supporting suture framework if the tension on the surrounding skin is great enough. When this happens, the more superficial elastic dermis

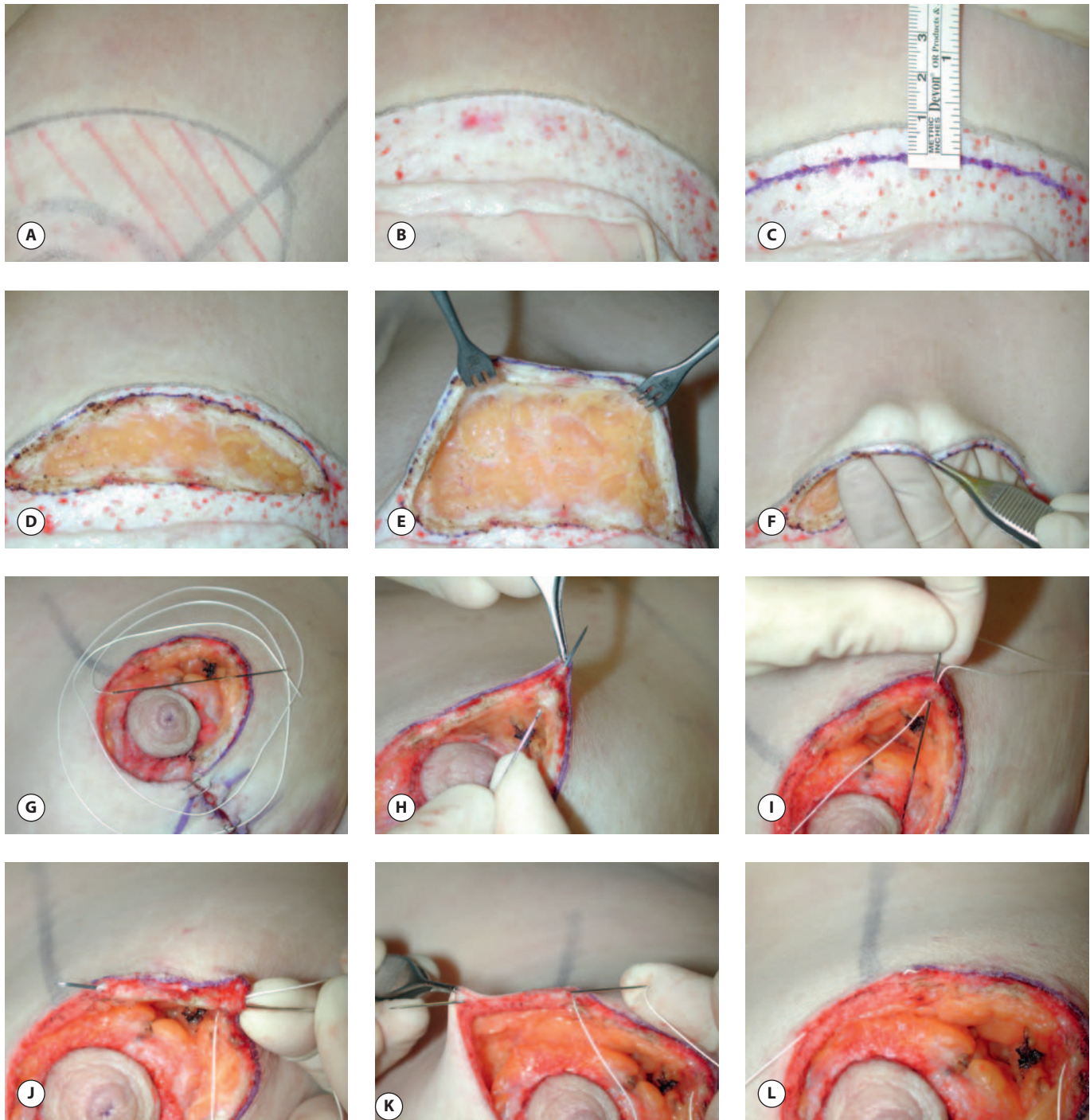


Figure 5.20 (A,B) Preoperative markings in preparation for periareolar mastopexy. The limits of the periareolar pattern are outlined (A) and the initial incision is carried only through the superficial dermis. The skin is then de-epithelialized to expose the deeper dermis of the peripheral margins of the periareolar pattern (B). (C,D) An incision line is marked in the de-epithelialized dermis 5–6 mm inside the outer periareolar incision (C) and the dermis is divided at that point, creating a shelf of dermis around the periphery of the periareolar defect (D). This shelf will eventually hold the purse string suture. (E,F) The dermal shelf is slightly undermined around the periphery of the periareolar defect just at the level of the dermis to allow the purse string suture to cinch down the circular defect without creating excessive tissue bunching. (G) A straight needle swedged onto the purse string suture material facilitates passage of the suture directly in the dermal shelf with a minimum of passes and a maximum of efficiency.

(H,I) The placement of the purse string suture begins by passing the needle from deep to superficial through the dermal shelf (H) and ends by passing the needle from superficial to deep (I). In this fashion, the fairly bulky knot complex that forms after the suture strands are tied together will pass easily under the dermal shelf, which effectively covers the knot and prevents subsequent exposure. (J) The straight needle is passed directly in the substance of the dermal shelf to position the suture within the firm support structure of the dermal edge. (K,L) The most efficient utilization of the purse string technique involves minimizing as much as possible any skip areas between 'bites' of the straight needle. By beginning each pass of the straight needle directly at the point where the previous pass ended (K), exposure of the suture strand is minimized (L) and the tension created when the purse string suture is cinched down will be evenly distributed around the entire circumference of the periareolar defect.

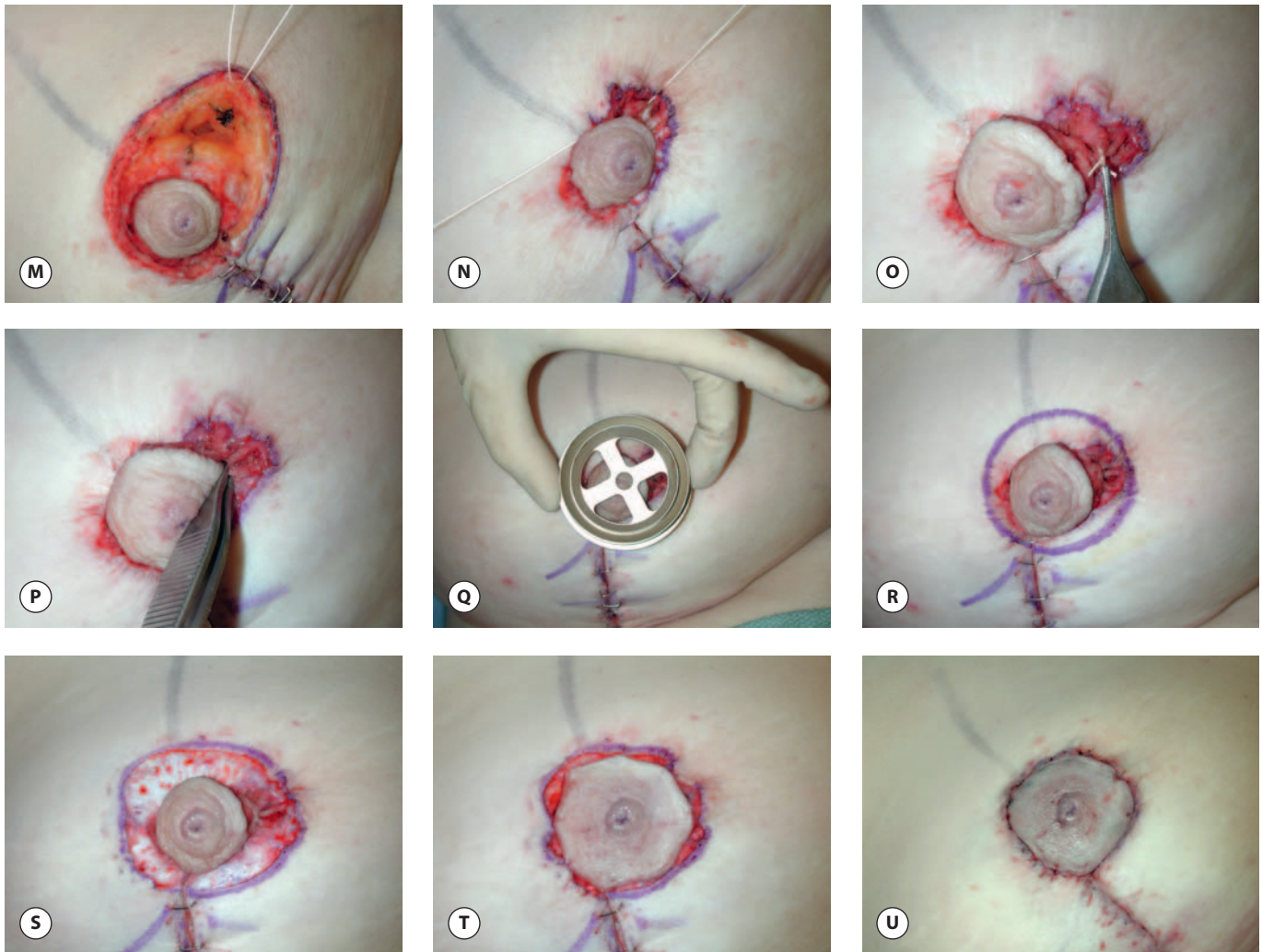


Figure 5.20 (Continued) (M,N) After the purse string suture has been securely placed in the architectural scaffold of the dermal shelf (M), the defect is cinched down by pulling on the free ends of the suture (N). It is at this point that Gore-Tex provides maximal benefit as the smooth and yet strong nature of the suture material allows it to slide easily through the dermal shelf without catching or bunching. The closing down of the periareolar opening is intentionally overdone slightly to allow for subsequent revision in an attempt to create a perfectly round areolar shape. (O,P) The suture ends are tied with 8–10 throws to prevent knot slippage (O). The knot complex is dabbed with betadine and then buried

under the dermal edge to prevent subsequent erosion with exposure of the knot (P). (Q,R) At this point, it is very common for the periareolar defect to be irregularly oval shaped. Therefore, the patient is placed upright to allow gravity to exert whatever effect it might have on the shape of the periareolar opening and a nipple marker is used to re-shape the defect into a perfect circle. (S,T,U) The additional skin areas are de-epithelialized with care taken to avoid cutting the Gore-Tex suture (S) and the areola is inset first with eight evenly spaced 4-0 absorbable monofilament interrupted sutures (T) followed by a running subcuticular suture to complete the procedure (U).

of the areola is pulled over the top the stable purse string support and a widened areola results (Figures 5.21, 5.22). In order better to secure the areola into the fixed periareolar opening, the interlocking Gore-Tex suture technique was developed. In this technique, all of the modifications described earlier are utilized, including the creation of a dermal shelf, undermining of the skin edges to ease the periareolar closure and use of the Gore-Tex suture on a straight needle to manage the periareolar defect. What differs is the manner in which the suture is placed. Before suture placement, eight evenly spaced orientation marks are placed on the outer diameter of the periareolar opening as well as the areola itself. By starting at the most medial point, the Gore-Tex is passed from deep to superficial through the dermal shelf. The suture is then directed over to the corresponding point

on the areola and a small bite of areolar dermis is incorporated in the stitch. The suture is directed back over to the dermal shelf and the needle is passed directly in the dermis until the next orientation mark is reached. Here, the needle goes back over to the corresponding point on the areolar dermis, again to incorporate a small bite of tissue. This process repeats until the suture has passed all the way around the defect, where the needle ends by passing from superficial to deep under the dermal shelf. The appearance of the pattern created by placing the suture in this fashion is one of a wagon wheel. Ideally, all the bites of dermis through the areola are equal and the spacing between the 'spokes' is even. By then pulling on the free suture ends, the Gore-Tex strand can be seen to slide smoothly through the fairly complex weave created by the pattern and the purse string is clinched

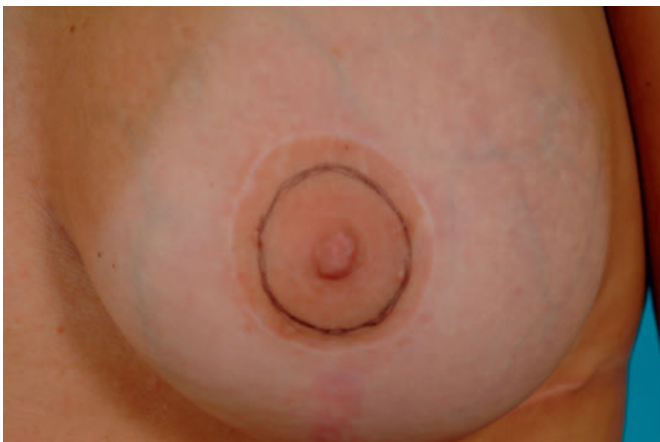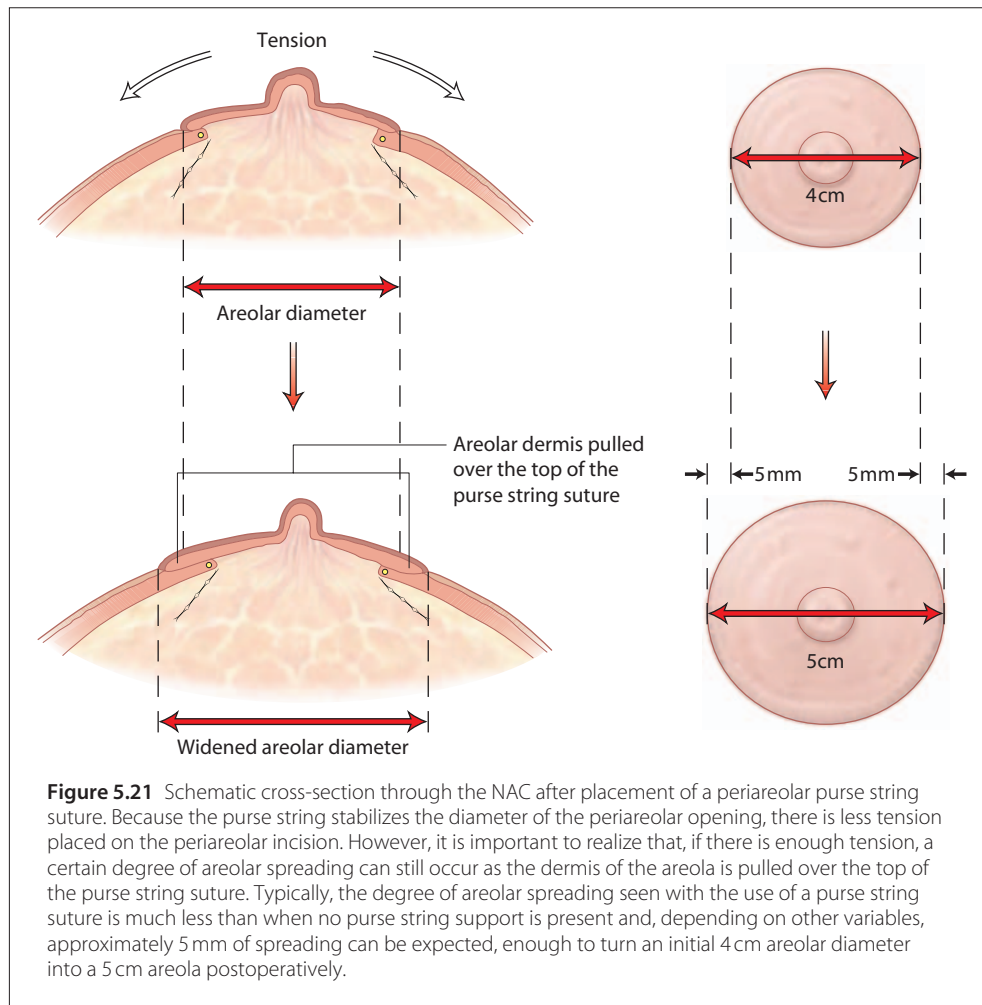


Figure 5.22 One-year postoperative result after placement of a periareolar Gore-Tex purse string suture. The suture can be palpated as an inner ring within the substance of the areola (black line) as a result of tension pulling the areola over the top of the purse string suture, creating a mild widening of the areola diameter.

down until the two unequal diameters are brought together. While a small amount of widening of the contracted areola contributes to the closure of the gap between the two diameters, it is mainly the outer periareolar incision that is cinched down

to close the wound. Because of the friction encountered by the Gore-Tex as it is passed through the extensive dermal framework of the periareolar dermal shelf and the areola, it holds without even the need to place a knot. Typically, the diameter of the periareolar opening is made smaller than intended and by using gentle manipulation, the size of the overcorrected areolar defect can be slowly massaged open to whatever diameter is desired. As before, 8–10 throws are placed to keep the knot from slipping and the knot complex is buried under the dermal shelf. The shape of the areola is then checked with the patient in the upright position and if it is not round, additional superficial de-epithelialization is performed at the appropriate margins of the breast skin flaps to create a round shape and the incision is then closed with a running subcuticular 4–0 absorbable monofilament to complete the closure. By interlocking the dermis of the areola into the periareolar closure using the same purse string suture as described, the tendency for the areolar dermis to be pulled over the purse string is held in check. As a result, a more stable distribution of forces is created that tends to resist areolar spreading postoperatively (**Figures 5.23–5.25**).

While this technique has been used successfully in primary periareolar cases, where the results have been particularly dramatic is in secondary revisions where patients have presented with widened areolar diameters after an initial periareolar procedure. Despite the presence of, at times, dramatically enlarged

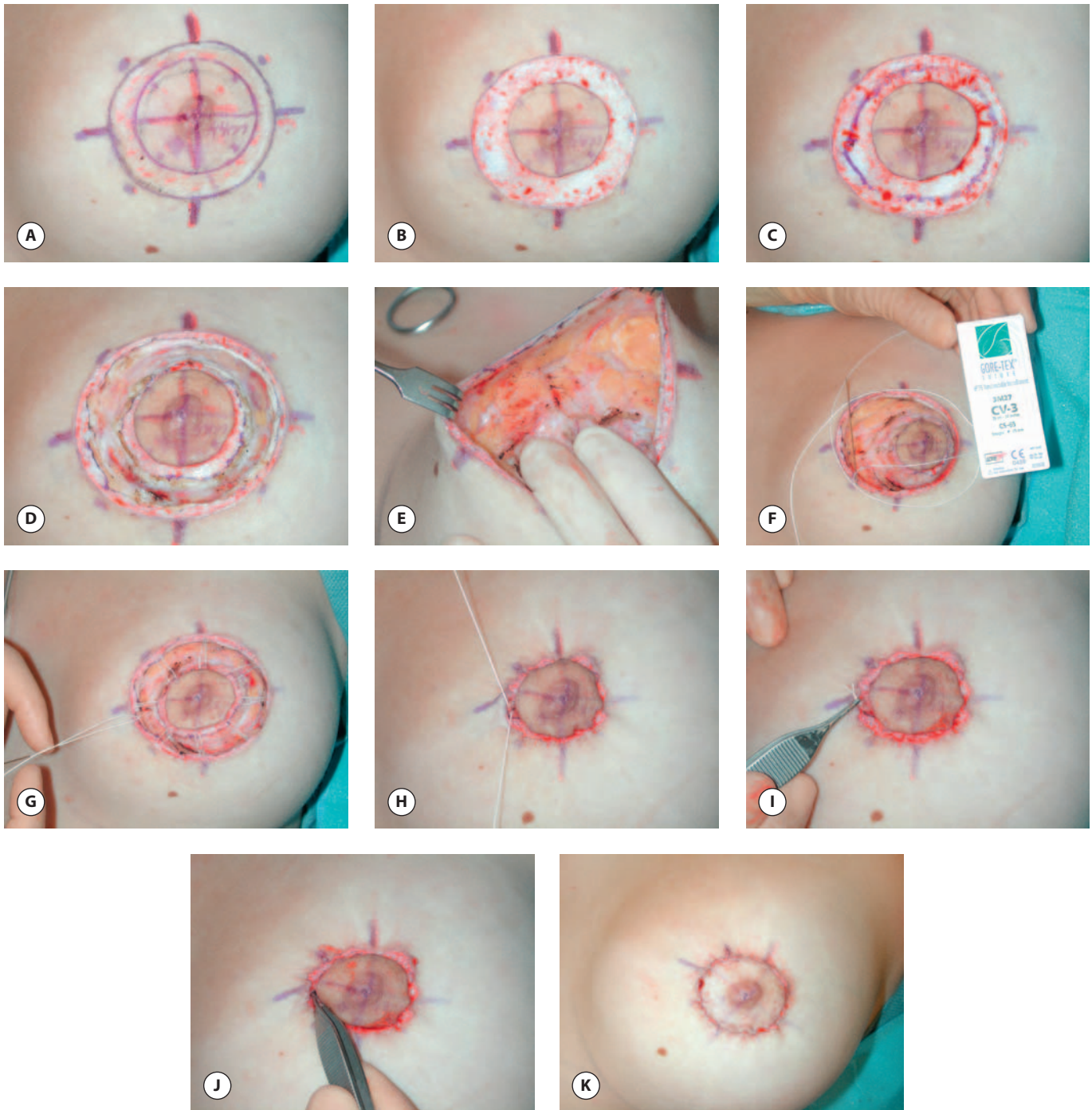
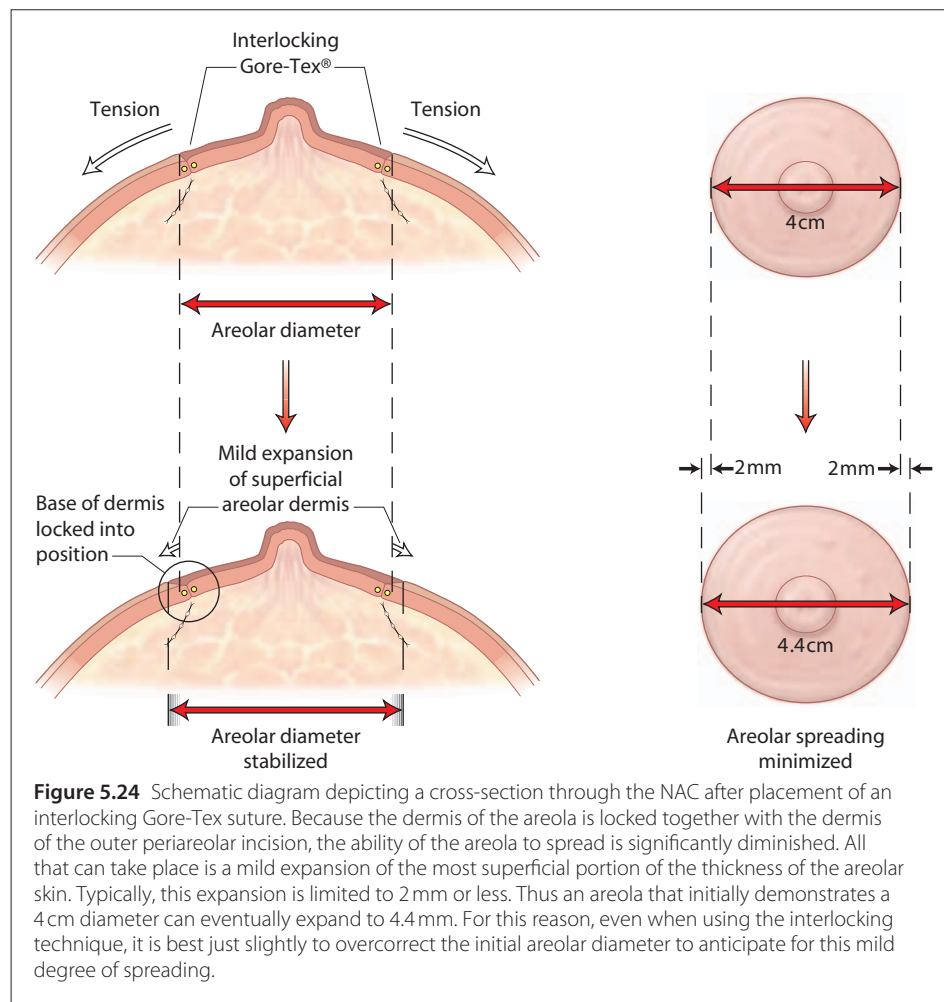


Figure 5.23 (A) Preoperative markings in preparation for application of the interlocking Gore-Tex suture technique in a 20-year-old patient who presents for revision of a widened areolar diameter after previous periareolar surgery. A 44 mm areolar incision is marked with the areola under stretch while the outer incision is diagrammed to be just outside the existing widened areola. Eight evenly spaced cardinal points are marked on both the inner areolar diameter and the outer periareolar incision. These marks will guide subsequent suture placement to ensure even cinching up of the disparate periareolar diameters. (B) The incisions are made extending just into the superficial dermis and the area between the two circular incisions is de-epithelialized. (C,D) The dermis is divided approximately 5 mm inside the outer periareolar incision such that a small dermal shelf is constructed that will eventually hold the interlocking purse string suture. (E) The surrounding breast flaps are undermined at a level just under the dermis for a distance of 1–2 cm away from the incision

edge to allow the outer periareolar incision to be cinched down without creating tissue crowding and distortion of the periareolar closure. (F) When applying the interlocking technique, the optimal suture material to use is Gore-Tex. The suture is strong, permanent and slides through the complex interlocking weave without difficulty, a fact that facilitates precise control of the shape and dimension of the periareolar closure. In this case, a CV-3 size suture was used swedged onto a CS 65 straight needle. (G) Appearance of the interlocking weave after placement of the Gore-Tex suture. (H) The suture is cinched down by pulling the two free ends until the desired areolar diameter is created. (I,J) After securing the suture ends with 8 to 10 square knots, the fairly substantial knot complex is buried under the skin edge to eliminate the risk for subsequent exposure. (K) Final appearance of the areola after closure of the wound with a running subcuticular 4–0 absorbable monofilament suture.



areolar diameters, a small, circular and stable areolar size and shape have been restored using this technique.

Areolar herniation The skin of the areola has a greater elasticity than the surrounding breast skin. Also, the fascial support structure of the breast is greatly attenuated to absent in the area under the areola. As a result, pressure from the underlying breast volume can stretch the skin of the areola to a greater degree than the skin of the breast (Figure 5.26). This difference in skin elasticity leads to the third technical concept of periareolar surgery, namely that *when performing skin envelope reducing procedures that increase the pressure being placed on the breast parenchyma, the differing elasticities between the breast skin and areola can result in an exaggerated bulging or 'herniation' of the areola. This tendency for the areola to herniate can be overcome by making the initial areolar incision small enough to create a trampoline effect on the areola when it is inset into the periareolar defect. By slightly increasing the pressure on the areola, the tendency to bulge or herniate is reduced.* Because the periareolar diameter is stabilized by the purse string suture, the effect of the tension created by inseting the areola into the periareolar defect is confined to the areola alone and is more or less separate from the surrounding breast skin. In this fashion, the tension on the more elastic areola can be adjusted separate from the tension

on the surrounding breast skin such that there is no elasticity differential between the two. The result is that pressure from below cannot be differentially expressed through the areola and the tendency to herniate is reduced. Occasionally, areolar herniation is noted early in the postoperative recovery period when none was noted at the time of surgery. This is because temporary swelling in the breast has caused the more elastic areola to stretch in relation to the surrounding breast skin. When the swelling subsides, the areolar herniation will recede. Also, if areolar herniation is persistent after the swelling resolves, it does tend to improve over time as the entire skin envelope of the breast as well as the areolar skin accommodates to its new size and shape. When areolar herniation is noted at the time of surgery, simply reducing the diameter of the areola and re-insetting it into the periareolar defect will usually correct the problem. It must be remembered, however, that, in each circumstance, management of areolar herniation depends upon a strong and stable purse string support of the periareolar closure.

Using these technical modifications, it is possible to reliably control the shape, diameter and position of the areola in periareolar surgery. Of course, it is important to realize that, even with these modifications, the positive effect of the purse string suture technique can be overcome. There is a limit to the size of the periareolar opening beyond which the quality of the overall

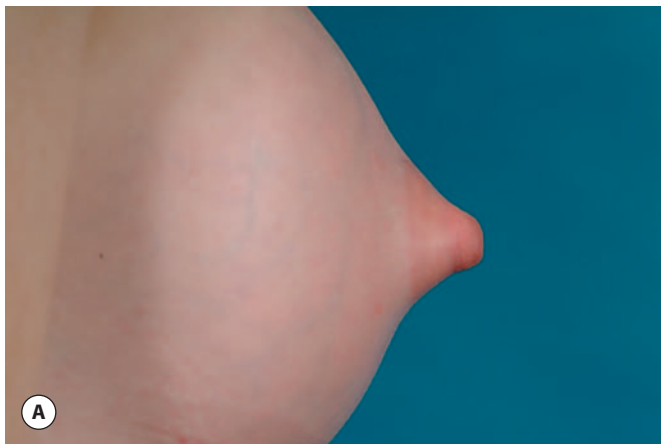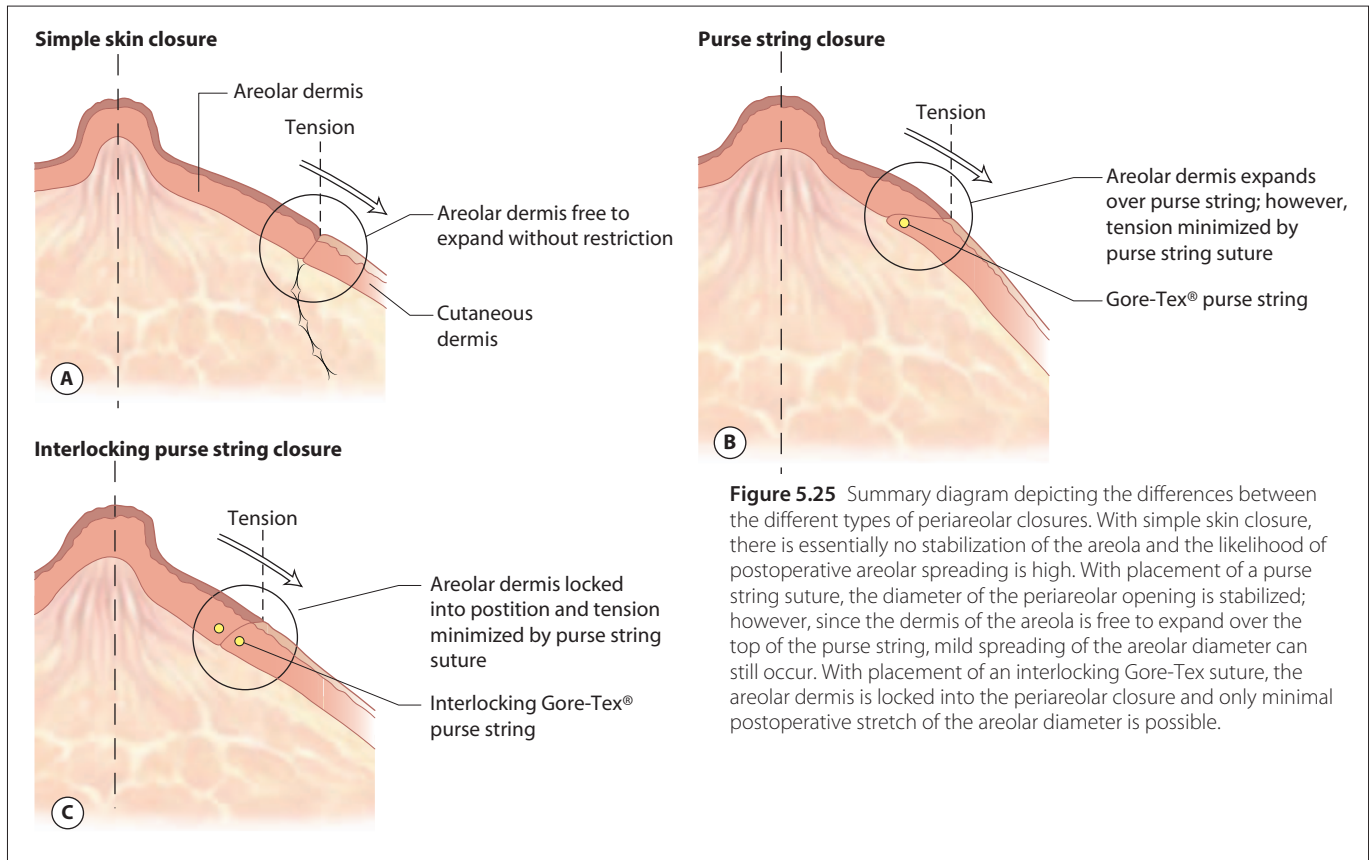
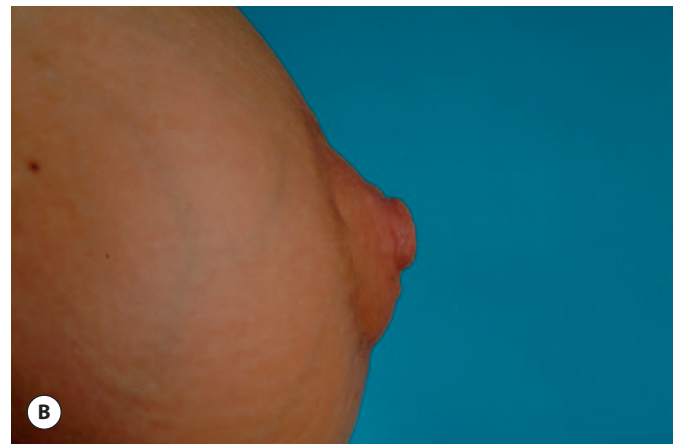


Figure 5.26 (A) Lateral close-up view of the NAC after breast augmentation. As a result of the lack of fascial support to the underside of the areola coupled with the pronounced elasticity of the areolar skin, there is herniation of the breast parenchyma through the area of the areola due to the pressure created by the mass effect of the implant and the native



breast volume. **(B)** Lateral close up view of the NAC after augmentation mastopexy. Here as well, pressure created by the mass effect of the implant combined with the native breast parenchyma is manifested as herniation through the area of the areola.

result becomes compromised. When the diameter of the outer periareolar incision exceeds 10cm, depending on the elasticity of the tissues, complications such as persistent pleating around the areolar closure, widened areolar scars, postoperative areolar spreading with shape distortion and purse string suture

failure become increasingly more likely. Also, breakage of the purse string closure can result in sudden spreading of the areolar diameter. If scar stabilization of the periareolar closure is strong enough, the tendency for subsequent areolar spreading can be minimized. In most instances, however, the described technical

modifications can enhance the reliability and dependability of periareolar surgery in mastopexy.

Managing the Skin Envelope

The skin envelope becomes problematic in mastopexy patients for two reasons.

Not only is there usually an excess of skin in relation to the volume of the breast, but the elasticity of the skin, or the ability of the skin to rebound after a stress is placed on it, is reduced. The result is a stretched-out underfilled skin envelope that provides inadequate support for underlying fat and parenchyma. For this reason, the operative strategy of any mastopexy procedure must include an effective management of the redundant and ptotic skin envelope. While this goal seems simple enough, other factors come into play when designing a skin envelope strategy. Certainly, the resulting scar pattern in the skin is a major consideration for these patients who are undergoing an aesthetic procedure and limiting the scar to the most minimal pattern possible is a required element of any operative strategy. Also, the postoperative changes that can take place must be taken into account as sufficient recurrent stretching of the skin can occur so as to have a deleterious effect on the quality of the aesthetic result. For this reason, the skin management plan ideally should provide for easy revision should this become necessary in the future. Finally, whatever skin pattern is used, it must provide for lifting of the NAC to correct NAC ptosis and allow parenchymal reshaping to be performed as needed to correct volume ptosis, all without compromising the blood supply to the NAC or the skin flaps. To accomplish these tasks, there are three standard approaches to managing the redundant skin in mastopexy.

Periareolar As discussed previously, periareolar approaches can be utilized with great success to lift the position of the NAC. However, periareolar techniques are much more effective in lifting the NAC than they are at reducing the skin envelope. This is because, when increasing amounts of periareolar skin are removed, not from just above the NAC, but from around the periphery of the areola, the shape of the breast becomes adversely affected as the projection decreases and breast begins to demonstrate a flattened appearance with rounding out of the lower pole of the breast. Generally, when the NAC is lifted more than 3 cm, flattening of the breast projection will begin to develop. The point at which periareolar skin reduction begins to compromise breast aesthetics varies depending on other factors including the size of the breast, the degree of ptosis, the amount of skin laxity, the body habitus of the patient and the nature of any underlying reshaping techniques that are used. Generally speaking, however, as more skin is removed, the degree of deformity becomes more noticeable. For this reason, it is best to utilize a periareolar approach for patients who primarily require a lift of the position of the NAC with only a minimal amount of skin resection.

The technique is simply an extension of the other periareolar techniques described previously. The top of the periareolar pattern is estimated by grasping the superior aspect of the inferiorly malpositioned areola and manually lifting it to a new position higher on the breast mound until it appears to be located at the proposed point of maximal projection of the breast. This point is marked as is the inferior aspect of the areola skin junction with the breast skin. A curved line is then drawn

communicating these two points both medially and laterally. In shorter patients with just a modest amount of NAC ptosis, the resulting pattern tends to be more circular. This is an advantage as the circular periareolar pattern matches well with the perfectly circular areolar incision to create a round areola after the intervening skin has been removed and the purse string suture is cinched down. In taller patients, patients with a more ptotic NAC, or in patients with an excessive degree of skin laxity, the resulting pattern becomes more of an oval shape. In these patients, it is generally necessary to adjust the de-epithelialized skin margins after placement of the purse string suture to obtain a round areola.

All of the technical steps described previously apply to periareolar mastopexy. However, one additional technical point merits emphasis when dealing with larger periareolar openings. As the dimensions of the periareolar opening begin to exceed 10 cm in diameter, the pleating that forms as the outer periareolar incision is cinched down to the diameter of the inner areola can be significant, making subsequent placement of the subcuticular suture difficult. To help evenly distribute the discrepancy between the circumferences of the two incisions, a modified subcuticular closure technique is used. Here, instead of taking evenly spaced 'bites' of dermis on either side of the incision as would be done with a wound where the two incision lengths are even, the length of dermis incorporated in a single pass of the needle through the dermal shelf of the outer periareolar incision is greater than in the inner areolar incision. One fairly straightforward way to accomplish this is by placing a horizontal mattress bite in the outer incision and a vertical mattress bite in the inner incision. By gradually working this inequality in the amount of tissue incorporated in each pass of the needle around the entire perimeter of the defect, even large differences in areolar diameter can be effectively taken up ([Figure 5.27](#)). As the powerful forces of wound contracture subsequently come into play, these pleats then settle significantly over time. In modest size defects, all that is left after full healing occurs is often just a minor skin irregularity noted at the margin of the periareolar skin with the incision. However, for larger defects, the pleating in the skin edge, even after full healing has occurred, can create a noticeable and persistent wrinkle, particularly in the superomedial margin of the incision ([Figure 5.28](#)). For these reasons, periareolar management of the redundant skin envelope in mastopexy can be effectively used up to a variable but identifiable limit. When problems regarding the shape of the breast, the shape or size of the areola or the quality of the periareolar scar begin to become noticeable, alternative techniques must be used to obtain the optimal result.

Circumvertical The circumvertical skin pattern is the most powerful and versatile skin reduction technique available for use not only in mastopexy, but in augmentation mastopexy and breast reduction as well. The technique can be thought of as simply adding a vertical component to a periareolar skin pattern. For smaller skin redundancies, the vertical component is truly vertical and simply extends straight down to the inframammary fold. For larger cases, the lower portion of the vertical plication turns laterally along the inframammary fold as the redundant skin is taken up. In every instance, however, the pattern is considered to be circumvertical. The tremendous advantage afforded by adding the vertical component is twofold. First, by removing a segment of skin from the underside of the breast that communicates with the periareolar incision, the dimensions

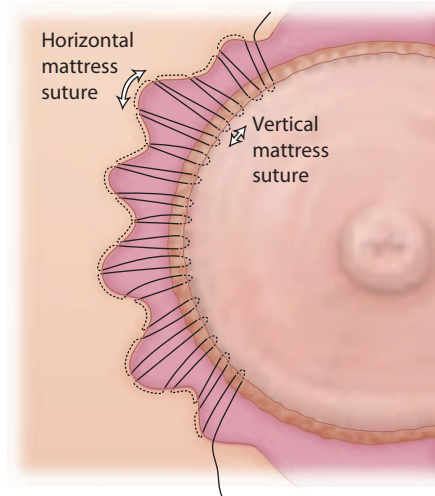


Figure 5.27 Schematic diagram demonstrating the suture technique used for closure after periareolar mastopexy. As a result of the differing dimensions of the larger diameter outer periareolar incision versus the smaller diameter of the inner areolar incision, a redundancy in the outer skin edge is present after placement of the purse string suture. This inequality in incision length is gradually and evenly equalized during final wound closure with the placement of a running subcuticular suture using a horizontal mattress technique in the outer skin edge and a corresponding vertical technique in the inner areolar edge. In this fashion, the pleating that results after final wound closure is distributed as evenly as possible thus creating the best chance for a smooth and well-healed periareolar scar.

of the periareolar defect are reduced, which creates a much more manageable periareolar opening (**Figure 5.29**). Therefore, in patients who were perhaps at risk for compromised periareolar aesthetics due to the large size of the periareolar incision, the postoperative finding of a widened or distorted areola with an unattractive periareolar scar is significantly reduced. Second, the plicating maneuver of removing skin from the inferior pole of the breast is a powerful shaping technique. Tightening the skin in this fashion not only reduces the skin envelope but also

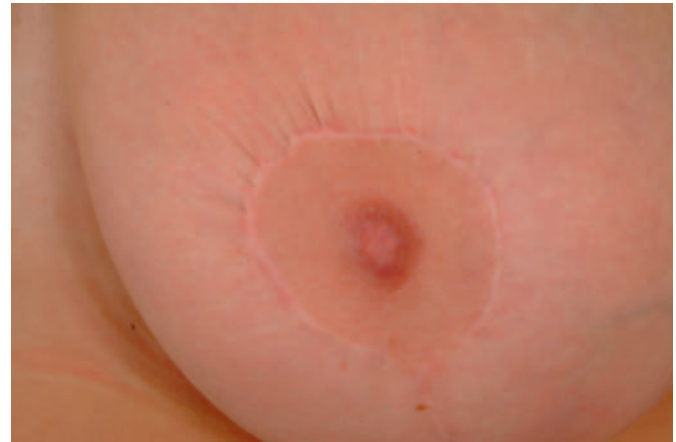

Figure 5.28 After periareolar lifting procedures, persistent pleating particularly at the superomedial aspect of the areola can be seen after purse string closure of larger periareolar defects.

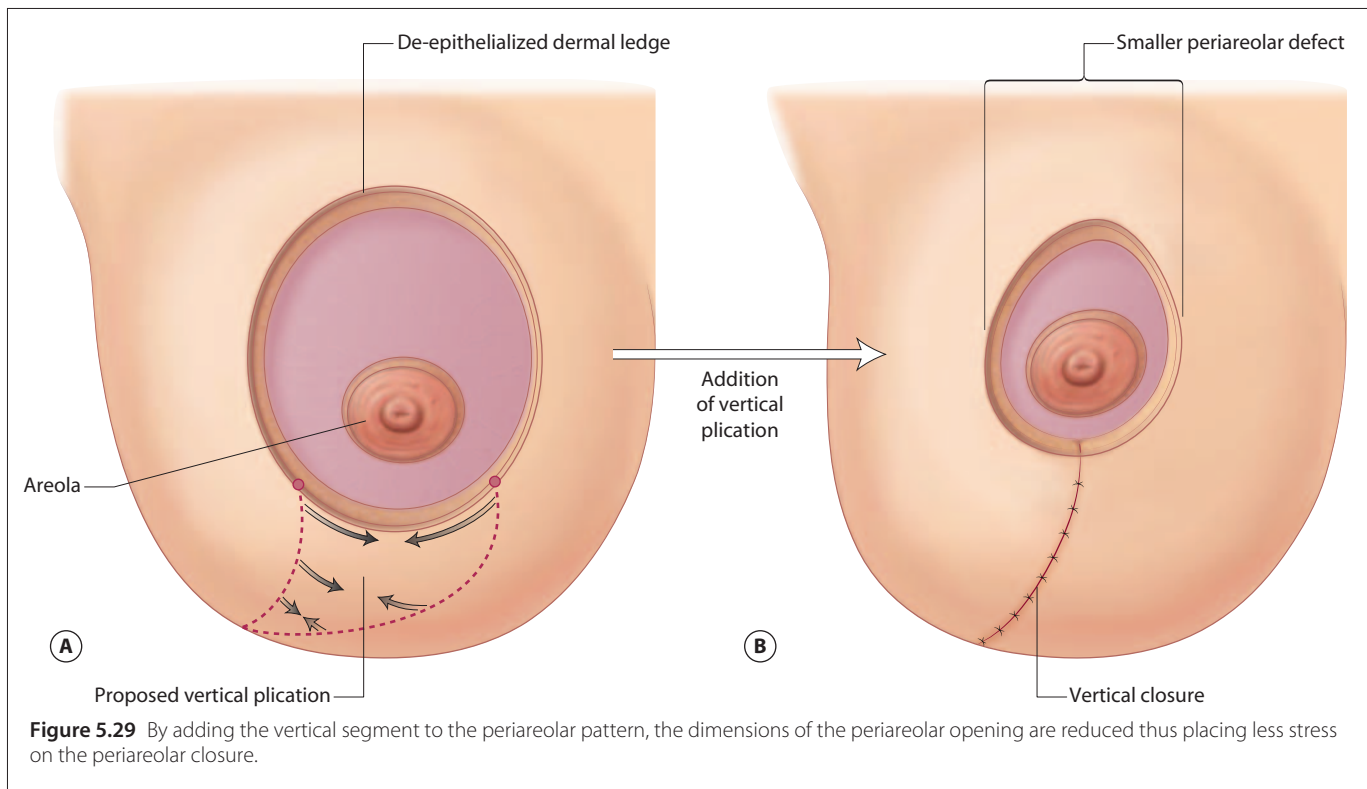


Figure 5.29 By adding the vertical segment to the periareolar pattern, the dimensions of the periareolar opening are reduced thus placing less stress on the periareolar closure.

slightly lifts the NAC and increases the projection of the breast, while at the same time narrowing the breast base diameter. Also, any tendency for the periareolar component to flatten the breast contour is generally more than offset by the addition of a vertical segment to the pattern. The only drawback to the addition of a vertical segment relates to the presence of the additional scar that runs down the front of the breast from the inferior portion of the areola down to the inframammary fold. However, this unavoidable disadvantage must be viewed in the context of what is achieved by adding the vertical component. Typically, the vertical scar heals in an imperceptible fashion and is the most inconspicuous of all the standard scar locations used in breast surgery today. Therefore, when assessing the positive effects adding a vertical component can have on the shape of the breast and the overall quality of the aesthetic result, the vertical scar is nearly always a reasonable tradeoff in achieving the optimal result. For this reason, if the addition of a vertical component is deemed to improve the aesthetic result even slightly, it is highly advisable to add it to the overall pattern. For the vast majority of patients, optimizing shape at the expense of the additional vertical scar is well accepted as a necessary strategy to provide the optimal result (Figure 5.30).

Inverted T Historically, the most commonly used technique for managing the redundant skin envelope in mastopexy was the Wise pattern inverted T approach. As a result, it is this technique against which all other 'short scar' techniques are measured in terms of results and complications. Here, the apex of the inverted T is located by transposing the inframammary fold anteriorly onto the breast by placing the fingers of the left hand under the breast and palpating with the right hand where the tips of the fingers could be felt. An angled inverted V pattern is then drawn from this point downward, skirting the medial and lateral margins of the areola with the lengths of these two limbs being 5–7 cm long. A medial and lateral extension is then drawn as needed to meet a similar line drawn directly in the inframammary fold. The strategy of this marking pattern is to keep the inframammary component of the incision as short as possible to appropriately take up any redundancy in the skin pattern and yet not leave behind a 'dog ear' at either the medial or lateral end of the incision. After the breast is re-shaped, the areola is then inset into a matching defect created by removing a circular segment of skin at the apex of the vertical incision (Figure 5.31). The advantage afforded by this technique relates to the ease with which the skin envelope can be reduced as even large skin redundancies can be managed without difficulty. Because of the manner in which the pattern is designed, there is a more or less 1:1 relationship in the lengths of the corresponding skin incisions, which eases closure and prevents any of the pleating or skin redundancy that can be noted with periareolar or circumvertical techniques. Because of the familiarity many surgeons have with the inverted T technique along with the directness of the skin closure, this pattern remains a popular choice for mastopexy.

It must be noted that the major drawback associated with the Wise pattern technique is the presence of the inframammary scar. For patients who are approaching their mastopexy procedure with an aesthetic mindset, the presence of this

scar can be quite objectionable and many patients who are otherwise excellent candidates for a breast-lifting procedure will decline based on concerns related to the scar. Therefore, although the pattern is well suited for the treatment of macromastia where the dimensions of the skin envelope tend to be more substantial, in my opinion, this skin management strategy is overly aggressive when applied to mastopexy. The same goals can be reached using periareolar and circumvertical techniques with a reduced scar burden for the patient. For this reason, the inverted T skin pattern is used only in special circumstances where previous scars or other sequelae from previous surgery make short scar techniques less predictable.

Breast Reshaping

Conceptually, previous attempts at mastopexy have focused on taking up the redundant skin envelope and lifting the position of the NAC. Shape was created as a by-product of the skin envelope management strategy with the result being directly related to the inherent elasticity of the patient's tissues. For instance, when the inverted T pattern is used in mastopexy, the shape of the breast is built into the surgical strategy by the way the skin is managed. The vertical portion narrows the breast slightly while the horizontal component shortens and lifts the breast. In essence, the shape of the breast is determined by the pattern of the skin resection and how the remaining skin wraps around the breast parenchyma. However, it has long been recognized that relying on the skin to support the breast shape is a strategy that can ultimately fail for many patients due to the fact that, as the skin stretches, the breast parenchyma becomes ptotic once again and the upper pole develops a concavity (Figure 5.32). For this reason, many surgeons have advocated an 'overcorrection' in the shape of the breast at the time of the initial procedure in an attempt to compensate for these potential postoperative changes. Such compensation is variably successful and maintenance of long-term breast shape after mastopexy remains as one of the primary, and perhaps one of the most elusive, goals of any mastopexy procedure. For this reason, several different shaping strategies have been developed in an attempt to shape the breast more directly and improve the results of mastopexy. Although numerous specific techniques have been described, they can be summarized into one of several different approaches including suture fixation of the breast parenchyma, suture fixation of various internal pedicle flaps or dermal flaps, or the use of an artificial mesh to wrap around and support the breast.

Suture fixation of breast parenchyma In breast ptosis, the internal connective tissue scaffold of the breast is generally very lax. Therefore, even when the skin envelope is tightened, there is little internal support of the breast parenchyma. As a result, when the breast skin inevitably relaxes postoperatively, there is no restraining force to help maintain breast shape and the breast sags. In an attempt to reconstruct the stretched-out supporting framework of the breast such that it complements the tightened skin envelope and therefore helps create a more aesthetic and long-lasting breast shape, various types of parenchymal plication strategies have been developed. All of these strategies have as their goal a tightened and firmer breast mound that will withstand the test

of time as the soft tissues relax postoperatively. When using this technique, any skin pattern can be used to address the redundant skin envelope. Once the initial skin incisions are made, the skin envelope is elevated away from the underlying breast parenchyma at a level that would normally be considered mastectomy flap thickness. This will be more easily done

when using an inverted T or circumvertical pattern; however, it is possible to use a periareolar pattern as well, although exposure will be somewhat limited using this approach. It is important to elevate the skin flaps all the way to the periphery of the breast to release the tethered skin completely away from the breast parenchyma. If this is not done, distortions created

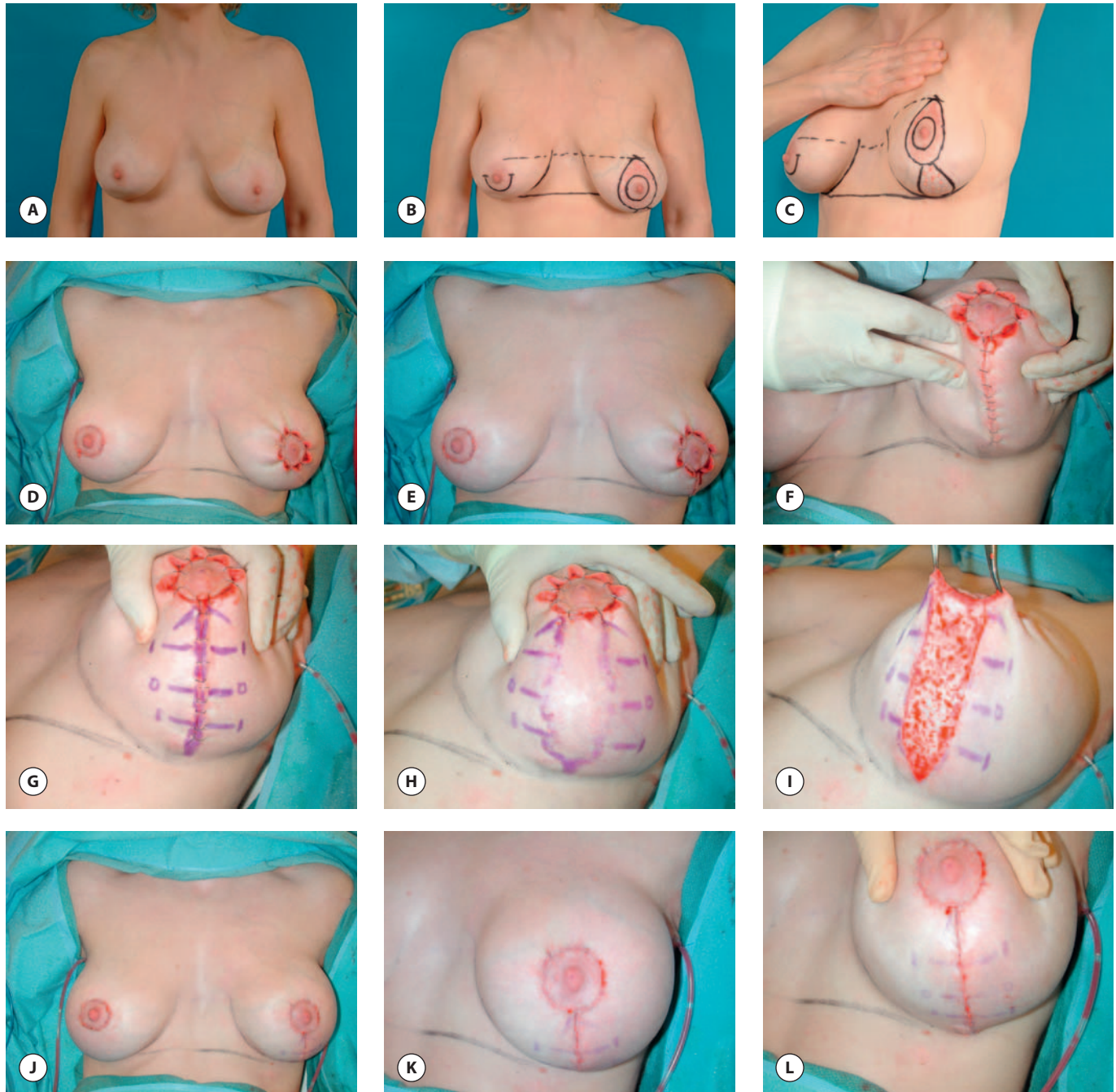


Figure 5.30 (A) Preoperative appearance of a patient who presents with left-sided recurrent ptosis and widening of the areola after primary augmentation mastopexy. (B,C) Preoperative markings in preparation for combined periareolar revision along with vertical plication of the lower pole of the breast. (D) After periareolar revision alone, the lower pole of the breast appears excessively rounded and the apex of the breast is flattened due to the forces created by the periareolar closure. (E) With addition of

the vertical segment, the base diameter of the breast is narrowed and the overly ptotic lower pole is lifted to provide better symmetry with the opposite side. (F-I) After the redundant lower pole skin is plicated to good effect, the area is marked, the staples removed and the intervening skin is de-epithelialized. (J-L) After final closure, the breast is lifted, the areola is smaller and the vertical plication line extends down to the inframammary fold but not beyond.

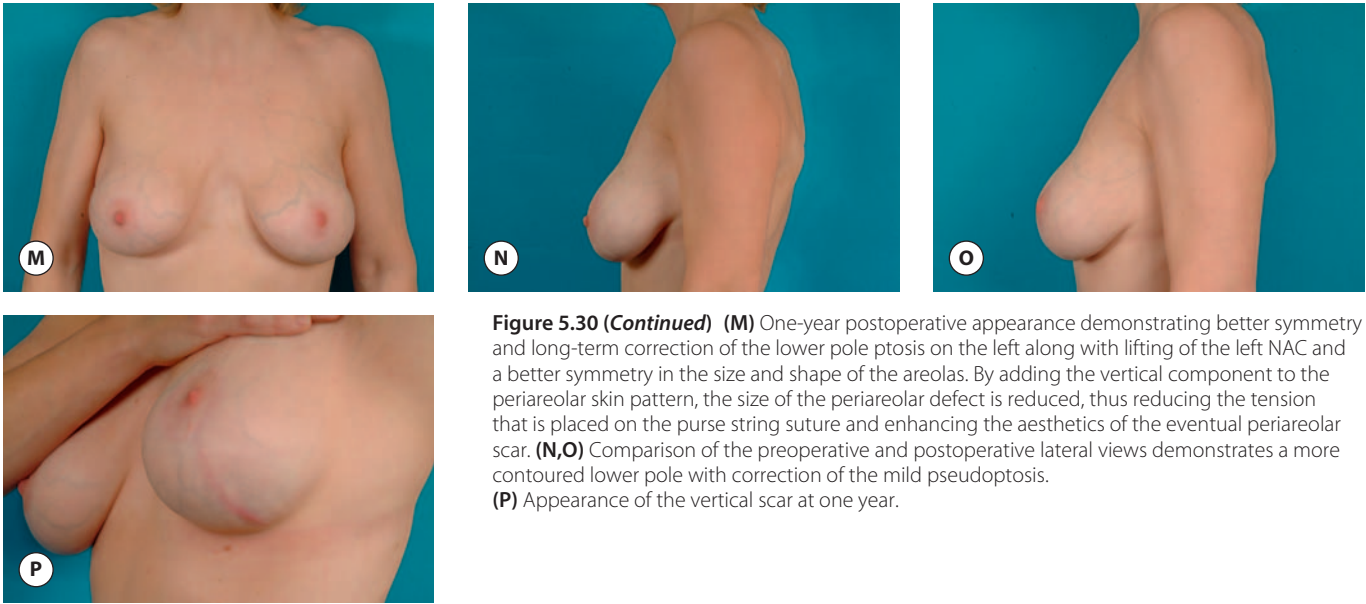
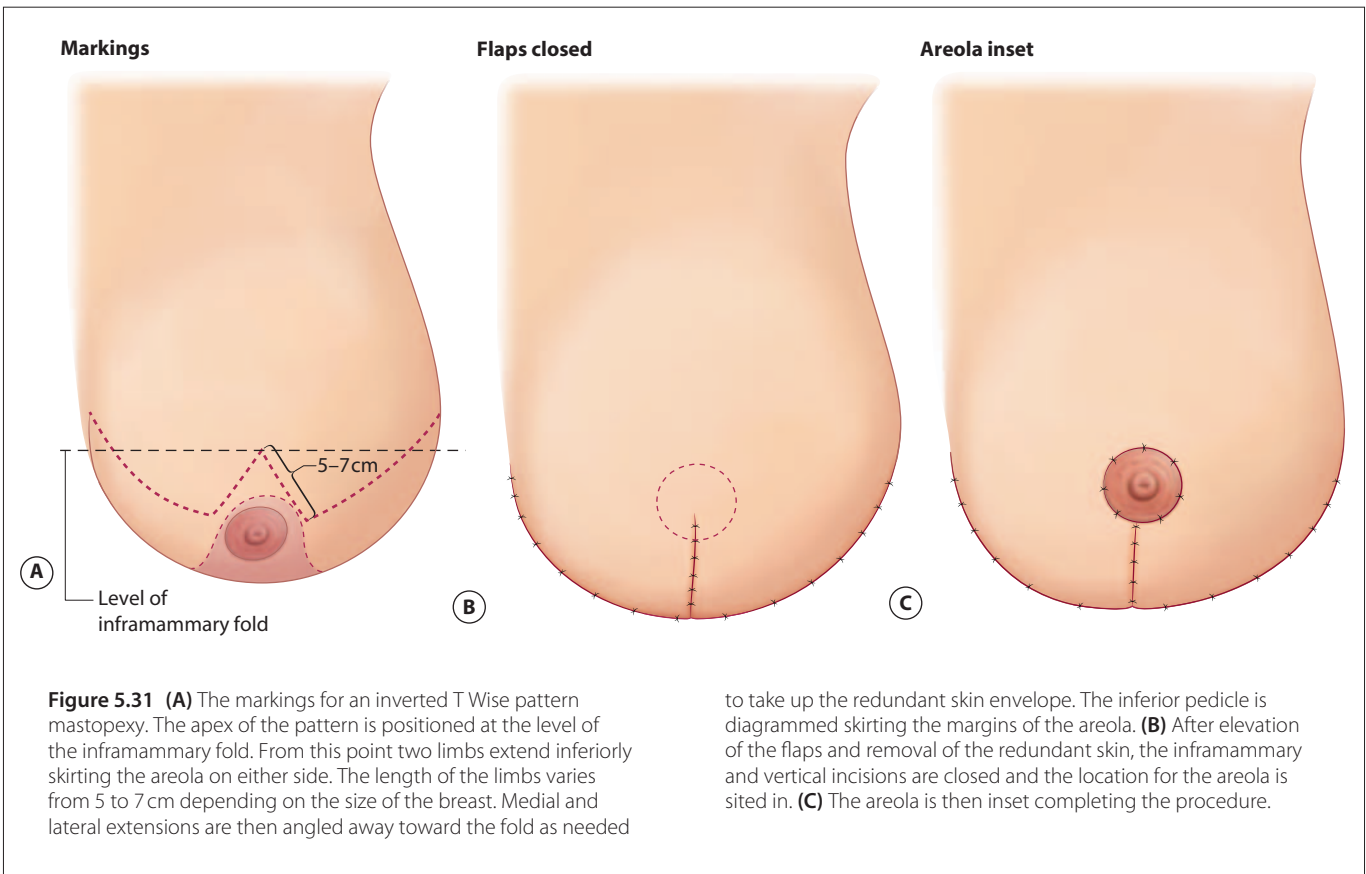


Figure 5.30 (Continued) (M) One-year postoperative appearance demonstrating better symmetry and long-term correction of the lower pole ptosis on the left along with lifting of the left NAC and a better symmetry in the size and shape of the areolas. By adding the vertical component to the periareolar skin pattern, the size of the periareolar defect is reduced, thus reducing the tension that is placed on the purse string suture and enhancing the aesthetics of the eventual periareolar scar. (N,O) Comparison of the preoperative and postoperative lateral views demonstrates a more contoured lower pole with correction of the mild pseudoptosis. (P) Appearance of the vertical scar at one year.



by the plication of the breast parenchyma may become visible through the skin envelope postoperatively. Once the flaps have been developed, the breast parenchyma can be suture plicated to restore a more youthful, full and firmer appearance. Plication begins in the upper half of the breast first by imbricating the superior pole parenchyma upon itself. This serves to lift the

position of the NAC and corrects any concavity present preoperatively in the upper pole of the breast. Once this contour is reset, a vertical plication line is run from the bottom of the areola down to the inframammary fold (IMF). This serves to narrow the width of the breast and increases the projection of the breast mound (Figure 5.33). Together, these two plication strategies

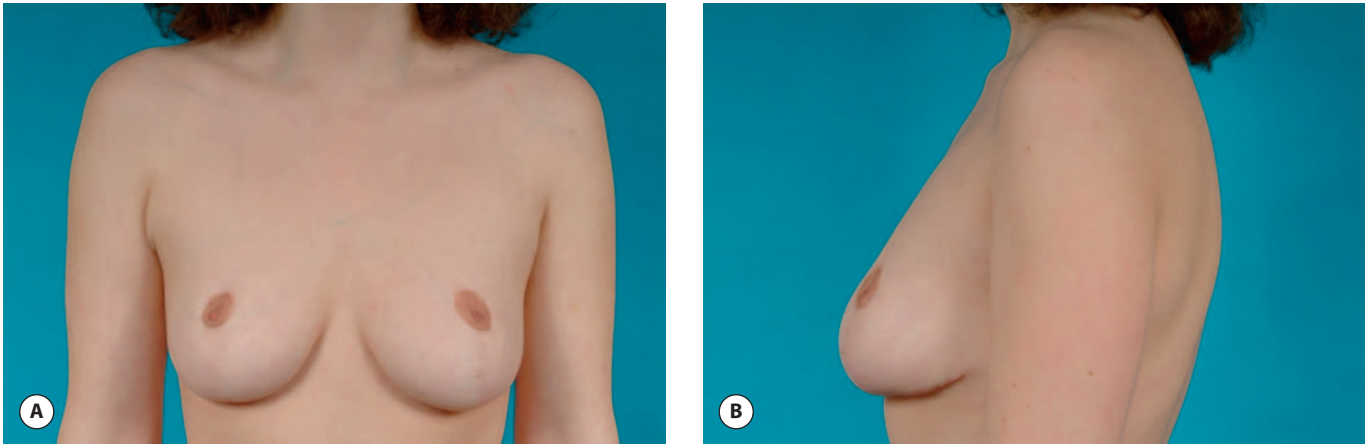


Figure 5.32 (A,B) Five-year postoperative appearance of a patient after undergoing inverted T pattern mastopexy. Due to stretching of the skin of the lower pole along with relaxation of the soft tissue support structure of the breast, most of the volume of the breast has descended inferiorly, creating a pseudoptotic appearance with a high-riding NAC. The drag of

the inferiorly malpositioned volume can be seen as it pulls on the fixed position of the areola. In this case, the pull of the breast parenchyma on the areola is so great that the shape of the areola is one of an elongated oval with the inferior edge of the areola being buckled and almost pulled under the fixed inferior skin edge of the NAC scar.

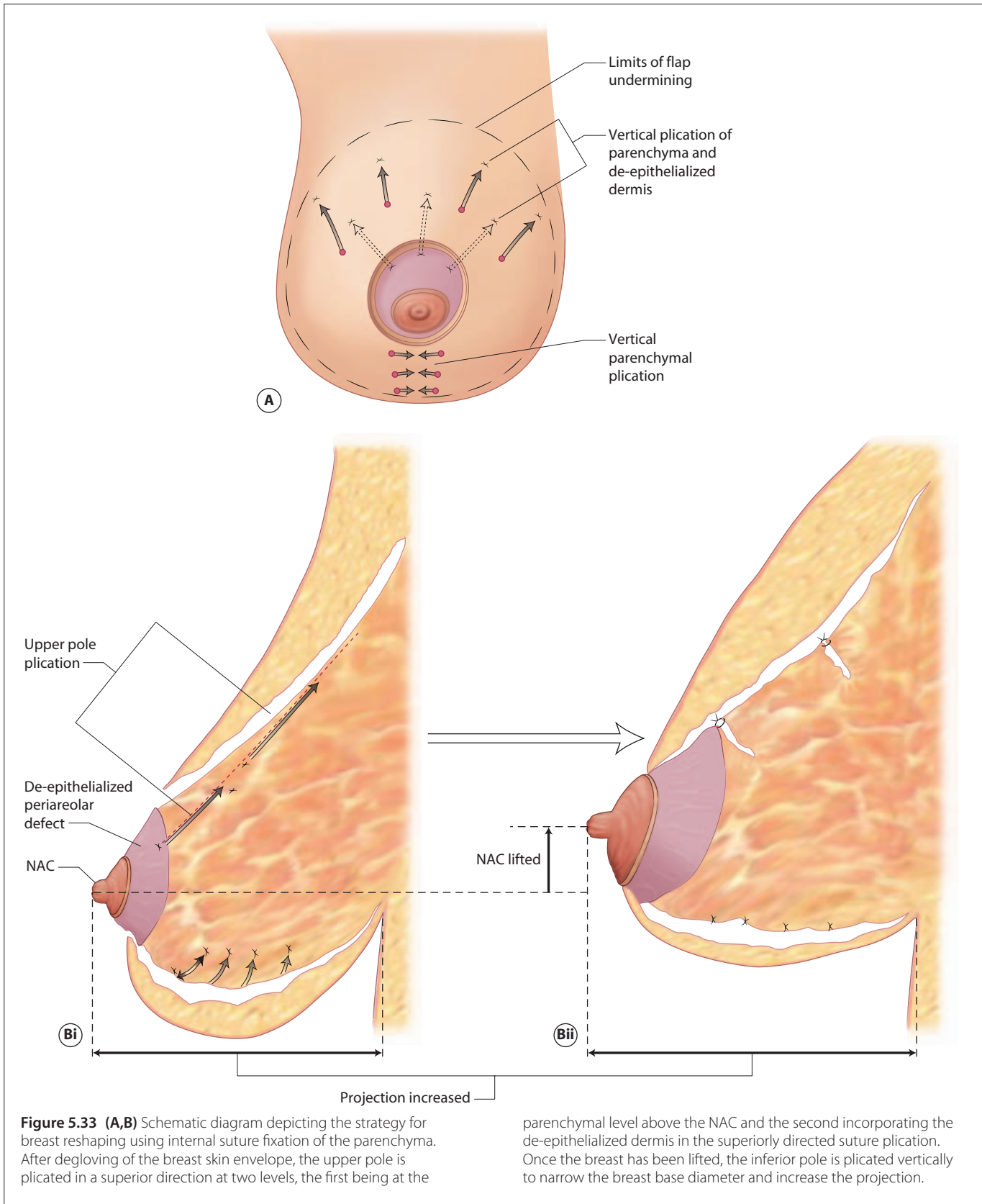
will serve to reduce the effective surface area of the breast mound. As a result, the existing breast volume is redistributed in a more confined space, which results in a firmer and more uplifted appearance to the breast. It may be advisable to use 3–0 non-absorbable monofilament (Prolene) suture for this plication to avoid any possibility that early hydrolysis of an absorbable suture could lead to loss of parenchymal support before scar tissue has sufficiently developed to hold the shape. Once the breast is reshaped, the skin envelope is tailored to wrap around the newly formed breast in a way which complements the reduced breast surface area. When using this parenchymal plication strategy, it is important to note that the end result must be overcorrected as a certain amount of postoperative settling will occur. Also, because the effective surface area of the breast is being reduced, the breast will likely appear smaller to the patient, even though no tissue other than skin is removed. Given the wide area of dissection, it is advisable to use a drain postoperatively to prevent a seroma from leading to complications such as infection, scarring and shape distortion. This parenchymal plication technique is a very straightforward method of breast reshaping and additional plication can be added as needed to accomplish specific corrections. No matter how the plication is performed, the concept is the same, namely separate the skin envelope from the gland, reshape the gland and then wrap the reduced skin envelope around the gland using any one of the several skin patterns described previously (Figure 5.34).

Suture fixation of internal flaps The glandular separation and plication approach is a fairly aggressive and technically demanding technique for breast reshaping that does carry a certain risk for potential vascular compromise to the skin flaps. Therefore, as an alternative, suture fixation of internally designed flaps has been described as another very versatile technique for breast reshaping. This approach has the advantage of providing a more direct control of the shape of the breast without the need to separate completely the breast skin envelope from the gland.

Pedicle flaps Perhaps the most well-known type of internal flap is the inferiorly based parenchymal flap used in conjunction with

the vertical mammoplasty procedure. In this technique, the blood supply to the NAC is based on a superior pedicle and the skin envelope is managed using a circumvertical approach. Inferiorly, a parenchymal flap is designed extending up from the inframammary fold to the inferior border of the areola. The width of the flap will vary depending on the size of the breast but it generally ranges anywhere from 6 to 8 cm. As the medial and lateral skin flaps are dissected free from around the lower pole of the breast, the inferior pedicle flap is developed. Inferiorly, the flap is dissected free from its dermal attachments along the inframammary fold. Medially and laterally, the flap is divided by extending the dissection deeply within the breast parenchyma through to the septum. The deep superior border of the flap is then the septum itself with the contained blood vessels that define the blood supply to the flap. The flap is then sutured superiorly under the breast, which is then folded around the pedicle flap as the vertical incision is closed and the NAC is inset. The flap easily reaches the superior pole of the breast and thus provides direct fill to this area, completely correcting any preoperative concavity which may be present. Also, by securing this flap superiorly, any tendency for the inframammary fold to drop is minimized as this flap slings the fold up and holds it in position. Initially, as with many procedures performed on the breast, the appearance of the upper pole of the breast will be excessively full; however, with time, the fullness settles into a persistent and long-lasting contour correction (Figures 5.35, 5.36).

A modification of the inferior parenchymal flap technique for upper pole reshaping has been described that involves suturing the flap under a small strip of muscle elevated from the lower leading edge of the pectoralis major muscle. It is theorized that fixating the flap in this fashion more securely holds the flap in position and provides more reliable recontouring of the upper pole of the breast. Concerns over this technique have focused on placing breast tissue under muscle and thus compromising the ability of this tissue to be properly



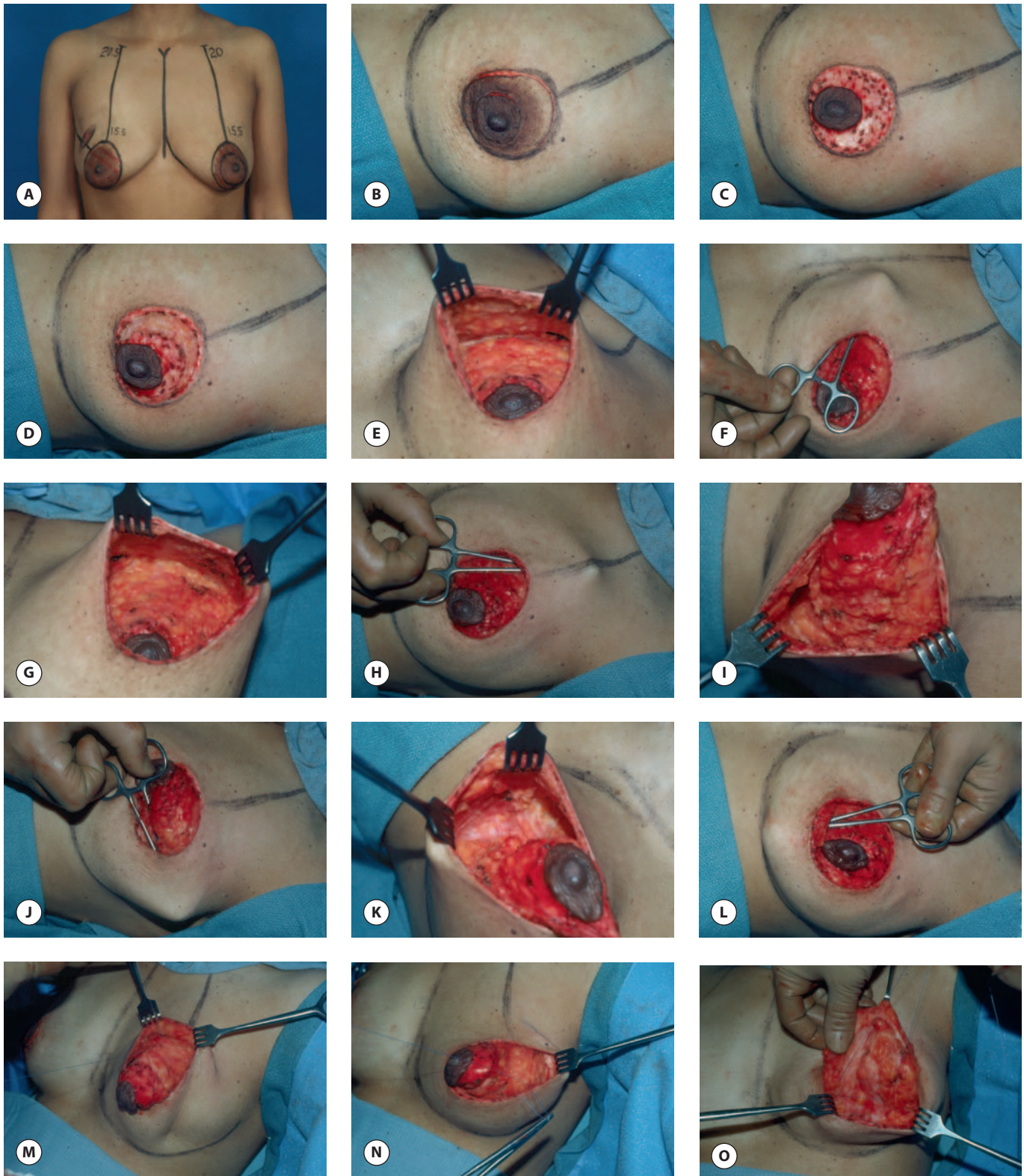


Figure 5.34 (A) Preoperative markings of a patient in preparation for left-sided periareolar mastopexy with internal parenchymal plication and right mastectomy with latissimus dorsi flap with tissue expander breast reconstruction. The periareolar pattern is drawn to not only lift the position of the NAC but also to reduce the areolar diameter. (B,C,D) A 44 mm areolar diameter is incised along with the outer periareolar incision (B) and the intervening skin is de-epithelialized (C). The dermis is then divided around the periphery of the periareolar defect, leaving a small dermal cuff eventually

to hold the purse string suture (D). (E,F) A medial breast flap is developed by separating the parenchyma from the overlying skin envelope at the level of the breast fascia (E). Dissection proceeds to the medial border of the breast but does not divide the internal mammary perforators (F). (G–L) The same dissection strategy used superiorly (G,H), laterally (I,J) and inferiorly (K,L) to separate completely the breast from the overlying skin envelope. (M,N) Once the parenchyma is freed from the overlying skin envelope, the parenchyma is plicated superiorly upon itself to lift the breast and correct the glandular ptosis.

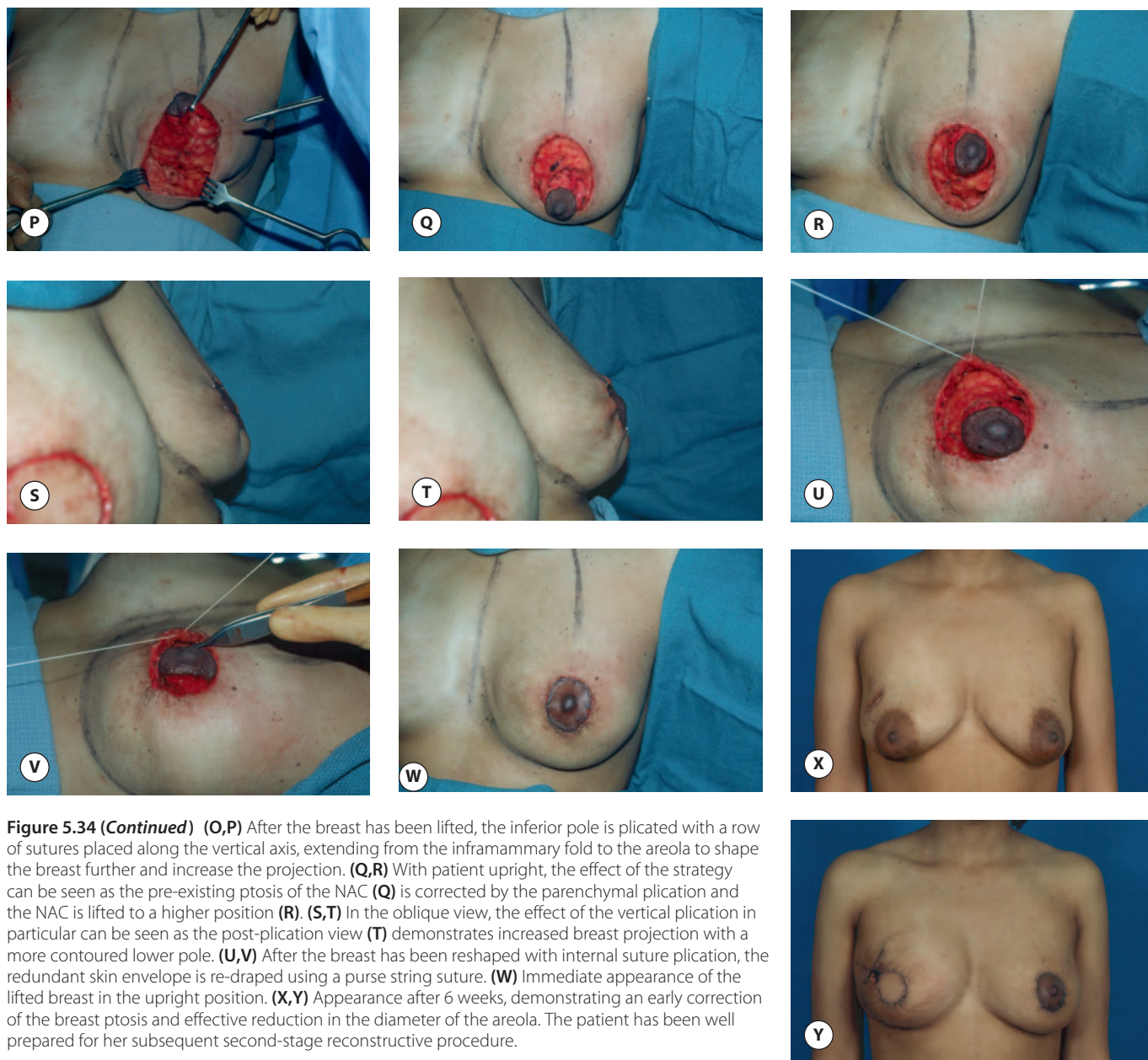


Figure 5.34 (Continued) (O,P) After the breast has been lifted, the inferior pole is plicated with a row of sutures placed along the vertical axis, extending from the inframammary fold to the areola to shape the breast further and increase the projection. (Q,R) With patient upright, the effect of the strategy can be seen as the pre-existing ptosis of the NAC (Q) is corrected by the parenchymal plication and the NAC is lifted to a higher position (R). (S,T) In the oblique view, the effect of the vertical plication in particular can be seen as the post-plication view (T) demonstrates increased breast projection with a more contoured lower pole. (U,V) After the breast has been reshaped with internal suture plication, the redundant skin envelope is re-draped using a purse string suture. (W) Immediate appearance of the lifted breast in the upright position. (X,Y) Appearance after 6 weeks, demonstrating an early correction of the breast ptosis and effective reduction in the diameter of the areola. The patient has been well prepared for her subsequent second-stage reconstructive procedure.

screened via mammography. While the oncologic issues are debatable, my personal feelings regarding the technique have more to do with possible constriction of the blood supply to the flap with potential ischemia and fat necrosis being the result of a tight muscle sling, either initially at the time of flap elevation, or subsequently as the muscle swells during the early phase of healing. This coupled with the fact that the flap can be reliably sutured up into position by simply directly affixing it superficially to the fascia of the pectoralis major muscle has led me to choose the direct approach in those patients who are candidates for use of the flap as opposed to the use of the muscle sling. Certainly, further research into this area will clarify the utility of the muscular sling in utilizing this flap.

Breast resuspension One variation to the flap reshaping strategy involves the use of the entire underside of the breast to resuspend the breast superiorly. In this technique, the breast is approached from an inferior direction, using either an inframammary fold incision or the lower portion of a vertical incision. A subglandular pocket is created that extends up to and slightly beyond the superior pole of the breast. Once the breast is released from its attachments to the pectoralis major muscle, it is lifted superiorly and reattached by suturing the deep surface of the breast to the pectoralis major fascia in a location that is higher up on the chest wall. This serves to shift the entire breast position superiorly and thus functions as an operative correction for positional breast ptosis. Also, upper pole concavity can be addressed by using the superior translocation to effectively 'autoaugment' the upper pole of the breast. Although an element

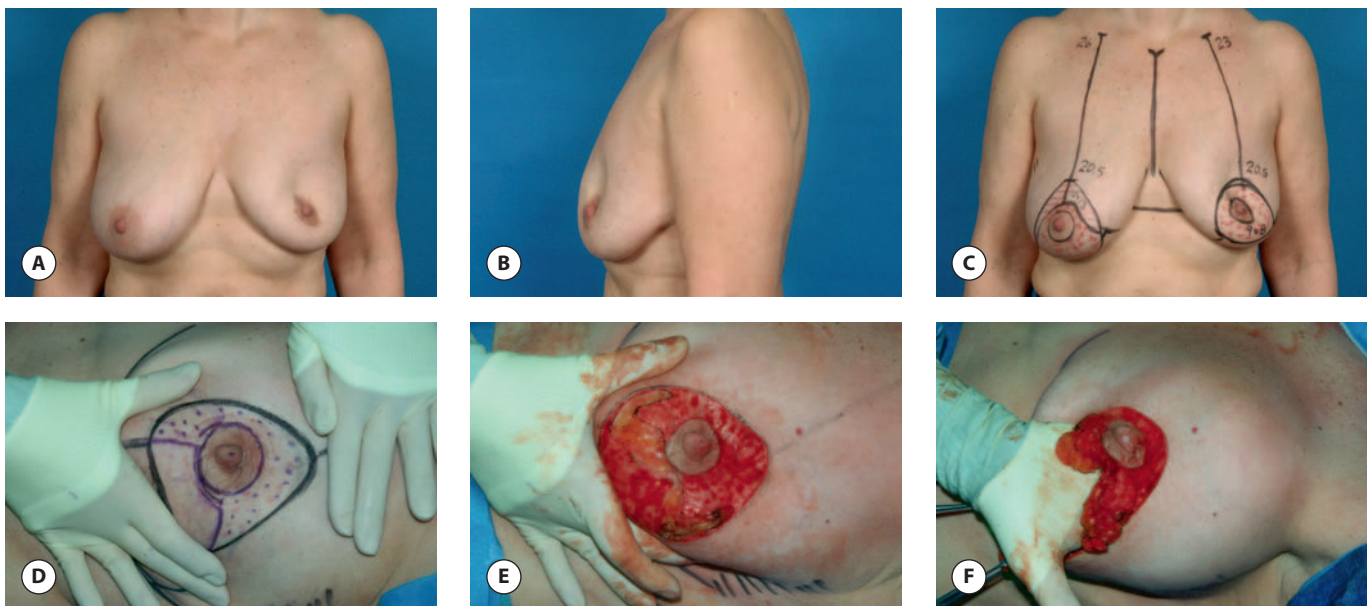
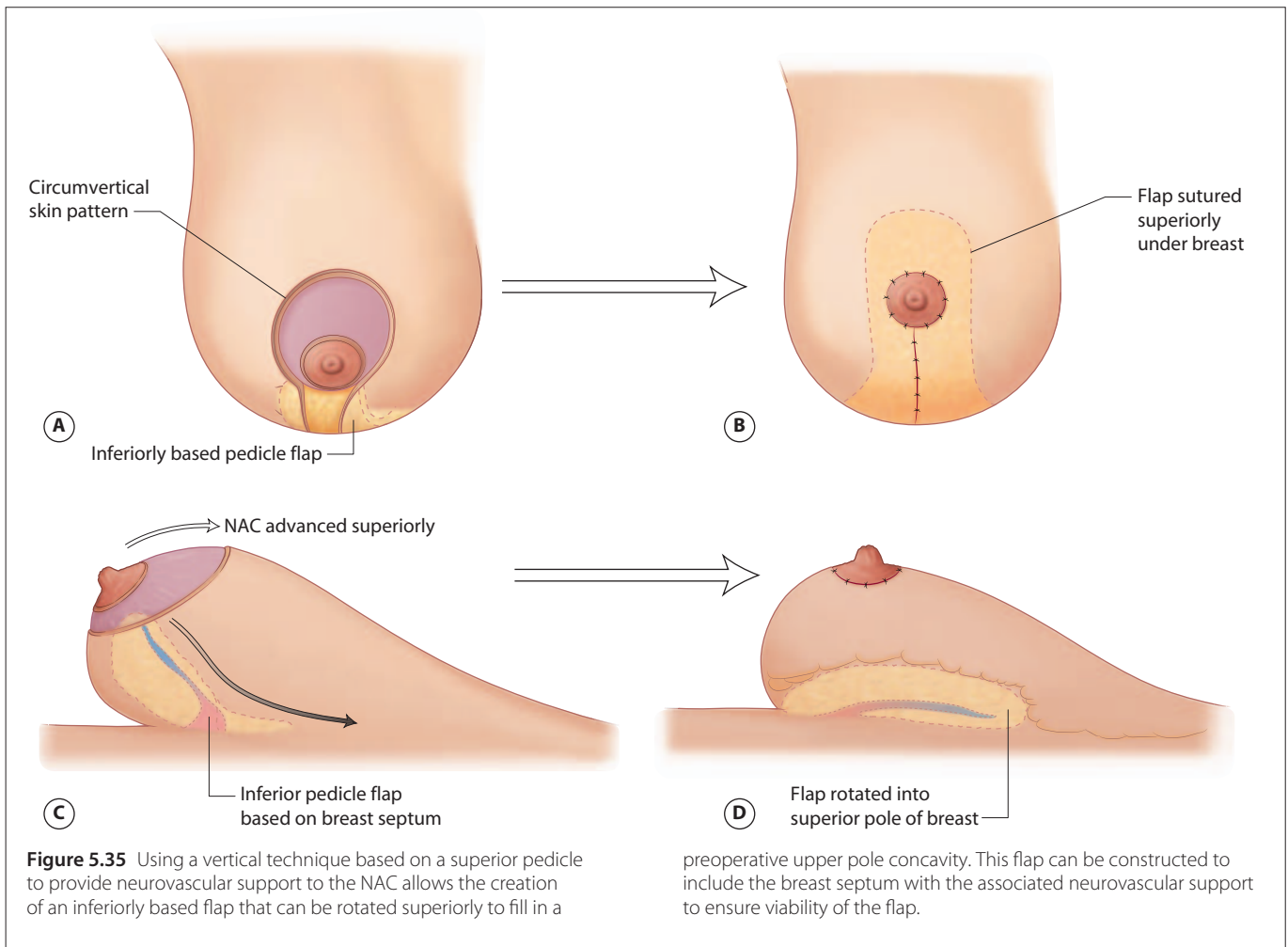


Figure 5.36 (A,B) Preoperative appearance of a 34-year-old woman who has previously undergone removal of a benign tumor from the superior aspect of the left breast, resulting in a significant contour depression in the region above the NAC. (C) Preoperative marks in preparation for a right-sided

circumvertical (SPAIR) mastopexy in conjunction with a left superior pedicle circumvertical mastopexy using an inferiorly based flap to fill in the upper pole defect. (D,E) The previous incision in the left breast was made just below the areola, which necessitated a superior pedicle approach to ensure

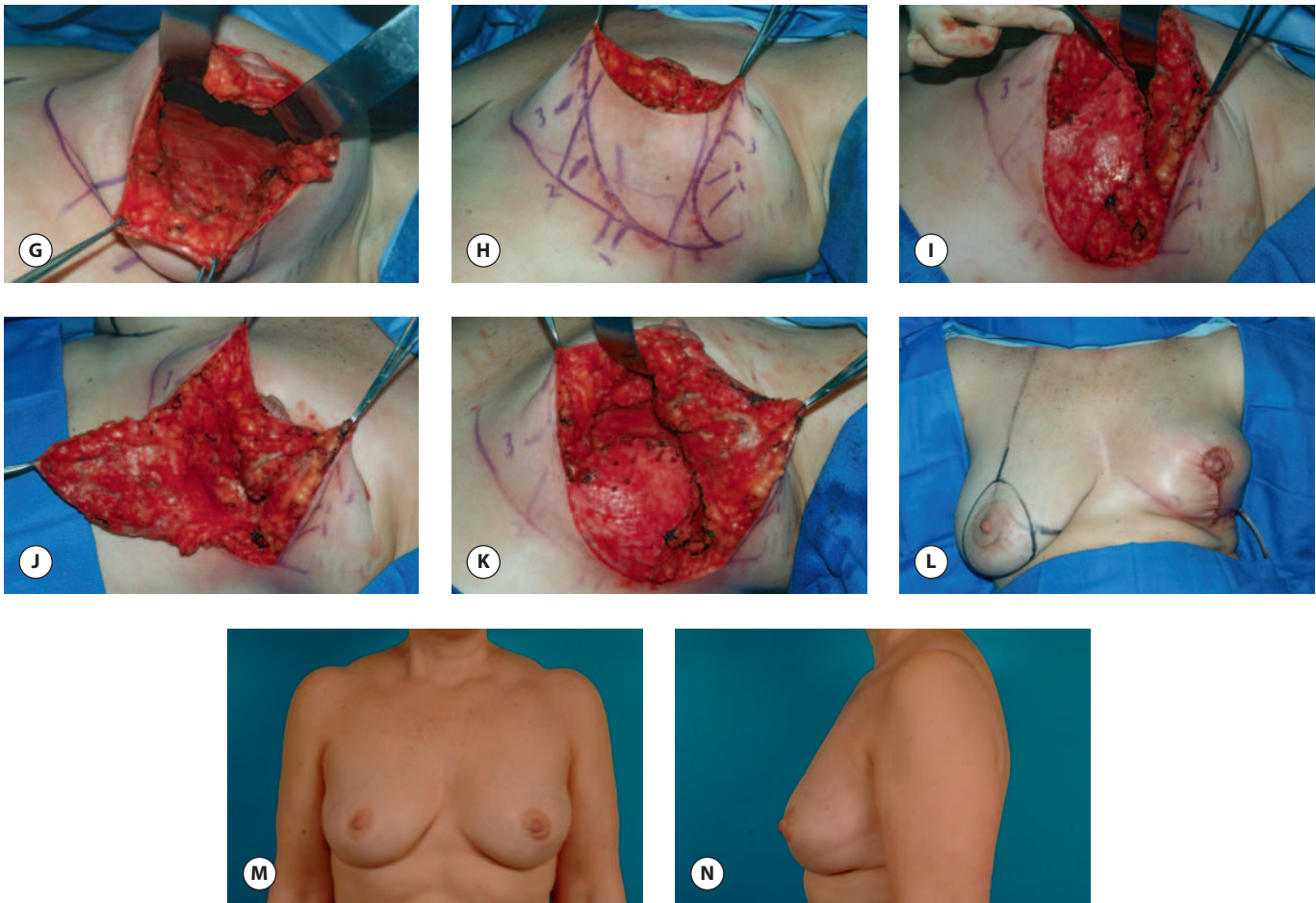


Figure 5.36 (Continued) adequate vascularity to the NAC. The incision is plainly visible after the surrounding periareolar skin has been de-epithelialized. **(F,G)** Once the incision has been opened, the superior pole of the breast is undermined to prepare for flap advancement. **(H)** After plication of the vertical segment has confirmed the proper shape, the area that will be de-epithelialized is determined and marked with a purple surgical marker. The dimensions of the planned inferior pedicle

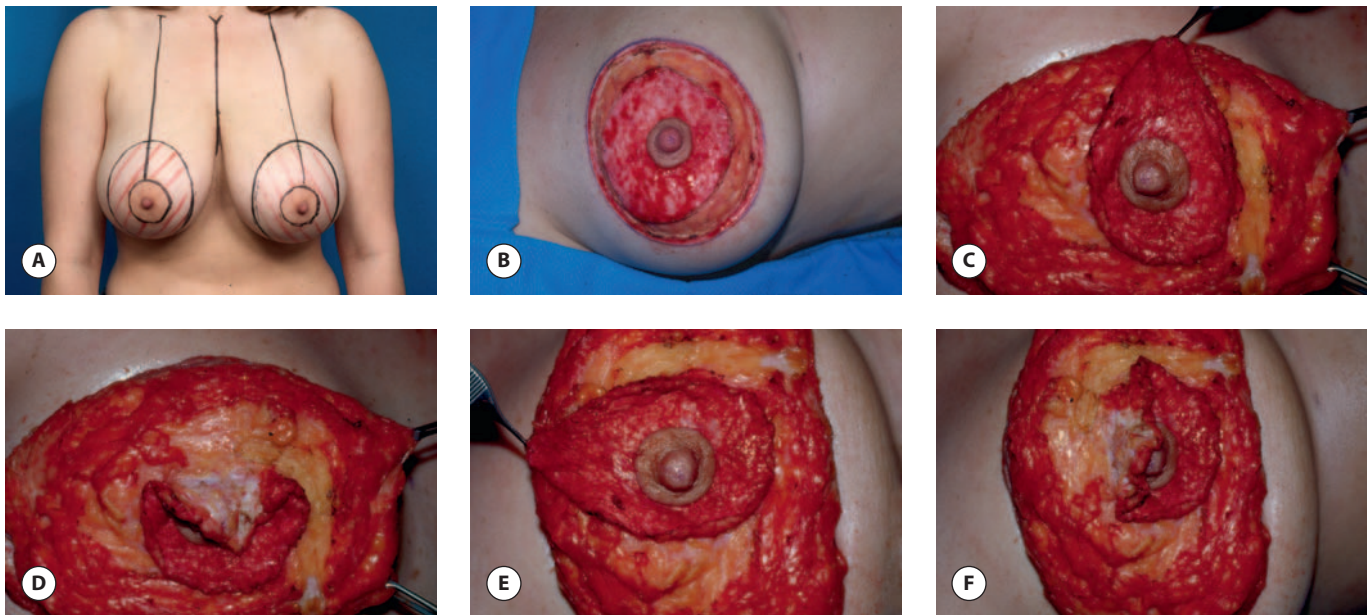
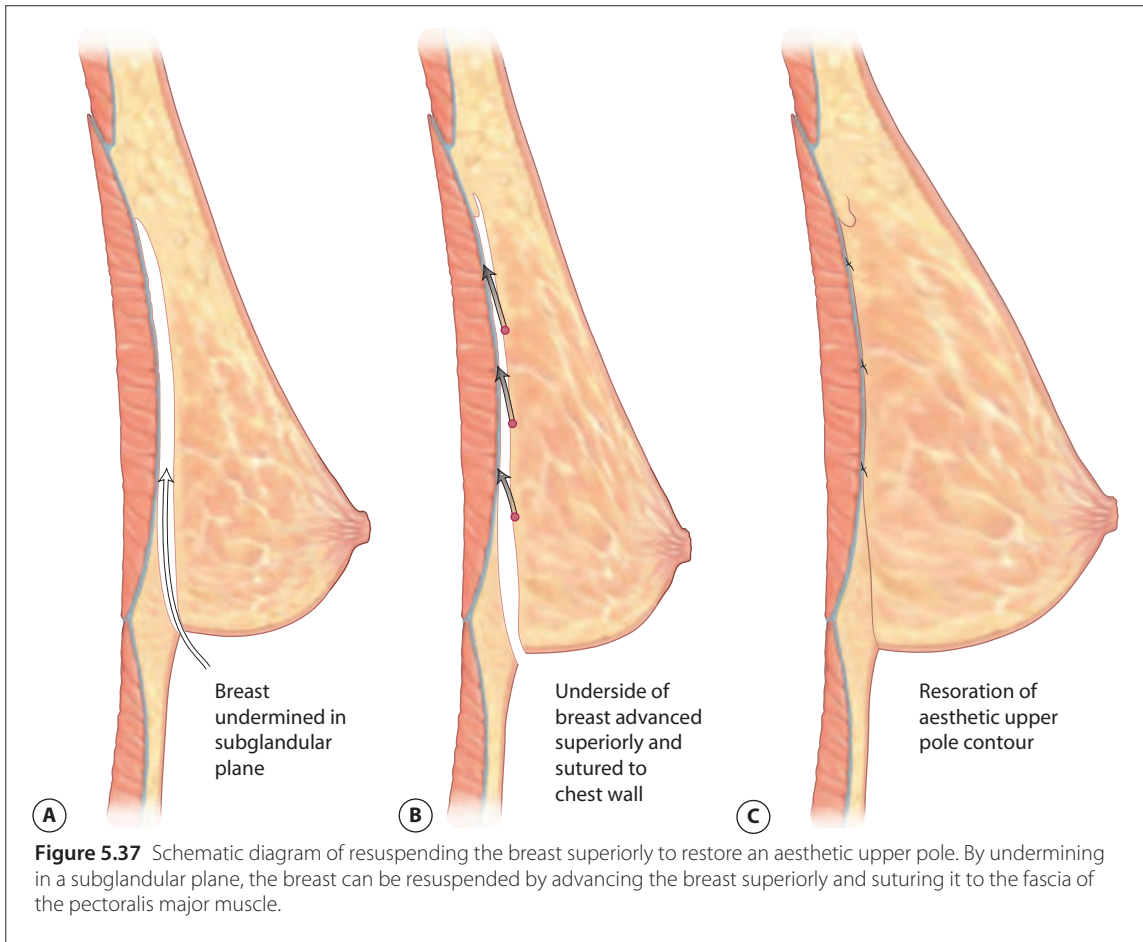
flap lie well within the margins of the redundant skin pattern. **(I-K)** The flap is developed and inset by suturing it to the underlying pectoralis major muscle. **(L)** Immediate appearance of the left breast, demonstrating complete correction of the upper pole depression and lifting of the breast and NAC. **(M,N)** Four-year postoperative result, demonstrating a symmetric appearance with complete correction of the preoperative left upper pole contour deformity.

of overcorrection must be employed with this technique to take into account recurrent stretching of the tissues, this resuspension strategy can be used in conjunction with skin envelope retailoring to provide for a very simple and yet effective mastopexy technique (**Figure 5.37**).

Dermal flaps In an attempt to suture fixate the breast parenchyma into position, it is possible to use the redundant skin envelope left over after skin retailoring to act as an internal bra-siere to help hold the breast parenchyma up into position. In periareolar approaches, the redundant dermis around the areola is de-epithelialized and undermined up to the NAC. The circular dermal flap can then be sutured to the surrounding breast parenchyma such that the redundant parenchyma is reinforced into a more compact and supported shape (**Figure 5.38**). Also, when using an inverted T skin pattern, rather than discarding the redundant wings of the lateral skin flaps, they can be de-epithelialized, released from the inframammary fold and wrapped around the inferior pedicle to help mold and shape the breast into a more projecting and aesthetic mound. Although only small

flaps may be available after retailoring of the skin envelope, even partial coverage of the breast parenchyma can aid in molding the breast.

Mesh Although not a commonly used technique, various types of synthetic and mixed absorbable/non-absorbable meshes have been used to provide sturdy and long-lasting support to the shape of the breast. In that regard, the technical strategy is the same as when dermal flaps are used and as well when the breast is plicated. By applying a molding force to the redundant and ptotic breast parenchyma that has been separated away from the surrounding breast flaps, the redundancy is taken up and the shape of the breast is improved (**Figure 5.39**). The advantage provided by mesh as opposed to dermal flaps is that there is no limitation to the surface area of the mesh that can be applied to the breast, which allows the entire gland to be supported. Also, with the non-absorbable mesh materials, permanent support of the breast will be accomplished. The major concern related to the use of mesh in the breast relates to oncologic issues. Despite evidence to the contrary, possible interference with mammographic



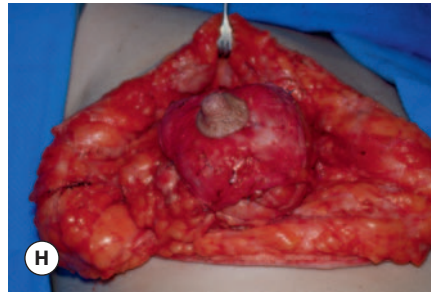
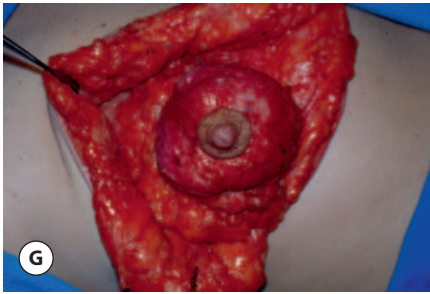

Figure 5.38 (Continued) (G,H) Appearance of the dermal flap after it has been wrapped around the central breast mound to help cone and shape the breast and increase projection.

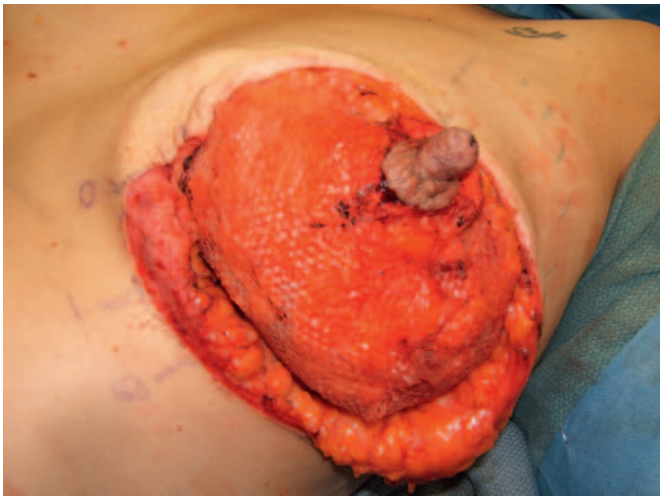


Figure 5.39 Intraoperative appearance of a meshed collagen matrix applied to the lower pole of the breast in a patient undergoing a circumvertical mastopexy. The mesh is designed to help shape the breast and provide long-term support to the parenchyma, thus resisting any tendency for the breast to 'bottom out' over time.

evaluation of the breast prevents many surgeons from adopting this approach. Also, the placement of a widely dispersed foreign body in an organ that has a well-recognized and significant malignant potential also causes concern. Despite these concerns, this technique is a very important conceptual concept when applied to breast shape. Once it is realized that the breast shape can be controlled by the application of an external force, all that remains is to determine the optimal external force, whether that be suture plication, dermal flaps or soft tissue rearrangement. Research into the possible development of mesh materials that are 'physiologically inert' may well allow this technique to become a valuable adjunct in shaping the breast in the future.

Operative Strategies

Any procedure designed to correct breast ptosis must generally satisfy three requirements. First, the nipple and areola must be lifted to a higher position without compromising the blood supply. Second, the redundant skin envelope must be reduced. And third, the shape of the breast must be controlled. To assist in organizing a surgical plan, it is helpful to categorize the procedures utilized to perform mastopexy in terms of a matrix with management of the skin envelope identified along the vertical axis and techniques to manage shape listed along the horizontal

axis (**Figure 5.40**). Such an organizational plan summarizes how each of the technical maneuvers described in this chapter can be utilized, either alone or perhaps more effectively in combination, to provide for an effective operative strategy to meet the needs of a specific patient.

General Considerations

Mastopexy is a procedure that is easily done on an outpatient basis. While it is possible to perform skin only procedures under local anesthesia, more aggressive internal shaping procedures are more effectively performed with either the assistance of IV sedation or under general anesthesia.

Periareolar Mastopexy (1A mastopexy procedure)

For patients who present with minimal breast ptosis and who require a lift of the NAC of 3cm or less, a simple periareolar procedure may be all that is required. In these cases, there must not be a significant redundancy to the skin envelope as the periareolar approach has limited utility in reducing this redundancy without flattening the breast and creating an exaggerated, rounded contour to the lower pole of the breast. Similarly, the pre-existing breast shape must be acceptable as a simple skin procedure will typically not have any effect on the shape.

The markings for the periareolar lift are as described previously. It is advantageous to use the interlocking Gore-Tex technique for closure of the periareolar defect as this will provide a degree of stability and reliability to the result above that provided for by a simple periareolar purse string approach. However, no matter what approach is used, it is advisable to overcorrect the areolar diameter slightly when applying the purse string suture as it is inevitable that a small amount of spreading will occur postoperatively. Overall, however, this procedure is very attractive as an operative correction for breast ptosis because of the simplicity of the technique and the requirement for only a periareolar scar (**Figure 5.41**).

In my experience, it is only the occasional mastopexy patient who is a candidate for a periareolar lift alone. However, in reconstruction patients, the technique can be very useful as a means to lift a mildly ptotic NAC on the side opposite a unilateral breast reconstruction. By slightly lifting the NAC on the uninvolved breast, the reconstructed NAC on the

		Shape Management	
		A – Skin Redraping	B – Internal Fixation
Skin Envelope Management	1 – Periareolar	Technique – Simple skin only periareolar lift Indications – lifting of NAC 3 cm or less with no significant reduction of skin envelope required, upper pole full, no internal shaping required	Technique – Periareolar lift with internal parenchymal plication Indications – lifting of NAC 3 cm or less with no significant reduction of skin envelope required, marked volume ptosis present with concavity in upper pole
	2 – Circumvertical	Technique – Simple skin only circumvertical lift Indications – lifting of NAC more than 3 cm, skin envelope excessive, no internal shaping required	Technique – Circumvertical lift with internal parenchymal plication, breast resuspension, flap support Indications – lifting of NAC more than 3 cm, skin envelope excessive, marked volume ptosis present with upper pole concavity
	3 – Inverted T	Technique – Simple skin only inverted T lift Indications – lifting of NAC more than 3 cm, skin envelope markedly excessive, no internal shaping required	Technique – Inverted T lift with internal parenchymal plication, breast resuspension, flap support Indications – lifting of NAC more than 3 cm, skin envelope excessive, marked volume ptosis present with upper pole concavity

Figure 5.40 Summary table describing the various techniques for performing mastopexy. By considering the surgical options available for management of the skin envelope together with the shaping strategy for the breast, a simplified and organized matrix can be developed that describes any procedure designed to treat the ptotic breast. Therefore, while a circumvertical approach using mesh versus an internally based flap may seem like two different procedures, in actuality both strategies are employing the same concept and therefore can be described as 2B mastopexy operations. Organizing the options for mastopexy in this manner assists in developing a logical approach to the surgical management of ptosis.

cancer side can be properly positioned at the apex of the reconstructed breast mound, a maneuver that can improve significantly the overall aesthetic appearance of the result. To this end, periareolar mastopexy alone can be a very useful technique to accomplish this task in reconstructive patients.

Periareolar Mastopexy with Internal Shaping (1B mastopexy procedure)

When a patient with minimal ptosis does present with a less than ideal breast shape, internal parenchymal plication can be used in conjunction with a periareolar skin pattern to lift and reshape the breast. Again, this technique is ideally limited to patients who require less than 3 cm of lift and do not have an excess of lower pole breast skin. After the periareolar incision is made, the skin flaps are dissected away from the breast in all directions down to the chest wall. Once the breast mound has been

separated from the surrounding skin flaps, the parenchyma is plicated as described by suturing the superior pole to itself horizontally and adding a vertical plication line down the center of the lower pole. The effect of these shaping sutures is to reduce the internal surface area of the breast mound, therefore there is a limit to the extent that the breast skin can re-drape around the new breast without creating a redundancy that results in a distorted appearance. Occasionally, the inferior periareolar skin pattern can be extended slightly inferiorly to take up some of this redundancy in the lower pole, but only to a limited extent. If the lower pole still has a flattened or distorted contour, a vertical segment must be added to the pattern to create the optimal result. Once the breast is properly reshaped and the skin envelope is re-draped around the breast, either with an isolated periareolar incision or with a circumvertical pattern, the interlocking Gore-Tex suture is applied to finish the procedure. This sequence of maneuvers presents a demanding technical challenge for the surgeon and is only applicable to a minority of patients who present with breast ptosis. However, when used with the periareolar approach, the advantage is an improved shape with preferably only a periareolar scar (Figure 5.42).

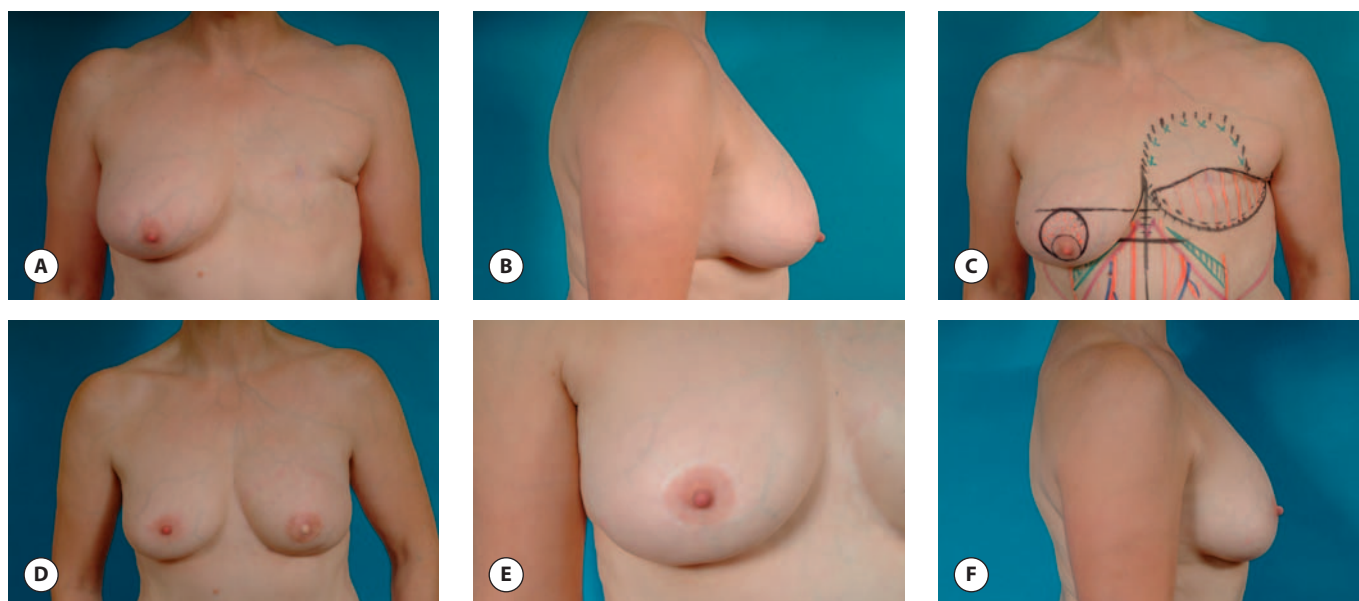


Figure 5.41 (A,B) Preoperative appearance of a patient after left-sided modified radical mastectomy as primary treatment for an intraductal carcinoma. The opposite uninvolved right breast demonstrates a full rounded shape but the position of the NAC is slightly ptotic and falls below the apex of the breast mound. **(C)** Preoperative marks in preparation for left-sided delayed TRAM flap breast reconstruction along with right-sided skin only (1A) periareolar mastopexy. Because the preoperative shape of the right breast is satisfactory and the skin envelope is not excessive, all that is required is a simple lift of the NAC to restore an aesthetic relationship between the NAC position and the breast mound.

(D) One-year postoperative appearance after final second stage revision of the left reconstructed breast along with reconstruction of the left NAC. By elevating the position of the right NAC at the first procedure, reconstruction of the new NAC on the left can be symmetrically positioned at the apex of the reconstructed breast mound in a way that maximizes the aesthetics of the final result. **(E,F)** At 2½ years, the mastopexy on the right is well maintained with no appreciable spreading of the areola being noted **(E)**. However, on the lateral view, a mild flattening with lack of projection is noted **(F)**, a finding that represents the major drawback associated with stand alone periareolar procedures.

Circumvertical Mastopexy

In patients who present with reasonable upper pole fullness and therefore do not need aggressive reshaping of the breast, but yet have a redundant and ptotic skin envelope along with ptosis of the NAC, what is required is a contoured resection of the redundant skin along with lifting of the NAC. In these patients, a simple circumvertical skin resection can be a technically straightforward and predictable option for performing a mastopexy. Here, the top of the periareolar pattern is determined by lifting the top of the areola up to the desired location on the breast and marking this point in line with the breast meridian. As a check measurement, this point should be anywhere from 4 to 6 cm above the inframammary fold line, which is drawn connecting the IMF from each breast across the midline such that it can be seen with the breasts in repose. If there is an asymmetry in the level of the IMF, the measurement is taken using the higher of the two folds. An oval-shaped pattern is then drawn around the existing areola, skirting the medial, lateral and inferior borders, which then identifies the periareolar component of the skin pattern. By pinching together the skin of the inferior pole of the breast, a rough estimate of the location and the shape of the vertical component of the skin pattern can be estimated. This identifies the proposed limits of the skin resection. At surgery, prior to any incisions being made, the planned incisions can be temporarily stapled together and the patient placed upright to assess the result of this initial plication. At this point, appropriate alterations can be made to raise or lower the top of the periareolar pattern, alter the takeout of skin around the

areola, or be more or less aggressive with the vertical component. This estimation is a completely artistic determination that is made by removing or adding staples as needed. Once the desired shape has been created, the skin edges that have been plicated with staples are marked and the staples removed. The dimensions of the skin pattern are easily visualized at this point and the incisions are deepened through the dermis and the redundant skin is either removed or simply de-epithelialized. If desired, a small amount of parenchyma can be removed under this vertical segment as needed to reduce slightly the size of one or both breasts depending on the presence of any preoperative asymmetry in breast size. Plication of the parenchyma in the inferior pole of the breast can also be performed as needed and the vertical incision is closed. An interlocking Gore-Tex suture completes the periareolar closure. This technique is easily performed and provides consistent, reliable results for a wide variety of patients. Should recurrent ptosis occur, it is a simple matter to re-tighten the skin envelope along the existing scar lines, which allows effective revision without the need for any additional scars (**Figure 5.43**).

One particular group of patients who are excellent candidates for this approach includes those patients who present with recurrent ptosis of the breast after previous augmentation mastopexy. In these cases, as a result of pregnancy, weight gain or simply aging, the internal support structure of the breast as well as the skin envelope stretches over time with the end result being a mismatch in the position of the implant versus the position of the breast. In essence, the implant tends to remain located in the upper pole of the breast while the breast parenchyma and

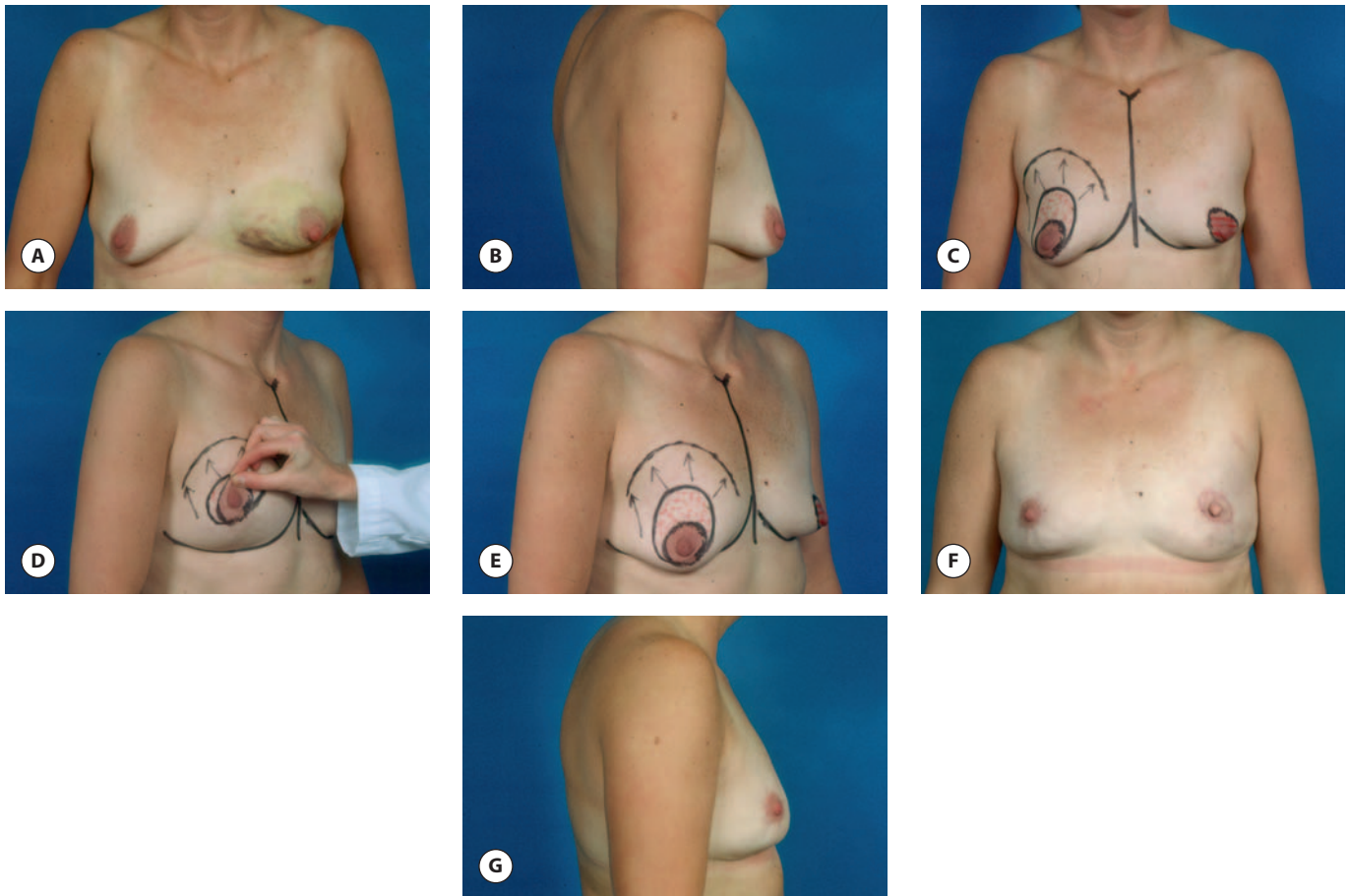


Figure 5.42 (A,B) Preoperative appearance of a 36-year-old woman with an intraductal carcinoma of the left breast. The opposite right breast demonstrates ptosis of the NAC along with a redundant skin envelope with volume ptosis and a concavity in the upper pole of the breast. In this patient, a simple periareolar mastopexy will not address the volume ptosis and internal parenchymal plication will be required to reshape the breast. **(C)** Preoperative marks in preparation for an immediate left-sided autogenous latissimus dorsi musculocutaneous flap breast reconstruction along with a right-sided periareolar mastopexy with internal parenchymal plication (1B procedure). **(D,E)** The new position for the NAC is determined by manually lifting the areola up to a point on the breast where it visually appears to be located at the apex of the breast mound. Marking where the top of the areola abuts up against the skin of the breast superiorly

then determines the top of the periareolar pattern. The rest of the marking pattern then sweeps medially, laterally and inferiorly around the margins of the areola thus identifying the skin that will be de-epithelialized at the time of surgery (red dots). The locations for the internal plication sutures (black arrows) are marked to indicate the extent to which the breast parenchyma will be lifted. The periareolar defect will be managed with a Gore-Tex purse string suture. **(F,G)** One-year postoperative appearance after completion of the second stage revision on the left with reconstruction of the NAC. The volume ptosis of the right breast as well as the inferiorly malpositioned NAC have been corrected. Because of this, the reconstructed NAC on the left could also be positioned at the apex of the reconstructed breast thus improving the final overall appearance of both breasts.

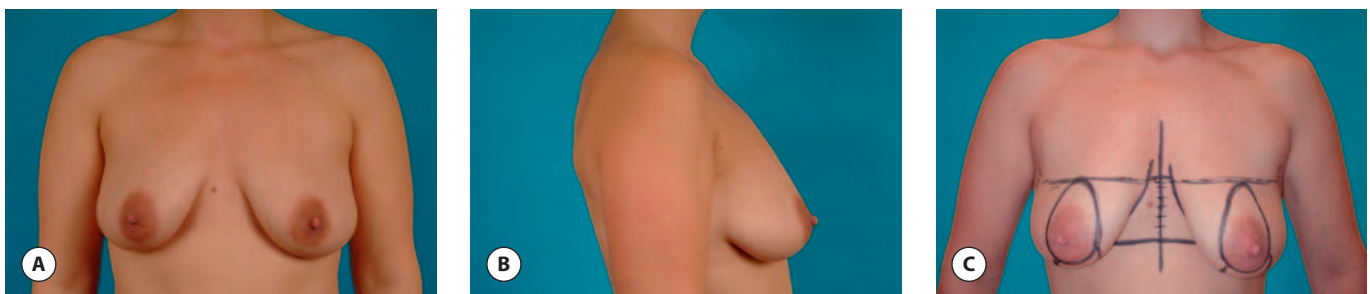


Figure 5.43 (A,B) Preoperative appearance of a 36-year-old woman in preparation for circumvertical skin only (2A procedure) mastopexy. There is asymmetry in the size of the breasts and each breast has a broad, flattened appearance with a redundant skin envelope. Also, the areolar diameter is slightly widened. **(C)** Preoperative marks demonstrating that, while the NAC is located at the most projecting point of the breast, the right nipple is located just at the level of the IMF (1B location) but the left is below the fold (1C). Due to the fact that the top of the areola will be lifted 4–5 cm,

there will be a real risk of creating a flattened non-projecting breast if only a periareolar pattern is used. For this reason a circumvertical skin tightening is planned. This strategy will allow the base diameter of the breast to be narrowed, with the left side being tightened slightly more vigorously than the right to correct the asymmetry that is present not only in the shape, but also in the NAC position, and will also allow the NAC to be lifted without creating undue tension on the periareolar closure. Because the shape of the breast is not excessively ptotic, no internal plication is required.

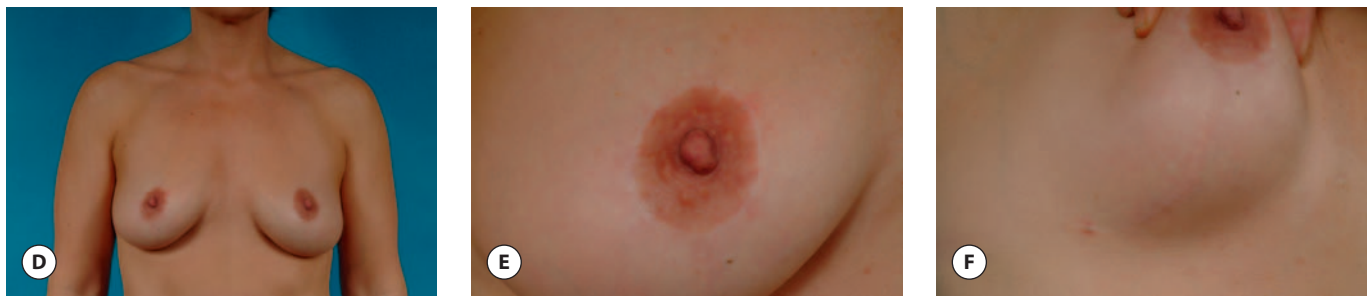

Figure 5.43 (Continued) (D) The result at 1 year demonstrates improved symmetry in the position of the NACs, which are now located above the inframammary fold (1A position) and have a smaller more proportionate diameter. The base diameter of the breast is narrowed and the overall

aesthetic appearance is improved. (E,F) The scar around the areola (E) as well as the vertical scar (F) have both healed in a fine line fashion and there is no excessive widening of the areolar diameter.

skin fall inferiorly. In severe cases, two separate breast contours can be created, leading to what is called a 'snoopy dog' deformity. When the implant is not malpositioned superiorly and it is the ptotic breast that is responsible for the shape distortion, simple skin only circumvertical mastopexy can be a technically straightforward and reliable technique to reposition the breast parenchyma such that it once again lies on top of the implant. Because the shape of the breast is largely being created by the underlying implant, using the skin envelope to lift the ptotic parenchyma can provide just enough of a correction to restore an aesthetic shape to the breast and lift the inferiorly malpositioned NAC. In these patients, there is also less likelihood of recurrent soft tissue ptosis due to the fact that the soft tissue framework has already become ptotic once. There is a variable limit to the extent that the skin, fat, parenchyma and internal fascial support can stretch and that limit is approached during the ptosis recurrence. Therefore, despite the fact that skin only procedures carry a variable risk for recurrent ptosis, in augmentation mastopexy patients who present with recurrent ptosis and who have reasonable skin elasticity, a skin only procedure can provide a long-term solution (Figure 5.44).

Resuspension Circumvertical Mastopexy

For patients who present with a redundant skin envelope and a ptotic gland with concavity in the upper pole of the breast, something more than a simple skin resection must be performed to provide the best result. One option for these types of patients is to use the proposed vertical portion of the circumvertical skin pattern as an access portal to the breast and then develop a subglandular pocket. Using the resuspension technique described previously can then allow the entire gland to be translocated superiorly, which provides a mild improvement in the positional ptosis and, if done aggressively enough, can correct the upper pole concavity. It is necessary once again to overcorrect the upper pole contour to provide a long-lasting result as tissue relaxation will lead to partial relapse of the upper pole shape. Once the breast is reshaped, the circumvertical pattern including the interlocking Gore-Tex technique is applied as before to complete the procedure. This procedure is easily performed and is simply an extension of the circumvertical approach described previously. As such, the extent to which the breast is disassembled is minimized, which keeps potential complications to a minimum. Should revision become necessary, as with the circumvertical approach alone, it is easily performed and can

provide excellent results with no additional scars. For these reasons, the circumvertical mastopexy with breast resuspension has proven to be an attractive option for many patients seeking mastopexy (Figures 5.45, 5.46).

While the resuspension strategy is an attractive option for breast reshaping in mastopexy, it must be realized that the degree to which the breast can be lifted is limited. In my experience, despite attempts to significantly overcorrect the upper pole contour, the eventual upper pole shape is neutral at best, meaning that when the breast is viewed from the side, a straight line contour is noted extending from the clavicle to the nipple. However, such a result does not mean that the technique offers no advantage. When a mastopexy is performed, simply tightening the skin envelope more than a modest amount can tend to exacerbate any tendency for an upper pole concavity to worsen if the effect of the surgical manipulation alters the shape of the lower pole of the breast but has no effect on the upper pole. For patients who present with a mild tendency for concavity in the upper pole, the resuspension strategy can correct the concavity or, at the very least, prevent this contour from worsening and that can be a useful advantage in properly selected patients.

SPAIR Mastopexy

Due to the fact that breast reduction and mastopexy are closely related procedures, there is a commonality to the numerous surgical approaches that can be applied to each. In fact, in some instances, the exact same pattern used for breast reduction can also be used for mastopexy with the caveat being that no parenchyma is removed. Such is the case with the short scar, periareolar, inferior pedicle, reduction (SPAIR) mammoplasty procedure. By applying the concepts used to perform breast reduction, a very reliable and widely applicable method for mastopexy can also be developed. What results is the most complex and invasive of all the techniques described in this chapter. However, it is also the most complete in terms of correcting the preoperative deformity that patients with severe breast ptosis can present with. Conceptually, the procedure carries the blood supply to the NAC on an inferior pedicle. Breast flaps are created

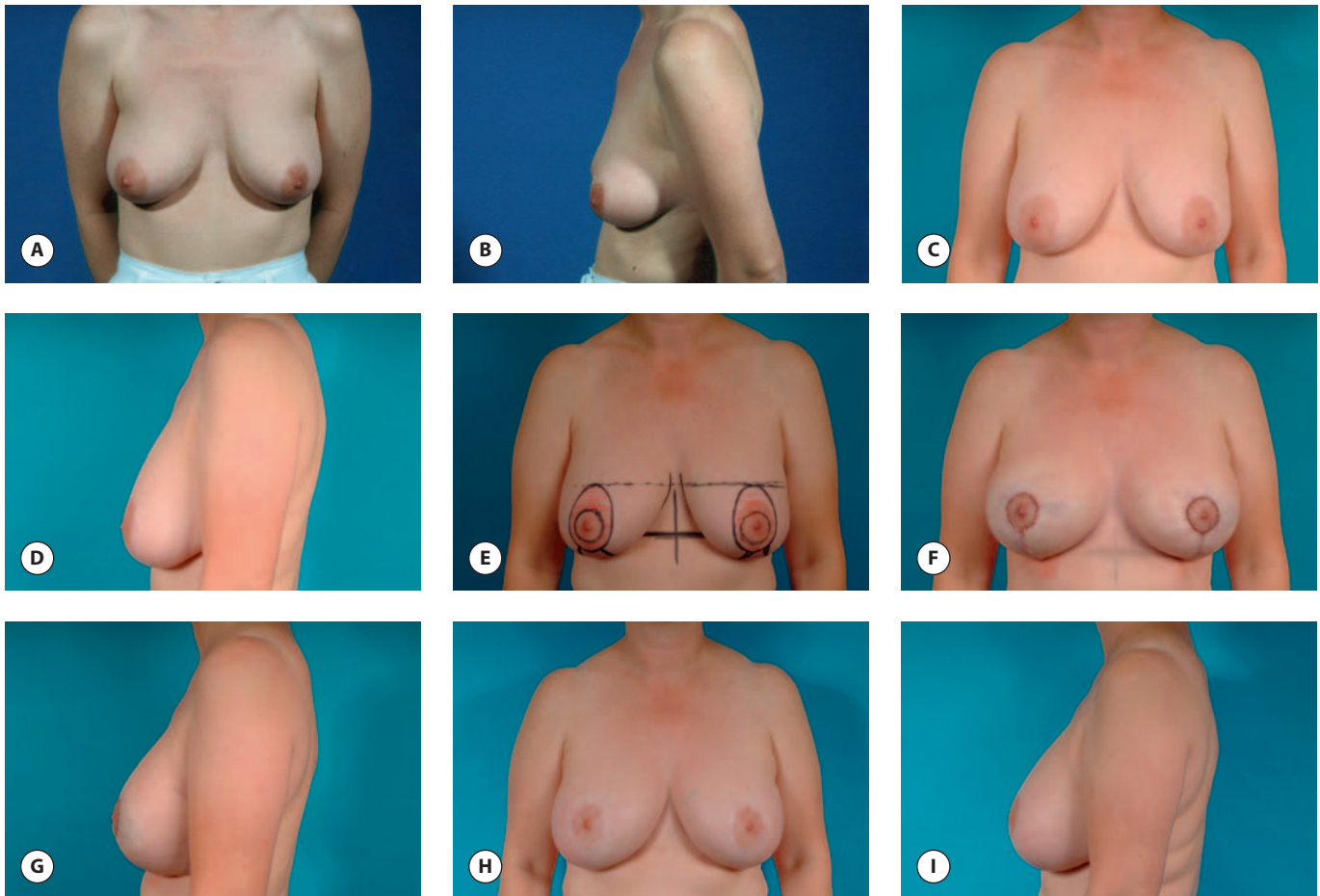


Figure 5.44 (A,B) Initial preoperative appearance of a 38-year-old woman prior to undergoing bilateral periareolar augmentation mastopexy. (C,D) Ten-year postoperative appearance demonstrating widened areola diameters and positional breast ptosis. While the NAC is at the most projecting point on the breast mound, the overall appearance is one of ptosis as the main substance of the breast has descended inferiorly away from the implant. This can be seen on the lateral view as the implant creates a slight bulge superiorly and the breast parenchyma fills out the lower pole of the breast. Essentially there is a mismatch in position between the breast implant above and the breast parenchyma below. (E) Preoperative markings in preparation for circumvertical skin only (2A) mastopexy. The nipples lie just above the inframammary fold, creating a 1A type NAC position. However, despite this otherwise acceptable location, a full circumvertical skin pattern will be required due to the widened base

diameter of the breast and the need to use the pattern to lift the ptotic breast parenchyma superiorly such that it lies over the implant rather than below it. (F,G) Appearance of the breasts immediately after application of the circumvertical revision in conjunction with an interlocking Gore-Tex periareolar purse string suture. The procedure involved tightening of the skin envelope alone without exposing or otherwise manipulating the underlying implants. The areolar diameters are reduced and symmetrically located and the breast volume has been lifted to complement better the position of the implant. (H,I) Four-year postoperative result demonstrating long-term improvement in the shape of the breast despite the fact that a skin only procedure was performed. While there has been mild expansion of the diameter of the areolas as compared to the initial immediate postoperative appearance, the NACs are properly located at the apex of the breast mound and are symmetric from side to side.

such that parenchymal shaping maneuvers can be used to auto-augment the upper pole of the breast and completely correct any shape deficiencies that are invariably present. Finally, the redundant skin envelope is managed using a circumvertical skin pattern strategy along with an interlocking Gore-Tex technique to finish the periareolar closure.

Patient marking The patient is marked in the upright position with the arms resting comfortably at the sides. The inframammary fold is marked on each side by drawing the location of the fold directly in the crease that forms as the breast is gently lifted away from the chest wall (Figure 5.47 A–C). It is important to place this mark directly in the fold as the location of the fold will not change postoperatively, therefore, there is no need to artificially raise or

lower the incision location in an attempt to compensate for the bottoming out phenomenon. Because the support structure of the inframammary fold is not violated in the SPAIR mastopexy, bottoming out in the classic sense does not occur. The position of the breast on the chest wall is noted and a meridian line is visualized such that it divides the breast into two equal halves. This line is drawn from the clavicle down to and beyond the inframammary fold (Figure 5.47 D,E). The top of the proposed incision in the areola is then lifted superiorly to a point where the apex of the breast is destined to be positioned. The exact location of this point is identified by estimating, based on the visual appearance of the breast as the areola is lifted, where the point of maximal projection of the breast will eventually be located. The areola is positioned here and the top of the periareolar pattern is drawn where it intersects

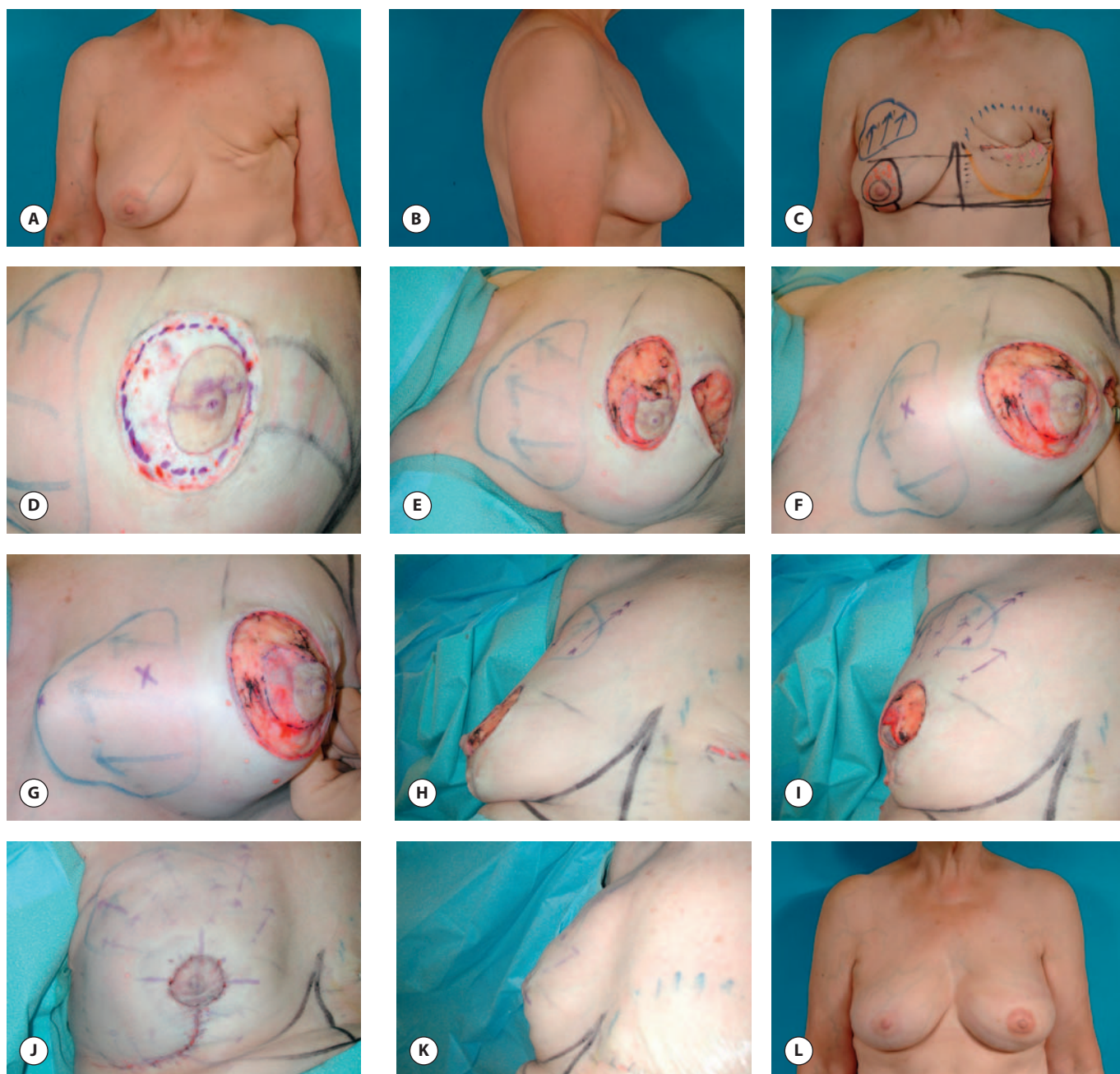


Figure 5.45 (A,B) Preoperative appearance of a 71-year old-woman in preparation for left latissimus dorsi flap breast reconstruction done in conjunction with a right circumvertical mastopexy. Due to the mild concavity that is present in the upper pole of the right breast, a resuspension strategy will be used to provide better control of this contour in anticipation of the creation of a similar upper pole appearance on the reconstructive side. (C) Preoperative marks demonstrating the proposed extent of the periareolar component on the right along with the resuspension of the breast parenchyma superiorly. (D) The periareolar pattern is de-epithelialized and the proposed incision through the dermis to create the dermal shelf is drawn. (E) After the edges of the periareolar defect have been undermined to prepare for eventual placement of the purse string suture, the vertical incision is made and an extended subglandular pocket is created. (F,G) A suture is placed on the underside of the breast just at the lower margin of the concavity (F) and the

parenchyma is advanced superiorly and sutured to the pectoralis major fascia (G). Three sutures are placed, one each at the 10, 12 and 2 o'clock positions. The parenchyma is advanced until the upper pole contour is visually overcorrected, creating a mildly convex contour. A second row of sutures is similarly placed to lift the central portion of the breast. (H,I) With the patient placed upright, the effect of the superior resuspension can be seen as the ptotic volume (H) is repositioned superiorly (I). Note that the upper pole contour is overcorrected in anticipation of postoperative tissue relaxation leading to partial loss of the contour correction. (J,K) Final appearance after application of the vertical segment and closure with the Gore-Tex periareolar interlocking purse string suture. (L) The result at 2 years after completion of the second stage reconstruction on the left demonstrates excellent symmetry and an overall aesthetic appearance to each breast.

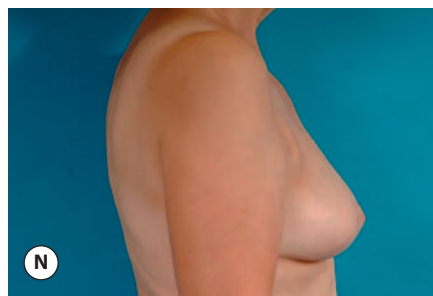
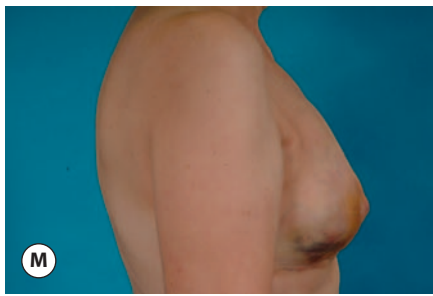

Figure 5.45 (Continued) (M) On the lateral view, the degree of upper pole fullness at 1 week postoperatively is demonstrated (M). Two years later (N), with the resolution of tissue swelling and mild soft tissue relaxation, a pleasing neutral contour to the upper pole of the breast has been achieved.

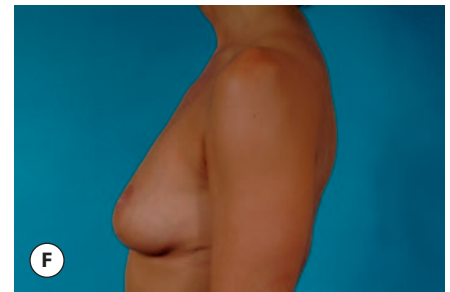
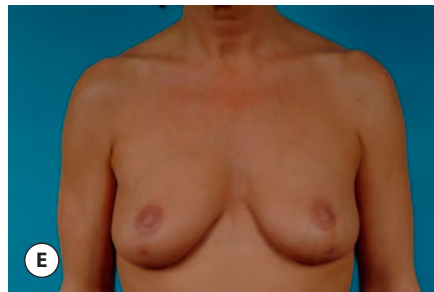
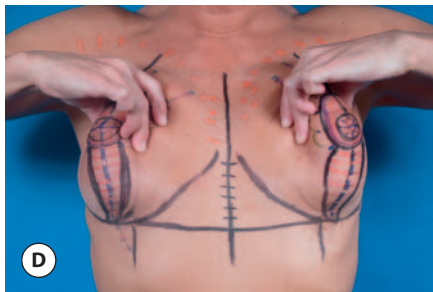
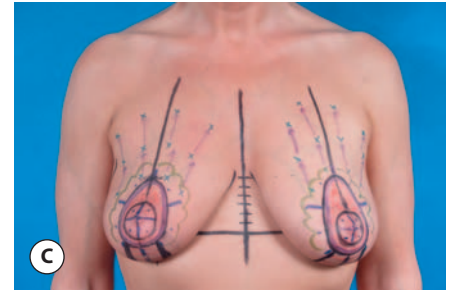
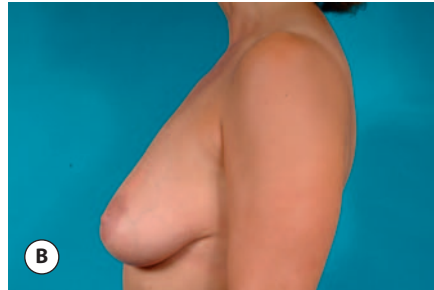
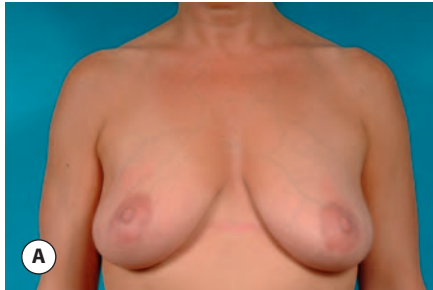


Figure 5.46 (A,B) Preoperative appearance of 51-year-old woman in preparation for bilateral resuspension circumvertical mastopexy.

(C,D) Preoperative marks. (E,F) Ten-month postoperative result.

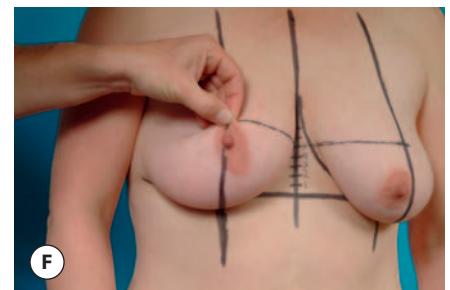

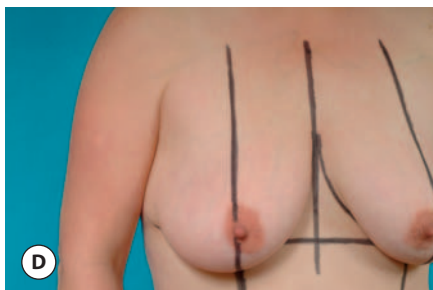
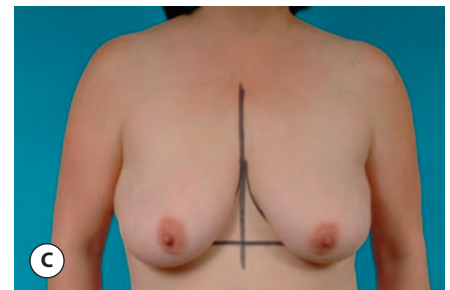
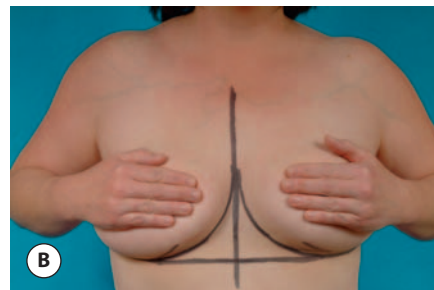
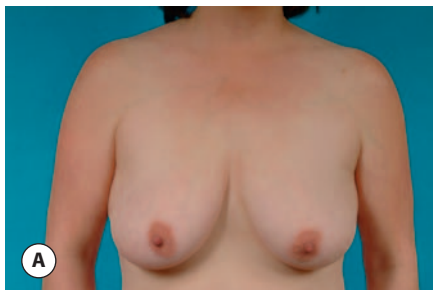


Figure 5.47 (A) Preoperative appearance of a 36-year-old woman with NAC and volume ptosis, skin redundancy and NAC asymmetry who presents for SPAIR mastopexy. (B) The marking procedure is begun by first identifying the midsternal line and the location of each inframammary fold. (C) By communicating the IMF location with a line that runs across the midline, the location of the fold can be determined from afar without the need to manipulate the breast and possibly distort the soft tissue

relationships. (D,E) The breast meridian is drawn in a fashion that bisects the breast volume into two equal halves (D). If the NAC is asymmetrically positioned, it is ignored during the determination of this line. This line is then carried down onto the chest wall (E) ultimately to aid in properly locating the central portion of the pedicle. (F) The top of the periareolar pattern is identified by lifting the ptotic NAC up to the apex of the breast mound and transposing this point onto the superior pole of the breast.

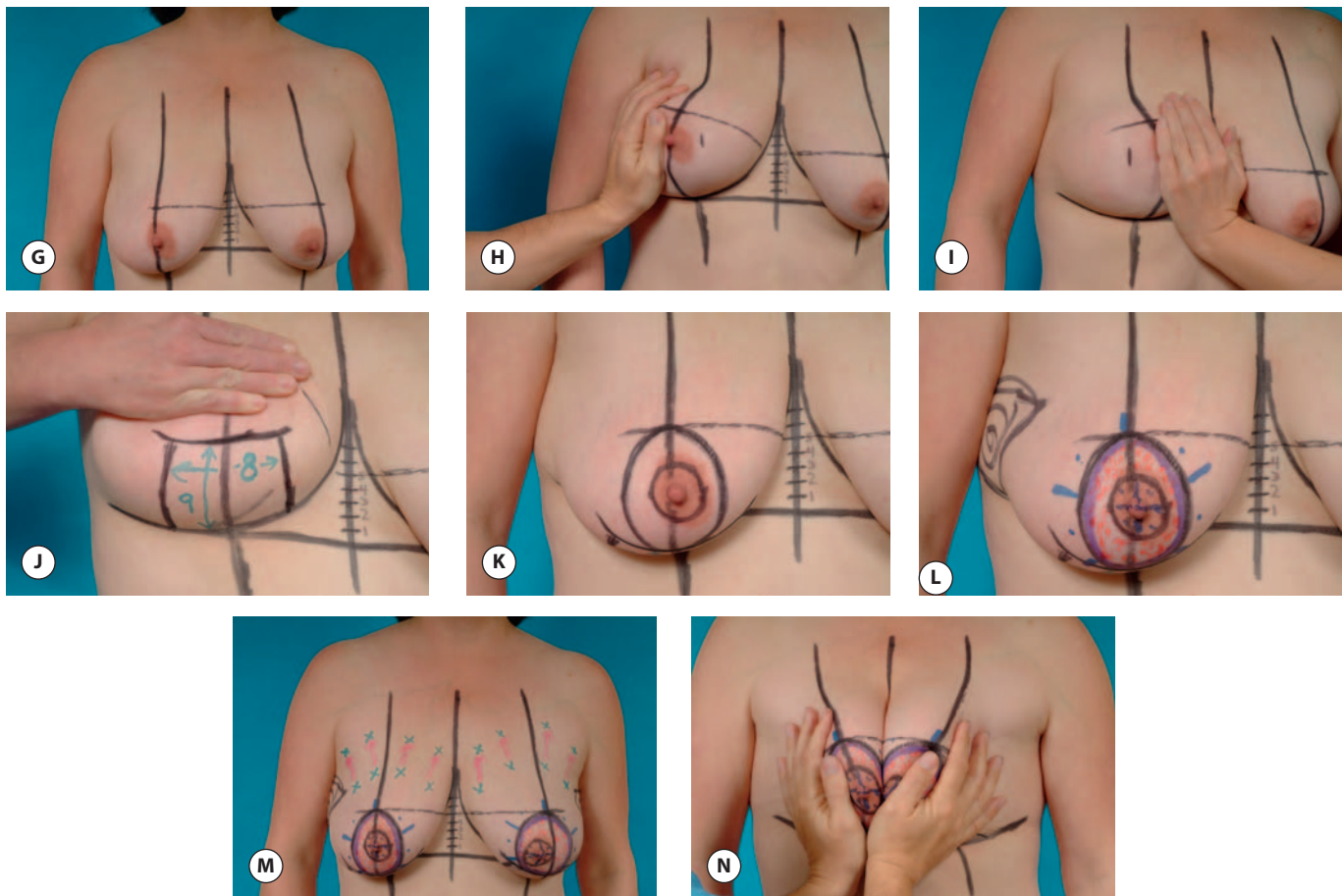


Figure 5.47 (Continued) (G) This point is symmetrically located from side to side with the aid of a line that parallels the location of the inframammary fold. It is not uncommon for this line to be located 5–6 cm above the previously drawn inframammary fold line. (H,I) The breast is gently pushed up and out (H) and then up and in (I) and the breast meridian is transposed onto the breast skin at the level of the nipple to identify the optimal amount of breast skin to preserve during the development of the periareolar pattern. (J) An 8 cm wide pedicle is drawn along the IMF centered on the breast meridian. A distance of 8–10 cm (in this instance 9 cm) measured from the IMF line is then diagrammed up on either side of the pedicle and

these two points are communicated in a line that parallels the IMF. (K) The four cardinal points are joined to create a periareolar pattern that takes on the shape of an elongated oval. (L) The eight orientation marks to guide the eventual placement of the interlocking Gore-Tex suture are made in the outer periareolar skin and the areola. (M) The appearance of the final marking pattern. Note that the left NAC is medially malpositioned and therefore ignored as the left breast meridian is drawn. The proposed extent of superior pole plication is illustrated by the pink arrows. (N) A final check for symmetry can be performed by compressing the breast in the midline to be certain that the same amount of skin has been preserved on each side.

the breast meridian line (Figure 5.47 F). The same location is identified on the opposite breast and a line running parallel to the inframammary fold line is drawn across the chest (Figure 5.47 G). The position of the top of the periareolar pattern can be checked by measuring the distance between the IMF line and the line denoting the top of the periareolar pattern. This distance can measure up to 6 cm in some patients. It should be emphasized, however, that the measured distance is meant to be only a confirmatory finding to support the estimation made by the surgeon as to the proper location for the top of the periareolar pattern. In smaller breasts, the remainder of the periareolar incision is diagrammed so as to skirt the medial, inferior and lateral borders of the existing areola. The resulting shape assumed by the proposed periareolar incision becomes that of an elongated oval. In larger breasts, a displacement maneuver is used to simulate what the desired contour will be. By gently transposing the breast medially and laterally with just enough pressure to create the desired shape and noting where the breast meridian would be located at a level even with the nipple, the proper amount of skin can be preserved to eventually wrap

around the inferior pedicle in a contoured fashion (Figure 5.47 H,I). Finally, to complete the periareolar pattern, an 8 cm pedicle is diagrammed inferiorly centered on the breast meridian. On either side of this pedicle, a distance is measured up from the inframammary fold 8–10 cm and these two points are smoothly joined in a manner that parallels the shape of the inframammary fold (Figure 5.47 J). The 8 cm measurement is used in smaller breasts and the 10 cm measurement is used in more ptotic patients with a large skin envelope excess. Once these four cardinal points have been determined, they are smoothly joined together in what becomes an elongated oval (Figure 5.47 K). The landmarks for the interlocking Gore-Tex suture are applied and marks are checked for symmetry to complete the marking process (Figure 5.47 L,M). A useful maneuver to ensure symmetric application of the marks is to compress the breasts against each other in the midline to be sure that the marks are evenly and symmetrically applied and that the same amount of skin is left behind (Figure 5.47 N). This can be very helpful in patients who present with any degree of asymmetry. Although the amount of skin resected from each side may

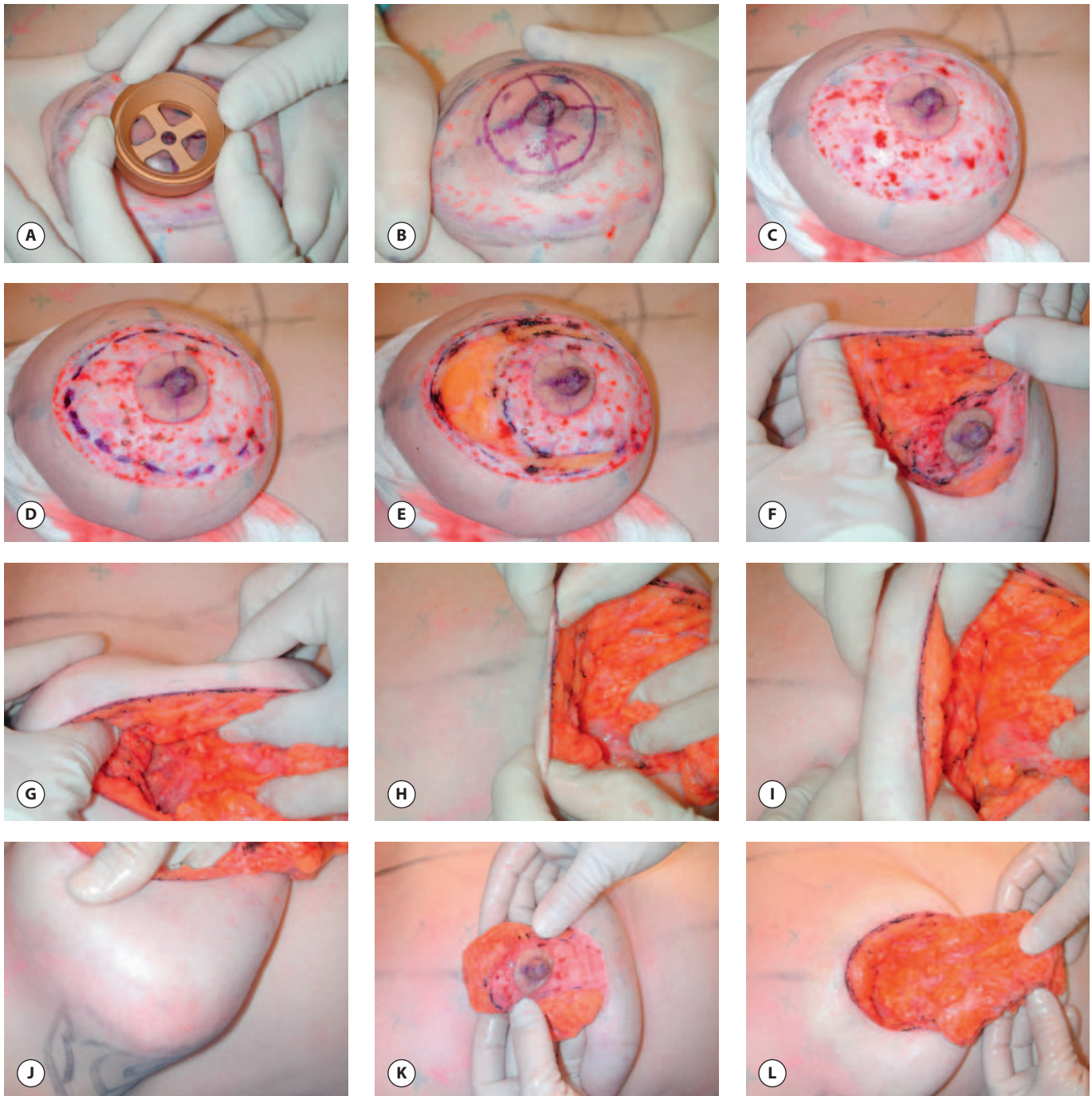


Figure 5.48 (A,B) A multidiameter areolar marker is used to create a 40 mm areolar diameter with the breast and areola under tension. (C) After the areolar and periareolar incisions are made, the intervening skin is de-epithelialized. (D,E) The dermal shelf is marked (D) and the dermis divided to define the periareolar opening as well as the inferior pedicle (E).

(F–I) The medial flap is dissected to be quite thin initially (F) and then become thicker as dissection nears the chest wall (G). The same is true for the superior flap (H,I). (J) Laterally, the flap is dissected at the level of the breast fascia and is therefore somewhat thin. (K,L) Appearance of the inferior pedicle with the attached NAC after flap development.

differ, leaving behind the same amount of skin on each side offers the best environment for obtaining symmetry. A useful adage to remember in this regard is, ‘it’s not what you take, it’s what you leave behind that is important’.

Flap development At surgery, the proposed areolar incision is made with the assistance of a multidiameter areolar marker.

With the areola under stretch, an areolar diameter of 40–44 mm is diagrammed and incised (Figure 5.48 A,B). The outer periareolar incision is made and the intervening skin de-epithelialized (Figure 5.48 C). The dermis is divided around the periphery of the periareolar defect leaving a 5 mm dermal cuff that will ultimately hold the periareolar Gore-Tex purse string suture. The dermis in the inferior 25% of the periareolar pattern is left intact

to preserve the dermal contribution of the blood supply to the NAC (Figure 5.48 D,E). The medial, superior and lateral breast flaps are then developed in preparation for breast reshaping. Initially, dissection of the superior and medial flaps proceeds directly under the dermal shelf and then progressively curves downward toward the chest wall, creating a flap that will be

4–6 cm in thickness. The end result is a flap that is quite thin initially but then becomes substantially thicker at the base of the breast (Figure 5.48 F–I). In contrast, however, the lateral flap is dissected at the level of the investing breast fascia down to the chest wall (Figure 5.48 J). If the lateral flap is left too thick, experience has shown that a pronounced lateral fullness to the

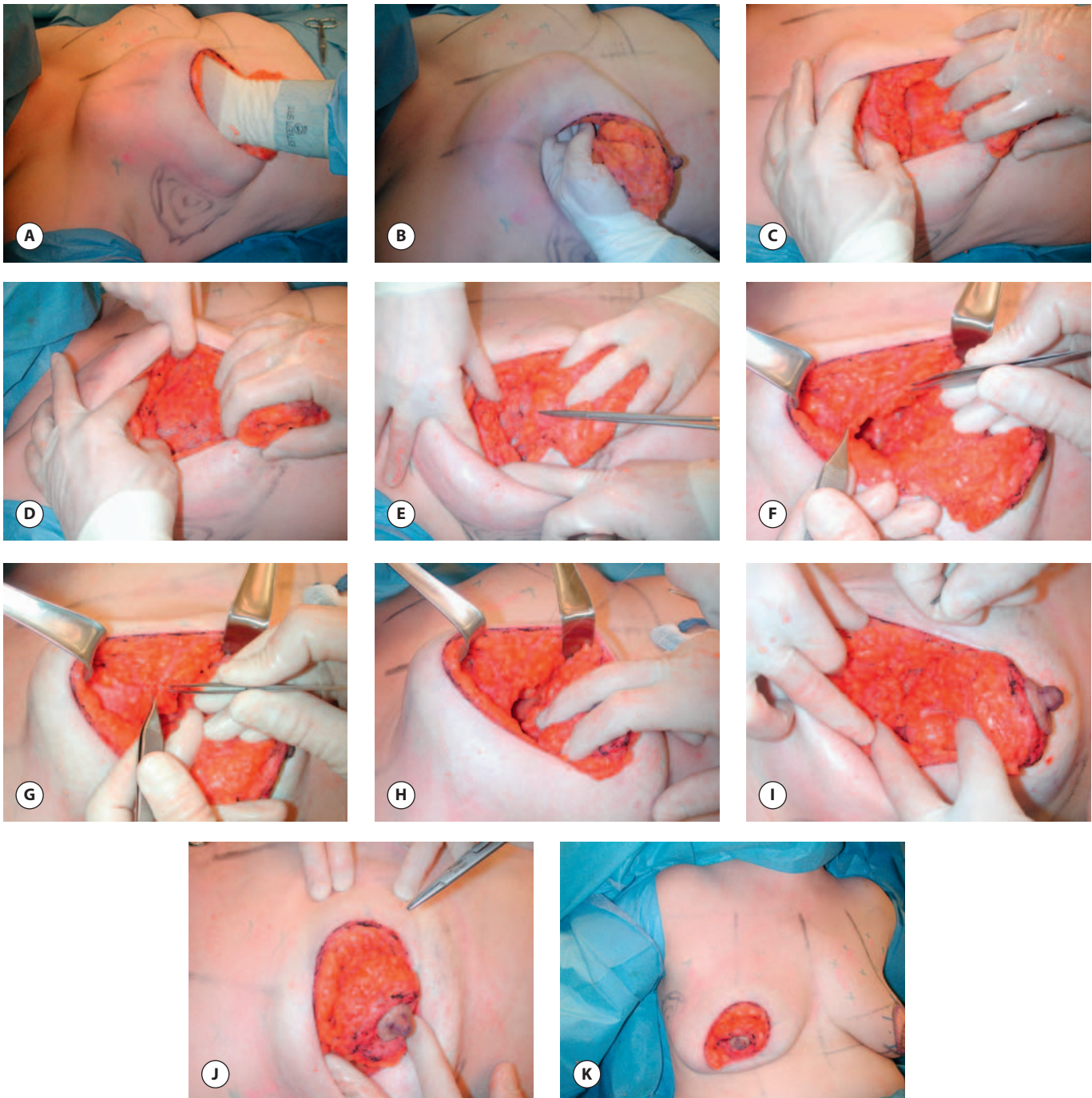


Figure 5.49 (A) The upper flap is undermined up to the general region of the clavicle to prepare for flap resuspension. (B) The medial flap is elevated over the medial internal mammary perforators but not beyond in order to preserve this vigorous source of blood supply to the breast. (C–E) The leading edge of the superior flap is advanced superiorly and sutured to the pectoralis major fascia to provide an autoaugmentation to the upper pole

of the breast. (F–H) The medial flap is plicated upon itself to create a medial fullness and more rounded contour. (I) The inferior pedicle is advanced superiorly and sutured to the pectoralis major fascia. (J,K) The pedicle is sutured to the surrounding breast flaps (J) to further shape the breast. At the conclusion of the shaping process, the favorable effect of the shaping maneuvers can be seen on the breast with the patient upright (K).

breast will often result. An effort is made to make a smooth transition between the base of the thicker superior flap and the thinner lateral flap to avoid the possibility of a visible contour step off in the superolateral aspect of the breast. Once the flaps have been developed, the inferior pedicle with the attached NAC can be identified as it lies in the center of the breast mound. Every effort is made to avoid undermining the pedicle and to keep as wide a base of attachment as possible to ensure maximal neurovascular supply to the pedicle (Figure 5.48 K,L).

Breast reshaping Once the flaps have been developed, the superior flap is undermined up to a level that approaches the clavicle (Figure 5.49 A) and the medial flap is undermined over to but not beyond the internal mammary perforators (Figure 5.49 B). Superiorly, the leading deep edge of the flap is advanced up and under itself, where it is sutured to the pectoralis major fascia in three locations using an absorbable 3-0 monofilament suture (Figure 5.49 C-E). Ideally, these sutures are placed correspondingly at the 10, 12 and 2 o'clock positions to evenly advance the flap superiorly. Absorbable sutures can be used in this procedure as a result of the fact that the flaps are actually undermined and directly repositioned. Scar will eventually form, which then functions to hold the repositioned tissues into place. In this fashion, an autoaugmentation of the upper pole of the breast is performed using the soft tissue thickness of the superior flap as the basis for supplying tissue to fill in the upper breast contour. The deep leading edge of the medial flap is then imbricated to itself again with the 3-0 absorbable monofilament suture (Figure 5.49 F-H). This serves to gather the medial flap tissues together, which creates a more rounded and improved medial breast contour. The inferior pedicle that was created by default after dissection

of the flaps is now translocated superiorly such that it meets the superior flap, at which point the deep margin of the pedicle is secured to the pectoralis major fascia with two to three sutures (Figure 5.49 I). If there is a sharp tissue edge around the apex of the pedicle, this edge is trimmed to provide a rounded smooth contour. Finally, if the surrounding flaps have enough bulk, the pedicle can be directly sutured to the medial and superior flaps to assist further in holding the pedicle in position to improve the shape of the breast (Figure 5.49 J,K).

Vertical plication From a technical standpoint, the plication of the redundant skin in the lower pole of the breast is a very straightforward maneuver and yet, at the same time, it is this maneuver that requires the most artistry on the part of the surgeon. The procedure is begun by placing the patient upright at least 45 degrees to allow gravity to affect the breast in a way that allows the surgeon to accurately assess the effect of the vertical plication. By placing traction on the most superior aspect of the inferior pedicle, the skin envelope will buckle medial and lateral to the pedicle (Figure 5.50 A). These two buckle points are grasped with a forceps and the edges are brought together and temporarily secured with what is called the 'key' staple (Figure 5.50 B-D). This is the fixation point that sets the remainder of the pattern as all other judgments regarding the extent of plication are based on the key staple as a starting point. The de-epithelialized dermal shelf on either side of the key staple is grasped with a hemostat and, by providing upward traction, the lower pole skin envelope is placed under tension (Figure 5.50 E). In this position, when inward pressure is applied against the center of the lower pole of the breast, the edges can be seen to imbricate in a vertical to slightly oblique orientation that identifies

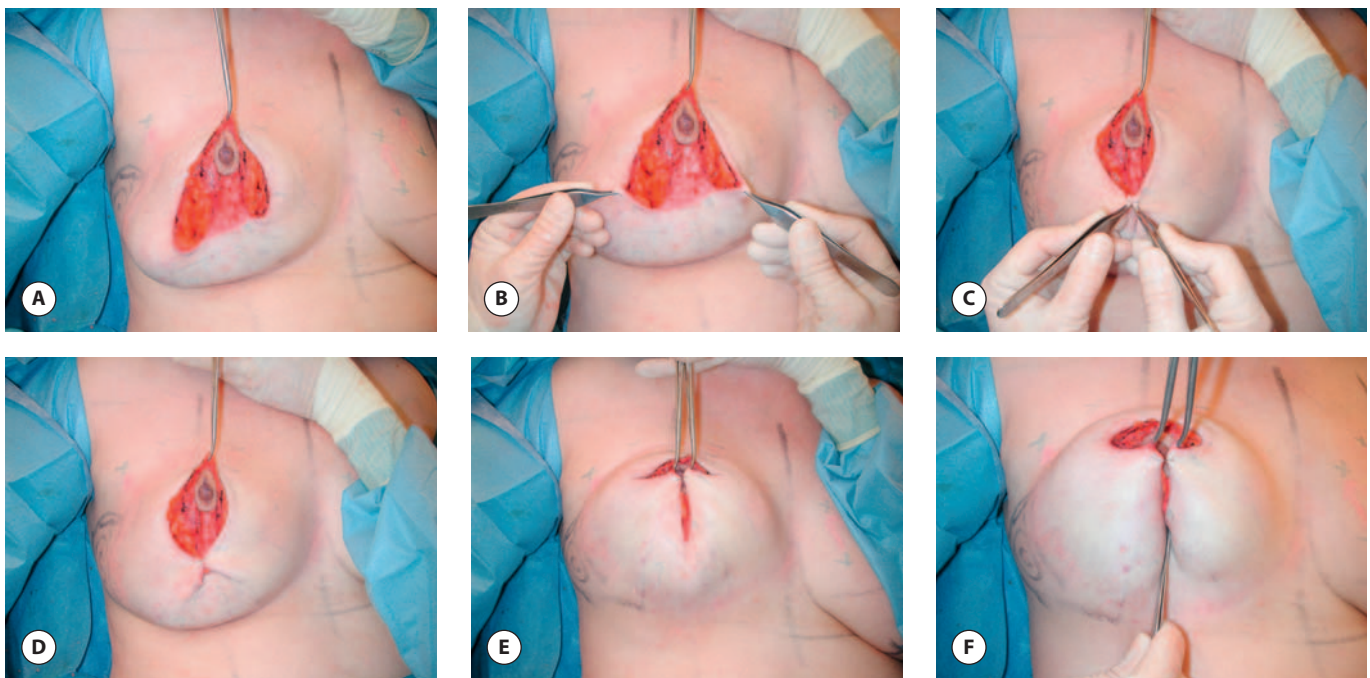


Figure 5.50 (A) The pedicle is grasped along the superior margin and upward traction is applied. (B-D) As a result, two buckled skin folds develop medial and lateral to the pedicle (B). The points are grasped with forceps and stapled together to position the key staple (B-D). (E) The dermal shelf

on either side of the key staple is grasped with a hemostat and upward traction is placed on the lower pole skin envelope. (F) By pushing inward on the central portion of the lower pole of the breast, the flaps imbricate upon themselves to reveal the location of the optimal line of plication.

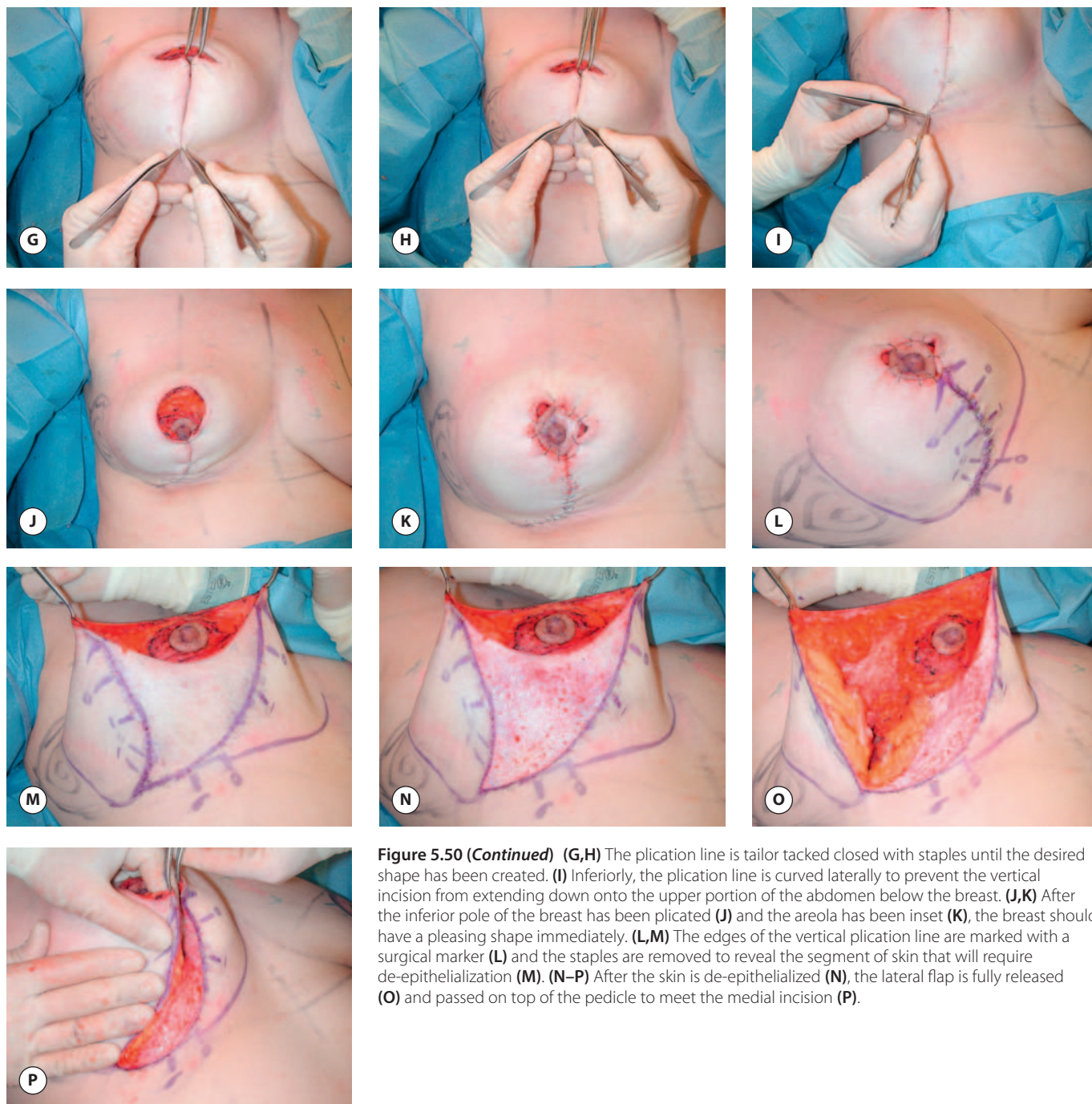


Figure 5.50 (Continued) (G,H) The plication line is tailor tacked closed with staples until the desired shape has been created. (I) Inferiorly, the plication line is curved laterally to prevent the vertical incision from extending down onto the upper portion of the abdomen below the breast. (J,K) After the inferior pole of the breast has been plicated (J) and the areola has been inset (K), the breast should have a pleasing shape immediately. (L,M) The edges of the vertical plication line are marked with a surgical marker (L) and the staples are removed to reveal the segment of skin that will require de-epithelialization (M). (N–P) After the skin is de-epithelialized (N), the lateral flap is fully released (O) and passed on top of the pedicle to meet the medial incision (P).

the plication line needed to optimally create the desired breast shape (Figure 5.50 F). It is then a simple matter to apply staples sequentially to secure the plication line in the desired location (Figure 5.50 G,H). As the plication line nears the inframammary fold, it is angled laterally to prevent the vertical incision from extending down onto the upper abdomen (Figure 5.50 I). Once the vertical segment is fully plicated, the dimensions of the peri-areolar defect will be markedly reduced and the areola can be inset into the defect to allow final assessment of the breast shape (Figure 5.50 J,K). At this point, further tightening of the plication line can be performed as needed to create the best shape possible. Conversely, some staples can be loosened slightly to correct

excessive lower pole flattening. Essentially, whatever maneuver is required to create the best shape possible is what is required at this point. This aspect of the shaping strategy represents one of the major advantages of the technique, namely, that the shape immediately on the table is designed to be the shape that is ultimately created after full healing has occurred. In patients with poor skin tone, it may be advisable to over-tighten the plication line slightly in anticipation of some postoperative skin envelope relaxation. Once the vertical segment has been set, the margins of the plication line are marked and the staples are removed (Figure 5.50 L,M). The vertical segment is de-epithelialized and the lateral flap is fully released to allow it to cross over on top

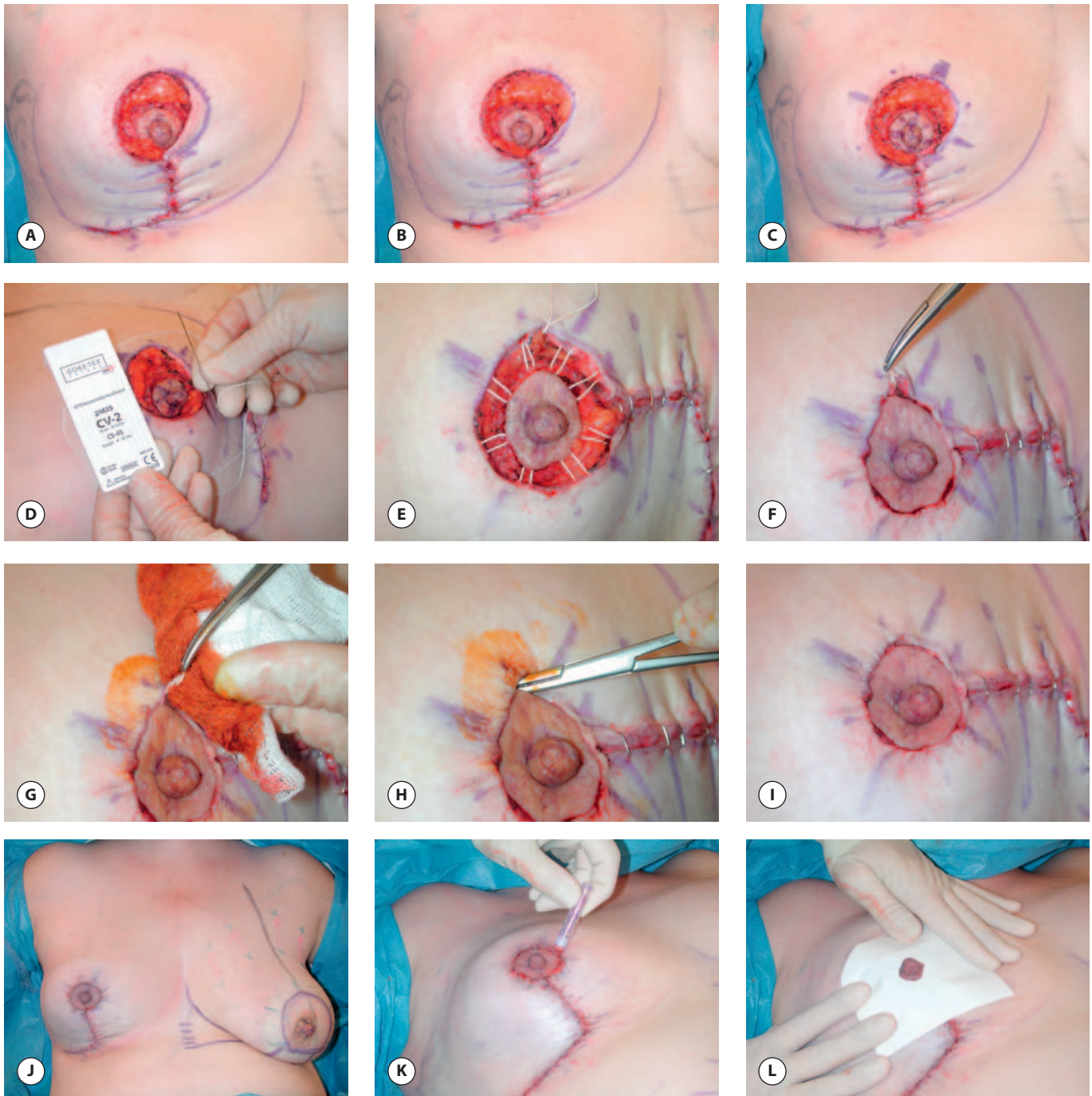


Figure 5.51 (A,B) In the upright position, if the periareolar defect is not round after closure of the vertical segment (A), additional debridement is performed to create a rounded opening (B). (C–H) The marks to guide the placement of the interlocking Gore-Tex suture are made (C) and the suture is placed incorporating eight separate fixation points in the areola

(D,E). After the purse string suture is conched down (F), the knot complex is dabbed with betadine (G,H) and buried under the medial skin flap. (I,J) A layered closure using a 4-0 absorbable monofilament suture is performed (I) to complete the procedure on the right (J).

of the de-epithelialized pedicle to meet the medial incision line (Figure 5.50 M–P). This maneuver creates a more contoured lower pole and obviates any potential for flattening along the incision line that can occur when the lower pole tissues are simply imbricated without any tissue release. The vertical incision is then closed in layers to prepare for placement of the purse string suture.

Control of the periareolar defect The patient is once again placed upright and the shape of the periareolar defect is assessed. If it is not round, additional skin and underlying parenchyma is removed to create a round opening, being sure to maintain a dermal shelf in the course of revising the defect (Figure 5.51 A,B). The markings for an interlocking Gore-Tex purse string suture are applied and the suture is placed as described

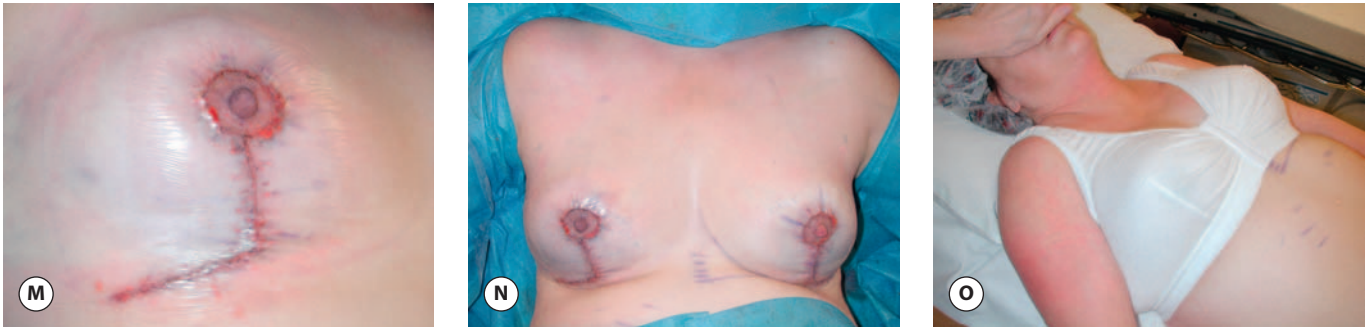

Figure 5.51 (Continued) (K–N) After skin closure, tissue glue is applied to the incision line (K) followed by an occlusive dressing (L,M) to complete the procedure (N). (O) A support garment is applied for comfort.

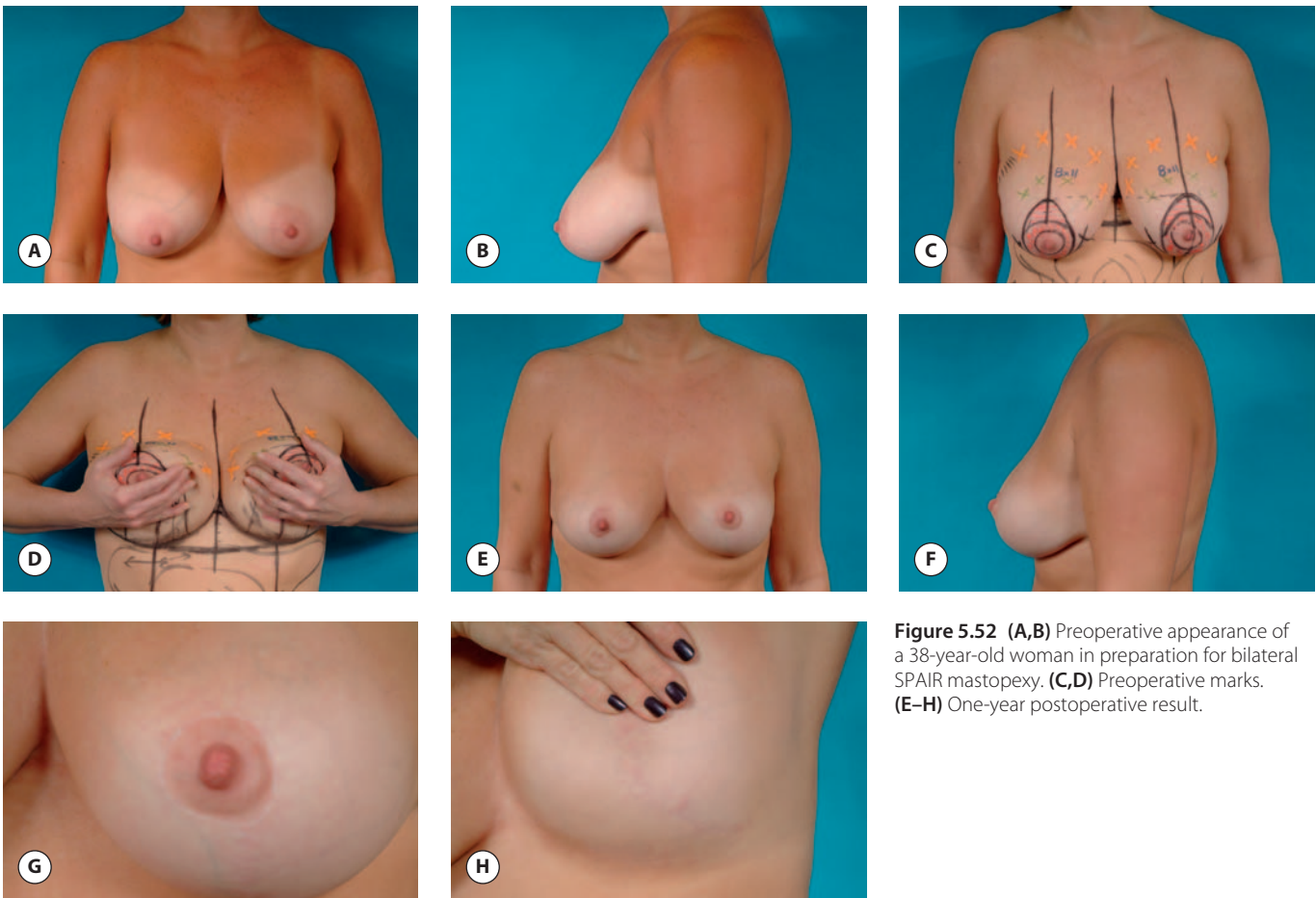


Figure 5.52 (A,B) Preoperative appearance of a 38-year-old woman in preparation for bilateral SPAIR mastopexy. (C,D) Preoperative marks. (E–H) One-year postoperative result.

previously (Figure 5.51 C–H). Final inset is performed in a layered fashion (Figure 5.51 I,J) and an occlusive dressing consisting of tissue glue (Dermabond-Ethicon Corporation) and Opsite is applied (Figure 5.51 K–N). A support garment is placed to provide support to the newly repositioned breasts (Figure 5.51 O).

Using this operative strategy, each of the elements that describe the ptotic patient is addressed. The positional ptosis and concavity in the upper pole are directly corrected by strategically developing the flaps and the pedicle, advancing them superiorly and suture fixating them into position. The redundant skin envelope is reduced using the circumvertical skin pattern along with the interlocking Gore-Tex suture technique to manage the periareolar opening. The SPAIR mastopexy technique is reserved

for patients who present with more severe cases of breast ptosis where the degree of breast descent on the chest wall is pronounced or the amount of internal reshaping required to provide the optimal result is considered extensive. While it is the most complex and involved of all the mastopexy procedures described in this chapter, it is also a very consistent and reliable technique for management of the ptotic breast (Figures 5.52–5.54).

Postoperative Care

With all of the described procedures, the postoperative care is generally the same. While a support garment will not create breast shape by itself, it can help support the newly positioned

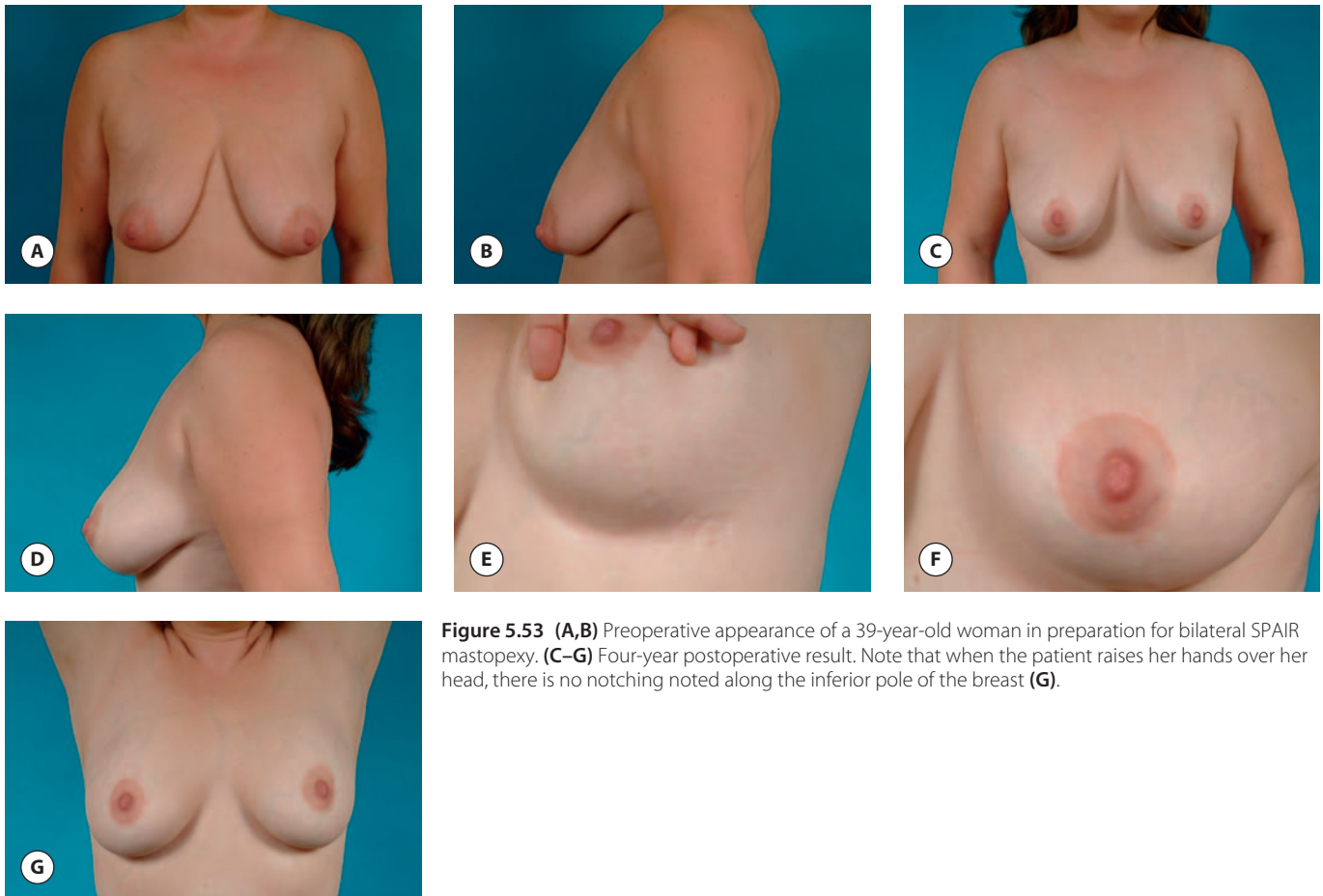


Figure 5.53 (A,B) Preoperative appearance of a 39-year-old woman in preparation for bilateral SPAIR mastopexy. (C–G) Four-year postoperative result. Note that when the patient raises her hands over her head, there is no notching noted along the inferior pole of the breast (G).

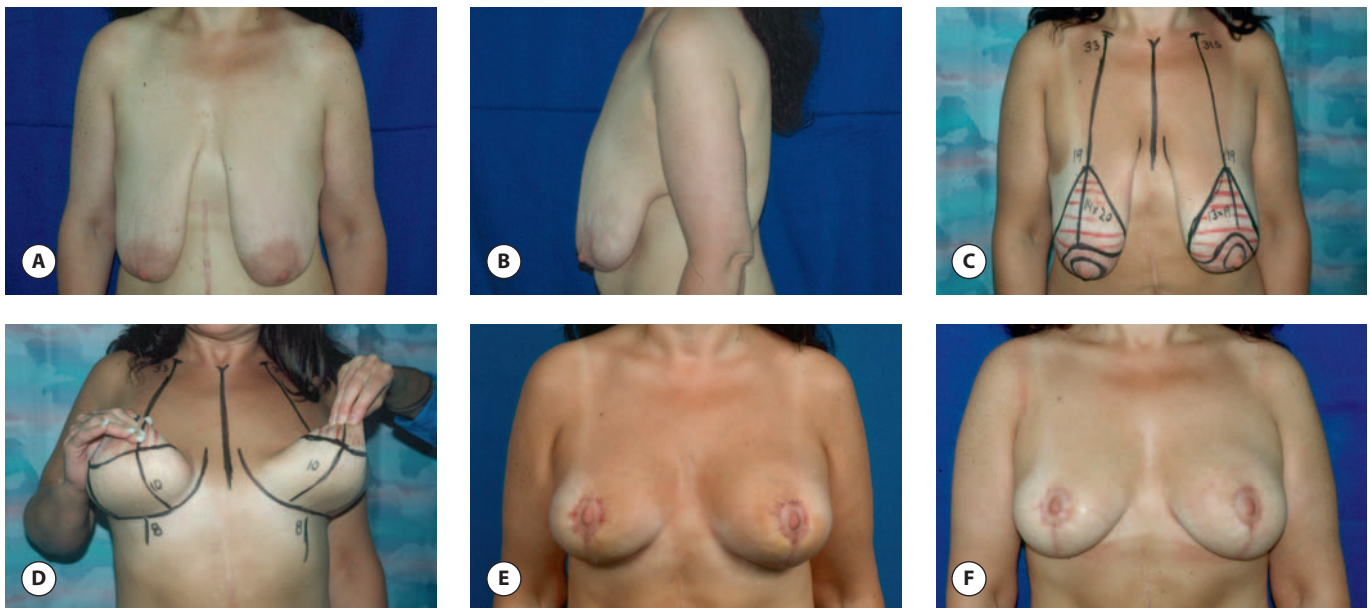


Figure 5.54 (A,B) Preoperative appearance of a 44-year-old woman in preparation for bilateral SPAIR mastopexy after undergoing a 150 pound (68 kg) weight loss after gastric bypass surgery. Due to the severe shape distortion, the full SPAIR procedure will be required to reshape the breast

adequately and take up the redundant skin envelope. (C,D) Preoperative marks. (E–G) Frontal view demonstrating the result at 1 week (E), 6 weeks (F) and 7 years (G).

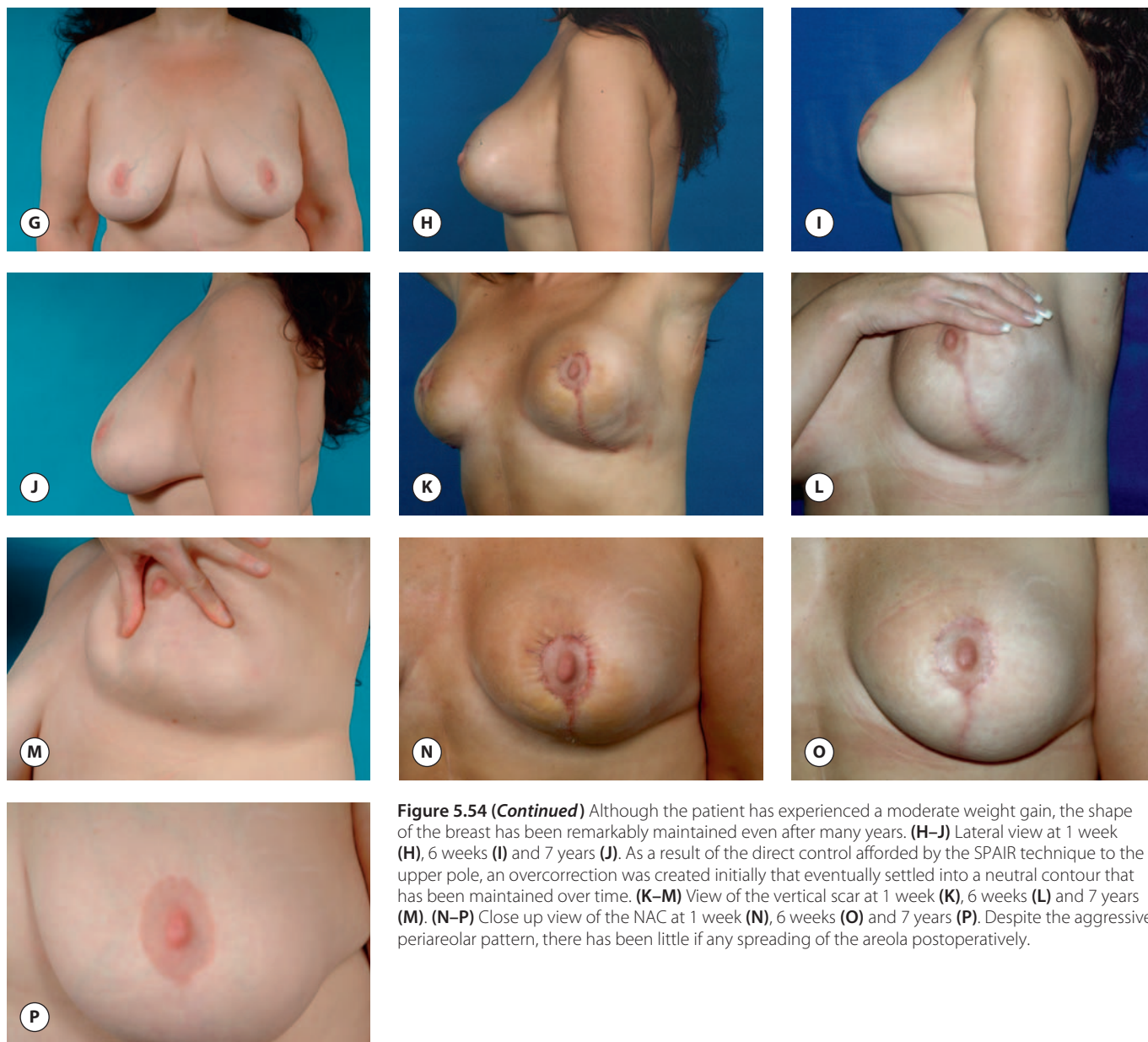


Figure 5.54 (Continued) Although the patient has experienced a moderate weight gain, the shape of the breast has been remarkably maintained even after many years. (H–J) Lateral view at 1 week (H), 6 weeks (I) and 7 years (J). As a result of the direct control afforded by the SPAIR technique to the upper pole, an overcorrection was created initially that eventually settled into a neutral contour that has been maintained over time. (K–M) View of the vertical scar at 1 week (K), 6 weeks (L) and 7 years (M). (N–P) Close up view of the NAC at 1 week (N), 6 weeks (O) and 7 years (P). Despite the aggressive periareolar pattern, there has been little if any spreading of the areola postoperatively.

breast flaps and pedicle until early scar formation begins to secure the tissue into position. Also, the mild compression afforded by the garment can help reduce swelling and result in greater patient comfort postoperatively. In cases where the vascular supply to the NAC is at all in doubt, a support garment is not applied until after the viability of the NAC has been assured. Opsite dressings and suture ends are clipped and removed at approximately 7 days

postoperatively and scar treatment with a vitamin E based ointment (Amology) is initiated and continued for 6 weeks. Return to work is allowed as early as 1 week, depending on the occupation, and return to athletic activities at 4–6 weeks. Follow up is arranged at 1 week, 6 weeks, 6 months and 1 year, after which full healing is deemed to be complete.

Summary

In this chapter, the attributes of an aesthetic breast that become altered as the breast becomes increasingly ptotic are identified and a 'tool chest' of available techniques are described that can be variably used to correct specific breast deformities as needed. By strategically combining these various

techniques, several specific procedures can be developed to treat progressively worsening degrees of breast ptosis. Skillfully applying these techniques can provide outstanding and long-lasting results for patients with breast ptosis.

Augmentation Mastopexy

Introduction

For many patients, breast hypoplasia and ptosis of either the gland or the nipple-areola complex (NAC) very often occur together. Perhaps the most common scenario for this presentation is the postpartum patient who presents after having delivered and breast-fed several children. After the transient increase in breast size that stretches out the supporting structures of the breast, involution may occur that then leaves the skin envelope variably underfilled and ptotic. Also, the NAC is very often positioned low on the breast mound (Figure 6.1). In these patients, simply performing a breast augmentation alone can result in a superiorly malpositioned implant in relation to the breast mound and an NAC position that remains far too low to be aesthetically acceptable (Figure 6.2 A,B). Conversely, performing a mastopexy alone may leave the remaining breast skin envelope underfilled as there is often not enough existing breast parenchyma to provide the result the patient is trying to achieve. For these reasons, to obtain the best result, it becomes necessary to combine the two procedures. While the rewards for such a surgical undertaking can be tremendously gratifying, the difficulty of the procedure is greater than for either operation alone. This is related to the fact that the two operations have opposing goals. Breast augmentation increases the volume of the breast and therefore expands

the surface area to accommodate the new volume. In contrast, mastopexy generally reduces the skin surface area in the process of accomplishing the lifting of the NAC. Therefore, any operative procedure designed to treat hypoplasia with ptosis must artistically coordinate these two competing surgical maneuvers in such a manner so as to allow a lifting of the NAC and a reduction in the skin envelope but yet leave behind enough skin to easily accommodate the new breast volume provided by the implant. Also,

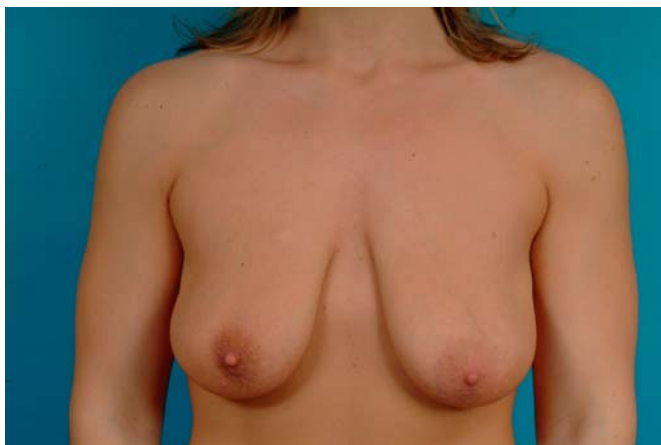

Figure 6.1 Appearance of a typical patient presenting for augmentation mastopexy. Not only is the skin envelope underfilled and ptotic, but the NAC is positioned low on the breast mound. Attempting to treat this patient with an augmentation alone will create a distorted breast appearance with an abnormal convexity in the upper pole of the breast, an inferiorly malpositioned NAC and, most likely, a persistent ptosis of the lower pole of the breast off the bottom of the implant, all of which results in a very unaesthetic breast contour.

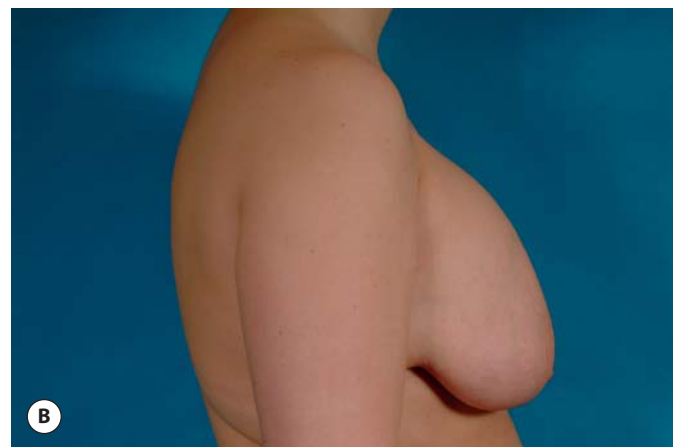
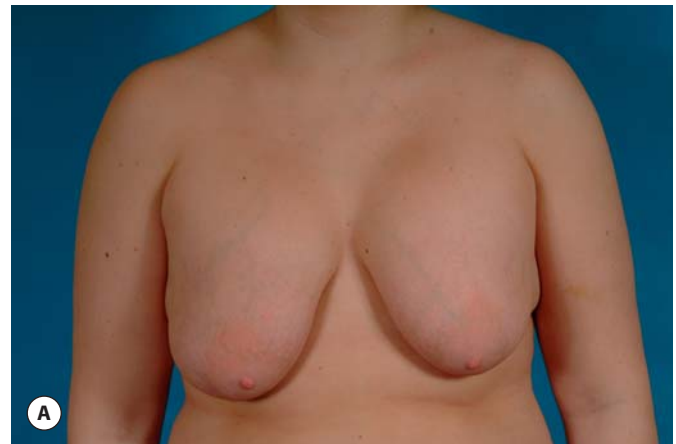
Figure 6.2 (A,B) Postoperative appearance of a patient after undergoing a bilateral transaxillary subpectoral breast augmentation in the face of significant ptosis of the gland and NAC. The implant is malpositioned superiorly and the main substance of the breast continues to fall away from the bottom of the implant, creating what is commonly called a 'double bubble' deformity. Also note there is essentially no lifting of the NAC as a result of implant placement and the low position of the NAC creates a decidedly unaesthetic and aged look to the breast.

Increasing degree of ptosis

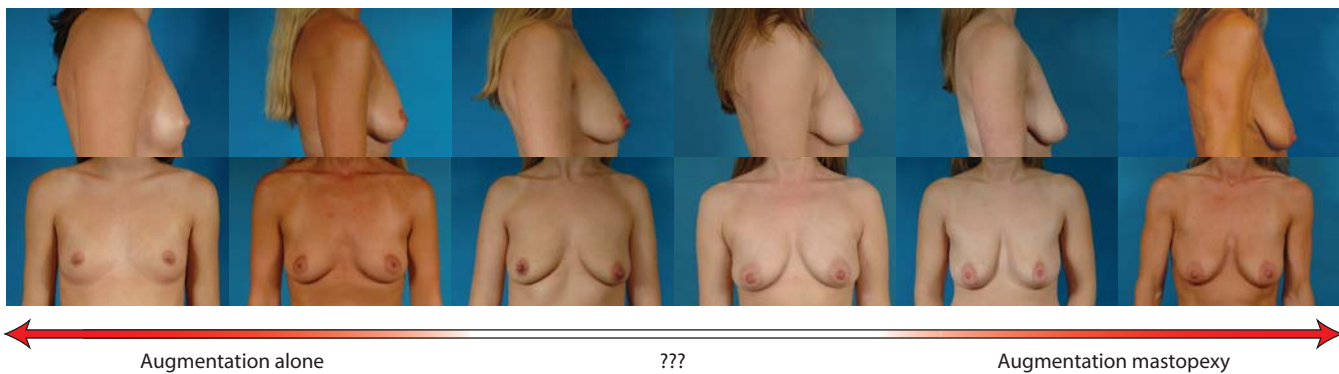


Figure 6.3 As demonstrated by the patient examples on the left, when the NAC is at or near the most projecting portion of the breast mound, the decision to proceed with an augmentation alone is relatively straightforward. Likewise, as demonstrated by the patient examples on the right, when the NAC is located well below the inframammary fold, the

decision to proceed with an augmentation mastopexy can be made with confidence. However, for the patients in the middle between these two extremes, the need for a mastopexy can be difficult to ascertain. Many patients presenting for breast augmentation fall into this category.

these goals must be accomplished in a manner that reliably preserves the blood supply to the NAC, results in the least amount of cutaneous scar possible and provides an aesthetic and long-lasting result, all in one operation. When viewed in this context, it is easy to understand why many surgeons believe augmentation mastopexy to be one of the most challenging aesthetic procedures performed on the breast. However, by strategically applying the principles outlined in the previous chapters on augmentation and mastopexy, a sound and reliable surgical plan can be developed that will allow these two procedures to be combined successfully.

Indications

In evaluating patients for breast augmentation, it is easy to recognize those patients who have an NAC position that is located well up onto the breast and who will do well with the simple placement of an implant. In these patients, the NAC will end up being located directly at the apex of the breast and an aesthetic relationship between the breast mound and the NAC position can be achieved. Conversely, it is also easy to identify those patients who have such profound ptosis that nothing short of a mastopexy will restore balance to the breast mound and nipple position. However, there are many patients who present for breast augmentation who seem to fall in between these two extremes (Figure 6.3). Not only is the breast deficient in volume, but the location of the NAC falls somewhere between the apex of the breast and the lower breast border. This anatomic relationship is extremely common, particularly in postpartum patients, and it presents for the plastic surgeon one of the most difficult decisions that must be made in the patient with breast hypoplasia, namely, when to add a mastopexy to the overall operative plan to achieve the best result. The difficulty in making this decision lies in the fact that ptosis is not an all or none phenomenon. How much ptosis in the position of the NAC that can be accepted and still have a reasonable result may well come down to a matter of personal preference for both the patient and the surgeon. Whether to accept a slightly less than ideal breast volume to NAC relationship must be weighed against the scar

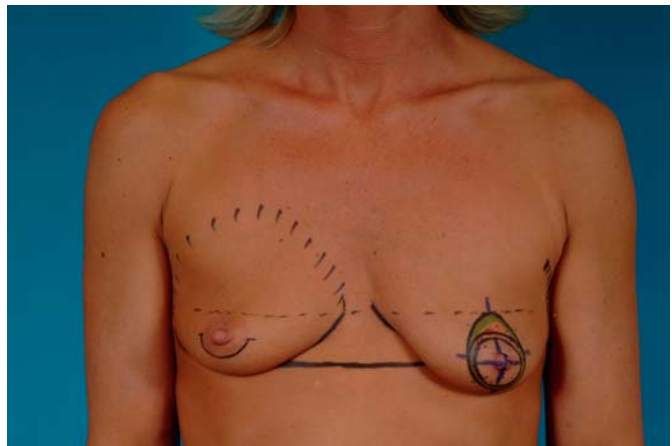


Figure 6.4 The preoperative appearance of a patient in preparation for a right-sided breast augmentation along with a left-sided augmentation mastopexy. By using the fold line drawn across the midline, it can be seen that the left nipple is either at or just below the level of the fold. This then indicates that the best result will be obtained, and the best chance for symmetry with the right breast will occur, if a periareolar lift is performed on the left side.

that would be created on the breast to accomplish the mastopexy. Many patients are reluctant to accept anything more than an inconspicuous inframammary fold or transaxillary scar and will therefore accept a slightly low NAC position to avoid an additional scar on the breast. However, determining exactly where the NAC will end up in relation to the remainder of the breast can be difficult as the simple act of adding an implant to the underfilled skin envelope of the breast will result in a minor lifting effect on the NAC and how much lift will be achieved can be difficult to predict. One preoperative anatomic relationship I have found useful in making the decision of whether or not to perform a mastopexy with the augmentation involves observing the position of the nipple in relation to the inframammary fold (IMF). This relationship is assessed by drawing a line across the chest connecting the most inferior extent of the two inframammary folds together and then standing back and observing where the nipple lies in relation to this fold line (Figure 6.4). In the

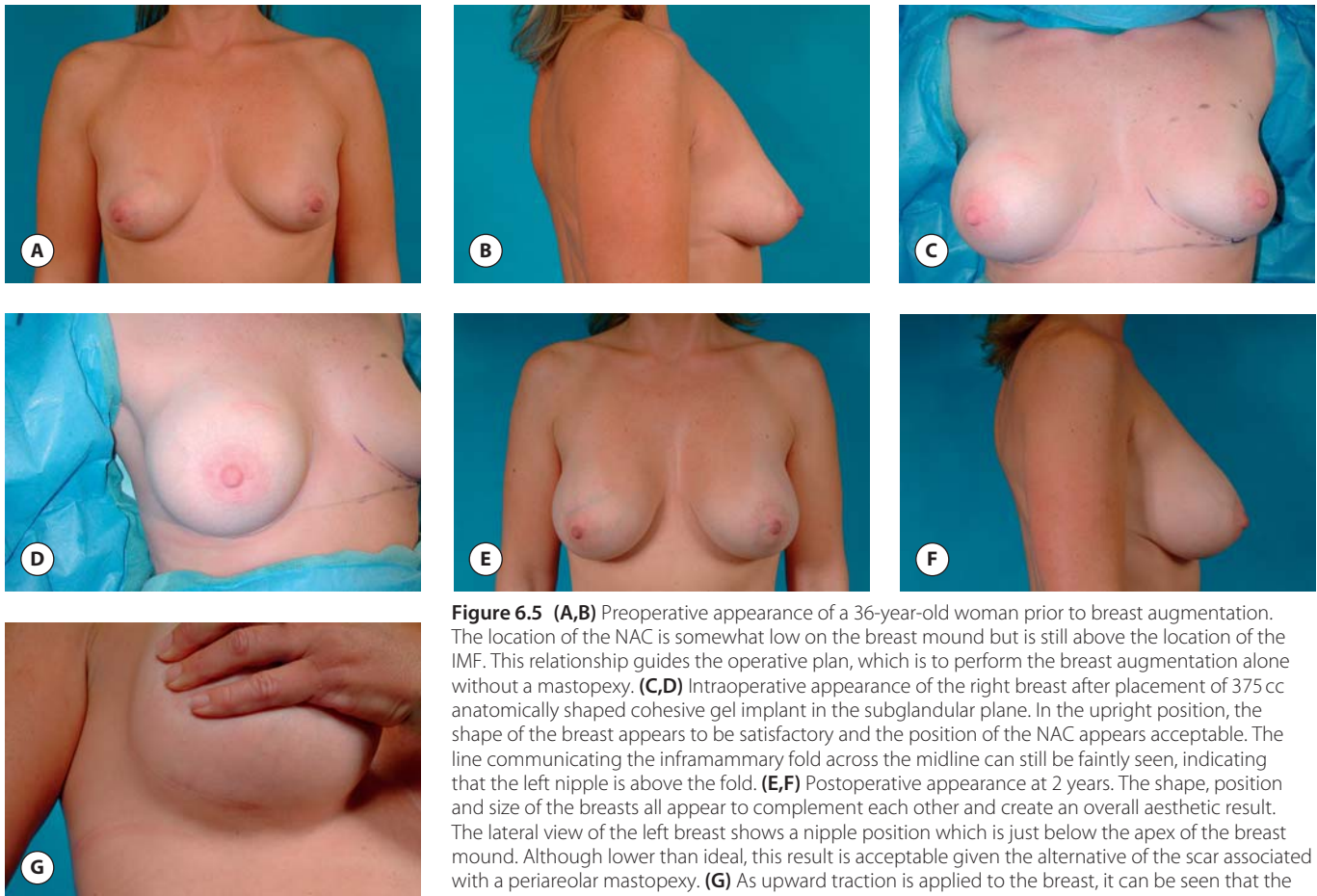


Figure 6.5 (A,B) Preoperative appearance of a 36-year-old woman prior to breast augmentation. The location of the NAC is somewhat low on the breast mound but is still above the location of the IMF. This relationship guides the operative plan, which is to perform the breast augmentation alone without a mastopexy. (C,D) Intraoperative appearance of the right breast after placement of 375 cc anatomically shaped cohesive gel implant in the subglandular plane. In the upright position, the shape of the breast appears to be satisfactory and the position of the NAC appears acceptable. The line communicating the inframammary fold across the midline can still be faintly seen, indicating that the left nipple is above the fold. (E,F) Postoperative appearance at 2 years. The shape, position and size of the breasts all appear to complement each other and create an overall aesthetic result. The lateral view of the left breast shows a nipple position which is just below the apex of the breast mound. Although lower than ideal, this result is acceptable given the alternative of the scar associated with a periareolar mastopexy. (G) As upward traction is applied to the breast, it can be seen that the scar remains in the IMF, which was not lowered, and the implant remains properly positioned under the breast mound.

case of a fold asymmetry, it is advisable to base decisions on the higher of the two folds as this will be the rate-limiting contour influencing the final result. By using this static line drawn across the midline, an accurate determination of where the nipple lies in relation to the fold can be made without the need to perform any lifting or other manipulation of the breast. Assuming the location of the IMF remains unchanged and stable postoperatively, it is then possible to use the nipple to fold relationship as a guide to assessing the need for a mastopexy. Three types of relationships are possible:

Nipple above fold – This is the easiest clinical presentation to manage as the vast majority of patients will achieve an aesthetic result with simply an augmentation alone. Of course, the higher the position of the NAC the better, as the ideal location for the NAC after the placement of the implant is at the most projecting portion of the new breast mound. However, even in patients where the nipple is just slightly above the fold, a reasonable result can be obtained using standard augmentation techniques and incision locations without the need for a mastopexy (Figure 6.5 A–G). One nuance that can be utilized in these types of patients is to lean more towards a periareolar approach for the breast augmentation rather than using an inframammary or transaxillary incision. In this fashion, should a periareolar mastopexy ever become necessary in the future, the extra scar burden is minimized since half the scar is already present.

One unique clinical situation where a mastopexy is indicated despite the fact that the nipple is above the fold involves the occasional patient who presents with pseudoptosis. In these cases, a significant portion of the gland can descend into the lower pole of the breast and yet the NAC is positioned normally. Typically, the skin envelope in the lower pole is redundant and underfilled. This clinical presentation is potentially troublesome and must be recognized preoperatively as simply inserting an implant in this type of patient can create an over-expansion of the lower pole and result in an exaggerated and overly rounded lower pole contour with an NAC position which appears to be superiorly displaced. Therefore, while these patients do not necessarily require a periareolar mastopexy, they can often benefit from a ‘vertical’ mastopexy where the redundant and ptotic skin and gland of the lower pole of the breast is plicated from the bottom of the areola down to the IMF to create the desired lower pole shape. By taking up the excess tissue in the lower pole of the breast, the position and shape of the breast mound are brought into better harmony with the position of the NAC. Also, the vertical incision affords ready access to the breast and can easily be used to develop the pocket and place the implant. This very straightforward and easily performed technique adds a powerful shaping strategy to the overall operative plan and can lead to excellent results in appropriately selected patients (Figure 6.6 A–G).

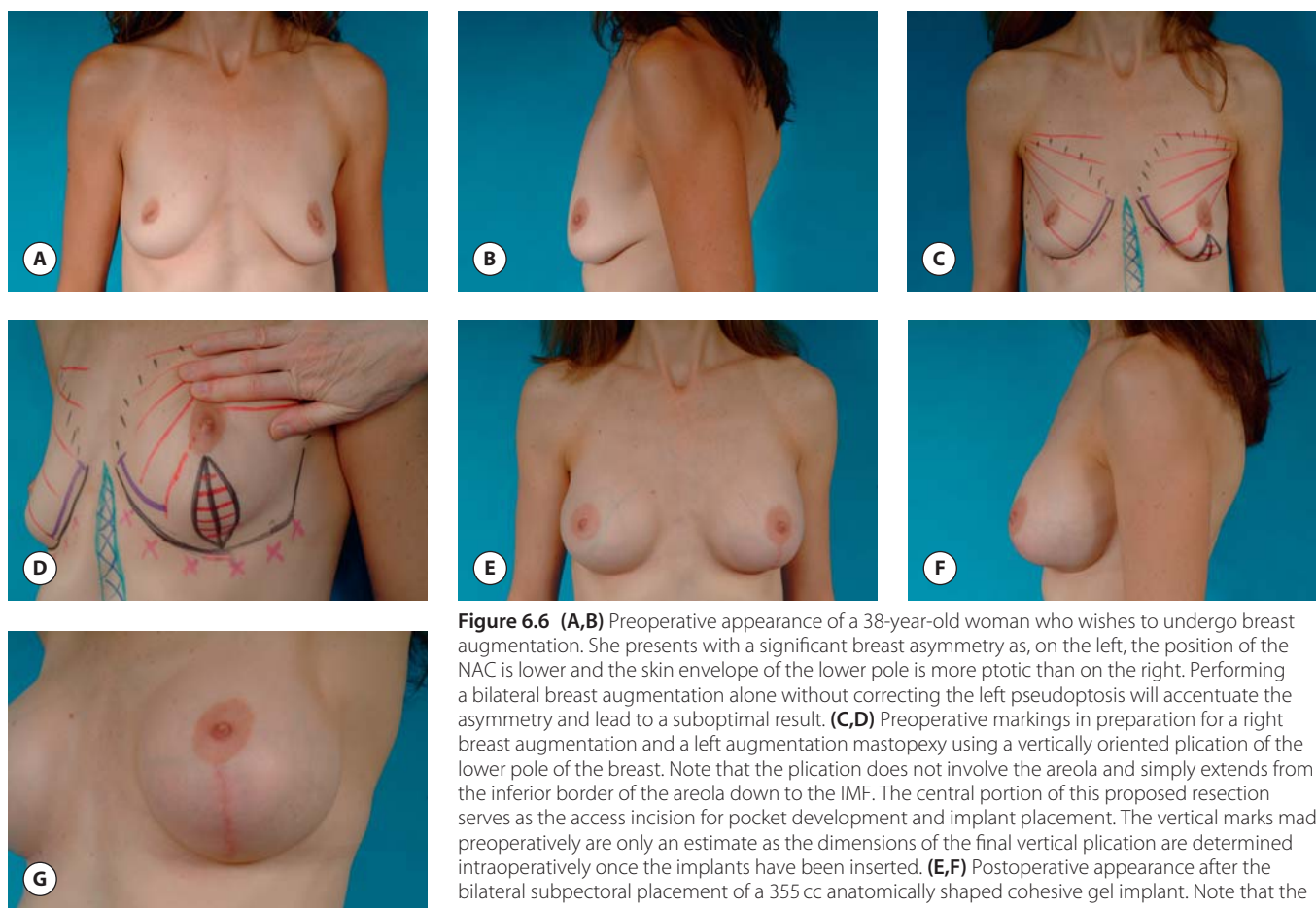


Figure 6.6 (A,B) Preoperative appearance of a 38-year-old woman who wishes to undergo breast augmentation. She presents with a significant breast asymmetry as, on the left, the position of the NAC is lower and the skin envelope of the lower pole is more ptotic than on the right. Performing a bilateral breast augmentation alone without correcting the left pseudoptosis will accentuate the asymmetry and lead to a suboptimal result. (C,D) Preoperative markings in preparation for a right breast augmentation and a left augmentation mastopexy using a vertically oriented plication of the lower pole of the breast. Note that the plication does not involve the areola and simply extends from the inferior border of the areola down to the IMF. The central portion of this proposed resection serves as the access incision for pocket development and implant placement. The vertical marks made preoperatively are only an estimate as the dimensions of the final vertical plication are determined intraoperatively once the implants have been inserted. (E,F) Postoperative appearance after the bilateral subpectoral placement of a 355 cc anatomically shaped cohesive gel implant. Note that the left breast is lifted and the base diameter narrowed as a result of the 'vertical' mastopexy. Overall, the symmetry in the size and shape of the breast as well as the position of the NAC is excellent. (G) The vertical scar typically heals very well and does not significantly detract from the overall aesthetic appearance of the breast.

Nipple at the fold – Many patients present with one or both nipples at or very near the level of the inframammary fold. It is in these patients that the decision to perform a mastopexy becomes difficult. Both the patient and the surgeon are eager to avoid placing any more scars on the breast than are absolutely necessary and this leads to an understandable reluctance on the part of both to proceed with mastopexy. One surgical maneuver that can be used in these types of patients is to lower the inframammary fold as part of the surgical approach. Although this can result in an overall breast contour that appears somewhat low on the chest wall, the volume provided by the breast implant ends up being properly positioned directly under the NAC. Therefore, as far as the location of both the NAC and the breast mound is concerned, the breast implant is aesthetically positioned. If the degree of lowering of the overall breast position is not excessive, this approach can be used to great advantage. In these cases, it is helpful to use an anatomically shaped gel implant to avoid a contour irregularity in the upper pole of the breast. The more natural upper pole slope of these types of devices helps prevent an unaesthetic step off from becoming visible as could occur with, for instance, a round saline device. Also, because the volume of a shaped cohesive gel implant is more aggressively distributed in the lower pole of the device, there is a more effective filling out of the lower pole of the breast, which tends to lift the NAC position to greater

extent than a round implant does (Figure 6.7 A–F). In essence, this strategy involves lowering the implant to fit the breast, which stands in contrast to the usual augmentation mastopexy strategy, which involves raising the breast and NAC to fit the implant. Not all patients are candidates for this approach as there is a limit as to how far the fold can be lowered without creating significant shape or breast position problems. For this reason, many patients who present with the nipple at the level of the fold benefit from the inclusion of a mastopexy done in conjunction with the breast augmentation.

When the nipple is located at the level of the fold and the decision has been made to incorporate a mastopexy with the breast augmentation, this can most often be accomplished with a periareolar approach alone. It can be rationalized that the resulting periareolar scar is only slightly more extensive than would be associated with a traditional periareolar incision alone for breast augmentation where the scar is limited to the lower half of the areolar border, and the improvement in the overall aesthetic appearance of the breast seems worth the extra scar burden. However, the major drawback to the periareolar approach remains the flattened breast contour that can result when the dimensions of the periareolar pattern become too large. Not only does the apex of the breast appear flattened, but the contour of the lower pole appears to bulge, which creates an overly rounded

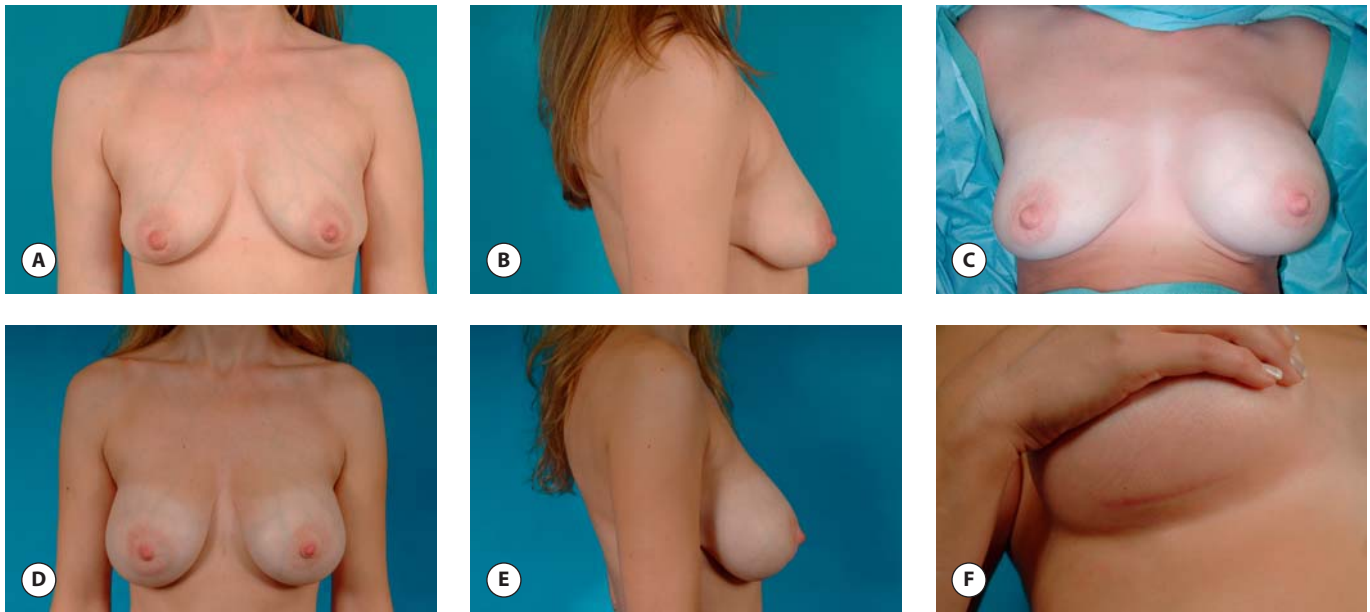


Figure 6.7 (A,B) Preoperative appearance of a 39-year-old woman in preparation for breast augmentation. The nipples are located directly at the level of the fold. If the inframammary fold is left intact, the implant will be superiorly displaced and will create excess upper pole fullness with ptosis of the gland and NAC off the bottom of the device. Therefore, the operative plan will include a slight lowering of the fold in an attempt to create an implant pocket that is located more under the ptotic breast mound and inferiorly displaced NAC, along with the use of an anatomically shaped gel implant to help control the contour of the upper pole. (C) Appearance of the left breast after placement of a 375 cc cohesive anatomically shaped silicone gel implant in the subglandular plane. Note that the fold has been

lowered as compared to the unoperated right breast, which allows the implant to be better positioned under the breast mound and NAC. (D,E) Appearance of the breasts 2 years after implant placement. Although the position of the breasts is low on the chest wall, the implant has maintained its position under the breast mound and the NAC is properly located at the point of maximal breast projection. In addition, the contoured upper pole of the implant has created a natural slope to the upper pole of the breast. Using this strategy, the scar associated with a periareolar mastopexy has been avoided. (F) Appearance of the inframammary scar. Note that the scar has ridden up onto the breast slightly as the fold was lowered to allow the implant to be properly positioned.

appearance. In selected cases, this bulging can be partially corrected by extending the lower portion of the periareolar pattern slightly inferiorly into the lower pole breast skin. By taking up this redundant skin into the periareolar pattern and combining it with a breast augmentation, the excess lower pole skin is reduced and it may be possible to avoid placing a vertical scar on the breast to correct this contour deformity. However, there is a limit to which this maneuver can be applied without creating a periareolar defect that is too large to be comfortably managed and, if the overall shape of the breast appears distorted or flattened in any way, it may become necessary to add a vertical component to the skin pattern. Typically, depending on the other variables involved for a particular patient, the NAC can be lifted up to 6 cm using a periareolar pattern alone without creating a significant deformity (Figure 6.8 A-C). Beyond 6 cm, a circumvertical skin pattern becomes increasingly necessary to appropriately take up the redundant skin envelope, particularly in the lower pole, and restore an aesthetic breast contour. This is a decision which is easily made at the time of surgery. After placement of the implant, the proposed periareolar pattern can be plicated into position to assess the breast contour. The effect of adding a vertical component can then be assessed. Typically, if the contour of the breast is improved even slightly by adding the vertical component, it is advisable to incorporate this into the pattern. Most patients will be more satisfied with an aesthetic breast contour with a vertical scar than a flattened and distorted result with only a periareolar scar. With adequate preoperative education, most patients can accept the vertical scar as a necessary part of their procedure.

Nipple below the fold – This is the most severe situation and represents the greatest mismatch in the location of the breast mound in relation to the NAC. Typically, there is a redundant and ptotic skin envelope associated with this combination of variables and the surgical plan must include all of the critical elements involved in surgical correction including adding the appropriate volume to the breast with the implant, taking up the redundant skin envelope and lifting the position of the NAC. In these cases, the operative strategy can be summarized as keeping the inframammary fold in position and placing the breast implant anatomically on the chest wall and then lifting not only the NAC but the entire breast up and over the implant to bring the implant and the breast into better positional harmony. Although there is the occasional patient who can have all of these surgical goals reached with only a periareolar approach, most patients in this category will need a circumvertical skin pattern to achieve the optimal result. The significant advantage afforded by this technique relates to the addition of the vertical component to the skin pattern. The plication of the lower pole in a vertical direction is one of the most powerful shaping maneuvers that can be performed on the soft tissues of the breast. It effectively narrows a widened breast base diameter, elevates the NAC and increases the projection of the breast, all with one simple maneuver. In essence, the vertical plication serves variably to reverse all of the changes that result from the loss of structural support which leads to breast ptosis in the first place. Also, the incision can be used to access the underside of the breast to place an implant into either the subpectoral or the subglandular position. Knowing

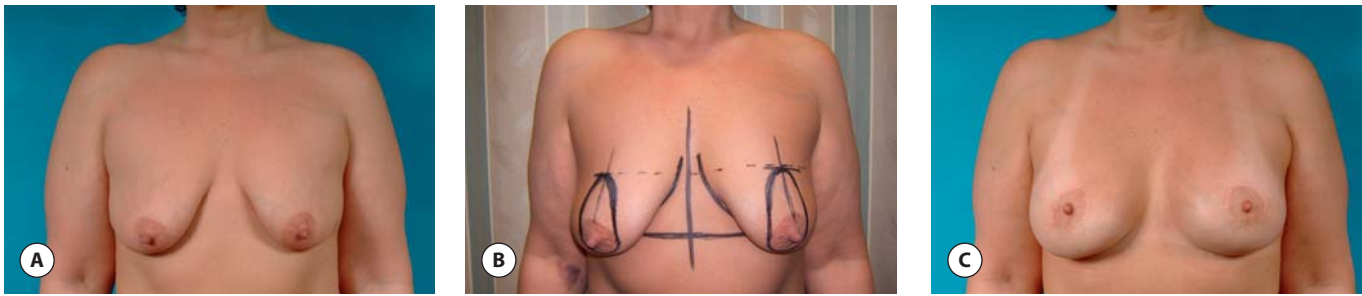

Figure 6.8 (A) Preoperative appearance of a 43-year-old woman with ptosis who presents for breast augmentation. (B) Preoperative markings with the inframammary fold line drawn across the midline demonstrate that the left nipple is just at the level of the fold while the right nipple is below the fold. This along with the ptotic nature of the skin envelope make the strategy of lowering the fold in an attempt to place the implant under the ptotic breast mound an unattractive option as the likelihood of a persistent breast distortion with excess upper pole fullness and pseudoptosis of the lower pole of the breast becomes a significant possibility. To achieve the optimal result, a lifting of the NAC will be required to position these tissues properly over the breast implant. The periareolar pattern is diagrammed to position the NAC at what is projected to be the apex of the breast and the markings are then joined around and under the existing NAC removing as little medial and lateral breast skin as possible. It is important to diagram the top of the periareolar pattern high enough to lift the NAC adequately

and avoid a low-riding NAC position postoperatively. In patients such as this, it is not unusual for this distance between the IMF line and the top of the periareolar pattern to exceed 6 cm or more. This depends on a stable and properly positioned IMF. (C) The result 6 months after the placement of a 300 cc smooth round silicone gel implant in the subglandular plane demonstrates a full rounded breast with an aesthetic shape and good symmetry. The breast mound and NAC have been lifted and are now more anatomically positioned over the volume provided by the breast implant. However, the scar around the NAC is irregular, which does detract somewhat from the quality of the overall result. The degree of lift using a periareolar pattern alone demonstrated by this case likely represents the limit to which this strategy can be used without creating an unmanageable periareolar closure. When more lift is needed, adding a vertical component to the skin pattern is required to prevent any possible compromise in either the shape of the breast or the quality of the scar around the NAC.

ahead of time that the vertical component will be used also removes any uncertainty in the scar pattern that is created, which allows the patient to be fully educated about her result. For these reasons, although these types of patients are the most challenging in terms of the degree of preoperative deformity, they are also the most straightforward as far as surgical planning is concerned and, in that respect, easier to correct surgically (Figure 6.9 A–H).

Staging

Despite the complexity of the procedure, most surgeons attempt to perform augmentation mastopexy as a single operation. The advantages associated with this combined approach include the cost savings associated with one operation rather than two, as well as the safety and convenience factor of not having to come back for a second procedure. Certainly, it is possible and entirely acceptable to perform augmentation mastopexy as a single procedure. With appropriate operative planning followed by adept surgical technique, outstanding results can be obtained. However, of all the aesthetic operations performed on the breast, augmentation mastopexy is arguably the most complicated. As such, it is not surprising that there is a higher complication and revision rate than that associated with other simpler breast procedures. To help reduce these potential complications and improve the reliability of the procedure, a staged approach to augmentation mastopexy has been advocated. Typically, this planning strategy involves performing the mastopexy first to allow the new skin envelope and nipple position to settle and heal completely. At a later date, generally 6–12 months later after all swelling has subsided, the implant is inserted and the aesthetics of the breast and/or NAC are revised as needed to provide for the optimal result. This strategy allows the size and shape of the breast implant to be chosen with greater confidence since the skin envelope dimensions and NAC position are now stable. Any potential for there to be a mismatch between

the breast and the implant is minimized due to the increased control the staged approach provides in the decision-making process (Figures 6.10 A–R and 6.11 A–F). As an alternative, it is possible to reverse the order of the procedures and perform the augmentation first and then follow up a later date with the mastopexy. This strategy can work well for patients who present with mild ptosis and will require only a minimal breast lift. In these cases, it is reasonable to proceed with the augmentation first and assess the quality of the result after full healing has taken place. If there is any persistent ptosis at that point, then a small periareolar mastopexy can be performed to obtain the optimal result. This strategy is utilized only with the full understanding of the patient that two procedures may well be required to obtain the desired result. For patients with a greater degree of ptosis, the implant first, mastopexy second strategy has less appeal as the degree of deformity that is present after the breast augmentation may be significant and waiting for the breast to settle before performing the mastopexy may be unacceptable to many patients.

Although the staged approach may facilitate easier overall decision making, most patients will be reluctant to undergo two operations, for both cost and convenience reasons. While I have at times performed augmentation mastopexy as a staged procedure, it has long been my approach to perform augmentation mastopexy as a single operation. It is my view that a certain percentage of patients will require a revision to achieve the optimal result and such revisions will be easier to perform with less operative manipulation involved if most of the work was done at the initial procedure. Of course, it is important to completely educate the patient about these issues ahead of time to provide fully informed consent about what can be expected postoperatively.

Technique

The surgical technique for augmentation mastopexy requires the application all of the elements previously described for either

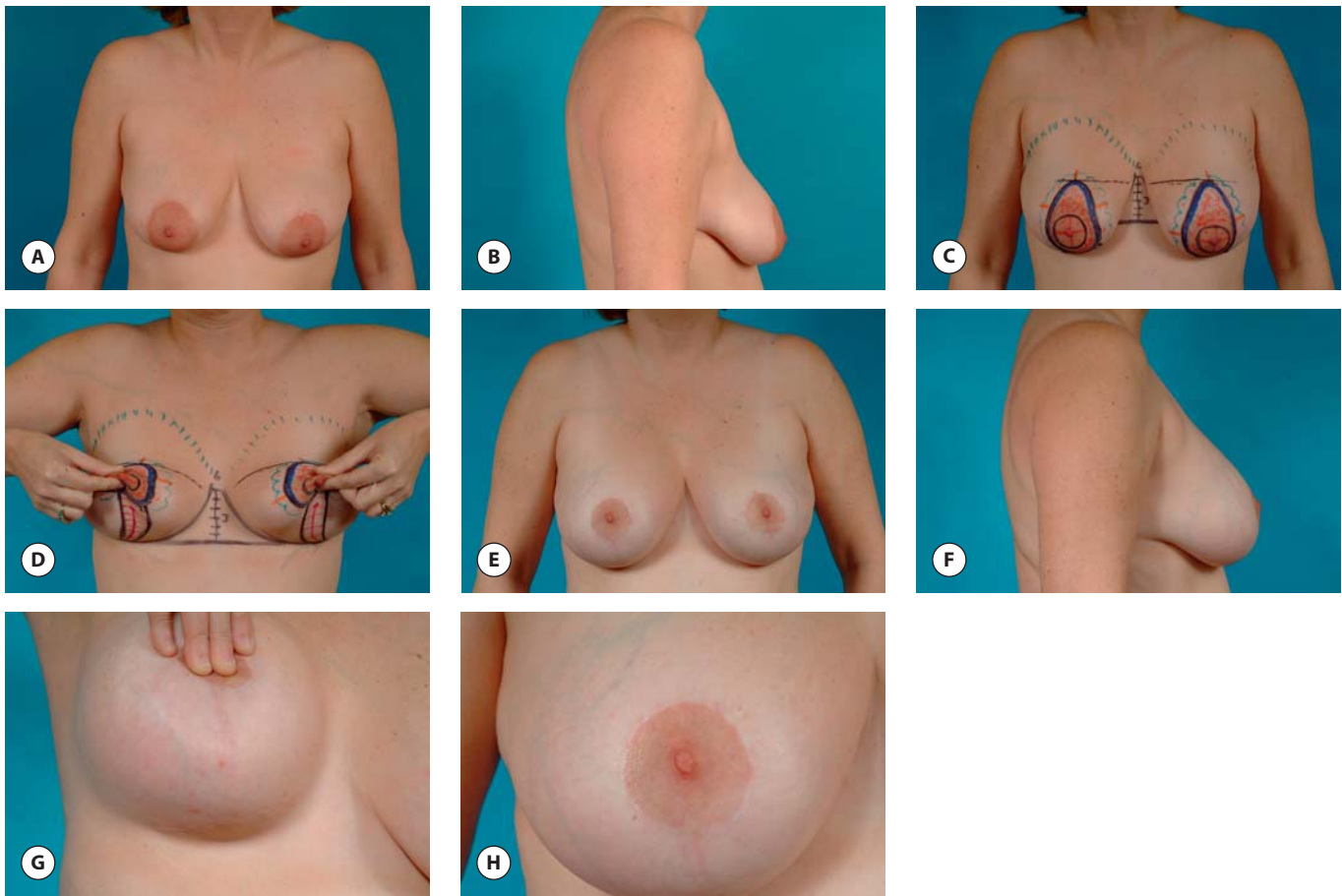


Figure 6.9 (A,B) Preoperative appearance of a 41-year-old woman in preparation for circumvertical augmentation mastopexy. (C,D) Preoperative markings demonstrate that the nipples are well below the IMF, indicating the necessity for the circumvertical approach. The top of the periareolar pattern is drawn 5 cm above the fold line and the remainder of the pattern skirts the existing landmarks of the native areola. The vertical component is estimated and marked such that the midline of the vertical pattern runs directly down the central meridian of the breast.

This meridian, marked in red, will serve as the access incision for pocket development and placement of the breast implant. (E,F) Result at 2 years after the subglandular placement of a 275 cc smooth round silicone gel implant on the right and a 250 cc implant on the left demonstrates a full rounded breast with aesthetic contours and good symmetry. The NAC has been lifted and there is no excess fullness in the upper pole of the breast. (G,H) Close-up views of the vertical and periareolar scars reveal a faded appearance with no evidence of widening or hypertrophy.

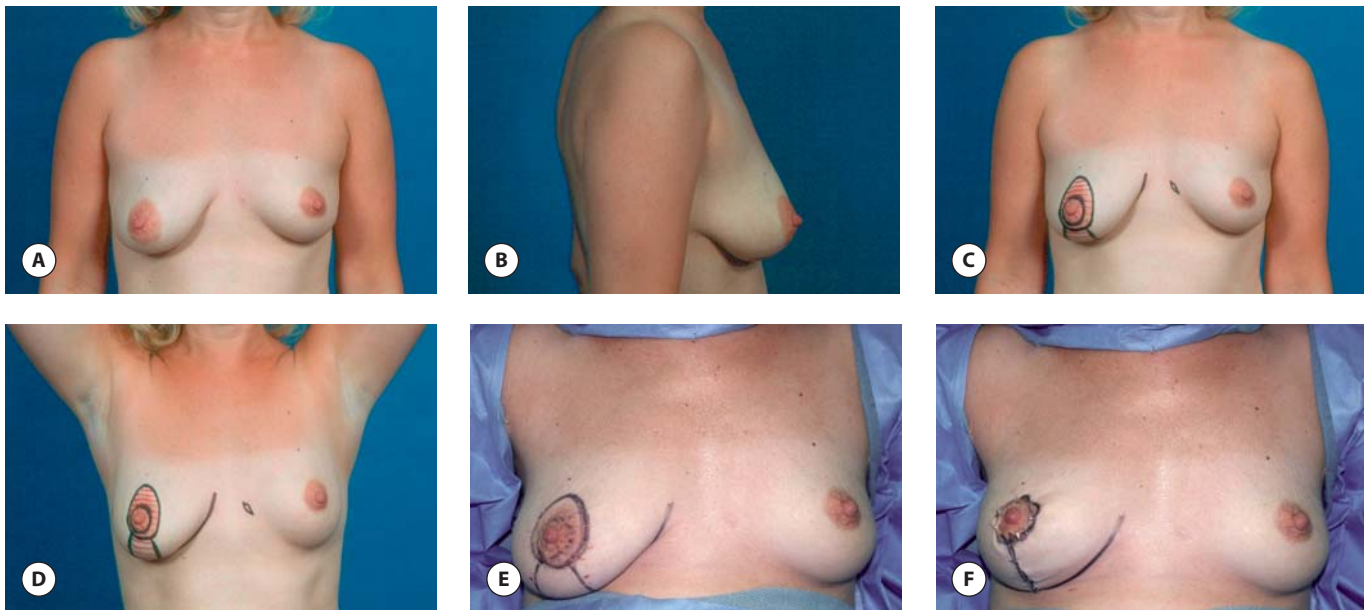


Figure 6.10 (A,B) Preoperative appearance of a 39-year-old woman in preparation for a right-sided equalizing circumvertical mastopexy. The right breast is ptotic as compared to the left and the areola has a larger diameter. (C,D) Preoperative marks demonstrating the proposed circumvertical skin

pattern. (E) On the operating table, the ptotic appearance of the right breast creates a significant asymmetry as compared to the left. (F) After plication of the skin along the planned lines of incision with staples, the accuracy of the proposed pattern is confirmed before any actual incisions are made.

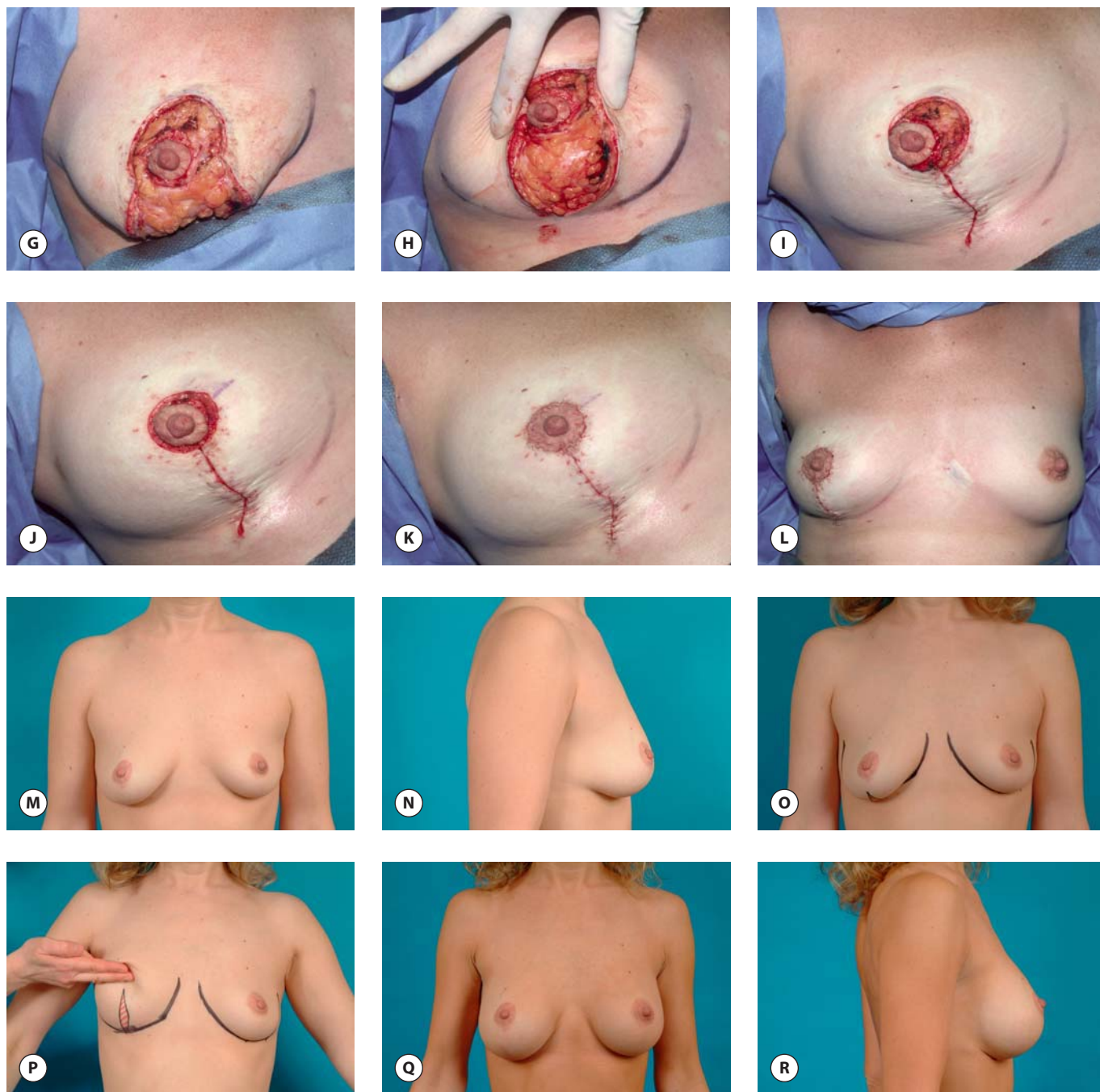


Figure 6.10 (Continued) (G,H) Appearance of the breast after removal of skin only from within the limits of the planned resection pattern. No undermining has been performed. (I–K) After closure of the vertical segment, the dimensions of the periareolar opening are greatly reduced (I). The periareolar Gore-Tex purse string suture is then placed and cinched down (J) and the areola inset into the periareolar opening (K). (L) At the conclusion of the procedure, excellent symmetry has been achieved with the opposite unoperated breast. (M,N) Result at 2 years demonstrates a marked improvement in the overall symmetry of the breasts; however, the volume is lacking. (O,P) Preoperative marks in preparation for bilateral

breast augmentation. On the left, an inframammary fold incision will be used and, on the right, the lower portion of the existing vertical scar will be used as access to the breast. (Q,R) Seven-month postoperative result after the bilateral placement of 255 cc anatomically shaped cohesive silicone gel implants in the subglandular plane, demonstrating excellent symmetry, a full pleasing lower pole and a natural upper pole contour. Using a staged approach by first correcting the asymmetry on the right and then at a later time adding volume bilaterally allowed precise decisions to be made that ensured a symmetric postoperative result.

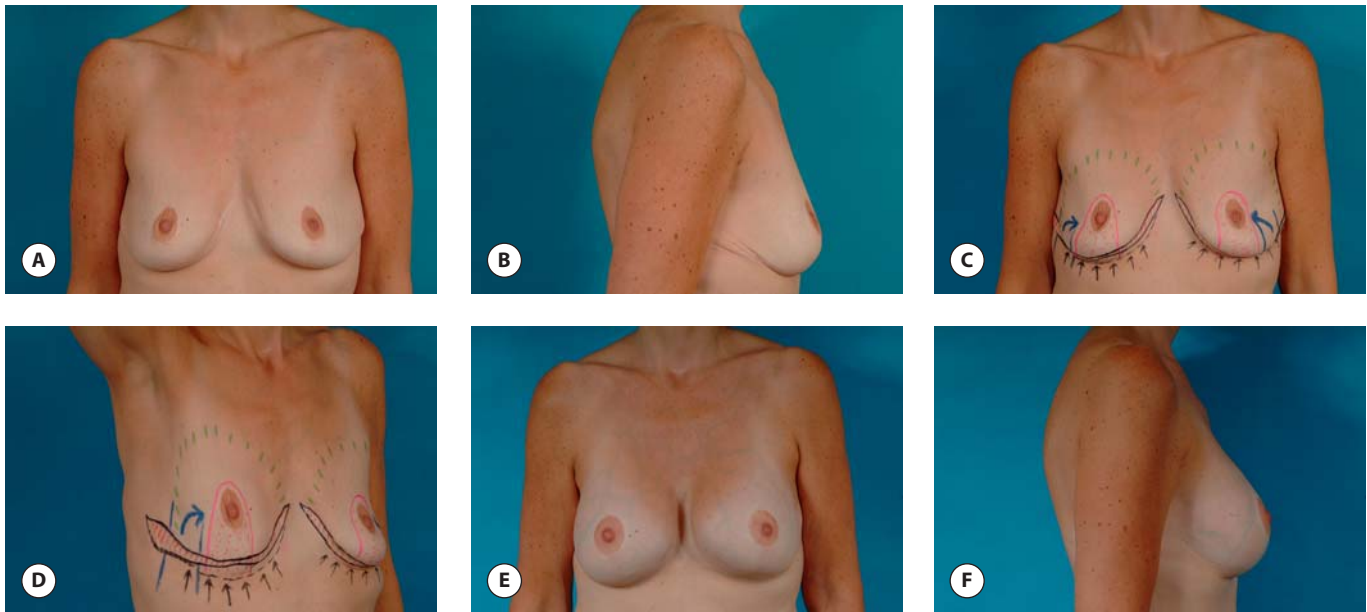


Figure 6.11 (A,B) Preoperative appearance of a 45-year-old woman who underwent an inverted T pattern inferior pedicle breast reduction 4 years previously. She then lost 80 pounds (36 kg) after undergoing a gastric bypass 3 years later with her weight dropping from a maximum of 228 pounds (103 kg) to a relatively stable 150 pounds (68 kg). She presents concerned about the loss of volume in her breasts and the widened scars present along the medial and lateral portions of the inframammary fold incision. (C,D) Preoperative marks in preparation for augmentation mammoplasty along with revision of the inframammary fold scar. The access to the breast will be through the lateral inframammary fold incision (blue arrow) with the pocket being developed in the subglandular plane. The attachments to the central inferior breast will be preserved as much as possible to respect the integrity of the inferior pedicle, which was used during the original

breast reduction to maintain blood supply to the NAC (pink outline). Medial and lateral to the pedicle, the inframammary fold will be sutured back up superiorly by tacking Scarpa's fascia down to the chest wall to help elevate and redefine the inframammary fold (black arrows). An anatomically shaped cohesive gel implant will be used to help control the shape of the upper pole of the breast. The proposed limits of pocket dissection are outlined in green. (E,F) Appearance 3 years after placement of a 395 cc anatomically shaped cohesive gel implant in the subglandular plane. The skin envelope has been filled out and a pleasing shape restored to the breast. This case represents an example of an unplanned, but successful, staged augmentation mastopexy where the skin envelope was reduced and the NAC raised at the first procedure and then, after the weight loss, the volume was finalized with the placement of the breast implant.

procedure alone; however, combining these two operations does require several important alterations in planning and execution. Four basic techniques will be described including periareolar augmentation mastopexy, circumvertical augmentation mastopexy, inverted T augmentation mastopexy and an advanced method of breast shaping called resuspension circumvertical augmentation mastopexy.

Periareolar Augmentation Mastopexy

Indications Patients who present with an inferiorly malpositioned NAC and do not demonstrate a marked excess in the skin envelope are excellent candidates for periareolar augmentation mastopexy. In these patients, the periareolar pattern is utilized predominantly to lift the NAC and only a minor reduction in the surface area of the skin envelope is performed. The limits of the technique are determined by many other variables including the size of the breast, the laxity of the skin and the degree to which the NAC needs to be repositioned. For this reason, it can be difficult to apply any specific recommendations about when to apply just a periareolar lift versus moving to a circumvertical approach. Basically, the decision becomes more of an artistic judgment on the part of the surgeon. If the shape of the breast that results after the periareolar lift appears inordinately rounded in the lower pole, or the aesthetics of the NAC become compromised, it is best to add a vertical component to the periareolar pattern.

Marking The patient is marked in the upright position. The most important landmark to determine is the top of the periareolar pattern. This is done first by gently pinching the top of the proposed areolar incision and manually lifting it up onto the breast until a point is reached where the NAC is positioned directly at the apex of the breast mound. The skin is then marked at this point, which represents the 12 o'clock position of the periareolar pattern. By releasing the NAC and letting it fall down, the amount of skin between the top of the areola and the upper margin of the periareolar incision that will need to be de-epithelialized can be seen (Figure 6.12 A-I). The same point is then identified on the opposite breast and care is taken to ensure that the apex of the periareolar pattern has been symmetrically located on each breast. As a check to the proper location of the top of the periareolar pattern, a measurement from the inframammary fold line that runs across the chest wall extending from one breast to the other to a similar line connecting the tops of the matching periareolar marks can be made. This measurement is often 6 cm or more, depending on other variables including IMF location, breast size and skin elasticity. The fact that the top of the periareolar pattern can extend this far above the IMF can be very surprising and even alarming to many surgeons as, historically, one of the more distressing complications associated with augmentation mastopexy is bottoming out of the breast, creating an expanded lower pole and a superiorly displaced NAC. With the techniques concerning management of

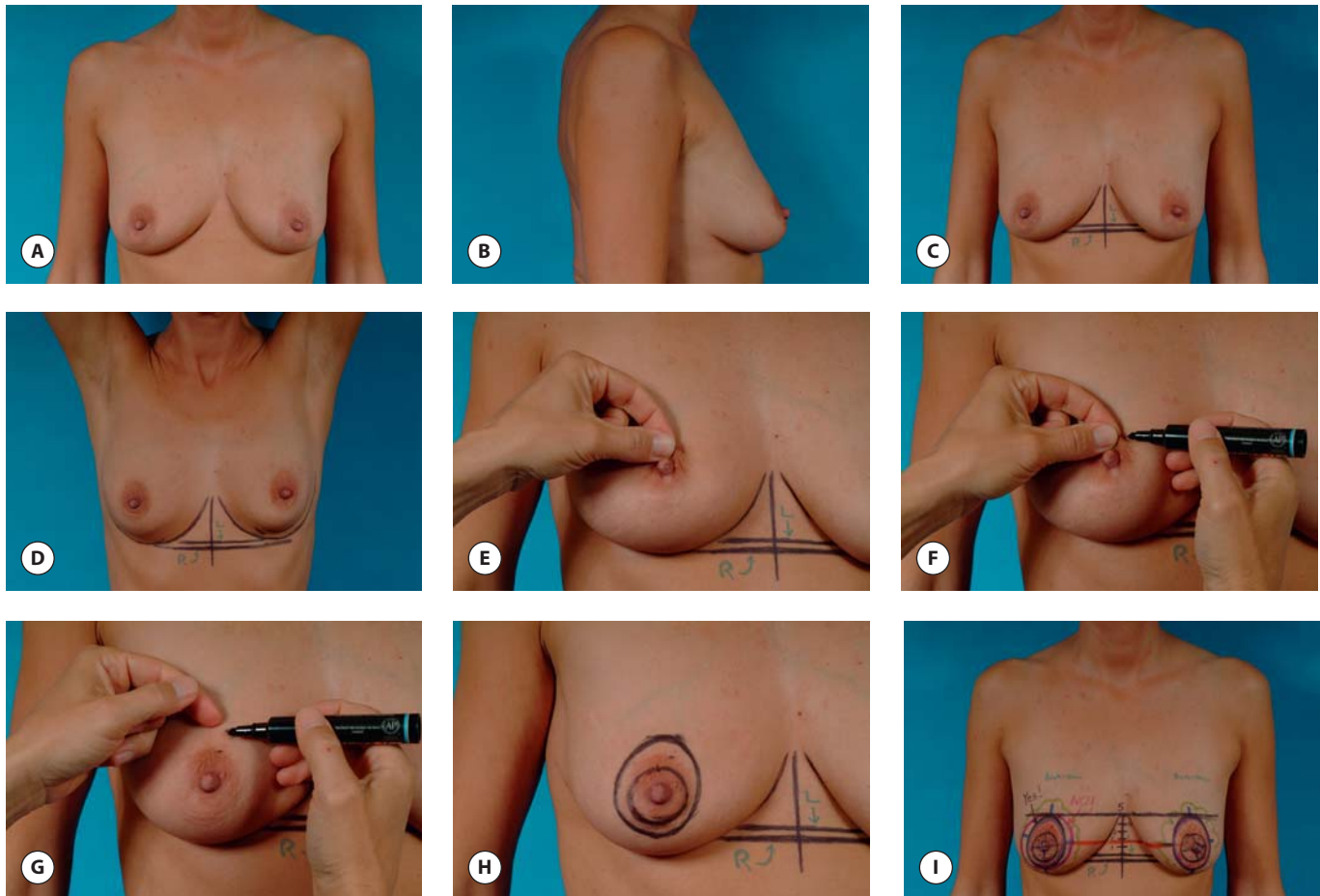


Figure 6.12 (A,B) Preoperative appearance of a 44-year-old woman in preparation for augmentation mastopexy. Despite the fact that the nipples are above the fold, this patient desires a periareolar lift to provide the best result possible and is accepting of the periareolar scar. (C,D) When the inframammary fold lines are drawn across the chest wall, it can be seen that the left IMF is higher than the right. In this circumstance, the fold asymmetry can be managed by either lowering the fold on the left or raising the fold on the right. It is far easier to lower the IMF rather than raise it, therefore, typically, this is the strategy that is recommended as long as the overall position of the breast is not lowered to excess. (E–H) To estimate the position of the NAC, the right breast is chosen as this is the breast which demonstrates the fold position which will be used to set the position of both breasts after the left fold is lowered. The top of the proposed periareolar incision is grasped and lifted up until it is positioned at the apex of the breast. Using a surgical marker, this point is marked and the breast is allowed to fall away. This identifies the top of the periareolar pattern. The periareolar oval is drawn such that it skirts the margins of the native areola medially, inferiorly and laterally as it joins with the superior periareolar mark. The proposed areolar incision mark is estimated and

diagrammed. At surgery, this mark will be finalized and drawn in with the areola under maximal stretch such that it measures 40 mm. (I) The final marks in preparation for periareolar augmentation mastopexy. The limits of the outer skin incision are noted in black. It is important to note that only a minimal amount of skin is removed medially and laterally in an attempt to reduce the stresses placed on the periareolar closure after placement of the implant. This results in an oval-shaped pattern as opposed to the rounded pattern (pink mark), which, if used, could create a tight periareolar closure. The purple mark just inside the proposed periareolar incision delineates the dermal shelf which will be created to support the interlocking Gore-Tex suture. The blue orientation lines and dots in the areola and outside the periareolar incision will be used to guide the placement of this suture such that the discrepancy between the two incisional diameters is taken up evenly. The lime green mark outlines the limits of undermining of the edges of the periareolar opening just under the dermis to allow tissue redistribution after the purse string suture is cinched down. Note that, in relation to the higher of the two folds, the amount of lift of the top of the periareolar pattern is 5 cm. It can also be noted that, preoperatively, the nipple is approximately 2 cm above the level of the left fold.

the inframammary fold described previously, it must be recognized that the location of the inframammary fold will not change as long as the attachments of Scarpa's fascia to the inferior border of the breast remain intact. As such, the IMF provides a solid foundation to the breast that will not descend in an unanticipated fashion postoperatively. Certainly, the skin can stretch but, because of the support provided by the fold, a more secure NAC location can be predicted and experience has shown that the degree of lift above the fold line can be up to 6 cm for many patients or the resulting NAC position will be low in relation to

the rest of the breast mound (Figure 6.13 A–E). While this measurement is important, it must be realized that, with this technique, the final determinant that governs the placement of the top of the areola is the manual lifting maneuver, as using artistic judgment to determine the location of the NAC ultimately will be more accurate than adhering to any sort of fixed measurement strategy. If the distance from the top of the proposed areolar incision and the apex of the periareolar pattern is less than 3 cm, the procedure should be very straightforward. If the distance measures 3–6 cm, the increased periareolar dimensions

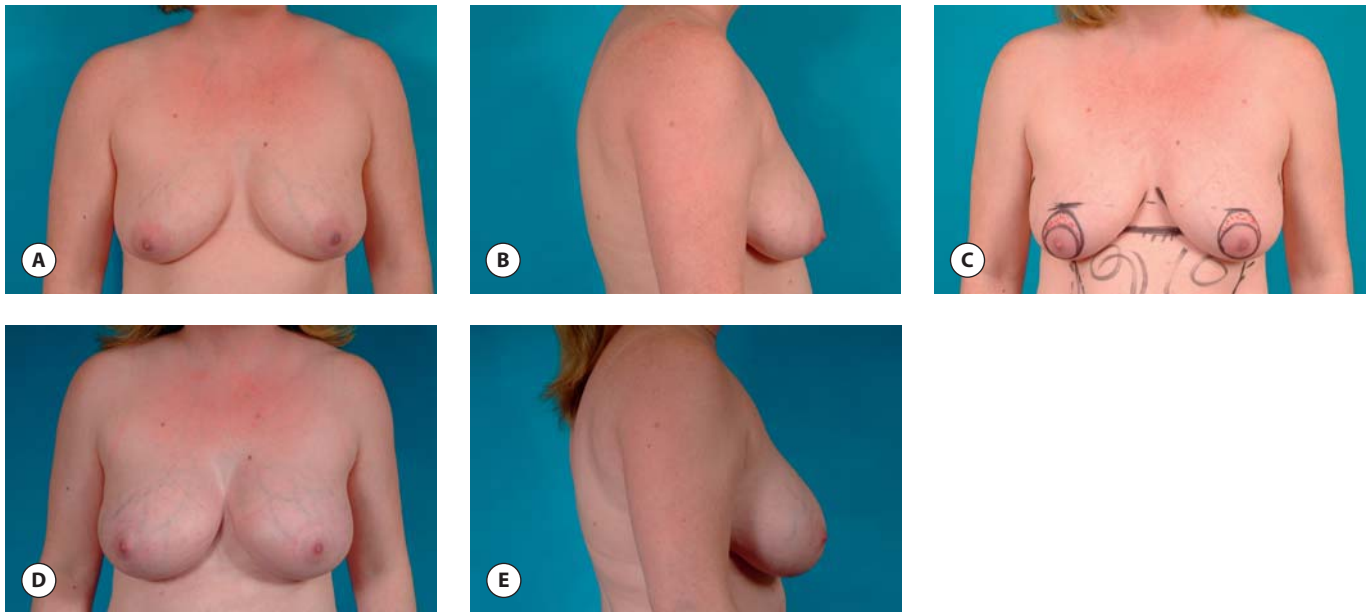


Figure 6.13 (A,B) Preoperative appearance of a 33-year-old woman in preparation for augmentation mastopexy. (C) Preoperative marks outline only a minimal lift of the NAC with the periareolar pattern. (D,E) Appearance 6 months after the placement of a 390 cc moderate-profile smooth round saline implant filled to 400 cc in the subglandular plane, along with management of the NAC using the interlocking Gore-Tex technique. While

the overall size and shape of the breast is acceptable, the NAC position remains slightly below the apex of the breast mound because the initial periareolar pattern was not aggressive enough in lifting the position of the NAC. This case demonstrates that, as long as the location of the inframammary fold remains stable, the top of the periareolar pattern must at times be higher than expected in order to position the NAC appropriately.

place more stress on the periareolar closure as well as on the shape of the breast. The effect of this incision pattern must then be carefully assessed during surgery to determine if a vertical segment will be needed in the skin pattern to obtain the optimal result. If the distance exceeds 6 cm, caution in the use of the periareolar pattern alone must be exercised as compromise in the size, shape or location of the NAC becomes more likely and the shape of the breast can be adversely affected. If this occurs, a vertical segment must be added to the skin pattern to obtain the best result.

Once the top of the pattern is marked, the remainder of the periareolar pattern must be determined. To accomplish this, the medial and lateral margins of the areola are noted and the periareolar mark is drawn so that it skirts the areola medially, inferiorly and laterally, creating what amounts to the shape of an elongated oval. This mark is meant to ensure that any redundant areola will be removed after the diameter of the actual areolar incision is determined intraoperatively. This completes the periareolar marking. Additional marks meant to reinforce the placement of the interlocking Gore-Tex are made to identify the corresponding eight cardinal points of the two competing diameters. Also, marking important landmarks such as the inframammary fold, the borders of the breast and the midsternal line can assist in improving the accuracy of shaping the breast intraoperatively.

Surgical technique (Figure 6.14 A–N) At surgery, care must be taken to ensure that the patient is properly secured to allow upright assessment of the size and shape of the breast. The inferior half of the periareolar incision is made and a small dermal cuff is preserved along the incision length to prepare for the eventual placement of the periareolar purse string closure. The pocket is developed and the chosen implant is inserted.

Alternatively, a likely sizer can be inserted to allow flexibility in implant choice if desired. One side of the proposed periareolar mastopexy is then tailor tacked together with staples and the patient is placed upright to compare the effect of the mastopexy to the unlifted side. If there was any question as to the need for the mastopexy, it should be answered at this point. Simply put, if the mastopexy improves the relationship of the NAC position with the breast mound, from the standpoint of providing the best result possible, it is advisable to proceed with the mastopexy. This decision must be balanced with the willingness of the patient to accept the periareolar scar. With proper patient education, any potential conflicts in this regard should be avoided and patient satisfaction with the procedure enhanced. Once the decision to proceed with the mastopexy has been finalized, it is advisable to tailor tack up the other side to ensure a symmetric result. If any changes to the pattern will improve the shape of the breast or the position of the NAC, they are made at this point by re-tailor tacking up selected portions of the pattern to create the desired effect. Once the periareolar pattern has been finalized, the edges are marked with a surgical marker and the staples are removed. The intervening skin between the areolar incision and the outer periareolar incision is de-epithelialized and the dermis divided around the perimeter of the defect leaving behind a 5 mm dermal cuff. The Gore-Tex suture is applied using the interlocking technique and the final diameter is chosen. If the areola is not perfectly round, additional skin is de-epithelialized at this point to make the defect as round as possible and the areola is inset with a running 4–0 absorbable monofilament suture.

At times, there can be a tendency for the areola to bulge after placement of an implant done in conjunction with a periareolar mastopexy. Simple periareolar revision with tightening of the

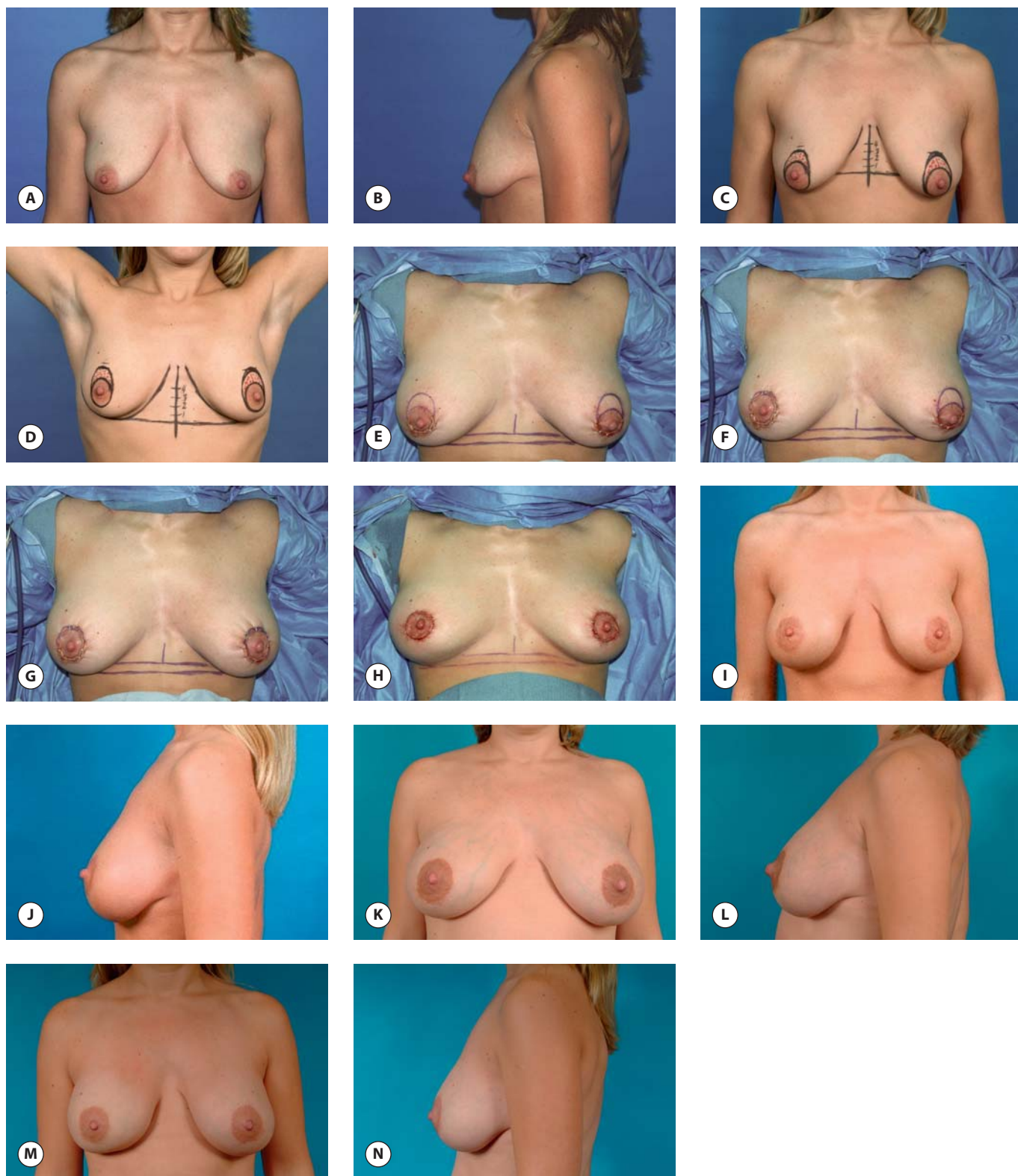

Figure 6.14 (A,B) Preoperative appearance of a 24-year-old woman in preparation for augmentation mastopexy. (C,D) Preoperative markings show that while the right nipple is just at the level of the IMF, the left nipple is actually below it, confirming the need for a periareolar mastopexy. The top of the periareolar pattern is diagrammed 3 cm above the IMF and, as a result of the preoperative asymmetry, the degree of lift is slightly more aggressive on the left than on the right. (E) Upright intraoperative appearance after the placement of a 290cc anatomically shaped cohesive silicone gel implant in a subpectoral pocket through a periareolar incision. Although the shape of the breast appears satisfactory, the position of the NAC remains low. (F) Appearance after the right NAC is temporarily tailor tacked into position with staples. The overall aesthetic result on the right is superior to the left as a result of the proposed

periareolar lift. (G) Appearance after the NAC is tailor tacked up on both sides. This maneuver confirms that the lift will enhance the overall result. (H) Final result after application of the periareolar purse string suture. (I,J) Appearance 2 years after augmentation mastopexy. (K,L) The patient subsequently became pregnant postoperatively with enlargement of the breast stressing the postoperative result. (M,N) Two years after giving birth and 4 years after the original procedure, the breasts have maintained an aesthetic appearance with the nipple being located at the apex of the breast. No obvious deleterious change in the breast has resulted from the pregnancy-induced volume increase in the breast. This case shows that the results obtained after augmentation mastopexy can maintain an aesthetic appearance over time, even in the face of recurrent soft tissue stresses.

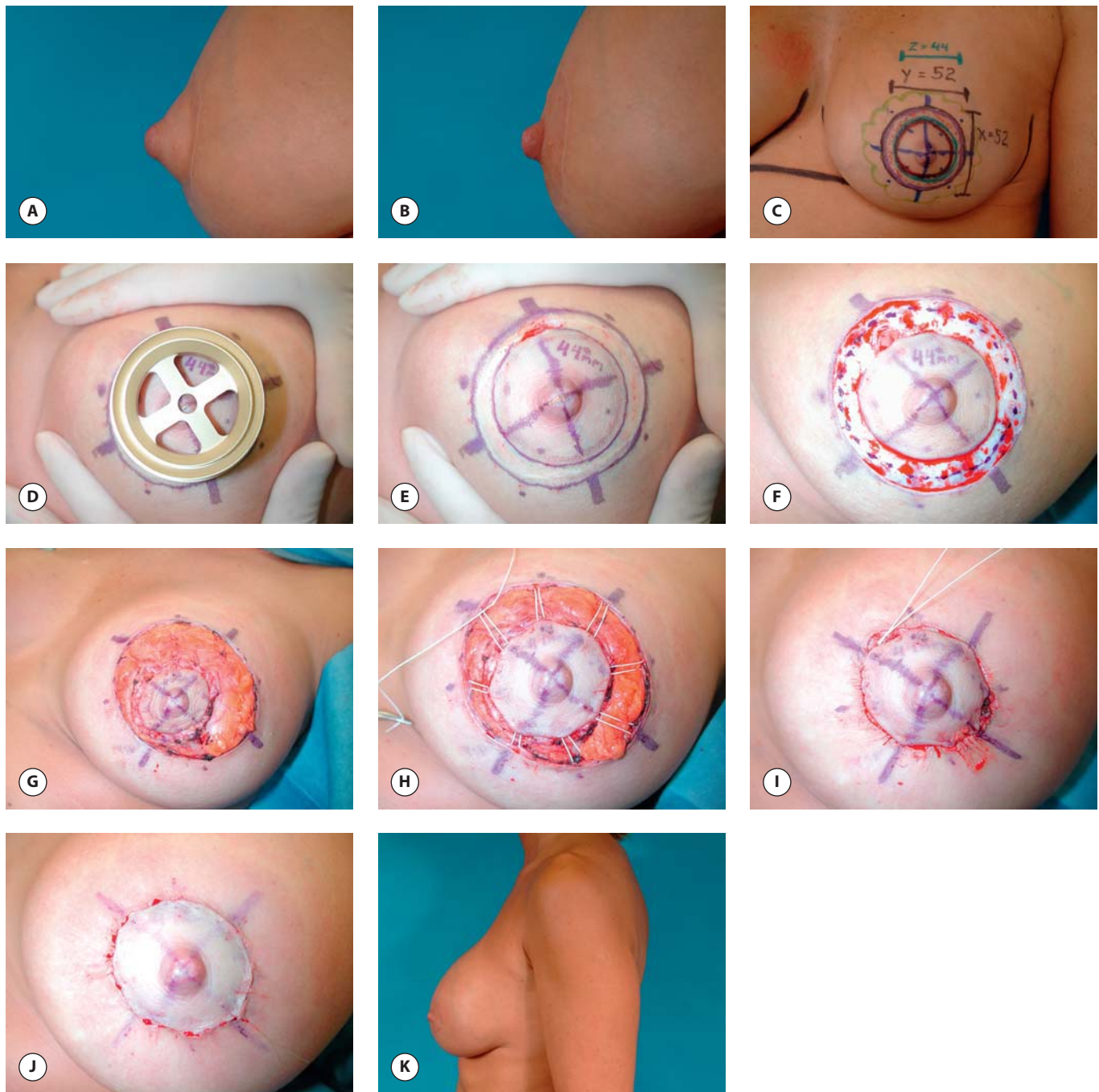


Figure 6.15 (A) Appearance of the left NAC after periareolar augmentation mastopexy showing pronounced herniation with an apical contour deformity. (B) With stimulation of the areola, contraction of the muscle fibers within the dermis causes the tension on the areola to increase, which completely corrects the herniation. This provocative test is an excellent indicator of the likelihood that operative reduction of the areolar diameter will provide correction of the herniated deformity with the areola in a relaxed state. (C) Preoperative marks in preparation for periareolar revision. The current areolar diameter of 52 mm will be re-incised at 44 mm. The markings for the interlocking Gore-Tex have been applied. (D) With the areola under maximum tension, a multidiameter areolar marker is used to outline a 44 mm circle. (E) A small stab incision has been made to remove the old Gore-Tex suture. The planned reduction in the areolar diameter can be seen. The orientation marks for the eight

cardinal points have been applied to guide eventual placement of the new interlocking Gore-Tex suture. (F) Appearance of the defect after de-epithelialization of the redundant skin. The proposed dermal incision is marked to create a dermal shelf into which the Gore-Tex suture will be placed. (G) Appearance of the defect after undermining of the skin edges in preparation for placement of the interlocking Gore-Tex purse string suture. (H) The wagon wheel appearance of the interlocking suture prior to cinching. Each of the cardinal points has been accurately approximated to ensure an even pulling together of the two unequal circular incisions. (I) Appearance after tightening of the purse string suture. (J) Final inset has been accomplished with a subcuticular 4-0 absorbable monofilament suture. (K) Postoperative lateral view of the relaxed areola shows complete correction of the areolar herniation.

areola using the interlocking Gore-Tex technique can completely correct this tendency for areolar herniation (Figure 6.15 A–K).

Circumvertical Augmentation Mastopexy

Indications For patients who present not only with an inferiorly malpositioned NAC, but also have a redundant and ptotic skin envelope, the circumvertical pattern is indicated. This is due to the fact that adding the vertical segment to the periareolar pattern not only effectively reduces the dimensions of the skin envelope, but it is also a powerful shaping maneuver which can dramatically improve the overall aesthetic quality of the result. The circumvertical approach is such a remarkably versatile and effective technique, it is my recommendation to use it liberally rather than risk overextending the periareolar technique when there is any doubt as to the quality of the final result. The vertical scar tends to heal in a very satisfactory fashion and most patients can accept this scar over the potential shape distortion which can occur when it is not utilized secondary to concerns over the scar.

Marking The markings for a circumvertical approach are very similar to the periareolar markings described above (Figure 6.16 A–D). Locating the top of the periareolar pattern and deciding on the horizontal and vertical dimensions is performed exactly as in a periareolar mastopexy. The only difference is that a vertical component is added to the marking pattern. While the top of the periareolar pattern is an important and relatively fixed landmark, the dimensions of the vertical takeout are entirely subject to adjustment intraoperatively and therefore these initial vertical marks can be viewed as preliminary. Again, a manual pinching together of the lower pole skin can provide a visual clue about how much skin will likely need to be removed to narrow the base diameter of the breast appropriately and take up the excess skin in the lower pole. Although this vertical takeout can be positioned slightly medially or laterally in some patients to good effect, it is generally ideal to base it directly in the meridian line of the breast. This will ensure that a more or less equal amount of breast skin will be removed medially as well as laterally, which tends to enhance the creation of a symmetric breast contour. In smaller breasts, the vertical takeout extends directly down to the inframammary fold but not beyond. It is actually advantageous to end the vertical resection just above the proposed IMF as there is a tendency for the bottom of the pattern to extend down onto the chest wall as the exact dimensions of the pattern are finalized during surgery. In larger breasts, it may become necessary to curve the pattern out laterally above the fold to take up the redundant skin. The necessity of this alteration in the pattern can be assessed at the time of marking by gently gathering together the lower pole breast skin, sometimes with the tips of the fingers of both hands, and observing the effect of varying degrees of skin tightening on the shape of the breast. With practice, a properly positioned and appropriately aggressive vertical takeout can be accurately applied using this maneuver, again remembering that the exact dimensions will be determined intraoperatively. What this does accomplish, however, is a general identification of which portion of the breast will be eventually involved in the vertical plication. This area then becomes a free zone in which an incision can be made to access the breast and develop a pocket for the breast implant. This incision is diagrammed directly in the center of the proposed vertical takeout. By using the vertical incision to gain access to the breast, less

manipulation is done to the periareolar tissues, which results in less risk for potential vascular compromise to the NAC. After the location of the vertical segment has been estimated, other marks can be applied regarding the placement of the interlocking Gore-Tex suture, as well as diagramming the borders of the breast to help guide dissection intraoperatively. This completes the marking pattern.

Surgical technique Again the patient is carefully prepared for upright positioning intraoperatively as the final dimensions of the skin envelope reduction and the application of the final circumvertical pattern will very much depend on accurate observations to be made with the full effect of gravity being exerted on the breasts.

Strategically, there are two options that can be used to sequence the procedure. In selected cases, it may be advisable to perform the mastopexy first and then add an implant once the skin pattern and dimensions have been set. Typically, this technique can be used to good effect when only a very modest implant will be used. In these cases, the more significant alteration in the anatomy of the breast is the skin envelope reduction and the addition of the implant does not change the volume to skin envelope relationship to a great degree. Therefore, it is easier to precisely set the skin envelope and then add a small implant. However, if the effect of adding the implant is comparatively more significant than the skin envelope reduction, it is far more predictable to place the implant first and then re-tailor the skin envelope around the new breast volume (see Figure 6.16 E). This approach will guard against an inadvertently overexuberant skin envelope reduction from hindering the easy placement of an appropriately sized device. For these reasons, it is usually preferable to place the implant first in nearly every instance and then add the circumvertical pattern to fit the new breast volume. This stepwise approach allows the most control over the result and allows an appropriate augmentation to be performed without risking an over-resection of the skin envelope, which is surprisingly easy to do.

With this in mind, the procedure is begun by making an incision in the center of the previously marked vertical resection area and the underside of the breast is exposed. It is important to stay above Scarpa's fascia as it inserts into the base of the breast as the pocket is developed to avoid opening up the loose subscarpal space below the fold. In this fashion, the anatomical integrity of the fold will be maintained and the likelihood of inadvertently lowering the fold will be reduced. From this access point it is possible to easily develop either a subglandular or a subpectoral pocket. Because the changes that are going to be made in the size and shape of the breast tend to be significant, it can be very helpful to use implant sizers to guide implant selection. The chosen sizer is inserted and the skin envelope is then plicated around the new breast volume. A very reproducible sequence to apply the pattern is first to staple the areola into the defect and then, with the patient upright, plicate the inferior pole as needed to create an attractive and rounded lower pole contour. In patients with a greater degree of ptosis and larger breast skin envelopes, it will be necessary gently to curve the plication out laterally to avoid running the plication line down onto the abdominal wall. This will result in a 'J'-shaped line of plication with the only difference between smaller and larger breast skin envelopes being that the plication line runs out laterally more in the breasts with a relatively greater amount of redundant skin. With this technique, there will be some minor bunching

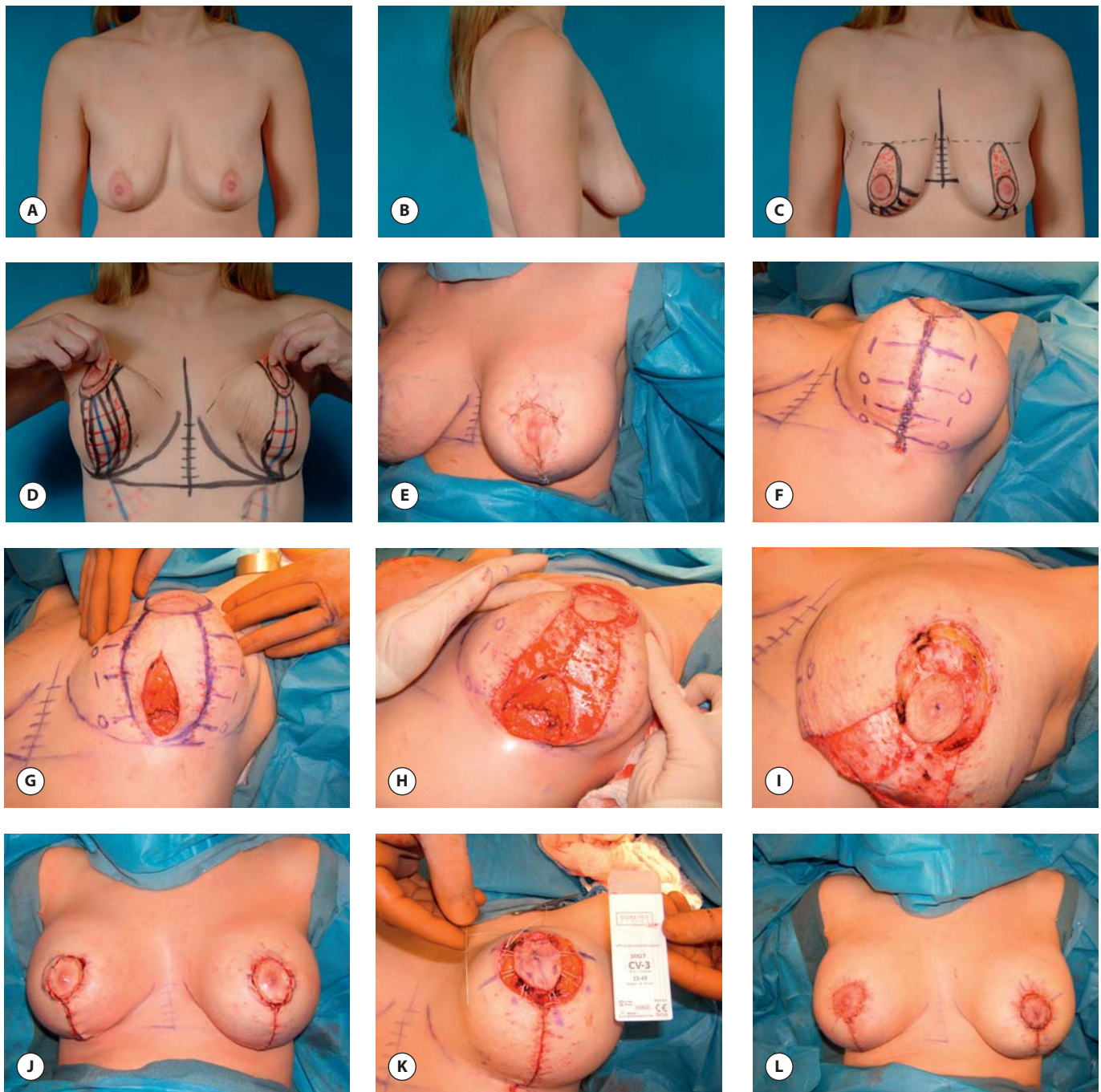


Figure 6.16 (A,B) Preoperative appearance of a 34-year-old woman in preparation for circumvertical augmentation mastopexy. (C,D) Preoperative marks showing the top of the proposed periareolar pattern being located 6 cm above the inframammary fold line. The periareolar oval is diagrammed so as to limit the amount of skin resected medially and laterally to decrease the stress on the subsequent periareolar closure. The access to the breast will be through the center of the proposed vertical pattern (blue line). (E) Appearance of the breast after the development of a subglandular pocket with addition of a 350 cc sizer coupled then with temporary plication of the circumvertical skin pattern. Overall, an aesthetic breast size and shape has been created. By using this tailor tack approach, inadvertent over-resection of skin or the use of an implant which is too big can be avoided. (F) Once the desired shape has been created, the plicated inferior skin segment is marked not only along the edges of the plication, but with horizontal orientation lines as well to aid in subsequent

reassembly of the vertical incision after the staples are removed and the skin de-epithelialized. (G) After removal of the vertical plication staples, the dimensions of the vertical segment can be seen. The access incision to the breast for dissection of the pocket can be seen at the midline base of the vertical pattern. (H) The vertical segment has been de-epithelialized. (I) The periareolar dermis is incised, keeping a 5 mm cuff of dermis around the peripheral margin to support the interlocking Gore-Tex suture. (J) Appearance of the breasts after the insertion of a 330 cc high-profile smooth round saline implant filled to 350 cc on the left and 370 cc on the right. The circumvertical incision is tailor tacked together and the periareolar component is rounded off to help ensure a circular shape to the areola once the interlocking Gore-Tex suture is applied. (K) Appearance of the periareolar defect after the additional rim of skin has been de-epithelialized and the interlocking Gore-Tex suture placed. (L) Final appearance after inset of the NAC.

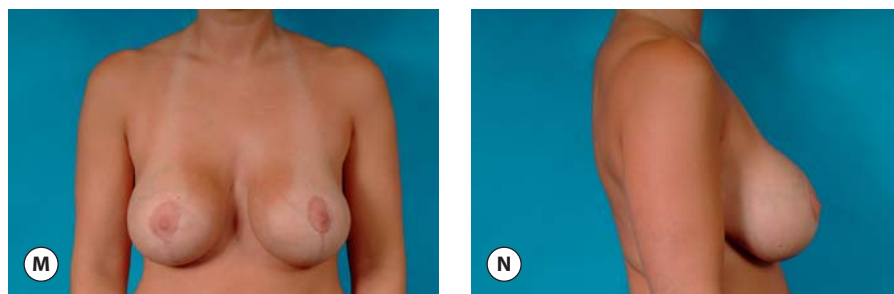


Figure 6.16 (Continued) (M,N) Final result at 7 months.

of the skin just under the areola but, because the dimensions of the vertical segment tend not to be excessively wide and skin in these patients tends to be quite elastic, a controlled and stepwise plication of the vertical segment can be achieved that allows a direct and accurate molding of a contoured breast shape. The pattern can be easily adjusted by adding or removing staples as needed to create the desired result. In this fashion, the skin envelope can be accurately tailored to match the volume and dimensions of the newly augmented breast without the risk of over-resection of skin. It is helpful to proceed to the opposite breast at this point and place the implant and plicate the skin envelope in a similar fashion. Once both breasts have been pliated, the patient can be placed upright and any fine tuning to the plication pattern can be performed as needed to create the best symmetry. This is most helpful in patients who present with a preoperative asymmetry and it is very common to develop a slightly different plication pattern on each breast in an attempt to correct the asymmetry. Once the final breast volume and shape have been determined, the vertical plication, line is marked with a surgical pen. It is highly recommended to apply crosshatch marks with the pen to allow the two sides of the vertical incision to be accurately reapproximated after the vertical segment has been de-epithelialized. If this is not done, it can be at times surprisingly difficult to realign the vertical incision along the lines that were determined by the initial plication, which can then adversely affect the shape of the breast (see [Figure 6.16 F](#)). It should be noted that the dimensions of the periareolar opening can be altered as well and, if this has been done, these areas are likewise marked. The staples are then removed and the skin within the vertical segment is de-epithelialized (see [Figure 6.16 G,H](#)). The implant is inserted and properly positioned and the breast parenchyma is reapproximated along the vertical incision with an absorbable 4-0 monofilament by closing the medial and lateral parenchymal pillars with both deep and superficial sutures. This will help prevent the parenchymal tissues in the vertical segment from inadvertently separating and allowing the implant to semi-herniate into the lower pole of the breast. The vertical skin incision is closed in layers, again with a layer of interrupted absorbable 4-0 monofilament sutures followed by a subcuticular suture of the same material. This technique pliicates the de-epithelialized dermis in the vertical segment upon itself, which tends to create a vertical strut that runs down the inferior central lower pole of the breast. The pliicated dermis tends to be somewhat stiffer than the surrounding parenchyma and, in selected patients, this may provide an additional layer of support for the lower pole of the breast.

Finally then, the interlocking Gore-Tex suture is applied to the remaining periareolar defect and the areola is inset as before (see [Figure 6.16 I-K](#)). It is very common for the periareolar closure

to proceed in a more comfortable fashion when using the circumvertical approach due to the fact that the vertical segment reduces the dimensions of the periareolar opening. As a result, there is less of a mismatch in the size of the areolar diameter versus the size of the periareolar opening and it is easier to inset the areola without creating an inordinate amount of tissue pleating or bunching. This, along with the ability to create a more contoured and shapely lower pole in the breast, highlights the major advantages of the circumvertical skin pattern. By combining the NAC lifting effect of the periareolar skin pattern with the shaping power of the vertical plication, an aesthetic breast mound with a properly positioned NAC can be achieved in a straightforward and controlled fashion (see [Figure 6.16 L-N](#)). For these reasons, the circumvertical approach is perhaps the most reliable and effective skin pattern for use in augmentation mastopexy.

Inverted T Augmentation Mastopexy

With the advent of circumvertical techniques, it is the unusual patient who requires the classic Wise pattern inverted T skin resection strategy for cases of augmentation mastopexy. Compared to the circumvertical scar, many patients and surgeons see the extended inframammary fold scar as a significant disadvantage for a cosmetic procedure, even though the scar is placed in what is hoped to be a relatively hidden location. However, an inverted T approach with a short horizontal component can be very useful in dealing with the excessive skin envelopes which can occasionally be seen in patients with profound ptosis. The marking and surgical proceed exactly the same as with the circumvertical approach. However, when the vertical segment is pliicated together, instead of curving the plication out laterally to take up the redundant skin, a small horizontal plication centered on the vertical segment is added to finalize the shape of the lower pole of the breast. This plication is performed just at the level of the inframammary fold and the medial and lateral wings of the plication are extended as far as necessary to take up the redundant skin. It is rarely necessary to extend the resection medially and laterally as far as is generally required when performing a Wise pattern breast reduction and, in that regard, only a short horizontal scar is created, which is strategically placed in the inframammary fold. This is a very straightforward technique that can allow facile management of the excessive skin envelope seen in patients with profound preoperative breast ptosis.

Resuspension Augmentation Mastopexy

As noted previously, the most effective way to shape the breast in any type of aesthetic breast procedure is to insert a breast

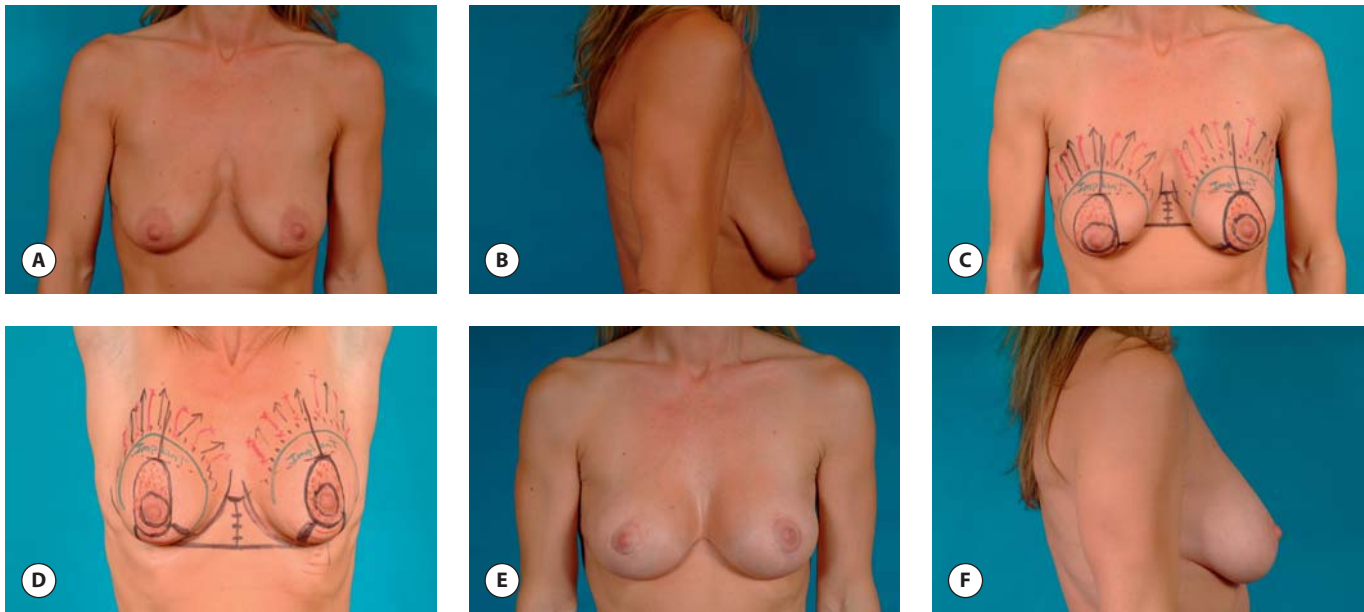


Figure 6.17 (A,B) Preoperative appearance of a 40-year-old woman in preparation for augmentation mastopexy. The combination of the patient's extremely trim body habitus and the ptotic position of the breast results in a very thin soft tissue cover in the superior pole. This patient is at risk for a visible implant contour in the superior pole of the breast after standard augmentation mastopexy. (C,D) Preoperative marks in preparation for resuspension augmentation mastopexy. The upper peripheral border of the breast will be undermined and resuspended internally to 'autoaugment' the upper pole and

soften the chest wall–implant interface. The interlocking Gore-Tex technique will be used to manage the periareolar portion of the mastopexy pattern.

(E,F) Postoperative result 6 months after the placement of 150 cc moderate-profile smooth round silicone gel implants in the subglandular position shows a very natural appearance to the breast with smooth contours and a straight line slope from the upper chest down to the apex of the breast. By pulling the soft tissues of the upper pole of the breast superiorly to help fill in the concavity, a visible implant contour has been prevented.

implant. The volume provided by the implant directly fills the upper pole of the breast and, in many patients, corrects the preoperative concavity that is often present. However, in patients who are very thin with little soft tissue cover in the upper pole of the breast, a step off can sometimes be seen at the upper border of the implant as it lies against the chest wall. In the case of saline implants, this step off can be particularly prominent and can result in an unnatural and augmented look to the breast, even after the lifting and skin tightening effect of the mastopexy has been applied. Cohesive anatomic gel implants can be used to help correct this step off; however, for many reasons including lack of availability, risk of rotation or simply patient or surgeon preference, these devices may not be appropriate for some patients. In these instances, it can be helpful to utilize the patient's own tissues as an internal flap to autoaugment the upper peripheral contours of the breast in an attempt to soften the edges of the breast and create a more natural appearance. This technique is called the resuspension augmentation mastopexy.

The procedure is usually performed in conjunction with a circumvertical pattern as the vertical incision affords easy access to the underside of the breast. The preoperative markings are performed as in any circumvertical augmentation mastopexy. At

surgery, the underside of the breast is exposed through the vertical incision and a subglandular pocket is created. The upper half of the pocket is over-dissected beyond the limits required to place an implant to allow the underside of the breast to be resuspended superiorly. With the aid of a lighted retractor, the deep surface of the breast just at the junction of the superior pole with the chest wall is sutured superiorly a distance of 4–6 cm to pull this tissue up and under the upper breast flap. Three to four sutures along the upper peripheral margin are used to resuspend the superior pole of the breast in an attempt to fill in the peripheral hollow these types of patients can present with. Once the superior pole has been filled in, there is ample room then to place the breast implant into either the remaining subglandular space or a subpectoral pocket (Figure 6.17A–F). Together, this 'autoaugmentation' of the upper pole of the breast along with the placement of a breast implant can completely reshape the upper pole contour into a very natural slope and create a full but not obviously augmented look to the breast. It is advisable to overcorrect the initial upper pole contour as some settling will occur over time. This resuspension maneuver provides an additional and very effective technique for breast shaping in patients who are at risk for visible implant contours after traditional augmentation mastopexy.

Summary

Although augmentation mastopexy can truly challenge the artistic and technical talents of the aesthetic surgeon, by intelligently applying the concepts of periareolar and circumvertical

skin management, and combining the principles that govern appropriate implant selection, outstanding results in a very difficult subgroup of patients can be achieved.

Breast Reduction

There is no other procedure in breast surgery where the surgeon has a greater opportunity to demonstrate his or her aesthetic abilities than with a breast reduction. In these cases, there is an excess of skin, fat and parenchyma usually coupled with an overall breast shape that is usually less than aesthetic. With careful surgical manipulation of the volume of the breast along with intelligent incision planning, a beautiful and long-lasting breast shape can be created that complements the reduction in breast volume.

The goal of this chapter is to discuss those factors that can optimize the result, no matter which technique is eventually utilized.

Preoperative Evaluation

Chief Complaint

There are many factors that merit specific attention when assessing a patient for a potential breast reduction. The most basic of these relates to the patient's physical complaints related to her large breasts. It is important to document each patient's specific complaints, which can include, but are not limited to, neck and back pain, headaches, shoulder grooving with painful indentations in the skin secondary to support garments, submammary intertrigo and paresthesias in the hands and fingers. More often than not, there is a general discomfort about the upper torso

related to years of excess weight dragging down from the shoulders. One useful maneuver used to assess the effect of the weight of the breast on the upper torso is to gently lift each breast upwards with the examining hand while standing in front of the patient (Figure 7.1). By taking the weight of each breast off the chest wall, many patients will observe an immediate relief of symptoms. It should be stressed in each patient consultation that the purpose of undergoing a breast reduction is to relieve these upper torso complaints. Such a discussion, properly documented in the patient's chart, has practical as well as medicolegal implications as some patients become so focused on the aesthetic appearance of the breast postoperatively that this basic fact is at times forgotten amidst discussions related to scarring or breast shape.

Reproductive History

Childbearing can have a tremendous impact on the size and shape of the breast. To have a better historical understanding of the stresses that have been placed on the breast and the associated supporting soft tissue framework, it is helpful to document the number of children a patient has had, whether or not she breast-fed and how long it has been since she stopped. Also, the maximum size that developed either as a result of pregnancy alone, or during the breast-feeding process itself, can be helpful in understanding how dramatically the skin envelope was

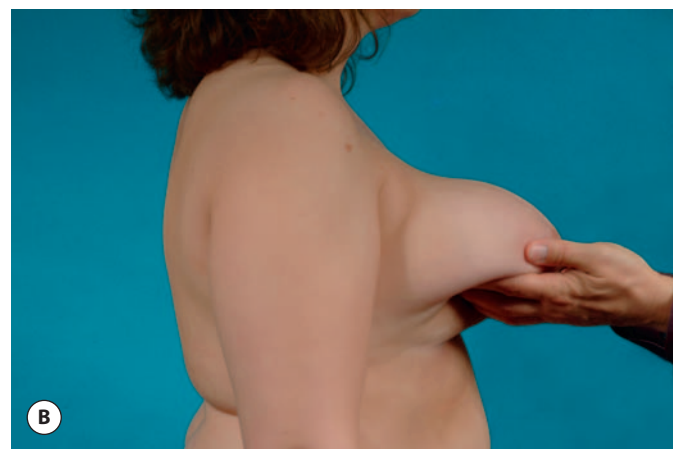
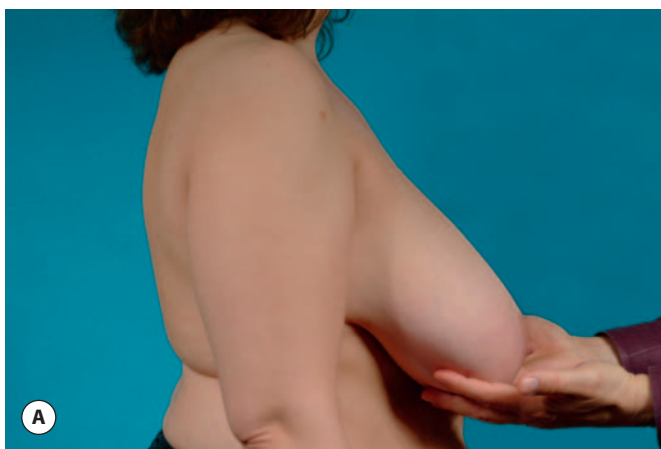


Figure 7.1 (A,B) By standing in front of the patient and lifting the breast until the weight is entirely supported by the lifting hand, the effect of a breast reduction can be simulated. This simple maneuver can be used to

help demonstrate to the patient what effect the reduction in breast volume is likely to have on preoperative upper torso symptoms.

stretched. This information may explain why the breast has a certain appearance and, as well, allow the surgeon to predict, at least to some extent, how the skin envelope will react to surgical manipulation. Whether or not a patient wishes to attempt to breast-feed in the future should also be noted and discussed preoperatively. It is generally permissible to allow patients who wish to breast-feed after breast reduction to make the attempt. If the breast ducts are still in continuity with the nipple, it is entirely possible that a breast reduction will not appreciably interfere with the ability to breast-feed. Of course, this is by no means a guarantee and these issues must be discussed preoperatively to help head off any misconceptions on the part of the patient.

In patients who have recently given birth and who may or may not be breast-feeding, a common question relates to the timing of a proposed breast reduction. The most important variable affecting this decision is whether or not the breast has reached a stable size and shape. Once the swelling associated with childbirth and/or breast-feeding has subsided, the surgeon can optimally make intraoperative decisions concerning the long-term size and shape of the breast. Therefore, it is recommended to wait for 6–12 months after either the pregnancy or the cessation of breast-feeding before performing a breast reduction to allow full breast involution to occur. Some patients continue to demonstrate discharge from the nipple for an extended time after pregnancy or breast-feeding. If after 1 year this discharge persists, an evaluation by an endocrinologist may be helpful. In the absence of any other pathology, a breast reduction can safely be done under these circumstances; however, drains are recommended to help prevent fluid accumulation inside the breast.

Past Surgical History

Information relating to previous breast surgery must be documented as the location of previous breast biopsy scars may influence planning of the pedicle or skin pattern. For example, occasionally, a patient will present with a previous inframammary fold scar related to a thoracotomy performed as an infant. In these instances, the use of a superior pedicle may more safely carry the blood supply to the nipple and areola. Also, in patients who have undergone previous surgical procedures, the nature of these operations can provide a basis for comparison as to what to expect when a breast reduction is performed. Typically, the recovery from a breast reduction is not as taxing or painful as other commonly performed procedures such as hysterectomy or other types of abdominal procedures, and comparing the two can give a useful frame of reference that many patients can find reassuring.

Past Medical History

Conditions that may influence the ability of a patient to recover from a breast reduction must also be considered. Systemic illnesses such as hypertension and diabetes are commonly noted and are associated with an increased incidence of wound healing difficulties. Any medical condition that can potentially impact on the viability of the nipple–areola complex (NAC), pedicle or skin flaps must be documented preoperatively to allow the patient fully to understand the risks involved. Armed with an understanding of these preoperative risk factors, the surgeon then has the ability to utilize a more conservative surgical approach as needed to maximize the chances for success.

It is helpful to make special note of any history related to inflammatory bowel disease. In particular, a past history of ulcerative colitis has been associated with the development of pyoderma gangrenosum, a condition characterized by a progressively enlarging and painful ulcer located at an incision line. Initially, the ulcer is small and is associated with a clear drainage that leads to a benign presumptive diagnosis of a 'stitch abscess' or premature erosion of an absorbable suture through to the surface of the skin. Generally, the ulcer enlarges

despite the institution of oral antibiotic therapy. Eventually, the ulcer becomes painful in a manner that seems out of proportion to the appearance of the wound and the wound edges develop an irregular undermined purplish border (Figure 7.2). Biopsy reveals an inflammatory infiltrate and the process is rapidly reversed with a tapered course of oral steroids. Recognizing any previous history of diagnosed ulcerative colitis or even colitis-like symptoms can lead to a heightened index of suspicion and early diagnosis should this condition develop.

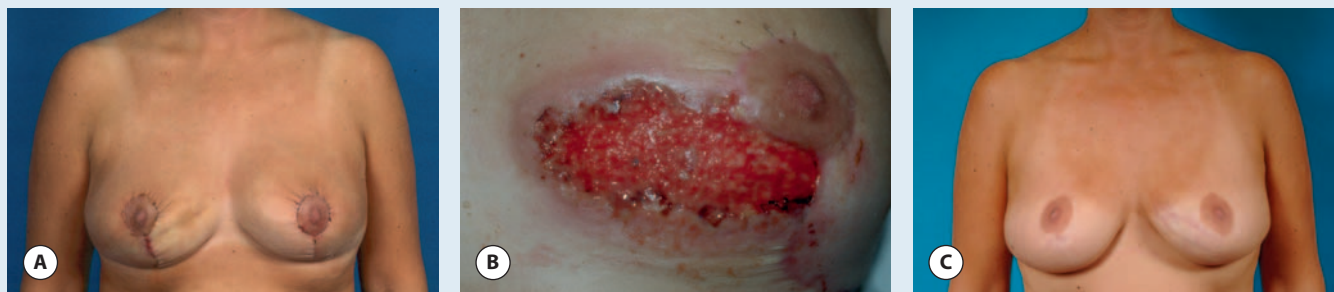

Figure 7.2 (A) Immediate postoperative appearance of a 35-year-old woman after undergoing routine breast reduction using the SPAIR technique. (B) After a period of several weeks, a small wound separation was noted inferior to the left NAC that was refractory to local wound care and antibiotics. A painful ulcer of significant size ultimately developed

with irregular hemorrhagic borders. Biopsy confirmed the diagnosis of pyoderma gangrenosum and a course of systemic steroids was begun. The wound rapidly recovered and healed without further complication. (C) Appearance of the breasts roughly 3 years after the initial procedure.

Family History

Many patients assume a direct link between their own macromastia and the size of the breasts of first and even second and third degree relatives. Macromastia is generally not thought to be a directly transmissible genetic condition and it can be helpful to dispel these assumptions as the many variables that can affect the size of the breast are discussed during the consultation. Some women are actually relieved to receive this information as an unspoken worry for their own daughter's potential for macromastia can be of some concern. More to the point, however, is any family history for breast cancer that may be present. This is important information to document as these patients are at a variably increased risk for the development of breast cancer and this information can guide the decision of whether or not to obtain a mammogram preoperatively. Current American Cancer Society guidelines recommend the initiation of mammographic surveillance of the breast to begin at the age of 40. For patients scheduled to undergo breast reduction, a much younger age guideline is used by many surgeons. The main reason for this is to document preoperatively the presence of any suspicious lesions in the breast before it is surgically altered and to allow these lesions to be appropriately dealt with. When an occult cancer is found in a breast reduction specimen, it can be difficult to isolate it to a specific area of the breast thus obviating the possibility for a lumpectomy with radiation treatment as a treatment option. Realistically, such patients are best treated with mastectomy to be certain any residual tumor is removed. In an effort to prevent as much as possible any potential for finding an occult breast cancer, many surgeons simply obtain mammographic clearance of every patient they see who presents for breast reduction. While complete, this strategy seems excessive when applied to younger women and another common strategy is to use an age cutoff for obtaining a mammogram of anywhere from 25 to 30 years of age. Also, when a history of breast cancer is present in a first degree relative, it is very common to suspend any type of age cutoff guideline and a mammogram is generally obtained in any patient with a family history of breast cancer.

It is my practice to obtain preoperative mammograms on all patients 25 years and older and in all patients over 20 with a family history of breast cancer. For patients who have had mammograms, I recommend a repeat study if it has been more than 1 year since the last mammogram.

Social History

A smoking history essentially doubles a patient's risk for wound healing complications and for potential vascular compromise to the pedicle. This fact alone may affect the choice of technique for selected patients. For this reason, it is very important to document whether or not the patient smokes and to identify how many packs a day she smokes and how many years she has been smoking.

Another very important aspect of the social history relates to the nature of whatever interpersonal relationship the patient may have with a significant other. It would be less than optimal to perform a breast reduction only to find out later that the significant

other was either not informed or, even worse, against the procedure being performed at all. Clearly, the breast can play a very important role in the personal life of the patient and any alteration in the size, shape or sensation of the breast with the addition of scars can have a significant effect on how the patient interacts in an intimate setting. For this reason, it is always recommended that the role of any significant other be assessed at the time of the initial consultation. Of course, the best of circumstances is when the significant other accompanies the patient to the initial consultation as preoperative education can occur and questions can be answered. If not, it is always prudent to ask if anyone else will have any interest at all postoperatively in the decision the patient is making so that person's role in the recovery process can be assessed. If there is any suspected conflict regarding the decision to undergo a breast reduction, it is prudent to arrange a second preoperative consult with both the patient and her significant other being present to head off any potential misunderstandings postoperatively that may compromise the final result. If the patient acknowledges that her significant other is aware of her plans and is supportive, it is reasonable to proceed. This approach will help to proactively manage expectations ahead of time and will lead to a much more successful outcome rather than trying to deal with these issues after the fact.

Surgical Timing

There are three general time periods in a woman's life where macromastia can develop to the point where upper torso symptoms begin to develop and surgery can become indicated. Macromastia can first present in adolescent girls in association with general pubertal development. Anywhere from the age of 12 up to 18 years of age, breast growth over and beyond what would be considered proportionate to the remainder of the body habitus can occur. This early phase of breast over-development presents challenges that are unique in the treatment of macromastia. Not only can there be the usual upper torso symptoms found in other types of macromastia, but other issues related to the emotional well-being of the patient during this very volatile and important part of a young woman's life must also be considered. As breast volume increases, it is not uncommon for patients to become extremely self-conscious, often to a point of withdrawing socially. As a result, important social skills can either be delayed in developing or fail to develop altogether. Also, from a simple anatomic standpoint, it can be difficult for such young patients with macromastia to participate in sports or other athletic activities without the size of the breasts being a hindrance. For all of these reasons, it is completely acceptable to consider surgical correction of macromastia even as a young teenager. What must be balanced against the decision to perform surgery early is the potential for breast development to be incomplete with further growth postoperatively necessitating a re-reduction later on. For this reason, each case must be assessed individually to arrive at the best solution for the patient. If breast over-development is modest, it is reasonable to wait until the age of 16–18 in the hope that breast size will have stabilized toward the end of pubertal development. However, if at any time, even in patients as young as 14, breast over-development begins to interfere with what the family or the patient sees as normal social development, it is completely reasonable to proceed with a breast reduction, accepting the fact

that another touch up reduction may well be required at a later date when breast development has completely stabilized.

The second life event that can significantly affect the size of the breast is pregnancy. How the breast will respond to pregnancy and subsequent breast-feeding is extremely variable from patient to patient. In almost all patients, a transient perinatal enlargement of the breast occurs that is sustained by a period of breast-feeding. After breast-feeding is suspended, many patients will not regress to their pre-pregnancy breast size and some degree of macromastia may persist as a permanent condition. Also, breast ptosis very often becomes exaggerated as a result of the cyclical expansion and involution of the soft tissue support structure of the breast associated with pregnancy and breast-feeding. For these reasons, many patients who demonstrated only modest breast hypertrophy prior to pregnancy will subsequently develop more severe macromastia after pregnancy and will present for breast reduction in the postnatal period. It is prudent to assess whether any further pregnancies are planned as the cyclical changes in breast size that can occur with pregnancy can adversely affect the result after breast reduction is performed.

Lastly, and usually somewhat later in life, many women will present with macromastia associated with weight gain as it is very common for the breast to increase significantly in size as the overall weight of the patient increases. In some patients, even only a modest increase in weight can result in a disproportionate increase in the size of the breast. In others, a weight gain that pushes the body habitus of the patient into the obese to morbidly obese category is required to affect significantly the size of the breast. No matter what the circumstance, in order to provide a stable result, it is best to delay surgery until the patient's weight remains somewhat constant over a defined period of time. It is reasonable to delay surgery until there is a weight fluctuation of no more than 10 pounds (4.5 kg) over a time span of 6 months to 1 year to ensure that an unexpected change in the weight of the patient will not adversely influence the postoperative size and shape of the breast. Certainly, a further increase in the weight of the patient could create a recurrence of symptoms, but a much more common concern on the part of patients is related to what will happen to the breast should the patient lose weight. It can be very difficult to predict how the volume of the breast will

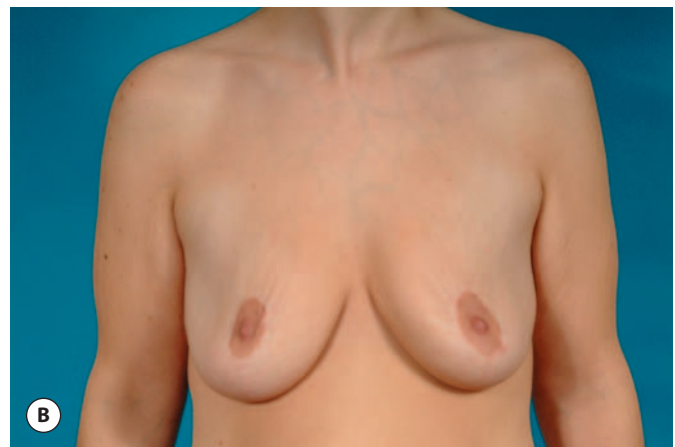
change in association with a generalized weight loss and the exact relationship between breast size and overall body weight can be quite variable. What can be stated for certainty is that breast size will change in association with an overall reduction in body fat. In patients where breast volume has historically been sensitive to the overall weight of the patient, the change in breast size that occurs can be significant. In other patients, there may be only a negligible change in the size of the breast. No matter what the circumstance, it is best to caution the patient that any change in body fat content can subsequently have an effect on not only the size but the shape of the breast as well (Figure 7.3).

Effect on Breast-feeding

Another common concern, particularly for younger patients who are of childbearing age, is the effect that breast reduction surgery has on the ability to breast-feed. The answer to this question is somewhat dependent on the technique employed to perform the procedure with the critical determinant being whether or not the substance of the gland has been divided from, and no longer communicates with, the nipple. Therefore, in patients who have undergone a free nipple grafting technique, there is little hope of maintaining breast-feeding potential as the direct ductal communication between the nipple and the gland has been severed. While it is remotely possible that an 'inosculatory' regrowth of the ductal remnants in the nipple and the gland could occur, allowing these structures to variably reconnect, the likelihood of this occurring to any functional degree is low. Alternatively, in the inferior pedicle technique, the main central substance of the gland remains connected to the nipple, which, theoretically, should preserve the ability to breast-feed. Other pedicled techniques such as the vertical breast reduction technique follow a similar logic. Therefore, if a superior pedicle or a superomedial pedicle is constructed so as to maintain a communication between the nipple and a large enough retained glandular segment, breast-feeding potential should be maintained. Of course, there are many other variables involved in successful breast-feeding that have nothing to do with the surgical alteration of the breast and many women who wish to breast-feed cannot for a host of different reasons. As a general rule, approximately two-thirds

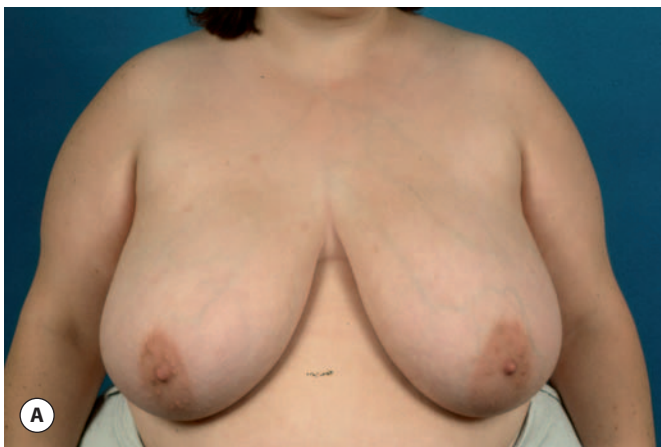

Figure 7.3 (A) Preoperative appearance of a 28-year-old woman prior to undergoing breast reduction. **(B)** Three-year postoperative appearance after undergoing breast reduction followed by a gastric bypass procedure resulting in a 120 pound (54 kg) weight loss. Along with the general loss of



body fat, a profound change in the size and shape of the breast is observed. There is a significant loss of volume along with a redundant and ptotic skin envelope. This case demonstrates the dramatic changes in the breast that can be observed when there is change in the weight of the patient.

of women who wish to breast-feed are able to do so and this ratio is not changed by breast reduction surgery that maintains a direct nipple to gland communication.

Examination

Observations

Weight The purpose of the examination is to identify those anatomic relationships that are potentially likely to influence the final result and develop a surgical plan designed to deal with them. To that end, the exam begins with a notation regarding the height and weight of the patient. In particular, the weight is best documented on an in-office scale that remains constant over time. It is best to weigh each patient the same way every time to provide the most consistent result. It is my practice to weigh each patient in her undergarments and changing gown to remove clothing as a confounding variable. In this fashion, there can be no question as to how the weight of the patient has changed over time. This can be an issue for patients who gain or lose significant amounts of weight postoperatively and note a change in the size or shape of their breast. Having this information for review can help the patient understand how her change in body habitus may have affected the breast. Also, documentation of the patient's weight over time can protect the surgeon should any medicolegal issues develop postoperatively.

Breast base width Many patients, particularly those with significant macromastia associated with varying levels of obesity, present with a very wide breast base diameter that extends in a diffuse fashion onto the lateral chest wall. In many cases, the base diameter of the breast is not only wide but asymmetric as well (Figure 7.4). Making note of this aspect of breast shape can direct appropriate attention to managing each breast in a slightly different fashion using a preoperative plan that narrows the wider breast to a greater degree than the opposite narrower breast. Also, liposuction recontouring of the lateral chest wall fullness can be used to recreate proportion between this area and the reduced breast. It is advisable to discuss the need for lateral

liposuction ahead of time with the patient as this aspect of the procedure can lead to additional swelling and ecchymosis over and above that seen with a standard breast reduction procedure.

Upper pole contour The contour of the upper pole of the breast is assessed for any degree of concavity. Should there be a lack of fullness in the upper pole, direct surgical recontouring with internal suture suspension will be required to provide the optimal result and this must be factored into the overall surgical plan (Figure 7.5).

Lower pole skin texture In patients with severe macromastia, the weight of the breast along with the expansion of the skin envelope can be so severe that ischemic changes can be noted in the most dependent portion of the breast. Often these changes can be seen as a dull rubor present in the skin along with the presence of a dilated capillary network (Figure 7.6). Such changes are indicative of a reduced capacity for these tissues to tolerate surgical manipulation and serve as a marker for increased risk of wound healing difficulties and possible NAC ischemia. Making note of these changes can allow the surgeon to alter the technique of reduction as needed and also allow adequate preoperative counseling to be done to appraise the patient of her risk for complications.

Breast consistency It is possible to gauge the consistency of the breast via palpation and use this information as a guide to the amount of fat that is present. Fibrous parenchyma can easily be distinguished from the softer and more compliant superficial fat as the fibrous tissue has a lobulated or 'cobblestone' texture that can be detected through the skin. Distinguishing between a breast that has been largely replaced by fat versus a fibrous breast can help predict how easy it will be surgically to reshape the reduced breast. Typically, a breast with a higher percentage of fibrous tissue is more difficult to dissect accurately and is less forgiving during shaping than a fatty breast. Anticipating these factors ahead of time can help the surgeon prepare for the challenges each particular patient may present at the time of surgery.

Asymmetry Finally, any asymmetry in the size and shape of the breasts, the level of the inframammary fold (IMF) and the

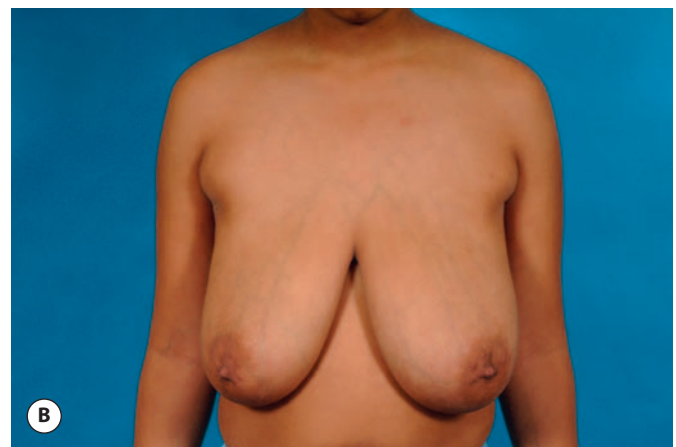
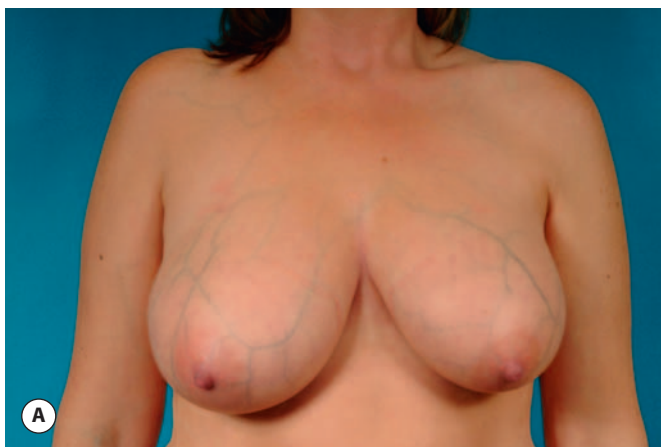
Figure 7.4 (A,B) Significant asymmetry in breast base width, as demonstrated in each of these patients, can profoundly affect the eventual result after breast reduction, particularly if the same pattern is used on each

side. To obtain the best symmetry, a more aggressive skin resection will be required on the wider side to narrow the breast to the desired degree.

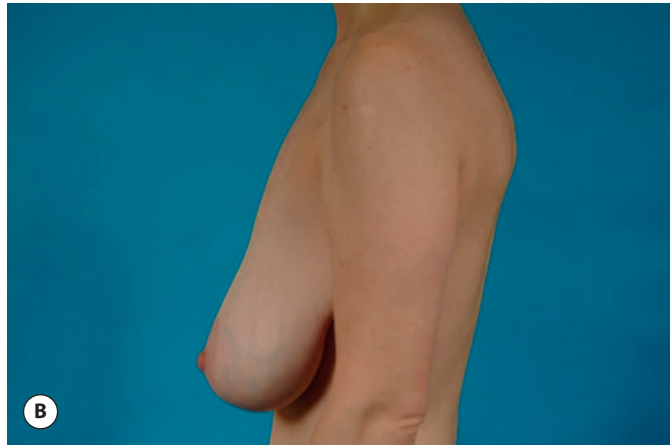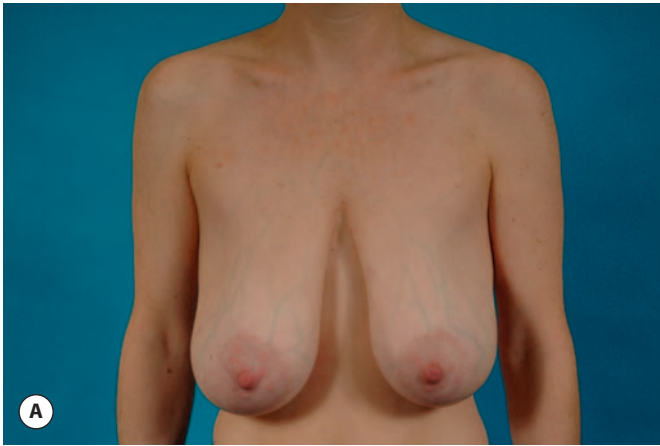


Figure 7.5 (A,B) In patients with excessive ptosis, a lack of fullness in the upper pole of the breast can often be noted. In these patients, restoration of

an aesthetic upper pole contour is best accomplished with internal suture plication to reposition the breast superiorly to recreate upper pole fullness.

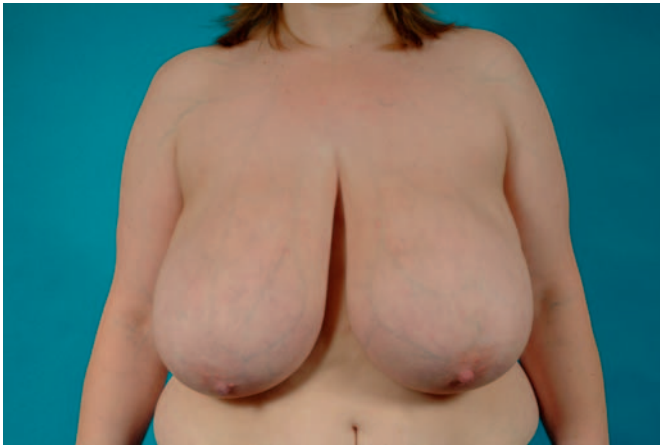

Figure 7.6 In patients with profound macromastia, the weight of the breast can be of sufficient magnitude so as to create a relative ischemia in the most dependent portion of the breast. This often manifests as a dependent rubor with a dilated capillary network being visible through an atrophic and thin cutaneous cover. Such patients are at risk for postoperative complications including ischemia and possible necrosis of the skin, fat and NAC.

position of the NAC are noted. To assess these relationships it is helpful to stand several feet away from the patient as she stands comfortably upright and observe the overall appearance of the breasts. At times it requires a careful and considered side to side comparison, but often subtle differences in the volume or shape of the breasts can be identified. When asymmetries are noted, they often come as a complete surprise to the patient and it can sometimes be helpful to have the patient stand in front of a mirror to confirm these asymmetries. Once identified, each asymmetry can then be discussed as to how it will be treated. It is at this point that a very important part of the preoperative consult takes place. Generally, patients will seek reassurance that any difference in the size or shape of the breasts will be corrected. It is helpful to communicate to the patient that every effort will be made to create the most symmetrical result possible and the overwhelming likelihood is that whatever asymmetries are present will be improved. However, it

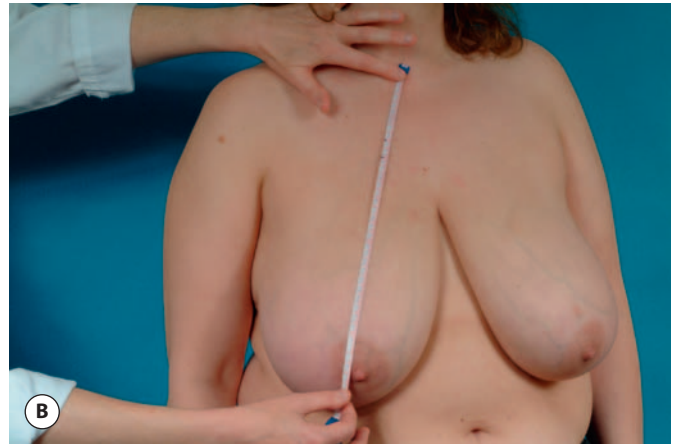
is very common for small asymmetries in size, shape or position to persist even after the breast reduction has fully healed. By proactively discussing the issue of breast asymmetry, patients become better educated as to the challenges that breast reduction can pose with regard to the quality of the final result and are better able to accept and understand any small asymmetries that may persist postoperatively. Using this approach can be a tremendous aid in helping to head off any patient misconceptions about breast reduction and can help to maintain a very high level of patient satisfaction.

Breast Measurements

After a general overview of the size, shape and symmetrical relationship of the breasts is completed, documentation of several key measurements is performed. First, the length from either the midclavicle or the sternal notch to the nipple is measured (**Figure 7.7**). This provides information regarding the length of the breast. In many instances of significant macromastia, this measurement will be in excess of 30 cm. The usefulness of this measurement is somewhat limited, however, in patients undergoing a breast reduction using an inferior pedicle technique as it does not have a direct bearing on the length of the pedicle that will ultimately provide vascular inflow to the NAC. Patients with an excessive clavicle to NAC distance may simply have a breast that is positioned low on the chest wall. For this reason, a second measurement is performed documenting the distance in the midline of the breast from the inframammary fold up to the nipple (**Figure 7.8**). When using an inferior pedicle technique, this measurement provides a direct measure of the length of the pedicle that will be providing vascular inflow to the NAC. As a general guideline, for patients who measure 15 cm or less, necrosis of any portion of the NAC or underlying fat or parenchyma is unusual and an inferior pedicle technique can be used with confidence. For pedicle lengths of 15–20 cm, the risk for vascular compromise increases but does not preclude the safe use of an inferior pedicle technique. For lengths of greater than 20 cm, greater care in the creation and management of the pedicle is strongly advised so as to avoid ischemic complications. Of course, numerous other factors enter into the usefulness of the

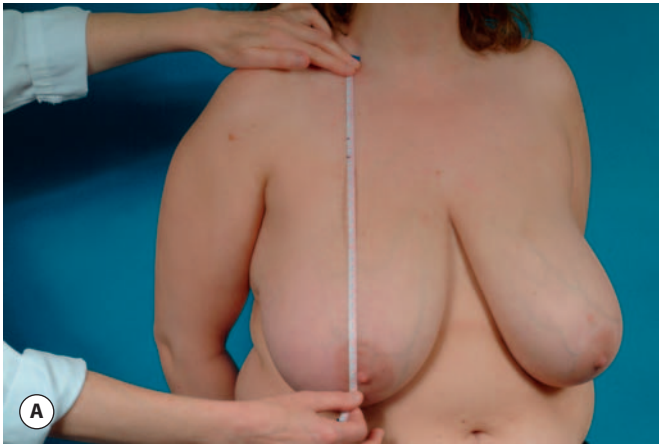

Figure 7.7 (A,B) Preliminary measurements of the breast in preparation for breast reduction include documentation of either the clavicle to nipple distance **(A)** or the sternal notch to nipple distance **(B)**. These



measurements can serve as indicators not only of the size of the breast but also of the degree of ptosis that is present.

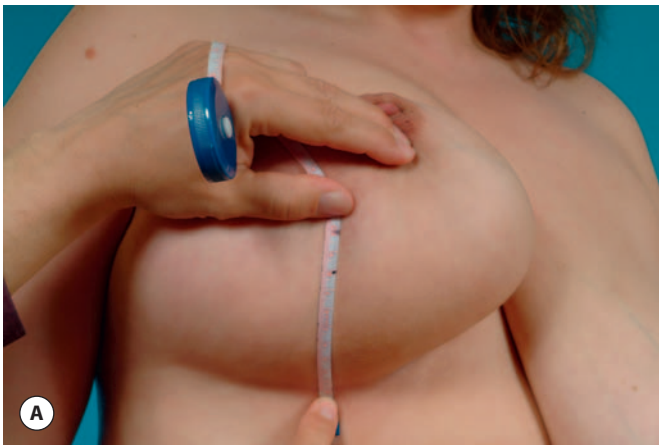
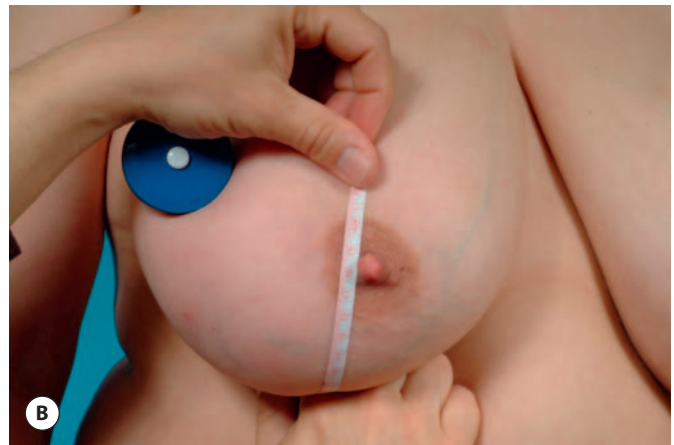
Figure 7.8 (A,B) A more clinically significant measurement in patients undergoing a breast reduction using an inferior pedicle technique is the measured distance from the inframammary fold to the nipple in the relaxed position. This measurement is a more direct indicator of the length of the



pedicle. It is obtained by placing the tip of the measuring tape directly at the fold **(A)** and then allowing the breast to fall naturally under the influence of gravity alone. By gently pulling the measuring tape up to the level of the nipple **(B)**, the pedicle length can be measured.

length of the pedicle as a predictor for potential complications including obesity, volume of reduction, medical illness and a smoking history. It is possible to use inferior pedicles in excess of 30 cm in length without any hint of vascular compromise (**Figure 7.9**). Therefore, despite the lack of direct correlation between the length of the pedicle and the potential for ischemic complications, it is still a worthwhile effort to document this measurement as it can serve as a guide to assist the surgeon in predicting when ischemic complications might become more likely. Lastly, measuring the dimensions of the areola (in cases where the areola is asymmetric) can document the presence of an excessively large areolar diameter. This then triggers discussion of the fact that the areolar diameter will be made smaller. Rarely is this an issue for patients and special requests for an inordinately large or small postoperative areolar diameter can be factored into the surgical plan. As with the subject of asymmetry, it is far better to have these types of discussions ahead of time rather than trying to recover after the fact with the uncomfortable task of having to deal with a dissatisfied patient postoperatively.

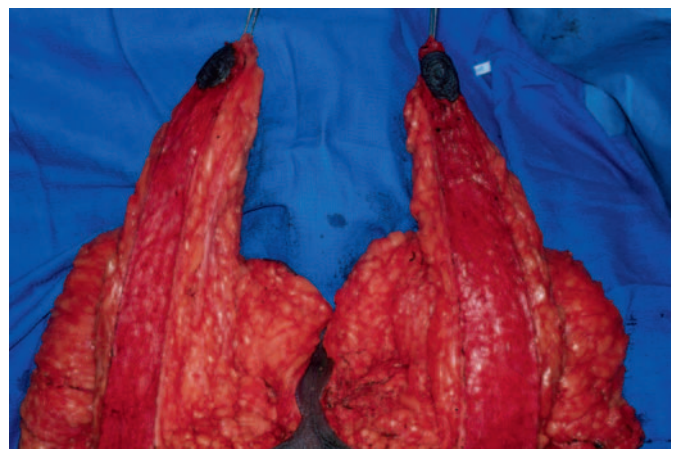


Figure 7.9 When using the inferior pedicle technique, pedicle lengths in excess of 30 cm can be used to maintain the vascularity of the NAC, particularly when the internal breast septum and the associated vascular arcade is preserved during the dissection of the pedicle.

Finally, an estimation as to the weight that will be removed from each breast is performed. This maneuver is extremely subjective and is influenced to a tremendous degree by the experience of the surgeon. To accomplish this task, the underside of the breast is supported with the upturned palms of both hands and the redundant breast is lifted until the weight of the breast is wholly supported by the surgeon. By gently lifting up and down, a 'feel' for the overall weight of the breast can be gained and the amount of excess estimated. This maneuver is performed separately for each breast and the weight estimations adjusted based on a visual determination of the level of volume asymmetry. This information is very useful at the time of surgery and can help guide the amount removed from each breast.

Patient's desires After the overall breast evaluation has been made and the breast measurements have been performed, it is important to assess what the goals of the patient are for breast reduction. It is here that specific issues such as size, shape, areolar diameter and symmetry are optimally discussed. Although most patients will have reasonable expectations, at times it can be surprising to discover what preconceived notions some women can have regarding the results of breast reduction. For instance, one fairly common example is the overweight woman who requests 'A' cup breasts. By sorting out these unrealistic expectations ahead of time, the chances for a misunderstanding between the patient and the surgeon are greatly diminished and the potential for patient dissatisfaction is reduced.

Operative Technique

Overall Strategy

The individual approach that a given surgeon takes toward breast reduction can be quite variable. For instance, some surgeons are quite comfortable with one particular method of breast reduction and simply apply that method in every case, i.e. the inverted T inferior pedicle breast reduction. Other surgeons attempt to apply different techniques depending on several variables including breast size, shape, skin excess and degree of ptosis. Certainly, the variety of different techniques available for breast reduction has increased markedly over the past decade and much attention has been directed at 'short scar' strategies for the treatment of macromastia. Although the 'one technique' approach has served many surgeons well over the years, familiarity with these other techniques allows the surgeon to apply these methods strategically in appropriately selected patients to optimize further the consistency and aesthetic results of breast reduction.

While it is a more versatile technical strategy to attempt to apply different techniques depending on the preoperative appearance of the patient, it can be difficult to sort through the various procedures and, in particular, identify those attributes of each technique that may provide real advantage in specific clinical situations. This is particularly true when individual surgeon's names are used as descriptors of a specific technique and no indication is given as to the specific details of the specific method. Also, small technical modifications are commonly employed by many surgeons that can often be at variance to the original description of a given technique. To avoid this confusion and to help properly evaluate the merits of each individual technique, it is helpful to realize that any breast reduction technique

can be broken down into four elements with each element satisfying a specific surgical goal:

1. Management of the blood supply to the NAC – In any breast reduction procedure, some type of pedicle must be created that preserves the vascularity of the NAC. This strategically sculpted extension of breast parenchyma contains the arterial inflow and venous outflow to that segment of breast parenchyma that includes the NAC. These vessels are not specifically identified within the tissues that make up the pedicle, but rather it is assumed based on previous experience that sufficient vascular communications will be present in a given pedicle to keep the tissues viable. To this end many different pedicles have been described, each with a documented history of success. These include the inferior pedicle, superior pedicle, superomedial pedicle, lateral pedicle, vertical bipedicle, horizontal bipedicle and central mound. Each pedicle choice has certain advantages and disadvantages associated with it, depending on what the other elements of the operative plan include.
2. Management of the excess parenchyma – The redundant parenchyma must be removed without interfering with the vascularity to the pedicle and the NAC. Typically, the decision is first made as to how the pedicle will be constructed and then, almost by default, the redundant parenchyma is removed from around the pedicle.
3. Management of the excess skin – The redundant and usually ptotic skin envelope must be reduced in a manner that creates a pleasing shape and yet minimizes and hides the resulting scar in the most ideal place possible. It is here that the 'short scar' techniques that have been recently described and popularized afford some advantage over the more traditional inverted T approach. As with the choice of pedicle and decisions regarding removal of the excess parenchyma, fashioning an appropriate skin incision pattern must be done in a way that supports and complements the other elements of the procedure.
4. Management of shape – While the overriding goal in breast reduction is to reduce the volume of the breast in an effort to relieve upper torso complaints, it is inescapable that the end result of a successful breast reduction must not only provide a breast that is smaller but also produce a breast that has a pleasing shape. Here again, several different techniques have been described to provide 'shape' which range from simply relying on the skin envelope to support the breast, to the use of internal suturing techniques and even internally based chest wall flaps.

By using this strategy for describing and evaluating a breast reduction technique, it is possible to organize a surgical approach better and develop a understanding of how all the components of a breast reduction procedure fit together to create a successful more complete outcome. To this end, several different combinations of techniques that satisfy these requirements can be recognized as specific methods of breast reduction. Although minor variations on these themes exist, there are basically four distinct procedures that are used to perform breast reduction. These include liposuction breast reduction, vertical breast reduction, short scar periareolar inferior pedicle (SPAIR) breast reduction and inverted T breast reduction with or without a free nipple and areola graft. Each of these procedures will be described in detail.

Liposuction Breast Reduction

Operative strategy overview While recent developments in breast reduction technique have focused on reducing the extent of cutaneous scarring, perhaps no other strategy is more effective at accomplishing this than liposuction breast reduction (LBR). Although some have referred to LBR as ‘no scar’ breast reduction, it is perhaps more accurate simply to recognize that whatever small scars are created are generally so inconsequential as to be of no significance at all. In this method, standard liposuction technique is applied to the breast through strategically placed stab incisions to allow sufficient reduction in breast volume to be performed. These scars can be hidden in the inframammary fold, around the areolar junction with the breast and in the axilla. Using two entry portals allows for crosshatching to be performed and more effectively allows for the removal of greater amounts of breast volume than one portal alone. Several reports have documented the utility of this technique in safely reducing the breast in a fashion that does not interfere with the

subsequent ability of the breast to be appropriately screened with mammography. In difficult cases, magnetic resonance imaging (MRI) evaluation can be used to visualize dense areas. What becomes an issue in LBR is the ability to remove appropriate amounts of tissue in dense breasts as well as managing the redundant skin envelope once the volume is reduced. Certainly, in the aged breast, when the bulk of the breast volume is made up of fat, a significant volume reduction can be accomplished with relative ease. In the more youthful fibrous breast, volume reduction can be somewhat limited using standard liposuction technique. In these cases, it may be more helpful to use alternative techniques such as ultrasound assisted liposuction (UAL) or power assisted liposuction (PAL) to extract the fat from within the interstices of the breast parenchyma more effectively. Once the desired volume reduction is performed, a relative excess of skin is created. In young patients with a more elastic skin quality, a mild rebound contraction takes place with modest amounts of fat removal and acceptable results can be obtained without the need for any type of skin tightening procedure (Figure 7.10). In

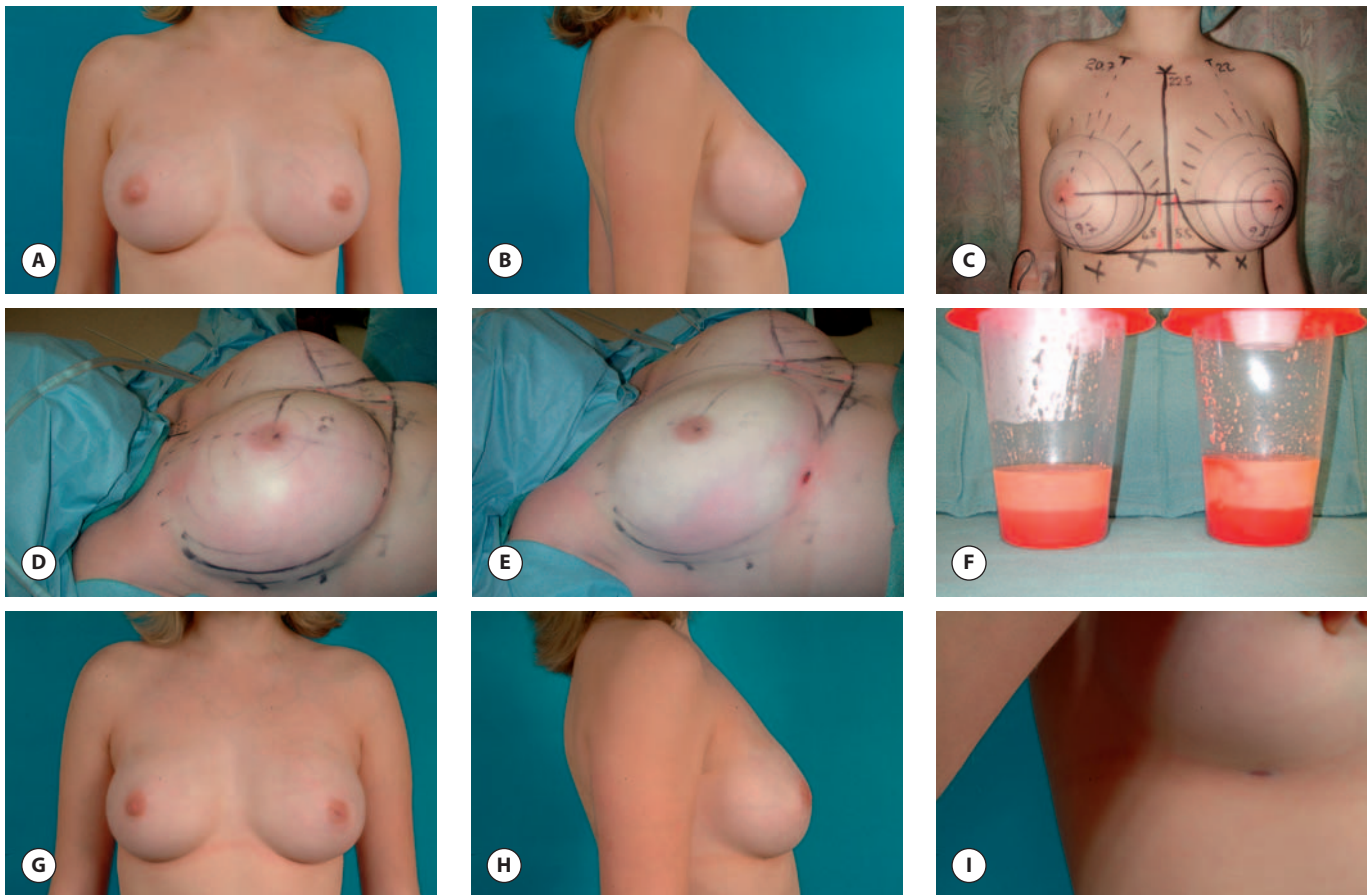


Figure 7.10 (A,B) Preoperative appearance of a 19-year-old woman who presents with mild macromastia. In addition to strain on her neck and back, she notes difficulty wearing clothes and participating in sports-related activities. As a result of the relatively modest amount of volume that will need to be removed to relieve her symptoms, as well as the likelihood that her skin will rebound and not create any redundancy after volume reduction, she presents as an excellent candidate for liposuction breast reduction. (C) Preoperative marks in preparation for liposuction breast reduction. (D,E) Intraoperative appearance of the right breast after the addition of 500 cc of tumescent fluid through an inframammary fold stab incision (D).

After the fat and fluid have been removed via power assisted liposuction technique using a 4 mm five-hole mercedes tip cannula, the size and contour of the breast is visibly reduced (E). (F) Appearance of the liposuction aspirate from each breast. (G–I) Ten-week postoperative appearance after the removal of 200 cc of fat from each breast. The breasts are smaller, more comfortable and better proportioned relative to the remainder of her body habitus, all accomplished without the need for any skin incisions on the breast. The scar resulting from the small stab incision hides easily within the inframammary fold (I).

older patients, this effect is less dramatic and an excessive and ptotic skin envelope can result after volume reduction that exacerbates the ptotic appearance of the breast. While some surgeons have simply accepted this unavoidable and variably unaesthetic ptotic breast shape, others have applied skin envelope reduction techniques in an attempt to improve the aesthetic result. In all instances, however, the simplicity and speed with which the procedure can be performed makes it an attractive technique in appropriately selected patients. Using the technique analysis described previously, LBR involves basically the use of a central mound to maintain the vascularity of the NAC, removes tissue in a diffuse fashion from each segment of the breast, either accepts skin redundancy or uses a standard skin excision pattern to take up the excess skin and shape the breast.

Marks In younger patients who will not require tightening of the skin envelope after volume reduction, strategic placement of the incision portals can result in well-hidden and almost imperceptible scars. Also, placing incision portals in different quadrants of the breast can allow for passage of the liposuction cannula in a crisscrossing manner, resulting in smoother fat removal, which minimizes the potential for the creation of inadvertent divots or other contour irregularities. One strategy combines the use of a stab incision in the medial and lateral portions of the inframammary fold. This can be combined with an incision at the areolar border or high in the axilla to provide a different axis of approach for passage of the liposuction cannula. Using different approaches maximizes the ability of the surgeon to remove appropriate amounts of fat evenly and thoroughly from each quadrant of the breast. Touch up spot removal is also facilitated.

In patients who will have an excessively redundant skin envelope after volume reduction, a decision must be made as to the management of this excess skin. In selected cases, it may be reasonable simply to accept the redundant and underfilled skin envelope as a consequence of the volume reduction. The breast will have a decidedly unaesthetic appearance; however, the procedure is simple and can be performed quickly. Recovery is relatively easy and relief of symptoms is fairly predictable. Patients who are candidates for LBR alone with no skin excision include the elderly as well as patients who are considered to be at increased risk for complications resulting from a prolonged operative procedure. Also, certain patients may simply elect to decline skin envelope reduction secondary to concerns over the scar, or lack of concern over the less than ideal resulting shape of the breast. Conversely, if the shape of the breast is a concern, a standard skin envelope reduction pattern can be diagrammed and the access portals for liposuction incorporated into this pattern. Everything from a periareolar approach to a full inverted T skin pattern can be used, depending on the degree of skin redundancy as well as the comfort level of the surgeon. It is important to mark the patient preoperatively exactly as they would be marked for a standard breast reduction using the technique of choice for a given surgeon. Strategically then, once the volume of the breast has been reduced, the skin pattern can be excised removing skin only without the need for any internal dissection of the breast. Placing these marks preoperatively can ease the intraoperative decision making that occurs when the time comes to reduce the skin envelope.

Operative technique Although the procedure could potentially be performed with IV sedation used in conjunction with

tumescent local anesthesia, the use of a general anesthetic is also an excellent option. Using a solution consisting of 1 liter of normal saline combined with 30cc of 1% lidocaine with epinephrine, tumescence of the breast is performed. Fluid is added to the breast until the consistency of the breast is quite firm. Typically, 1 liter of fluid is used in each breast. After appropriate tumescence has been applied, volume reduction is performed using standard liposuction technique. The utilization of smaller three-hole mercedes tip cannulas in the range of 3–4mm in diameter can help prevent inadvertent over-resection of fat with the creation of contour irregularities as can potentially occur when larger, more aggressive cannula diameters are used. Fat removal is concentrated evenly around the more superficial and peripheral contours of the breast, as well as deeply under the breast. Finally, the cannula is passed directly through the substance of the breast in an attempt to remove fat from within the more dense fibroglandular stroma. This maneuver will be more successful in older patients or more obese patients where much of the breast has been replaced by fat. In younger patients or patients with a more dense character to the breast, it will be much more difficult to remove this interstitial fat. In these types of patients, power assisted liposuction or the use of ultrasonic liposuction is more effective in removing this interstitial fat. Volume removal proceeds until the desired effect is noted. As the liposuction aspirate collects in the catch container, the fat will be noted to float on top of the tumescent fluid, which allows direct measurement of the amount of fat removed. Although small amounts of actual breast parenchyma can be sheared off and removed with the fat, the contribution of this tissue to the overall volume of aspirate is negligible.

After appropriate volume reduction has been performed, the redundant skin envelope is addressed. There is no need to perform any deep dissection within the breast to remove additional volume, therefore removal of the redundant skin envelope is simply a superficial procedure. The redundant skin is removed according to the previously made marks, limiting the resection to no deeper than the dermis. Additional tailoring can be performed as needed to recontour the breast into the most aesthetic shape possible. The incisions are then simply closed without the need for any drains ([Figures 7.11, 7.12](#)).

It is my personal preference nearly always to plan a skin envelope reduction along with the reduction in breast volume and I have found the circumvertical pattern to be a very effective pattern to use in these cases. The skin pattern is marked exactly the same as a standard SPAIR mammoplasty. After the volume has been reduced, the skin envelope is temporarily tailor stapled into position along the previously made marks or until a pleasing shape has been created and the margins of this final pattern are then marked. After removing the staples, the segments of skin that will need to be removed can easily be seen and full thickness excision is performed. No attempt to dissect deeply into the breast is made for fear of devascularizing the NAC. Using this strategy, an effective breast reduction can be performed and the redundant skin envelope taken up, without the need for internal dissection of breast flaps.

Postoperatively, a support garment is worn simply for comfort for a period of 4–6 weeks or until the swelling has largely resolved. Wound care proceeds as for any surgical incision. Any exposed suture ends are clipped at 7–10 days and the incision is treated with a vitamin E-based scar cream for a period of 6 weeks. Decisions regarding return to work are made individually

depending on the nature of the patient's occupation. Many patients can return to light duty in as little as 3–5 days; however, I allow up to 6 weeks off for occupations involving heavier manual labor. Recreational aerobic or weight lifting activities are restricted for 4 weeks from the time of surgery.

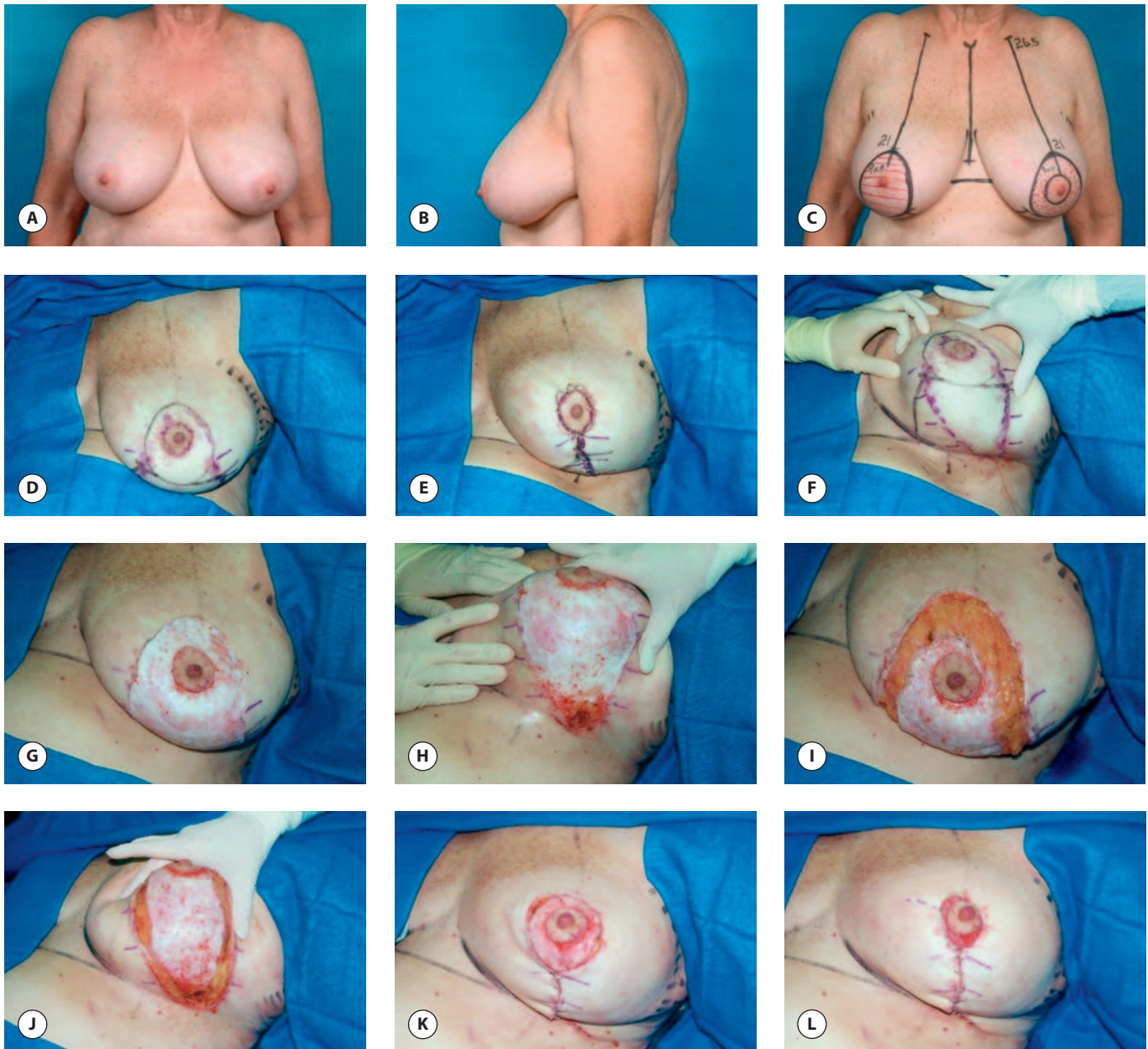


Figure 7.11 (A,B) Preoperative appearance of a 70-year-old woman who presents with an invasive lobular carcinoma of the right breast in association with left macromastia. (C) Preoperative marks in preparation for a right modified radical mastectomy with immediate latissimus dorsi flap with tissue expander breast reconstruction and left breast reduction using liposuction followed by skin envelope recontouring using a circumvertical technique. (D) Immediate postoperative appearance of the left breast after reduction using power assisted liposuction technique. The skin envelope is redundant and ptotic. (E) After circumvertical plication, the base diameter of the breast is narrowed, the NAC lifted and the overall shape of the breast

is improved. (F) Appearance of the inferior pole of the breast after removal of the plication staples showing the vertical segment that will need to be de-epithelialized. (G,H) The redundant skin envelope identified by the plication maneuver is de-epithelialized. Note the access portal at the base of the vertical segment that was used to perform the liposuction. (I,J) The margins of the de-epithelialized segment are scored through the dermis, but no deeper, to allow easier closure without creating tissue crowding. (K,L) After closure of the vertical segment (K), a purse string suture is used to cinch down the periareolar defect (L).

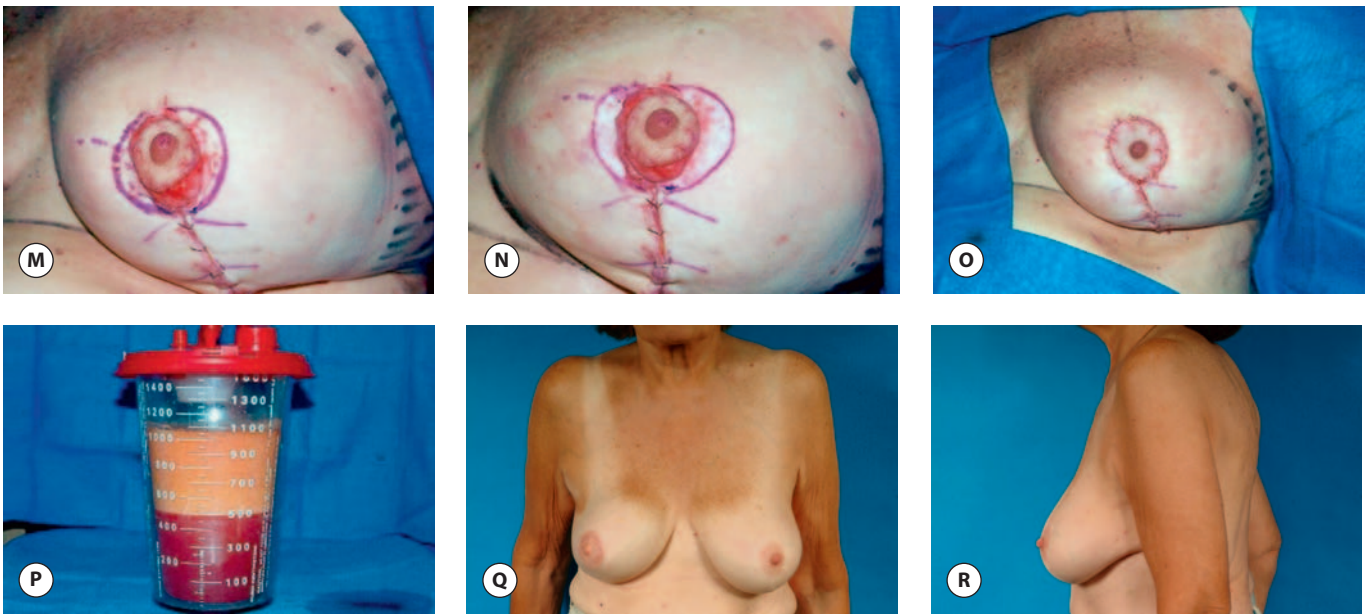


Figure 7.11 (Continued) (M–O) The irregular periareolar defect (M) is rounded off and the additional skin de-epithelialized to create a circular defect (N), before final closure is accomplished (O). (P) Appearance of the aspirate showing that approximately 550 cc of fat was removed from

the breast. (Q,R) Four-year postoperative result after replacement of the tissue expander on the right with a permanent silicone gel implant and reconstruction of the NAC.

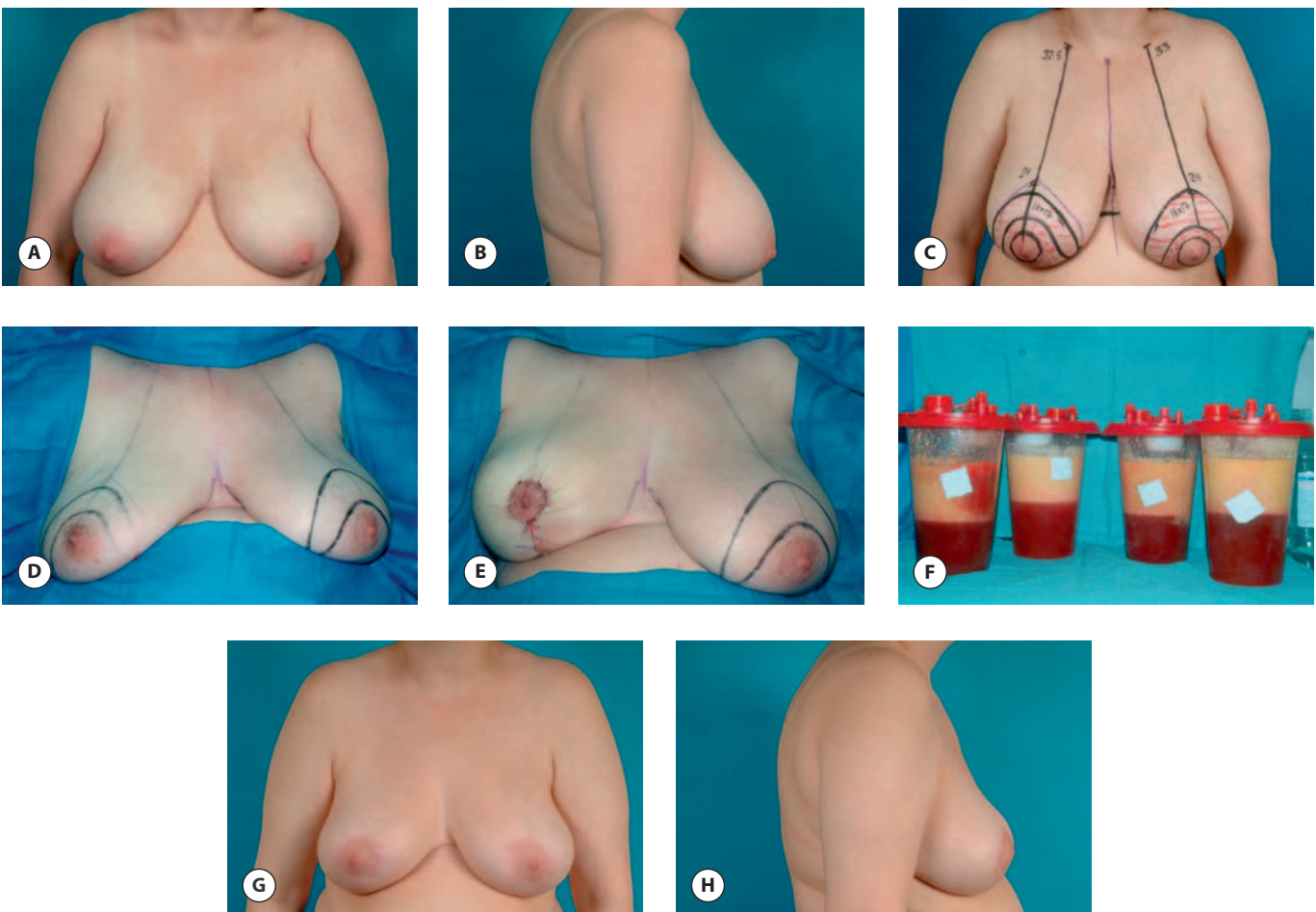


Figure 7.12 (A,B) Preoperative appearance of a 42-year-old woman in preparation for liposuction breast reduction followed by skin envelope recontouring. (C) Preoperative marks demonstrating the planned circumvertical recontouring strategy. (D) Immediate appearance of the right breast after power assisted liposuction reduction. (E) Appearance after skin envelope recontouring using a circumvertical pattern. (F) Appearance

of the liposuction aspirate after removing 1200 cc of fat from each breast. (G,H) One-year postoperative appearance demonstrating a reduction in breast volume, a lifting of the position of the NAC and an aesthetic recontouring of the skin envelope. It is important to note, however, that the upper pole contour remains underfilled as a result of the lack of direct internal tissue rearrangement that is afforded by more invasive approaches.

It must be recognized that, while this operative strategy is simple and can be considered to be relatively less invasive than standard reduction techniques, several disadvantages are associated with this technique. Perhaps the most significant technical disadvantage is that no internal breast rearrangement or direct breast re-shaping can be performed. Where this effect is most dramatically noted is in the upper pole of the reduced breast. Very typically, a hollowing out of the upper pole is created after volume reduction via liposuction and, while the skin tightening may initially seem partially to correct this contour, the effect is short lived. Once the swelling in the breast recedes, the skin envelope inevitably relaxes and a hollowing out of the upper pole of the breast is the result. If patients have not been advised of this beforehand, it can potentially be a source of patient dissatisfaction postoperatively. In addition, since very little actual breast parenchyma is removed in the aspirate, any opportunity to screen the tissue via histologic examination is essentially lost. Therefore, in patients who have any marker for potential breast pathology including a previous family history of breast cancer, or previous biopsies documenting histologic changes associated with increased risk for breast cancer, LBR may not be the ideal choice as a breast reduction technique as the opportunity to screen the breast specimen for pathology is lost. Despite these limitations, it is advisable to send the liposuction aspirate to pathology for analysis. By doing so, the volume of tissue removed is documented and at least a general and non-specific histologic evaluation of a portion of the aspirate can be performed. Should an occult breast cancer be identified in the aspirate, appropriate treatment options could be considered, with the most likely treatment option being mastectomy since the exact location of the tumor would be unknown.

It is highly recommended that the patient obtain a baseline postoperative mammogram once the breast has fully healed to document the postoperative mammographic appearance of the breast. This is done anywhere from 6 to 12 months after the procedure. In this fashion, any future mammograms can be compared to the baseline study to allow better interpretation of any questionable findings which may develop.

Vertical Breast Reduction

Operative strategy overview Up until the mid-1990s, the most commonly used method for breast reduction by far was the inverted T inferior pedicle technique. Although effective, this technique resulted in an inframammary scar that extended from the parasternal area to the axilla in many patients. While it was recognized that this scar was unavoidable, it was still seen as a significant disadvantage, particularly when it healed in anything less than a fine line fashion. Therefore, when the ‘vertical’ mammoplasty was introduced to plastic surgery, a great deal of interest resulted. This technique allowed a breast reduction to be performed with only a periareolar and a vertical scar with the majority of the inframammary scar being eliminated. In general terms, the technique is based on a superior or superomedial pedicle with the excess parenchyma being removed from the inferior pole of the breast. A combined periareolar and vertical skin resection pattern is used and simple skin redraping is relied upon to shape the breast. Although this surgical strategy seems relatively straightforward, many nuances have been incorporated into the individual applications of the technique by surgeons around the world and in depth considerations of these nuances are beyond the intent of this book. What will be described here is a vertical technique

that incorporates the basics of the procedure with modifications designed to minimize the disadvantages.

Pedicle The original descriptions of the vertical mammoplasty based the blood supply to the NAC on a superior pedicle. While this pedicle was familiar to plastic surgeons around the world, most American plastic surgeons had no experience with it. This is likely why the procedure was relatively slow to catch on in the USA. At times, the pedicle construction in the hands of some surgeons created a flap of tissue that appeared alarmingly thin with the possibility of compromise of the vascularity to the NAC being a real concern. And, in fact, as the technique became more commonly practiced in the USA, anecdotal reports of NAC necrosis raised concerns about the reliability of the superior pedicle. To address these concerns, a slight reorientation of the pedicle into more of a superomedial direction was described. This essentially increases the chances that the flap of tissue carrying the NAC will include the robust second intercostal perforator off the internal mammary system. Also, when the NAC is rotated up into the periareolar defect, less tension is placed on the NAC than with the standard vertical pedicle. As a result there is potentially less compromise to the blood supply to the NAC. This superomedial pedicle modification is now utilized by many surgeons who use the vertical mammoplasty technique.

One additional variable that impacts the construction of the pedicle is the size of the breast and the magnitude of the proposed breast reduction. Although experienced surgeons can apply the technique in cases where 1000 grams or more of tissue is removed from each side, the risk for vascular compromise to the NAC is increased as the length of the pedicle becomes longer. Also, subsequent shaping of the breast and tailoring of the skin envelope becomes very difficult in these larger reductions and wound breakdown with delayed healing and excessive scarring along the inferior pole of the breast is a significant concern. For these reasons, it is my practice to limit the use of the vertical technique to those patients who I estimate will comfortably have up to 300–400 grams of tissue removed from each side depending on other variables such as body habitus, ptosis and overall health. Specifically, for example, if the patient is obese, has an excessive skin envelope or has a smoking history, I will use another technique. By constructing a generous pedicle that does not require excessive undermining to transpose, the blood supply to the NAC can be reliably preserved.

Parenchyma With the creation of a superior or superomedial pedicle, the tissue in the inferior pole of the breast becomes expendable and it is this tissue that is removed to accomplish the breast reduction. Typically, removal of tissue can be feathered around the pedicle to allow additional amounts of parenchyma to be removed as needed. This is a technical maneuver that must be performed with great care as over-resection of tissue in this area can create a divot-like deformity in the inferior pole of the breast. At times, this resulting cleft is seen only when the patient raises her arms and puts the lower pole of the breast under a relative stretch and, occasionally, it can be seen even as a static deformity with the arms at the sides (Figure 7.13). This potential complication

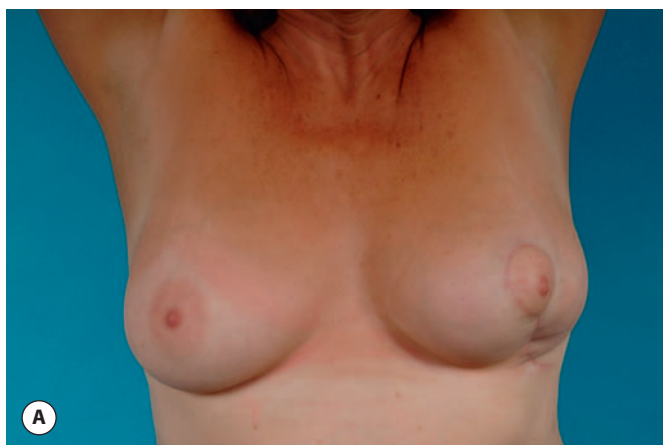
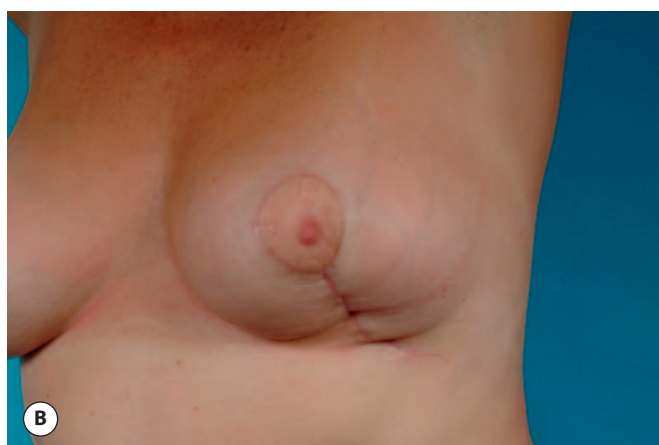
Figure 7.13 (A,B) Appearance of a patient who has undergone a vertical mammoplasty on the left. When she raises her arms, the tension along the



inferior pole of the breast highlights the notch that is very commonly left over after the tissues in the inferior pole have been resected.

is made even more troublesome by the fact that it is very hard to predict when this complication will occur as traditional vertical technique has advocated that the inferior pole of the breast be made to appear markedly flattened and even distorted to a certain extent at the end of the procedure. Therefore, the shape that will result in the inferior pole of the breast once full settling has taken place can be a source of uncertainty. This aspect of the vertical mammoplasty creates a significant conceptual problem. Vertical mammoplasty enthusiasts believe that removing this inferior pole tissue will prevent the breast from developing the well-known complication of 'bottoming out' with loss of an aesthetic lower pole contour. What remains underemphasized is that the surrounding breast parenchyma that is expected to fall into the lower pole void also stretches and, in a sense, bottoms out. If the attachments of Scarpa's fascia in the lower pole of the breast are likewise resected with the parenchyma, the propensity of the remaining lower pole tissues to 'bottom out' into the subscarpal space is further aggravated. This phenomenon was recognized early on thus leading to the realization that if the lower pole contour was not overcorrected initially, an overly ptotic and elongated lower pole with an inordinately high NAC position could result. In effect, the eventual shape of the breast that results after vertical mammoplasty actually depends on a certain and undefined component of bottoming out. Therefore, the technical challenge of removing just enough tissue from the lower pole of the breast to allow the surrounding parenchyma to fall into the void and, at the same time, predicting how much the breast would settle seems to be a relatively unpredictable task, leaving the quality of the final result perhaps more to chance than might be optimal. Also, these uncertainties become more significant as the amount of breast tissue removed increases.

To make this part of the procedure more predictable, it is my practice never to create a discernable void in the inferior pole of the breast after resection of the lower pole tissue. The medial and lateral breast flaps on either side of the resection cavity must fall in and meet in the midline. When the tissues are particularly loose, these flaps or 'pillars' as they have been referred to can be sutured together for additional support. Also, the attachments of Scarpa's

fascia to the underside of the breast are respected and preserved to avoid opening up the poorly reinforced loose subscarpal space to pressure from above. While surprisingly large amounts of tissue can be removed respecting these technical modifications, again limiting the amount resected to 400 grams or less greatly assists in making the aesthetic result more predictable.

Skin The original description of the vertical mammoplasty advocated creating a periareolar opening that had the exact circumference as the incision in the areola. In this way, the two incisions would match perfectly, creating a well-healed and inconspicuous scar. This strategy, however, created an incision length from the bottom of the periareolar pattern down to the inframammary fold that could reach alarming lengths in larger reductions. The length of this 'vertical' incision could be reduced somewhat by stopping the inferior extent of the incision short of the IMF by several centimeters and then adding an additional component of plication after the breast had been reduced. This maneuver tended to prevent the vertical scar from extending down onto the abdomen. Also, the placement of an accordion type suture pulled up to gather the incision was advocated as a means of shortening the distance between the IMF and the bottom of the areola. Despite these maneuvers, one of the hallmark complications of a less than ideal result after a vertical mammoplasty is a bottomed out, ptotic appearing breast where the distance from the IMF to the bottom of the areola is far too long and out of proportion to the overall shape of the breast. In essence, since the length of the periareolar and areolar incisions are nearly equal, any redundancy in the skin pattern must be taken up by the vertical segment alone. In larger breast reductions, this can result in a pronounced excess of bunched skin at the bottom of the vertical segment near the IMF. Several strategies for managing this bunched skin have been advocated, including the use of purse string sutures, debulking with liposuction, as well as just simply allowing the area to heal and contract in over time. Despite these surgical maneuvers, the end result of this skin excess problem is often a contracted, irregular and atrophic scar that distorts the lower pole of the breast. It is most often visible when the arms

are raised over the head but, in severe instances, can be seen as a static deformity with the arms at the sides. With this in mind, it is telling that secondary revision of this lower pole deformity accounts for many of the revisionary procedures that have been reported after traditional vertical mammoplasty. To avoid these types of complications, it is far better to distribute the stress of managing the redundant skin envelope over the entire incision length. This is accomplished by diagramming a periareolar lift type pattern drawn in a manner very similar to a patient undergoing a circumvertical mastopexy where the outer periareolar incision has a larger diameter than the inner areolar incision. By using a purse string suture to control the larger periareolar opening, the dimensions of the vertical incision can be diminished, which places less overall stress on the vertical component. Secondly, there is no significant drawback to curving the inferior portion of the incision out laterally near the IMF to help take up the remaining vertical component of excess skin. This curvilinear skin takeout allows skin to be removed along two vectors both horizontally and vertically, a maneuver that affords great latitude in taking out any redundant skin and negates any potential for the vertical scar to extend down onto the chest wall as can happen with a straight vertical skin takeout. For vertical mammoplasty 'purists', these modifications run against the traditional teaching of precisely equal periareolar closures and a vertical component that runs straight down to the IMF without medial or lateral deviation. However, once these modifications become part of the overall plan, the advantages of the vertical, or more precisely the circumvertical mammoplasty, become evident.

Shape Because the initial shape of a standard vertical mammoplasty can be so distorted, it is difficult to reliably perform any additional and separate shaping maneuvers other than simply to close the vertical incision and allow the postoperative settling process to run its course. In traditional vertical technique, when the immediate postoperative result is created, the remaining breast parenchyma is forcibly pushed into the upper pole of the breast to such an extent that the upper pole actually bulges. When this is combined with the flattened lower pole contour created by the aggressive vertical closure along with the bunched skin closure just above the IMF, the result can be decidedly unaesthetic. This is, however, how the initial result must appear as significant settling of the breast does occur. As the skin envelope relaxes, the forces shifting the breast parenchyma superiorly are overcome by gravity and, more often than

not, an acceptable breast shape ultimately results. However, there is no direct control, particularly in the upper pole. This can be problematic for patients who present with an upper concavity as it is very likely this concavity will persist after the final shape has settled into place. When the modifications described previously are employed, these early shape issues are avoided as the breast demonstrates an aesthetic appearance immediately and maintains a pleasing shape during the healing process. As a result, the need for shaping maneuvers can be assessed and performed as needed with confidence. Therefore, in selected patients, it is possible to undermine the breast in a subglandular plane and use the suture suspension technique described previously for augmentation mastopexy to autoaugment the upper pole of the breast. Since the shape of the breast can be assessed immediately, these sutures can be used to good effect to fill in any preoperative upper pole concavity that may be present.

Taking these considerations into account, the following modified vertical mammoplasty technique is recommended in appropriately selected cases. Patients who are candidates for this procedure are those who need only a modest reduction of approximately 400 grams or less, although it is possible to push this limit to roughly 500 grams as needed. Typically, the breast preoperatively has a full appearance without an overly ptotic or excessively redundant skin envelope. Also, the technique works best in patients who do not have an excessive upper pole concavity as this contour is better corrected using the SPAIR technique.

Marks The marks for this modified vertical mammoplasty are straightforward and easy to apply. With the patient standing upright and the shoulders held in a tension free posture, a line joining the two inframammary fold locations is marked across the torso so that it can be seen in the midline area between the breasts (Figure 7.14 C). If the inframammary folds are asymmetric, the higher fold line is used as the reference line. The breast meridian is then diagrammed on each side in such a way so as to divide the breast vertically into two equal halves (Figure 7.14 D). Measuring up from the inframammary fold reference line in the midline, an additional line is marked extending superiorly in 1 cm increments. At the 4 cm mark, a second line is drawn parallel to the inframammary fold reference line and this line extends across the tops of the breasts such that it intersects the breast meridian on each side. This then becomes the superior extent of the proposed periareolar incision (Figure 7.14 E). By then transposing the breast superomedially and superolaterally, the breast meridian can be 'ghosted' onto the breast to identify the medial and lateral

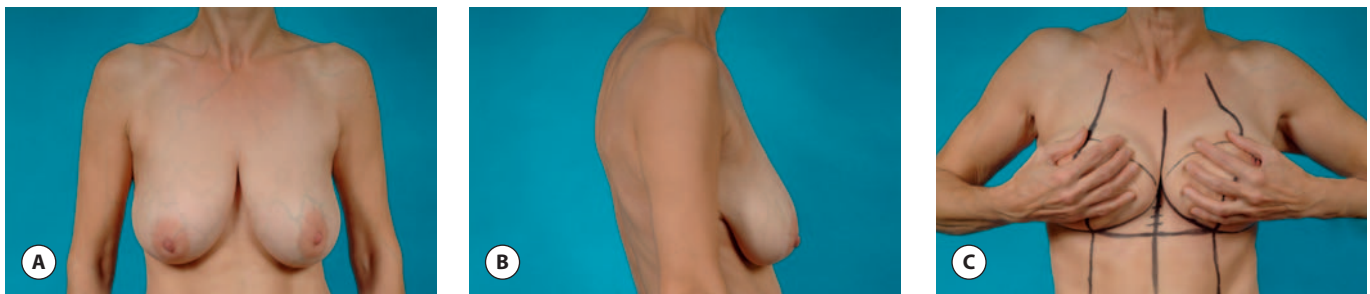


Figure 7.14 (A,B) Preoperative appearance of a 48-year-old woman in preparation for breast reduction using the vertical technique. (C) A line connecting the location of the inframammary fold on each side is drawn

across the midline to allow the location of the fold to be seen with the breasts in repose without any manipulation possibly distorting the fold position.

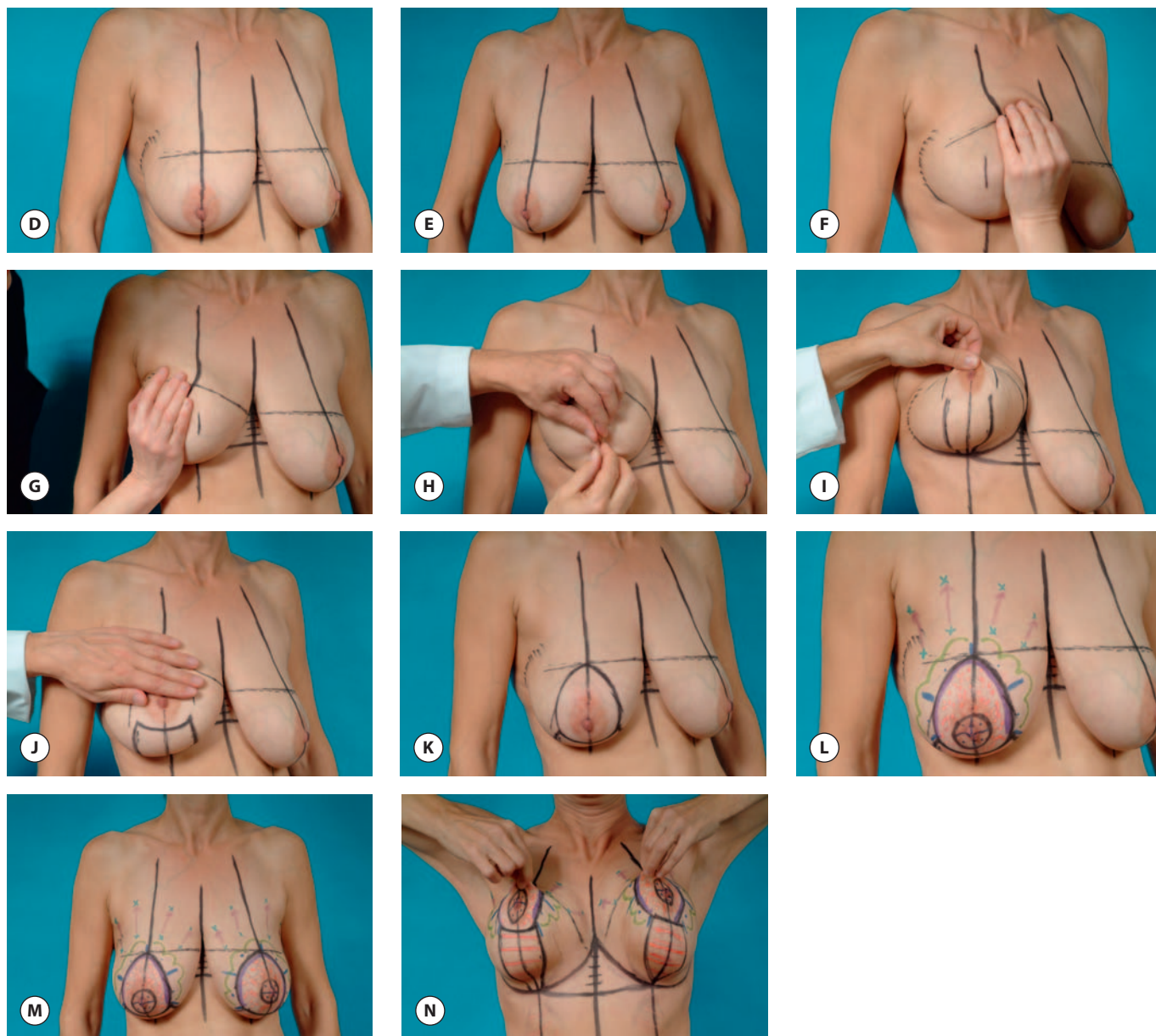


Figure 7.14 (Continued) (D) A breast meridian is then drawn in such a way so as to divide the breast into two equal halves. It is important to ignore the position of the nipple as this line is drawn as many nipple positions are translocated either medially or laterally and using an off center nipple position could skew the location of the breast meridian. (E) A line is drawn in the midline marked off in centimeter increments. For most patients, by measuring up 4 cm from the inframammary fold line and then marking a line parallel across the chest until it meets the breast meridian, the proper location for the top of the periareolar pattern will be identified. This point can be raised or lowered as needed according to the judgment and experience of the surgeon to meet the needs of an individual patient. (F,G) By transposing the breast superomedially and superolaterally and 'ghosting'

the position of the meridian onto the breast, the medial and lateral extent of the periareolar pattern can be determined. (H,I) By pinching the lower pole skin envelope with a pinching maneuver applied by fingers, a pleasing breast shape can be created. This maneuver identifies the approximate margins of the vertical takeout that will be required to create an aesthetic breast shape. (J,K) By drawing a line just under the inferior border of the areola and smoothly communicating this line around to the medial, superior and lateral marks, an elongated oval will result that then identifies the dimensions of the periareolar component. (L) The eight cardinal points used to identify the fixation points for the interlocking Gore-Tex suture are applied and the proposed locations for the subglandular suspension sutures are drawn. (M,N) Symmetrically applying the marks completes the marking process.

extent of the periareolar pattern (Figure 7.14 F,G). The margins of the proposed vertical extension of the pattern are then marked. By lifting the top of the areola up to the desired level on the breast, the inferior pole of the breast can be pinched together until a pleasing shape has been created. The approximate location of this vertical takeout is then estimated and marked with the

line extending down to the inframammary fold (Figure 7.14 H,I). When the distance from the IMF to the nipple exceeds 10cm, it is best to begin to draw the inferior vertical segment with a slight lateral curve as it extends inferiorly toward the IMF. This will prevent the vertical incision from becoming too long and will help shape the breast appropriately. A smooth line is then drawn just

below the inferior margin of the areola and the medial, superior and lateral points are joined into a smooth and slightly elongated oval (Figure 7.14 J,K). Since the management of the periareolar opening is similar to that which occurs in an augmentation mastopexy, it is possible to use the interlocking Gore-Tex technique to assist in managing the periareolar closure. These marks are applied as desired by marking the eight cardinal points around the areola as well as around the periareolar incision (Figure 7.14 L). Symmetrically applying the marks from side to side completes the marking pattern (Figure 7.14 M,N).

Operative technique At the time of surgery, the areola is placed under maximal tension with the aid of a breast tourniquet and an areolar diameter of 40–44 mm is marked with the aid of a multidiameter areolar marker (Figure 7.15 A,B). The areolar and periareolar incisions are then made and the intervening tissue de-epithelialized (Figure 7.15 C). The dermis is divided around the periphery of the periareolar opening leaving a small 5 mm dermal cuff that will ultimately hold the Gore-Tex purse string suture. This dermal cuff is undermined directly at the level of the dermis for a distance of 1–2 cm back from the incisional edge. This eventually will allow the periareolar opening to be closed without inordinate bunching or tissue crowding (Figure 7.15 D). The proposed vertical skin incisions are then made and the intervening segment of breast tissue removed (Figure 7.15 E–G). Trimming either medially or laterally can be performed as needed to reduce the breast further. If needed, the parenchymal removal can extend medially and laterally around the inferior half of the areola. Every effort should be made to keep the attachments of Scarpa’s fascia to the underside of the breast intact. At no time should the amount of tissue that is removed be so extensive that a void is created in the inferior pole of the breast. If desired, the breast can now be undermined in the subglandular plane to allow the underside of the breast to be advanced superiorly. This undermining is limited to the central breast area and every effort is made to keep the internal mammary perforators intact (Figure 7.15 H,I). By advancing the deep surface of the breast superiorly and suturing it to the pectoralis major fascia with a 3-0 absorbable monofilament, any preoperative concavity that may have been present in the upper pole of the breast can be corrected. One to three such sutures can be used as needed to shape the upper pole (Figure 7.15 J). Once the desired amount of tissue has been removed, the vertical pillars are closed again with a 3-0 absorbable monofilament suture (Figure 7.15 K,L) and the skin incision is closed in a tailor tack fashion with staples until a pleasing shape is created (Figure 7.15 M,N). If necessary, the inferior extent of the plication can curve outward along the IMF as needed to create a pleasing aesthetic shape to the lower pole. By inseting the NAC into the periareolar defect again with staples and sitting the patient up, the shape of the breast can be assessed. Further plication, tissue removal or elevation of the NAC can be performed as needed to create the desired result. Once the optimal size and shape have been created, the stapled edges are marked with a surgical marker and the staples removed (Figure 7.15 O,P). The redundant skin is de-epithelialized (Figure 7.15 Q) and the vertical segment closed. A drain may be placed as desired. The NAC is then inset using the interlocking Gore-Tex technique (Figure 7.15 R–T). At this point the breast should have a pleasing shape. Slight fullness in the upper pole and a mild flattening along the

vertical segment are acceptable but should not be so excessive as to detract from the aesthetic appearance of the breast (Figure 7.15 U–X). Dressings consist of Dermabond tissue glue to the incision which is then covered with Opsite dressings. A surgical bra is applied. Postoperatively, suture ends are clipped at 7–10 days and a vitamin E-based scar cream is applied for 6 weeks. Non-strenuous activities are allowed almost immediately; however, vigorous exertion is delayed for 4 weeks. Full healing has generally taken place by 6 months, at which time the final shape of the breast can be reliably assessed (Figures 7.16 A,B, 7.17 A–H).

SPAIR Mammoplasty

Operative strategy overview While the vertical mammoplasty paved the way for a better understanding of how to reduce the breast with fewer scars, there are several disadvantages associated with the procedure including the potential for postoperative shape distortion with a high-riding NAC and wound breakdown at the inferior margin of the vertical incision. Also, these complications become more likely with larger reductions. However, it is the necessity to significantly over-correct the shape of the breast with an attendant settling period where the shape of the breast matures over time that is problematic for many surgeons as most patients have a desire to achieve a more or less aesthetic result immediately. In an attempt to address these concerns, a new limited scar procedure called the short scar *periareolar inferior pedicle reduction* or SPAIR mammoplasty has been described that is designed to allow an effective reduction in breast volume to be performed while, at the same time, providing an excellent shape with a limited cutaneous scar burden. The procedure bases the blood supply to the NAC on an inferior pedicle, resects tissue peripherally from around the superior hemisphere of the pedicle, uses a circumvertical skin management strategy and controls shape with internal suturing. This procedure has proven to be an excellent option for a wide range of patients ranging from those seeking simple mastopexy to those needing reductions of 2000 grams or more.

Marks The marking pattern for the SPAIR procedure is best applied with the patient standing upright, weight evenly distributed on both feet and the shoulders and arms held in a tension free and loose posture at the sides (Figure 7.18 A,B). The goal of the marking pattern is to identify the dimensions of the skin envelope that will need to be preserved to easily wrap around the inferior pedicle that will be used to carry the NAC. To this end, this operation typifies exactly the old axiom that it is not what is taken that is important, but rather it is what is left behind that will most directly affect the final result. Initially, the midline over the sternum is marked along with the location of the inframammary fold on each side. The most inferior extent of the inframammary fold for each breast is identified and a line connecting these two points is carried across the midline. If the two folds are at different levels, these two lines will not intersect and further marks are based on the higher of the two folds. This line drawn across the torso allows the location of the fold to be identified visually without the need to manipulate the breast in any way (Figure 7.18 C,D). Laterally, the inframammary fold line is extended over and around the lateral margin of the breast to mark the limits of the dissection of the lateral flap (Figure 7.18 E). In the midline, a distance of 4 cm is measured up from the inframammary fold line (Figure 7.18 F)

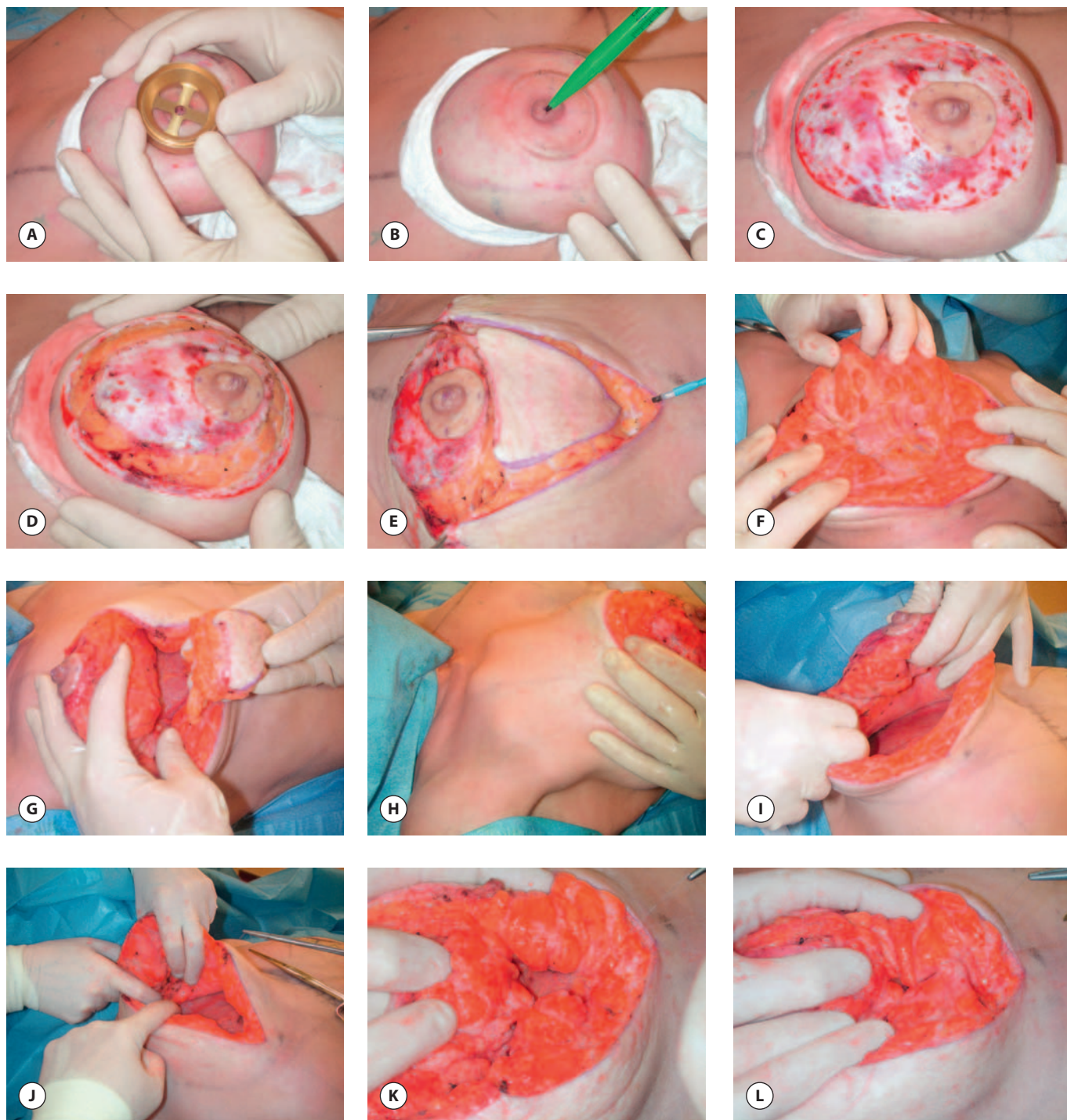


Figure 7.15 (A,B) With the NAC under maximal tension, a 40–44 mm areola is marked with the aid of a multidiameter areolar marker. (C) The areolar and periareolar incisions are made extending partially into the dermis and the intervening segment of skin is de-epithelialized. (D) The dermis is divided leaving a 5 mm dermal cuff that will eventually hold the purse string suture and the periareolar skin edges are then undermined just at the level of the dermis for a distance of 2–3 cm to allow a tension-free purse string closure. (E–G) The margins of the proposed vertical segment are incised (E) and the redundant skin and parenchyma are removed (F,G). Care is taken not to undermine below the inferior attachments of

Scarpa's fascia as they insert into the breast. (H–J) The underside of the superior margin of the breast is undermined in a subglandular plane (H,I) and the leading edge of the superior flap is pulled up and under itself and sutured to the pectoralis major fascia in an attempt to 'autoaugment' the upper pole of the breast and correct a preoperative upper pole concavity (J). (K,L) The vertical pillars are closed to create an aesthetic breast shape. This maneuver also prevents a 'dead space' from forming in the inferior pole of the breast that can lead to notching and shape distortion in the lower pole.

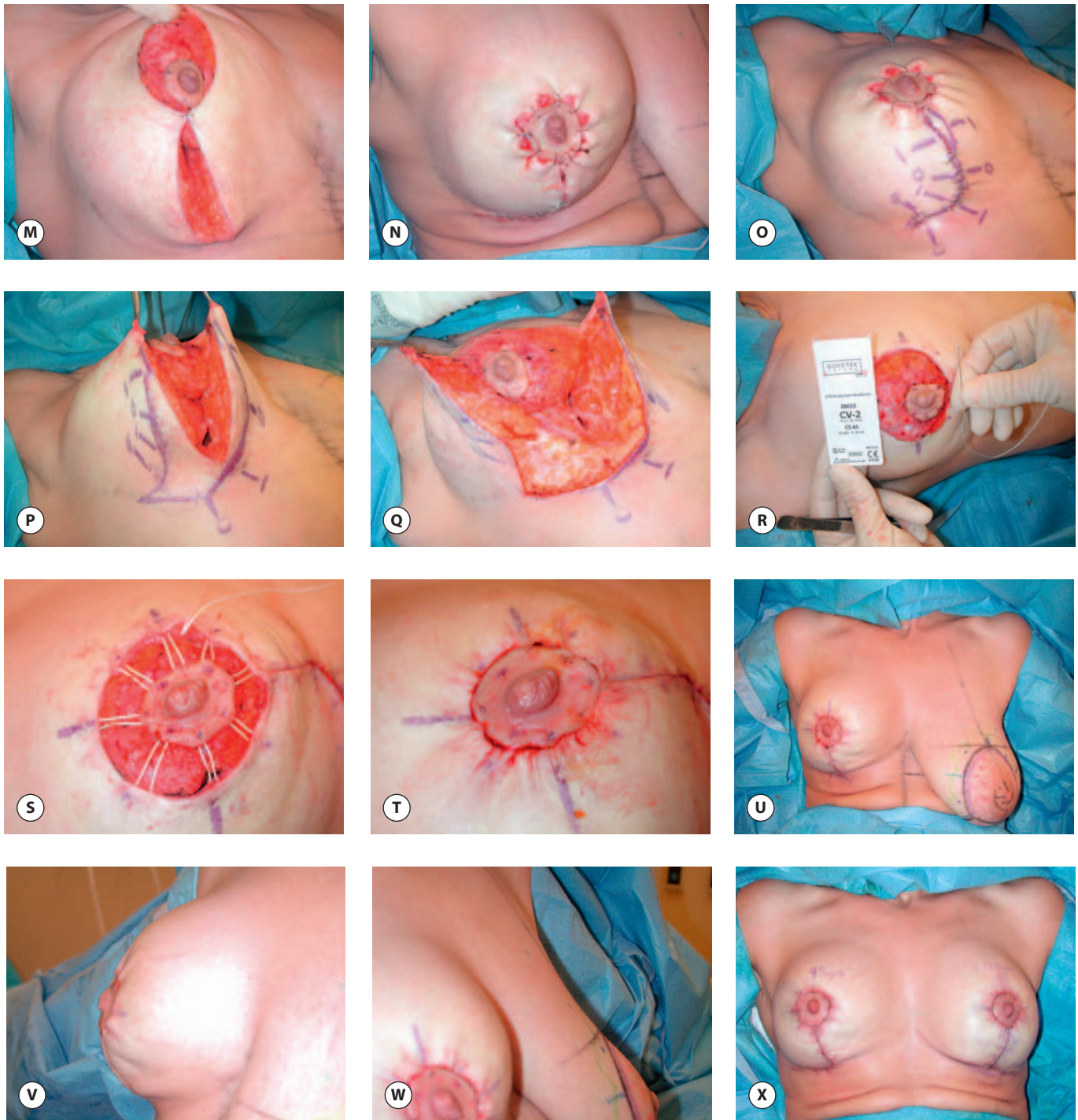


Figure 7.15 (Continued) (M,N) The remaining skin envelope of the lower pole of the breast is 'tailor-stapled' together to create an aesthetic breast shape. This shape is checked with the patient in the upright position. (O–Q) The plicated skin edges are marked (O) and the staples removed to reveal the redundant skin (P) that is then de-epithelialized (Q). (R,S) The eight cardinal points are placed (R) in preparation for the application of an interlocking Gore-Tex suture (S). (T) Immediate appearance of the NAC after the interlocking Gore-Tex suture is cinched down. (U) Appearance

of the right breast after the completion of the procedure. (V,W) After resuspension of the superior breast flap and plication of the ptotic inferior pole tissues, the upper pole of the right breast demonstrates an over-corrected fullness (V) that stands in stark contrast to the underfilled upper pole contour on the untreated left breast (W). (X) Final appearance demonstrating good symmetry and an overall aesthetic appearance after removal of 98 grams of tissue from the right breast and 120 grams of tissue from the left. Note the fullness in the upper pole of each breast.

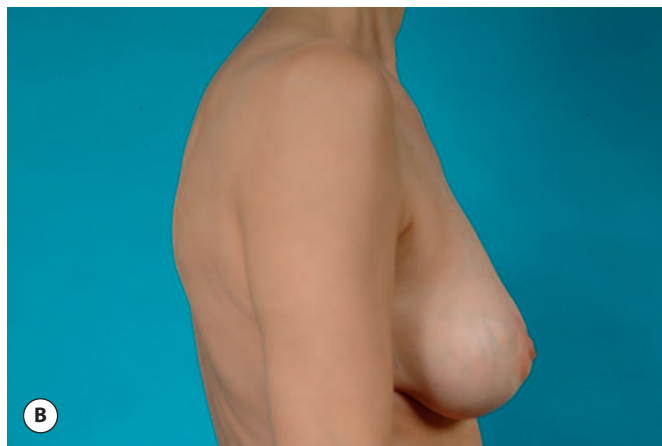
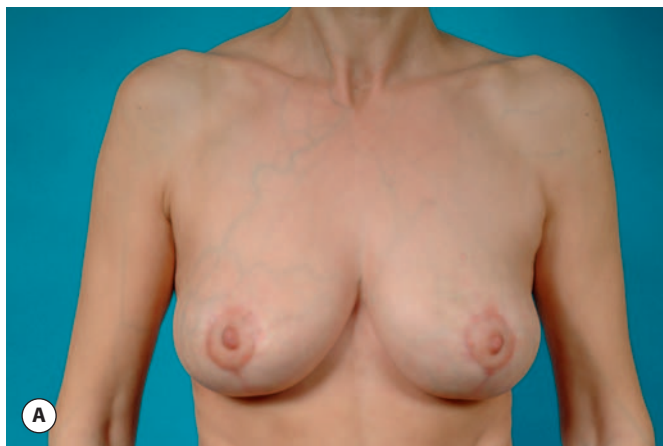


Figure 7.16 (A,B) Four-month postoperative result demonstrating an aesthetic breast shape and excellent symmetry. Note that on the lateral

view, the overcorrected upper pole shape has settled into a pleasing contour.

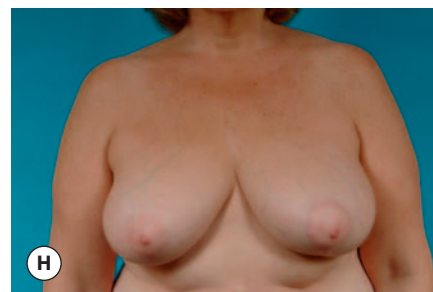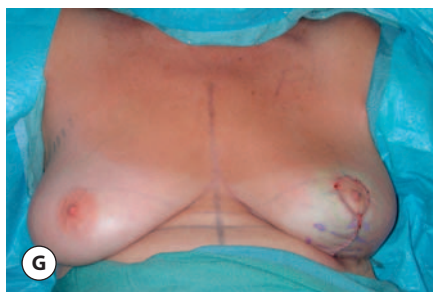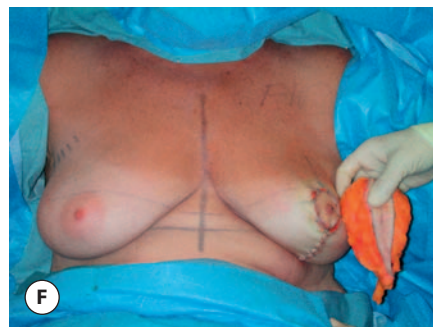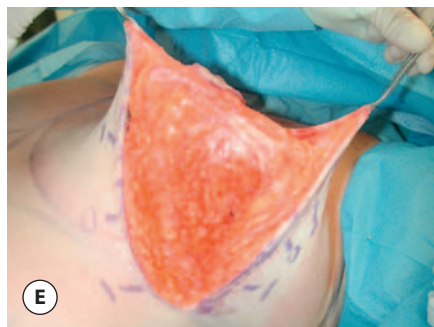
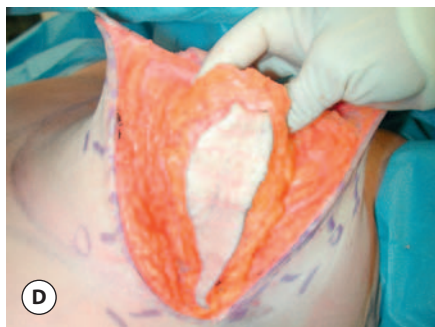
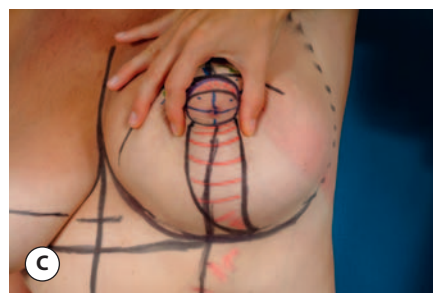
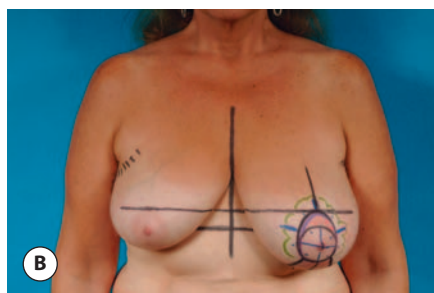
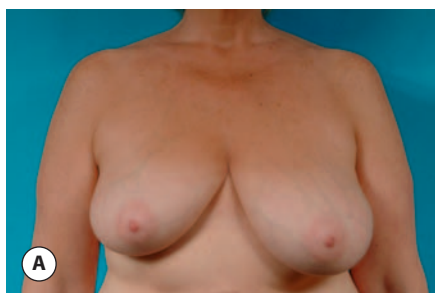


Figure 7.17 (A) Preoperative appearance of a 49-year-old woman in preparation for a left unilateral vertical breast reduction to correct her preoperative asymmetry. **(B,C)** Preoperative marks. **(D–F)** The vertical segment is resected from the inferior pole of the breast. **(G)** Immediate

results after the removal of 168 grams of tissue from the left breast. **(H)** Final result at 15 months demonstrating better symmetry and an overall aesthetic result.

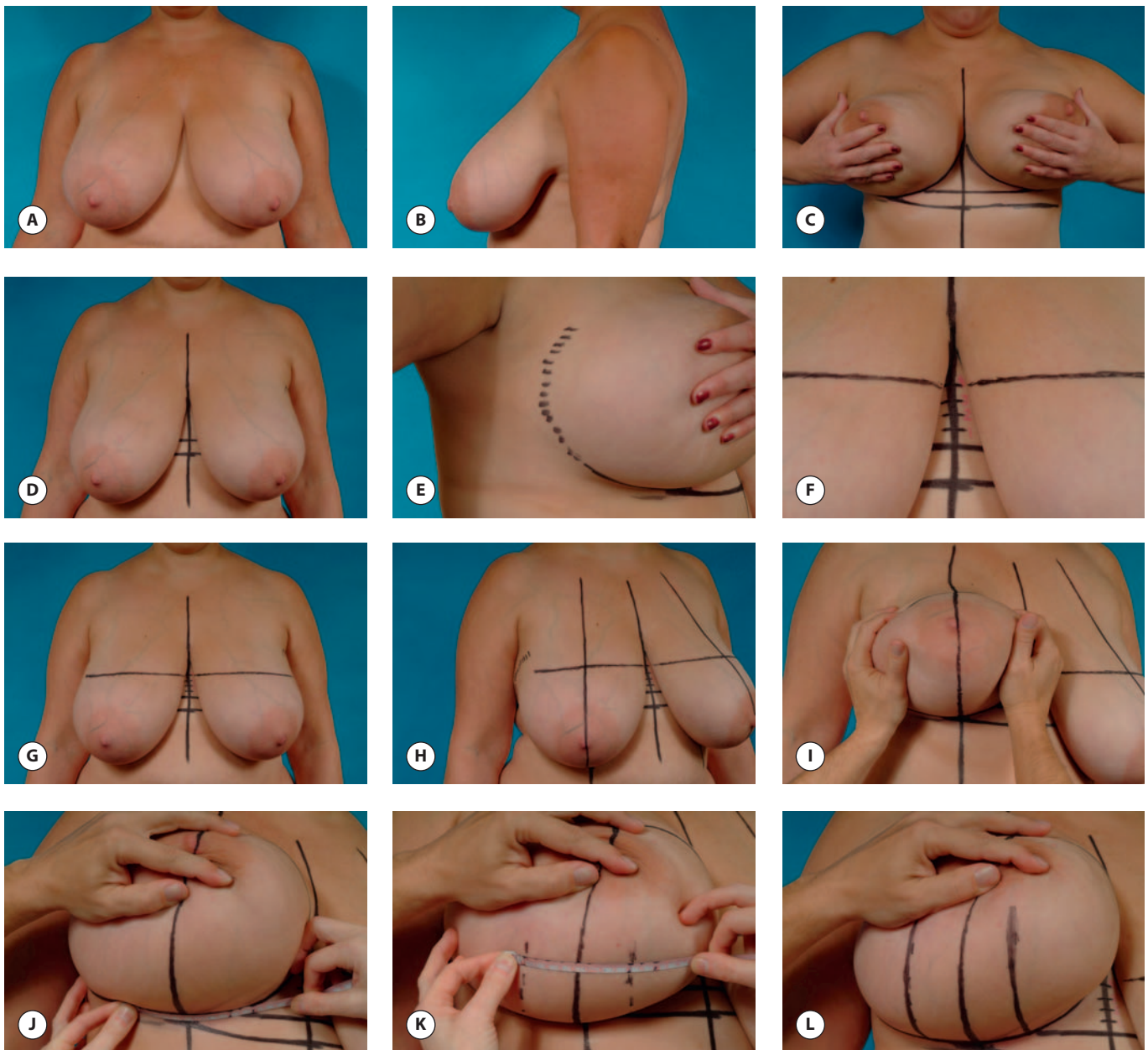


Figure 7.18 (A,B) Preoperative appearance of a woman in preparation for bilateral breast reduction using the SPAIR technique. **(C)** A line is drawn along the inframammary fold on each side and the two folds are joined with a line that extends across the midline. In this case, there is an asymmetry in the fold level with the left fold being slightly higher than the right. **(D)** As a result of drawing the fold line across the midline, it is possible to identify the location of each fold directly without moving or distorting the breasts in any way. As a result, the remainder of the marking pattern can be applied with greater accuracy. **(E)** The inframammary fold line is extended laterally around the breast to define the limits of the lateral flap dissection. **(F)** In the midline between the breasts, a distance of 4 cm is measured up from the inframammary fold line. In this case, the higher of

the two folds is chosen to set the remainder of the pattern. **(G)** This 4 cm measurement sets the top of the periareolar pattern and a line parallel to the inframammary fold line is drawn across the top of the breasts at this level. **(H,I)** The breast meridian is diagrammed in such a way so as to divide the breast volumetrically into two equal halves. To this end, the position of the nipple is ignored to prevent an asymmetrically located nipple from skewing the location of the meridian line. **(J)** An 8 cm wide inferior pedicle is diagrammed centered on the breast meridian. This pedicle width is used for all reductions regardless of size. **(K,L)** The 8 cm width is confirmed further up onto the breast **(K)** allowing a perfectly centered pedicle to be constructed on the breast **(L)**.

and a second line parallel to the inframammary fold line is drawn across the top of each breast **(Figure 7.18 G)**. This line marks the top of the periareolar pattern. The breast meridian is then marked on each side by visually dividing the breast in half and drawing a line that bisects the breast extending from the upper chest down

and around the breast and onto the chest wall **(Figure 7.18 H,I)**. When drawing the breast meridian it is best to ignore the position of the nipple as many patients present with a nipple position that is either laterally or more commonly medially translocated and basing the location of the breast meridian on such a translocated

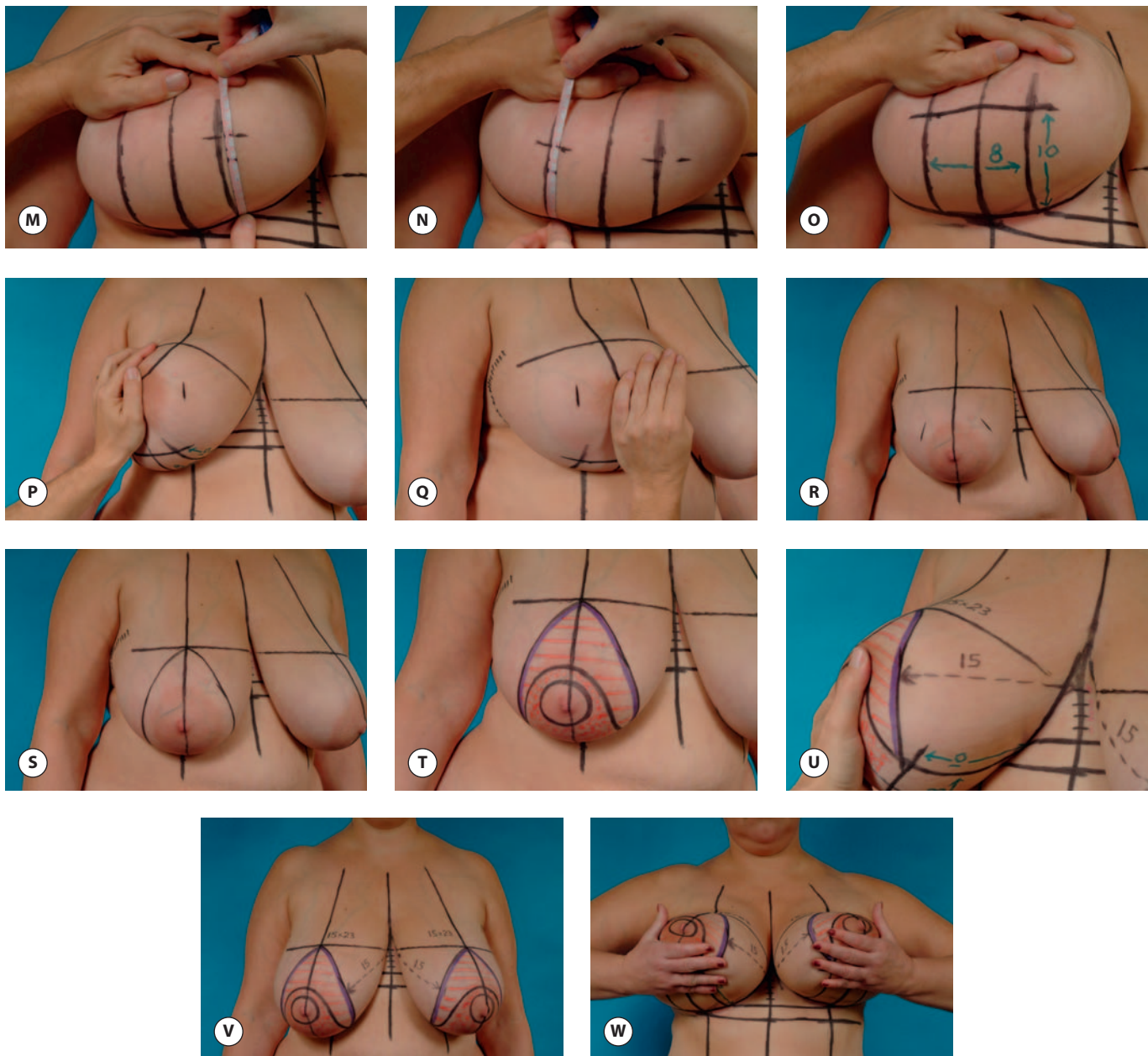


Figure 7.18 (Continued) (M–O) On either side, a distance of 8–10 cm is measured up on either side of the pedicle (M,N) and these points are joined with a line that parallels the curve of the inframammary fold (O). In this case, due to the large size of the breast, the longer measurement was chosen to be certain the inferior skin envelope was of sufficient dimension to easily accommodate the eventual volume of the reduced breast. (P,Q) By rotating the breast first up and out (P) and then up and in (Q), the location of the breast meridian can be translocated onto the breast medially and laterally to determine how much skin must be preserved to wrap easily around the reduced breast. (R,S) Once the four cardinal landmarks have been determined (R), these points are joined into what becomes an elongated oval that defines the periareolar pattern (S). (T) After the location of the periareolar pattern has been finalized, the proposed inferior pedicle is diagrammed by extending the pedicle marks up and around the NAC, skirting the top of the proposed areolar incision by a distance of 2–3 cm. In this marking system, the skin to be removed is marked with red lines and the skin to be de-epithelialized is

marked with red dots. The purple line represents the dermal shelf that will be created to hold the Gore-Tex purse string suture. (U) As a final check, the distance from the midsternal line over to the medial portion of the periareolar pattern at the level of the nipple must measure at least 12 cm to ensure that there will be enough skin medially to re-drape around the reduced breast. In this instance the measurement is 15 cm, indicating that a sufficient amount of skin will be preserved to accomplish this task. (V,W) Final appearance of the marking pattern with the breasts in repose and with the breasts elevated to allow visualization of the inframammary fold. Note that the dimensions of the periareolar defect measure 15 × 23 cm on each side. This measurement serves as an indicator of how challenging the skin re-draping portion of the procedure is likely to be. Reviewing these marks after the operation is completed and full healing has occurred can be a valuable education tool that can allow the surgeon to shorten dramatically the learning curve related to performing the procedure.

nipple would cause the remainder of the marking pattern to be applied asymmetrically. Once the top of the pattern is identified, the inferior portion is then marked. By lifting the inferior pole of the breast away from the abdomen, an 8 cm wide pedicle can be measured centered on the breast meridian (Figure 7.18 J). This measurement is repeated along the breast meridian as it extends up onto the breast and in this fashion a perfectly oriented 8 cm wide inferior pedicle is drawn directly in the midline of the breast (Figure 7.18 K,L). On either side of the pedicle, a distance of 8–10 cm is measured up from the inframammary fold (Figure 7.18 M,N) and these two points are joined in a line that parallels the line of the inframammary fold (Figure 7.18 O). As an approximation, in smaller breast reductions of 500 grams or less per side, the 8 cm measurement is used and in larger reductions of more than 1000 grams per side, this length measures 10 cm. For reductions between 500 and 1000 grams per side this length measures 9 cm. The goal of these marks is to identify a skin envelope in the lower pole of the breast of sufficient surface area easily to cover the lower portion of the breast after it is reassembled. To this end, there is no advantage to shortening this measurement to 7 cm and only in cases of gigantomastia where 1500 grams per side or more are planned to be removed can the measurement be lengthened up to 12 cm. Finally then, the amount of skin that will be preserved medially and laterally is determined. By gently rotating the breast up and out until a smooth and rounded contour is created in the medial portion of the breast, the breast meridian can be translocated onto the medial breast skin at the level of the nipple (Figure 7.18 P). This mark then determines how much skin must be left medially to wrap easily around the reduced breast. The process is then reversed as the breast is rotated up and in and a mark is made on the lateral portion of the breast that will similarly identify how much lateral skin to preserve (Figure 7.18 Q). In this fashion, four cardinal landmarks are identified that define the dimensions of the periareolar portion of the pattern (Figure 7.18 R). The lateral, superior and medial marks are then smoothly joined to the inferior pedicle marks to determine the limits of the periareolar pattern (Figure 7.18 S). After the periareolar pattern is finalized, the proposed limits of the inferior pedicle are outlined by carrying the 8 cm pedicle marks up and around the NAC, skirting the proposed areolar incision by a distance of 2–3 cm (Figure 7.18 T). As a final check to the marking pattern, the distance from the midsternal line to the most medial edge of the periareolar mark should measure at least 12 cm (Figure 7.18 U). If this is not the case, the markings should be rechecked to be certain the breast was not unintentionally pulled too far laterally as the medial mark was made. Lastly, the dimensions of the periareolar pattern are measured at their widest horizontal and vertical extent. This measurement is helpful in that it is an indication of how challenging the procedure will be, particularly as it relates to managing the skin envelope. In an approximate fashion, any measurement less than 15 cm indicates that the procedure should proceed easily and skin redraping will not be a challenge. For measurements of between 15 and 20 cm, it can be anticipated that intraoperative adjustment of the proposed vertical segment may well be required to obtain the best result. And for measurements greater than 20 cm, experience with the technique will be required to manage the redundant skin envelope effectively. It is highly recommended that the marking pattern be photographed and photos of the marks be made available in the operating room at the time of surgery. This visual information can be of help in confirming intraoperative observations that are sometimes made during the

procedure relative to asymmetries in breast volume or, in particular, differences in breast width. Also, these photos can be referenced later after full healing has taken place and the final result has stabilized. Going back and assessing how the marking pattern impacted upon the final result can be an enlightening educational tool (Figure 7.18 V,W).

Operative technique – initial dissection The procedure is performed under general anesthesia and, while most patients are able to be discharged home the same day, occasionally a patient will elect to stay overnight in the hospital either for pain control issues or to help manage postoperative nausea and vomiting. At surgery, the patient is placed in a mild beach chair position to help bring the base of the breast up level with the plane of the floor. This helps the surgeon better judge how the tissue planes fit together during the dissection. The periareolar tissues as well as the proposed vertical segment are infiltrated with a diluted solution of 1% lidocaine with epinephrine to assist with hemostasis (Figure 7.19 A). A breast tourniquet is applied and the areola is placed under maximal stretch while an areolar diameter of 40–44 mm is marked with the aid of a multidiameter areolar marker. The areolar and periareolar incisions are made and the skin over the inferior pedicle is de-epithelialized as is a small segment of skin immediately adjacent to the periareolar incision (Figure 7.19 B). The dermis is then divided around the entire periphery of the periareolar defect leaving a cuff of dermis attached to the periareolar skin incision that measures 5 mm in width (Figure 7.19 C,D). This dermal cuff will serve as the architectural scaffold into which the Gore-Tex purse string suture will eventually be placed. The dermis of the inferior pedicle is left intact to preserve whatever potential dermal contribution is present to the vascularity of the NAC. Once the dermal shelf has been created along the margins of the periareolar incision, the dermal edges are undermined and the flaps are dissected away from the main substance of the breast mound. Flap dissection proceeds in an exacting fashion by initially dissecting the flaps directly at the level of the dermis and then progressively increasing the thickness of the medial (Figure 7.19 E,F) and superior (Figure 7.19 G,H) flaps until the chest wall is reached. At this point the thickness of the medial and superior breast flaps approaches 4–6 cm. Every effort must be made to make these dissection planes as smooth and evenly contoured as possible. Laterally, the flap is dissected down to the lateral mark directly at the junction of the superficial fat with the breast capsule (Figure 7.19 I). This creates a lateral flap that is only 1–2 cm thick in most patients; however, experience has shown that the lateral flap must be this thin or the breast will demonstrate too much lateral fullness and a ‘boxy’ appearance to the breast will result. At the junction of the relatively thinner lateral flap with the thicker superior flap in the upper outer quadrant of the breast, every effort must be made to make this transition smooth and without an abrupt step off. This will help ensure a smooth rounded contour to the breast in this area. The reasoning behind this flap dissection strategy is that the initial flap dissection must be thin to allow the skin edges to be eventually pulled in by the purse string suture without creating tissue crowding as the flap edges are drawn around the inferior pedicle. Deeply, however, the medial and superior flaps are left thicker to provide substance and a smooth and contoured shape to the reduced breast. It is important to emphasize that the dissection along the medial and lateral aspects of the

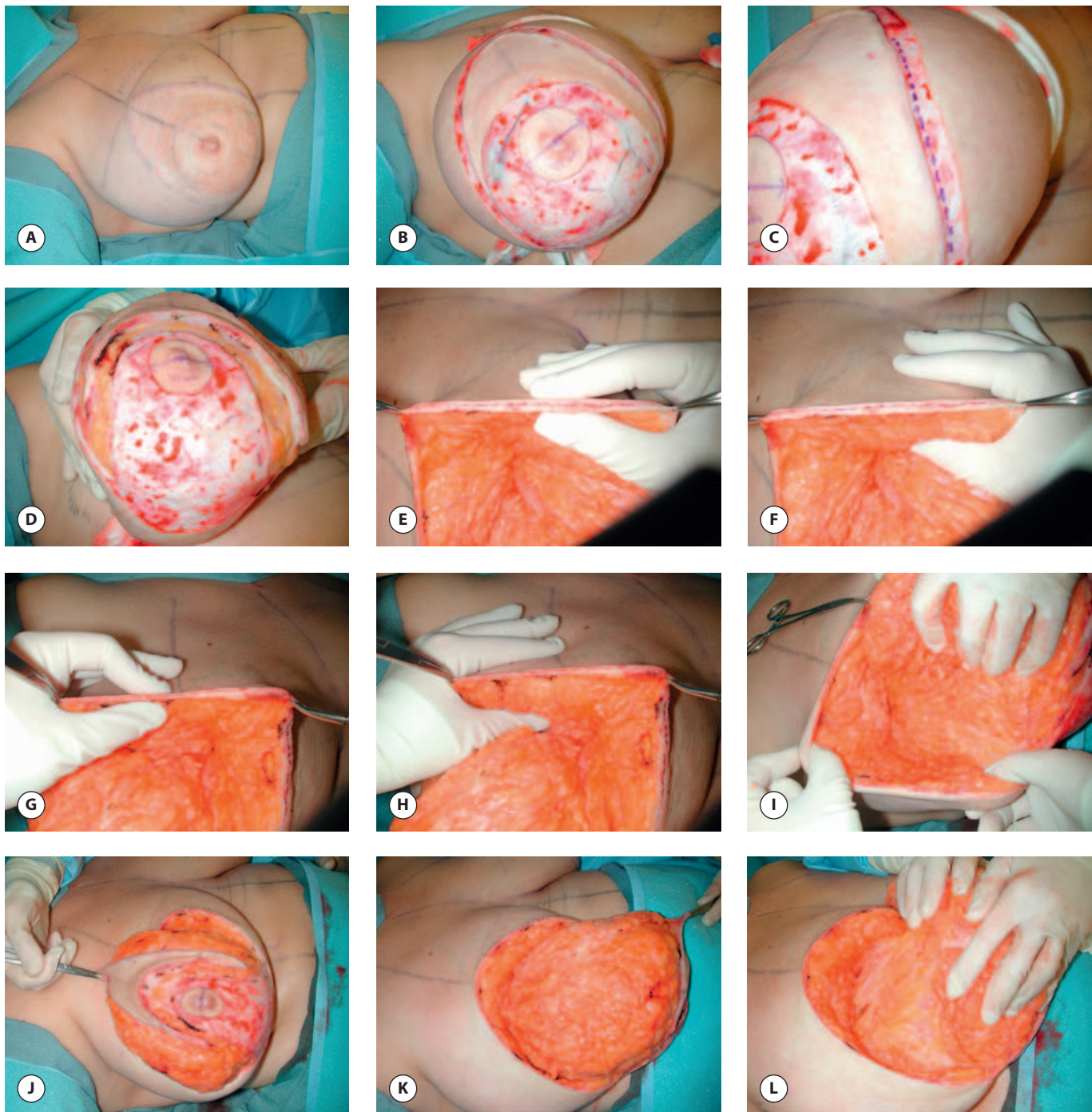


Figure 7.19 (A) At the beginning of the procedure, the patient is placed slightly upright to allow the surgeon better to visualize how the dissection planes will fit together during the operation. To assist in hemostasis, a dilute solution of lidocaine with epinephrine is injected into the dermis across the entire proposed periareolar and vertical skin pattern. The vasoconstrictive effect of the epinephrine greatly aids in maintaining hemostasis particularly during de-epithelialization. (B) After placement of a breast tourniquet to maximally stretch the areola, an areolar diameter of 40–44 mm is diagrammed and the areolar and periareolar are incisions scored. The skin about the limits of the inferior pedicle is de-epithelialized as is a rim around the periareolar incision. (C,D) The dermis around the periphery of the periareolar incision is divided leaving a 5 mm dermal cuff (C). This small rim of dermal collagen will serve as a firm and reliable architectural scaffold to ultimately hold the purse string suture. The dermis around the limits of the inferior pedicle is then likewise divided (D). (E,F) Medially, the flap

dissection proceeds directly under the dermis to create a very thin flap (E) that then becomes progressively thicker until the dissection reaches the pectoralis major muscle. At this point the flap is commonly 4–6 cm thick (F). (G,H) The same strategy is used to create the superior flap. In this fashion, the leading edges of the flaps will easily fit around the inferior pedicle without creating a tissue crowding effect and the thicker deep portions of the flaps will create a smooth and contoured base to the breast. (I) The lateral flap dissection proceeds at the level of the breast capsule. (J,K) Once the flaps have been dissected, the main substance of the breast mound can be delivered from within the confines of flaps. (L) By dissecting along the internal breast septum, the redundant tissue in the superior aspect of the breast mound can be better delineated, allowing the pedicle to be safely skeletonized without risking injury to the underlying septum and the associated vascular arcade supplying the tissues in the inferior pedicle and the NAC.

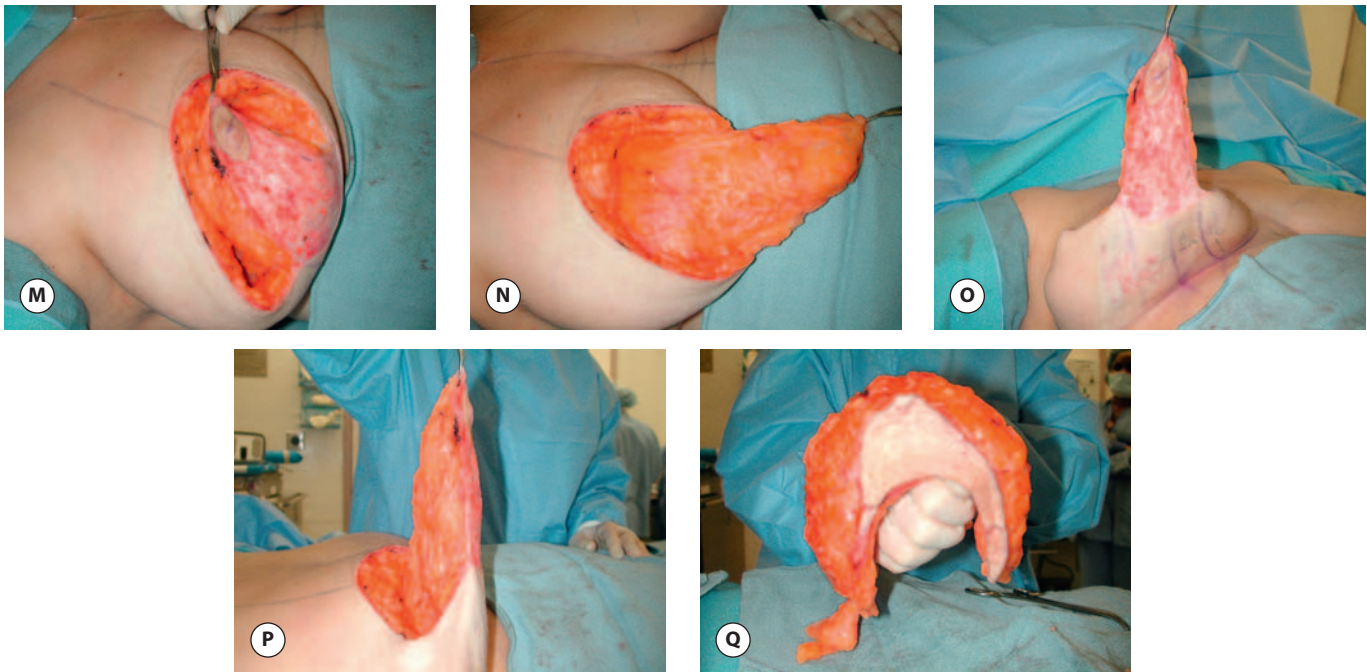


Figure 7.19 (Continued) (M) Appearance of the pedicle after skeletonization. The pedicle should easily fit within the confines of the dissected flaps. (N) Along the underside of the pedicle, the vascular arcade of the internal septum can be identified. (O,P) Appearance of a full and evenly constructed inferior pedicle that will facilitate subsequent breast

shaping. (Q) Appearance of the resected excess breast parenchyma after it has been dissected from around the inferior pedicle. The shape of the specimen is that of a horseshoe with the lateral segment being slightly longer than the medial segment.

pedicle along the inframammary fold must stop slightly above the fold to avoid opening the loose subscarpal space. In this manner, the position of the inframammary fold will remain unchanged as a result of the procedure and a stable breast shape will be better maintained over time.

Once the flaps have been developed, the main substance of the breast mound can be delivered from within the confines of the flaps (see [Figure 7.19 J,K](#)). The redundant parenchyma is then dissected free from around the pedicle, working from medial to lateral. During this dissection, the internal breast septum is protected by, working from deep to superficial, to better isolate the redundant tissue in the superior aspect of the breast mound (see [Figure 7.19 L](#)). This allows the pedicle to be skeletonized with little risk of inadvertent injury to the septum and the associated vascular arcade supplying the NAC. Every effort is made not to undermine the pedicle and a full and evenly contoured pedicle of parenchyma is retained to provide vascularity to the NAC as well as provide the basis for the eventual shape of the breast (see [Figure 7.19 M-P](#)). Once the pedicle has been completely skeletonized, it should fit evenly into the space created by the flap dissection without any excess fullness or, conversely, any areas that are in any way underfilled. The shape of the excised segment of parenchyma is that of a horseshoe with the lateral limb being slightly longer than the medial limb (see [Figure 7.19 Q](#)). Trimming can be done in any area where the dissection planes seem uneven or excessively full. Once the breast has been completely reduced, the weight of the resected specimen is recorded for comparison to the preoperative estimates as well as for comparison to the amount eventually resected from the opposite breast. Such comparisons can be particularly helpful in cases of breast asymmetry.

Operative technique – breast shaping After the major portion of the breast reduction has been accomplished, the breast must then be reassembled into a pleasing aesthetic shape. In many patients, simply as a result of the preoperative planning of the procedure and the manner in which the surrounding flaps and pedicle have been sculpted, all that is required at this point is a tailor tack recontouring of the lower pole skin envelope to create an aesthetic shape. However, in patients who present with any degree of concavity in the upper pole of the breast, internal breast shaping maneuvers can be used to good effect to improve the overall quality of the final result. To prepare the breast flaps for internal suture plication, first the medial and superior flaps are undermined to release them from their attachments to the pectoralis major muscle and allow repositioning. The medial flap is undermined for a distance of 1–3 cm with care being taken not to inadvertently injure the very important internal mammary perforators. The superior flap is undermined up to and beyond the superior border of the breast ([Figure 7.20 A,B](#)). The deep leading edge of the undermined superior flap is then advanced upward to shift the position of the entire flap superiorly, where it is sutured to the pectoralis major fascia to hold it in position. One to three evenly spaced sutures are used to secure the flap in the desired location. In essence this amounts to an ‘autoaugmentation’ of the superior pole of the breast. The degree to which the flap is advanced superiorly is determined individually for each patient. Mildly ptotic patients will require only a modest flap advancement while extremely ptotic patients will require a more aggressive degree of undermining and a more significant flap advancement to correct the upper pole concavity ([Figure 7.20 C-F](#)). Medially, the undermined leading edge of the flap is imbricated upon itself to gather the deep flap tissues

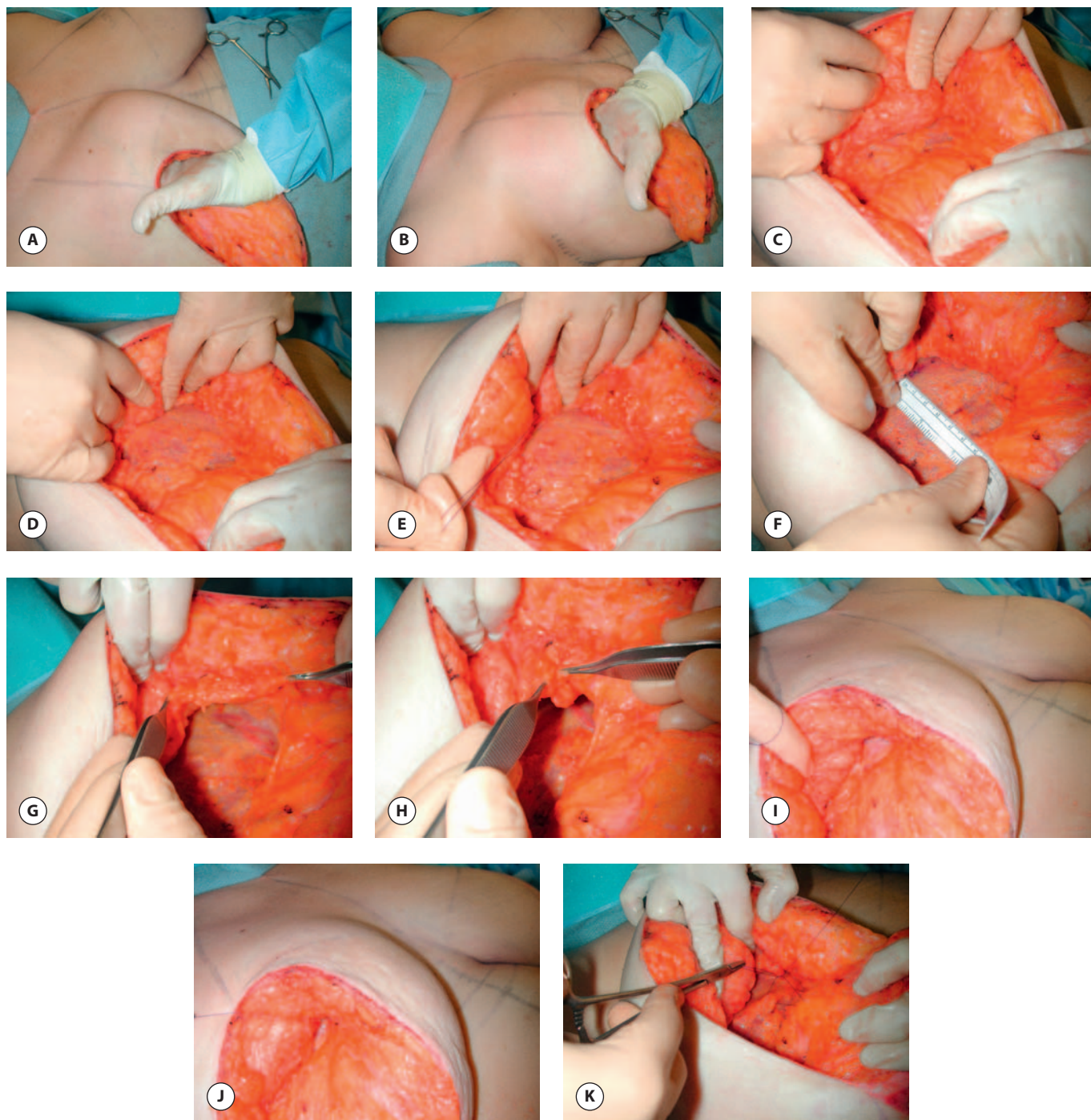


Figure 7.20 (A,B) To begin breast shaping, the medial and superior flaps are undermined. **(C-F)** The undermined edge of the superior flap is identified **(C)** and advanced superiorly **(D)** and sutured to the fascia of the pectoralis major muscle **(E)** to shift the superior flap tissues into the upper pole of the breast. This accomplishes an 'autoaugmentation' of the upper pole and can correct any element of upper pole concavity that may be present preoperatively. In this case, approximately 5 cm of flap advancement was accomplished using this technique **(F)**.

(G,H) Medially, the undermined edge of the dissected flap is imbricated upon itself to gather this tissue together to create a fuller, more rounded medial contour. **(I,J)** Before medial flap plication, the medial contour of the breast appears flattened **(I)** and after plication a fuller and more rounded contour is created **(J)**. **(K)** The underside of the inferior pedicle is sutured to the pectoralis major fascia as needed to secure it in the center of the breast and keep these tissues from falling off laterally.

together and create a more rounded and full medial contour to the breast **(Figure 7.20 G-J)**. Finally, the base of the inferior pedicle is sutured down to the pectoralis fascia to hold the pedicle in position and keep it from falling off laterally in the breast

(Figure 7.20 K). The net effect of these shaping maneuvers is to improve the three-dimensional relationship between the flaps and the pedicle with the goal being a full and rounded breast contour that is properly positioned on the chest wall.

There is some controversy as to the whether or not the described shaping maneuvers have any real effect on the eventual shape of the breast. This is understandable given that much of this uncertainty stems from experience gained from the vertical mammoplasty. It is important to remember that, in the vertical mammoplasty procedure, as a result of the removal of tissue from the inferior pole of the breast, there is nothing to halt the inexorable descent of the remaining superior pole tissues as they stretch and fall into the void created by the inferior tissue resection. Therefore, even in cases where internal flap suspension has been attempted, progressive loss of contour has been noted, leading to the conclusion that internal shaping sutures are of little value. However, with the SPAIR mammoplasty, the tissues of the inferior pedicle are not only present, but sutured into position. As a result, the pedicle serves to block any tendency from the resuspended superior flap to fall away inferiorly and the upper pole contour is maintained to a much greater degree. Certainly, it is necessary to overcorrect the contour of the upper pole slightly as there will be some tissue stretch that is noted over time; however, there is no doubt that internal flap shaping can tremendously influence the eventual shape of the breast in a positive fashion.

Operative technique – skin envelope management After the breast has been reduced and the shaping maneuvers applied as needed, the redundant skin envelope in the inferior pole of the breast must be managed. The exact dimensions of the skin resection are determined using a ‘tailor tack’ approach with skin staples. By securing a hemostat to the pedicle and applying upward traction, the redundant skin flaps on either side of the pedicle will buckle. These two buckle points are stapled together to begin the plication of the inferior pole. This staple point is called the key staple as it sets the rest of the plication pattern (Figure 7.21 A–C). The remainder of the redundant skin envelope is then folded in on itself and progressively stapled into position until a smooth and contoured shape has been created (Figure 7.21 D,E). As the staple line is developed from superior to inferior, the pattern curves inferolaterally along the inframammary fold as much as needed to create an aesthetic shape. At no time should the staple line extend down onto the upper abdomen. It is this lateral curving of the plication line that prevents many of the wound healing problems seen at the base of the vertical incision in the more classic vertical mammoplasty techniques. Alternatively, a small ‘T’ can be added at this point to take up the redundant tissue. The critical goal of this plication maneuver is to take up the redundant skin envelope and create an aesthetic breast shape immediately. This represents one of the great advantages of the SPAIR technique, namely that the breast must have an aesthetic appearance at the time of the procedure. Not only is this an advantage for the patient, but the surgeon can now make much more accurate and technically correct judgments about breast size and shape due to the fact that the breast has an aesthetic shape immediately as compared to the classic vertical mammoplasty where the distorted early breast appearance can hinder such efforts. To this end then, after the vertical segment has been pliated, the NAC is inset into the periareolar defect with staples and the patient is placed upright to assess the shape of the breast. Adjustment of the staple line can be

performed as needed by either tightening a bit more the line of plication or, alternatively, loosening some of the staples to create the desired shape. Once the desired breast shape has been achieved, the patient is returned to the supine position and the plication line is marked with a surgical marker. Cross-hatched orientation marks are placed across the plication line to aid in accurately putting the vertical incision back together once the appropriate skin segments have been either de-epithelialized or resected (Figure 7.21 F). After the staples have been removed, the dimensions of the pliated inferior skin envelope can be visualized. The shape of the resection area typically assumes that of a canted ‘V’ with the inferior point of the ‘V’ angled laterally along the inframammary fold (Figure 7.21 G). The inferior pedicle is then de-epithelialized to preserve any potential contribution the subdermal vascular plexus may be providing to the blood supply to the NAC (Figure 7.21 H) and the redundant medial and lateral wedges of tissue on either side of the pedicle are removed (Figure 7.21 I). It is helpful in particular to remove the lateral wedge of tissue in a full thickness fashion as this then allows the lateral flap to pass over on top of the de-epithelialized inferior pedicle to meet the medial incision without creating any tissue crowding or bunching (Figure 7.21 J). A drain is placed as desired and the vertical incision is closed using 4-0 absorbable monofilament sutures placed in an inverted interrupted fashion followed by a subcuticular skin closure with the same material (Figure 7.21 K).

It is the on the table adjustments that sets the SPAIR mammoplasty apart from other breast reduction procedures and the management of the inferior skin envelope is the most difficult aspect of the procedure. The plication of the inferior skin envelope is an artistic sculpting maneuver that requires an ability to manage tissue in three dimensions and make needed adjustments based on an accurate assessment of the shape of the breast in the upright position. It is easier to perform in smaller breast reductions and becomes more of a challenge in cases where the skin envelope is markedly redundant and ptotic. However, it is the same basic maneuver no matter the size and shape of the breast. In larger cases, the lateral extension of the vertical incision simply becomes longer.

Operative technique – management of NAC The final step in completing the procedure is management of the periareolar defect. Here all the technical details described previously for either the simple purse string or the interlocking Gore-Tex closure are utilized. If the dimensions of the periareolar defect are greater than 10cm, the tendency is to use the simple purse string technique as use of the interlocking Gore-Tex technique can become cumbersome with periareolar defects larger than this. When the interlocking Gore-Tex technique is used, it is helpful to re-resect the periareolar opening to create a circular defect. Commonly, this will require resecting a small additional wedge of skin along the medial margin of the periareolar defect (Figure 7.22 A). Once the defect is re-excised, the eight cardinal points utilized in the interlocking Gore-Tex technique are applied (Figure 7.22 B) and the suture is placed in the

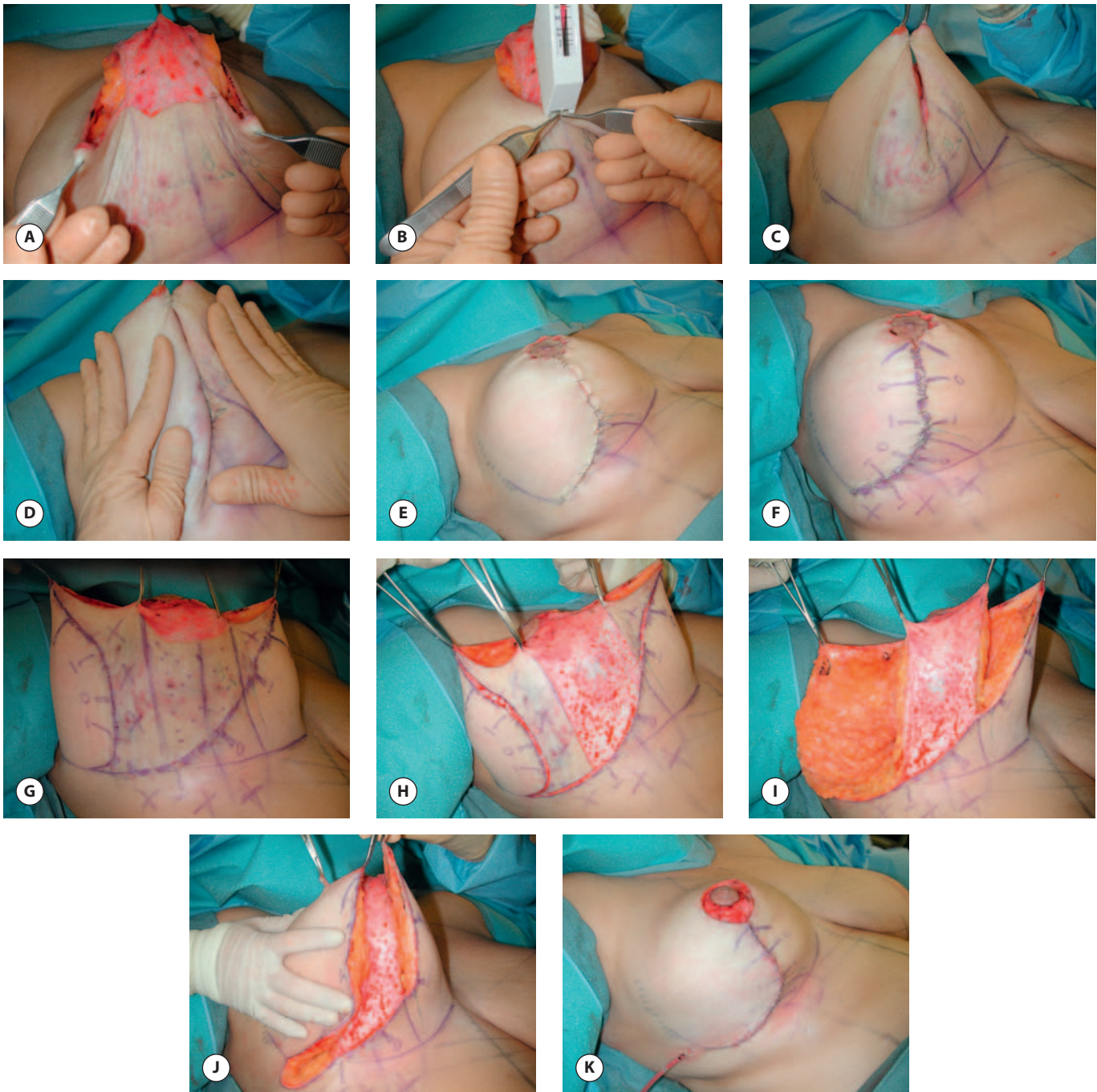


Figure 7.21 (A–C) By placing upward traction on the inferior pedicle, two buckle points will be created on either side of the pedicle **(A)**. By grasping these points and bringing them together with a 'key' staple, the top of the vertical pattern is set **(B)**. By grasping the dermal edges at this key staple point and applying upward traction, the general location and shape of the remainder of the vertical plication line can be visualized **(C)**. **(D,E)** By folding the redundant inferior pole skin in on itself **(D)**, the vertical plication line can be set by progressively tailor tacking the skin edges together until a pleasing shape is created **(E)**. Near the inframammary fold, the plication line curves out laterally as the redundant skin envelope is gradually taken

up. **(F)** After the shape of the inferior pole is set, the plication line is marked and cross-hatches applied to aid in accurately reclosing the vertical incision once the redundant skin is removed. **(G)** The appearance of the inferior skin segment is that of a canted 'V' with the point of the 'V' variably angled off laterally. **(H,I)** The inferior pedicle is de-epithelialized **(H)** and medial and lateral wedges of tissue are removed from either side of the pedicle **(I)**. **(J)** The lateral flap is passed over the top of the de-epithelialized inferior pedicle and joined to the medial incision. **(K)** Appearance after closure of the vertical segment using the cross-hatch marks as a guide to accurate closure.

dermal shelf developed at the beginning of the procedure, creating the characteristic pinwheel appearance **(Figure 7.22 C)**. The purse string is then cinched down and the areola inset with a running 4-0 absorbable monofilament suture to complete the

procedure **(Figure 7.22 D–F)**. Postoperatively, suture ends are clipped at 7–10 days and a support garment is worn for comfort for 6 weeks. Full return to vigorous activity is allowed at 4 weeks **(Figures 7.23–7.27)**.

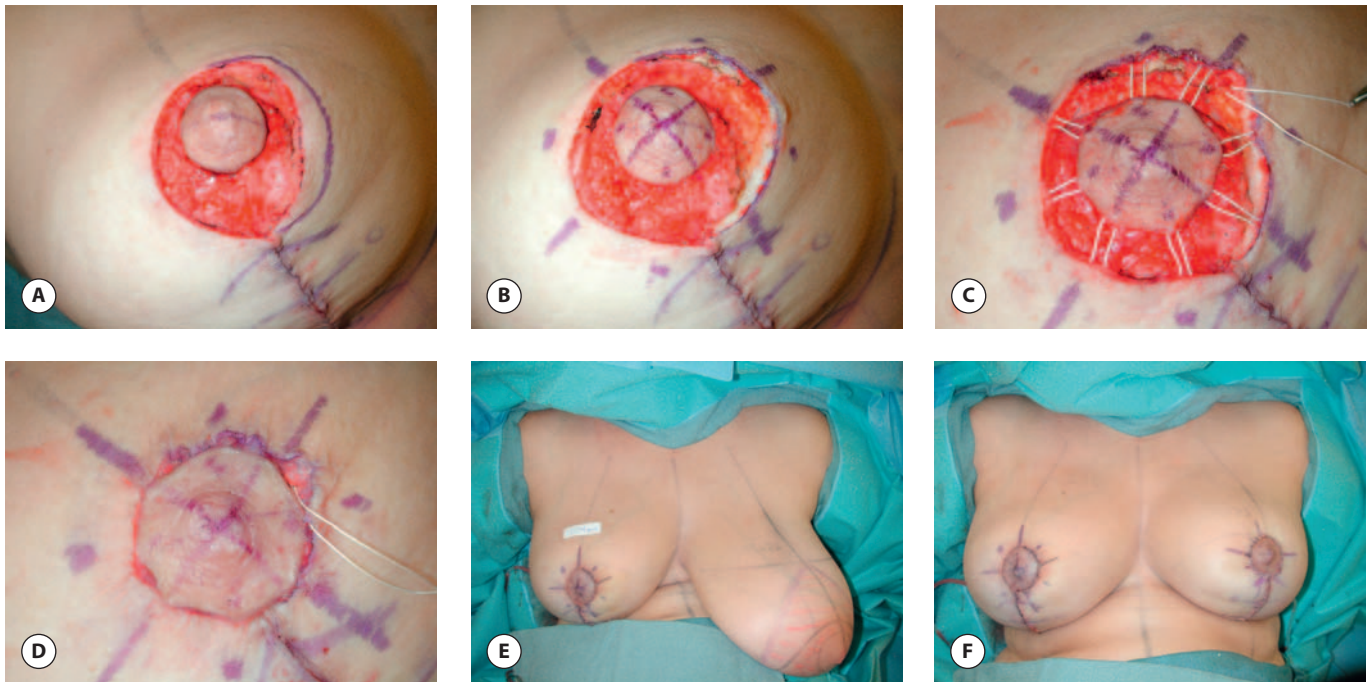


Figure 7.22 (A,B) The periareolar defect is re-excised to create a circular opening (A) and the eight cardinal points are applied in preparation for placement of the interlocking Gore-Tex suture (B). (C,D) The Gore-Tex suture is passed in an interlocking fashion around the periphery of the periareolar defect using the dermal shelf created at the beginning of the procedure as an architectural strut to hold the suture (C). The suture is then

cinched down to create a periareolar opening of the desired dimension (D). (E) Appearance of the right breast after the resection of 1004 grams. Note that, as compared to the left breast, the base diameter is reduced, the NAC diameter reduced, the breast is lifted, the upper pole has been filled in and the shape is aesthetic. (F) Final appearance at the conclusion of the case demonstrating an aesthetic and symmetric result.

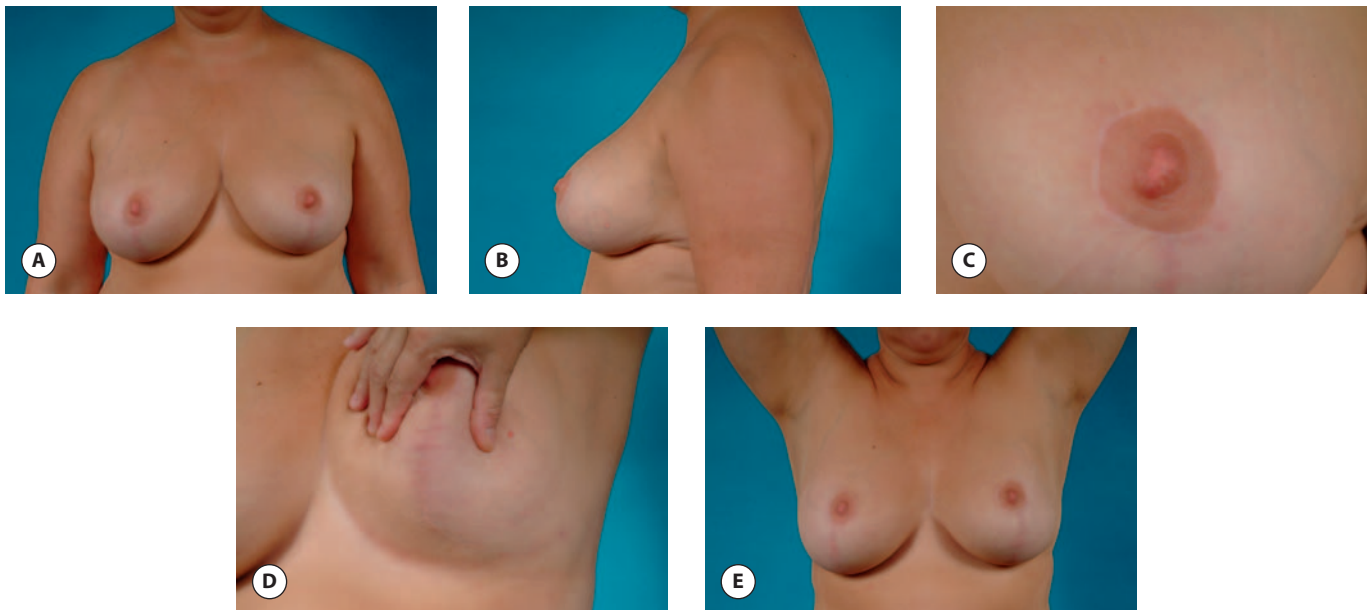


Figure 7.23 (A,B) Two-month postoperative result after the removal of 1004 grams of tissue from the right breast and 961 grams of tissue from the left.

Inverted T (Wise) Pattern Inferior Pedicle Breast Reduction

Operative strategy overview For many surgeons, the gold standard technique for performing breast reduction remains the

inverted T inferior pedicle technique. This technique bases the blood supply to the NAC on an inferior pedicle, resects tissue from around the periphery of the pedicle and uses a tapered wedge pattern to resect skin from around the inferior pole of the breast with a central superior extension that results in a scar

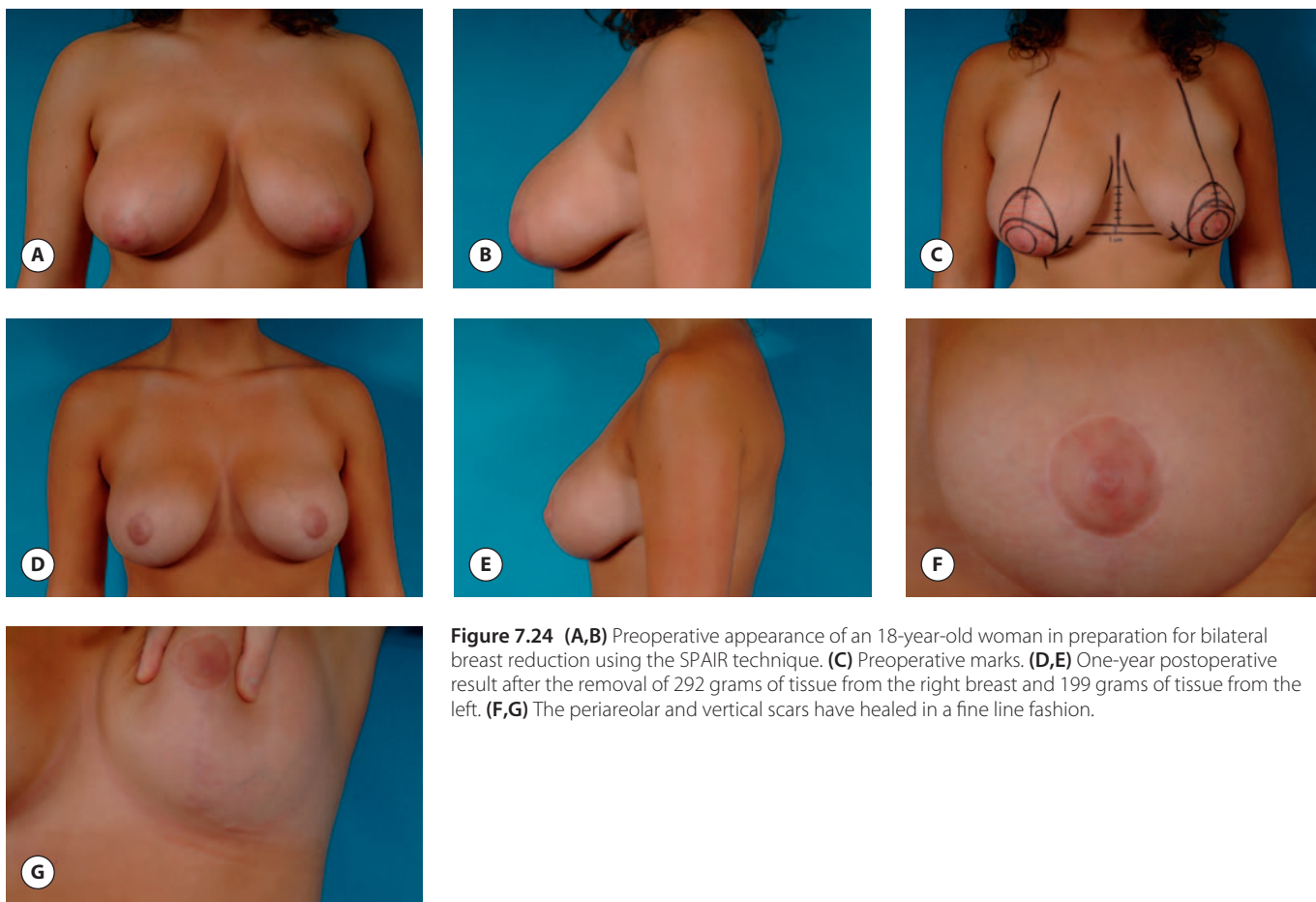


Figure 7.24 (A,B) Preoperative appearance of an 18-year-old woman in preparation for bilateral breast reduction using the SPAIR technique. (C) Preoperative marks. (D,E) One-year postoperative result after the removal of 292 grams of tissue from the right breast and 199 grams of tissue from the left. (F,G) The periareolar and vertical scars have healed in a fine line fashion.

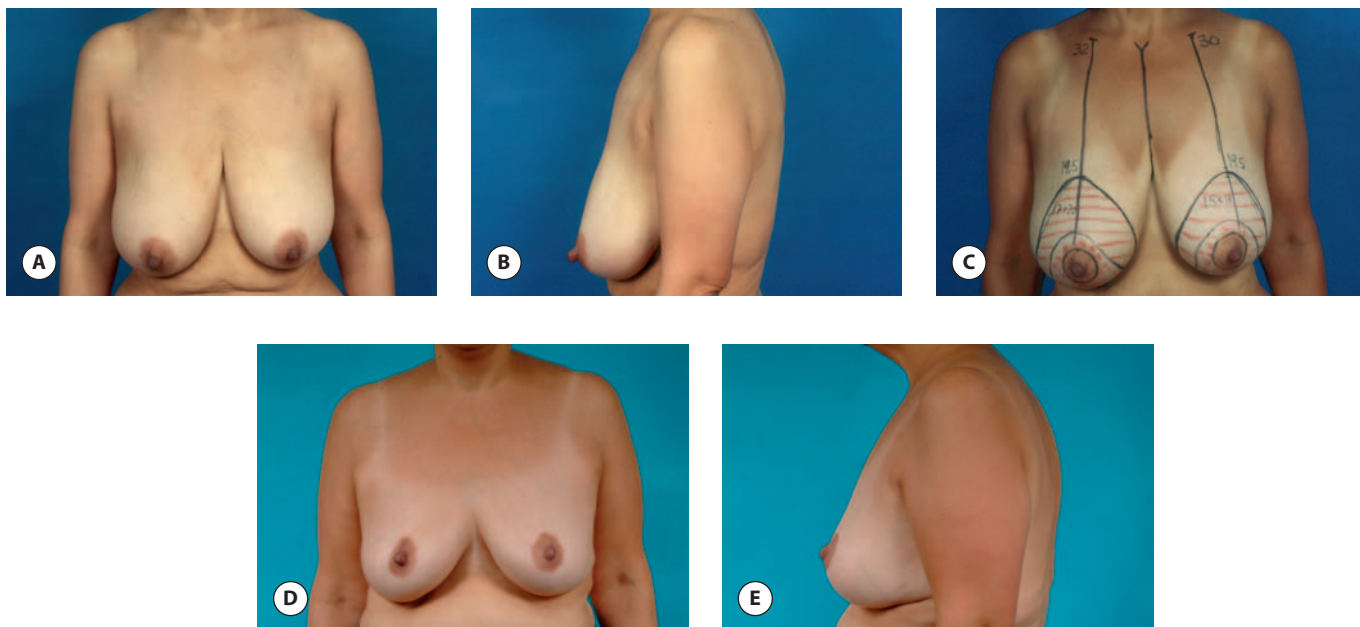


Figure 7.25 (A,B) Preoperative appearance of a 50-year-old woman in preparation for bilateral breast reduction using the SPAIR technique. (C) Preoperative marks. (D,E) Nine-year postoperative result after the removal of 580 grams of tissue from the right breast and 500 grams of

tissue from the left. This case demonstrates the stability afforded by the SPAIR technique as, despite the passage of many years, the shape of the breast, and in particular the upper pole, remains aesthetic.

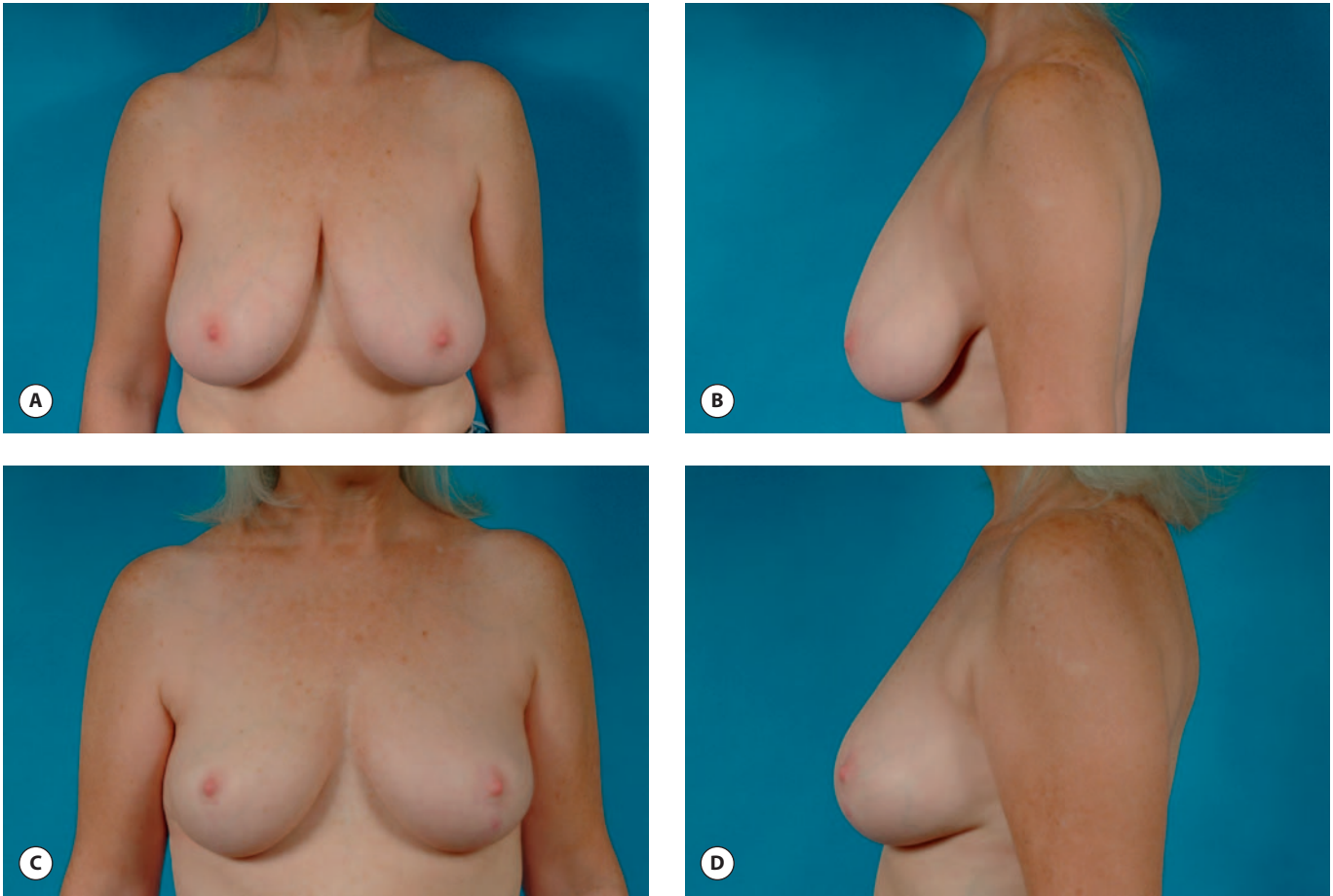


Figure 7.26 (A,B) Preoperative appearance of a 51-year-old woman in preparation for bilateral breast reduction using the SPAIR technique.

(C,D) One-year postoperative result after the removal of 212 grams of tissue from the right breast and 213 grams of tissue from the left.

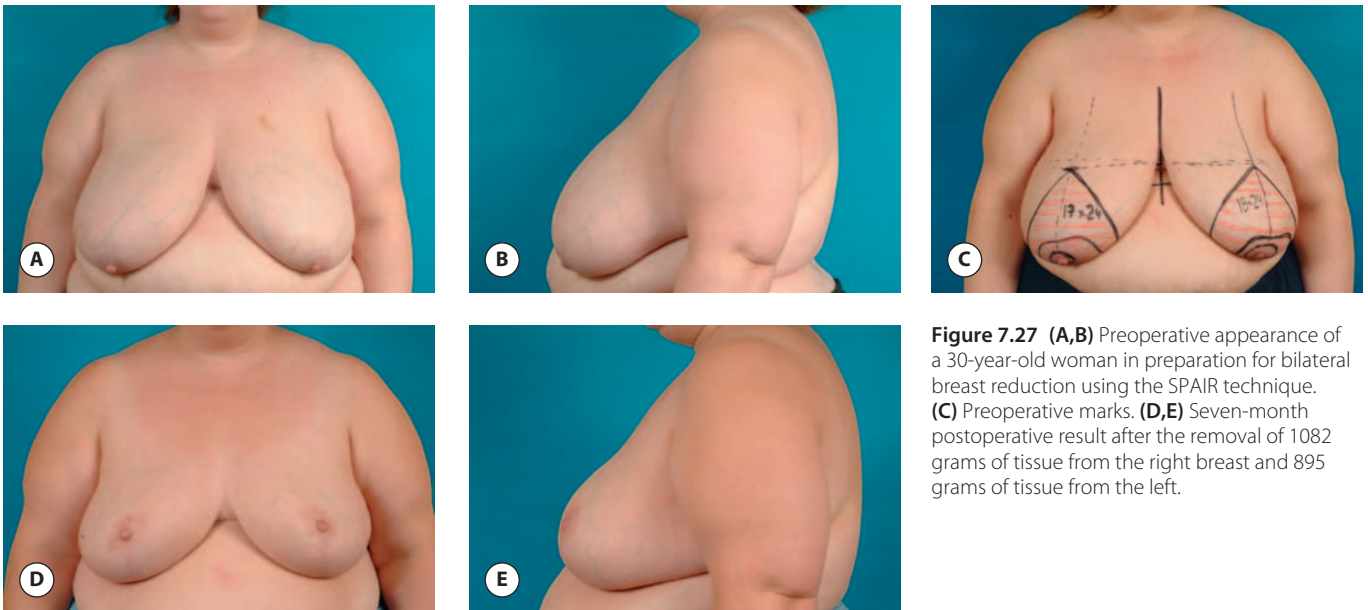


Figure 7.27 (A,B) Preoperative appearance of a 30-year-old woman in preparation for bilateral breast reduction using the SPAIR technique. (C) Preoperative marks. (D,E) Seven-month postoperative result after the removal of 1082 grams of tissue from the right breast and 895 grams of tissue from the left.

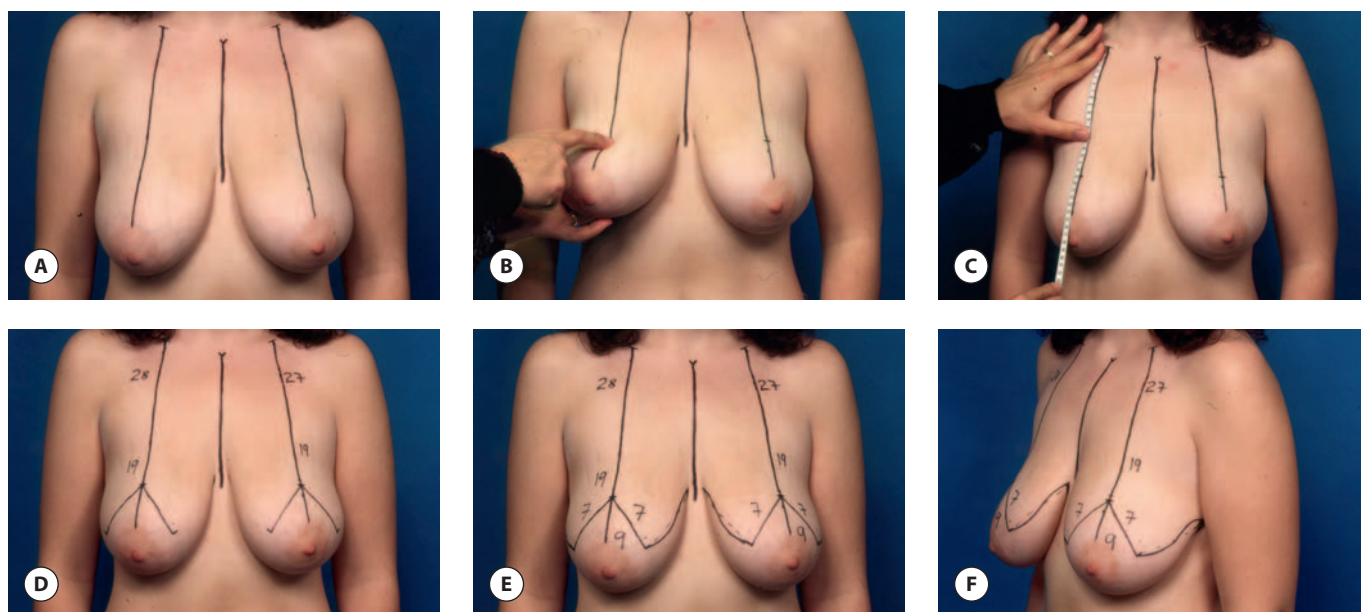


Figure 7.28 (A) The markings for an inferior pedicle inverted T breast reduction begin by first marking the midline and then diagramming the breast meridian on each side. (B) By placing the fingers of the hand under the breast at the level of the inframammary fold, the level of the fold is transposed anteriorly onto the breast. (C) The length of the breast meridian is measured from the clavicle down to the fold mark. Depending on the height and weight of the patient and the size of the breast, this distance typically measures anywhere from 18 to 23 cm. (D) Using the fold mark as the top of the pattern, medial and lateral limbs are drawn

extending inferiorly. These limbs measure 7 cm in length. (E) The distance between the inferior extent of the limbs ranges from 7 to 10 cm with the 10 cm measurement being used for a larger wide breast and the 7 cm measurement used for a smaller narrower breast. (F) A line is drawn in the inframammary fold and the inferior extent of the medial and lateral limbs are connected in an arcing fashion to the most medial and lateral extent of the inframammary fold line. The length of the inframammary fold incision is made long enough to be certain a dog ear will not result once the inframammary fold incision is closed medially and laterally.

along the inframammary fold with a central extension up to and around the NAC, hence the name the inverted T.

Marks The patient is marked in the upright position. A line is drawn in the midline of the chest and a breast meridian is then drawn on each breast designed to separate the breast visually in half (Figure 7.28 A). The location of the inframammary fold is transposed onto the anterior surface of the breast by placing the fingers of the examining hand under the breast at the level of the fold and curling them forward so they can be palpated with the opposite hand (Figure 7.28 B). The distance from the clavicle to this point is then measured as an aid to applying the marks symmetrically (Figure 7.28 C). A 7 cm limb is then angled down medially and laterally from this point (Figure 7.28 D), creating a distance of between 7 and 10 cm between the bottom of these limbs. This distance determines how much the base diameter of the breast will be narrowed. A line is diagrammed in the inframammary fold and it is carried far enough medially and laterally to ensure that a dog ear will not form at the end of the incision after closure. The inferior ends of the vertical limbs are then joined to the inframammary line with an arcing sweep that preserves a small amount of skin centrally and resects more skin laterally. This minor adjustment can assist in maximizing breast projection and help in narrowing the breast base diameter (Figure 7.28 E, F).

Operative technique As with the other breast reduction techniques, an incision measuring 40–44 mm is made around the areola with the areola under maximal tension. The incisions are

then made through the dermis and into the subcutaneous tissue around the entire periphery of the pattern. However, the base of the inferior pedicle is left undisturbed and the skin about the pedicle is simply de-epithelialized (Figure 7.29 A–C). The superiorly based flaps are then dissected free from the remainder of the breast mound using a similar dissection strategy to the SPAIR procedure. The goal is to sculpt the flaps such that they are somewhat thin to begin with and then become progressively thicker as dissection proceeds down to the chest wall. This will ensure that smooth rounded contours will be created once the flaps are closed around the inferior pedicle. The inferior pedicle is then skeletonized with care being taken not to undermine the pedicle and potentially interrupt the vessels in the breast septum. Also, dissection proceeds carefully in the region of the inframammary fold on either side of the pedicle to avoid opening up the loose subscarpal space, which could potentially lead to inferior migration of the breast parenchyma and the classic complication of ‘bottoming out’ (Figure 7.29 D,E). The flaps are then approximated along the inframammary fold and up along the vertical incision with interrupted and running 4-0 absorbable monofilament sutures. The patient is then placed in the upright position and a circular defect is created in the midline at the apex of the breast. The areola is then sutured into position to complete the procedure (Figure 7.29 F–H).

The advantages of the classic inferior pedicle inverted T breast reduction are that it is a very technically straightforward procedure, it is widely applicable to many patients and even very large breast reductions can be performed with relative ease

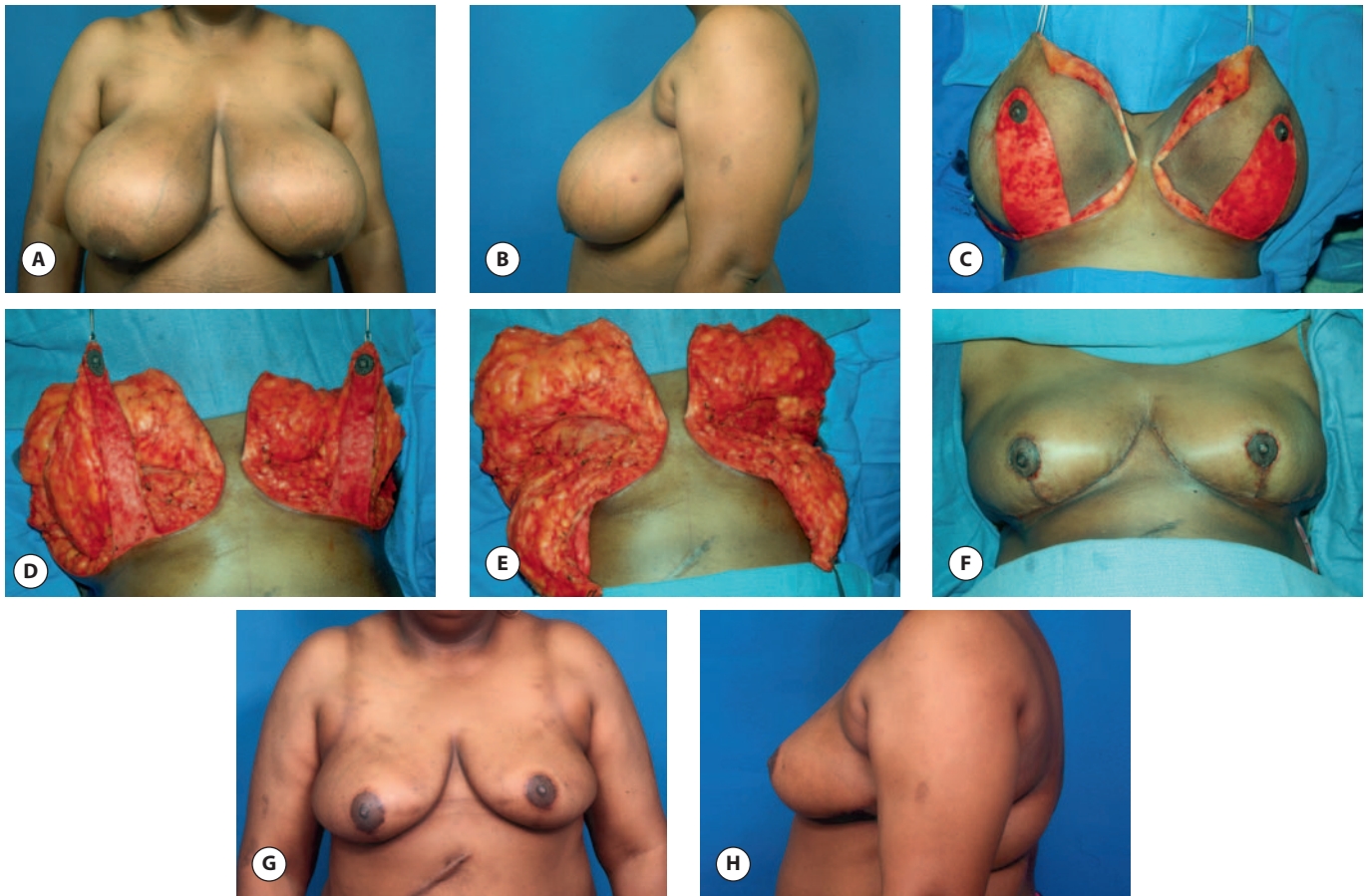


Figure 7.29 (A,B) Preoperative appearance of a 40-year-old woman in preparation for inverted T inferior pedicle breast reduction. (C) The inferior pedicle is de-epithelialized and the incisions around the periphery of the pattern are extended through the dermis. (D,E) After development of the flaps, the inferior pedicle is skeletonized with care being taken not to undermine the pedicle or violate the inframammary fold of the breast.

(F) Final appearance of the breasts after closure of the flaps and inset of the areolas on each side; 1669 grams of tissue was removed from the right breast and 1657 grams of tissue from the left. (G,H) Three-year postoperative result. Despite the large amount of tissue that was removed, the breasts are soft with no evidence of fat necrosis.

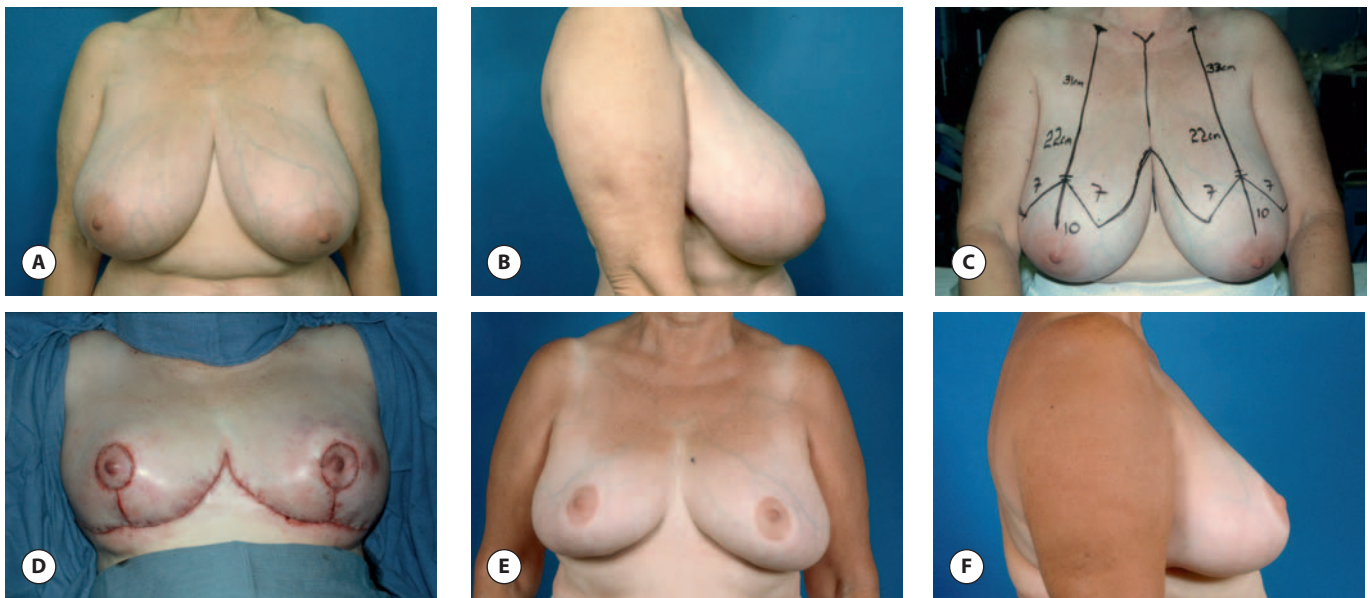


Figure 7.30 (A,B) Preoperative appearance of a 53-year-old woman in preparation for bilateral breast reduction using the inverted T inferior pedicle technique. (C) Preoperative marks. The distance between the vertical limbs was measured at 10 cm to narrow the breast maximally.

(D) Intraoperative appearance after the removal of 1110 grams of tissue from the right breast and 1140 grams of tissue from the left. (E,F) The nine-year postoperative result demonstrates an aesthetic result with well-healed scars.

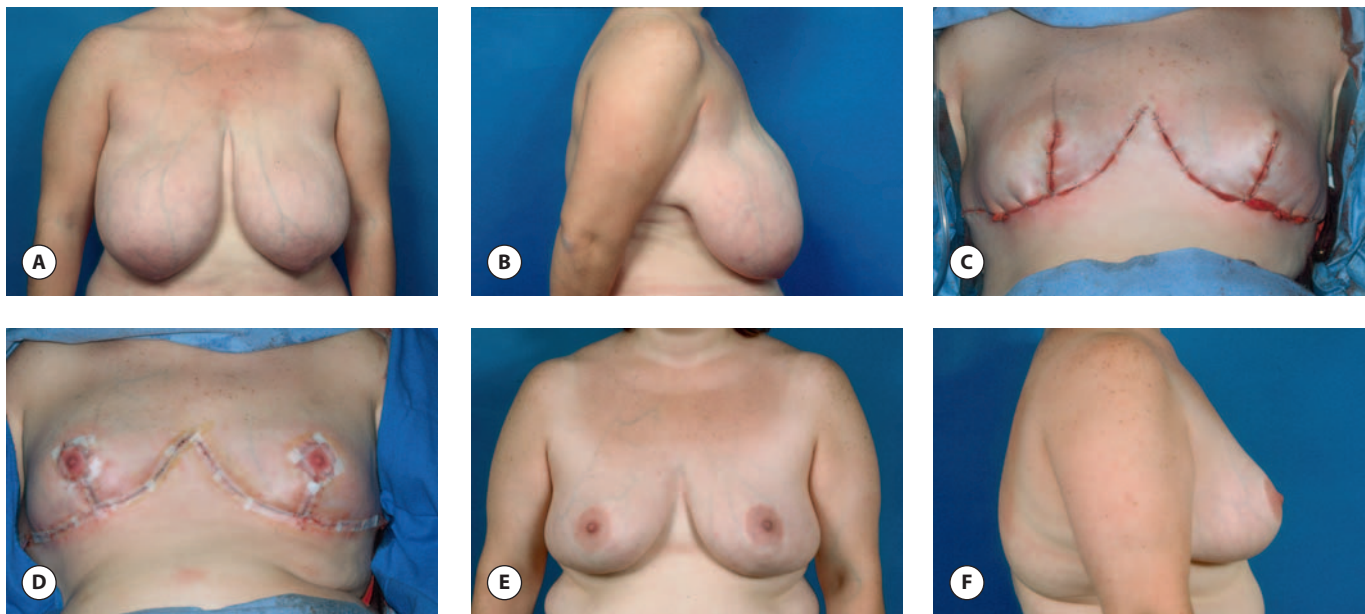


Figure 7.31 (A,B) Preoperative appearance of a 32-year-old woman in preparation for bilateral inverted T inferior pedicle breast reduction. (C) After preliminary closure of the breast flaps around the inferior pedicle, the breasts demonstrate a symmetric appearance. (D) Final appearance

after inseting of the areolas; 1320 grams of tissue was removed from the right breast and 1090 grams of tissue from the left. (E,F) Nine-year postoperative appearance demonstrating a symmetrically aesthetic result that has remained stable over time.

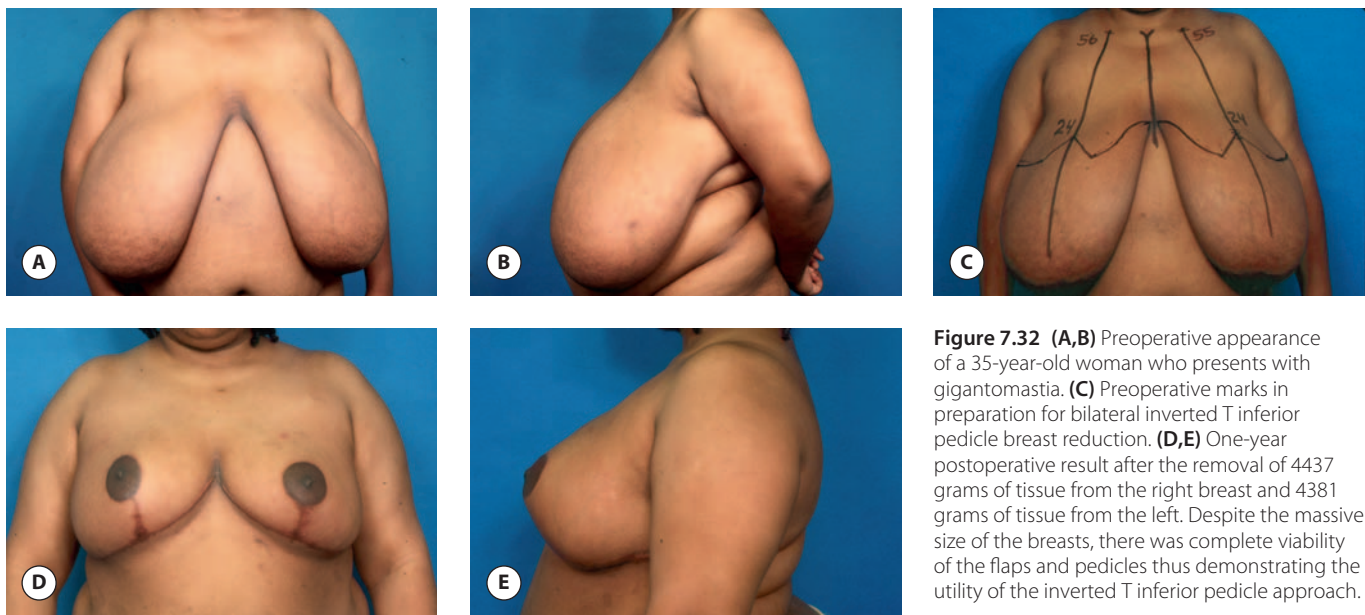


Figure 7.32 (A,B) Preoperative appearance of a 35-year-old woman who presents with gigantomastia. (C) Preoperative marks in preparation for bilateral inverted T inferior pedicle breast reduction. (D,E) One-year postoperative result after the removal of 4437 grams of tissue from the right breast and 4381 grams of tissue from the left. Despite the massive size of the breasts, there was complete viability of the flaps and pedicles thus demonstrating the utility of the inverted T inferior pedicle approach.

(Figures 7.30–7.32). One nuance to this classic technique relates to the shaping of the breast. After the flaps and pedicle have been dissected free, it is possible to suture the pedicle to the pectoralis major fascia using absorbable shaping sutures to stabilize the shape of the breast during the early healing process. Utilization of such internal shaping sutures is just one of many maneuvers that have been reported over the years in an attempt to improve the results of breast reduction (Figure 7.33 A–I).

Another nuance to the classic inverted T inferior pedicle procedure involves the use of a free nipple graft. In selected cases, the length of the pedicle may be so excessive that it is deemed by the surgeon an unreasonable risk to attempt a pedicled procedure. In these cases, the NAC is removed as a full thickness graft, thinned slightly and temporarily placed in a saline moistened sponge. Then, after the breast is reassembled and the inframammary and vertical skin incisions are closed, the location

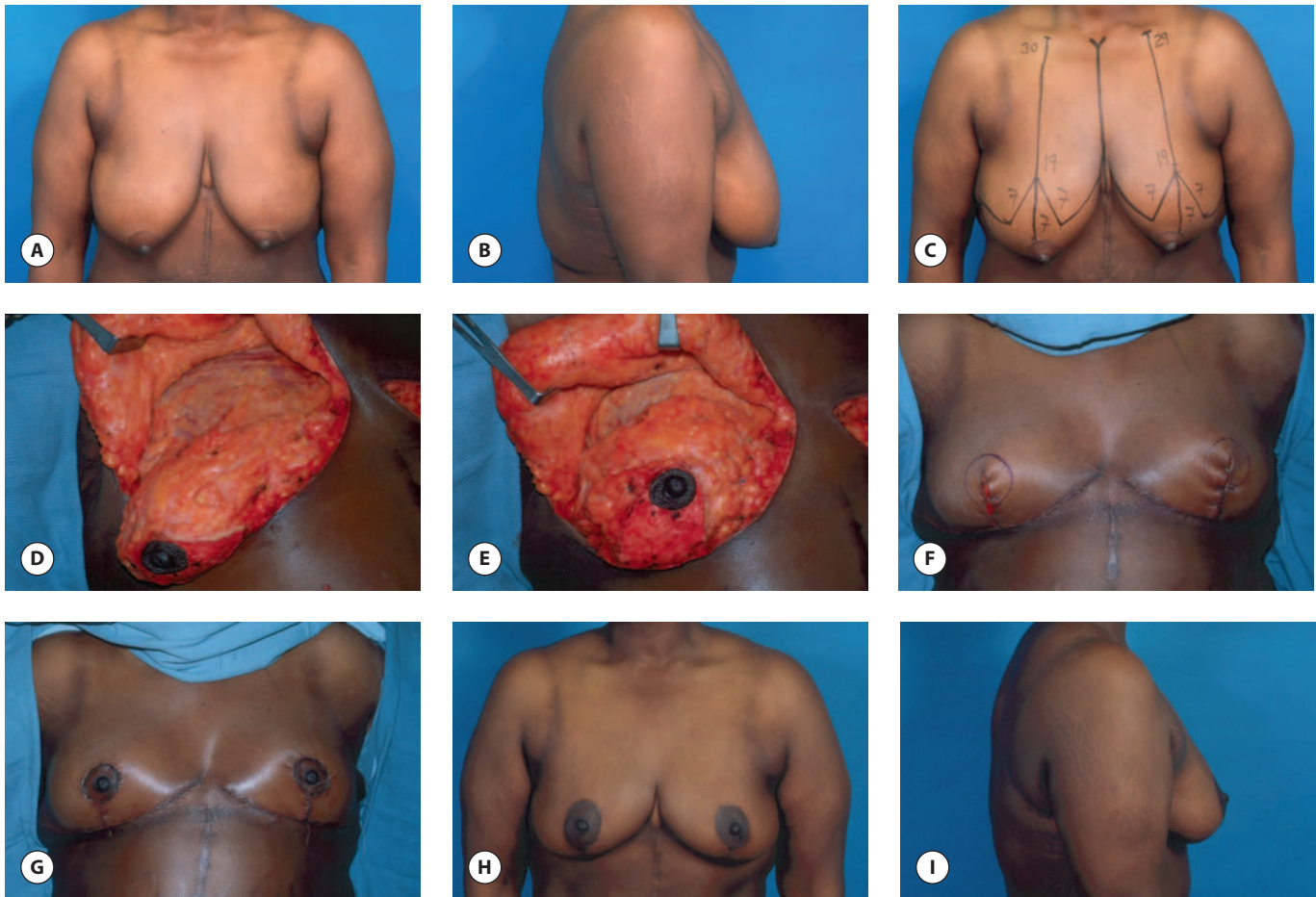


Figure 7.33 (A,B) Preoperative appearance of a 38-year-old woman in preparation for bilateral breast reduction using the inferior pedicle inverted T technique. (C) Preoperative marks. (D) After skeletonization the pedicle can be seen to easily fall away laterally, potentially creating a hollow in the medial and superior portions of the breast. (E) In an attempt to improve the

shape of the breast, the pedicle is repositioned and sutured in a contoured fashion to the pectoralis major fascia. (F,G) Using this internal suture suspension strategy re-distributes the volume of the pedicle to ensure that a rounded and full breast shape is created. (H,I) Five-year postoperative result demonstrating a stable and symmetrically aesthetic result.

for the NAC is determined with the patient upright and this area is de-epithelialized and the graft applied and secured with a bolus tie-over dressing. An alternative method is to attempt a pedicled procedure initially with conversion over to a full thickness graft technique only after it becomes clear that the pedicled NAC is ischemic. In this instance, the NAC is removed as a full thickness graft and the ischemic portion of the pedicle is debrided back to viable tissue. The flaps are closed and the NAC applied as a graft as before. The disadvantage of the full thickness

graft technique relates to the certain loss of sensation that results as well as the potential for variable take of the NAC as a graft with loss of nipple projection. Also, in patients with darkly pigmented areolas, variable take of the graft can result in depigmentation of the areola. However, in properly selected patients, the technique can provide consistent and reliable results while obviating the possibility of NAC necrosis. It remains up to each individual surgeon to assess the risks versus the benefits when deciding when to use the free NAC graft technique.

I have never intentionally planned a breast reduction using a free NAC graft as, in the vast majority of cases, it is not necessary, particularly if the internal breast septum and the associated vascular arcade is left intact. In cases of recognized NAC ischemia, it is best to close the breast (the areola can be left unsutured to remove pressure from the skin closure as a possible etiologic factor in the NAC ischemia) and deliver the patient to the recovery room, where the patient can be warmed

and the effects of vasoconstrictors in the local anesthetic can be allowed to wear off. If, after 1 hour, the NAC still remains ischemic as manifested by a cyanotic blue color or even worse, a pale appearance with no capillary refill, conversion to a free NAC graft is indicated. In 15 years of practice, I have had to utilize this sequential strategy once in one breast. For this reason, it remains my preference to use the free NAC graft technique only in cases of documented NAC ischemia.

Summary

The opportunities provided by the various techniques for breast reduction will excite the aesthetically minded surgeon. By applying these techniques appropriately and incorporating an artistic flair in the performance of these procedures, truly

beautiful results can be obtained. To this end, breast reduction remains as a defining procedure that can showcase the aesthetic capabilities of the surgeon who endeavors to master this challenging operation.

Management of the Tuberous Breast

Management of the tuberous breast represents perhaps the greatest challenge in all of aesthetic breast surgery as, in its most dramatic form, the preoperative deformity in breast shape can be significant. It is important to remember, however, that at times the condition can also be subtle and yet significantly impact in an adverse way the result obtained after aesthetic breast surgery. To avoid poor results in these types of patients, it is very important to recognize which elements of the deformity are present preoperatively and then develop a sound surgical plan designed effectively to correct the anatomic abnormalities that are present.

Clinical Presentation

Typically, a fully involved tuberous breast deformity will include a superiorly malpositioned inframammary fold that appears high in relation to what would be considered a 'normal' breast position. Present along with this is usually a constricted lower pole skin envelope that is likewise tight and unexpanded. As a result, whatever breast parenchyma is present variably protrudes through the areola, creating a 'pseudoherniation'. It appears as if the embryonic breast bud was restricted to a small area of the anterior chest wall with an abnormally absent peripheral expansion and, as the breast develops during puberty, it has nowhere to go as it grows except forward. Because the areolar dermis is more elastic than the surrounding breast skin, there is a preferential expansion through the areola, which leads to the herniated appearance (**Figure 8.1**). Anatomically, in severe tuberous breast cases, fibrous bands can be identified along the underside of the breast in association with the constricted breast base diameter (**Figure 8.2 A**). Once these bands are cut, the entire breast mound can be observed to expand, creating a more normal breast appearance (**Figure 8.2 B**). Currently, it is not known if these bands are responsible for the deformity or, conversely, are present as a result of the deformity. Either way, it is interesting to postulate what role these bands might have in the development of the condition.

Further complicating the altered overall appearance of the breast is the fact that asymmetry is a very common finding in patients with this condition. At times this asymmetry can be as dramatic a finding as the basic abnormality itself (**Figure 8.3**). It is not at all uncommon for one breast to present as a hypoplastic, misshapen mound that contrasts starkly with an enlarged, ptotic and disproportionate opposite breast with a nipple–areola complex (NAC) that appears to be medially translocated. Clearly, adequate surgical treatment must be geared toward artistically reshaping both breasts to maximal advantage in an attempt to restore symmetry.

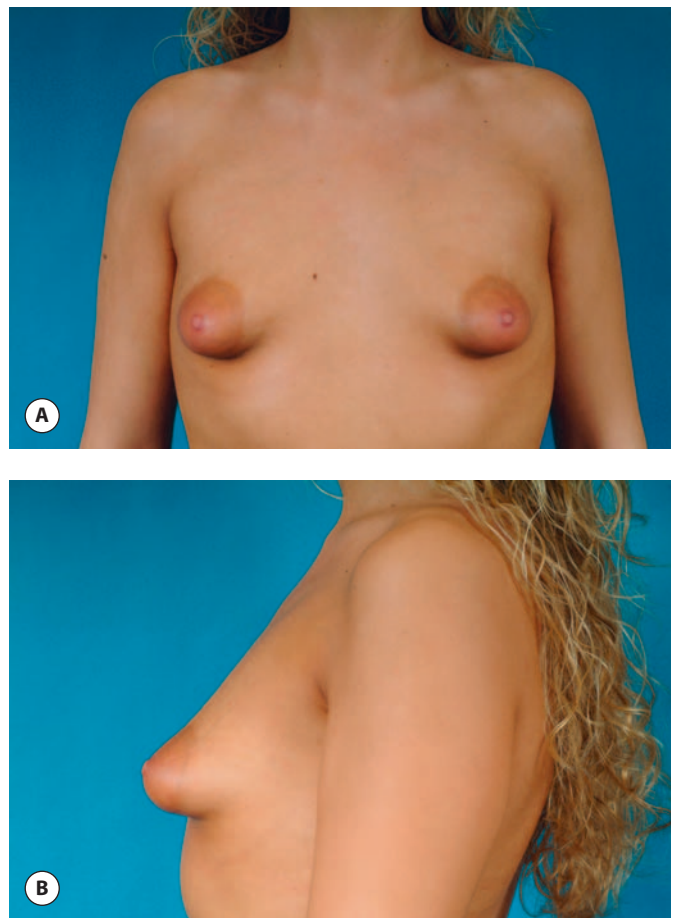


Figure 8.1 (A,B) Preoperative appearance of a 19-year-old woman with a fully developed 'classic' tuberous breast deformity. The breast is hypoplastic in general and whatever parenchyma is present is located mainly under the NAC. There does not appear to be normal peripheral expansion of the breast mound. As a result, growth of the constricted breast bud projects through the elastic areolar skin, creating an areolar 'pseudoherniation'. Along with this is seen a concomitant enlargement of the areolar diameter. As a result of the failure of the breast bud to expand peripherally, the surrounding breast skin remains tight and the IMF that does form is malpositioned superiorly.

Additionally, the tuberous breast deformity is not an all or none entity and, for any given patient, there can be varying degrees of involvement. As a result, the appearance of the breast can range from a subtle tightening of the inframammary fold all

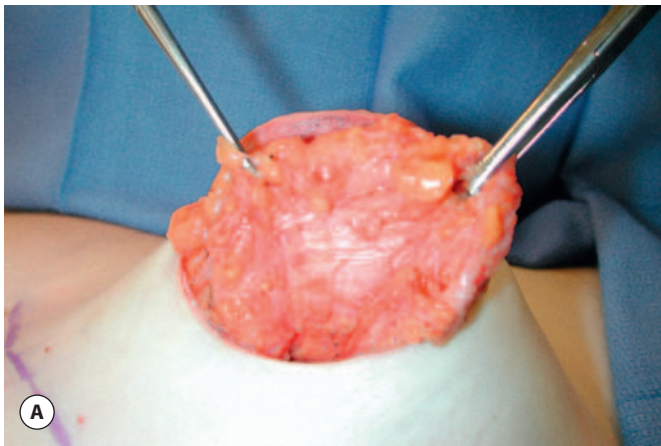
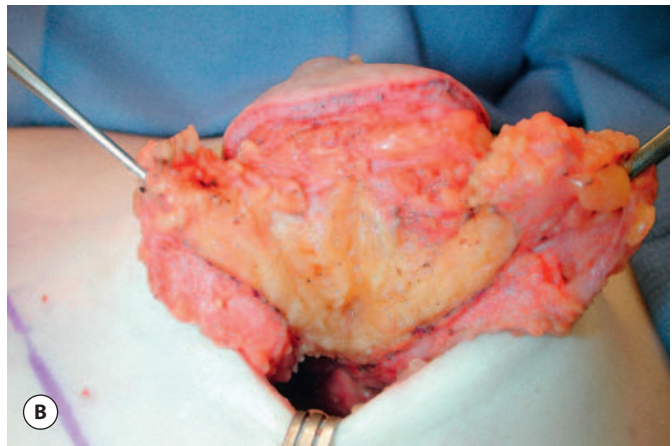


Figure 8.2 (A) Appearance of the underside of the breast in a patient with a severe tuberous breast deformity. The breast mound has been dissected free from the pectoralis major muscle and a subglandular pocket has been created. Horizontally oriented fibrous bands can be clearly visualized along the underside of the breast. These bands appear to be restricting peripheral



expansion of the breast mound. It may be that these fibrous bands restrict normal breast bud development, resulting in the spectrum of deformity seen in tuberous breast patients. **(B)** After radial release of these bands, a more normal peripheral expansion of the breast parenchyma can be created. Such a maneuver is central to optimal correction of the tuberous breast.

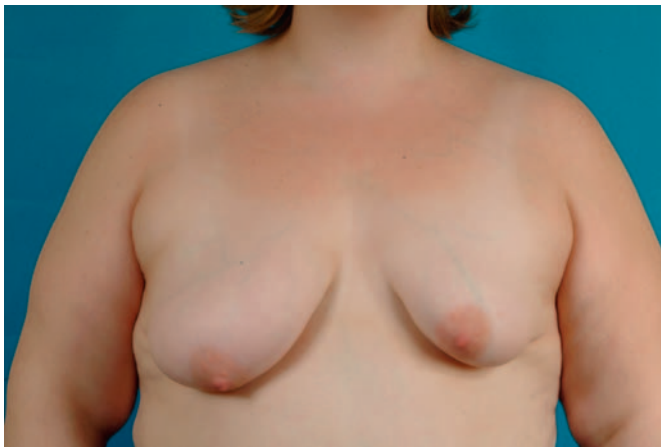

Figure 8.3 A very common presentation for patients with the tuberous breast deformity includes a smaller hypoplastic breast with a constricted base on one side and a larger and more profoundly ptotic breast on the other. Interestingly, both breasts, despite the size difference tend to exhibit an inframammary fold location that is superiorly malpositioned.

the way to the fully developed deformity with asymmetry as described previously (**Figure 8.4**). All of these factors combine to make treatment of the tuberous breast one of the most demanding surgical challenges in all of aesthetic breast surgery.

Surgical Strategies

Treatment of the tuberous breast deformity must generally focus on three main areas. First, the constricted skin envelope with the malpositioned inframammary fold must be normalized as much as possible. Second, the anatomic relationships that result in areolar herniation must be remedied. And, finally, any asymmetry in the size or shape of the breasts must be addressed. In most instances, it is necessary to combine these surgical strategies to optimize the final result.

Management of the Constricted Skin Envelope

The tightness of the skin envelope around the breast is perhaps the most difficult feature of the hypoplastic tuberous breast to correct. Not only does this constricted skin envelope interfere with the placement of an appropriately sized breast implant, but the lack development of a normal breast mound fails to stretch the skin appropriately, resulting in an abnormally high and tight inframammary fold. In essence, a new inframammary fold must be created surgically and the deformity or crease associated with the old fold must be overcome to create a smooth lower pole contour. Successful management of this aspect of the tuberous breast deformity will, in large part, determine the quality of the aesthetic result.

It must be emphasized that, even in patients who demonstrate only a mild tendency toward a tuberous breast, the inframammary fold contour can create significant problems in breast shaping. This can become very important in a general breast augmentation practice as the subtly high and mildly tight inframammary fold can escape the notice of the surgeon, only to become a problem later at the time of surgery when the lower pole of the breast appears constricted or the previous fold fails to soften completely as a new and lower fold position is created. These types of patients can be recognized by carefully observing the nature of the medial inframammary fold crease. If there is any convexity or superiorly oriented curving of the medial lower pole contour, a mild tuberous breast can be diagnosed (**Figure 8.5**). Recognition of this deformity preoperatively can help prepare the surgeon for what is to come at the time of surgery and allow for appropriate preoperative technical planning to be done. Also, the patient can be advised ahead of time as to the nature of her deformity, which then allows reasonable expectations to be set.

Perhaps the most difficult determination that must be made by the surgeon is whether or not the constricted inferior pole skin can be expanded enough to allow the primary placement of a breast implant to create a natural contour in the lower pole of the breast. Also, it must be determined whether or not the crease created by the old inframammary fold (IMF) can be overcome by the implant once the new and more inferiorly located fold is

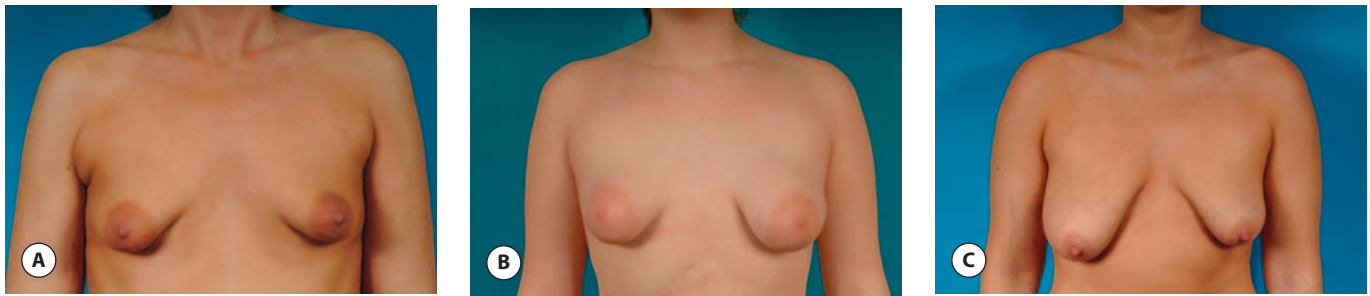


Figure 8.4 (A–E) Although each of these patients presents with differing degrees of deformity, they all demonstrate the basic findings of the tuberous breast, namely a variably constricted breast base with an abnormal medial IMF contour; a high, tight IMF, varying degrees of areolar ‘pseudohermiation’ and asymmetry.

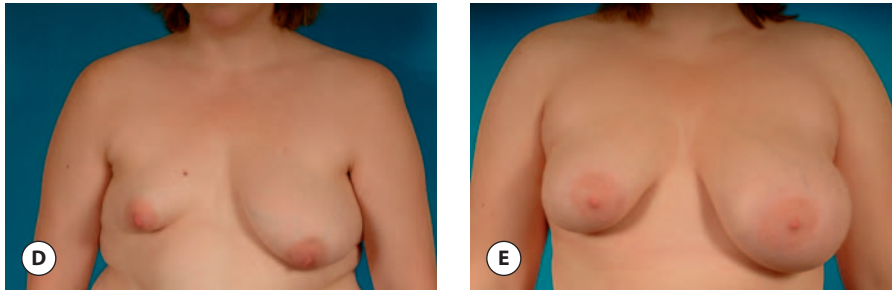


Figure 8.5 (A) Preoperative appearance of a 43-year-old woman in preparation for breast augmentation. In addition to the general hypoplasia and moderate ptosis of the NAC, there is a subtle convexity noted at the medial portion of the inframammary fold indicative of a mild degree of constriction in the lower pole of the breast, particularly on the left. This represents a mild form of tuberous breast deformity. Failure to recognize

this soft tissue constriction and appropriately release it at the time of implant placement can lead to persistent deformity with asymmetry.

(B) Preoperative marks in preparation for augmentation mastopexy.

(C) One-year postoperative result demonstrating a smooth and full medial pole contour after vigorous scoring and soft tissue release along the medial inframammary fold.

created. This is a critical decision point in designing a successful operative strategy as, in fully developed tuberous breast cases, a persistent fold and a flattened and tight lower pole contour will very commonly persist despite aggressive release of the underlying soft tissue support structures. In these patients, better control of the lower pole and the location of the IMF can be afforded with the primary use of a tissue expander. In this fashion, the constricted skin envelope can be stretched sufficiently over time to allow the subsequent placement of an implant and any persistent crease in the old IMF can be softened. Deciding between the primary insertion of an implant versus the use of a staged tissue expander/implant strategy is the major determination that must be made when treating a patient with a tuberous breast deformity. This decision is complicated by other factors. To a certain extent, an old IMF crease that does not completely soften initially may subsequently relax over time due to the influence of the underlying implant. When this old fold will fill out and to what extent will be very patient dependent and is therefore subject to a significant degree of variability. As a result, an early persistent fold that can detract from the overall result after surgical correction may or may not improve over time and in no way can this be predicted with certainty. Added to this is the desire on

the part of many patients to accomplish surgical correction in one operation. Besides the basic advantages of needing only one operation on traditional considerations such as operative risk, recovery and time off work, many patients have a financial incentive to effect correction in one stage. Unfortunately, insurance companies very commonly do not extend benefit coverage for tuberous breast correction and the procedure is considered cosmetic. As a result, a great many patients have financial constraints that allow only one procedure. All of this combines to place a fair amount of pressure on the surgeon to provide a one-stage correction.

To this end, several surgical strategies can be employed to maximally expand the skin of the lower pole and accurately lower the IMF. By placing the implant in the subglandular plane, direct force is applied to the skin of the lower pole and any tethering effect created by the pectoralis major muscle can be obviated. Also, by using the subglandular plane, the underside of the breast can be stretched and released as needed. As noted previously, there may be tethering fascial bands running horizontally along the underside of the breast. By radially scoring up into the parenchyma and dividing these bands, a visual and palpable release of the underside of the breast will be noted, resulting in a softer and more compliant breast mound. Taken together,

these two maneuvers will allow the soft tissue envelope and the implant to better complement one another, resulting in a smooth and naturally contoured lower pole.

In more severe cases, it may be necessary to completely divide the lower half of the gland in a radial fashion to release fully the soft tissue constriction. These radial releasing incisions can be carried all the way to the dermis as needed to allow the soft tissue envelope maximally to expand. A useful approach that can facilitate a full soft tissue release is to utilize a periareolar incision to access the breast and then develop a dissection plane along the lower hemisphere at the level of the breast capsule. In this fashion, the underside of the breast can be accessed and released as needed and the lower half of the breast mound can also be divided radially to accomplish a complete correction of the soft tissue constriction caused by the breast itself. Also, any tethering bands that remain in the skin flap can be divided in a checkerboard type fashion to complete the release. Particular attention can be directed to the old fold as needed to be certain there are no unrecognized soft tissue attachments that may be contributing to a persistent crease that fails to soften completely. One additional advantage associated with the periareolar approach is that the setting of the new IMF level is more easily accomplished from above rather than through an incision in the IMF. Not only can it be difficult to determine accurately where to place the IMF incision such that it falls directly in the fold, but the technical challenge of trying to set the soft tissue attachments of the new fold through such a closely positioned incision can be difficult. After the overlying soft tissue has been completely released, the only remaining tethering force influencing the shape of the lower pole will be the lower pole breast skin. Therefore, any remaining tightness to the lower pole contour of the breast, or any persistent crease that is present in the region of the old fold, will be due to this unexpanded skin envelope and the only way to overcome such restriction is with the placement of a tissue expander.

Expander versus implant Ultimately, the decision regarding whether or not a tissue expander will be required will depend upon the judgment and experience of the surgeon. It does merit reinforcing that it is rarely an error to use a tissue expander and effect a correction of the tuberous breast deformity in a staged fashion. By placing the expander in the subcutaneous plane, the full effect of the expansion can be exerted on the constricted skin envelope and the peripheral margins of the new breast including the inframammary fold can be set. Expansion can proceed until the contour of the old fold is overcome. Later, after the skin envelope has been expanded, replacement of the expander with a carefully selected permanent implant can be accomplished in a controlled and accurate fashion. By basing the implant volume, base diameter and projection on the specific measurements of the expander that was used and noting the volume to which it was filled, a very aesthetic result can be obtained. In addition, should any other breast contour, such as the location of the IMF or the position of the NAC require revision, it can be performed at this time as well. Typically, such revisions are much easier to accomplish after expansion which makes it easier to obtain a consistent aesthetic result than when these contours are managed in one stage with the placement of an implant.

When deciding on whether or not to use a tissue expander, the major variable that must be assessed first in any patient with a tuberous breast deformity is how severely the skin envelope is constricted. If the skin of the breast is adherent to the underlying

chest wall, it is unlikely, even after aggressive release, that sufficient laxity can be created to allow the convenient placement of an implant and a tissue expander will be required to stretch out the constricted skin envelope appropriately. In these cases, the native breast is severely hypoplastic and there is commonly NAC herniation in association with a high, tight IMF. Conversely, if there is demonstrable laxity to the skin envelope and the NAC is freely movable in relation to the chest wall, there is likely a good chance that the simple insertion of an implant in association with an aggressive soft tissue release will sufficiently fill out the skin envelope and provide for an acceptable result without the need for a tissue expander. Between these two relatively straightforward extremes lies a vexing gray area where the best choice may not be readily apparent. In some patients, reducing the opposite breast may allow an implant to be placed primarily to obtain acceptable symmetry. However, at times, it will be necessary to accept a suboptimal result if the overriding goal is to accomplish a one-stage reconstruction. In selected cases, the surgeon can make an intraoperative change in the surgical plan and insert a tissue expander if it appears that the skin envelope will not relax to an acceptable degree. No matter what the surgical plan entails, it is very important that the patient understand the magnitude of her deformity and the surgical challenges that result. In particular, when there is a request to accomplish the procedure in a single stage, the patient must understand that the aesthetics of the result may be compromised and subsequent revision may be required.

Management of Areolar Herniation/Enlarged Areola

When the areola is excessively large or there is any degree of areolar herniation, a reduction in the diameter of the areola using periareolar techniques is indicated. By combining an outer periareolar incision with an inner areolar incision that ranges from 40 to 44 mm, the excessive and redundant areola can be removed resulting in a smaller areolar diameter. Also, the net effect of this maneuver is to equalize the propensity of the surrounding breast skin and the areolar skin to stretch under the influence of the underlying forces created by the parenchyma and the implant. In essence, the weak spot in the overall breast skin envelope, namely the areola, is repaired with the result being that the pressure from the underlying structures is now evenly dispersed over the entire breast mound. In this fashion, any tendency for the areola to herniate is corrected. It is here, in particular, that the interlocking Gore-Tex technique described previously is particularly useful. By evenly distributing the inevitable tension on the periareolar closure at the superficial dermal level, any tendency for the areola to spread will be minimized. Also, all of the releasing maneuvers described previously are facilitated by the periareolar approach.

Management of Breast Asymmetry

When a symmetric tuberous breast deformity is present, the same operative techniques are simply applied from side to side as needed to provide a symmetric result. However, it is very common for the breasts to demonstrate asymmetrically variable deformity in shape and size. One common variant of this clinical presentation is the patient who presents with a fully developed hypoplastic tuberous breast on one side and an enlarged and ptotic breast on the other. It is important to realize that the enlarged

breast almost invariably demonstrates many of the attributes of a tuberous breast including a superiorly dislocated IMF and a constricted base diameter. Very often, the breast protrudes over the IMF, creating an exaggerated ptosis with an enlarged areola that tends to be displaced medially. Adequate treatment to provide for a symmetric result must then concentrate not only on the frankly tuberous hypoplastic breast, but the enlarged and ptotic breast as well. From a surgical planning perspective, it is my preference to either reduce or lift the enlarged breast at the same time as the hypoplastic breast is treated with an implant in the hopes of providing the best symmetry possible in one stage. Should a revision subsequently be required, the breasts will display a greater degree of symmetry than they did initially and the revision will be easier to accomplish with greater accuracy.

At the time of surgery, it is recommended to treat the more severely involved breast first as this is the breast where there will be the least amount of control over the final result. Typically, this will be the hypoplastic breast that is released and augmented to the desired size. Once the hypoplastic breast is set, the opposite breast can then be more accurately reduced or lifted to the desired size and shape required to obtain the best symmetry. Although the goal is perfect symmetry, it is best to recognize that the preoperative deformity of many patients is significant and, typically, the breasts present with different anatomic features that make each unique in reference to the other. For this reason, despite considerable effort, it may not be possible to obtain exact symmetry in many cases. Appropriate preoperative

counseling can prepare patients for this eventuality and help in setting realistic expectations.

Clinical Applications

Soft Tissue Reconstruction

In some patients with a fully developed tuberous breast deformity, there may be enough tissue to allow the breast simply to be re-sculpted without the need for an implant. In these cases, it is possible to utilize a standard mastopexy technique to reshape the breast and lift and reposition the NAC. However, a technique that manages only the skin envelope will not adequately address the deformity as internal dissection and release of the constricted breast base is required to allow the breast to splay out and more anatomically fill out the skin brassiere. My preferred method for doing this is with the short scar periareolar inferior pedicle (SPAIR) technique. Because of the way the breast flaps are developed, an internal release of the constricted base is accomplished that allows the normal dimensions of the breast to be restored. Then, after the inferior pedicle is developed, the underside base of the pedicle can be scored to release completely any deep restraining bands that may be present. Once the breast is reshaped and the widened areola reduced, a standard circumvertical pattern is applied to normalize the skin envelope ([Figure 8.6](#)). This same strategy can be used in

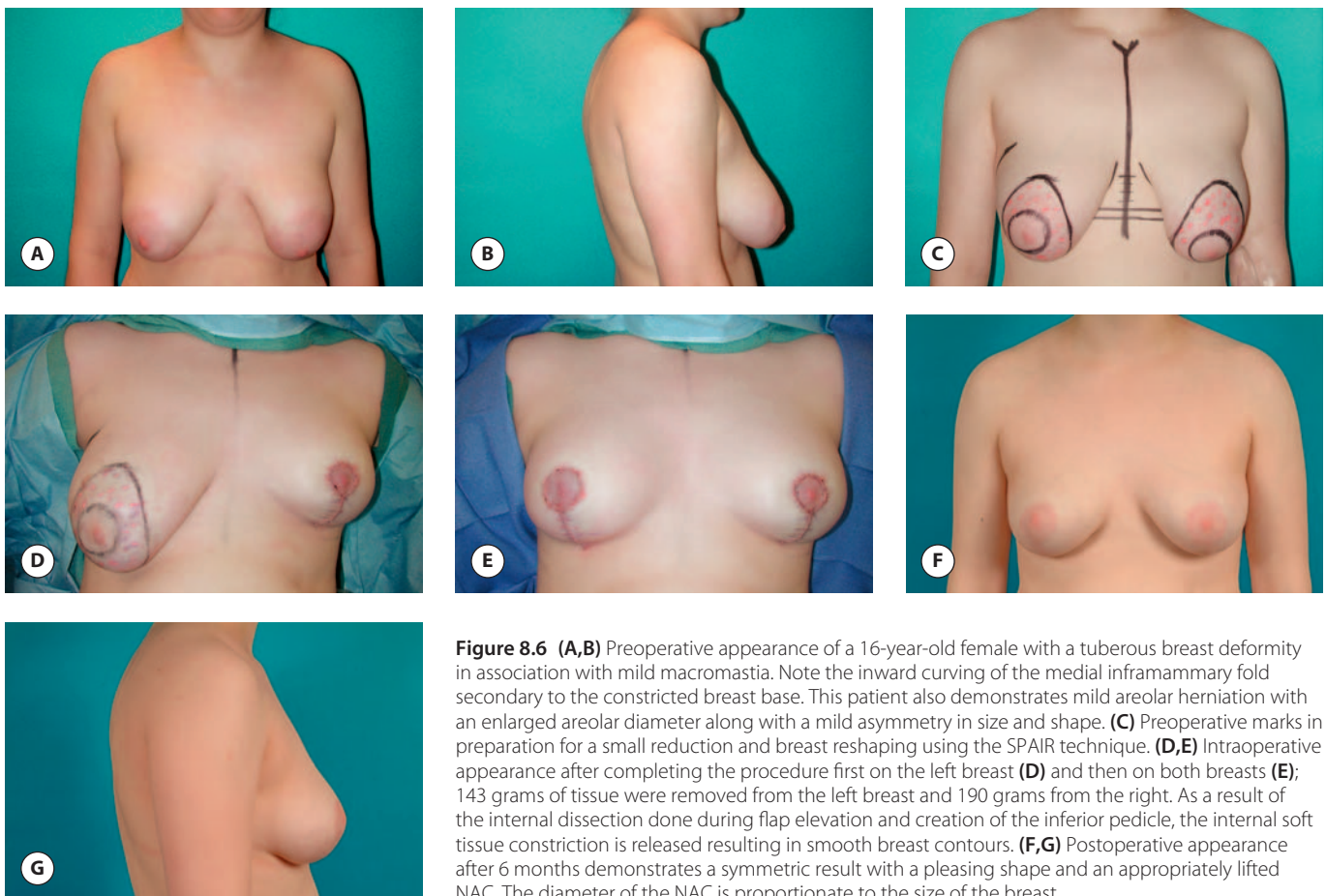


Figure 8.6 (A,B) Preoperative appearance of a 16-year-old female with a tuberous breast deformity in association with mild macromastia. Note the inward curving of the medial inframammary fold secondary to the constricted breast base. This patient also demonstrates mild areolar herniation with an enlarged areolar diameter along with a mild asymmetry in size and shape. (C) Preoperative marks in preparation for a small reduction and breast reshaping using the SPAIR technique. (D,E) Intraoperative appearance after completing the procedure first on the left breast (D) and then on both breasts (E); 143 grams of tissue were removed from the left breast and 190 grams from the right. As a result of the internal dissection done during flap elevation and creation of the inferior pedicle, the internal soft tissue constriction is released resulting in smooth breast contours. (F,G) Postoperative appearance after 6 months demonstrates a symmetric result with a pleasing shape and an appropriately lifted NAC. The diameter of the NAC is proportionate to the size of the breast.

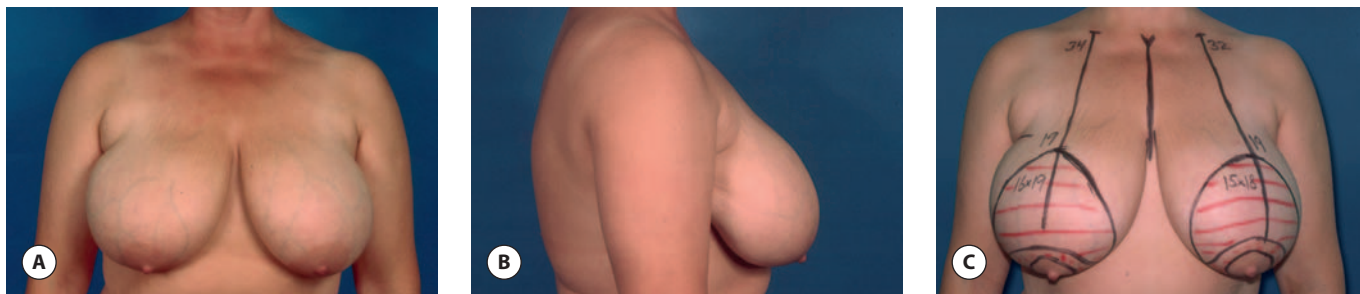


Figure 8.7 (A,B) Preoperative appearance of a 43-year-old female with a bilateral tuberous breast deformity that presents in conjunction with significant macromastia. The IMF is superiorly displaced causing the enlarged breast to fall over the fold, creating an overly ptotic appearance. (C) Preoperative marks in preparation for bilateral reduction and breast reshaping using the SPAIR technique. (D,E) Postoperative appearance after 3 years demonstrates a symmetric and contoured result along with a properly positioned NAC.

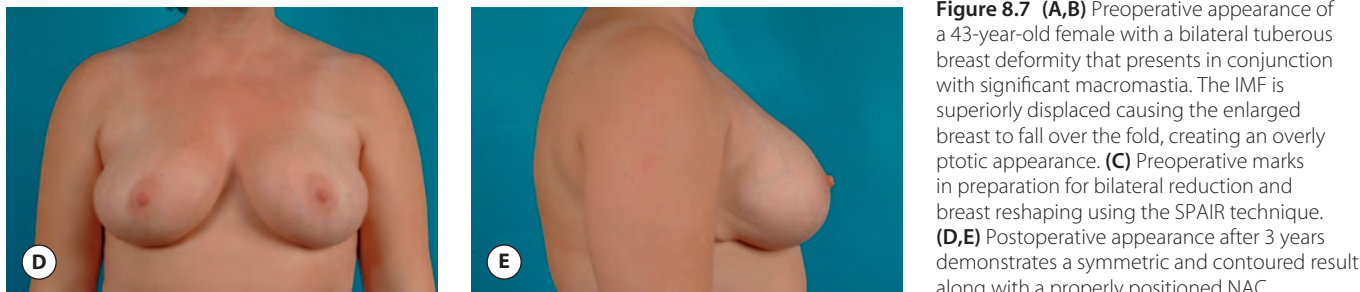


Figure 8.8 (A,B) Preoperative appearance of a 44-year-old female with a tuberous breast deformity variant that includes macromastia in association with a significant asymmetry. (C) Preoperative marks in preparation for a right-sided mastopexy and a left breast reduction. On the right, a skin only circumvertical mastopexy was all that was required to create a contoured breast and there was no need for internal parenchymal release. On the left,

a full breast reduction using the SPAIR technique was performed removing 540 grams of tissue. (D,E) Postoperative appearance at 1 year demonstrates improved symmetry in both the size and shape of the breasts as well as in the location of the NAC. The areola is also smaller and an overall aesthetic result has been obtained.

patients with a tuberous breast deformity that includes any degree of macromastia as a reduction in breast volume can easily be accomplished along with the associated soft tissue release and reshaping of the breast. As with more standard techniques of breast reduction, the advantage of using the SPAIR technique is that an effective method for reshaping the breast and reducing the volume is provided that results in only a circumvertical scar pattern with the inframammary fold scar being eliminated. Because the technique is associated with only a modest settling

during the postoperative recovery period, the classical finding of ‘bottoming out’ associated with the Wise pattern inferior pedicle technique is negated and the shape of the breast does not significantly change over time (Figure 8.7). This, along with the fact that the technique can be applied to a wide variety of breast sizes and shapes makes it particularly applicable to the subset of tuberous breast patients who present with asymmetric macromastia (Figure 8.8). Because the shape of the breast is aesthetic immediately, no provision for trying to predict how the breast

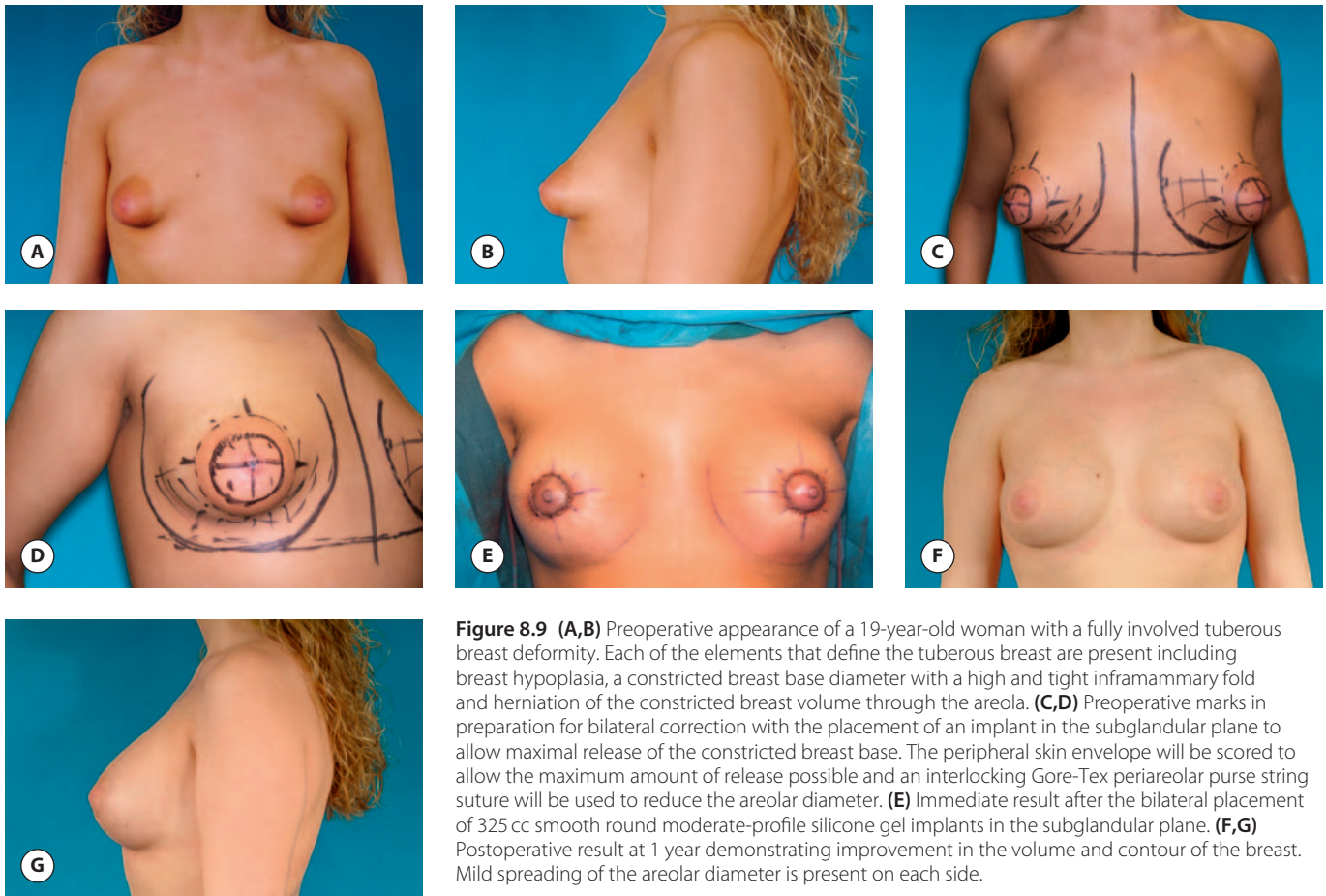


Figure 8.9 (A,B) Preoperative appearance of a 19-year-old woman with a fully involved tuberous breast deformity. Each of the elements that define the tuberous breast are present including breast hypoplasia, a constricted breast base diameter with a high and tight inframammary fold and herniation of the constricted breast volume through the areola. (C,D) Preoperative marks in preparation for bilateral correction with the placement of an implant in the subglandular plane to allow maximal release of the constricted breast base. The peripheral skin envelope will be scored to allow the maximum amount of release possible and an interlocking Gore-Tex periareolar purse string suture will be used to reduce the areolar diameter. (E) Immediate result after the bilateral placement of 325 cc smooth round moderate-profile silicone gel implants in the subglandular plane. (F,G) Postoperative result at 1 year demonstrating improvement in the volume and contour of the breast. Mild spreading of the areolar diameter is present on each side.

shape will change over time is required, therefore the breasts can be sculpted with confidence at the initial procedure and very aesthetic results can be obtained.

Implant Based Reconstruction

If there is not enough native breast parenchyma to adequately fill out the skin envelope after it has been released, then additional volume must be provided for in the form of an implant. After it has been determined that the soft tissue envelope of the hypoplastic constricted breast is compliant enough to accept a breast implant, planning for the placement of the implant proceeds as it does for any breast augmentation. The three major decisions that must be made, namely implant choice, incision location and pocket selection, are made based on the dictates of the clinical situation. As noted previously, the subglandular plane can afford a practical advantage to shaping the breast in most patients as the skin envelope is more directly filled out by the implant when it is placed on top of the pectoralis major muscle rather than underneath it. In this fashion, any potential tethering effect of the muscle is obviated and the implant can fill out the skin envelope unimpeded by any potential internal constriction. Also, the incision location is optimally situated at either the IMF or around the areola. If there is any degree of areolar herniation or enlargement, a periareolar approach is best used to access the subglandular plane as this will also allow the altered

areolar dynamics to be addressed as discussed previously (Figure 8.9). If the areola is not enlarged or does not need repositioning, the IMF incision can provide a direct approach to the underside of the breast and allow soft tissue release and implant insertion (Figures 8.10, 8.11). The transaxillary approach is the least favored approach as direct visualization of the altered and constricted elements of the soft tissue envelope can be difficult at best, even with endoscopic control, and subglandular placement of the implant may be difficult to accomplish through this incision. Finally, implant selection proceeds as with a standard breast augmentation. Essentially, any type of implant can provide an aesthetic result given the types of considerations discussed in the chapter on breast augmentation.

Tissue Expander Based Reconstruction

In cases where it has been determined that an implant will be required to provide the needed volume in the affected breast, but the soft tissue envelope is too constricted to allow the primary placement of an implant, a tissue expander must then be used to prepare the pocket. The same types of considerations that influence decision making for implant placement also come into play when using a tissue expander. Namely, the optimal plane for insertion of the device is the subglandular plane and the most versatile incision location is periareolar. The only important variable influencing the expander choice relates to the base diameter

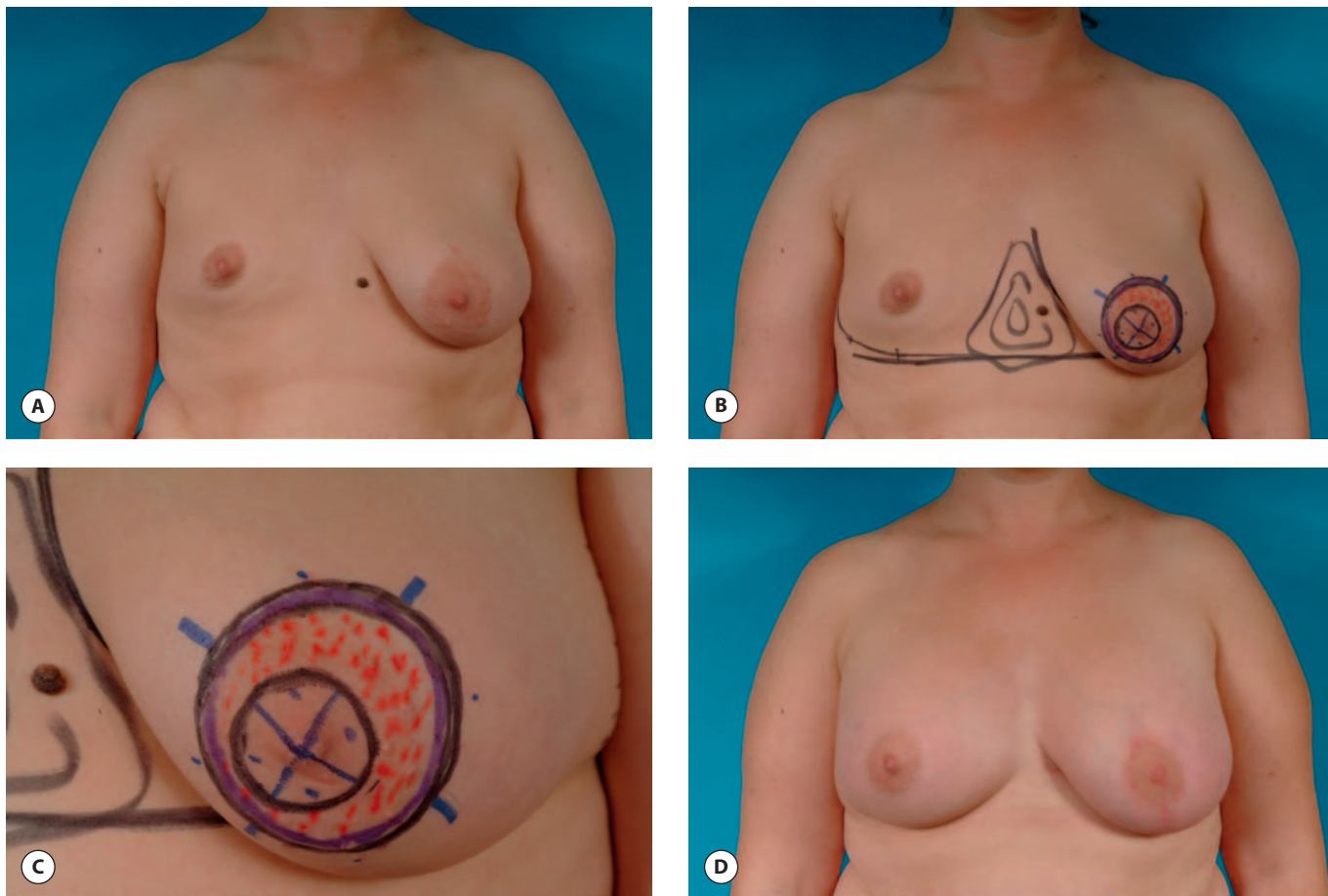


Figure 8.10 (A) Preoperative appearance of a 35-year-old woman who presents with a tuberous breast variant consisting of a hypoplastic right breast along with an overly ptotic left breast with a superiorly displaced and tight IMF. Note that the areolar diameter is also slightly widened and the areola itself is slightly translocated medially. (B,C) Preoperative marks in preparation for a right breast augmentation along with a left circumvertical augmentation mastopexy. To correct the medial areolar malposition, an asymmetric periareolar skin excision will be used to try to reposition the areola more laterally (C). (D) Appearance of the patient 3 months after undergoing subglandular placement of a 600 cc high-profile smooth round

silicone gel implant on the right along with a 350cc moderate-profile smooth round silicone gel implant on the left. On both sides, the underside of the breast was scored to accomplish a soft tissue release and allow the comfortable placement of the implants. On the left, a circumvertical skin pattern was used in conjunction with an interlocking Gore-Tex suture. An overall improvement in the symmetry of the size and shape of the breasts, as well as in the position and diameter of the NACs is evident. Because the skin along the inframammary fold on the right was mobile, an implant could be placed primarily on the right thus accomplishing this correction in a single stage.

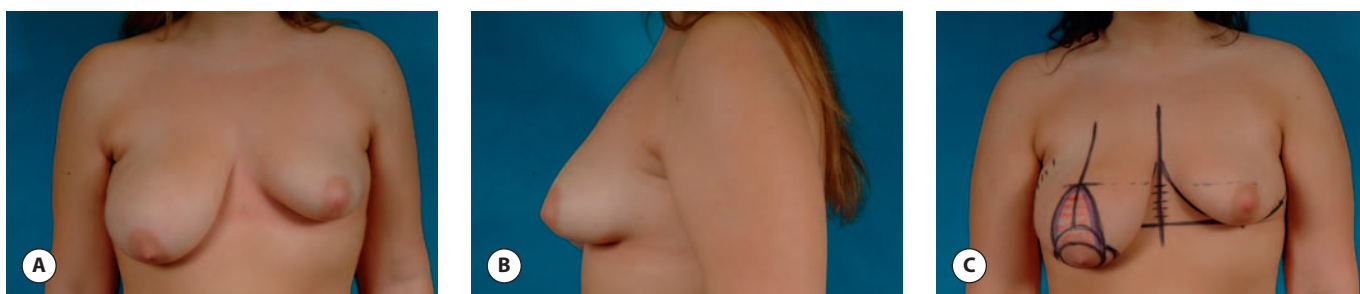


Figure 8.11 (A,B) Preoperative appearance of a 20-year-old woman who presents with a mild tuberous breast deformity in association with a marked asymmetry. On each side, the inframammary fold is mildly constricted and each breast seems to fold over the inframammary crease in an exaggerated fashion. (C,D) Preoperative marks in preparation for a left single-stage breast augmentation and a right circumvertical inferior pedicle reduction. (E,F) Appearance of the breast after removal of the wedge

of tissue from the superior pole within the dimensions marked by the periareolar pattern. By removing the tissue from the area above the NAC, space is made to easily transpose the inferior pedicle carrying the NAC up into the defect without creating a tissue crowding effect (E). The underside of the inferior pedicle is scored to release the soft tissue constriction and allow the breast to expand and fill in the void created by the removal of the tissue (F).

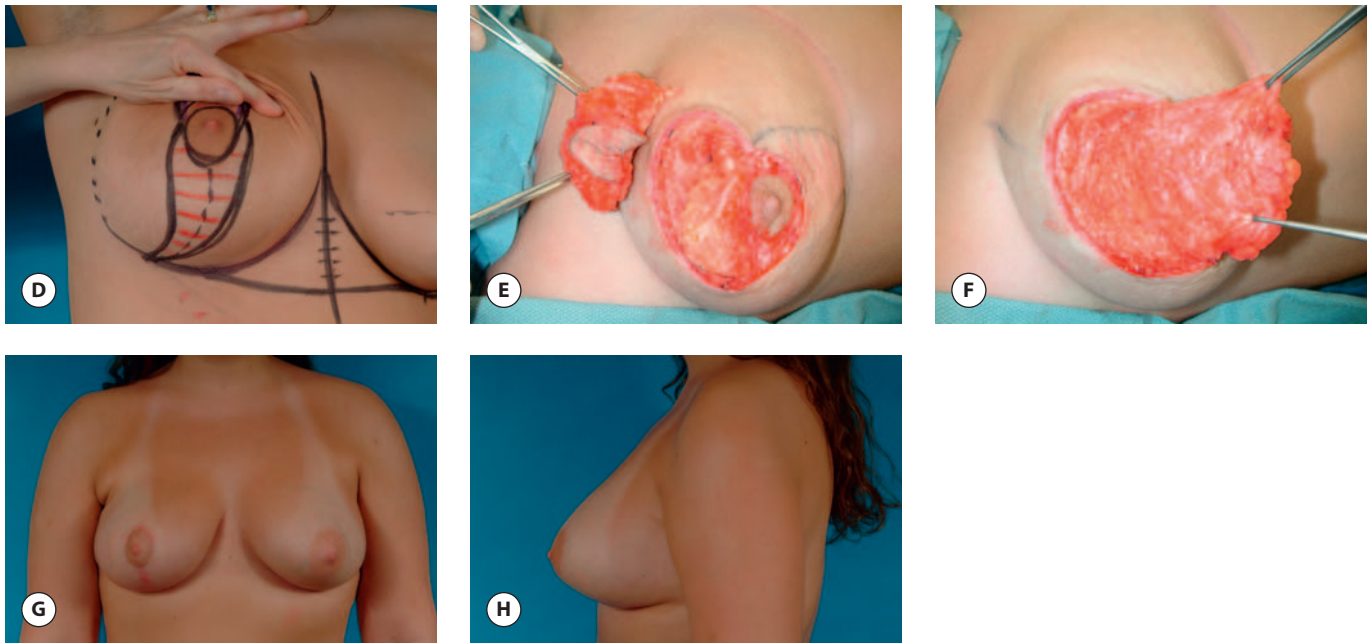


Figure 8.11 (Continued) (G,H) Postoperative appearance 2 months after undergoing subglandular placement of a 375 cc smooth round moderate profile plus silicone gel implant on the left with lowering of

the inframammary fold along with a small circumvertical inferior pedicle reduction/lift on the right. A pleasing shape with reasonable symmetry has been achieved.

of the device. It is important to completely fill out the width of the tuberous breast to be certain an appropriate implant can ultimately be inserted into the pocket. For this reason, the same types of considerations that are used in the breast augmentation implant selection are employed in choosing an expander. Essentially, the base diameter of the desired breast is measured and an estimate is made of the medial and lateral soft tissue contribution to this measurement. By subtracting half of the medial and lateral pinch thickness, a starting width for the expander can be determined. It is my preference to choose a base diameter that slightly exceeds this measurement by up to a centimeter as it is much more preferable to have a larger pocket at the time of expander exchange for the implant than a pocket that is not wide enough. Selecting the height of the expander is dependent on surgeon preference. In some cases, it can be advantageous to use a full-height device to ensure that every last portion of the pocket is stretched to make room for the subsequent implant. Candidates for this strategy include those patients who present with a soft tissue envelope that is severely constricted in all directions. Alternatively, it can also be advantageous to use a mid-height device to focus expansion on a tight lower pole. This strategy will limit the magnitude of the deformity created during the expansion process and may be more applicable in those patients in whom the expander will remain in place for 6 months to a year or more.

At surgery, scoring of the overlying soft tissue framework of the breast proceeds as in implant placement and the expander is positioned such that the inferior base is located directly at the proposed level of the new inframammary fold. If the opposite breast is enlarged or ptotic, it is best to perform a primary mastopexy or a reduction as described previously along with placement of the expander. In this fashion, once filling of the expander begins, the opposite breast will provide a stable construct that can guide the adequacy of the expander inflation. Filling of the expander begins approximately 2 weeks after surgery

and proceeds as quickly as possible until the desired size and shape of the breast have been created. Because the expander is in the subcutaneous plane, it is very easy to find the fill valve using the magnetic valve finder and filling of the device generally proceeds without difficulty. The device is re-expanded every 2 weeks until the desired volume has been added. A period of 3–4 months is then allowed to pass to allow the soft tissues to settle completely and ensure that any residual edema has resolved.

At times it can be advantageous to plan a long-term expansion process, leaving the expander in place for a year or more. Candidates for this strategy include young girls in their mid- to late teens who present with a tuberous breast on one side and an immature and incompletely developed breast on the other. In such cases, initial reconstruction of the tuberous breast may provide short-term symmetry; however, once the opposite breast reaches full maturity and changes in the size, shape or volume of the breast occur, the symmetry may be lost and a revisionary procedure later in life may become necessary. It can be a better option to insert an expander once the deformity begins to result in a noticeable breast asymmetry and then simply keep the expander in place for up to several years, occasionally inflating the device as needed to keep up with the growth of the opposite breast. Once breast growth appears to have stabilized, the expander can be removed and replaced with an appropriately sized permanent implant (Figure 8.12).

At the time of expander removal and replacement with the permanent implant, any revisionary procedure required to obtain the best aesthetic result possible can and should be performed. In many instances, such maneuvers can include partial or complete capsulectomy, raising or lowering the inframammary fold, recontouring the lateral chest wall via liposuction, or redoing a mastopexy to create symmetry in the location of the NAC (Figure 8.13). It is for this reason that my personal approach utilizes two distinct devices each managed at a separate operative procedure. This is in contrast to the use of combination

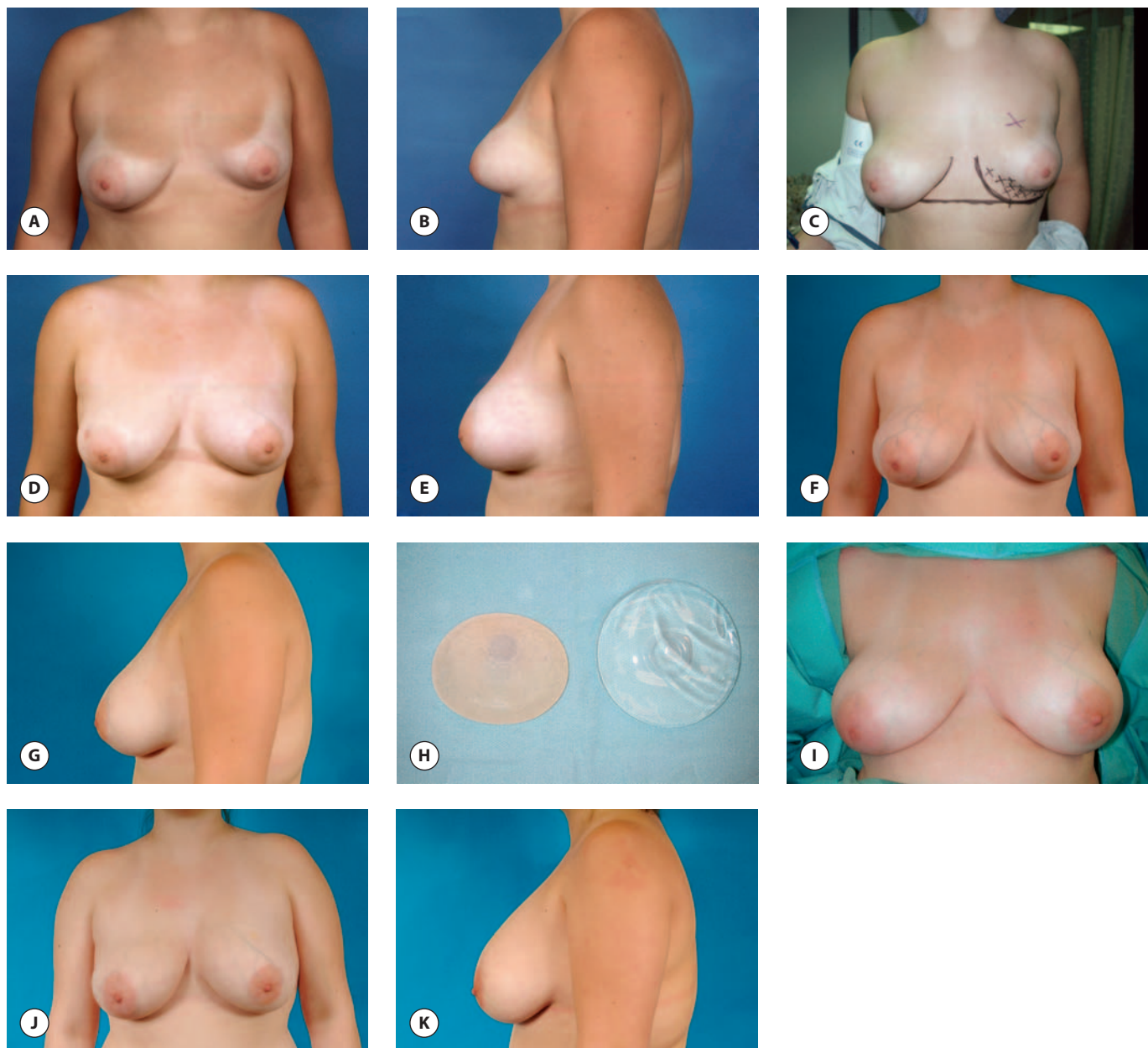


Figure 8.12 (A,B) Preoperative appearance of a 15-year-old girl with a mild tuberous breast deformity on the left in association with a marked asymmetry. (C) Preoperative marks in preparation for placement of a tissue expander on the left. The plan is to allow the device to be left in place for a period of several years until the size and shape of each breast has stabilized to a greater degree. (D,E) Six-month postoperative appearance after placement of a 12 cm wide tissue expander filled to 200 cc in the subglandular plane. Reasonable symmetry has been achieved, enough to allow the patient to wear clothing including bathing suits without feeling self-conscious about her appearance. (F,G) Three-year postoperative result demonstrating acceptable symmetry and a breast size and shape that

has remained stable over time. (H,I) At the age of 18, the expander was removed and replaced with a 400 cc moderate profile plus, smooth round silicone gel implant (H). The capsule was scored and released to allow the placement of a slightly larger device to correct the mild asymmetry that was present with the tissue expander. Immediately at the time of implant placement, the overall symmetry appears improved (I). (J,K) Appearance 1 year after replacement of the tissue expander with the permanent implant. Using the delayed, staged approach has allowed the surgical decision making to keep pace with the growth of the patient to optimize the overall quality of the final result.

expander/implant devices constructed of an internal saline bladder surrounded by an outer silicone gel envelope of varying thickness and volume. The inner bladder is connected to a remote valve via a silicone rubber tube that passes through the outer silicone gel layer. Once the device is inserted and subsequently inflated to the desired volume, the valve and the tubing can be removed from the device by pulling the tubing free

from a self-sealing sheath that passes through the implant. This procedure is performed under local anesthesia and involves a small incision located over the location of the remote valve. The advantage of this approach is that only one general anesthetic is required to complete the procedure as the valve removal is easily performed in the office. Also, only one device is required, which can help hold down costs for patients who do not qualify for

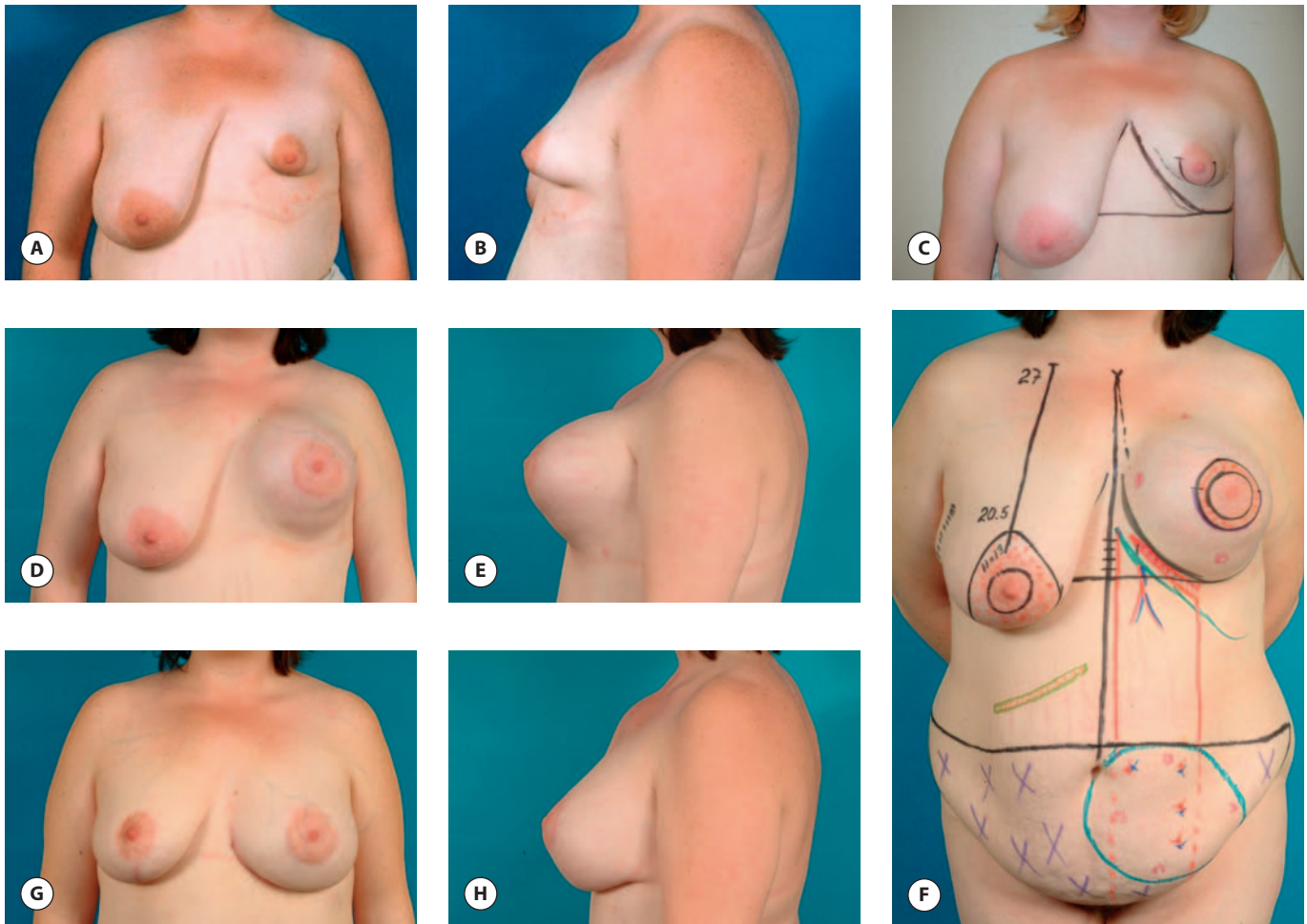


Figure 8.13 (A,B) Preoperative appearance of a 32-year-old woman with a fully involved tuberous breast deformity on the left in association with right-sided macromastia. Although the right breast seems fully developed, the inframammary fold is actually superiorly malpositioned and mildly constricted as evidenced by the slight convexity noted along the lower medial breast border. (C) Preoperative marks in preparation for first-stage placement of a tissue expander through a periareolar incision. (D,E) Postoperative appearance after the subglandular placement of an anatomically shaped tissue expander in the subglandular plane subsequently filled to 1120 cc. Aggressive parenchymal scoring was performed at the time of expander placement. (F) Preoperative marks in preparation for removal of the tissue expander and replacement of the deficient breast volume with a single pedicle completely de-epithelialized

TRAM flap along with an opposite right breast mastopexy using the SPAIR technique. The expansion process has prepared the soft tissue envelope of the left breast for the placement of a permanent implant. However, in this case, the patient desired eventually to undergo an abdominoplasty, therefore the TRAM flap technique was utilized to take advantage of the excess soft tissue in the lower abdomen that was destined for ultimate excision and thereby avoid the use of an implant. (G,H) Postoperative appearance 8 months after TRAM flap reconstruction on the left and right-sided mastopexy. In the interim, the left inframammary fold was elevated using an external abdominal advancement flap technique. The final result demonstrates a full and natural contour to the left breast that perhaps would not have been expected given the magnitude of the preoperative deformity.

insurance coverage. The disadvantage is that the dimensions of the expander/implant are fixed and, since the device by default also functions as the permanent implant, any design feature of the device regarding base diameter or projection that does not create the desired result cannot be changed. Also, strict utilization of the expander/implant 'one-stage' strategy eliminates the opportunity to revise the soft tissue envelope at the second-stage procedure and can prevent the surgeon from achieving the best result possible. Therefore, although some authors have been able to utilize such combination expander/implant devices to good effect, greater versatility is afforded when the surgeon has the freedom to alter the soft tissue dynamics at a second procedure where the expander is removed and a carefully chosen

permanent implant is inserted. In this fashion, strict control over all the variables that combine to determine the quality of the final result is maintained and the surgeon is not locked into the dimensions of the initial expander in terms of base diameter, shape, or projection.

No matter what the specifics of the expansion strategy may be, the basic design of the expansion approach remains sound and the opportunity to expand the soft tissue envelope over time can greatly enhance the ability of the surgeon to reshape the breast, reposition the inframammary fold and aesthetically reconstruct the size and shape of the resulting breast with a properly chosen permanent implant. By using this staged approach, consistent and aesthetic results can be obtained.

Summary

Correction of a patient with a tuberous breast deformity represents one of the most significant challenges that an aesthetic breast surgeon can face. However, by accurately analyzing the nature of the deformity and developing a surgical plan designed to address each element of the deformity in a such

a way that the technical maneuvers complement one another, excellent results can be obtained. There is perhaps no other instance in aesthetic breast surgery where the results, for both the patient and surgeon alike, can be more rewarding.

Management of Gynecomastia

Gynecomastia may be defined as enlargement of the male breast. However, from a surgical point of view, it may be more helpful to view the condition as a *persistent* enlargement of the breast as transient breast enlargement during puberty is actually a normal finding occurring in up to 65% of normally developing adolescent boys. It is this persistence that generally motivates patients to seek treatment as the enlarged breast can create a significant contour deformity when compared to the appearance of a normal male chest contour. From a therapy standpoint, there are three main presentations of gynecomastia that require slightly different approaches when it comes to designing an appropriate course of treatment.

Adolescent gynecomastia – As a consequence of the changing hormonal environment that occurs in the adolescent male, end organ responses in the character and size of the breast can occur. As a result, variable thickening and enlargement of the breast is commonly associated with early sexual development beginning as early as age 12. The likely cause of this end organ response is related to a change in the ratio of normal circulating hormones responsible for secondary sexual development. In the majority of cases, these changes are short lived and the breast simply regresses back to a more normal appearance over a time period of 1 to 2 years. However, in a small subset of patients, these changes can persist, resulting in an enlarged breast contour.

The hallmark finding in patients with adolescent gynecomastia is a firm, fibrous mass of tissue that develops directly under the areola (**Figure 9.1**). This mass can be variable in size and can herniate through the elastic areolar skin, resulting in a very obvious contour abnormality. In addition, it is not uncommon for a surrounding

fibrofatty stroma of varying volume to develop in concert with the subareolar mass. The magnitude of this fatty overgrowth is directly related to the body habitus of the patient with more obese patients tending to demonstrate a more dramatic increase in the size of the breast (**Figure 9.2**). Along with the general breast overgrowth can be noted an excess of skin to the point that actual ptosis of the breast mound can be noted (**Figure 9.3**). Finally, as a result of the enlarged subareolar breast bud along with the general increase in the volume of the breast, the diameter of the areola can increase significantly, all of which combines to create a decidedly abnormal breast contour for a young adolescent male (**Figure 9.4**).

It is interesting to postulate what relationship a fully developed case of gynecomastia may have with the tuberous breast deformity seen in adolescent girls. Both likely represent a situation where an isolated breast bud develops under the nipple–areola complex (NAC), resulting in herniation and widening of the areola. In females, if the surrounding fibrofatty stroma fails to develop normally, the usual peripheral contours of the breast and, most notably the inframammary fold, fail to form in a physiologic manner and the appearance is very similar to that of an adolescent male with gynecomastia. Of course, the aesthetic goal in females is then to create normal contours with added volume, while in males the goal is to remove the fibrofatty breast bud and decrease the volume of the breast.

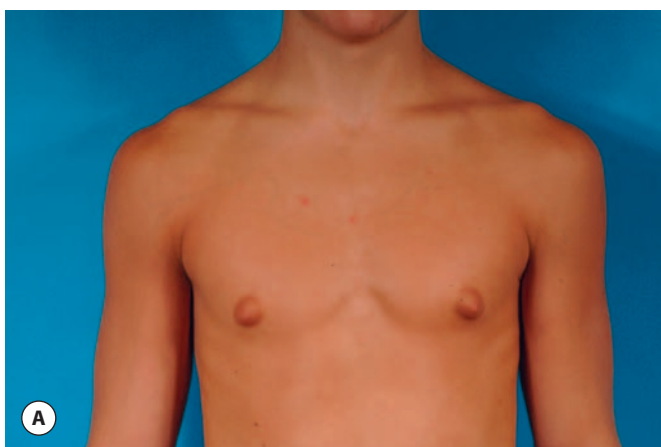
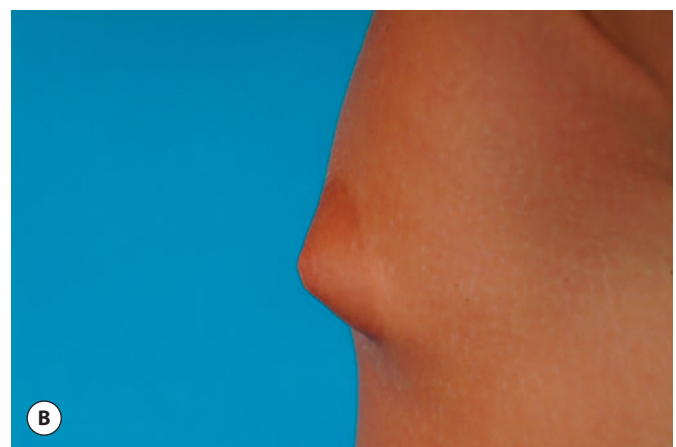


Figure 9.1 Adolescent gynecomastia very often presents as an isolated fibrous mass directly under the areola. This mass causes a variable



protrusion through the elastic areolar skin along with widening of the areolar diameter.

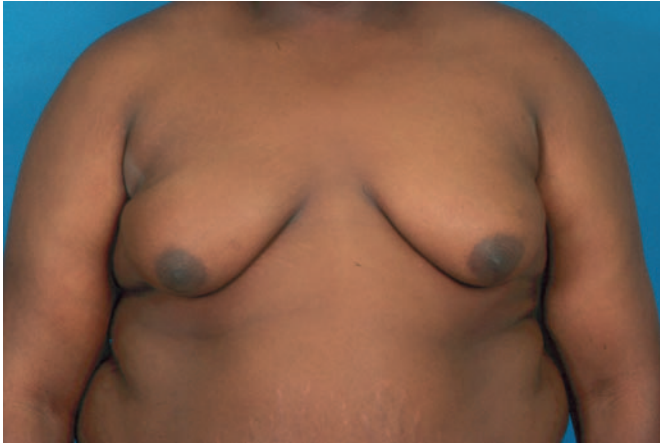

Figure 9.2 With increasing levels of obesity, the surrounding fibrofatty stroma can undergo significant hypertrophy leading to the formation of a prominent breast-like contour. In adolescent boys such as this, it is easy to understand the emotional trauma that can result from such a condition.

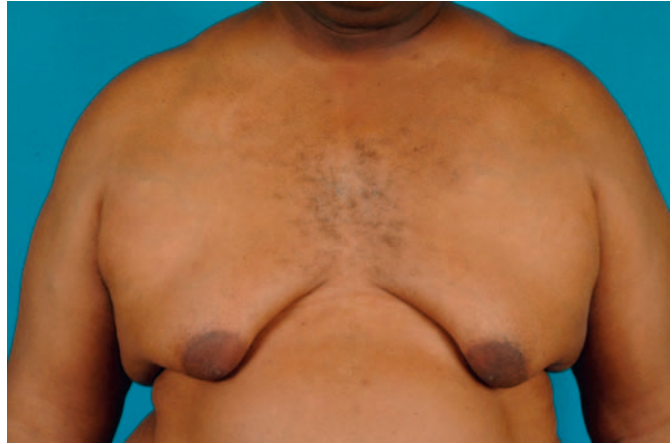

Figure 9.3 As the breast enlarges, the elastic skin envelope can exhibit varying degrees of ptosis. In severe cases, the magnitude of the deformity can be dramatic.

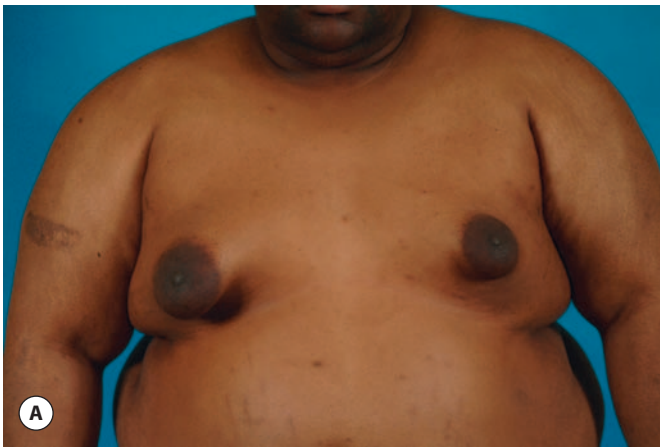
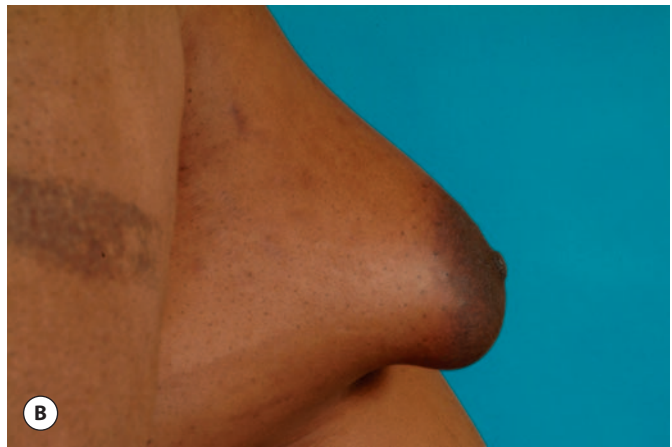
Figure 9.4 As the volume of the breast increases, the areolar diameter can widen, creating an overall look similar to that seen in adolescent girls with a



tuberous breast deformity.

Senescent gynecomastia – Alternatively, persistent gynecomastia can develop later in life, generally after the age of 50. Here the nature of the enlarged breast is slightly different as the fibrofatty component of the breast tends to be more predominant (Figure 9.5). Generally, the patient will experience a gradual enlargement of the breast that develops over the course of a year or more and this enlargement will often be tied to an overall gain in weight. A subareolar thickening may be noted but the enlargement of the breast is more diffuse in the older male and often there will be associated fatty deposition under the arm and higher up onto the chest wall toward the clavicle. Again, a change in the ratio of the sex hormones may be responsible for this change in body habitus with the natural decline in circulating levels of testosterone that is noted with advancing age being the likely etiologic factor. These patients generally seek treatment in an effort to restore a more normal overall male chest wall contour.

Pathologic gynecomastia – Gynecomastia occurring during the relative extremes of life, i.e. in teenage boys or middle to aged to older men, is not an unexpected finding as it can develop as a normal consequence of changing hormonal levels that can occur

at these times in life. Gynecomastia developing suddenly at any other time must be considered to be a pathologic finding until proven otherwise. An example of a case of pathologic gynecomastia would be the sudden development of a fibrous type of gynecomastia in an otherwise healthy 35-year-old man with no change in medication or drug history. In such a patient, a tumor that may be actively secreting sex hormone-like compounds must be suspected and an appropriate workup undertaken. Other factors that might arouse suspicion for pathologic gynecomastia include rapid onset, pain, bilateral involvement and tissue overgrowth that is predominantly fibrous and located in the subareolar area.

One specific variant of pathologic gynecomastia is that which occurs as a result of exogenous hormone administration. Gynecomastia has been noted to develop as a result of recreational drug use with marijuana being widely recognized as a common cause of the condition. Also, young males involved in the sport of bodybuilding will sometimes develop a very discrete and fibrous subareolar type of gynecomastia secondary to the use of either injectable or oral testosterone or testosterone precursor-like drugs, along with a whole host of other anabolic steroid type

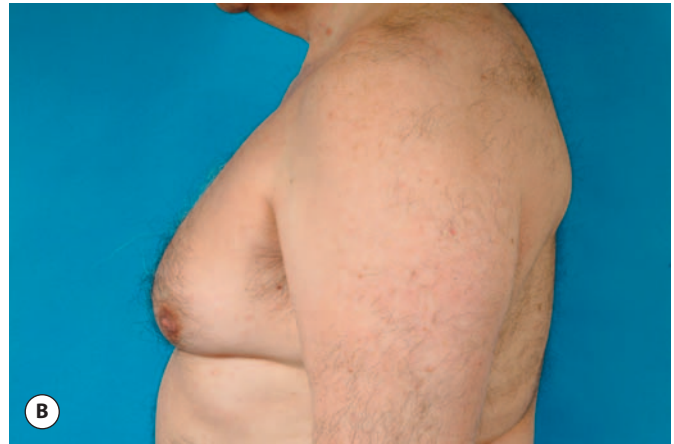
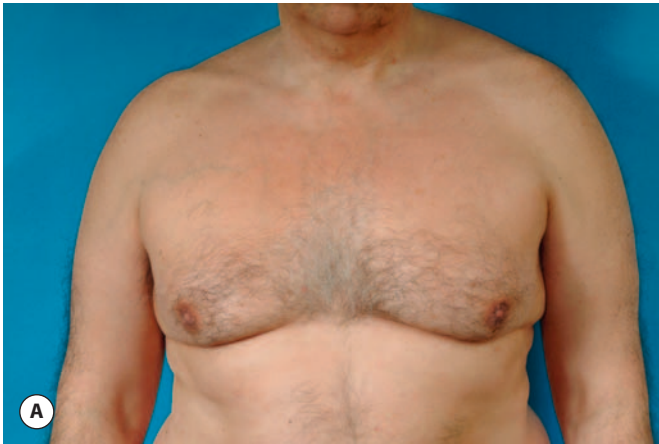
Figure 9.5 (A,B) Senescent gynecomastia in a 60-year-old man. With advancing age, the general size of the breast has increased to the point where it has become uncomfortable for the patient to wear even casual clothing such as golf shirts without being conscious of the prominent

breast contour. In this setting, the etiology for the breast enlargement is hypertrophy of the surrounding fibrofatty stroma as opposed to a prominent subareolar breast bud. Treatment is therefore directed more at a general volume reduction of the breast as opposed to direct subareolar excision.

substances. Screening for any history of drug use becomes particularly important in these types of patients in order to clarify the etiology of the condition and, as well, to develop an appropriately targeted treatment plan. Specifically, it is highly advisable that such patients discontinue all exogenous drug use prior to undergoing any form of surgical treatment.

Workup

History

The workup for a patient with gynecomastia involves documenting the history of the condition including making note of the age of onset, the time course and progression of breast growth, any tendency toward spontaneous involution and the presence of pain in the breast. Any changes in the weight of the patient are noted and what effect these weight changes had on the size of the breast is documented. The presence of other types of systemic symptoms including weight loss, night sweats, loss of appetite and general malaise are recorded as they may be signs of a pathologic etiology and either a tumor or drug use must be suspected. In addition, any changes in vision or olfaction are noted as these may be indicative of a pituitary tumor. A medication history is taken that includes specific questioning regarding the use of recreational drugs as well as anabolic steroids.

Examination

The character of the breast is documented via palpation to assess for the presence of any type of discrete mass. Also, some estimation as to the consistency and size of the fibrous subareolar component is made as compared to the surrounding fibrofatty stroma. The degree of extension of the firm subareolar disc of tissue is determined and any degree of areolar herniation or widening is noted. An estimation is made as to how much of the breast contour is due to fatty accumulation and where this fatty accumulation extends to in relation to the breast. Specifically, any extension of fatty accumulation under the arm or up onto the chest wall must be noted in order to guide appropriate recontouring at

the time of surgery to create a smooth and even chest contour. Additionally, any asymmetry in the size or shape of the breast is documented in order to direct appropriate treatment at the time of surgery. Finally, a testicular exam is performed to rule out the presence of a mass and a possible hormonally active testicular tumor.

Laboratory Tests

Should there be any question as to the etiology of a patient with gynecomastia, referral to an endocrinologist should be considered. Subsequent evaluation may include blood testing for circulating hormone levels related to the gonadal-pituitary axis as well as the thyroid. Routine blood chemistries including liver function studies are indicated as well. Magnetic resonance imaging of the head can be performed to evaluate for the presence of a pituitary tumor. Many surgeons reserve such evaluations for cases of suspected pathologic gynecomastia, although it must be recognized that it is never inappropriate to refer a patient for endocrine evaluation.

Indications for Treatment

Although pain may occasionally be noted in patients with gynecomastia, it is most certainly the altered chest contour along with the emotional sequelae of the condition that motivates nearly all patients to seek treatment. This is particularly true in adolescent males. It must be recognized that the teenage years are a vitally important time period during which significant social and emotional growth occurs. In these patients, even modest cases of gynecomastia can result in social withdrawal and avoidance of any situation that will require the patient to take his shirt off. As a result, important social activities including participation on athletic teams, swimming and even casual interaction with other peers are avoided secondary to the embarrassment the patient feels about his appearance. Once gynecomastia is recognized, it is reasonable to delay definitive surgical excision for up to 2 years or more, as some patients will spontaneously regress on their own as their internal hormonal environment stabilizes. Typically, this will occur by the age of 15. However, should any

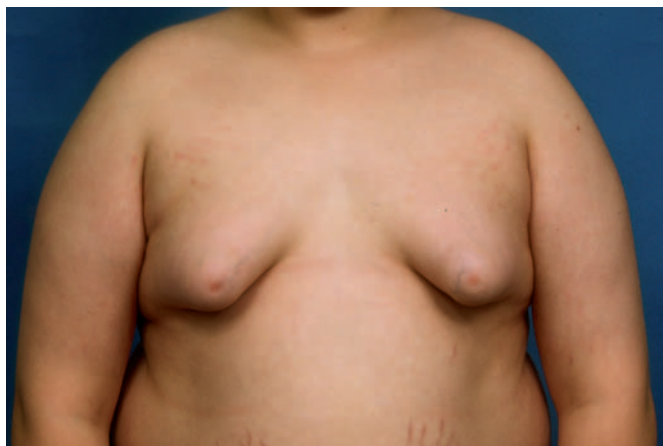

Figure 9.6 In the obese, the prominence of the breast contour can be striking even taking into account the generalized elevation in the body mass index. Restoration of such patients back to a normal male chest contour can assist greatly in allowing normal social development to take place unencumbered with feelings of deformity.

degree of social withdrawal become noticeable as a result of the condition, it is entirely reasonable and recommended to proceed with surgical treatment.

Special mention must be made concerning those patients who present with gynecomastia in association with significant obesity. Certainly, in these patients, the major cause of the enlarged breast contour is the excess general fatty accumulation. Although some stromal overgrowth in the subareolar region may be present, it is generally overwhelmed by the significant amount of fat present in the breast. This combination can often lead to surprising levels of breast development that can result in significant breast ptosis (Figure 9.6). Therefore, while any first line therapy would best be directed primarily at weight loss, the adverse effect such breast development can have on a patient who is likely already struggling with body image issues can be quite damaging. For this reason, it is very reasonable and even advisable to proceed with surgical correction of gynecomastia in the obese. Normalizing the contour of the chest wall may well allow the patient to make appropriate lifestyle changes later in life as he matures that will lead to a healthier body composition.

In older men, the enlargement of the breast has typically occurred over a longer period of time in association with a progressive weight gain. As such, the composition of the breast is largely fatty in nature. In these cases, there is generally less of an emotional overtone to the condition and, as a result, less urgency in arriving at a surgical solution. If lifestyle changes are either unsuccessful or simply declined by the patient, appropriate treatment is often directed at the entire anterior and lateral chest wall in an effort to recontour the whole of the upper anterior torso.

Surgical Technique – General Concepts

Treatment of gynecomastia can be thought of as having two specific aims: reducing the volume of the breast and retaioring the redundant skin envelope as needed.

These operative goals must be satisfied using incisions that are strategically located so that they not only afford adequate exposure to allow accurate glandular resection to be performed, but also end up in aesthetically advantageous locations. This is a very

important part of the treatment plan as it must be remembered that scar remains a significant concern for these patients and it is unacceptable to trade the contour deformity for an unsightly or obvious scar on the breast.

Volume Reduction

Reducing the volume of the breast is a key element of any surgical technique designed to treat gynecomastia. With this in mind, there are three main techniques for volume reduction that are generally employed: direct excision, liposuction alone or a combination approach.

Direct excision When gynecomastia presents as an isolated fibrous mass directly under the areola, the most expedient surgical treatment is direct excision. Patients with this presentation are very commonly trim and well-developed adolescent boys who are often times very involved in athletics and have low body fat levels. As such, there is no significant surrounding fibrofatty stroma in the periphery of the breast, therefore, the subareolar mass creates a very obvious contour deformity. It is not at all uncommon for this condition to present asymmetrically with one side being more involved than the other.

The procedure can be performed under local anesthesia with intravenous sedation or, conversely, general anesthesia can be used. The proposed incision as well as the surrounding breast flaps are infiltrated with a dilute solution of lidocaine with epinephrine to aid in hemostasis and, as well, allow clearer identification of tissue planes and, in particular, the plane between the fibrous breast bud and the overlying fat associated with the breast flaps. An incision is made along the lower border of the areola just at the junction of the pigmented areolar skin with the non-pigmented skin of the lower breast. Typically, this incision heals in an imperceptible fashion and is well tolerated by most patients. The incision extends along the entire lower half of the areolar border to allow adequate exposure for removal of the fibrous subareolar tissue. Around the inferior lower half of the breast, the fibrous button of tissue is dissected free from the surrounding breast flaps until the limits of the fibrous mass that were marked preoperatively are reached. Every effort is made to leave behind any fat that may be associated with the flaps as this fat can soften the resulting breast contour and help guard against the creation of a central depression after removal of the fibrous component. Centrally, the fibrous bud is then sharply transected such that approximately 5–10mm of evenly layered fibrous tissue remains attached to the underside of the areola. This is a sculpting maneuver designed to prevent over thinning of the areola resulting in a central depression. It must be smoothly performed and may extend slightly past the margins of the areola on all sides. It is generally necessary to do this because there is no fat directly under the areola and, if the subareolar breast bud is removed at the dermal level, a step off will be created at the junction of the areola with the surrounding thicker breast flaps creating a postoperative contour deformity. Once the fibrous mass has been smoothly dissected free from the areola, dissection is resumed superiorly again leaving behind any fat that might remain on the breast flap. Finally, the fibrous mass is freed from any attachments that remain to the pectoralis major muscle and removed. If any irregularities in the contour of the breast persist, scissor dissection can be used further to thin the peripheral flaps to create a smooth contour. With removal of the subareolar tissue, it can commonly be observed that the areola retracts to a

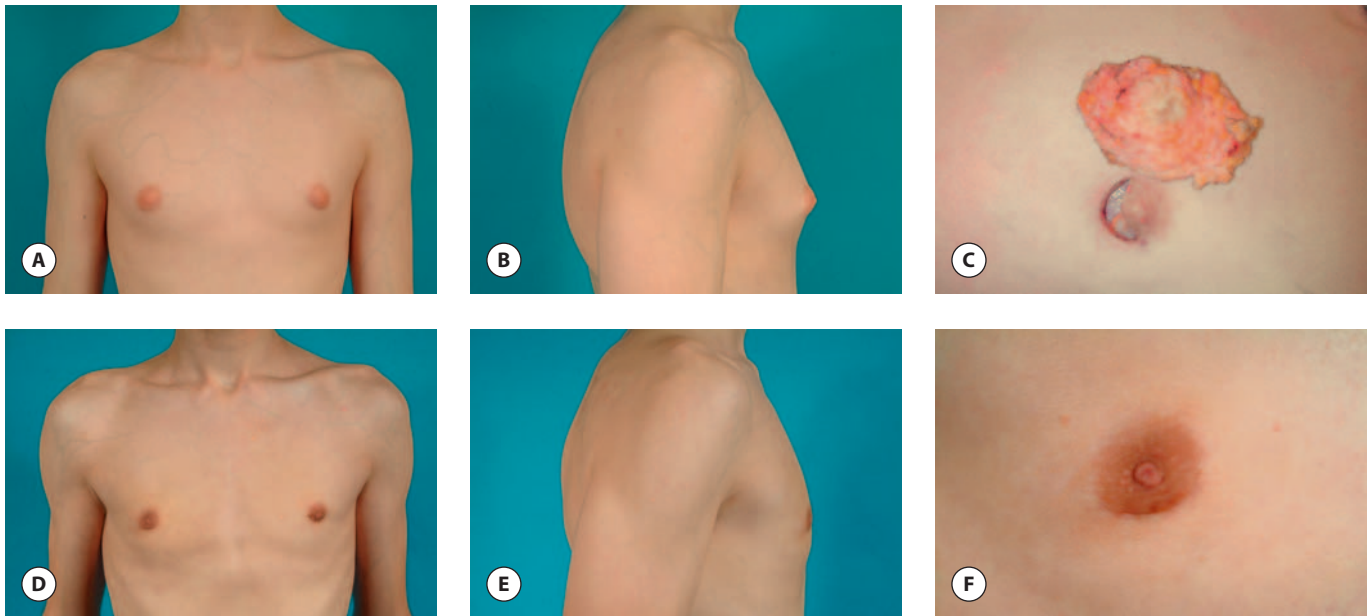


Figure 9.7 (A,B) Preoperative appearance of a trim 16-year-old male who presents with bilateral adolescent gynecomastia of 2 years' duration. The breast enlargement consists of a firm subareolar fibrous mass with little surrounding fibrofatty accumulation. The right breast is slightly more involved than the left and there is mild dilation of the areolar diameter bilaterally. (C) At surgery, a well-demarcated subareolar fibrous mass was dissected free from the surrounding breast flaps using an inferiorly located periareolar incision. A thin layer of fibrous material was left on the underside of the areola to guard against the development of a central

contour deformity. After removal of the fibrous material, smooth thin flaps can be noted along with an immediate reduction in the diameter of the areola. (D–F) Postoperative appearance at 6 weeks reveals a smooth chest wall that now reveals muscular contours appropriate for the age of the patient. The scar has healed imperceptibly along the inferior border of the areola therefore there is no appreciable evidence of any operation on the breast. This aspect of the procedure offers significant advantage in this impressionable and very image conscious patient population.

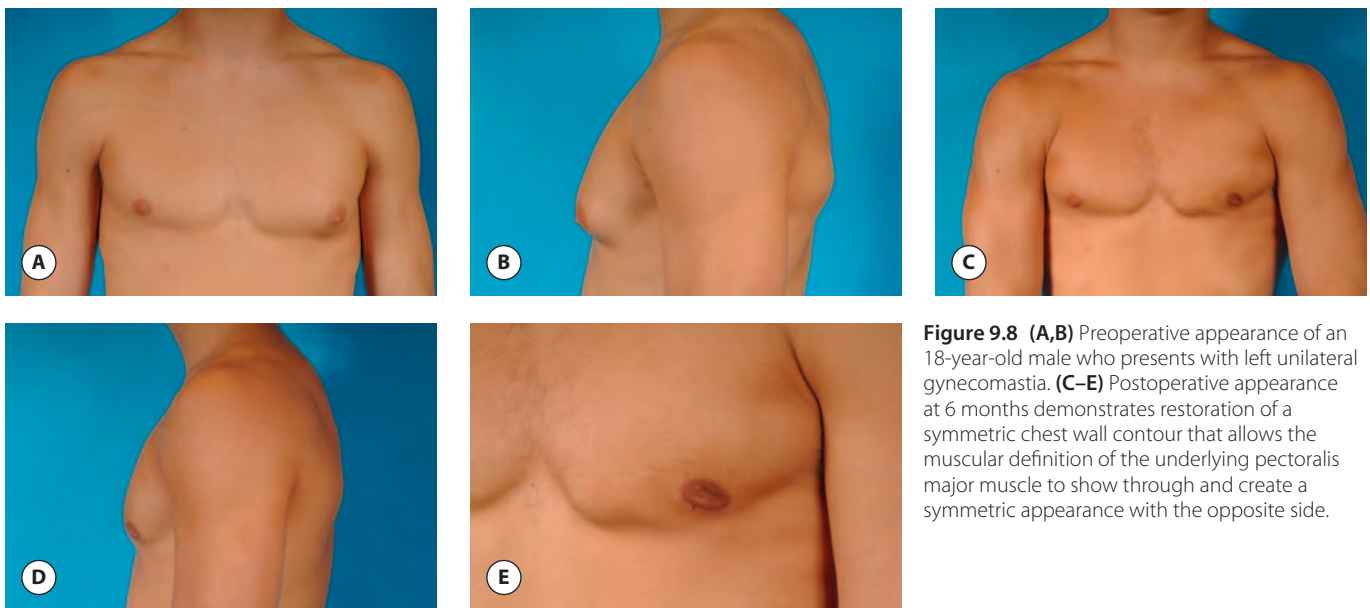


Figure 9.8 (A,B) Preoperative appearance of an 18-year-old male who presents with left unilateral gynecomastia. (C–E) Postoperative appearance at 6 months demonstrates restoration of a symmetric chest wall contour that allows the muscular definition of the underlying pectoralis major muscle to show through and create a symmetric appearance with the opposite side.

more normal diameter now that the mass effect of the underlying breast bud has been removed. Hemostasis is assured and the wound closed in layers with interrupted inverted 4-0 absorbable monofilament sutures followed by a running subcuticular of the same material. At this point, the contour of the breast should be smooth with no high points or depressions. Dermabond is applied to the skin incision followed by an Opsite dressing. A support vest

is worn for several weeks to assist in smoothly and gently compressing the breast flaps against the chest wall. Suture ends are clipped at 1 week and full return to activity is allowed at 4–6 weeks. With careful attention to dissection planes and, in particular, accurate and even thinning of the subareolar fibrous layer, complete correction can be achieved on a consistent and reliable basis (Figures 9.7, 9.8).

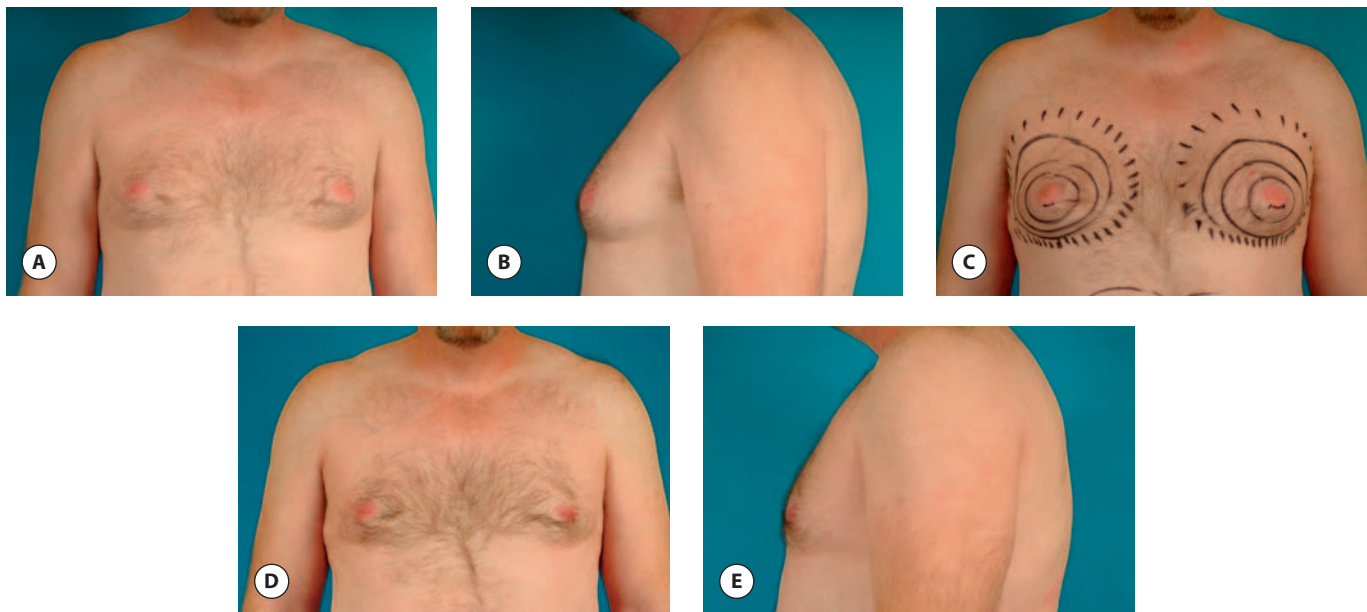

Figure 9.9 (A,B) Preoperative appearance of a 43-year-old man who presents with senescent gynecomastia. Due to the fibrofatty nature of the breast enlargement, simple liposuction can be used to manage the volume excess. (C) Preoperative marks in preparation for liposuction recontouring

through a small stab incision placed at the lower border of the areola. (D,E) Ten-month postoperative appearance demonstrating a smooth chest wall contour with no evidence of any fullness in the subareolar area. The scar is well hidden at the lower border of the areola.

Liposuction When gynecomastia presents as largely a fibrofatty accumulation of tissue, liposuction contouring can be very effectively used to restore a normal chest wall contour. Typically, these types of patients will be either younger obese adolescents or older men who present with senescent gynecomastia. Although a subareolar accumulation of fibrous tissue may be present, it tends to be infiltrated by enough fat that the liposuction cannula can penetrate it to reduce the projection in the subareolar area and create a normal appearing chest wall.

As noted with direct excision, the procedure can be performed either under local tumescent anesthesia with intravenous sedation or, conversely, under general anesthesia. Although there are many options for incision placement, it is my preference once again to utilize the junction of the pigmented areolar skin with the non-pigmented chest wall skin as a camouflage that hides the subsequent scar very well. Conversely, additional incisions can be made anywhere along the inframammary fold, or laterally along the chest wall. These incisions can be useful in thinning the central quadrant of the breast due to the fact that a better mechanical advantage is afforded to the passage of the cannula from an area remote to the area to be treated. Once incision placement has been finalized, small stab incisions are made and tumescent fluid is added to the breast. It is helpful to mark this area preoperatively to ensure that the removal of fat is feathered appropriately with an eye toward creating smooth contours under the arm, superiorly along the upper chest and inferiorly below the fold. A usual tumescent fluid mixture is utilized consisting of 40–60cc of 1% lidocaine with a 1:100000 epinephrine concentration added to one liter of normal saline. Typically, one liter of fluid is added to each breast or until the consistency of the tumesced tissues becomes firm. Then, using a 3–4mm cannula, standard liposuction is performed evenly removing tissue from the area that was marked preoperatively. Particular attention is directed in the subareolar area where external pinching compression with the fingers

of the opposite hand can be used to help drive the dense fat interspersed within the subareolar fibrous network into the tip of the cannula. This can help adequately debulk this area and ensure that a residual subareolar bulge will not be present postoperatively. In difficult cases, it can be advantageous to approach the breast from two different directions, to maximize the removal of fat in an even and controlled fashion. Note is made of the amount of tumescent fluid instilled and the amount of liposuction aspirate removed from each side to ensure symmetry. Each incision is closed in a standard fashion and dressed with Dermabond and Opsite. A support vest is worn for 2 weeks and return to full activity is allowed at 4–6 weeks (Figure 9.9).

It is in the patient with gynecomastia that the newer techniques for liposuction have perhaps the greatest applicability. Due to the fibrous consistency of not only the subareolar breast bud but also the surrounding fibrofatty stroma, passing the liposuction cannula through the tissues can require considerable effort. However, with power assisted liposuction that utilizes an oscillating motion to the tip of the cannula, or with ultrasound assisted liposuction, passage of the cannula through the tissues can be performed with much less effort. As a result, a more controlled and even removal of fat can be accomplished with less risk for the creation of a contour defect.

Combination approach Typically, most gynecomastia patients will present with a firm subareolar fibrous breast bud in combination with a peripherally located supporting fibrofatty stroma. To recontour both the breast and the chest wall appropriately, it is necessary to address each of these anatomic features. A common

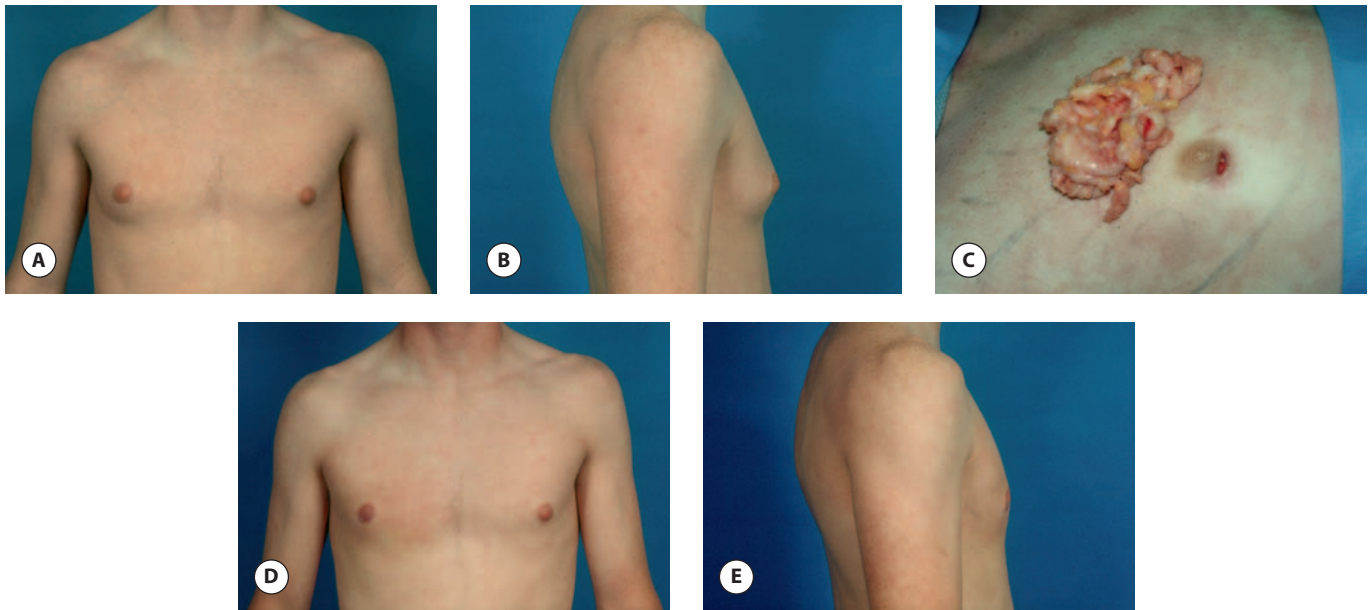

Figure 9.10 (A,B) Preoperative appearance of a 16-year-old male with bilateral gynecomastia. There is a small peripheral fibrofatty component that will require recontouring. (C) After liposuction recontouring of the peripheral margins of the breast, the central breast bud is removed in

strands until a smooth subareolar contour has been created. The resected fibrous tissue is shown just above the small periareolar incision. (D,E) One-week postoperative appearance demonstrating a smooth breast contour with an undetectable periareolar scar.

error is to rely simply on liposuction to recontour the breast and leave the subareolar fibrous component intact. If the fibrous portion is of sufficient size, it will cause a persistent areolar protrusion that can become noticeable once the swelling associated with the procedure resolves and this persistent contour deformity can be a source of patient dissatisfaction.

The operative planning and execution proceed quite simply as described. Initially, the breast is tumesced through stab incisions located around the areola or peripherally through the fold or lateral chest wall. Liposuction is used to definitively recontour the peripheral margins of the breast up to the area centrally where the fibrous component is located. Every effort is made to honeycomb through the dense subareolar area as much as possible to remove any fat that may be dispersed within. Once the peripheral margins have been appropriately treated and no further fat can be easily removed from the subareolar area, the mass effect of this remaining fibrous portion must be assessed, not only visually but also via palpation. If any suggestion of a mass effect is noted under the areola, it is highly recommended that the remaining fibrous tissue be thinned to prevent a persistent contour deformity from developing. While it is possible to open up the inferior portion of the areola as described previously to allow direct removal of the fibrous component, it is also possible to use a scar limiting approach called the ‘pull through’ technique. Here, a small 1 cm incision is made at the junction of the inferior areola with the chest wall skin in a way that exposes the glistening white fibrous component underneath. By grasping this tissue with a heavy clamp, it can be pulled through the incision and debrided until the desired contour correction has been achieved. This maneuver is facilitated by the previously performed liposuction as the honeycomb effect created by the passage of the cannula through the fibrous mass assists in breaking up the architectural integrity of the mass, allowing it to be pulled out in strands. Debridement is continued until a smooth subareolar contour has been obtained (Figures 9.10, 9.11). It is

also possible to approach the fibrous breast bud from a remote incision location laterally or inferiorly along the inframammary fold. Using an incision located away from the area of the areola can at times assist in more smoothly contouring the subareolar area than when the incision is located at the areolar junction (Figure 9.12). Whatever approach is used, the pull through technique offers advantage not only in limiting the scar, but also has been quite useful in preventing inadvertent over-resection in the subareolar area with the creation of the classic ‘saucer’ deformity. It is a very useful approach in treating patients who require a combination procedure.

Skin Retailoring

As a general rule, most patients who undergo treatment for gynecomastia will not require any reduction at all in the remaining skin envelope of the breast as the propensity of the breast and chest wall skin to retract is significant. It is only in the minority of patients that this retraction is insufficient to create a normal chest wall contour. It is for this reason that many surgeons are reluctant to proceed with a primary skin envelope reduction at the same time that the volume is reduced and instead apply a staged strategy to allow the skin retraction to proceed and then later reassess the need for skin envelope reduction (Figure 9.13). Using this strategy, an aesthetic result can very often be achieved using a less aggressive skin envelope reducing technique with fewer scars than was initially thought. This staged approach is recommended for patients who present with mild skin redundancy as the reduction in scar burden that occurs when no skin envelope reducing procedure is required is a very significant advantage.

In those patients who present with extreme skin laxity, skin with poor elasticity or in those patients who present with a redundant skin envelope after primary volume reduction, a skin reducing procedure is indicated. The operative planning for

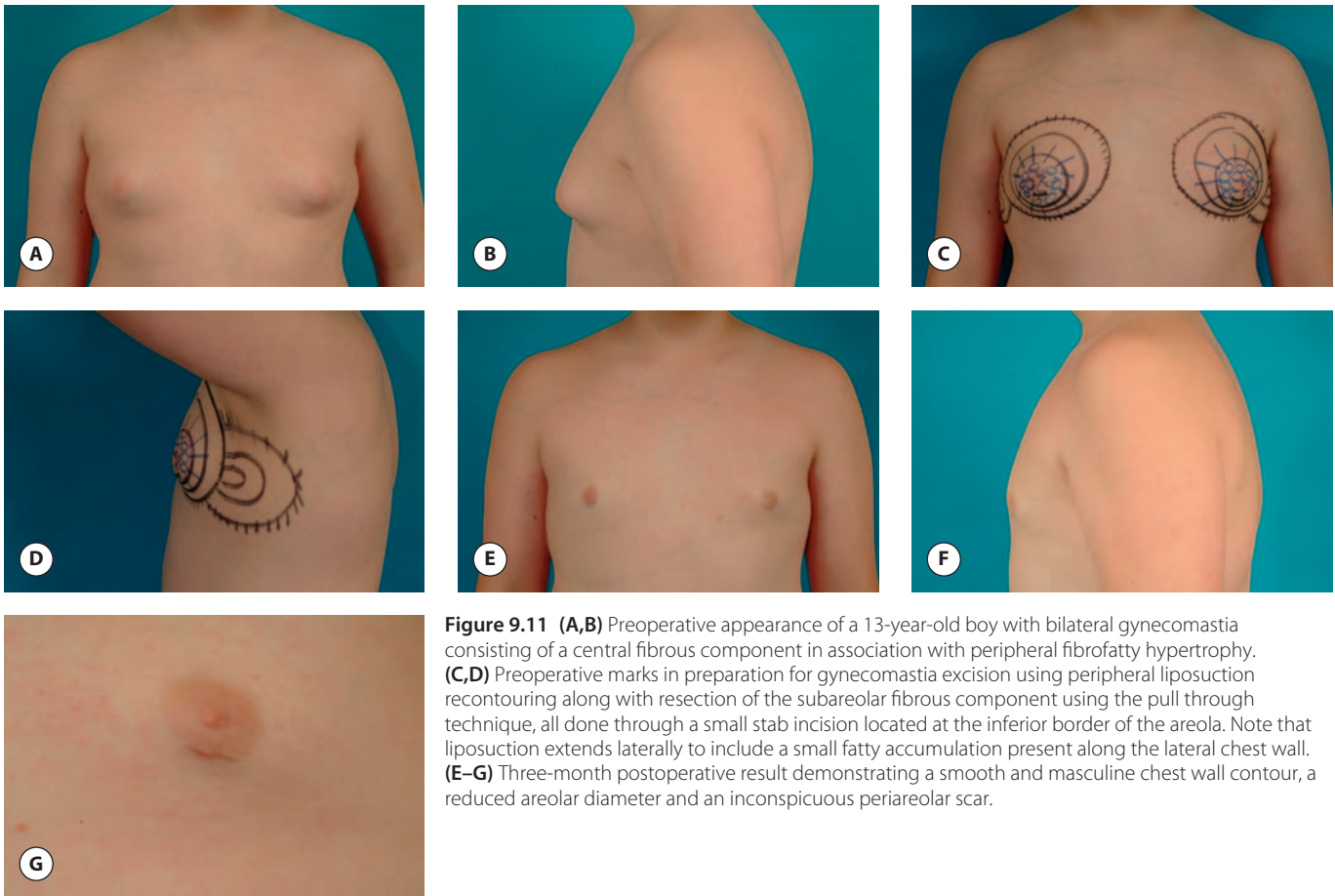


Figure 9.11 (A,B) Preoperative appearance of a 13-year-old boy with bilateral gynecomastia consisting of a central fibrous component in association with peripheral fibrofatty hypertrophy. (C,D) Preoperative marks in preparation for gynecomastia excision using peripheral liposuction recontouring along with resection of the subareolar fibrous component using the pull through technique, all done through a small stab incision located at the inferior border of the areola. Note that liposuction extends laterally to include a small fatty accumulation present along the lateral chest wall. (E-G) Three-month postoperative result demonstrating a smooth and masculine chest wall contour, a reduced areolar diameter and an inconspicuous periareolar scar.

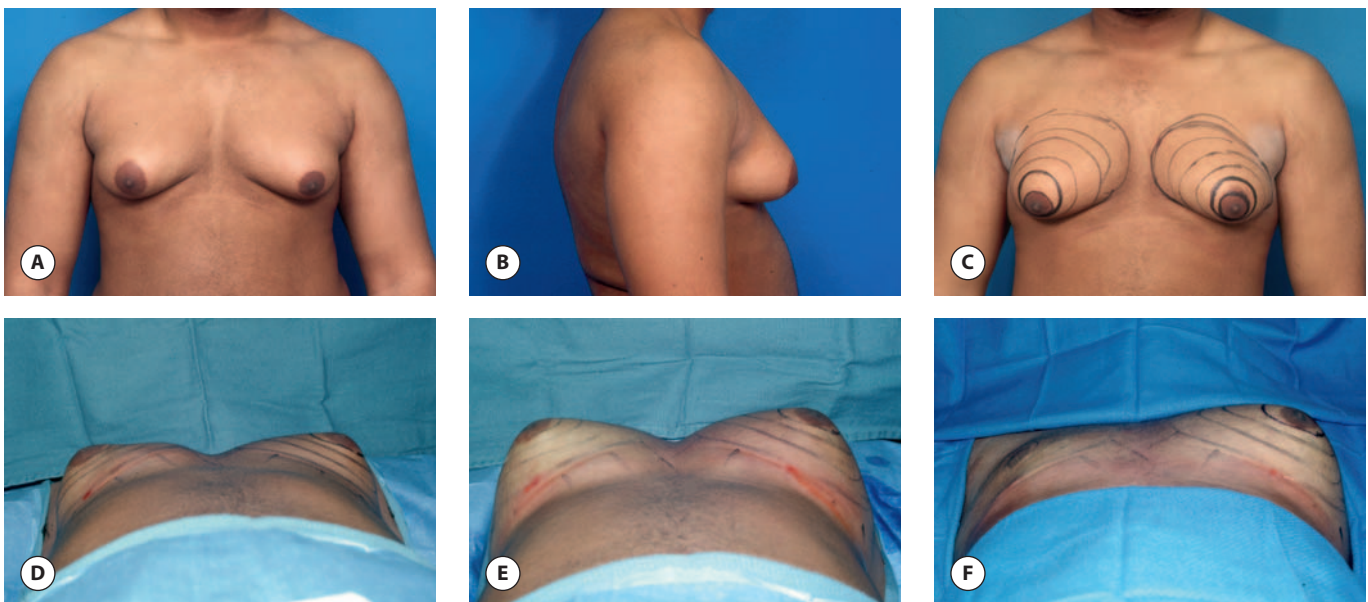


Figure 9.12 (A,B) Preoperative appearance of a 23-year-old man with bilateral gynecomastia consisting of an excessive breast volume, an expanded skin envelope and an enlarged areolar diameter. (C) Preoperative marks in preparation for gynecomastia excision using peripheral liposuction recontouring along with resection of the subareolar fibrous component using the pull through technique. The expanded skin envelope will be allowed to contract and simply re-drape around the remaining soft tissue left over after resection of the excessive parenchyma and fat. Should the

skin envelope appear to be excessively redundant, a proposed periareolar skin resection is diagrammed if needed. (D) In the supine position, the excessive volume of the breast becomes evident when viewed from below. (E) Same view of the breasts after each side has been expanded with approximately one liter of tumescent fluid. (F) Appearance of the right breast after the completion of liposuction. Note that a small subareolar fibrous breast bud remains after removal of the surrounding fat.

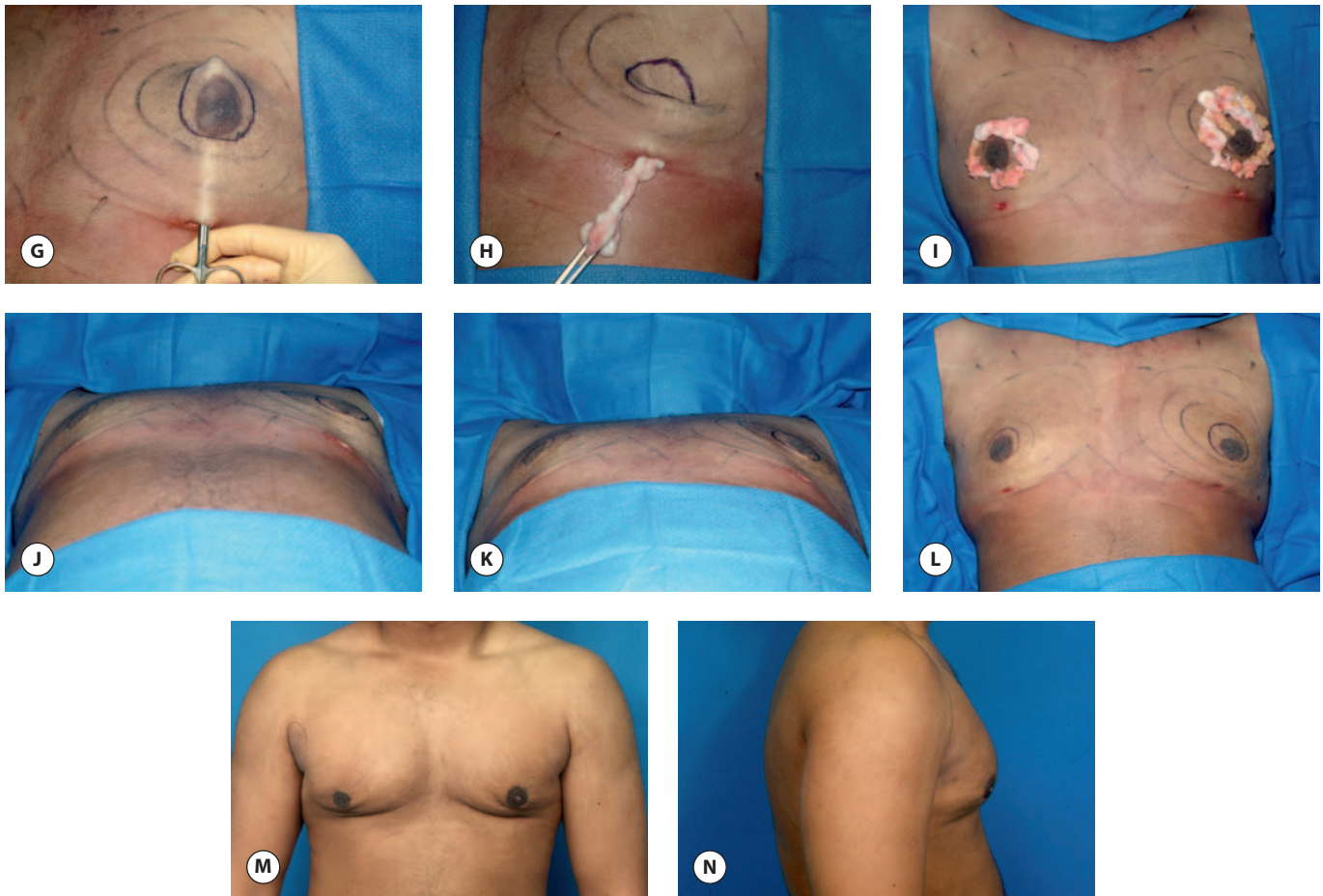


Figure 9.12 (Continued) (G) Once the excess fat has been removed, the subareolar breast bud is excised using the pull through technique. Utilizing a small stab incision placed at the inframammary fold, a tunneling technique is used to grasp the strands of fibrous tissue left over after the area has been perforated with multiple passes of the liposuction cannula. (H) The strands are pulled out in segments until the subareolar area has been adequately recontoured. (I) Appearance of the multiple strands of parenchyma removed from under each areola. (J) Before the subareolar area has been recontoured with the pull through technique, a small residual bulge is

noted under each areola. (K) After resection of the breast bud from each side, the chest wall contour is noted to be completely flat. (L) Immediate postoperative appearance after the completion of the procedure. The skin envelope appears to lay flat against the chest wall therefore no additional periareolar skin excision is performed. (M,N) Early postoperative result demonstrating a normal male chest wall contour after re-draping of the skin envelope and a reduction in the diameter of the areola. The small stab incision remains well hidden in the inframammary fold.

these patients proceeds in a fashion very similar to the approach used for women seeking mastopexy with the major goals of the procedure being the removal of the excess skin, lifting of the NAC position, reshaping of the breast and chest wall contour and the creation of the least amount of cutaneous scar possible.

Direct local resection In many patients, the lateral soft tissues can become redundant after removal of sufficient amounts of fat and parenchyma, particularly in the area just lateral to the margin of the pectoralis major muscle. The resulting folds that form in the lower lateral portion of the chest wall can be a source of patient dissatisfaction. This area is very amenable to simple excision to remove the redundant skin and tighten the lateral chest contour, all at the expense of a very well-camouflaged scar. Managing the skin envelope in this fashion can greatly improve the results obtained after volume reduction of the breast.

Periareolar pattern The periareolar pattern is indicated in those patients who will require a lifting of the position of the NAC,

a small reduction in the skin envelope, or both. The pattern is applied as in any mastopexy with the top of the periareolar incision planned to extend no more than 2–3 cm above the inframammary fold as, in a male, the position of the NAC is naturally located slightly lower than it is in a female. The remainder of the pattern is drawn in a circular pattern around the areola, removing as much skin as necessary to tighten the skin envelope and create a smooth chest wall contour. Note that the usual practice used in females of limiting the amount of skin removed medially and laterally is suspended as nearly all of the breast volume will be removed and no accommodation is needed for creating an aesthetic breast shape. At the time of surgery, the incision in the areola is drawn in a circular fashion with the areola under stretch at a maximum diameter of 3 cm, a measurement much less than that commonly used in women. In primary cases of skin envelope reduction, the lower portion of the periareolar incision can be used to access the breast to allow excision of the fibrous component to be performed as needed. Once completed, the intervening skin is de-epithelialized and the resulting

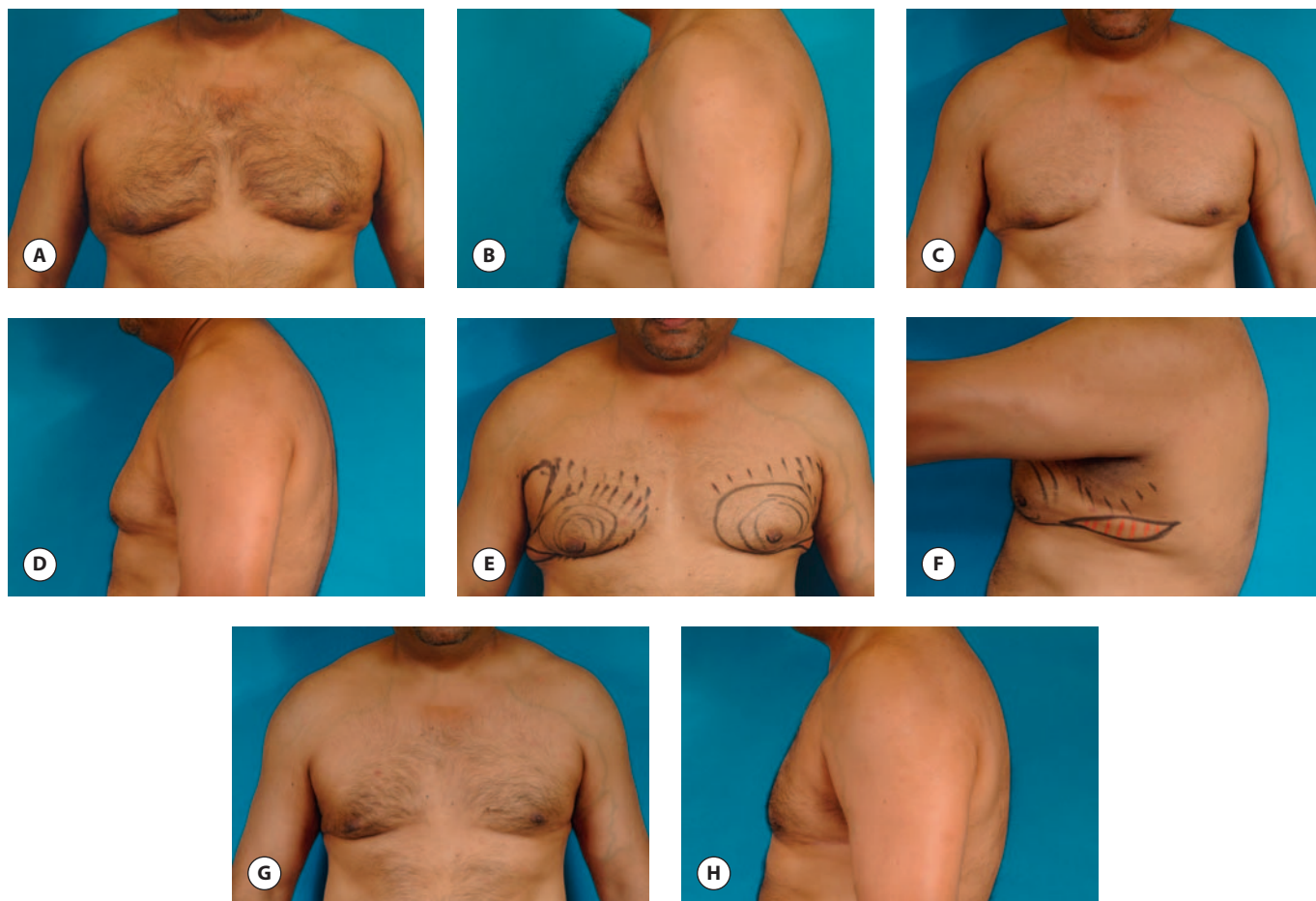


Figure 9.13 (A,B) Preoperative appearance of a 48-year-old male with bilateral senescent gynecomastia associated with weight gain. (C,D) Two-year postoperative result after liposuction treatment alone. There remains a small element of breast enlargement and the skin envelope is redundant along the lateral chest wall, creating a small fold. (E,F) Preoperative marks

in preparation for repeat liposuction along with resection of the skin fold along the lateral chest wall. (G,H) Two-month postoperative result demonstrating a smooth and contoured chest wall with correction of the lateral skin redundancy.

defect is managed with a periareolar purse string suture. It is my practice to use the interlocking Gore-Tex technique to limit the amount of postoperative areolar spreading that occurs. The dermis of the periareolar defect is not divided as it is in traditional mastopexy technique in females because the subareolar area is typically thinned significantly in males and dividing the dermis could cause vascular embarrassment to the NAC with possible ischemia and necrosis being the result. In cases of delayed periareolar skin envelope reduction, the dermis can be divided and a dermal shelf created as is done in standard periareolar purse string technique due to the fact that revascularization of the supporting tissues under the NAC has occurred and the potential for creating ischemia by dividing the dermis is significantly reduced. By dividing the dermis, less stress is placed on the periareolar closure due to less tissue bunching and the tendency for the areolar diameter to spread postoperatively is reduced. In cases of modest skin excess, the periareolar technique can allow a contoured chest wall to be created with only a minimum of scar that tends to be well accepted by many patients. Should the patient have any tendency toward hair growth in the chest area, a significant camouflage effect can be the result, making the procedure all the more acceptable (Figure 9.14).

Circumvertical pattern While the periareolar approach can be quite useful in elevating the position of the NAC and mildly reducing the skin envelope, it does become somewhat limited as an effective skin envelope reducing technique in patients with a pronounced skin excess. Typically, such patients will not only require reduction of the skin envelope in the vertical direction, but will also need reduction in the horizontal direction. This narrowing of the base diameter of the skin envelope is often required to tighten the skin envelope sufficiently and create a normal male chest wall contour. The application of the vertical component proceeds very similarly in males as compared to females. After the majority of the excess breast volume has been reduced using liposuction, the redundant lower pole skin is plicated with staples intraoperatively in conjunction with the application of the periareolar pattern and the patient is placed in the upright position to assess the effect. Additional revision using the tailor stapling technique is used to create the desired result. The staple line is marked, the staples removed and the intervening skin is de-epithelialized. The lateral portion of the vertical incision line can be divided just through the dermis to ease the tension on the vertical closure. This incision can also be used as an access portal to the breast to facilitate internal dissection as needed, and any remaining

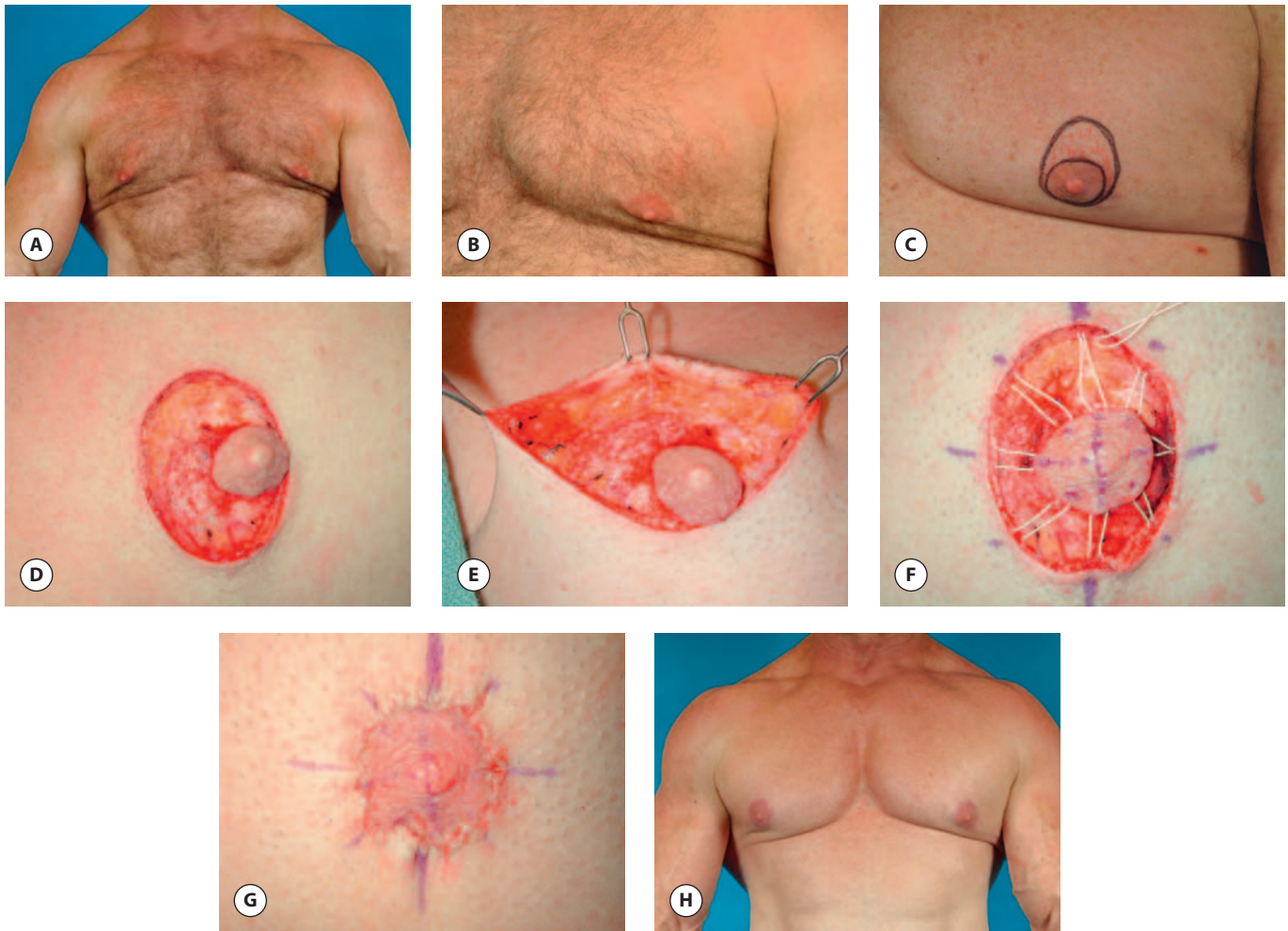


Figure 9.14 (A,B) Preoperative appearance of a 49-year-old male who has previously undergone gynecomastia excision who presents with mild NAC ptosis along with redundancy and wrinkling in the skin envelope along the lateral border of the pectoralis major. (C) Preoperative marks in preparation for mild skin envelope reduction and lifting of the position of the NAC. (D) Appearance of the NAC after de-epithelialization of the redundant periareolar skin and development of a small dermal cuff around the periphery of the defect for subsequent placement of the interlocking Gore-Tex purse string suture. (E) The surrounding flaps are slightly undermined for 1–2 cm directly at the level of the dermis to minimize the potential

creation of distortion due to tissue crowding as the purse string suture is tied down. (F) Eight evenly spaced points are alternatively diagrammed along the periareolar and areolar margins to guide the passage of the Gore-Tex purse string suture. After the suture has been placed, it has the appearance of spokes on a wheel. (G) Immediate postoperative appearance after the purse string suture has been tied down and the areola inset into the defect. (H) Postoperative appearance at 6 months reveals tightening of the skin envelope with resolution of the lateral wrinkling along with mild elevation of the position of the NAC.

fibrous tissue present under the areola can then be excised as in the direct excision technique described previously. The pedicle supporting the NAC can be thinned as needed, being certain to leave at least 1 cm of tissue attached to the underside of the NAC as well as the pedicle itself. Near the inframammary fold (IMF), the pedicle can be left a bit thicker to avoid inadvertently diminishing the blood supply to the NAC. After the breast volume has been appropriately reduced, the vertical incision is closed with interrupted and running 4-0 absorbable monofilament sutures. The periareolar portion is re-de-epithelialized as needed to create a perfectly round areolar closure and the interlocking Gore-Tex technique is applied as before. In cases of delayed skin envelope reduction, no additional internal dissection is required and the application of the circumvertical pattern involves simple tailor staple reshaping of the chest wall contour, de-epithelialization of the redundant skin, release of the dermis as needed to allow tension

free closure and application of the interlocking Gore-Tex suture. As before, the dermis can be released with confidence as the skin flaps and NAC will demonstrate adequate vascularity secondary to revascularization from the underlying pectoralis major muscle. The circumvertical skin pattern is a powerful short scar technique for restoring a normal chest wall contour in patients with gynecomastia who present with significant redundancy or laxity in the skin envelope (Figures 9.15, 9.16).

Horizontal pattern In cases of significant skin redundancy, a horizontally oriented pattern with no vertical component can be used to remove the excess skin and reshape the breast. Using this strategy, the blood supply to the NAC is provided using an inferior pedicle and the surrounding tissues are smoothly excised to debulk the breast. The pedicle itself can be mildly undermined as desired to ensure a smooth chest wall contour. After

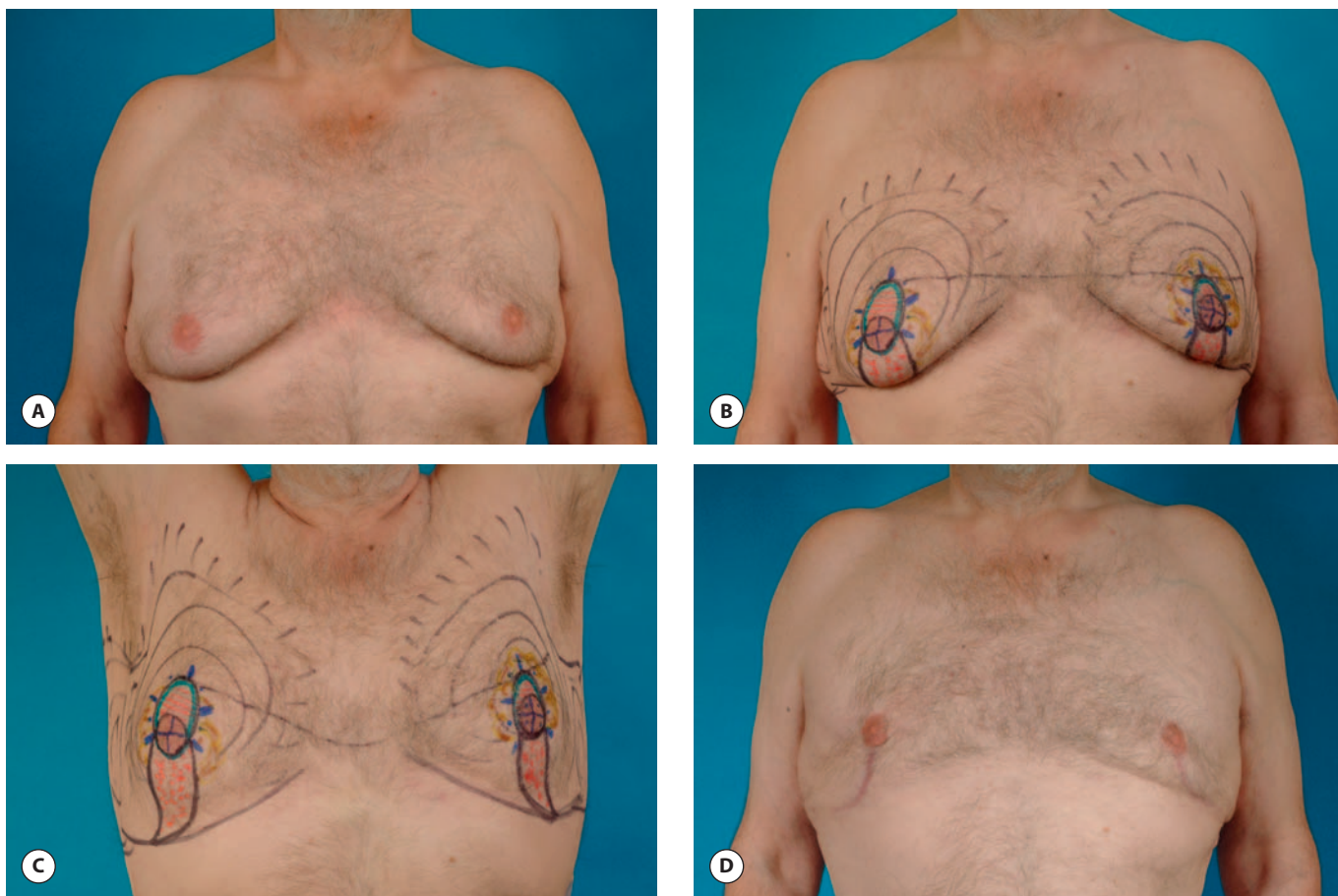


Figure 9.15 (A) Preoperative appearance of a 52-year-old man after undergoing a gastric bypass procedure with an associated weight loss of 120 pounds (54 kg). There is redundant skin present across the chest wall in association with a mild amount of persistent volume excess in the breasts.

(B,C) Preoperative marks in preparation for liposuction recontouring along with a circumvertical skin tightening procedure. (D) Six-month postoperative result demonstrating a normal male chest wall contour and a well-healed circumvertical scar.

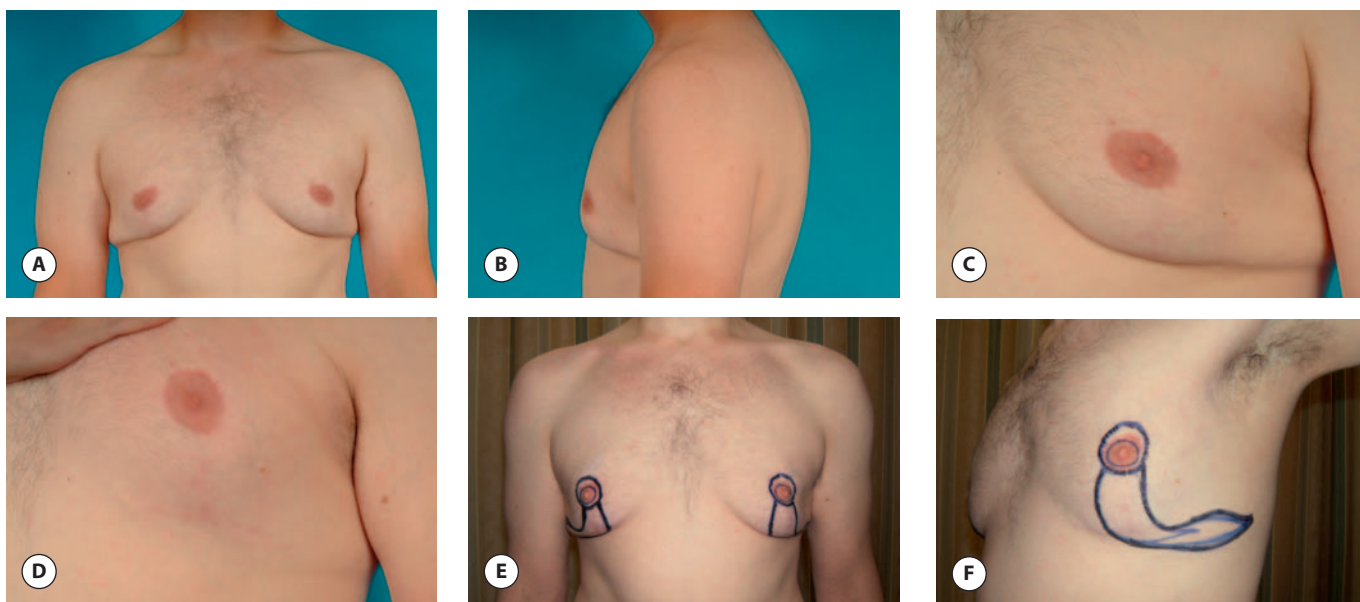


Figure 9.16 (A–D) Preoperative appearance of a 24-year-old male who presents 1 year after undergoing gynecomastia excision in conjunction with an inverted T skin envelope retailoring procedure. There is redundancy of the skin envelope in association with a mild persistent excess of breast volume. The inverted T and periareolar scars are well

healed and the areolar diameter is slightly widened. (E,F) Preoperative marks outline a planned circumvertical approach designed to narrow the base diameter of the breast, tighten the lateral skin redundancy that extends under the arm, narrow the diameter of the areola and remove excess breast volume.

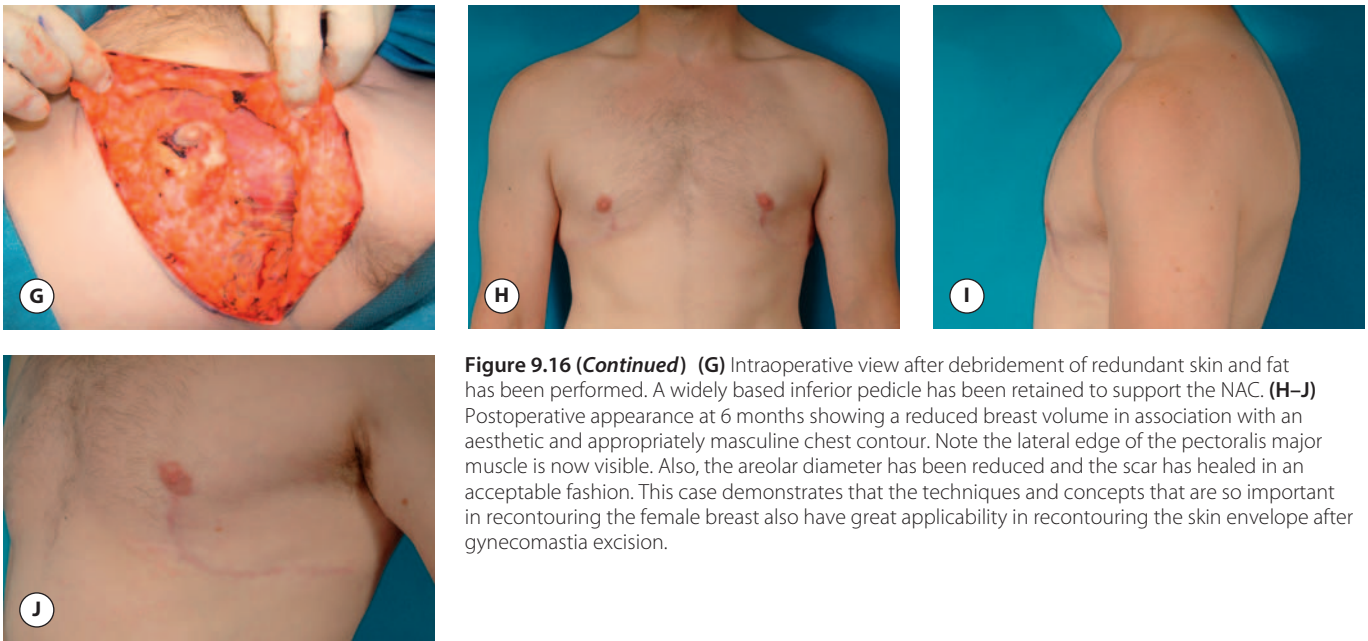


Figure 9.16 (Continued) (G) Intraoperative view after debridement of redundant skin and fat has been performed. A widely based inferior pedicle has been retained to support the NAC. (H–J) Postoperative appearance at 6 months showing a reduced breast volume in association with an aesthetic and appropriately masculine chest contour. Note the lateral edge of the pectoralis major muscle is now visible. Also, the areolar diameter has been reduced and the scar has healed in an acceptable fashion. This case demonstrates that the techniques and concepts that are so important in recontouring the female breast also have great applicability in recontouring the skin envelope after gynecomastia excision.

the breast volume has been reduced, the horizontal incision is closed and the location for the NAC determined, again keeping in mind that the ideal location in a male is somewhat more inferiorly located than in a female. A circular cutout is made and the NAC is inset into the defect. By placing the resulting scar in the inframammary fold, it becomes less conspicuous as compared to a vertical scar that can be more easily seen running directly down the center of the breast (Figure 9.17).

Typically, the patients who present with a marked skin redundancy are also variably obese. The horizontal pattern has a greater utility than the circumvertical pattern in these patients as there is commonly a mild residual redundancy in the skin envelope of the breast after resection and recontouring. The redundancy tends to hide the inframammary scar, thus satisfying to a greater degree than the vertical scar, one of the major goals in the surgical treatment of gynecomastia, that being correction of the deformity with the least conspicuous scar possible.

Complication Management

Surgical correction of gynecomastia is typically a well-tolerated procedure that provides consistent results. Despite this, however, as with any surgical procedure, a certain percentage of the time a complication may well develop. While unavoidable complications such as infection, bruising, delayed healing, pain and loss of sensation may occur, these are usually self-limited and if need be, easily treated. There are, however, certain procedure-specific complications that do merit comment.

Hematoma Perhaps the most common early complication is hematoma formation as, particularly in more dramatic cases of volume excess, the potential area of undermining and dissection

can be significant. Also, the exposure can be limited and, as is the case with liposuction, there may be no direct control of bleeding other than pressure and reliance on the clotting cascade. Usually, there is no question as to the diagnosis as the breast rapidly expands, sometimes to considerable proportions, resulting in ecchymosis and pain. In any case where a hematoma is noted and there is a potential space that can fill with blood clot, as occurs after direct excision, it is recommended that the patient be taken back to the operating room for exploration and evacuation of the clot. If the bleeding source is identified it is controlled; however, very often, the offending perforator cannot be isolated. The wound is irrigated and a drain placed as postoperative seroma formation is a common occurrence. Should a small hematoma be treated expectantly, the bleeding may stop; however, the length of time it takes for the clot to dissolve is lengthy and often results in residual scarring and tissue tethering that can result in a contour deformity. Therefore, even with small hematomas, surgical exploration is recommended.

Residual contour deformity In patients with gynecomastia, removing the fibrous and fatty components of the breast in such a way that even and contoured flaps are left behind can be a technical challenge. Over-resection of the subareolar fibrous mass can create a central depression under the areola, resulting in an uneven chest wall contour. Also, uneven application of liposuction can create contour irregularities in the periphery of the chest wall. One common area for persistent fatty accumulation, particularly in the obese, is under the arm along the lateral chest wall. Whatever the cause, anything less than a smooth chest contour causes concern for the patient and usually results in revisionary surgery. When planning a revision, it is best to treat the high areas first with specifically targeted liposuction using small cannulas to reduce the magnitude of the deformity. Then should any residual depression be noted, lipofilling is indicated to fill in the contour defect. Standard technique using small aliquots of transplanted fat harvested from the abdomen can be very effective in smoothing out postoperative surface irregularities. Judicious use of these

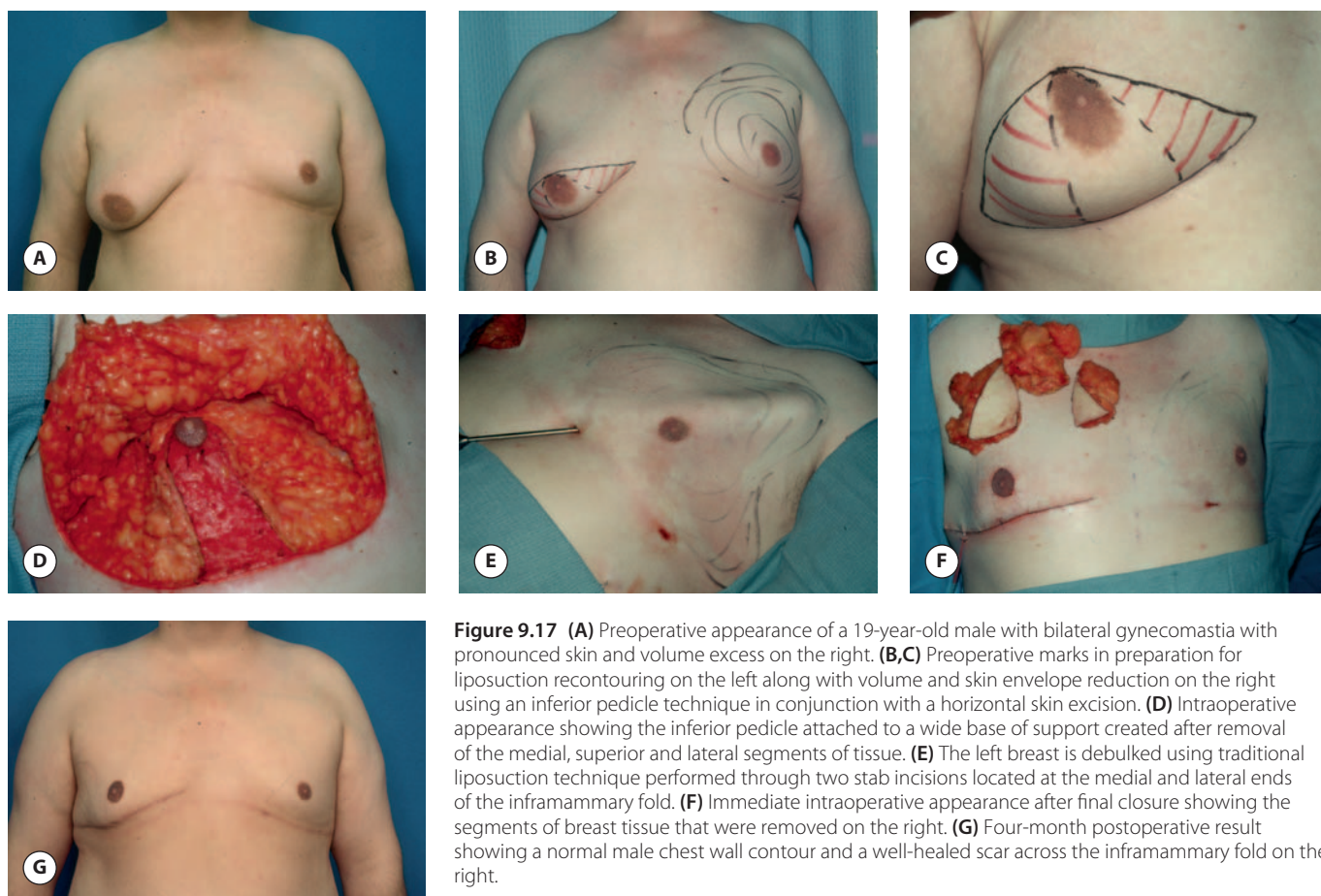


Figure 9.17 (A) Preoperative appearance of a 19-year-old male with bilateral gynecomastia with pronounced skin and volume excess on the right. (B,C) Preoperative marks in preparation for liposuction recontouring on the left along with volume and skin envelope reduction on the right using an inferior pedicle technique in conjunction with a horizontal skin excision. (D) Intraoperative appearance showing the inferior pedicle attached to a wide base of support created after removal of the medial, superior and lateral segments of tissue. (E) The left breast is debulked using traditional liposuction technique performed through two stab incisions located at the medial and lateral ends of the inframammary fold. (F) Immediate intraoperative appearance after final closure showing the segments of breast tissue that were removed on the right. (G) Four-month postoperative result showing a normal male chest wall contour and a well-healed scar across the inframammary fold on the right.

modalities can help restore a smooth chest wall contour when contour irregularities occur after first stage gynecomastia excision.

Excess skin After removal of the excess fibrous tissue and fat, the skin generally retracts around the remaining tissue to create a smooth chest wall contour. When the skin envelope is redundant or has poor elasticity, this retraction may be incomplete, resulting in unsightly folds or ridges in the skin. Once full healing has occurred and the swelling has completely resolved, the redundancy in the skin envelope can be addressed as described previously. Using what amounts to perhaps an unintended staged procedure can actually serve to provide excellent results with a minimum of cutaneous scar.

Insufficient excision Regrowth of either the fibrous component or the fibrofatty stroma in patients with gynecomastia is an

unusual occurrence; however, insufficient excision, particularly in the obese, can occur. In patients with a high body mass index (BMI), it can sometimes be difficult to judge when an appropriate endpoint is reached when trying to match an appropriate chest wall contour to the rest of the trunk and some patients may seek additional contouring after the primary attempt at excision has been undertaken. In these cases, it is important to set realistic expectations and identify precisely those areas that are cause for concern. In particular, should there be any residual fibrous tissue under the areola, it may be wise to perform either direct excision or use the pull through technique to smooth out this area if this was not performed at the primary procedure. This can sometimes be seen in obese patients where liposuction alone was used to perform the volume reduction. With appropriately directed surgical attention to specific problem areas, successful recontouring can be accomplished such that excellent results can be obtained.

Summary

Gynecomastia can challenge the surgical decision making and technical expertise of the surgeon. Balancing issues such as incision placement, exposure, skin redundancy and scar demands that the nature of the condition be precisely identified so that a successful surgical plan can be developed for each individual patient. When these variables are carefully

controlled and the surgical plan is executed with precision, excellent results can be obtained. Because of the significant emotional and psychological overtones that can be associated with gynecomastia and the improvement that can result, particularly in adolescent boys, the rewards for both the patient and the surgeon make the effort well worthwhile.

FURTHER READING

Chapter 1

- Bayati S, Seckel BR. Inframammary crease ligament. *Plast. Reconstr. Surg.* 95: 501–508, 1995.
- Brown J, Schwartz RA. Supernumerary nipples: an overview. *Cutis* 71: 344–346, 2003.
- Cunningham L. The anatomy of the arteries and veins of the breast. *J. Surg. Oncol.* 9: 71–85, 1977.
- Del Vecchio C, Caloca J Jr., Caloca J, Gómez-Jauregui J. Evaluation of breast sensibility using dermatomal somatosensory evoked potentials. *Plast. Reconstr. Surg.* 113: 1975–1983, 2004.
- Estourgie SH, Nieweg OE, Olmos RA, Rutgers EJ, Kroon BB. Lymphatic drainage patterns from the breast. *Ann. Surg.* 239: 232–237, 2004.
- Farina MA, Newby BG, Alani HM. Innervation of the nipple-areola complex. *Plast. Reconstr. Surg.* 66: 497–501, 1980.
- Garnier D, Angonin R, Foulon P, Chavoïn JP, Ricbourg B, Costagliola M. The inframammary fold: myth or reality? *Ann. Chir. Plast. Esthet.* 36: 313–319, 1991.
- Grossl NA. Supernumerary breast tissue: historical perspectives and clinical features. *South. Med. J.* 93: 29–32, 2000.
- Hamdi M, Greuse M, Nemec E, Deprez C, De Mey A. Breast sensation after superior pedicle versus inferior pedicle mammoplasty: anatomical and histological evaluation. *Br. J. Plast. Surg.* 54: 43–46, 2001.
- Jaspars JJ, Posma AN, van Immerseel AA, Gittenberger-deGroot AC. The cutaneous innervation of the female breast and nipple-areola complex: implications for surgery. *Br. J. Plast. Surg.* 50: 249–259, 1997.
- Loukas M, Clarke P, Tubbs RS. Accessory breasts: a historical and current perspective. *Am. Surg.* 73: 525–528, 2007.
- Macchi V, Tiengo C, Porzionato A, Parenti A, Stecco C, Mazzoleni F, De Caro R. Medial and lateral pectoral nerves: course and branches. *Clin. Anat.* 20: 157–162, 2007.
- Maliniac JW. Arterial blood supply of the breast. *Arch. Surg.* 47: 329–343, 1943.
- Muntan CD, Sundine MJ, Rink RD, Acland RD. Inframammary fold: a histologic reappraisal. *Plast. Reconstr. Surg.* 105: 549–556, 2000.
- Nakajima H, Imanishi N, Aiso S. Arterial anatomy of the nipple-areola complex. *Plast. Reconstr. Surg.* 96: 843–845, 1995.
- Nava M, Quattrone P, Riggio E. Focus on the breast fascial system: a new approach for inframammary fold reconstruction. *Plast. Reconstr. Surg.* 102: 1034–1045, 1998.
- O'Dey D, Prescher A, Pallua N. Vascular reliability of nipple-areola complex-bearing pedicles: an anatomical microdissection study. *Plast. Reconstr. Surg.* 119: 1167–1177, 2007.
- Palmer JH, Taylor GI. The vascular territories of the anterior chest wall. *Br. J. Plast. Surg.* 39: 287–299, 1986.
- Reid CR, Taylor GI. The vascular territory of the acromiothoracic axis. *Br. J. Plast. Surg.* 7: 194–212, 1984.
- Robbins TH. Innervation of the nipple-areola complex. *Plast. Reconstr. Surg.* 68: 453, 1981.
- Rosson GD, Holton LH, Silverman RP, Singh NK, Nahabedian MY. Internal mammary perforators: a cadaver study. *J. Reconstr. Microsurg.* 21: 239–242, 2005.
- Sarhadi NS, Shaw Dunn J, Lee FD, Soutar DS. An anatomical study of the nerve supply to the breast, including the nipple and areola. *Br. J. Plast. Surg.* 49: 156–164, 1996.
- Sarhadi NS, Shaw-Dunn J, Soutar DS. Nerve supply of the breast with special reference to the nipple and areola: Sir Astley Cooper revisited. *Clin. Anat.* 10: 283–288, 1997.
- Schlenz I, Kuzbari R, Gruber H, Holle J. The sensitivity of the nipple-areola complex: an anatomic study. *Plast. Reconstr. Surg.* 105: 905–909, 2000.
- Schlenz I, Rigel S, Schemper M, Kuzbari R. Alteration of nipple and areola sensitivity by reduction mammoplasty: a prospective comparison of five techniques. *Plast. Reconstr. Surg.* 115: 743–751, 2005.
- Schmidt H. Supernumerary nipples: prevalence, size, sex and side predilection – a prospective clinical study. *Eur. J. Pediatr.* 157: 821–823, 1998.
- Suami H, Pan WR, Mann GB, Taylor GI. The lymphatic anatomy of the breast and its implications for sentinel lymph node biopsy: a human cadaver study. *Ann. Surg. Oncol.* 15: 863–871, 2008.
- van Deventer, PV. The blood supply to the nipple-areola complex of the human mammary gland. *Aesthet. Plast. Surg.* 28: 393–398, 2004.
- Wuringer E. Refinement of the central pedicle breast reduction by application of the ligamentous suspension. *Plast. Reconstr. Surg.* 103: 1400–1410, 1999.
- Wuringer E, Mader N, Posche E, Holle J. Nerve and vessel supplying ligamentous suspension on the mammary gland. *Plast. Reconstr. Surg.* 101: 1486–1493, 1998.
- Wuringer E, Tschabitscher M. New aspects of the topographical anatomy of the mammary gland regarding its neurovascular supply along a regular ligamentous suspension. *Eur. J. Morphol.* 40: 181–189, 2002.

Chapter 2

- DiBernardo BE, Adams RL, Krause J, Fiorillo MA, Gheradini G. Photographic standards in plastic surgery. *Plast. Reconstr. Surg.* 102: 559–568, 1998.
- Dickason WL, Hanna DC. Pitfalls of comparative photography in plastic and reconstructive surgery. *Plast. Reconstr. Surg.* 58: 166–175, 1976.
- Fahmy FS, Hemington-Gorse SJ. The sitting, oblique, and supine marking technique for reduction mammoplasty and mastopexy. *Plast. Reconstr. Surg.* 117: 2145–2151, 2006.
- Galdino GM, Swier P, Manson PN, Vander Kolk CA. Converting to digital photography: a model for a large group or academic practice. *Plast. Reconstr. Surg.* 106: 119–124, 2000.
- Galdino GM, Vogel JE, Vander Kolk CA. Standardizing digital photography: it's not all in the eye of the beholder. *Plast. Reconstr. Surg.* 108: 1334–1344, 2001.
- Hammond DC, Hollender HA, Bouwense CL. The sit-up position in breast surgery. *Plast. Reconstr. Surg.* 107: 572–576, 2001.
- Letterman G, Schurter M. A sitting position for mammoplasty with general anesthesia. *Ann. Plast. Surg.* 20: 522–526, 1988.
- Morrison CM, Shoda P, Zins JE. A simple method of maintaining patient modesty and standardisation in plastic surgery photography. *J. Plast. Reconstr. Aesthetic Surg.* 61: 716, 2008.
- Parker WL, Czerwinski M, Sinno H, Loizides P, Lee C. Objective interpretation of surgical outcomes: is there a need for

- standardizing digital images in the plastic surgery literature? *Plast. Reconstr. Surg.* 120: 1419–1423, 2007.
- Persichetti P, Simone P, Langella M, Marangi GF, Carusi C. Digital photography in plastic surgery: how to achieve reasonable standardization outside a photographic studio. *Aesthet. Plast. Surg.* 31: 194–200, 2007.
- Smoot EC, Ross D, Silverberg B, Ruttle M, Newman LM. The sit up position for breast reconstruction. *Plast. Reconstr. Surg.* 77: 60–65, 1986.
- Yavuzer R, Smirnes S, Jackson IT. Guidelines for standard photography in plastic surgery. *Ann. Plast. Surg.* 46: 293–300, 2001.

Chapter 3

- Brand KG. Polyurethane-coated silicone implants and the question of capsular contracture. *Plast. Reconstr. Surg.* 73(3): 498, 1984.
- Brown MH, Shenker R, Silver SA. Cohesive silicone gel breast implants in aesthetic and reconstructive breast surgery. *Plast. Reconstr. Surg.* 116(3): 768–779, 2005.
- Capozzi A, Pennisi VR. Clinical experience with polyurethane-covered gel-filled mammary prostheses. *Plast. Reconstr. Surg.* 68(4): 512–520, 1981.
- Collis N, Coleman D, Foo IT, Sharpe DT. Ten-year review of a prospective randomized controlled trial of textured versus smooth subglandular silicone gel breast implants. *Plast. Reconstr. Surg.* 106(4): 786–791, 2000.
- Cunningham B. The Mentor study on contour profile gel silicone MemoryGel breast implants. *Plast. Reconstr. Surg.* 120(7 Suppl 1): 33S–39S, 2007.
- Fagrell D, Berggren A, Tarpila E. Capsular contracture around saline-filled fine textured and smooth mammary implants: a prospective 7.5-year follow-up. *Plast. Reconstr. Surg.* 108(7): 2108–2112, 2001.
- Fruhstorfer BH, Hodgson EL, Malata CM. Early experience with an anatomical soft cohesive silicone gel prosthesis in cosmetic and reconstructive breast implant surgery. *Ann. Plast. Surg.* 53(6): 536–542, 2004.
- Hakelius L, Ohlsén L. Tendency to capsular contracture around smooth and textured gel-filled silicone mammary implants: a five-year follow-up. *Plast. Reconstr. Surg.* 100(6): 1566–1569, 1997.
- Handel N, Cordray T, Gutierrez J, Jensen JA. A long-term study of outcomes, complications, and patient satisfaction with breast implants. *Plast. Reconstr. Surg.* 117(3): 757–767, 2006.
- Handel N, Silverstein MJ, Jensen JA, Collins A, Zierk K. Comparative experience with smooth and polyurethane breast implants using the Kaplan-Meier method of survival analysis. *Plast. Reconstr. Surg.* 88(3): 475–481, 1991.
- Hedén P, Boné B, Murphy DK, Slicton A, Walker PS. Style 410 cohesive silicone breast implants: safety and effectiveness at 5 to 9 years after implantation. *Plast. Reconstr. Surg.* 118(6): 1281–1287, 2006.
- Hester TR Jr., Cukic J. Use of stacked polyurethane-covered mammary implants in aesthetic and reconstructive breast surgery. *Plast. Reconstr. Surg.* 88(3): 503–509, 1991.
- Hester TR Jr., Nahai F, Bostwick J, Cukic J. A 5-year experience with polyurethane-covered mammary prostheses for treatment of capsular contracture, primary augmentation mammoplasty, and breast reconstruction. *Clin. Plast. Surg.* 15(4): 569–585, 1988.
- Picha GJ, Goldstein JA, Stohr E. Natural-Y Mème polyurethane versus smooth silicone: analysis of the soft-tissue interaction from 3 days to 1 year in the rat animal model. *Plast. Reconstr. Surg.* 85(6): 903–916, 1990.
- Sinclair TM, Kerrigan CL, Buntic R. Biodegradation of the polyurethane foam covering of breast implants. *Plast. Reconstr. Surg.* 92(6): 1003–1013, 1993.
- Tarpila E, Ghassemifar R, Fagrell D, Berggren A. Capsular contracture with textured versus smooth saline-filled implants for breast augmentation: a prospective clinical study. *Plast. Reconstr. Surg.* 99(7): 1934–1939, 1997.
- Vázquez G, Pellón A. Polyurethane-coated silicone gel breast implants used for 18 years. *Aesthet. Plast. Surg.* 31(4): 330–336, 2007.
- Wong CH, Samuel M, Tan BK, Song C. Capsular contracture in subglandular breast augmentation with textured versus smooth breast implants: a systematic review. *Plast. Reconstr. Surg.* 118(5): 1224–1236, 2006.

Chapter 4

- Banbury J, Yetman R, Lucas A, Papay F, Graves K, Zins JE. Prospective analysis of the outcome of subpectoral breast augmentation: sensory changes, muscle function, and body image. *Plast. Reconstr. Surg.* 113(2): 701–707; discussion 708–711, 2004.
- Barnett A. Transaxillary subpectoral augmentation in the ptotic breast: augmentation by disruption of the extended pectoral fascia and parenchymal sweep. *Plast. Reconstr. Surg.* 86(1): 76–83, 1990.
- Dowden RV. Dispelling the myths and misconceptions about transumbilical breast augmentation. *Plast. Reconstr. Surg.* 106(1): 190–194, 2000.
- Góes JC, Landecker A. Optimizing outcomes in breast augmentation: seven years of experience with the subfascial plane. *Aesthet. Plast. Surg.* 27(3): 178–184, 2003.
- Graf RM, Bernardes A, Auersvald A, Damasio RC. Subfascial endoscopic transaxillary augmentation mammoplasty. *Aesthet. Plast. Surg.* 24(3): 216–220, 2000.
- Graf RM, Bernardes A, Rippel R, Araujo LR, Damasio RC, Auersvald A. Subfascial breast implant: a new procedure. *Plast. Reconstr. Surg.* 111(2): 904–908, 2003.
- Gylbert L, Asplund O, Jurell G, Olenius M. Results of subglandular breast augmentation using a new classification method – 18-year follow-up. *Scand. J. Plast. Reconstr. Surg. Hand. Surg.* 23(2): 133–136, 1989.
- Hendricks H. Complete submuscular breast augmentation: 650 cases managed using an alternative surgical technique. *Aesthet. Plast. Surg.* 31(2): 147–153, 2007.
- Henriksen TF, Fryzek JP, Hölmich LR, McLaughlin JK, Kjølner K, Høyer AP, Olsen JH, Friis S. Surgical intervention and capsular contracture after breast augmentation: a prospective study of risk factors. *Ann. Plast. Surg.* 54(4): 343–351, 2005.
- Pound EC 3rd, Pound EC Jr.. Transumbilical breast augmentation (TUBA): patient selection, technique, and clinical experience. *Clin. Plast. Surg.* 28(3): 597–605, 2001.
- Puckett CL, Croll GH, Reichel CA, Concannon MJ. A critical look at capsule contracture in subglandular versus subpectoral mammary augmentation. *Aesthet. Plast. Surg.* 11(1): 23–28, 1987.
- Seify H, Sullivan K, Hester TR. Preliminary (3 years) experience with smooth wall silicone gel implants for primary breast augmentation. *Ann. Plast. Surg.* 54(3): 231–235, 2005.
- Serra-Renom J, Garrido MF, Yoon T. Augmentation mammoplasty with anatomic soft, cohesive silicone implant using the transaxillary approach at a subfascial level with endoscopic assistance. *Plast. Reconstr. Surg.* 116(2): 640–645, 2005.
- Siclovan HR, Jomah JA. Advantages and outcomes in subfascial breast augmentation: a two-year review of experience. *Aesthet. Plast. Surg.* 32(3): 426–431, 2008.
- Silverstein MJ, Handel N, Gamagami P. The effect of silicone-gel-filled implants on mammography. *Cancer.* 68(5 Suppl): 1159–1163, 1991.
- Silverstein MJ, Handel N, Gamagami P, Waisman E, Gierson ED. Mammographic measurements before and after augmentation mammoplasty. *Plast. Reconstr. Surg.* 86(6): 1126–1130, 1990.

- Spear SL, Carter ME, Ganz JC. The correction of capsular contracture by conversion to 'dual-plane' positioning: technique and outcomes. *Plast. Reconstr. Surg.* 118(7 Suppl): 103S–113S, 2006.
- Tebbetts JB. Transaxillary subpectoral augmentation mammoplasty: a 9-year experience. *Clin. Plast. Surg.* 15(4): 557–568, 1988.
- Tebbetts JB. Dual plane breast augmentation: optimizing implant–soft-tissue relationships in a wide range of breast types. *Plast. Reconstr. Surg.* 107(5): 1255–1272, 2001.
- Vazquez B, Given KS, Houston GC. Breast augmentation: a review of subglandular and submuscular implantation. *Aesthet. Plast. Surg.* 11(2): 101–105, 1987.
- Wong CH, Samuel M, Tan BK, Song C. Capsular contracture in subglandular breast augmentation with textured versus smooth breast implants: a systematic review. *Plast. Reconstr. Surg.* 118(5): 1224–1236, 2006.
- Graham JK. Cosmetic surgery IV: mastopexy. *J. La State Med. Soc.* 134: 21–22, 1982.
- Gruber RP, Jones HW Jr. The 'donut' mastopexy: indications and complications. *Plast. Reconstr. Surg.* 65: 34–38, 1980.
- Guimaraes J, Maia M, Monteiro E, Ferraro A. Aesthetic correction of mild pectus excavatum with autologous tissue during mastopexy. *Plast. Reconstr. Surg.* 108: 757–762, 2001.
- Gulyas G. Marking the position of the nipple-areola complex for mastopexy and breast reduction surgery. *Plast. Reconstr. Surg.* 113: 2085–2090, 2004.
- Hagerty RC. External mastopexy with imbrication following explantation. *Plast. Reconstr. Surg.* 103: 976–979, 1999.
- Hall-Findlay EJ. Pedicles in vertical breast reduction and mastopexy. *Clin. Plast. Surg.* 29: 379–391, 2002.
- Hammond DC. Short scar periareolar inferior pedicle reduction (SPAIR) mammoplasty. *Plast. Reconstr. Surg.* 103: 890–901; discussion 902, 1999.
- Hammond DC. Short scar periareolar inferior pedicle reduction (SPAIR) mammoplasty. *Oper. Tech. Plast. Reconstr. Surg.* 6: 106–118, 1999.
- Hammond DC. Short scar periareolar inferior pedicle reduction (SPAIR) mammoplasty/mastopexy: how I do it step by step. *Perspect. Plast. Surg.* 18: 61–70, 2001.
- Hammond DC. The SPAIR mammoplasty. *Clin. Plast. Surg.* 29: 411–421, 2002.
- Hammond DC. The short scar periareolar inferior pedicle reduction (SPAIR) mammoplasty: new trends in reduction and mastopexy. *Semin. Plast. Surg.* 18: 231–234, 2004.
- Hammond DC, Khuthaila DK, Kim J. The interlocking Gore-Tex suture for control of areolar diameter and shape. *Plast. Reconstr. Surg.* 119: 804–809, 2007.
- Hammond DC, Alfonso D, Khuthaila DK. Mastopexy using the short scar periareolar inferior pedicle reduction technique. *Plast. Reconstr. Surg.* 121(5): 1533–1539, 2008.
- Hinderer UT. Circumareolar dermo-glandular plication: a new concept for correction of breast ptosis. *Aesthet. Plast. Surg.* 25: 404–420, 2001.
- Hoefflin SM. Using skin darts to improve breast reduction and mastopexy scars. *Plast. Reconstr. Surg.* 89: 996, 1992.
- Krupp S. Mastopexy: modification of periwinkle shell operation. Ten years of experience. *Aesthet. Plast. Surg.* 14: 9–14, 1990.
- Kwei S, Borud LJ, Lee BT. Mastopexy with autologous augmentation after massive weight loss: the intercostal artery perforator (ICAP) flap. *Ann. Plast. Surg.* 57: 361–365, 2006.
- Letterman G, Schurter M. Suggested nomenclature for aesthetic and reconstructive surgery of the breast. Part II: Augmentation mammoplasty and mastopexy. *Aesthet. Plast. Surg.* 9: 293–296, 1985.
- Lewis GK. A method of mastopexy with fascia lata transplants. *J. Int. Coll. Surg.* 26: 346–353, 1956.
- Liu D, Xu G, Zhang Y. [Reduction mammoplasty and mastopexy with a circumareolar incision]. *Zhonghua Zheng Xing Shao Shang Wai Ke Za Zhi.* 11: 132–134, 1995.
- Lockwood T. Reduction mammoplasty and mastopexy with superficial fascial system suspension. *Plast. Reconstr. Surg.* 103: 1411–1420, 1999.
- Marconi F. The dermal pursestring suture: a new technique for a short inframammary scar in reduction mammoplasty and dermal mastopexy. *Ann. Plast. Surg.* 22: 484–493; discussion 494, 1989.
- Marin-Bertolin S, Gonzalez-Martinez R, Velasco-Pastor M, Gil-Mateo MD, Amorrrortu-Velayos J. Mondor's disease and aesthetic breast surgery: report of case secondary to mastopexy with augmentation. *Aesthet. Plast. Surg.* 19: 251–252, 1995.
- Mendez-Fernandez MA. An easy-to-make, easy-to-use device for preoperative marking for reduction mammoplasty and mastopexy. *Ann. Plast. Surg.* 26: 602–603, 1991.

Chapter 5

- Baran CN, Peker F, Ortak T, Sensoz O, Baran NK. Unsatisfactory results of periareolar mastopexy with or without augmentation and reduction mammoplasty: enlarged areola with flattened nipple. *Aesthet. Plast. Surg.* 25: 286–289, 2001.
- Bartels RJ, Strickland DM, Douglas WM. A new mastopexy operation for mild or moderate breast ptosis. *Plast. Reconstr. Surg.* 57: 687–691, 1976.
- Benelli L. A new periareolar mammoplasty: the 'round block' technique. *Aesthet. Plast. Surg.* 14: 93–100, 1990.
- Brink RR. Evaluating breast parenchymal maldistribution with regard to mastopexy and augmentation mammoplasty. *Plast. Reconstr. Surg.* 86: 715–719; discussion 720–721, 1990.
- Brink RR. Evaluating breast parenchymal maldistribution with regard to mastopexy and augmentation mammoplasty. *Plast. Reconstr. Surg.* 106: 491–496, 2000.
- Dinner MI, Artz JS, Foglietti MA. Application and modification of the circular skin excision and pursestring procedures. *Aesthet. Plast. Surg.* 17: 301–309, 1993.
- Elsahy NI. The hexagonal technique for mastopexy and reduction mammoplasty. *Aesthet. Plast. Surg.* 6: 107–115, 1982.
- Elsahy NI. The modified hexagonal technique for reduction mammoplasty and mastopexy. *Aesthet. Plast. Surg.* 10: 45–50, 1986.
- Erol OO, Spira M. A mastopexy technique for mild to moderate ptosis. *Plast. Reconstr. Surg.* 65: 603–609, 1980.
- Ersek RA, Ersek SL. Circular cinching stitch. *Plast. Reconstr. Surg.* 88: 350–352, 1991.
- Fahmy FS, Hemington-Gorse SJ. The sitting, oblique, and supine marking technique for reduction mammoplasty and mastopexy. *Plast. Reconstr. Surg.* 117: 2145–2151, 2006.
- Faria-Correa MA. Endoscopic abdominoplasty, mastopexy, and breast reduction. *Clin. Plast. Surg.* 22: 723–745, 1995.
- Fayman MS. Short scar mastopexy with flap transposition. *Aesthet. Plast. Surg.* 22: 135–141, 1998.
- Flowers RS, Smith EM Jr. 'Flip-flap' mastopexy. *Aesthet. Plast. Surg.* 22: 425–429, 1998.
- Goulian D Jr. Dermal mastopexy. *Plast. Reconstr. Surg.* 47: 105–110, 1971.
- Goulian D. Jr. Dermal mastopexy. *Clin. Plast. Surg.* 3: 171–175, 1976.
- Graf R, Biggs TM. In search of better shape in mastopexy and reduction mammoplasty. *Plast. Reconstr. Surg.* 110: 309–317; discussion 318–322, 2002.
- Graf R, Reis de Araujo LR, Rippel R, Neto LG, Pace DT, Biggs T. Reduction mammoplasty and mastopexy using the vertical scar and thoracic wall flap technique. *Aesthet. Plast. Surg.* 27: 6–12, 2003.

- Mladick RA. Mastopexy after explantation. *Plast. Reconstr. Surg.* 103: 330, 1999.
- Neri JB. Mastopexy and breast reduction in Asians. *Ann. Acad. Med. Singapore.* 12(Suppl): 456–459, 1983.
- Nicolle F. Improved standards in reduction mammoplasty and mastopexy. *Plast. Reconstr. Surg.* 69: 453–459, 1982.
- Nicolle FV. Reduction mammoplasty and mastopexy: a personal technique. *Aesthet. Plast. Surg.* 8: 43–50, 1984.
- Nigro DM. Crescent mastopexy and augmentation. *Plast. Reconstr. Surg.* 76: 802–803, 1985.
- Parenteau JM, Regnault P. The Regnault 'B' technique in mastopexy and breast reduction: a 12-year review. *Aesthet. Plast. Surg.* 13: 75–79, 1989.
- Pedron M. Minimal-scar breast reduction and mastopexy. *Aesthet. Plast. Surg.* 29: 261–273, 2005.
- Peled IJ. The concentric mastopexy and the purse-string suture. *Plast. Reconstr. Surg.* 87: 385, 1991.
- Peled IJ. Periareolar mastopexy. *Plast. Reconstr. Surg.* 89: 770–771, 1992.
- Perez-Macias JM. Personal mastopexy technique for breast stabilisation: update. *Br. J. Plast. Surg.* 57: 178, 2004.
- Pinsky MA. Radial plication in concentric mastopexy. *Aesthet. Plast. Surg.* 29: 391–399, 2005.
- Ramatschi P, Muhlbauer W. [Mastopexy with few scars]. *Langenbecks Arch. Chir.* 369: 295–296, 1986.
- Ramatschi P, Muhlbauer W. [Mastopexy with few scars]. *Zentralbl. Chir.* 112: 1283–1291, 1987.
- Regnault P. Breast reduction and mastopexy, an old love story: B technique update. *Aesthet. Plast. Surg.* 14: 101–106, 1990.
- Regnault P, Daniel RK, Tirkanits B. The minus-plus mastopexy. *Clin. Plast. Surg.* 15: 595–600, 1988.
- Ritz M, Silfen R, Southwick G. Fascial suspension mastopexy. *Plast. Reconstr. Surg.* 117: 86–94, 2006.
- Rohrich RJ, Beran SJ, Restifo RJ, Copit SE. Aesthetic management of the breast following explantation: evaluation and mastopexy options. *Plast. Reconstr. Surg.* 101: 827–837, 1998.
- Rohrich RJ, Gosman AA, Brown SA, Reisch J. Mastopexy preferences: a survey of board-certified plastic surgeons. *Plast. Reconstr. Surg.* 118: 1631–1638, 2006.
- Rohrich RJ, Thornton JF, Jakubietz RG, Jakubietz MG, Grunert JG. The limited scar mastopexy: current concepts and approaches to correct breast ptosis. *Plast. Reconstr. Surg.* 114: 1622–1630, 2004.
- Scioscia PJ, Hagerty RC. Internal mastopexy following explantation. *Plast. Reconstr. Surg.* 97: 1014–1019; discussion 1020–1022. 1996.
- Ship AG, Weiss PR, Engler AM. Dual-pedicle dermoparenchymal mastopexy. *Plast. Reconstr. Surg.* 83: 281–290, 1989.
- Spear SL, Giese SY, Ducic I. Concentric mastopexy revisited. *Plast. Reconstr. Surg.* 107: 1294–1299; discussion 1300, 2001.
- Spear SL, Kassan M, Little JW. Guidelines in concentric mastopexy. *Plast. Reconstr. Surg.* 85: 961–966, 1990.
- Weiner DL, Aiache AE, Silver L, Tittiranonda T. A single dermal pedicle for nipple transposition in subcutaneous mastectomy, reduction mammoplasty, or mastopexy. *Plast. Reconstr. Surg.* 51: 115–120, 1973.
- Whidden PG. The tailor-tack mastopexy. *Plast. Reconstr. Surg.* 62: 347–354, 1978.
- de la Fuente A, Martin del Yerro JL. Periareolar mastopexy with mammary implants. *Aesthet. Plast. Surg.* 16: 337–341, 1992.
- Don Parsa F, Brickman M, Parsa AA. Augmentation/mastopexy. *Plast. Reconstr. Surg.* 115: 1428–1429, 2005.
- Elliott LF. Circumareolar mastopexy with augmentation. *Clin. Plast. Surg.* 29: 337–347, v, 2002.
- Friedman RM. Augmentation/mastopexy: 'surgeon beware'. *Plast. Reconstr. Surg.* 113: 2230–2231, 2004.
- Gasperoni C, Salgarello M, Gargani G. Experience and technical refinements in the 'donut' mastopexy with augmentation mammoplasty. *Aesthet. Plast. Surg.* 12: 111–114, 1988.
- Gruber R, Denkler K, Hvistendahl Y. Extended crescent mastopexy with augmentation. *Aesthet. Plast. Surg.* 30: 269–274; discussion 275–276, 2006.
- Hammond DC, Khuthaila DK, Kim J. The interlocking Gore-Tex suture for control of areolar diameter and shape. *Plast. Reconstr. Surg.* 119: 804–809, 2007.
- Hoffman S. Some thoughts on augmentation/mastopexy and medical malpractice. *Plast. Reconstr. Surg.* 113: 1892–1893, 2004.
- Karnes J, Morrison W, Salisbury M, Schaeferle M, Beckham P, Ersek RA. Simultaneous breast augmentation and lift. *Aesthet. Plast. Surg.* 24: 148–154, 2000.
- Marin-Bertolin S, Gonzalez-Martinez R, Velasco-Pastor M, Gil-Mateo MD, Amorrrortu-Velays J. Mondor's disease and aesthetic breast surgery: report of case secondary to mastopexy with augmentation. *Aesthet. Plast. Surg.* 19: 251–252, 1995.
- Nigro DM. Crescent mastopexy and augmentation. *Plast. Reconstr. Surg.* 76: 802–803, 1985.
- Owsley JQ Jr. Simultaneous mastopexy and augmentation for correction of the small, ptotic breast. *Ann. Plast. Surg.* 2: 195–200, 1979.
- Persoff MM. Vertical mastopexy with expansion augmentation. *Aesthet. Plast. Surg.* 27: 13–19, 2003.
- Pinsky MA. Radial plication in concentric mastopexy. *Aesthet. Plast. Surg.* 29: 391–399, 2005.
- Puckett CL, Meyer VH, Reinisch JF. Crescent mastopexy and augmentation. *Plast. Reconstr. Surg.* 75: 533–543, 1985.
- Rappaport NH, Spira M. A simplified technique for deepithelialization in patients requiring augmentation mastopexy. *Plast. Reconstr. Surg.* 70: 494–495, 1982.
- Ship AG, Weiss PR, Engler AM. Dual-pedicle dermoparenchymal mastopexy. *Plast. Reconstr. Surg.* 83: 281–290, 1989.
- Siggelkow W, Lebrecht A, Kolbl H, Faridi A. Dual-plane implant positioning for capsular contracture of the breast in combination with mastopexy. *Arch. Gynecol. Obstet.* 273: 79–85, 2005.
- Snow JW. Crescent mastopexy and augmentation. *Plast. Reconstr. Surg.* 77: 161–162, 1986.
- Spear S. Augmentation/mastopexy: 'surgeon, beware'. *Plast. Reconstr. Surg.* 112: 905–906, 2003.
- Spear SL. Augmentation/mastopexy: 'surgeon, beware'. *Plast. Reconstr. Surg.* 118(Suppl): 133S–134S; discussion 135S, 2006.
- Spear SL, Boehmler JH 4th, Clemens MW. Augmentation/mastopexy: a 3-year review of a single surgeon's practice. *Plast. Reconstr. Surg.* 118(Suppl): 136S–147S; discussion 148S–149S, 150S–151S, 2006.
- Spear SL, Low M, Ducic I. Revision augmentation mastopexy: indications, operations, and outcomes. *Ann. Plast. Surg.* 51: 540–546, 2003.
- Spear SL, Pelletiere CV, Menon N. One-stage augmentation combined with mastopexy: aesthetic results and patient satisfaction. *Aesthet. Plast. Surg.* 28: 259–267, 2004.
- Tapia A, Blanch A, Salvador J, Prat J, Albert I. Evolution of the vertical scar in Lejour's mastoplasty technique. *Aesthet. Plast. Surg.* 20: 377–384, 1996.

Chapter 6

- Cardenas-Camarena L, Ramirez-Macias R. Augmentation/mastopexy: how to select and perform the proper technique. *Aesthet. Plast. Surg.* 30: 21–33, 2006.
- Ceydeli A, Freund RM. 'Tear-drop augmentation mastopexy': a technique to augment superior pole hollow. *Aesthet. Plast. Surg.* 27: 425–432; discussion 433, 2003.

Chapter 7

- Aboud M, Vadoud-Seyedi J, De Mey A, Cukierfajn M, Lejour M. Incidence of calcifications in the breast after surgical reduction and liposuction. *Plast. Reconstr. Surg.* 96(3): 620–626, 1995.
- Ahmad J, Lista F. Vertical scar reduction mammoplasty: the fate of nipple-areola complex position and inferior pole length. *Plast. Reconstr. Surg.* 121(4): 1084–1091, 2008.
- Ariyan S. Reduction mammoplasty with the nipple-areola carried on a single, narrow inferior pedicle. *Ann. Plast. Surg.* 5(3): 167–177, 1980.
- Azzam C, De Mey A. Vertical scar mammoplasty in gigantomastia: retrospective study of 115 patients treated using the modified Lejour technique. *Aesthet. Plast. Surg.* 31(3): 294–298, 2007.
- Bolger WE, Seyfer AE, Jackson SM. Reduction mammoplasty using the inferior glandular 'pyramid' pedicle: experiences with 300 patients. *Plast. Reconstr. Surg.* 80(1): 75–84, 1987.
- Casas LA, Byun MY, Depoli PA. Maximizing breast projection after free-nipple-graft reduction mammoplasty. *Plast. Reconstr. Surg.* 107(4): 955–960, 2001.
- Ceydeli A, Gamboa M. Dermafascial fixation suture: a technique for a more durable projection with short-scar (vertical) reduction mammoplasty. *Aesthet. Plast. Surg.* 30(5): 592–594, 2006.
- Courtiss EH. Reduction mammoplasty by suction alone. *Plast. Reconstr. Surg.* 92(7): 1276–1284, 1993.
- Courtiss EH, Goldwyn RM. Reduction mammoplasty by the inferior pedicle technique. An alternative to free nipple and areola grafting for severe macromastia or extreme ptosis. *Plast. Reconstr. Surg.* 59(4): 500–507, 1977.
- Cruz NI, Korchin L. Lactational performance after breast reduction with different pedicles. *Plast. Reconstr. Surg.* 120(1): 35–40, 2007.
- Cruz-Korchin N, Korchin L. Vertical versus Wise pattern breast reduction: patient satisfaction, revision rates, and complications. *Plast. Reconstr. Surg.* 112(6): 1573–1578, 2003.
- Di Giuseppe A. Breast reduction with ultrasound-assisted lipoplasty. *Plast. Reconstr. Surg.* 112(1): 71–82, 2003.
- Georgiade GS, Riefkohl RE, Georgiade NG. The inferior dermal-pyramidal type breast reduction: long-term evaluation. *Ann. Plast. Surg.* 23(3): 203–211, 1989.
- Georgiade NG, Serafin D, Morris R, Georgiade G. Reduction mammoplasty utilizing an inferior pedicle nipple-areolar flap. *Ann. Plast. Surg.* 3(3): 211–218, 1979.
- Gerzenshtein J, Oswald T, McCluskey P, Caplan J, Angel MF. Avoiding free nipple grafting with the inferior pedicle technique. *Ann. Plast. Surg.* 55(3): 245–249, 2005.
- Hall-Findlay EJ. A simplified vertical reduction mammoplasty: shortening the learning curve. *Plast. Reconstr. Surg.* 104(3): 748–759, 1999.
- Hammond DC. Short scar periareolar inferior pedicle reduction (SPAIR) mammoplasty. *Plast. Reconstr. Surg.* 103(3): 890–901, 1999.
- Hammond DC. The SPAIR mammoplasty. *Clin. Plast. Surg.* 29(3): 411–421, 2002.
- Hidalgo DA. Improving safety and aesthetic results in inverted T scar breast reduction. *Plast. Reconstr. Surg.* 103(3): 874–886, 1999.
- Hidalgo DA. Y-scar vertical mammoplasty. *Plast. Reconstr. Surg.* 120(7): 1749–1754, 2007.
- Hidalgo DA, Elliot LF, Palumbo S, Casas L, Hammond D. Current trends in breast reduction. *Plast. Reconstr. Surg.* 104(3): 806–815, 1999.
- Hofmann AK, Wuestner-Hofmann MC, Bassetto F, Scarpa C, Mazzoleni F. Breast reduction: modified 'Lejour technique' in 500 large breasts. *Plast. Reconstr. Surg.* 120(5): 1095–1104; discussion 1105–1107, 2007.
- Jackson IT, Bayramicli M, Gupta M, Yavuzer R. Importance of the pedicle length measurement in reduction mammoplasty. *Plast. Reconstr. Surg.* 104(2): 398–400, 1999.
- Kakagia D, Tripsiannis G, Tsoutsos D. Breastfeeding after reduction mammoplasty: a comparison of 3 techniques. *Ann. Plast. Surg.* 55(4): 343–345, 2005.
- Kreithen J, Caffee H, Rosenberg J, Chin G, Clayman M, Lawson M, Seagle MB. A comparison of the LeJour and Wise pattern methods of breast reduction. *Ann. Plast. Surg.* 54(3): 236–241, 2005.
- Lacerna M, Spears J, Mitra A, Medina C, McCampbell E, Kiran R, Mitra A. Avoiding free nipple grafts during reduction mammoplasty in patients with gigantomastia. *Ann. Plast. Surg.* 55(1): 21–24; discussion 24, 2005.
- Lassus C. An 'all-season' mammoplasty. *Aesthet. Plast. Surg.* 10(1): 9–15, 1986.
- Lassus C. Breast reduction: evolution of a technique – a single vertical scar. *Aesthet. Plast. Surg.* 11(2): 107–112, 1987.
- Lassus C. A 30-year experience with vertical mammoplasty. *Plast. Reconstr. Surg.* 97(2): 373–380, 1996.
- Lejour M. Vertical mammoplasty and liposuction of the breast. *Plast. Reconstr. Surg.* 94(1): 100–114, 1994.
- Lejour M. Evaluation of fat in breast tissue removed by vertical mammoplasty. *Plast. Reconstr. Surg.* 99(2): 386–393, 1997.
- Lejour M. Vertical mammoplasty: early complications after 250 personal consecutive cases. *Plast. Reconstr. Surg.* 104(3): 764–770, 1999.
- Lista F, Ahmad J. Vertical scar reduction mammoplasty: a 15-year experience including a review of 250 consecutive cases. *Plast. Reconstr. Surg.* 117(7): 2152–2165, 2006.
- Mandrekas AD, Zambacos GJ, Anastasopoulos A, Hapsas DA. Reduction mammoplasty with the inferior pedicle technique: early and late complications in 371 patients. *Br. J. Plast. Surg.* 49(7): 442–446, 1996.
- Matarasso A. Suction mammoplasty: the use of suction lipectomy alone to reduce large breasts. *Clin. Plast. Surg.* 29(3): 433–443, 2002.
- Matarasso A, Courtiss EH. Suction mammoplasty: the use of suction lipectomy to reduce large breasts. *Plast. Reconstr. Surg.* 87(4): 709–717, 1991.
- McKissock PK. Reduction mammoplasty with a vertical dermal flap. *Plast. Reconstr. Surg.* 49(3): 245–252, 1972.
- McKissock PK. Reduction mammoplasty by the vertical bipedicle flap technique. Rationale and results. *Clin. Plast. Surg.* 3(2): 309–320, 1976.
- Moskovitz MJ, Baxt SA, Jain AK, Hausman RE. Liposuction breast reduction: a prospective trial in African American women. *Plast. Reconstr. Surg.* 119(2): 718–726, 2007.
- Moskovitz MJ, Muskin E, Baxt SA. Outcome study in liposuction breast reduction. *Plast. Reconstr. Surg.* 114(1): 55–60, 2004.
- Pennington DG. Improving the results of inferior pedicle breast reduction using pedicle suspension and plication. *Aesthet. Plast. Surg.* 30(4): 390–394, 2006.
- Ramon Y, Sharony Z, Moscona RA, Ullmann Y, Peled IJ. Evaluation and comparison of aesthetic results and patient satisfaction with bilateral breast reduction using the inferior pedicle and McKissock's vertical bipedicle dermal flap techniques. *Plast. Reconstr. Surg.* 106(2): 289–295, 2000.
- Restifo RJ. Early experience with SPAIR mammoplasty: a useful alternative to vertical mammoplasty. *Ann. Plast. Surg.* 42(4): 428–434, 1999.
- Ribeiro L, Accorsi A Jr., Buss A, Marcal-Pessoa M. Creation and evolution of 30 years of the inferior pedicle in reduction mammoplasties. *Plast. Reconstr. Surg.* 110(3): 960–970, 2002.
- Robbins TH. A reduction mammoplasty with the areola-nipple based on an inferior dermal pedicle. *Plast. Reconstr. Surg.* 59(1): 64–67, 1977.

- Wallace WH, Thompson WO, Smith RA, Barraza KR, Davidson SF, Thompson JT 2nd. Reduction mammoplasty using the inferior pedicle technique. *Ann. Plast. Surg.* 40(3): 235–240, 1998.
- Widgerow AD. Breast reduction with inferior pedicle fascial suspension. *Aesthet. Plast. Surg.* 29(6): 532–537, 2005.

Chapter 8

- Choupina M, Malheiro E, Pinho C, Ferreira A, Pinto A, Cardoso A, Reis J, Amarante J. Tuberous breast: a surgical challenge. *Aesthet. Plast. Surg.* 26(1): 50–53, 2002.
- DeLuca-Pytell DM, Piazza RC, Holding JC, Snyder N, Hunsicker LM, Phillips LG. The incidence of tuberous breast deformity in asymmetric and symmetric mammoplasty patients. *Plast. Reconstr. Surg.* 116(7): 1894–1899, 2005.
- Dinner MI, Dowden RV. The tubular/tuberous breast syndrome. *Ann. Plast. Surg.* 19(5): 414–420, 1987.
- Foustanos A, Zavrvides H. Surgical reconstruction of tuberous breasts. *Aesthet. Plast. Surg.* 30(3): 294–300, 2006.
- Grolleau JL, Lanfrey E, Lavigne B, Chavoin JP, Costagliola M. Breast base anomalies: treatment strategy for tuberous breasts, minor deformities, and asymmetry. *Plast. Reconstr. Surg.* 104(7): 2040–2048, 1999.
- Kneafsey B, Crawford DS, Khoo CT, Saad MN. Correction of developmental breast abnormalities with a permanent expander/implant. *Br. J. Plast. Surg.* 49(5): 302–306, 1996.
- Mandrekas AD, Zambacos GJ, Anastasopoulos A, Hapsas D, Lambrinaki N, Ioannidou-Mouzaka L. Aesthetic reconstruction of the tuberous breast deformity. *Plast. Reconstr. Surg.* 112(4): 1099–1108, 2003.
- Meara JG, Kolker A, Bartlett G, Theile R, Mutimer K, Holmes AD. Tuberous breast deformity: principles and practice. *Ann. Plast. Surg.* 45(6): 607–611, 2000.
- Muti E. Personal approach to surgical correction of the extremely hypoplastic tuberous breast. *Aesthet. Plast. Surg.* 20(5): 385–390, 1996.
- Panettiere P, Del Gaudio GA, Marchetti L, Accorsi D, Del Gaudio A. The tuberous breast syndrome. *Aesthet. Plast. Surg.* 24(6): 445–449, 2000.
- Persichetti P, Cagli B, Tenna S, Simone P, Marangi GF, Li Vecchi G. Decision making in the treatment of tuberous and tubular breasts: volume adjustment as a crucial stage in the surgical strategy. *Aesthet. Plast. Surg.* 29(6): 482–488, 2005.
- Rees TD, Aston SJ. The tuberous breast. *Clin. Plast. Surg.* 3(2): 339–347, 1976.
- Ribeiro L, Accorsi A Jr., Buss A, Pessôa MC. Short scar correction of the tuberous breast. *Clin. Plast. Surg.* 29(3): 423–431, 2002.
- Ribeiro L, Canzi W, Buss A Jr, Accorsi A Jr. Tuberous breast: a new approach. *Plast. Reconstr. Surg.* 101(1): 42–50, 1998.
- Teimourian B, Adham MN. Surgical correction of the tuberous breast. *Ann. Plast. Surg.* 10(3): 190–193, 1983.
- Toranto IR. Two-stage correction of tuberous breasts. *Plast. Reconstr. Surg.* 67(5): 642–646, 1981.
- Versaci AD, Rozzelle AA. Treatment of tuberous breasts utilizing tissue expansion. *Aesthet. Plast. Surg.* 15(4): 307–312, 1991.
- von Heimburg D, Exner K, Kruff S, Lemperle G. The tuberous breast deformity: classification and treatment. *Br. J. Plast. Surg.* 49(6): 339–345, 1996.
- Braunstein GD. Gynecomastia. *N. Engl. J. Med.* 328: 490–495, 1993.
- Cohen IK, Pozee AL, McKeown JE. Gynecomastia. In EH Courtiss (ed.), *Male Aesthetic Surgery*. St Louis, Mosby, 1991.
- Courtiss EH. Gynecomastia: analysis of 159 patients and current recommendations for treatment. *Plast. Reconstr. Surg.* 79: 740–753, 1987.
- Gingrass MK, Shermak MA. The treatment of gynecomastia with ultrasound-assisted lipoplasty. *Perspect. Plast. Surg.* 12: 101–112, 1999.
- Hammond DC, Arnold JF, Simon AM, Capraro PA. Combined use of ultrasonic liposuction with the pull-through technique for the treatment of gynecomastia. *Plast. Reconstr. Surg.* 112: 891, 2003.
- Hammond DC, Khuthaila DK, Kim J. The interlocking Gore-Tex suture for control of areolar diameter and shape. *Plast. Reconstr. Surg.* 119: 804–809, 2007.
- Hodgson EL, Fruhstorfer BH, Malata CM. Ultrasonic liposuction in the treatment of gynecomastia. *Plast. Reconstr. Surg.* 116: 646–653, 2005.
- Iwuagwu OC, Calvey TA, Ilesley D, Drew PJ. Ultrasound guided minimally invasive breast surgery (UMIBS): a superior technique for gynecomastia. *Ann. Plast. Surg.* 52: 131–133, 2004.
- Matarasso A. Suction mammoplasty: the use of suction lipectomy to reduce large breasts. *Plast. Reconstr. Surg.* 105: 2604–2607, 2000.
- Maxwell GP, Gingrass MK. Ultrasound-assisted lipoplasty: a clinical study of 250 consecutive patients. *Plast. Reconstr. Surg.* 101: 189–202, 1998.
- Morselli PG. 'Pull-through': a new technique for breast reduction in gynecomastia. *Plast. Reconstr. Surg.* 97: 450–454, 1996.
- Neuman JF. Evaluation and treatment of gynecomastia. *Am. Fam. Physician* 55: 1835–1844, 1997.
- Nydick M, Bustos J, Dale JH, Rawson RW. Gynecomastia in adolescent boys. *J. Am. Med. Assoc.* 178: 449–454, 1961.
- Persichetti P, Berloco M, Casadei RM, Marangi GF, Di Lella F, Nobili AM. Gynecomastia and the complete circumareolar approach in the surgical management of skin redundancy. *Plast. Reconstr. Surg.* 107(4): 948–954, 2001.
- Prado AC, Castillo PF. Minimal surgical access to treat gynecomastia with the use of a power-assisted arthroscopic-endoscopic cartilage shaver. *Plast. Reconstr. Surg.* 115(3): 939–942, 2005.
- Ramon Y, Fodor L, Peled JJ, Eldor L, Egozi D, Ullmann Y. Multimodality gynecomastia repair by cross-chest power-assisted superficial liposuction combined with endoscopic-assisted pull-through excision. *Ann. Plast. Surg.* 55(6): 591–594, 2005.
- Rohrich RJ, Beran SJ, Kenkel JM, Adams WP, DiSpaltro F. Extending the role of liposuction in body contouring with ultrasound-assisted liposuction. *Plast. Reconstr. Surg.* 101: 1090–1102, 1998.
- Rohrich RJ, Ha RY, Kenkel JM, Adams WP Jr. Classification and management of gynecomastia: defining the role of ultrasound-assisted liposuction. *Plast. Reconstr. Surg.* 111(2): 909–923, 2003.
- Rohrich RJ, Raniere J Jr., Beran SJ, Kenkel JM. Patient evaluation and indications for ultrasound-assisted lipoplasty. *Clin. Plast. Surg.* 26: 269–278, 1999.
- Rosenberg GJ. Gynecomastia: suction lipectomy as a contemporary solution. *Plast. Reconstr. Surg.* 80(3): 379–386, 1987.
- Simon BE, Hoffman S, Kahn S. Classification and surgical correction of gynecomastia. *Plast. Reconstr. Surg.* 51: 48–52, 1973.
- Strasser EJ. Ultrasound aspiration for gynecomastia. *Plast. Reconstr. Surg.* 112(7): 1967–1969, 2003.
- Walgenbach KJ, Riabikhin AW, Galla TJ et al. Effect of ultrasonic assisted lipectomy on breast tissue: histological findings. *Aesthet. Plast. Surg.* 25(2): 85–88, 2001.

Chapter 9

- Bracaglia R, Fortunato R, Gentileschi S, Seccia A, Farallo E. Our experience with the so-called pull-through technique combined with liposuction for management of gynecomastia. *Ann. Plast. Surg.* 53: 22, 2004.

INDEX

NB: Page numbers in **bold** refer to figures

A

Accessory nipples, **1, 2**
Accessory parenchymal development, **1**
Adolescent gynecomastia, **195, 195, 196, 199**
 preoperative appearance, **199, 202**
 postoperative appearance, **199, 202**
Aerobic activities, **157**
Age *see* Senescent gynecomastia
Allergies, **11**
American Cancer Society, **149**
Anatomically shaped implants
 saline, **35–37**
 rotation, **37**
 rupture, **37**
 shape, **35–36, 36**
 silicone gel, **25–28**
 cohesive, **38, 42–43, 47, 53, 58, 69, 131–133, 132, 136–137**
 full-height mid-profile, **60**
 construction, **19, 21**
 height, **37**
 incision length, **37**
 measurement, **57**
 orientation, **37, 69**
 semi-cohesive textured, **27**
 surface texture, **29–30, 31**
 textured cohesive, **27, 28, 37, 37, 42, 43, 75**
 full-height full-profile, **76**
 full-height mid-profile, **74**
 mid-height full-profile, **78–79, 80**
 mid-height low-profile, **59, 72, 73, 78, 79, 80**
 vs round, **77, 77, 78, 79**
Anatomically shaped tissue expanders, **33**
Anatomy, **1–9**
 arterial, **2–3, 3**
 embryology, **1–2, 1, 2**
 fascial support, **4, 5, 5, 6, 7, 8, 9**
 fat, **5–6**
 innervation, **3, 3**
 lymphatic drainage, **3**
 muscles, **7–9, 9**
 parenchyma, **5–6**
 physiologic/structural, **1**
 skin, **6–7**
 venous drainage, **3**
Anesthesia, **14, 156**

Angling superiorly, **66**
Animation, breast, **46, 47, 48, 49**
Areola, **2**
 dimensions, **54, 153**
 elasticity, **91, 91**
 elongation, **90**
 enlarged, **186, 187**
 herniation, **98–100, 99, 186, 187**
 incision, **92, 186**
 see also Periareolar incision
 necrosis, **92**
 -reducing purse string procedure, **53**
 shape, asymmetrical, **90–91, 90**
 spreading, **54, 91, 91, 92, 93, 96, 98, 99**
 widening, **91, 91–93, 95, 96, 97, 103, 115–117**
Areolar markers, **121, 164**
Arm abduction test, **12, 13, 14**
Armboards, **12, 13, 14, 14, 16, 16, 18**
Asymmetry, **12, 151–152**
 breast, **87, 132, 166, 186–187**
 base width, **151, 151**
 chest wall, **55**
 inframammary fold (IMF), **54, 55, 87, 89, 114, 138**
 muscle release, **48**
 nipple-areola complex (NAC), **53–54, 54, 88, 119–120**
 shoulder height, **13**
 tuberous deformity, **86, 183–184, 185, 188, 188**
Augmentation, **39–81**
 evaluation, **51–64**
 variability, **39, 39**
 implant malposition, **8, 15, 43, 44, 46, 67, 67**
 patient marking *see under* Marking, patient
 periareolar approach, **75–76, 76, 131, 132, 133**
 planning, **19, 40–51**
 preoperative appearance, **13, 20, 39, 39, 59, 60, 134**
 postoperative appearance, **21, 29, 59, 60, 134**
 results, **58–61**
 type 1, **58, 59, 71**
 type 2, **59, 60, 70–74, 76, 77, 78–79, 80**
 type 3, **60, 60, 78**
 type 4, **61, 61**
 subglandular, **7, 8, 20**

 preoperative appearance, **20, 53–54, 60, 70–73, 78–80, 131, 133, 136, 145**
 postoperative appearance, **9, 20, 53–54, 60–61, 70–73, 78–81, 131, 133, 136, 145**
 subglandular, partial, **77**
 subpectoral, postoperative appearance, **15, 36**
 subpectoral, partial
 preoperative appearance, **74**
 postoperative appearance, **21, 47, 61, 74**
 surgical strategies, **40, 40**
 surgical technique, **64–81**
Augmentation mastopexy, **129–145, 185**
 indications, **130–134, 130**
 patient marking, **137–139, 138, 139, 140, 141**
 preoperative appearance, **90, 103, 117, 129–130, 132, 138–140, 145**
 postoperative appearance, **90, 132, 139, 140**
 recurrent ptosis, **114, 116**
 smaller implants, **91**
 staging, **134, 135–136, 137**
 surgical technique, **134–145**
 see also Circumvertical augmentation mastopexy
Autoaugmentation, **145, 145, 164, 171, 172**
Axillary breast development, preoperative appearance, **2**

B

Bacteria, **68**
 breast duct, **41, 42, 42, 44**
 seeding of implant space, **46, 68**
Base diameter
 breast, **55, 56, 102, 115–116, 132, 157**
 implant, **34, 57–58, 58**
 as primary variable, **62–63, 62**
Base width, breast, **151, 151**
Biocell, **30–33, 32, 37**
Biofilm formation, **42**
Biopsy
 history, **51, 159**
 scars, previous, **88, 148**
Bleeding
 blunt pocket development, **77**
 transaxillary incision, **43**
 transumbilical incision, **43**

- Blood supply
to breasts, 2–3, **3**, **122**
to flaps, 105, 108
to pectoralis major, 9
see also Nipple-areola complex (NAC),
blood supply to
- Blunt pocket development, 77
- Body mass index (BMI), **198**
- Bodylogic Implant Selection System, 81
- Breast cancer, 51, 88, 149, 159
- Breast-feeding, 51, 81, **81**, 83, 89, 147–148,
150–151
- Bud, breast
fibrous, 198
isolated, 195
subareolar, **197**, **203**
- Bunching, tissue, 93, 204
- C**
- Calipers, skin fold measuring, 55, 56, **56**, **58**
- Cancer
breast, 51, 88, 149, 159
intraductal carcinoma, **114**, **115**
lobular carcinoma, **157**
- Capsular contracture, 22, **27**, 30, 33–34, 38
augmentation, 42–44, 46, 48, **48**, **68**, **68**,
72
- Capsulectomy, total, 11, **22**, **30**
- Chest wall asymmetry, 55
- Childbearing, 147–148
see also Pregnancy
- Circumvertical augmentation mastopexy,
142–144
indications, 142
patient marking, 142, **143**
preoperative appearance, **135**, **143**
postoperative appearance, **135**, **144**
surgical technique, 142, **143–144**, 144
- Circumvertical inferior pedicle reduction/
lift, **191**
- Circumvertical mastopexy, **112**, 114, **115**,
116, 161
patient marking, **115**, **117**, **118**
preoperative appearance, **115**
postoperative appearance, **116**
resuspension, 116, **118**, **119**
skin only, 116
surgical options, **113**
- Circumvertical pattern, 103, **190**
skin envelope, 133
recontouring, **157**
reduction, 100–102, **101**, **103–104**,
156
retailoring, 204–205, **206–207**
tightening procedure, **206**
- Circumvertical SPAIR mastopexy, patient
markings, **109**
- Cleavage, 52–53, **53**
- ‘Cobblestone’ texture, fibrous tissue, 151
- Collagen, 33, **170**
- Complications, 11
- Confidence, patient, 11
- Connective tissue
framework, **85**
support, 5
- Consent, informed, 11
- Consistency, breast, 151
- Constriction
breast base, **185**, **187**, **189**
layer model, 74–75
- Contamination, 68, **68**, 69, **69**
pillow, 14
see also Bacteria
- Contour, breast
deformity, 207–208
lower pole, 42, **42**, 161
ptosis grade, 89
recontouring, **158**, **200**, **201**, **202**, **206**
upper pole, 36, **36**, 37, **110**, 151, **152**,
158, **165**
- Cooper’s ligaments, 4, 4
- Crescent mastopexy, 90, **90**
- Cross-hatched orientation marks, 173, **174**
- D**
- Dacron patches, 29, **30**
- Dermabond tissue glue, 163, 200
- Dermal cuff, 92, **107**, **111**, 121, 139, 169
- Dermal flaps, 110, **111–112**
- Dermal shelf, 92–93, 95–96, 95, 100, 123,
123, 125
marking, **121**
- Diabetes, 148
- Direct excision, gynecomastia, 198–199,
199
- Direct local resection, skin retailoring,
203
- Double bubble deformity, 35, **129**
- Double capsule formation, 31–33, **32**
- ‘Dual plane’ technique, 74–75
- Dual-chambered implants, 35
- E**
- Ectopic nipple, 1
- Elasticity
differential, areola vs breast skin, 98
outer shell, implant, 25
skin envelope, 6, 42, 79, **79**, 85, 98, **99**,
100
grading, 58, **58**
soft tissue, 52
- Embarrassment, 197
- Embryology, 1–2, 1, **2**
- Endoscopic technique, 43, 77
- Epinephrine, **170**, 198
- Evaluation
augmentation, 51–64
variability, 39, **39**
breast reduction, 147–151, **150**
for optimal approach, 11–14, **12**, **13**, **15**
preoperative, 39, **39**, 51–64
ptosis, 87–90
- Examination, 51, 89, 151–154, 197
- Excision
direct, gynecomastia, 198–199, **199**
insufficient, gynecomastia, 208
- Exercises, implant displacement, 72
- Expanders, tissue, 31, 43
anatomically shaped, 33
/implants combination devices, 191–193
reconstruction, **157–158**, 189, 191–193,
192, **193**
vs implants, 186
- Expansion strategy, staged approach, 193
- Expectations, patient, 39, 51, 61, 89, 149,
152, 154
- F**
- Family history, 149, 159
- Fascia, **49**, **50**, 75
architecture, 1
constriction, 67
‘fascial sparing’ technique, 66
support, 4, 5, 5, 6, 7, 8, 9
- Fat, 1, 5–6, 92
necrosis, 108
superficial layer, 76
thick layer, 19, 66, 67
- Fibrous bands, in tuberous deformity, 183,
184
- Fibrous breast bud, 198
- Filling, implant, 22–25, **22**, **23**, **24**, 27, 42,
76
closed system, 69, **69**
fill volume, 22–27, **22–24**, 34–35, 43
fixed volume, 25, 34
material, 29
underfilled, **26**, **28**, 29
- Flaps
blood supply to, 105, 108
dissection strategy, 169
inferiorly based, 105, 108, **109**, **110**
interlocking Gore-Tex sutures, 97
internal, 105–112
inverted T inferior pedicle reduction, **179**
lateral, 122–123, 160, **174**
latissimus dorsi, **107**, **115**, **118**, **157**
medial, **107**, 122, 160
pedicle, 105, **109–110**
SPAIR mammoplasty, 169, **170**, 171, **172**
SPAIR mastopexy, 121–123, **121**, **122**
strategy for creating, **170**
superior, 122–123, **172**
TRAM reconstruction, **114**, **193**
- Flattened appearance
breast, 92, 100, 102
implants, 73
lower pole, 45, **46**, **47**
- Food and Drug Administration (FDA), 35, 37
- G**
- Gastric bypass procedure, **84**, **150**, **206**
- Gel implants *see* Anatomically shaped
implants; Silicone gel implants

- Gigantomastia, 169
 preoperative appearance, 180
- Glandular ptosis, 107
- Gore-Tex *see* Interlocking Gore-Tex sutures
- Grafts, 180–181
 full thickness technique, 181
- Gynecomastia, 195–208
 adolescent, 195, 195, 196
 preoperative appearance, 199, 202
 postoperative appearance, 199, 202
- bilateral
 preoperative appearance, 201, 202, 208
 postoperative appearance, 202, 203, 208
- complication management, 207–208
- excision, 206
- indications, 197–198, 198
- pathologic, 196–197
- preoperative appearance, 205, 206
- postoperative appearance, 205, 206, 207
- senescent, 196, 197
 preoperative appearance, 200, 204
 postoperative, 200, 204
- surgical technique, 198–208
- tuberous breast, 195, 196
- unilateral, 199
- ## H
- Headrest, 14
- Height
 breast, 57, 57, 58
 implant, 37
 patient, 51, 151, 178
- Hematoma, 207
- Hemostasis, 20, 41, 66, 67, 77, 170, 198
- History taking, 197
 breast cancer, 88
 family, 149
 medical, 148
 reproductive, 147–148
 smoking, 149, 153, 159
 social, 149
 surgical, 148
- Horizontal pattern
 mattress bite, 100
 skin retailoring, 205, 207, 208
- Hormone administration, exogenous,
 196–197
- Hypertension, 148
- Hypertrophy, breast, 85
- Hypoplasia, 59, 79, 80, 129, 183–185,
 189–190
- ## I
- Ideal breast, 83, 84
- Implants, 19–38
 anatomically shaped *see* Anatomically
 shaped implants
 assessment, 25–26, 55
 behavior of, 19–29, 22, 23, 24, 25, 26,
 27, 28, 29
- ‘bottoming out’, 44
- complications, 89
- construction of, 19, 21
- displacement exercises, 69, 72
- /expander combination devices, 191–193
- vs expanders, 186, 191
- ‘feel’ effect, 19
- filling *see* Filling, implant
- flattening, 73
- high-riding, 45
- insertion of, 67, 68, 69, 75
- malpositioned, 8, 15, 43, 44, 45, 46, 67,
 67, 129
- outer shell *see* Shell, outer implant
- reconstruction, 189, 189, 190
- round *see* Round implants
- saline *see* Saline implants
- selection of, 19, 38, 40, 50–51, 189
 primary variable methods, 61–64, 62
- silicone gel *see* Silicone gel implants
- sizers, 63, 63, 64, 67, 139, 142, 143
- stacking, 29
- surface area/volume relationship, 28
- surface texturing, 29–34, 30, 31, 42, 43, 75
- types of, 34–37
- visibility of, 48–49, 73
- weight of, 5
see also Wrinkling
- Incision
 areolar, 92, 186
 for augmentation, 40–44, 41, 69
 inframammary fold (IMF), 40–41, 41,
 108, 136
 length of, 42, 42, 75, 76
 stab, 156, 202, 203
 vertical, 108
see also Periareolar incision
- Inferior parenchymal flap technique, 105,
 108
- Inferior pedicle technique, 150, 152–153,
 153, 174
see also under Wise pattern inverted T
 approach
- Inferior pole tissues, 159–160, 160, 174
 plicating of, 108
 ptotic, 165
- Inflammatory bowel disease, 148
- Inflammatory response, 34
- Inframammary fold (IMF), 1, 2, 5, 6, 7, 8, 11
 asymmetry, 89, 114, 138
 constricted, 190
 incision, 108
 marking, 163, 167
 measurements, 52, 52, 89, 152, 153
 nipple location
 above, 131, 131, 132
 at, 132–133, 133, 134
 below, 133–134, 135
 nipple-areola complex (NAC) ptosis, 86,
 86–87, 131
 position of, 55, 66, 137–138, 139, 171,
 183, 184–186, 184
 ptosis grade, 89
- scars, 40, 41, 102, 133, 137
- Inframammary fold (IMF), augmentation and
 asymmetry, 54, 55, 87
 incision for, 40–41, 41, 136
 location, 84
 lowering, 78, 79, 80, 81, 132
 measurements, 52, 52
 periareolar, 42, 75–76
 subglandular, 64–72
 implant insertion, 67, 68, 69
 incision closure, 69
 patient marking, 64–65, 64, 65
 pocket development, 65–67, 65, 66
 postoperative care, 69, 70, 71, 72, 73
 subpectoral, 72–75, 74
 ‘dual plane’ technique, 74–75
- Ingrowth, 33, 34
- Innervation, 3, 3
 to nipple-areola complex (NAC), 3
- Intercostal arteries, 9
- Intercostal nerves, 3
- Intercostal perforators, 66, 66
- Interlocking Gore-Tex sutures
 augmentation mastopexy, 139, 139, 142,
 143, 144, 145
 breast reduction, 162, 173–174, 175
 gynecomastia, 205
 mastopexy, 93, 95–98, 96–99, 112–120
passim, 120, 125, 163, 165
 patient marking, 97
 purse string, 189, 204, 205
 augmentation mastopexy, 136,
 139–142, 140–141
 breast reduction, 163, 168, 169
 mastopexy, 117–118, 121, 125–126
 tuberous deformity, 186, 190
- Internal mammary perforators, 9, 66, 66,
 107, 163, 171
- Internal parenchymal plication, 115
- Internal suture suspension strategy, 181
- Interpersonal relationships, 149
- Intraductal carcinoma, 114, 115
- Intraoperative considerations, 14, 15,
 16–18, 16, 17, 18
- Inverted T approach *see* Wise pattern
 inverted T approach
- Ischemia, 108, 152
 complications, 153
 nipple-areola complex (NAC), 92, 181
 pressure-induced localized, 16
- Isolated breast bud, 195
- ## K
- Key staples, 123, 123, 174
- Knots, 92–93, 96
 bulky, 94
 complex of, 95
- ## L
- Laboratory tests, 197
- Lap sponges, 67

Laser leveller, 12, 13
 Latissimus dorsi flap, 107, 115, 118, 157
 Lidocaine, 170, 198
 Liposuction, 156, 200, 200
 debulking with, 160
 gynecomastia, 201, 201, 203, 204
 recontouring
 patient marking, 200, 201, 202, 206, 208
 postoperative appearance, 200, 201, 202, 206
 uneven application of, 207
 Liposuction breast reduction (LBR), 155–159
 patient marking, 155, 156, 157
 preoperative appearance, 157, 158
 postoperative appearance, 157–158
 surgical strategy, 155–156, 155
 surgical technique, 156–157, 157, 158, 159
 Lobular carcinoma, 157
 Lower pole tissues, 160
 contour deformity, 42, 42, 161
 expansion, 85
 flattening, 45, 46, 47
 full rounded contour, 83
 shape, 55
 skin pinching, 142
 skin texture, 151, 152
 Lymphatic drainage, 3

M

Macromastia, 149, 151, 152, 152
 asymmetric, 86, 188
 preoperative appearance, 155, 157
 postoperative appearance, 155
 tuberous deformity, 187, 188, 193
 Magnetic resonance imaging (MRI), 25, 26, 155, 197
 Males *see* Gynecomastia
 Mammoplasty, modified vertical, 161
 Mammograms, 46, 51, 89, 108, 110, 149, 159
 Mandrils, 19, 21, 34
 Marking, patient, 11, 12, 12
 augmentation
 inframammary fold (IMF) subglandular, 64–65, 64, 65
 mammoplasty, 80, 137
 augmentation mastopexy, periareolar, 137–139, 138, 139, 140, 141
 breast reduction, 111
 bilateral, 176, 177, 180, 181
 inferior pedicle, 178, 178, 179, 180
 vertical, 161–163, 161–162
 circumvertical mastopexy, 115, 117, 118
 augmentation, 142, 143
 SPAIR, 109
 gynecomastia, 205, 206
 adolescent, 202
 bilateral, 202
 senescent, 204
 incision, periareolar, 93

interlocking Gore-Tex sutures, 97
 liposuction, 206, 208
 recontouring, 200, 201, 202
 liposuction breast reduction (LBR), 155, 156, 157
 mastopexy, periareolar, 94, 107–108
 reconstruction
 latissimus dorsi musculocutaneous flap, 115, 118
 TRAM flap, 114, 193
 resuspension, breast, 119, 145
 SPAIR
 mammoplasty, 163, 167, 167–168, 169, 176, 176–177
 mastopexy, 109, 117, 119–120, 120–121, 126, 127–128
 tissue expander removal, 193
 tuberous breasts, 188, 189, 190, 192, 193
 tuberous deformity, 185
 Wise pattern inverted T, 102
 mastopexy, 104, 105, 181
 Mastectomy, 107, 114, 149
 Mastopexy, 83–128
 breast ptosis, defined, 83–87
 operative strategies, 112–126, 113
 preoperative appearance, 131
 postoperative care, 126, 128
 ptosis evaluation, 87–90
 surgical techniques, 90–112, 113
 tuberous deformity, 188
 see also Augmentation mastopexy
 Measurements, 28, 152–154
 clavicle to nipple, 89
 inferior pedicle inverted T breast reduction, 178
 inframammary fold (IMF), 52, 52
 to nipple, 89, 152, 153
 intermammary distance, 89
 midclavicle to nipple, 152, 153
 SPAIR mammoplasty, 163, 167, 167–168, 169
 sternal notch to nipple, 89, 152, 153
 upper pole thickness, 56–57
 see also Positional measurements, augmentation and; Shaping measurements, augmentation
 Medial pectoral nerve, 9
 Medical history, 148
 Meme implant, 29, 31
 Mentor Corporation, 81
 Mesh, 110, 112, 112
 Milk line, 1, 1, 2
 Muscles, 7–9, 9
 Muscular sling technique, 108

N

Necrosis
 areolar, 92
 fat, 108
 of nipple-areola complex (NAC), 152, 152, 159
 pressure, 16
 Nerve compression, 16, 16

Nerve supply, 3, 3
 to pectoralis major, 9
 Nipple-areola complex (NAC), 1
 accessory nipple, 1, 2
 asymmetry, 53–54, 54, 88, 119–120
 blood supply to, 2, 4–5, 5, 130, 204
 breast reduction, 159, 163, 175
 management of, 154
 mastopexy, 92, 100, 105, 122
 dimensions, 53, 54
 discharge, nipple, 148
 ectopic nipple, 1
 graft technique, 180–181
 high-riding, 105, 163
 ischemia, 92, 181
 isolated breast bud, 195
 lifting, 87, 90–100, 114, 129, 133, 134, 137, 157–158
 location, 51–52, 55
 above inframammary fold (IMF), 131, 131, 132
 at inframammary fold (IMF), 132–133, 133, 134
 augmentation mastopexy, 130–134, 130, 139, 139
 below inframammary fold (IMF), 133–134, 135
 gynecomastia, 203, 205
 mastopexy, 83, 84, 85, 89
 malposition, 85, 115
 necrosis, 152, 152, 159
 ptosis *see under* Ptosis
 relative to breast mound, 18
 scar, 105
 sensitivity of, 42–43
 SPAIR mammoplasty, 173–174, 175, 176–177

O

Obesity, 83, 84
 breast reduction, 150, 151, 153, 159
 gynecomastia, 195, 196, 198, 198, 207, 208
 Operating table, 12, 14, 15, 16
 Opsite dressings, 126, 128, 163, 200
 Overdevelopment, breast, 149–150

P

Parenchyma, 1, 5–6, 49, 50, 92
 constriction, 67
 excess, 171
 management of, 154
 plicating of, 104–105, 107, 108, 113, 114, 115
 ptotic, 102
 release of, 42
 suture fixation, 102–105, 106
 thick layer, 19
 vertical breast reduction, 159–160, 160
 Pathologic gynecomastia, 196–197
 Patient expectations, 39, 51, 61, 89, 149, 152, 154

- Patient height, 100
 Patient marking *see* Marking, patient
 Pectoralis major muscle, 1, 9, 44–45, 49, 50
 blood supply to, 9
 blunt pocket development, 77
 breast resuspension, 108
 contraction of, 15, 46, 47, 48–49, 48, 79
 fibers of origin, 43
 inferior, 44, 44, 45, 46
 gynecomastia, 207
 inframammary fold (IMF) augmentation, 72–74, 75
 muscular definition, 199
 nerve supply to, 9
 symmetric release of, 46, 46, 48
 upper pole reshaping, 105, 108
 Pectoralis minor muscle, 1, 9, 73, 77
 Pedicle, 159, 171
 flaps, 105, 109–110
 management, 4–5, 5
 Perforators, internal mammary, 9, 66, 66, 107, 163, 171
 Periareolar augmentation, 75–76, 76, 131, 132–133
 incision, 41–43, 41, 42
 length calculation, 42, 42
 mastopexy, 92
 Periareolar augmentation mastopexy, 137–142
 indications, 137
 patient marking, 137–139, 138, 139, 140, 141
 preoperative appearance, 117
 postoperative appearance, 117, 141
 surgical technique, 139, 140, 141, 142
 Periareolar defect, 204
 breast reduction, 158, 159, 175
 control of, 125–126, 125, 126, 127, 128
 dermal shelf, 92
 interlocking Gore-Tex technique for closure, 112
 mastopexy, 93, 94–95, 101
 reduction of, 101, 104
 Periareolar incision, 54, 91, 92–93, 93, 170
 augmentation, 41–43, 41, 42
 closure, 91, 99, 101, 103
 length, 100
 patient marking, 93
 tuberous deformity, 186, 189, 193
 Periareolar lift, 112–113
 pleating, 101
 suture placement, 92–93, 93, 94–95
 Periareolar mastopexy, 112, 114
 with internal shaping, 113, 115
 patient marking, 94, 107–108
 preoperative appearance, 76
 postoperative appearance, 48, 76
 surgical options, 113
 Periareolar pattern
 cardinal landmarks of, 168, 169
 location of, 168
 parenchymal plication strategy, 103
 skin reduction, 100, 101, 203–204
 Photographs, 12–14, 14, 15
 of patient marking, 12, 169
 preoperative, 17
 Physical discomfort, 147, 147
 Pinch thickness
 medial/lateral, 55–56, 56
 upper pole, 56–57, 56
 Planning, preoperative, 40–51
 Plication, 132, 163
 inferior skin envelope, 173
 internal suture, 171
 ‘J’-shaped line of, 142
 line, 123–124, 124, 174
 parenchyma, 104–105, 107, 108, 113, 114, 115
 pattern, 173
 ptotic inferior pole tissues, 165
 skin, 135
 strategies, 101, 101, 104–105
 uneven, 93
 vertical, 103, 106, 133, 142, 143, 144
 SPAIR mastopexy, 123–125, 123–124
 Pocket development, 43
 blunt, 77
 inframammary fold (IMF) augmentation, 65–67, 65, 66
 Pocket plane, augmentation, 40, 44–50
 Polyurethane foam, 29–30, 31, 33, 34
 Positional breast ptosis, 83, 83, 84, 117
 Positional measurements, augmentation, 51–55
 breast volume, 55, 55
 chest wall asymmetry, 55
 clavicle to nipple, 51–52, 51
 inframammary fold (IMF)
 asymmetry, 54, 55
 to nipple, 52, 52
 intermammary distance, 52–53, 53
 nipple-areola complex (NAC)
 asymmetry, 53–54, 54
 dimensions, 53, 54
 sternal notch to nipple, 52, 52
 Postoperative care, 157
 inframammary fold (IMF) augmentation, 69, 70, 71, 72, 73
 mastopexy, 126, 128
 Power assisted liposuction (PAL), 155, 155, 156, 157, 158, 200
 Pregnancy, 51, 80, 80–81, 81, 83, 89, 147–148, 150
 reproductive history, 147–148
 Preoperative evaluation, 39, 39, 51–64
 for optimal approach, 11–14, 12, 13, 15
 Preoperative planning, 40–51
 Pressure
 -induced localized ischemia, 16
 intraluminal, 23
 necrosis, 16
 Projection
 implant, 34, 35
 nipple-areola complex (NAC), point of maximal, 83
 as primary variable, 62, 62, 63
 Prolene suture, 105
 Pseudocapsules, 32–33, 32
 Pseudoherniation, 183, 183, 185
 Pseudoptosis, 85, 87, 87, 131, 132, 134
 Ptosis, 78, 152
 adolescent gynecomastia, 196
 defined, 83–87
 degree of, 50–51
 evaluation, 87–90
 glandular, 107
 grade, breast contour, 89
 gynecomastia, 198
 nipple-areola complex (NAC), 78, 129, 185, 205
 classification, 86
 grading, 86, 86
 /inframammary fold (IMF), 86, 86–87
 mastopexy, 83, 85–87, 85–89, 100, 108, 114–115, 119
 periareolar mastopexy, 112
 positional, 83, 83, 84, 117, 126
 pre/postoperative appearance, 103–104, 108, 114, 115, 129, 134, 135
 recurrent, 114, 116
 skin, 85, 85, 88, 89
 envelope, 156
 surgical management of, 113
 tuberous deformity, 184
 volume, 83, 84, 85, 85, 115, 119
 Pubertal development, 149
 Pull through technique, 201, 203
 Purse string sutures, 157, 160–161
 areolar-reducing procedure, 53
 closure, 99, 99, 101, 164
 simple, 173–174
 interlocking Gore-Tex *see under*
 Interlocking Gore-Tex sutures
 periareolar, 91, 92, 93
 support, 95
 technique, 91, 93, 94–95, 96, 98, 100, 107, 108
 Pyoderma gangrenosum, 148, 148
 R
 Reconstruction, 75, 107, 112–113, 115
 expanders, 157–158, 189, 191–193, 192, 193
 implants, 189, 189, 190
 patient marking, 114, 115, 118, 193
 soft tissue, 187–189, 187, 188
 TRAM flap, 114, 193
 Rectus abdominis, 1, 9
 Reduction, breast, 147–182
 examination, 151–154
 measurements, 153
 patient marking, 111
 preoperative evaluation, 147–151, 150
 postoperative appearance, 148, 150
 surgical strategy, 154
 surgical technique, 154–181
 surgical timing, 149–150, 150
 tuberous deformity, 188
 see also Volume reduction
 Replicon implant, 29, 31
 Reproductive history, 147–148

- Reshaping, breast, 159
 mastopexy, 102–112, **105**
 SPAIR mastopexy, **122**, **123**
- Resuspension, 108
 augmentation mastopexy, 144–145, **145**
 circumvertical mastopexy, 116, **118**, **119**
 mastopexy, 108, 110, **111**
 strategy, 116
- Rotation, 29
- Round implants, 34–35, 69, 132
 profiles, 34
 saline *see* Saline implants
 shape, 34
 silicone gel *see* Silicone gel implants
 vs anatomic, 77, **77**, **78**, **79**
see also Wrinkling
- S**
- Safety, patient, 11
- Saline implants, 43, **69**, 76
 ease of use, 38
 fully filled, **28**
 incisions, 42
 insertion of, 69, 75
 round, 20–22, **22**, **23**, **23**, **25**, **25**, **34**
 smooth round, **24**, **47**, **54**
 high-profile, **61**, **70**, **71**, **77**, **143**
 moderate-profile, **60**, **61**, **71**
 soft tissue, 57
see also Anatomically shaped implants;
 Wrinkling
- ‘Saucer’ deformity, 201
- Scalloping edge distortion, 22–23, **23**, **24**,
 25
- Scarpa’s fascia, 3–5, 4–9, 65–66, **65**, 76,
137, 142, 160, 163, **164**
- Scars, 123
 areolar, **207**
 biopsy, 88, 148
 contraction, 93
 fine line healing, **116**
 inframammary fold (IMF), 7, 8, 9
 augmentation, 40, **41**, **72**, 79, **79**
 augmentation mastopexy, 130, **133**,
 137
 breast reduction, **155**, 159, 175
 gynecomastia, **203**, 207
 limiting, 90, 132, 201
 liposuction breast reduction (LBR), 155
 nipple-areola complex (NAC), **105**
 patient marking, 156
 pattern in skin, 100
 periareolar, 41, **41**, 101, 112, 113, **176**,
 201, **206**
 personal relationships, 149
 short scar techniques, 102
 stabilization, 91
 subareolar, **199**
 transaxillary, 43, **43**, 130
 treatment, 128, 163
 vertical, 102, **104**, **116**, **128**, **132**, **133**,
 135, 142, **176**, 207
 widened, 92, 99, **137**
- Wise pattern inverted T, 102, **206**
see also SPAIR entries
- Senescent gynecomastia, 196, **197**, **200**
 preoperative appearance, **204**
 postoperative appearance, **204**
- Sensation, retaining, 43
- Septum, 4, **4**, **5**, **49**, **50**, 66, **170**, 171
- Serratus anterior muscle, 1, 9, 44–45, **44**
- Shape, areolar, 90–91, **90**
- Shape, breast, **17**, **18**, 55, 74, **150**
 implant shape, 50, 51
 management of, 154
 /size, 46, 61, 88, 142, 148
 subglandular pocket, 48
 vertical technique, 124, 161
- Shape, implant, 19, 50, 51
 assessment, 25–26
- Shaping, breast, **172**
 constricting layer model, 74–75
 maneuvers, **122**, 173
 SPAIR mammoplasty, 171–173, **172**
see also Reshaping, breast
- Shaping measurements, augmentation,
 55–58
 breast base diameter, 55, 56
 breast height, 57, 57, 58
 implant base diameter, 57–58, 58
 medial/lateral pinch thickness, 55–56, **56**
 upper pole pinch thickness, 56–57, **56**
see also Reshaping, breast
- ‘Sharpie’ brand of markers, 11, **12**
- Shell, outer implant, 19, **21**, **28**, 76
 cracks in, **27**, 75
 design, 22
 surface texture, 30, 42, 43, 75
 Biocell, 30–33, **32**, 37
 Siltex, 33, **33**, 34, 37
- Short scar strategies, 154
see also SPAIR (short scar, periareolar,
 inferior pedicle, reduction) *entries*
- Shoulder
 level, **13**, 17, **17**
 position, 12
- Silicone gel implants, 48, **59**, **60**
 ease of use, 38
 fully filled, **28**
 gel bleed, 48
 insertion of, 69
 round, 23–25, **25**, **30**, **31**, **34**, 57, 69,
 75–76
 smooth round, 30, 38, **135**, **145**
 high-profile, **24**, **35**, **61**, **190**
 moderate-profile, **24**, **26**, **189**, **191**,
 192
 soft tissue, 57
 textured round, 42
see also Anatomically shaped implants;
 Wrinkling
- Siltex, 33, **33**
 surface, 34, 37
- Size, breast, 148, 149, 150, **150**, 159
 /shape, 46, 61, 88, 142, 148
 smaller appearance, 89, 89
- Sizers, implant, 63, **63**, **64**, 67, 139, 142, **143**
- Skin
 anatomy, 1, 6–7
 elasticity, 6, 42, 83, **85**, 98, **99**, 100
 excess, 154, 156, 160, 208
 misalignment, 75
 only circumvertical mastopexy, 116
 plication of, **135**
 ptosis, 85, **85**, **88**, 89
 reduction technique, circumvertical,
 100–102, **101**, **103–104**
 stretching, 100
 texture, lower pole, 151, **152**
- Skin envelope, 98, 147–148
 augmentation results, 58–61, **59**, **60**, **61**
 characteristics, 58–61
 grading, **59**
 elasticity, 79
 managing, mastopexy, 100–102, **113**
 plication of, 173
 ptosis, **196**
 recontouring, **158**
 reduction, 98, 156, 201, 203
 SPAIR mammoplasty, 172, **174**
 to volume relationship, 35
 tuberous breast, 184–186, **185**
 wrinkling in, **205**
- Skin retailoring, 201, 203–207, **204**, **206**
 circumvertical pattern, 204–205,
 206–207
 direct local resection, 203
 horizontal pattern, 205, 207, **208**
 periareolar pattern, 203–204
- Skip areas, dermal shelf, 93
- Smoking, 149, 153, 159
- ‘Snoopy dog’ type deformity, 44, **45**, 116
- Social history, 149
- Soft tissue
 constriction, **190**, 191
 distortion, 43
 elasticity, 52
 expansion, 83
 framework, 19, 74
 layer, 40
 paucity of, **20**
 pinch thickness, 50, 55, 56–57, **56**, 58
 reconstruction, 187–189, **187**, **188**
 recurrent ptosis of, 116
 relaxation, **119**
 release, 80, 185
 wrinkling, **28**
- SPAIR (short scar, periareolar, inferior
 pedicle, reduction) technique,
 tuberous deformity, 187–188, **187**,
188, **193**
- SPAIR mammoplasty, 163–175
 marking for skin envelope reduction,
 156
 patient marking, 163, 167, **167–168**, 169,
 176–177
 preoperative appearance, **167–168**, 176,
 177
 postoperative appearance, **148**, **175**, **176**,
 177
 surgical strategy, 163

- surgical technique, 169–174
 initial dissection, 169, **170–171**, 171
 nipple-areola complex (NAC)
 management, 173–174, **175**,
176–177
 shaping, 171–173, **172**
 skin envelope management, 172, **174**
- SPAIR mastopexy, **89**, 102, 116–126, 161
 measurements for, 120
 patient marking, **109**, 117, **119–120**,
 120–121, **126**, **127**, **127–128**
 preoperative appearance, **126**, **127**
 postoperative appearance, **126**, **127–128**
- Stab incision, 156, **202**, **203**
- Stacking, of implants, 29
- Staging, 134, **135–136**, **137**
- Subareolar breast bud, **197**, **203**
- Subfascial plane, pocket, 49–50, **50**
- Subglandular augmentation *see under*
 Inframammary fold (IMF),
 augmentation
- Subglandular plane, 43, 48–49, **49**, 185, **192**
- Subglandular pocket, 67, **67**, 108, 116
 partial, 74
 tuberous breast, **184**
- Submuscular pocket plane, complete,
 44–45, **44**, **45**
- Subpectoral augmentation, inframammary
 fold, 72–75, **74**
 ‘dual plane’ technique, 74–75
- Subpectoral plane, 43
 partial pocket, 45–46, **45**, **46**, **47**, **48**, **48**
- Subpectoral pocket, partial, 77
- Superior flap tissues, 122–123, **172**
- Support garment, 126, 128
- Surface texturing, 38
 implant, 29–34, **30**, **31**, 42, 43, 75
- Surgical history, 148
- Sutures, 69, 128
 absorbable monofilament, 91, 93, **95**, 123,
 144, 180
 accordion type, 160
 horizontal mattress technique, **101**
 internal techniques, 154
 flaps fixation, 105–112
 knots, 92–93
 materials, 91–92, **92**
 monofilament material, permanent, 91
 non-absorbable monofilament, **92**, 105
 parenchyma fixation, 102–105, **106**, **107**
 periareolar lift placement, 92–93, **93**,
94–95
 periareolar mastopexy techniques, **101**
 placement technique, 91
 plication of, **106**, **108**
 shaping, 113
see also Interlocking Gore-Tex sutures;
 Purse string sutures
- Swelling, differential elasticity, 98
- T**
- Tailor stapling technique, **165**, 204
 Tailor tacking, **90**, **124**, **140**, 171, 173, **174**
- Textured implants, 42, 43
 insertion of, 75
see also under Anatomically shaped
 implants
- Tissue
 bunching, 93, 204
 crowding effect, 92
 expanders *see* Expanders, tissue
 expansion, 75
 layers, 74
 resected specimen removal, 154, 171
 stretching, 85
 swelling, **119**
see also Soft tissue
- TRAM flap reconstruction, **114**, **193**
- Transaxillary augmentation, 76–77
 incision, 43, **43**
 subpectoral, **129**
 tuberous deformity, **189**
- Transumbilical breast augmentation
 (TUBA), 43–44
- Tuberous breast, 49, 183–193
 clinical applications, 187–193
 clinical presentation, 183–184, **183**, **184**,
185
 gynecomastia, 195, **196**
 preoperative appearance, **86**, **183**, **185**,
187–190, **192**, **193**
 postoperative appearance, 187, 188, **189**,
190, **191**, **192**, **193**
 round gel implants, 75, **189**, **190**, **191**,
192
 surgical strategies, 184–187
- Tumor, benign, **109–110**
- Tunneling technique, **203**
- U**
- Ulcerative colitis, 148, **148**
- Ultrasound assisted liposuction (UAL), 155,
 156, 200
- Upper pole tissues
 bulging, **46**, **61**
 concave, 102, 104, 116, 126
 contour, 151, **152**, **158**, **165**
 deformity, 36, **36**, **37**, **110**
 control, implants, 38
 fullness, 45, **134**, **152**
 hollowing out, 159
 reshaping, 105
 shape, 55
- V**
- Variability, evaluation, 39, **39**
- Variables, implant selection, 62–63, **62**
- Venous drainage, 3
- Vertical breast reduction, 150, 159–163
 parenchyma, 159–160, **160**
 patient marking, 161–163, **161–162**
 pedicle, 159
 preoperative appearance, **161**, **166**
 postoperative appearance, **166**
 shape, 161
 surgical strategy, 159
 surgical technique, 163, **164–165**, **166**
- Vertical mattress
 bite, 100
 suture, **101**
- Vertical plication, **103**, **106**, 133, 142, **143**,
 144
 SPAIR mastopexy, 123–125, **123–124**
- Vertical scars, 102, **104**, **132**, 133, 142, **176**,
 207
- Vertical technique, 87, **101**, **109**
- Vitamin E-based scar cream, 163
- Volume
 breast/implant, 55, **55**
 as primary variable, 62, **62**, 63, **64**
- Volume ptosis, 83, **84**, 85, **85**, **115**, **119**
- Volume reduction, 198–200
 combination approach, 200–201, **201**,
202–203
 direct excision, 198–199, **199**
 liposuction, 200, **200**
see also Reduction, breast
- W**
- Weight
 body mass index (BMI), 198
 breast, 147, **147**, **152**
 gain, 128, 150, **204**
 implant, 5
 loss, 83, **84**, **127**, **137**, **150**, 198, **206**
 patient, 51, 151, **178**
 resected specimen, 154, 171
- Weight lifting activities, 157
- Wise pattern inverted T approach, 102, 103,
105
 augmentation mastopexy, 144
 inferior pedicle breast reduction, **137**,
 154, 159, 175–181, **180**, 188
 measurements for, **178**
 patient marking, 178, **178**, **179**, **180**
 preoperative appearance, **137**, **179**,
180, **181**
 postoperative appearance, **137**, **181**
 surgical strategy, 175, 178
 surgical technique, 178, **179**, 180–181,
180, **181**
 mastopexy, 102, **104**, **105**, **181**
 skin envelope retailoring procedure, **206**
 skin pattern, 110
 surgical options, **113**
- Wound
 contracture, 100
 dehiscence, 92
- Wrinkling, 93, 100
 anatomically shaped implants, 25, **28**,
 29, 37
 round implants, 25–26, 34–35
 saline, 23, 25, 29, **29**
 silicone gel, **24**, 25–26, 29
- Wuringer, E., 4